

NEW ERA EDITION

**MEDICAL REPORTING**  
**IN PITMAN'S SHORTHAND**

BY  
**HENRY DICKINSON**



**LIBRARY**  
**THE PACKARD SCHOOL**  
**253 Lexington Avenue**  
**NEW YORK CITY.**



653

D


U - dict. - Pit.

t.

LIBRARY  
THE PACKARD SCHOOL

253 Lexington Avenue

NEW YORK CITY





# MEDICAL REPORTING IN PITMAN'S SHORTHAND

WITH AN INTRODUCTION AND  
LISTS OF PHRASEOGRAMS,  
OUTLINES AND ABBREVIATIONS

BY

HENRY DICKINSON,

(SILVER AND BRONZE PITMAN MEDALLIST)

OFFICIAL SHORTHAND-WRITER TO THE ROYAL SOCIETY OF MEDICINE ;  
THE ROYAL MEDICO-PSYCHOLOGICAL ASSOCIATION ; THE ROYAL  
SOCIETY OF TROPICAL MEDICINE AND HYGIENE ; THE MEDICAL  
SOCIETY OF LONDON ; THE OPHTHALMOLOGICAL SOCIETY OF THE  
UNITED KINGDOM ; THE ROYAL INSTITUTE OF BRITISH ARCHITECTS,  
AND OTHER BODIES. REPORTER TO "THE LANCET"

*NEW ERA EDITION*

(REVISED AND SLIGHTLY ENLARGED)

*Isaac Pitman*

LONDON  
SIR ISAAC PITMAN & SONS, LTD.

## PUBLISHERS' NOTE

---

THE reader will doubtless observe that there are in the following pages certain words derived from the Greek, in which the author has followed the pronunciation usually adopted in the medical profession, rather than the pronunciation given to such words by non-medical speakers.

For example, the hard sound of *k* is given to the letter *c* in words like *cephalic*.

The author has also preferred, in some instances, outlines not in entire agreement with standard forms.

SIR ISAAC PITMAN & SONS, LTD.  
PARKER STREET, KINGSWAY, LONDON, W.C.2  
THE PITMAN PRESS, BATH  
THE RIALTO, COLLINS STREET, MELBOURNE  
2 WEST 45TH STREET, NEW YORK  
SIR ISAAC PITMAN & SONS (CANADA), LTD.  
70 BOND STREET, TORONTO

PRINTED IN GREAT BRITAIN  
AT THE PITMAN PRESS BATH



## MEDICINE

THE Medical is one of the quartette of professions—Engineering, the Law, the Church, Medicine—to which the term “great” is frequently applied. Engineering, the science of construction, is concerned with removing Nature’s barriers against inter-communication between peoples, the mutual transfer of their products, and with providing for all an ever-widening congeniality of environment. There is, perhaps, no more concise definition than that adopted by civil engineers: the utilization of the forces of Nature for the service of man. The function of the Legal profession is, broadly, the safeguarding and maintaining of those great traditions of honest dealing between men upon which the superstructure of harmonious professional and commercial intercourse has been reared. While ministers of religion apply themselves specially to man’s spiritual needs and, when life is nearing its earthly close, impart consolation and point to the larger hope, the doctor’s daily warfare against disease and premature dissolution has, as its frequent sequel, the giving back, in measure more or less full, of life itself. It is the increasing success of this last-named supreme function which is responsible for the application to this profession of the adjective “noble”; and it goes far to explain the wonderfully confident dexterity of the surgeon during his performance of a difficult and delicate operation, in full consciousness that a momentary relaxation of his concentration, at any of the stages of his adventure among the tissues, may cost the patient his life.

In order that advances may be made in any science, a careful system of record of fact and experience among a large number of its devotees is essential, for it is only by the tabulation and comparison of these observations, in varied circumstances, that trustworthy generalizations can be arrived at. Hence the scope for the employment in this profession of the great time-saver, shorthand, will at once be evident.

The objective of many who will consult this little work will probably be to become a shorthand clerk or a secretary to a busy medical man. Others will desire to become proficient in taking

Baccant - Jan. 24 '39

verbatim notes of lectures, demonstrations, and discussions ; and it is hoped that guidance for both will be found in the following pages. It is, of course, presumed that the aspirant has thoroughly familiarized himself with the excellent advanced textbooks on the system, for nothing can compensate for the lack of this mastery.

The late Thomas Allen Reed—an authority whose name will always be associated with Phonography—says, in one of his books, that technical reporting is one of the most difficult departments of shorthand writing ; and those who have had a varied experience in professional note-taking will not be disposed seriously to question the statement. This difficulty is especially pronounced when the speaker's audience consists of brother experts, for technicalities are then their familiar medium of expression. The terminology is more trying to the note-taker under these conditions than at inquests, or when medical cases are discussed in course of law, for in those circumstances the language employed must be simple enough to be "understood of the people" (personified by the jury) and (dare one add?) understood by counsel also.

Minute accuracy in research and investigation naturally needs, as its vehicle, an equal precision of language, and when communications are clothed in the accepted technical phraseology it ensures the apprehension, by the trained listener, of the exact meaning of the speaker. It must be the proud care of the shorthand writer to see that in the process of transition from the lips to the printed page the exact shade of meaning is preserved. It may be stated, in a broad way, that specialism connotes meticulous attention to detail. In the domain of bacteriology, for example, it is not sufficient for the discoverer of a causal microbe to tell his audience what the organism looks like ; he will proceed to describe the methods of its isolation, his means of studying its life-history, the staining reactions employed, and its behaviour under the various reagents to which it has been exposed in the laboratory. To convey all this in untechnical language would be almost an impossibility. What a wealth of information, for example, is conveyed in the brief announcement : "Widal and von Pirquet negative ; positive agglutination to paratyphoid *b.*" To the doctor this means that the tests for typhoid fever and tuberculosis proved negative, but that patience was rewarded by the discovery that the disease in question is one which was not



even suspected a short time ago, namely, one of the varieties of paratyphoid fever. Similarly, when a doctor reads out, in a discussion, a list and the relative numbers of various kinds of cells found in the blood examination, it enables the clinician hearing it for the first time to balance the diagnostic probabilities during such rapid review ; indeed, the writer's admiration has often been aroused by the rapidity and accuracy with which the recital of such figures has resulted in a firm grasp of the condition of affairs by the listener, as shown by the argument subsequently advanced. Again, such a term as paramyoclonus multiplex, or pseudo-hypertrophic muscular paralysis, conjures up in the mind of the expert a complete picture of the disease which bears the name.

It will be evident to the note-taker that when such highly technical language is employed there is a peculiar need for the record to be strictly verbatim, since any word missed is not only a step towards an inaccurate transcript should an attempt be made to "make it read" (for leaving blanks is abhorrent to every conscientious reporter) but the continual consciousness of such failure is likely to unsettle him during the whole of the remainder of the "take," a dispersion of energy which he really cannot afford. And it must be realized that the speed of scientific discussions is often quite high, even when judged by the fallacious criterion of the number of words (instead of syllables) uttered per minute. The reason for this is not far to seek. The type of speaker most frequently heard at medical debates is the lecturer-consultant, functions which generally follow a brilliant studentship, with, in many cases, a diploma in Arts as well as in Science ; and his readiness of expression as a lecturer, with the wealth of special knowledge which a consultant necessarily possesses, impart a peculiar capacity to make the utmost of the ten minutes usually allowed to each speaker. The Great War furnished some good examples of this, such as on those occasions when Army Medical Officers from various base hospitals have met to exchange experiences and formulate the best lines of treatment for the most prevalent campaign diseases. And this, of course, is only typical of the mutual exchange of knowledge which is constantly going forward in other professions, based as it is on the principle of all endeavouring to contribute to, as all hope to draw from, the common stock of accumulated knowledge and experience.

## A FEW WORDS TO ASPIRANTS

To those whose aim is to become an amanuensis or a secretary to a consultant, one would say it is impossible too early or too emphatically to impress the need for personal trustworthiness and reliability. The standard of ethics in the profession (and the etiquette which is but its expression) is of the highest, and is based upon the tenderest regard for the feelings of the sufferer. Hence, there must be a rigorous suppression of any tendency to make the work the subject of conversations. The more completely the secretary allows himself to be impressed with the sacredness of his trust, the better for all concerned, seeing that much of his work will involve the recording of intimate family and personal information. This advice may be presented in tabloid form by saying: Work and remember, but don't talk, even "in confidence."

It is desirable, in the interests of accuracy, that the medical shorthand clerk shall have some knowledge of anatomy, of the main mechanisms of the body, and a familiarity with the names of most of the drugs commonly used in prescriptions. These will not only form a useful foundation for his technical vocabulary, but will give him an intelligent grasp of the reasons which underlie much of the material he will be called upon to deal with in his work. Certainly he will, when so equipped, be in a position to avoid many pitfalls which otherwise would be almost inevitable.

A very important use of shorthand in medicine consists in the recording of lectures and discussions, and it was chiefly that function which the author had in mind when writing this little book. To satisfactorily perform this work, knowledge of the kind already referred to cannot be too extensive. And the note-taker will need to keep himself mentally alert, for a proportion of speakers in most discussions talk in quite a low voice. Moreover, there is a tendency on the part of some speakers to rapidly slur words over, giving them only a portion of their due expression, so that, though there is little risk of the expert listener missing any points, it becomes a matter of difficulty for the shorthand writer to catch every word. The writer well remembers, early in his career, hearing, in reply to a criticism, what sounded like "Notebee." One speaker, in the discussion on a case, had suggested the possibility of the disease being tubercle; and then it dawned



on the writer that the meaning of the strange ejaculation was that search had been made for Tubercle bacilli (spoken of colloquially as "T.B.") but none had been found. Probably everyone else in the room knew instantly what the speaker meant, but on this occasion the recognition was a slower process on the part of the scribe.

The desirability of using good materials scarcely needs to be urged; it is so self-evident. It is well to avoid very highly-glazed paper, for it is good to feel some suggestion of resistance to the gliding of the pen over the surface, and it appears to cause no hindrance to speed. A reliable fountain pen is of the first importance, and such is easy to procure; yet a surprising number of people still use the pencil for taking a note, notwithstanding the greater legibility of the ink note, and the trivial alternations of pressure needed to impart the required differences in thickness. Given a sufficiently resilient pen, the economy of muscle and nerve force which it secures is quite appreciable, especially towards the end of a long sitting, even supposing the pencil-writer to be equipped with a sufficient armoury of well-prepared pencils. The small so-called "intrinsic" muscles of the hand which are concerned in writing, with their controlling nerves, are very delicate and highly specialized (finding, perhaps, their highest function in the expert pianist), and due appreciation of this fact must result in a realization of what their integrity means to the busy note-taker. The slightly greater pressure needed for a pencil will, after many thousands of impressions at a sitting, make a demonstrable difference in the degree of fatigue. Moreover, the sharpening of a pencil must occasionally be needed at awkward times, and there are occasions when the procedure constitutes a definite nuisance to others.

Unfortunately, the facilities afforded by societies to the shorthand writer whom they desire to render a verbatim account, are not invariably what they should be. There are times when all the available table accommodation is utilized for microscopes or specimens, and though part of the programme may consist of an epidiascopic or lantern demonstration, the note-taker may be told that no light can be permitted him, as it would mar the success of the demonstration. Sometimes, therefore, he has to manage with only such reflected glimmer as the illumined screen affords. Hence, it is not at all a bad plan occasionally to practise

taking a note in semi-darkness, as a precaution against being "left" when there has been such a lamentable lack of due provision for his work. In such cases he should not try to get more than about half-a-dozen lines of notes to each page, and should use his left thumb as a guide for line spacing. There should be no attempt to vocalize in such circumstances; any effort of the kind is apt to prove more ludicrous than helpful.

Medicine is eminently a progressive science, hence its terminology must necessarily be constantly receiving additions, a fact which demands continual care and watchfulness on the part of those who are closely associated with the profession. This continual cropping up of new words renders necessary the capacity to insert instantly the crucial or distinguishing vowel when writing unfamiliar terms. If, as some contend, the Advanced Stage of Phonography is that in which vowels are dispensed with, then assuredly that is not the style for technical reporting; the clamant need for accuracy is too great, and this fact will lead the scribe to err on the side of simplicity of style, from which he will gradually feel his way towards a briefer record. It is not easy to conceive of an accurate note of a really technical discussion without fairly free vocalization; and the feeling of security this gives will be well worth the extra effort.












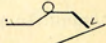

































There is no need to enter into the reasons for the few departures from strict textbook orthodoxy which this book contains; but those who follow the suggestions herein set forth may rest assured that the outlines presented have passed through the ordeal of practical experience, and, therefore, may be regarded as safe.























































The examples of medical matter set out after the list of outlines, being actual transcripts, may prove useful as exemplifying the kind of work to be expected in the various special departments which together constitute "the profession." These may usefully serve as dictation exercises, each example being taken down several times.

Advantage has been taken of the revision of this book to add 80 new words and phrases which have become current in the profession since the last printing.










































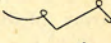





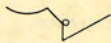












































## MEDICAL WORDS AND PHRASES

A		
abarticulation		absinthism 
abdomen		absolute ether 
abdominal		absorbent cotton 
abdominal aorta		acanthosis nigricans 
abdominal enlargement		acarus 
abdominal gestation		acarus scabiei 
abdominal inspiration		accelerator 
abdominal reflex		accessory nerve 
abdominal respiration		accrementation 
abdominal ring		acephalous 
abdominal tumour		acetabulum 
abdominal viscera		acetate of soda 
abdominal wall		acetic acid 
abducens muscles		acerbity 
abductor brevis		acetonaemia 
abductors		acholia 
aberration		achondroplasia 
abortion		achorion schoenleinii 
abrasion		achromatic lens 
abscess cavity		achromatopsy 
abscess of the brain		acidification 
abscission		acidulate 
		acne agminata 

acne varioliformé		adrenal gland	
acne vulgaris		adrenalin	
aconitine		adventitia	
aerodynia		aegophony	
acromegaly		aerobic bacilli	
acromial		afferent nerves	
acromio-clavicular		after-birth	
acromion		after-pains	
actinomycosis		agar-agar	
acuminate papules		agglutination	
acute fever		agglutinin	
Addison's disease		agminate glands	
adductor longus		agoraphobia	
adductor policis		agrammatism	
adenitis		agraphia	
adeno-carcinoma		air-hunger	
adenoid		albinism	
adenoid gland		albuminuria	
adenoma		albuminuric retinitis	
adenoma sebaceum		albugosuria	
adeno-myoma		aldehyde	
adhesive plaster		alienation	
adipose tissue		alimentary canal	
adiposis dolorosa		alimentary tract	
adjuvant		alimentation	
adolescent period		allantois	
adrenal capsule		alopecia areata	



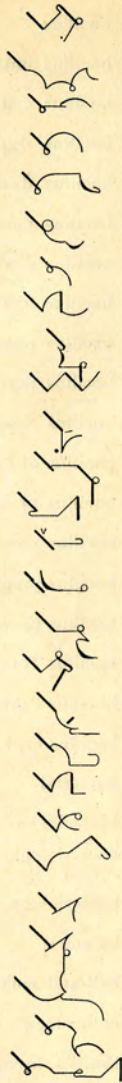Altmann's granules		anaesthesia	
alveolar abscess		anaesthetic area	
alveolar process		analgesic	
alveolus		analogue	
amaurosis		anasarca	
amaurotic		anaspadias	
amblyopia		anastomotic circulation	
amblyopic vision		anchoyloblepharon	
amenorrhoea		anchylosis	
ametropic vision		anchylostomiasis	
amino acids		aneurysm of the arch of the aorta	
ammonia sulphate		aneurysmal dilatation	
ammonium carbonate		angina pectoris	
amnesic defect		angio-sarcoma	
amniotic bands		ankle clonus	
amniotic fluid		anodyne	
amorphous quinine		Anopheles	
ampèremeter		anorexia	
amphoric breathing		anosmia	
amphoric resonance		antenatal	
amputation flap		anterior poliomyelitis	
amylaceous disease		anterior superior spine	
amyloid degeneration		anterior uveitis	
amytonia congenita		antero-lateral column	
amyotrophic		antero-posterior	
amyotrophic muscular atrophy		anteversion	
anaemic murmur		Anthrax bacillus	

antiperistaltic		arthritis deformans	
antipyretic		arthropathic wasting	
antipyrin		arthropathy	
antiseptic		arthroplasty	
antispasmodic		articular cartilage	
antistaphylococcic serum		articular nerve	
antistreptococcic serum		artificial	
antitoxin		aryepiglottic fold	
aortic arch		aryteno-epiglottideus	
aortic regurgitation		arytenoid cartilage	
aortic stenosis		arytenoideus	
apex beat		ascending paralysis	
apex murmur		ascitic fluid	
aponeurosis		aspergillosis	
aponeurotic		asphyxial	
apoplectic		asphyxiate	
apoplectic seizure		aspiration	
apoplectiform		aspiration needle	
appendecostomy		asthenic symptoms	
appendectomy		asthenopia	
appendix vermiformis		asthmatic	
Army Medical Department		astigmatic	
arteriole		astigmatism	
arterio-venous aneurysm		astigmometer	
arteritis		astragalus	
arthrectomy		asymmetry	
arthritis		atavism	




atheroma		bacillus	
atheromatous degeneration		bacillus anthracis	
athetoid movements		bacillus coli communis	
athyroidism		bacillus diphtheriae	
atoxyl treatment		bacillus dysenteriae	
atresia ani		bacillus enteritidis	
atropine		bacillus geniculatus	
attolens aurem		bacillus lepre	
atrahens aurem		bacillus mesentericus	
auditory meatus		bacillus mycoides	
auditory nerve		bacillus Neapolitanus	
auricular flutter		bacillus of flavus	
auricular nerve		bacillus of malaria	
auriculo-ventricular rings		bacillus paratyphosis B	
auscultation		bacillus prodigiosus	
autogenous vaccine		bacillus pyocyane	
auto-inoculation		bacillus Tetanus	
autolysis		bacillus tuberculosis	
auto-toxoemia		bacillus typhosus	
axillary glands		bacterial	
axillary vein		bactericide	
axis cylinder		bacteriological examination	
axolemma		bacteriology	
Azygos vein		balanitis	
<b>B</b>		ball-and-socket joint	
bacillary invasion		balneology	
bacilluria		Banti's disease	

barber's itch  
 barium sulphate  
 basic murmur  
 basilar  
 basilic vein  
 basisphenoid  
 bed-sore  
 belladonna  
 benzoic acid  
 beriberi  
 betol  
 bicarbonate of soda  
 bichloride  
 biconcave  
 biconvex  
 bicuspid valve  
 Bier's bandage  
 bi-focal  
 bifurcation  
 bile-duct  
 bilious fever  
 bilirubin  
 binaural  
 binaural stethoscope  
 binocular  
 bismuth meal  
 bismuth oxychloride


















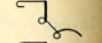



























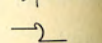










blastoderm  
 blennorrhagia  
 blepharitis  
 blepharospasm  
 blood-agar  
 blood clot  
 blood count  
 blood examination  
 bloodless operation  
 blood letting  
 blood stained  
 blood stasis  
 blood stream  
 blood vessels  
 bone marrow  
 bone tumour  
 boracic acid  
 borax  
 borborygmi  
 bougie  
 bouillon  
 brachialis anticus  
 brachycephalic  
 brachial glands  
 brachial plexus  
 brachial veins  
 bradycardia















































































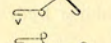

































brain disease		buccal mucous membrane	
brain tumour		buccal nerve	
breast cancer		buccinator	
breath sounds		bulb of urethra	
breathlessness		bulbar paralysis	
breech presentation		bulbous nerve	
Bright's disease		bullous eruption	
British Pharmacopoeia		buphthalmos	
broad ligament		bursitis	
broad ligament cyst		butyric acid	
bromide eruption			
bromide of iron		<b>C</b>	
bronchial breathing		cachectic	
bronchial mucosa		cachexia	
bronchial tubes		cadaver	
bronchiectatic		Caesarean myomectomy	
bronchioles		Caesarean section	
bronchitis		caffein	
bronchocele		caisson disease	
bronchophony		calcaneo-scaploid	
bronchopneumonia		calcaneum	
bronchorrhoea		calcareous	
Brownian movement		calcareous degeneration	
bruit		calcify	
Brüning's light		calcination	
bubonic plague		calcium chloride	
bubonocele		calcium lactate	
		calcium salts	

calculus		carbonaceous monoxide	
calculus pyonephrosis		carbonate of soda	
calices of the kidneys		carbon dioxide	
callus		carcinoma	
Calmette's reaction		cardiac murmur	
calomel		cardiac nerves	
camphorated		cardiograph	
camphorated chalk		cardio-inhibitory	
canaliculi		cardio-spasm	
canaliculus		cardio-vascular	
canalization		caries of the spine	
cancellous bone		Carlsbad waters	
cancer cell		carminative	
cancer of breast		carotid artery	
cancerous cachexia		caruncle	
cancerum oris		caseate	
cannabis indica		caseation	
cannula		casein	
cantharides		catalepsy	
capillary circulation		cataleptic	
capillary vessels		catamenia	
capsicum fruit		cataract extraction	
capsular ligament		catarrhal	
capsulotomy		cathartic	
carbol-fuchsin		catheter	
carbolic acid		catheterism	
carbonaceous material		cauda equina	


















































caudal vertebrae		cervico-facial	
cauterization		chalybeate waters	
cavernous breathing		chancre	
cavernous sinus		chancroid	
celloidin		Charcot's disease	
cellular tissue		Chaulmoogra	
cellulitis		chemosis	
centigrade		Cheyne-Stokes respiration	
cephalic plate		chiasma	
cephalotribe		chickenpox	
cerebellar tumour		chloral	
cerebellum		chloral hydrate	
cerebral		chloroform	
cerebral hemispheres		chloroform anaesthesia	
cerebral tumour		chloroform poisoning	
cerebritis		chloroform water	
cerebro-spinal fluid		chlorosis	
cerebro-spinal meningitis		cholagogue	
cerebrum		cholangitis	
cervical cord		cholecystectomy	
cervical enlargement		cholecystitis	
cervical glands		cholecystotomy	
cervical muscles		cholelithiasis	
cervical nerves		cholera vibrio	
cervical spine		chondro-arthritis	
cervical sympathetic		chondro-dystrophia faetalis	
cervical vertebrae		chondroma	























































chondro-sarcoma		climacteric period	
chorda tympani		clinical	
choreiform		clinoid process	
choroid plexus		clonus	
choroidal degeneration		club-foot	
choroidal vein		coagulability	
choroiditis		coagulation period	
choroido-retinal degeneration		coagulum	
choroido-retinitis		cobra-venom	
chromatic scale		coecydynia	
chromatolysis		coecygeal	
chrysarobin		coecyx	
chrysophanic acid		cochlea	
cicatricial tissue		cod liver oil	
cicatrix		cod liver oil and malt	
cinchona bark		coeliotomy	
circulatory system		colchicum	
circumflex nerve		colectomy	
circumvallate papillae		collargol injection	
cirrhosis		collateral circulation	
cirrhosis of the liver		College of Physicians	
cirrhosis of the spleen		College of Surgeons	
citrate of magnesia		collodion	
clarification		collodium	
claustrophobia		colomboma iris	
cleft palate		colon bacillus	
cleido-cranio-dysostosis		colostomy	




colotomy		convulsion	
colour-blindness		convulsive seizure	
colpotomy		co-ordination	
comedones		copper sulphate	
Comma bacillus		coraco-brachialis	
comminuted fracture		coracoid process	
commissural fibres		corium	
communicating nerve		cornea	
complement-fixation		corneitis	
compressor		corona ciliaris	
concussion of the brain		coronal suture	
condyloma		corpora albicantia	
congenital disease		corpora cavernosa	
congestion		corpora quadrigemina	
conjunctival tissue		corpora striata	
conjunctivitis		corpus callosum	
connective tissue		corpus luteum	
consanguinity		corrosive sublimate	
constrictor muscles		corrugator supercillii	
constrictor urethrae		cortical layer	
contractile tissue		cortical substance	
contractility		coryza	
contraindicate		cosmetic operation	
contralateral nystagmus		costal cartilage	
contrectation		counter-irritant	
convalescent institution		counter-irritation	
convolution		cover-glass	

coxalgia		cutaneous nerves	
coxa vara		cysticercus	
cranial bones		cystitis	
cranial tumour		cystocele	
cranio-tabes		cystoma	
craniotomy		cystoscopy	
creatin		cytology	
creatinin		cytolysis	
creosote		cytoplasm	
crepitant râle			
crepitation		<b>D</b>	
cretinism		dacryocystitis	
cretinoid		dacryocystotomy	
cribriform plate		dandruff	
crico-arytenoid joint		Darier's disease	
crico-thyroid		deaf-mutism	
Crile's tubes		debilitating	
Crooke's tubes		decidual cast	
croton oil		deciduoma malignum	
crucial ligament		deciduous teeth	
crucial temperature		decinormal	
crural nerve		decussate	
cryptogamic disease		defaecation	
cryptorchid		defibrinated	
cubitus varus		Deiter's nucleus	
curettage		delirium tremens	
cutaneous affection		deltoid	
		dementia paranoïdes	



dementia proecox		diastolic murmur	
dendron		diastolic thrill	
denture		diathermy	
deodorant		diathesis	
depressor		dicrotic pulse	
dermatitis artefacta		dielectric	
dermatitis herpetiformis		dietetic	
dermatitis repens		differential count	
dermoid cyst		differential diagnosis	
Descemet's membrane		digastric muscle	
desquamation		digastric nerve	
desquamative		digestive	
desquamative dermatitis		digital examination	
diabetes mellitus		digitalis	
diabetic coma		digitalin	
diagnostic sign		dilatation murmurs	
dialysation		dilator muscle	
dialysis		dioptr	
diaphoresis		diphtheria	
diaphoretic		diphtheritic paralysis	
diaphragm		diphtheritic throat	
diaphragmatic		diphtheritic toxin	
diaphysis		diphtheroid bacilli	
diastase		diplegia	
diastole		diplococcus rheumaticus	
diastolic bruit		disarticulation	
diastolic impulse		disease-carriers	

disease contacts  
 disinfection  
 disinfection of the skin  
 dislocation of the hip  
 diverticulum  
 dorsal vertebrae  
 dorsiflexion  
 dorsum ilii  
 drainage tube  
 Duchenne's paralysis  
 ductus arteriosus  
 duodenal  
 duodenostomy  
 duodenum  
 dura mater  
 dynamometer  
 dysaesthesia  
 dyscrasia  
 dysenteric  
 dysentery  
 dyspepsia  
 dysphagia  
 dysphasia  
 dyspituitarism  
 dyspnoea  
 dysthyroidism  
 dystrophia adiposo-  
 genitalis

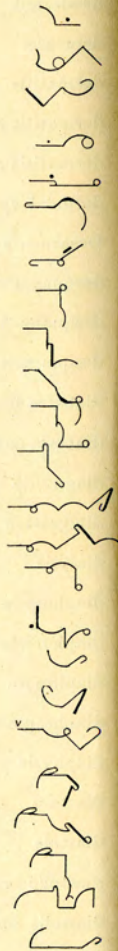


dystrophy  
 dysuria




## E

ear-ache  
 Easton's syrup  
 eburnation  
 ecchymosis  
 echinococcus  
 eclampsia  
 écraseur  
 ecstasy  
 ectoderm  
 ectopia vesicae  
 ectothrix  
 ectropion  
 eczema marginatum  
 eczema rubrum  
 eczematous  
 edentulous  
 efferent  
 effleurage  
 Eichen's operation  
 elastic bandage  
 elastic fibres  
 elastic tissue  
 electric contractility  
 electric current

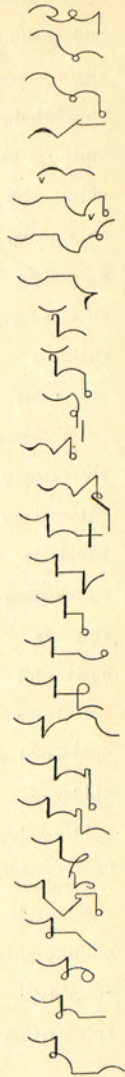




electric reaction  
 electric sensibility  
 electric stimulation  
 electrode  
 electrolysis  
 electrolytic  
 electro-massage  
 electrometer  
 electromotive  
 electroscope  
 electrotonus  
 elephantiasis  
 eliminate  
 elixir  
 emaciation  
 emasculation  
 embolic  
 embolism  
 embrocation  
 embryology  
 embryonic  
 emesis  
 emetic  
 emetine  
 emmenagogue  
 emmetropia  
 emollient























































emotional insanity  
 emphysema  
 emphysematous  
 empirical  
 empyoema  
 encephalitis  
 encephalocele  
 encephaloid  
 enchondroma  
 enchondromatous  
 encysted tumour  
 endarteritis  
 endarteritis obliterans  
 endemic disease  
 endocardial  
 endocarditis  
 endocrinous  
 endocrinous system  
 endolymph  
 endometritis  
 endometrium  
 endonasal treatment  
 endopericarditis  
 endoscope  
 endosmosis  
 endosmotic  
 endosteal sarcoma



endothelioma		epiglottidean	
endothelium		epiglottis	
engorgement		epilepsy	
enophthalmos		epileptic	
ensiform cartilage		epileptiform	
entamoeba coli		epiphora	
entamoeba histolytica		epiphyseal	
enteralgia		epiphysis	
enteric fever		epiphysitis	
enteritis		epiplocele	
enterocele		episcleritis	
enterostomy		epispiadias	
enterotomy		epistaxis	
entomology		epithelial layer	
enucleate		epithelioma	
enucleation		epithelium	
enuresis		erector spinae	
eosinophil		eructation	
ependyma		erysipelalous inflammation	
epidermal appendages		erythema	
epidermis		erythema toxicum	
epidermolysis bullosa		erythematous eruption	
epidermophytum inguinale		erythroblast	
epididymis		erythrodermia	
epididymitis		essential paralysis	
epigastric		ethmoid sinus	
epigastrium		ethyl chloride	



eucalyptol		extensor longus	
eucalyptus		external auditory meatus	
euonymin		extrasystolia	
Eustachian bougie		extra-uterine	
Eustachian tube		extravasation	
eversion		extravasation of blood	
evisceration		extravasation of urine	
exacerbation		extroversion	
exanthemata		eyeball	
excision		eyebrow	
excoriation		eyelash	
excretory organs		eyelid	
exfoliative dermatitis		eyesight	
exocardial		eyestrain	
exophthalmic goitre			
exophthalmos		<b>F</b>	
exostosis		face muscles	
expectorant		facial nerve	
expiration		facial paralysis	
expired air		factitious urticaria	
exploratory incision		falciform ligament	
exploratory operation		falling of the womb	
extensor brevis		Fallopian tube	
extensor carpi radialis		falx cerebelli	
extensor carpi ulnaris		falx cerebri	
extensor communis		faradic current	
extensor indicis		faradic response	

faradic stimulation



faradism



farinaceous food



far-sighted



fascia dentata



fasciculus



fatal accident



fatal illness



fatty degeneration



fatty degeneration of the heart



fatty tumour



faucial tonsil



febrifuge



fecundation



Fehling's solution



femoral ring



fenestra ovalis



fermentation



ferrocyanide



fibrillary tremor



fibrinogen



fibrinoplastin



fibro-cartilaginous



fibroid degeneration



fibroid tissue



fibro-plastic



fibrosis



fibrous degeneration



fibrous tissue



filaria



filiform



filtration angle



Finsen light



first incision



first intention



first sound



fistula in ano



flaccid paralysis



flap operation



flat-foot



flexor muscle



flocculent



fluctuate



fluorescent screen



foetid atmosphere



folliculitis



folliculitis decalvans



fontanelle



foramen magnum



foramen ovale



foramen of Winslow



forensic medicine



formalin



ornication



fourchette

fovea centralis

Fowler's solution

fracture of the humerus

fracture of the fibula

fracture of the patella

fracture of the tibia

fragilitas ossium

Friedreich's disease

frontal sinus

frontal sinus disease

frontal sinus inflammation

frontal sinus operation

frontal sinusitis

fronto-ethmoidal cells

fronto-nasal cavity

frostbite

fuchsine

functional disease

functional paralysis

fundus oculi

fungating tumour

funiculus

furfuraceous

furunculosis

fusiform

fusion-point



## G

Gaertner ducts

galactagogue

galactocele

gall bladder

gall stones

gall stone colic

galvanic battery

galvanic current

galvanic stimulation

galvanic testing

galvano-cautery

galvanometer

ganglionic cells

gangrene

gastralgia

gastric follicles

gastric juice

gastric nerve

gastric ulcer

gastritis

gastrocnemius

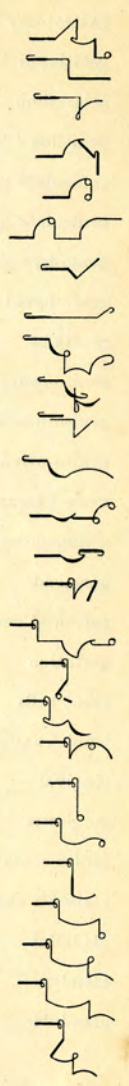
gastrodynia

gastro-enteritis

gastro-enterostomy

gastro-enterotomy

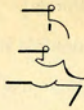gastro-jejunostomy






gastrostomy		glaucoma	
gastrotomy		glenoid fossa	
gelatinous tissue		gliomatosis	
gelsemium		gliomatous	
gemellus		globulin	
geniculate bodies		globus hystericus	
geniculate ganglion		glomerulo-nephritis	
genio-hyo-glossus		glomerulus	
genio-hyoid		glossalgia	
genitalia		glossitis	
genito-crural nerve		glosso-pharyngeal nerve	
genito-mesenteric		gluteus maximus	
genito-urinary		gluteus medius	
genu valgum		gluteus minimus	
genupectoral		glycogen	
germicide		glycosuria	
germinal vesicle		gonococcal	
gestation		gonococcus	
giant cells		gonorrhoeal	
Gimbernat's ligament		graafian follicles	
gingival		gracilis	
gingivitis		granulation	
girdle sensation		granulation tissue	
glabrous skin		granuloma fungoides	
gladiolus		Graves' disease	
glanders		gravidarium	
glandular		gray substance	

gustatory aura  
gustatory nerve  
gynaecology




## H

habit spasm  
habitat  
habituate  
haemacytometer  
haemadynamometer  
haematemesis  
haematin  
haematuria  
haematocele  
haematogenous  
haematolysis  
haematoma  
haematoxylin  
haemoglobin  
haemoglobinometer  
haemoglobinuria  
haemophilia  
haemoptysis  
haemorrhage  
haemorrhoids  
haemostatic  
haemothorax







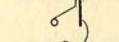



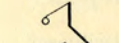















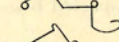







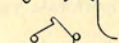

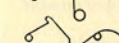





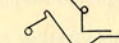

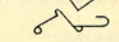

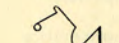

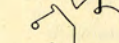

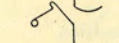




















































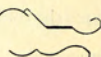


hair follicle  
hallucination  
hamamelis  
hamstrings  
hare-lip  
haversian canal  
hay fever  
healing process  
heart beat  
heart-block  
heart-burn  
heart disease  
heart impulse  
heart murmur  
heart sounds  
heart's action  
heart's apex beat  
hebephrenia  
Heberden's nodes  
hebetude  
hemagogue  
hemeralopia  
hemiancoesthesia  
hemiancoesthetic  
hemianopsia  
hemiatrophy  
hemichorea



hemierania		histology	
hemiopia		Hodgkin's disease	
hemiplegia		Holmgren's test	
hemispasm		homatropine	
hemostatic		homicidal mania	
hepatic cells		homolateral	
hepatic duct		homologous	
hepatic vein		homonymous	
hepatitis		hormones	
hepatization		hospitalism	
hepato-cystic duct		house physician	
hepatorrhaphy		house surgeon	
hepatotomy		housemaid's knee	
hereditary		Hunter's canal	
heredity		hydatid	
hermaphrodite		hydatid cyst	
hernial sac		hydraemia	
hernial swelling		hydramnios	
herniotomy		hydrastis	
herpes gestationis		hydrated	
herpes Zoster		hydrocele	
herpetiform		hydrocephalis	
heterophoria		hydrochloric acid	
hip-joint disease		hydrocyanic acid	
hippocampus		hydronephrosis	
hippus		hydropathic	
Hirschsprung's disease		hydrophobia	











































hydrophthalmos		hypertrophic	
hydropneumothorax		hypertrophy	
hydrosalpinx		hypnosis	
hydrotherapy		hypnotism	
hyoglossus		hypochondria	
hyoid bone		hypochondriasis	
hyoscine		hypochondrium	
hyoseyamus		hypogastric	
hyperacusis		hypoglossal	
hyperaemia		hypophosphate	
hyperaesthesia		hypophysis	
hyperblast		hypophysis cerebri	
hypercatharsis		hypopyon	
hyperextension		hypostatic	
hyperidrosis		hyposulphate	
hyperkeratosis		hyposulphite	
hypermetropia		hypothernar	
hypermyotrophy		hypothernar eminence	
hyperostosis		hypothetical	
hyperpituitarism		hysterectomy	
hyperplasia		hysteria	
hyperplastic		hystero-epilepsy	
hyperpyrexia		hystero-myoma	
hypersecretion		hystero-paralysis	
hyperthyroidism		hysteroid	
hypertonia		hysteroptosis	
hypertonic		hysterotomy	

I			
ice-cap		ilio-inguinal	
ichthyoid		ilio-inguinal nerve	
ichthyol		ilio-pectineal	
ichthyol ointment		ilio-pelvic	
ichthyosis		ilio-psoas	
ichthyosis sebacea		illegitimacy	
icteric		illegitimate child	
icteroid		imbecility	
icterus neonatorum		imbibition	
ideation		immersion objective	
ideo-motor		immunity	
idio-muscular		immunize	
idiocy		impacted bone	
idiopathic		impacted fracture	
idiosyncrasy		impaired resonance	
ileo-appendicular		imperforate anus	
ileo-caecal		imperforate vagina	
ileo-caecal fossa		impermeable	
ileo-caecal valve		impetigo	
ileum		impetigo contagiosa	
iliac crest		impetigo herpetiformis	
iliacus		implantation cyst	
ilio-femoral		impotence	
ilio-hypogastric		impregnation	
		inanimate	
		inanition	

inarticulate		infraorbital	
incised wound		infraorbital nerve	
incisor teeth		infraspinal	
incoherent speech		infrasternal	
incontinence of foeces		infundibulum	
incontinence of urine		ingesta	
inco-ordination of muscles		ingestion	
incurable disease		ingravescent	
indicanuria		inguinal canal	
indigestion		inguinal glands	
indirect vision		inguinal hernia	
indolent ulcer		inhalation	
induced current		inherited disease	
infantile		inhibition	
infantilism		inhibitory centre	
infarction		inhibitory nerves	
infectious disease		initial incision	
inflammation		initial stage of labour	
inflammatory		innervation	
inflammatory condition		innocent tumour	
inflammatory state		innominate artery	
inflation		innominate bone	
influenza		inoculation	
infraclavicular		inorganic	
infracostals		insalivation	
inframammary		insanity	
inframaxillary		insomnia	



inspiration		intestinal obstruction	
inspissated fluid		intestinal stasis	
inspissated material		intestinal tract	
inspissated pus		intracranial	
insufflation		intracranial growth	
insufflator		intracranial operation	
integument		intracranial tumour	
interarticular		intramuscular injection	
intercellular		intraocular haemorrhage	
intercostal nerves		intraocular pressure	
intercostal space		intraocular tumour	
interfascicular		intrathoracic glands	
interlobar		intrauterine	
intermeningeal		intravenous	
intermission		intraventricular	
intermittent fever		introversion	
intermittent pulse		intubation	
intermuscular		intussusception	
internal capsule		inunction of mercury	
internal ear		involuntary contraction	
interorbital		involuntary movement	
interosseous		iodide of iron	
interstitial		iodide of potassium	
interstitial keratitis		iodoform	
interstitial tissue		ionization	
intervertebral discs		ipecacuanha	
intestinal canal		ipecacuanha wine	

iridectomy



irido-cyclitis



iridochoroiditis



iridodesis



iridoplegia



iritis



irritability



ischaemia



ischio-rectal



Island of Reil



isolation hospital



isthmus of the thyroid



iter



## J

jaborandi



Jacksonian epilepsy



Jacksonian fits



Jacobson's nerve



jactitation



jaundice



jaw-jerk



jejunostomy



jejunum



jugular vein



jurisprudence



## K

karyokinetic



karyolysis



kathade



keloid scar



keratitis



keratitis punctata



keratoconus

keratosis follicularis  
spinulosa

kerion



kidney abscess



kidney disease



Killian's operation



Killian's tubes



kilogram



kinetic energy



Klebs-Loeffler bacillus



kleptomania



knee-jerk



Koch's bacillus



kyphosis



## L

labio-glossal palsy




labium major




labium minor




laboratory cultures



laboratory experiments



laboratory tests




labyrinthine deafness




labyrinthine syndrome



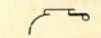
labyrinthitis




lachrymal disease



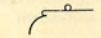
lachrymal glands




lachrymal nerve




lachrymal sac




lachrymal stenosis




lactagogue




lactation



lacteals




lactose fermentation




lacuna



lambdoid suture




lamellar cataract




lamina cribrosa





lamination




laminectomy




lancinating pain

Landouzy-Dejerine  
myopathy


Landry's paralysis




laparo-colotomy



laparo-cystotomy



lapartomy



lardaceous disease



laryngeal spasm



laryngeal stenosis



laryngeal stridor



laryngectomy



laryngismus



laryngitis



laryngology



laryngoscope



laryngotomy



larynx



lateral column



lateral sinus thrombosis



lateral tract



latissimus dorsi



laxative pill



leishmania



lens capsule



lens opacity



lenticular nucleus



leontiasis ossia



lepra bacillus



leptomeningitis



leptothrix



lethargic state

























































leucocyte cells























































leucocyte count





leucocythaemia		lipomatosis	
leucocytometer		liquid paraffin	
leucocytosis		liquor amnii	
leucodermia pernicioso		liquor arsenicalis	
leucorrhoea		liquor sanguinis	
leukaemia		lithaemia	
leukoma		lithiasis	
levator anguli scapulae		lithium waters	
levator ani		lithotomy	
levator palati		lithotrite	
levator palpebrae		lithotrixy	
lichen annulatus		lithuresis	
lichen planus		liver-dullness	
lichen planus atrophicus		lock-jaw	
lichen planus hypertrophicus		locomotor ataxy	
lichen spinulosus		longitudinal sinus	
lichenoid eruption		lordosis of the spine	
ligamentum pectinatum		lumbago	
ligation of artery		lumbar enlargement	
light-reflex		lumbar nerves	
lime-salts		lumbar region	
linea alba		lumbar vertebrae	
linea semilunaris		lumbricales	
lingual movements		lung abscess	
lingual muscle		lung disease	
lipoid bodies		lung fibrosis	
lipoma		lupus erythematosus	

lupus vulgaris		malinger	
Luschka's bursa		malleolus	
lymphadenitis		malleus	
lymphadenoma		malpighian corpuscles	
lymphæmia		mammary gland	
lymphangitis		mammary secretion	
lymphangioma		maniacal fury	
lymphatic glands		manometer	
lymphatic system		manubrium sterni	
lymphatism		marasmus	
lymphodermia perniciosa		Marchi staining	
lymphogenous		marginal convolution	
lympho-sarcoma		masculinity	
lymphoid tissue		massage	
lysis		masseter muscle	
		masseter nerve	
		masseur	
<b>M</b>		mastication	
macroductyly		mastitis	
macroglossia		mastoid bone	
macula lutea		mastoid cells	
malaria parasite		mastoid operation	
malign tumour		mastoid process	
malignancy		mastoiditis	
malignant disease		maxillary bone	
malignant glands		maxillary nerve	
malignant growth		maxillary sinus	
malignant tumour			

McBurney's incision



McBurney's point



Meckel's diverticulum



median nerve



mediastinal glands



mediastinitis



medical officer-in-charge



medico-legal



medico-political



medico-psychological



medulla oblongata



medullary



Megalosparon



megrin



meibomian glands



melancholia



melano-carcinoma



melanoderma



melanotic sarcoma



membrana propria



membrana tympani



mendelian theory



Ménière's disease



meningitis



meningocele



menopause



menorrhagia




menstrual period



menstruum




mercurial inunction




mesenteric glands



mesentery




meso-appendix




mesoblast



metabolism




metacarpal bones




metamorphosis




metastases




metastatic growth




metatarsal bone




metatarsalgia



meteorism




methylated spirit




metritis




metrorrhagia




microcephalus




micrococcus




micrococcus citreus




micrococcus deformans




micrococcus epidermidis




micrococcus erysipelatis




micrococcus gonorrhæa





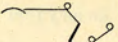





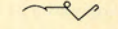













































micrococcus melitensis




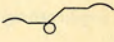








































































































micrococcus neoformans
















































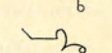

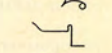

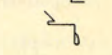






micrococcus pneumoniae		modus operandi	
micrococcus pyogenes aureus		mollities ossium	
micrometer		molluscum contagiosa	
microscopic examination		Mongoloid idiocy	
microsporon		monochromatic lens	
microsporon furfur		monococcus	
microtome		monocular vision	
micturition		monomania	
middle-ear disease		mononuclear	
midwifery		monoplegia	
migraine		morbid growth	
miliaria rubra		morbiliform eruption	
miliary tubercle		morbus cordis	
milk-teeth		moribund condition	
milliampère		morphology	
milliamperemeter		Morvan's disease	
milligrame		motor centre	
millimetre		muco-enteritis	
mind-blindness		muco-pus	
mind-deafness		mucous membrane	
miner's nystagmus		multiform eruption	
mitral constriction		multilocular	
mitral murmur		multinuclear	
mitral obstruction		multipara	
mitral regurgitation		multiple neuritis	
mitral stenosis		muscle grafting	
mitral valve		museular atrophy	

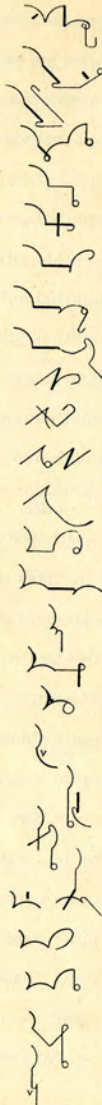muscular co-ordination		myxaedema	
muscular development		myxosarcoma	
muscular irritability		<b>N</b>	
muscular paralysis		Naevoid tumour	
muscular rigidity		naevus	
muscular sensibility		narcosis	
muscular spasm		narcotic poison	
muscular stiffness		nasal catarrh	
muscular system		nasal polypus	
muscular wasting		naso-labial	
musculo-cutaneous nerve		naso-palatine	
musculo-spiral nerve		naso-pharyngeal	
mutilating wound		nausea	
myasthenia gravis		nauseate	
mycelium		navicular bone	
mycosis fungoides		navicular fossa	
mydriasis		near-sightedness	
myelo-meningocele		nebula of the cornea	
mylo-hyoid		neerobiosis	
myocarditis		necrosis of bone	
myocardium		Nematoid worm	
myoclonus multiplex		neo-salvarsan	
myoma		neoplasm	
myopathy		nephralgia	
myopia		nephrectomy	
myositis ossificans		nephritis	
mytotic figures		nephrolith	

nephrolithotomy		nitric acid	
nephrotomy		nitrite of amyl	
nerve centre		nitrite of ethyl	
nerve deafness		nitro-glycerine	
nerve stretching		nitrogenous	
nerve suture		nitrous acid	
nervous centre		nitrous ether	
nervous mechanism		nomenclature	
nervous system		nuclear paralysis	
nettle-rash		nucleolated	
neuralgia		nucleolus	
neurasthenia		nucleoplasm	
neurectomy		nucleus ambiguus	
neurilemma		nux vomica	
neuroglia		nyctalopia	
neurological examination		nymphomania	
neuromuscular		nystagmus	
neuron		0	
neuroparalytic		obesity	
neuropathic		objective signs	
neuroretinitis		objective symptoms	
neurotic temperament		oblique incision	
night-blindness		oblique muscle	
nightmare		obstetrics	
night-terrors		obstruction of the bowels	
nipple-line		obturator	
nitrate of silver		occipital groove	




occipital lobe		opaque meals	
occipital nerve		open-air treatment	
occlusion		operative interference	
occupation neuris		ophthalmia neonatorum	
ocular nerves		ophthalmic nerve	
oculo-motor nuclei		ophthalmic surgeon	
odontitis		ophthalmitis	
odontoblast		ophthalmologist	
odontological		ophthalmology	
odontoma		ophthalmoplegia	
odontome		ophthalmoplegia externa	
oesophagostomy		ophthalmoscope	
oesophageal		ophthalmoscopic examination	
oesophageal examination		opisthotonos	
oesophageal nerve		opponens minimi	
oesophageal tumour		opponens pollicis	
oesophagismus		Opsonic index	
oesophagitis		opsonin	
olecranon		optic chiasma	
olfactory nerve		optic commissure	
omental hernia		optic disc	
omentum		optic foramen	
omo-hyoid		optic nerve	
onychchia		optic neuritis	
onychomycosis		optic thalamus	
oöphorectomy		optic tract	
oöphoritis		optical test	

oral administration  
 orbicularis oris  
 orbicularis palpebrarum  
 orbital cellulitis  
 orchitis  
 organic disease  
 organic lesion  
 organic mischief  
 organo-therapy  
 original lesion  
 orthopaedic operation  
 orthopaedic surgery  
 orthopnoea  
 os calcis  
 os magnum  
 os uteri  
 osmic acid  
 osmosis  
 ossify  
 osteitis deformans  
 osteo-arthritis  
 osteogenesis imperfecta  
 osteoma  
 osteomalacia  
 osteomyelitis  
 osteoperiostitis  
 osteophyte

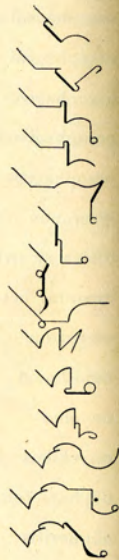


otitis media  
 otolith  
 otorrhoea  
 ovarian cyst  
 ovarian extract  
 ovarian tumour  
 ovariectomy  
 ovaritis  
 oxalic acid  
 oxygenation  
 ozoena  
 ozonic ether

























































## P























































pabulum  
 pachyblepharon  
 pachydermatous  
 pachydermia  
 pachymeningitis  
 paediatrics  
 Paget's disease  
 painter's colic  
 palatine arch  
 palato-glossus  
 palliative treatment  
 palmar fascia  
 palmar cutaneous  
 palmaris brevis












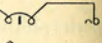












































palmaris longus		paratyphoid	
palpation		parenchyma	
palpebral fissure		parenchymatous inflammation	
palpitation of the heart		paresis	
pampiniform plexus		paretic symptoms	
pan-hysterectomy		parietal lobe	
pan-ophthalmitis		paroleine	
pancreatic disease		paronychia	
pancreatic duct		parotid gland	
pancreatic extract		parotitis	
pancreatic juice		parovarian cyst	
pannus		parturient	
papillitis		parturition	
papilloma		passive movement	
papular eruption		Pasteurization	
Paquelin's cautery		patheticus	
paracentesis		pathogenesis	
paraldehyde		pathognomonic	
paralysis agitans		pathological	
paralysis of accommodation		pectinate ligament	
parametritis		pectineus	
paramyoclonus		pectoral muscle	
paramyoclonus multiplex		pectoralis major	
paraphymosis		pectoralis minor	
paraplegia		pectoriloquy	
parasitic		pediculation	
parasiticide		pediculus capitis	




























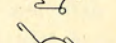









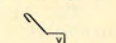

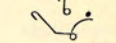
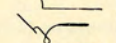


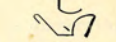




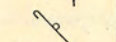







pediculus pubis		pericarditis	
pediculus vestimenti		pericardium	
peduncle of the brain		perichondritis	
peliosis rheumatica		perichondrium	
Pellagra		perichoroidal	
pelvic cavity		pericranium	
pelvic cellulitis		perifolliculitis	
pemphigoid eruption		perihepatitis	
pemphigoid lesions		perilymph	
pemphigus		perimeter	
penetrating wound		perimetritis	
penicillium		perineal	
peptic ulcer		perineorrhaphy	
peptogen		perinephritis	
peptones		perineurium	
peptonised beef		periodicity	
peptonised food		periodontitis	
peptonuria		periosteal growth	
perchloride of iron		periosteum	
perchloride of mercury		periostitis	
percussion		peripheral nerves	
perforating ulcer		peripheral neuritis	
periarthritis		periproctitis	
periarthritis		peristalsis	
periarticular		peristaltic wave	
pericaecal		perisystole	
pericardial		peritoneal adhesions	



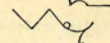



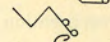





















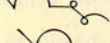
























peritoneal fluid		pharmaceutical	
peritoneal inflammation		pharmacology	
peritoneum		pharmacopoeia	
peritonitis		pharyngeal nerve	
perityphlitic adhesions		pharyngeal pouch	
perityphlitis		pharyngitis	
permanganate of potash		pharyngotomy	
pernicious anaemia		phenacetin	
peroneus brevis		phenol	
peroneus longus		phimosiis	
peroneus tertius		phlebitis	
peroxide		phlebotomy	
perspiration		phlegmasia	
pertussis		phlegmasia dolens	
petechiae		phlegmatic	
petechial haemorrhages		phlegmonous inflammation	
petit mal		phlyctenule	
petrosal nerve		phonation	
petrosal sinus		phosphate of soda	
petrous bone		phosphatic calculus	
Peyer's patches		phosphaturia	
phagedenic ulcer		phosphoric acid	
phagocyte		photophobia	
phagocytosis		photopia	
phalanges		phrenic abscess	
phalanx		phrenic nerve	
phantom tumour		phthisical	

physiology		plantar ligament	
physostigmine		plantar muscle	
pia arachnoid		plantar reflex	
pia mater		plantar tissue	
picric acid		plantaris	
pigment epithelium		plasmo-sarcomatosis cutis	
pigment sarcoma		plastic operation	
pigmentation		platysma	
pilocarpine		plethoric temperament	
pineal gland		pleural cavity	
pisiform		pleural effusion	
pitchblende		pleurisy	
pituitary body		pleuritic friction	
pituitary disease		pleuritic rub	
pituitary extract		pleximeter	
pituitary fossa		plexus	
pituitary gland		plumbism	
pituitary tumour		pneumococcal toxaemia	
pityriasis circinata		pneumococcus	
pityriasis marginata		pneumogastric	
pityriasis rosea		pneumogastric nerve	
pityriasis rubra		pneumohoemothorax	
pityriasis versicolor		pneumonia	
placenta praevia		pneumonic crisis	
placental tissue		pneumopyothorax	
plague-spot		pneumothorax	
plantar fascia		podalic	



podophyllin pill		precordial dullness	
podophyllum		prediastolic	
polioencephalitis		predisposition	
poliomyelitis		pregnancy	
polyarthritis		preliminary incision	
polyarticular		premature labour	
polycythaemia		premolar teeth	
polygonal		premolars	
polyneuritis		presbyopia	
polypi		presentation of the foetus	
polyuria		presystolic	
popliteal nerve		presystolic bruit	
popliteal vein		presystolic murmur	
popliteus muscle		prickle-cells	
portal circulation		primipara	
portal vein		primordial	
post-mortem examination		procidencia recti	
post-nasal space		procidencia uteri	
potassium iodide		proctalgia	
Pott's disease		proctitis	
Pott's fracture		proctoceles	
Poupart's ligament		proctodynia	
praecordial murmur		proctology	
praecordium		proctoplasty	
precentral		proctorraphy	
precipitation		prodromal signs	
precocity		prognosis	






















































progressive muscular atrophy		pubes	
proliferation		pubiotomy	
proliferative		pudendum	
pronation		puerperal eclampsia	
pronatorquadratus		puerperal fever	
pronatorquadratus radii		puerperal mania	
prophylactic treatment		puerperal sepsis	
proptosis		puerperal toxæmia	
prostate gland		puerperium	
prostatectomy		pulmonary disease	
prostatitis		pulmonary nerve	
protoplasm		pulmonary phthisis	
pruritus ani		pulmonary tuberculosis	
pseudo-hypertrophic dystrophy		pulp-chamber	
pseudo-nystagmus		pulsatile tumour	
psoriasiform eruption		pulsation	
psoriasis		pulse-rate	
psoas magnus		pulse-temperature ratio	
psychasthenia		pulsus alternans	
psychiatry		pulsus intermittens	
psychology		pultaceous	
psychotherapy		punctum lachrymale	
pterygoid		punctum caecum	
pterygium		pupillary membrane	
ptomaine poisoning		purgative medicine	
ptosis		purpura haemorrhagica	
ptyalism		purpura neonatorum	

purpura rheumatica		pyriform muscle	
purpura senilis		pyrogallic acid	
purpura simplex		pyrometer	
purpuric spots		pyuria	
purulent			
purulent ophthalmia		<b>Q</b>	
pustulation		quadratus femoris	
putrefaction		quadratus lumborum	
putrescence		quadratus muscle	
pyaemic abscess		quadriceps extensor	
pyarthrosis		quadrigeminal bodies	
pyelitis		quadrumana	
pylephlebitis		quadruped	
pylorectomy		qualitative analysis	
pyloric orifice		quantitative analysis	
pyloric spasm		quantivalence	
pyloroplasty		quarantine	
pylorus		quartan fever	
pyogenesis		quassia extract	
pyogenic membrane		quickening sensation	
pyonephrosis		quiescent symptoms	
pyopneumothorax		Quinic fever	
pyorrhoea alveolaris		quininism	
pyosalpinx		quinone compounds	
pyramidal tract		quinsy	
pyramids of Malpighi		quintan fever	
pyrexial		quintessence	
		Quotidian ague	

LIBRARY  
THE PACKARD SCHOOL

253 Lexington Avenue



R			
racemose		rectus abdominis	
radial nerve		rectus externus	
radiating lesions		rectus internus	
radiating lines		recuperation	
radical cure		recurrent fever	
radio-active		recurrent laryngeal nerve	
radiolus		recurrent symptoms	
radium treatment		red blood cells	
radius		red bone marrow	
railway spine		red corpuscles	
râle		red nucleus	
ramus		reduplication of the second sound	
ranula		reflex action	
raphé		reflex movements	
Ray fungus		reflex pain	
Raynaud's disease		reflex symptoms	
reaction of degeneration		refraction of the eye	
reagent		refraction error	
receptaculum chyli		refraction index	
recipe		refractometer	
recrudescent disease		refrangibility	
rectal fistula		regenerated tissue	
rectocele		regeneration of tissue	
rectotomy		regional anatomy	
recto-uterine		regurgitant murmur	
recto-vesical		regurgitant sound	
		regurgitation	

regurgitation of blood



regurgitation of fluid



regurgitation of food



reinforcement of reflexes



rejuvenate



rejuvenescence



relapsing fever



relapsing symptoms



relaxation of tissue



remission of paroxysms



remittent fever



renal calculus



renal glands



renovation



reposition



reproductive function



reproductive organs



resection



residual air



residual urine



resolvent



resonance



resorcin



respiration



respiration rate



respirator



respiratory murmur



restiform bodies



restlessness



rete Malpighii



rete mirabile



rete mucosum



rete olecrani



rete testis



retention cyst



retention of urine



reticular cartilage



reticulation



reticulum



retina



retinal artery



retinal detachment



retinitis pigmentosa



retinoscopy



retractile tissue



retractor



retrahens aureum



retro-ocular



retro-peritoneal



retro-pharyngeal



retrocollic



retroflexion



retrograde

























































retropulsion









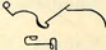









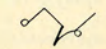



































retroversion		Röntgen rays	
reversion to type		rosacea	
rhachitis		rose-rash	
rheostat		roseola	
rheumatic fever		Royal Army Medical Corps	
rheumatic nodules		rubefacient	
rheumatic pain		rubeola	
rheumatism		rudimentary organ	
rheumatoid arthritis		rupia	
rhinalgia		rupture	
rhinitis			
rhinophyma		<b>S</b>	
rhinoplasty		Sabouraud's pastilles	
rhinoscleroma		saccharate	
rhinoscope		saccharin	
rhinoscopy		saccharometer	
rhomboid muscle		saccharomyces	
rhythmic beat		saccharomyces fungus	
rickets		sacculated	
rigidity		sacculus	
rigor mortis		sacculus laryngis	
rima glottidis		sacral index	
rinderpest		sacral nerves	
ringworm		sacral plexus	
Rinné's test		sacro-coccygeal	
rods and cones		sacro-iliac	
Rhomberg's symptom		sacro-iliac joint	
		sacro-ischiatic	


















































































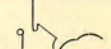


























sacrovertebral		saphenous nerve	
sacrum		saphenous vein	
sagittal furrow		saponification	
sagittal nucleus		sapraemia	
sagittal sinus		saprophytic	
sagittal suture		sarcolemma	
Saint Vitus' dance		sarcoma	
sal-alembroth		sarcomatosis	
sal ammoniac		sarsaparilla	
sal volatile		sartorius muscle	
sal volatilis		scabies	
salicin		scalenus	
salicylate of soda		scalp wound	
salicylic acid		scaphoid bone	
saline aperient		scapula	
saline bath		scarification	
salivary calculi		scarlatina	
salivary glands		scarlatiniform	
salivation		scarlet fever	
salol		scarlet fever desquama- tion	
salpingectomy		schizomycetes	
salpingitis		sciatic nerve	
salpinx		sciatica	
salvarsan		scirrhous of the breast	
salvarsan injections		scissor-gait	
sanatorium treatment		sclerema neonatorum	
santonin		scleritis	


















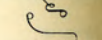




































sclerodactylia		secondary haemorrhage	
scleroderma		secondary lesions	
scleroma		secondary manifestation	
sclerosis		secondary symptoms	
sclerotic		secondary syphilis	
sclerotitis		secreting cells	
sclerotome		sedative medicine	
sclerotomy		sedentary occupation	
scothic resonance		see-saw nystagmus	
scoliosis		segregation	
scopolamine		Seidlitz powder	
scorbutic		sella turcica	
scotoma		semicircular canal	
Scrivener's palsy		semilunar cartilage	
scrofula		semilunar valve	
scrofuloderma		semimembranosus	
scrofulous		seminal tubes	
scurvy		seminiferous tubules	
scybala		semispinalis	
sebaceous		semitendinosus	
sebaceous cyst		sensibility	
seborrhoea capitis		sensorium	
seborrhoea congestiva		sensory nerves	
seborrhoea corporis		sensory symptoms	
seborrhoea oleosa		sepsis	
secondary eruption		septic infection	
		septic intoxication	

septicaemia		Sinusoidal current	
septum cerebelli		sitz-bath	
septum cerebri		skeletal muscles	
septum of the nose		skin-grafting	
septum ventriculorum		skin-incision	
sequestrum		skiagram	
serial sections		skiagraphy	
sero-purulent		skull-cap	
serous coat		sleeping sickness	
serous membrane		sleeplessness	
serpiginous ulcer		slough	
serratus magnus		smegma	
serratus posticus		Snellen's types	
serum-albumin		snow-blindness	
serum therapy		snuffles	
sesamoid		sodium chloride	
sheath of Schwann		softening of the brain	
shin-bone		solar plexus	
shingles		soleus muscle	
shoulder blade		solidification	
sialagogue		solitary follicles	
sibilant r�le		solitary glands	
sigmoid flexure		soluble albumen	
sigmoid valves		somnambulism	
Simpson light		somnolence	
sinapism		somnolent	










































































































soporific mixture		spina bifida	
sordes		spinal-accessory nerve	
sore throat		spinal cord	
souffle		spinal nerves	
spasmodic contracture		spindle-celled sarcoma	
spasmus nutans		spinous	
spastic diplegia		spirillum	
spastic paralysis		spirometer	
specific disease		splanchnic	
specificity		splanchnic nerve	
spectacle lens		splay-foot	
spectroscope		splenectomy	
speculum		splenetic symptoms	
speech-centre		spleno-medullary leukamia	
spermatic artery		splenotomy	
spermatic cord		spondylarthritis	
spermato-cystitis		spongioplasm	
spermatocele		spongiose tissue	
spermatorrhoea		spongy bones	
spermatozoon		spontaneous generation	
sphenoid		sporadic cretinism	
spherical aberration		spotted sickness	
sphincter ani		squamous epithelium	
sphincter of the iris		squamous suture	
sphygmogram		stagnation of blood	
sphygmograph		standardized lymph	
sphymoid		stapedius	























































staphylococcus		stertorous breathing	
staphylococcus pyogenes aureus		stethoscope	
staphylococcus pyogenes citreus		sthenic	
staphyloma		still-born	
starvation treatment		stimulant action	
stasis		stomach ache	
static breeze		stomach pump	
static electricity		stomach tube	
status epilepticus		stomachic	
stearin		stomatitis	
steatoma		strabismus	
stenosis of the pylorus		stramonium	
stercoraceous		strangulated hernia	
stereoscopic photograph		strangury	
stereoscopic radiogram		stratified epithelium	
stereoscopic vision		streptococcus	
sterility		streptothrix	
sterilization		stretcher-bearer	
sterilization of the dressings		stricture of the urethra	
sterilizer		stridulous	
sternal		strontium	
sterno-clavicular		strophanthus	
sterno-costal		strumous diathesis	
sterno-mastoid		strychnine	
sterno-thyroid		stupor	
sternum		stuporose state	
stertor		styloid process	

stylo-glossus		subscapular nerve	
stylo-hyoid		subserous	
stylo-mastoid		subsistence	
stylo-pharyngeus		substantia gelatinosa	
sub-acute illness		substantia nigra	
sub-acute symptoms		subsultus tendinum	
subarachnoid		succus entericus	
subclavian		succussion	
subclavicular		sudoriparous glands	
subclavius		suffocation	
subconjunctival		suffusion	
subcutaneous incision		sulphate	
subdural haemorrhage		sulphate of quinine	
subdural space		sulphide	
subinvolution		sulphonal	
subjective sensations		sulphuric acid	
subjective symptoms		sulphuric ether	
sublingual		sulphurous acid	
sublingual gland		summer rash	
subluxation		superciliary	
submaxillary		superficial reflex	
submental		superficial wound	
suboccipital		supernumerary digits	
subordination		supination	
subperiosteal		supinator brevis	
subperitoneal		supinator longus	
subscapular		suppository	







































































































suppression of urine		symptom-complex	
suppurating wound		symptomatic	
suppuration		symptomatology	
supraclavicular		synchondrosis	
supraorbital		synchronous	
supraorbital foramen		syncopal	
supraorbital nerve		syncope	
suprarenal capsule		syncytial	
suprascapular		syndrome	
supraspinal		synechia	
supraspinatus		synovia	
supratrochlear nerve		synovial membrane	
Surgeon-General		synovitis	
surgical tuberculosis		synthesis	
suspended animation		synthetic compounds	
suspensory muscle		syphilides	
swallowing		syphilis	
sweat glands		syphilitic	
swelling		syphilitic infection	
sycosis		syphilitic inflammation	
symblepharon		syphilitic stigma	
Syme's operation		syphiloma	
symmetrical eruption		syringomyelia	
sympathetic inflammation		systematic	
sympathetic ophthalmia		systemic	
symphysis of the jaw		systemic vessels	
symphysis pubis		systole	

systolic bruit		taste-cones	
systolic murmur		taxis	
<b>T</b>			
tabes dorsalis		teaspoonful	
tabes mesentericus		teething	
tabetic gait		teetotalism	
tabetic symptoms		tegmen tympani	
tablespoonful		tegmenum	
tache cérébrale		telangiectasis	
tachycardia		telangiectatic	
tactile cells		Telegrapher's cramp	
tactile reflexes		telepathy	
tactile sensation		Telephone tinnitus	
taenia solium		temperament	
talipes calcaneus		temperature	
talipes equino-varus		temperature chart	
talipes equinus		temporal bone	
talipes valgus		temporal hemianopia	
talipes varus		temporal muscle	
tampon		temporizing treatment	
taraxacum		temporo-facial	
tarsal cartilage		temporo-sphenoidal lobe	
tarsal cyst		tenaculum	
tarsectomy		tenderness to the touch	
tartar emetic		tendo Achillis	
tartaric acid		tendo-synovitis	
		tendon reflex	

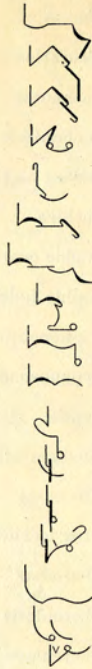
tenesmus		thecal abscess	
tenonitis		theobromine	
Tenon's capsule		therapeutical	
tenotomy		thermanaesthesia	
tensor palati		thermo-cautery	
tensor tarsi		thermometer	
tensor tympani		thermostat	
tentorium cerebelli		Thomsen's disease	
teratoma		thoracentesis	
terebene		thoracic cavity	
terebene Canadensis		thoracic nerve	
teres major		thoracic symptoms	
teres minor		thoracic viscera	
terminal phalanges		three times a day	
terminology		throat symptoms	
tertian fever		throat trouble	
tertiary symptoms		thrombo-phlebitis	
tertiary syphilis		thrombosis	
test-types		thrombus	
testicular sensation		thymol	
tetanic spasm		thymus	
tetanoid movement		thyro-arytenoid	
tetanus bacillus		thyro-epiglottideus	
tetanus neonatorum		thyro-hyoid	
thalamic centre		thyroid cartilage	
thalamus		thyroid gland	
theca vertebralis		thyroidectomy	



thyrotomy		torpor	
tibia		torsion of the intestine	
tibialis anticus		torticollis spasm	
tibialis posticus		torticollis	
tic douloureux		touch-corpuscles	
tincture of opium		tourniquet	
Tinea barbae		toxaemia	
Tinea circinata		toxaemic state	
Tinea decalvans		toxicology	
Tinea favus		trabeculae	
Tinea tonsurans		trachea	
Tinea versicolor		tracheal tugging	
tinnitus		tracheotomy	
tinnitus aurium		tracheotomy tube	
tissue regeneration		tracheotomy wound	
tobacco amblyopia		trachoma	
tobacco blindness		tragacanth	
tolerant point		tragus	
tongue-tie		trans-condylar amputation	
tonic spasm		transfixing	
tonicity		transfusion	
tonsillitis		transmigration	
tonsillotome		transparent medium	
tophi		transplantation	
tophus		transplantation of tissue	
topographical anatomy		transposition of vertebrae	
torcular Herophili		transudation	

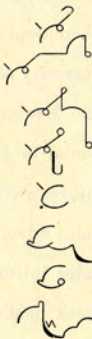
transversalis		trismus	
transverse axis		trituration	
transverse colon		trochanter	
transversus pedis		trochanteric	
trapezius		trochar and cannula	
trapezoid		trochlea	
traumatic iritis		trophic centres	
traumatic neurasthenia		trophic function	
traumatic trismus		trophoneurosis	
traumatism		trypanosomiasis	
trematode worm		trypsin	
trepanning		tubal gestation	
trephine opening		tube-casts	
treponema		tuber ischium	
triangular ligament		tubercular	
triceps muscle		tuberculosis	
trichiasis		tuberculous	
trichiniasis		tuberculous disease	
trichinosis		tuberculous process	
trichophyton Megaloporon		tuberculous sinus	
tricuspid murmur		tuberosity of the ischium	
tricuspid regurgitation		tubo-ovarian	
tricuspid valve		tubular breathing	
trigeminal		tumefaction	
trigeminal nerve		tunica adventitia	
trigeminal neuralgia		tunica intima	
trigone of the bladder		tunica media	

tunica vaginalis  
 turbinated body  
 turbinated bone  
 turgescence  
 turpentine  
 tympanic membrane  
 tympanic nerve  
 tympanic ossicles  
 tympanites  
 tympanum  
 typhlitis  
 typhoid fever  
 typhoid state  
 typhoid ulceration  
 typhomania  
 typhus fever  
 tyrosin




## U

ulceration  
 ulcerative colitis  
 ulcerative stomatitis  
 ulcerous condition  
 ulna  
 ulnar nerve  
 ulnaris  
 ultra-violet light



ultra-violet rays  
 umbilical cord  
 umbilical hernia  
 umbilical ring  
 umbilical vesicle  
 umbilicated lesion  
 umbilicus  
 uncinatè gyrus  
 unguis bones  
 unguent  
 unguentum hydrargy-  
 rum  
 unicellular  
 unilateral  
 unilocular cyst  
 unioocular  
 unipolar  
 univalent  
 universal joint  
 unnerved  
 unsoundness of mind  
 ununited fracture  
 urachus  
 uraemia  
 uraemic symptoms  
 urate of soda  
 ureameter  
 ureter





ureteric calculus



urethra



urethritis



uretolith



urethroscope



urethrospasm



urethrotomy



uric acid



urinary organs



uriniferous tubules



urinometer



urobilin



uroedema



urolith



urticaria acuta



urticaria chronica



urticaria papulosa



urticaria pigmentosa



urtication



uterine contractions



uterine gestation



uterine souffle



uterine tumour



uterofixation



utricle



uveitis



uvula



uvulitis



uvuloptosis



## V

vaccination rash



vaccine lymph



vaccine therapy



vaccine virus



vacuolated



vacuole



vagina



vaginal examination



vaginismus



vaginitis



vagus nerve



valerian



valgus



Valsalva's sinus



valvulae conniventes



valvular disease



valvular incompetence



vaporization



varicella



varices



varicocele



varicose aneurysm




varicose condition



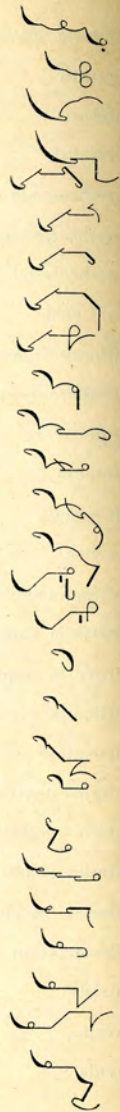varicose veins



variola  
 varioloid  
 variolation  
 vas aberrans  
 vas afferentia  
 vas deferens  
 vas efferentia  
 vas vasorum  
 vascular growth  
 vascular pulsation  
 vascular system  
 vascularity  
 vascularization  
 vaso-constrictor  
 vaso-dilator  
 vaso-inhibitory  
 vaso-motor  
 vastus externus  
 vastus internus  
 vegetable albumin  
 vegetable proteids  
 vegetation adenoids  
 vena cava inferior  
 vena cava superior  
 venereal disease  
 venereal sore  
 venesection



venous noevus  
 venous stasis  
 venter of ilium  
 venter of kidney  
 ventricle of brain  
 ventricle of heart  
 ventricular band  
 ventricular beat  
 ventricular systole  
 vermicide  
 vermicular motion  
 vermiform appendix  
 vermiform process  
 vermifuge  
 verrucose condition  
 verrucose state  
 version  
 vertebra  
 vertebral column  
 vertex  
 vertiginous  
 vesical calculus  
 vesical growth  
 vesication  
 vesicatory  
 vesico-rectal  
 vesico-vaginal




vesicular eruption



vestibule of the ear



viability



viable



vibrio



vicarious



vicarious menstruation



Vienna paste




virility



virulent cancer



virulent poison




virus of disease



vis medicatrix



visceral disease



viscosity




viscous secretion



viscus



visual acuity




visual field



visual perception



vital capacity



vital statistics



vitreous humour




vivisection



vocal cord



vocal fremitus



vocal resonance



volatile oil



volitional



volvella



voltaic



voltaic current



voltaism



volumetric analysis



voluntary movement



voluntary muscle



volvulus



vomere



vomitory



voracious appetite



vortex



vulvar



vulvitis



vulvo-vaginal



## W

ward-nurse



ward-sister



warty



wasting disease



wasting disorder



water-brash



water-cure



waxy degeneration



weaning period





Weber's test



wet-pack



Wharton's duct



wheezing breath



white matter of the brain



whitlow



whooping cough



wisdom teeth



Wolfian bodies



woolsorter's disease



word-blindness



word-deafness



wrist-drop



Writer's cramp



Writer's palsy



wry-neck

**X**

xanthelasma



xanthic



xanthoma



xanthosis



xeroderma



xerophthalmia



xerosis



xiphisternum



xiphoid



xiphoid cartilage



yawn

**Y**

yaws



yeast fungus



yellow fever



yellow ligament



Y-shaped cartilage

**Z**

zero



zinc chloride



zinc ointment



zinc paste



zinc sulphate



zingiber



zona pellucida



zona vasculosa



zonaesthesia



zonula



zonula ciliaris



zonular cataract



zonule of zinn



zooglea



Zoster



zygoma



zygomatious



zyme



zymoma


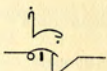



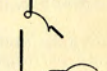





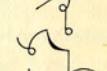

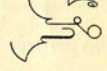

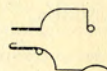





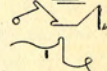











zymotic disease




## APPENDIX

*(The following list contains 80 new words and phrases which have become current in the profession since the last printing of this work.)*

acapnia		contramine	
acrocyanosis		cosmo-telluric	
actinotherapy		cystectomy	
adamantinoma		decerebrate	
adeno-fibroma		duodenectomy	
amyloidosis		embryotomy	
angiomalacia		endocrine glands	
antiscorbutic		entropion	
apnoea		erythrocytes	
arthrodosis		fat-soluble vitamins	
arthroplasty		focal sepsis	
bacillus botulinus		fulguration	
bilivaccine		galactose	
biotripsis		glio-sarcoma	
blastomycetic dermatitis		helminthic	
blood-sugar curve		hemihypertrophy	
blood pressure		high-frequency current	
bone tumour		hyperchloridia	
cheilotomy		immuno-transfusion	
cholesterol		insulin	
Cloquet's canal		intra-tracheal ether	

ischoemic paralysis




kala-azar




keratectasia



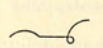
keratoplasty




laevulose



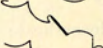melanoma




mucocele



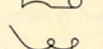
myotonia congenita




neurofibromatosis




novarsenobillon




otomycosis




pansinusitis




papilloedema




parapsoriasis




parathyroid



perithelioma




phytosterol



pituitrin




pleuro-pneumonia




poikilodermia




poikilo-osmosis



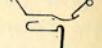
propylene



psycho-analysis




Purkinje cells




quadriplegia




ramisectomy




sanocrysin



Schamberg's disease




Schick test




Sigma Una test




spasmophilia



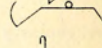
splenomegaly




stabilarsan



sulfarsenol




suprapituitary



thoracoscope




transillumination




undulant fever



vitiligo



Von Pirquet's reaction





## EXERCISES

---

### I

THIS is not so uncommon as the number of recorded cases would lead us to suppose. Some people object to the terms "word-blindness" and "letter-blindness" as implying rather a defect in the visual perception, therefore I submit an alternative name, "Alexia congenita." Blindness here means mental blindness, that is to say, that the patient does not appreciate written characters, owing to some defect in the visual-memory centre, without there being impairment of the centres for primary vision, and so without there being blindness in the literal sense of the word. The word and letter visual centres are situated on the left side of the parietal lobe, in the neighbourhood of the supramarginal and angular convolutions, and this is connected by commissural fibres with the primary visual centres in the occipital lobes, and the auditory letter centre is in the posterior part of the first temporo-sphenoidal convolution on the left side. As this patient is apparently letter and word deaf, in that she has very little knowledge of the alphabet and cannot spell, the defect in her case seems to be somewhere about the posterior end of the fissure of Sylvius, on the left side. If the lesion is situated so as to affect the fibres running from the primary visual centres to the angular and supra-marginal convolutions, in both hemispheres, they would almost certainly involve the optic radiations to the occipital lobes, and so cause hemianopia, or some other cause of blindness. I do not think the word centre in this case is entirely functionless, because she can sometimes pick out one or two letters, and she has some power of writing. If the centre were entirely without function, it would be impossible to stimulate the graphic motor centre, and so there would be absolute agraphia.

The next is a case of polio-encephalo-myelitis. There is marked internal strabismus of the right eye, owing to paralysis of the external rectus. There is no paralysis of other cranial muscles; speech is slow and hesitant, but articulation is clear. There are some quasi-voluntary pawing movements in the right arm, and at times coarse involuntary tremors on both sides, but voluntary movements are fairly well co-ordinated. Slight

hypotonia is present in fingers and wrist. Arm-jerks are not exaggerated. Plantar response is of the Babinski type, extensor. The case resembles the cerebellar type of polio-encephalitis, but the absence of knee-jerks and the presence of the extensor plantar response show that the disease has affected the posterolateral columns as well as the cerebello-spinal apparatus. Some regard polio-encephalitis and poliomyelitis as identical diseases. Certainly the association of poliomyelitis with measles and other exanthemata is most uncommon, but it is otherwise with polio-encephalitis.

## 2

The multiformity in the pemphigoid eruptions is due to a number of causes, of which the most obvious are : variations in the type of initial lesion ; the occurrence of several types of lesion synchronously ; variations in the type of lesion occurring in different attacks ; differences in the stage of evolution of individual lesions ; endless differences in distribution and grouping. The types of initial lesions met with are the familiar prurigo-like papules, paulo-vesicles, vesicles, bullae, and erythematous or urticarial patches. Sometimes these papules are grouped in a herpetiform fashion, or have a tendency to involute in the centre and give rise to circinate figures with rings of vesicles at the border, which may coalesce to form gyrate patterns. The vesicles may be acuminate, forming the apices of papules, or rounded, appearing on apparently healthy skin or developing on a red basis. Sooner or later they are surrounded by an inflammatory halo from the growth of secondary micro-organisms in the contents. The vesicles may be isolated and irregularly distributed, but as a rule they are clustered in small groups of six or eight, or arranged in a circinate manner at the edge of an erythematous patch, like herpesiris. They usually remain discrete, but occasionally may be closely aggregated to form multilocular bullae. These bullae may develop on an inflammatory or urticarial base, and may be regular in outline, and unilocular, or irregular and multilocular. They may be so flabby as to suggest epidermolysis bullosa, or the fluid contents may be slight and the dissociation of the epidermis considerable, giving rise to a desquamating appearance, recalling a mild pemphigus foliaceus. The contents of the vesicles and bullae are at first clear and sterile, but soon become opaque and purulent from secondary infection with pyogenic micro-organisms. The



transition may be so rapid that the early stage may pass unobserved, and the lesion suggest a pustule d'emblée. In those cases in which the vesicles become rapidly purulent there is a close correspondence to impetigo herpeticiformis. In the blood, the chief change is an increase in the coarse granular eosinophiles; indeed, eosinophilia has been observed so frequently in the pemphigoids that its presence has been regarded by some as of diagnostic significance, and as suggestive of the action of some toxin in the bone marrow. Occasionally this increased eosinophilia has been noted in the contents of the bullae, and occasionally in the cellular infiltration in the corium. Out of 27 cases of dermatitis herpeticiformis, only 13 showed a definite increase of eosinophiles; and it was noted that in 18 out of 26 cases of dermatitis herpeticiformis there was an increase of the large mononuclear leucocytes. In one case there was lymphocytosis in the cerebrospinal fluid. It has been asserted that the serum which exudes from the blood vessels in the pemphigoids has a cytolytic action, which assists in the formation of vesicles and bullae by causing a disintegration of the interepithelial fibrils of the prickle-cells, but if present this must be slight, or the average size of the bullae would be greater. Where indicanuria exists, it has usually been found to be associated with the outbreaks of the eruption, and its presence is suggestive of an auto-intoxication from the putrefactive changes in the alimentary tract. It is in the papillary and sub-papillary layers of the corium that the initial changes take place. These consist of a marked dilatation of the capillaries, with oedema of the surrounding fibrous tissue, rarefaction of the fibrous bundles of the collagen, a dense infiltration of cells, an exudation of serum, and an extravasation of lymphocytes, eosinophiles, and of polynuclears if suppuration has taken place. The condition has all the appearances of an acute inflammatory disturbance in the upper part of the corium, the result of some toxic irritant.

### 3

There is an universal chromatolytic change in the cells of the central nervous system, sparing no system or group of neurones entirely. Especially affected were the smaller cells of the autonomic nuclei, that is to say, the vagus and glossopharyngeal. In the cerebellum, the Purkinje cells show less chromatolysis than the large motor cells of the medulla oblongata, spinal cord,



and Betz cells, and there is no increase of the glia tissue. There is a hypothyroidism occurring at this time of life characterized by an atrophy of the glandular structure of the thyroid, interstitial fibrous hyperplasia, and abundant infiltration of the same with lymphocytes; a condition of chronic inflammation, arising from a toxic state, probably local in its source, as the adjacent parathyroids show no such change. There is usually abundant colloid in the pars intermedia, which may be regarded as evidence of thyroid insufficiency. It may be stated that the characteristic perinuclear chromatolysis of the nerve cells was not discovered in two cases of simple atrophy of the thyroid gland. Examination of the gland in these two cases showed still normal colloidal vesicles, and vesicles filled with epithelium or degenerated epithelium; and although there was an increase of the interstitial fibrous tissue, there was no lymphocytic infiltration indicative of a local toxic inflammation; neither was there any increase of weight of the pituitary body, nor excess of colloid observed in section of this gland. It is permissible, therefore, to correlate the changes in the nervous system with this particular form of hypothyroidism, in which the gland has undergone a pseudo-hypertrophy, or in which the gland is considerably below the average weight. The increase of colloid in the pituitary may be regarded as an index of the extreme degree of hypothyroidism.

#### 4

In the following cases of multiple neuritis, objective disturbances of sensation were absent, and though there was a certain amount of pain—in one case considerable pain—the symptoms were essentially those of motor paralysis. Instances of this type of neuritis, excluding, of course, those of single nerves, are not at all uncommon. The great majority of cases of multiple neuritis are alcoholic, and sensory disturbances form one of the most striking clinical features. In the earlier stages of the motor type of polyneuritis, when the disease is spreading and invading successive groups of muscles, the difficulty of diagnosis from an ascending spinal paralysis, and also from certain cases of anterior poliomyelitis, may be difficult. Moreover, many of the most characteristic features of multiple neuritis are absent or inconspicuous. Thus, in alcoholic neuritis women are far more often affected than are men, especially women between

40 and 50 years of age. The legs are involved first, and in the majority the arms escape or are only slightly affected, whilst pains, tenderness of nerves and muscles, and peripheral loss of cutaneous sensibility are prominent, and these symptoms, with certain other features, especially the mental changes, which form the well-known Korsakoff's syndrome, and the cardiac weakness due to the action of alcohol on the heart muscle, all contribute to make up a characteristic and striking clinical picture. Again, in acute toxic polyneuritis the cause is generally obscure. Except in those cases which follow influenza, or some such infective disease, the onset is insidious, may take place during apparent good health, and the absence of constitutional disturbance seems to negative the idea of infection. In the majority of cases which conform clinically to the type of polyneuritis, the onset and progress of the paralysis are slower than in a typical case of Landry's paralysis, and in the second or third week the paralysis begins to be definitely greater at the periphery of the limbs, if not in all four extremities at first, yet either in the arms or the legs, and to predominate in the extensors, whilst alterations in the normal electrical reactions of the most affected muscles begin to be evident. The diagnosis from acute anterior poliomyelitis is not so difficult, and in most cases the sufferers from this disease are much younger than those from acute toxic polyneuritis; and there are the decided signs of constitutional disturbance at the onset of acute poliomyelitis, the characteristic pains on passive movements of the joints, the absence of such symmetrical paralysis, the escape of a muscle or group of muscles in the otherwise paralysed limb, the recovery of some muscles soon after the onset, and the frequent presence of large lymphocytosis in the cerebro-spinal fluid.

## 5

Lugaro, speaking of consciousness, said: "Subjective observation has shown us that the essential character of consciousness—without which we could not comprehend consciousness itself—is the act of establishing relationships between diverse impressions; there is no consciousness without distinction." He mentioned that Tanzi has indicated that if from the subjective point of view the distinctions demand, as a necessary condition, the formation of multiple, precise and constant relationships between the various sensations, it is necessary, from the objective point of



view, that the dynamic processes which form their substratum should present the same multiplicity, precision, and constancy. And, therefore, the individual stimuli coming from the outside world must be separately conducted to the centre, and, combining there, assume the most varied but definite relationships and become intimately united with the accurately localized records left by former processes. And since all the possible and varied symbolic constructions which constitute conscious phenomena result from the grouping together of the elementary distinctions, it is necessary that all the dynamic processes corresponding to the elementary distinctions develop with orderly distribution in an individual centre, and assume there the most varied relationships of combination corresponding to the single groups of distinctions. Upon these dynamic processes so essential for clear distinction, that is, for clear consciousness, depends the affective tone of the sensations and states of consciousness in general. Any disturbance of them, by toxic action or otherwise, will interfere with the psychic functions, and amongst other disorders weakening of sensory attention and of apperception, and a morbid affectivity may be produced.

## 6

Lymphogenous inflammation is characterized by certain definite phenomena: (1) the reaction of the cells of the fixed connective tissues; (2) the proliferation of the cells of the adventitial sheath of the veins and capillaries; (3) the appearance of scavenger cells where the myelin is disintegrated; (4) nerve cell degeneration and neuronophage phenomena. Naturally, the histological character of the inflammatory products varies with the potency of the exciting agent. The proliferation of the adventitial cells is worthy of special notice, as it forms a picture identical with that of the periarteritis found in general paralysis of the insane, and some other conditions. A study of experimental lymphogenous infection of nerves has enabled us to form two important deductions. The first of these is, that the lymph path of nerves is an important mechanism of brain and cord infection; and the second is, that in all probability general paralysis and tabes dorsalis are lymphogenous infections. There is another mode of infection of the central nervous system, and that is by the blood stream, and many data go to show that over and above the deleterious influence on nerve tissue of organisms



and toxins, we cannot lose sight of the effects of the products of altered metabolism, and the influence of hypersecretion and hyposcretion of the ductless glands. We have commenced with a study of the effect on the spinal cord of a bacterial intoxication, and the abdominal cavity was chosen for several reasons, partly to ascertain how far such toxi-infection affected the sympathetic ganglion chain. It appeared necessary to determine this point, as infection of the abdominal sympathetic and its functional disturbance presumably should, by reaction upon the vascular system, be an important factor in the mechanism of production and localization of spinal cord lesions. *Post-mortem*, the capsules used were found surrounded by an accumulation of inflammatory cells, and the vessels of the mesentery, stomach, small and large intestines were much congested. The inflammatory reaction extended from the neighbourhood of the capsules a considerable distance along the mesentery, and there was abundant evidence of reaction in connection with the sympathetic ganglia. Some of these were surrounded by masses of degenerate polymorphonuclear cells, by cells of the lymphocyte type, and fibroblasts. The vessels passing into the ganglion substance showed proliferative changes in the adventitial sheath. Within the ganglia there was chromatolysis of the nerve cells. Much of the chromophyle substance had disappeared from the centre of the cells, and the nucleus was displaced to the periphery. The spinal cords were fixed in formalin and bichromate of potassium, and pieces from all regions were cut in longitudinal and transverse section. No evidence of lymphogenous invasion was found in the sheath of the spinal ganglia, the perineurium of the spinal roots, or in either the dura mater or the pia arachnoid. The hypertrophied cells of the glia were of the amoeboid type, and frequently formed a row of elements lying end to end. No karyokinetic figures were seen. Many of these amoeboid neuroglia cells clustered thickly round the veins and capillaries of the white matter, and frequently the cell body was closely applied to the adventitial sheath, or attached to it by branching processes. In addition to the generalized neuroglia reaction, there were small scattered sclerotic foci consisting of glial elements in the resting stage following proliferation. These nuclei were smaller than normal, filled with chromatic substance, and their cell bodies and processes massed together to form a syncytium. The nerve cells showed early chromatolysis. In some the

nucleus was rather diffusely stained, an appearance suggestive of the initial stage of homogeneous atrophy, and the chromophile elements in the cell centre had an increased affinity for the stain, while their edges were not so sharply outlined as in the normal. It became clear that in lymphogenous lesions the inflammatory phenomena reach their maximum; in haematogenous intoxications the inflammatory reaction is reduced to a minimum. In the vascular system of the cord there is evidence of disturbance of sympathetic action; in the dilatation, haemorrhages with sclerotic foci, and in the hyaline thrombosis, all of which point to stasis.

## 7

You will notice the transparent zone immediately beneath the carious cavity. This is an area of increased calcification due to a defensive action on the part of the pulp, the dentinal fibrils in that situation becoming calcified against the advancing caries. In the next specimen the translucent zone is cut obliquely across, and immediately behind it is the area of decalcification. There is, therefore, a pitched battle going on in the dentine ahead of the carious process. There is a defensive action taking place in the increased calcification of the dentine, which is a vital manifestation on the part of the pulp, and there is an offensive action opposed to this by the attacking micro-organisms in the saturation and decalcification of the dentine by acids. As the carious process gains ground and advances towards the pulp, the pulp makes more powerful efforts at self-protection by throwing up a barricade of secondary dentine against the threatened wall. The next slide shows that the pulp may still continue its efforts at self-protection after it is actually invaded by micro-organisms, and suppuration has occurred. At the top one can see the thick layer of secondary dentine which has been formed opposite the threatened breach; this has been broken through at some part by the micro-organisms which have thus reached the pulp and caused suppuration, as shown by the large abscess cavity in the pulp tissue. Immediately below this abscess, however, one can see a new layer of partly formed secondary dentine, with which the pulp has endeavoured to localize the trouble. In considering this process of the formation of secondary dentine, it is necessary to distinguish between what I may call physiological and pathological formation. By physiological formation I mean the regular deposit of an uniform layer of secondary dentine over



the threatened surface of the pulp; it is the result of continued stimulation, and is in no sense a pathological change. It does not interfere with the vascular or nervous supply of the rest of the pulp, which remains as healthy as before. By pathological formation I mean the irregular deposits of secondary dentine which occur in the form of nodules or spines in the substance of the pulp. These deposits are usually due to some local irritation, and are distinctly pathological in origin. I now turn to the question of treatment, with special reference to the possibility of inducing the natural protective action of the pulp in lieu of devitalization.

## 8

The bones showed an irregular subperiosteal deposit of new bone on the shaft. Microscopic sections of a decalcified piece were prepared, and microphotographs are shown. The original compact bone of the shaft is separated by a very open meshwork of bony trabeculae from a less deeply stained outer layer of newly-formed bone. In most other necropsies on cases of pulmonary hypertrophic osteoarthropathy the bones have, I think, been only microscopically examined, but the subperiosteal deposit of friable layers of new bone appears to be a feature observed in all cases. The microscopic structure of the newly-formed bone is apparently similar to that found in cases of chronic periostitis when accompanied by new bone formation. Yet clinically the bone affection, in its absence of pain, differs from ordinary kinds of periostitis. Syphilis may cause a diffuse hypertrophic osteoperiostitis of long bones, with much subperiosteal formation of new bone on the diaphyses, especially of the tibiae, and in such cases the bony change may be almost symmetrical in distribution, and relatively painless, but the bones of the hands and feet are not affected in the same way that they are in pulmonary hypertrophic osteoarthropathy.

The growth in the next case was, histologically, a plasmacytoma or plasmoma. Examination of films from the heart blood gave small lymphocytes 1.2%; large lymphocytes 19%; large mononuclears and transitionals 0.6%; polymorphonuclears 77.3%; eosinophiles 0; myelocytes 1.8%. A good many of the polymorphonuclears appeared immature, approaching the myelocyte type. No nucleated red cells were seen. The pancreas showed no disease, and there was no cholelithiasis. The spleen showed an increase of fibrous trabeculae. There was a fibrotic thickening



of the walls of the arteries. The suprarenal glands were not examined. There was a swelling of the dorsal root fibres in the root-entry zone, suggesting slight compression of the dorsal roots; there was no evidence of metastasis of the bone-marrow growth, and no enlargement of lymphatic glands. The marrow in the humerus contained peculiar cell-infiltrates. The cells present all the morphological characters of plasma cells; the nucleus has chromatin granules arranged mostly at the periphery. In the centre of the nucleus is usually seen a clear space which lodges the nucleolus, staining a bright red, in contrast to the green nuclear chromatin. The cytoplasm is often voluminous, with intensely basophil reaction. In many cases the cytoplasm is highly vacuolated, the intervening granular substance staining deeply with the pyronin. During mitosis the basophilia of the cytoplasm is greatly reduced, and the chromatin is arranged in the centre of the cell as a twisted highly pyknotic band. Degeneration of the plasma cells is more in evidence than active proliferation. The cytoplasmic residue still retains its marked affinity for pyronin. The perinuclear halo, the intranuclear space, and the substance contained in the cytoplasmic vacuoles take up the green or acid stain. It has been noted in the nucleus of the *entamoeba histolytica*. Eosinophil myelocytes are very numerous. Small erythroblastic foci are seen here and there. The giant cells of the marrow are not increased in number. The main points around which discussion has centred have been the differentiation of the various forms of bone-marrow growth, the presence or absence of metastases, and the morphology of the cells constituting the bone-marrow growth. The time is not yet ripe for the adoption of very dogmatic views as to the exact place of myeloma in the classification of diffuse affections involving the haematopoietic apparatus.

## 9

I propose to make an attempt to give a classification of nystagmus, contrasting the characters of the various types, and indicating the conditions under which they arise physiologically and pathologically.

There is first the ocular, which can be subdivided into pseudonystagmus, true nystagmus without visual vertigo, and true nystagmus with visual vertigo. Secondly, there are the vestibular cases, which, again, can be separated into the labyrinthine

and the retro-labyrinthine or intracranial. Thirdly, there are the mixed ocular and vestibular conditions.

I would suggest that in certain cases, ocular and vestibular nystagmus occur together spontaneously, forming a mixed type. In support of this are the following facts: We meet with a nystagmus presenting certain characters, caused by some disturbance in the neuro-muscular mechanism which are associated with the control of eye movements, when attempts at the visual fixation of objects are made, in persons whose labyrinths are perfectly healthy. This type can be elicited physiologically, and it occurs spontaneously under certain pathological conditions. It is best designated ocular nystagmus. We also find a nystagmus presenting certain characters which differ from those under the first heading, by throwing stimuli from the labyrinth along the ocular paths. When testing for vestibular nystagmus in the presence of a spontaneous ocular, one finds a slow and quick rhythmic movement on deviation of the eyes to the side of the quick component, and the more rapid oscillatory movement to the opposite side. At times, unless the stimulus is very active, it is difficult to dissociate the quick and slow components, on account of the previous spontaneous, bilateral, oscillatory type. The stimulus applied to the vestibular tracts by a cerebellar tumour evokes a feebler response in the ocular paths than if the same stimulus were applied directly to the labyrinth. Stimuli applied directly to peripheral end-organs evoke more active responses than when similar stimuli are introduced centrally, or along the paths which normally carry central impulses from these organs.

## 10

The expression "irregularity of the pulse" is not synonymous with "irregularity of the heart." The radial pulse may beat with perfect regularity, yet on auscultating the heart, certain arrhythmical beats may often be heard, but which fail to transmit a pulse-wave to the wrist. The varying time-intervals between the beats which indicate the arrhythmia may affect the whole heart, auricles and ventricles, or there may be disassociated action between the two sets of chambers. There may be irregularity due to premature systole, and it often occurs in hearts which are, for all practical purposes, sound. The intermittent pulse frequently attributed to indigestion, flatulence, or neurosis is of this type. On auscultating a heart in which premature



systoles occur, it will be found that abortive heart sounds can be heard corresponding in time with the intermission of the pulse. If normal beats and premature systoles alternate, the result is frequently, a bigeminal pulse, or a trigeminal. Premature systole has relations with other forms of disordered mechanism, notably with paroxysmal tachycardia. An attack of tachycardia, lasting hours or days, is nothing more than a long series of premature systoles. Respiratory irregularity is particularly apt to occur in children after febrile attacks. After diphtheria it might be mistaken for serious heart weakness unless we are thoroughly alive to its nature, and it has sometimes been considered an evidence of perverted innervation in suspected meningitis. Vagus influence is partially suspended during pyrexia; during convalescence this influence is temporarily exaggerated, and causes the periodic slowing of the pulse. Heart-block is evidence of degeneration or functional impairment of a particular region of the cardiac musculature. In complete heart-block there no longer exists any relation between the respective actions of the two chambers. The ventricle takes on a slow action of its own, the so-called "idio-ventricular rhythm." The myocardial disease, which causes interruption of the auriculo-ventricular conducting fibres, thus producing heart-block, may be acute or chronic. Myocarditis is exceedingly common in acute rheumatism. We talk of endocarditis and pericarditis, but we are apt to ignore the accompanying myocarditis. Polygraphic observations have demonstrated the occurrence of mild degrees of heart-block during rheumatic attacks, and these have been noticed in connection with pneumonia, influenza, and other febrile diseases. Stokes-Adams' disease is characterized by syncope, unconsciousness, failure of the radial pulse, and sometimes convulsions. There is also irregularity due to auricular fibrillation; it is most commonly met with in cases of rheumatic heart disease, especially mitral stenosis. The persistently irregular pulse sometimes seen is due to auricular fibrillation induced by degenerative changes. In the absence of regular co-ordinated auricular contractions, there is also absence of regular ventricular contractions; fibrillation causes irregular and spasmodic stimulation of the auriculo-ventricular band, and from this ensue irregular, disorderly ventricular contractions, generally feeble and rapid. It has been pointed out that the presystolic bruit generally met with in mitral stenosis is altered in character after fibrillation sets in.



The accented crescendo murmur running up to the first sound is caused by the contraction of the auricle forcing the blood through the narrowed orifice. The presence of auricular fibrillation is an important sign of heart failure, and doubtless greatly aggravates other pre-existing mechanical difficulties due to dilatation, valvular defects, and so on. Further evidences of failure, such as oedema of the feet or lungs, breathlessness or orthopnoea, enlargement of the liver, may be eventually expected in cases in which fibrillation is persistent.

## II

With regard to growths in the middle and upper part of the sigmoid flexure, the lymphatic glands receiving direct vessels from this part of the colon include the epicolic and paracolic glands, the intermediate glands lying on the sigmoid arteries in the mesosigmoid, and the main group glands on the inferior mesenteric artery. The ideal operation in these cases is practically the same as that already described, with the difference that more of the mesosigmoid will be removed, and the gut will be divided above at the junction of the descending colon and the sigmoid flexure. It seems likely that the ideal operation will be terminated, in a large proportion of cases, by a permanent colostomy. If the ideal operation necessitates a colostomy, the comparative disadvantage is so enormous that it will rarely be performed. Lacking as we do sufficient knowledge as to the possibility of anastomosis after excision of the inferior mesenteric trunk, and being unwilling to consider even the possibility of a permanent colostomy after excision of a growth in the middle of a sigmoid flexure, we must perform an operation which removes the majority of the possibly affected glands. This consists in exposing the inferior mesenteric vessels, dividing the peritoneum over them, and stripping off as many glands of the main group as is possible without damaging the vessels. This is done from the point of origin of the left colic artery down to the origin of the lowest sigmoid artery. The sigmoid arteries are tied at their origin, the lowest being preserved if its removal be not necessitated by the position of the growth. The descending colon is then mobilized and the gut divided above, at the junction of the descending colon and the flexure, and below in the lower part of the flexure. Almost the whole of the mesosigmoid will thus be removed, including the intermediate, paracolic, and epicolic

glands, and probably the greatest number of the main group glands corresponding to this part of the sigmoid flexure. The operation is terminated by an anastomosis between the end of the descending colon and the lowest part of the sigmoid flexure.

## 12

In this case I have no doubt that what was at one time thought to be succulent spores were those of megalosporon; and I think that the large-spore Trichophyton is apt to be found in Spring, rather than at any other time. The appearance at once suggests that the large-spored ectothrix has been the origin of the case. I have not come across a microsporon in spontaneous Kerion. The cases of exceptional ringworm produced by large ectothrix fungi are not difficult ones to recognize, but the rare cases produced by the endothrix fungus are very puzzling from the point of view of clinical diagnosis.

The next case presents disseminated, denuded, somewhat irregular areas of the scalp, red and depressed, chiefly on the vertex and sides; also a diffuse thinning of the hair in other parts. The condition is probably *Tinea tonsurans*, most likely of the large-spore variety. The stumps displayed, when examined, typical megalosporon ectothrix.

This patient has a rose-red maculo-lenticular eruption, without itching. A group of raised flat papules developed on the upper part of the chest, over the sternum, which, enlarging circumferentially, became papulo-tubercular; there has also been a moist patch accompanied by sero-purulent exudation. Beyond a slight superficial congestion, the mucous membrane of the mouth and throat is unaffected.

## 13

The disease is not a true inflammatory one, but a progressive ossifying hyperplasia of the connective tissue and fasciae of the striped skeletal muscles. The tendency of this hyperplasia is congenital, but not hereditary. Even slight trauma plays a great part as an exciting cause of the exacerbations, and hence these subjects should be shielded from traumata. The microscopical appearances of the affected parts, the relative absence of constitutional symptoms during the local exacerbations, and the peculiar deformity of the big toes, hallux valgus with microdactyly, found present in many cases, are against adopting any



theory of infection to account for the disease. The bony plates may develop at sites far removed from the periosteum, for instance, in the middle portion of the fascia covering the vastus externus muscle of the thigh. In ordinary localized traumatic myositis ossificans, on the other hand, the ossification appears to spread from the periosteal attachments of muscles and tendons at the site of the traumata, as if osteoblasts and osteoclasts had been let loose from the periosteum as the result of the traumata.

## 14

This patient's case is one of metastatic suppurative iridochoroiditis. Her age is 23, and she attended the hospital complaining of inflammation and defective sight in the right eye. She had a sudden attack of faintness and vomiting, with acute pain in the head and the right eye; her sight was very misty. The right eye was found to be generally congested, with much swelling and chemosis of the conjunctiva and slight mucopurulent discharge. The eyeball was tender to palpation, and there was slight exophthalmos. The pupil was semi-dilated; probably it had been fixed with a mydriatic; the cornea was hazy and oedematous. The anterior chamber was of normal depth, and there was no hypopyon. The condition remained the same for several weeks, except that the congestion and chemosis gradually decreased. When the cornea became clear, it was seen that the anterior chamber was extremely deep. The iris, deeply concave, shelved back towards a greyish-green opaque layer posteriorly, but leaving a distinct interval all round, in which the ciliary processes could be seen. On the concave surface of the iris, and near the posterior opaque layer, was a well-defined complete ring of haemorrhage. There is a complete absence of any sign of the lens, and it is remarkable that in the space of not more than 24 hours the cornea became quite clear.

## 15

The catalytic action of the solutions named, and of organic ferments, is stopped by the action of poisons, such as chloroform or hydrocyanic acid, or by salts precipitating their solution. In that respect the action of colloidal metals can quite be compared to the action of diastases and of natural colloids. There has been now established the almost absolute harmlessness of the action of electrical colloidal silver on animals, either by



ingestion, or by subcutaneous, intravenous, intraperitoneal, or intrapleural injections. The electric colloidal metals have, *in vitro*, a very high antiseptic power, as shown in their effect upon the white or golden staphylococcus, pneumococcus, streptococcus, and colon bacillus. The specific action of silver on the *aspergillus fumigatus* is reinforced by the colloidal state of the metal. There is an elevation of the phagocytic coefficient; it is not because the leucocyte becomes endowed with new properties, but because in the serum some true specific opsonins are formed. Colloidal silver preserves rabbits from ten times the lethal dose of diphtheritic, tetanic, and dysenteric toxins. Even the phenomena of anaphylaxis themselves are influenced by colloidal metals. One can, without making them incur any risk, de-anaphylactize guinea-pigs, producing a state of anti-hypersensibility by injecting into their general circulation 5 to 10 centigrams of electroargol.

## 16

There is also the field of radio-biological research, in which it has been shown that the effect of radio-active agencies on nuclear activity is much more marked during mitosis than during the resting or vegetative periods of the cell. The two or three large germinal cells seen might be detached Malpighian bodies moving to take up new situations in relation to the surrounding proliferation. The few mature leucocytes attract attention by their characteristic amoebism, and the more active contortions when on the point of undergoing mitosis. But the nuclear phases of this process are less clearly seen when displayed in the metamorphosis of the newt's leucocyte or mononucleated white cell, into the more inert nucleated red cell, during the erythrocytosis that follows upon high feeding. In the next series, marginal growth of the connective tissue stroma cells is seen to be proceeding. They appear as fixed radiating fusiform prolongations. In their cytoplasm small spherical granules are seen to stream to and fro in the direction of growth. Doubtless the absence of a capsule or limiting membrane influences the rate of peripheral proliferation. The reason why the bone marrow in adults is seen to be charged with masses of these polynuclear cells is not that they are generated in the myelin matrix as such, but they are there in order to undergo secondary regeneration as mononuclear myelocytes.

AN ABRIDGED CATALOGUE OF THE  
**SHORTHAND, TYPEWRITING**  
 AND  
**STATIONERY PUBLICATIONS**  
 OF  
**SIR ISAAC PITMAN & SONS, LTD.**

---

LONDON: PITMAN HOUSE, PARKER STREET, KINGSWAY, W.C.2.

BATH: The Pitman Press.

MELBOURNE: Pitman House, Little Collins Street.

Associated Companies:

NEW YORK: Pitman Publishing Corporation, 2 West 45th St.

TORONTO: Sir Isaac Pitman & Sons (Canada), Ltd. (incorporating  
 The Commercial Text Book Company), Pitman House, 381-383 Church St.

INDIA: A. H. Wheeler and Co., Bombay, Calcutta and Allahabad.

---

**THE PRICES CONTAINED IN THIS CATALOGUE APPLY ONLY  
 IN GREAT BRITAIN.**

All the Books in this Catalogue are New Era Editions, and in foolscap 8vo size, unless otherwise stated.

---

**CONTENTS**

	PAGE
DICTATION AND SPEED PRACTICE BOOKS . . . . .	5-6
FOREIGN ADAPTATIONS OF PITMAN'S SHORTHAND . . . . .	8
GRAMMALOGUES AND CONTRACTIONS . . . . .	4
PENS AND PENCILS . . . . .	9
SHORTHAND DICTIONARIES . . . . .	4
SHORTHAND INSTRUCTION BOOKS . . . . .	2-3
SHORTHAND PHRASE BOOKS, ETC. . . . .	4
SHORTHAND READING BOOKS . . . . .	6-7
SHORTHAND STATIONERY . . . . .	8-9
SHORTHAND TEACHERS' BOOKS . . . . .	8
TYPEWRITING WORKS . . . . .	9-10
WORKS IN THE ORDINARY TYPE . . . . .	10



## SHORTHAND INSTRUCTION BOOKS

<b>PITMAN'S SHORTHAND TEACHER.</b> An elementary work suited for self-instruction or class teaching . . . . .	9d.
<b>Key</b> . . . . .	9d.
<b>PITMAN'S SHORTHAND EXERCISES.</b> A Series of Graduated Sentence Exercises for use with the <i>Shorthand Teacher</i> . . . . .	3d.
<b>PITMAN'S SHORTHAND PRIMERS.</b> For use in Day Schools and Evening Classes. In three Books: Elementary, Intermediate, and Advanced . . . . .	9d.
<b>Keys to Books I, II, and III</b> . . . . .	9d.
<b>PITMAN'S SHORTHAND READING LESSONS, No. 1</b> . . . . .	8d.
<b>Key</b> . . . . .	4d.
<b>PITMAN'S SHORTHAND READING LESSONS, No. 2</b> . . . . .	8d.
<b>Key</b> . . . . .	4d.
<b>PITMAN'S SHORTHAND READING LESSONS, No. 3</b> . . . . .	8d.
<b>Key</b> . . . . .	4d.
<b>PITMAN'S SHORTHAND COPY BOOKS, Nos. 1, 2, 3, and 4</b> . . . . .	6d.
Foolscap 4to (8 $\frac{3}{4}$ in. $\times$ 6 $\frac{1}{2}$ in.) . . . . .	Each
<b>PROGRESSIVE STUDIES IN PITMAN'S SHORTHAND.</b> A simple and extended exposition of the principles of Pitman's Shorthand . . . . .	2/-
<b>PITMAN'S SHORTHAND INSTRUCTOR.</b> Complete Instruction in the system . . . . .	Cloth 4/6
<b>Key</b> . . . . .	2/-
	Cloth 2/6
<b>SUMMARIES FROM "PITMAN'S SHORTHAND INSTRUCTOR"</b> . . . . .	4d.
Size, 2 $\frac{3}{4}$ in. $\times$ 4 in. . . . .	
<b>GRADED SHORTHAND READINGS—</b>	
Elementary, with Key. In crown 8vo, oblong . . . . .	10d.
Intermediate, with Key. In crown 8vo, oblong . . . . .	10d.
Advanced, with Key. In crown 8vo, oblong . . . . .	10d.
<b>GRADUATED READING EXERCISES IN PITMAN'S SHORTHAND.</b> These exercises are taken from <i>Pitman's Graded Shorthand Readings</i> (Elementary and Intermediate) . . . . .	1/-
<b>PITMAN'S SHORTHAND MANUAL.</b> Contains instruction in the Intermediate Style with 120 exercises. Paper . . . . .	2/6
	Cloth 3/-
<b>Key</b> . . . . .	9d.
<b>SHORTHAND MANUAL READING AND DICTATION EXERCISES</b> . . . . .	9d.
<b>PITMAN'S SHORTHAND GRADUS.</b> Writing Exercises in ordinary print for <i>Manual</i> . . . . .	3d.
<b>PITMAN'S SHORTHAND REPORTER.</b> Containing instruction in the Advanced Style, with 52 Exercises . . . . .	2/-
	Cloth 2/6
<b>Key</b> . . . . .	9d.
<b>REPORTING EXERCISES.</b> Exercises on all the rules and contracted words. In ordinary print, counted for dictation . . . . .	6d.
<b>Key</b> . . . . .	1/-
<b>PITMAN'S SHORTHAND WRITING EXERCISES AND EXAMINATION TESTS.</b> In ordinary print. In crown 8vo. . . . .	2/-
<b>Key.</b> In crown 8vo, cloth . . . . .	3/6
<b>PROGRESSIVE WRITING AND DICTATION EXERCISES.</b> A collection of 82 letters and narrative exercises taken from the larger work, <i>Shorthand Writing Exercises and Examination Tests</i> . In crown 8vo. . . . .	1/-
<b>Key</b> . . . . .	1/6
<b>PROGRESSIVE WORD EXERCISES.</b> Containing exercises selected from the larger work, <i>Shorthand Writing Exercises and Examination Tests</i> . In crown 8vo . . . . .	1/-
<b>Key</b> . . . . .	1/6



<b>EXERCISES ON THE POSITION RULES OF PITMAN'S SHORTHAND.</b> In crown 8vo	1/-
<b>GRADUATED TESTS IN PITMAN'S SHORTHAND.</b> Illustrating all the rules in the Intermediate Style. In notebook form, post 8vo (6½ in. × 4½ in.), with ruled paper	8d.
<b>PITMAN'S SHORTHAND DRILL EXERCISES</b> (8½ in. × 6 in.)	8d.
<b>PITMAN'S PHRASE DRILL NOTEBOOK</b> (8 in. × 5 in.) With Key	6d.
<b>RAPID COURSE IN PITMAN'S SHORTHAND.</b> A series of Twenty Simple Lessons covering the whole of the system. Complete with supplementary exercises. In crown 8vo, cloth	4/6
<b>RAPID COURSE IN PITMAN'S SHORTHAND.</b> Without Appendix	
	Paper 2/-
	Cloth 2/6
<b>Key</b>	2/-
<b>ADDITIONAL EXERCISES ON "PITMAN'S SHORTHAND RAPID COURSE"</b>	10d.
<b>READING EXERCISES ON THE RAPID COURSE.</b> Forming the Key to <i>Additional Exercises on the Rapid Course</i>	1/-
<b>RAPID COURSE READING AND DICTATION EXERCISES</b>	9d.
<b>RAPID COURSE SHORTHAND READER</b>	1/-
<b>SHORTER COURSE IN PITMAN'S SHORTHAND.</b> A brief course for popular use	1/-
<b>Key</b>	6d.
<b>ADDITIONAL EXERCISES ON SHORTER COURSE</b>	6d.
<b>PITMAN'S SHORTHAND COMMERCIAL COURSE.</b> With Exercises Specially adapted for Commercial Students	Cloth 4/6
<b>Key</b>	2/-
<b>ADDITIONAL EXERCISES FOR "PITMAN'S SHORTHAND COMMERCIAL COURSE"</b>	1/-
<b>PITMAN'S SHORTHAND COMMERCIAL COURSE.</b> Without Exercises	2/6
<b>PITMAN'S SHORTHAND COMMERCIAL COURSE.</b> Notebook and Exercises	2/6
<b>READING EXERCISES ON THE SHORTHAND COMMERCIAL COURSE</b>	9d.
<b>THE ONE THOUSAND COMMONEST WORDS.</b> Compiled by Dr. LEONARD P. AYRES	6d.
<b>PITMAN'S SHORTHAND SCHOOL EDITION.</b> For use in day and evening continuation schools. Cloth	2/6
<b>Key</b>	1/-
<b>STUDENTS' SHORTHAND EXERCISES, EXAMINATION GUIDE, AND SPEED TESTS.</b> By A. FIELDHOUSE, F.R.S.A., and E. E. FIELDHOUSE, M.A., LL.B. In crown 8vo, cloth	3/-
<b>TALKS WITH SHORTHAND STUDENTS.</b> By JAMES HYNES	2/-
<b>CHATS ABOUT PITMAN'S SHORTHAND.</b> By GEORGE BLETCHER	2/-
<b>LECTURETTES ON PITMAN'S SHORTHAND.</b> By JAMES HYNES	2/-
<b>FACILITY EXERCISES FOR SHORTHAND STUDENTS.</b> By JAMES HYNES	4d.
<b>PITMAN'S SHORTHAND CATECHISM.</b> Containing over 1,200 questions and answers on the theory of the system. In crown 8vo	2/-
<b>EXAMINATION NOTES ON PITMAN'S SHORTHAND.</b> By H. W. B. WILSON. Crown 8vo, cloth	2/-
<b>WORD AND PHRASE-BUILDING EXERCISES IN PITMAN'S SHORTHAND.</b> By JAMES HYNES	9d.

## GRAMMALOGUES AND CONTRACTIONS

<b>DICTATION TESTS ON THE GRAMMALOGUES AND CONTRACTIONS OF PITMAN'S SHORTHAND.</b> By D. J. GEORGE . . .	1/-
<b>GRAMMALOGUES AND CONTRACTIONS.</b> For use in classes. . .	3d.
<b>VEST POCKET LIST OF GRAMMALOGUES AND CONTRACTIONS OF PITMAN'S SHORTHAND.</b> Size 2½ in. × 1½ in. . .	3d.
<b>HOW TO PRACTISE AND MEMORIZE THE GRAMMALOGUES OF PITMAN'S SHORTHAND.</b> Compiled by D. J. GEORGE. Size 7½ in. × 5 in. . .	6d.
<b>GRAMMALOGUE CHARTS.</b> Size 23 in. × 36 in. . .	2/6
<b>REVISION EXERCISES ON THE GRAMMALOGUES AND PHRASE WRITING.</b> By JAMES HYNES . . .	3d.
<b>GRAMMALOGUE AND CONTRACTION DRILL BOOK.</b> Size 8 in. by 5 in., notebook form, 40 pp. . .	6d.

## SHORTHAND DICTIONARIES

<b>PITMAN'S SHORTHAND DICTIONARY.</b> Contains the shorthand forms, fully vocalized, for over 62,000 words. In crown 8vo Cloth	7/6
<b>PITMAN'S POCKET SHORTHAND DICTIONARY.</b> Royal 32mo (3½ in. × 4½ in.) . . .	Cloth 2/6 Leather 3/6
<b>PITMAN'S ENGLISH AND SHORTHAND DICTIONARY.</b> Edited by A. REYNOLDS, M.A. Contains concise definitions as well as shorthand forms. In crown 8vo. . .	10/-

## SHORTHAND PHRASE BOOKS, ETC.

<b>SHORTHAND WRITERS' PHRASE BOOK AND GUIDE.</b> Each includes about 1,500 Technical Terms and Phrases with Shorthand equivalents. Each in fcap. 8vo, about 92 pp. . .	2/-
Banking	Legal
Commercial	Railway
Insurance	Electrical and Engineering
<b>PHONOGRAPHIC PHRASE BOOK.</b> Over 2,400 useful general Phrases . . .	1/6 Cloth 2/-
<b>REPORTERS' PHRASE BOOK.</b> By K. S. AIYAR, B.A. Contains a valuable list of phrases and "short-cuts." In crown 8vo. . .	2/-
<b>MEDICAL REPORTING IN PITMAN'S SHORTHAND.</b> By H. DICKINSON. With an Introduction and Lists of Phraseograms, Outlines, and Abbreviations. In crown 8vo, cloth . . .	3/6
<b>TECHNICAL REPORTING.</b> By THOMAS ALLEN REED . . .	3/6
<b>POLICE PHRASE BOOK AND VOCABULARY</b>	1/-
<b>CIVIL SERVICE SHORTHAND WRITER'S PHRASE BOOK.</b> Compiled by A. MARSHALL, P.C.T. . .	2/-
<b>MOTOR TRADE PHRASE BOOK AND VOCABULARY</b>	1/-
<b>SUPPLEMENTARY PHRASE BOOK.</b> By A. GUILDFORD REFFELL. . .	1/6
<b>ABASCRIPIT.</b> By G. P. LELY. For writing figures, sums of money, etc., at voice speed. Size 6 in. by 9 in. 40 pp. . .	3/-
<b>JAB FIGURES.</b> By G. P. LELY. A useful book for Pitman Shorthand Writers, representing in an abbreviated manner, telephone and car numbers, Sizes 6½ in. by 4½ in. . .	6d.

## DICTATION AND SPEED PRACTICE BOOKS

<b>VOCABULARY BUILDING IN PITMAN'S SHORTHAND.</b> By JAMES HYNES . . . . .	9d.
<b>Key</b> . . . . .	9d.
<b>GRADED LITERARY DICTATOR.</b> For theory and elementary speed classes. In crown 8vo, 64 pp. . . . .	1/-
<b>GRADED LITERARY SHORTHAND READER.</b> Forms the key to <i>Graded Literary Dictator</i> . In crown 8vo, 90 pp. . . . .	1/6
<b>PRACTICAL DICTATION EXERCISES FOR BEGINNERS.</b> In crown 8vo, 48 pp. . . . .	9d.
<b>REPORTING PRACTICE.</b> Dictation Exercises in ordinary type, marked in 20's and 30's. In crown 8vo. . . . .	3/6
<b>DICTATION PRACTICE IN BUSINESS CORRESPONDENCE.</b> A collection of business letters relating to various trades and professions. In crown 8vo . . . . .	1/-
<b>GUIDE TO HIGH SPEED WRITING IN PITMAN'S SHORTHAND.</b> By EMILY D. SMITH, F.C.T.S., and A. JEFFREY MUNRO, F.C.T.S. In crown 8vo . . . . .	2/6
<b>SHORTHAND CANDIDATE'S DICTATION EXERCISES.</b> Nos. I and II. In crown 8vo. . . . .	2/-
<b>BUSINESS LETTERS FOR DICTATION.</b> In crown 8vo, cloth . . . . .	3/6
<b>Key, in Shorthand</b> . . . . .	3/6
<b>GRADUATED COMMERCIAL LETTERS FOR DICTATION EXERCISES IN LETTER WRITING IN PITMAN'S SHORTHAND.</b> By A. H. GILBERTSON, A.C.I.S. 7 $\frac{3}{8}$ in. by 5 $\frac{1}{2}$ in. . . . .	1/-
<b>TEST EXERCISES IN PITMAN'S SHORTHAND</b> . . . . .	6d.
<b>TEST EXERCISES IN PITMAN'S SHORTHAND, KEY TO</b> . . . . .	9d.
<b>TESTS FOR SPEED STUDENTS.</b> In crown 8vo. . . . .	2/-
<b>SPEED TESTS AND GUIDE TO RAPID WRITING IN SHORTHAND.</b> In crown 8vo. . . . .	2/6
<b>ELEMENTARY EXAMINATION SPEED TESTS.</b> In crown 8vo. . . . .	8d.
<b>FIVE-MINUTE SPEED TESTS (Second Series).</b> The speeds range from 80-160 words a minute. In crown 8vo. . . . .	1/6
<b>FOUR-MINUTE SPEED TESTS.</b> The speeds range from 80-140 words a minute. In crown 8vo. . . . .	1/6
<b>SEVEN-MINUTE SPEED TESTS.</b> In crown 8vo. . . . .	1/6
<b>PUBLIC EXAMINATION SPEED TESTS.</b> The speeds range from 50-160 words a minute. In crown 8vo. . . . .	2/-
<b>HIGH SPEED IN PITMAN'S SHORTHAND.</b> By K. S. AIYAR, B.A. In crown 8vo. . . . .	2/-
<b>LIGHTNING SHORT CUTS TO HIGH SPEED IN PITMAN'S SHORTHAND.</b> By K. S. AIYAR, B.A. . . . .	2/6
<b>CUMULATIVE SPELLER AND SHORTHAND VOCABULARY.</b> By CHARLES E. SMITH. In crown 8vo, cloth . . . . .	2/-
<b>SHORTHAND SPEED CLASS.</b> By J. C. COSTELLO. In crown 8vo . . . . .	6d.
<b>SPEED PRACTICE.</b> In crown 8vo. . . . .	2/-
<b>SPEED TRAINING IN PITMAN'S SHORTHAND.</b> By T. F. MARRINER. . . . .	6d.
<b>ACQUISITION OF SPEED IN SHORTHAND.</b> By E. A. COPE. In ordinary print. In crown 8vo . . . . .	1/-
<b>THEORY TESTS IN PITMAN'S SHORTHAND (First and Second Series).</b> For Advanced, Theory, and Speed classes, with Key. In crown 8vo . . . . .	Each 8d.



<b>MISCELLANEOUS DICTATION TESTS FOR SHORTHAND STUDENTS.</b> In crown 8vo. . . . .	2/-
<b>BROWN'S SHORT-CUTS IN SHORTHAND.</b> By GEORGE BROWN, F.I.P.S. In crown 8vo. . . . .	1/-
<b>SHORTHAND COMMERCIAL LETTER-WRITER.</b> Advanced Style Key . . . . .	1/6 1/-
<b>THE SHORTHAND COMMERCIAL LETTER-WRITER AND KEY,</b> in one volume . . . . .	Cloth 2/6
<b>COMMERCIAL CORRESPONDENCE IN SHORTHAND.</b> Advanced Style. In crown 8vo . . . . .	Cloth 3/6
<b>BUSINESS CORRESPONDENCE IN SHORTHAND.</b> Advanced Style Key . . . . .	1/6 1/-
<b>ONE-SESSION DICTATION BOOK</b> . . . . .	1/-
<b>SECOND SESSION DICTATION BOOK.</b> In crown 8vo. . . . .	1/6
<b>MISCELLANEOUS CORRESPONDENCE IN PITMAN'S SHORTHAND.</b> First, Second, Third, and Fourth Series. Advanced Style with Keys in ordinary print. Each in crown 8vo, oblong . . . . .	1/6
<b>BRIEF REPORTING EXERCISES IN PITMAN'S SHORTHAND.</b> Consisting of Exercises in Advanced Phraseography, with Key counted in 10's for dictation. In crown 8vo . . . . .	1/6
<b>FACILITY NOTEBOOK FOR SHORTHAND STUDENTS.</b> A notebook with lines of shorthand for copying. 5 in. by 8 in. . . . .	6d.
<b>THE PRACTICAL PHRASER.</b> By JAMES HYNES. A series of phrase-writing exercises in shorthand only. Advanced Style. 5½ in by 7 in. . . . .	1/-

### PITMAN'S SHORTHAND READING BOOKS

In the Elementary Style.

<b>A RACE AGAINST TIME, AND OTHER STORIES</b> . . . . .	9d.
<b>READING LESSONS, No. 1</b> . . . . .	8d.
<b>Key</b> . . . . .	4d.
<b>SHORT STORIES.</b> Vols. I and II. A collection of interesting tales . . . . .	Each 9d.

In the Intermediate Style.

<b>READING LESSONS, No. 2</b> . . . . .	8d.
<b>Key</b> . . . . .	4d.
<b>PITMAN'S SHORTHAND READER, No. 1.</b> Containing extracts from standard authors, including Shakespeare, Charles Lamb, Hazlitt, Wordsworth, Pope, Kingsley, and Ruskin. With Key in ordinary print . . . . .	8d.
<b>TALKS ON COMMERCIAL TOPICS.</b> By W. J. WESTON, M.A., B.Sc. A specially suitable reader for Commercial Students. In crown 8vo . . . . .	1/-
<b>THE BATTLE OF LIFE.</b> By CHARLES DICKENS. Cloth . . . . .	2/-
<b>TALES AND SKETCHES.</b> By WASHINGTON IRVING; with Key in ordinary print . . . . .	2/-
<b>A DAUGHTER OF THE REGIMENT, AND OTHER STORIES.</b> Three stories by various authors . . . . .	1/-
<b>THE COBBLER, AND OTHER STORIES.</b> Three stories by various authors . . . . .	1/-
<b>GULLIVER'S VOYAGE TO LILLIPUT.</b> By JONATHAN SWIFT . . . . .	1/6
<b>ALICE IN WONDERLAND.</b> By LEWIS CARROLL . . . . .	Cloth 2/- 2/-

## In the Advanced Style.

<b>READING LESSONS, No. 3</b> . . . . .	8d.
<b>Key</b> . . . . .	4d.
<b>PITMAN'S SHORTHAND READER, No. 2.</b> Containing extracts from Addison, Dickens, Robert Louis Stevenson, Wordsworth, George Eliot, etc. Key in ordinary print . . . . .	8d.
<b>VARIED SHORTHAND READINGS.</b> A collection of literary extracts. Crown 8vo. . . . .	1/4
<b>SHORTHAND READING EXERCISES IN BUSINESS CORRESPONDENCE.</b> Size, 7 in. by 5 in. . . . .	1/-
<b>Key,</b> counted for Dictation . . . . .	10d.
<b>HALF HOURS WITH POPULAR AUTHORS.</b> Compiled by A. JEFFREY MUNRO. Vols I, II, III, and IV . . . . .	1/-
<b>READINGS FROM POPULAR AUTHORS.</b> Compiled by A. JEFFREY MUNRO. A delightful introduction to modern and classical literature. Vols. I, II, III, and IV . . . . .	1/-
<b>A CHRISTMAS CAROL.</b> By CHARLES DICKENS . . . . .	1/3
Cloth	2/-
<b>TALES FROM DICKENS.</b> Containing "The Tuggs's at Ramsgate," "The Bloomsbury Christening," "The Great Winglebury Duel," and "Mr. Watkins Tottle," from <i>Sketches by Boz</i> . Seventeen illustrations by P. Hudson. Cloth . . . . .	2/6
<b>THE STRANGE CASE OF DR. JEKYLL AND MR. HYDE.</b> By ROBERT LOUIS STEVENSON . . . . .	1/6
Cloth	2/-
<b>THE SIGN OF FOUR.</b> By Sir A. CONAN DOYLE. A complete Phonographic transcript of the famous "Sherlock Holmes" novel . . . . .	2/6
Cloth	
<b>SELECTED EXTRACTS FROM FAVOURITE AUTHORS.</b> Compiled by A. JEFFREY MUNRO. Vols. I, II, III, and IV . . . . .	1/-
<b>THE RETURN OF SHERLOCK HOLMES.</b> By Sir A. CONAN DOYLE. In three vols. Each cloth . . . . .	2/6
<b>TALES OF ADVENTURE AND MEDICAL LIFE.</b> By SIR A. CONAN DOYLE . . . . .	1/3
<b>THANKFUL BLOSSOM.</b> By BRET HARTE . . . . .	2/-
<b>KEYNOTES OF SUCCESS.</b> In shorthand and letterpress . . . . .	1/-
<b>SELECTIONS FROM AMERICAN AUTHORS.</b> With Key in ordinary print . . . . .	1/6
<b>THE LEGEND OF SLEEPY HOLLOW.</b> By WASHINGTON IRVING. With Key in ordinary print . . . . .	9d.
<b>RIP VAN WINKLE.</b> By WASHINGTON IRVING. With Key in ordinary print. Three illustrations . . . . .	8d.
<b>WAR OF INDEPENDENCE.</b> By JOHN FISKE . . . . .	2/6
<b>THE SILENT JUDGE AND OTHER STORIES.</b> By MAXWELL CROOKS . . . . .	1/-
<b>RANDOM REFLECTIONS.</b> By HAROLD DOWNS. With letterpress Key. In crown 8vo. . . . .	1/-
<b>GARDEN OF THE SOUL.</b> In Pitman's Shorthand, freely vocalized and beautifully reproduced. Compiled from authorized sources. Centenary Edition. In cloth gilt, 5 in. by 3 in. . . . .	3/6
<b>THE BOOK OF PSALMS.</b> From the Authorized Version of the Bible. Crown 8vo. cloth gilt. red edges . . . . .	3/6
<b>NEW TESTAMENT IN SHORTHAND.</b> Authorized Version. Cloth gilt . . . . .	6/-
Roan gilt	7/6

## FOREIGN ADAPTATIONS OF PITMAN'S SHORTHAND

<b>FRENCH PHONOGRAPHY.</b> By T. A. REED. Rules in English; Examples, etc., in French. Fourth Edition	2/-
<b>FRENCH SHORTHAND COMMERCIAL CORRESPONDENCE.</b> By T. A. REED. With a Key. Cloth	1/6
<b>STENOGRAPHIE PITMAN.</b> By SPENCER HERBERT. Cloth	3/-
<b>HOW TO ADAPT PITMAN'S SHORTHAND TO FRENCH.</b> By W. H. OLLIVE. In foolscap 4to	1/-
<b>CORRESPONDENCE COMMERCIALE EN STENOGRAPHIE PITMAN.</b> By SPENCER HERBERT. Cloth	3/-
<b>GERMAN SHORTHAND.</b> In German and English. In cr. 8vo. Cloth	4/-
<b>LATIN PHONOGRAPHY.</b> By Rev. W. TATLOCK, S. J. Rules in Latin	
Cloth	2/6
<b>SPANISH SHORTHAND.</b> In Spanish. Fifth Edition. Rules in Spanish	
Cloth	3/6
<b>Key</b>	2/6
<b>SPANISH SHORTHAND DICTIONARY.</b> In crown 8vo. Cloth	7/6
<b>TAQUIGRAFIA ESPANOLA CORRESPONDENCIA.</b> Commercial Correspondence Exercises. Cloth	1/6
<b>GAELIC SHORTHAND.</b> In crown 8vo, cloth	2/6
<b>AFRIKAANSE SHORTHAND.</b> In crown 8vo. Second Edition. Cloth	6/-
<b>Key</b>	3/6
<b>AFRIKAANSE SHORTHAND DICTATION BOOK.</b> By A. GELDENHUY. In crown 8vo	2/-
<b>ITALIAN SHORTHAND.</b> By P. P. DE CESARE. In crown 8vo	3/6

## SHORTHAND TEACHERS' BOOKS

<b>PITMAN'S SHORTHAND AND ENGLISH.</b> By W. F. DINGWALL, M.A., and J. HYNES. Crown 8vo. Cloth	2/6
<b>NOTES OF LESSONS ON PITMAN'S SHORTHAND.</b> By J. E. McLACHLAN. Crown 8vo. Cloth	2/6
<b>THE SHORTHAND TEACHER'S EXAMINATION: HOW TO PREPARE FOR IT.</b> By J. E. McLACHLAN. In crown 8vo. Cloth	2/6
<b>A COMMENTARY ON PITMAN'S SHORTHAND.</b> For Advanced Students and Teachers. By J. W. TAYLOR	5/-
<b>PRINCIPLES OF TEACHING APPLIED TO PITMAN'S SHORTHAND</b> By R. W. HOLLAND, O.B.E., M.A., M.Sc., LL.D. In crown 8vo	2/6
<b>TIPS TO TEACHERS OF PITMAN'S SHORTHAND AND OTHER COMMERCIAL SUBJECTS.</b> By J. HYNES. In crown 8vo.	1/-
<b>CHART OF THE PHONOGRAPHIC ALPHABET.</b> 22 in. x 35 in.	2d.
<b>DERIVATIVE AND COMPOUND WORDS IN PITMAN'S SHORTHAND.</b> By W. H. B. WILSON	2/-

## SHORTHAND STATIONERY

*In ordering through a bookseller, state particularly "Fono" series and the register number which is printed on each copy.*

<b>No. 1.</b> —80 pp., red lines, suitable for pen or pencil; with the Grammalogues printed inside the cover	Price 2d.
By post 3d.; six copies, by post, 1s. 3d.	
<b>No. 2.</b> —140 pp., red lines, suitable for pen or pencil; with the Grammalogues inside the cover	Price 3d.
By post, 4d.; six copies, by post, 1s. 11d.	
<b>No. 3.</b> —180 pp., with the Contracted Words inside the cover.	Price 5d.
By post, 6½d.	



- No. 4.—90 pp., superior paper, elastic back, flat opening . . . Price 4d.  
By post, 5d.
- No. 4a.—180 pp., superior paper, elastic binding; with List of Long-hand Press Contractions and Press Telegraph Regulations printed inside the cover. By post, 9d. . . . Price 7d.
- No. 5.—180 pp., 8 in. × 5 in., elastic binding to open flat or stitched . . . Price 8d.  
By post, 10d. Single lines . . . . .
- No. 5W.—180 pp., 8 in. × 5 in. Wider lines and red ruling. By post, 10d. . . . . Price 8d.
- No. 19.—140 pp., 9 in. × 4½ in., superior paper, red lines, red marginal lines . . . . . Price 8d.  
By post, 10d. This notebook forms a refill to Pitman's Notebook Cover and Transcribing Slope.
- No. 20.—200 pp., 8½ in. × 5½ in., elastic binding, single lines, stiff boards, marginal red lines . . . . . Price 1/-  
By post, 1s. 3d.
- No. 21.—"S.-O." 180 pp., 8 in. × 5 in., elastic binding, single lines, side opening. By post, 11d. . . . . Price 9d.
- SHORTHAND NOTEBOOK, No. 22.—Size 8½ in. × 5½ in., 156 pp. By post, 6½d. . . . . Price 4d.
- NOTEBOOK COVER AND TRANSCRIBING SLOPE, 9 in. × 5 in., cloth. This cover folds back and, being kept at the required angle by a piece of elastic, remains in a convenient position for transcribing . . . . . Price 2/6  
Including Notebook, 3s. 2d.; by post, 3s. 5d.  
Refills, price 8d.; by post, 10d.

## PENS AND PENCILS

- PITMAN'S "FONO" FOUNTAIN PEN, No. 3 (Mottled Brown). 14-carat Solid Gold Nib Iridium tipped, Box Lever Filling Device. Pocket Safety Clip and Rolled Gold Bands. . . . . 15/-
- PITMAN'S "FONO" LEVER SELF-FILLING FOUNTAIN PEN. . . . . 7/6  
With rolled gold band and larger nib . . . . . 10/6
- PITMAN'S "FONO" PENCIL . . . . . Each 2d.
- SPECIAL SHORTHAND PENCIL. . . . . Each 4d.

## TYPEWRITING WORKS

- PITMAN'S COMMERCIAL TYPEWRITING. By W. and E. WALMSLEY. Large post 4to . . . . . Cloth 5/-
- BUSINESS TYPEWRITING. By F. HEELIS. Large post 4to . . . . . 2/-
- PITMAN'S KEYBOARD MASTERY COURSE. By MAXWELL CROOKS. The book is prepared for use with Pitman's *Gramophone Course of Keyboard Instruction*. Large post 4to . . . . . 1/6
- PITMAN'S GRAMOPHONE COURSE OF TYPEWRITER KEYBOARD INSTRUCTION. Arranged by MAXWELL CROOKS. Complete, in strong case, together with one copy of *Instruction Book*. Comprising twelve 10 in. records (six discs) . . . . . Net 35/-
- TOUCH TYPEWRITING FOR TEACHERS. By MAXWELL CROOKS . . . . . Net 7/6  
Demy 8vo, cloth . . . . .
- TYPIST'S COMPANION, THE. By MAXWELL CROOKS. In crown 8vo cloth . . . . . 2/-
- TYPEWRITING EXAMINATION TESTS (R.S.A.). By ALBERT POTTS. In three books. Each in foolscap folio. . . . .
- Stage I. Elementary . . . . . 2/6
- Stage II. Intermediate . . . . . 2/6
- Stage III. Advanced . . . . . 3/6
- TOUCH TYPEWRITING MADE EASY. By G. B. WRIGHT. Large post 4to . . . . . 2/6

<b>TOUCH TYPEWRITING EXERCISES.</b> By T. J. SIMONS, F.C.T.S., F.I.P.S. Large post 4to . . . . .	1/6
<b>THE JUNIOR TYPIST.</b> By ANNIE E. DAVIS. In demy 8vo, cloth. Second Edition, Revised . . . . .	1/6
<b>NEW COURSE IN TYPEWRITING.</b> By Mrs. SMITH-CLOUGH. Large post 4to. Second Edition, Revised . . . . .	2/-
<b>A TYPEWRITING CATECHISM.</b> By Mrs. SMITH-CLOUGH. Large post 4to. Fifth Edition. Revised . . . . . <b>Net</b>	5/-
<b>PITMAN'S TYPEWRITER MANUAL.</b> Can be used with any machine. Seventh Edition. Large post 4to . . . . . <b>Cloth</b>	5/-
<b>PITMAN'S EXERCISES AND TESTS IN TYPEWRITING.</b> Compiled and arranged by W. WALMSLEY. Fcap. folio. Third Edition . . . . .	4/-
<b>ADVANCED TYPEWRITING.</b> By F. HEELIS. . . . .	3/6
<b>TYPEWRITER KEYBOARD CHARTS</b> . . . . . <b>Each</b>	3d.
<b>DICTIONARY OF TYPEWRITING.</b> (H. ETHERIDGE). Third Edition revised by MAXWELL CROOKS and F. DAWSON, F.C.T.S. In demy 8vo, cloth . . . . .	5/-
<b>HIGH SPEED IN TYPEWRITING.</b> By A. M. KENNEDY and F. JARRETT. Demy 4to . . . . .	2/6
<b>"FONO" LETTER-HEADINGS FOR TYPEWRITING STUDENTS</b> . . . . .	1/-
<b>QUESTIONS AND ANSWERS ON TYPEWRITING AND OFFICE PROCEDURE.</b> By ARTHUR E. MORTON. Large post 4to, cloth,	7/6
<b>THE BOOK OF THE UNDERWOOD TYPEWRITER.</b> By MAXWELL CROOKS. In crown 8vo. . . . . <b>Net</b>	2/6
<b>THEORY OF TYPEWRITING.</b> By FLORENCE LOCKEY. Large Post 4to.	6/-
<b>ELEMENTARY TYPEWRITING.</b> Being Part I of <i>The Theory of Typewriting.</i> By FLORENCE LOCKEY. Large post 4to . . . . .	2/-
<b>DUPLICATING AND COPYING PROCESSES.</b> By W. DESBOROUGH, O.B.E., F.C.I. Demy 8vo, cloth gilt . . . . . <b>Net</b>	5/-
<b>PITMAN'S TIKSKRIF.</b> By J. E. W. BEYER, P.C.T., F.C.T.S., and G. P. SCHEEPERS, B.A., B.C.D. In foolscap folio . . . . .	7/-
<b>TOETSBOARDKURSUS (AFRIKAANSE TYPEWRITING EXERCISES).</b> By J. E. W. BEYER, P.C.T., F.C.T.S., and G. P. SCHEEPERS, B.A., B.C.D. Demy 4to . . . . .	2/-

### WORKS IN ORDINARY TYPE

<b>LIFE OF SIR ISAAC PITMAN.</b> By ALFRED BAKER. In demy 8vo. With many illustrations, cloth . . . . .	5/-
<b>THE SHORTHAND WRITER.</b> By T. A. REED. In crown 8vo, cloth	3/-
<b>HISTORY OF SHORTHAND.</b> Fourth Edition, Revised. . . . .	6/-

# PITMAN'S COMMERCIAL TEXTBOOKS

## A SELECTION

---

### COMMERCE

<b>COMMERCE, Stage I.</b> By ALONZA JAMES, F.F.T.Com., F.R.Econ.S.	2/6
<b>COMMERCE FOR COMMERCIAL AND SECONDARY SCHOOLS.</b> By A. J. FAVELL, B.Sc.(Econ.), A.C.I.S.	3/6
<b>MANUAL OF BUSINESS TRAINING.</b> 11th Edition. By A. STEPHEN NOEL, F.R.Econ.S.	4/-
<b>BUSINESS HANDWRITING.</b> By W. BURTON	1/6

### ARITHMETIC

<b>BUSINESS ARITHMETIC. Part I.</b> Revised by IVOR T. PLANT.	2/6
Answers	1/6
<b>BUSINESS ARITHMETIC. Part II.</b> Revised by IVOR T. PLANT.	2/6
Answers	1/3
<b>COMPLETE BUSINESS ARITHMETIC.</b> Revised by IVOR T. PLANT.	4/-
Answers	Net 2/6
<b>ARITHMETIC CLASS BOOK.</b> By W. R. BARHAM, L.C.P. With Answers	2/6

### BOOK-KEEPING

<b>SHARLES'S ELEMENTARY BOOK-KEEPING</b>	2/6
<b>BOOK-KEEPING, STAGE I.</b> By A. J. FAVELL, B.Sc. (Econ.), A.C.I.S.	2/6
<b>BOOK-KEEPING, STAGE II.</b> By A. J. FAVELL, B.Sc. (Econ.), A.C.I.S.	3/6
<b>PRINCIPLES OF ACCOUNTS, PART I.</b> By J. STEPHENSON, M.A., M.Com., D.Sc.	3/6
<b>PRINCIPLES OF ACCOUNTS, PART II.</b> By J. STEPHENSON, M.A., M.Com., D.Sc.	5/-

### GEOGRAPHY

<b>INTRODUCTION TO ECONOMIC GEOGRAPHY.</b> By J. DAVIES, M.Sc.	3/6
<b>COMMERCIAL GEOGRAPHY OF THE WORLD.</b> By W. P. RUTTER, M.Com. Revised Edition	6/-

### HISTORY

<b>COMMERCIAL HISTORY.</b> By J. R. V. MARCHANT, M.A.	5/6
<b>THE RISE OF BRITISH COMMERCE.</b> By K. G. LEWIS, B.A., and N. BRANTON, B.Com.	3/6

### COMMERCIAL CORRESPONDENCE AND ENGLISH

<b>GUIDE TO COMMERCIAL CORRESPONDENCE AND BUSINESS COMPOSITION.</b> By W. J. WESTON, M.A. (Lond.), B.Sc. (Lond.)	2/6
<b>BUSINESS LETTERS IN ENGLISH.</b> By W. J. WESTON	3/6
<b>COMMERCIAL CORRESPONDENCE AND COMMERCIAL ENGLISH.</b>	3/6
<b>ENGLISH AND COMMERCIAL CORRESPONDENCE.</b> By HIROMU NAGAOKA AND DANIEL THEOPHILUS, B.A.	3/6

### LANGUAGES

<b>COMMERCIAL FRENCH GRAMMAR.</b> By F. W. M. DRAPER, M.A.	2/6
<b>COMMERCIAL GERMAN GRAMMAR, PITMAN'S.</b> By BITHELL, M.A.	3/6

---

Sir Isaac Pitman & Sons, Ltd. Parker St. Kingsway, W.C.2



AN UP-TO-DATE REFERENCE

# PITMAN'S DICTIONARY OF TYPEWRITING

BY

**H. ETHERIDGE**

THIRD EDITION

Revised by MAXWELL CROOKS  
and FREDERICK DAWSON, F.C.T.S.

This great standard Reference Work gives every possible detail of typewriting information. Typewriter mechanism is explained. Modern typewriters are dealt with in full. Hints on operation are given. There are articles on duplicating, commercial correspondence, display, tabulation, dramatic work, legal work, machine maintenance and care, typewriting examinations, etc. The illustrations and examples of typewritten work given enable you to get a deep insight into every important point raised in practical work and in examination study.

Cloth, 334 pp. Fully illustrated. 5s.

---

Sir Isaac Pitman & Sons, Ltd. Parker St. Kingsway, W.C.2

# PITMAN'S ENGLISH AND SHORTHAND DICTIONARY

NEW ERA EDITION

In crown 8vo, cloth gilt, 850 pp., 10s.

CONTAINING concise definitions and shorthand forms, fully vocalized, for over 60,000 words; a separate list of Proper Names; alphabetical lists of Grammalogues and Contractions; and a valuable Analytical Introduction dealing with the formation of outlines for various classes of words; an Appendix containing lists of Latin and Greek prefixes, commercial terms and phrases in five languages, and foreign words, phrases, and sayings. The definitions are supplied by MR. ARTHUR REYNOLDS, M.A. (Oxon).

## PITMAN'S SHORTHAND DICTIONARY

NEW ERA EDITION

In crown 8vo, cloth gilt, 390 pp., 7s. 6d.

CONTAINS the shorthand forms, fully vocalized, for 62,000 words; a separate list of Proper Names of Persons and Places; and alphabetical lists of all the Grammalogues and Contractions employed in the system. A valuable Analytical Introduction, which deals at length with the treatment of particular classes of words, is included.

## PITMAN'S POCKET SHORTHAND DICTIONARY

NEW ERA EDITION

WITH A COMPLETE LIST OF GRAMMALOGUES  
AND CONTRACTIONS.

Cloth, 236 pp., 3½ in. by 4¾ in., 2s. 6d.

Also in Leather, 3s. 6d.

CONTAINING a representative collection of words with their shorthand forms fully vocalized.

---

Sir Isaac Pitman & Sons, Ltd. Parker St. Kingsway, W.C.2

PITMAN'S  
"FONO" SELF-FILLING  

---

FOUNTAIN PENS

---



are specially made for shorthand writers. They give maximum service at a price well within the reach of students, and can be recommended without reserve to all shorthand and longhand writers. There are three models from which to select—

**"FONO" FOUNTAIN PEN, No. 1.**  
(Illustrated.) **7s. 6d.**

Black vulcanite barrel, fitted with lever self-filling device, 14-carat solid gold nib, iridium-tipped, and pocket clip.

**"FONO" FOUNTAIN PEN, No. 2.**  
(Presentation Style.) **10s. 6d.**

Similar to No. 1, with a larger nib and finished with rolled gold band and clip

**SUPER "FONO" FOUNTAIN PEN,**  
**No. 3. 15s.**

A super pen in every detail, handsomely finished in mottled brown and black, and fitted with 14-carat solid gold nib, iridium-tipped, and with box-lever self-filling device.



Every "Fono" Fountain Pen is thoroughly tested and fully guaranteed. Nibs are supplied to suit all writers.

---

Sir Isaac Pitman & Sons, Ltd. Parker St. Kingsway, W.C.2



# PITMAN'S SHORTHAND WEEKLY

Established 1892. Every Saturday. Foolscap 4to. 16 pages, 2d.; by post 2½d. Half-yearly volumes commence in April and October.

An illustrated miscellany of entertaining reading in Pitman's Shorthand, adapted for students in all stages. Twelve pages of Shorthand, in wrapper. The contents include a serial story by an eminent novelist, and in nearly every number there are one or more short stories, effectively illustrated by various artists. Amusing extracts, jokes, and anecdotes are given from time to time. Illustrated articles deal in a bright and entertaining style with topics of general interest. The WEEKLY may be ordered of all booksellers and newsagents or direct from the Publishers. The subscription rates are: 3 months, by post 2s. 9d.; 6 months, by post 5s. 5d.; 12 months, by post 10s. 10d., and monthly parts 10d., by post 11d.

## Pitman's Year Book and Diary


Edited by HAROLD DOWNS

In crown 8vo, cloth, 192 pp. 1s. 6d. net.

Published in November of each year.

---

Sir Isaac Pitman & Sons, Ltd. Parker St. Kingsway, W.C.2



# Pitman's Journal OF Commercial Education

FOUNDED BY SIR ISAAC PITMAN IN 1842

Every Saturday, 2d., by post 3d. Monthly, in a wrapper, 10d., by post 1s. Can be ordered from any Newsagent or Bookstall. Half-yearly volumes commence in April and October.


The only weekly periodical of its kind and the recognized organ of Commercial Education, now deals comprehensively with all aspects of Commercial Education, and is of maximum value to all students who are preparing for professional examinations or who are fitting themselves by self-study for responsible positions in the commercial world. Both junior and senior students are catered for, and in addition to all the popular subjects of a commercial course—Pitman's Shorthand, Typewriting, Book-keeping and Accountancy, Arithmetic, English Grammar and Composition, French, Spanish, and German, etc.—the various subjects of Professional and Secretarial Courses—Commercial Law, Company Law, Secretarial Practice, Commercial History, Commercial Geography, Psychology, Economics, Banking, Advertising Salesmanship, Shipping, and Insurance, etc.—are adequately treated in authoritative articles by experts.

Subjects of interest to commercial students and commercial and professional workers are also dealt with in leading articles and in notes, etc., and there are eight pages of printed shorthand, with key, and one page without key. "Answers to Correspondents" forms a link between students and the Editor, who is always pleased to help students to overcome their difficulties.

PITMAN'S JOURNAL OF COMMERCIAL EDUCATION can also be had by post DIRECT from the Publishers. The terms are: 3 months, by post 3s. 3d.; 6 months, by post 6s. 6d. 12 months, by post, 13s.

---

Sir Isaac Pitman & Sons, Ltd. Parker St. Kingsway, W.C.2





LIBRARY  
THE PACKARD SCHOOL

253 Lexington Avenue

NEW YORK CITY

Date Due

MAR 12 1947

FEB 18 1948



653

1590

D

Dickinson

AUTHOR

Medical reporting in Pitman's

TITLE

653

1590

D

LIBRARY

THE PACKARD SCHOOL

253 Lexington Avenue

NEW YORK CITY



