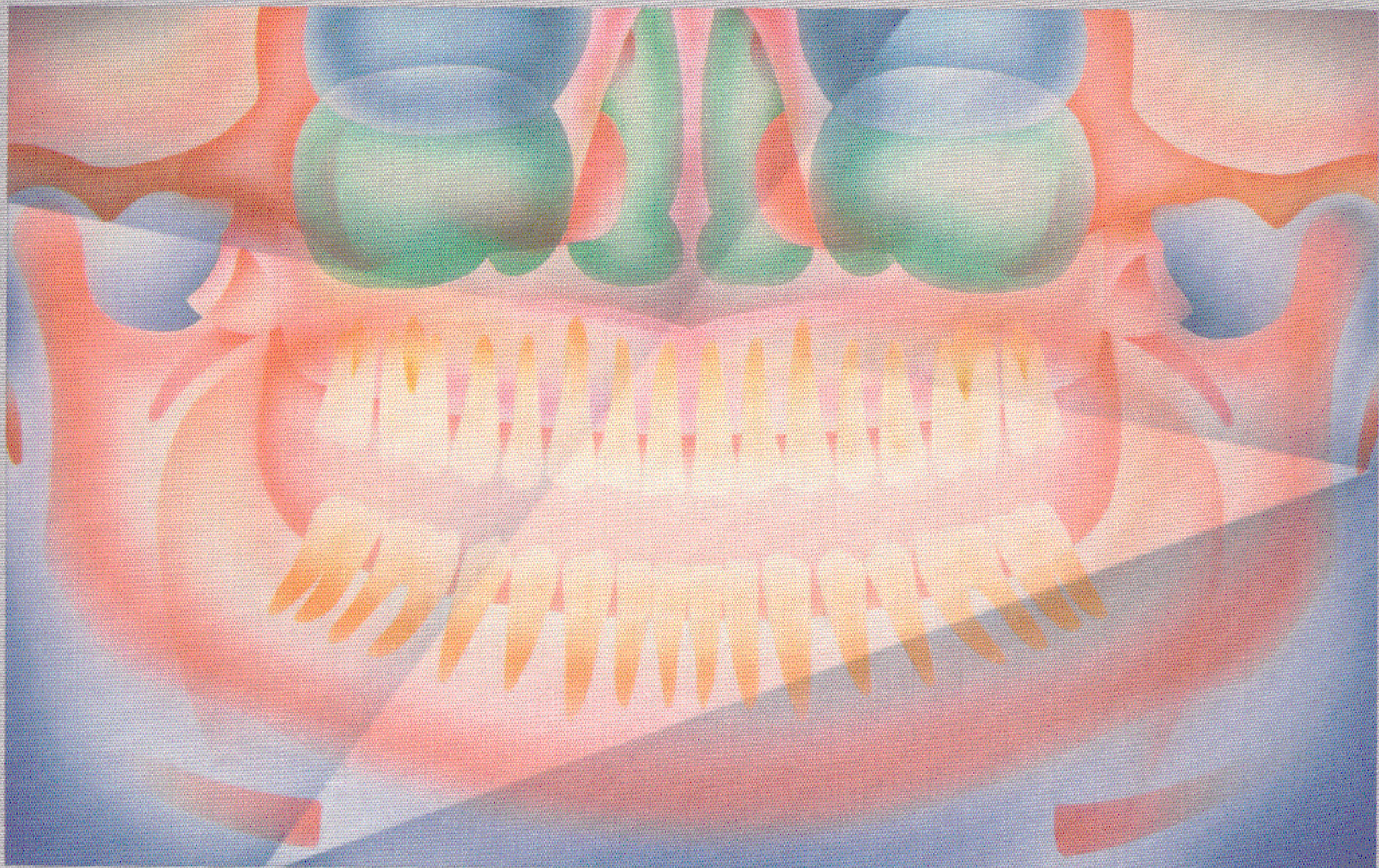

Color Atlas of Dental Medicine

Editors:
Klaus H. Rateitschak
Herbert F. Wolf

Radiology

Friedrich A. Pasler



Thieme

Table of Contents

Radiographic Examination of the Patient in the Dental Office

- 3 Examination Strategy and Active Protection Against Radiation Exposure**
- 4 Examination Strategies

Panoramic Radiography for Basic Information and Supplemental Examination Using Special Radiographs

- | | |
|--|--|
| <ul style="list-style-type: none"> 9 Technique for Panoramic Radiography 10 Technique for Panoramic Radiography 12 Positioning of the Patient in the Apparatus 14 Increased Radiographic Quality through Positioning According to Indication 17 Typical Incorrect Positioning 18 Incorrect Positioning 19 Positioning in the Mixed Dentition Stage 20 Positioning to Visualize Periodontal Destruction 21 Positioning of the Tongue 22 Depiction of the Alveolar Ridges 23 "Zonarc," A Special Instrument for Clinics 24 Special Radiographs Using the Cephalometric Attachment | <ul style="list-style-type: none"> 47 The Bite-Wing Radiograph 50 Examples of Diagnosis Using Bite-Wings |
| <ul style="list-style-type: none"> 25 Radiographic Anatomy in the Panoramic Radiograph 26 Survey of the Anatomic Structures Visible in a Panoramic Radiograph 27 Ventral Portion of the Facial Skeleton 28 Ventral Portion of the Facial Skeleton in the Maxilla 29 Variations in the Maxillary Sinus 30 Retromaxillary Space 31 External Ear and Temporomandibular Joint Region 32 Palatal Bone in the Shadow of the Coronoid Process 33 Tuberosity Region and the Cervical Vertebrae 34 Chin Region 36 Chin Region and the Body of the Mandible 37 Mandibular Canal, Mandibular Rami and the Cervical Vertebrae 38 Mandibular Canal and Retromolar Structures 39 Hyoid Bone and Cervical Region 40 Hyoid Bone and Subtraction Effect from the Base of the Skull 41 Angle of the Mandible and the Styloid Process 42 Examination of Children and Adolescents Using the Panoramic Radiograph 45 Diagram of Formation and Eruption of the Deciduous Teeth 46 Diagram of Formation and Eruption of the Permanent Teeth | <ul style="list-style-type: none"> 51 Apical and Periodontal Radiographic Technique 52 Radiographic Surveys for Patients of Various Ages 53 Apical and Periodontal Survey in Adults 54 Maxilla 58 Mandible 62 Third Molars |
| | <ul style="list-style-type: none"> 63 Radiographic Technique with the Occlusal Film 64 Intraoral 68 Extraoral |
| | <ul style="list-style-type: none"> 69 Radiographic Anatomy in Periapical and Occlusal Radiographs 70 Radiographic Anatomy During Tooth Development 71 Radiographic Anatomy of Special Regions 71 Maxillary Anterior Region 72 Maxillary Canine Region 73 Maxillary Premolar Region 75 Maxillary Molar Region 76 Mandibular Anterior Region 77 Mandibular Canine Region 78 Mandibular Premolar Region 80 Mandibular Molar Region 82 Radiographic Anatomy in Occlusal Radiographs |
| | <ul style="list-style-type: none"> 83 Localization Using Various Methods 86 Panoramic Radiography as an Aid in Localization 87 Special Localization Problems 87 Buccally Impacted Mandibular Canine 88 Ectopically Positioned Anterior Teeth 89 Apically Displaced Maxillary Third Molars 90 Axially Presented Maxillary Third Molars |

91	Errors in Technique That Reduce Radiograph Quality	110	Conventional Skull Films
92	Tips for Preparation of Good Panoramic Radiographs	110	First Standard Projection: Posteroanterior Cephalometric Skull Projection
92	Before Positioning the Patient in the Apparatus	111	Second Standard Projection: Lateral Cephalometric Skull Projection
93	With the Patient in the Apparatus	112	Special Construction of a High Capacity Cephalometric Instrument
94	Tips for Preparation of Good Radiographs	113	Third Standard Projection: Full Axial Projection of the Skull
94	Before Exposing the Film	114	Lateral Oblique Projection of the Mandible
95	Immediately Before Exposure	115	Special Positioning for the Lateral Oblique Projection of Mandible
96	Summary of Basic Rules for Preparation of High Quality Radiographs	116	Zygoma/Cheek Tangential Skull Projections
97	Common Errors During Preparation of Periapical Radiographs	117	Mandibular Posteroanterior Skull Radiograph (Reverse Towne)
102	Common Errors During Preparation of Occlusal Radiographs	118	Waters' Projection Radiograph
103	Processing Technique and Errors Leading to Poor Quality Radiographs	119	Supplemental Examination of the Maxillary Sinus with Additional Methods
104	Tips for Error-Free Processing	120	Transcranial Projection: "The Modified Schüller TMJ Film, Open and Closed"
105	Tips for Error-Free Development	121	Tomography: Supplemental Examination of the Temporomandibular Joint (TMJ)
106	Tips for Error-Free Fixation	122	Computed Tomography (CT)
107	Optimum Radiograph	124	Magnetic Resonance Imaging
108	Reducing Overdeveloped Radiographs		
109	Supplemental Examinations Using Conventional and Modern Imaging Techniques		

Selected Examples of Dental Radiographic Diagnosis

127	Anomalies of Dental Development and the Teeth	154	Sclerosing Osteomyelitis and Inflammatory Reactive Osteosis
128	Congenitally Missing Teeth, Retention and Inclusion	155	Osteomyelitis in Infants and Children
129	Retention, Malocclusion and Resorption	156	Acute Osteomyelitis
130	Retention of Supernumerary Teeth, Resorption of Retained Teeth	157	Secondary Chronic Osteomyelitis
131	Retained Teeth in Special Locations	158	Primary Chronic Osteomyelitis, Osteoradionecrosis
132	Retained and Ankylosed Teeth	159	Dentogenic Sinus Disorders
133	Mesiodens, Gemination, Taurodontism and Dens in dente	160	Panoramic Radiography of Dentogenic Sinus Pathology
134	Hypercementosis and Enamel Pearls	162	Additional Signs of Dentogenic Infection
135	Amelogenesis Imperfecta	163	Incidental Findings and the Significance of the Waters' Projection
136	Dentinogenesis Imperfecta	164	Acute Unilateral Dentogenic Sinusitis
137	Additional Dental Dysplasias	165	Schematic View of Sinus Diagnosis in Waters' Projection Radiographs
138	Posterior Open Bite with Macroglossia and "Idiopathic Root Resorption"	167	Acute and Chronic Maxillary Sinusitis
139	Concrements, Calcifications, Ossifications	168	Computed Tomography for Supplemental Diagnosis
147	Regressive Changes in Teeth and Jaws	170	Foreign Bodies, Root Fragments and Surgical Defects
151	Inflammation of the Jaws and Osteoradionecrosis	171	Temporomandibular Joint Disturbances
152	Acute and Chronic Apical Periodontitis	172	Examination of the Masticatory Organ Using the Panoramic Radiograph
153	Diffuse Sclerosing Osteomyelitis in Chronic Apical and Marginal Periodontitis	173	Temporomandibular Joint Pain with Malocclusion

174	Film Tomography of the Temporomandibular Joint	223	Chondroma
176	Computed Tomography of the Temporomandibular Joint with Direct Lateral Projection	224	Osteochondroma
177	Magnetic Resonance Imaging of the Temporomandibular Joint	226	Desmoplastic Fibroma
178	Hypoplasia and Exostosis of the Condyles	227	Ossifying Fibroma
179	Hyperplasia and Osteochondral Exostoses	228	Fibrous Dysplasia (Jaffé-Lichtenstein)
180	Inflammatory and Degenerative Changes	230	Fibrous Dysplasia and Cherubism
181	Cysts and Pseudocysts	231	Osteoid Osteoma, Osteoblastoma
182	Classification	232	Osteoma
183	Odontogenic Cysts	234	Exostoses and Enostoses
183	Radicular Cyst	236	Hyperostoses and Hypertrophies
184	Radicular Cyst in the Mandible	237	Osteoporosis and Atrophy
185	Radicular Residual Cyst in the Mandible	238	Bone Marrow Islands and Incorrect Interpretations
186	Radicular Cyst in the Maxilla	239	Osteogenesis Imperfecta and Osteopetrosis
187	Follicular Cyst	240	Osteitis Deformans (Paget's Disease of Bone)
190	Atypically Localized Follicular Cysts	241	Hemangioma
191	Nonodontogenic Cysts	242	Sarcoma
194	Pseudocysts	244	Carcinogenic Infiltration
197	Odontogenic Tumors and Pseudotumors	245	Mucoepidermoid Tumor
200	Ameloblastoma	246	Metastasis
202	Ameloblastic Fibroma	247	Traumatology
203	Odontogenic Myxoma	249	Radiographic Signs of Subluxation
205	Cementoma	251	Radiographic Signs of Tooth Fracture
205	Periapical Cemental Dysplasia	252	Radiographic Signs of Mandibular Fracture
207	Cementoblastoma	254	Mandibular Fracture During Mixed Dentition
209	Cementoblastoma, Cementum-forming Fibroma	255	Foreign Bodies and Postoperative Conditions
210	Odontoma	256	Various Therapeutic Materials Seen in the Radiograph
210	Complex Odontoma	257	Trauma, Osteosynthesis Material and Implants
211	Transition Forms	258	Deposition of Filling Materials
212	Compound Odontoma and Fibro-odontoma	259	Radiography of Root Fragments
213	Nonodontogenic Tumors and Pseudotumors	260	Tooth Extraction and Root Fragments
213	Benign Lesions	261	Fractured Bone and Sequestra
218	Malignant Lesions	262	Success and Failure with Root Tip Resection (Apicoectomy)
220	Central Reparative Giant Cell Granuloma	263	References
221	Peripheral Reparative Giant Cell Granuloma	265	Index
222	Histiocytosis X		

Radiographic Examination of the Patient in the Dental Office

Examination Strategy and Active Protection Against Radiation Exposure

With the gradual introduction of a systematic radiographic examination came the firm intention to optimize patient examinations. The corollary goal was to perfect the system because radiography provides the basis for treatment planning and evaluation of therapy. Furthermore, it is recognized that it is the medical obligation of the dentist to detect pathologic alterations as early as possible and to institute timely therapy for developmental anomalies. However, because no radiographic survey comprised of individual films can provide a complete view of the masticatory apparatus with all its components and with its relationships to adjacent regions, the panoramic radiograph is now beginning to play a more significant role as the basis for a systematic and economically favorable method for data collection that also protects the patient from unnecessary radiation.

During the initial examination, radiography should be used to examine not only the teeth but also the jaws, including the angles of mandible and the temporomandibular joints. Failing this, the dental examination, the treatment plan and in some cases even the treatment itself may be incomplete and therefore in error. Some have argued that the fulfillment of these requirements would lead to excessive cost and increased radiation dosage, but this is not true because early diagnosis of dental and jaw anomalies as well as other diseases of the jaws is associated in the final analysis with less cost and less radiation exposure. In addition, there are advantages in terms of the patient's general health. Taken together, these facts clearly support the use of panoramic radiography as the source of basic information; today there is a growing tendency to replace the conventional dental radiographic survey with the panoramic radiograph. The use of supplemental individual dental X-rays serves only to complete the overall survey in special situations, e.g., for the examination and treatment of periodontal diseases. Supplementing the panoramic radiograph with specific conventional skull films and other imaging techniques must be carried out or arranged for with knowledge of the technical and diagnostic possibilities, and with full consideration of the regulations pertaining to protection from excessive radiation.

The individual dentist who must decide the breadth of radiological diagnostic possibilities in his or her own practice will, in the future, be unable to deny the responsibility for a comprehensive oral examination of all patients. Finally, the dentist is the only health care professional who can examine the teeth, the oral mucosa and the jaws of large segments of the population on a more or less regular basis.

Examination Strategies

The term “examination strategy” stands for the rational selection of proven radiographic examination methods, depending upon the particular indication, in order to avoid unacceptable radiographs and unnecessary radiation exposure. Today it can already be stated that the use of panoramic radiography is mandatory in the following cases:

-
- Initial examination of new patients in all age groups (including orthodontic and periodontal patients)
 - Early diagnosis of developmental anomalies of the dental apparatus (recommended especially at ages 10, 15 and 20) to check the dentition and to diagnose early any odontogenic cysts and tumors
 - To clarify the cause of missing teeth
 - Radiographic examination of nonvital teeth
 - Suspicion of odontogenic diseases of the sinuses
 - Temporomandibular joint disturbances caused by malocclusion (in such cases, a panoramic radiograph should be taken with the patient in habitual occlusion)
 - Asymmetries of the face and the jaw
 - Pressure sensitive, painful as well as asymptomatic swellings
 - Poorly healing extraction wounds and suspicion of osteomyelitis
 - Examination of nonodontogenic cysts, tumors and tumor-like lesions
 - Suspicion of intraosseous or invasive growth of tumors, and suspicion of metastasis
 - Paresthesia of the mandibular nerve
 - Examination of systemic diseases and syndromes
 - Maxillofacial fractures, and suspicion of fracture following trauma
 - Before and after the performance of surgical interventions
-

It is self-evident that before taking a panoramic radiograph of a new patient, the dentist must request from the previous dentist any already available radiographs, in order to reduce radiation exposure and keep the cost to a minimum.

The recognition that only a panoramic radiograph provides a complete and perfect tool for the initial examination is leading to the acceptance of a new strategy for radiographic examination, where the goal is to reduce costs and reduce patient exposure to ionizing radiation. In this strategy, individual radiographs are viewed as special and supplemental.

This strategy evolves from the panoramic film; this is the basic radiograph, which can be classified into four diagnostic regions:

Dentoalveolar region (Fig. 1)

Maxillary region (Fig. 2)

Mandibular region (Fig. 3)

Temporomandibular joint region (including the retro-maxillary and cervical region) (Fig. 4)

Any supplemental special radiographs that may be necessitated by the situation can be taken in the dental office if appropriate equipment is available, otherwise the patient should be referred to a radiology clinic.

Special Radiographs for Examination of the Dentoalveolar Region (Fig. 1)

Depending upon the situation, supplemental radiographs of the following types may be indicated:

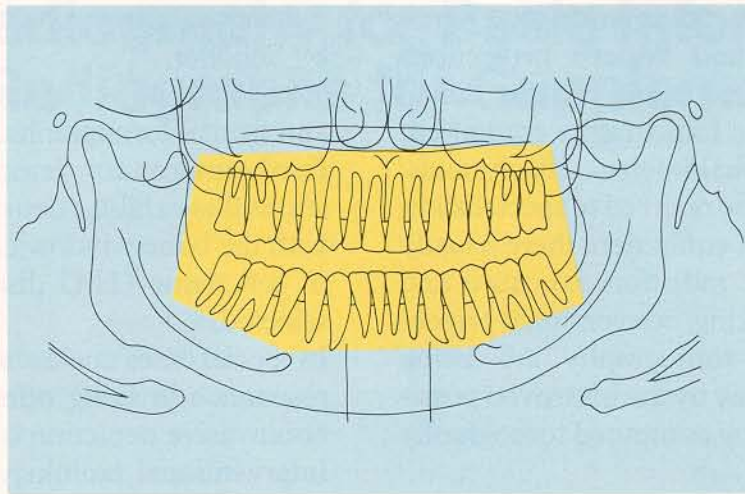
- Bite-wing radiographs for caries diagnosis
 - Periapical dental radiographs for examination of periapical lesions and endodontic problems
 - Dental radiographs for periodontal diagnosis (depiction of the root apex is not always necessary)
 - Dental radiographs and possibly occlusal radiographs to determine position in cases where localization is difficult
-

These radiographs can be taken with virtually any dental X-ray equipment.

Special Radiographs for Examination of the Maxillary Region (Fig. 2)

Depending upon the situation, supplemental radiographs of the following types may be indicated:

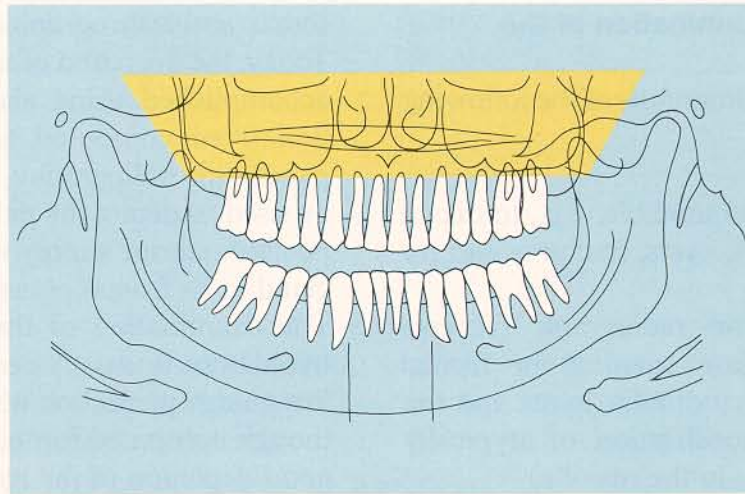
- Occlusal radiographs of the maxilla, e.g., for depiction of pathologic structural detail, depending on the indication
 - Cephalometric radiographs using lateral and postero-anterior projection, e.g., for problems of localization in the maxilla
 - Water’s projections of the facial skeleton with maximum jaw opening, e.g., for examination of the maxillary sinuses in cases of dentogenic involvement
 - Tomography and computed tomography
-



The four diagnostic regions in panoramic radiography

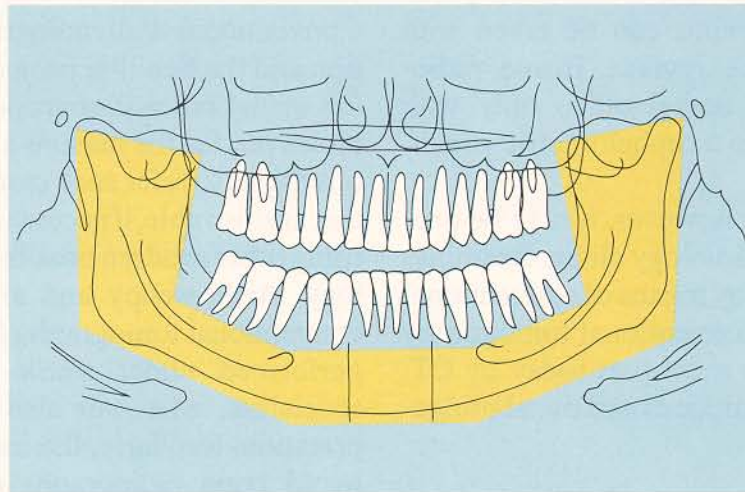
1 Dentoalveolar region

To complement the panoramic radiograph, in specific situations occlusal radiographs or periapical films precisely positioned with a film holder are employed.



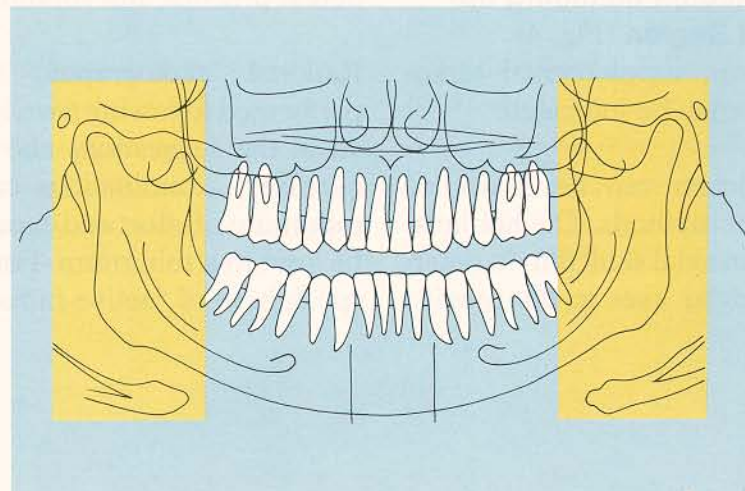
2 Maxillary region

Depending upon the demands of the case, occlusal films and skull films made with conventional or more modern imaging procedures may be required to supplement the panoramic radiograph.



3 Mandibular region

In addition to occlusal radiographs, the mandibular posteroanterior radiograph (reverse Towne projection) best serves to depict the anterior segment. In special cases, the "unilateral mandibular" technique or computed tomography may be employed as appropriate to complement panoramic radiography.



4 Temporomandibular joint region, including the retro-maxillary and cervical regions

For more detailed study of the temporomandibular joint, spiral tomography and especially computed tomography and magnetic resonance imaging are used in addition to conventional radiographic methods. Furthermore, arthrography and arthroscopy may be employed as intervention techniques.

Occlusal radiographs can be taken with any X-ray equipment. Cephalometric and Water's projections of the facial skeleton can be taken in the dental practice only if the panoramic radiography equipment features the additional cephalometric attachments. However, some cases should be referred to specialists in a radiology clinic because the equipment there usually provides a reduced level of radiation exposure and reduced cost. Generally speaking, conventional projection techniques and even tomography are being replaced for the most part today by the improved possibilities for resolution offered by computed tomography (CT).

Special Radiographs for Examination of the Mandibular Region (Fig. 3)

In certain cases, additional radiographs of the following types may be indicated:

- Occlusal radiograph of the mandible, e.g., to depict pathologic structural details, cysts, fractures and for localization
- Mandibular posteroanterior radiograph (reverse Towne) with maximum jaw opening for frontal depiction of the temporomandibular joints and the ascending rami, and for localization of atypically impacted third molars (also in the maxilla)

All types of occlusal radiographs can be taken with dental X-ray equipment. The reverse Towne radiograph can be taken in the dental office only with panoramic equipment that has a cephalometric attachment.

In some cases (see above), however, it may be prudent to refer the patient to a radiology clinic. Examination of the mandibular region by means of conventional radiographic technique and conventional tomography is also being replaced for the most part today by CT, except in patients with metal implants and metal bridge-work, which cause artifacts.

Temporomandibular Joint Region Including the Retromaxillary and Cervical Region (Fig. 4)

Depending upon the situation, supplemental radiographs of the following types may be indicated:

- The temporomandibular joints can be examined using *noninvasive* or *invasive* methods. The noninvasive technique begins with an axial skull film to determine the angle of the condylar axes to the median sagittal plane.

- Subsequent films consist of radiographs as described by Schüller.
- These may, however, also consist of a series of lateral and frontal tomographs.
- Furthermore, for temporomandibular joint alterations that exhibit a density similar to that of bone, CT with the bone window can be used; for the depiction of soft tissue (TMJ disc) the soft tissue window is selected.
- In special cases nuclear spin tomography or magnetic resonance imaging offer additional possibilities for noninvasive depiction of the TMJ disc.
- Interventional radiology of the temporomandibular joint continues to defend its position using arthroscopic and arthrographic methods.
- Today, the depiction of saliva glands is still frequently accomplished using sialography, despite competition from computed tomography. In addition to panoramic radiography, the lateral jaw projection can be used to depict the parotid gland. The mandibular posteroanterior survey is used to depict the parotid gland in its frontal plane.
- The examination of the stylohyoid chain and the hyoid bone is usually performed today by means of a low energy projection with lateral jaw exposure, even though computed tomography provides particularly good depiction of the hyoid bone.

Conventional skull radiographs such as the axial projection and the Schüller projection can also be prepared in the dental office if appropriate equipment is available. However, for the reasons already mentioned above it is often wise to refer such cases to special radiology clinics that are also able, if necessary, to extend the examination using other modern possibilities of radiographic technology. Arthroscopy and arthrography employed with conventional tomography (arthrotomography) must be performed under sterile conditions exclusively by specialists, who can also provide appropriate interpretation. Similarly, the indication for sialography and hyoid bone radiographs occurs only seldom in the dental practice and should therefore also be referred.

Rational radiographic examination should be performed following a well-considered plan, as presented in the suggestions above, because in this way the necessary examinations can be accomplished with a minimum of effort and expense. Radiation exposure can be kept to a minimum. For this reason, it is justified to speak here of “active radiation protection.”

Panoramic Radiography for Basic Information and Special Radiographs for Supplemental Examination

Technique for Panoramic Radiography

It is not possible in the scope of this book to describe the special radiographic technique of panoramic radiography with regard to all of the different equipment that is available today. On the other hand, it is possible to present general guidelines that apply equally to all apparatus. The clinical photographs that were used to portray the technique show the Orthopantomograph 10 S and the versatile Orthophos from Siemens Co.

Optimum interpretable radiographs can only be achieved with a carefully performed radiographic technique. Only a profound knowledge of the technical possibilities and limitations will permit the creation of acceptable radiographs, even under extraordinary circumstances. An unsystematic “search” according to one’s own spontaneous ideas rarely leads to success, but often to unnecessary additional radiation exposure.

In addition to the normal panoramic radiograph, many of the instruments available today can also be used to prepare conventional radiographs of the facial skeleton. This opens for the specialist and the interested general practitioner many new diagnostic possibilities and insights into broader relationships, which had not been accessible previously. Based on the experiences with cephalometric technique, the radiography industry has employed modern X-ray and generator technology, as well as new film-foil combinations and digital computers to create solutions that seemed unattainable only a few years ago.

Panoramic radiographs, which permit the use of various zonography programs on the reclined patient, must nevertheless be reconciled to special clinics because of the extraordinary costs in terms of space and equipment. An example in this regard is the Zonarc-R (Palomex, Inc.).

A new version of panoramic radiography is the Scanora R developed by E. Tammissalo. Such equipment permits, in addition to numerous zonography programs, the preparation of spiral tomography with a seated patient for depiction of the temporomandibular joint or cross sections of the jaw. This instrument, too, is generally limited to special diagnostic centers or larger group practices because of the high cost. In the near future, equipment for producing digitized radiographs will also be common in the dental practice.

This chapter provides only a momentary overview of today’s possibilities; the development of the technology continues at a rapid pace, and we stand today only at the start of the development in this field. For this reason, we will present primarily generally applicable radiographic technical rules.

Technique for Panoramic Radiography

In the late 1940s, Paatero developed the fundamentals of panoramic radiography from the principles of tomography. Three peculiarities characterize *classic tomography*:

- The movement in opposite directions of the X-ray and the film around the object determine the degree of elimination of undesired structures located outside the in-focus layer.
- The thickness of the in-focus layer depends upon the angle between the layer to be examined and the central ray.

- The choice of the layer position is achieved by shifting the center of rotation of the system.

Derived from these principles, *panoramic radiography* is characterized by the following:

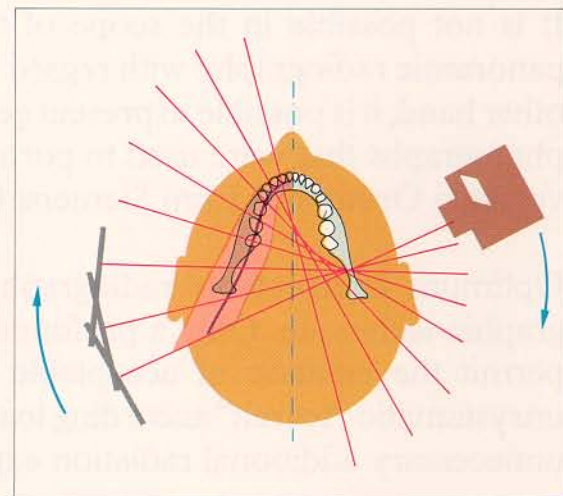
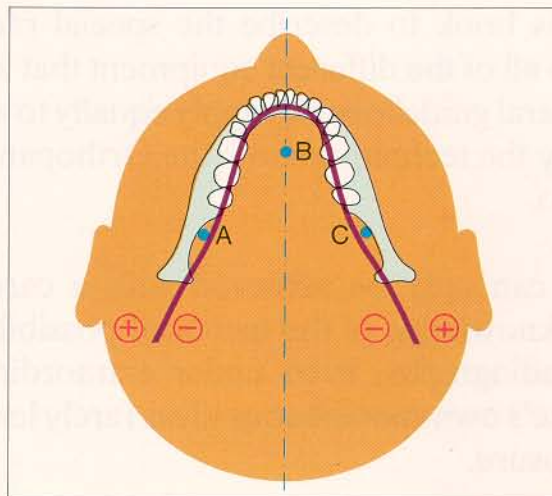
- X-ray source and film holder move clockwise around the approximately elliptically shaped dental arches.
- Structures close to or distant from the film, as well as the thickness of the in-focus layer are determined by the relationship of the speed of the film cassette (mounted on the film holder) to the speed of the X-ray source.

5 Location of the average position of the central in-focus layer, projected onto the mandible

The layer can be reduced (–) for children or enlarged (+) for adults as necessary.

6 Layer thickness

The field that is projected onto the left mandible exhibits the layer thickness for a normal case. X-ray source and film cassette rotate around the centers of rotation.

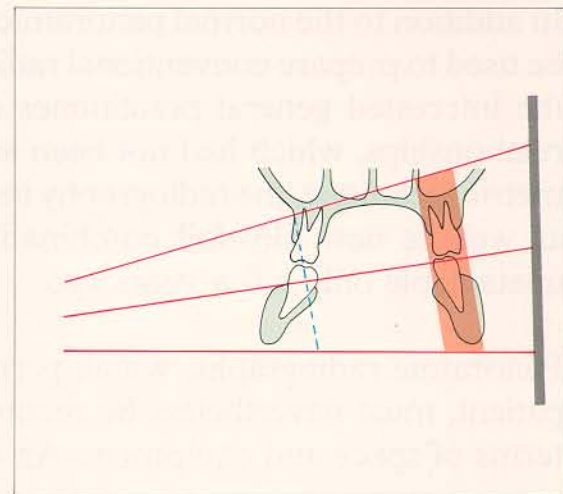
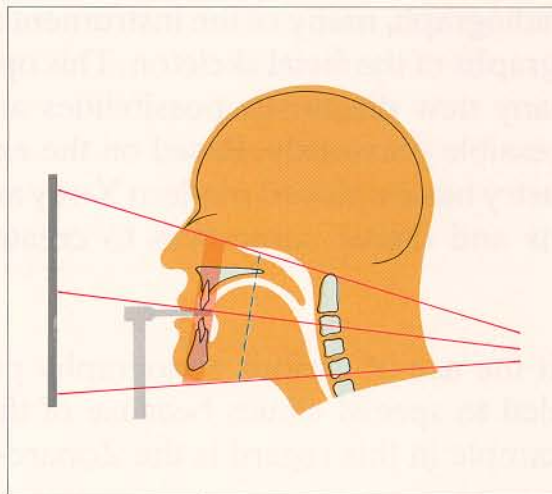


7 X-ray projection and "column" of the centers of rotation, viewed laterally

Dashed line indicates the "column" of the centers of rotation; the colored area represents the in-focus layer in the anterior region.

8 X-ray projection and fulcrum point, viewed dorsally

Dashed line represents the centers of rotation; the colored field is the in-focus layer in the right molar region. The object-film distance is larger in the maxilla because of the position of the central ray in relation to the plane of the film.

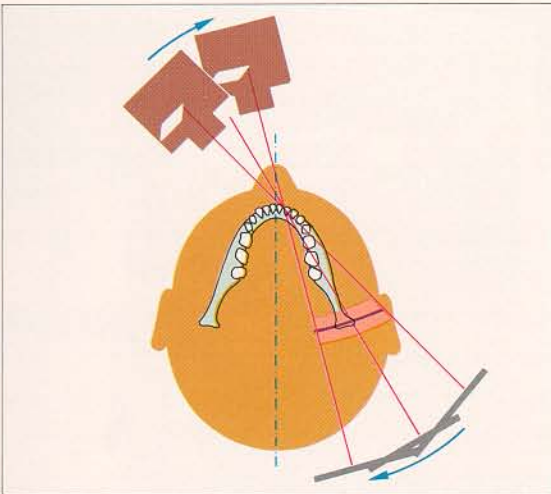


Advantages of panoramic radiography

- Presents a comprehensive dental examination by means of a panoramic representation of the masticatory system, including the temporomandibular joints and the maxillary sinuses.
- Permits detection of functional and pathologic relationships and of their effects on the masticatory system.
- Provides a documentary overview for treatment planning and follow-up.
- Reduces radiation exposure by means of a rational examination strategy.

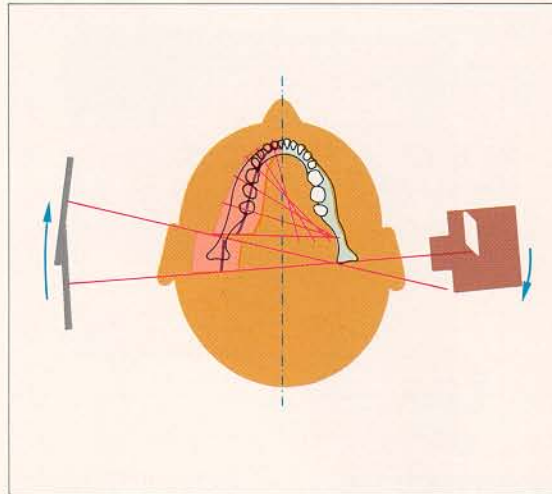
- With increasing speed and simultaneous increase in layer thickness, the plane is displaced and reversed toward the film and away from the center of rotation.
- The characteristic vertical slit plane that is mounted on the case and in front of the film eliminates any scatter radiation.
- The vertical, millimeter-wide ray creates three imaginary points of rotation if the course of the X-ray beam is viewed in a horizontal cross section (three-point procedure of Paatero). These imaginary centers

of rotation are generally referred to as the functional focus; in reality, when considered in space these are in fact moving rotation center columns leaning inward. These columns that move during the exposure always remain perpendicular to the central ray and therefore determine the angle of inclination of the in-focus layer vis-à-vis the vertical, depending upon the established angle of the X-ray source.



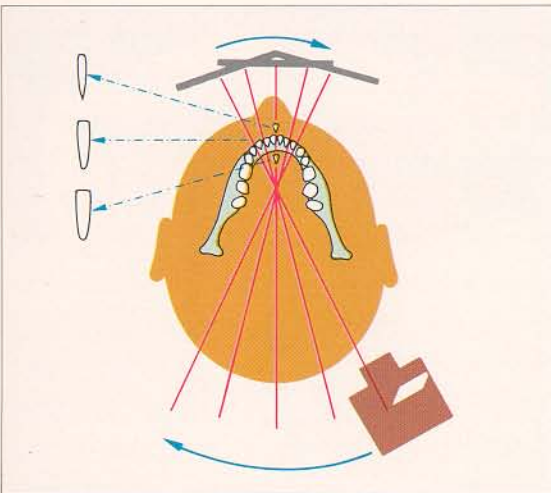
9 Temporomandibular joint, frontal

This schematic depicts the positioning of the X-ray head and the film cassette for frontal zonography of the right temporomandibular joint.



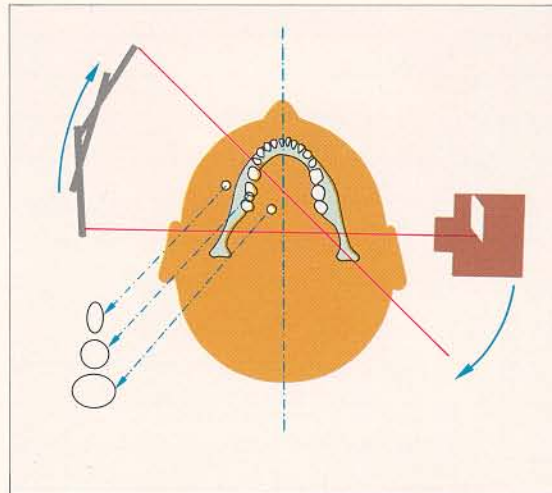
10 Temporomandibular joint, lateral

Shown here is the positioning and movement of the X-ray source and the film cassette for lateral zonography of the left temporomandibular joint.



11 Distortion of the front teeth

Front teeth that are located anterior to the in-focus layer appear reduced in size, while teeth behind the layer appear enlarged.



12 Distortion of a round body

Any round object that resides within the in-focus layer will be projected as a round object. A round body that is away from the layer will appear enlarged and flattened while an object near the film will be vertically oval and reduced in width.

Disadvantages of panoramic radiography

- Extreme class II and III anterior tooth relationships make it impossible to depict optimally the maxillary and the mandibular anterior segments simultaneously.
- The ratio of the focus-object distance to the object-film distance is not everywhere identical, resulting in a varying enlargement factor.
- Precise measurements are not possible.
- Structures that reside outside of the in-focus layer may be superimposed upon the normal structures of the jaw and mimic pathology.

Positioning of the Patient in the Apparatus

Correct positioning will determine the quality and the interpretability of the final radiograph.

The patient should be asked to remove eyeglasses, contact lenses, jewelry and, in some cases, dental prostheses (see p. 22).

The correct position of the collimator on the skin should be checked in the mirror. (Be careful with patients who have beards!) The position of the occlusal plane and the arrangement of the median sagittal plane of the occipital region of the head should be checked. The following step-by-step procedure is recommended:

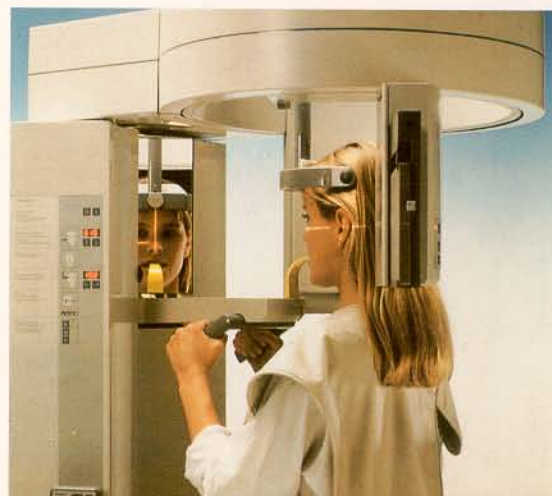
- Wash hands and apply gloves and mask in view of the patient
- Explain the movement of the film cassette and the X-ray head
- Explain the bite holder and insert the film cassette
- Select the proper exposure data
- Apply the lead apron for panoramic radiography
- Have the patient practice protrusive mandibular positioning and tongue position
- Explain to the patient the proper body position in the apparatus

13 Orthophos

Thanks to modern technology, the Orthophos from Siemens permits adjustments for especially narrow or wide dental arches, sinus radiographs, survey films and special projections for third molars as well as TMJ views in both lateral and frontal planes.

14 Patient correctly positioned in the Orthophos

Clearly visible is the collimator and the stable arrangement of the cephalostat. This apparatus employs a handy flat cassette.




15 Cephalostat and bite positioning aid

The robust construction of the cephalostat is a prerequisite to guarantee symmetrical positioning. The cephalostat automatically adjusts for any skull size.

16 Cephalometric attachment

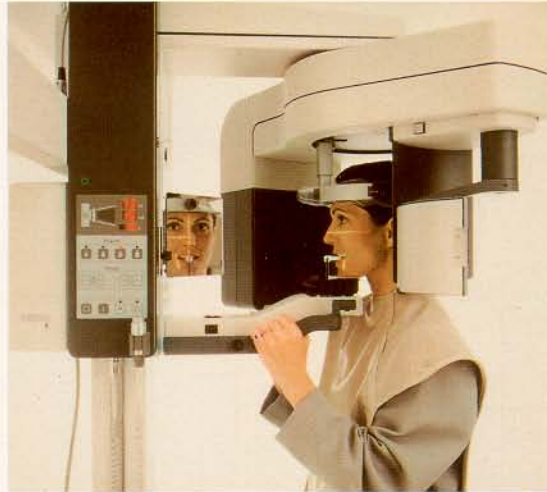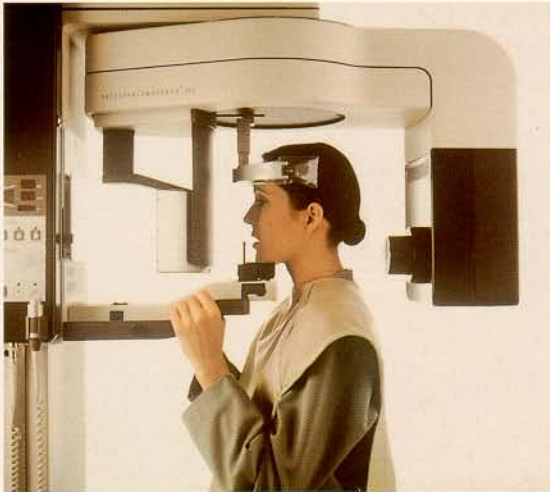This component of the apparatus permits not only the preparation of lateral cephalometric films but also the preparation of the most important standard skull projections in the standard positions of radiology.



Several modifications of patient positioning for special indications include those:

- for children in the mixed dentition age, for depiction of tooth buds or supernumerary teeth in the maxilla (p. 19)
- for periodontal diseases (p. 18)
- for temporomandibular joint disturbances in dentulous (p.15) or edentulous patients (p. 22)
- for special oral surgical problems

- Place the patient in the apparatus with symmetrical body position
- Have the patient bite into the markings on the bite block, making sure that the mandible is not displaced laterally (danger of asymmetric depiction of the mandible)
- Use the collimator to position the median sagittal plane and the anterior tooth layer
- Position the Frankfurt horizontal provisionally in the collimator
- Check the position of the median sagittal plane and the shoulder position, dorsal view
- Ask the patient to show the teeth, to permit proper final positioning of the occlusal plane, depending upon the indication. Generally speaking, the occlusal plane should be *slightly* elevated dorsally
- Ask the patient to press the tongue against the palate
- Ask the patient to take shallow slow breaths
- Expose the film

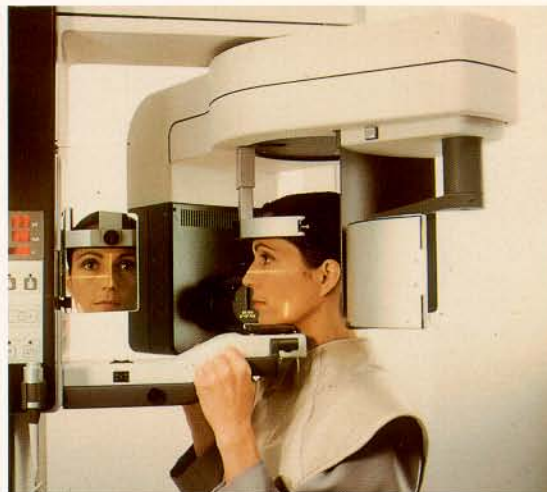
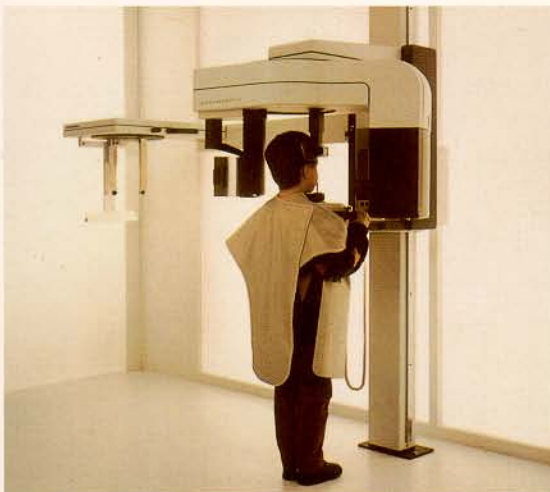


17 Profile view of a patient properly positioned in the apparatus (OP 10 S from Siemens)

Checking the patient's position only from the lateral view cannot insure proper positioning of the median sagittal plane in the apparatus, which is the determining factor for symmetry of the projection.

18 Lateral view of patient position

The collimator marks Frankfurt horizontal, the medial sagittal plane and the middle in-focus layer in the anterior segment.



19 Correct positioning of a patient in the apparatus

The feet are together in the central axis of the apparatus and somewhat in front of the body's center of gravity, to allow a lordotic posture of the lumbar spine with a flat back. With elderly patients, it is prudent to practice proper body position before taking the film.

20 Positioning in habitual occlusion

This position is appropriate for a temporomandibular joint projection.

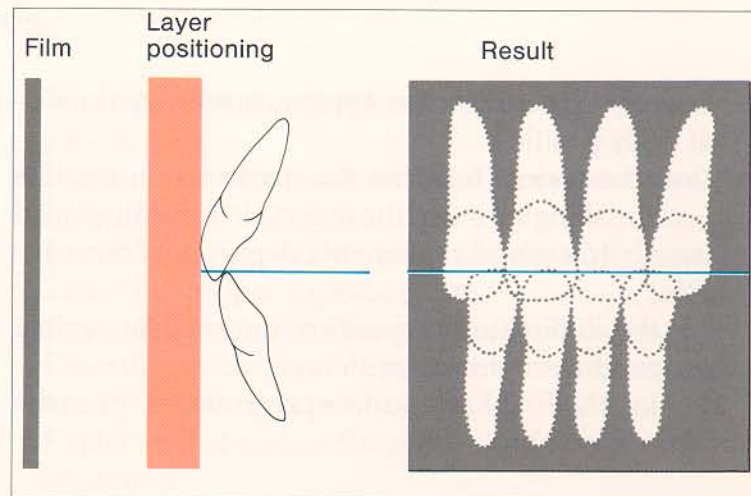
Mistakes in positioning that lead to decreased radiograph quality are frequently caused by the following:

- Asymmetric positioning of the mandible in the bite block
- Asymmetric positioning of the median plane in the cephalostat
- Improper positioning of the occlusal plane; anterior teeth outside the in-focus layer
- Tongue not pressed against the palate
- Failure to remove eyeglasses, contact lenses or jewelry

Increased Radiographic Quality through Positioning According to Indication

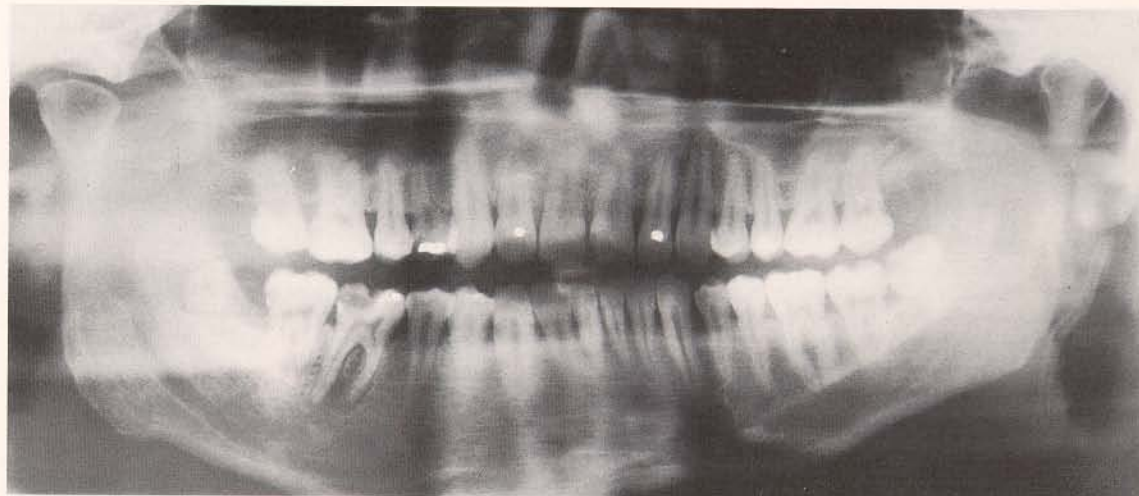
The following examples present errors in positioning, as well as tips to improve radiograph quality.

The experienced dentist will be thinking about the indication for the radiograph even as he positions the patient's head in the apparatus. Deviation from the norm will be accompanied by alterations of the projection conditions. The dentist should know to avoid such deviations, and how to put them to use.



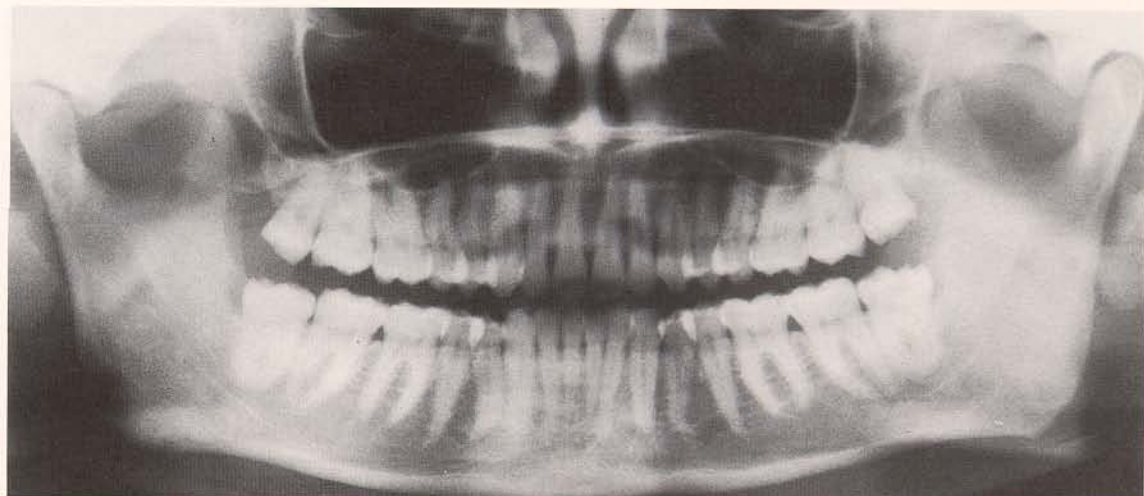
21 Positioning in the collimator

If the anterior teeth are located behind the in-focus layer, they will appear wider due to the greater object-film distance. Because they are outside the layer, they will also be blurred in appearance. Compare the diagram (above) and the radiograph (right) in the anterior segment and note the effect of an asymmetric positioning of the median sagittal plane (p. 18).

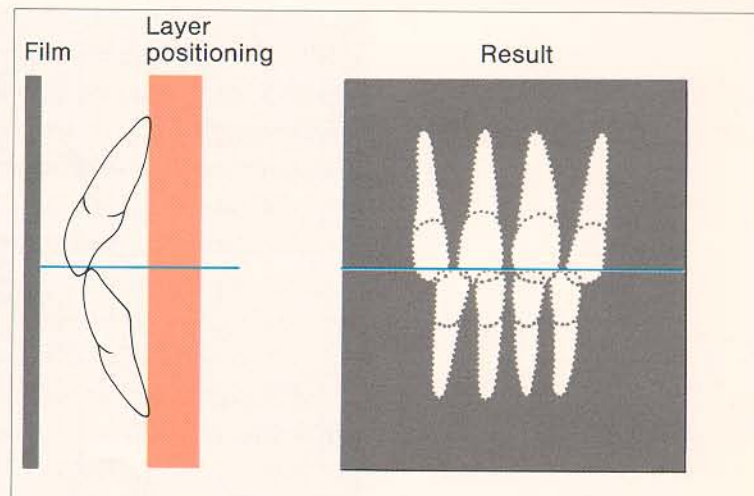


22 Positioning in the collimator

If the anterior teeth are located in front of the in-focus layer plane, they will appear on the radiograph considerably reduced in size as a result of the smaller object-film distance. Because they lie outside the layer, they will also appear blurred. Compare the diagram (below) and the radiograph (right) in the anterior segment.

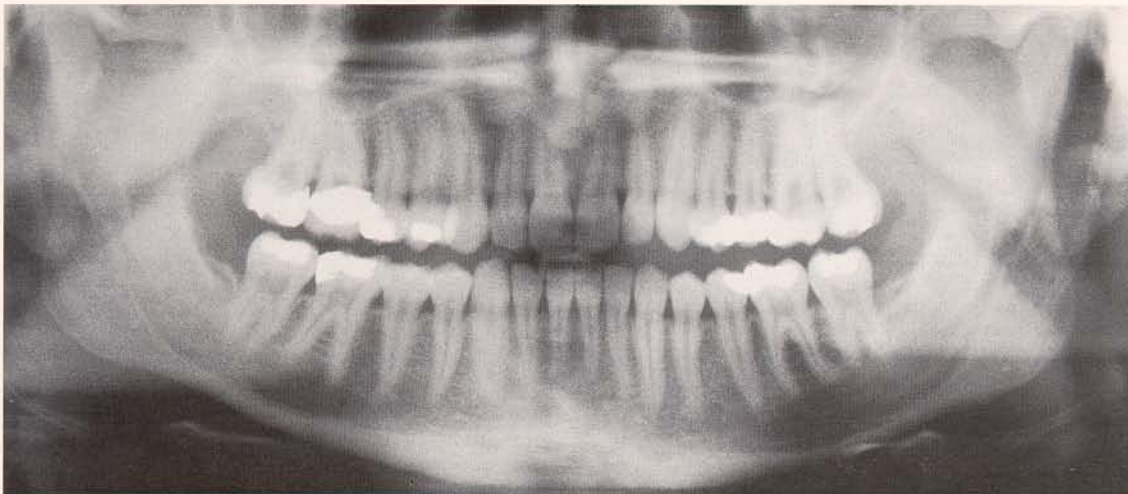
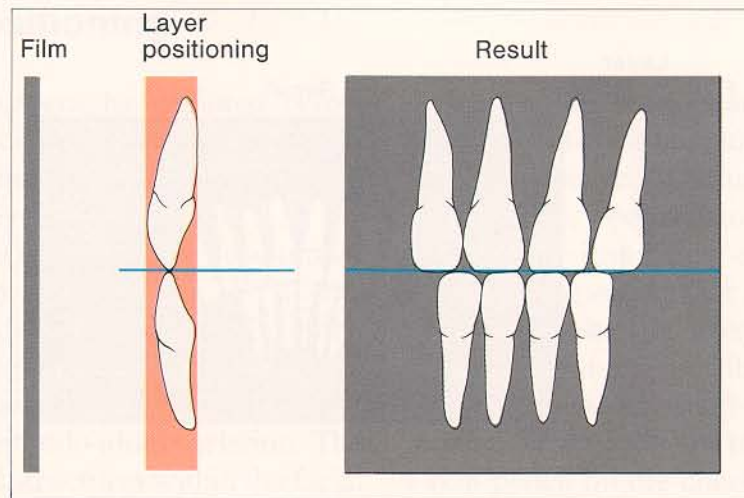


Position the median sagittal plane in the frontal collimator.
 Position the anterior dental segment in the collimator according to the indication.

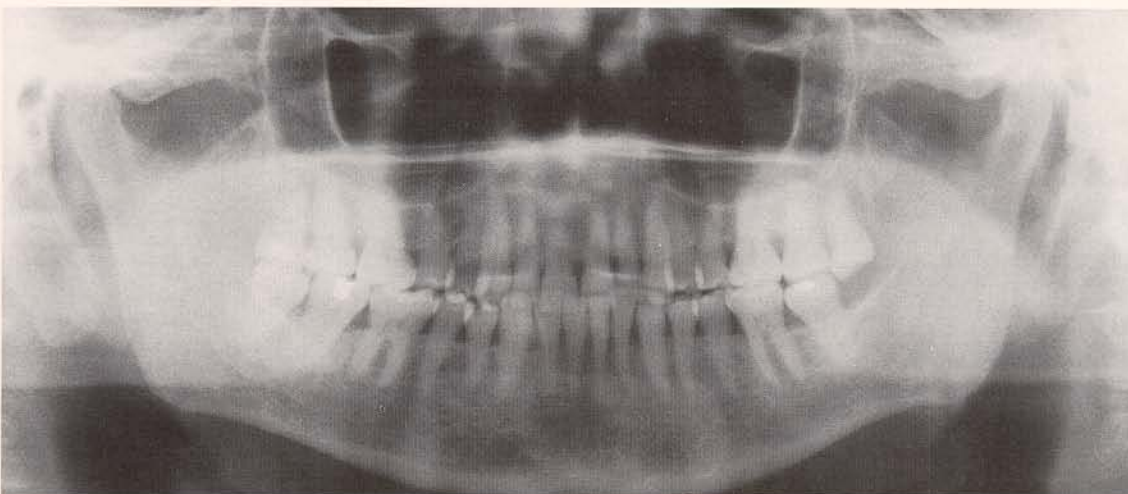


Typical Inocent P

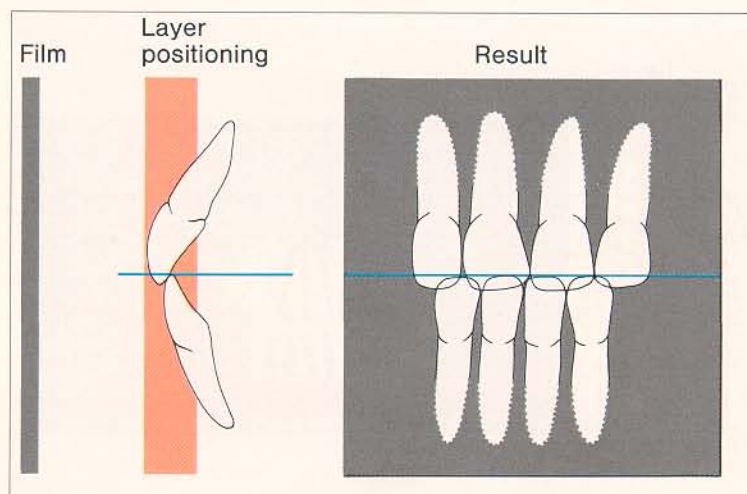
Both of the p and
 roval cross-section
 with constant p
 a constant d
 To measure the height
 of the occlusal surface
 should be measured at the
 level of the occlusal surface
 The depth of the furrow
 between the teeth is
 a constant p

**23 Positioning in the collimator**

Using the bite block to position the anterior teeth in the in-focus layer increases the likelihood that the teeth will appear in the radiograph clearly and without distortion. Compare the diagram (*above*) and the radiograph (*left*). If the tongue is pressed against the palate during the exposure, the roots of the anterior teeth will show more clearly against the background of this "soft tissue filter."

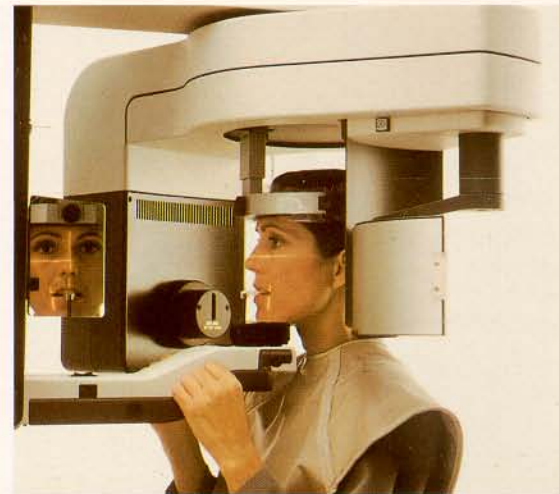
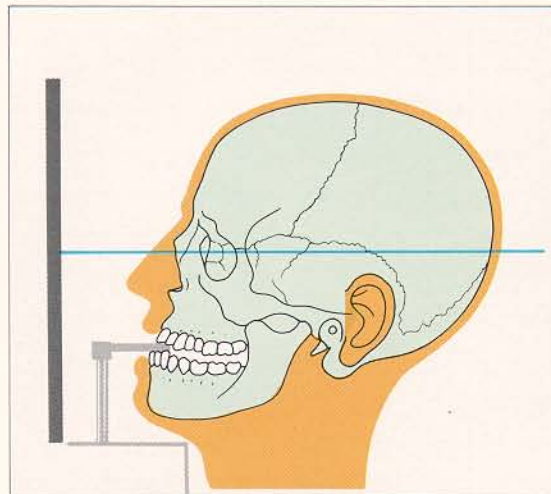
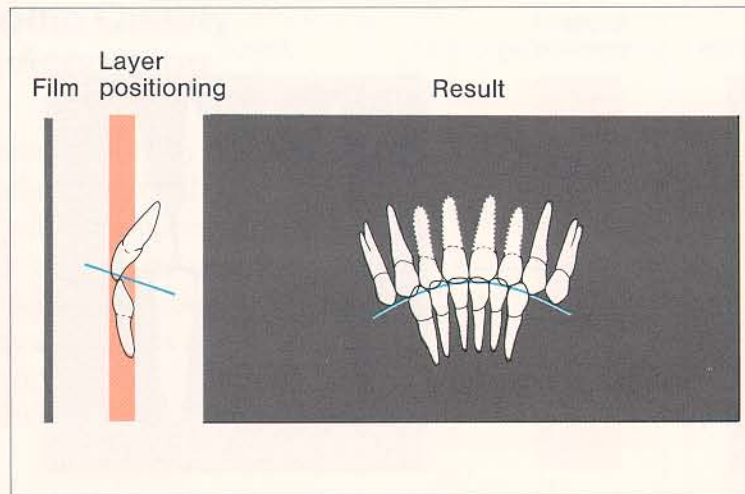
**24 Positioning in the collimator**

If it is necessary to take the radiograph with the patient in maximum intercuspation (e.g., jaw fractures or TMJ problems), the anterior teeth will often appear with a lack of detail because they will be at least partially outside the in-focus layer. Compare the diagram (*below*) and the radiograph (*left*). This technique may be used to examine the occlusal relationship vis-à-vis the condyle position.



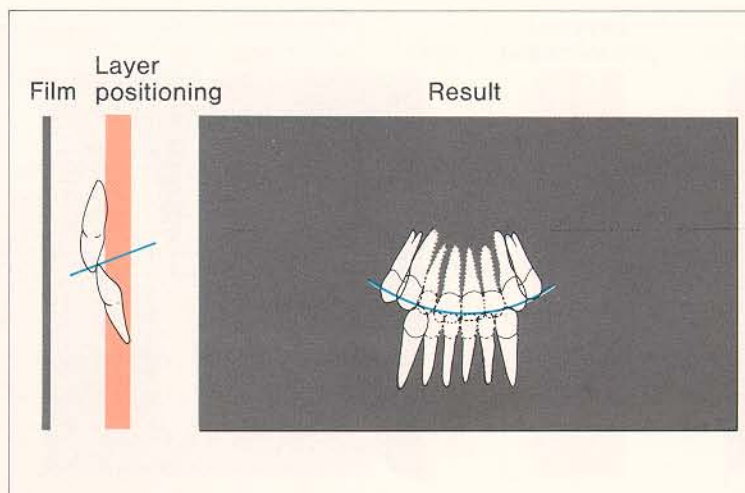
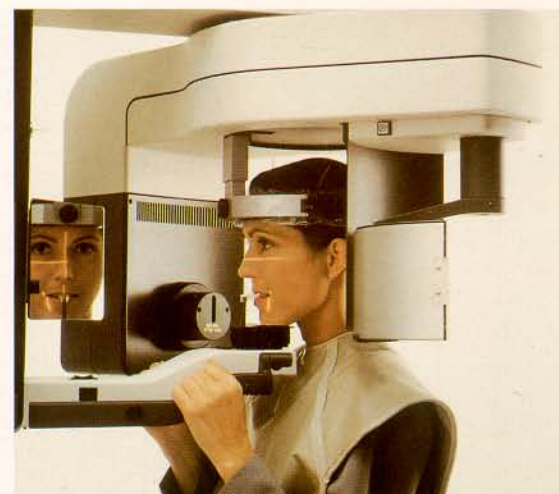
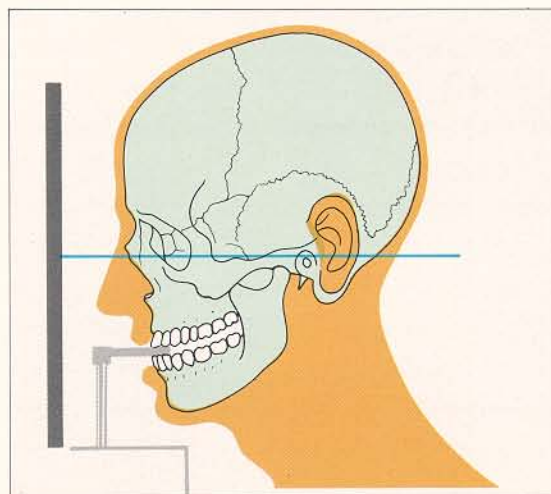
25 Improper positioning

Panoramic radiographs taken with the skull tipped too far backward often provide unsatisfactory results. The floor of the nose or the palatal vault shadows the roots of maxillary teeth, and the temporomandibular joints are projected far laterally. In such cases, the following procedure is recommended. After using the collimator to properly position the skull according to the Frankfurt horizontal, check the inclination of the occlusal plane, which may be considerably different from the Frankfurt horizontal. Asking the patient to display the teeth is of help in making this determination. If, when viewed from the side, the occlusal plane deviates considerably from the horizontal and if this inclination is from the dorsal inferior side, the position of the skull should be corrected until the occlusal plane is inclined slightly dorsally and superiorly. The diagrams (right) show the improper positioning from the lateral view and the diagrammatic result (above).



26 Improper positioning

Panoramic radiographs with the skull tipped too far forward often provide unsatisfactory results. The maxillary premolars appear superimposed upon each other, and the temporomandibular joints are projected upward. In such cases, the following procedure is recommended: After using the collimator to position the skull according to the Frankfurt horizontal, the inclination of the occlusal plane is checked. Note that the occlusal plane may vary considerably from the Frankfurt horizontal, and that asking the patient to display the teeth will simplify this determination. If the occlusal plane as viewed from the lateral aspect deviates significantly from the horizontal and is inclined significantly dorsally and superiorly, the skull position should be corrected until the occlusal plane is inclined slightly dorsally and superiorly. The diagrams (above) show the improper positioning from the lateral view and the diagrammatic result (right).

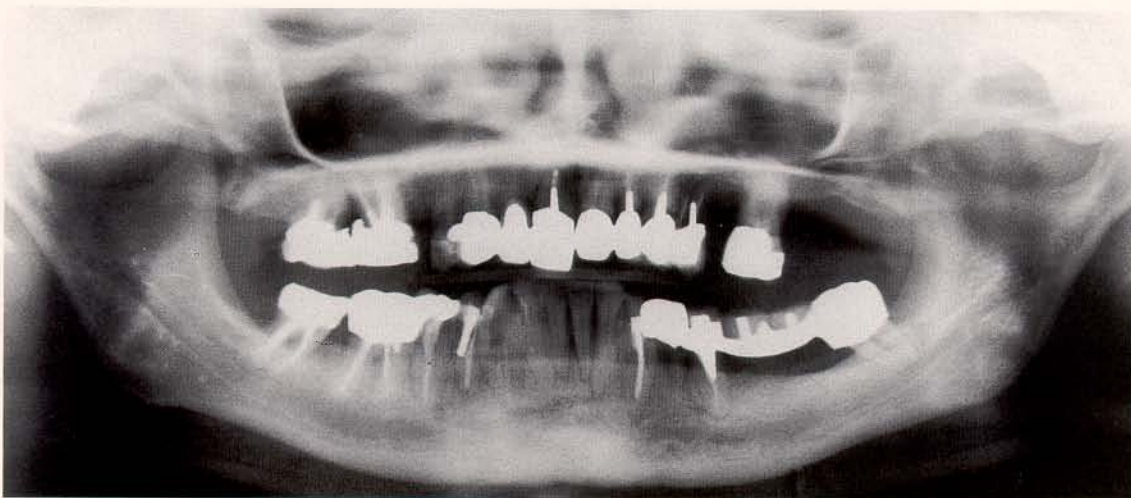


Typical Incorrect Positioning

Both of the panoramic radiographs depicted below reveal incorrect positioning of the occlusal plane, which led to unsatisfactory results because of ignorance of the consequences determined by the projection.

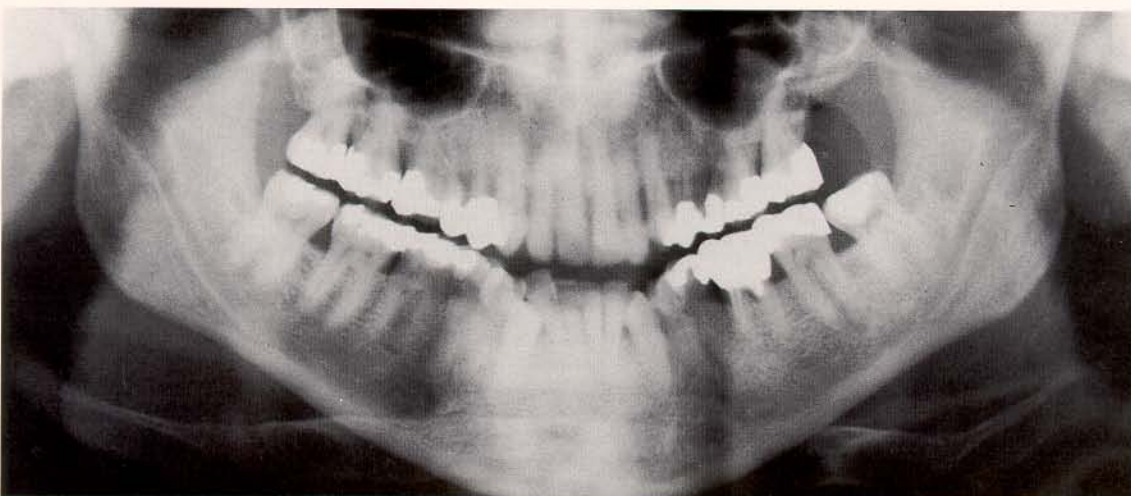
Experience has taught that unsatisfactory results may occur despite adherence to the rule that *all* patients should be positioned according to the Frankfurt horizontal. As is evident from cephalometric radiographs, the angle between the occlusal plane and the Frankfurt horizontal exhibits significant individual variation. The precise position of the dental structures within the facial

skeleton makes it necessary in almost every case to position the skull in the cephalostat according to the occlusal plane in order to avoid unsatisfactory radiographs and to obviate the necessity to retake such films. This can be achieved by inspection of the individual relationships *before* the exposure. For this reason, orthodontists are advised to take the lateral cephalometric radiograph *before* the panoramic film. If the preparation of the radiographs is delegated to auxiliary personnel, it is a good idea for the dentist to mark the occlusal plane with a skin pencil on the cheek.



27 Incorrect positioning

This panoramic radiograph clearly shows the disadvantage that results from incorrect positioning with the chin elevated. In children, incorrect positioning such as this precludes appropriate depiction of the tooth buds in the maxilla. In cases with TMJ problems neither the occlusion nor the position of the condyles can be assessed.



28 Incorrect positioning

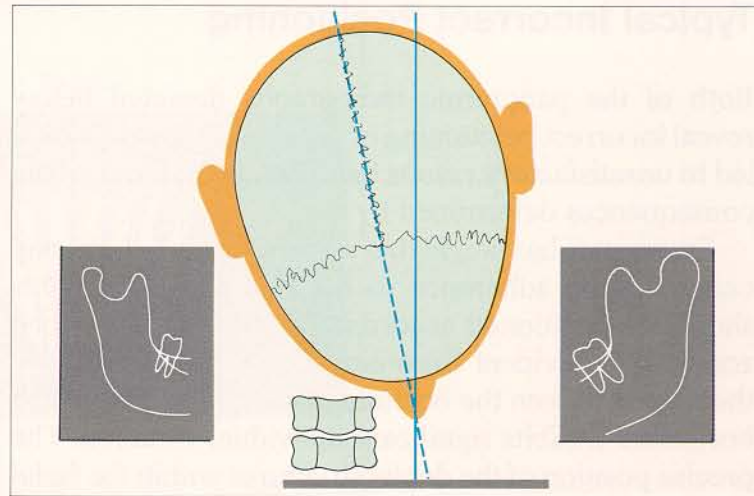
This panoramic radiograph clearly shows the disadvantages associated with improper positioning with the chin depressed. In children, this positioning may actually be an advantage if the desire is to depict the tooth buds of the maxilla more sharply and not superimposed by the palatal roof. On the other hand, this projection is not indicated as a standard projection for periodontal patients because of the superimposition in the premolar region.

The positioning of the occlusal plane should be made according to the indication for the radiograph.

Incorrect Positioning

Unfortunately, despite the cephalostat, no technique exists that can guarantee prevention of a deviation of the median sagittal plane laterally, and thereby an asymmetric portrayal of the structures of the facial skeleton. The positioning of the skull must therefore always also be carefully checked from the dorsal aspect.

The existence of a “technically elicited asymmetry” alters the depiction of normal structures, often to such an extent that they are diagnostically without value for the important lateral comparison.

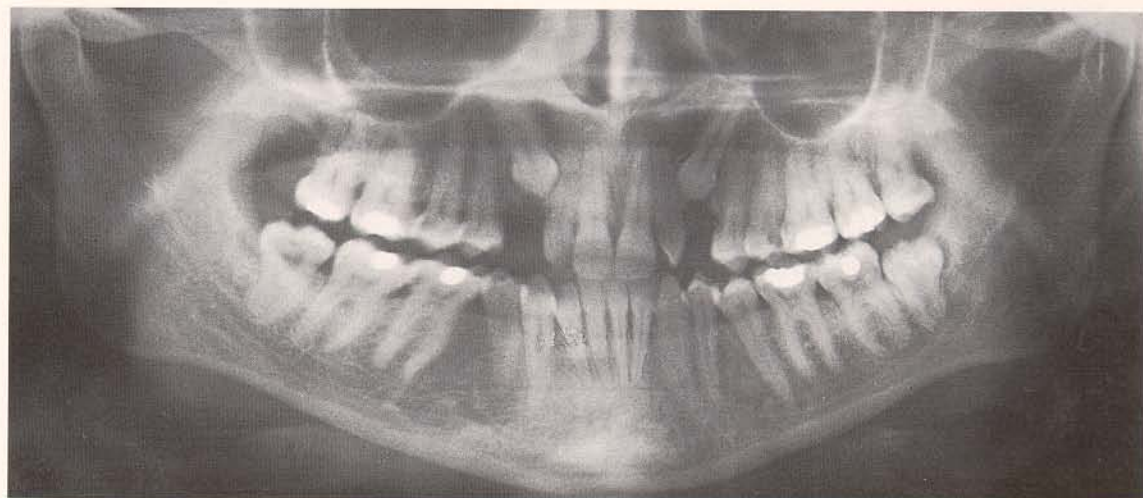
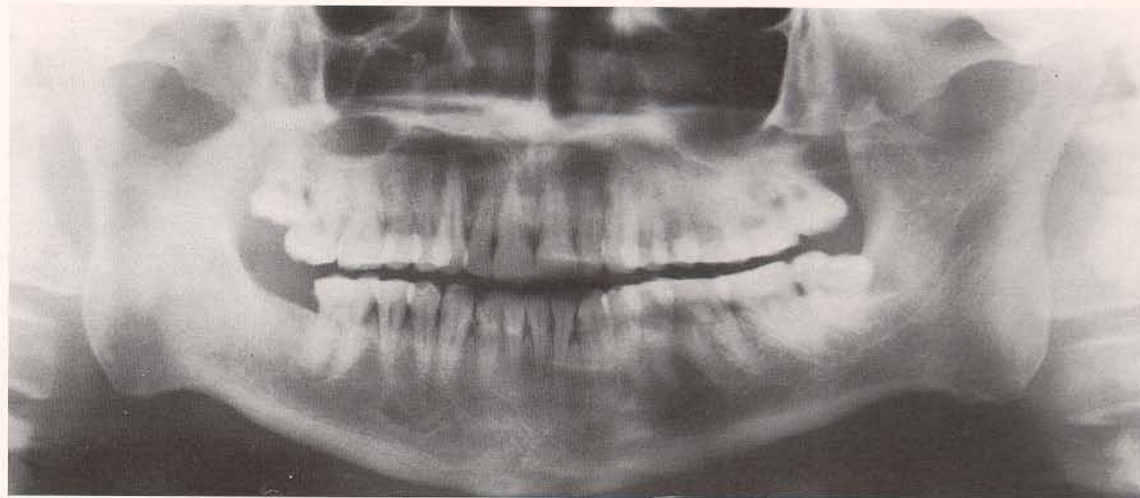


29 Technically elicited asymmetry of the facial skeleton in two panoramic radiographs

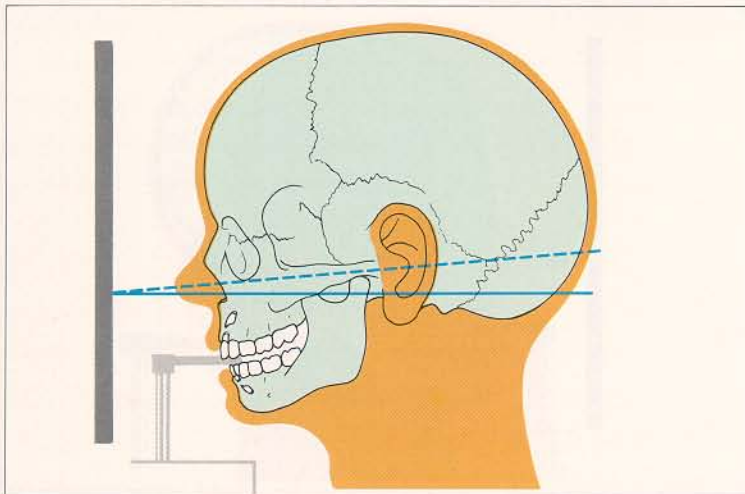
The diagram demonstrates the effect of asymmetric positioning of the median sagittal plane.

Above: This panoramic radiograph clearly demonstrates an asymmetry (the patient also moved during the exposure).

Below: Panoramic radiograph with a relatively minor asymmetry, which nevertheless led to rather severe differences of the depiction of the molars and the bony structures. Compare the shape of the left and right maxillary sinuses and the depiction of the lower concha of the nose.

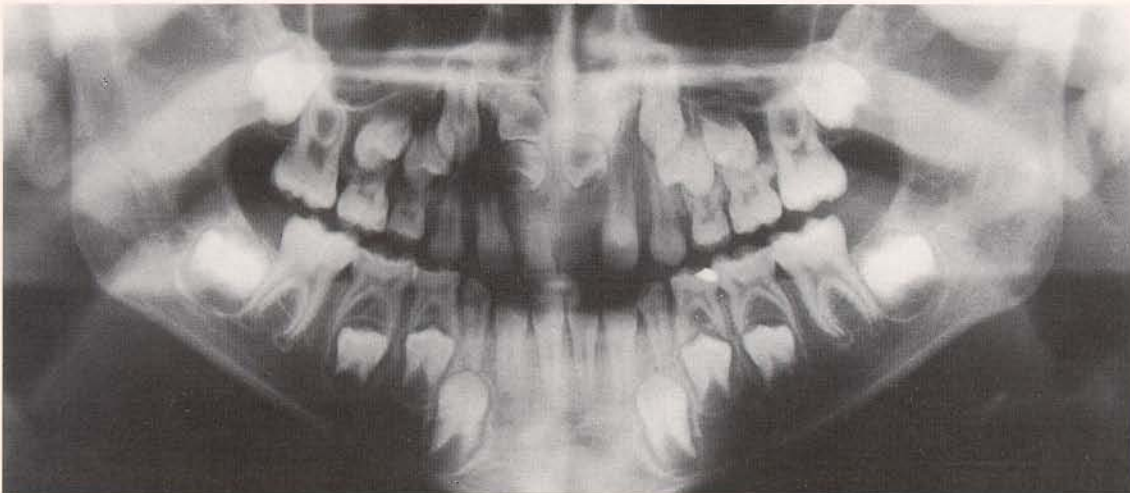


Positioning of the skull should be palpated dorsally, then checked and corrected.



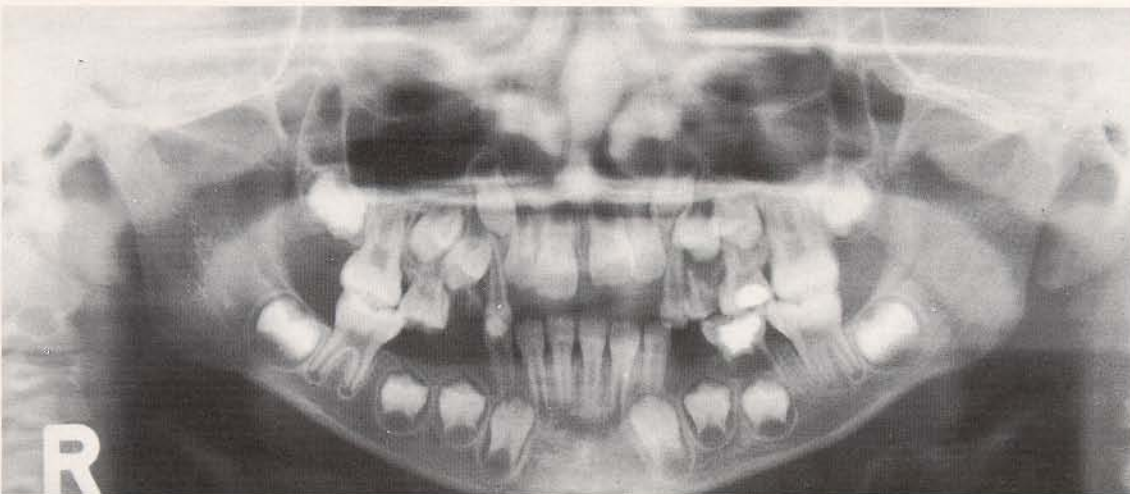
Positioning in the Mixed Dentition Stage

Depending upon the indication for the radiograph, in patients in the mixed dentition age, either *erupted* or the *not yet erupted* tooth buds must lie within the plane of focus of the vertical collimator if they are to appear sharply on the film. If, in addition, impacted or supernumerary teeth (e.g., mesiodens) in the maxilla are to be shown, the patient must be positioned with the occlusal plane inclined steeply dorsally without regard to the resolution of the TMJ. Clinical inspection before closure is absolutely necessary.



30 Improved resolution of the tooth buds in the maxilla of an 8-year-old boy

This film shows the double buds of the maxillary central incisors very well; this situation would not be clearly represented on a single periapical radiograph. The diagram (*above*) shows how the positioning of the anterior segment of the maxilla (and also of the mandible) can be employed for special indications.



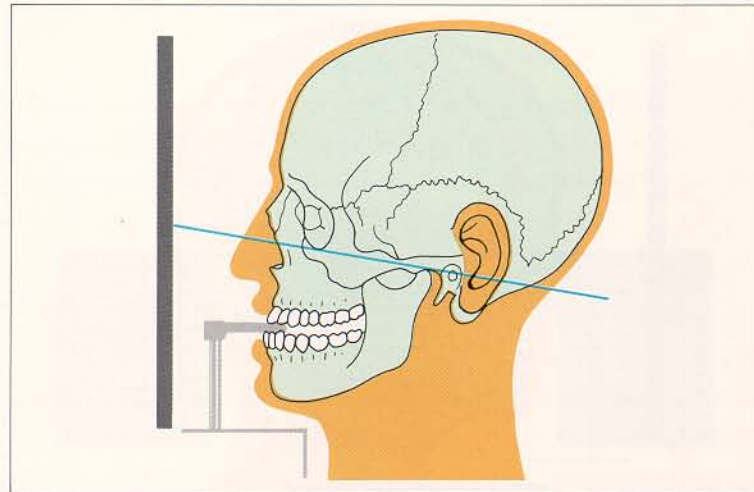
31 Panoramic radiograph of a 7-year-old girl

This film was made after eruption of the incisors, with a somewhat less steep positioning of the skull; this has permitted a good overview because the maxillary premolars are not yet superimposed by the structures of the palatal roof.

If the patient is in the mixed dentition stage, determine the position of the *tooth buds* in the anterior region before the exposure and, depending upon the indication, position them in the in-focus layer.

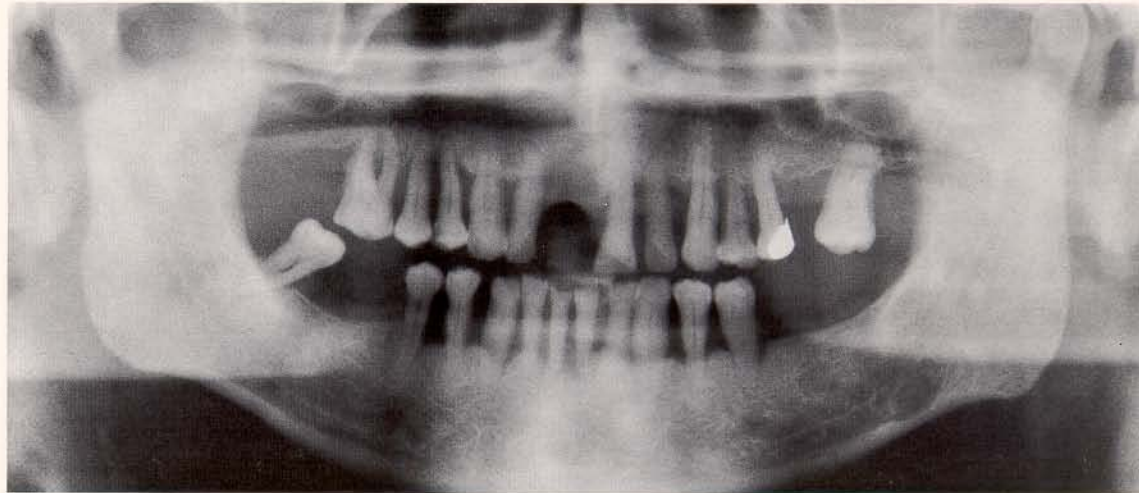
Positioning to Visualize Periodontal Destruction

If the patient is properly positioned, panoramic radiography can provide an excellent overview in cases of periodontal disease. With the central ray targeted flat and upward, and concomitantly with the use of the principles of tomography, usually a more realistic representation of the alveolar crest can be achieved than with individual periapical radiographs taken using various projection angles. If any teeth are inadequately portrayed on the panoramic film, targeted periapical radiographs can be used subsequently, thus sparing the patient excessive radiation exposure.



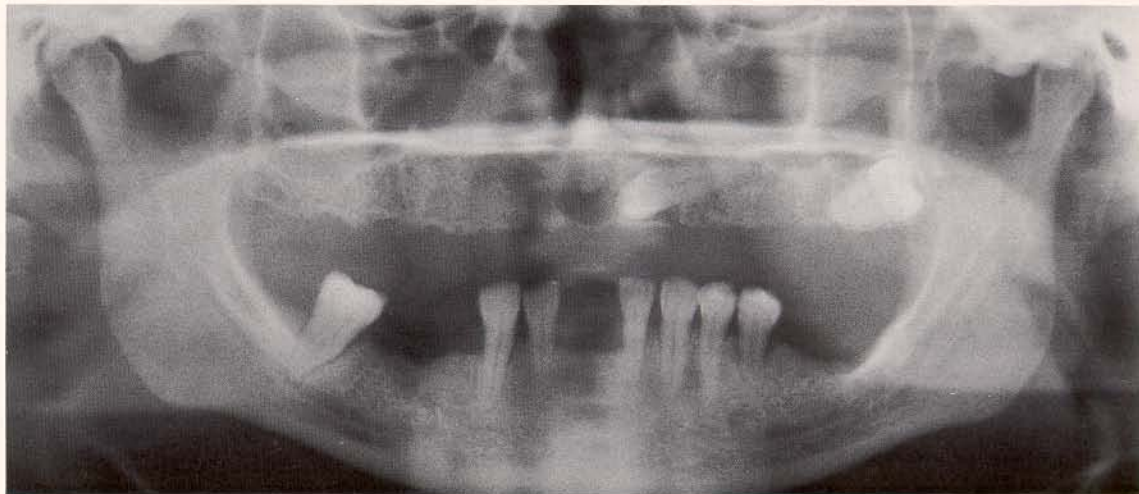
32 Proper depiction of the alveolar crest

The representation will be improved if the occlusal plane is positioned precisely horizontal in the cephalostat. Usually only a few special periapical radiographs (usually in the premolar region of the maxilla) are necessary to complete the survey. In most cases the traditional periapical film series can be avoided in favor of a better overview.

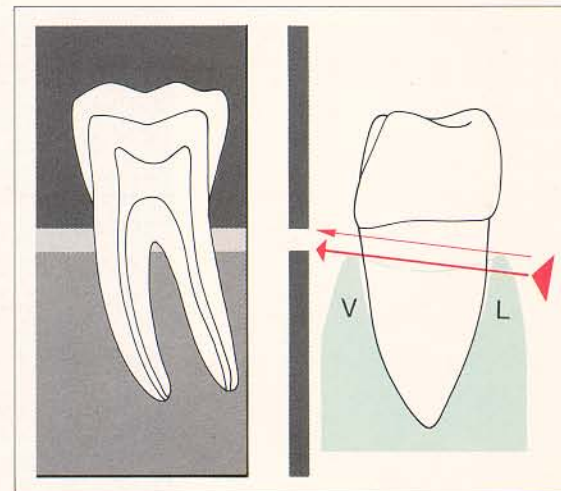
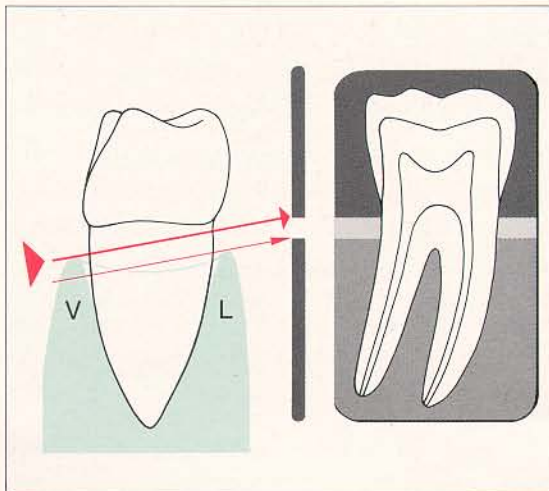


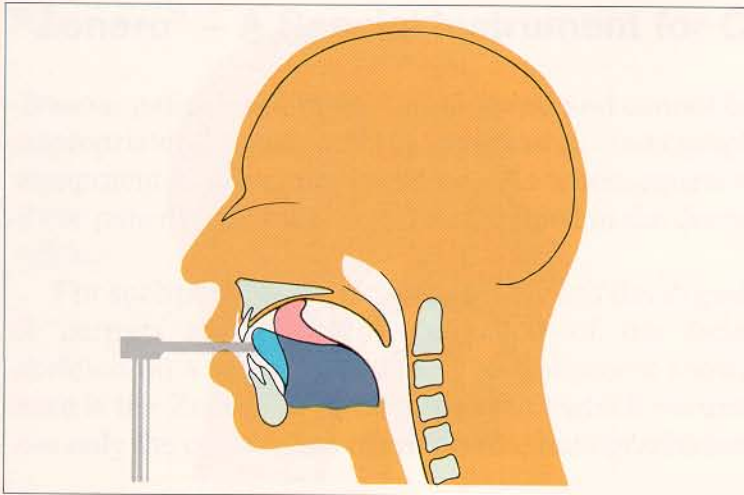
33 Comparison of X-ray targeting for periodontal interpretation using periapical radiographs and the panoramic film

Periapical radiographs (especially with apical projections) provide a distorted picture of the alveolar crest. Buccal portions will be portrayed inferiorly in the maxilla and superiorly in the mandible. Because the axis of the mandibular molars is usually in lingual orientation (see diagram) and that of the maxillary molars is tipped buccally, the panoramic radiograph provides a more realistic view of any bone loss.



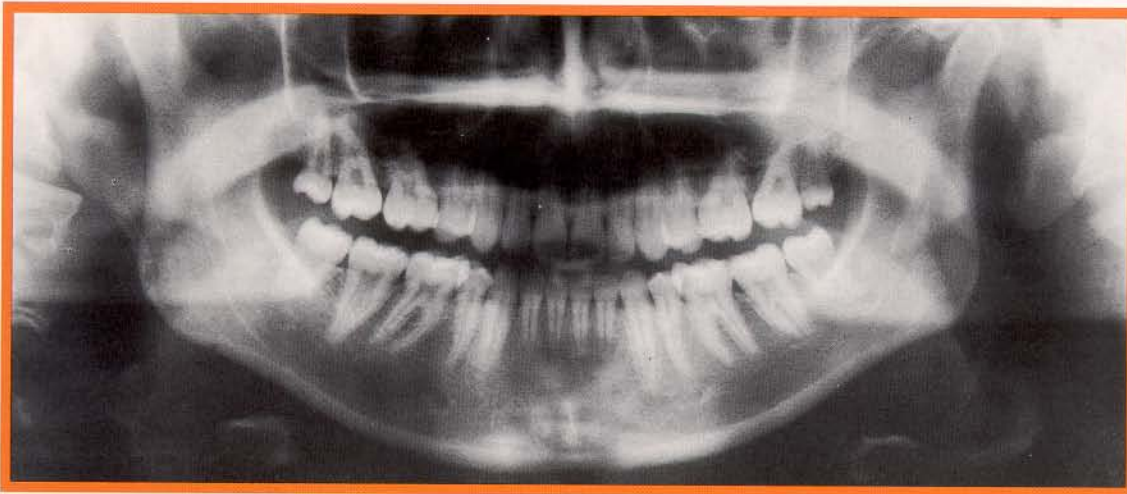
Note: As shown in the diagrams, in the mandible the buccal and the lingual portions of the alveolar ridge are shown differently in periapical films (left) and in panoramic radiographs (right). With regard to the actual anatomic situation (long axis of tooth), the panoramic radiograph illustrates the situation more realistically.





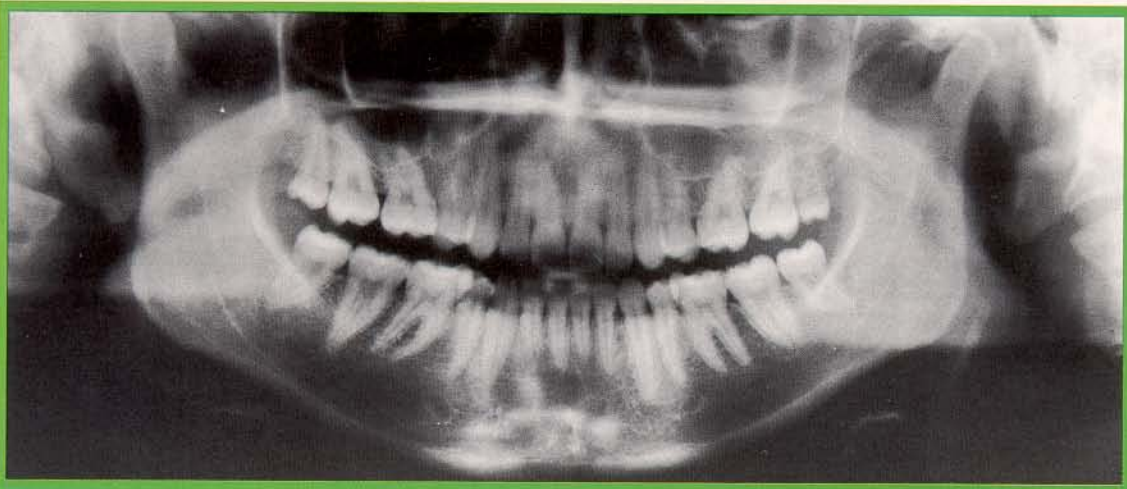Positioning of the Tongue

The quality and therefore the interpretability of panoramic radiographs are significantly influenced by summation effects, especially in the maxillary anterior region as a result of the filter effect of the tongue. If the tongue is maintained in its usual position during exposure, the roots of the maxillary anterior teeth are often invisible in the radiograph due to the lack of filter effect of the tongue. These teeth only become visible if the tongue is pressed against the palate during exposure, thus providing an addition effect. If the filtering effect of the tongue is lacking, subtraction effect occurs.



34 Incorrect tongue position

During exposure, the patient pressed the tip of the tongue against the crowns of the maxillary incisors, thus leaving an empty space below the palatal roof (see diagram, the tongue is depicted in blue). The cavity above the tongue permits a higher irradiation intensity in the region of the maxillary anterior tooth roots, so that these are overexposed and therefore invisible in the final radiograph.



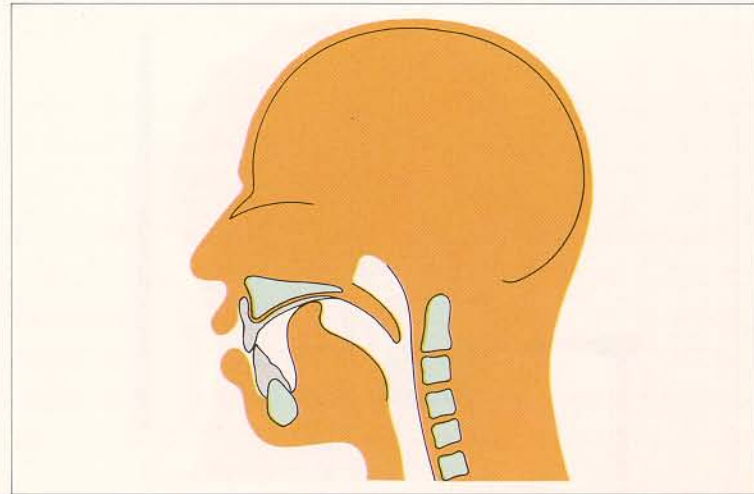
35 Same patient, correct tongue position

During exposure of this film, the patient correctly pressed the tongue against the roof of the mouth. In this position, the tongue acts as a radiation-absorbing filter (in the diagram above, the tongue is depicted in pink). With the tongue in this position, the radiation is weakened before it reaches the roots of the maxillary anterior teeth, and therefore the roots are more clearly visible in the radiograph.

Patients will most likely not understand the mechanism by which panoramic radiographs are made. To avoid incorrect radiographs and the subsequent excessive radiation exposure (retakes!), it is absolutely necessary to instruct the patient appropriately before exposure. Practicing correct tongue position is time-consuming, but it always leads to significant improvement of radiograph quality, especially in the maxilla.

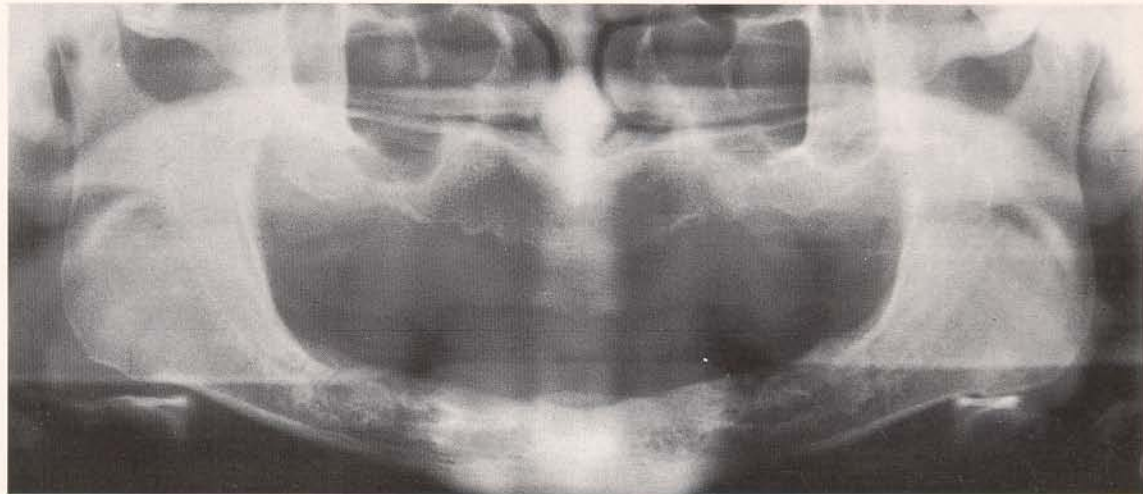
Depiction of the Alveolar Ridges

The depiction of the alveolar ridges in edentulous patients can sometimes present difficulties because the usually thin alveolar ridge of the maxilla is overexposed; this often occurs if the tongue is not pressed against the roof of the mouth during exposure. In contrast to previous opinions, in edentulous patients it is often effective to leave the patient's full dentures in place to act as a filter during panoramic radiography. An additional advantage is that with dentures in place it is possible to check the position of the condyles in the fossae.



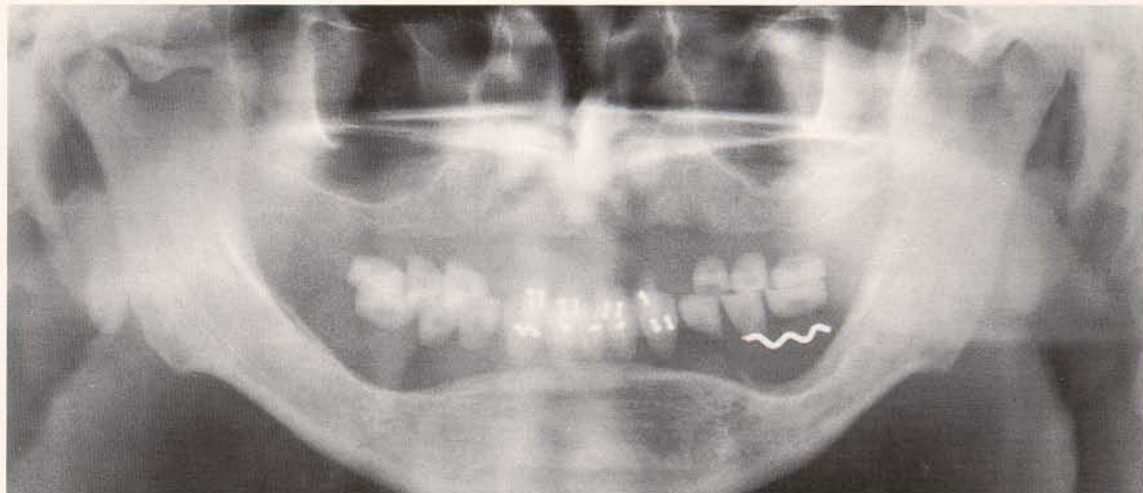
36 Improved radiographic technique

Improving the quality of panoramic radiographs of edentulous patients requires careful positioning and careful selection of the exposure data. Tongue positioning must be practiced. The diagram (above) shows the improvement of radiographic depiction of the alveolar ridges via use of the filter effect of acrylic prostheses.



37 Patient with complete dentures

If the desire is to gather information about occlusion and the position of the condyles in patients with TMJ problems, it is recommended that dental prostheses (even metal prostheses) be left in situ during exposure, with the patient in centric occlusion. Especially in the maxilla, acrylic prostheses serve as a filter, rendering the alveolar ridge more clearly visible on the radiograph.



The panoramic radiograph taken with the patient in habitual closure is the only film that depicts the occlusion in relation to the position of the condyles. The individual shape and axis position of the joints can render proper depiction more difficult. If the radiograph is taken with the patient biting on a bite block in the anterior edge-to-edge position, it is impossible to observe the position of the condyles in their fossae. The only way to get information about condylar position is with panoramic radiographs taken symmetrically with the patient in habitual occlusion.

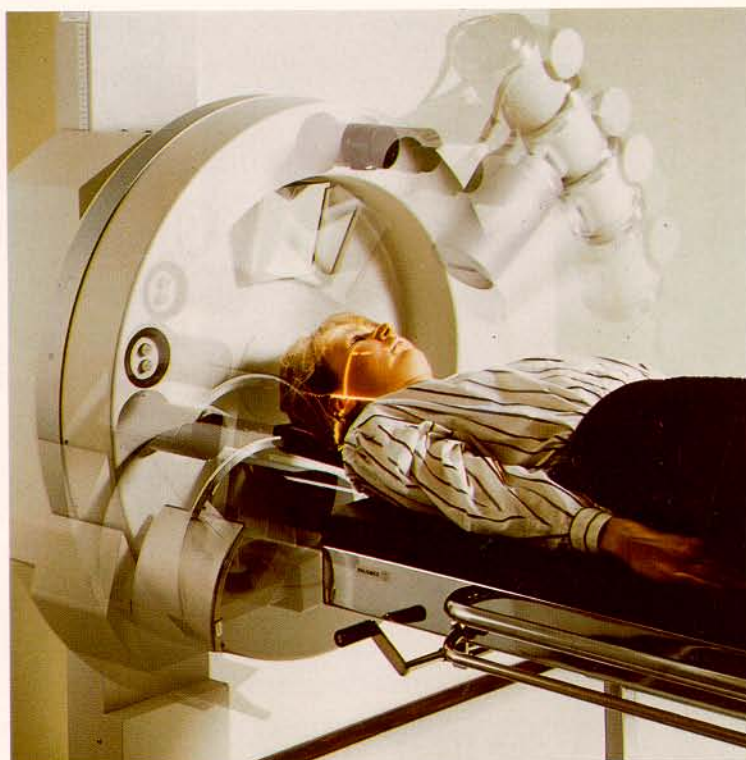
“Zonarc” – A Special Instrument for Clinics

Trauma patients are often incapacitated and cannot be appropriately positioned in panoramic radiograph equipment in common dental use. As a consequence, these patients cannot always be examined in the dental office.

For such patients, a special apparatus was developed. It permits zonographic examination of the facial skeleton on a reclining patient. The equipment shown here is the Zonarc M10 (Palomex Co.) which permits not only the preparation of panoramic radiographs but,

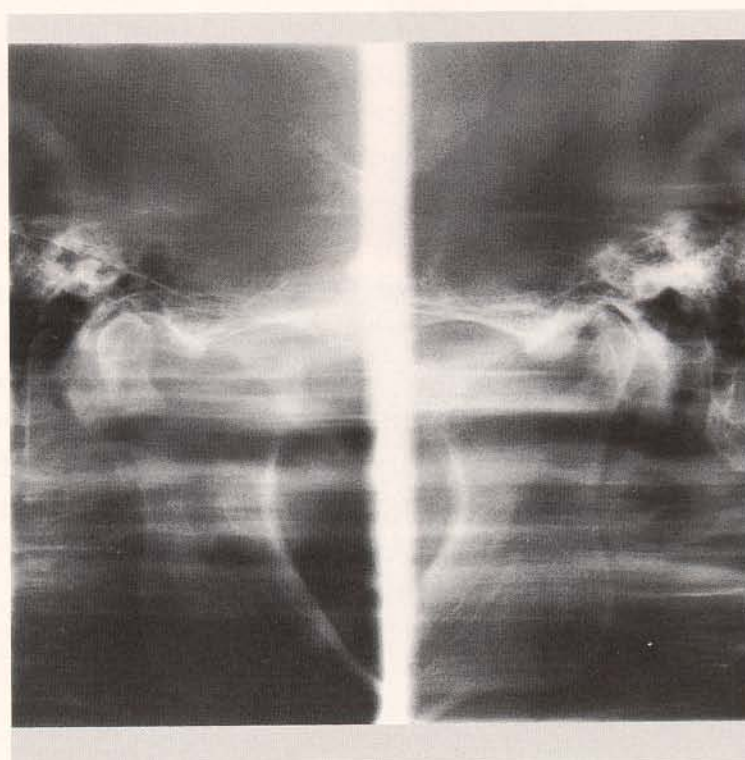
thanks to its numerous programs, also zonography projections that approximate cylinder-shape layers from various regions of the skull.

This technology demands that the clinician possess profound knowledge of spatial relationships as well as radiographic-anatomic knowledge of the two-dimensional representation of bent layers. A dentist who is experienced in evaluating normal panoramic radiographs will have no difficulty in this regard.



38 Zonarc, patient positioning and movement of the X-ray tube and film cassette

This figure shows the positioning of a patient who, for reasons of photographic clarity, is not draped with a lead apron. This trick photograph nevertheless provides a good idea of the coordinated movement of the X-ray tube and the film cassette around the head of the reclining patient.



39 Use of the Zonarc for simultaneous depiction of both temporomandibular joints with the patient in habitual occlusion

The differing depiction of the condyles in this case reveal that the condylar axes are positioned asymmetrically and in differing angles to the median sagittal plane. The right condyle also exhibits arthrotic alterations.

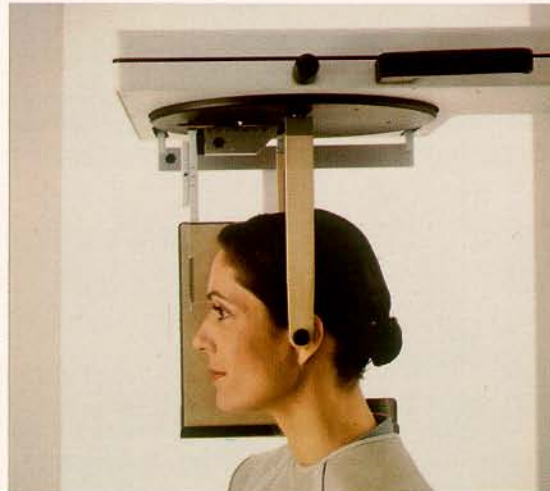
Special Radiographs Using the Cephalometric Attachment

The technique of cephalometric radiography in the dental practice, formerly used almost exclusively by orthodontists and oral surgeons has in recent years been simplified and expanded as a result of the extraordinary progress in the area of X-ray technology and film-foil combinations. Today, for example, use of the cephalometric attachment to the panoramic radiographic equipment permits taking the more important skull radiographs with low radiation dosage and with relatively good radiographic quality even in the dental office. This fact will surely enhance dental knowledge.

While modern electronics makes it possible for today's panoramic X-ray equipment to provide an almost unlimited array of projections, these generally do not significantly increase the clinician's information base. On the other hand, X-ray units that can be used with cephalometric attachments are capable of providing skull radiographs in the dental office, and this gives the clinician the distinct benefit of being able to visualize objects in any of the three dimensions. (See p. 109 ff. for the positioning technique for skull radiographs.)

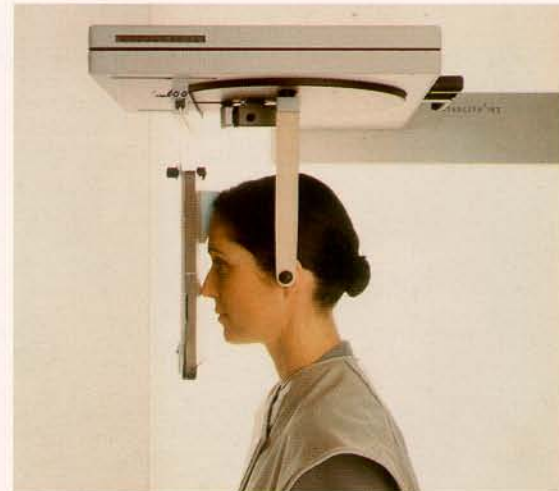
40 Positioning of the patient in the cephalometric attachment of a panoramic radiographic apparatus for a lateral cephalometric film

Note the position of the cervical vertebrae, which avoids superimposition upon the angle of the mandible.



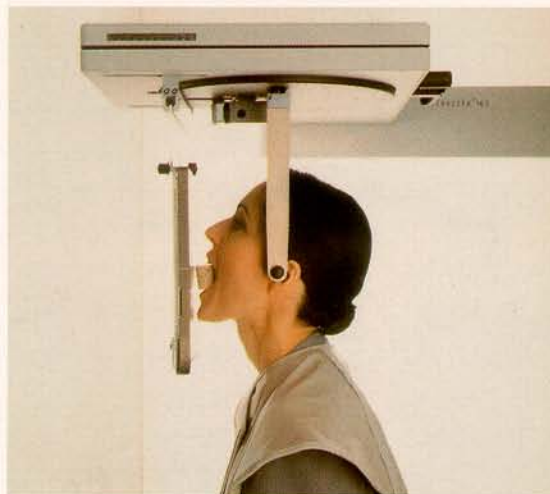
41 Positioning of the patient for a posteroanterior survey radiograph

Note the central ray projection, which causes the petrosal bone to be projected in the inferior portion of the orbit.



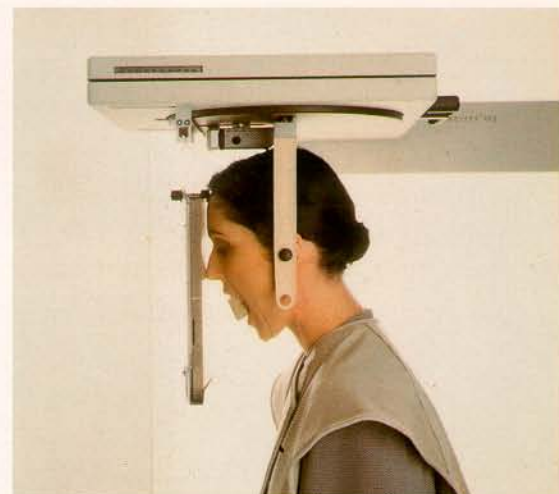42 Waters' projection

The correct positioning with maximum jaw opening shows the proper central ray projection to depict the maxillary sinus without superimposition by the petrosal bone.



43 Reverse Towne radiograph

The right photograph shows the correct positioning with maximum jaw opening. The condyles must be visible in the radiograph without any superimposition. The use of a bite block assures proper mouth opening and reduces the possibility of jaw movement during exposure.



In addition to a clear indication, the selected skull radiograph must also be taken according to the standards that govern conventional radiographic technique (see p. 109 ff.).

Radiographic Anatomy in the Panoramic Radiograph

Radiographic anatomy represents the basis for radiographic interpretation. It follows its own rules and demands understanding and knowledge of how X-rays work, as well as the normal anatomy of the irradiated spaces, depending on the radiographic technique used. Analogous to this essential knowledge, the following basic rules must be obeyed for every type of radiograph:

- The *tangential effect* of X-rays renders clearly visible in the irradiated space only those hard tissues with either high density or significant thickness; thin lamella which, at the moment of the exposure, are parallel or nearly parallel to the central ray simulate hard tissue of significant thickness and therefore appear in the radiograph as densely opaque. On the other hand, similar structures which, at the moment of exposure, are perpendicular to the central ray or nearly so may, even though they are relatively thick, appear transparent in the radiograph because of the exposure data necessary to penetrate the tissue.
- The *summation effect* of X-rays may lead to hard and soft tissue structures in the field being exhibited more clearly, or they may disappear entirely depending upon the selection of exposure data. For example, if soft tissues are projected upon one section of the bone, it will appear more dense than adjacent areas because the X-ray beam is already “weakened” when it hits the bone. On the other hand, if an air-containing space is projected onto a section of bone, the situation is one in which the X-ray beam is not weakened before it encounters the bone, penetrates it readily and therefore eliminates the typical radiograph features of bone. The first example is referred to as “addition effect,” and the second example as “subtraction effect.” The situation in such cases has absolutely nothing to do with radiographic signs of “sclerosis” or “resorption.”

Panoramic radiography is not an exception; it depicts in-focus layers of various thickness (but always thicker than 5 mm), and thus may be classified as a type of zonography. In the panoramic radiograph, the picture of the irradiated tissues is determined by the tangential effect and the summation effect; however, in keeping with the principle of tomography, all of the structures within the in-focus layer are shown relatively distinctly and somewhat enlarged, while all structures outside of the layer are depicted as blurred and reduced in size or as blurred, broadened and enlarged superimpositions; such appearance will depend upon whether the superimposed structures are between the in-focus layer and the film or between the in-focus layer and the focal spot.

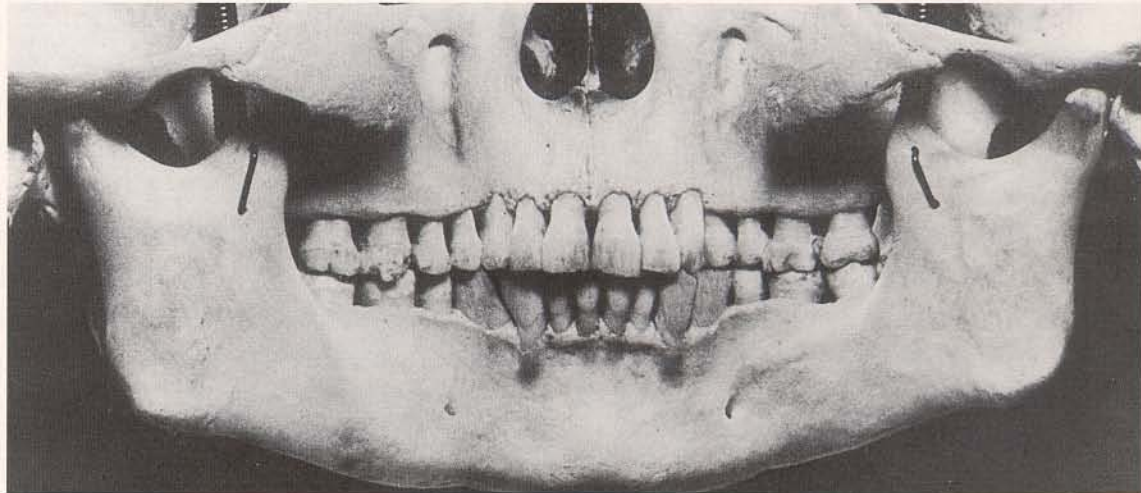
Survey of the Anatomic Structures Visible in a Panoramic Radiograph

The “trick” photograph of a human skull (Fig. 44) exhibits the surface bony structures, with the exception of the cervical vertebrae and the hyoid bone. Simply viewed, the picture is a composite of a frontal view and two lateral views of the facial skeleton. In an actual radiograph, these surface structures are superimposed by the anatomic spaces and structures lying beneath the surface. In keeping with the principle of zonography, structures such as the cervical vertebrae or the angle of

the mandible on the contralateral side are superimposed upon the object in question and therefore compromise its depiction. The sheer number of possibly visible structures is enormous. It is impossible to see all structures in a single picture. This is the reason why in this chapter we will present surveys and sections from various radiographs to give a complete and detailed demonstration of such structures.

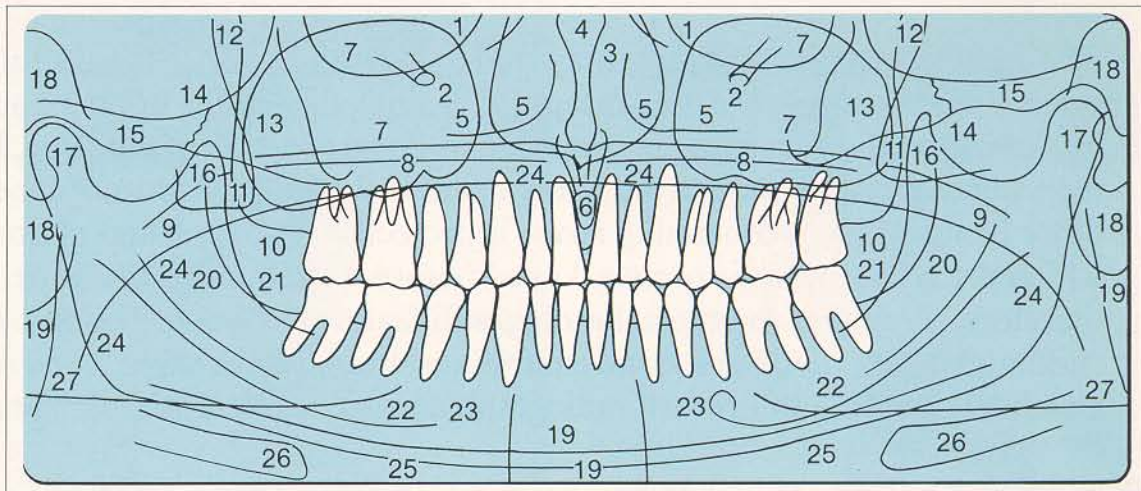
44 “Trick” photograph

This picture shows the bony surface structures of the facial skeleton that are captured in a panoramic radiograph. This picture does not, of course, show the hard tissue structures that lie beneath the surface, nor the soft tissues.



45 Diagram of the structures penetrated by the X-ray beam

Numbers 6 and 11 represent areas where numerous anatomic structures are close together; because of space limitation in this diagram, the structures are listed under a single number.



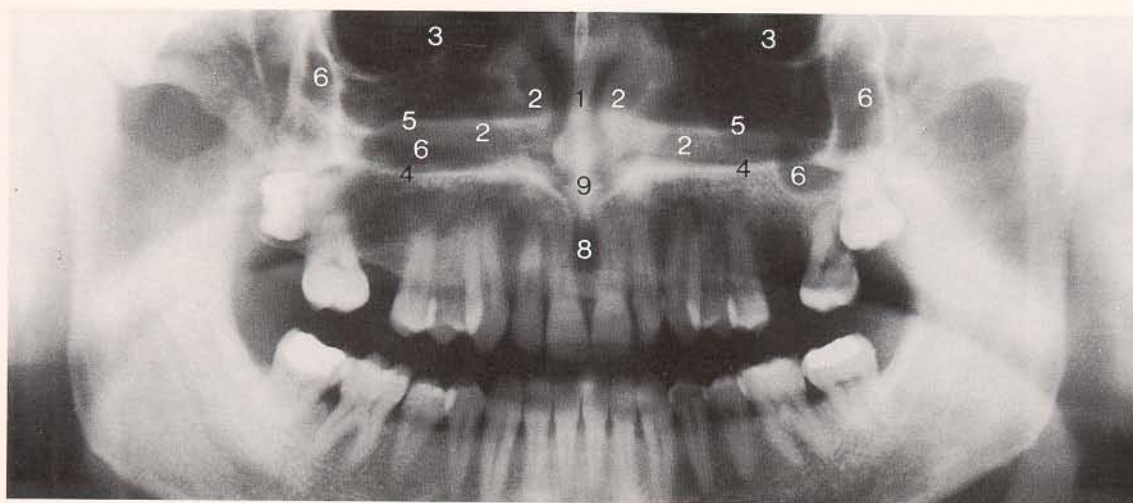
- | | |
|--|--|
| 1 Orbit | 14 Zygomaticotemporal suture |
| 2 Infraorbital canal | 15 Zygomatic arch, articular tubercle |
| 3 Nasal cavity | 16 Coronoid process |
| 4 Nasal septum | 17 Condyle |
| 5 Inferior nasal concha | 18 External ear with external auditory meatus |
| 6 Incisive foramen, superiorly located anterior nasal spine, nasopalatine canal | 19 Cervical vertebrae |
| 7 Maxillary sinus | 20 Temporal crest of the mandible |
| 8 Palatal roof and floor of the nose | 21 Oblique line |
| 9 Soft palate | 22 Mandibular canal |
| 10 Maxillary tuberosity | 23 Mental foramen |
| 11 Pterygoid processes (lateral and medial lamina) and the pyramidal process of the palatal bone | 24 Dorsum of the tongue |
| 12 Pterygopalatine fossa | 25 Compact bone of the inferior border of the mandible |
| 13 Zygomatic bone | 26 Hyoid bone |
| | 27 Superimposition of the contralateral jaw |

Ventral Portion of the Facial Skeleton

Depending upon the individual development of the facial skeleton and the positioning of the patient in the apparatus, the structures of the orbit and the nasal cavity appear in the picture. But regardless of whether or not these structures are visible or invisible in the radiograph, they do play a role in the overall appearance.

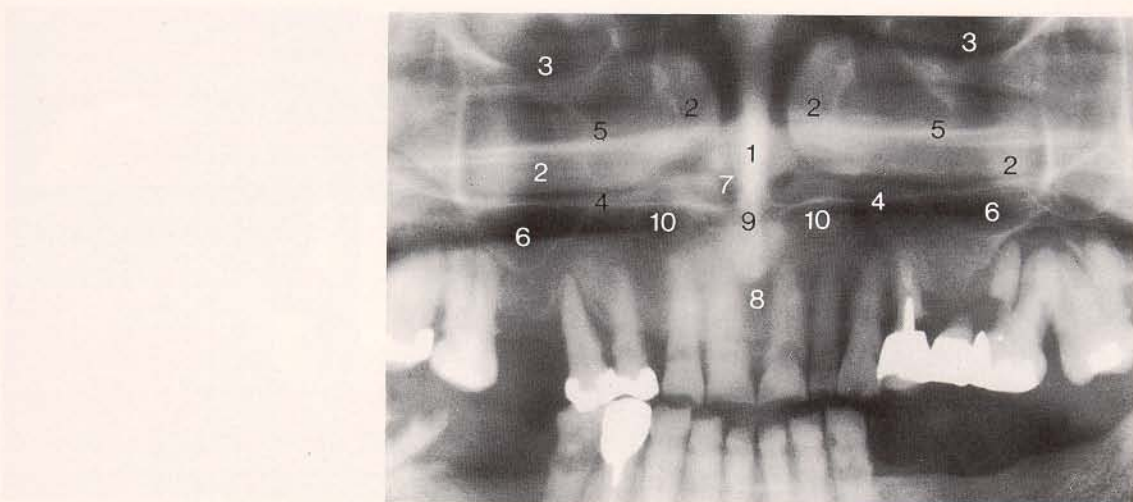
Taking as an example the inferior nasal concha, it is easy to imagine that the panoramic radiograph, as already mentioned, really consists of two broad lateral

and one narrow frontal view of the facial skeleton; structures lying further medial and superiorly, e.g., the superior nasal concha, are completely invisible. In the inferior portion of the orbit, foreign bodies are sometimes observed, and these appear to lie within the maxillary sinuses; as with the dorsal border of the sinus, the upper portion of the vertically aligned X-ray beam projects such objects obliquely and superiorly.



46 Structures of the nasal cavity, the floor of the nose/ palatal roof and the ventral portion of the maxilla

Depiction of the borders of the floor of the nose will depend upon the vertical angulation of the skull in the cephalostat.



47 Same region as above

Note the depiction of the inferior nasal concha, which is seen in its frontal appearance and in lateral projection. Note also the depiction of the right infraorbital canal, which is only visible thanks to the superimposition of the concha.

- 1 Nasal septum
- 2 Inferior nasal concha
- 3 Orbit, with right infraorbital canal
- 4 Laterobasal border of the nasal cavity
- 5 Horizontal portion of the pyramidal bone with the posterior border of the nasal cavity. The palatal roof itself, when it is visible at all, will be found between 4 and 5.
- 6 Maxillary sinus
- 7 Nasal entrance into the incisive canal
- 8 Incisive foramen
- 9 Anterior nasal spine with the nasal crest of the maxilla
- 10 Side of the nose

Ventral Portion of the Facial Skeleton in the Maxilla

Sometimes soft tissue structures appear clearly in the radiograph; this demonstrates that the addition effect must always be considered. On the other hand, the orbits and the maxillary sinuses, together with the nasal cavity and the epipharynx are easily penetrated by the X-ray beam, and this leads to darkening of the radiograph and a subtraction effect even on the bony background.

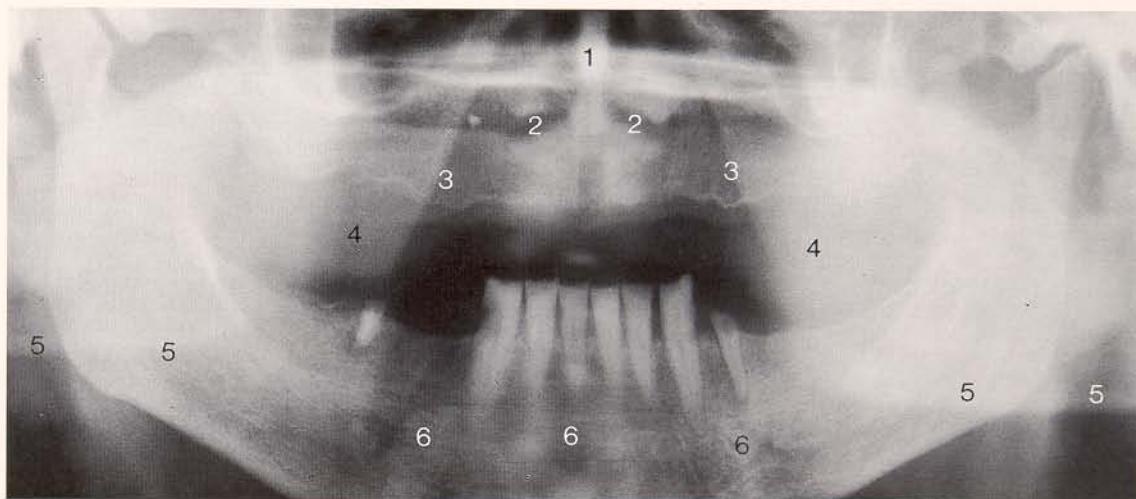
Although our primary purpose is not depiction of the soft tissues, an appropriate example will serve to

emphasize the result of the addition effect caused by soft tissues. This is emphasized because the shadowing influence of soft tissue may be of significance in diagnosis, especially if the exposure data were at or below the lower limit. On the other hand, the subtraction effects may lead the observer into diagnostic difficulties if the exposure data are at or above the upper limits.

These two examples clearly show the importance of a thoughtfully and carefully performed radiographic technique for the interpretability of radiographs.

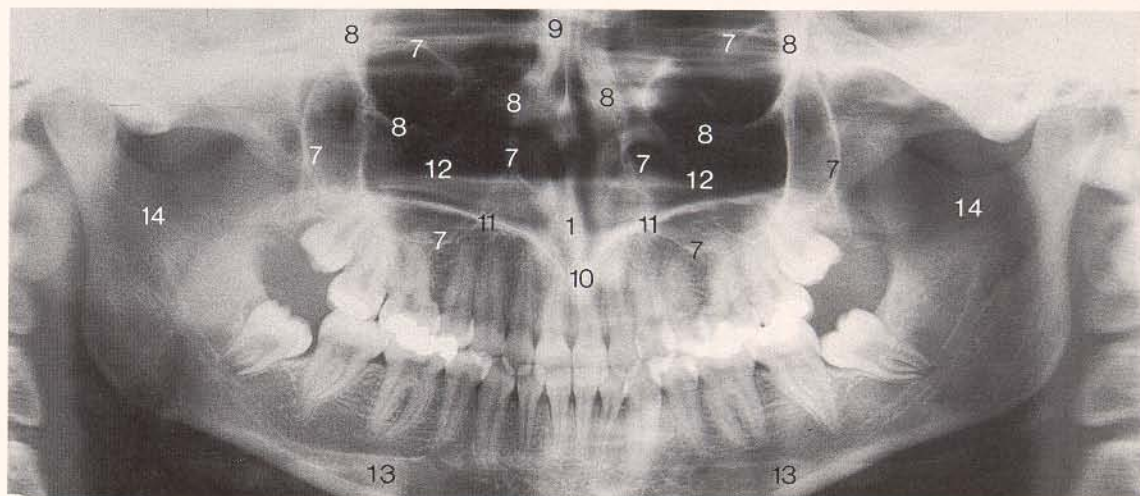
48 Addition effects

This panoramic radiograph clearly shows the addition effects caused by the superimposition onto the maxilla of the soft tissues of the cheeks; an addition effect can also be seen by the superimposition of the contralateral jaw on both sides of the mandible. In addition, both maxilla and mandible exhibit addition effects due to structures in the area of the cervical vertebrae. The chin holder of the positioning device is made of plastic and its shadow can also be seen in this film.



49 Subtraction effect

This film shows the result of the subtraction effect on the borders of the orbits caused by the influence of the superimposition of the air-containing maxillary sinuses. This radiograph was taken with the patient in maximum intercuspation.



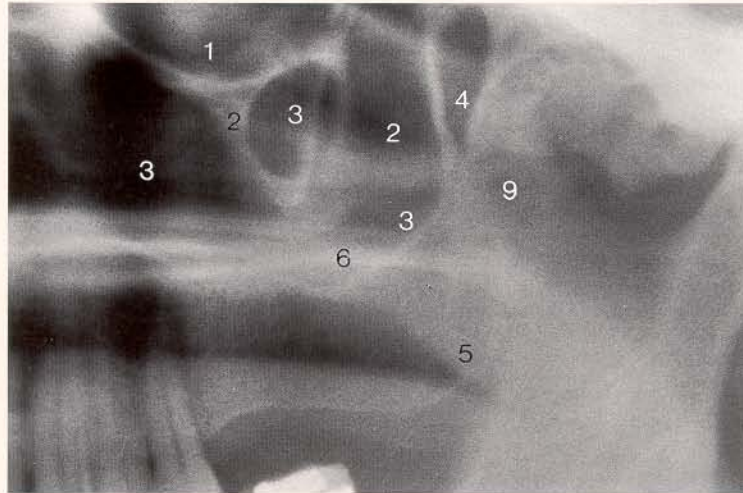
- 1 Nasal septum and maxillary nasal crest
- 2 Atlanto-occipital articulation
- 3 Nasolabial fold of the cheek
- 4 Cheek
- 5 Body of the mandible (distant from the film)
- 6 Plastic positioning device
- 7 Maxillary sinus (borders)
- 8 Orbit (borders)
- 9 Nasal bone
- 10 Anterior nasal spine
- 11 Laterobasal border of the nasal cavity
- 12 Horizontal portion of the palatal bone and dorsum of the tongue
- 13 Shadow of the hyoid bone
- 14 Air-containing epipharynx

Variations in the Maxillary Sinus

Even without technically elicited asymmetries, the individual and varying shapes and sizes of the sinuses demand a high degree of care and interpretation. The example given here presents what appears to be the existence of a cystoid radiolucency in the zygomatic region; however, CT revealed this to be an uncommonly shaped zygomatic recess of the sinus.

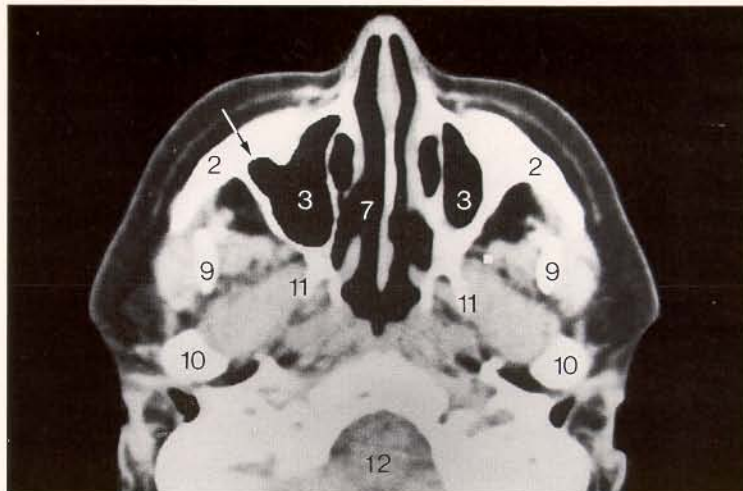
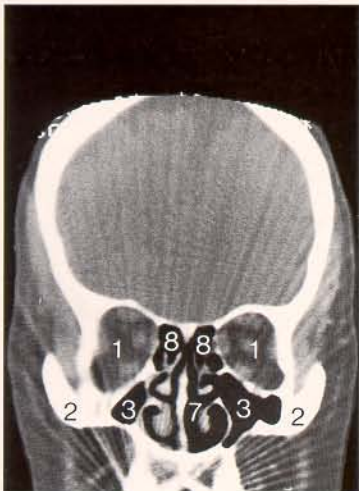
The maxillary sinus usually appears in radiographs as a single entity, separated in the region of the second premolar by a septum. The sinus usually consists of more or less pronounced areas that are known as the

anterior recess, posterior recess, zygomatic recess or alveolar recess. Sometimes the maxillary sinus appears as a space that is separated by heavy septa; in such cases it may be very difficult to distinguish radiographically between sinus recesses and dentogenic cysts, especially in the presence of nonvital teeth. From the dental point of view, the alveolar recess can usually be distinguished quite well in a panoramic radiograph, but the panoramic film should never be used alone for any examination of the entire sinus.



50 Section from a panoramic radiograph with a cyst-like radiolucency

The radiolucency in the region of the zygomatic recess of the maxilla mimics a pathologic process.



51 CT of the maxillary sinus region, skull reclined

Left: Frontal (coronal) section. Clearly visible is the asymmetry of the maxillary sinus (3) and the distention of the left sinus. Note in the CT the ray-like artifacts that resulted because the patient had metal bridgework.

Right: Axial section with the asymmetric sinuses. Note the distended shape of the left sinus (arrow).

- 1 Orbit
- 2 Body of the zygomatic bone
- 3 Maxillary sinus
- 4 Pterygopalatine fossa
- 5 Maxillary tuberosity
- 6 Floor of the nose and palatal roof
- 7 Nasal cavity with conchae and nasal septum
- 8 Ethmoid sinus
- 9 Coronoid process
- 10 Condyle
- 11 Pterygoid process, lateral and medial laminae
- 12 Occipital foramen

Retromaxillary Space

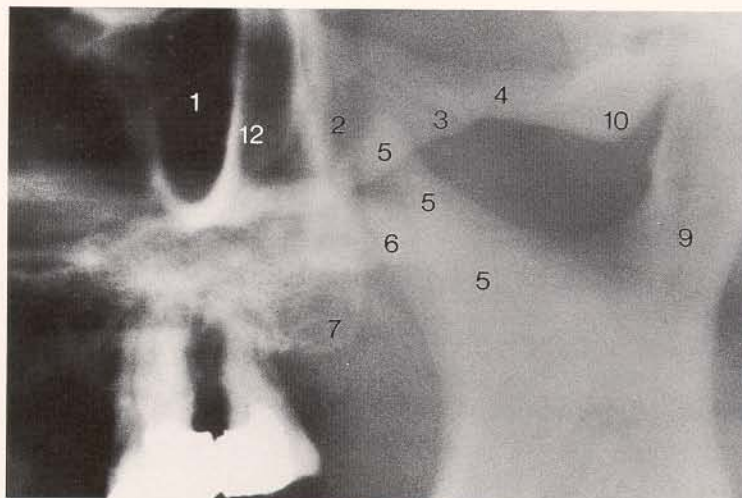
The retromaxillary space often presents as a complicated radiographic-anatomic picture because it is often superimposed by the zygoma, the pterygoid process with its two laminae and by the palatal bone. The lateral lamina especially often exhibits numerous variations, exhibiting bony defects and foramina; in the region of the coronoid process, these can produce subtraction effect and simulate the formation of “cystoid” lesions (for example, the pterygospinosum foramen of Civinini or also the crotaphiticobuccinator pore, which may occur near the foramen ovale). The “linea innominata”

resulting from the temporal aspect of the zygomatic bone represents the posterior portion of the V-shaped shadow which is well known in periapical radiographs of this region, and which “surrounds” the zygomatic recess of the maxillary sinus. It must not be confused with the dorsal border of the sinus, which opens into the anterior portion of the pterygopalatine fossa.

The maxillary tuberosity and the laminae of the pterygoid process are superimposed by the coronoid process, and this renders examination of this region difficult.

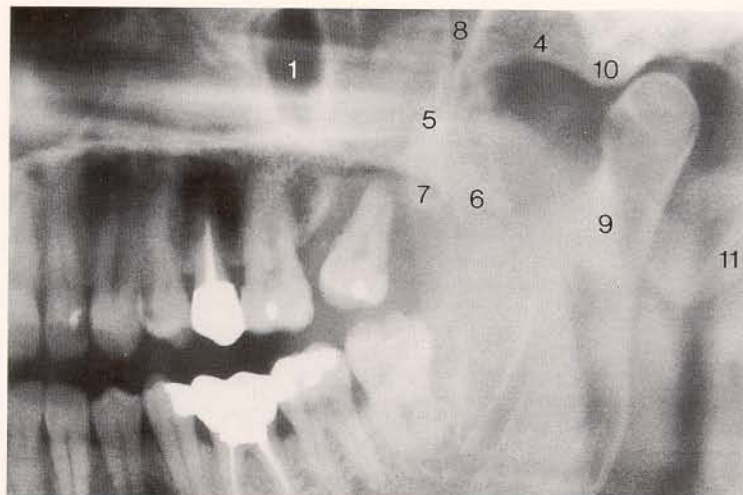
52 Depiction of the zygoma and the zygomatic arch

The zygomaticotemporal suture always courses from ventral superior towards dorsal inferior and cannot always be well visualized on radiographs. The surface of the zygomatic body is burned out by the X-ray beam; in this section, number 1 corresponds to a view into the zygomatic recess of the maxillary sinus.



53 Depiction of the pterygoid process

This is a section from a panoramic radiograph. The existing marginal periodontitis around tooth 28, permits a clearer depiction of the retromaxillary structures because of the reduced X-ray permeability.



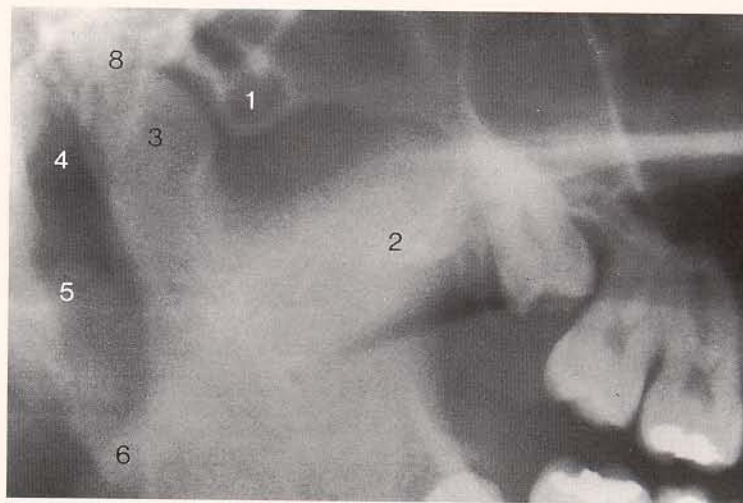
- 1 Maxillary sinus, zygomatic recess
- 2 Zygomatic bone
- 3 Zygomaticotemporal suture
- 4 Zygomatic arch
- 5 Coronoid process of the mandible
- 6 Pterygoid process of the sphenoid bone
- 7 Maxillary tuberosity
- 8 Pterygopalatine fossa
- 9 Articular process of the mandible
- 10 Articular tubercle of the temporal bone
- 11 Styloid process
- 12 Temporal aspect of the zygomatic bone (innominate line)

External Ear and Temporomandibular Joint Region

Often the auricle and the external acoustic opening are projected onto the articular process in such a way that the shadows caused by the soft tissues create an addition effect while the opening itself elicits a subtraction effect in the condyle; this is a situation that is easy to confuse with "arthritic manifestations."

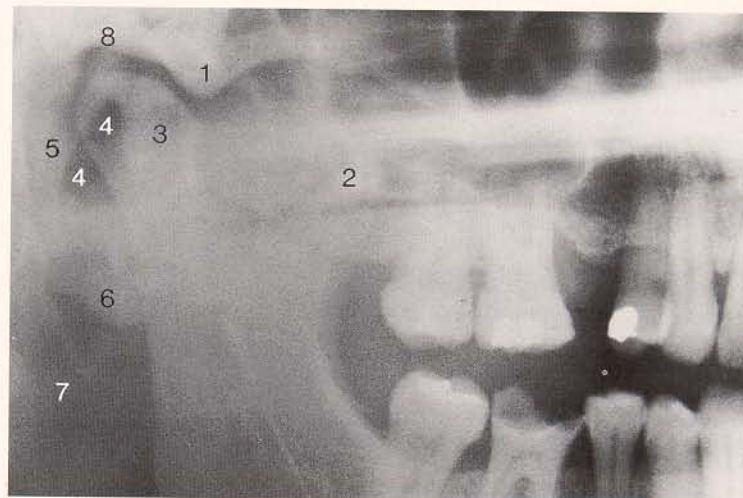
The panoramic radiograph taken with the patient in maximum intercuspation is the only radiograph that permits an information-rich examination of the occlusion in relation to the position of the condyles. One must also note, however, that the individual shape and axis

angle of the joints make evaluation more difficult. On the other hand, if the radiograph is taken with the anterior teeth in edge-to-edge relation, the position of the condyles in the fossae can of course not be evaluated. Radiographs taken symmetrically with the jaws closed can provide the opportunity to examine the condylar positions if the distance from the dorsal edge of the articular process to the ventral border of the condyle can be ascertained. However, definitive statements about condylar position and the shape of the roof of the joint capsule are usually not possible.



54 A particularly clear illustration of a pneumatized articular tubercle of the temporal bone

This and the following figure show the radiographic anatomy in this region. Note that in this and the subsequent figure the teeth were not in contact during the exposure.



55 Subtraction effect

This is a section from a panoramic radiograph that shows the subtraction effect wherein the condyle is superimposed, thus simulating osteolysis. Thorough knowledge of radiographic anatomy and of the subtraction effect will preclude incorrect interpretations.

- 1 Articular tubercle, pneumatized
- 2 Coronoid process superimposed upon the pterygoid process and portions of the soft palate
- 3 Condyle
- 4 Entrance of the auricle with external auditory opening
- 5 Soft tissue of the auricle
- 6 Ear lobe
- 7 Styloid process of the temporal bone
- 8 The medial portion of the glenoid fossa is usually depicted in panoramic radiographs, but is often superimposed by the tympanic crest (Fig. 54)

Palatal Bone in the Shadow of the Coronoid Process

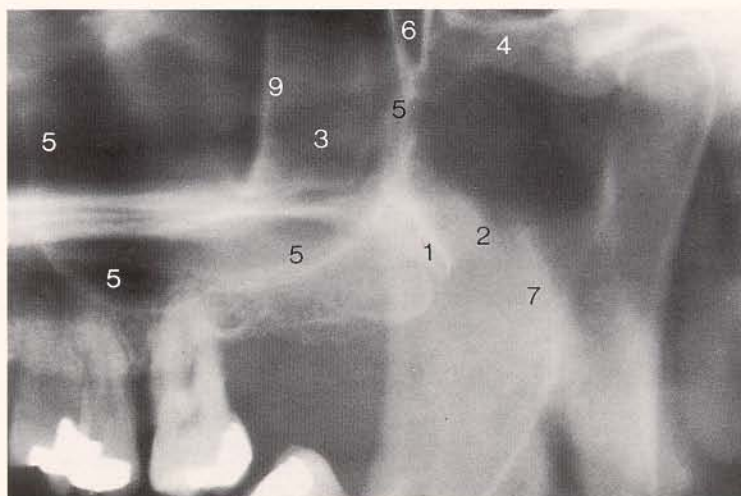
In addition to the lateral lamina of the sphenoid bone, sometimes also the hamulus of the medial lamina of the sphenoid bone and the pyramidal process of the palatal bone are visible. The coronoid process and those portions of the soft palate are superimposed in this region, and therefore an addition effect occurs.

It is imperative to remember that a panoramic radiograph of this region only provides a lateral view, and therefore the correct interpretations are rendered diffi-

cult because of the numerous and often surprising summation effects. The solution to this problem must be sought in radiographs that depict this region using a 90° alteration of the projection angle. The lateral view must therefore be supplemented (depending upon the indication) by a frontal or an axial depiction of the region, whether it is by conventional methods or via CT. Even the localization of impacted maxillary third molars should be determined as necessary with this knowledge.

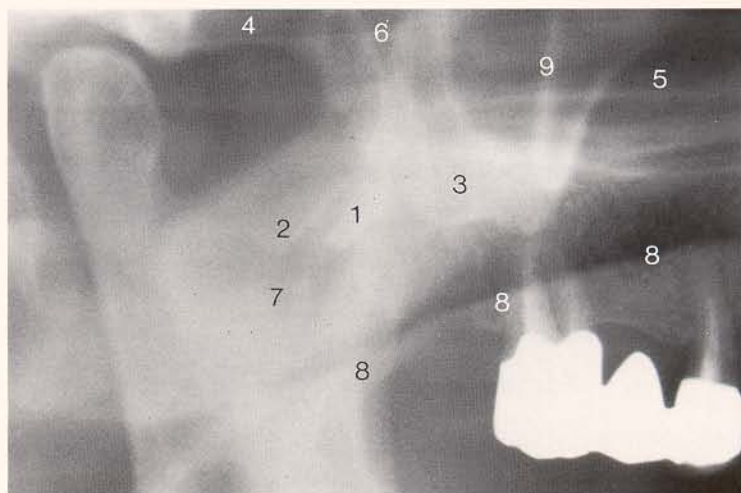
56 Clear illustration of the pyramidal process of the palatal bone, posterior to the maxillary tuberosity

The adjacent lateral lamina of the pterygoid process is visible. This is a section from a panoramic radiograph.



57 Superimpositions

This is a section from a panoramic radiograph. Despite the superimposition by the muscular attachments on the mandible and the soft palate, the body of the zygoma and the pterygoid process are clearly visible, as is the pyramidal process.

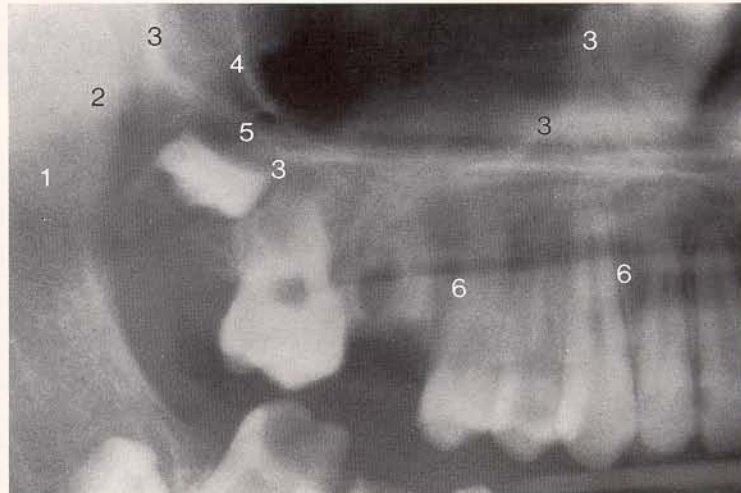


- 1 Pyramidal process of the palatal bone
- 2 Lateral lamina of the pterygoid process superimposed over the coronoid process
- 3 Body of the zygomatic bone
- 4 Zygomatic arch
- 5 Maxillary sinus (borders)
- 6 Pterygopalatine fossa
- 7 Soft palate
- 8 Dorsum of the tongue
- 9 Temporal aspect of the zygomatic bone (innominate line)

Tuberosity Region and the Cervical Vertebrae

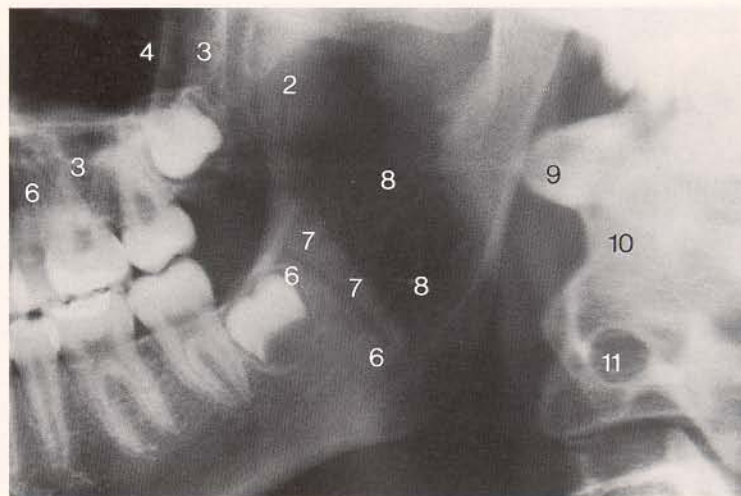
The major palatine foramen is almost never visible in the panoramic radiograph because of its position perpendicular to the central ray. On the other hand, one often sees the transversal foramen of the second cervical vertebra projected onto the contralateral side, appearing as an enlarged, round radiolucency. Further description

of the cervical vertebrae cannot be provided here, but the reader is referred to the special literature of this field. Figure 59 clearly exhibits the subtraction effect caused by the air-containing epipharynx on the depiction of the bony structures of the ascending ramus.



58 Tuberosity region with the dorsal portions of the maxillary sinus and the difficult-to-depict major palatine foramen

The major palatine foramen is vaguely visible superior to the tooth bud of the third molar.



59 Region of the angle of the mandible and the cervical vertebrae

This section from a panoramic radiograph reveals, in addition to the ascending ramus and the angle of the mandible, a portion of the cervical vertebrae with the transversal foramen of the second cervical vertebra.

- 1 Pterygoid process
- 2 Coronoid process
- 3 Maxillary sinus (borders)
- 4 Innominate line (temporal aspect of the zygomatic bone)
- 5 Major palatine foramen
- 6 Shadow from the soft tissue of the tongue
- 7 Shadow from the tissue of the soft palate
- 8 Air-containing epipharynx
- 9 Anterior tubercle of the atlas
- 10 Dens axis
- 11 Transversal axis foramen

Chin Region

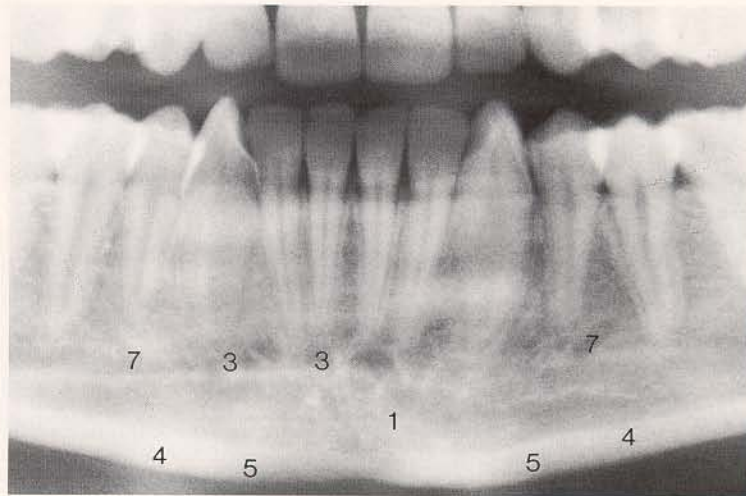
This region is often poorly depicted in panoramic radiographs, either because of the addition effect caused by the cervical vertebrae or the hyoid bone, or because of the subtraction effects if the mental fovea is positioned within the in-focus layer or the intervertebral spaces. Clear and sharp projections of this region, which are possible in young patients because of the low hydroxyapatite content of the vertebral column, nevertheless exhibit radiologically the complex structure of the symphysis following integration of the mental ossicles

and the eruption of the permanent anterior teeth. It is therefore not surprising that in this region ossifying fibroma and osteochondroma can be found in addition to the often observed post-traumatic pseudocyst and reparative granuloma.

Also here, it is important to remember that the panoramic radiograph can only provide an anterior summation picture of this region. Individual cases may demand depiction of the third dimension, either via occlusal radiographs or CT.

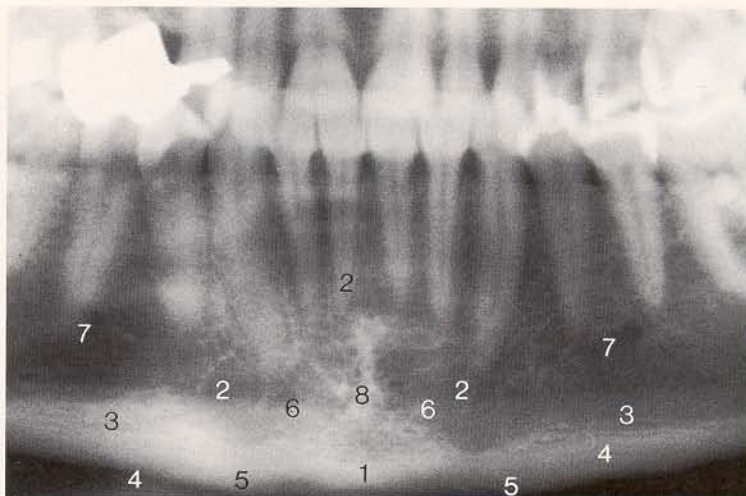
60 Chin region

This section from a panoramic radiograph depicts particularly well all of the possibilities for the existence of pathologic lesions. The previous symphysis, with the mental ossicles and the endochondral growth from the Meckle's cartilage have left traces of their former existence.



61 Chin region

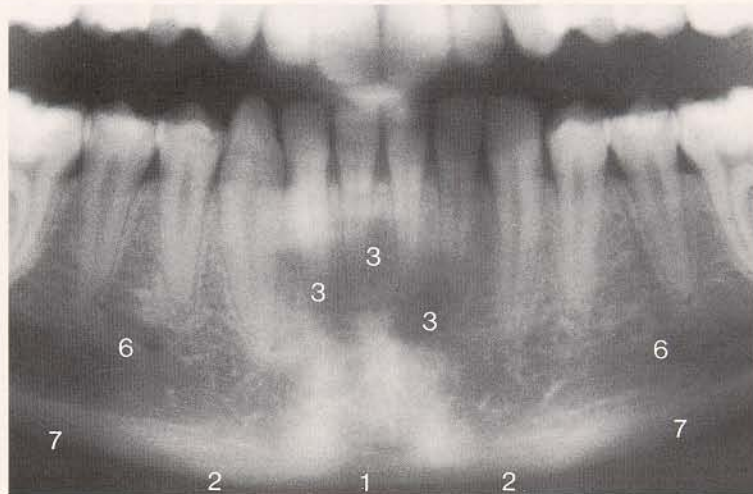
This section from a panoramic radiograph again shows the chin with the typical triangular shadowing of the protuberance and the hyoid bone. The mental foramen can be seen within the poorly trabeculated bony structure of the body of the mandible.



- 1 Mental protuberance
- 2 Mental fovea
- 3 Shadow of the hyoid bone
- 4 Compact bone of the mandible
- 5 Mental tubercle
- 6 Digastric (lingual) fovea
- 7 Mental foramen
- 8 Internal mental spine

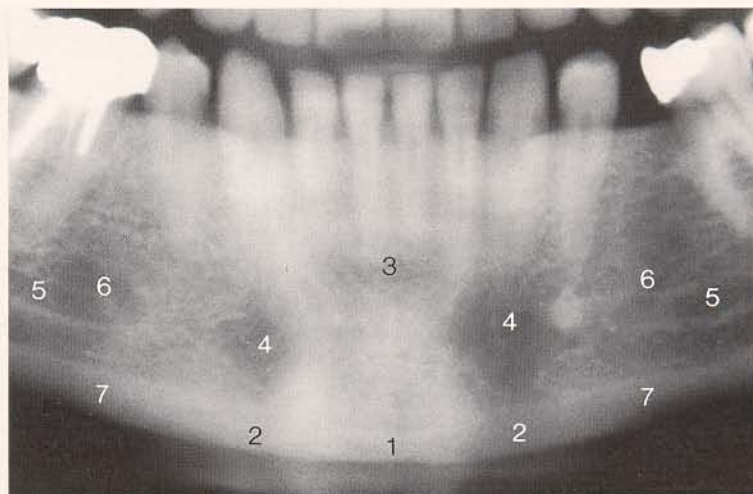
Figure 62 displays particularly well how the mental fovea may appear as a poorly demarcated osteolytic area if it is serendipitously located directly in the in-focus layer. Class II patients and those with pronounced fovea often exhibit this phenomenon. It is as well to mention that cystoid alterations in this region (p. 34) always depict a clear and typical margin contour if inflammation is not present. Malignant changes are extremely rare, with exception of the osteoclastoma.

Additional radiolucencies in this region may be caused by the intervertebral spaces between the first and the fourth cervical vertebrae. Depending upon the position of the skull in the cephalostat, these may present as narrow, roof-like radiolucencies, and may also be projected onto the anterior region of the maxilla (Figs. 35, 37, 66 and 67).



62 Clear depiction of a radiolucency caused by the upper portion of the mental fovea

Section from a panoramic radiograph. The buccolingual dimension of the bone is especially narrow in this area, and therefore often exhibits a well-demarcated radiolucency that is often difficult to distinguish from a pathologic lesion such as the traumatic pseudocyst. Note the reactive sclerosis in the periapical region. This followed disturbed eruption of vital tooth 44.



63 Clear depiction of the portion of the mental fovea inferior to the mental tubercle

Section from a panoramic radiograph. The mental fovea appears very frequently as a confusing radiolucency if the fovea itself is positioned directly in the in-focus layer. Note the small enostosis apical to tooth 34.

- 1 Mental protuberance
- 2 Mental tubercle
- 3 Mental fovea (upper portion)
- 4 Lower portions of the mental fovea as it encompasses the protuberance
- 5 Mandibular canal
- 6 Mental foramen
- 7 Compact bone of the mandibular border

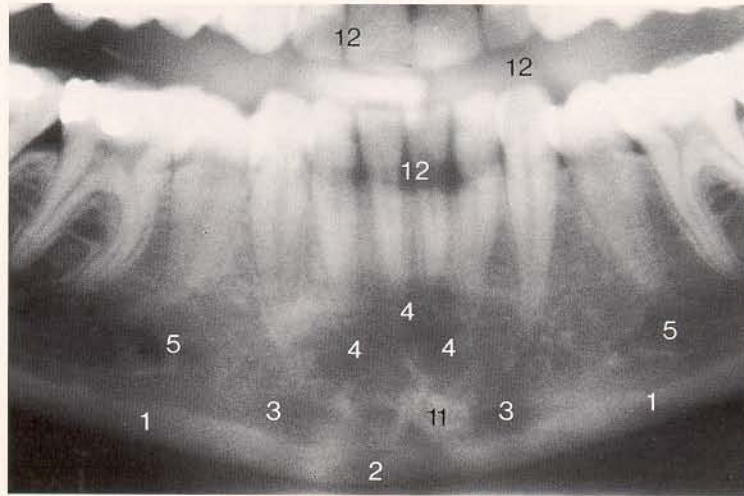
Chin Region and the Body of the Mandible

The section from a panoramic radiograph also exhibits a view of the chin region with an additional variant in terms of radiolucency. If the submaxillary fovea is especially pronounced, a significantly radiolucent and poorly trabeculated region may be observed beneath the clearly demarcated mylohyoid line. It is not infrequently diagnosed as a cystic alteration when observed

in periapical films because of the lack of a broader view. The mandibular canal is often invisible if the body of the mandible is excessively radiolucent, and often only the floor of the canal can be identified. On the other hand, the mylohyoid line may be superimposed upon the course of the mandibular canal and render its identification more difficult.

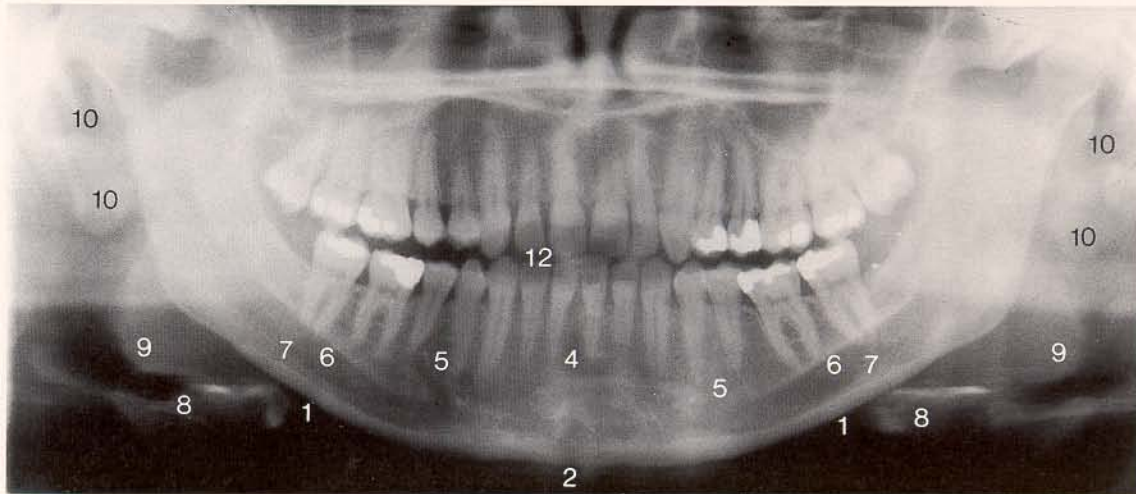
64 Digastric fovea

This section from a panoramic radiograph reveals the pronounced depressions that represent the attachments of the lingual digastric muscle, creating bilaterally the digastric fovea. Note also the small osteoma left of the midline on the inferior border of the mandible.



65 Mylohyoid line

This panoramic radiograph shows a clearly formed mylohyoid line on both left and right sides of the mandible. This structure is the attachment point for the mylohyoid muscle and is immediately coronal to the submaxillary fovea, which appears as a radiolucency on both sides.



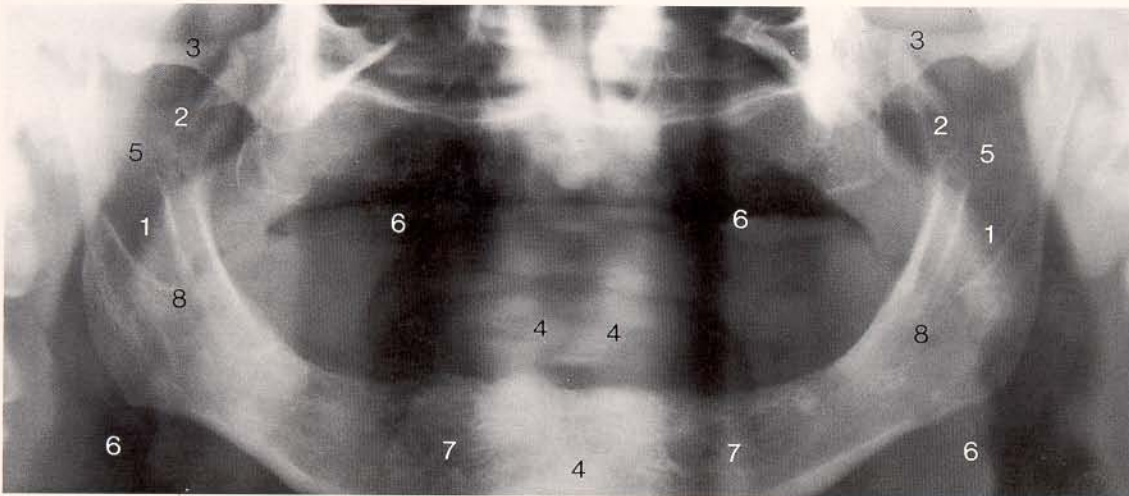
- 1 Compact bone of the mandible
- 2 Mental protuberance
- 3 Digastric fovea
- 4 Mental fovea
- 5 Mental foramen
- 6 Mylohyoid line
- 7 Submaxillary fovea
- 8 Hyoid bone
- 9 Base of the tongue
- 10 External auditory opening and soft tissues
- 11 Small osteoma
- 12 Radiolucency created by the lips

Mandibular Canal, Mandibular Rami and the Cervical Vertebrae

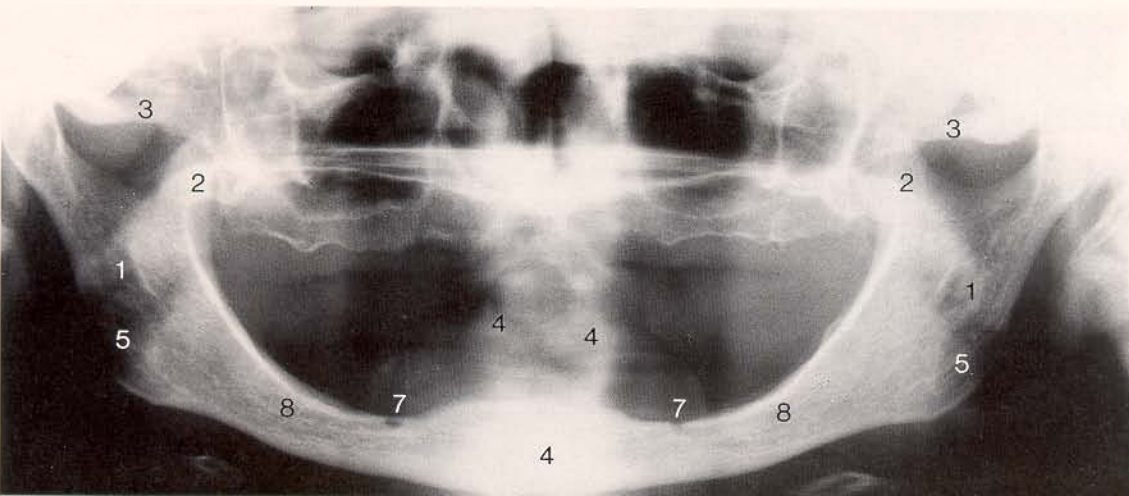
The mandibular foramen is usually difficult to discern on a panoramic radiograph because of the superimposition of the contralateral side of the jaw. Exceptions do occur, as shown in Figure 66, where the mandibular foramen is more inferior than normal and therefore readily visible. The course of the mandibular canal is usually readily visible in younger individuals to the second molar. From there to the mental foramen it is seldom readily visible because of the porosity of the canal walls, the superimposition of the highly radiolucent submaxillary fovea and the lack of trabeculation.

If the canal is visible, it appears as a fine radiopaque line. The mental foramen, located buccally, is superimposed by the bony lingual structures and is seldom clearly visible, but topographically more adequate than in periapical radiographs.

Examination of the mandible in panoramic radiographs is also complicated due to the addition effects by superimposition of the mandibular ramus onto the angle of the mandible on the opposite side; subtraction effects also may interfere due to the air-containing epipharynx, especially if the patient inhales deeply.

**66 Mandibular foramen**

This panoramic radiograph exhibits bilaterally well-formed mandibular foramina that are located more inferior than normal. This could be mistaken for osteolysis if the radiographic resolution of the ascending ramus were not sharp, because the depression is covered only by a lateral bony plate without spongy bone. Note also the depiction and superposition of the highly hydroxyapatite-containing cervical vertebrae, a phenomenon of age.

**67 Course of the ventral segment of the mandibular canal in an edentulous patient**

The atrophy of the alveolar process of the mandible has created a situation in which the mental foramen is at the crest of the ridge. This film also shows the subtraction effect caused by the air-containing epipharynx.

- 1 Mandibular foramen
- 2 Coronoid process
- 3 Zygomatic arch
- 4 Frontal view of cervical vertebrae
- 5 Subtraction effect caused by air-containing epipharynx
- 6 Base and dorsum of the tongue
- 7 Mental foramen
- 8 Mandibular canal

Mandibular Canal and Retromolar Structures

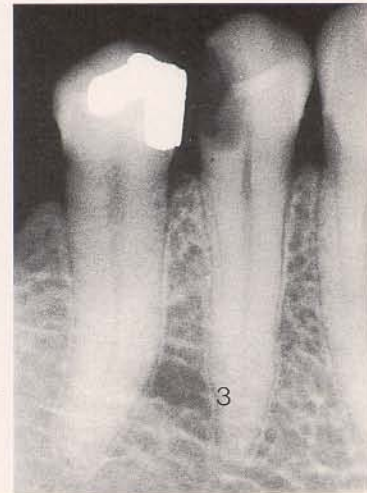
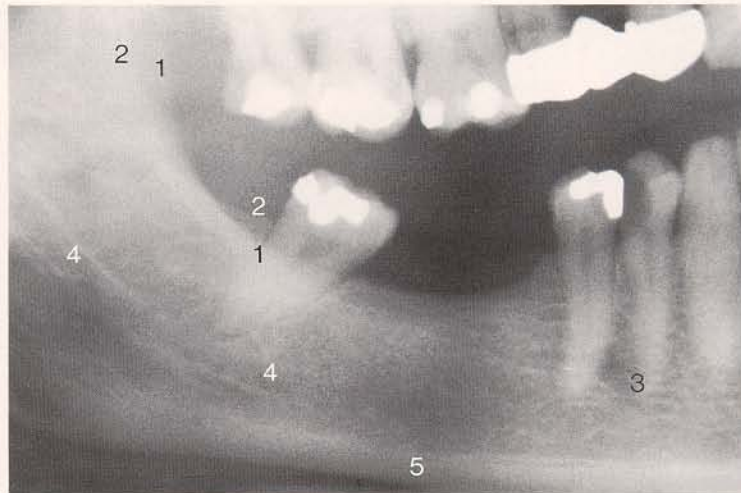
The structures of the body of the mandible and the retromolar region are usually targeted too steeply caudally when dental X-ray equipment is used. In addition, the long axes of the molars are inclined lingually. The panoramic radiograph provides a less distorted view of these structures because the central ray is targeted lingually and slightly from below in this region. In addition, if the mandibular canal and the mental foramen are visible despite the summation effect, the distance from these structures to the crest of the ridge is more faithfully

reproduced. A lateral tomograph can provide a better projection (as might be needed by an implantologist), but only if the skull is properly positioned with the mandibular canal parallel to the film. In addition, the use of low energy exposure is recommended because this will help to eliminate the summation effect on regular films and zonographs.

When making interpretations concerning retromolar structures, note that the lingual aspect of the retromolar area is projected upward.

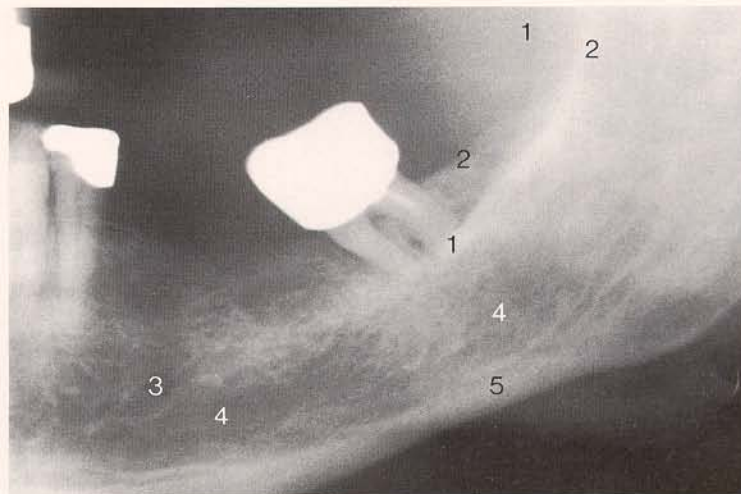
68 Position of the mental foramen

In this section from a panoramic radiograph (*left*) the mental foramen is depicted in its normal location. In the periapical film (*right*), however, the mental foramen appears more coronal than normal. The external oblique line together with the temporal crest comprise the retromolar trigone.



69 Radiographic anatomy in the dorsal section of the body of the mandible at the transition into the angle of the mandible

This section from a panoramic radiograph and that above (Fig. 68) demonstrate that the mandibular canal often cannot be discerned clearly along its entire length.



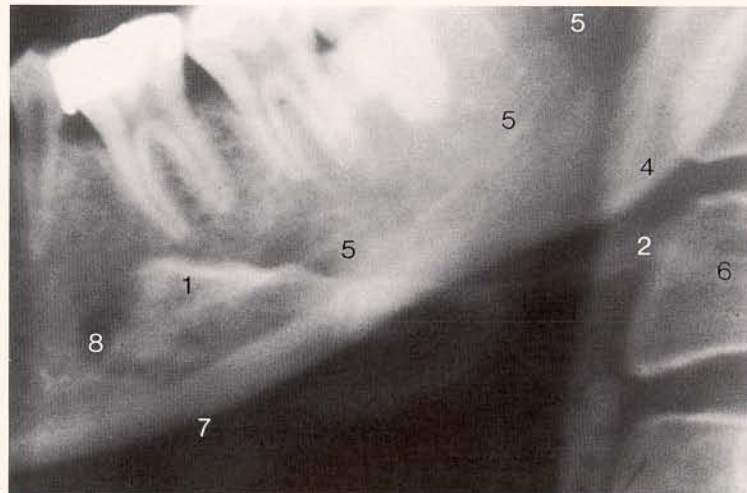
- 1 External oblique line (continuation of the anterior margin of the ascending ramus)
- 2 Temporal crest with retromolar trigone
- 3 Mental foramen
- 4 Mandibular canal
- 5 Compact bone of the mandible

Hyoid Bone and Cervical Region

If the hyoid bone moves during the exposure because the patient swallows, it usually appears very blurred on the radiograph and is projected up onto the body of the mandible as an addition effect. This addition effect occurs particularly frequently in prognathic patients with a flat mandibular angle, or if the mandible is positioned too steeply toward the cervical vertebrae. The artefact may give the appearance of a large stone in the duct of the submandibular gland. It is for this reason that the practitioner must recognize the importance of proper positioning of patient, skull and mandible before

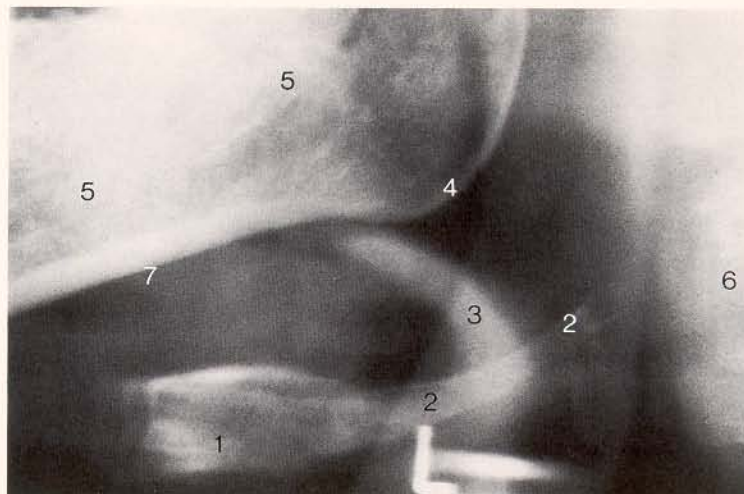
the exposure.

Sometimes even the epiglottis will be visible as an addition effect on the major horn of the hyoid bone. Using the conventional lateral jaw projection technique, with the central ray somewhat lower and the exposure made with lower energy it is possible to provide a better depiction of the hyoid bone (p. 40). Post-traumatic degenerative alterations of the hyoid bone are difficult to ascertain. Sometimes this may be accomplished using axial or lateral projections in film tomography or CT.



70 Addition effect in the body of the mandible

In this section from a panoramic radiograph, note the addition effect in the body of the mandible that was caused by superimposition with the hyoid bone. In this picture the mandible appears steeply oblique and near to the cervical vertebrae. This type of addition effect is difficult to avoid in prognathic patients with flat mandibular angles.



71 Region of the hyoid bone with superimposition by the epiglottis

The hyoid bone appears without distortion and in its normal position because the mandible was positioned forward and far removed from the cervical vertebrae. Note also the typical thin compact bone at the angle of the mandible.

- 1 Body of the hyoid bone
- 2 Major horn of the hyoid bone (the minor horn is almost never visible)
- 3 Epiglottis
- 4 Angle of the mandible
- 5 Mandibular canal
- 6 Cervical vertebrae
- 7 Compact bone of the mandible
- 8 Mental foramen

Hyoid Bone and Subtraction Effect from the Base of the Skull

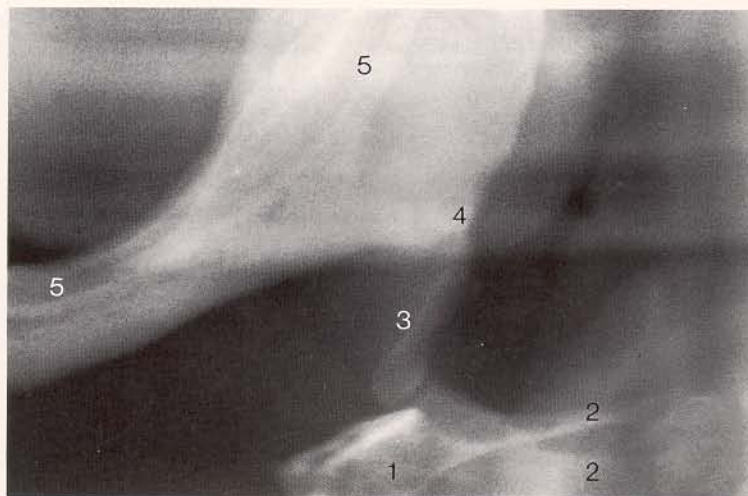
Very occasionally, one has the opportunity to see in a panoramic radiograph the minor horn of the hyoid bone, which may be connected joint-like with the body of the hyoid bone. This secures the flexible attachment of the hyoid bone to the styloid process via the stylohyoid ligament.

Equally rare is the observation of a summation effect from the base of the skull, which may become visible as

more or less sharply demarcated radiolucencies in the region of the semilunar suture. Such cases represent normal anatomic variation and include for example the pterygospinosum foramen of Civinini or the crotaphiticobuccinator pore (p. 30). Today such variations can be appropriately clarified using an axial CT.

72 Rare illustration of the minor horn of the hyoid bone

The minor horn of the hyoid bone appears to connect via a "joint" to the body of the hyoid bone. This represents a portion of the connection of the hyoid bone to the base of the skull. Injuries to the ligament apparatus, which sometimes lead to more or less complete ossification of the stylohyoid chain, may elicit occlusal disturbances that are difficult to diagnose clinically.



73 Enlarged radiolucent area above the semilunar suture

This is a section from a panoramic radiograph. The radiolucency appears as a typical subtraction effect extending from the base of the skull. Other radiolucencies in the ascending ramus of the mandible may be caused by the rare pterygospinosum foramen of Civinini or the crotaphiticobuccinator pore.

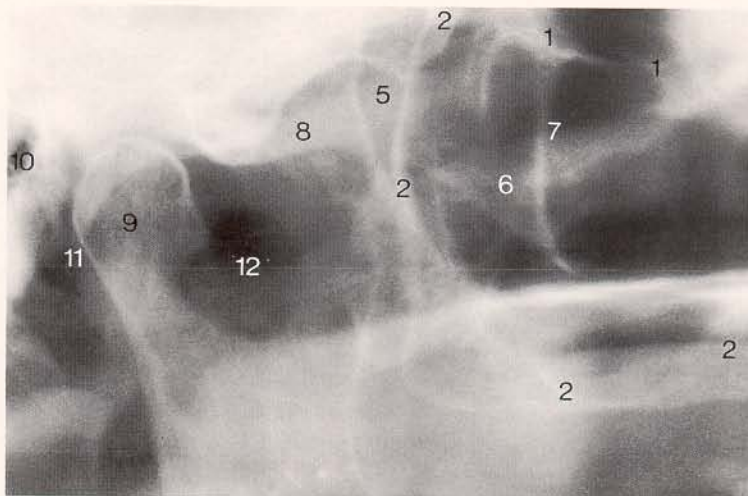


Figure 72:

- 1 Body of the hyoid bone
- 2 Major horn
- 3 Minor horn
- 4 Angle of the mandible
- 5 Mandibular canal

Figure 73:

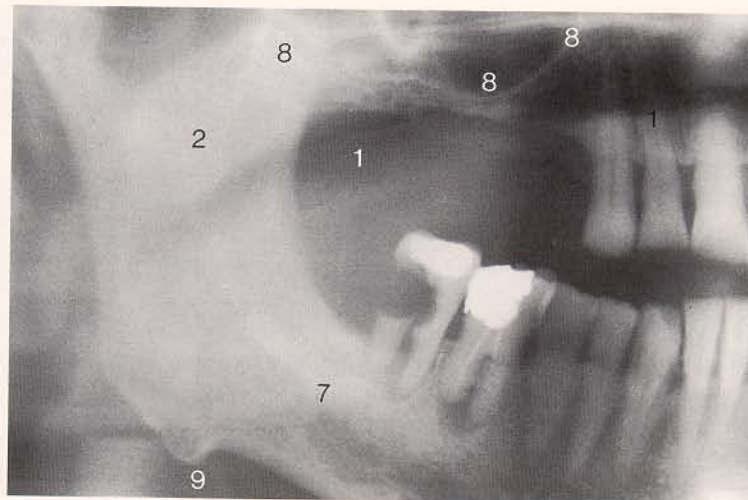
- 1 Orbit (borders)
- 2 Maxillary sinus (borders)
- 5 Pterygopalatine fossa
- 6 Zygomatic bone
- 7 Innominate line
- 8 Zygomatic arch
- 9 Condyle
- 10 Internal auditory opening
- 11 External auditory meatus
- 12 Radiolucency caused by the base of the skull

Angle of the Mandible and the Styloid Process

A tubercle sometimes forms either laterally from the attachment of the masseter muscle or lingually from the attachment of the medial pterygoid muscle, which anatomists term the angular process of the mandible. However, peripheral osteoma may also occur at precisely this location.

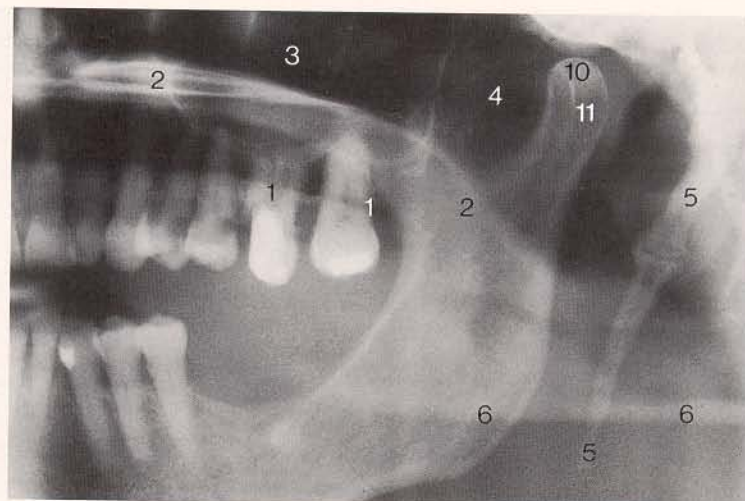
The stylohyoid ligament may partially or completely ossify, with formation of the so-called stylohyoid chain.

Often several joint-like connections can be discerned. Today, seemingly minor automobile accidents involving whiplash injuries often lead to long-term undiagnosed yet persistent damage to the stylohyoid ligament and the ossified portions of the stylohyoid chain.



74 Angular process of the mandible

In this section from a panoramic radiograph, the so-called angular process of the mandible is clearly depicted. This structure probably derives laterally from the attachment of the masseter muscle or lingually from the attachment of the medial pterygoid muscle.



75 Long styloid process

The styloid process has formed an almost complete stylohyoid chain to the minor horn of the hyoid bone. Note the radiolucencies caused by the air-containing spaces in this region.

- 1 Dorsum of the tongue
- 2 Floor of the nose with roof of the palate and the soft palate
- 3 Both maxillary sinuses superimposed upon the nasal cavity create a dramatic radiolucency
- 4 Air-containing epipharynx and the region of the posterior nasal aperture
- 5 Styloid process with joint-like connection
- 6 Radiopacity caused by the distant side of the mandible
- 7 Mylohyoid line
- 8 Maxillary sinus (border)
- 9 Angular process of the mandible
- 10 Condyle (medial)
- 11 Condyle (lateral)

Examination of Children and Adolescents Using the Panoramic Radiograph

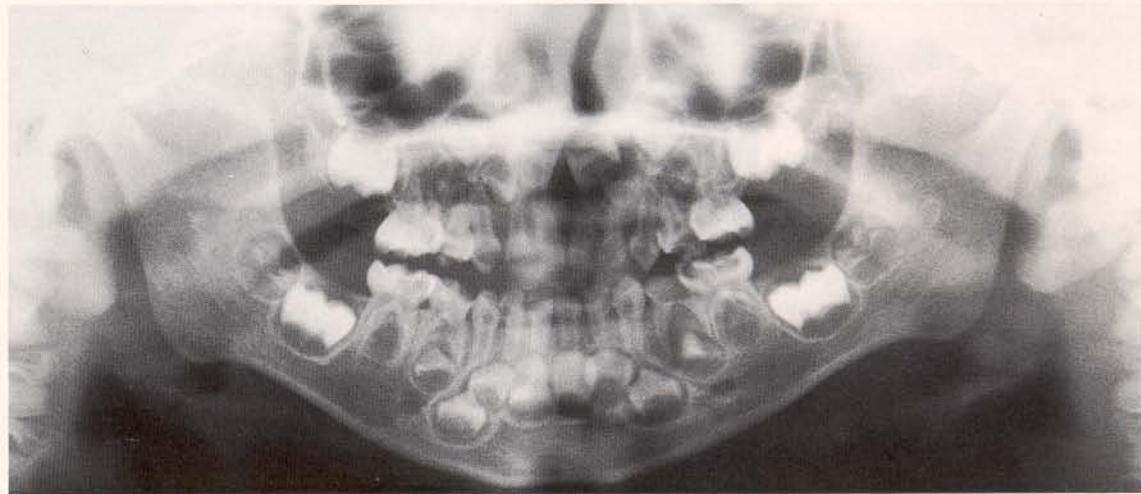
The prevalence of dental diseases has decreased in recent years because of the effect of dental preventive measures. Bite-wing radiographs are indicated for detection of coronal caries but they are not suitable for the examination of the *jaws*. The method of choice today to examine the jaws for anomalies and pathologic processes is panoramic radiography, and should be performed at a minimum during the 9th, 15th and the 20th years of life.

Summarized simply, the following developmental anomalies can be expected in children and adolescents:

- Disturbance of the normal developmental morphogenic processes of the bony structures of the jaw, including the temporomandibular joints in early childhood as well as during the course of the first and second decades of life, with formation of typical tumors and tumor-like lesions

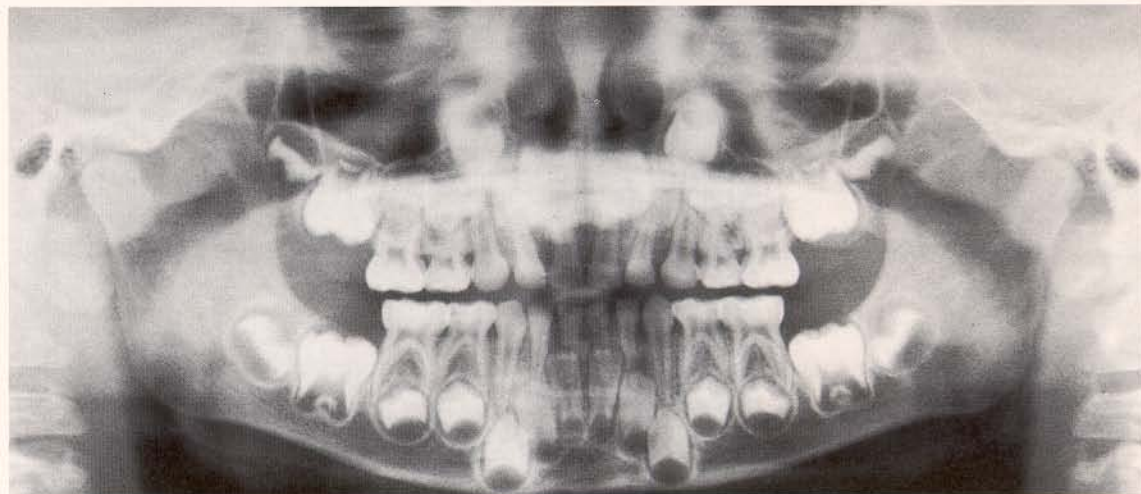
76 Panoramic radiograph of a 3½-year-old girl with deciduous dentition

While the formation of the crowns of the first permanent molars is complete, formation of the cusps of the second molars has only begun.



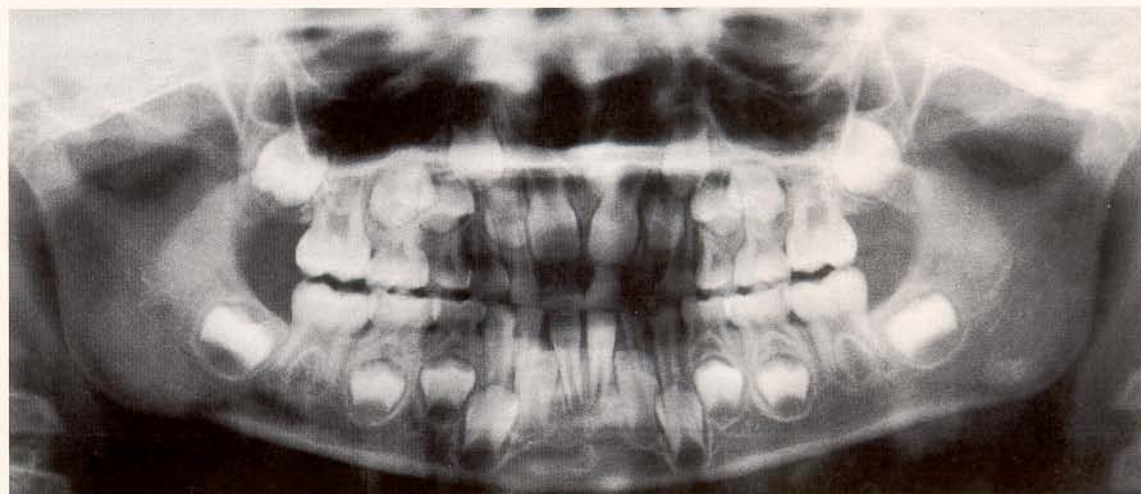
77 Panoramic radiograph of a 5-year-old boy with deciduous dentition

While root formation of the first permanent molars, the incisors and the canines is already in process, the formation of the crowns of the second permanent molars is not yet complete. Clearly visible are the maxillary sinuses.



78 Panoramic radiograph of a 6-year-old girl in early mixed dentition stage

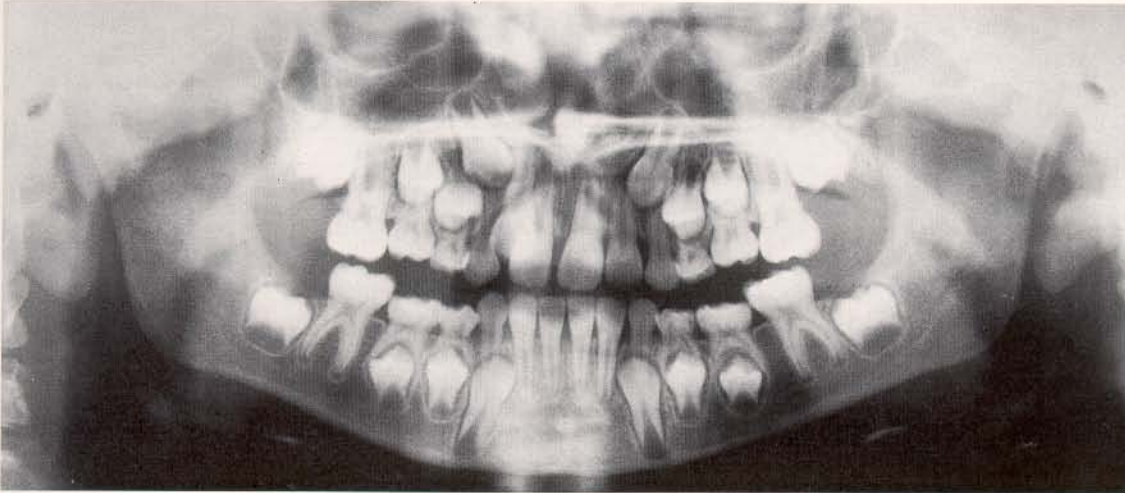
The first permanent molars and partially also the incisors have erupted; root formation is almost complete. The articular process has obviously begun to elongate.



- Improper development of the dental structures during the growth-intensive mixed dentition stage, with congenitally missing or supernumerary teeth as well as formation of typical odontogenic cysts and tumors, especially in the second decade of life
- Dysgnathia
- Systemic diseases

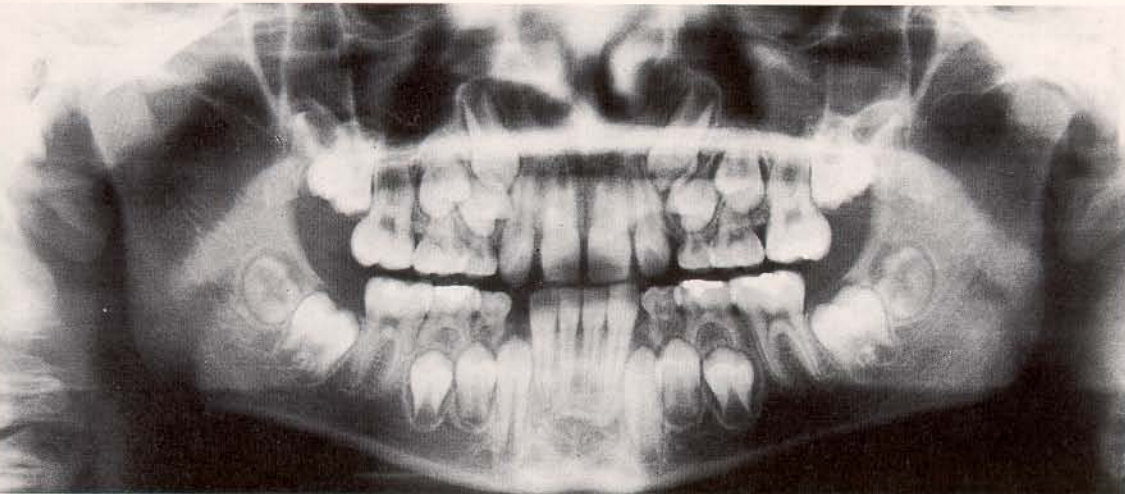
Specific dental diseases and inflammatory processes in the jaws may also play additional roles.

The selection of panoramic radiographs presented here derived from a 3½-year-old child to an 18-year-old adolescent. These films depict the development of the teeth and the maxillofacial structures in the facial skeleton of young persons. Of special note is the development of the maxillary sinus in the skull of early childhood, as well as the development of the ascending ramus of the mandible and the formation of the temporomandibular joints.



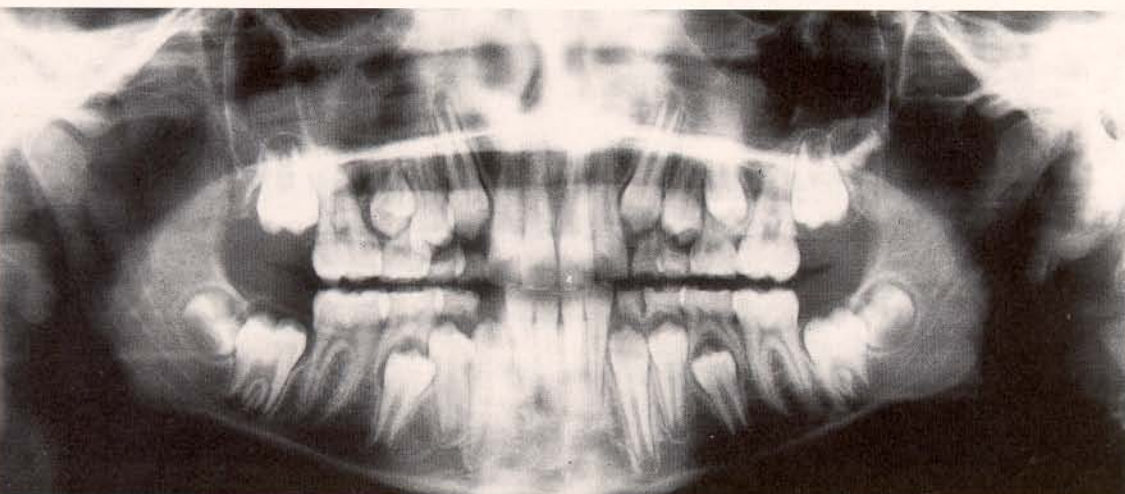
79 Panoramic radiograph of an 8-year-old girl in the mixed dentition stage

The apices of the roots of the first permanent molars are forming. Root formation of the other permanent teeth is progressing.



80 Panoramic radiograph of a 10-year-old girl in the mixed dentition stage

The formation of the apical foramina of the roots of the first permanent molars is complete. The crowns of the extremely variable third molars are visible.

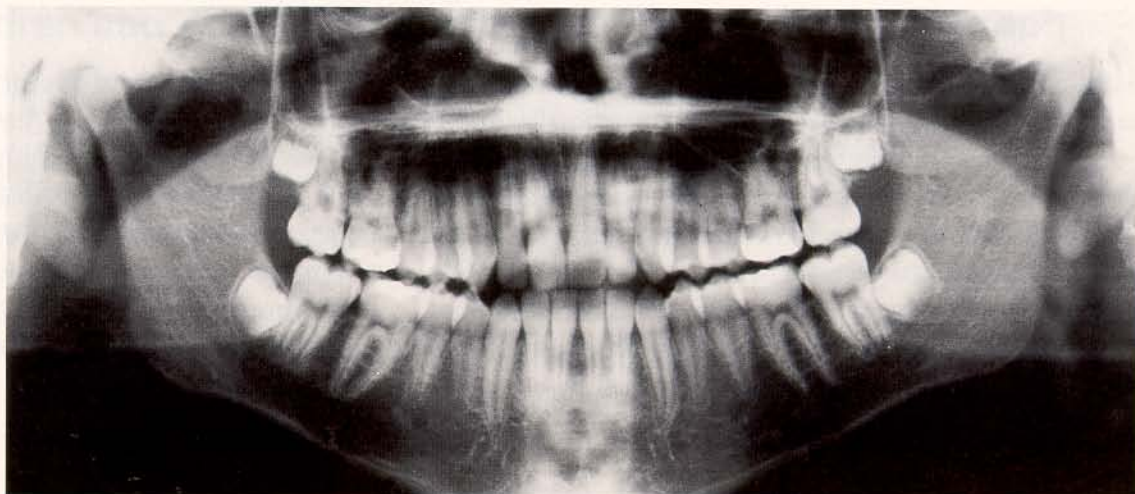


81 Panoramic radiograph of a 12-year-old girl in the mixed dentition stage

The deciduous canines and the deciduous molars are being resorbed by the erupting permanent teeth. The second permanent molars are erupting. The condyles no longer exhibit the round shape characteristic of children.

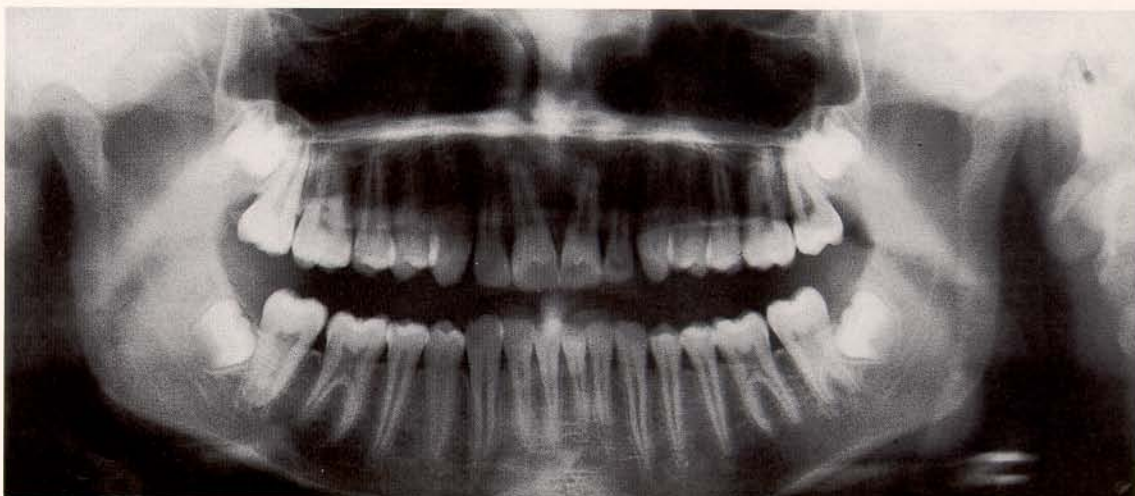82 Panoramic radiograph of a 14-year-old male with permanent dentition

The roots of the permanent teeth and most of the apical foramina have formed.



83 Panoramic radiograph of a 16-year-old female with permanent dentition

The root canals of the most recently erupted teeth are becoming narrower. The extremely variable third molars appear in various stages of development.



84 Panoramic radiograph of an 18-year-old male with fully developed permanent dentition

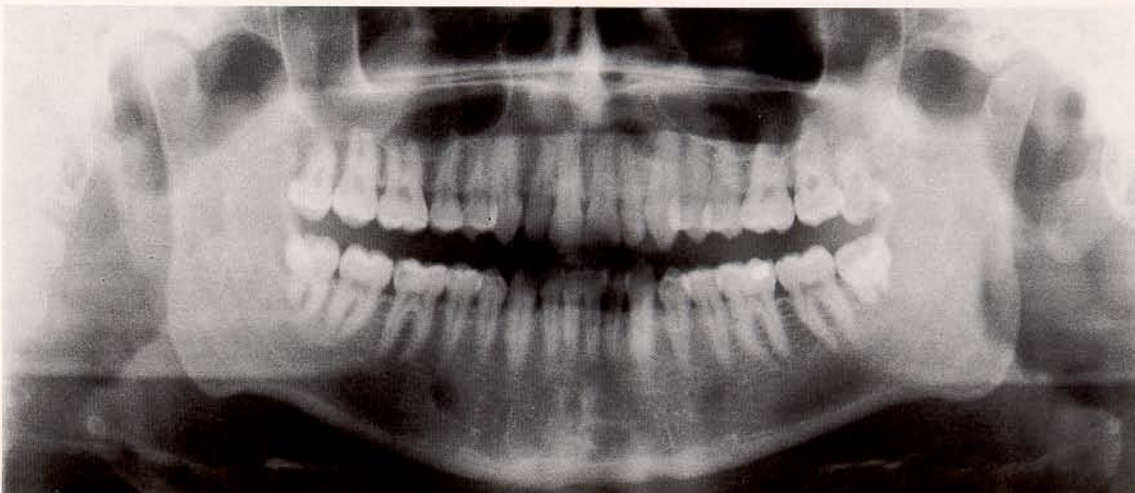
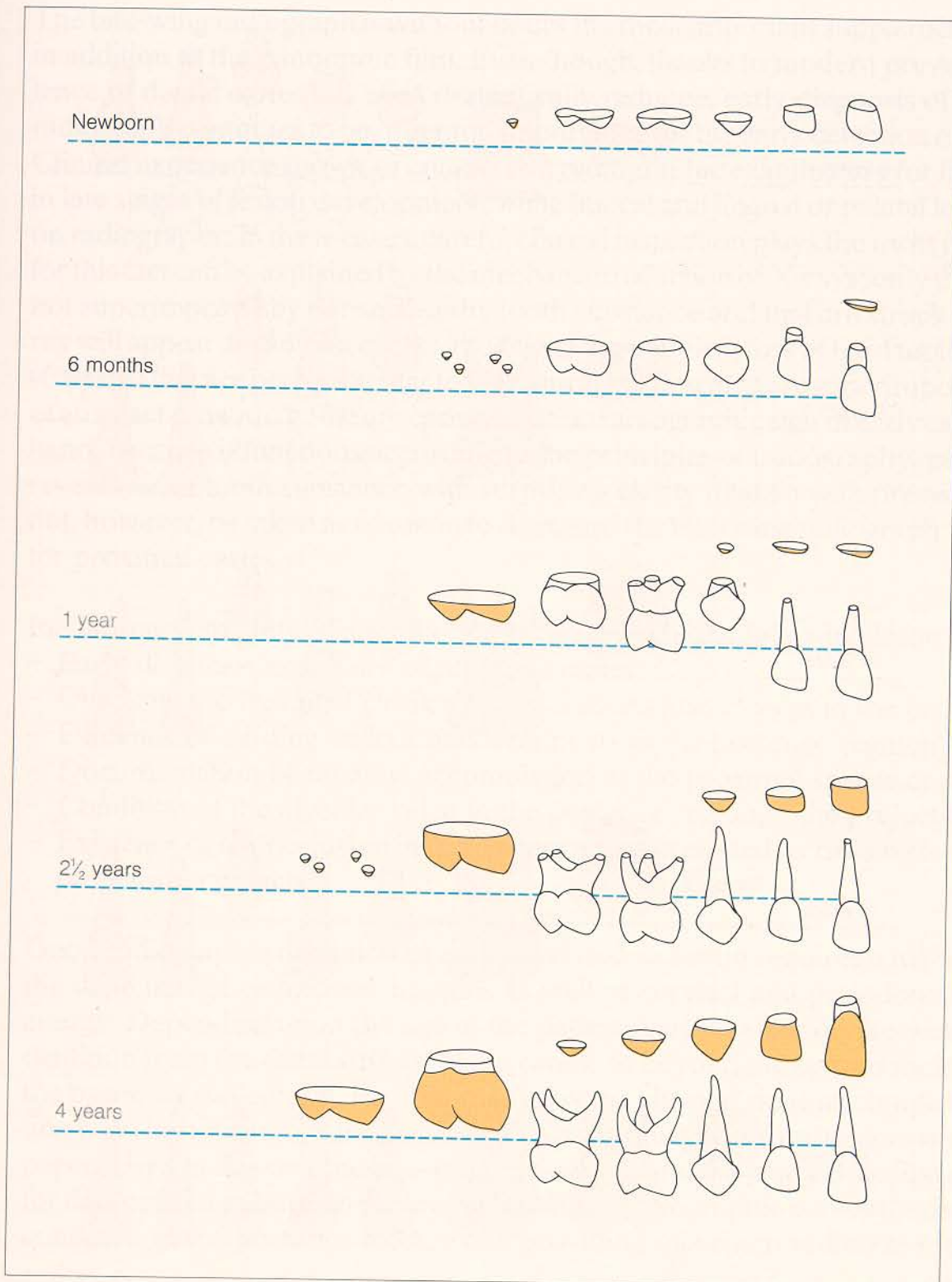


Diagram of Formation and Eruption of the Deciduous Teeth

The eruption of the deciduous teeth occurs according to the following time sequence:

Central incisors	6 – 8 months
Lateral incisors	8 – 12 months
Canines	15 – 20 months
First deciduous molar	12 – 16 months
Second deciduous molar	20 – 40 months



85 Formation and eruption of the deciduous teeth of the maxilla

The eruption times of the deciduous teeth in the mandible are very close to their maxillary analogues.

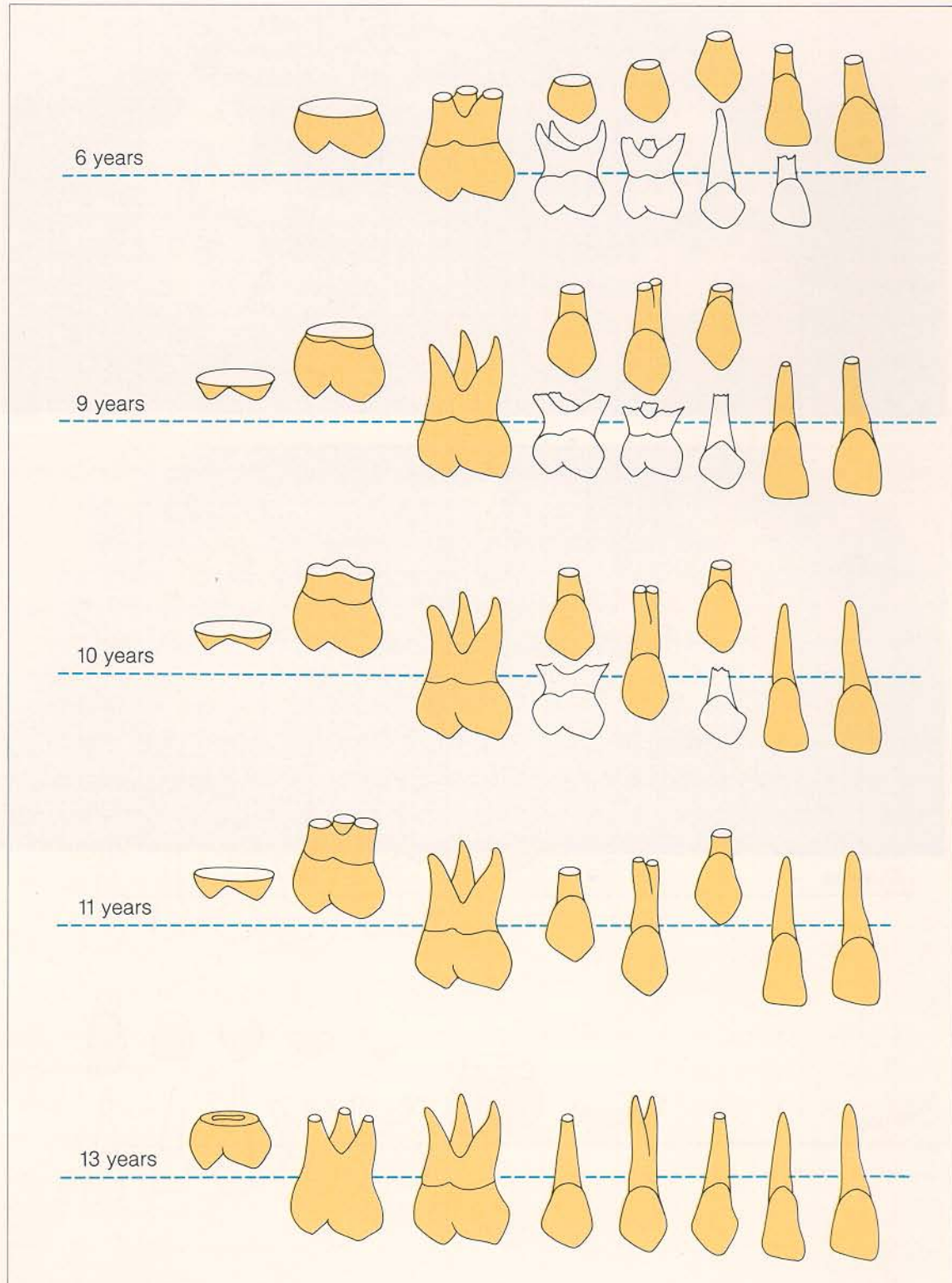
Diagram of the Formation and Eruption of the Permanent Teeth

The eruption of the permanent teeth usually occurs according to the following time sequence:

Central incisors	6 – 8 years
Lateral incisors	6 – 8 years
Canines	10 – 14 years
First premolars	9 – 12 years
Second premolars	10 – 13 years
First permanent molars	6 – 7 years
Second permanent molars	10 – 13 years
Third permanent molars	16 – 30 years

86 Formation and eruption of the permanent teeth of the maxilla

The eruption times of the mandibular permanent teeth are similar to their maxillary analogues.



The Bite-Wing Radiograph

The bite-wing radiograph is without doubt the most important supplemental film for data collection in addition to the panoramic film. Even though, thanks to modern preventive dentistry, the prevalence of dental caries has been dramatically reduced, early diagnosis of caries using the bite-wing radiograph continues to be of central importance for the early detection of incipient proximal caries. Clinical experience shows, of course, that radiographic examination for fissure caries is helpful only in late stages of lesion development, while buccal and lingual or palatal lesions are hardly ever seen on radiographs; in these cases, careful clinical inspection plays the most important role. The reason for this fact can be explained by the mechanism of action of X-rays; only those tooth surfaces that are not superimposed by dense, healthy tooth substance and that are struck tangentially by the central ray will appear as radiolucencies, thus signaling incipient loss of hard tooth structure. Tooth surfaces (Class V) that are perpendicular to the central ray or which are superimposed by the entire thickness of an intact crown, e.g., fissure caries, elicit no radiographic sign of early carious lesions. On the other hand, because it functions according to the principles of tomography, panoramic radiography can reveal loss of tooth substance with surprising clarity if taken with precise positioning. This should not, however, be taken as a reason to disregard the bite-wing radiograph when it comes to checking for proximal caries.

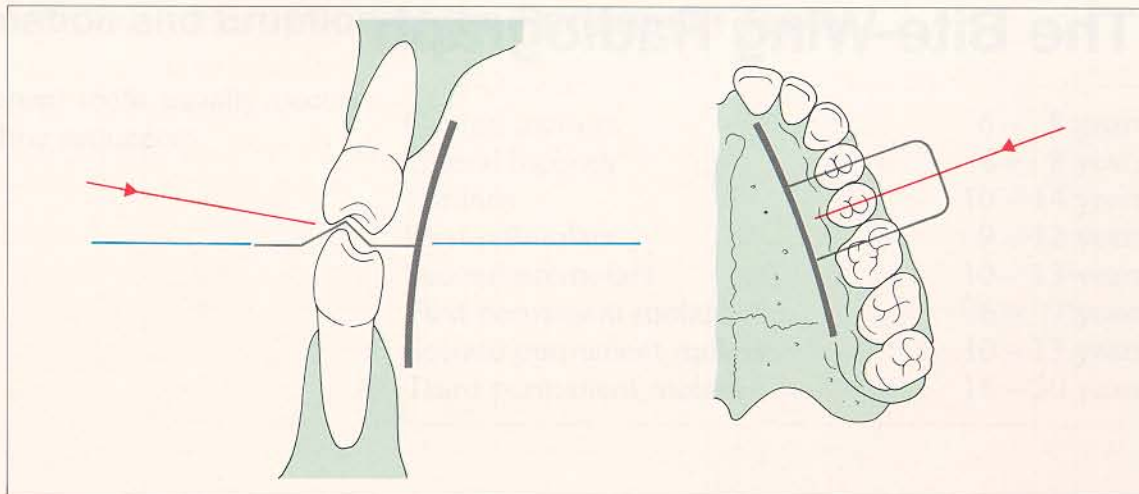
In summary, the bite-wing radiograph can provide the following information:

- Early diagnosis especially of proximal caries
- Checking the marginal closure of restorations and crowns in the proximal area
- Evidence of existing endodontic treatments in the posterior segments
- Documentation of calculus accumulation in the proximal spaces of posterior teeth
- Condition of the alveolar ridge in the posterior region, if the projection relationships are ideal
- Existence of malocclusion in the posterior region caused by missing teeth, missing antagonists or premature contacts

Good radiographic depiction of caries and malocclusion requires a higher energy exposure, while the depiction of restoration margins as well as cervical and periodontal problems require lower energy. Depending upon the age of the patient, various sizes of bite-wing films are available. The dentition from the distal surface of the canine to beyond the second molars should be captured on the bite-wing radiograph. In order to display the alveolar ridge as completely as possible, the elevation must be optimum, which necessitates using only those film holders with bite tabs no thicker than paper. Used in this way the bite-wing radiograph and the panoramic film not only provide the basis for data collection but also serve as an excellent radiographic survey for the regular evaluation of the condition of the posterior teeth, while providing minimum radiation exposure.

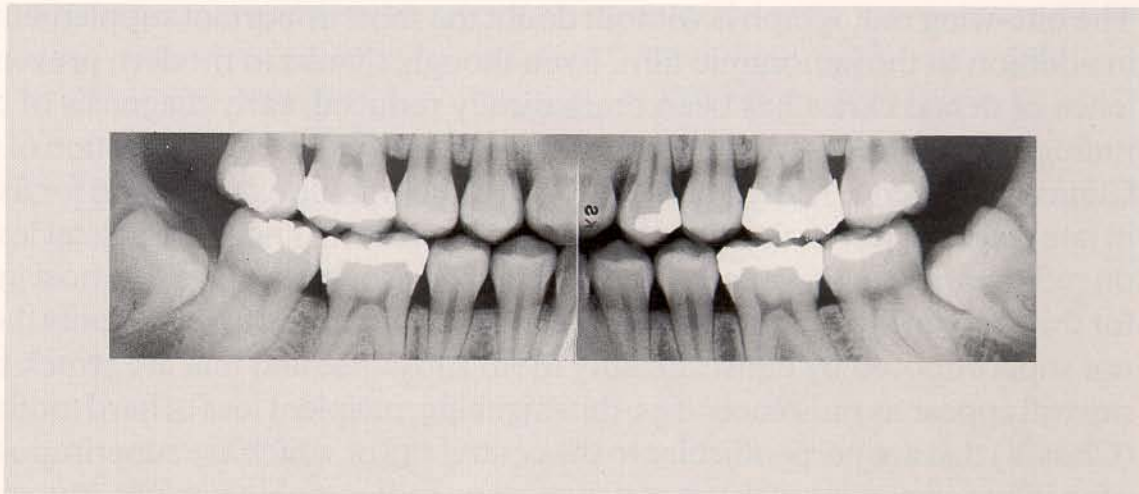
87 Diagram of correct film position and central ray targeting

For adolescents and adults, the long bite-wing film from Kodak can be used. The paper extension from the film packet must not be pulled too much. The central ray is targeted through either the maxillary second premolar or the first permanent molar.



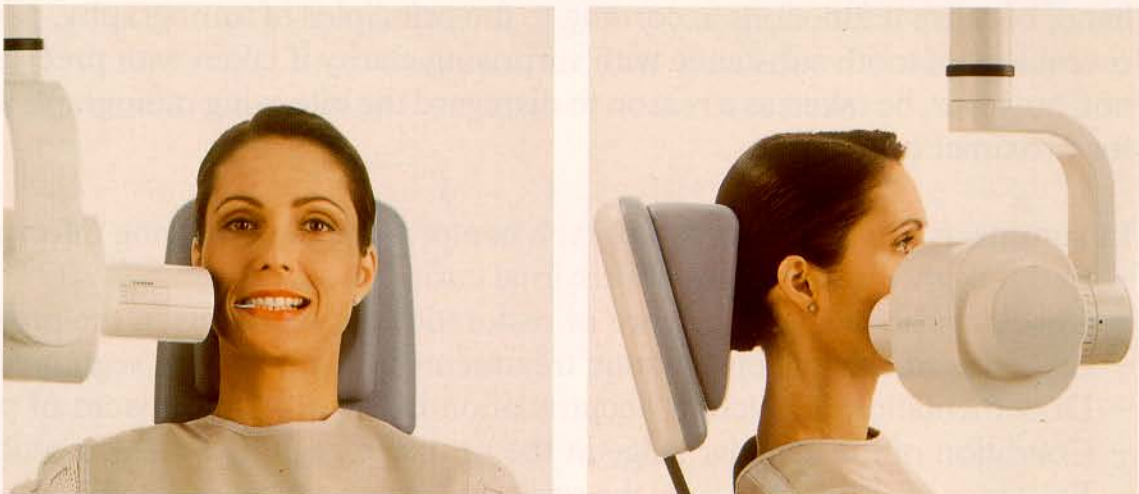88 Examples

These bite-wings were taken using the long (2.5 x 5.5 cm) bite-wing film from Kodak. If the paper tab is pulled too tightly, the distal edge of the film will be pushed inferiorly when the patient bites in centric occlusion. If the film is positioned too far anteriorly, the mesial edge of the film will be pushed upward during closure. Both of these errors will result in the occlusal plane appearing oblique on the finished radiograph.



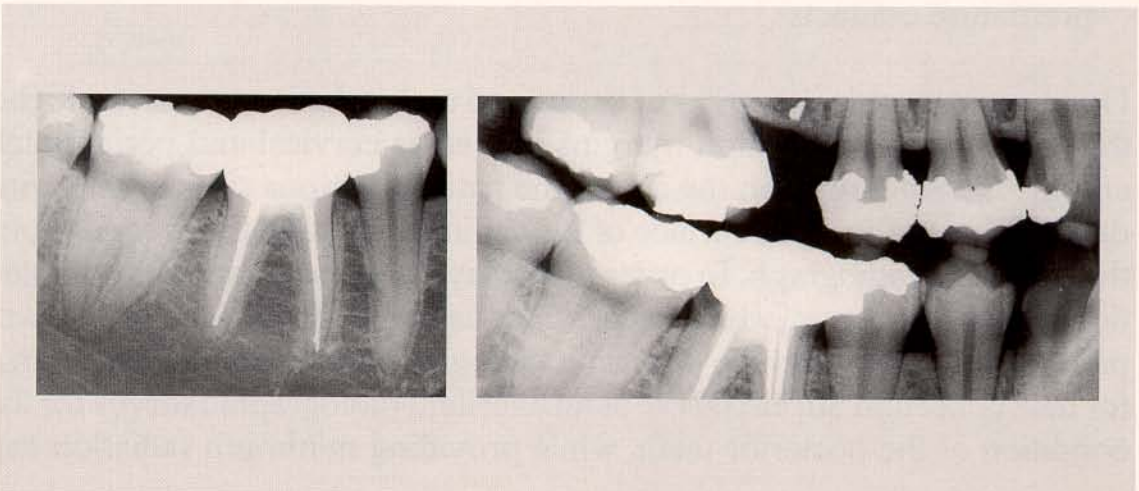
89 Proper central ray targeting, depicted from frontal and lateral views

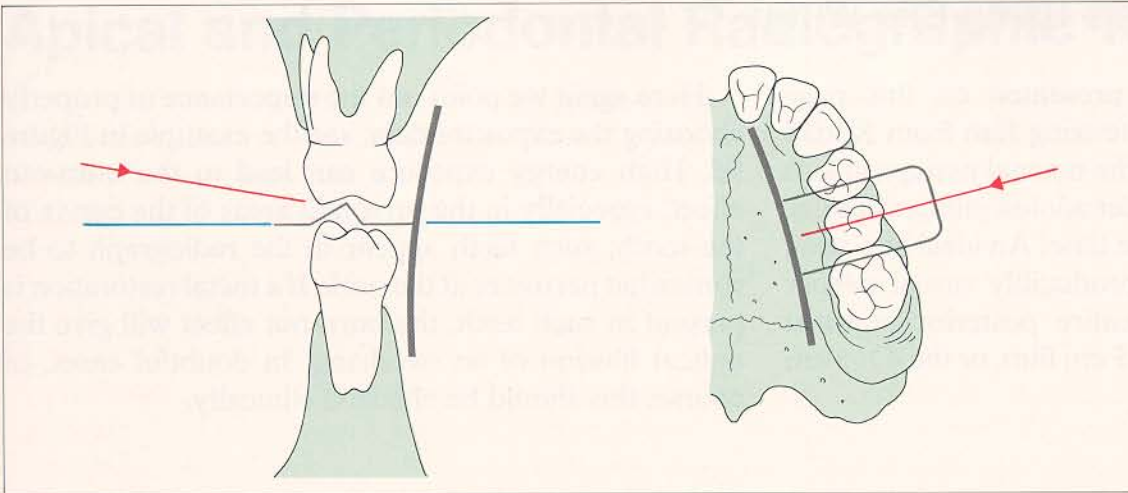
Note the patient's head position and the position of the film axis. Note also that the central ray is positioned at a 5–7° angle from the horizontal plane, vertically. The horizontal targeting appears "mesial eccentric," but it is in fact perpendicular to the film surface.



90 Significance of the proper targeting of the central ray for bite-wings in comparison to periapical radiographs

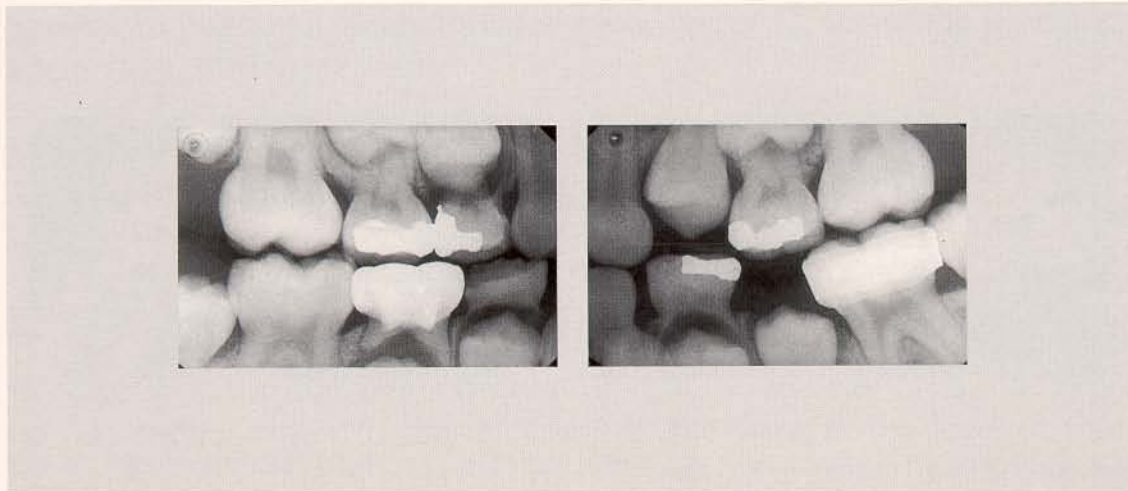
The bite-wing film (*right*) shows the superiority of the coronally targeted central ray for detection of carious lesions in the cervical area of tooth 46; compare to the periapical film (*left*).





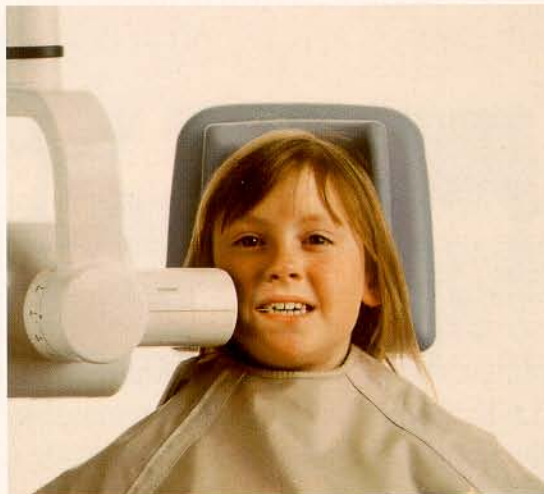
91 Diagram of correct film position and central ray projection

Depicted is the situation for either the child film or the normal film packet. The paper tab of the film packet must not be pulled too tightly. The central ray traverses the first or second deciduous molars.



92 Example

These bite-wings were taken using the 2x3 cm child film from Kodak.

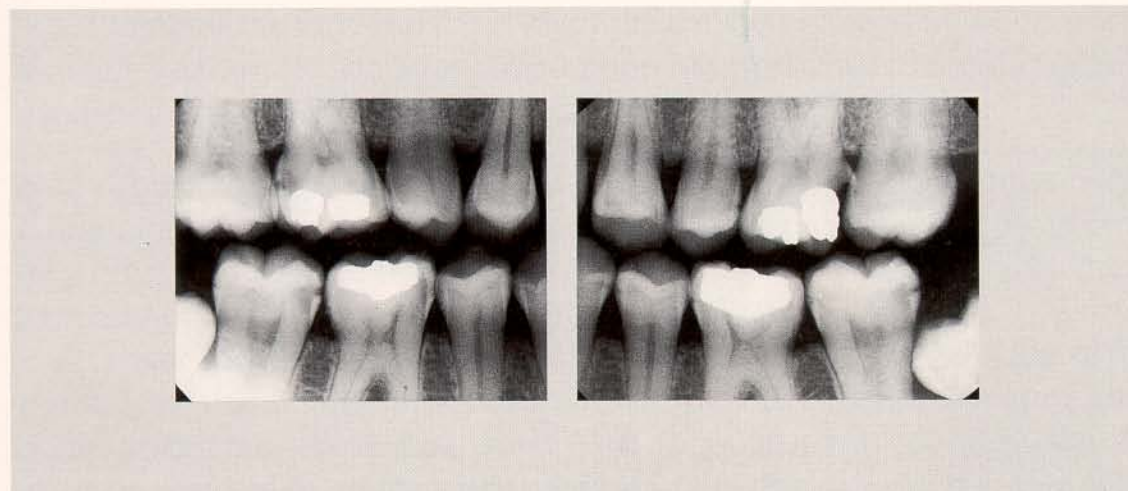


93 Film holder developed by Klausner

This device permits excellent positioning of the 3x4 cm film, but does not take full advantage of the film height.

94 Frontal view of proper central ray targeting for the child patient

The central ray is targeted with approximately a 5° angle. Note the head position and position of the film tab.



95 Bite-wing films for children

After the mixed dentition stage, a normal periapical film (3x4 cm) can be used for bite-wing exposures. In the bite-wing radiographs shown here, note proximal caries on the mesial of tooth 17, distal 16, distal 25, distal 26, distal 37, mesial 37, mesial 36, mesial 35, distal 34, mesial 46, mesial 47, occlusal 74 and distal 47!

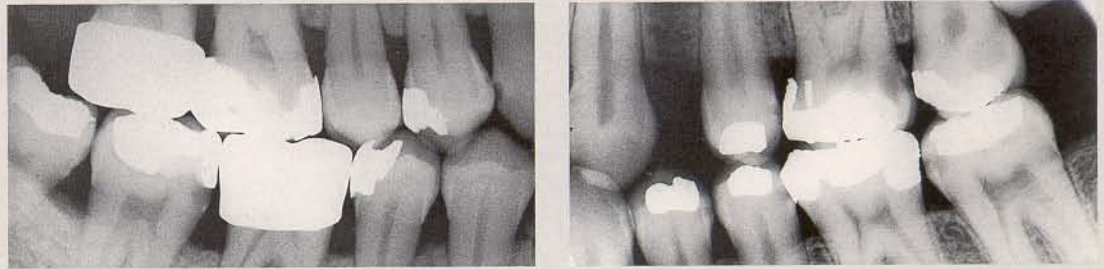
Examples of Diagnosis Using Bite-Wings

The bite-wing radiographs presented on this page clearly show that the long bite-wing film from Kodak has distinct advantages over the normal periapical-size film for the examination of older adolescents and adults. Careful technique is worth the time! An ideal bite-wing radiograph that can also reproducibly reveal deeper periodontal lesions in the entire posterior segment should be taken using a 3.5×5 cm film, or the 4×5 cm film from Agfa.

Here again we point out the importance of properly choosing the exposure data; see the example in Figure 96. High energy exposure can lead to the burn-out effect, especially in the proximal areas of the cervix of the tooth; such teeth appear in the radiograph to be somewhat narrower at the neck. If a metal restoration is present in such teeth, the burn-out effect will give the optical illusion of an overhang. In doubtful cases, of course, this should be checked clinically.

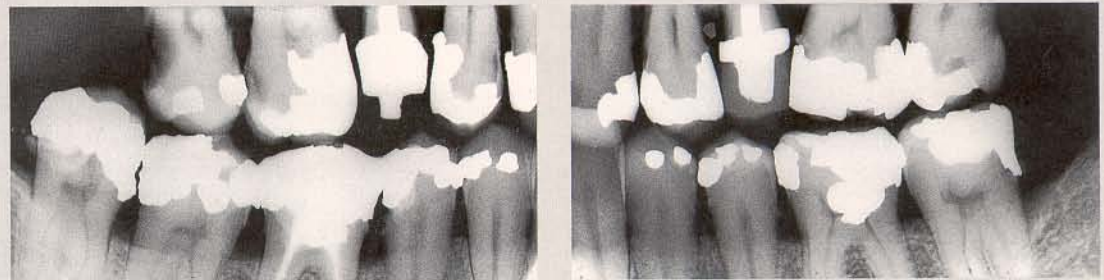96 Diagnostic possibilities with the bite-wing radiograph

These two films, from separate patients, show typical radiographic signs of overhanging restorations and crown margins in the proximal areas, proximal caries of varying severity, and an area of secondary caries resulting from a poor contact between teeth 47 and 46 (left).



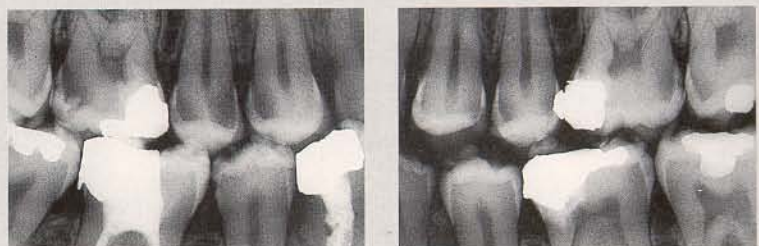97 Diagnostic possibilities with bite-wing radiographs

Both these films reveal not only various stages of proximal caries, but also the condition of the restorations with overhanging margins of the post-and-core, a supererupted tooth 48 and periodontal destruction resulting from advanced marginal periodontitis. With a film height of 3.5 or 4 cm, it would be possible to achieve ideal illustration of periodontal lesions of the posterior segment.



98 Bite-wings taken using the normal periapical film

These films were taken of a 20-year-old man 2 weeks after he had been examined clinically using mirror and probe, and dismissed as "caries free"! The bite-wing radiographs reveal numerous deep carious lesions.



Apical and Periodontal Radiographic Technique

Special radiographic techniques are necessary to show the apical and periodontal structures adequately, for two reasons:

- The best resolution as well as the least distortion will appear on the radiograph at the area where the central ray traverses the tissue.
- Only those tissues that have been exposed appropriately with regard to their thickness and density will be optimally depicted in the radiograph.

For these reasons, in order to produce a high-quality apical or periodontal radiograph, the central ray must pass through either the root apex or the alveolar crest. The exposure data must be selected corresponding either to the thickness of the bone at the level of the root apices or for proper depiction of the thinner alveolar crest. Taken to extremes, this means that if perfect depiction of the apical region is desired, the depiction of the tooth crown and the alveolar crest must be sacrificed to some degree; on the other hand, for a perfect periodontal projection, the depiction of the root apex will be compromised.

In reality, of course, nobody who is preparing a conventional radiographic survey will be prepared to consciously renounce the simultaneous depiction of the tooth crown and the root apex! However, since the introduction of the panoramic radiograph as the basic diagnostic film, new ideas concerning targeted application for the periapical radiograph have begun to evolve. On the other hand, because the concept of a more modern examination strategy using panoramic radiography does not yet enjoy general acceptance, a compromise must be found. One realistic approach to improve the still often used conventional radiographic survey is the regular use of a film holder that guarantees optimum positioning. In this regard, systems that position the film at a right angle to the X-ray tube have proved themselves in clinical practice; in this way, the separate, tiresome, and “free-hand” positioning of the film and the X-ray tube can be replaced by a compact targeting mechanism that virtually guarantees accuracy. In addition to improving conventional radiographic technique, film quality is improved and radiation dose is reduced.

Numerous investigators today are reporting new diagnostic possibilities offered by subtraction radiography and radiovisiography. These represent new and promising technologies. However, they must now satisfactorily pass a sufficient period of testing before they can be recommended for the daily practice.

As already mentioned, exposure data must be selected on the basis of the question to be answered. For the diagnosis of apical problems, the exposure data must be appropriate for the thickness of the bone surrounding the apex. If possible periodontal involvement is to be examined, the exposure data must be selected in appropriate relation to the thickness of the interdentially visible alveolar crest.

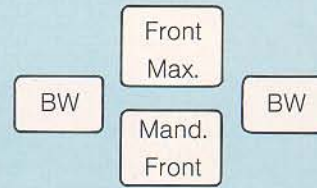
Radiographic Surveys for Patients of Various Ages

Depending upon the diagnostic questions that are encountered during the individual phases of growth and in patients of various ages, several different types of intraoral radiographic surveys may be indicated. Since the space available for the intraoral positioning of films varies considerably depending upon the age of the patient, various film formats have been developed to satisfy the diagnostic demands. The film formats that have been developed over the course of the past decades

based on clinical experience should be standardized as much as possible rather than being altered at the user's discretion. To ensure a high quality radiograph and to avoid unnecessary radiation exposure by retakes, each radiographic technique must be perfected through standardization. With the regular use of an appropriate film holder, one can avoid the numerous sources of error that accompany "free-handed" positioning of the film and the X-ray tube.

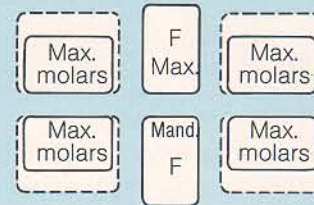
99 Radiographic survey for preschool children

This survey consists of two periapical radiographs (*middle*) and two small bite-wing radiographs using film size 2 x 3 cm. The periapical films are positioned as occlusal projections.



100 Radiographic survey for 6-year-old children

This radiographic survey for smaller children consists of 2 x 3 cm films or, for larger children two 2 x 3 cm films and four 3 x 4 cm films (dashed outline).



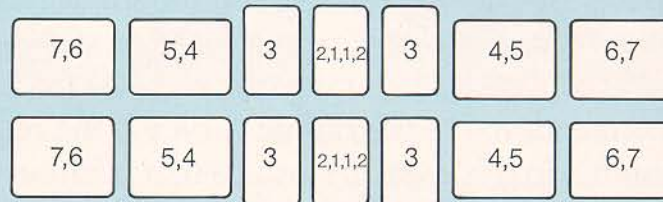101 Radiographic survey for children with mixed dentition

Six narrow child films are used to depict incisor (F) and canine (C) regions. Premolars and first permanent molars can be captured using periapical films.



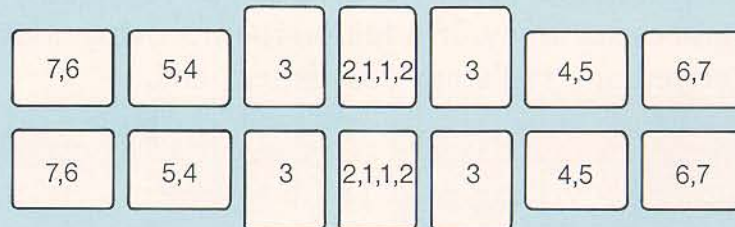
102 Radiographic survey for children nearing the end of the mixed dentition stage

The previously described 10-film survey (Fig. 101) is expanded by the addition of one more film in each molar region. This survey is also well indicated for use in adults with a narrow anterior arch.



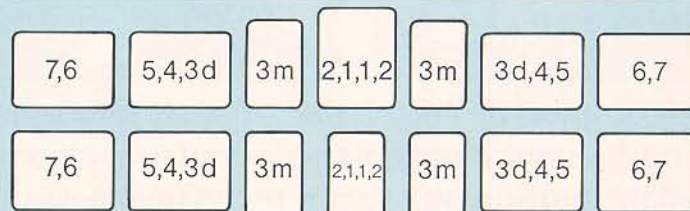103 Typical 14-film survey for adults

This survey will encompass all but the third molars, whose shapes and positions are extremely variable. Special radiographic techniques must be used sometimes for appropriate depiction of third molars.



104 Reduced periodontal radiographic survey using 14 films

The normal 18-film periodontal survey can be reduced to a 14-film series if the right-angle system from Beycodent is employed as described by Pasler.



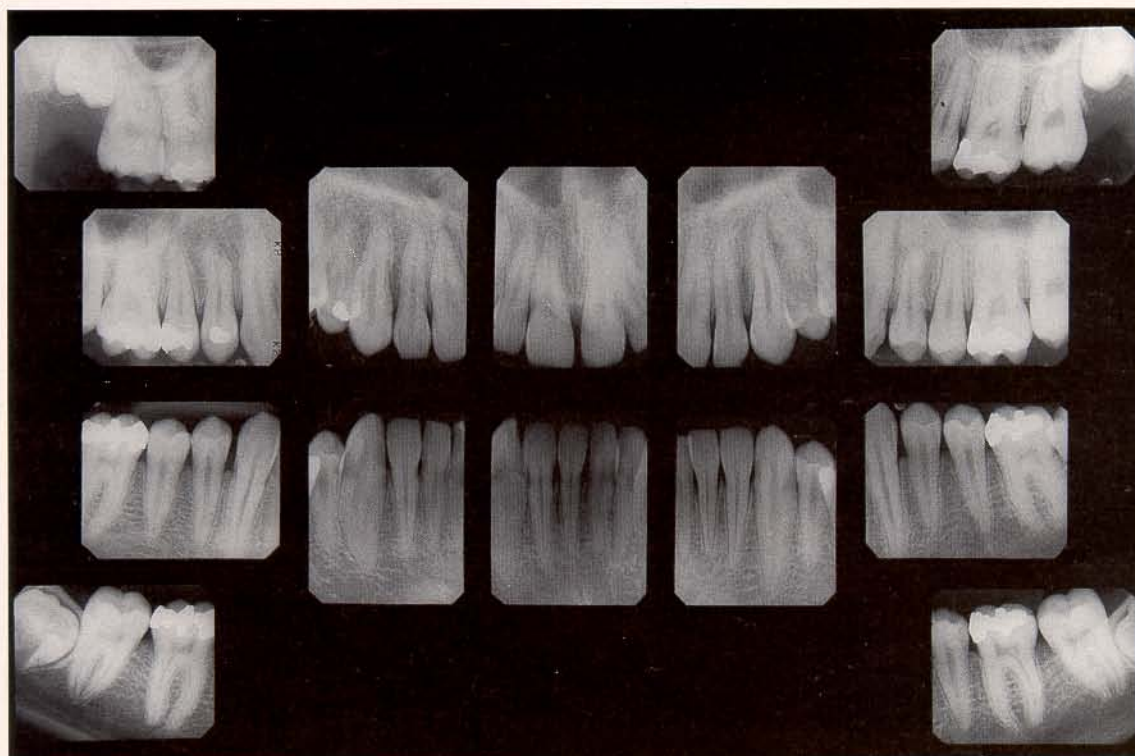
Apical and Periodontal Survey in Adults

The following pages present a 14-film survey for adults, using a film holder to eliminate the disadvantages associated with free-handed positioning; this technique is applicable equally for apical as well as for periodontal radiographs. In addition to the simple and practice-proven "Emmenix" film holder (Hager Co.), the preparation of apical and periodontal projections will be demonstrated with a targeting device that can provide significant enhancement of radiographic quality in comparison to free-handed positioning methods.

This is achieved via a system in which the film is held

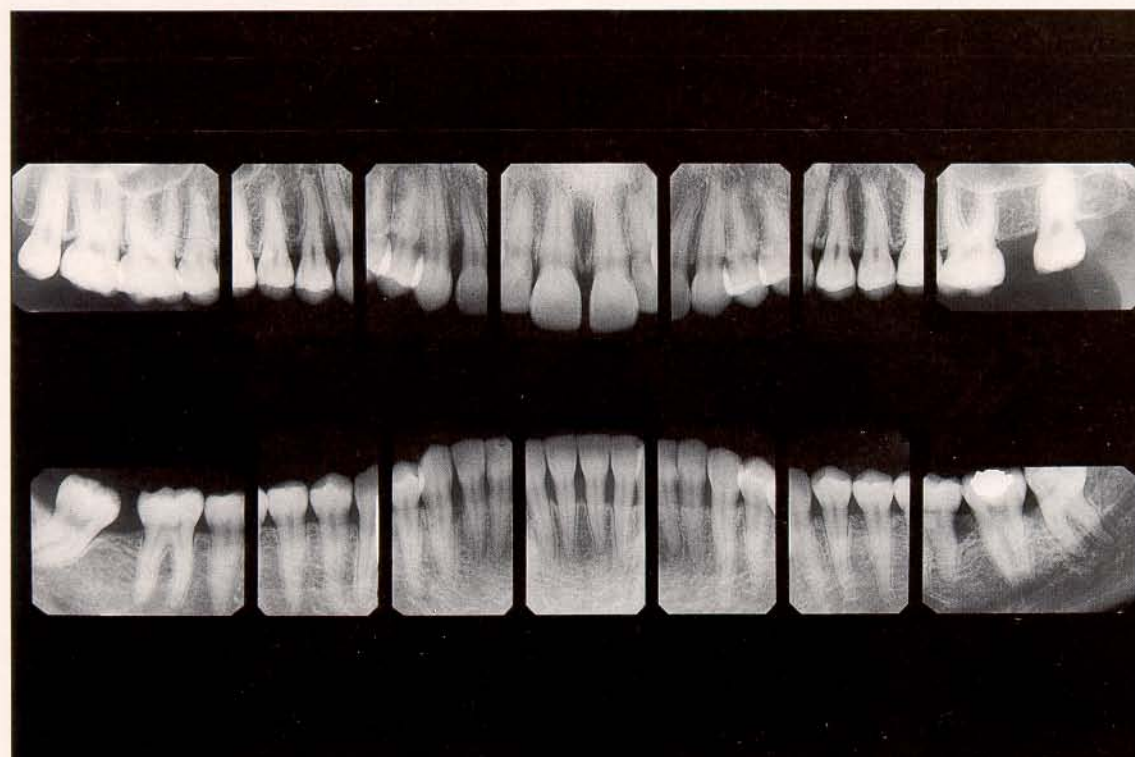in a sterilizable and interchangeable film holder attached to an adapter ring that can be connected to the tube of almost any dental radiographic equipment. This guarantees that the film is always at a right angle to the central ray and fixed in the center of the perfectly shielded X-ray beam; in addition, this insures proper positioning of the unit and the film, as well as maximum radiation protection with each exposure.

Depicted here is the right-angle system described by the author and manufactured in Germany by Beycodent.



105 Apical 14-film survey for an adult

The central ray is targeted onto the apex; depiction of the alveolar crest is of only secondary importance. The third molars must always be located and depicted through use of special projections if no panoramic radiograph is available.



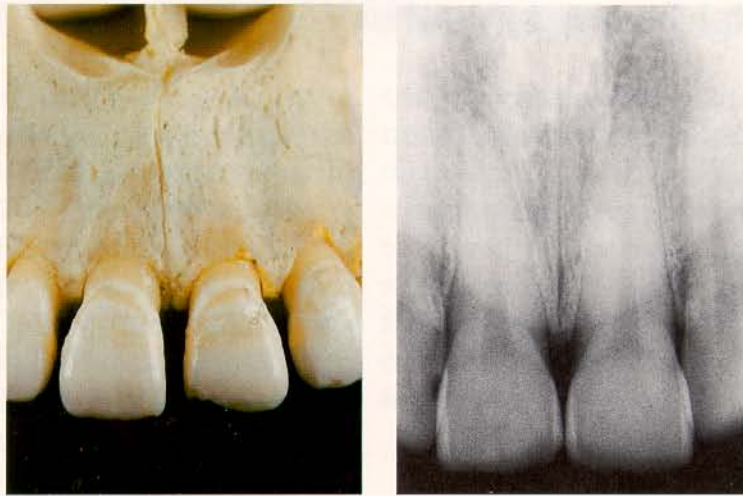
106 Periodontal 14-film survey for an adult

The central ray is targeted onto the alveolar crest; depiction of the root apices is of only secondary importance. The exposure data are reduced.

Maxillary anterior region

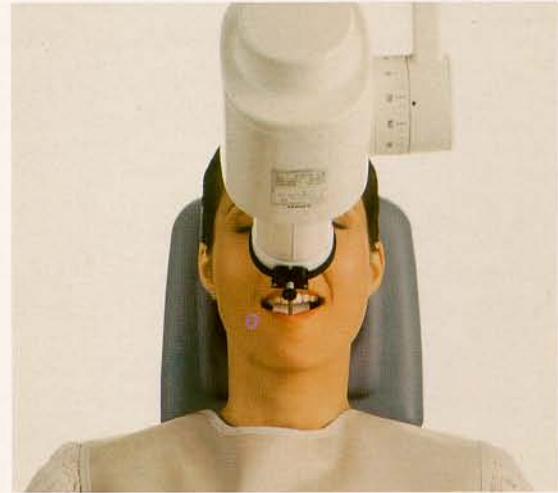
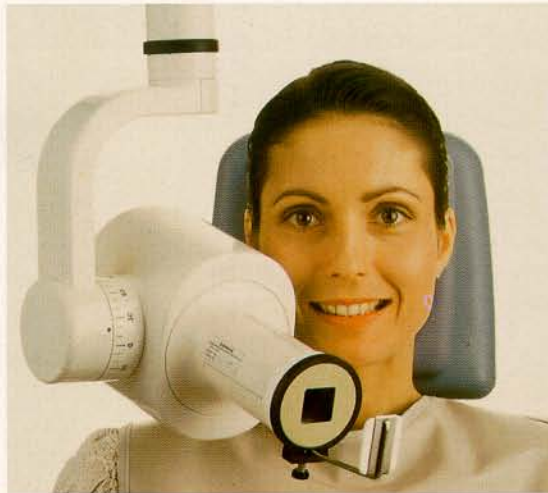107 Photograph and radiograph of the region

Depending upon the indication and the age of the patient, either a 2 x 3 cm or a 3 x 4 cm film is selected and used vertically.



108 Film holder for the right-angle technique, as modified by Pasler

This film holder consists of a rotatable adapter ring and four interchangeable metal film holders, which serve simultaneously for targeting. Two are for the four posterior tooth regions, and two (in different sizes) are for the anterior tooth regions. The film is fixed in a right-angle configuration to the central ray, and can be rotated in the adapter ring. Radiation exposure is reduced to a minimum by incorporation of a lead collimator.

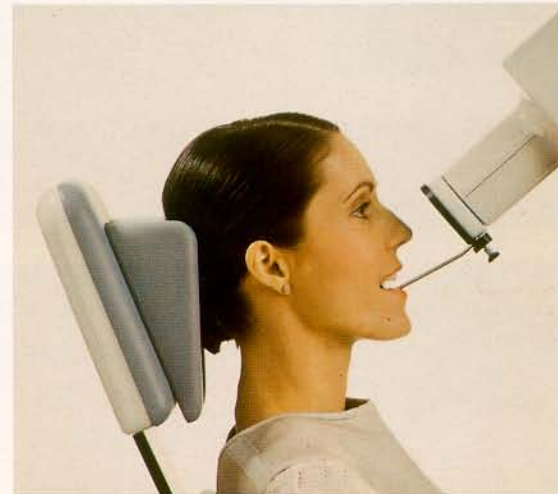
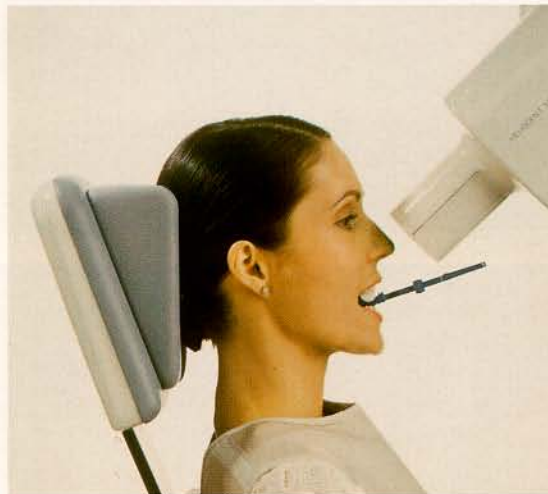
109 Positioning for the maxillary anterior region

Frontal view. Note the head position and the symmetrical positioning of the apparatus.

110 Positioning for the maxillary anterior region

Lateral view. The *left* picture shows the use of the Emmenix film holder, while the *right* picture shows the positioning with the film holder of Pasler. Note also the head position for radiography in the maxilla. "Snap-a-ray" is a similar model produced in the USA by Rinn Co.

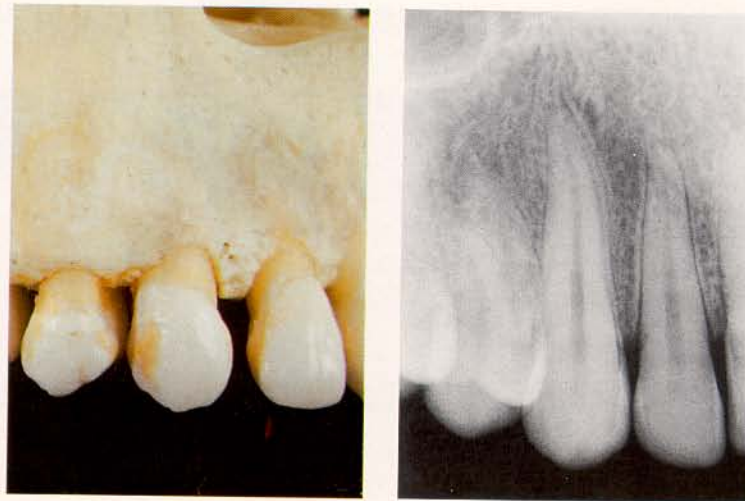

The preparation of a patient for the production of a full radiographic survey or only a single radiograph is of considerable psychological importance. It is useful to insert the film initially and allow the patient to relax. Observe the patient's reaction. Use topical anesthetics sparingly and in a targeted manner. Pay attention to proper head position: For maxillary radiographs, the bipupillary line and the occlusal plane of the maxilla should be horizontal. Select the proper horizontal and vertical angles for the projection according to the individual circumstance rather than blindly adhering to schematic tables.

Maxillary canine region

111 Photograph and radiograph of the region for a simple depiction of the canine

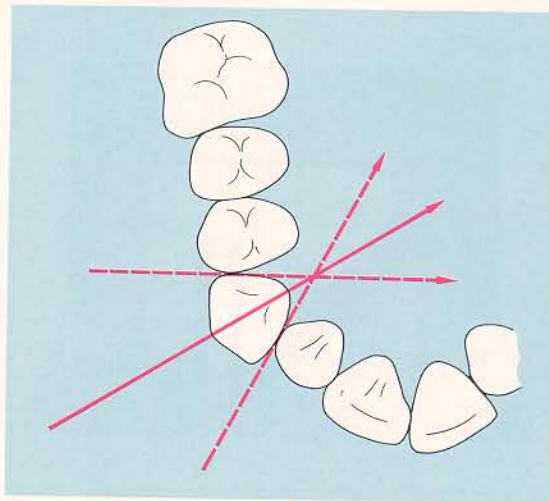
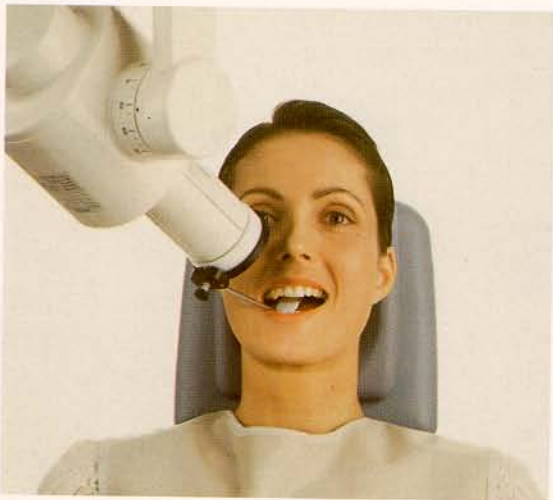The film packet is used vertically, either in the 2 x 3 cm or 3 x 4 cm format.



112 Positioning for an orthoradial depiction of the maxillary canine, for a periapical survey

113 Schematic representation of central ray projection in the horizontal angle

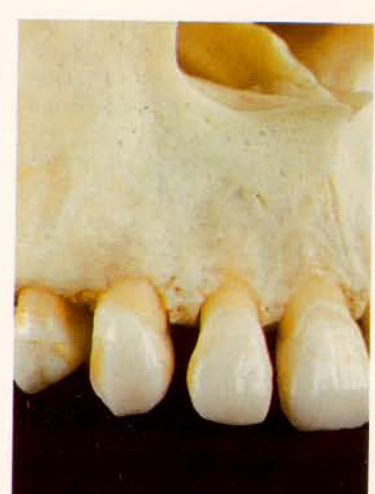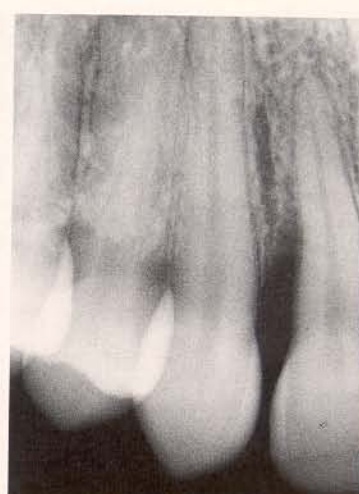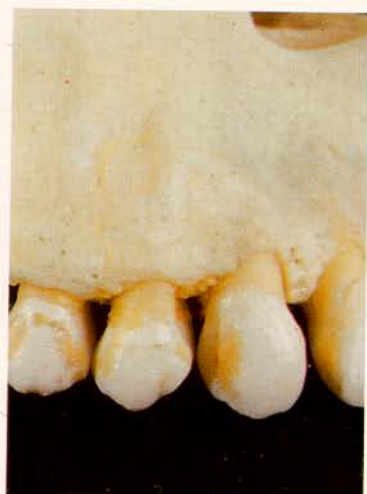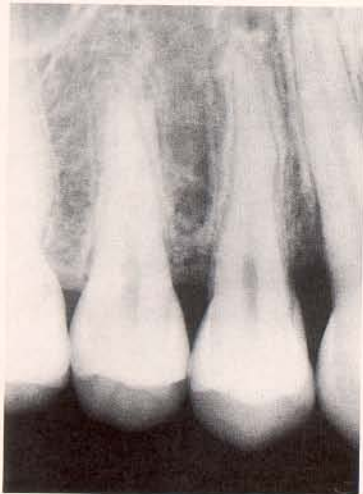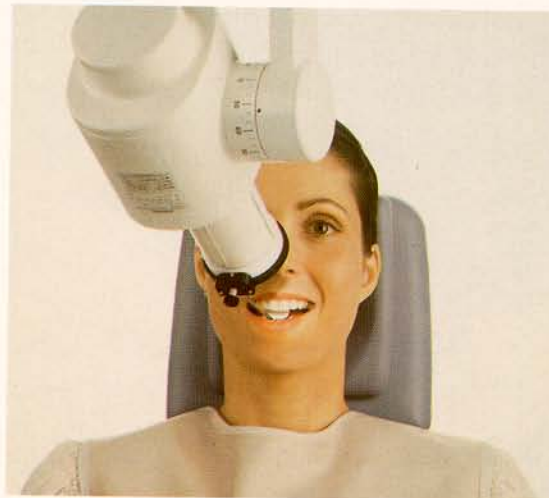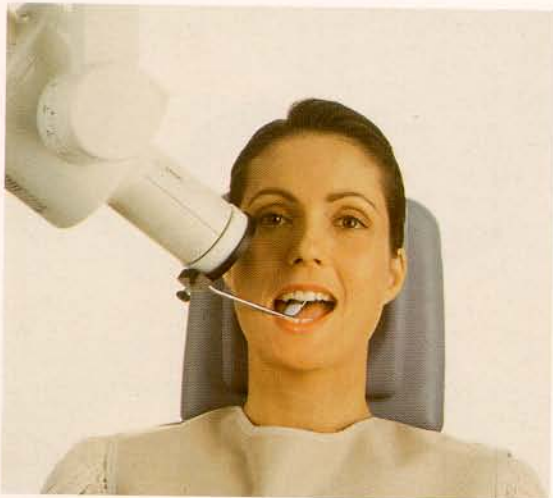Middle: Orthoradial central ray projection in comparison with the necessary mesial and distal shift of the central ray for optimum representation of the septa.



114 Eccentric positioning for the depiction of the distal and mesial septa of a maxillary canine

115 Radiographic pictures and photographs of a "periodontal" positioning technique for the maxillary canine

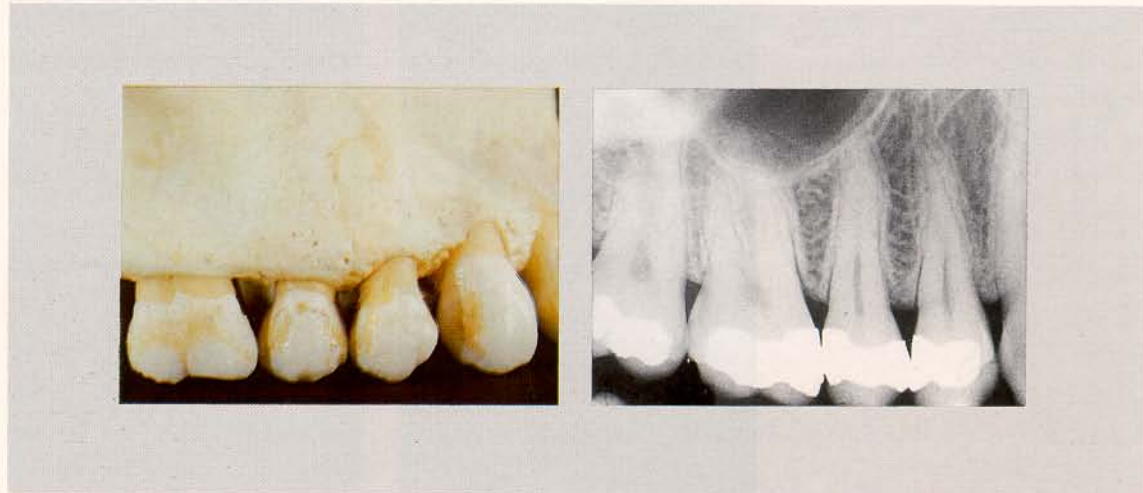The proper "targeting" from the horizontal angle is of critical importance.



Maxillary premolar region

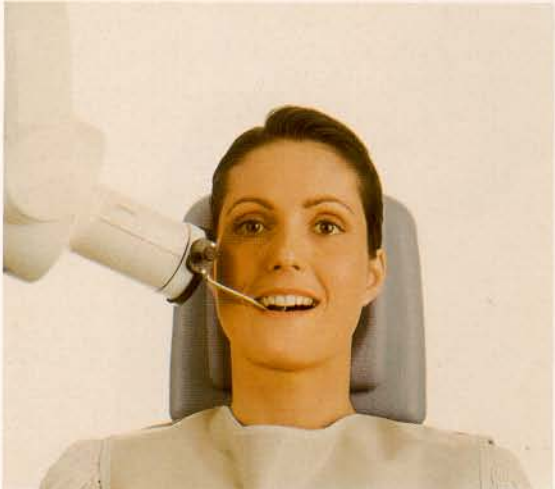
116 Photograph and radiograph of the region

The 2x4 cm film packet is used horizontally. The photograph shows the premolar region with an orthoradial projection view.



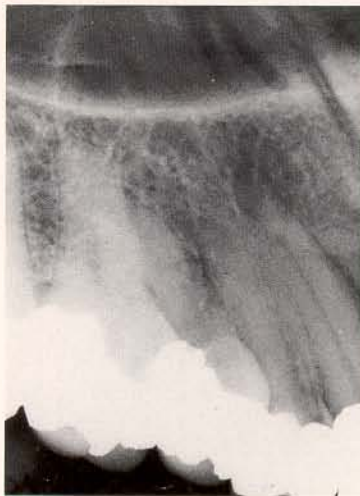117 Correct (orthoradial) and incorrect (mesial eccentric) central ray projection for premolars

In this schematic a rectangular bar is projected on the film surface to demonstrate the effect of "orthoradial" and "mesial eccentric" targeting.



118 Positioning for the maxillary premolar region

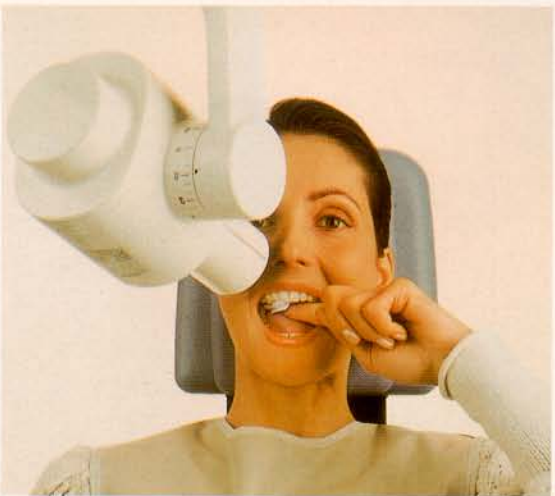Note the head position and the position of the film holder.



119 Typical unacceptable radiograph of the maxillary canine and premolar region

The central ray was not only projected too steeply from above, but also excessively eccentrically from the mesial aspect.

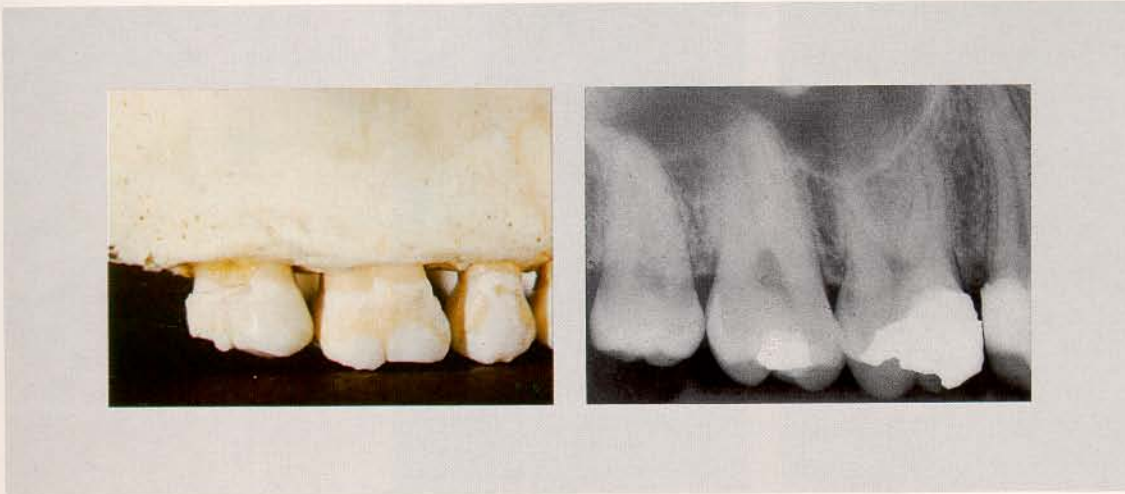
This type of error often occurs also with molar radiographs. In such projections, the teeth are superimposed upon each other.



120 Improper positioning for a maxillary premolar radiograph

With the X-ray tube in this position, the teeth will be projected as superimposed.

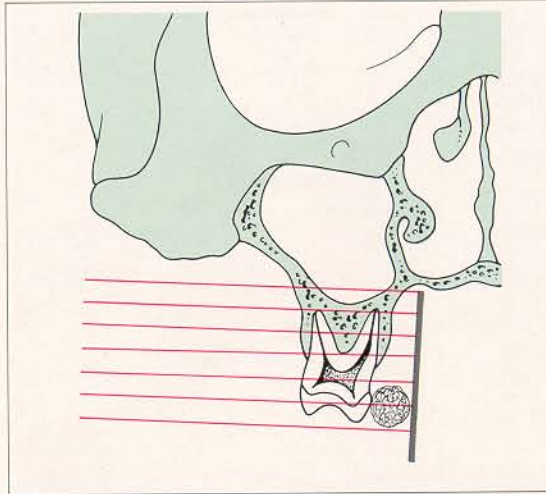
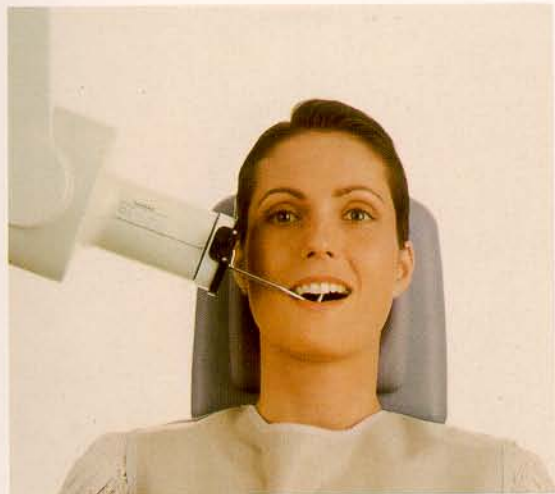Of major importance is the appropriate choice for *horizontal* and *vertical* tube angulation. In the posterior region of the jaw, the horizontal angle should be similar to an orthoradial projection to avoid the incorrect mesial eccentric positioning. At the same time, however, the vertical angle (p. 57) must be properly selected to avoid distortions of the teeth as well as summation effects with other structures. A targeting device (film holder) facilitates focusing on the critical procedures (Fig. 120).



Maxillary molar region

121 Photograph and radiograph of the region

The 3x4 cm film packet is used horizontally. The photograph shows the proper projection view in both horizontal and vertical angles. Thus the roots are not superimposed by the zygoma.

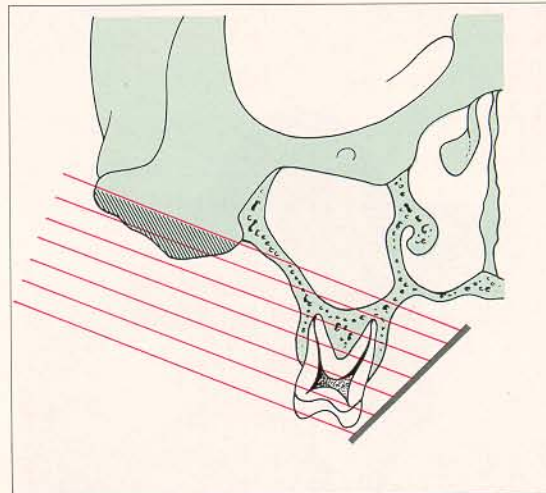
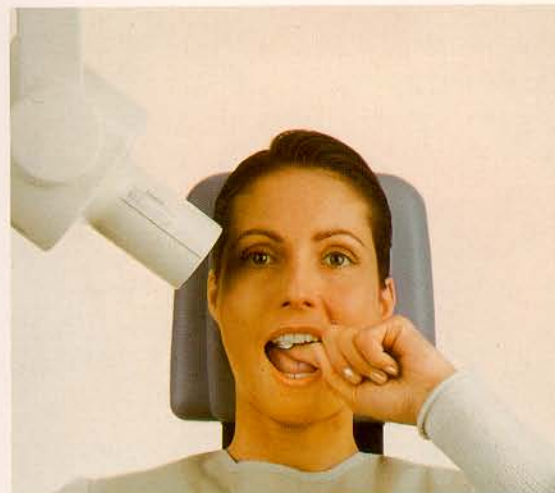

122 Positioning for the maxillary molar region

Note the position of the film holder and the horizontal and vertical angles of the tube; adjustments are made according to the photograph (Fig. 121).

123 Schematic diagram of the anatomically correct positioning for radiographs of the maxillary molar region

Note that the molar teeth are projected free of the zygoma.

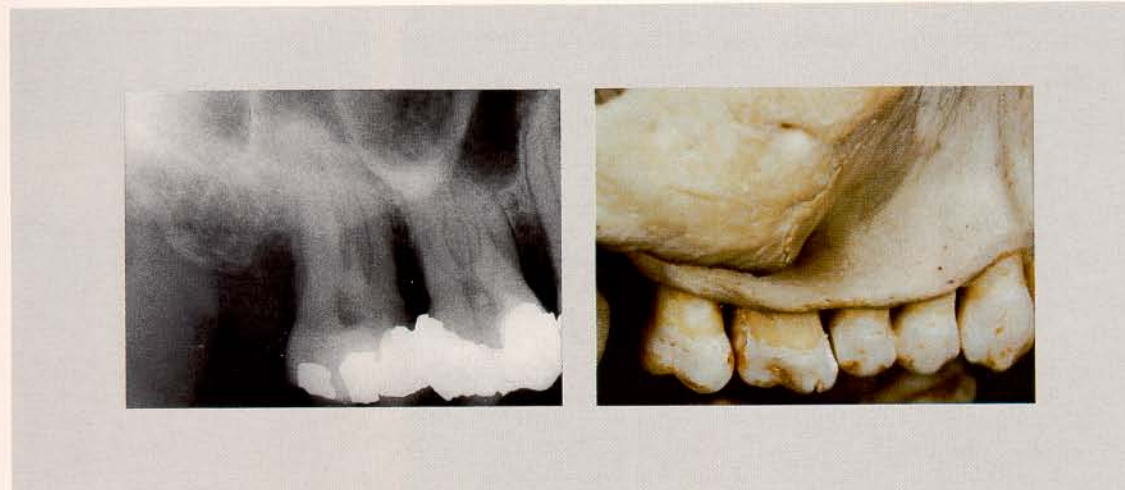


124 Improper positioning for the maxillary molar region

The vertical angle is too steep, and this will result in superimposition of the zygoma onto the roots of the molars.

125 Schematic diagram of a typical improper projection

Note that the molar region is superimposed by the zygoma.



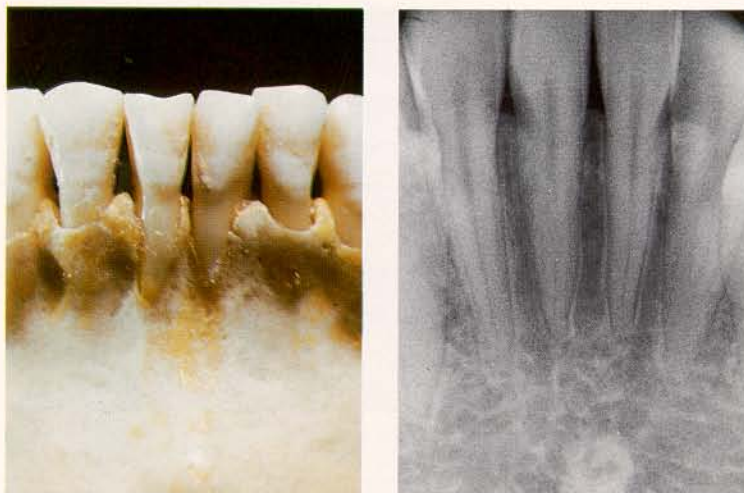126 Example of a typical unacceptable radiograph of the maxillary molar region, with an excessively steep vertical angle

The skull photograph demonstrates the anatomic relationships with too steep a projection. The roots of the molars are superimposed by the zygoma (see radiograph) when the projection angle is too steep.

Mandibular anterior region

127 Photograph and radiograph of the region

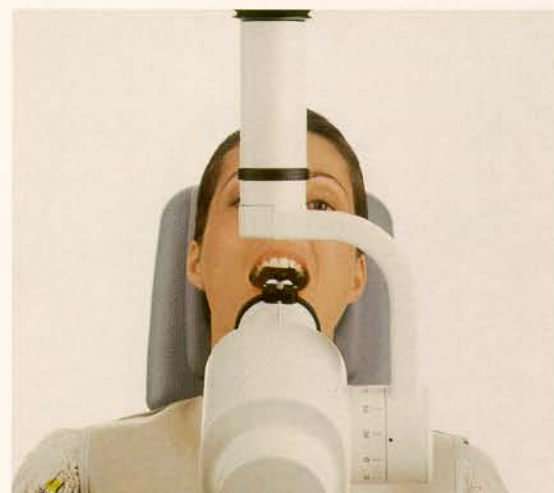
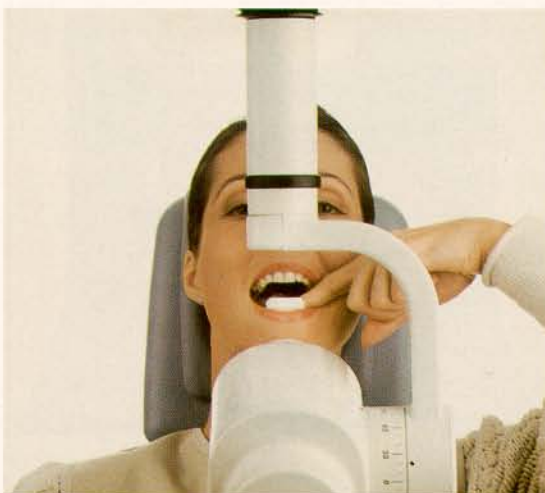Depending upon the indication and the age of the patient, either a 2x3 cm or a 3x4 cm film packet is selected and used vertically.



128 Positioning for the mandibular anterior area, without film holder

129 Positioning for the mandibular anterior region, using a film holder

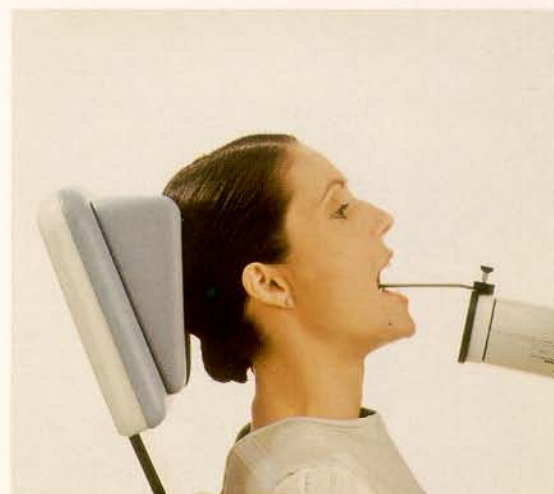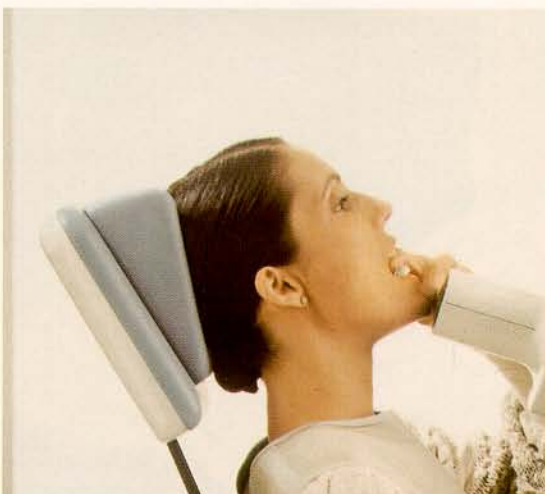View from the front. Note the head position and the symmetrical positioning of the X-ray tube.



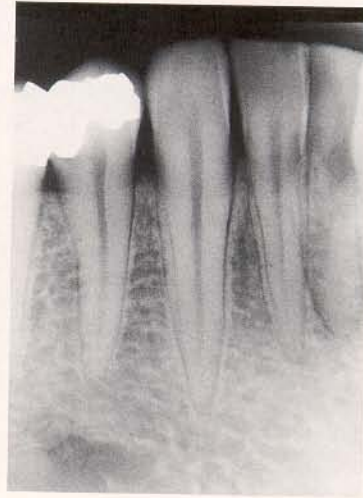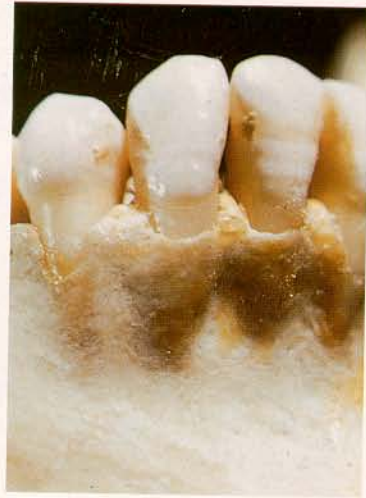130 Positioning for the mandibular anterior area, without film holder

131 Positioning for the mandibular anterior region, using a film holder

Lateral view. Note the head position. With the film holder, the central ray can be directed at a shallower angle because of the parallel intra-oral film position.



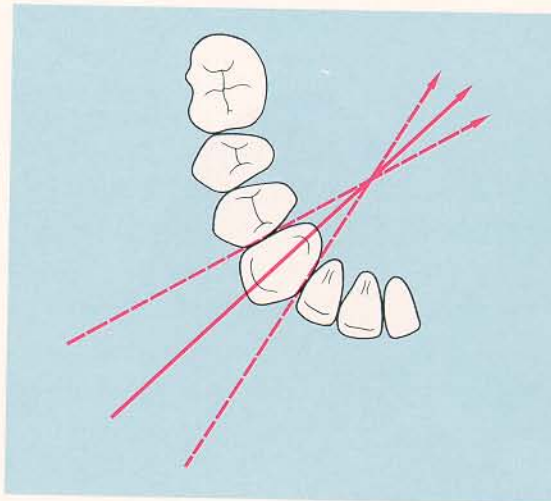
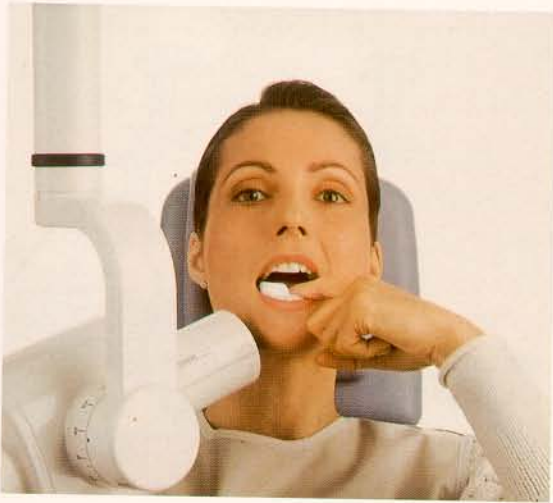A film holder allows placement of the film packet without having to bend it into a position dictated by anatomy. It is incorrect to press the film against the teeth and the alveolar process. In the maxilla, periapical film packets should be placed in the middle of the palate, and in the mandible toward the tongue. Therefore, in the mandible the film is not positioned anteriorly, but in the depth of the floor of the mouth. When the patient is asked to close the mouth, the musculature of the floor of the mouth relaxes and this simplifies placement of the film. Topical anesthetic may be used in the maxilla.



Mandibular canine region

132 Photograph and radiograph of the region for simple depiction of the canine

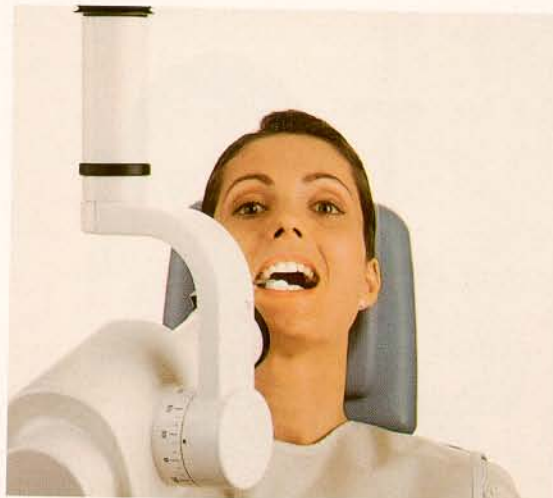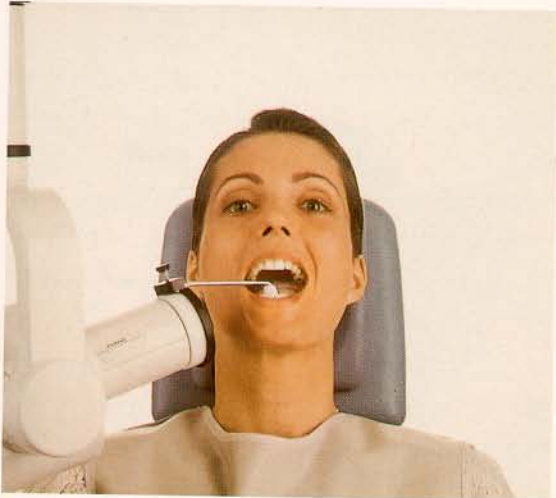Either the 2x3 cm or the 3x4 cm film packet is used vertically.



133 Positioning for depiction of the mandibular canine, without film holder

The film can only be placed without bending if the patient closes the mouth somewhat as the film packet is positioned. This relaxes the musculature of the floor of the mouth.

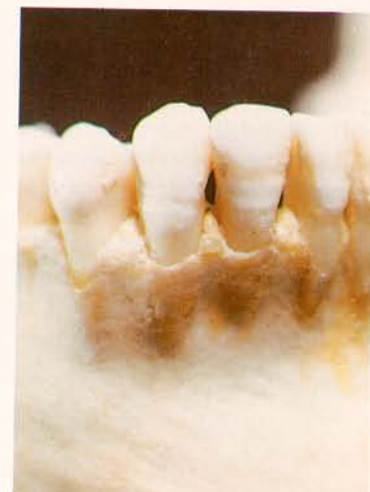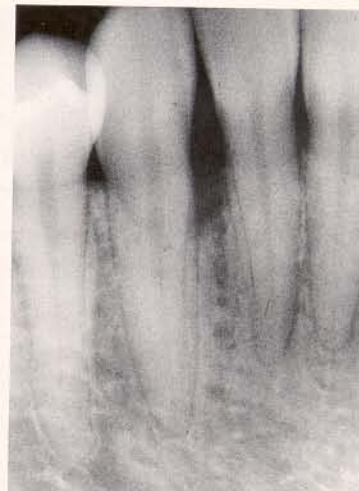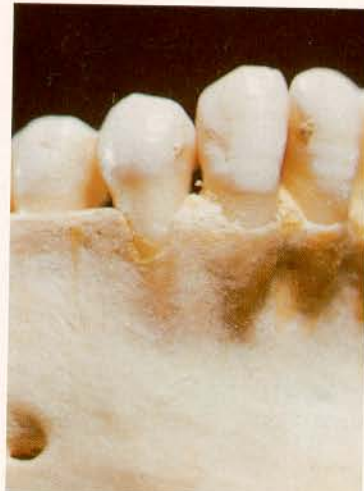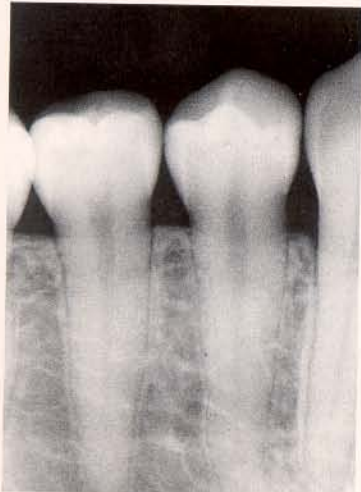134 Schematic diagram of the orthoradial projection as well as mesial and distal eccentric central ray projection as used for apical (middle) and for periodontal evaluations



135 Eccentric positioning for depiction of the distal and the mesial septa of the mandibular canine

136 Radiographs and photographs of a "periodontal" positioning technique for the mandibular canines

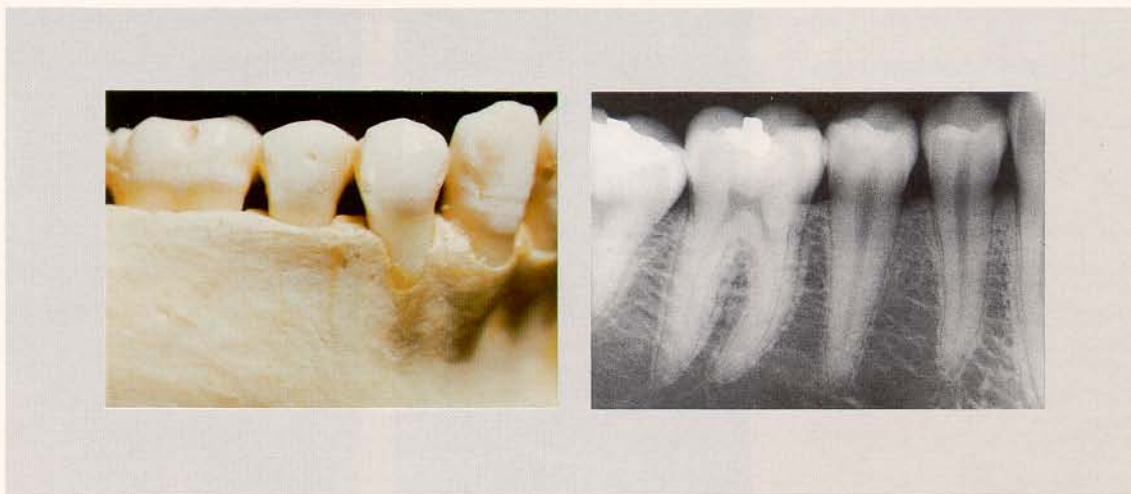
The 2x3 cm film packet is used vertically. The central ray is targeted toward the appropriate septum. Note the interdental spaces on both of the photographs!



Mandibular premolar region

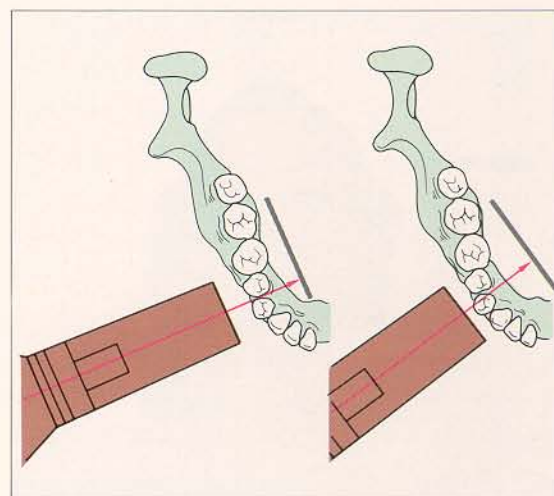
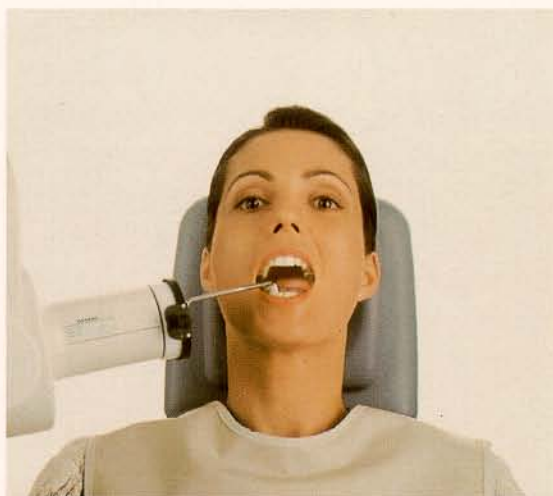137 Photograph and radiograph of the region

The 3x4 cm format film is used. Note the reproduction of the premolar region with regard to the central ray projection. A lateral direct view of the posterior segment is shown.



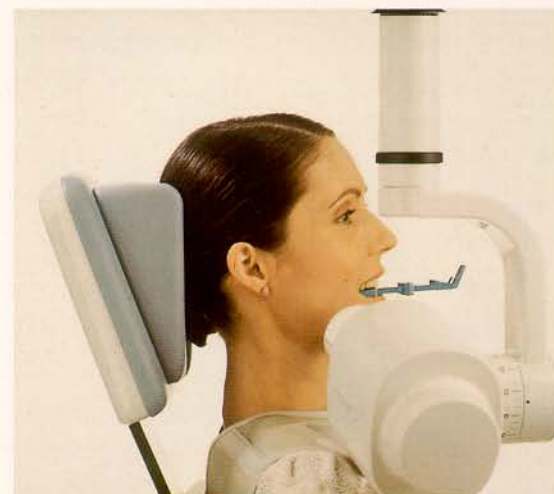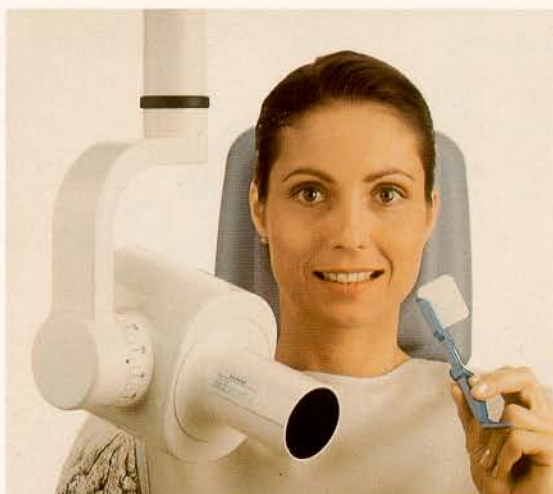138 Positioning for the mandibular premolar region

Note the positioning of the film holder in both horizontal and vertical aspects. The fixation screw on the film holder permits precise adjustment of the film packet in relation to the occlusal plane.



139 Variation of the central ray projection when the first premolar is mesially displaced (right)

A film holder that ensures right angle technique makes it possible to position the film packet correctly against the lingual frenum.

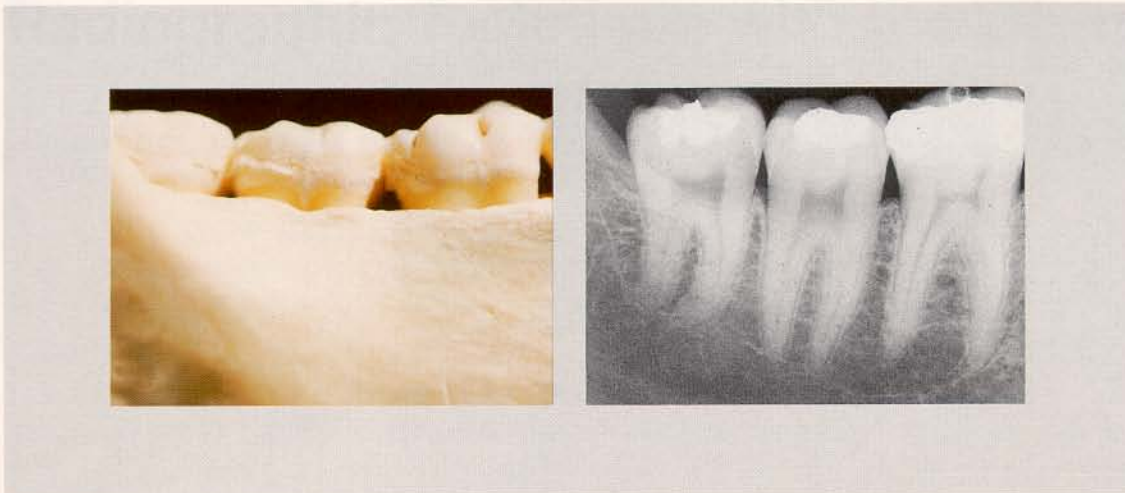

140 "Emmenix" film holder

Using this film holder (see also Fig. 110) it is possible to position the film correctly, especially in the mandible. The jaws are closed together; the handle of the film holder serves as an indicator of the proper positioning in the horizontal plane. The central ray should be targeted at a right angle to the film packet (and to the handle of the film holder).

Considerations when taking periapical radiographs in the mandible:

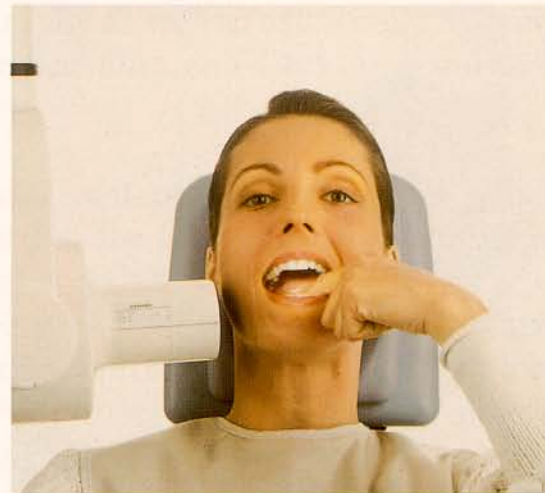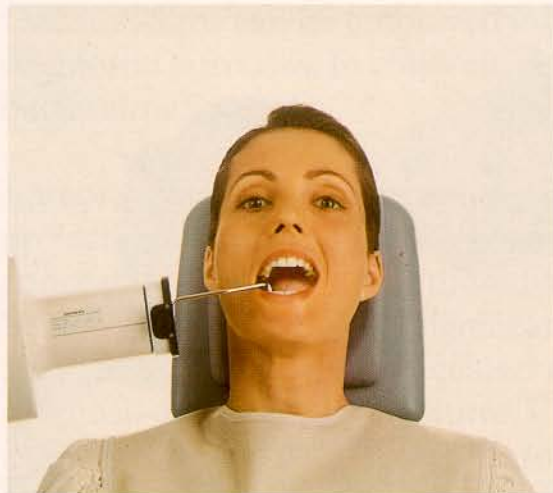- Use a film holder to position the (unbent) film packet towards the tongue.
- Select the appropriate film format to preclude having to bend the packet.
- When positioning the film, the patient should close the mouth slightly, to relax the floor of the mouth.
- To simplify adjustment of the central ray, the film holder should serve as a targeting instrument.



Mandibular molar region

141 Photograph and radiograph of the region

The 3x4 cm film format is used horizontally.

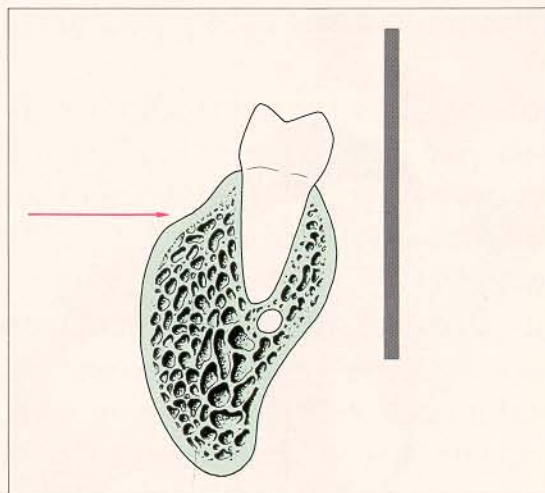
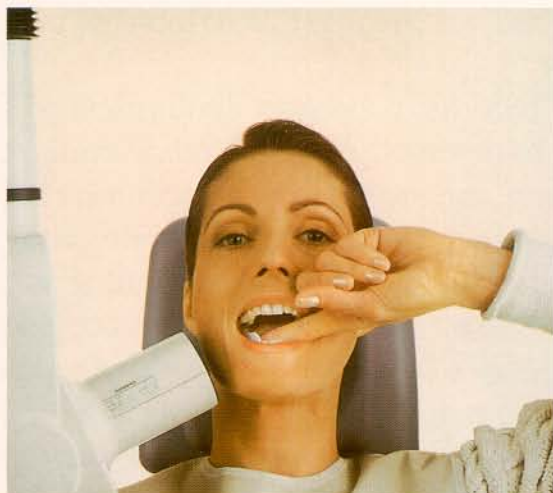

142 Positioning for the mandibular molar region

Note the correct head position for this mandibular radiograph, and the correct positioning of the film holder in both horizontal and vertical angles. Shown here is the correct position for a radiograph of tooth 46. For tooth 47, the only difference is an almost horizontal central ray projection.

143 Positioning without film holder

Note the position of the patient's head and left hand. If the patient swallows, the film will move.

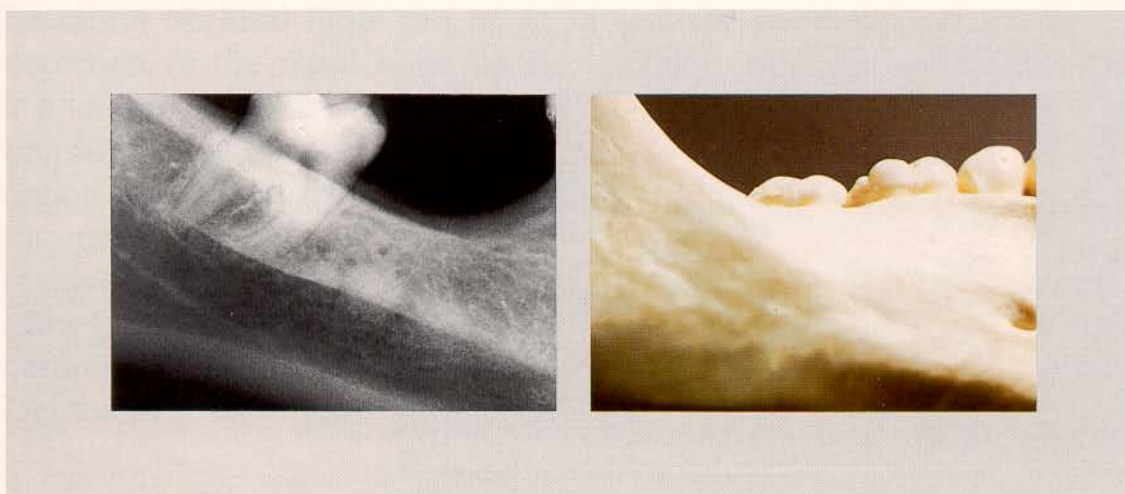

144 Incorrect positioning for the mandibular molar region

In an effort to display the molar roots completely, a common error is to select an excessively steep central ray projection.

145 Diagram of correct positioning

This figure shows that the lower second molar usually has a slight lingual inclination. Therefore a vertical angle of approximately 0° is indicated to depict this tooth correctly.



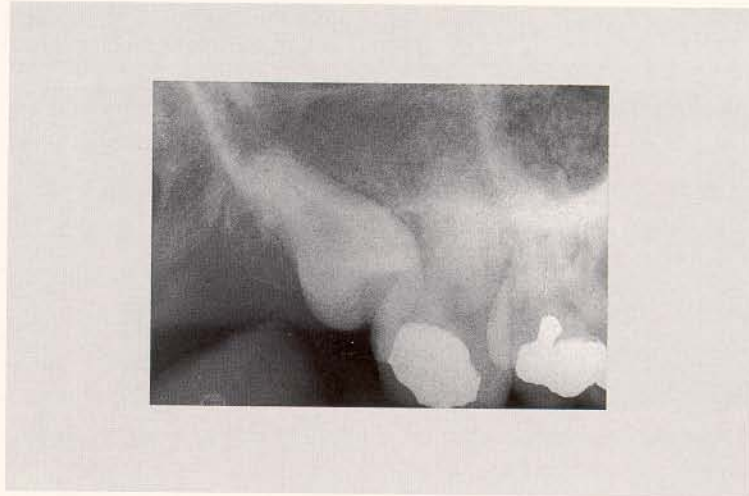
146 Common error, with excessively vertical projection angle

The photograph (right) simulates a typical incorrect projection. This will show the molars radiographically as shortened and with large crowns. The mylohyoid line can often be clearly seen.

Third molars

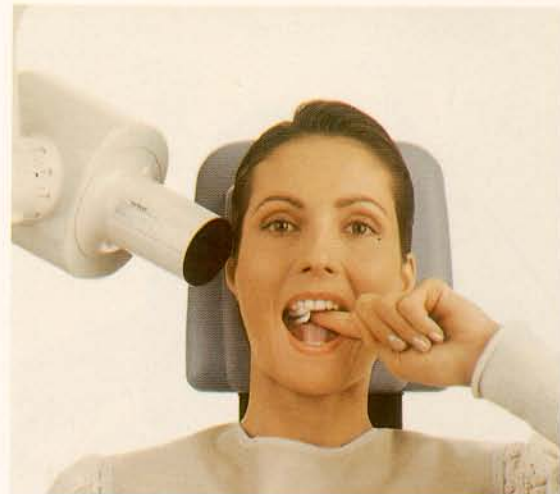147 Radiograph of an obliquely impacted maxillary third molar

The shape and location of impacted third molars are extraordinarily variable. It is for this reason that attempts to show them using periapical films often fail. In such cases, panoramic radiography as well as supplemental special radiographs for localization are indicated.



148 Positioning for depiction of a maxillary third molar

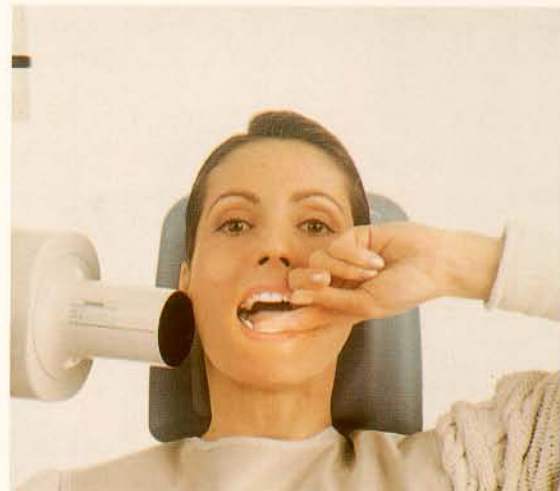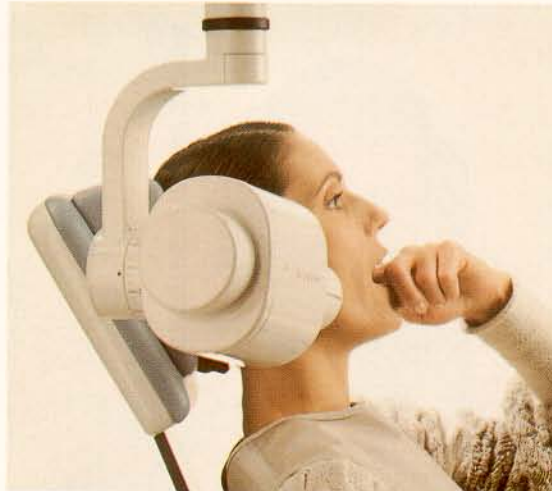If the periapical film does not display the tooth in its entirety, it does not mean that the film packet was not placed far enough posteriorly on the palate. The problem resides only with the direction of the central ray, which must be projected onto the tooth from behind and above anteriorly and inferiorly onto the film packet. In such cases even a film holder fails. Only mastery of a perfect central ray projection technique will succeed.



149 Positioning for depiction of a mandibular third molar

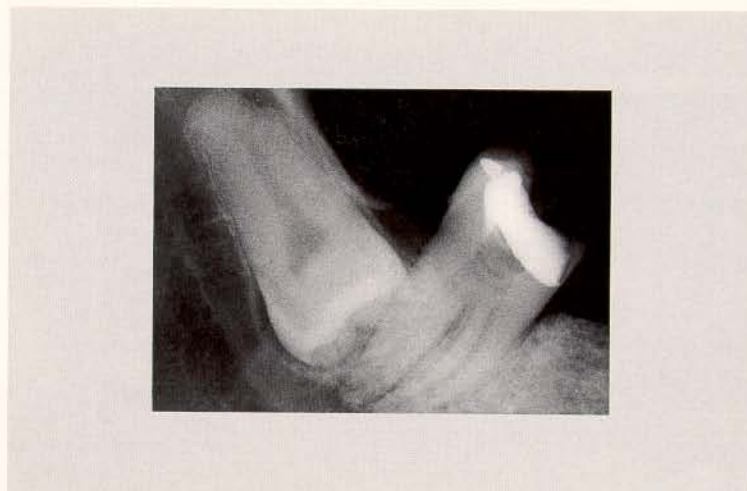If the tooth is not completely depicted on the film, it is again unlikely the fault of film positioning, rather one of central ray projection. The central ray must be projected upon the object (lower third molar) such that it is directed somewhat from posteriorly and superiorly to inferiorly and anteriorly.

Note: The tooth must be projected within the central ray onto the film. Proper direction of the central ray is of critical importance.



150 Radiograph of a horizontally impacted mandibular third molar

As in the maxilla, the 3x4 cm film packet is used horizontally. Correct radiography of mandibular third molars is also described in the legend to Figure 147 (above).



Radiographic Technique with the Occlusal Film

Occlusal films can be employed intraorally as well as extraorally to depict the third dimension for diagnostic purposes. In children, periapical films or a 4×5 cm occlusal film (Agfa) may be used as occlusal radiographs.

Intraoral occlusal radiographs permit axial projections of the mandible and modified axial projections of the maxilla. With regard to the long axes of the teeth, periapical radiographs and panoramic films provide orthoradial or eccentric views only. Depiction of the third dimension can be of utmost diagnostic significance if the indication is appropriate and if the technique is performed precisely. The occlusal radiograph is most often used for localization, as well as in the diagnosis of tumors and fractures. It is important that the occlusal radiograph be taken with a strictly axial projection with regard to the long axes of the teeth in the jaw being examined. The use of occlusal radiographs taken with the central ray not projected precisely axially (e.g., in the maxilla) may lead to incorrect diagnosis, for example in attempts to localize impacted teeth.

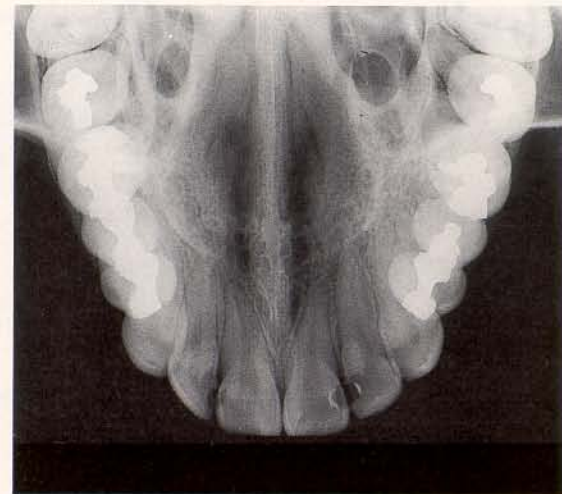
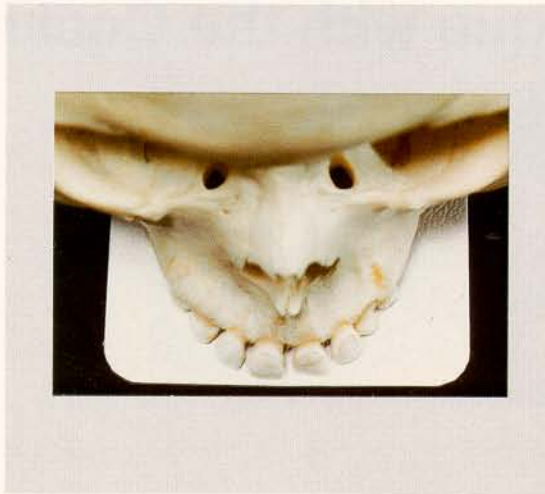
For edentulous patients examined in dental offices not yet equipped for panoramic radiography, an intraoral occlusal radiograph of the maxilla or the mandible may be employed to examine the jaws for the presence of root tips, retained or impacted teeth, cysts, tumors and tumor-like lesions. In young children, the standard periapical film packet may be used as an adequate occlusal film. In such cases, the goal is a simple illustration of the anterior teeth, often following trauma; therefore the projection of the teeth may be dealt with using the conventional bisecting angle technique. On the other hand, if a film holder is available for the right-angle system, it is possible to position the film in the central ray in all anterior regions, with minimum patient discomfort. In the case of fearful or traumatized children, this method may have psychological advantages.

Extraoral occlusal films can be employed for various special indications. For example, lateral depiction of the nasal bone of the maxillary anterior jaw region can be useful after trauma, in addition to localization of ectopic maxillary anterior teeth. Furthermore, lateral soft tissue projections of the lips may also be prepared. The occlusal film may also be used for depiction of the chin region without superimposition effects, for example to enhance panoramic radiography following trauma. Worthy of note is that the occlusal film used as a foil-free "periapical" film necessitates a relatively long exposure time; however, use of the special small cassette developed by Kodak (X-ray Intra-Oral Cassette, ca. 6×8 cm with "regular" foil) keeps exposure time within limits. Less commonly known among pedodontists is the extremely practical film from Agfa-Gevaert (Agfa Dentus M2, 4×5 cm).

Survey occlusal radiograph of the maxilla

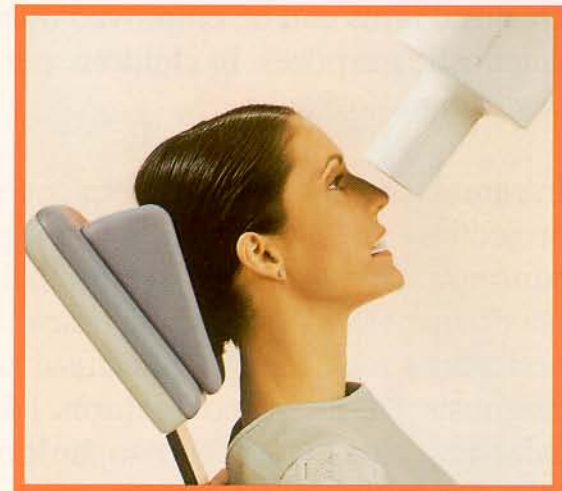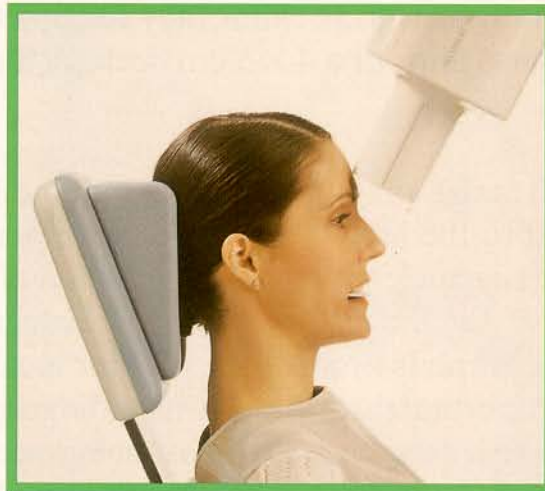151 Photograph and radiograph of the region

The 7.5x5.5 cm film packet is generally used for occlusal radiographs. For small children, the 3x4 cm periapical film packet can be used, and for special situations the 4x5 cm periapical film manufactured by Agfa.



152 Correct positioning for a maxillary occlusal radiograph

Note the film packet position and the central ray direction (left). Viewed laterally, the central ray is targeted through the maxillary first molar.

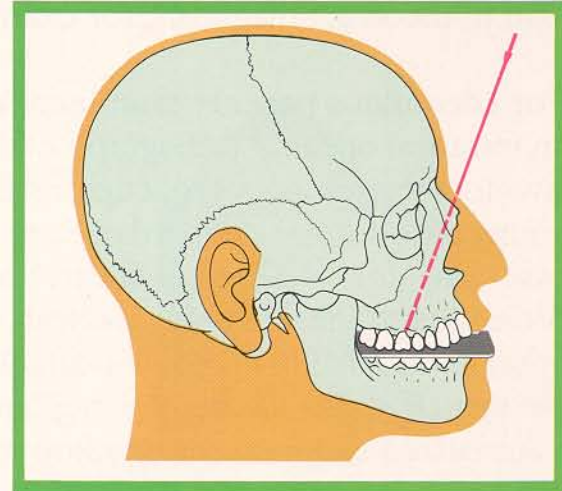
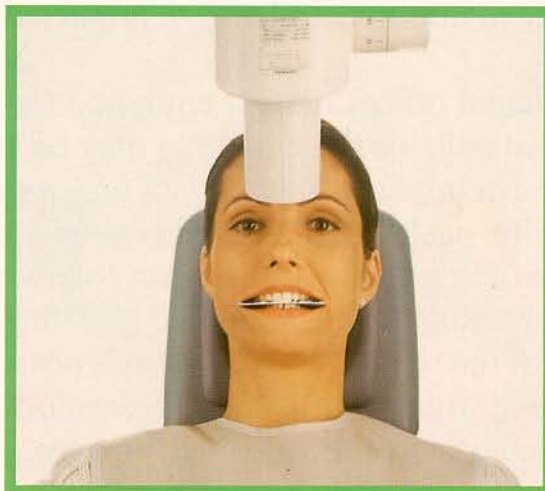


153 Incorrect positioning (right)

Compare the head position and the central ray direction in this photograph to that of Figure 152.

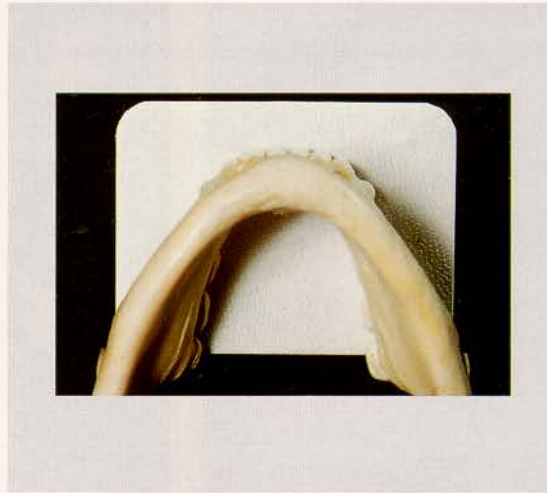
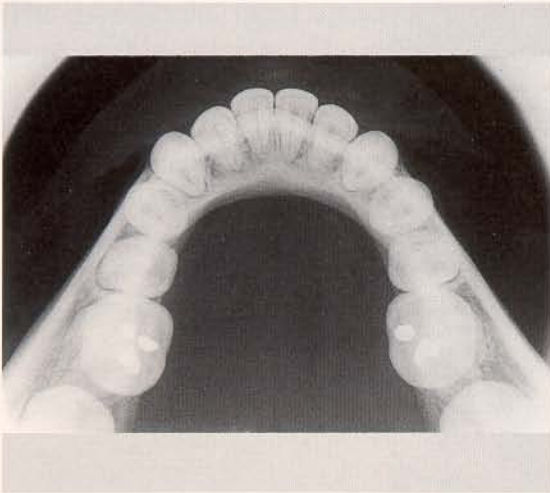
154 Correct positioning for a maxillary occlusal radiograph (front view)

Note the symmetric positioning of central ray and film packet.



155 Schematic diagram of the correct central ray projection (lateral view)

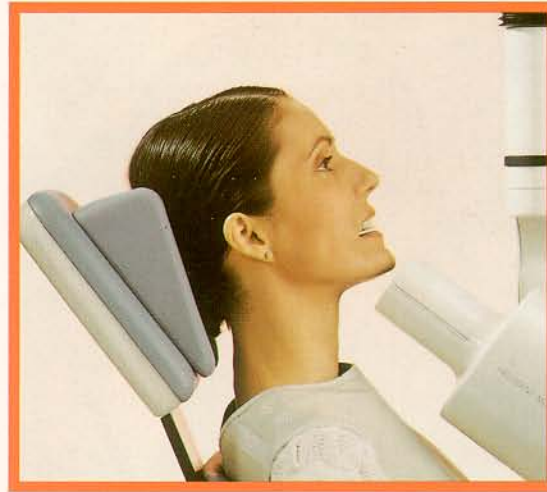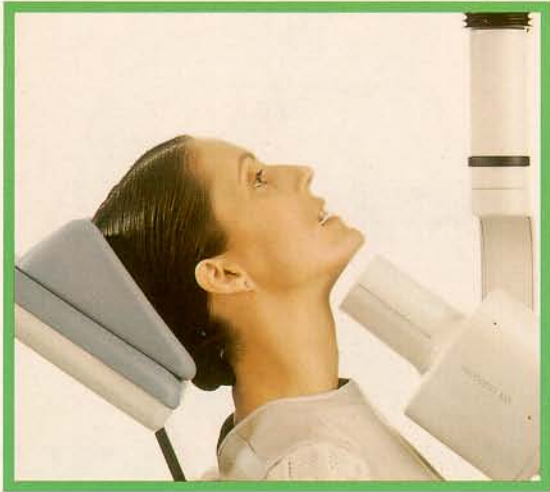Shown here are the proper head position and film packet position for a survey occlusal film in the maxilla. However, the central ray can be directed as described or precisely axially in relation to the long axes of the teeth. In the latter case, remember to increase the exposure time, and this will result in an elevated dose of radiation. Incorrect positioning, especially asymmetric targeting of the central ray, can lead to varying depiction of anatomic structures and therefore to incorrect interpretations.



Occlusal radiograph for a survey of the mandible

156 Photograph and radiograph

The foil-free 7.5 x 5.5 cm film packet is usually employed horizontally. For mandibular occlusal films in small children, the 3 x 4 cm periapical film packet or the 4 x 5 cm film from Agfa can be used.

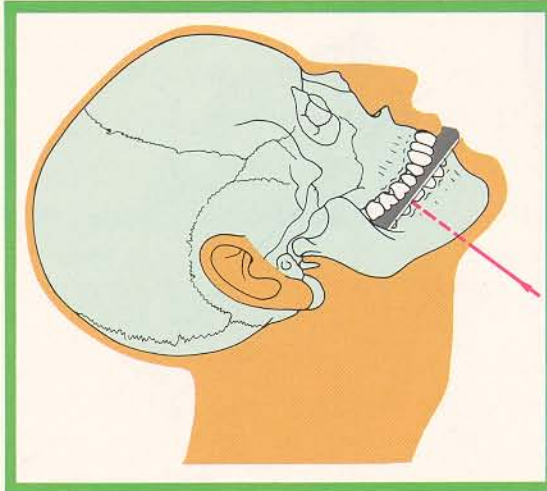


157 Lateral view of the correct positioning for a mandibular occlusal radiograph

Note the film position and the direction of the central ray. Viewed from the lateral aspect, the central ray is targeted through the mandibular first molar.

158 Lateral view of incorrect positioning

The incorrect positioning of the head interferes with proper direction of the central ray. This positioning does, however, permit the taking of radiographs of the mental spine.



159 Frontal view of correct positioning for the mandibular occlusal radiograph

Note the symmetrical positioning of the central ray and the film packet.

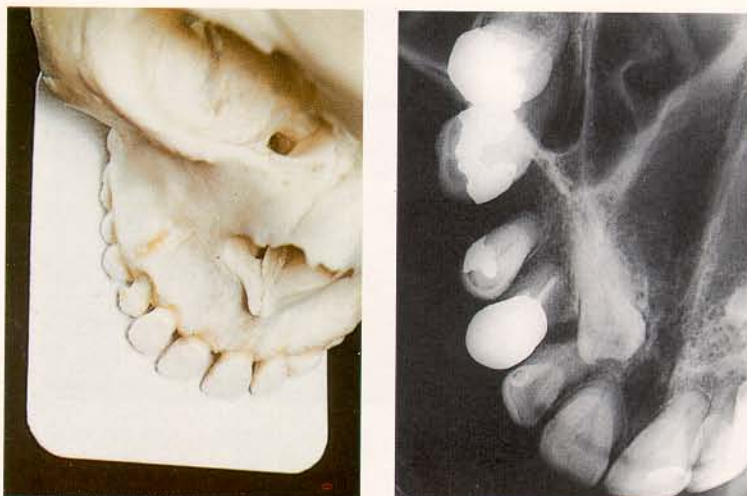
160 Lateral schematic view of the correct central ray projection

The overview provided by a mandibular occlusal radiograph is only useful if the indication is correct and the technical imperatives are properly carried out. This radiograph has been traditionally employed to supplement lateral projections. Only if the head is correctly positioned will it be possible for the central ray to impact the film at a right angle. To show thin vestibular or lingual boundaries of a lesion, the exposure time must be reduced by approximately one-half. The position of the mandibular third molars cannot be ascertained using this technique.

Unilateral occlusal radiographs of maxilla and mandible

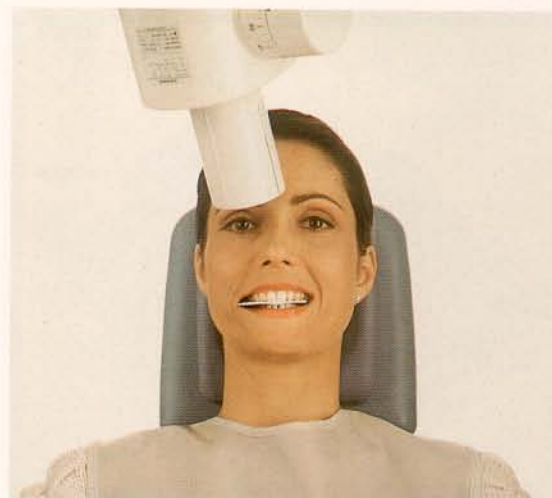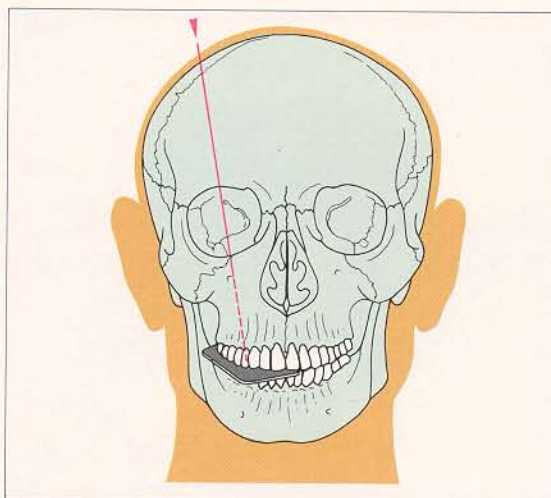
161 Photograph and radiograph

Usually the foil-free 7.5x5.5 cm occlusal film is used. In this case, the film packet is inserted lengthwise, with its outer edge parallel to the posterior dental segment.



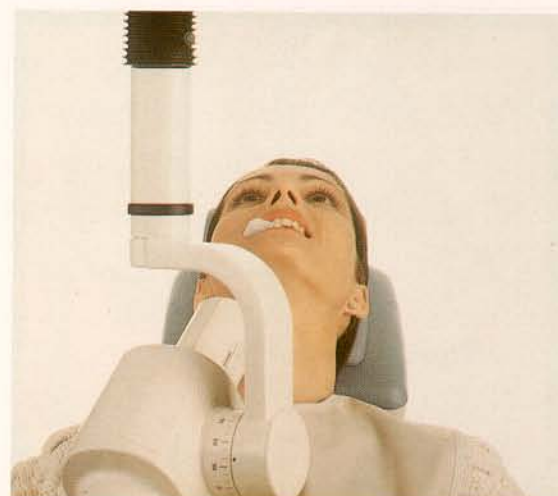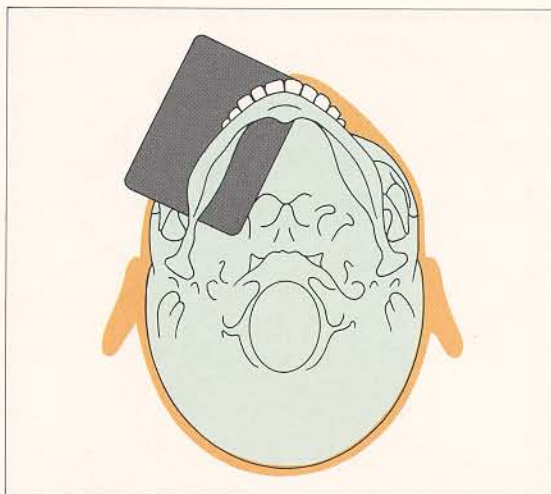
162 Diagram and photograph of proper positioning for a maxillary unilateral occlusal radiograph

This technique is often used for localization, but can lead to incorrect interpretation if the object is located superiorly. This is because the oblique projection portrays such objects as displaced palatally. However, this technique may be useful because it is a steeper projection (p. 85) that can supplement the standard periapical radiograph.



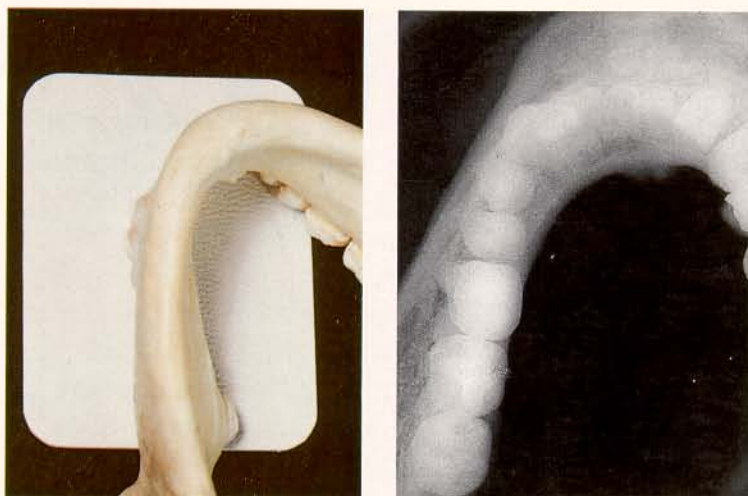
163 Diagram and clinical photograph of positioning for a mandibular unilateral occlusal radiograph

This technique is usually employed for detection of sialoliths in the ducts of the submandibular gland. For this indication, the exposure time should be reduced by one-half. Note the position of the head, which is similar to that employed for a mandibular occlusal radiograph. The central ray, however, is directed obliquely from below and laterally upward and inward.



164 Photograph and radiograph exhibiting the radiographic technique for unilateral mandibular occlusal films

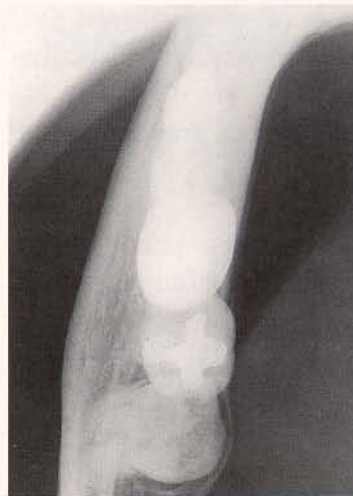The photograph shows clearly the axial direction of projection of the central ray with regard to the long axes of the teeth.



The mandibular third molars exhibit a myriad of positions within the jaw. The occlusal radiograph can be used to portray such teeth in an axial projection only if:

- the head of the patient is turned toward the healthy side to permit proper direction of the central ray
- the depiction of the other molar teeth, which appear severely distorted in this projection, is not relevant.

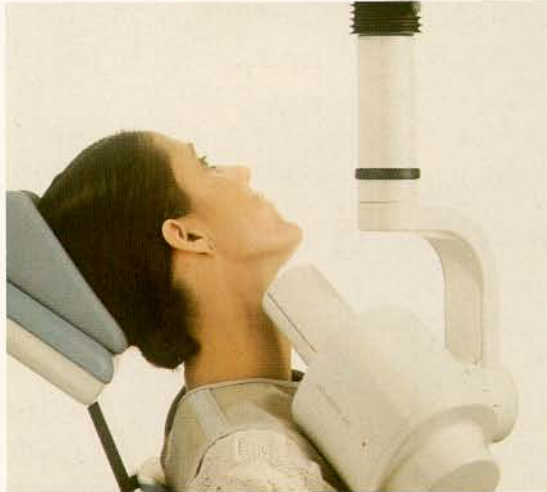
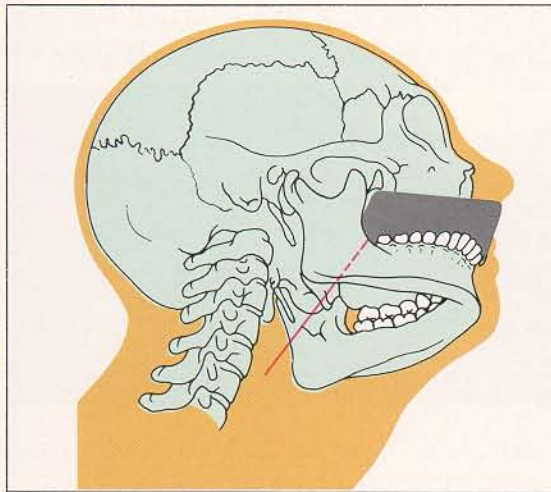
A better overview may be provided by the reverse Towne radiograph (p. 117).



Special positioning for mandibular third molars, and for small children

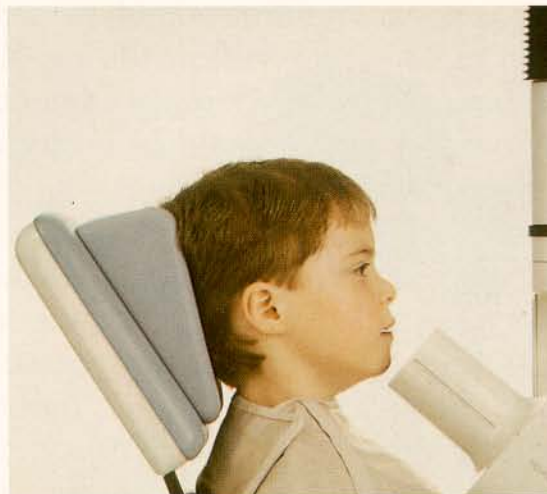165 Radiograph for localization of mandibular third molars

A standard occlusal film packet is employed, positioned longitudinally. Its posterior border must contact the ascending ramus of the mandible.



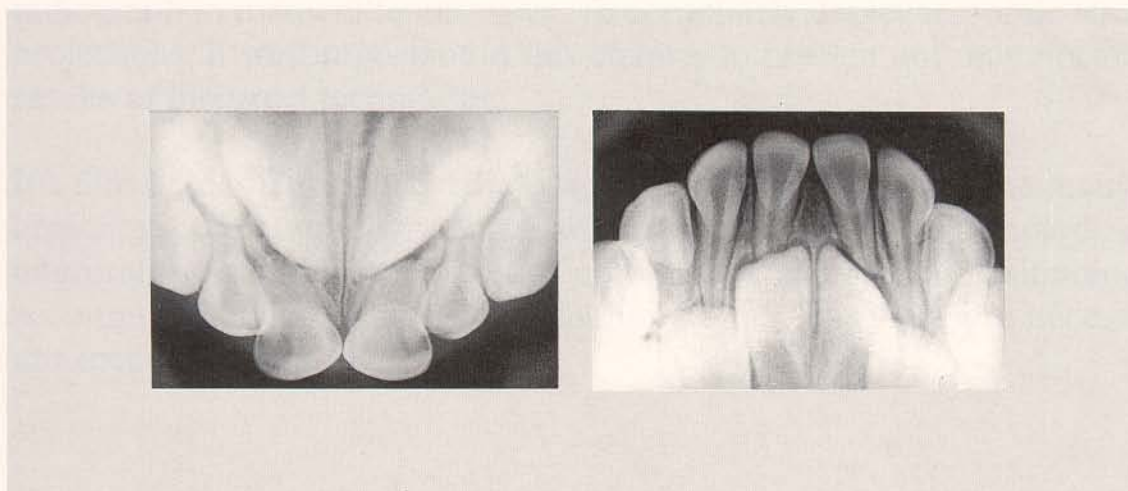
166 Diagram and photograph of positioning for localization of a mandibular third molar

After placing the film packet, the patient's head is turned and tilted toward the "healthy" side, to permit proper placement of the X-ray head. It is imperative that the central ray impact the third molar via the angle of the mandible, to be projected superiorly and anteriorly onto the film.



167 Positioning for radiographic depiction of the anterior region in small children following trauma

The 3x4 cm film packet is used as an occlusal film, positioned between the jaws and held there as the patient closes. Targeting of the central ray follows the rules for the bisecting angle technique.



168 Periapical film packet used as an occlusal film

This technique, supplemented with two bite-wing radiographs in 2x3 cm format may serve as a complete radiographic survey for small children.

The so-called chin radiograph is often employed as a supplement to panoramic radiography. It is recommended in the following situations:

- for clear depiction of the course of fracture lines, dislocations and fragments
- for follow-up of osteosynthesis
- to determine the expanse of cysts, pseudocysts, tumors and tumor-like lesions in the chin region.

For depiction of the lateral mandibular border, the central ray is targeted more steeply than in Figure 170.

Lateral views of the anterior region and the nasal bone, as well as lateral soft tissue projections of the nose or the lips can be prepared perfectly using the extraoral occlusal technique. Depending upon the particular situation, the film is exposed using only about one-third of the usual exposure data for hard tissues and about one-tenth for soft tissues. The object in question should always be projected at a right angle onto the film; a right angle film holder is used to advantage in such situations.

This specific dental examination method cannot be replaced by any other.

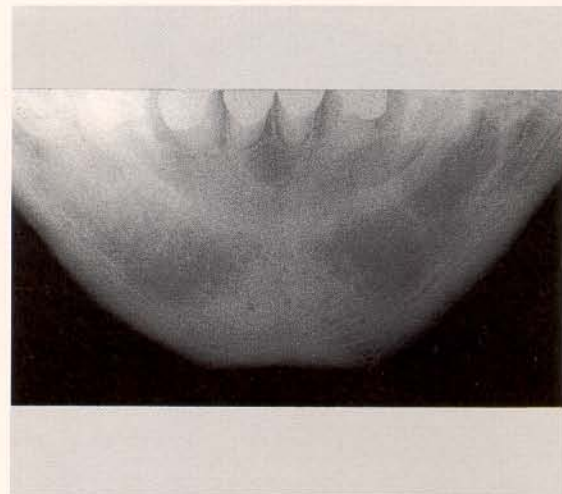
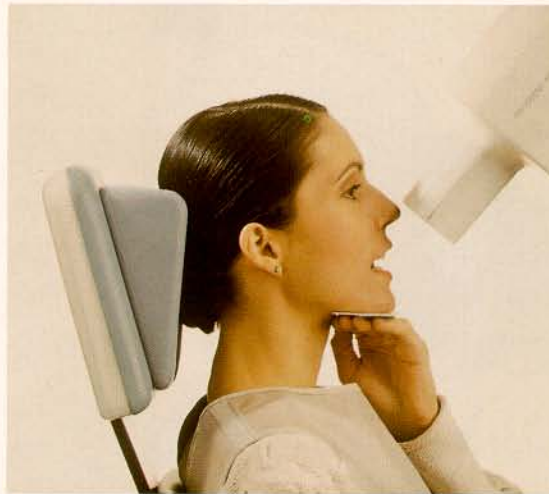Extraoral radiographs using the occlusal film

169 Positioning for the chin radiograph

The central ray projects the chin and the mandibular anterior teeth onto the film packet, using the bisecting angle technique.

170 Radiograph of the chin

The 7.5x5.5 cm format occlusal film is applied extraorally. It is indicated for localization of fracture fragments in the chin region.

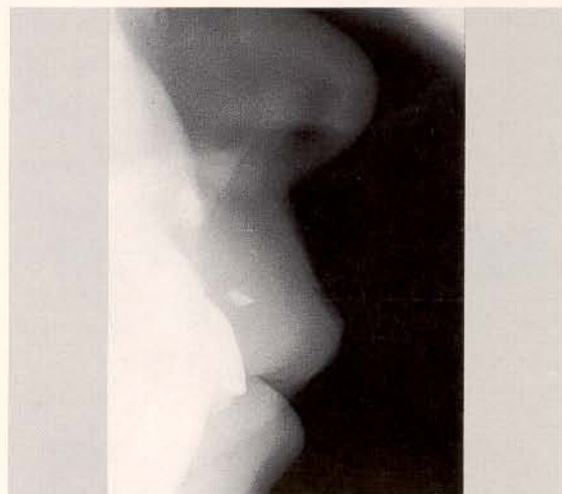
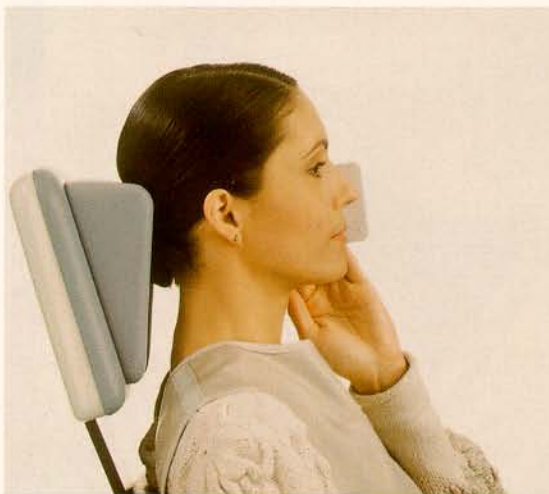

171 Positioning for a soft tissue exposure of the upper lip

The occlusal film packet is positioned as close to parallel as possible to the median sagittal plane. Depending on the indication, the packet can be moved toward the nasal bone or the lower lip.

172 Soft tissue radiograph using the occlusal film

This film can be used to show ectopic anterior teeth, nasal bone fractures, or foreign bodies after trauma. The central ray is targeted perpendicularly to the film packet.



Radiographic Anatomy in Periapical and Occlusal Radiographs

For all intraoral or extraoral dental radiographs, the radiographic anatomy as well as the general principles of radiology apply, as described in the section on radiographic anatomy in panoramic radiographs (p. 25).

The *tangential effect* and the *summation effect* play decisive roles in the depiction of structure borders, and ascertainment of three dimensional relief. The third dimension is often overlooked because it appears to be lacking, but it is in fact formed from overlying structures where enlargement and resolution are dependent upon the geometric relationships between film-object and object-focus. Any change in the central ray projection leads to an alteration of the radiographic illustration of the relationships among and between anatomic structures. This is why a single film can be insufficient and may even lead to incorrect interpretation when special examinations are performed using conventional radiographs. One need only consider the problems of localization. Dense, thick structures such as tooth roots may obscure thinner structures such as vestibular or lingual (palatal) alveolar walls because of increased X-ray absorption; on the other hand, the superimposition of such structures by air- or soft tissue-containing spaces may lead to radiolucencies as a result of less X-ray absorption. An example of this is the possible superimposition of mandibular premolar roots by the mental foramen.

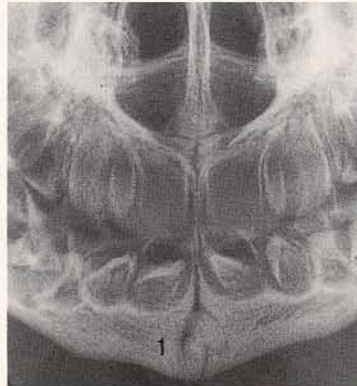
In this context, as already mentioned above, the *radiographic technique* used is of critical importance. In contrast to panoramic radiography, in which the patient is more or less immobilized by the cephalostat and the stationary X-ray beam positioning, the free-hand positioning of the film packet and the central ray vis-à-vis the random positioning of the skull during periapical radiography presents a broad variety of projection possibilities. As a consequence, projection variation causes structural details to shift in the third dimension, and may significantly alter the appearance of a radiograph in many different ways. To completely depict anatomic structures in various possible projections, it was important in this chapter to present not only normal projections but also the results of incorrect techniques.

If a film holder is routinely employed, it is possible to reduce the many possibilities for incorrect depiction of anatomic structures, which can lead to more standardized films that are easier to interpret. Finally it is important to note that certain special positionings cannot be satisfactorily accomplished even using a universal film holder; it is therefore necessary to have knowledge of unexpected structures.

Radiographic Anatomy During Tooth Development

173 Use of a periapical radiograph to depict the macerated skull of a newborn

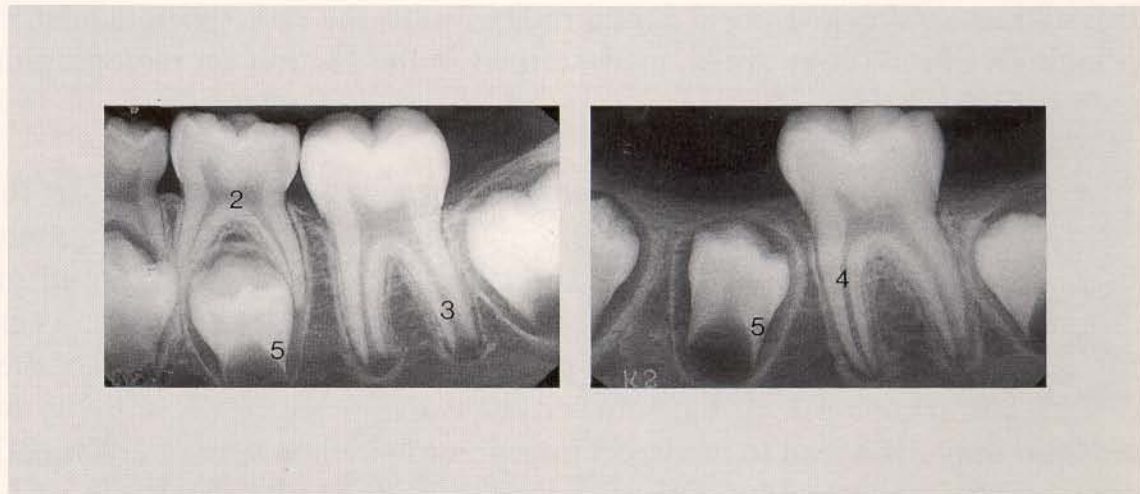
The region of the symphysis with the mental ossicles is clearly visible.



174 Normal eruption

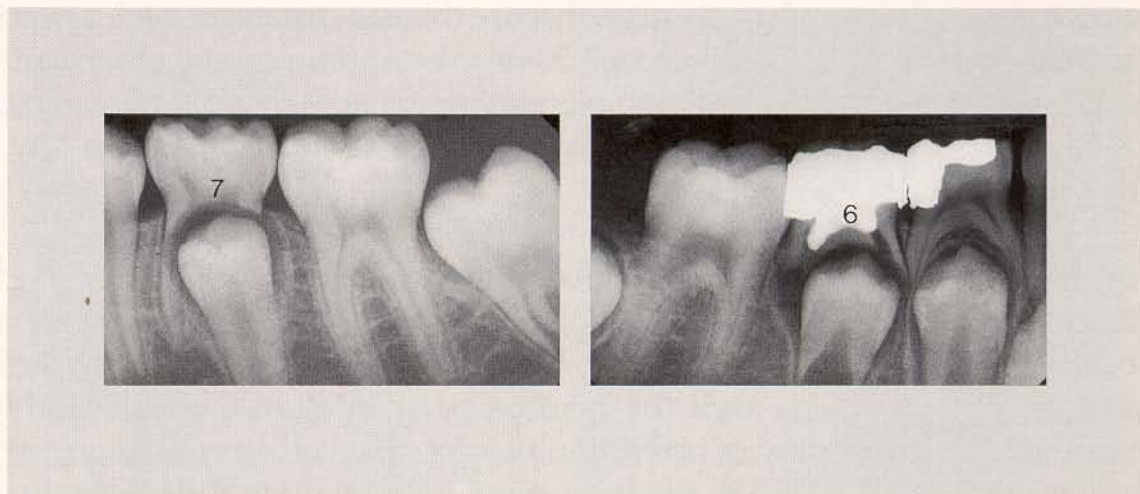
Left: The permanent teeth 34, 35, and 37 exhibit complete crown formation in this 7-year-old child. The apices of tooth 36 are not yet fully formed.

Right: 9-year-old child after extraction of 74 and 75. The root formation of 34, 35 and 37 has begun. The apices of tooth 36 have formed. The root canals of this tooth remain widely open.



175 Disturbances of tooth eruption

Left: This radiograph gives the impression that the mesial root tip of tooth 75, which shows signs of resorption, remains isolated in the alveolar bone. This and similar situations can lead to rotation and axial deformation of the permanent teeth. Root canal fillings, apical periodontitis and trauma to the deciduous teeth may also lead to displacement of permanent teeth.



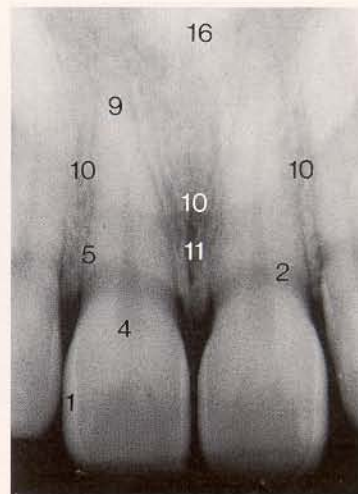
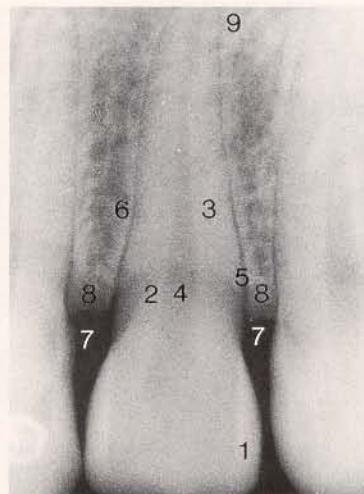
- 1 Symphysis of the mandible with mental ossicles
- 2 Normal eruption, with incipient resorption of the roots of deciduous tooth
- 3 Root formation not yet complete
- 4 Root apex and the root canal remain wide open
- 5 Incipient root formation
- 6 Apical periodontitis on tooth 85, which disturbs normal eruption of permanent tooth 45
- 7 Asymmetric root resorption on tooth 75

Radiographic Anatomy of Special Regions

Maxillary Anterior Region

The characteristic radiographic appearance of this region results from the varying thickness and density of the tissues. Anterior teeth exhibit shadowing, caused by enamel and superimposed bone, as well as radiolucencies at the cervical region of the tooth, which is not superimposed by other structures. The cervical dentin, which is not superimposed by alveolar bone or the enamel, is easily penetrated in its lateral aspects by the

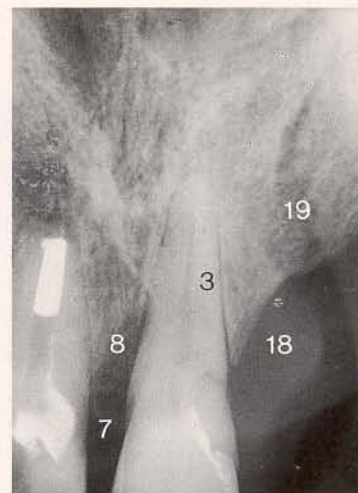
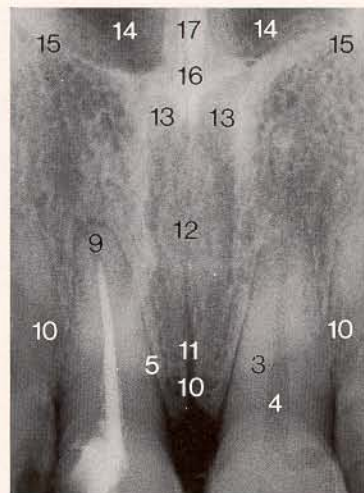
X-ray beam and therefore presents as a radiolucency (“burn-out effect”). The tip of the nose and the nasal orifices also contribute to both addition and subtraction effects; frequently the anterior portions of the floor of the nose and the median suture are clearly visible. Often it is difficult, however, to visualize the incisive foramen.



176 Radiograph of an intact tooth 22 (left)

This figure exhibits well the addition effects caused by enamel and alveolar bone, as well as the subtraction effects due to the periodontal ligament space and the pulp canal.

177 Radiograph of the maxillary central incisors



178 Radiograph of the nasopalatine canal system apical to teeth 11 and 21

179 Addition and subtraction effects caused by nasal soft tissues

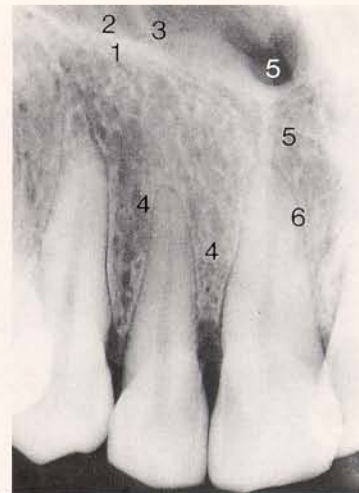
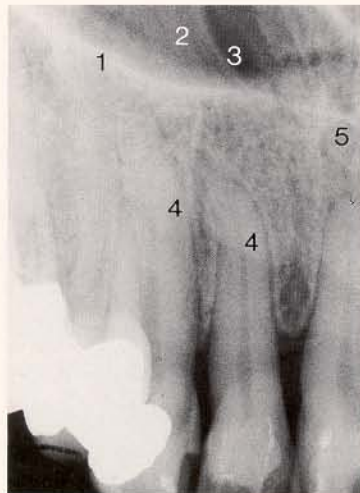
- | | |
|---|---|
| 1 Coronal enamel made visible via tangential effect | 10 Tip of the nose |
| 2 Cervical area of the tooth between the enamel layer and the entrance to the alveolus | 11 Median suture |
| 3 Tooth root | 12 Incisive foramen |
| 4 Pulp canal | 13 Nasopalatine canal |
| 5 Periodontal ligament space | 14 Nasal foramen of the nasopalatine canal |
| 6 Lamina dura | 15 Piriform aperture |
| 7 Vestibular margin of the alveolar bone | 16 Anterior nasal spine |
| 8 Palatal margin of the alveolar bone | 17 Nasal crest of the maxillary bone |
| 9 Apex | 18 Nasal cartilage |
| | 19 Nasal introitus |

Maxillary Canine Region

Figures 180 to 183 present eccentric views of the maxillary anterior region. In addition to the teeth, some of these films therefore exhibit other structures such as the nasal process of the maxilla and the nasal soft tissues, which result from the addition effect. The nasopalatine canal and the incisive foramen also often appear superimposed upon a central incisor. In this projection, both

roots of the first premolar appear, and sometimes a portion of the anterior lobe of the maxillary sinus is visible. The structure of the bone appears small meshed. This form is typical for the maxilla. Incisor teeth that are rotated or oblique in the central ray exhibit the burn-out effect at the cervical area of the crown.

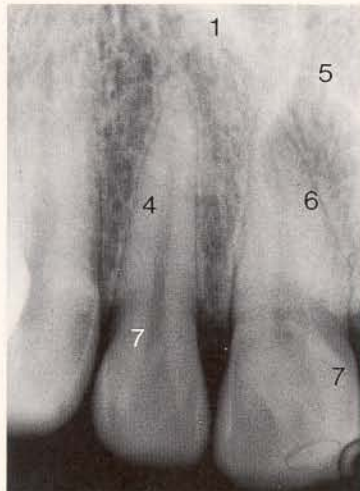
180 Distal eccentric projection, targeted on tooth 12 (left)



181 Distal eccentric projection, targeted on teeth 11 and 12 (left)

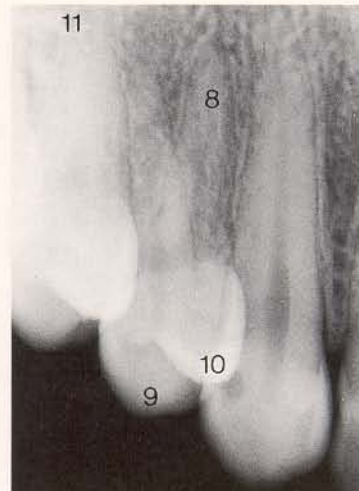
The incisive canal is superimposed upon the root of tooth 11.

182 Distal eccentric projection, targeted on teeth 11 and 12 (left)



In addition to the subtraction effect caused by the incisive foramen, tooth 12 also exhibits a burn-out effect at the cervical area, mesial and distal on the crown of the tooth.

183 Mesial eccentric projection targeted on tooth 13

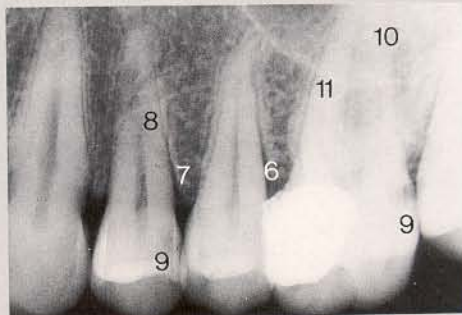
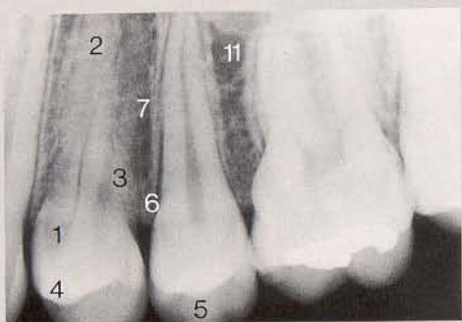

- 1 Laterobasal boundary of the nasal cavity
- 2 Frontal process of the maxillary bone
- 3 Piriform aperture
- 4 Lateral nasal border
- 5 Nasopalatine canal
- 6 Incisive foramen
- 7 Burn-out effect
- 8 Palatal root of tooth 14
- 9 Buccal cusp of tooth 14
- 10 Palatal cusp of tooth 14
- 11 Anterior lobe of the maxillary sinus

Maxillary Premolar Region

The possible relationships of the premolars and the molars to the maxillary sinus are so extraordinarily variable that it will not be possible to discuss them extensively here. Not only do the maxillary premolars exhibit quite variable root forms, the size and shape of the maxillary sinus also vary considerably. Of note is that

the periapical film only provides an orthoradial view of the region. The view is from lateral and superior onto the tooth roots and the floor of the sinus; it is for this reason that the floor of the sinus is never precisely outlined by the radiographically visible borders.

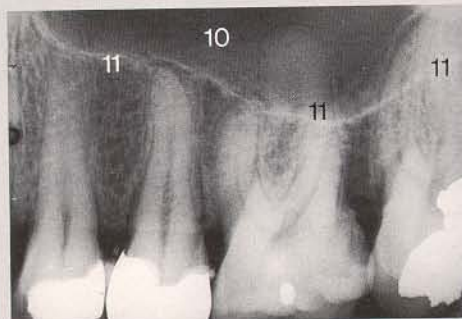
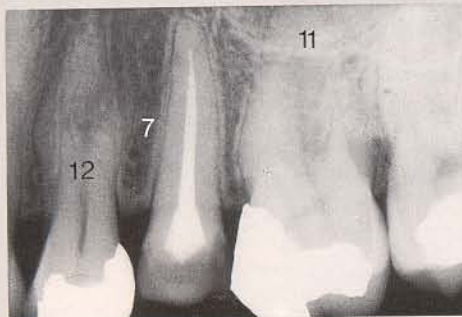
184 Radiograph of the region of teeth 24 and 25

Note the burn-out effect in the crown of tooth 24.

185 Radiograph of the maxillary left premolars

Note the root formation of tooth 24. Proximal caries is difficult to detect in periapical radiographs (note distal of tooth 24).



186 Radiograph of the region of teeth 24 and 25

Note that tooth 24 exhibits three roots!

187 Radiograph of teeth 24, 25 and 26

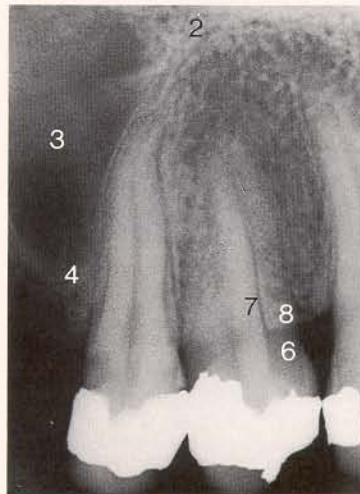Note the position of the floor of the sinus, which must be located between the buccal root tips and the palatal root tip of tooth 26.

- 1 Burn-out effect
- 2 Palatal root of tooth 24
- 3 Buccal root of tooth 24
- 4 Palatal cusp of tooth 24
- 5 Buccal cusp of tooth 25
- 6 Periodontal ligament space
- 7 Lamina dura
- 8 Dilacerated buccal root
- 9 Proximal caries
- 10 Floor of the maxillary sinus
- 11 Laterobasal border of the maxillary sinus
- 12 Tooth 24, exhibiting three roots

The radiographs of the premolar region presented on this page were not taken using the standard technique. Because of the steep projection angle, these films exhibit numerous anatomic details. The view is obliquely from above onto the floor of the nasal cavity and maxillary sinus. The palatal portion of the alveolar process of the maxilla is projected on the floor of the maxillary sinus,

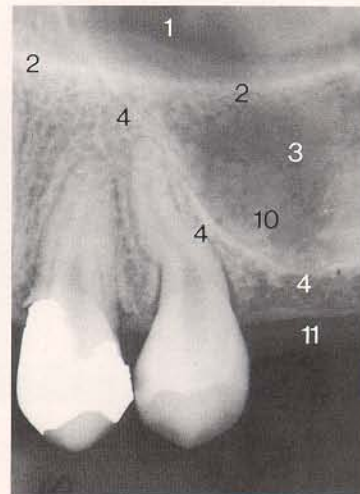
where it is seen as background formation. Usually a sinus is traversed by a septum that is often projected in the region of the root tip of the maxillary second premolar. The laterobasal walls of the nasal cavity often appear as a more or less horizontal opaque line at the upper border of the radiograph if the projection angle is steep or if the film has been bent.

188 Radiograph of the region of teeth 15 and 14 (left)



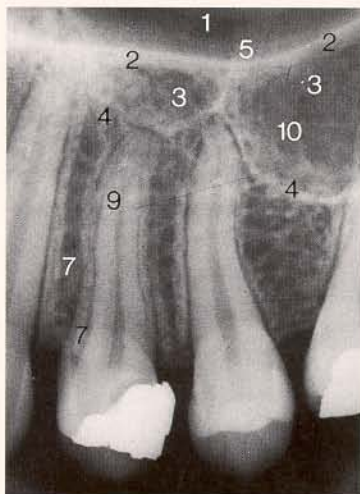
189 Radiograph of the region of teeth 24 and 25

After the loss of one or more molars, the maxillary sinus has expanded toward the alveolar crest and thus appears "far down" in the periapical radiograph.

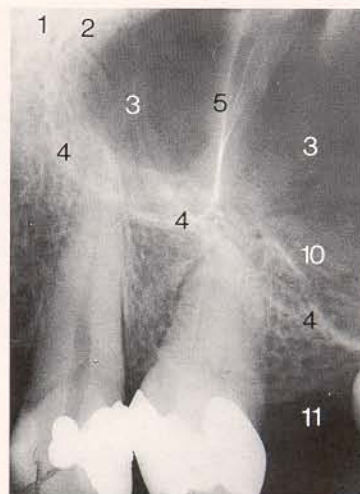


190 Radiograph of the region of teeth 24 and 25

Figures 190 and 191 reveal how the septum divides the anterior recess from the alveolar recess of the sinus.



191 Radiograph of the region of teeth 23 and 24

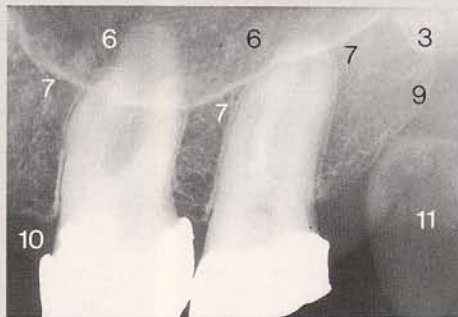
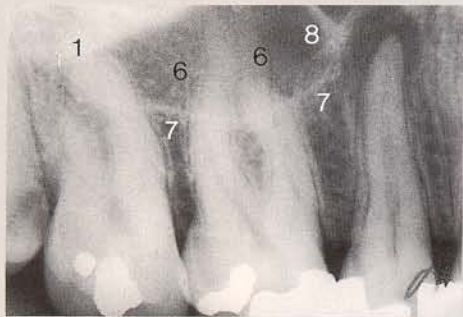


- 1 Floor of the nasal cavity
- 2 Laterobasal border of the nasal cavity
- 3 Floor of the maxillary sinus
- 4 Laterobasal border of the maxillary sinus
- 5 Septum dividing the anterior recess from the alveolar recess of the sinus
- 6 Burn-out effect
- 7 Periodontal ligament space
- 8 Interradicular bone septum anterior to the palatal root of tooth 14
- 9 Superimposed roots of tooth 24; the longer root is the palatal
- 10 Alveolar process appears as the "background" on the sinus floor
- 11 Alveolar crest

Maxillary Molar Region

Here again it is important to keep in mind that when viewing a periapical radiograph one is looking from above and laterally onto the zygoma, the molars and the tuberosity region. If the projection angle is excessively steep, and if the apical base of the alveolar process is low, the zygoma is often projected on the film such that the

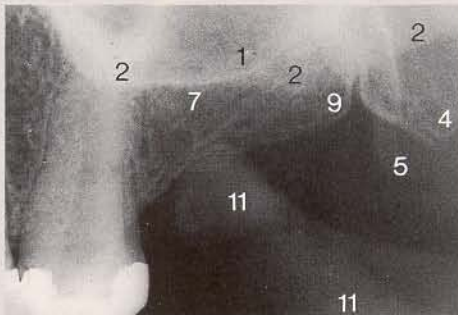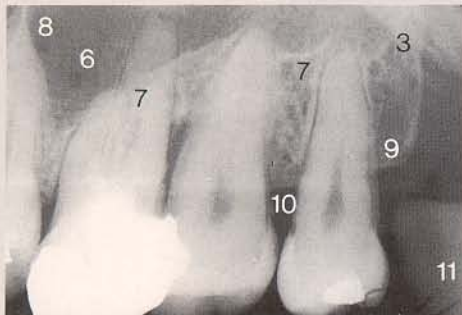root tips of the molars are obscured. Sometimes the pyramidal process of the palatal bone and the pterygoid process appear in the film. Sometimes the coronoid process of the mandible encroaches on the film, appearing as the so-called "radix relicta" projected on the tuberosity.



192 Periapical radiograph of the maxillary right molar region (left)

A well-demarcated chronic apical periodontitis on tooth 15 displaces the maxillary sinus and shows signs of reactive sclerosis.

193 Radiograph of the tuberosity region, maxillary left



194 Radiograph of the molar and tuberosity regions, maxillary left

195 Radiograph of the tuberosity region, maxillary left

The zygomatic process of the maxilla and the body of the zygoma shadow the root tips of 27 and the tuberosity region.

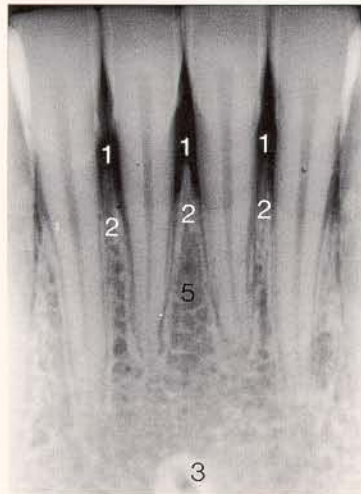
- 1 Body of the zygoma
- 2 Zygomatic process of the maxilla and shadow of the zygomatic bone
- 3 Pyramidal process of the palatal bone
- 4 Lateral lamina of the pterygoid process
- 5 Hamulus of the medial lamina of the pterygoid process
- 6 Floor of the maxillary sinus
- 7 Laterobasal border of the maxillary sinus
- 8 Septum of the sinus
- 9 Maxillary tuberosity
- 10 Alveolar crest
- 11 Coronoid process of the mandible

Mandibular Anterior Region

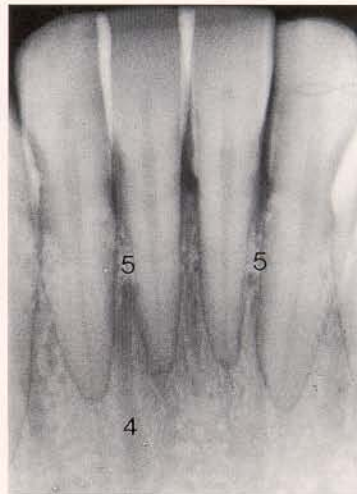It is usually possible to depict the four mandibular incisor teeth in a single periapical radiograph. If the mental fovea is deep and broad, a rather well-demarcated radiolucency will appear toward the alveolar crest; without perfect knowledge of the anatomic structures,

such radiolucencies have been described as “cystoid.” Especially in cases of advanced chronic marginal periodontitis, well-demarcated radiolucent bands appear to course apically between the roots of the anterior teeth. Such radiolucencies represent vascular canals.

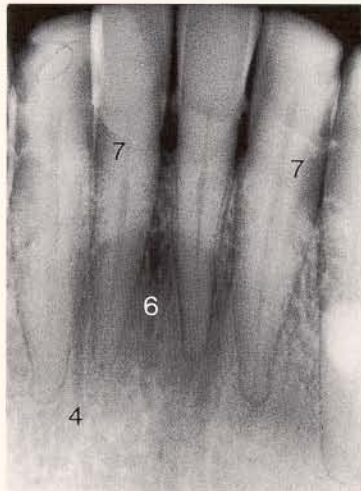
196 Normal periapical radiograph of the mandibular anterior teeth



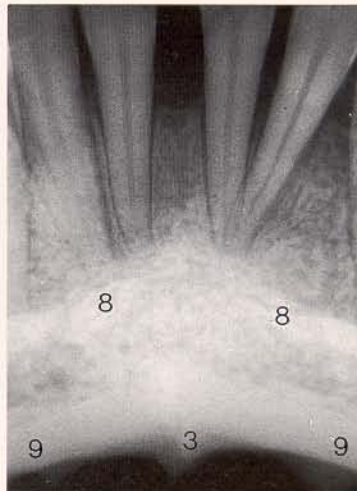
197 Periapical radiograph depicting vascular canals



198 Radiograph of a mandibular anterior segment clearly exhibiting the mental fovea



199 This periapical radiograph of the mandibular anterior region was taken with a steep projection angle and depicts the mental spine

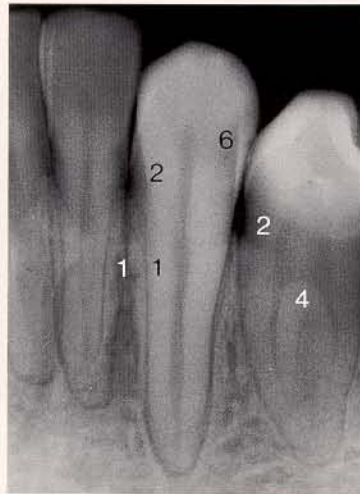


- 1 Labial portion of the interdental septum
- 2 Lingual portion of the interdental septum
- 3 Mental spine
- 4 Vascular canals depicted longitudinally
- 5 Cross sections of vascular canals
- 6 Mental fovea
- 7 Burn-out effect
- 8 Shadowing caused by the chin prominence
- 9 Compact bone

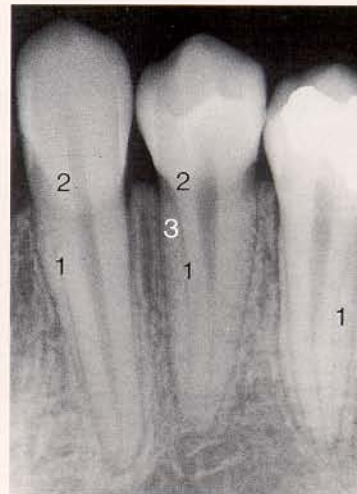Mandibular Canine Region

The bony structure of the mandible and the mandibular alveolar process is trabecular and unremarkable, but depending upon the radiographic projection angle, the canine tooth may exhibit several periodontal ligament spaces because of its flat and oval root form. Not infrequently one sees two completely developed roots; in an

orthoradial projection, these may be almost perfectly superimposed upon each other and therefore be difficult to ascertain. The same holds true for the first premolars. Enostoses are sometimes observed around the mental foramen.

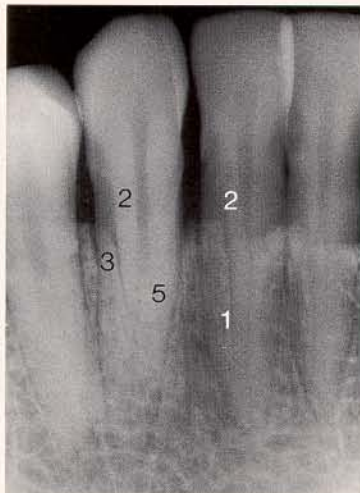


200 Radiograph of tooth 33 and a two-rooted 34



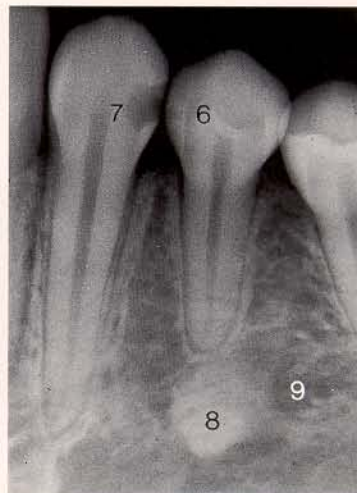
201 Radiograph of the region of teeth 33 and 34

Note the multiple periodontal ligament spaces resulting from the root form.



202 Radiograph of a two-rooted tooth 43

Note the easily visible course of the lingual portion of the alveolar ridge.



203 Radiograph of the region of teeth 33 and 34, with enostosis

- 1 Multiple periodontal ligament spaces on flat or slightly indented root surfaces; the alveolar walls are projected onto the lateral surfaces of the root
- 2 Burn-out effect
- 3 Interdental septum
- 4 Two-rooted premolar
- 5 Two-rooted canine
- 6 Dental caries
- 7 Prepared cavity with a non-radiopaque filling material
- 8 Enostosis
- 9 Mental foramen

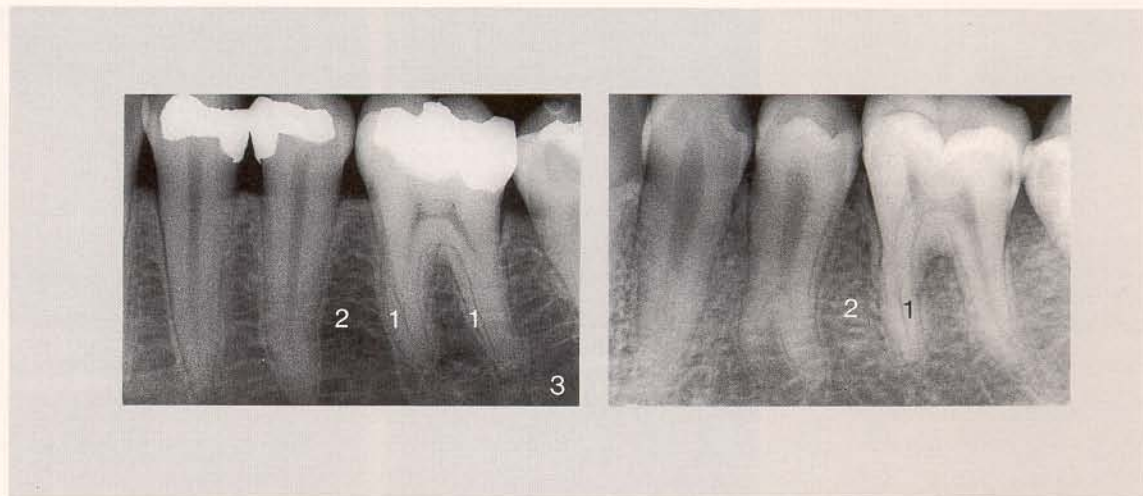
Mandibular Premolar Region

The typical, somewhat trabecular bony structure of the mandible persists down to about the level of the root tips. Apical to this area are located marrow-rich, trabecular-poor cavities that therefore appear strongly radiolucent. Often this radiolucency is enhanced more by the submaxillary and sublingual fovea. The mental foramen

is almost always observed between the roots of the premolars, but is often very difficult to discern because of the strongly radiolucent surroundings and the background of the lingual bony structures. Rarely, a variation of the root form, the "taurodont," is observed.

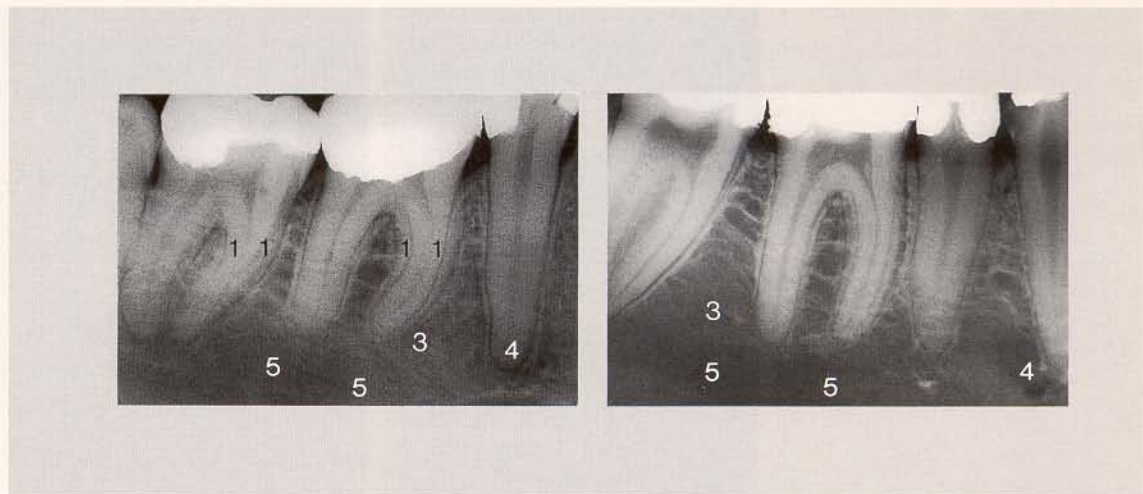
204 Periapical radiograph of the premolars, mandibular left

205 Radiograph of the left mandibular premolar region, exhibiting a taurodont



206 Radiograph of tooth 44 with superimposition of the mental foramen

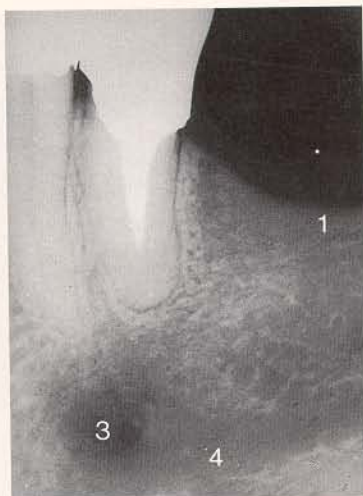207 Radiograph of the region of teeth 45 and 46, showing sparse trabeculation



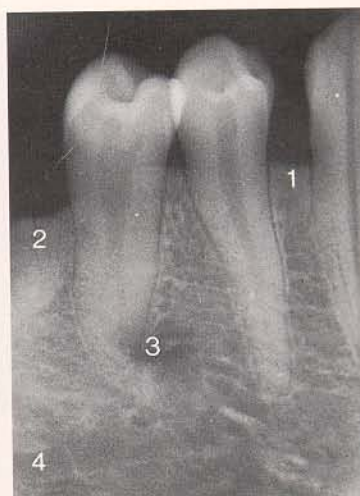
- 1 Depiction of multiple periodontal ligament spaces in this lateral projection of root surfaces
- 2 Typically trabeculated bone structure of the mandibular alveolar process
- 3 Zone of poor or no trabeculation in the body of the mandible
- 4 Mental foramen superimposed upon the tips of the premolars
- 5 The course of the mandibular canal can scarcely be discerned in this radiograph

The periapical radiographs depicted on this page were not taken using the standard technique for the premolar region. Because of the steep projection angle, these films depict anatomic details that are hardly visible in standard projections. Especially interesting is the apparently variable position of the mental foramen due to the different projection angles. The position of this foramen

cannot be unequivocally located in periapical films as compared to panoramic radiographs. For the non-dentist examiner, the superimposition of the mental foramen on or near the root tip of a premolar may present diagnostic problems. Figure 211 provides the criteria for differentiating the radiographic subtraction effect from a chronic apical periodontitis.

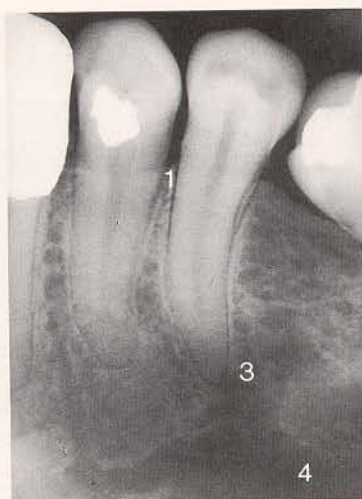

208 Radiograph of the region of teeth 34 and 35, with a steep projection angle



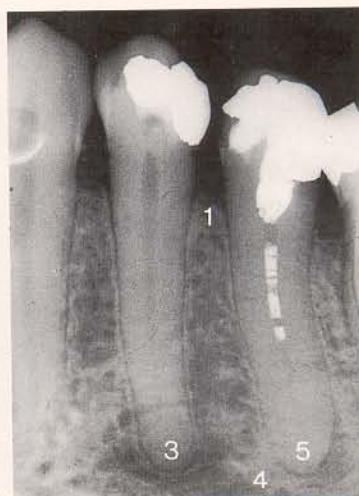
209 Radiograph of the region of teeth 45 and 44, with a steep projection angle

The mesial inferior corner of the film packet was bent.



210 Radiograph of the region of teeth 34 and 35

In addition to the excessively steep projection angle, the inferior margin of the film packet was bent.



211 Radiograph of the region of teeth 34 and 35

The appearance of the excessively long roots reveal that the bottom portion of the film packet was bent.

- 1 Buccal portion of the alveolar ridge
- 2 Root fragment
- 3 Mental foramen partially superimposed upon the root tips of the premolars; note the intact periodontal ligament space
- 4 Mandibular canal
- 5 Periapical lesion with reactive sclerosis; note the apparent loss of the periodontal ligament space in the region of the osteolysis

Mandibular Molar Region

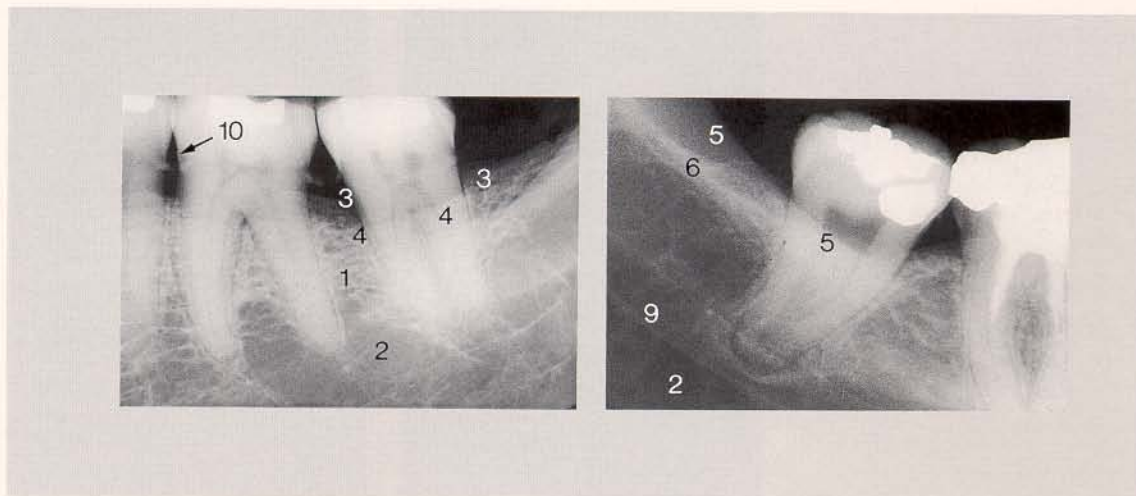
Periapical radiographs of the molar area exhibit numerous anatomic structures that are often difficult to interpret because such films represent only a small section of the mandible. The location of the mandibular canal can often only be detected, if at all, by the radiographic appearance of its floor, because the roof of the

canal is porous. The mylohyoid line often obscures the course of the canal, leading to incorrect interpretation; it also suggests excessive transparency of the submaxillary fovea. The external oblique line dominates and obscures the internal oblique line with the retromolar tuberosity.

212 Periapical radiograph of the region of teeth 36 and 37

213 Radiograph of the region of tooth 48

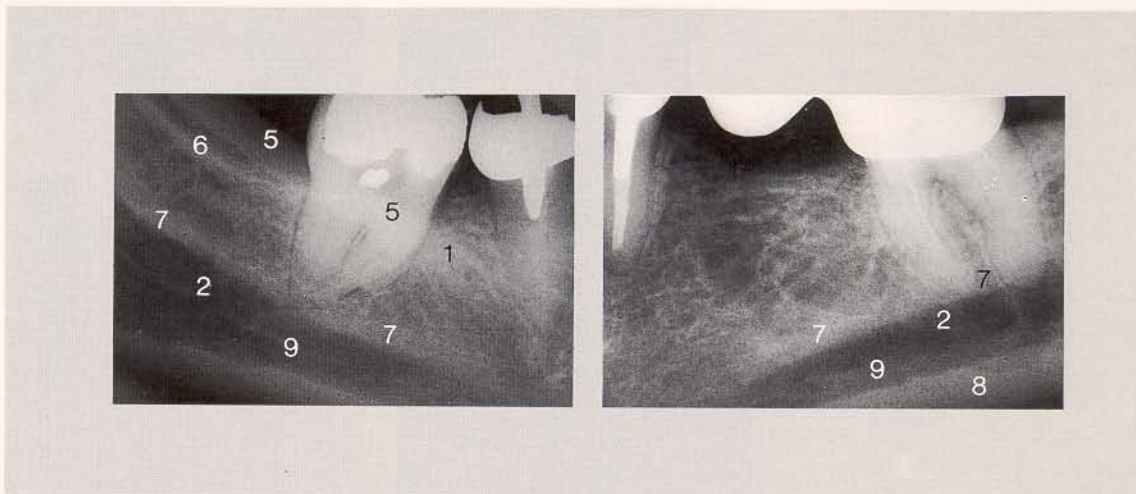
The apex of the nonvital tooth 48 is superimposed on the mandibular canal.



214 Periapical radiograph (steep projection angle) of the region of tooth 46

In this film and also in Figure 215 the mylohyoid line appears superimposed upon the mandibular canal because of the steep projection angle.

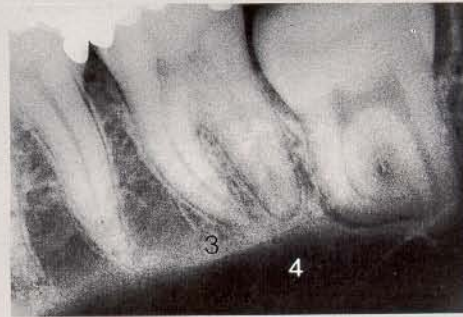
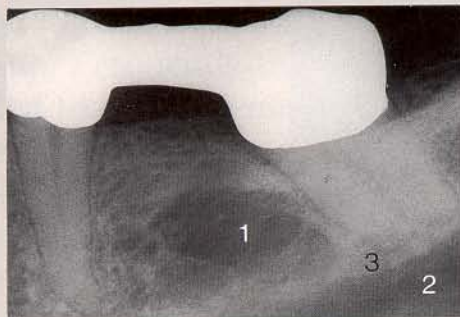
215 Periapical radiograph of the region of tooth 37



- 1 Structures of the alveolar process
- 2 Region of the body of the mandible exhibiting poor trabeculation
- 3 Buccal portion of the alveolar ridge
- 4 Lingual portion of the alveolar ridge
- 5 External oblique line (anterior border of the ascending ramus)
- 6 Internal oblique line (temporal crest)
- 7 Mylohyoid line
- 8 Compact bone of the mandible
- 9 Floor of the mandibular canal
- 10 Calculus

In addition to the anatomic details provided on the previous page, it is important to note the following variations: In elderly patients (especially women) and following tooth extractions, the fat-filled marrow space often expands into the region of the alveolar process. The clearly visible and well-demarcated radiolucency should not be mistaken for a "cystoid" lesion. Just below

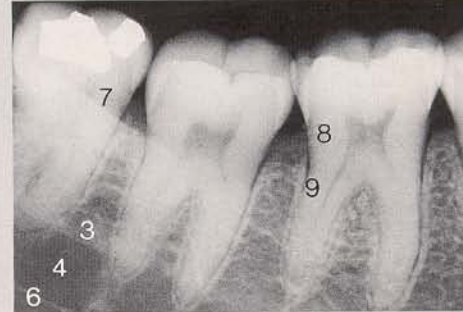
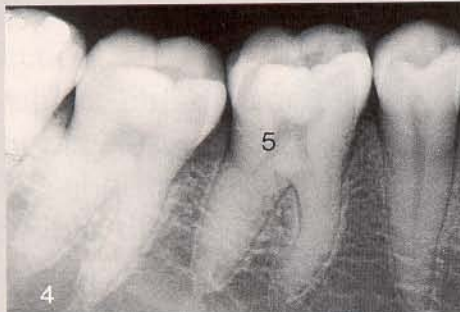the pulp chamber of lower molars, one sometimes observes roundish radiopacities, but these should not be confused with "enamel pearls"; rather they are created by the addition effect resulting from superimposition at the root trunk. This phenomenon disappears if the central ray projection is altered.



216 Radiograph of the molar region revealing an island of bone marrow

217 Periapical radiograph of the molar region showing the submaxillary fovea

This region of poor trabeculation in the body of the mandible is in sharp contrast to the well-trabeculated alveolar process.



218 Radiograph of the molar region showing an apparent "enamel pearl" on tooth 46

219 Radiograph of the same tooth with a different central ray projection

In the molar region, with a slightly eccentric projection, the phenomenon of "enamel pearl" is sometimes visible.

- 1 Bone marrow island
- 2 Mandibular canal superimposed on the submaxillary fovea
- 3 Mylohyoid line
- 4 Submaxillary fovea
- 5 "Enamel pearl" as an addition effect at the root trunk near the bifurcation on tooth 46 (see Figure 218, and compare Figure 219 with an altered central ray projection)
- 6 Floor of the mandibular canal
- 7 External oblique line
- 8 Buccal portion of the alveolar ridge
- 9 Lingual portion of the alveolar ridge

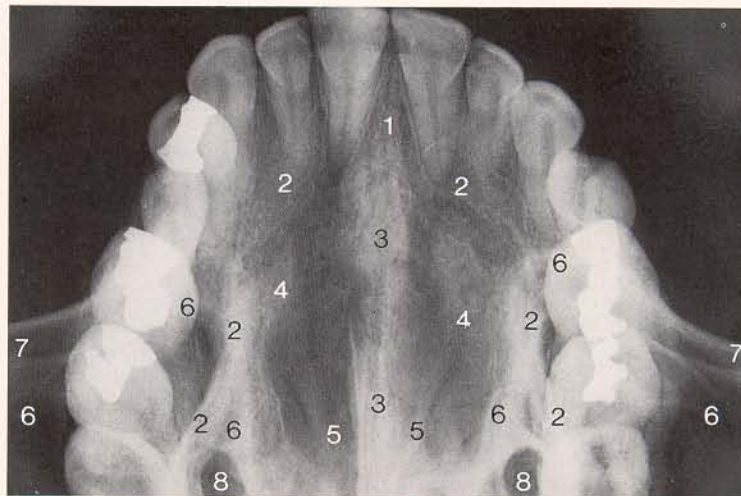
Radiographic Anatomy in Occlusal Radiographs

Because of the anatomic relationships of the skull, the survey occlusal radiograph of the maxilla can only be taken using an oblique projection angle. The radiograph therefore superimposes the alveolar process, the nasal cavities, the maxillary sinuses and the nasolacrimal canal. The occlusal radiograph can be used for localization of structures only with great care, or in combination

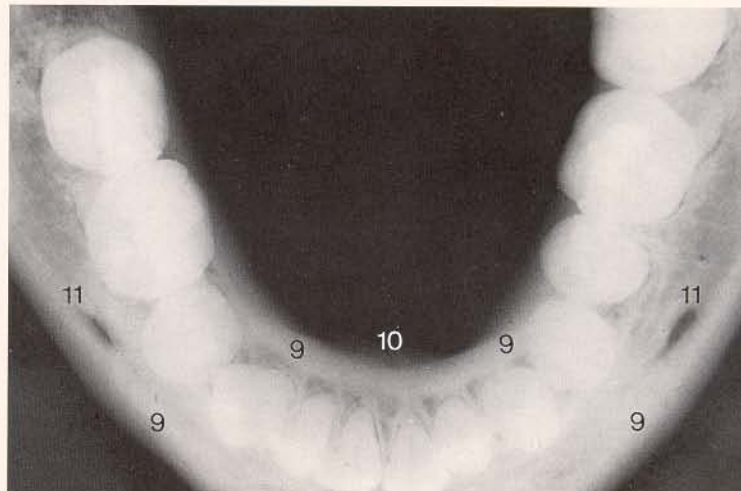
with a panoramic radiograph or an orthoradial periapical film.

In the ideal case, the survey occlusal radiograph of the mandible should depict the teeth along their axes and should show the surrounding compact bone as well as the mental foramina. The mandibular occlusal radiograph is often useful for localization.

220 Overview occlusal radiograph of the maxilla



221 Overview occlusal radiograph of the mandible



- 1 Anterior nasal spine
- 2 Boundary of the nasal cavity
- 3 Maxillary nasal crest and nasal septum
- 4 Superimposed conchae
- 5 Nasal bone
- 6 Maxillary sinus
- 7 Canine fossa and infraorbital margin
- 8 Nasolacrimal canal
- 9 Buccal and lingual compact bone
- 10 Mental spine
- 11 Mental foramen

Localization Using Various Methods

Usually the position of impacted teeth and retained root tips, but also those of foreign bodies and fracture lines, must be determined before or during appropriate therapy. During endodontic therapy, “localization radiographs” are often necessary, especially for interim examination and for follow-up. Frequently the so-called *eccentric projection* is appropriate, wherein the central ray is projected toward the mesial (mesial eccentric radiograph) or toward the distal (distal eccentric radiograph). Such films are supplemental to the standard orthoradial periapical film. It will not be possible here to present examples of all possible indications for determination of the position of structures in radiographs. The principle will be presented using several typical cases of retained and impacted teeth.

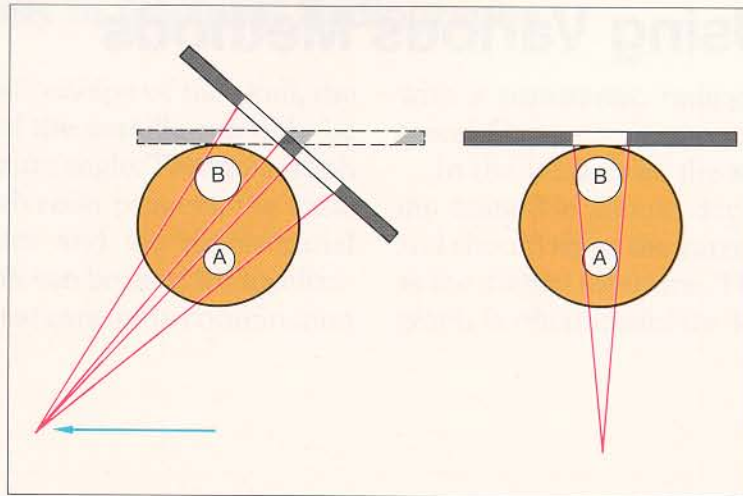
In general, the following guidelines should be observed:

1. An object whose position must be localized precisely should be radiographed together with either an obvious reference object or with a characteristic anatomic structure. The basis for localization technique is a change in positional reference that results from altering the central ray projection.
2. The object-film distance of the two objects provides clues:
 - Objects closer to the film appear sharper and of actual size.
 - Objects distant from the film appear blurred and enlarged.
3. If possible, the object in question should be radiographed using at least two different central ray projections that are perpendicular to each other. This is usually only possible through the use of whole skull radiographs.
4. If the object in question and its reference object cannot be examined as described in point 3 above due to technical reasons, two periapical films may be employed. The first is taken as a standard orthoradial projection, while the second employs a horizontal or vertical change in the central ray projection (Clark’s technique). The apparent “movement” of the object in these two radiographs will provide clues as to its exact location.
5. Panoramic radiography extends these well known possibilities. Objects that lie in front of the image layer appear blurred and reduced in size, while those that are behind the film appear out of focus and enlarged.

If the distance between the object in question and the reference object is too small, all methods for radiographic localization will fail, thus giving an indirect indication that the two objects are in fact in close proximity. Skull films are indispensable in many cases because they permit not only definitive changes of the central ray projection but also provide a clear overview.

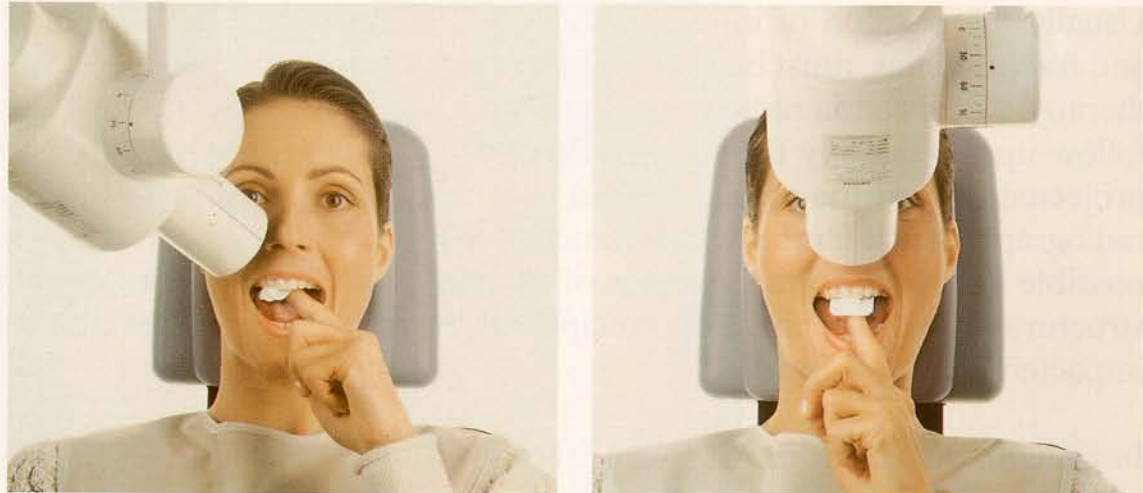
222 Localization using horizontal shift of the central ray projection

Schematic depiction of the orthoradial (*right*) and the distal eccentric (*left*) projections to localize impacted tooth 13 (B). The film packet need not be positioned identically for both projections. Only the proper central ray projection and the complete depiction of the crown of the tooth in question are important to compare its position to the reference object (A).



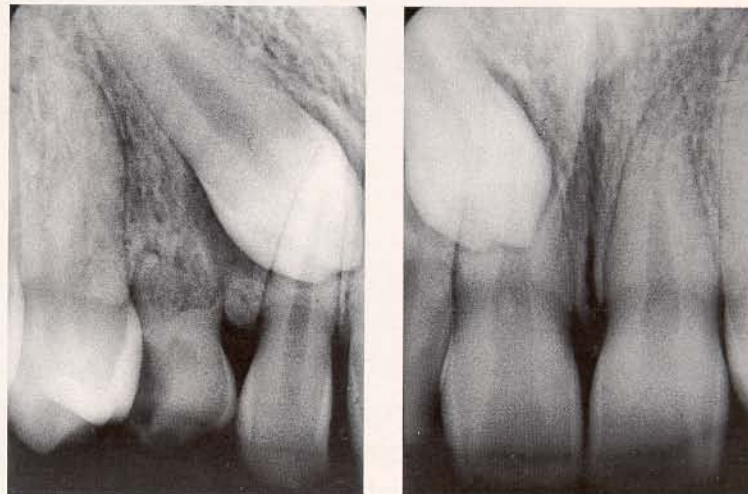
223 Set-up for horizontal shift of the central ray for localization of tooth 13

Note the differing film position and the distal eccentric shift of the central ray. A film holder substantially simplifies positioning of the film. This same localization technique can be used with multirouted teeth to provide radiographic evaluation of individual roots.



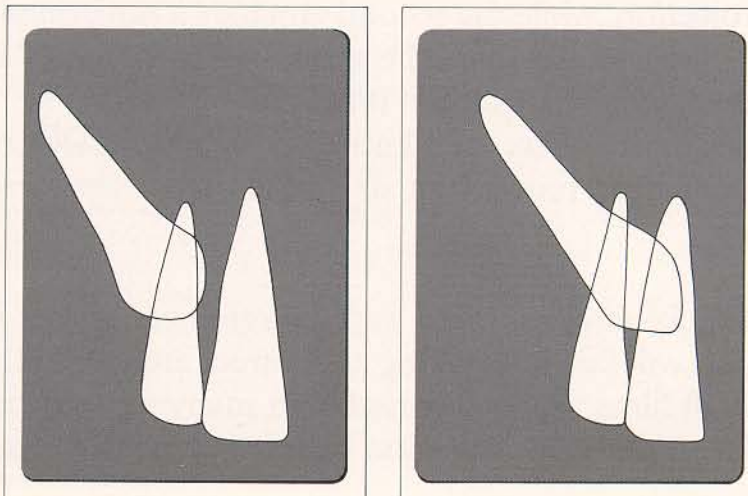
224 Examples of results, as viewed in radiographs

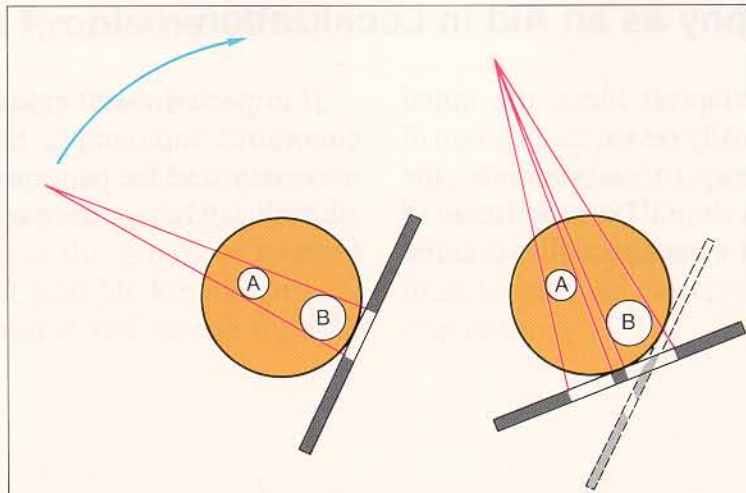
Right: Result with the initial standard orthoradial projection; *left:* result after movement of the X-ray tube into the distal eccentric position. A rule of thumb is that objects which move with the central ray movement are actually behind the reference object (Hotz). Thus, tooth 13 is positioned palatally.



225 Diagram of the horizontal shift of the central ray

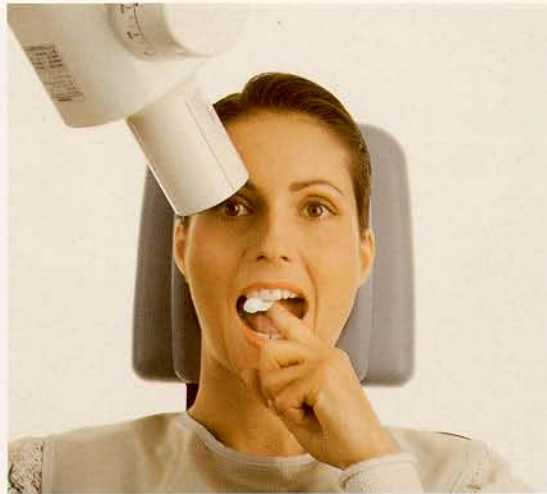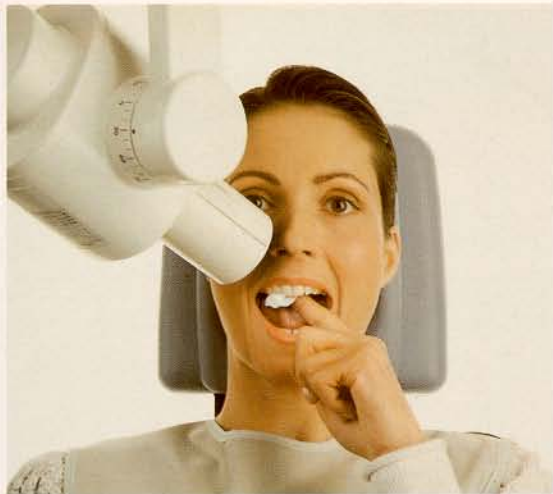
The crown of tooth 13 appears separate from tooth 11 (*left*) when the central ray is projected using the distal eccentric technique. If tooth 13 were positioned buccally (*right*), it would appear enlarged and would appear superimposed upon the root of tooth 11 in the radiograph.





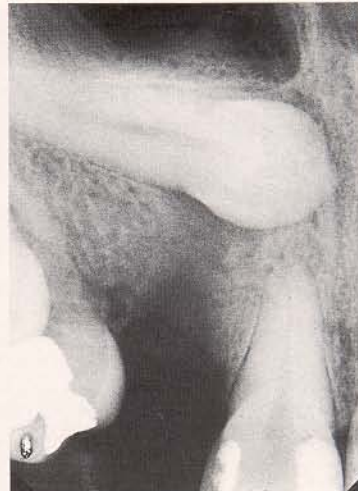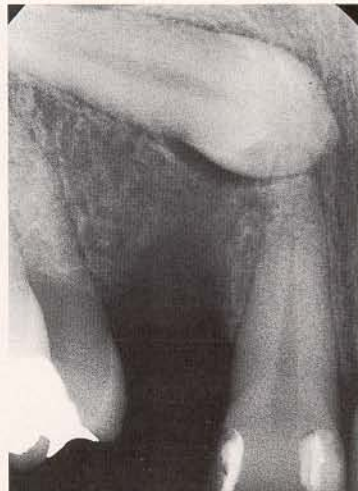226 Localization by vertical shift of the central ray

Schematic depiction of a standard orthoradial (*left*) and a steep projection (*right*) to localize an impacted tooth (B). The films need not be identically positioned for the two exposures. Most important is the proper central ray projection for depiction of the crown of tooth 13 (B) and the depiction of the root tip of 11 (A).



227 Set-up for the vertical shift of the central ray for localization of tooth 13

Note the vertical shift of the central ray in the right picture. This technique can be simplified by use of a film holder affixed to the end of the X-ray tube.





228 Result as seen in the radiograph

Left: Result with the initial standard orthoradial projection.

Right: Result after vertical shift of the X-ray tube.

These two films reveal that tooth 13 is positioned *palatally*, according of the rule of thumb that objects which appear to move *with* the central ray are located behind the reference object (Hotz).



229 Diagram of vertical central ray shift

The central ray, which enters from above at a high angle (*right*) provides a radiograph that shows a separation between the crown of tooth 13 and the root tip of 11. If tooth 13 were located buccally (*left*), it would appear enlarged and would significantly overlap the root of tooth 11.

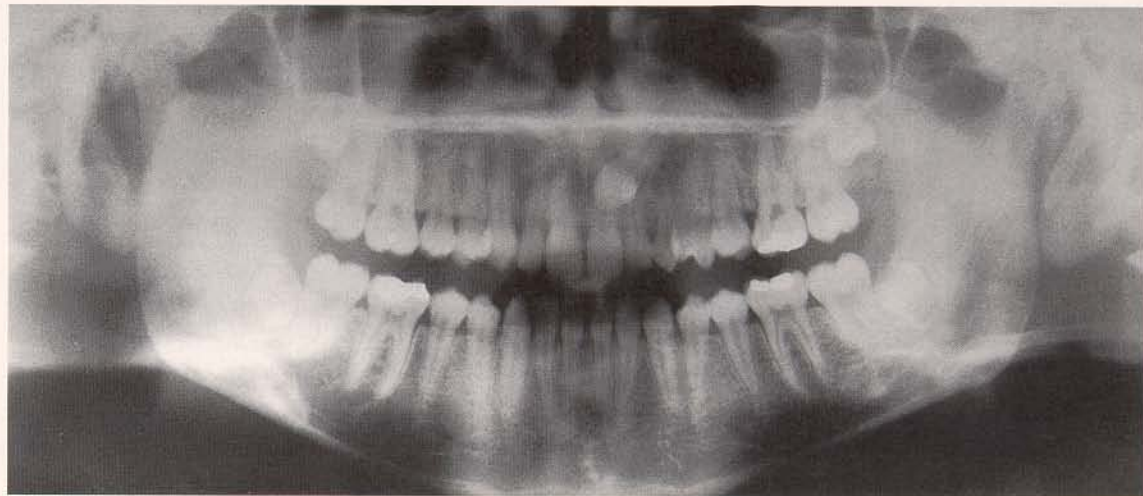
Panoramic Radiography as an Aid in Localization

In contrast to individual periapical films, the initial panoramic radiograph will usually reveal the position of impacted teeth. Nevertheless, to substantiate the diagnosis, the panoramic film should be supplemented with an occlusal radiograph or a periapical film in some cases.

If impacted teeth appear in an axial location in the panoramic radiograph, however, the greatest care is necessary, and the panoramic film *must* be supplemented with lateral, posteroanterior or axial skull projections.

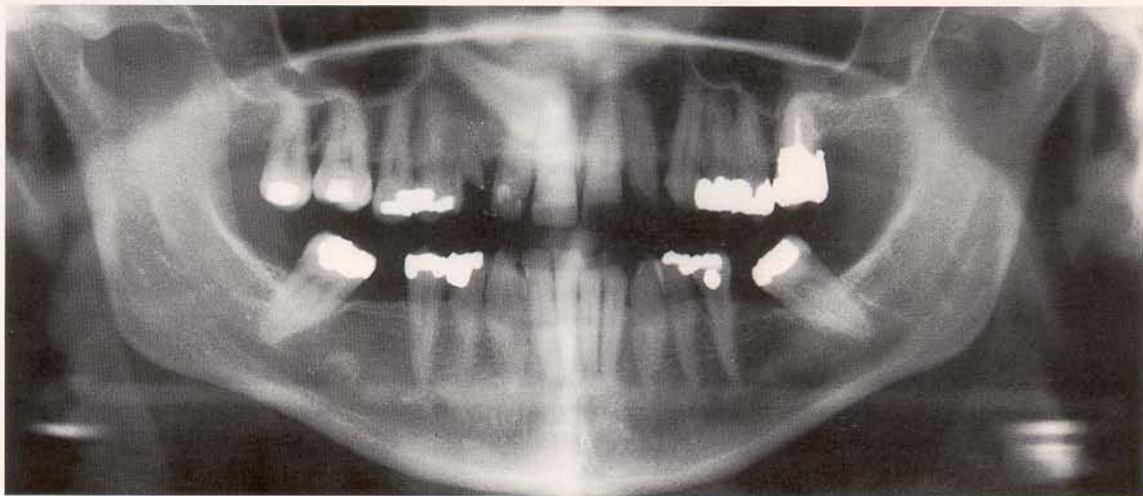
230 Palatal position of tooth 23, viewed in the panoramic radiograph

A comparison of the size of tooth 23 with the reference object (tooth 13), which is aligned within the dentition clearly reveals the slight enlargement of the crown and the root, indicating a greater object-film distance.




231 Palatal position of tooth 13 as seen in the panoramic radiograph

Tooth 13 is not sharply depicted and its crown appears greatly enlarged, indicating that tooth 13 is impacted palatally at great distance from tooth 11 and its root tip is located high and ventrally in the canine fossa.



232 Diagram of the apparent variation of shape of impacted maxillary canines, as seen in the panoramic radiograph

The incisors or the normally developed canine (0) of the contralateral side serve as reference objects and are shown sharply and of normal size when in the image layer (L). If the impacted tooth is located buccally, it appears out of focus and reduced in size (1). If all or part of the impacted tooth is located palatally (2 or 3), it will appear blurred, and part of it will appear enlarged (distant from the film). F = plane of the film.

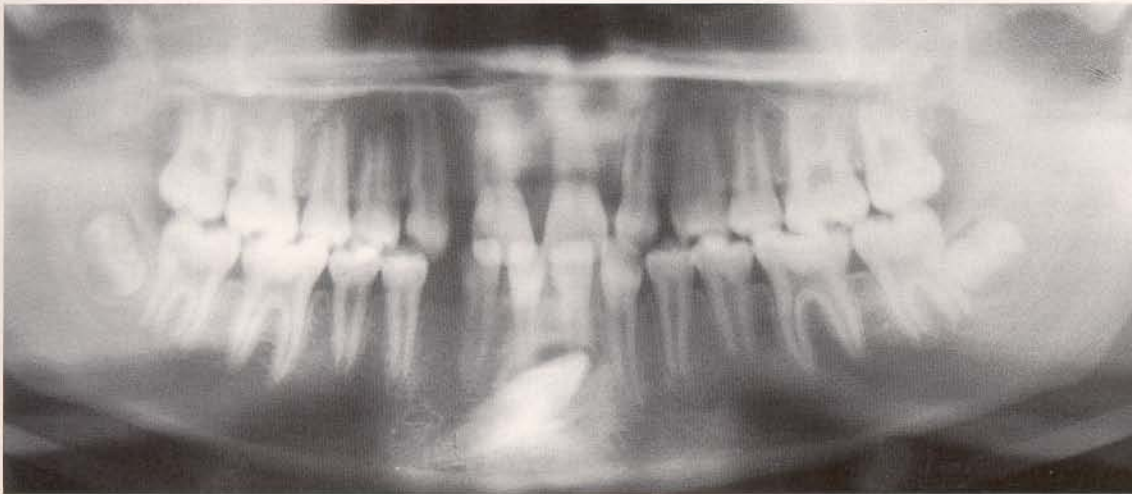


Special Localization Problems

Buccally Impacted Mandibular Canine

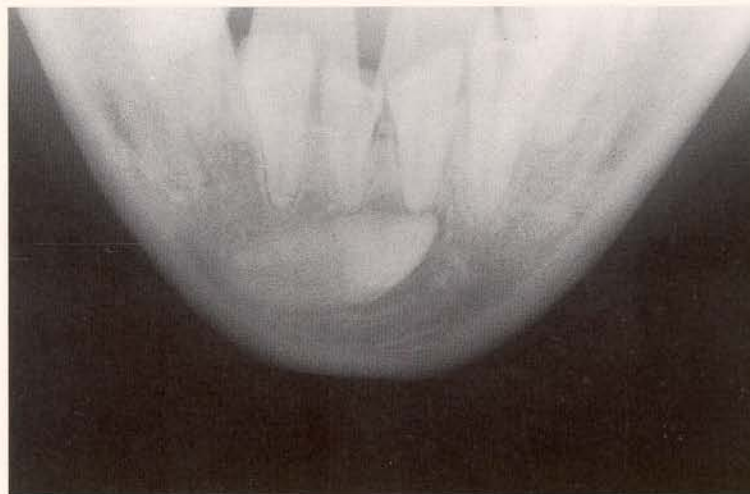Whenever panoramic radiographs must be supplemented with occlusal films for purposes of localization, one should attempt to project the group of teeth in question axially. If this is not possible for anatomic or technical reasons, the panoramic radiograph must be

supplemented with appropriate periapical radiographs or skull films. Often success is achieved only after numerous projections; such additional radiographs must be planned, however, and carried out in a logical sequence.



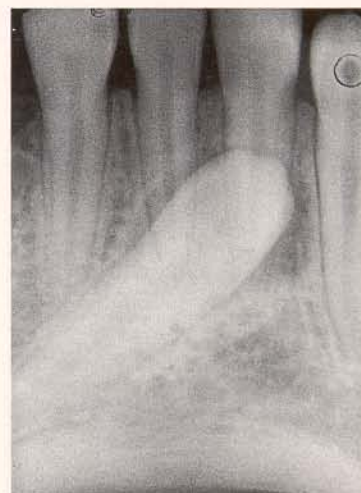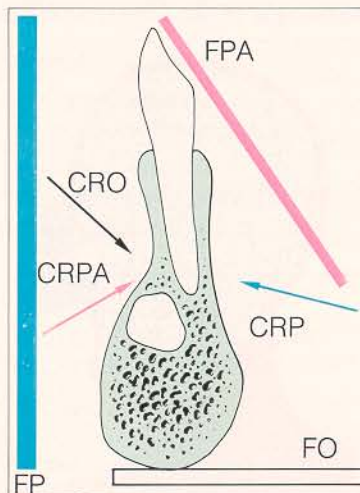
233 Section from a panoramic radiograph of a 13-year-old female

In addition to the congenitally missing teeth 18, 12, 21 and 33, this film reveals that tooth 43 is impacted, apparently in a buccal location; it appears superimposed on the root tips of teeth 41 and 31. This projection does not allow precise localization of the impacted tooth because it appears enlarged as a result of the axial rotation and therefore simulates a lingual position (large object-film distance).



234 Occlusal radiograph (taken with less than true axial projection)

This film shows clearly the position of the buccally impacted canine. It obviously resides ventral to the root tips of teeth 42, 41, and 31.



235 Periapical radiograph and projection diagram

- CRP** = central ray, panoramic radiograph
- FP** = plane of film, panoramic radiograph
- CRO** = central ray, occlusal projection
- FO** = plane of film, occlusal projection
- CRPA** = central ray, periapical projection
- FPA** = plane of film, periapical projection

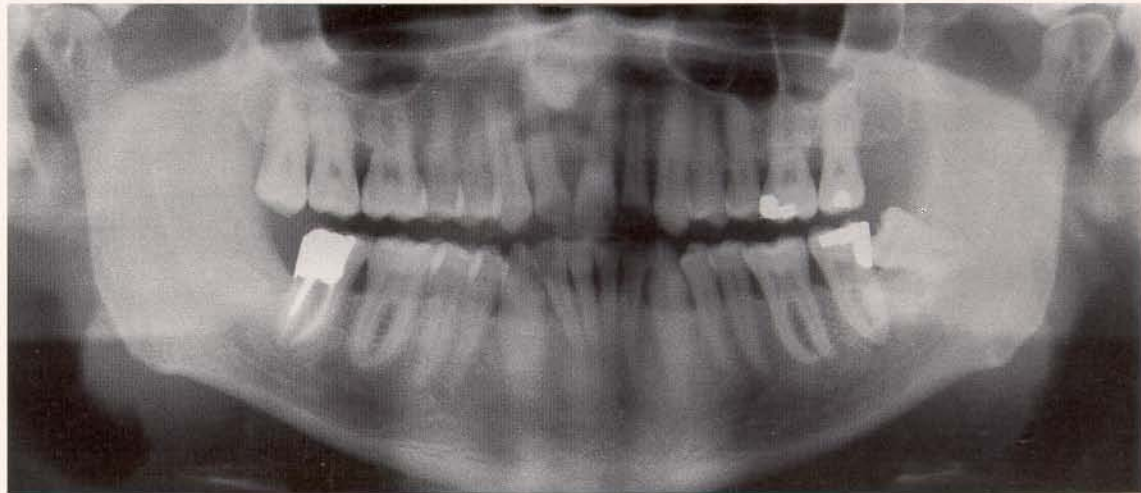
Ectopically Positioned Anterior Teeth

Whenever any individual tooth is missing (count the teeth!) or when crowns of teeth appear tipped or abnormally spaced, an absolute indication exists for a radiograph that can provide an overview, to ascertain any abnormalities of tooth development or pathological processes in the jaws as early as possible. A timely

and complete radiographic examination may help to prevent later additional radiation exposure and complex therapy. In addition to panoramic radiography, in the maxilla extraoral radiographs using the occlusal film are helpful, as are skull films (e.g., lateral cephalometric radiographs).

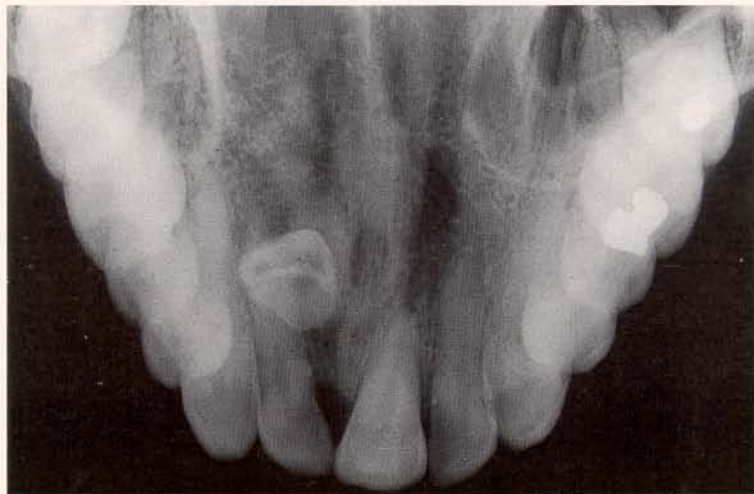
236 Panoramic radiograph of a 46-year-old female

This film reveals only a vague radiopacity with the approximate density of tooth substance adjacent to the anterior nasal spine. Careful examination reveals that tooth 11 is missing!



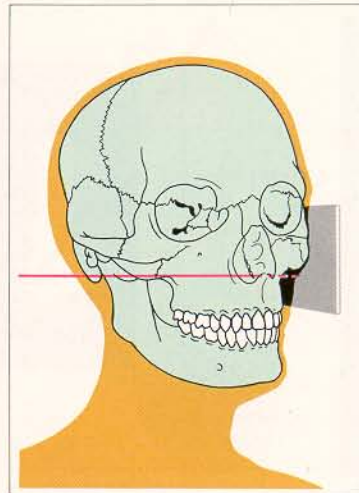
237 Occlusal radiograph

This film reveals that the missing tooth 11 was shown in the panoramic and occlusal radiographs axially and with an enlarged crown, indicating that it is distant from the film plane. This is easy to understand when one appreciates the actual position of the crown, the central ray projection and the film position.



238 The lateral occlusal exposure (used extraorally) provides the definitive information

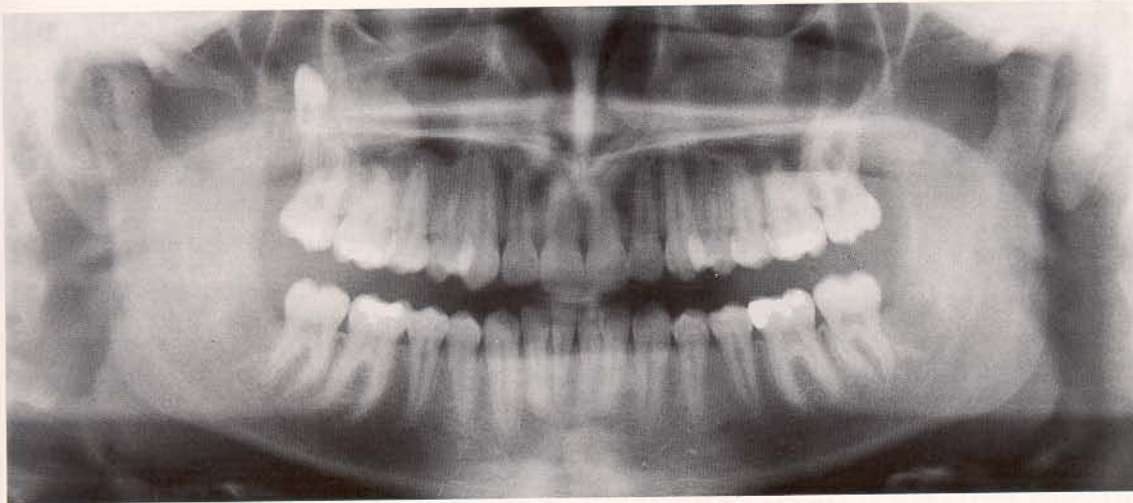
The tooth crown of 11 is clearly depicted in its ectopic position superimposed on the distended anterior nasal spine. The diagram illustrates the central ray projection and the film positioning on the patient (see also p. 68).



Apically Displaced Maxillary Third Molars

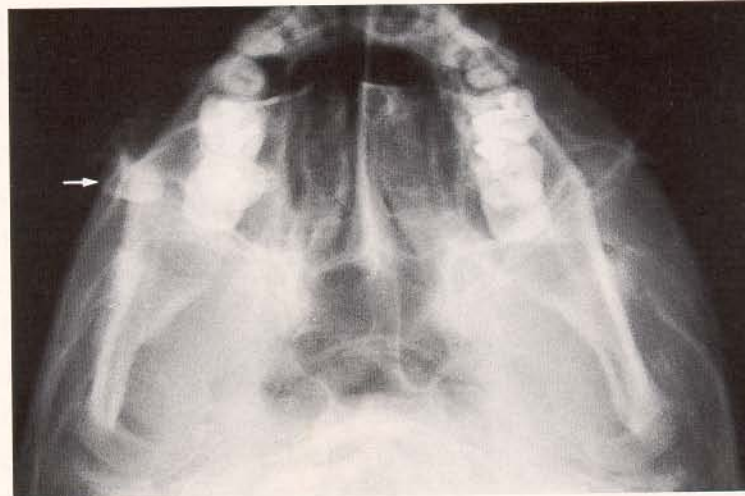
The success of dental caries prophylaxis as well as the rather universal concern about radiation exposure have led to a situation in which young patients today are examined only sporadically using bite-wing radiographs. Because even a perfectly prepared full series of radiographs often cannot portray wisdom teeth that are

abnormally positioned, panoramic radiography may provide the only means to detect such teeth. As demonstrated by the following example, however, panoramic films are not sufficient to localize apically positioned third molars precisely; supplemental skull films must be employed.



239 Panoramic radiograph of an 18-year-old female

This film reveals the high apical displacement of impacted tooth with a follicular cyst. However, this interpretation is not sufficient to ascertain the precise location of the tooth in the third dimension.



240 Axial skull radiograph of the same patient

This film provides information about the actual location of the tooth in the third dimension. Not only does the tooth reside high in the maxillary tuberosity, but it is also displaced lateral to tooth 17 (arrow). See p. 113 for this radiographic technique.

The following localization techniques are recommended to supplement a panoramic radiograph:

Region	Mandible	Maxilla
Impacted anterior teeth (including maxillary mesiodens)	<ul style="list-style-type: none"> ● Clark, horizontal ● compare size and focus 	<ul style="list-style-type: none"> ● Clark, horizontal and vertical ● lateral extraoral occlusal
Impacted canines	<ul style="list-style-type: none"> ● Clark, horizontal ● compare size and focus ● axial occlusal film 	<ul style="list-style-type: none"> ● Clark, horizontal and vertical
Impacted premolars	<ul style="list-style-type: none"> ● Clark, horizontal ● axial unilateral occlusal film 	<ul style="list-style-type: none"> ● Clark, horizontal
Impacted molars	<ul style="list-style-type: none"> ● axial unilateral occlusal film ● Clark, horizontal 	<ul style="list-style-type: none"> ● Clark, horizontal
Impacted third molars	<ul style="list-style-type: none"> ● Clark, horizontal ● axial occlusal film ● reverse Towne with maximum jaw opening ● CT 	<ul style="list-style-type: none"> ● reverse Towne with maximum jaw opening ● lateral skull film ● axial skull film ● CT

We recommend against using an occlusal film alone in the maxilla; skull radiographs are absolutely indicated if impacted teeth are located ectopically in any region of the maxilla.

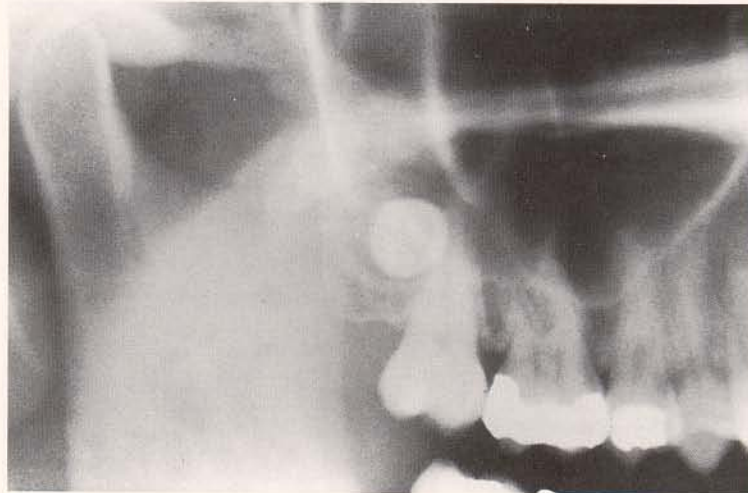
“Axial” Presentation of Maxillary Third Molars

In addition to axial skull films and lateral cephalometric radiographs, one of the most important techniques to supplement a panoramic film is the posteroanterior mandibular radiograph (reverse Towne) with maximum jaw opening (p. 117). Third molars impacted in unusual locations as well as supernumerary molars in both maxilla and mandible can also be depicted well using the

reverse Towne projection. With regard to the surgical procedures that may be undertaken on the basis of radiographic findings, the dangers that can result from a cursory interpretation of a single two-dimensional radiograph must not be underestimated. If expansive follicular cysts are present, computed tomography is indicated.

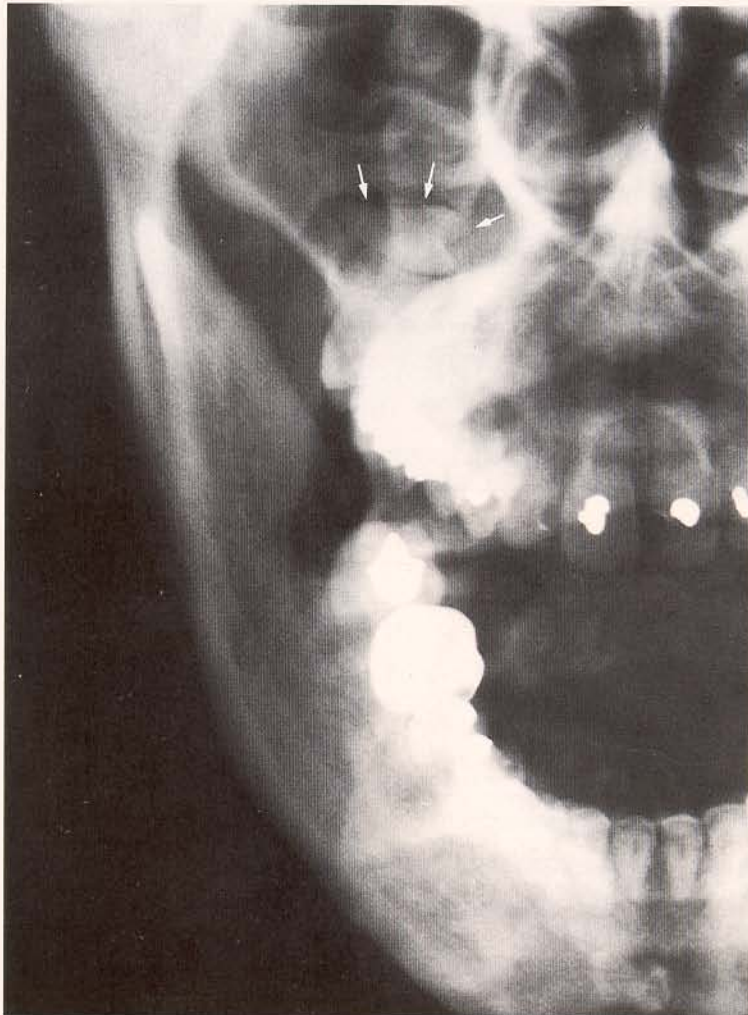
241 Section from the panoramic radiograph of a 25-year-old female

This view suggests that tooth 18 is impacted in an extreme apical location, and that the central ray encountered this tooth axially. As shown in the figure below, however, this is an incorrect interpretation.



242 Section from a posteroanterior mandibular radiograph

Same patient. This film reveals tooth 18 in its actual location (arrows). It is positioned obliquely, with its crown oriented medially on the floor of the posterior recess of the right maxillary sinus.



Errors in Technique that Reduce Radiograph Quality

Retaking radiographs exposes the patient to unnecessary additional radiation. Therefore extreme care should be exercised in every case to avoid errors that compromise high quality interpretable radiographic documentation. Every patient has the right to expect proper use of modern radiographic methods that guarantee minimum X-ray exposure. Inadequate knowledge or experience is an unacceptable excuse for utilizing radiographic examination as an experimental exercise. Taking a perfect dental radiograph is not comparable to “instant photography,” rather it is demanding and requires time. Radiographs taken under constraints of time are often of poor quality. Personnel charged with taking radiographs must follow directions from their superiors and comply with all regulations concerning protection from radiation; on the other hand, the dentist must provide precise instructions for taking radiographs and must supervise their realization with responsibility and competency.

With regard to *panoramic radiography*, the most common errors may be traced to positioning, first of all positioning of the patient in the apparatus and secondly positioning of the patient's head. With older units it is also possible to affix the film cassette improperly. Movement of the head or the mandible during exposure can lead to films that invite incorrect interpretation; it is for this reason that patients must be instructed before films are taken and observed during the exposure. Foreign bodies such as jewelry or a carelessly placed lead apron will lead to excessive radiation exposure if the film must be retaken; it may lead to incorrect interpretation. It is very important for perfect depiction of the maxilla that the patient press the tongue against the palate during the entire radiographic exposure; this has already been described in the section on radiographic techniques. This tongue placement, unusual for most patients, should be practiced before positioning the patient in the apparatus. Dental prostheses, especially metal partial dentures, may be either removed or allowed to remain in the patient's mouth, depending upon the indication, for example to clarify a temporomandibular joint disturbance or to evaluate traumatic impact. Similarly, full dentures are usually left in situ for radiographic depiction of the alveolar ridge of edentulous patients; this makes use of the filtering effect of prosthesis materials.

During the preparation of *periapical radiographs*, careless placement or bending of the film packet and incorrect projection of the central ray in both vertical and horizontal angles represent the most common sources of error. It is therefore highly recommended that an appropriate film holder be used to provide reproducibility and to enhance patient comfort.

Errors related to radiograph exposure time are actually less common today than is usually assumed, because of the automatic exposure devices on modern apparatus.

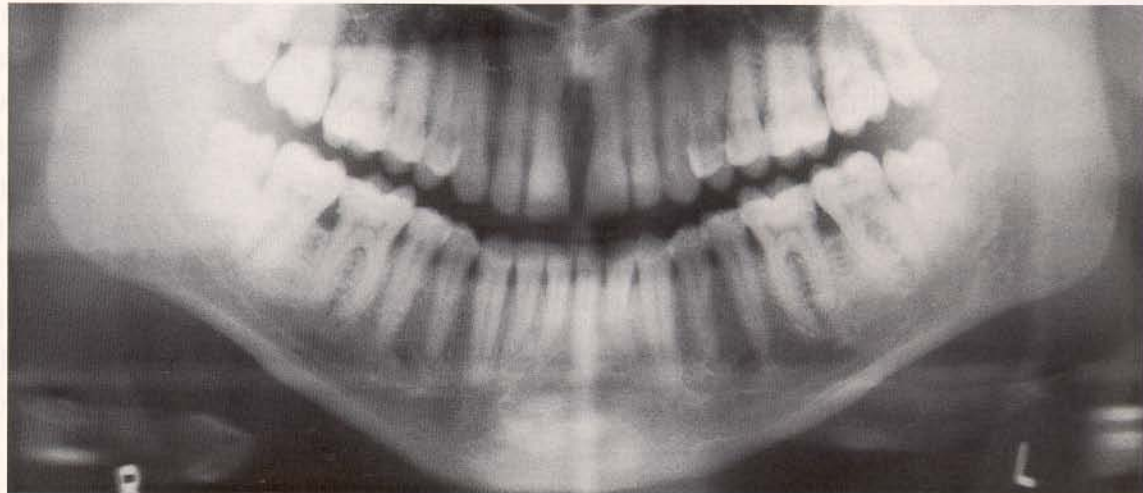
Tips for Preparation of Perfect Panoramic Radiographs

Before Positioning the Patient in the Apparatus

- Take the time to explain the apparatus and the film cassette rotation to the patient
- Set the appropriate exposure data
- Have the patient remove all jewelry from ears, hair and neck
- Demonstrate the bite holder for the patient; he or she should practice biting in centric relation
- Have the patient practice proper tongue position
- Depending upon the indication, either remove the patient's prostheses or leave them in situ
- Apply the protective lead apron to the patient
- Utilize appropriate barrier techniques

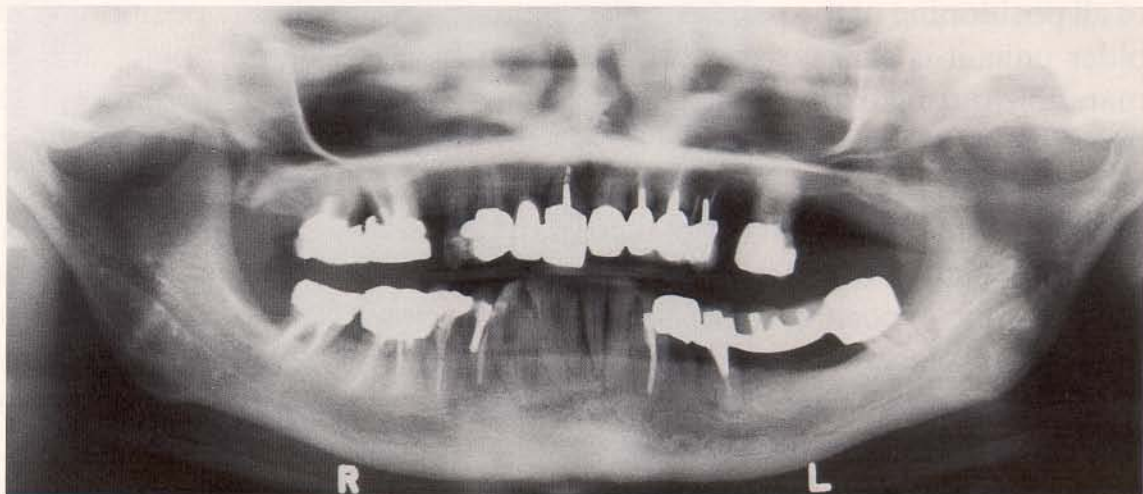
243 Improper positioning of the patient: Head tipped too far forward

Note the superimposition effects in the premolar regions of the maxilla. The temporomandibular joints are projected completely out of the film.



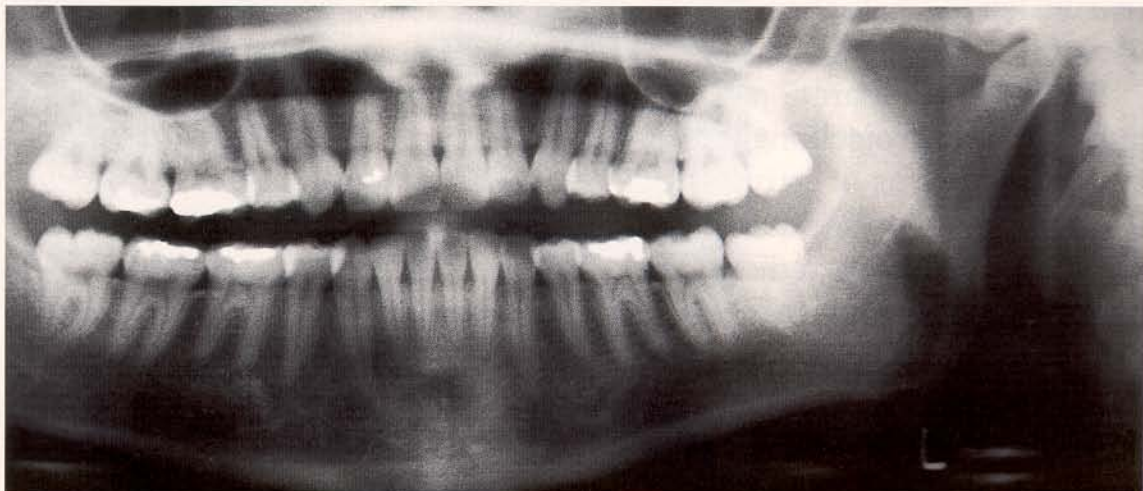
244 Improper positioning: Head tipped too far back

Note the superimposition on the maxillary alveolar process by structures of the floor of the nose and the palatal roof. The temporomandibular joints are projected far laterally.



245 Old equipment

When using older equipment, the film cassette must be placed precisely in the initial position before positioning the patient in the apparatus to preclude loss of important radiographic information. Failure to do so will result in the necessity to retake the radiograph, and therefore to additional radiation exposure for the patient.

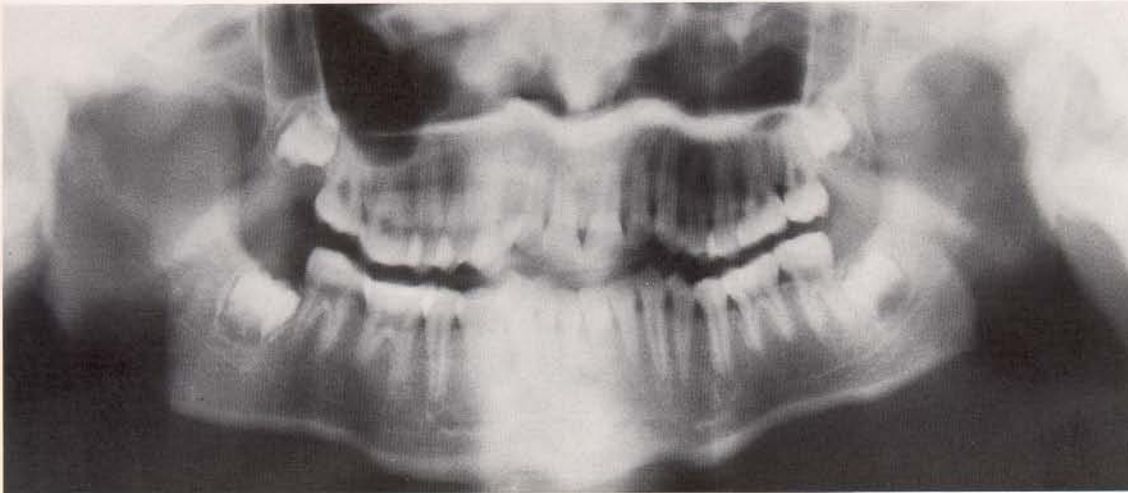


With the Patient in the Apparatus

The technician should position and check for:

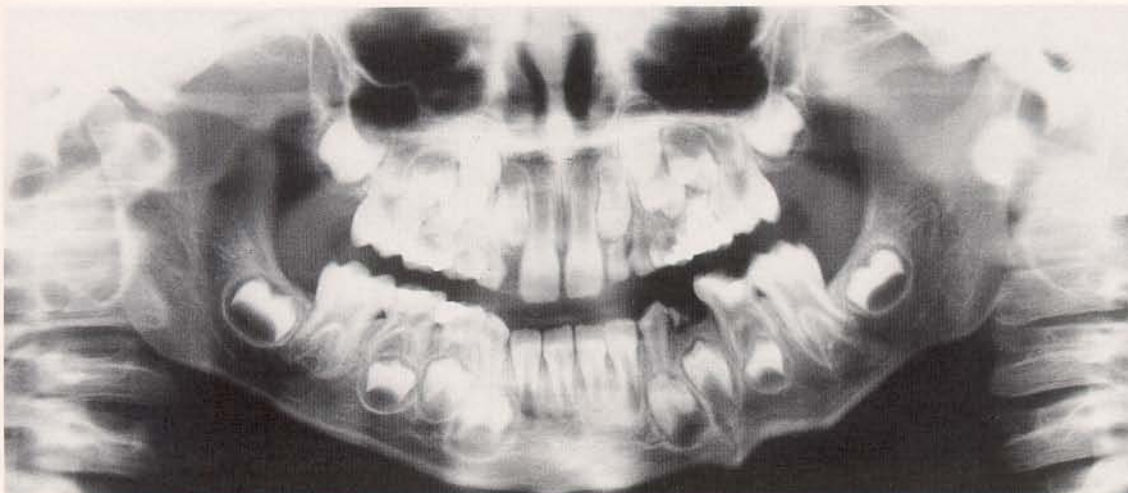
- Body position
- Head position
- Positioning of the image layer using the collimator
- Occlusal plane (depending upon indication)
- Position of the protective lead apron (from behind)

- Setting of the median saggital plane using the collimator
- Median saggital plane (from behind)
- Final check
- Ask patient to continue shallow breathing
- Exposure



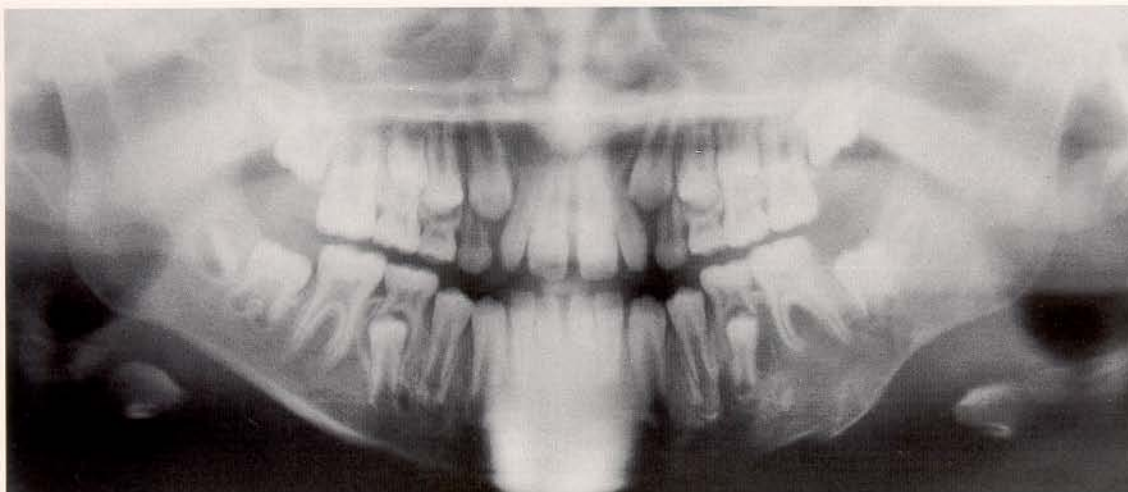
246 Movement of the head during the exposure

Apparent deformation of both maxilla and mandible at the same location because the narrow slit diaphragm creates vertical tracks in the same direction of movement.



247 Movement of the mandible during the exposure

This movement has created typical deviations from the norm (compare with the body of the mandible, right), limited to the mandible.



248 Movement of the mandible during the exposure

This postoperative follow-up radiograph reveals a step in the thinned cortical bone on the left side that suggests a spontaneous fracture.

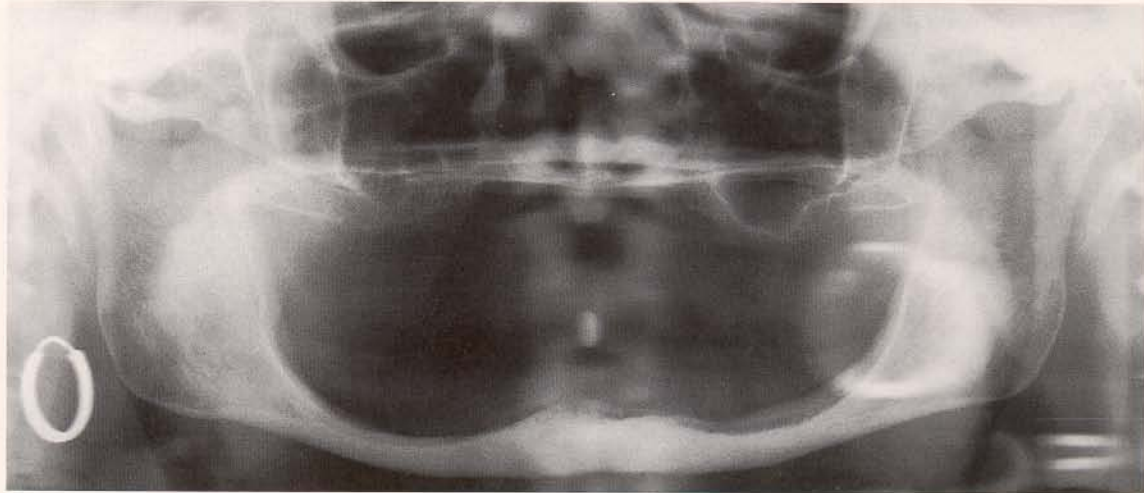Tips for Preparation of Perfect Radiographs

Before Exposing the Film

- Set the exposure data appropriately
- Explain the procedure to the patient
- Ask the patient to remove eyeglasses, jewelry and prostheses
- Wash hands and put on rubber gloves in view of the patient
- Take time to position the film, noting any sensitivity of the patient
- Apply topical anesthetic as required
- Ask the patient to breathe through the nose (shallow breathing)

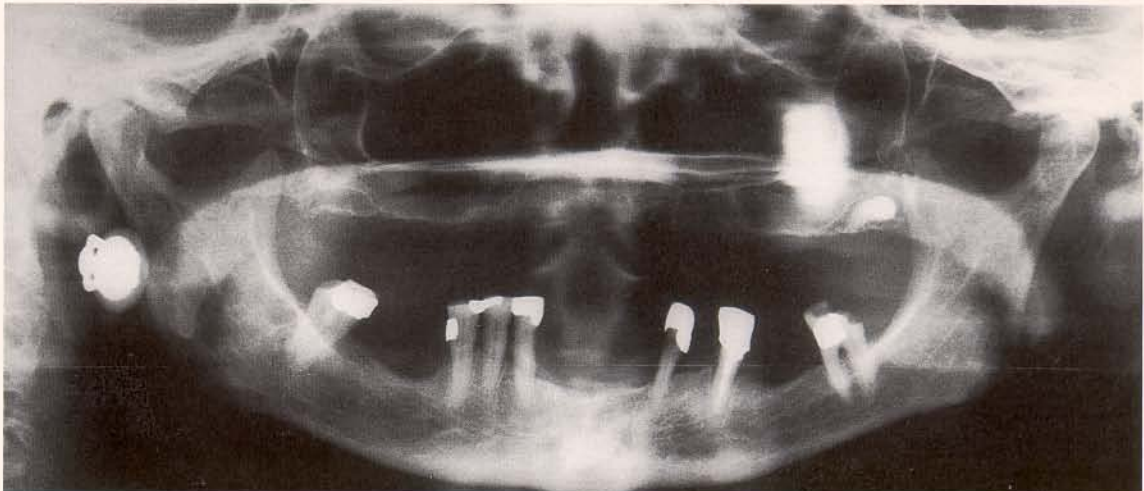
249 Foreign body

The earring that was left in place on the right earlobe during radiographic exposure created a blurred, enlarged ring of radiopacity at the left angle of the mandible. With the typical X-ray projection, this artefact was projected superiorly.



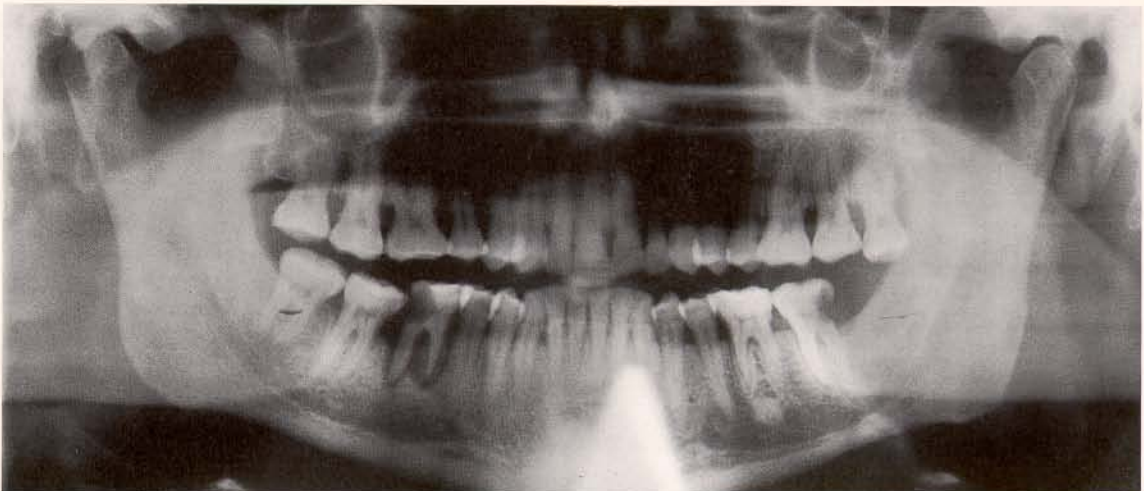250 Foreign body

The metal jewelry in the right earlobe created in the tuberosity region of the left maxilla a blurred, enlarged and somewhat more superiorly located radiopacity. Incorrect interpretation of such a radiographic appearance could result.



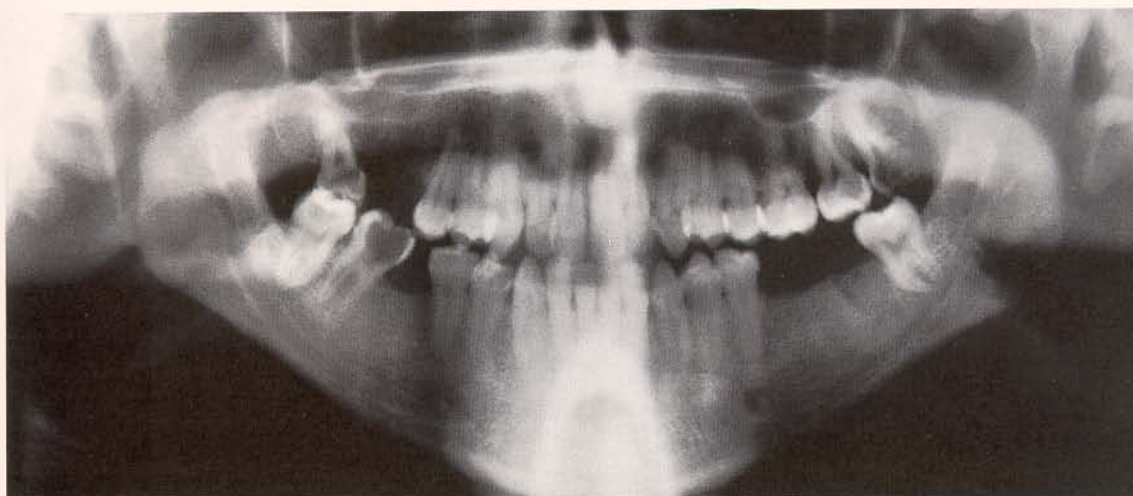
251 Foreign body

The protective lead apron was not carefully positioned and created a dense, typical radiopacity. This usually is observed in the apical region of the mandibular anterior teeth.

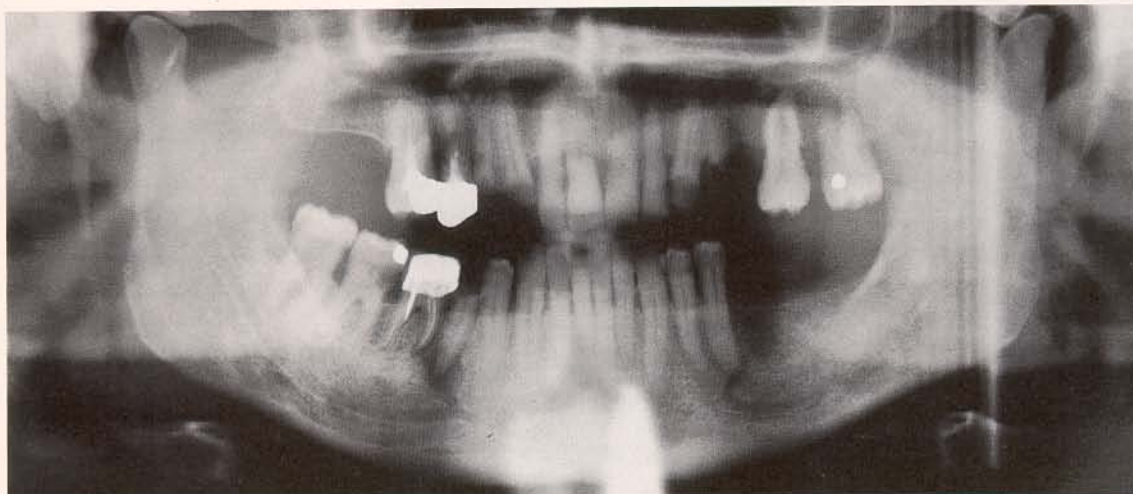


Immediately Before Exposure

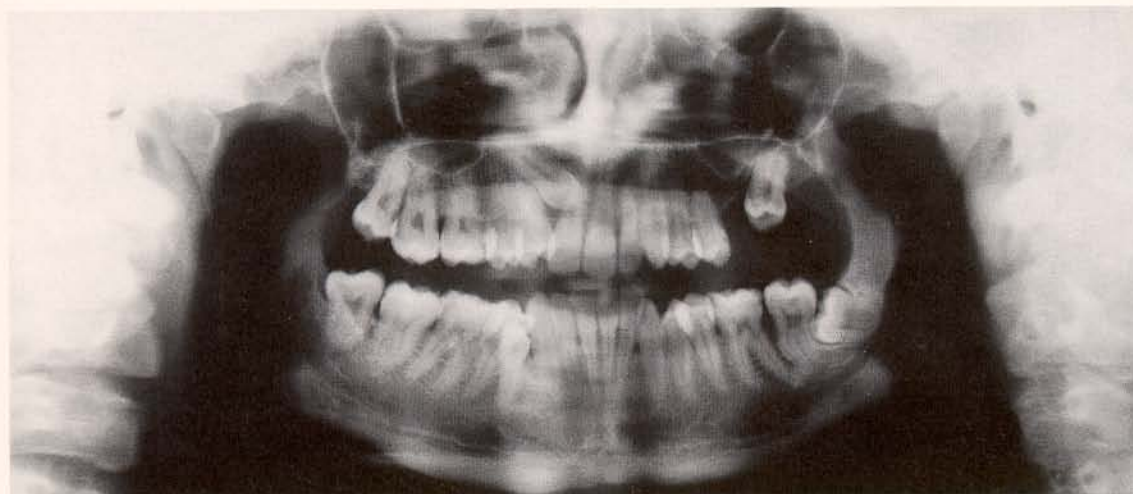- Position the patient's head appropriately
- Insert and position the film packet in the available space and without bending
- Utilize cotton rolls or, better, a film holder
- After film placement and immediately before exposure, ask the patient to close slightly—the patient will relax
- Recheck head position
- Target the X-ray tube onto the object, also when using a film holder
- Exposure



252 Napkin chain
The chain holding the patient's napkin may appear on the film and make interpretation difficult. It must therefore be removed before exposing the film. Similarly, if the patient is wearing clothing with a zipper at the neck, it should be opened before the exposure.



253 Carelessly placed protective apron
In elderly patients with kyphosis, this often leads to interference with the film cassette movement, which causes jerky movement of the X-ray source. This results in a striped exposure of the film (*left*).



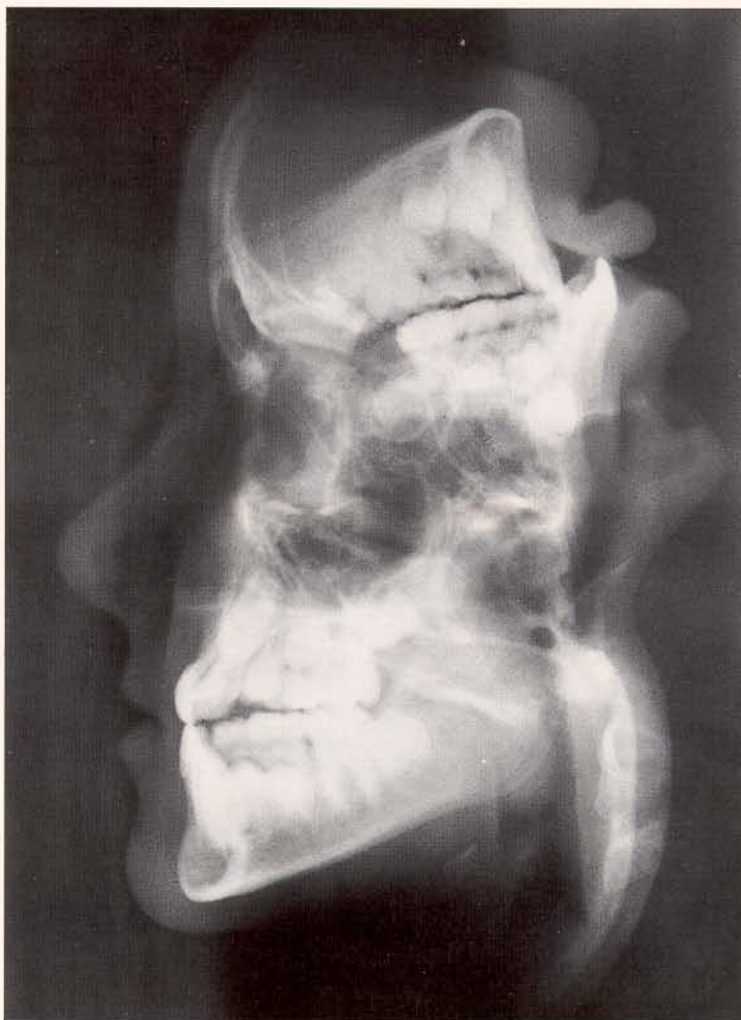254 The patient's breathing should be shallow during the exposure
In this picture, one sees the impressive subtraction effect that results from air, which serves as a negative contrast medium on the ascending mandibular rami if the patient holds his or her breath and presses against the closed palatal vault.

Summary of Basic Rules for Preparation of High Quality Radiographs

- Patients are human beings, not experimental objects
- Set clear indications for the procedure
- Proceed according to accepted radiographic techniques
- Never take radiographs under pressure of time
- Adhere to the highest standards of organization and cleanliness during preparation

255 Double exposure of film cassettes

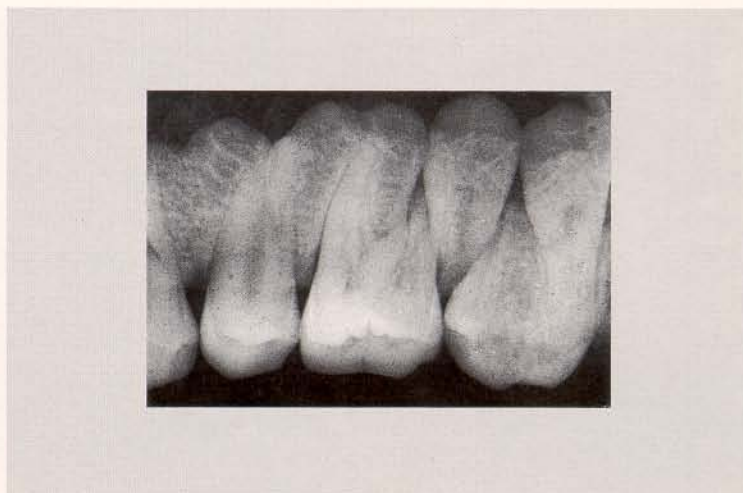
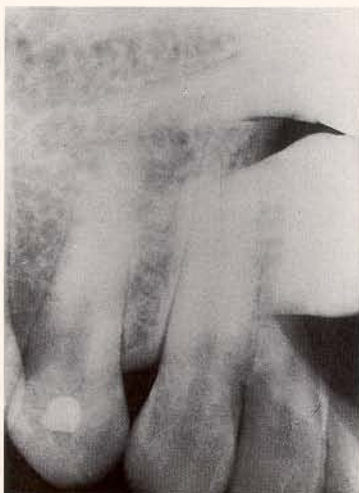If an exposed film cassette (in this case a lateral cephalometric exposure) is not carefully marked as "exposed" or if it is not immediately developed, the danger of a double exposure exists.



Note: Develop immediately or, better, immediately mark "exposed."

256 Double exposure of dental films

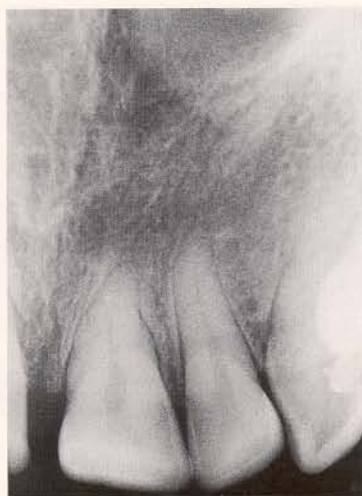Casual storage of exposed dental films may lead to mix-ups. Physicians, dentists, and auxiliary personnel must expose their patients to the minimum possible ionizing radiation. Inherent in this obligation is the avoidance of repeating radiographs due to carelessness.



Common Errors During Preparation of Periapical Radiographs

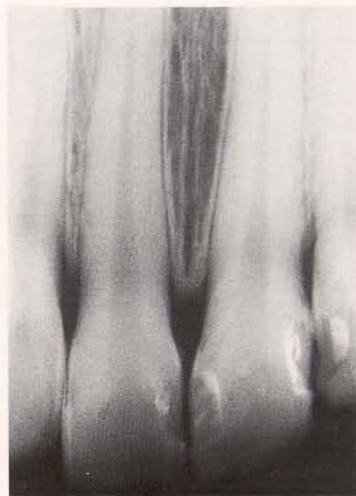One very common error results from film packets that are bent during or before placement in the oral cavity. Another involves incorrect projection of the central ray, which may be either too flat or too steep, or which may be eccentrically rather than orthoradially targeted upon

the object. Periapical radiographs must be considered as projection *planes*, and therefore should not be bent. The projection of the central ray in both vertical and horizontal angles must be carefully adjusted. Whenever possible, appropriate film holders should be employed.



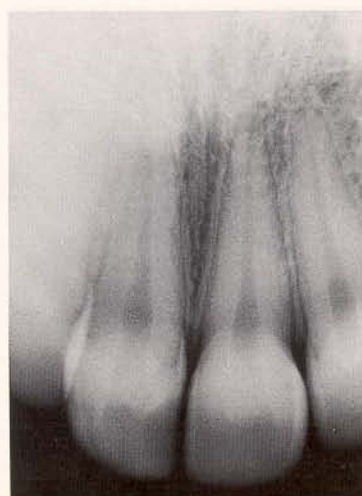257 Unacceptable radiograph

The film packet was pressed against the palate with a finger, and was bent. In addition, the central ray projection was too steep.



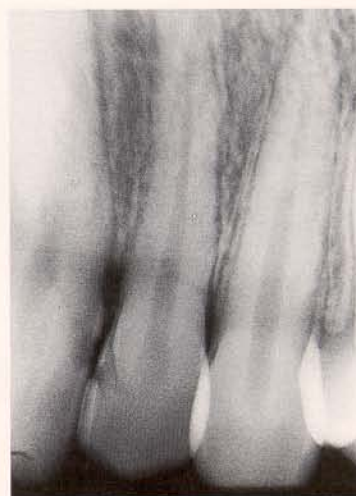258 Unacceptable radiograph

This film packet was held with a finger, and was bent. In addition, the central ray projection was too flat.



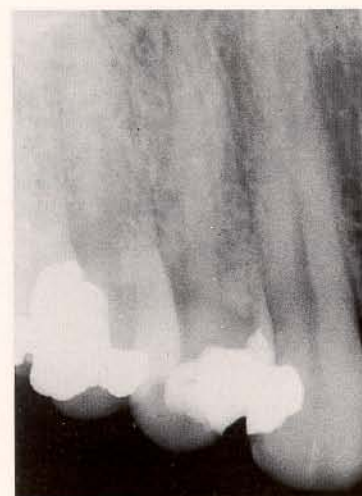259 Unacceptable radiograph

The film packet was bent axially between teeth 11 and 12.



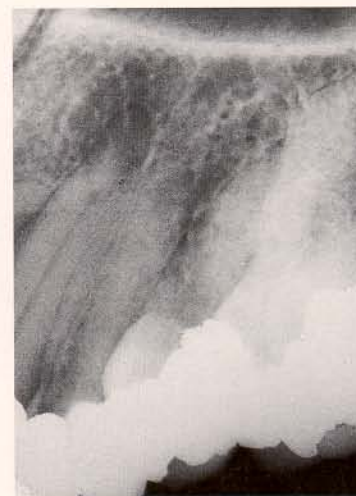260 Unacceptable radiograph

The mesial edge of this film packet was bent.



261 Unacceptable radiograph

This group of teeth was targeted with the central ray too far mesial.



262 Unacceptable radiograph

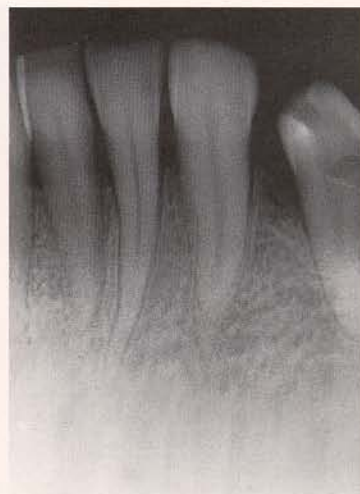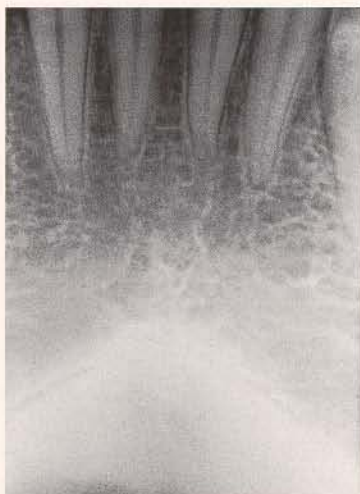The central ray projection was too steep and also eccentrically mesial.

On this page we will continue with the topic of distorted or otherwise bent films, to demonstrate additional typical mistakes of this type. Use of a film holder that ensures the “right-angle technique” completely obviates such errors. Figure 267 depicts a somewhat suspect positioning aid: In this case, the patient was asked to

position the periapical film using thumb and forefinger of the right hand. Radiographs of anterior teeth may be overexposed if the overworked technician forgets to change the exposure data from previously exposed molar radiographs.

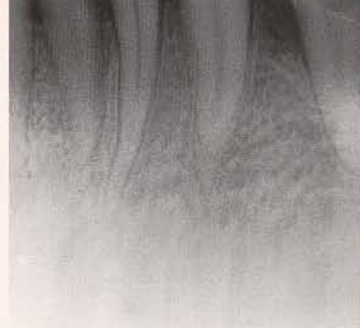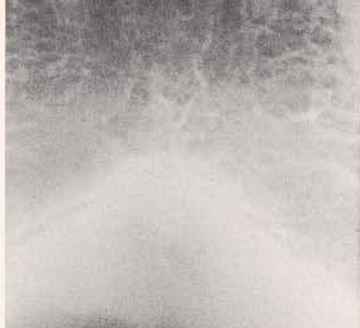263 Unacceptable radiograph

The film was bent at the floor of the mouth and the central ray was targeted too steeply.



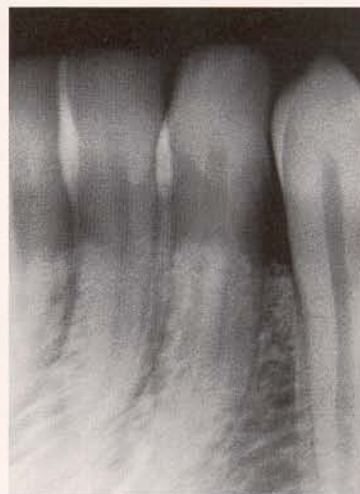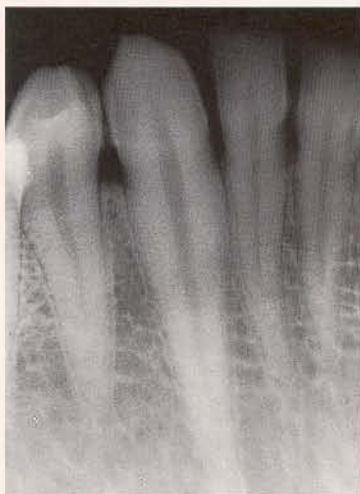264 Unacceptable radiograph

The film packet was bent at the floor of the mouth, resulting in a typical “washed out” appearance.



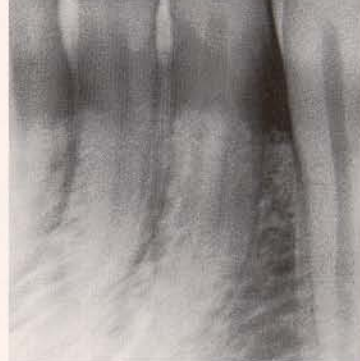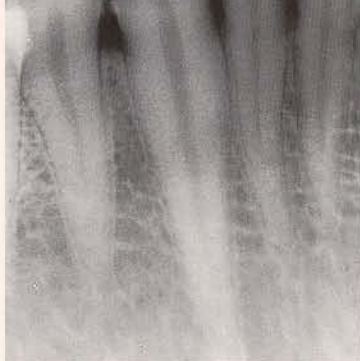265 Unacceptable radiograph

Film packet was bent at the floor of the mouth, resulting in oblique projection of the roots.



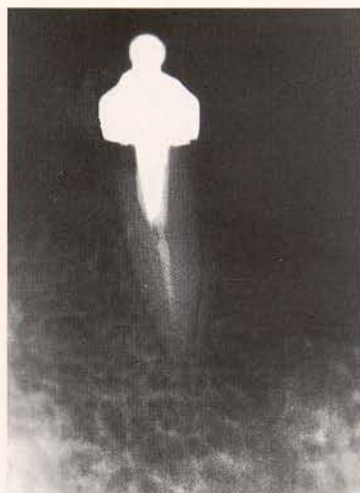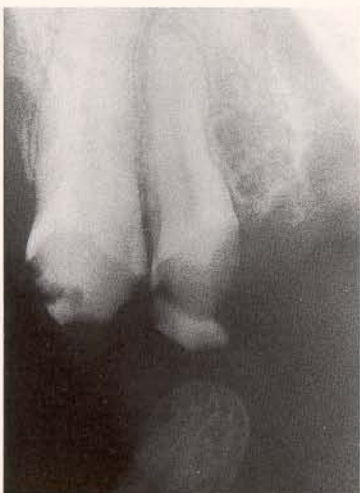266 Unacceptable radiograph

The film packet was bent mesially at the floor of the mouth, resulting in distortions.



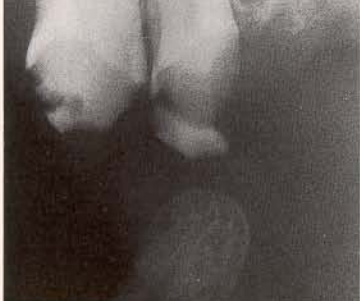267 Unacceptable radiograph

The film packet was held between thumb and forefinger of the right hand. The tip of the index finger can be seen at the bottom of this picture.



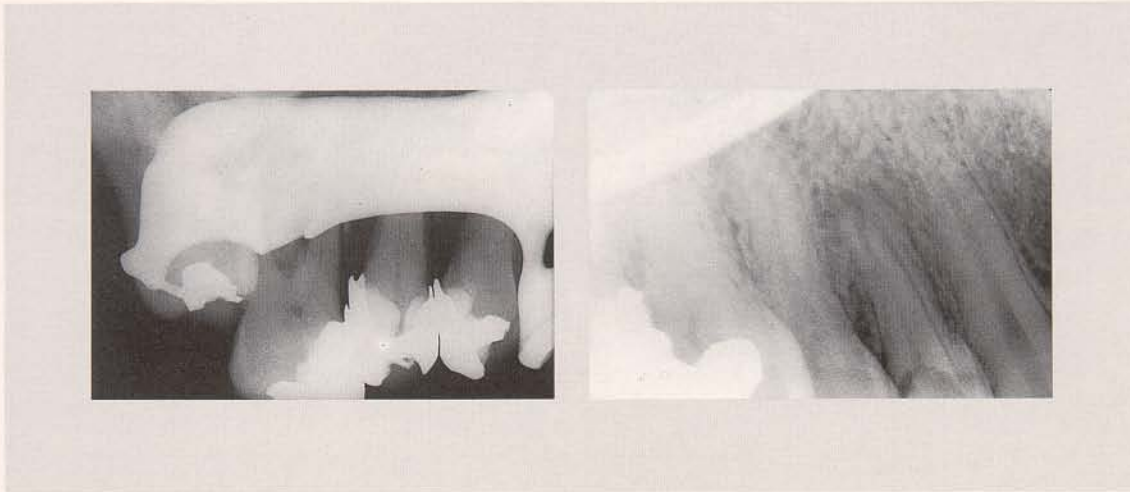
268 Unacceptable radiograph

Overexposed periapical film.



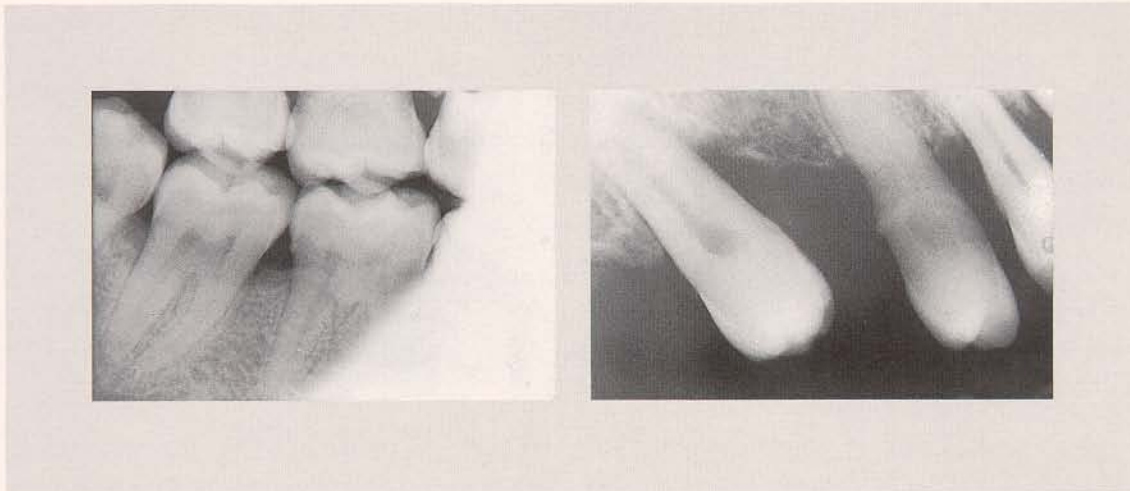
Patients should always remove eyeglasses and prostheses when periapical radiographs are taken. If the diaphragm of the X-ray tube is visible in the radiograph, it is an indication that the central ray has been either eccentrically directed onto the film, or not at all. The preparation of radiographs may be compared with a "shadow game" in which the shadows only become visible after the films are developed. It is obligatory that

in every case the object be "cast" onto the film via the X-ray beam. Film holders are particularly helpful. Film packets that are exposed in the reversed position yield underexposed films and also exhibit the gridwork characteristic of the lead foil. Improper use of the timing device can lead to either overexposure or underexposure.



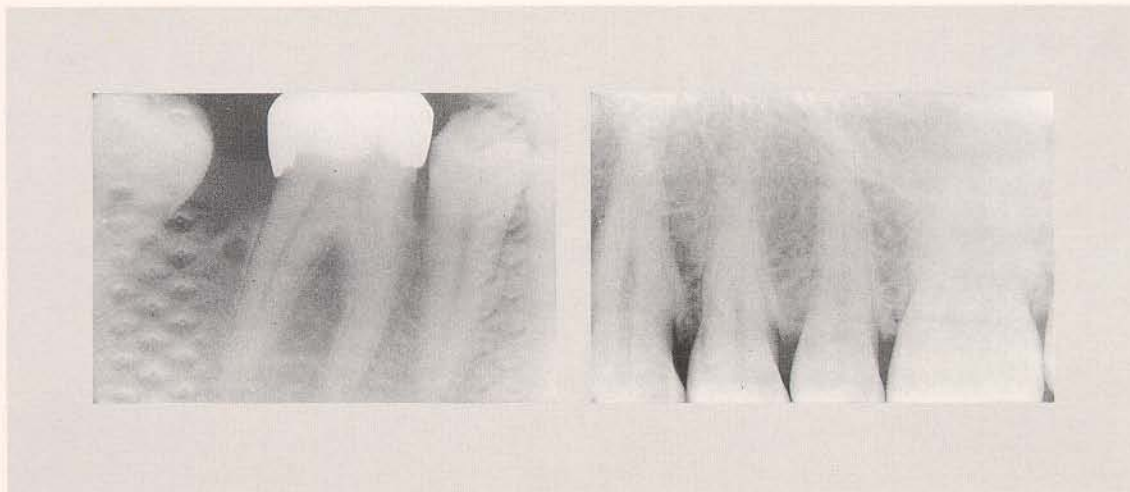
269 Unacceptable radiograph
This patient's partial denture was not removed.

270 Unacceptable radiograph
The patient's metal-framed eyeglasses were not removed.



271 Unacceptable radiograph
Improper targeting of the central ray produced this "cone cut."

272 Unacceptable radiograph
Improper targeting of the central ray; the root tips are not visible in the radiograph.



273 Unacceptable radiograph
The film packet was placed backwards. The gridwork of the lead foil is visible in the radiograph.

274 Unacceptable radiograph
Underexposure.

The X-ray beam must project the targeted objects onto the film; it is for this reason that the free-hand adjustment of the central ray and the proper positioning of the film are of particular importance. Use of appropriate film holders permits the technician to concentrate on the targeting of the object. Warping or bending the plane of the film packet should be strictly avoided. The film

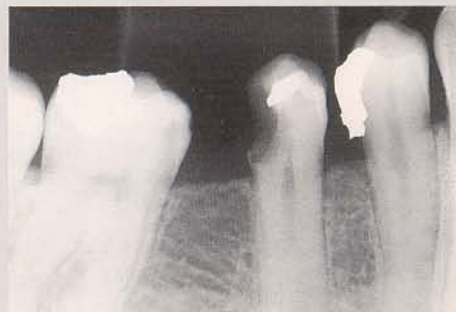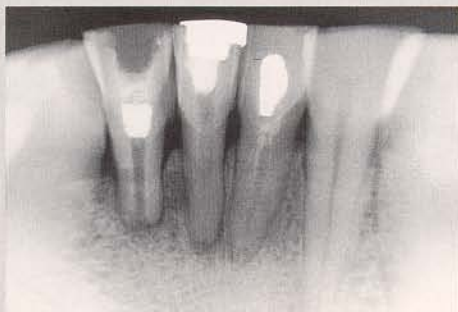should always be positioned (with or without a film holder) in a position where adequate space is available to permit placement of the film without bending. In the anterior region periapical films should always be used vertically, and in the posterior segment in the oblong format.

275 Unacceptable radiograph

The thumb was used to hold this incorrectly positioned film.

276 Unacceptable radiograph

The incorrectly placed film and incorrect targeting of the central ray prevented depiction of the root tips.

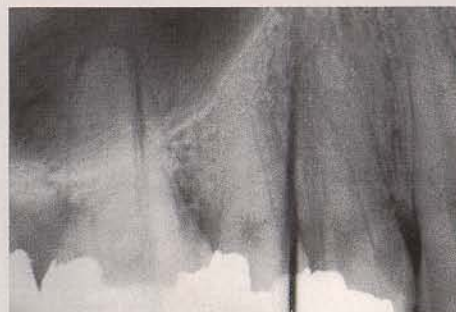

277 Unacceptable radiograph

This molar film was taken with an excessive vertical angle.

278 Unacceptable radiograph

This film was bent before exposure.

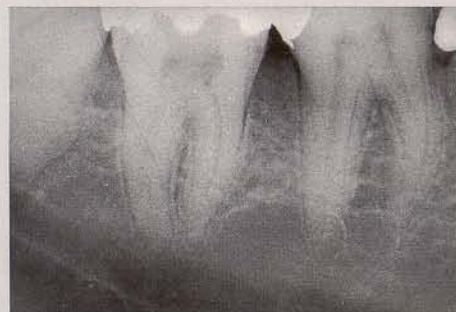

279 Unacceptable radiograph

This radiograph was taken with an excessively flat projection angle. Suspected diagnosis: cyst.

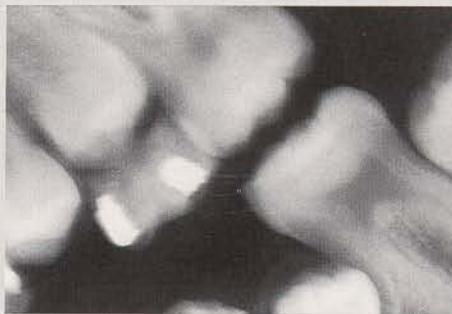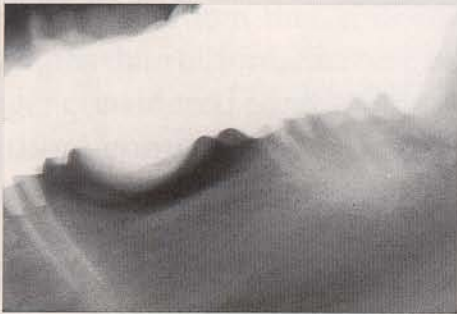280 Correctly prepared radiograph of the situation in Figure 279

In this film, the apical region is clearly shown, and exhibits no hint of a cyst.



In the mandible, film packets held by the patient are often moved before exposure because of involuntary swallowing, uncomfortable film position or poor stability. In such cases, a film holder helps the patient to relax, maintains the film packet in the proper location, and gives the technician enough time to check everything

before exposure. Without a film holder, the tuberosity region is often targeted from too high an angle because the film is positioned too flatly. Radiographs taken in this way often superimpose the zygomatic bone onto molar teeth.

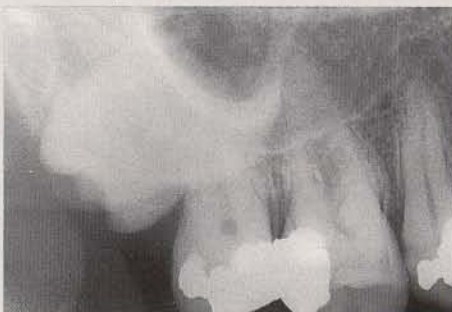
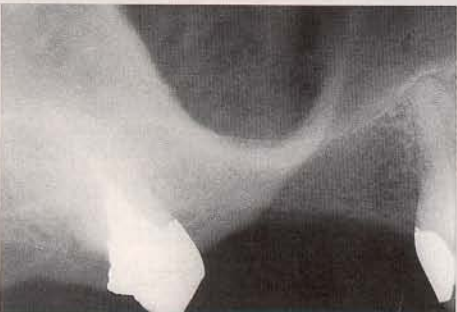

281 Unacceptable radiograph

The film was moved during the exposure because the patient swallowed.

282 Unacceptable radiograph

This bite-wing film was moved during the exposure.

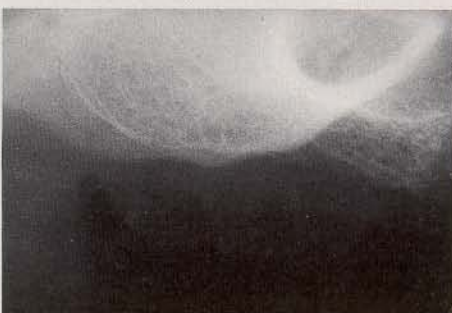
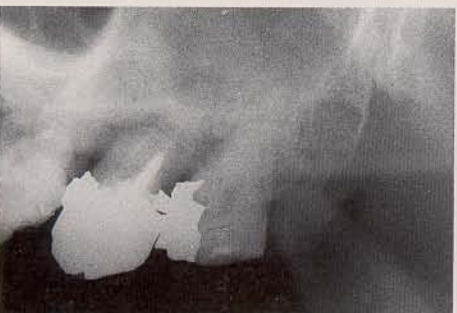
283 Unacceptable radiograph

This film of the maxillary molar region was taken with an excessively steep projection angle.

284 Unacceptable radiograph

In this radiograph, the maxillary molar region was depicted with an excessively high projection angle, the result being superimposition of the zygomatic bone upon tooth 18.



285 Unacceptable radiograph

This radiograph of the tuberosity region was taken with an excessively steep projection angle.

286 Unacceptable radiograph

Excessive angulation. The zygomatic bone shadows the alveolar crest.

Common Errors During Preparation of Occlusal Radiographs

Because the occlusal radiograph is seldom employed, the dentist or technician is often unsure of how to perform the procedure properly. Incorrect film positioning, i.e., inappropriate for the indication, and incorrect (often asymmetric) direction of the central ray lead in too many cases to radiographs that are useless for diagnostic purposes.

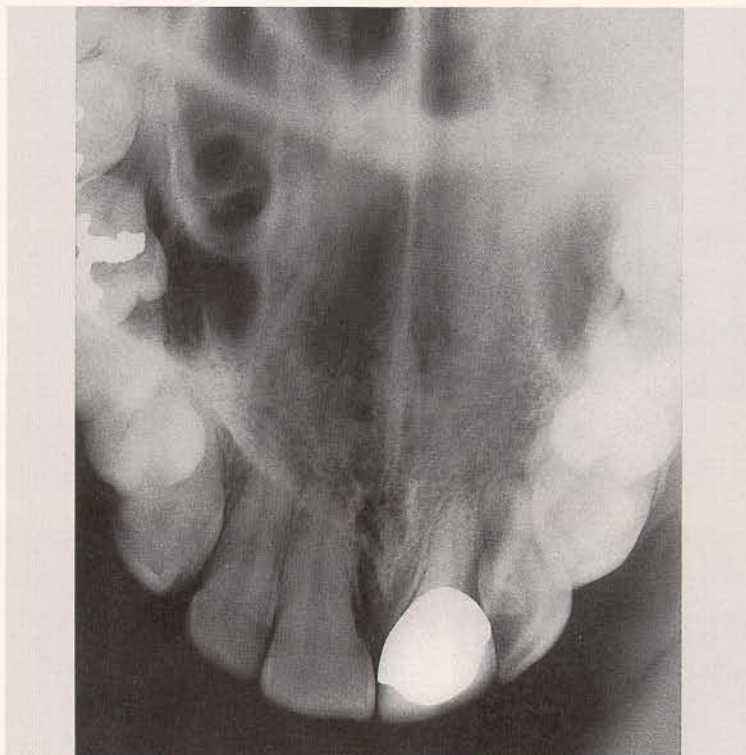
The technically correct preparation of occlusal survey radiographs and lateral occlusal films is of particular significance in the dental practice. This

method often provides the only possibility to portray and evaluate diagnostically the third dimension, which is impossible with other radiographic techniques (periapical films, panoramic radiographs).

On the other hand, it is of extreme importance that the dentist be aware that the occlusal radiograph of the maxilla will always be associated with an oblique projection that produces distortions. Only in the mandible is a perfect tooth-related axial projection possible.

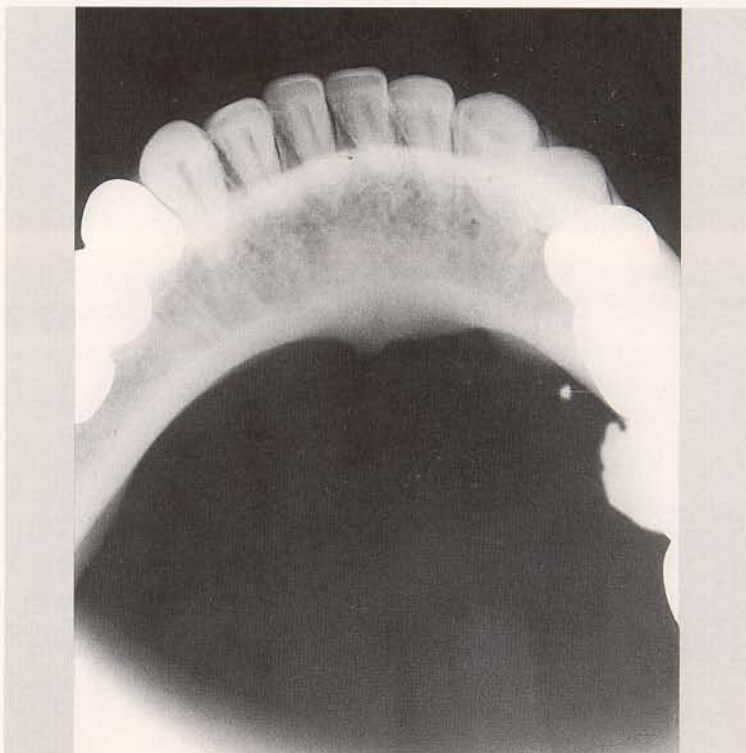
287 Unacceptable radiograph

Asymmetrically prepared occlusal film of the maxilla. In addition, the film was positioned longitudinally rather than in oblong format, and this led to additional loss of important information.



288 Unacceptable radiograph

This occlusal survey film of the mandible was taken asymmetrically (note the cone cut). The film packet was positioned longitudinally rather than transversely, and this led to a film that does not provide a true overview of the mandible.



Note: When taking occlusal films, one should always make a clear differentiation between survey films and specific section projections (e.g. lateral jaw or topographical mandibular occlusal projections). Positioning of the film and projection of the central ray must be adjusted according to the specific indication.

Processing Technique and Errors that Lead to Poor Quality Radiographs

Depending upon the equipment in the dental office, developing radiographs is performed either conventionally or automatically. Both methods have inherent advantages and sources of error. There is no argument that, if used properly, conventional wet developing provides higher quality radiographs than automatic methods. However, the fact is that the use of a conventional darkroom is no longer considered contemporary, for a variety of reasons, and today automatic film development is the more common practice despite some disadvantages. One disadvantage is that errors may cause the patient to be subjected to unnecessary additional irradiation when a spoiled radiograph must be retaken. Strict guidelines therefore must be applied for film developing. The following describes in general terms the sources of error that must be acknowledged.

Of the utmost importance is that absolutely no daylight should penetrate the darkroom. The darkroom lamp must be properly installed and checked from time to time because it represents an additional source of unintended film exposure; the filters on darkroom lamps may, with time, weaken or fade. The principle of strict cleanliness must be adhered to; chemicals and water droplets on the tabletop represent sources of error that can render interpretation of the radiograph impossible, therefore leading to the necessity to retake the film, and the attendant unnecessary radiation exposure of the patient. Precise mixing of the chemicals and checking to see that they are not out of date is also of critical significance, as is proper control of the bath temperatures. If the prescribed temperature has not been achieved, development of radiographs must not be undertaken. Cleaning of the tanks and inspection of all machinery must be performed regularly and according to manufacturers' specifications; this can often be most expeditiously accomplished through a service contract with the manufacturer or sales representative of the company. Unpacking both exposed or unexposed radiographic film must be done with extreme care. The films should be handled only by the edges whenever possible.

Storage of unexposed radiographic film packets is also significant. Poorly stored films age faster, leading to a film fog that reduces contrast and therefore compromises the clarity of the films. Film packets should be stored in a cool location, in an upright position and not together with chemicals. Whenever a fresh carton of radiographic films is opened, the first film from that package should be developed and fixed without being exposed, as a check for film fog. This can provide information about improper storage or undesired invasion of light. Manually developed radiographs must always be sufficiently rinsed if they are to be stored over the long term. Finished films should be stored completely dry in protective plastic sheets to prevent yellowing.

Finally a word about care and handling of film cassettes and intensifying screens. Check the effectiveness of the cassette-locking device regularly as well as the fit of cassette lids. Intensifying screens should be maintained in a clean condition using special solvents, to preclude radiographic artefacts. The screens should be replaced in a timely manner.

Tips for Error-Free Processing

- Work in a clean area, with clean hands.
- Remove films (panoramic films) from cassettes *slowly*, and handle by edges only.
- Examine the light source of the darkroom. Change filters regularly. They fade! Do not use conventional red light lamps, but only special (15 watt) darkroom lamps. Check doors for light-proof closure.
- Do not use high intensity lights near or above automatic developers.
- Do not manipulate exposed films for too long, even in the darkroom.
- Use chemicals according to manufacturers' directions and at the proper working temperature.
- An unexposed film subjected to correct development procedure should be completely transparent. Perform this check regularly! Observe also the expiration dates.

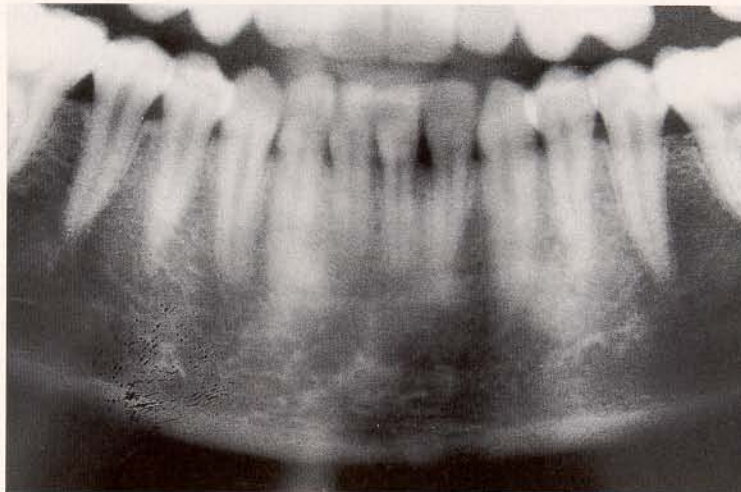
289 The panoramic radiograph exhibits "flashes" as a result of static electrical discharge

This can occur when humidity is extremely low and a film is unwrapped too quickly.



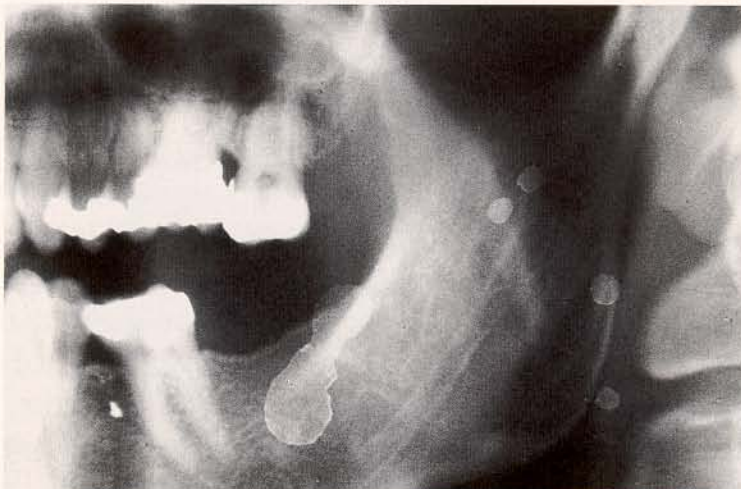290 Dirty film

This panoramic film was handled by a technician whose fingers were contaminated with developing solution. Note the "fingerprint" near teeth 43 and 44. If such films are handled with fingers contaminated with water or fixative solution, bright spots will appear due to inhibition of normal development processes.



291 Water drops

Note the bright spots at the angle of the mandible and in the ascending ramus, caused by water drops falling onto the exposed film before development.



Tips for Error-Free Development

Underdevelopment

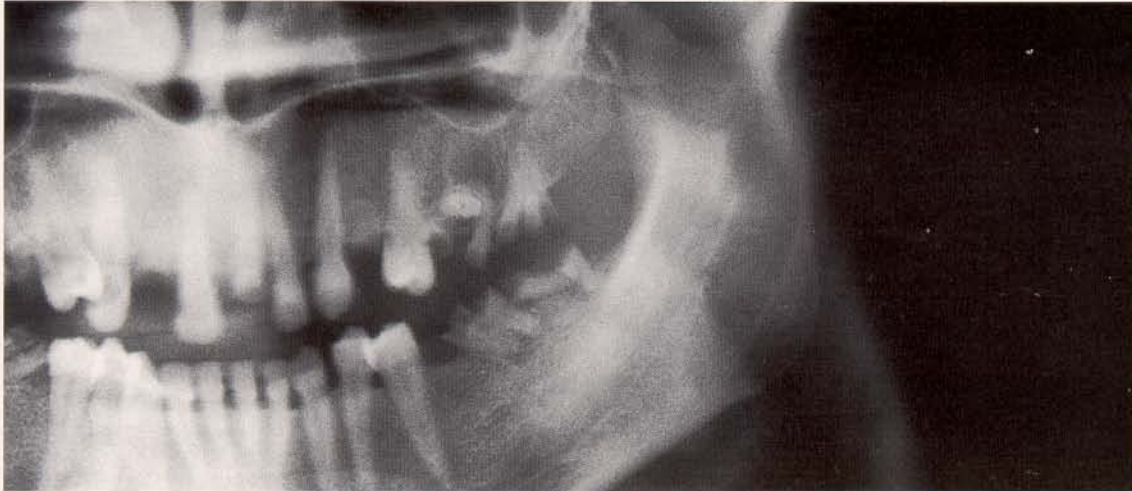The radiograph will appear too bright and lacking in contrast if:

- development time is too short,
- the baths are too cold (check temperature of solutions),
- the development solution is too old (solution should be changed at least every three weeks).

Overdevelopment

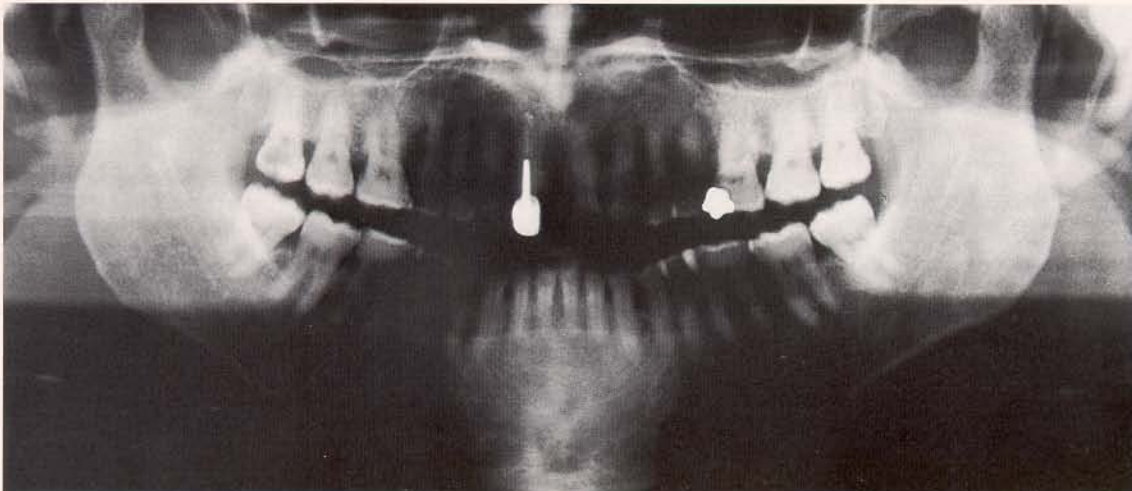
The radiograph will be too dark and, with formation of fog, will be lacking in contrast if:

- development time is too long,
- development solutions are too warm,
- the film itself is too old or has been stored in an excessively warm location.



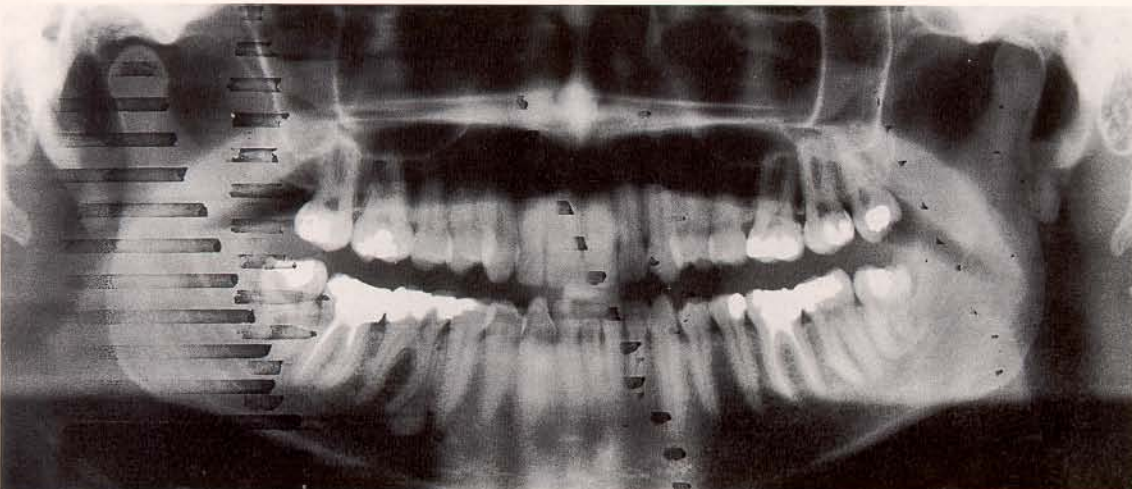
292 Incidental light exposure

After exposure of the film, the closure of the film cassette was inadvertently released and light was therefore permitted to enter. The consequence can be seen on the left side of the jaw (right side of this figure).



293 Outdated film, outdated developer

Outdated film or developer or possibly also excessively high temperature with standard processing time, results in "gray" radiographs as shown here; unfortunately, the full effect cannot be captured in a photograph.



294 Panoramic radiograph that was processed in an automatic developing machine whose rollers had been contaminated with old developer solution

Machines must be cleaned regularly according to the manufacturer's instructions. It is wise to begin each working day by running exposed and developed films (e.g., incorrect radiographs) through the machine as test films.

Tips for Error-Free Fixation

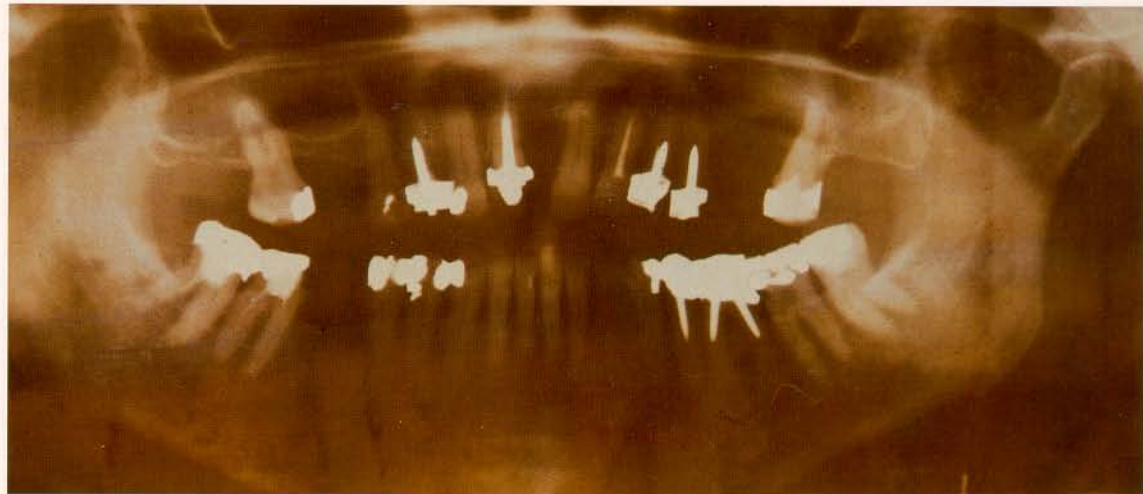
- Individual films must not be allowed to come in contact with each other either in the developer solution or in the fixative solution. Such contact precludes the chemicals from working effectively.
- If the fixation time is too short, the emulsion can be washed away.
- If the fixation solution is too cold, the final film will be lacking in contrast.
- Radiographs allowed to remain in the fixation solution too long will lose density.

Correct times and temperatures for hand developing:

At 20°C	4 min	in developer
	15 sec	intermediate rinse
	10 min	in fixative
	20 min	final rinsing

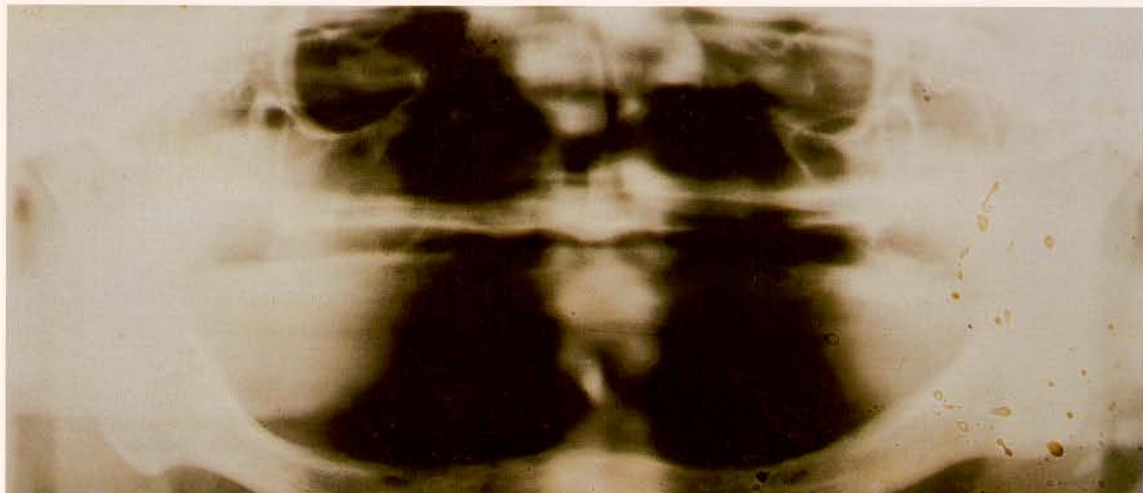
295 Insufficient rinsing

This figure exhibits the typical yellow-brown discoloration after insufficient final rinsing. This problem sometimes occurs after careless conventional radiographic development.



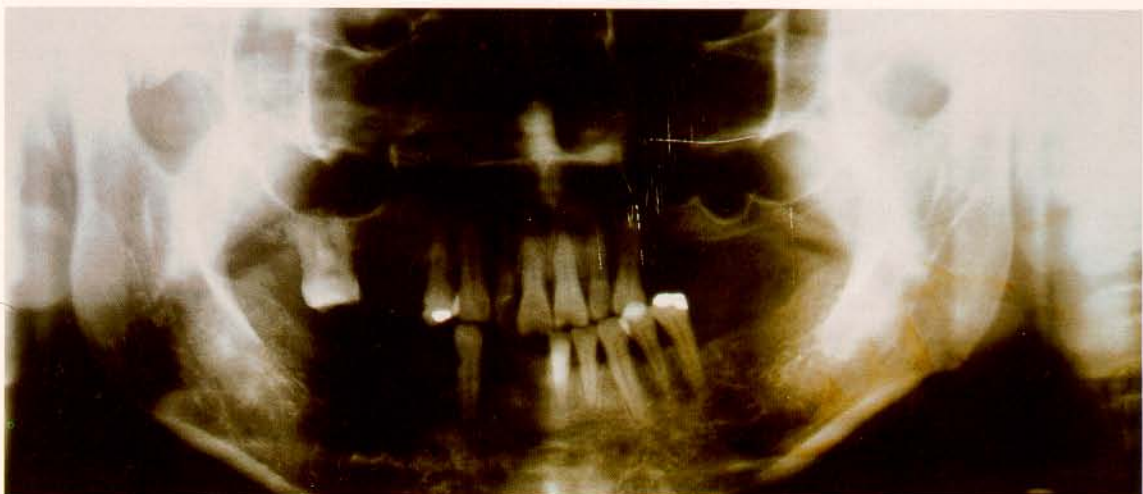
296 Radiograph contaminated after developing

Drops of developer solution fell onto this radiograph after development.



297 Incompletely fixed film

In addition to the incomplete fixation, this film was scratched.

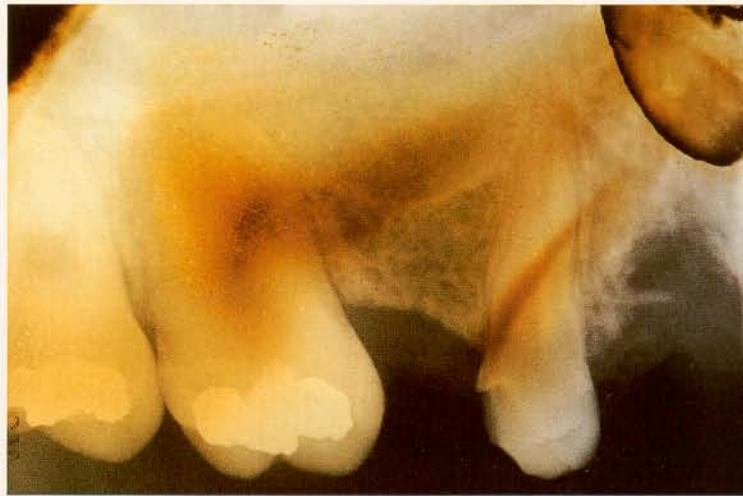

Optimum Radiographs

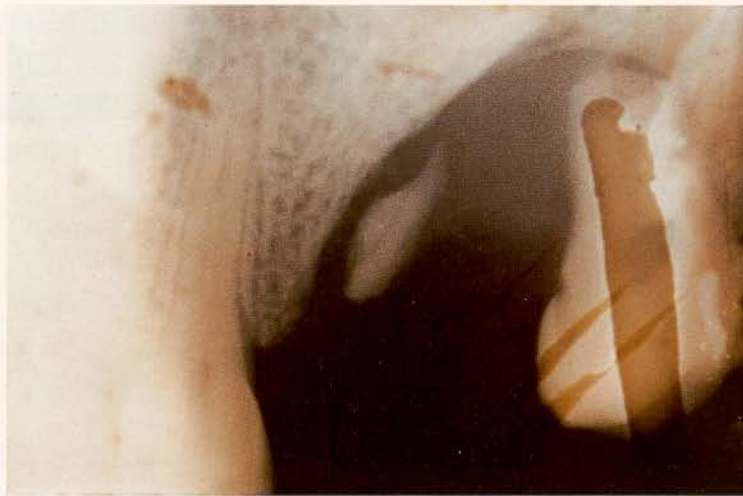The optimum radiograph exhibits maximum radiographic contrast:

- This consists of the *object contrast*, which results from the different densities of the various substances traversed by the X-ray beam.

- An additional factor is the *film contrast*, which depends upon the characteristics of the film itself and the development process. Underdevelopment inhibits optimum contrast, while overdevelopment leads to blackening and fogging.

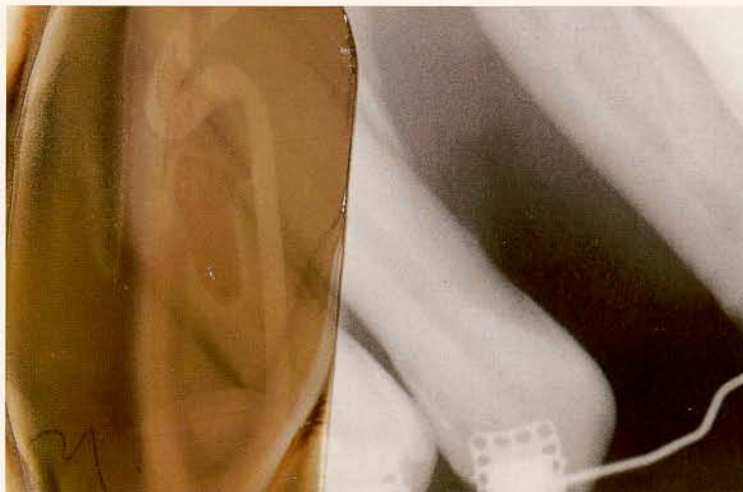

298 Insufficiently fixed film



299 Film contaminated with chemicals

In addition to the contamination, this film was incorrectly positioned and poorly targeted by the X-ray beam.



300 Film contact during fixation

The fixation solution cannot work on the emulsion, resulting in this typical brown discoloration.

Reducing Overdeveloped Radiographs

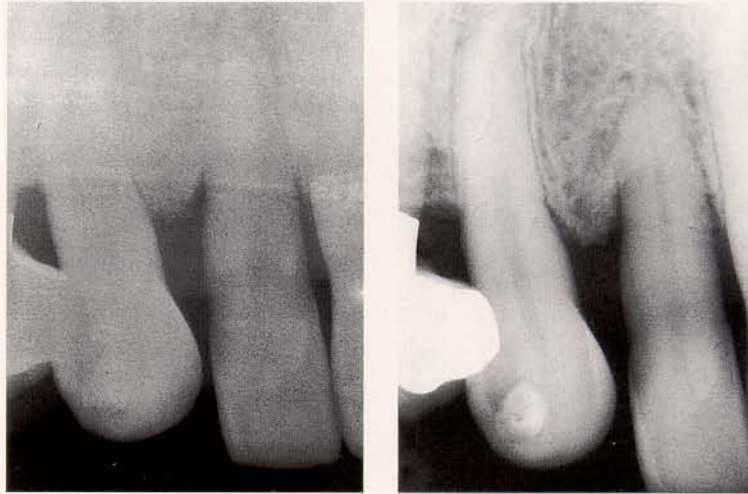
Overdeveloped radiographs may sometimes be corrected (reduced) through use of the Farmer technique, which involves use of two solutions that must be kept separate from one another.

Solution I	Water	500 ml
	Sodium thiosulfate	50 g
Solution II	Water	100 ml
	Potassium ferrocyanide	10 g

Immediately before use, four parts of Solution I are mixed with one part of Solution II. This solution is not stable and must be discarded. Observe laws and regulations for waste disposal procedures! Always wear rubber gloves when using these solutions. Rinse frequently with water. After reduction using these solutions, the film must be placed for one minute in the fixative solution. A final extensive water rinse must be performed.

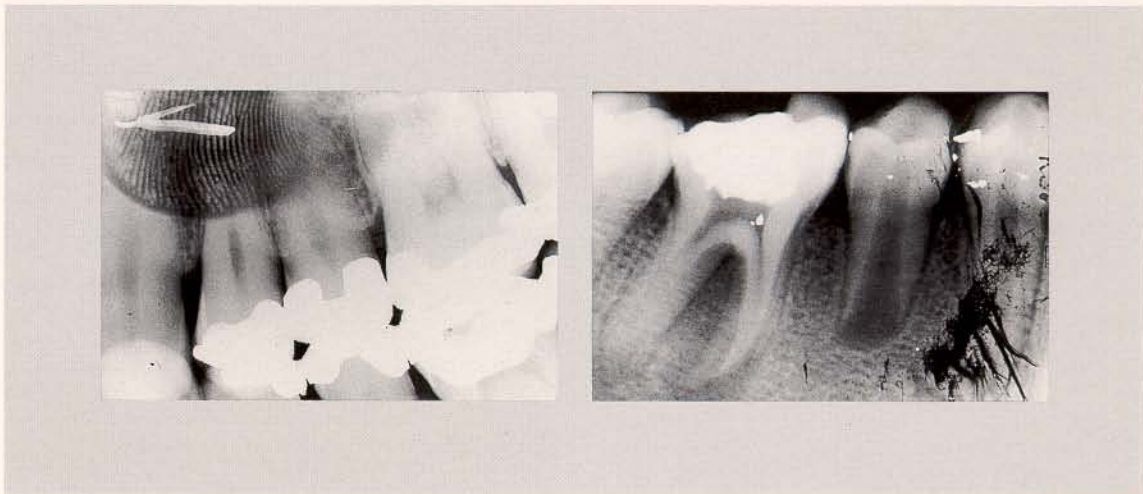
301 Effect of developer that is too cold and too old (left)

The radiograph was retaken and developed using appropriate conditions (right).



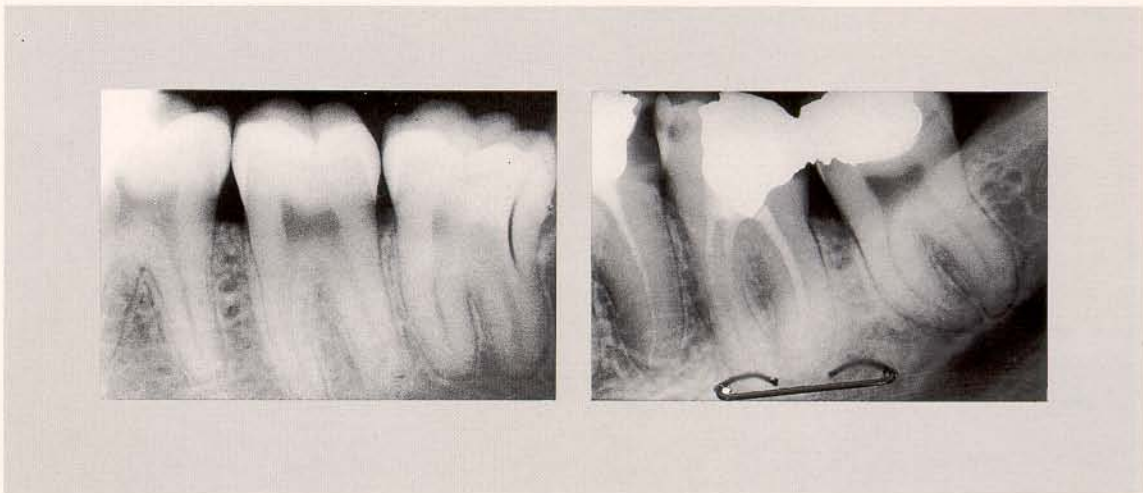
302 Radiograph exhibiting a fingerprint caused by developer solution

The bright line within the fingerprint resulted from scratching with a fingernail.



303 Result when the film packet becomes saturated with saliva and adheres to the film

This is a disadvantage of paper-wrapped films, which must be developed immediately after exposure.



304 Impression of a fingernail on tooth 38

The obvious half-moon dark line on the distal surface of tooth 38 was caused by a fingernail when the film was removed from its packaging.

305 Incorrect location of a staple to affix the radiograph (for additional examples, see Pasler 1989)

Supplemental Examinations Using Conventional and Modern Imaging Techniques

Panoramic radiography offers the dentist a realm of diagnostic possibilities that will lead to additional knowledge and a deeper understanding of anatomic relationships. This will provide new therapeutic insight, and will lead the dental practitioner to an awareness of the necessity to become expert not only with panoramic radiography and its diagnostic possibilities but also with supplementary conventional and more contemporary methods of imaging. For many and varied reasons it may seem impossible for the dentist to possess and routinely use all of the possibilities afforded by modern techniques for examination in his or her practice; it is nevertheless necessary that practitioners be aware of the more important examination techniques and the diagnostic possibilities that they offer so that the dentist can advise and refer patients appropriately.

Today it is possible to take advantage of numerous diagnostic possibilities offered even by panoramic radiography, because modern electronics in the newer instruments permit the creation of many targeted projections in addition to the normal panoramic film. When used properly, for example as a final check after completed therapy, the radiation dose to patients at follow-up examinations can be significantly reduced. However, no *new* information will be gleaned from targeted projections because the direction of the central ray projections is not altered. More interesting from a diagnostic point of view is the possible development of lateral cephalometric equipment into a dental skull instrument, because only the inclusion of the third dimension can provide any significant contribution toward perfecting dental examination technique. Most modern instruments combine the choice of various targeted projections with the possibility of spiral tomography in the third dimension. This chapter will provide additional examples of the projections described on p. 24.

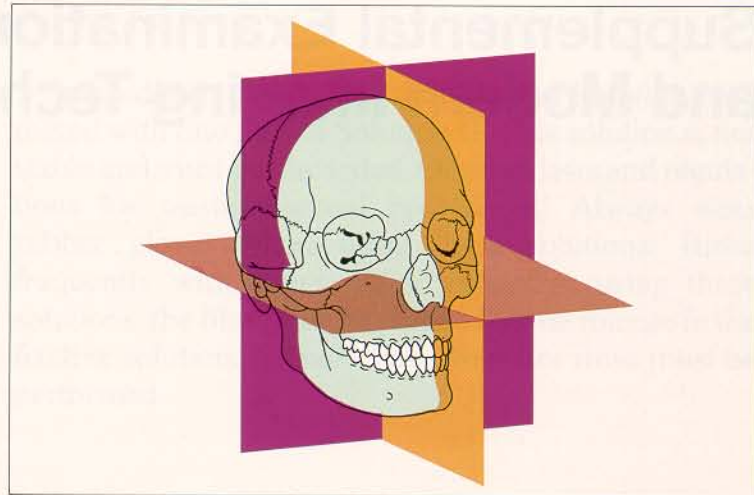
There can no longer exist any doubt that today's dentist must possess knowledge about dentogenic diseases of the maxillary sinus as well as occlusion-related lesions of the temporomandibular joint; the inclusion of these regions in the dentist's diagnostic considerations has become mandatory. Therefore in this chapter we will present examples of the range of possibilities offered by conventional tomography as well as computed tomography (CT), insofar as they affect the dentist's sphere of operation. In addition, the dentist must be aware of the diagnostic possibilities offered by magnetic resonance imaging (MRI) for the depiction of lesions of the disk in the temporomandibular joint, even though today we still remain far from the time when this technique may be viewed as a mandatory supplement to clinical examinations.

Conventional Skull Films

First Standard Projection: Posteroanterior Skull Projection

All skull projections, regardless of the methods by which they are produced, may be basically included in the scheme of the three standard projections:

1. posteroanterior skull projection
2. lateral skull projection
3. axial skull projection



306 All of the possible skull projections originate from the three standard projections

The diagram shows the frontal plane, the median sagittal plane and the axial plane, which orients on the Frankfurt line.

307 Positioning for the first standard projection, the skull overview with posteroanterior central ray projection

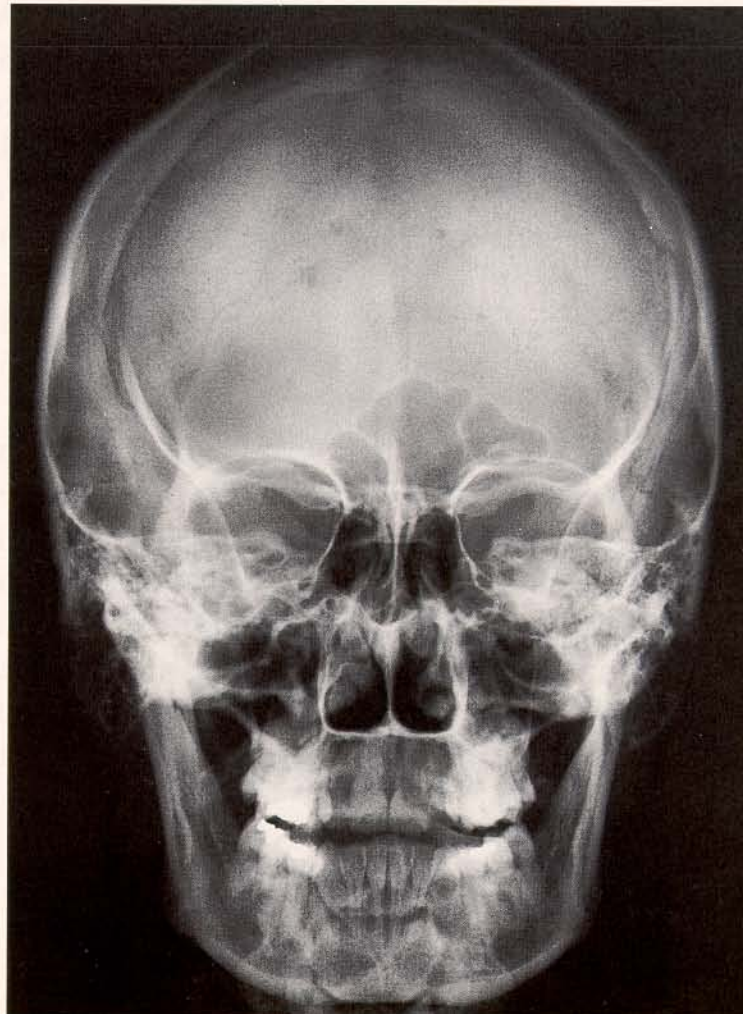
The petrous portions of the temporal bones are projected in the orbits.



308 Typical "posteroanterior skull overview" radiograph

In orthodontics and in oral and maxillofacial surgery, this radiograph is used primarily for depiction of cranial asymmetries.


(Radiographic anatomy of the skull radiographs may be reviewed in Pasler 1989)



Second Standard Projection: Lateral Skull Projection

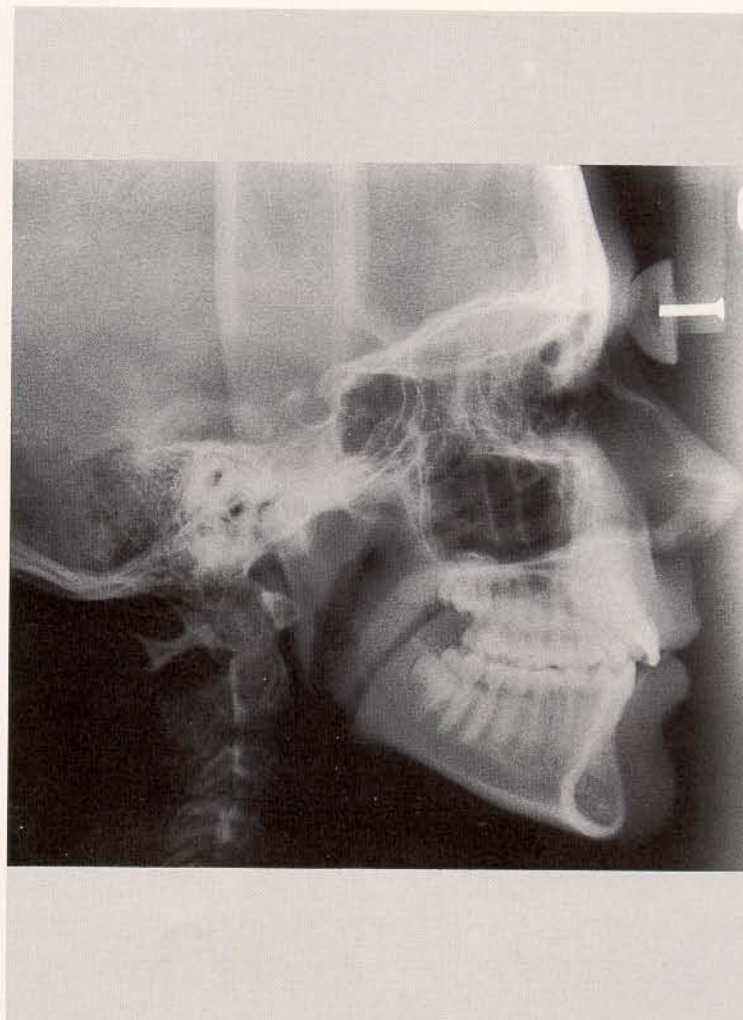
Following general use in medical radiology, the second standard projection (lateral skull overview) is taken with the right side of the head against the film cassette (Fig. 309). The central ray is directed through the sella turcica. The lateral cephalometric radiograph in common use in dentistry is taken as a partial skull film with the central ray targeted through the region of the auditory foramen. The head may be positioned with either the left or right side against the cassette. This radiograph is used primarily in orthodontics and oral

surgery. However, it may also be used in prosthodontics to check on esthetic and functional characteristics of the anterior region, and the head profile. As a lateral view of the anterior tooth region of the facial skeleton, it serves as an ideal supplement to panoramic radiography to depict the anterior tooth region. Thus this radiograph can be important for determining the spatial characteristics of cysts, tumors and impacted teeth in the paramedian region.



309 Positioning for the lateral skull projection

Normal position in radiology. The usual focus-film distance in radiology for skull projection is 1 m, but for dental cephalometric projections it is 1.5 m.



310 Typical cephalometric radiograph

In this case the film was taken with the left side against the cassette, with the use of a special soft tissue filter made of aluminum. The focus-film distance of 1.5–2 m and the careful fixation of the skull in the cephalostat permits one to mark measuring points directly on the film and allows subsequent evaluation using cephalometric analysis.

Note: Cephalometric films taken in the dental practice cannot be compared with those from radiology clinics because of the differing focus-film distances.

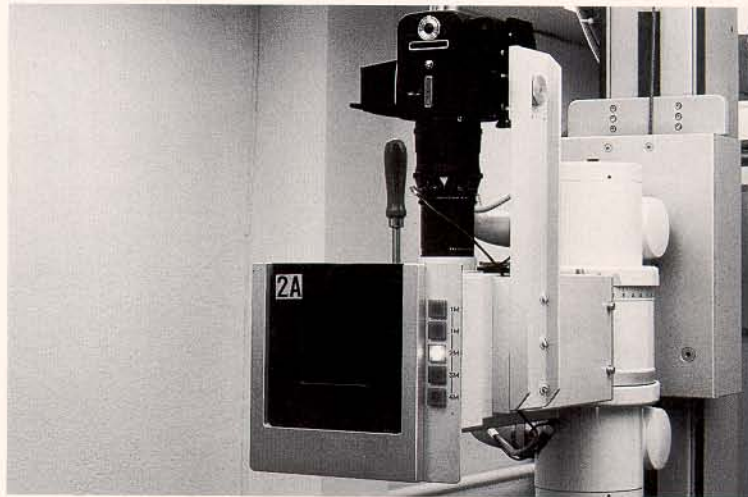
Special Construction of a High Capacity Cephalometric Instrument

Working in collaboration with the Siemens-Albis Company (Zurich) in 1975, the author developed an instrument that permits a precise choice of various focus-film distances combined with security contacts that automatically block the exposure if the selection of

distance or diaphragm is incorrect. The incorporation of a reflex lens camera permits the immediate superimposition of a radiograph and a photograph that can be copied with all dimensions maintained accurately.

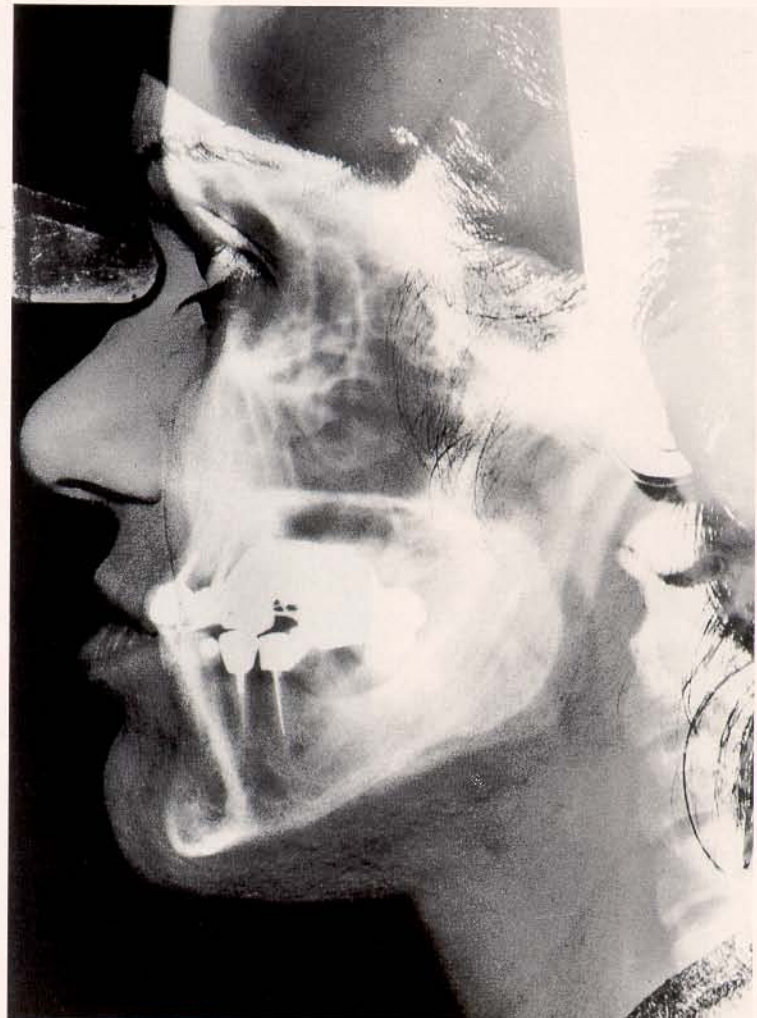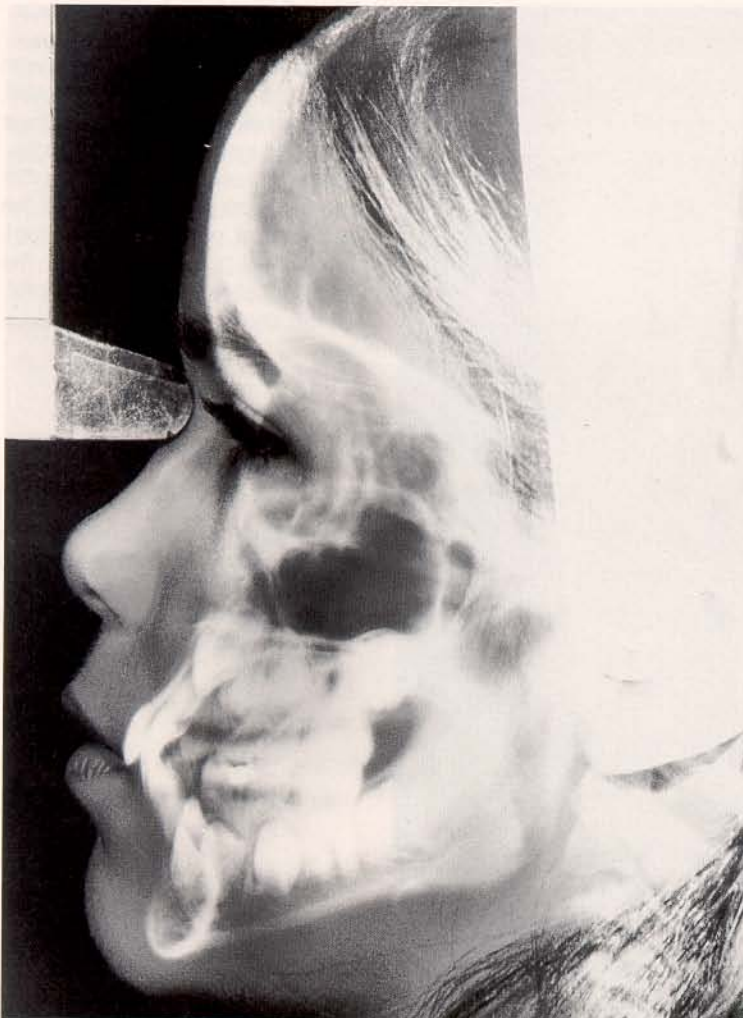311 Special radiographic instrument

This figure shows the tube portion of the instrument, with diaphragm insert and camera position.



312 Radiographic and photographic projections superimposed

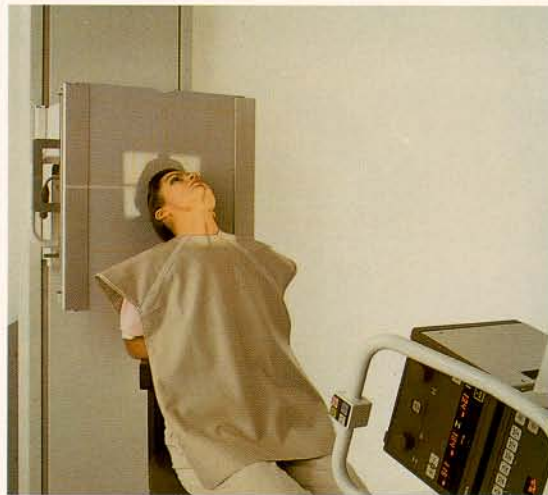This technique can be used to follow the development of facial profile in children or as a check for profile in prosthetics or oral surgical cases.



Third Standard Projection: Axial Skull Radiograph

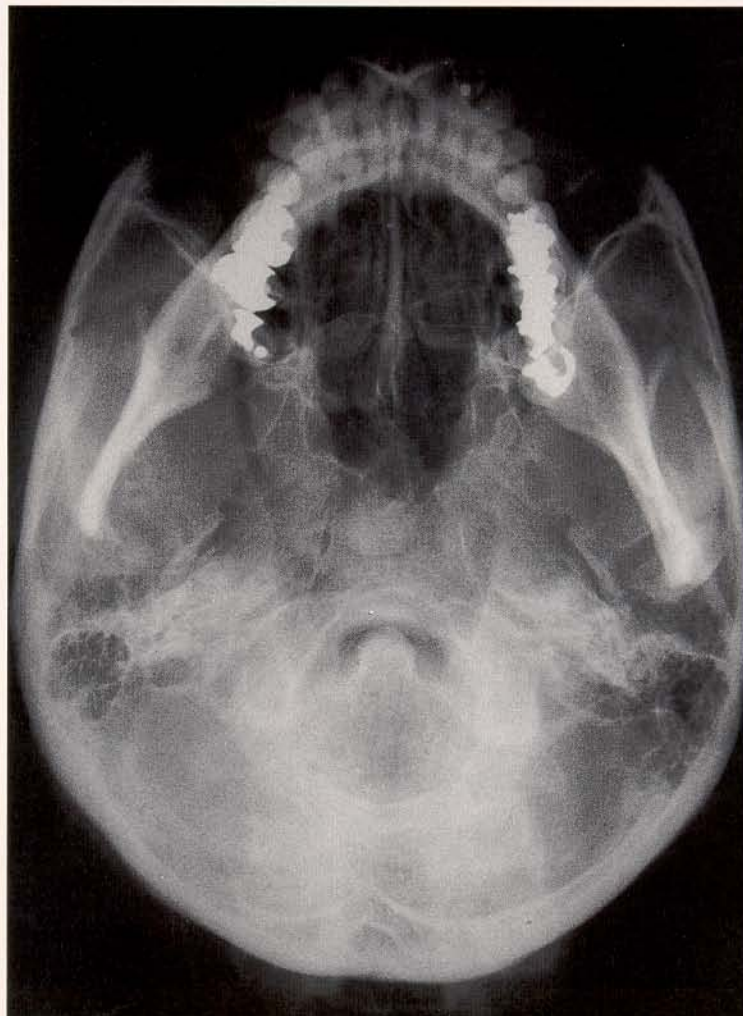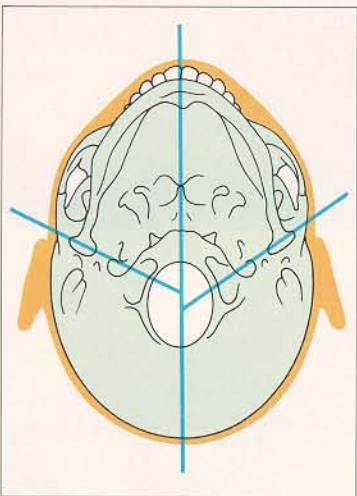
The third standard projection, the axial skull radiograph, is also important for examination in dentistry, and this film can be taken in the dental practice if appropriate equipment is available. The axial skull film is used primarily for the depiction of skull asymmetries, especially the condyles, their shape and their axial angle

with the median sagittal plane. Fractures of the zygoma and problems of localization, e.g., impacted maxillary third molars can also be approached using an axial skull film. Today, axial computed tomography (CT) is often used instead of the axial skull radiograph.



313 Positioning for the axial skull radiograph

The Frankfurt horizontal plane is positioned parallel to the cassette table, and the central ray is targeted perpendicularly toward the middle of the zygomatic arch and the plane of the film. The picture on the right shows a modified central ray projection that can be used to create a view of the zygomatic arch. Note the positioning of the X-ray unit.



314 Diagram of the condylar axes in an axial skull projection

More precise views of the temporomandibular joints can be prepared after correct determination of the angle.

315 Axial skull radiograph

To view the temporomandibular joint along its axis, the axial skull film is the basic projection prior to the use of Schüller projections and temporomandibular joint tomography.

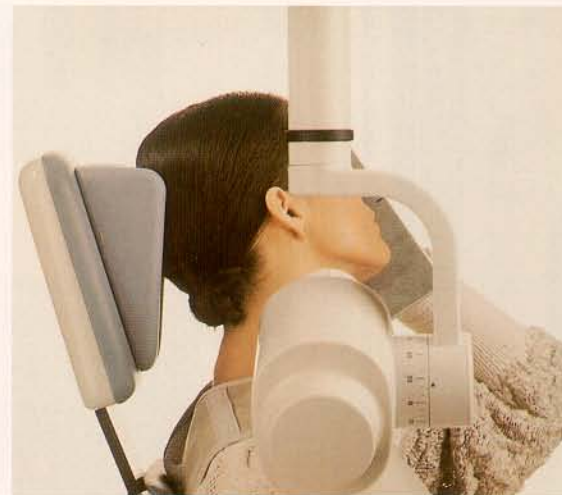
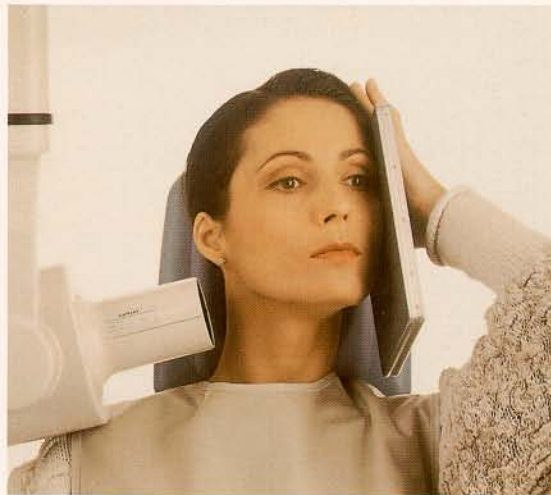Lateral oblique Jaw Projection

Since the beginning of this century, no other radiographic technique for depiction of the jaws has proven itself like the lateral jaw projection. Today, this technique is still used to great advantage wherever panoramic radiography is not available. On the other hand, it can be diffi-

cult to prepare a good radiograph using the apparatus for skull films, especially in elderly patients. The dental X-ray unit, because of its excellent mobility in all directions, is most suitable for this technique, as will be explained in more detail below.

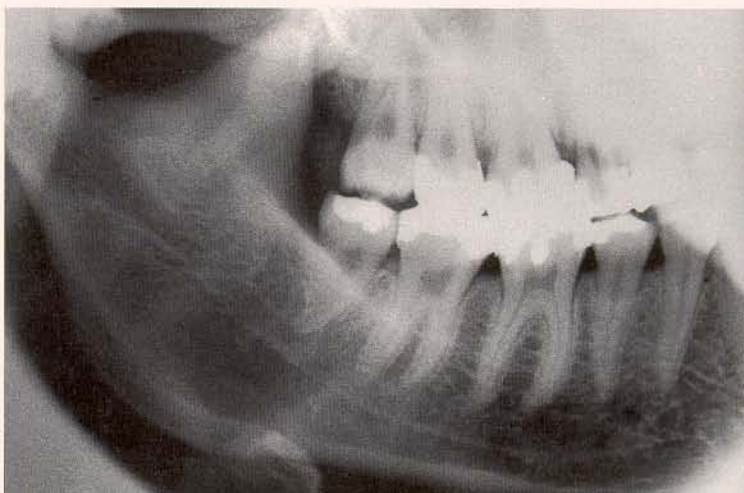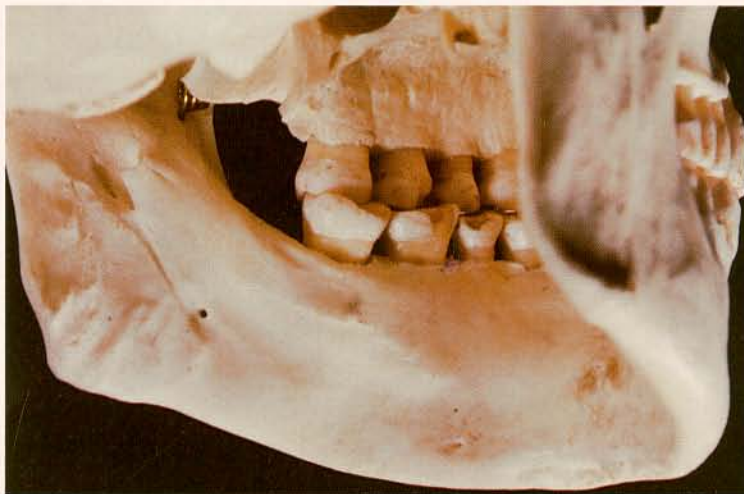316 Use of the dental X-ray unit to take a lateral oblique jaw projection

Positioning of the film cassette and the central ray as seen from the front and from the side. Note that the cassette is *not forced* against the cheek, to avoid distortions. At the same time, the chin must be *lifted considerably* to make sure that the angle of the mandible is not superimposed upon the vertebrae.



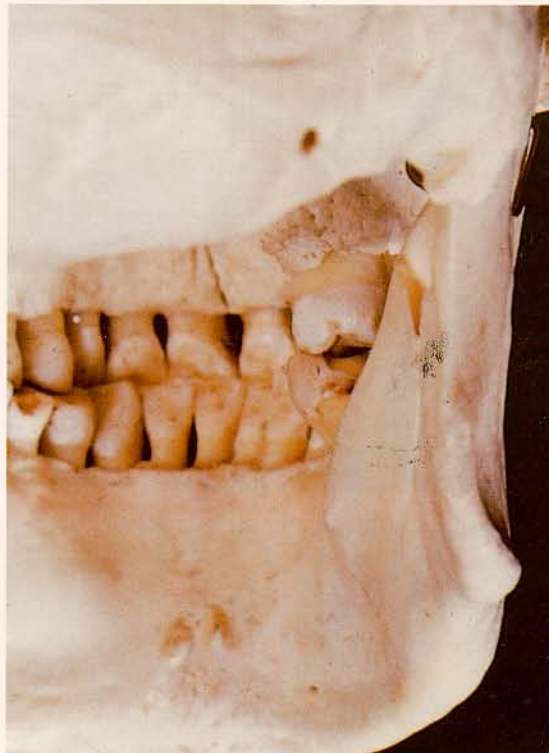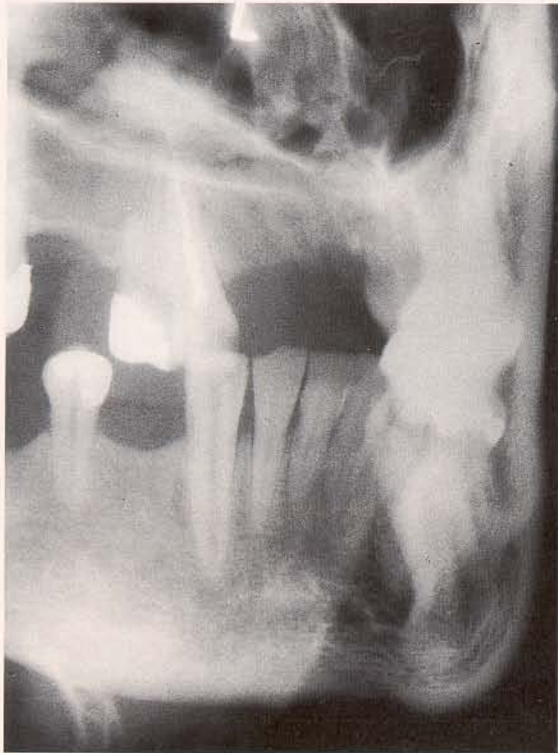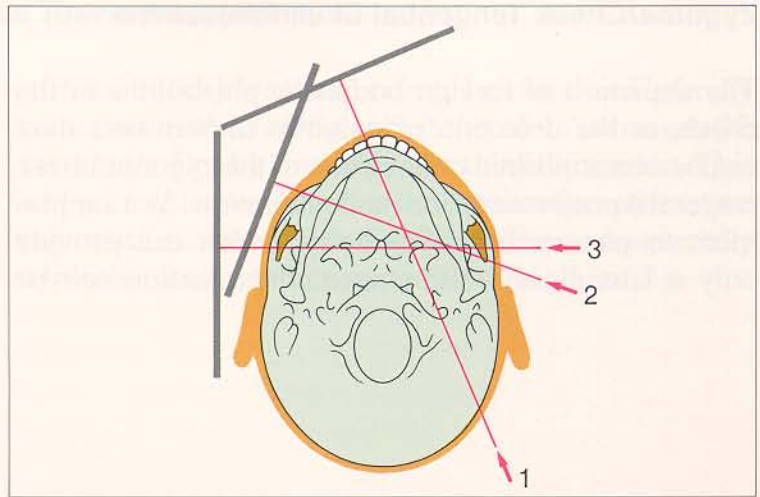
317 Photograph and radiograph of the lateral oblique jaw projection, targeted toward the angle of the jaw and the horizontal ramus

The photograph clearly shows how this portion of the mandible must be targeted to produce the desired radiograph. The diagram in Figure 318 shows the projection angle in position 2.



Special Positioning for the Lateral oblique Jaw Projection

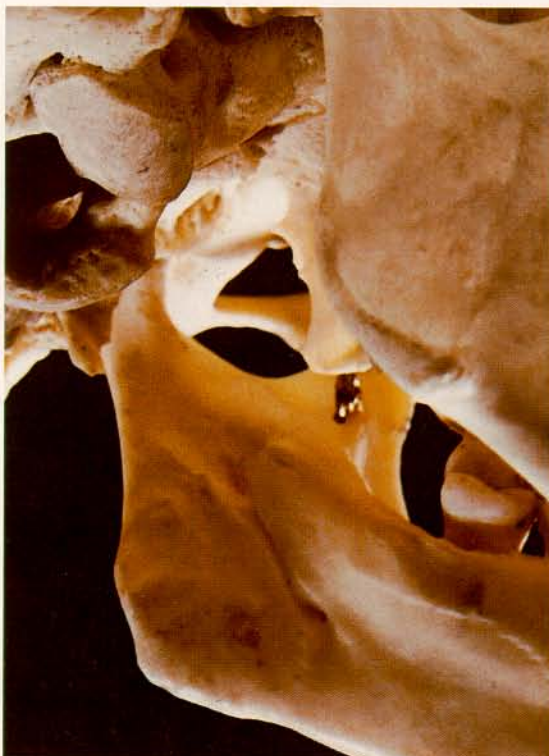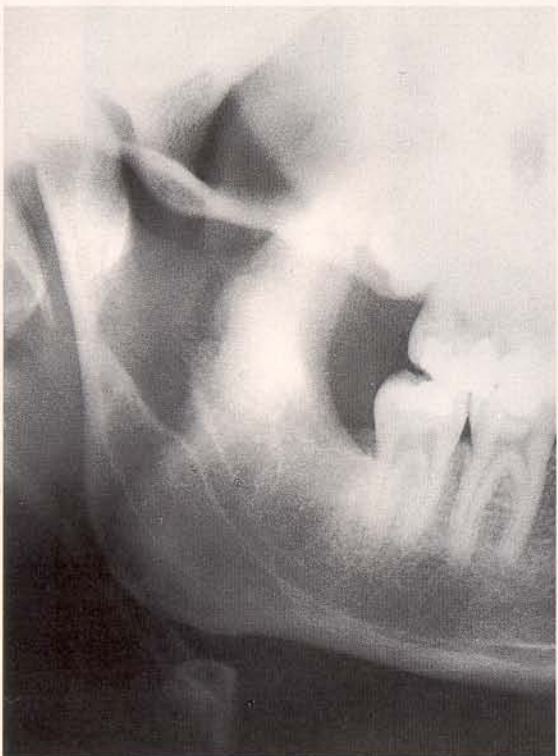Besides the radiographs shown on the previous page, the dental X-ray unit can be used to make additional projections, for example to better depict the mandibular anterior region and the ascending ramus of the mandible. The diagram in Figure 318 shows the position of the film cassette and the direction of the central ray for the three projections. If the maxilla is to be included in the radiograph, the central X-ray beam must be targeted accordingly, directed steeply upward.



318 Possible projections for the lateral oblique jaw technique (above)

319 Radiograph and photograph: Example of the technique for depicting the anterior region of the jaws

The entry point for the central ray must be between the cervical vertebra and the mandibular angle of the side furthest from the film (see also Fig. 318, position 1).



320 Radiograph and photograph: Example of the projection technique for depicting the ascending ramus of the mandible

The central ray is targeted from beneath the angle of the mandible on the opposite side toward the middle of the upper third of the ascending ramus (see also Fig. 318, position 3).

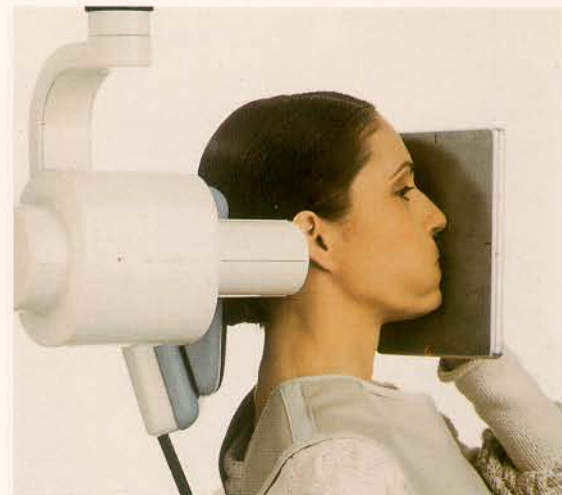
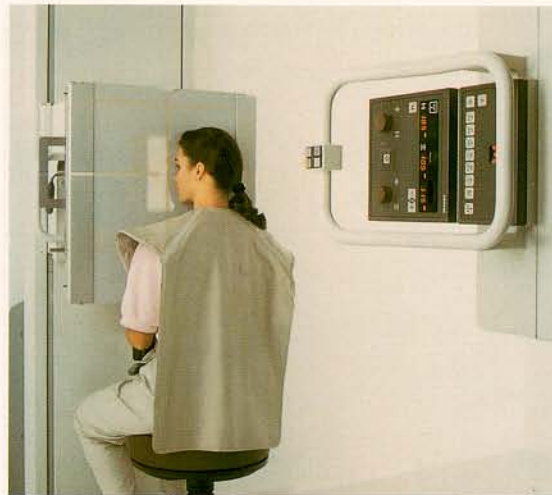Zygoma/Cheek Tangential Skull Projections

The depiction of foreign bodies or phleboliths in the cheek, or the detection of sialoliths in Stenson’s duct can be accomplished on the basis of the zygoma/cheek tangential posteroanterior skull projection. As a supplement to panoramic radiography, which can provide only a lateral view, the tangential projection can be

performed in the dental office using the dental X-ray unit and a normal film cassette (13 × 18 cm) or an occlusal film packet. Processing of such films used to present some difficulties, but the automatic developing units that are common today for panoramic radiographs essentially eliminate any problems.

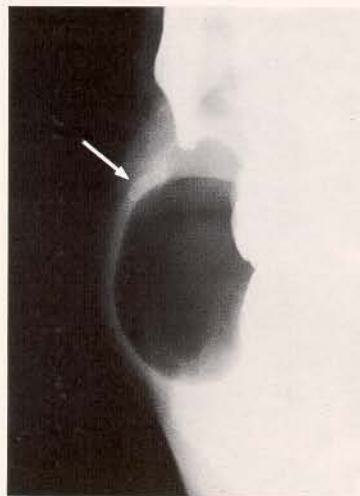
321 Positioning for the zygoma tangential posteroanterior skull film using the skull radiography unit (left), and the “cheek tangential” positioning with the dental X-ray head

Note that the patient has puffed out the cheeks (right); this makes it possible to depict soft tissue structures even with very low exposure times.

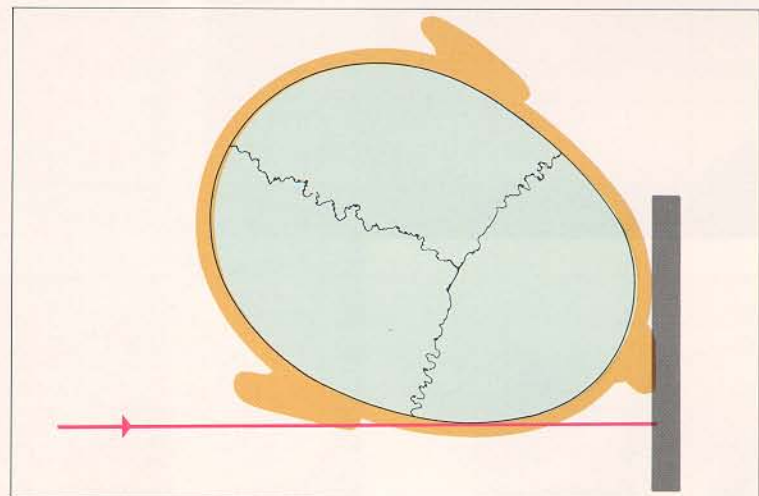


322 The radiograph clearly depicts a sialolith in the saliva duct leading from the parotid gland

The posterior teeth and the zygoma appear only as opaque shadows because of the very low exposure time.



323 Diagram of the principle of the “zygoma tangential posteroanterior” skull projection technique



Panoramic radiography equipment that is also suitable for lateral cephalometric films (e.g., Siemens OP-10) may also allow the preparation of the following skull radiographs:

- Lateral cephalometric and posteroanterior films
- Axial and Waters’ projections
- Reverse Towne projection

Using dental X-rays units, the following projections are possible:

- Lateral jaw films
- Cheek tangential radiographs

Mandibular Posteroanterior Skull Radiograph (reverse Towne projection)

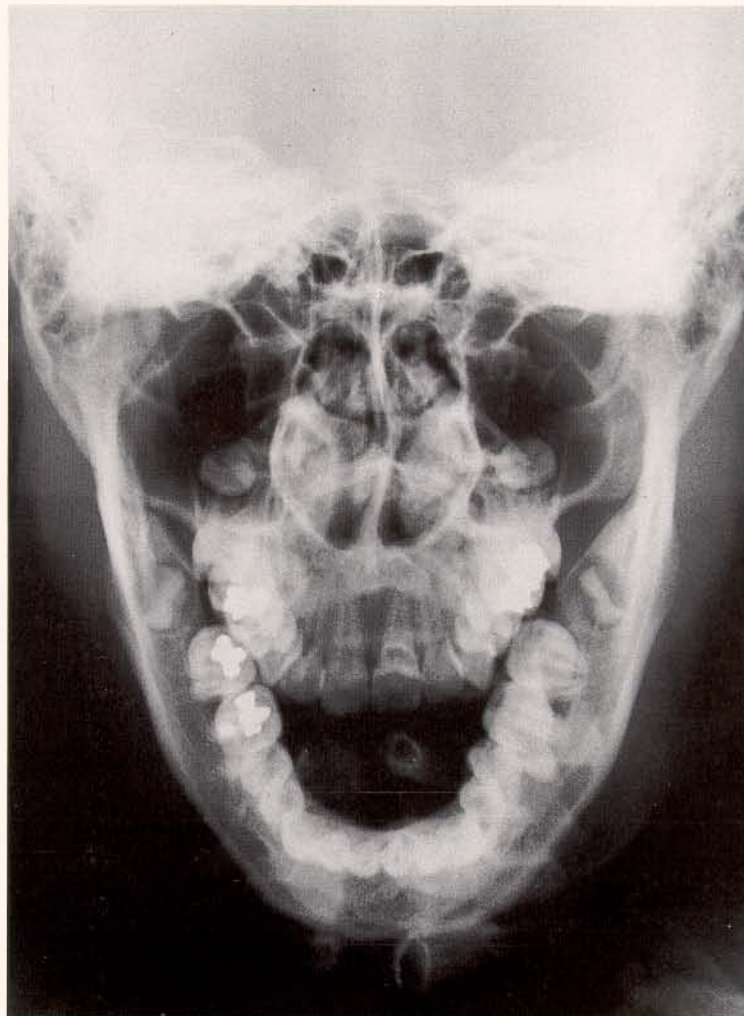
One of the most important skull radiographs is the mandibular posteroanterior radiograph with maximum jaw opening. This radiograph can be taken routinely in many dental practices today using the lateral cephalometric feature of the panoramic X-ray unit. The reverse Towne projection provides a frontal view of those

portions of the jaws that can only be visualized laterally in the panoramic radiograph; it therefore enhances the panoramic film by providing the third dimension. This is of critical importance for the localization of fracture fragments, tumors, cysts, foreign bodies and especially atypically positioned impacted third molars.



324 Positioning for the reverse Towne radiograph with maximum jaw opening, using skull film equipment

To prevent jaw movements, the maximally opened mandible is fixed in position using a bite block. The central ray projection permits visualization of the condyles above the sinus. Uniform exposure of all structures on the film is possible only through use of aluminum filters positioned laterally (Pasler 1989).



325 Typical example of a reverse Towne radiograph with maximum jaw opening

The view in the frontal plane reveals the angle of the mandible and the ascending ramus with the condyles. The dorsal portion of the maxilla and the palatal bone are viewed through the floor of the sinus.

Waters' projection

This is also one of the more important skull radiographs. It is part of the basic examination of the maxillary sinuses, as well as the frontal and ethmoid sinuses; as such it is part of the mandatory radiographic examinations of the nose and adjacent sinuses, as well as ear-nose-throat examinations. In dentistry, it serves as an

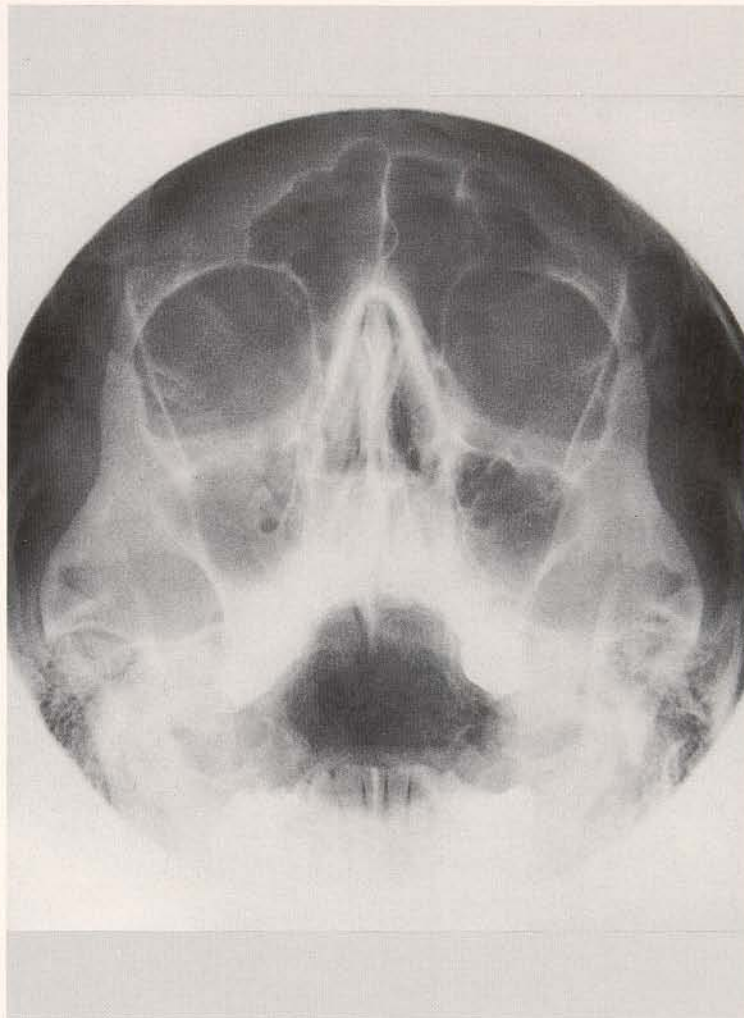
important adjunct to the panoramic radiograph, especially with pathology that effects the maxillary sinus, for example the existence of dentogenic sinusitis. In certain cases, this radiograph will need to be supplemented by other radiographic examination techniques, as determined by appropriate specialists.

326 Positioning for the Waters' projection, using skull film equipment

A bite block is used to secure maximum jaw opening; note the head position vis-à-vis the film cassette. The central ray must traverse the superior edge of the petrosal bones so that these appear below the maxillary sinus in the final radiograph. *Right:* View of the appropriate positioning of the X-ray head and the collimator.

**327 Radiograph of a typical Waters' projection with maximum jaw opening (with appropriately employed collimators)**

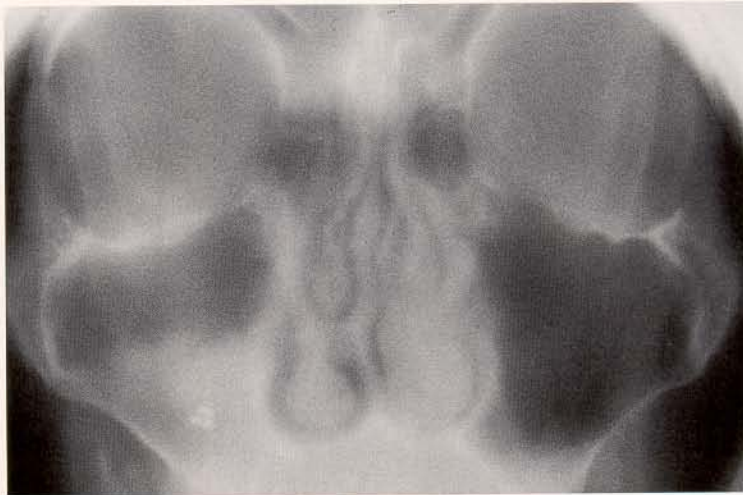
This low-energy exposure depicts the initial stages of an acute, bilateral rhinogenic maxillary sinusitis with shadowing of the ethmoid cells. Even though all the clinical symptoms point towards an acute sinusitis, the radiograph in initial stages is often without significant findings. Only after several days, i.e., when the inflammatory process has persisted, does the X-ray permeability of the sinus change; ultimately it becomes opaque. In order to discern such early conditions radiographically, a low-energy projection with low exposure time must be used. The use of a collimator will reduce the radiation exposure.



Supplemental Examination of the Maxillary Sinus with Additional Methods

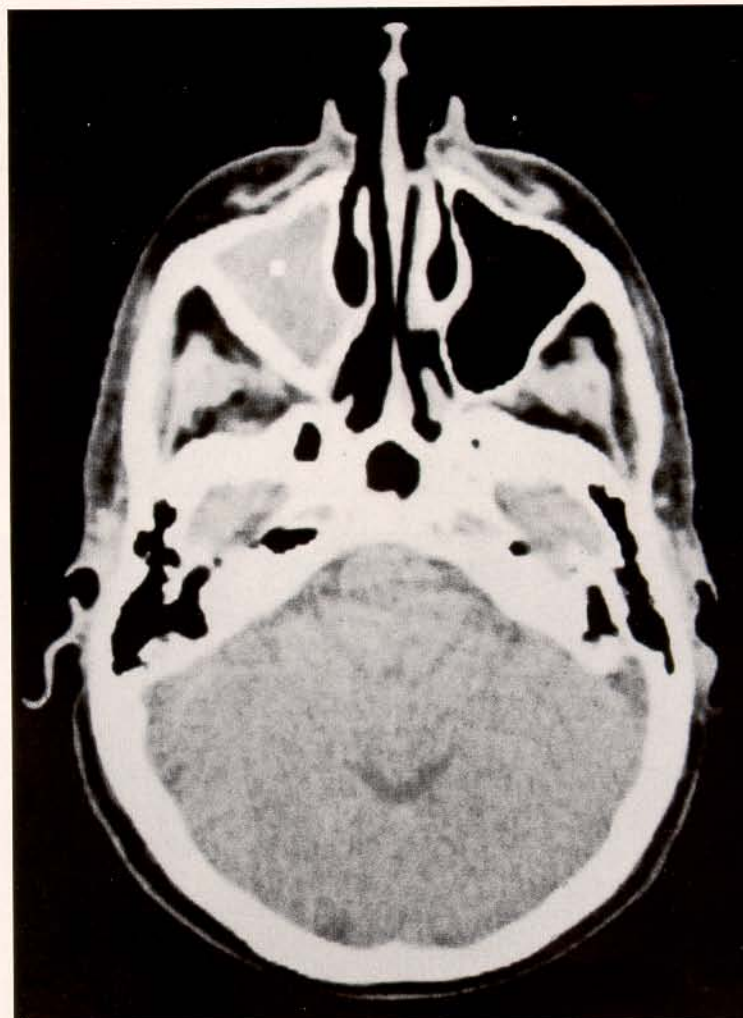In every case where the clinical examination and the panoramic radiograph provide evidence of disease in the maxillary sinus, panoramic radiography must be supplemented by additional radiographic examinations. In addition to the already described Waters' projection and the radiographic examinations for the nose and adjacent sinuses, tomography in both frontal and lateral projections can provide useful information. Using these techniques, the sinus can be viewed layer by layer. In addition, examination using computed to-

graphy has become standard, because by using this technology it is possible to depict bony structures and also the soft tissues with concomitant density measurements. In every case, the patient's physician or medical specialist should be consulted to ensure adequate examination with minimum X-ray exposure. It is the obligation of the dentist to diagnose any dentogenic origin for sinus pathology, and to initiate dental therapy for any such condition.



328 Frontal tomography of a unilateral maxillary sinusitis with aspergillosis on the right side

This figure was taken from a series of frontal spiral tomograms; it presents a case of aspergillosis. The mycotic masses have accumulated around the foreign body (usually the remnant of a root canal filling). The left maxillary sinus contains air and appears to be unaffected.



329 Axial computed tomogram made with the soft tissue window depicts a unilateral (right) chronic sinusitis of dentogenic origin

As a sign of the chronic inflammation, the sinus walls appear thickened due to reactive sclerosis. The sinus does not contain air. The left sinus exhibits normal structure.

Transcranial projection: “The Modified Schüller TMJ Film, Open and Closed”

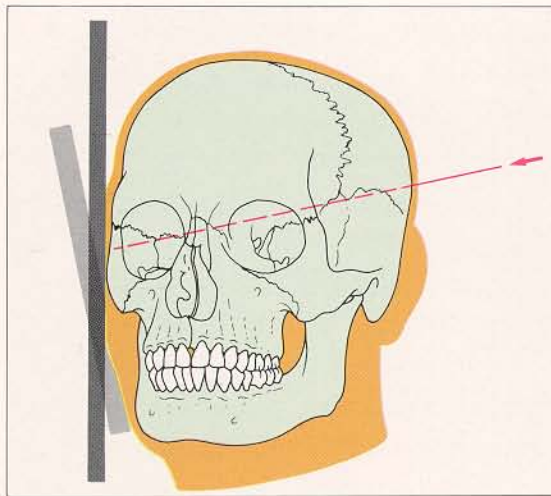
Many TMJ problems can be detected even in their early stages by careful examination of a panoramic radiograph (p. 171 ff.). However, once definitive traumatic lesions of the disc or degeneration of the bony structure of the condyle have occurred, other examination methods may be indicated. Possibilities include invasive and noninvasive techniques. The latter include axial skull projections, Schüller projections, conventional tomography, CT and magnetic resonance imaging. Invasive techniques include arthrography and arthros-

copy, which can only be performed under sterile conditions.

Unfortunately, the dentist in private practice has only very limited possibilities to make diagnoses of the TMJ, even though the treatment of dysgnathia, malocclusions and comprehensive dental reconstruction demand perfect and interpretable records with high precision. Furthermore, collaboration with clinics and radiologists is often problematic for various reasons.

330 Diagram and photograph of positioning of the skull for the TMJ film as modified according to Schüller

To portray the condyles as closely as possible along their long axes, either the X-ray head and the film or the patient can be appropriately positioned after evaluation of an axial skull film. The vertical median sagittal plane should be approximately parallel to the film cassette, with a horizontal angle of no more than 10° to the cassette and a vertical angle of no more than 25°.



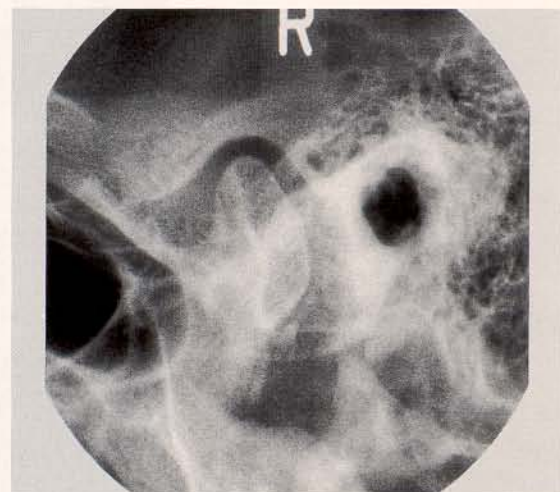
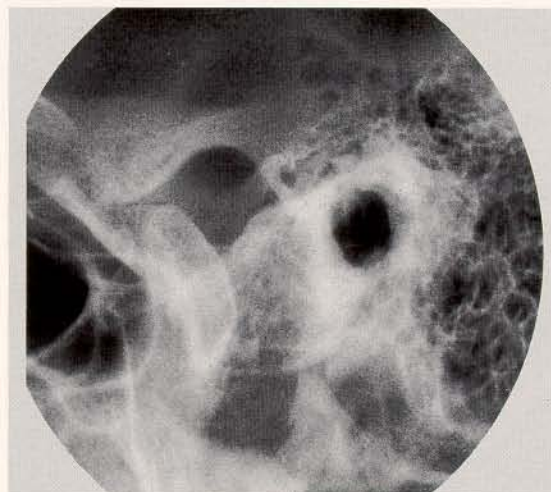
331 Detail of the positioning for the Schüller projection with mouth closed, and mouth open

Note that during the second exposure with the mouth open (*right*) only the mandible has been moved to the open position, otherwise variation in the depiction of structures will occur between the films taken with mouth closed and open, and this could hamper interpretation.



332 Typical radiographs of the right TMJ as seen in the modified Schüller projection

Note especially the precise depiction of anatomic details in both films. The external auditory meatus, the posterior clinoid process and the zygomatic process of the temporal bone are portrayed exactly in the same position. Films such as these result only from careful radiographic techniques!

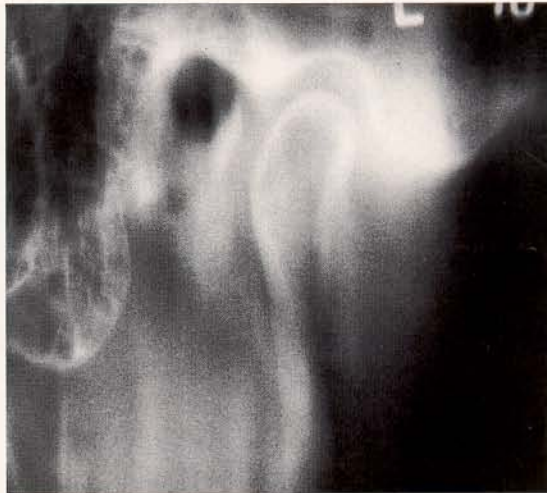
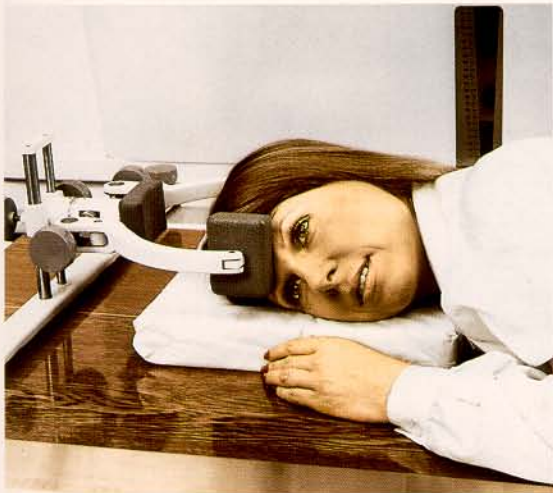


Tomography: Supplemental Examination of the Temporomandibular Joint (TMJ)

The clear representation of the TMJ, which is superimposed by the petrosal bone, presents high demands for the preparation of interpretable tomograms in both lateral and frontal planes. The X-ray tube and film cassette concomitantly execute single and very complex movements around the center of the selected layer; such movements allow clear reproduction of the structures selected for illustration, and blur superimpositions that are not located within the layer. The greater the movement (expressed in degrees), the thinner will be the thickness of the layer, and the sharper will be the

depiction. Spiral tomography results in the best depiction of the TMJ.

It is therefore very important to secure exact parallelism between the film cassette table and the position of the targeted anatomic structures, and therefore of the patient. On the other hand, tomograms prepared with more than 5 mm layer thickness (so-called zonographs) are more difficult to interpret. The articular disc can be rendered visible through the use of contrast material injected into the TMJ spaces.



333 Positioning of the patient for a lateral tomogram

A head-holding device should be used to provide precision positioning. The appropriate arrangement of the condylar axis must be calculated beforehand using axial projections.

334 Linear projection of the left TMJ

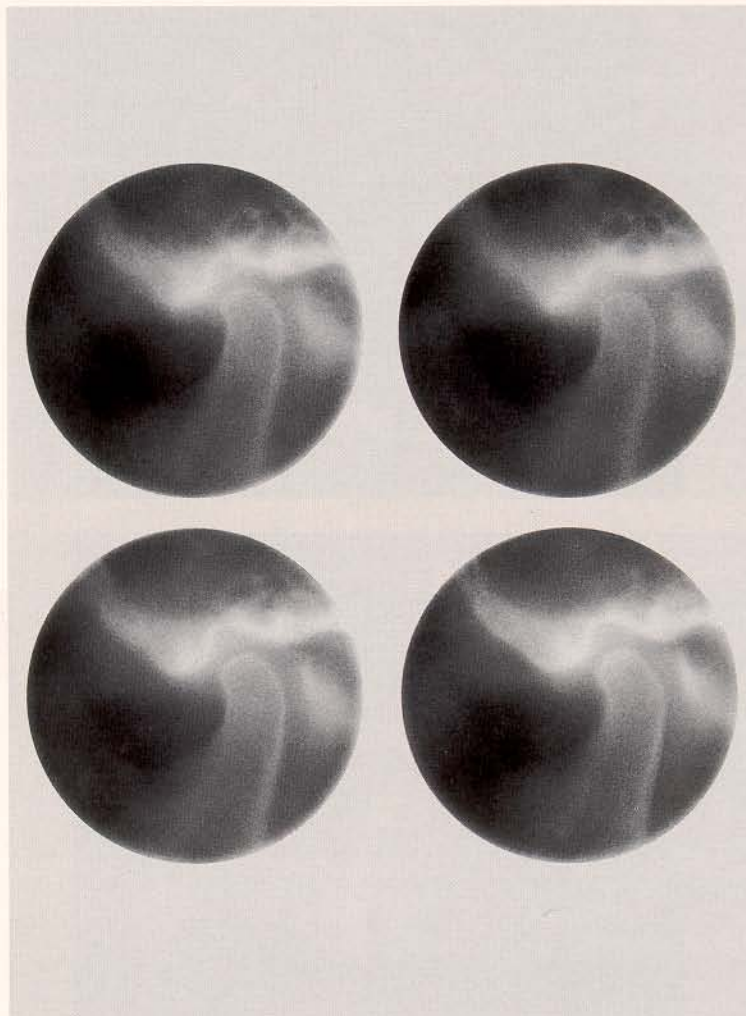
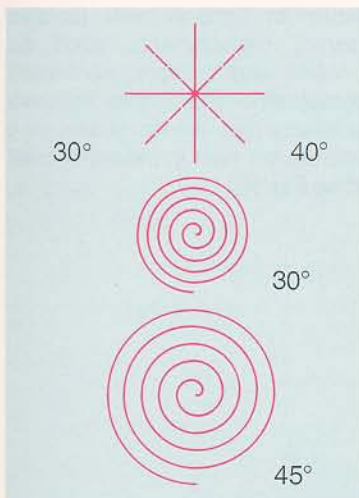
Despite good depiction of the positional relationships of the condyle to the fossa, this technique is still hampered by superpositioning of the (perpendicular) projected petrosal bone in the direction of movement.

335 Diagram of movements during linear and spiral projections

The 45° spiral projection results in thinner layers than the 30° spiral projection on the linear projection. Therefore, best results with the TMJ can be obtained using the 45° spiral technique.

336 Spiral projection of the left TMJ

These low-energy projections provide views of the TMJ that are free of superimposition, and clearly demonstrate the superiority of this technique. If a contrast medium is deposited into the upper and lower joint spaces before the exposure, it is possible to portray the disc and its behavior during the opening movement (arthrotomography).



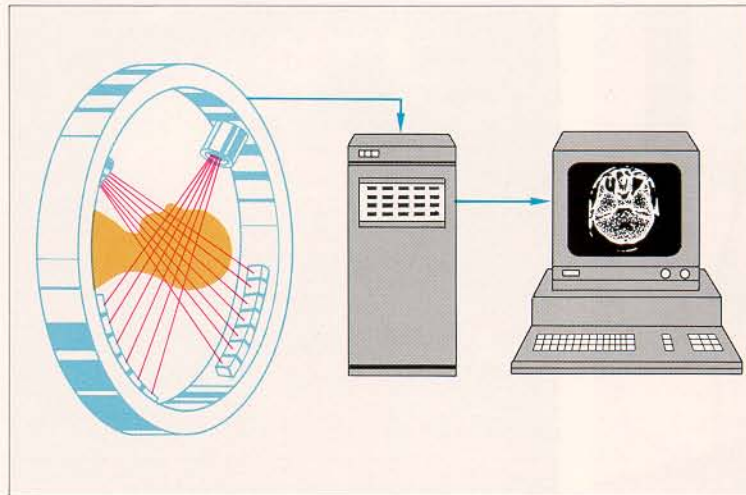
Computed Tomography (CT)

Since the invention of computed tomography (Hounsfield 1974), the examination technique for the facial skeleton and particularly the TMJ has entered a new phase. Ever more refined improvements of the X-ray tube placement and of the detector system have made it possible to reduce the initial exposure time of 5 minutes down to a few seconds, and this has made possible major advances. Modern equipment today consists of approximately 1000 detectors that can be tipped and are mounted in a fixed ring arrangement and an independently moved, fan-shaped single X-ray beam. Fourth-

generation CT is a robust instrument that permits localization of large lesions of the dental area and, on the basis of the measured density, even permits specific diagnosis. Using 2000 registered gray values that would be impossible to discern with the naked eye, specifically oriented sections ("windows") can be selected to portray in the final picture the gray scale of bony or soft tissue structures. Positioning of the patient for examination of the TMJ, however, is associated with difficulties due to the construction characteristics of the instrument.

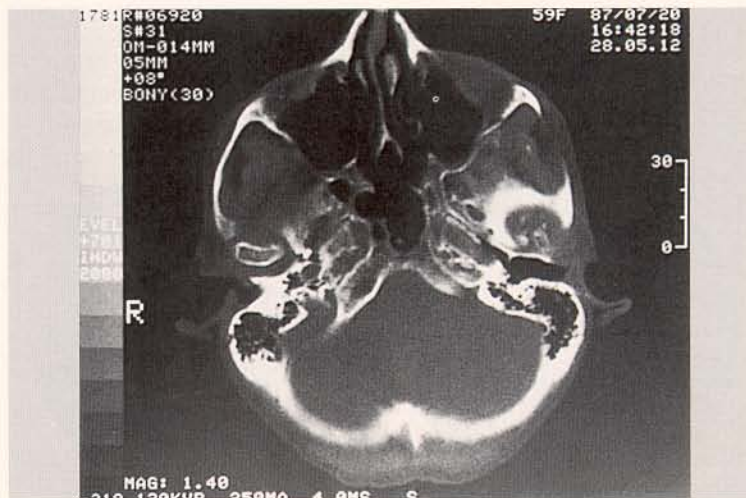337 Diagram of the function of a CT

The X-ray tube and the detector system are mounted in a frame that can be rotated and tipped. While the "frame" rotates around the axis of the patient, the fan-shaped X-ray beam scans an axial section of 2–12 mm thickness, and the detectors measure the radiation intensity behind the object. The volume elements of the selected layer are then computed and the picture is synthesized on the monitor.



338 Example of an axial depiction of the TMJs in the condylar plane

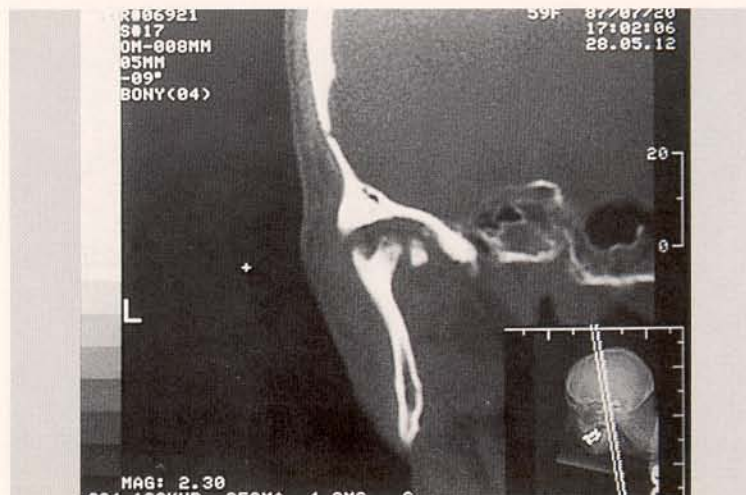This pictorial overview reveals an intact right condyle; the remnant of the left condyle is evidence of the postoperative condition. Note the expansive arthrosis at the joint fossa. (Courtesy Dr. K. Weibel, Baden)



Note: In patients with metallic dental replacements such as crowns and bridges, computed tomograms often have massive artefacts that render observation impossible near the alveolar crest (See Fig. 51).

339 Example of coronal direct scanning of the TMJs

Enlarged representation of the patient shown in Figure 338, with reclined skull. Note the skull positioning of the patient, who reclines face down for this CT (lower right insert). (Courtesy Dr. K. Weibel, Baden)

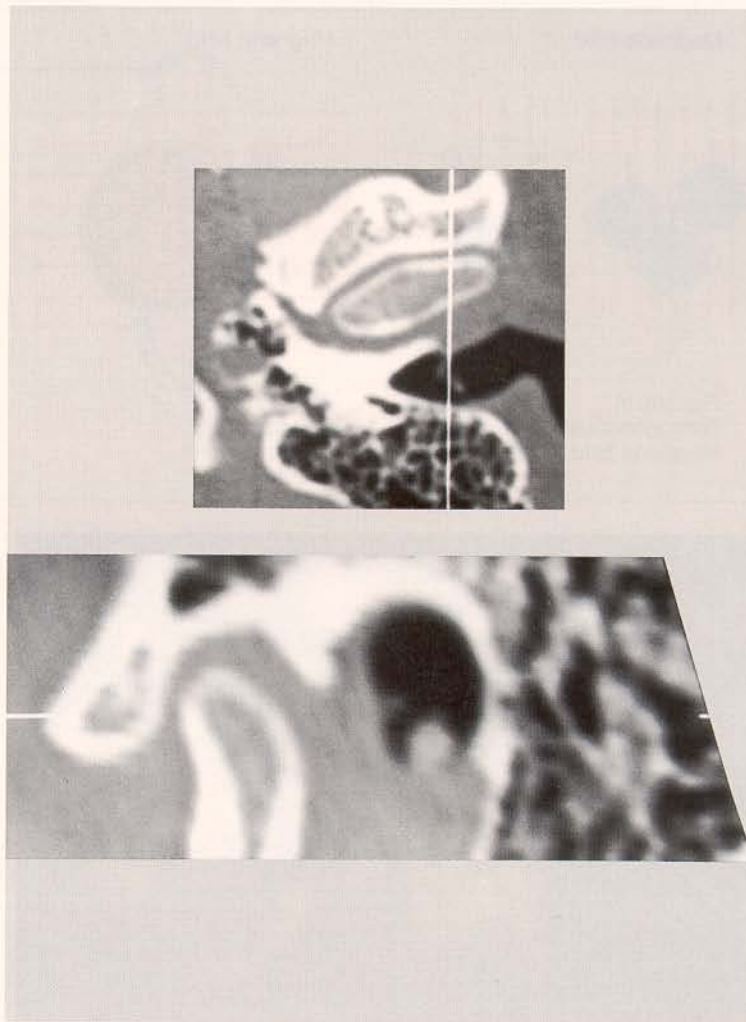


Selected Examples of Dental Radiography

Using numerous axial plane scanings, it is possible to reconstruct sections in the paramedian plane, e.g., for lateral depiction of the TMJ. Because the image formation of such reconstructed images is less than in direct projections, resolution of the final image is also not of the same quality. Improvement of the situation can only be achieved if the number of points in the photographic matrix is increased by means of direct projection.

For this reason, whenever possible the patient should be placed in the gantry in a very special position: The paramedian plane of the TMJ is positioned in the tipped

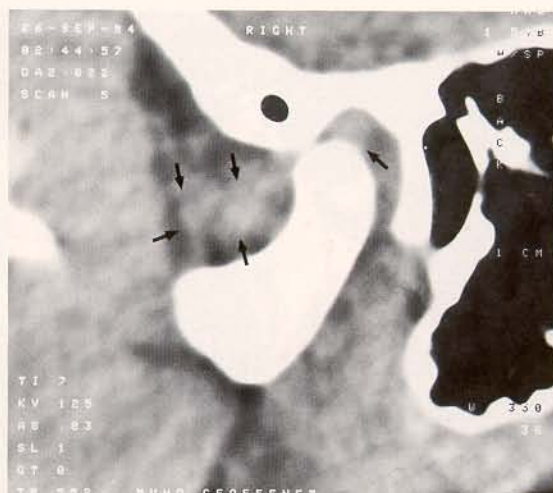
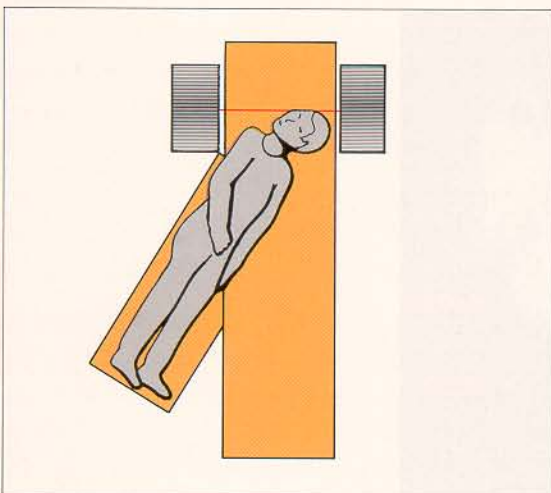
gantry in such a way that the plane is positioned like an axial projection. The result is a lateral and sharply depicted scan that can display the disc in at least two dimensions if the soft tissue window is selected. This represents great progress. In order to position the patient in this special way, various positioning aids are described in the literature; however, in reality such aids are usually impossible to use if the examination requires an extended period of time or if the patient is elderly.



340 Lateral reconstruction from axial CT layers represented with the bone window

This figure depicts a "zoomed" section from an axial layer at the height of the condyles. The white vertical line that traverses the mastoid cells, the lateral condyle region and the lateral portion of the articular eminence describes the plane of section for the computed lateral view of the TMJ (below).

...the patient is positioned in the gantry in such a way that the paramedian plane of the TMJ is positioned in the tipped gantry in such a way that the plane is positioned like an axial projection. The result is a lateral and sharply depicted scan that can display the disc in at least two dimensions if the soft tissue window is selected. This represents great progress. In order to position the patient in this special way, various positioning aids are described in the literature; however, in reality such aids are usually impossible to use if the examination requires an extended period of time or if the patient is elderly.



341 Direct lateral representation of the right TMJ using the soft tissue window

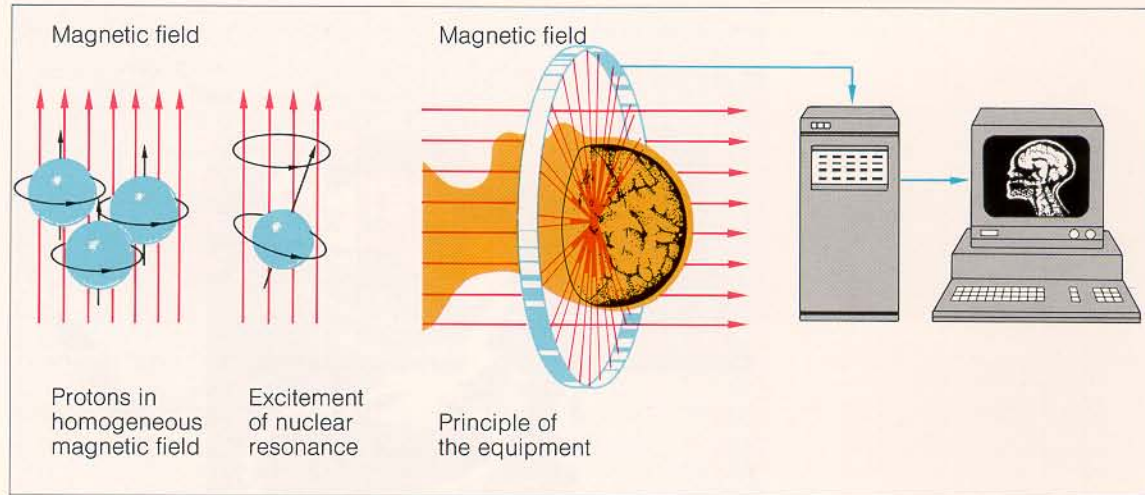
With the patient's jaw in rest position, the perforated and anteriorly displaced disc is visible (arrows). To produce this type of direct depiction, the patient must be placed in the gantry in such a way that the paramedian TMJ plane is positioned as for an axial projection. The diagram (left) shows how the patient is positioned in the gantry of the CT apparatus to get a lateral section through the TMJ region, as in an "axial" direct view. This positioning of the patient demands an additional lateral table, as shown. This position requires great flexibility of the patient's cervical vertebrae.

Magnetic Resonance Imaging

Magnetic resonance imaging, also known as magnetic resonance tomography, is an image-producing technique without the use of ionizing radiation. The creation of such an image involves the use of atoms, e.g., hydrogen atoms, which possess a nucleus with a magnetic moment and a nuclear rotatory impulse. Hydrogen is present in sufficient quantities throughout nearly all body tissue and its nuclear constituents (the protons) possess the characteristics of gyroscopes and magnets. The application of an external magnetic field

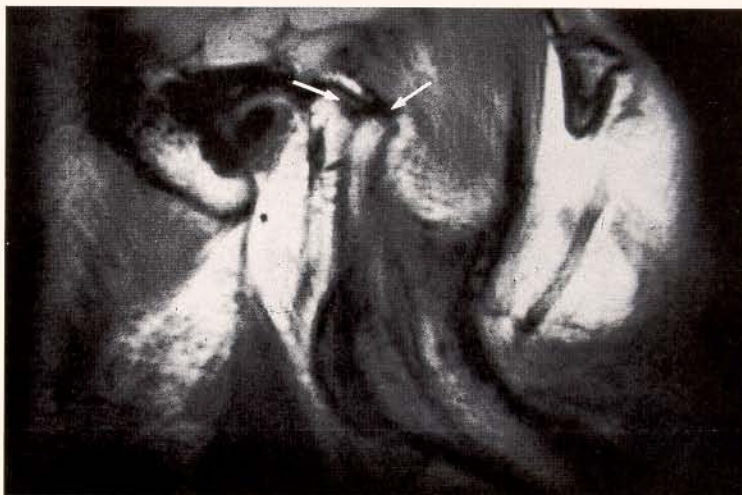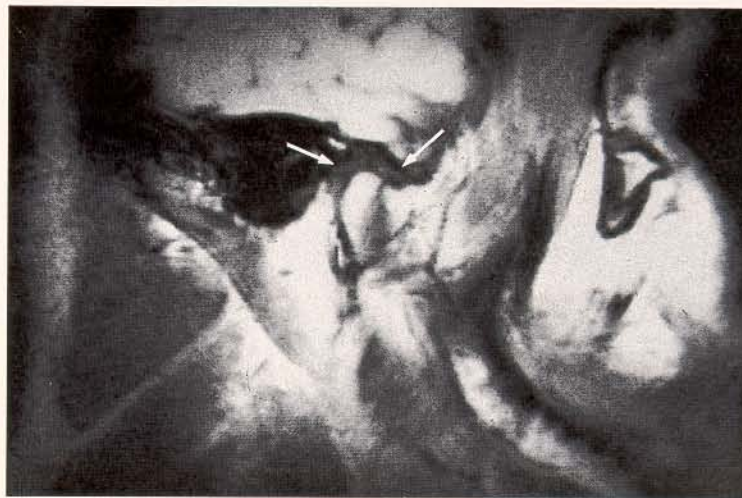causes the magnetic moment of the nucleus to align parallel to the field lines (see Fig. 342). An electromagnetic pulse in resonance frequency applied perpendicular to these lines of field, tips the magnetic moments away from their primary direction and forces them to elicit a signal that can be processed into an image with the help of a computer. The image will have signal-rich (light) and signal-poor (dark) zones. A qualitatively satisfactory TMJ image requires the use of special surface coils.

342 Functional diagram for magnetic resonance imaging



343 Lateral magnetic resonance images of a closed and an open normal TMJ

The typical appearance is presented in these two pictures. With regard to the details that are of interest to us, it can be shown that the compact bone elicits no signal (e.g., black), while marrow bone with its higher water content elicits an enhanced signal (e.g., lighter). The articular disc is marked darkly; it appears in the proper anatomic position regardless of whether the jaw is closed or open (arrows). (Courtesy Dr. E. Steinhäuser, Erlangen)



Note: Elderly patients who are depressed, or patients with claustrophobia may require premedication to reduce anxiety before MRI examination.

Caution: Patients with cardiac pacemakers or other implants must not be exposed to the magnetic effects of this instrument.

Selected Examples of Dental Radiographic Diagnosis

Anomalies of Dental Development and the Teeth

Endogenous as well as exogenous factors can directly or indirectly elicit abnormalities of the dental lamina, which develops in close harmony with the surrounding tissues. Viewed in this way, the goal of this chapter is to summarize a large number of anomalies of the teeth that the dentist in daily practice may encounter as isolated cases or as serendipitous radiographic observations.

The list of abnormalities is long, and includes, for example, hyperodontia, hypodontia and anodontia, as well as the persistence and the inclusion of deciduous teeth, the retention of permanent tooth buds and the tooth primordia of supernumerary teeth such as the mesiodens, supernumerary premolars of the mandible and supernumerary molars of the maxilla. Such abnormalities can be considered as odontoma-related forms.

Also included are dysplasias of the tooth crowns such as dens in dente, double tooth buds and “twinning” of the tooth crowns, as well as abnormal development of the tooth roots such as concrescence and the taurodont. Concretions of maxillary molars call to mind the complex odontoma of this region that occurs preferentially in women.

Amelogenesis imperfecta or hereditary enamel hypoplasia assumes a particular place in the category of anomalies of dental development, as do the other enamel hypoplasias with their sex-linked inheritance pattern of incomplete dominance as an ectodermal odontopathy. The radiographic examination of such lesions is of importance mainly for forensic reasons, and is of little diagnostic significance.

On the other hand, osteogenesis imperfecta is a mesodermal malformation with simple dominant inheritance. It is characterized by dentin malformation and by shortened roots and altered root form. Anomalies of this kind may be associated with corresponding developmental anomalies of the skeleton, and it may therefore be more reasonable to discuss them under the rubric “osteopathy.” The features of such lesions are usually only described in radiographic terms, because a targeted histologic examination is usually not performed in a living patient.

Numerous syndromes are accompanied by odontodysplasias. Their appearance in radiographs should therefore always lead the practitioner to a careful search for their origins. The various forms may be reviewed in the appropriate literature.

Most developmental malformations can only be correctly diagnosed by means of a complete radiographic examination of the dental structures. For definitive diagnosis in the individual case, the use of panoramic radiography as well as foil-free films for targeted or special projections is recommended.

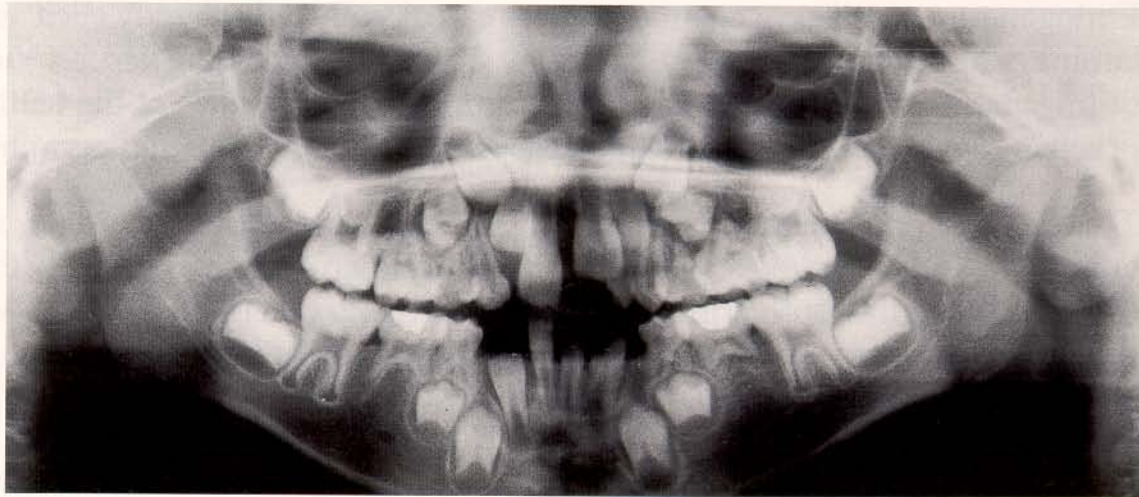
Congenitally Missing Teeth, Retention and Inclusion

We have selected three typical examples from the myriad of cases: The relatively common congenitally missing second premolar, which often leads 1) to the persistence of the second deciduous molar, 2) the tipping of the first permanent molar and the other molars, and 3) the inclusion of deciduous molars in their

original location at the deciduous occlusal plane. Note that retained deciduous molars and retained tooth buds of permanent molars must be followed up using panoramic radiography at regular intervals if surgery is not immediately indicated.

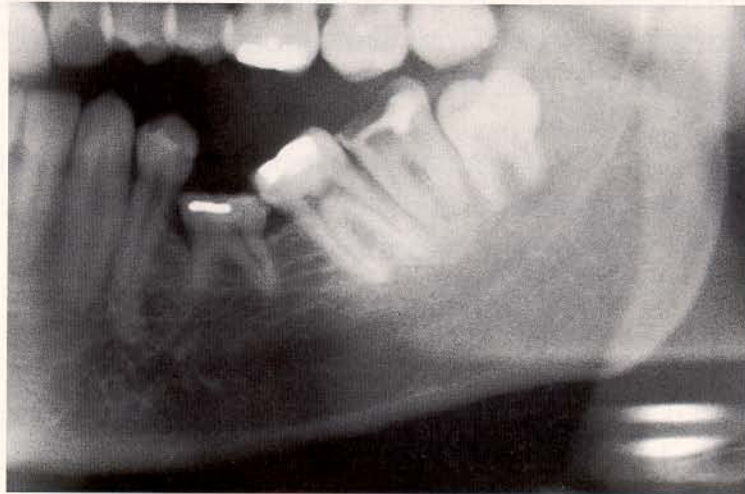344 Hypodontia in a 7-year-old female

Note the complete congenital absence of all permanent tooth buds of the second premolars and the retarded eruption in the maxillary and mandibular anterior areas.



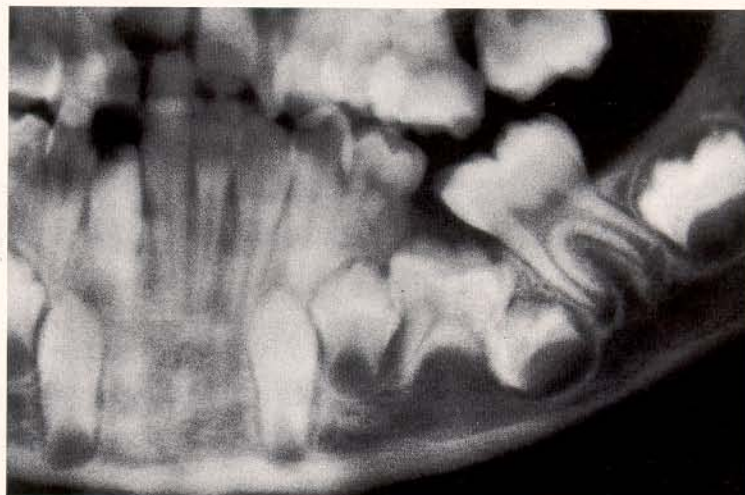
345 Inclusion of a persisting deciduous tooth 75

Permanent tooth 35 was congenitally absent. Note that tooth 34 as well as teeth 36, 37 and 38 have tipped toward the deciduous molar in this 23-year-old female. As a consequence of a tongue thrust habit, this patient also exhibited a lateral open bite.



346 Entrapment of deciduous tooth 75

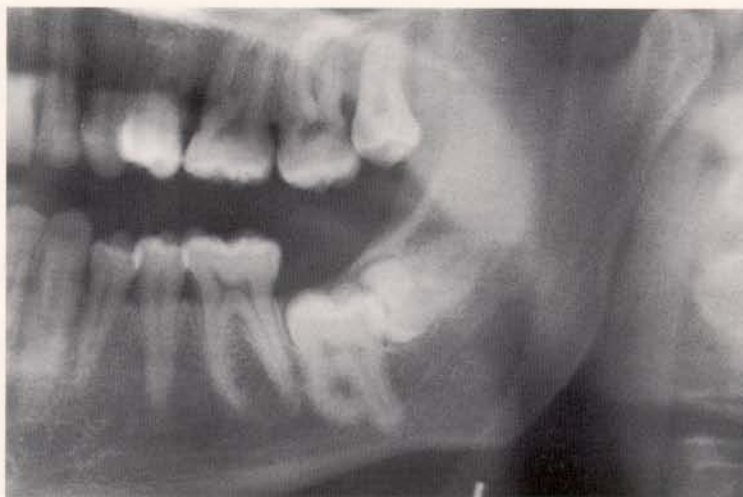The mesial tipping of tooth 36 enhanced the intrusion of the already entrapped tooth 75. This appears to have led to retention of permanent tooth 35 and inhibition of its further development.



Retention, Malocclusion and Resorption

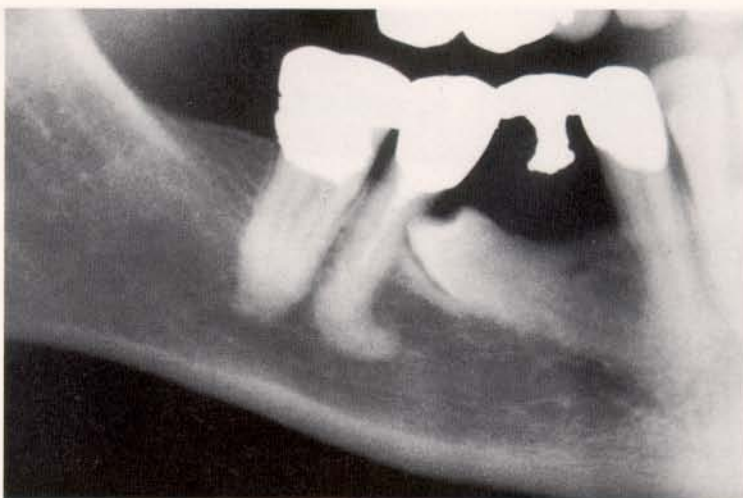Because early retention of teeth often leads to malocclusion and TMJ problems in younger individuals, it is important to remember that at every initial examination all teeth must be accounted for. Retained teeth, which are often discovered accidentally on panoramic radiographs, may have been responsible for unexplained

problems that patients experienced over many years. Failure to perform a complete examination of all patients may sometimes lead to uncomfortable surprises and to an unnecessary loss of confidence by the patient.



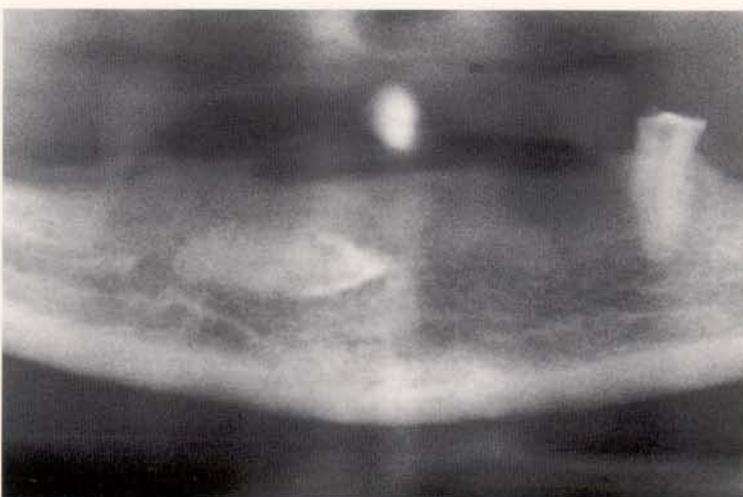347 Retention of tooth 37 by the horizontally impacted tooth 38 in this 26-year-old male

Note the incomplete formation of the mesial root of tooth 37 and the opening of the interdental space between teeth 26 and 27, the latter caused by a premature occlusal contact between 36 and 27.



348 Retention of tooth 44 in a 74-year-old female

The crown of the retained tooth is positioned buccally.



349 Retention of tooth 43 in a 53-year-old female

Note the loss of the follicular sack. This is always an indication of the initiation of crown resorption or the formation of ankylosis.

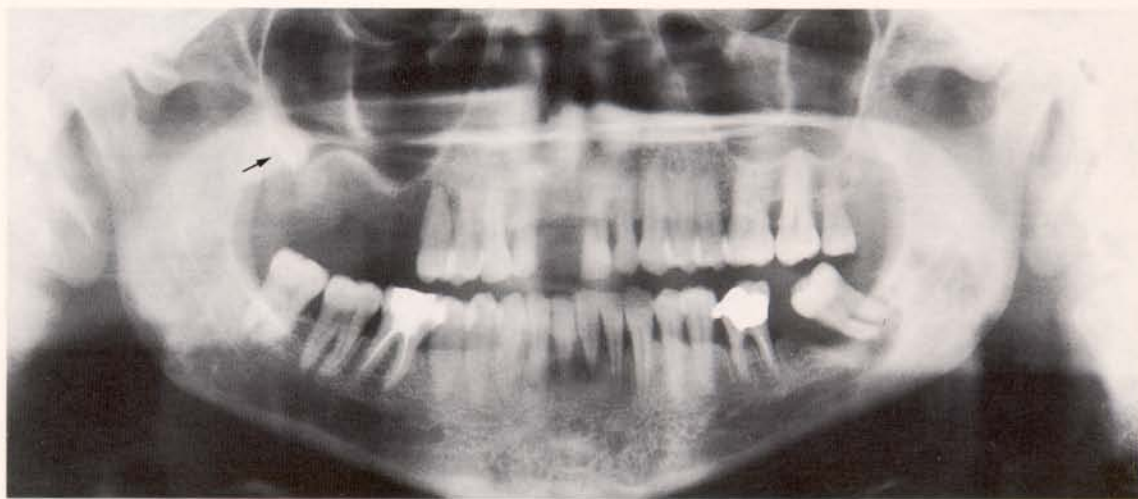
Retention of Supernumerary Teeth, Resorption of Retained Teeth

Supernumerary maxillary molars such as upper fourth or fifth molars are almost never detected in the conventional radiographic survey. Such supernumerary teeth represent a focus for the formation of follicular cysts developing in the sinus, and must therefore be removed. The syndrome of cleidocranial dysostosis is mentioned

in this context because it is typified by hyperodontia as well as skeletal developmental disturbances. Retained teeth whose crowns resorb often represent the etiology of undiagnosed problems over many years. Only the panoramic radiographic technique can routinely permit detection of such processes.

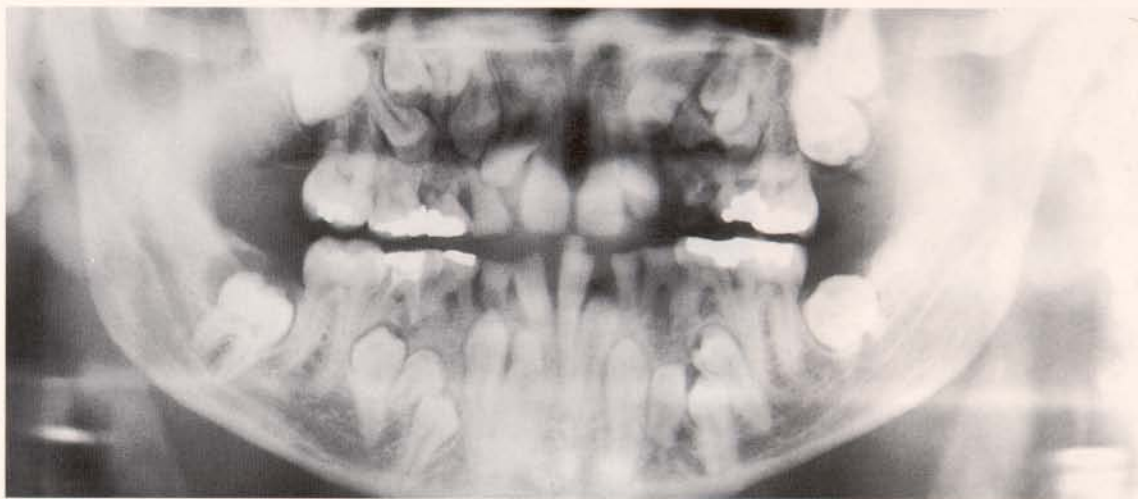
350 Retained tooth 18 in a 42-year-old female

The extreme position (arrow) of this impacted tooth provides evidence why such teeth that often elicit "pains of unknown origin" cannot be detected without panoramic radiography. Note especially the reactive sclerosis on the floor of the sinus! However, the precise location of this tooth cannot be defined from the panoramic film alone (p. 89ff.).



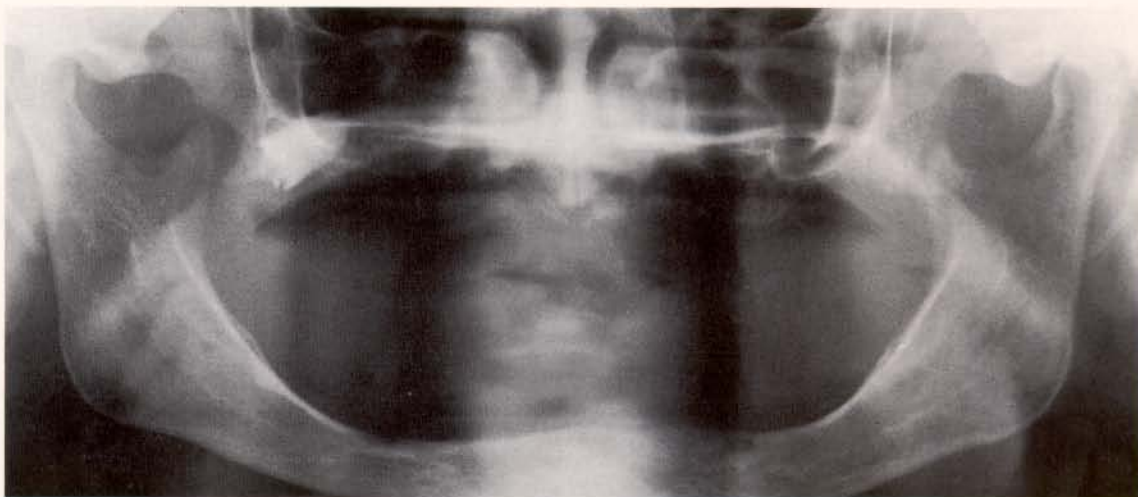351 Duplication of tooth primordia extending into the premolar region

This observation is a signal symptom of hereditary cleidocranial dysostosis (Marie-Sainton, 1897). The syndrome also manifests the lack of collar bones, skeletal anomalies, follicular cysts with tooth impaction and hyperodontia, as in this 13-year-old male.



352 Retained tooth 18 exhibiting substantial crown resorption

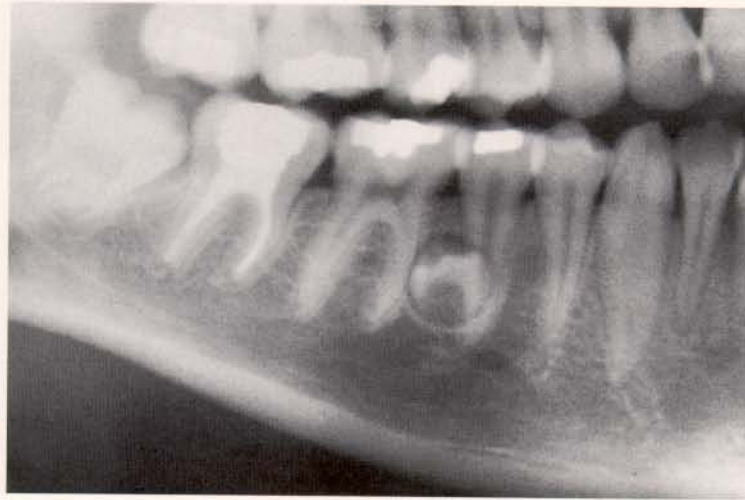
This 83-year-old female had complained for years of nebulous pain in the TMJ region.



Retained Teeth in Unusual Locations

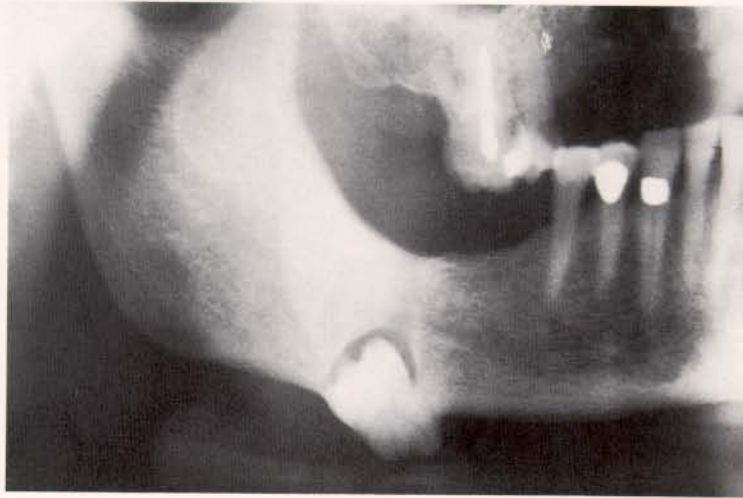
Supernumerary mandibular premolars are usually oriented with their crowns towards the lingual; this is easy to confirm using the unilateral occlusal radiograph with carefully targeted central ray in the direction of the long axis of the teeth. Extreme retention and impaction of mandibular molars, such as depicted in Figure 354

are rare, but without the use of panoramic radiography they are often not detected. Supernumerary rudimentary maxillary fourth or fifth molars may be superimposed upon the normally configured maxillary molars and are often difficult to discern even with special projections.



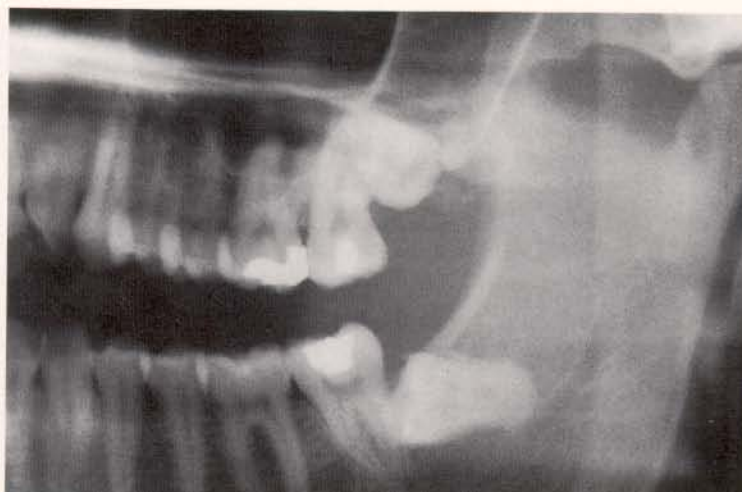
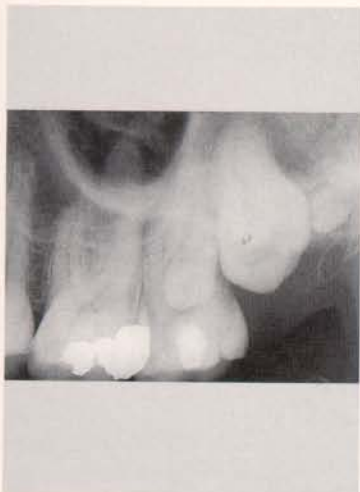353 Supernumerary mandibular premolar in a 16-year-old female

This type of supernumerary premolar, with its usually rudimentary crown is almost always localized toward the lingual. In such cases the unilateral occlusal radiograph of the mandible is indicated.



354 Retained tooth 48 in 57-year-old male

It was possible to actually palpate this tooth extraorally. The danger of spontaneous mandibular fracture exists if inappropriate surgical technique is applied. The clinician should consider the use of CT if such teeth exhibit large follicular cysts.



355 Retention of several supernumerary rudimentary maxillary molars

This is a comparison between the panoramic radiograph (*right*) and the periapical film (*left*). The picture is reminiscent of a mature compound odontoma. The tooth, which is located mesially and palatally to tooth 28, may be missed without the periapical radiograph. It is for this reason that in cases of diagnostic difficulties, the panoramic film should be supplemented with periapical radiographs.

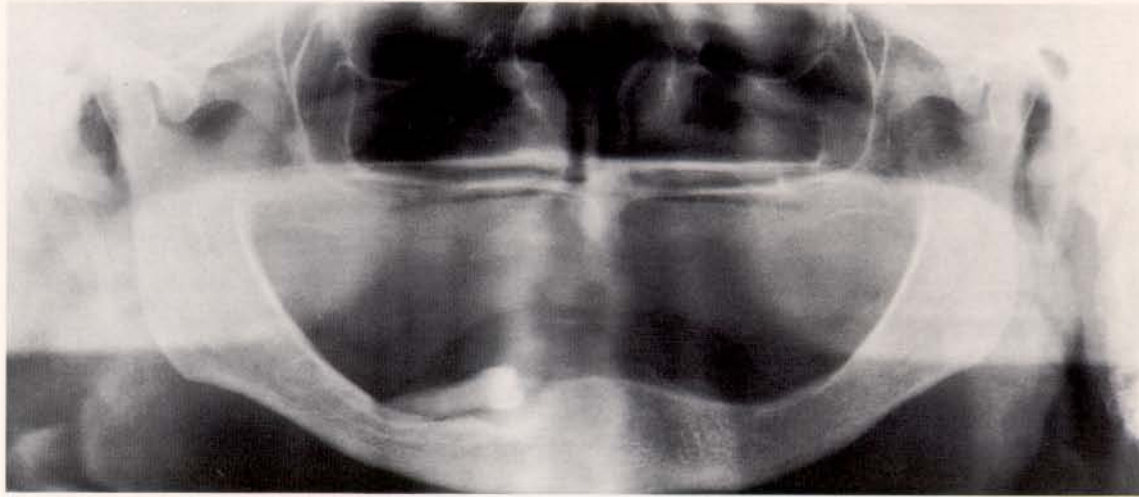
Retained and Ankylosed Teeth

Presented here is an additional case of an impacted tooth in an unusual location; this tooth was the cause of undiagnosed difficulties throughout many years. Ankylosed teeth are, by definition, teeth whose roots are fused with the alveolus in such a way that no periodontal ligament space can be detected on the radio-

graph. Such teeth are therefore usually diagnosed as retained or impacted. Retained teeth whose crowns lack a follicular sac surrounding them are classified under the term ankylodontia because they appear to be fused with the surrounding bone.

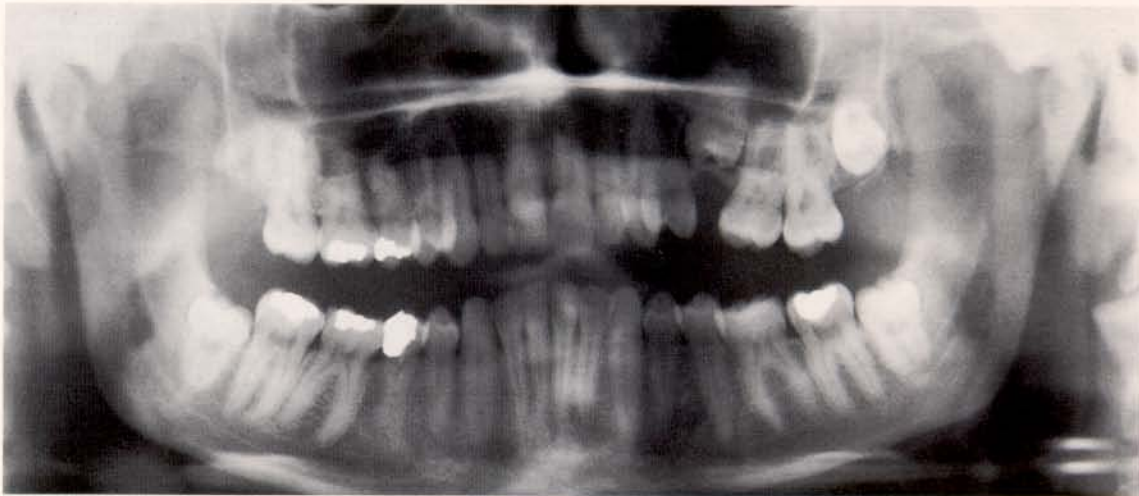356 Retained tooth 45 in a 74-year-old female

This tooth was completely covered by mucosa. Its crown rested upon the mental foramen and was not clinically visible.



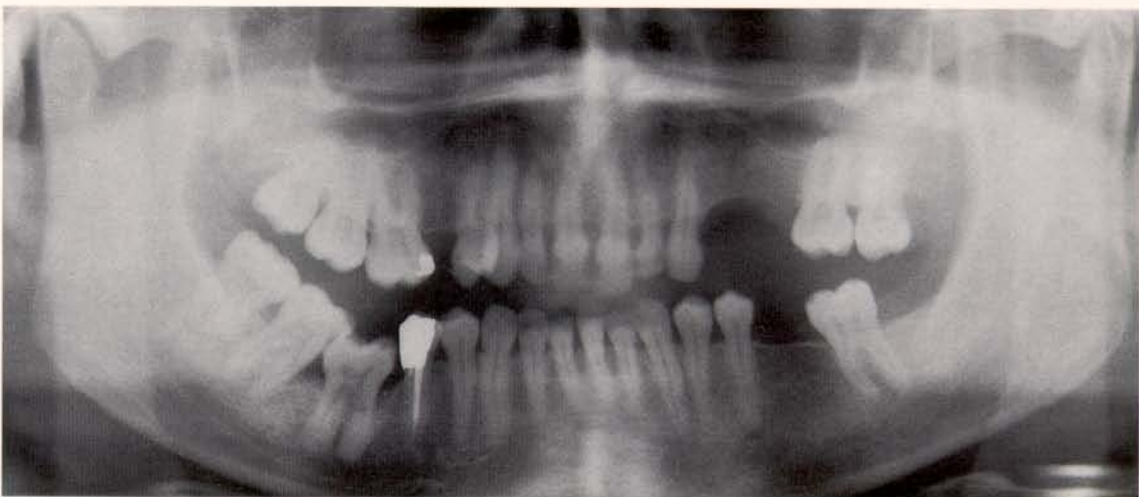
357 Tooth 25 ankylosed at the floor of the sinus following persistence of deciduous tooth 65 in a 25-year-old female

Note the tipping of the adjacent permanent teeth.



358 Ankylosed tooth 46 in an included position in a 36-year-old male

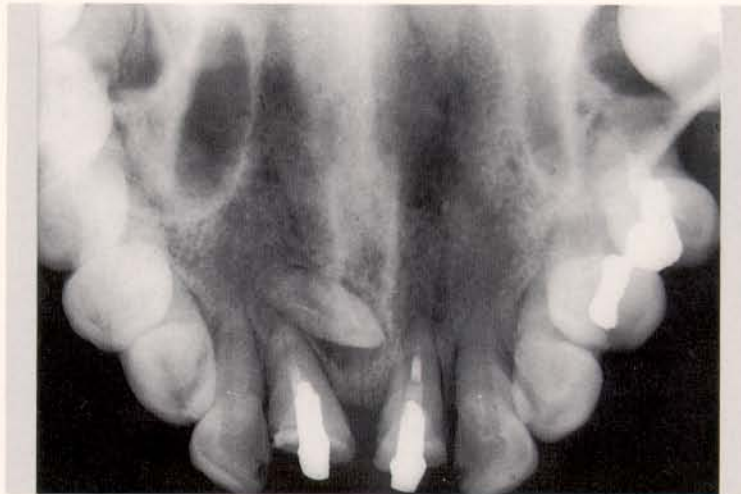
Note the lack of a periodontal ligament space. The exact depiction of periodontal ligament space is impaired by the printing process.



Mesiodens, Gemination, Taurodontism and Dens in dente

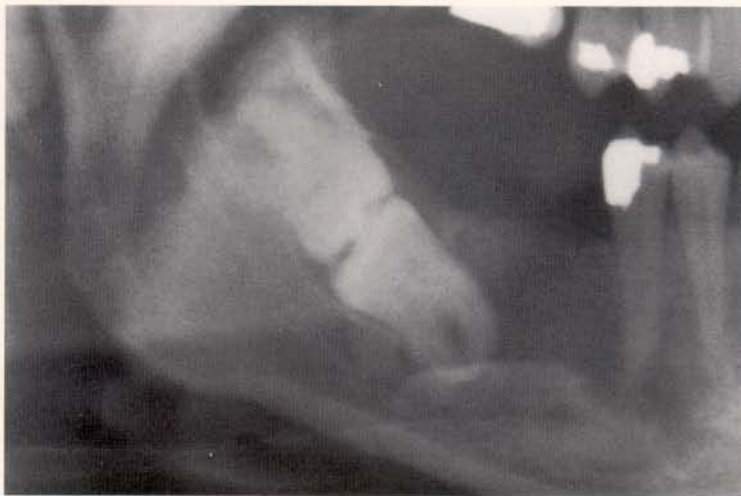The supernumerary central incisor has inherited the special designation of mesiodens because of its relatively common occurrence. The mesiodens is the result of a developmental anomaly of the dental organ in the area of the median suture. This supernumerary tooth is often very poorly developed and should be localized radiographically using the so-called tube shift principle as

described by Clark (p. 84ff.) and not only with an occlusal film. Gemination is very rare, being observed almost exclusively in the region of the mandibular molars. Additional dental developmental anomalies are represented by the taurodont and the invagination of the dens in dente.



359 Mesiodens as seen in an occlusal film of a 44-year-old female

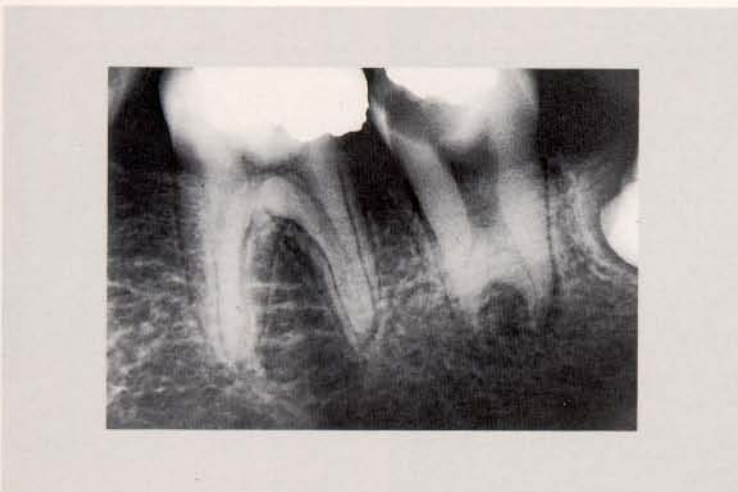Detection of mesiodens can be achieved with an occlusal film, but this will not provide precise localization. The mesiodens can be visualized using the horizontal localization technique (see p. 85ff.).



360 Gemination of teeth 48 and 47

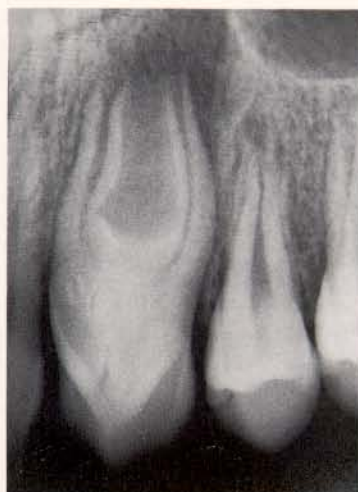The two mandibular molars developed simultaneously in a single follicular sac.

Courtesy Dr. H. Aronis, Bruxelles.



361 Taurodont

Tooth 37 exhibits a typically elongated pulp chamber and short, dilacerated roots.



362 Dens in dente

A particularly remarkable case of dens in dente exhibiting pulpal necrosis with its attendant periapical lesion.

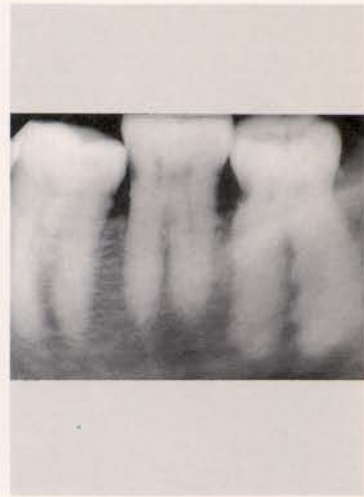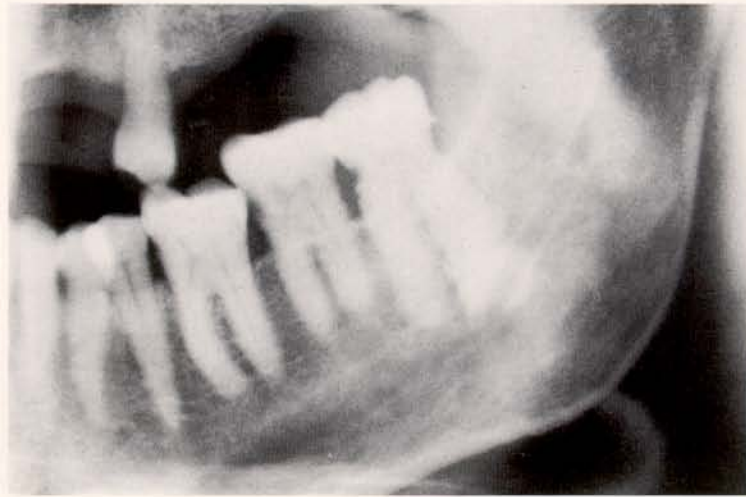
Hypercementosis and Enamel Pearls

Hypercementosis is observed relatively frequently on nonvital teeth. Its presence represents an expression of host defense against chronic infection. If hypercementosis occurs adjacent to vital teeth, the differential diagnosis must include osteopathy, e.g., Paget's disease,

which is sometimes detected in elderly males. Enamel pearls can only be well detected radiographically if they extend into the interdental area. Enamel pearls may be incorrectly diagnosed when they appear as the result of superimposed radicular processes of molar teeth.

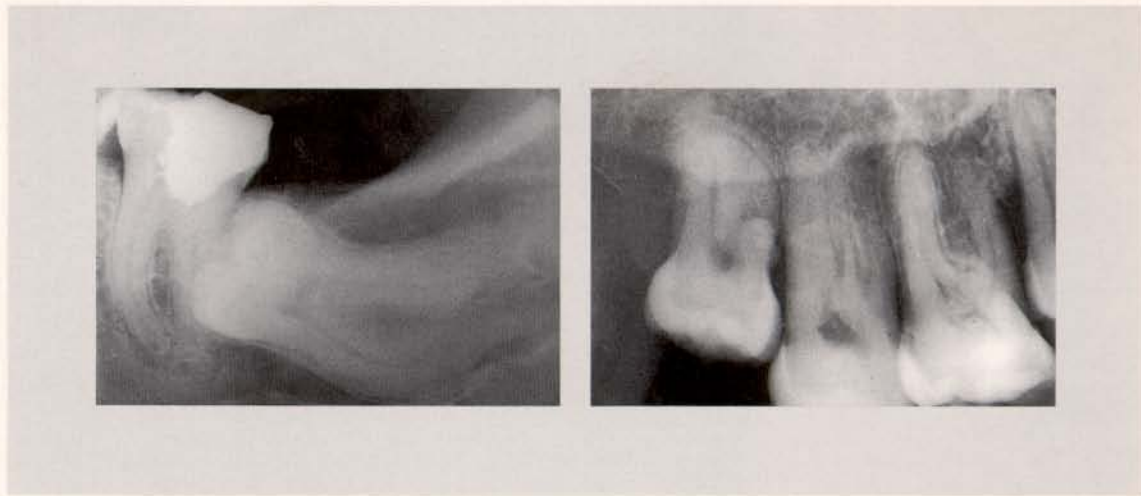
363 Hypercementosis shown on panoramic and periapical radiographs for comparison

If cemental hypertrophy is detected in elderly men, one must consider the possibility of osteitis deformans (Paget's disease).



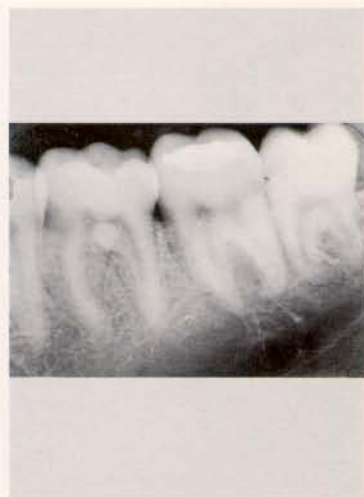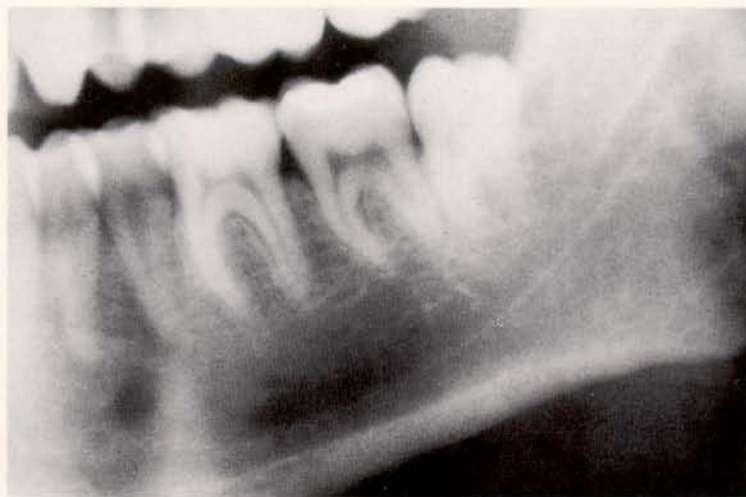364 Hypercementosis

This condition occurs most frequently in nonvital teeth as an expression of host defense. However, it may also occur near vital teeth, either as a corollary condition of osteopathy or an idiopathic lesion.



365 Enamel pearl

Enamel pearls often occur near the cemento-enamel junction (tooth 18, mesial), as a hamartoma in the category of odontogenic tumors.



366 Enamel pearl

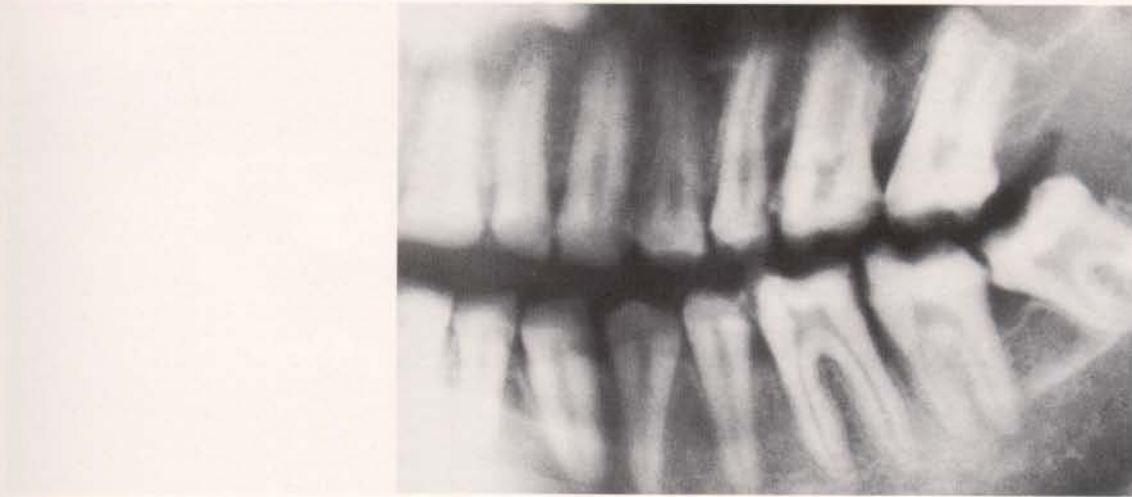
The enamel pearl is often incorrectly diagnosed because of the angle of the radiographic projection, for example in bi- and trifurcations of molars, where an apparent pearl may result from the addition effect. Right: An apparent enamel pearl on tooth 36 is not visible on the panoramic radiograph (left) because of the different radiographic projection.



Amelogenesis Imperfecta

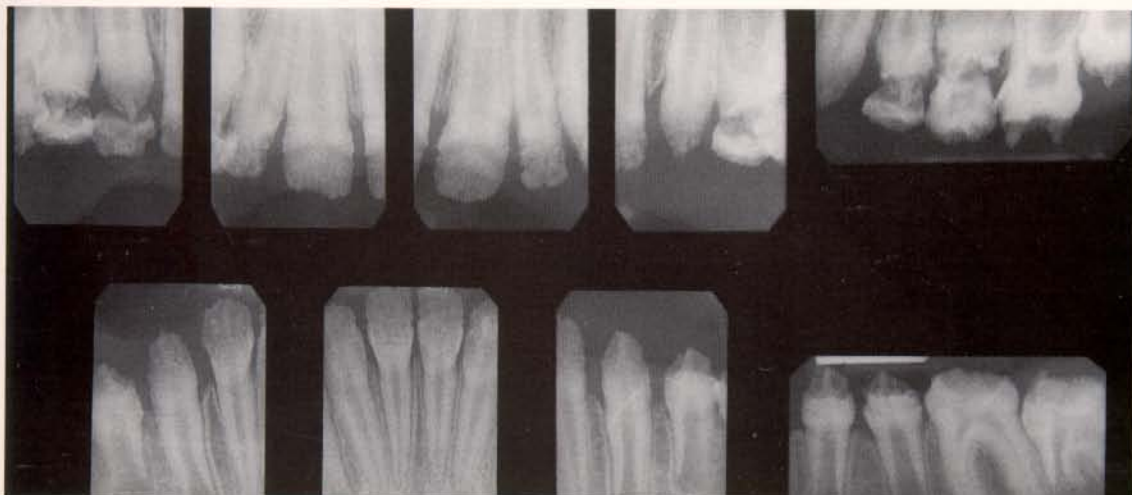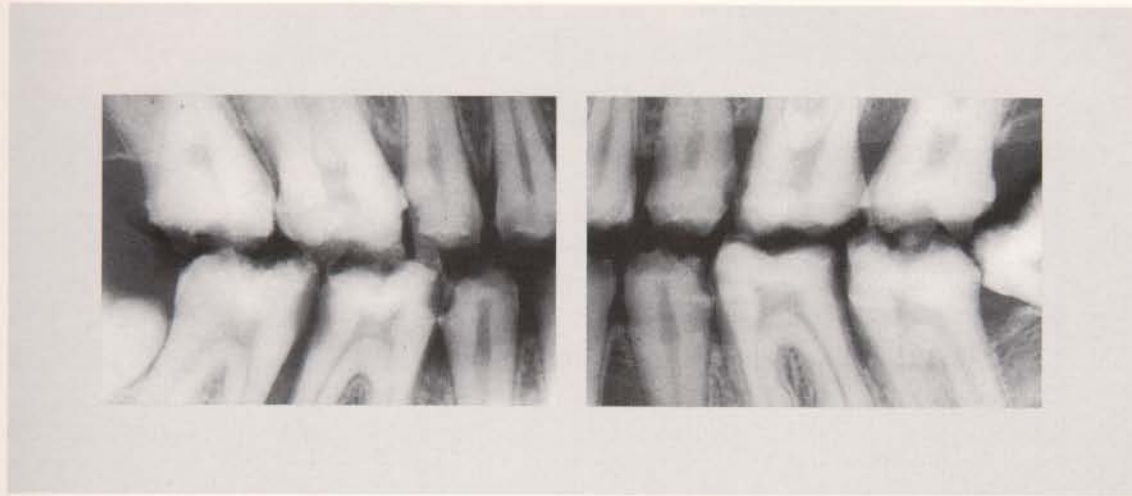
Amelogenesis imperfecta or hereditary enamel hypoplasia is an ectodermal odontopathy with incomplete dominance and sex-linked heredity. It presents clinically as a typically brown discoloration of the enamel, which is either relatively smooth and thin (typical in

males), or vertically ridged (typical in females). While classical examples of enamel hypoplasia need not be examined radiographically to arrive at a diagnosis, a forensic indication for radiographic analysis may exist.



367 Amelogenesis imperfecta as it appears in a panoramic radiograph and a bite-wing film of the same patient

Of note is the extremely thin layer of enamel on the tooth surfaces (male form).



368 Detail from the radiographic survey of a case of amelogenesis imperfecta

The enamel is vertically ridged and relatively thick (female form).

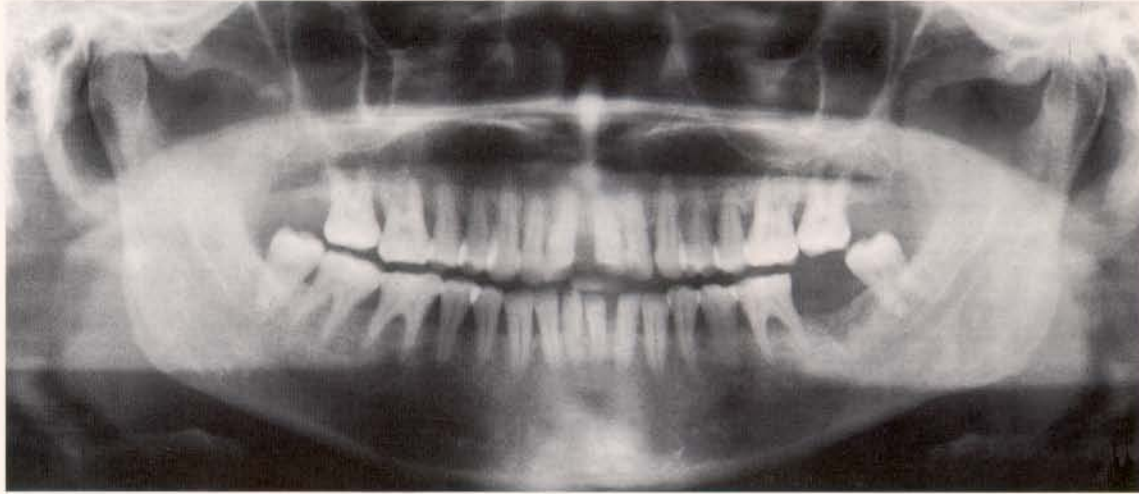Dentinogenesis Imperfecta

Dentinogenesis imperfecta is the result of a mesodermal malformation with disturbance of dentin formation, and is a disorder that is inherited as a simple dominant trait. It may also be combined with osteogenesis imperfecta. Because of the short, conically deformed roots, the

crowns of the teeth appear large and plump. A thin layer of enamel covers the malformed dentin; the dentin is completely insensitive. A typical sign of the malformation is the rapid reduction in size of the pulp chamber, which is initially quite large.

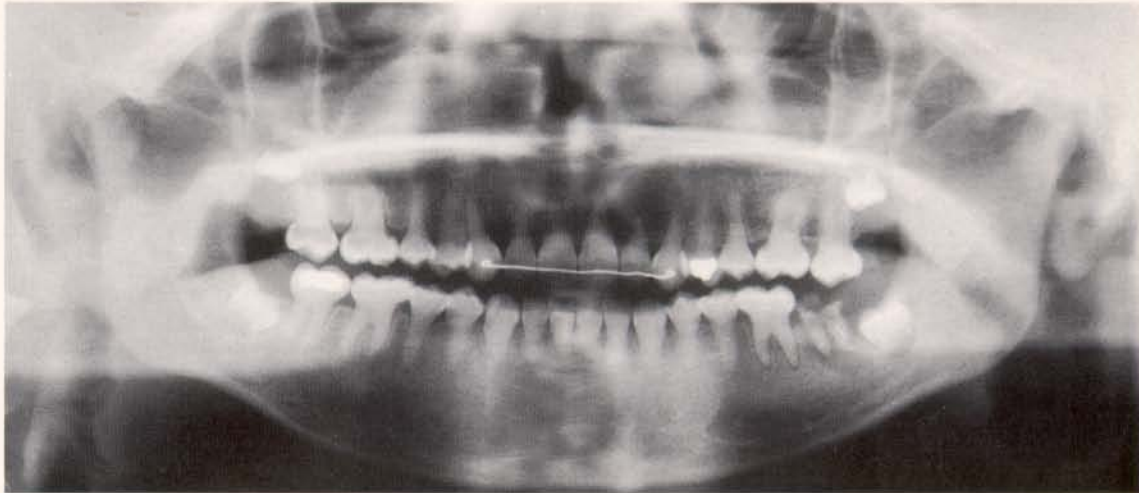
369 Dentinogenesis imperfecta in a 38-year-old female

This case exhibits a mild form with slender roots. The condition is inherited as a simple dominant trait. The thin layer of enamel exhibits cracks. Enamel and dentin are gradually worn away due to attrition.



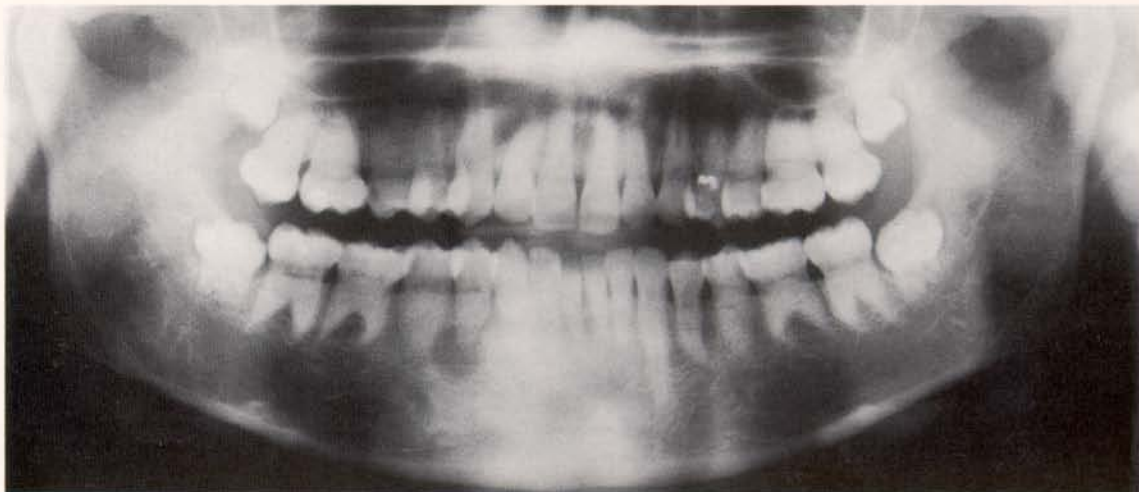
370 Dentinogenesis imperfecta in an 11-year-old female

Note the typical disproportion between crowns and roots. Such patients may also exhibit signs of osteogenesis imperfecta. Note that the pulp chambers and the root canals have already become obliterated.



371 Dentinogenesis imperfecta in a 19-year-old female

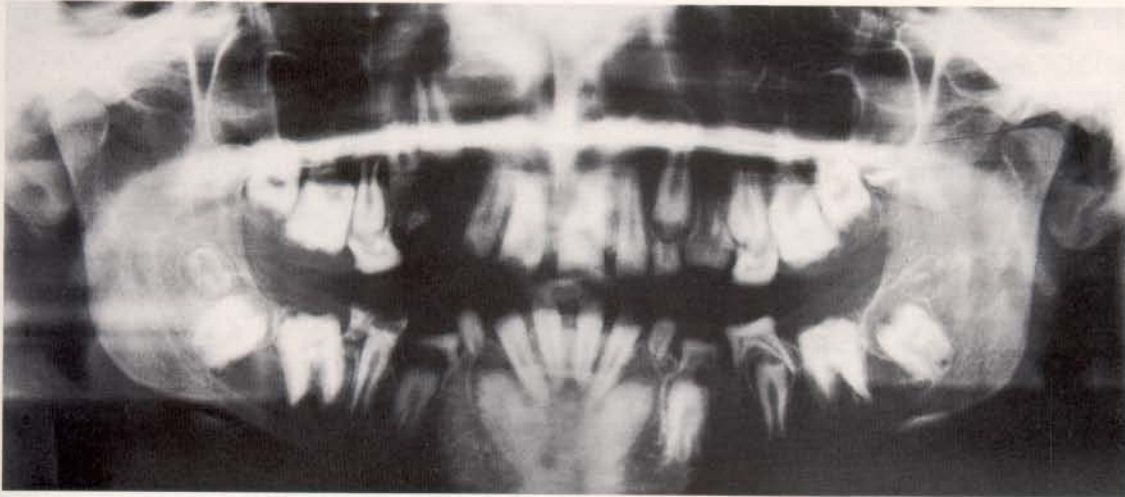
The pulp chambers, which were initially large, are already considerably reduced in size. The roots are shorter than normal and bizarre in shape.



Additional Dental Dysplasias

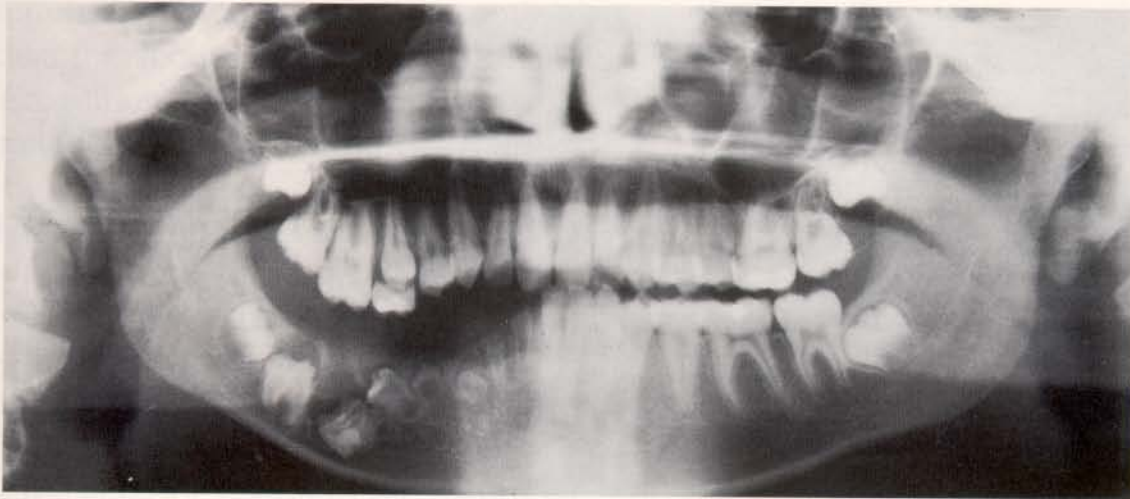
Odontogenesis imperfecta with its attendant malformation of teeth and disturbances in eruption patterns results from perturbation of odontoblast function. This is frequently combined with dysfunction of osteoblasts, a condition known as osteogenesis imperfecta. In addition to this genetically determined form, local odonto-

genic dysplasias of uncertain etiology may also occur. A peculiar form of odontogenic dysplasia is the so-called "shell tooth," which is characterized by a completely formed layer of enamel with an apparently enlarged pulp chamber and complete absence of root formation.



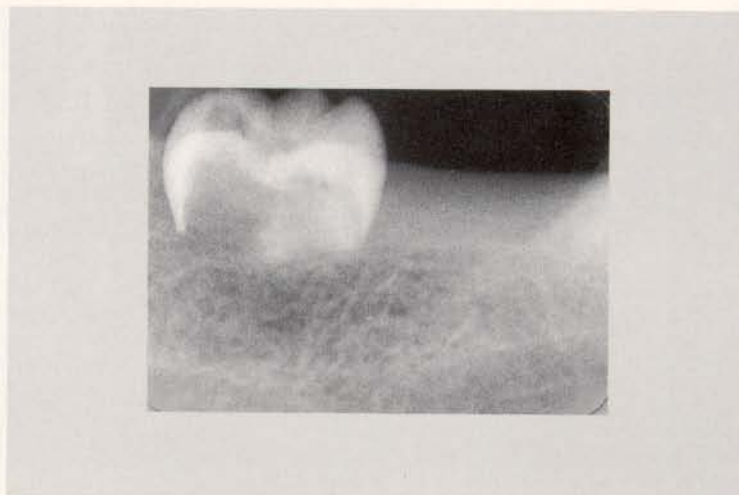
372 Odontogenesis imperfecta

Note that the pulp chambers vary considerably in size. The malformed teeth do not erupt. All parts of the teeth are involved. This condition is often observed in patients who also suffer from osteogenesis imperfecta.



373 Odontogenic dysplasia localized to the right side of the mandible

Note that all dental structures are malformed, and the teeth have failed to erupt. The etiology is assumed to include early childhood trauma that led to local disturbance of odontoblast function.



374 "Shell tooth"

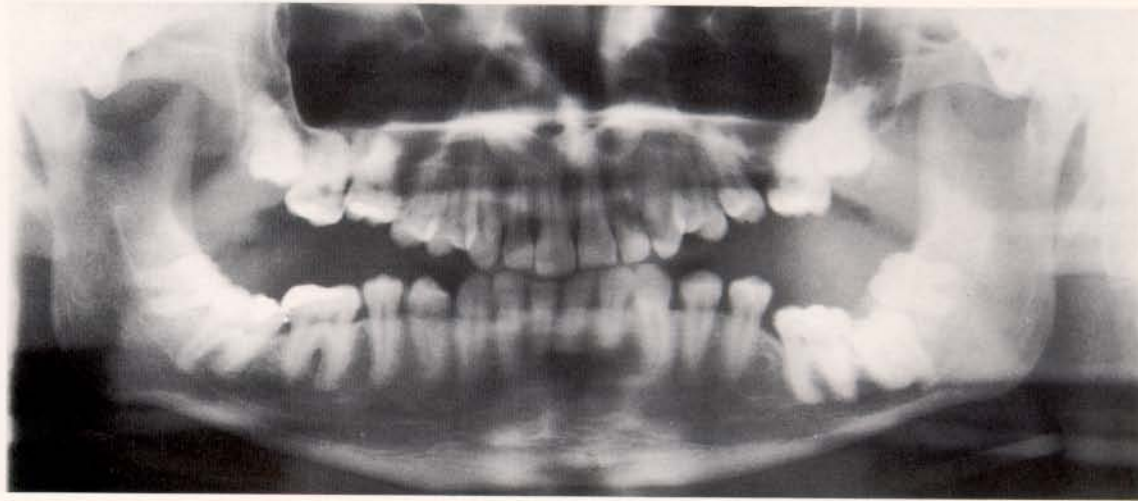
This is one form of dentinogenesis imperfecta in which the roots do not form at all and the pulp chamber appears to be enlarged.

Posterior Open Bite with Macroglossia and “Idiopathic Root Resorption”

Although neither of these conditions fits strictly into this chapter, they are presented here to provide a comparison with the previously presented cases of dentinogenesis as well as odontogenesis imperfecta.

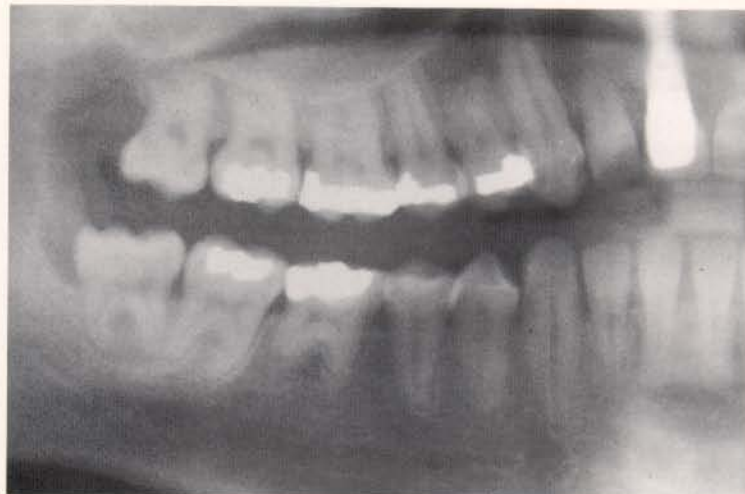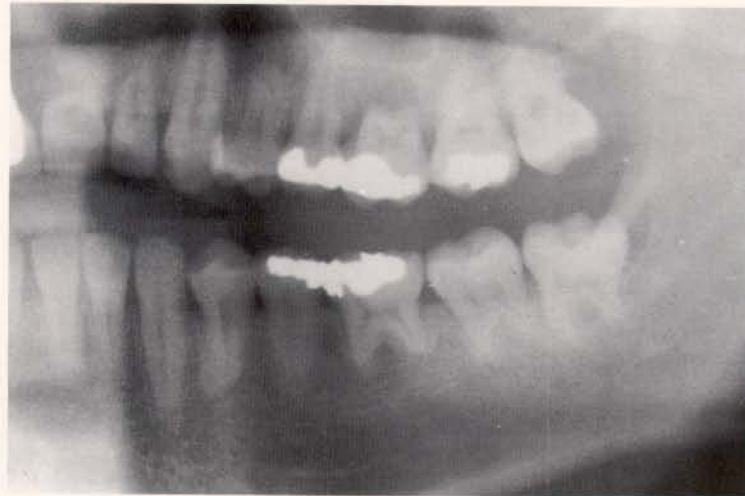Alterations of root form in the molar area in the first case (Fig. 375) and root resorptions in the second case (Fig. 376) demonstrate the obvious differences compared to the previous cases.

375 Posterior open bite in a case of macroglossia and multiple retention of teeth
Compare to the previous cases (e.g., of dentinogenesis imperfecta).



376 “Idiopathic root resorption”
Compare this appearance to that of the previously depicted dentinogenesis imperfecta. In this case, however, two accidents had occurred in early childhood and therefore the traumatic origin of this condition was clear. Above is a section from the panoramic radiograph depicting the maxillary left side; below, the patient's right side.

Courtesy Dr. P. Ledermann, Herzogenbuchsee.



Concretions, Calcifications, Ossifications

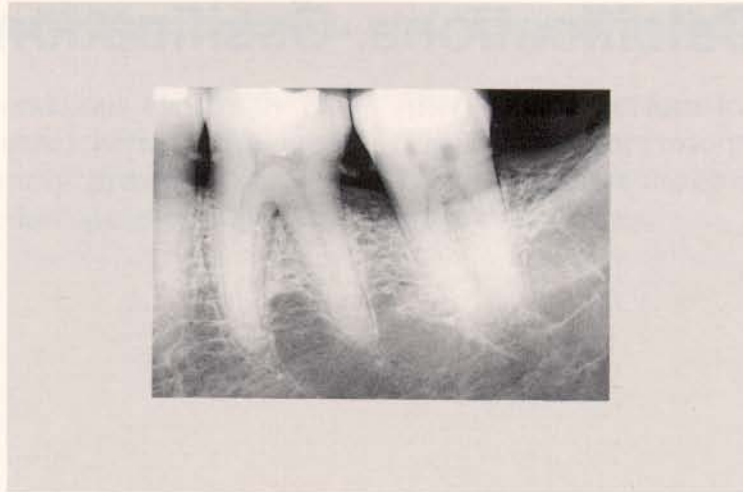
Combining these three topics permits discussion of various radiopaque objects and structures that are not always observed outside the jaws and that are relatively easy to detect there radiographically. In many cases during the production of periapical films and especially in panoramic radiographs, the X-ray beam encounters these structures and they appear as superimpositions upon the teeth and jaws. Since radiographs represent only a two-dimensional picture and the third dimension is lacking, one is tempted to interpret such objects and structures that appear at various locations in the film not as results of addition but rather as actual alterations of structures in the jaws. Furthermore, radiopaque objects outside the jaws become much more clearly visible than would be possible without this apparent layering, due to the additive effect of X-ray beam dampening. One must keep in mind that individual periapical radiographs as well as the panoramic film can provide only a “summation” picture. Even panoramic radiography falls into the classification of zonography (more than 5 mm layer thickness) and not tomography (less than 5 mm layer thickness), which is why the summation effect cannot be completely excluded. All of the above-mentioned conditions make it clear that incorrect interpretations can be avoided only with great care. Everything depends upon recognition of the misleading addition effect and the elimination of the risk of incorrect interpretation by means of other projections to ascertain that third dimension.

The most important structures and situations that create confusing radiopacities include:

- Supra- and subgingival calculus, which is visible only on the proximal surfaces and in some cases masks the tooth root
- Sialoliths from the submandibular gland, which may produce shadows at the angle of the mandible and in the premolar-molar area of the mandible if they reside within Wharton’s duct
- Sialoliths from the sublingual gland; these are usually too small to produce any addition effect in the anterior region of the mandible
- Sialoliths from the parotid gland, if they reside in the anterior portion of the gland, which may be projected onto the mandibular ramus in a panoramic film, or near the maxillary molars if they reside within Stensens’s duct
- Multiple osteoma and calcified acne foci in the soft tissue of the cheek
- Calcified lymph glands, which may cause apparent radiopacities in the mandible
- Ossification in myositis ossificans
- Ossification of the stylohyoid ligament
- Superimposition upon the body of the mandible by the hyoid bone if a patient swallows during exposure of the panoramic radiograph.

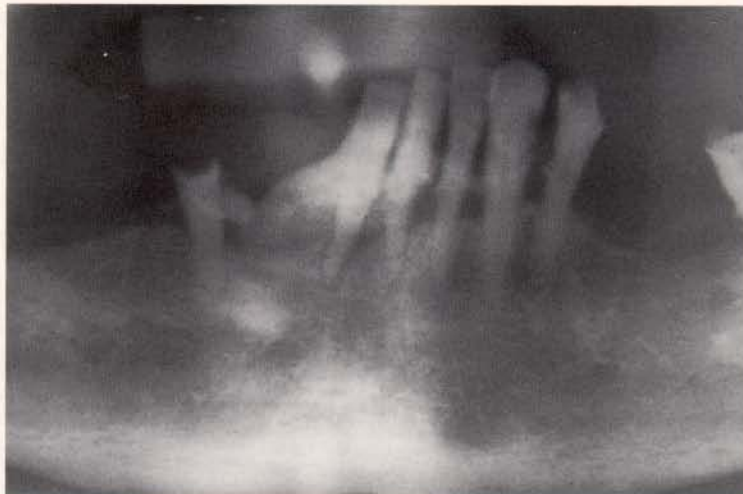**377 Supragingival calculus
"spurs"**

Periapical film of the left molar region of the mandible, taken at low voltage.



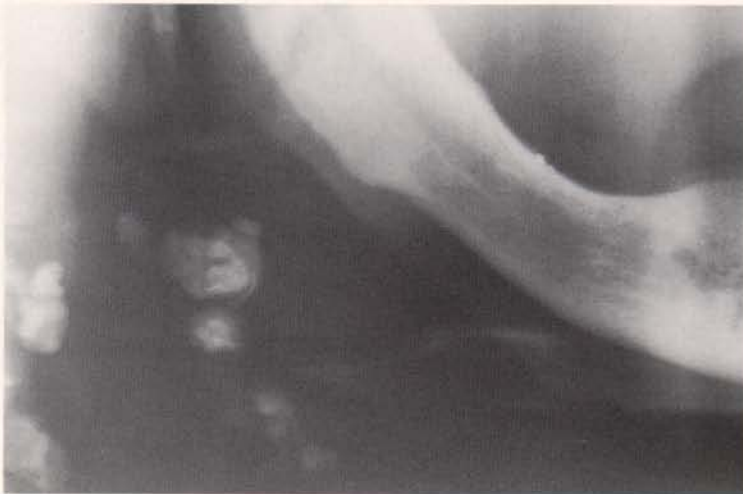**378 Supragingival calculus in
a 79-year-old female**

This section from a panoramic radiograph depicts a massive accumulation of supragingival calculus.

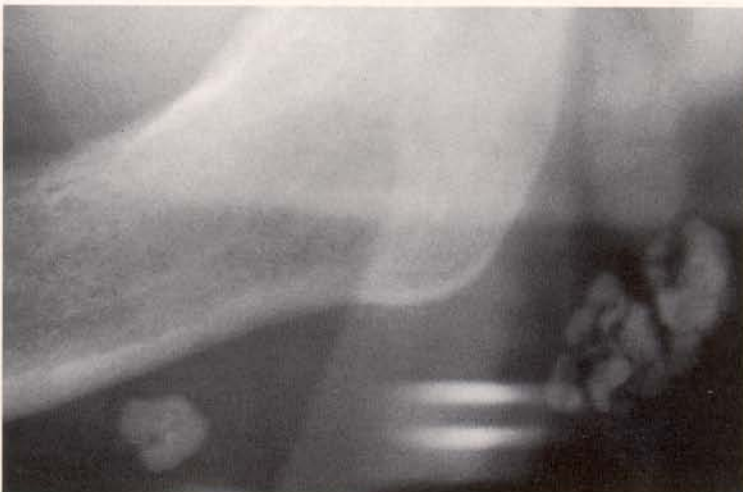

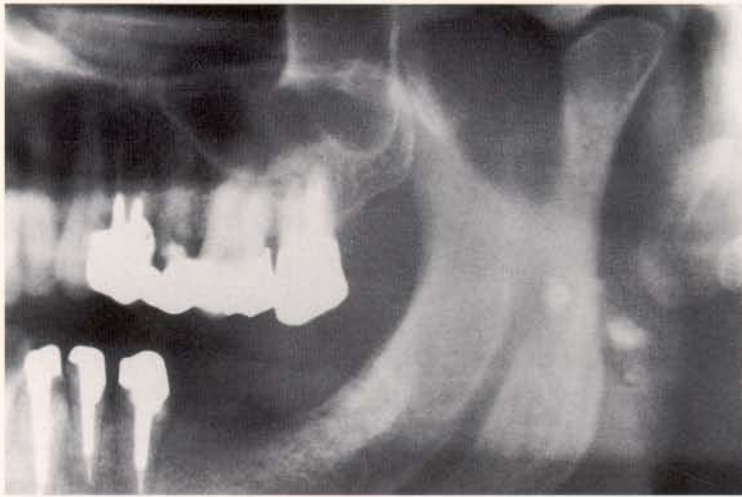**379 Calcified cervical lymph
nodes in a 79-year-old male**

Calcified lymph nodes were often seen in earlier times following tuberculosis. Such calcified lymph nodes are still occasionally observed today in elderly patients.



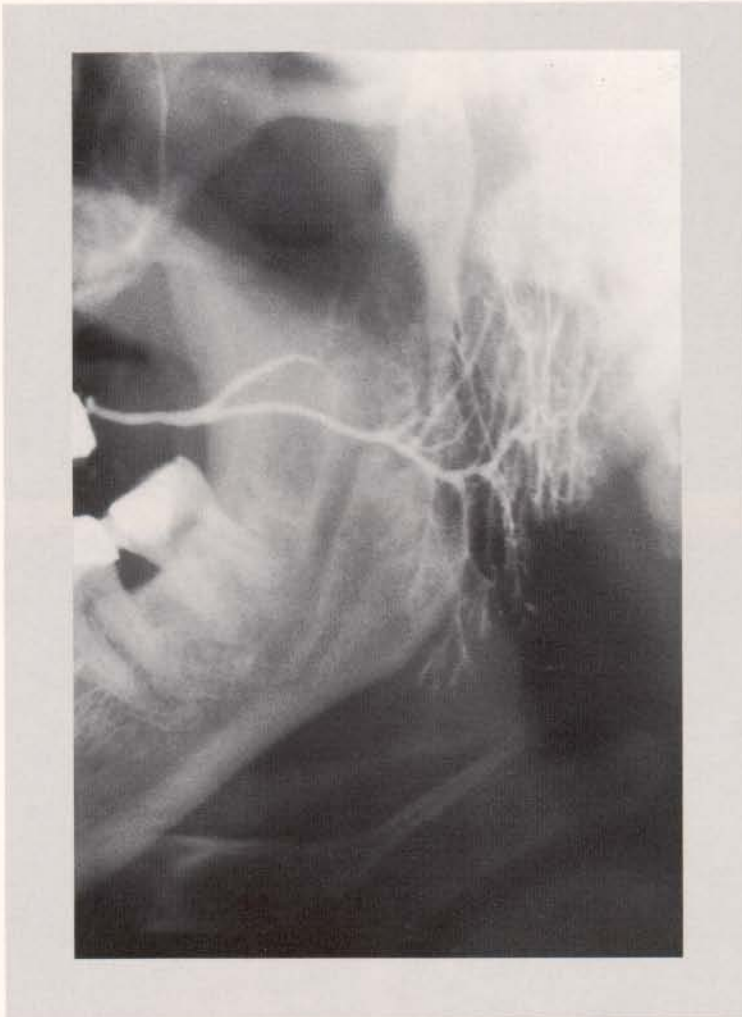
**380 Calcified cervical lymph
nodes in a 59-year-old male**





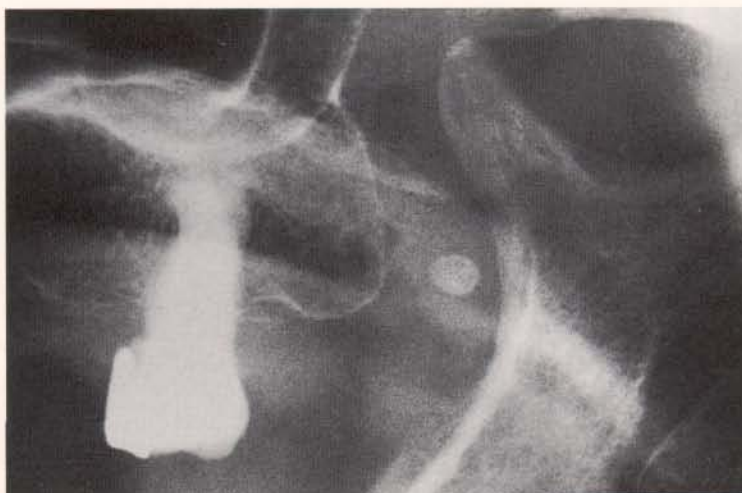381 Calcification in the parotid gland of a 54-year-old male following mumps

The use of sialography permits depiction of the configuration on the parotid gland in a panoramic radiograph (see Fig. 382).



382 Sialography of the parotid gland of a 47-year-old male

Anatomic position of the gland and the duct as seen in the radiograph. Radiographic diagnosis for the parotid gland may also be performed using conventional radiographs in the frontal plane, or via CT.

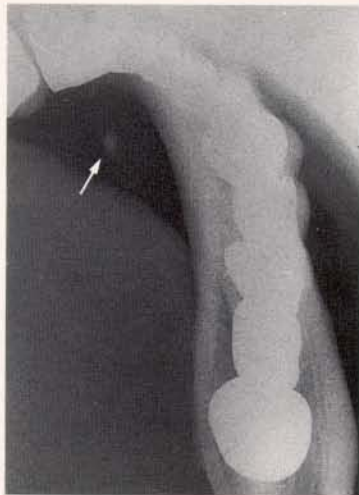

383 Sialolith within Stensen's duct of the parotid gland in a 74-year-old female

Other calcifications, such as phleboliths or osteoma on the pterygoid process can occur in this region. With the help of a tangential zygoma projection (phleboliths) or an axial skull film, or with CT (osteoma on the pterygoid process), the differential diagnosis can be determined.

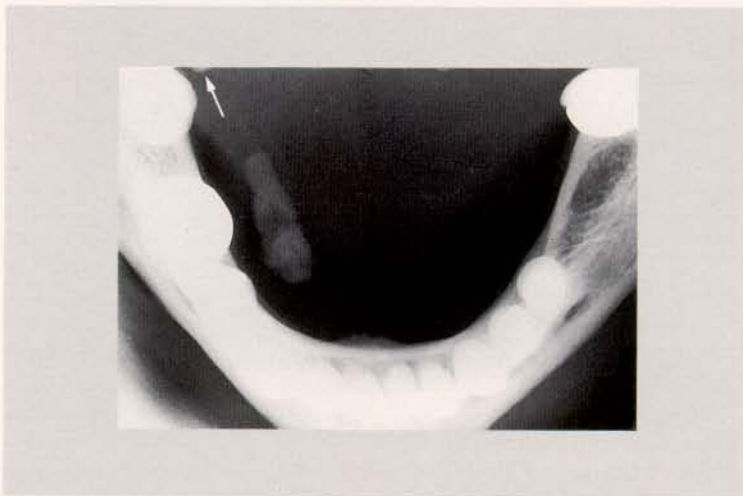
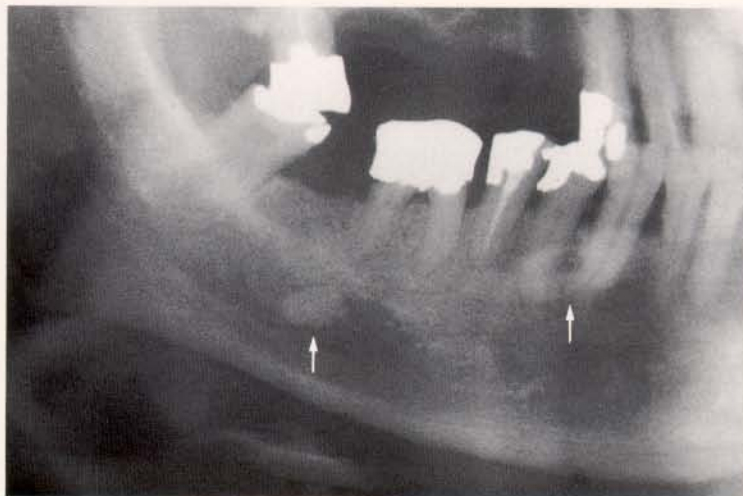
384 Small sialolith from the sublingual gland in a 70-year-old female

This excellent depiction of the sialolith was achieved using a lateral mandibular occlusal projection.



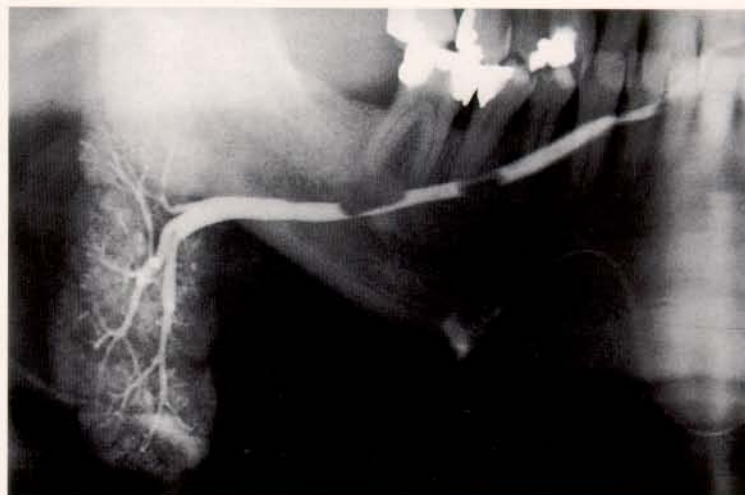385 Sialolith within Wharton's duct of the submandibular gland in a 56-year-old female

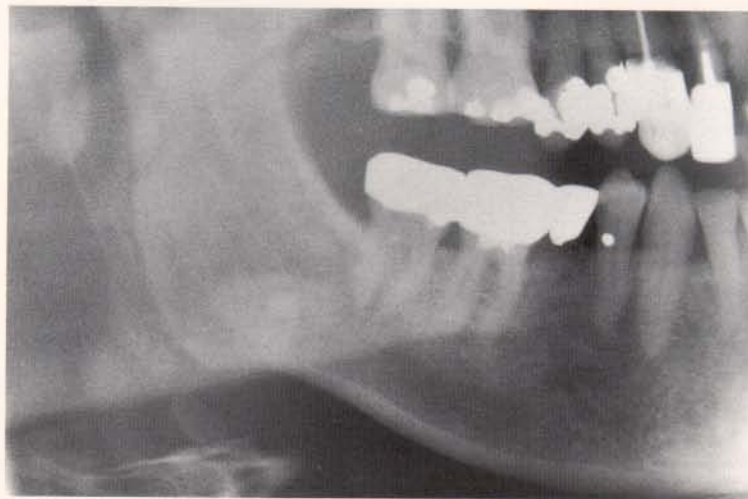The comparison of a panoramic radiograph and a less than ideal occlusal film is instructive: The stone appears near the roots of teeth 44 and 43 in the panoramic film, and is also clearly visible in the occlusal film. The more distal stone (arrow) appears in the panoramic film inferior to the distal root of 46 (resembling a retained root tip), but this stone is not visible in the incorrectly prepared occlusal film (below).



386 Sialography of the submandibular gland in a 55-year-old male

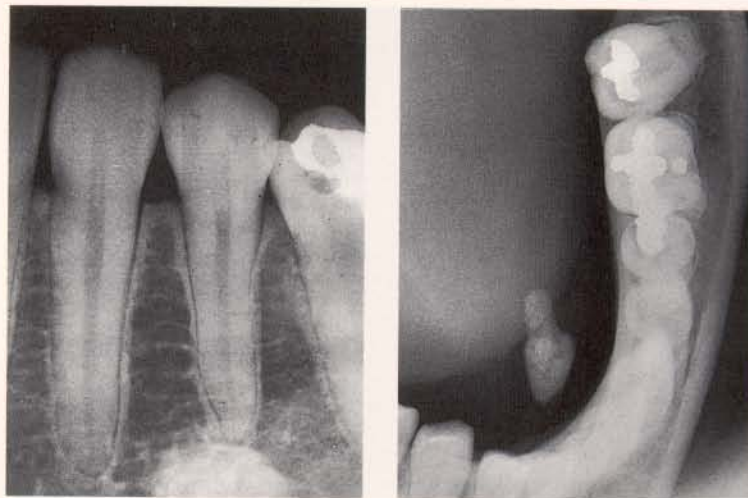
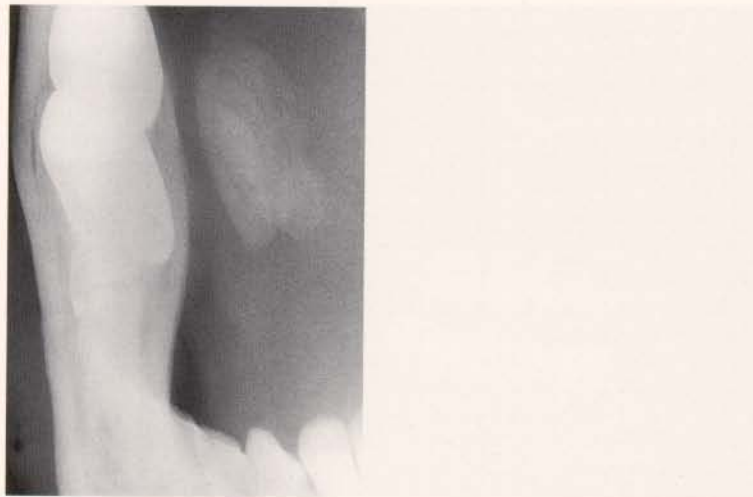Typical course of the glandular ducts as seen in the panoramic film. The ossified portion of the hyoid bone is superimposed upon the lower segment of the gland, giving the appearance of ectopic calcification.





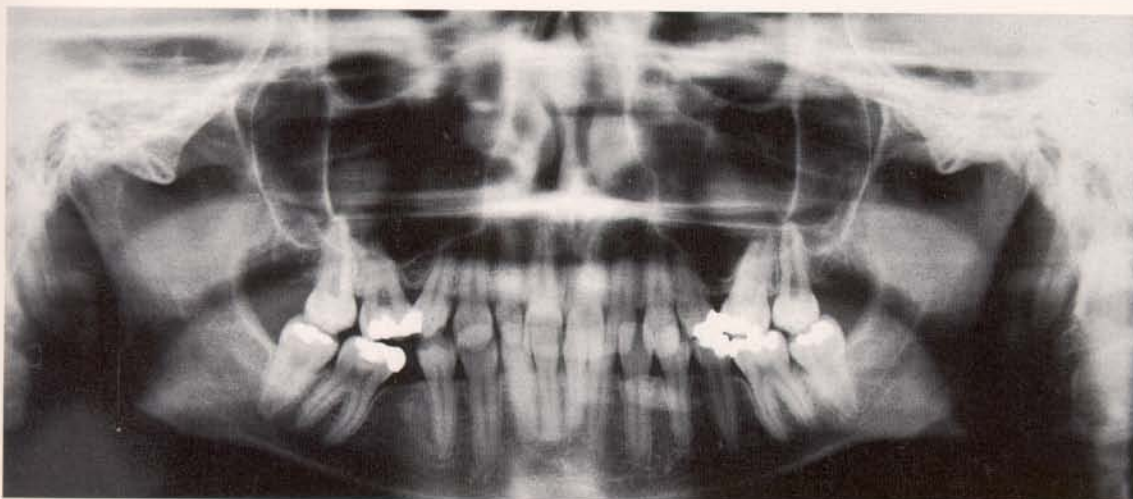
387 Large, lamellated sialolith in the curve of the saliva duct in a 62-year-old male

The sialolith is shown on the section from a panoramic radiograph, above. The vertical occlusal film (below) depicts the sialolith's position and its entire expanse.



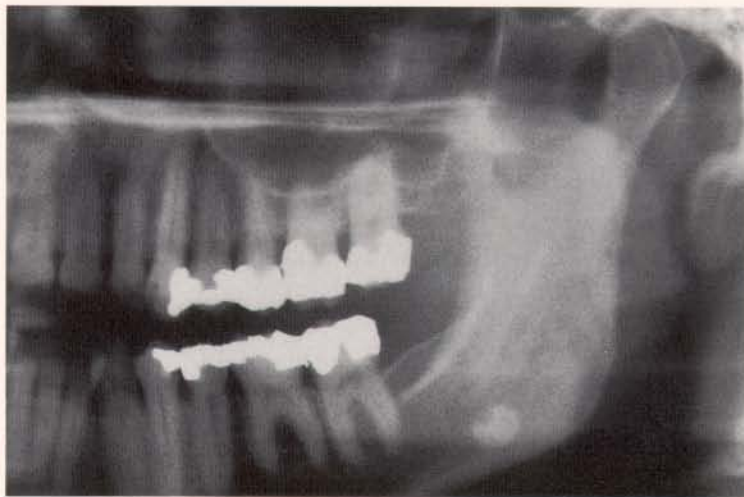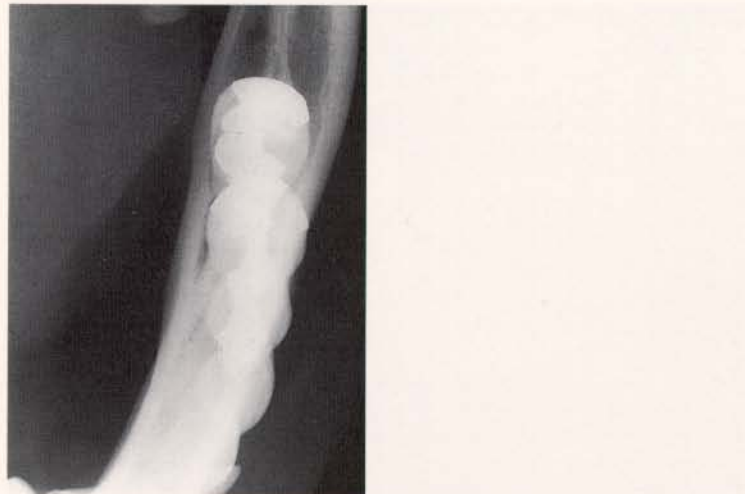388 Peg-shaped sialolith in the anterior section of Wharton's duct from the left submandibular gland of a 53-year-old male

The combination of an occlusal film, a periapical radiograph and the panoramic radiograph depicts the typical localization of this type of stone in three "classic" dental radiographs. This case also depicts the possibilities for incorrect diagnosis in such cases, especially in the periapical and panoramic films (see Pasler 1989).



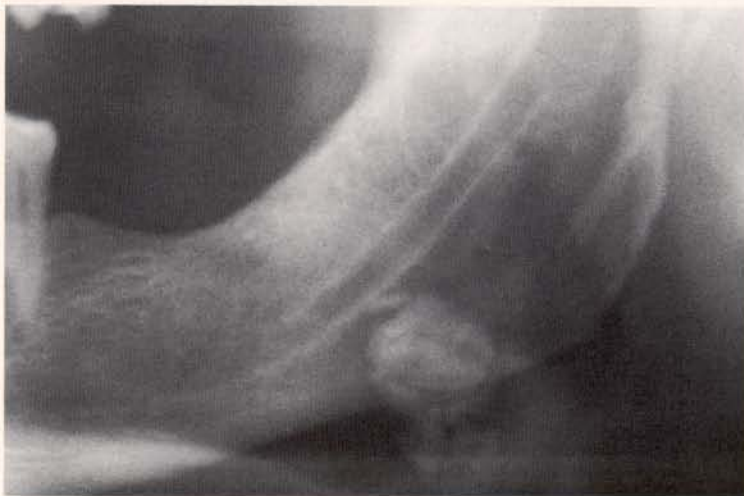389 Small sialolith at the curvature of the duct in a 41-year-old female

The occlusal film (top) presents a poor depiction of the stone, despite acceptable radiographic technique. The section from the panoramic radiograph of the same case (below) clearly depicts the position of the oval sialolith at the curvature of Wharton's duct.



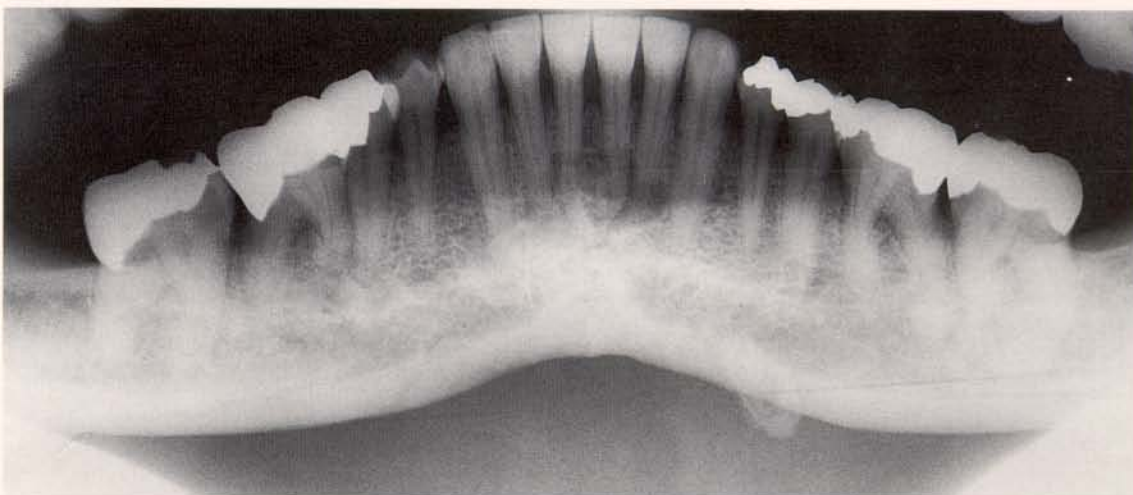
390 Large sialolith at the curvature of Wharton's duct in a 64-year-old male

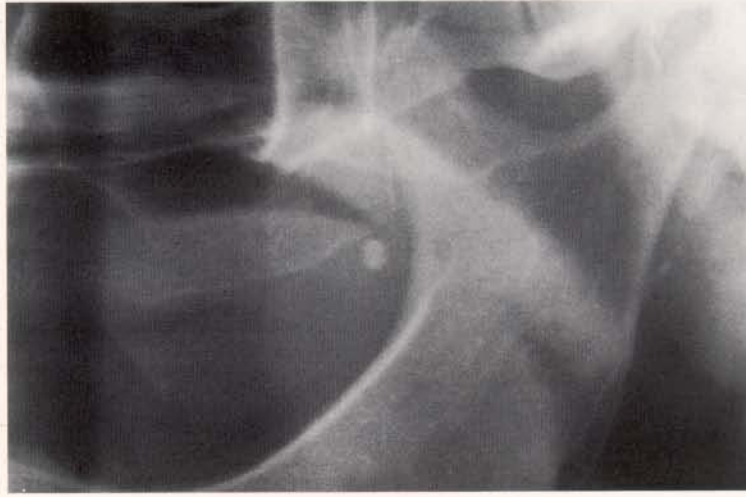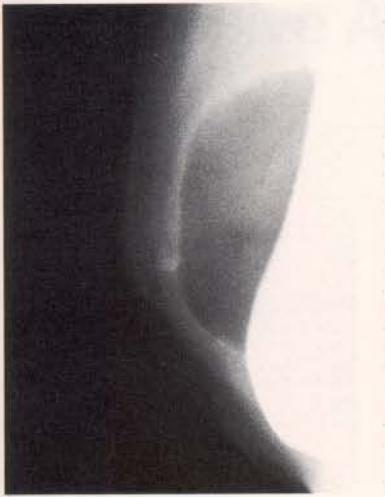The sialolith has induced induration and calcification of a portion of the gland.



391 Sialolith within Wharton's duct of the left submandibular gland in a 48-year-old female

This radiograph shows fibrous periapical dysplasia (cementoma) on various teeth and at various stages of development. (This radiograph was taken using the intraoral source technique, in which the anode is located in the patient's mouth.)



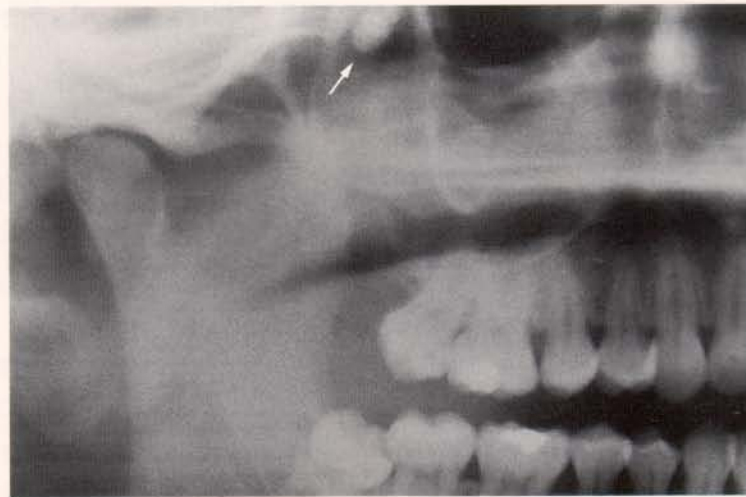

392 Phlebolith in the cheek of a 45-year-old female

Phleboliths are calcified thrombi, such as are commonly formed in hemangiomas. This phlebolith was depicted using the "tangential cheek projection."

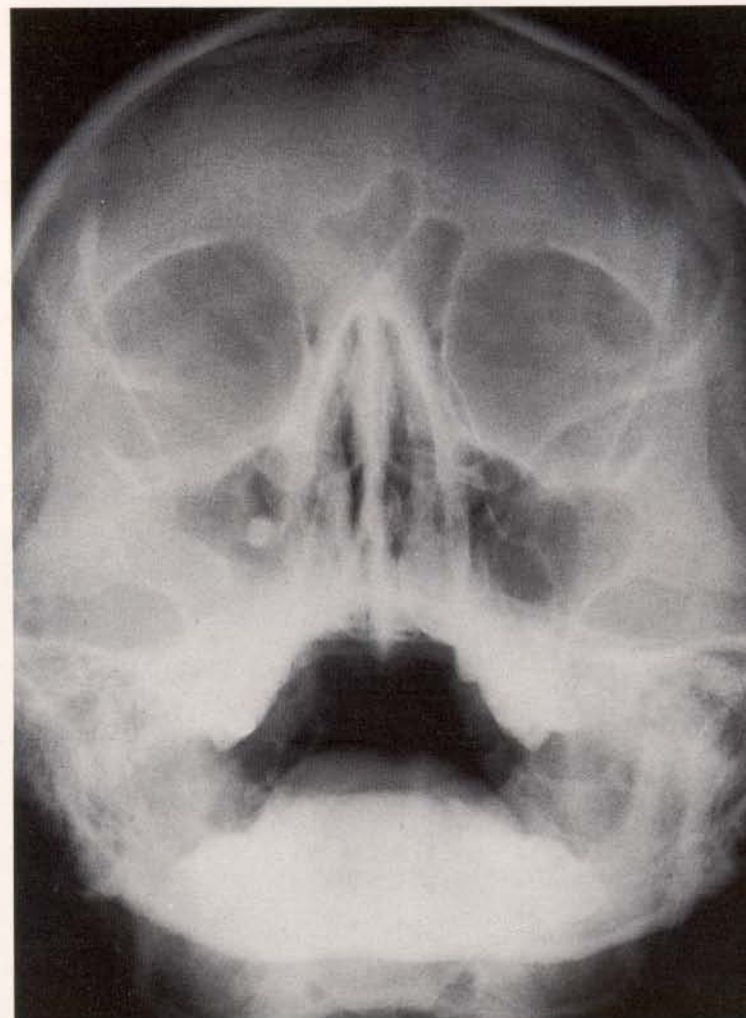393 Phlebolith in the left cheek of a 65-year-old female

Section from a panoramic radiograph. The highly oval form of the stone indicates that the object is near the film.



394 Rhinolith in the maxillary sinus

Section from a panoramic radiograph showing a rhinolith located at the posterior wall of the right maxillary sinus (arrow).

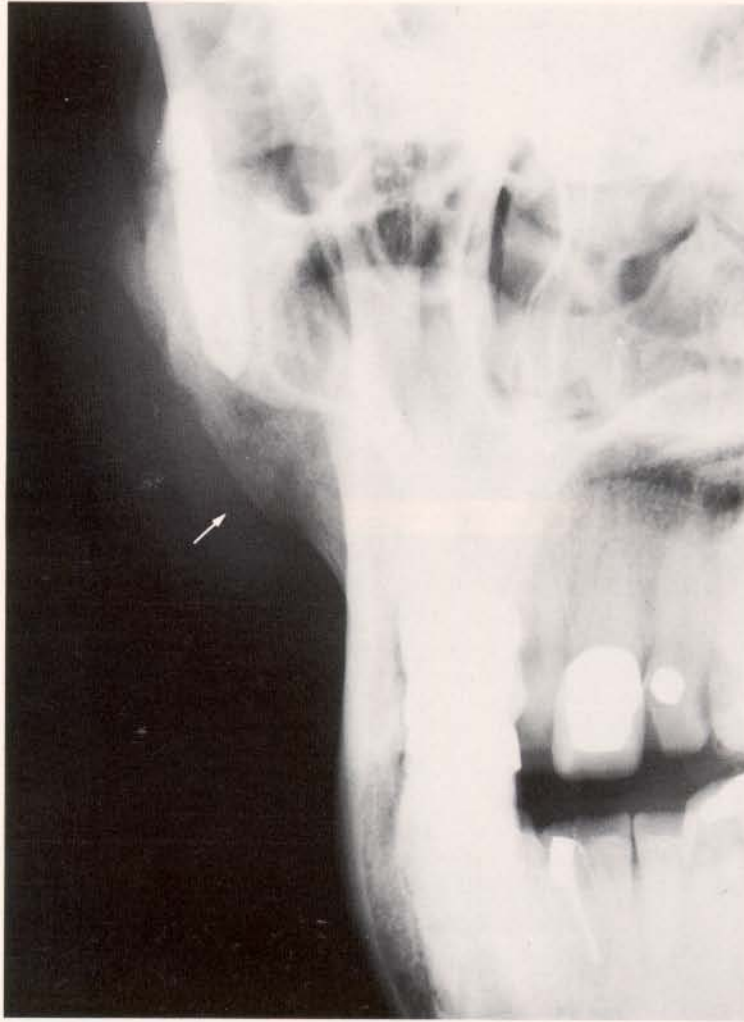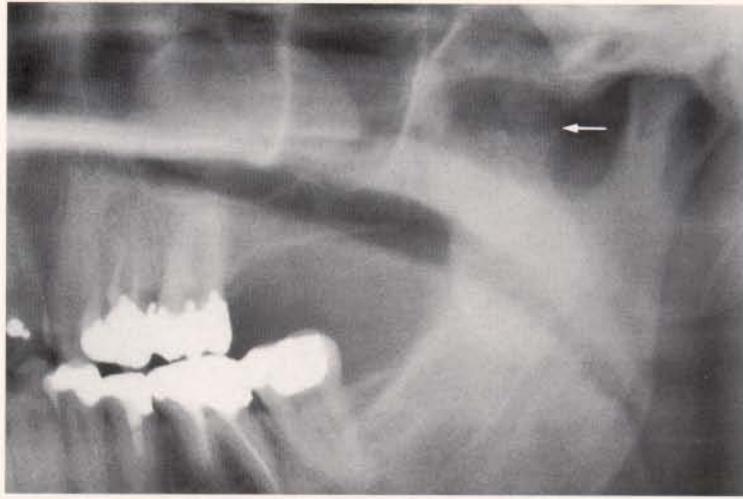


395 Rhinolith in the right maxillary sinus

This Waters' projection shows the same case as depicted in Figure 394. Note the different presentations of the maxillary sinus in the two radiographs: Only the Waters' projection also reveals the presence of chronic sinusitis.

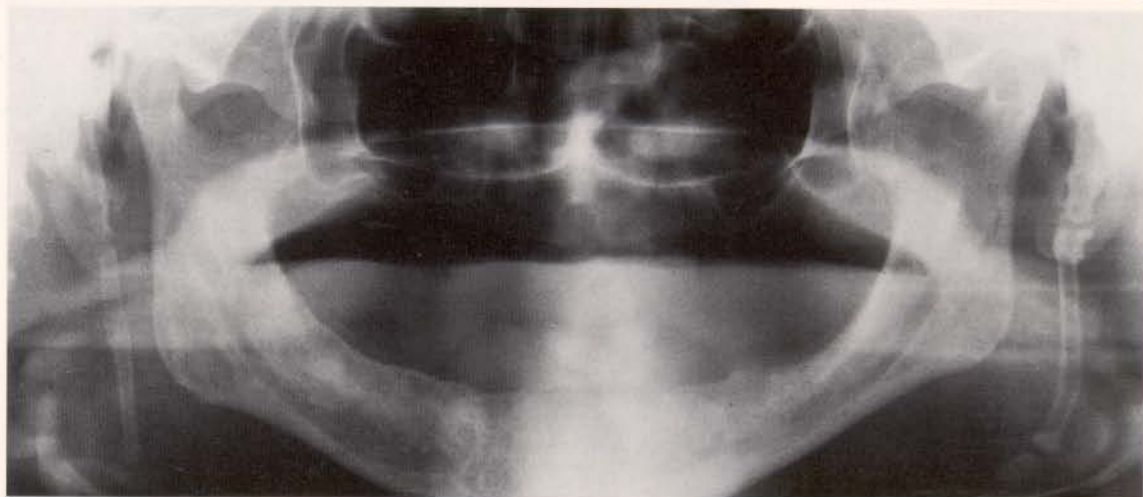396 Myositis ossificans in a 36-year-old female

Ossifications of this type appear to result from trauma or repeatedly occurring inflammatory events. In this case, the ossification of the masseter muscle has led to limited ability to open the mouth. The top picture shows a section from a panoramic radiograph; the picture below shows the massive ossification in a tangential zygoma projection (arrow).



397 Ossification of the stylohyoid ligament

The ossification sometimes extends to the minor horn of the hyoid bone and therefore gives the visual impression of forming a "stylohyoid chain," which also exhibits non-ossified sections or even small joints. Such long and slender ossifications lead not infrequently to "discomfort of unknown etiology" in the retromaxillary region.



Regressive Alterations of Teeth and Jaws

The term regressive is generally limited in use to alterations such as abrasion, atrophy, degeneration, necrosis or resorption.

Abrasion, which can be diagnosed clinically and which therefore need not be examined radiographically, can result from either physiologic or nonphysiologic wear. For forensic reasons, documentation of certain cases may be indicated both photographically and radiographically. Several characteristic examples will be presented in this section.

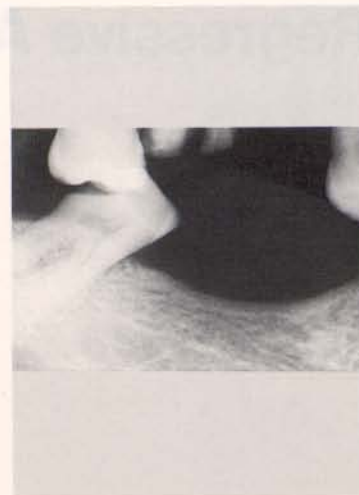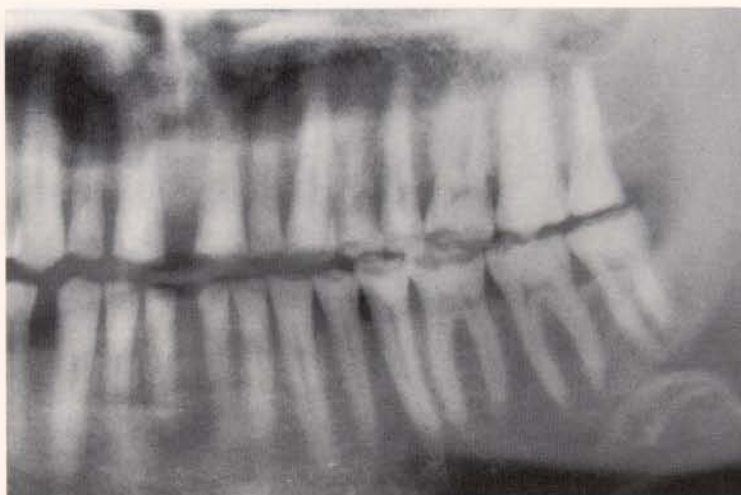
Wedge-shaped defects are quite easy to detect clinically, and also on radiographs when the defects extend toward the interdental area. On the other hand, resorption of the crowns of retained or impacted teeth as well as root resorptions on vital or nonvital teeth can be inspected only by means of radiographic examination. It must be emphasized that all abnormalities in the mixed dentition must be investigated using an appropriate radiographic projection (panoramic radiograph!). This is also the case for any permanent tooth that apparently "failed to erupt."

Enlarged pulp chambers in the teeth of adults indicate compromised formation of secondary dentin. Radiopacities in the pulp chamber usually represent free or adherent denticles, and radiographic differentiation is seldom possible because even adherent denticles may appear as free, and vice versa, depending upon their position in the projected X-ray beam. Of additional note is that the vestibular wall of the alveolus is projected upon the pulp chamber in periapical radiographs and may compromise the interpretability of the film.

Idiopathic root resorption may be localized centrally or peripherally. The central form has also been termed "internal granuloma," and is usually the result of pulpa trauma, for example during tooth preparation. The peripheral form usually occurs following injury to the periodontal ligament, for example through accident or attempts to reimplant luxated teeth. It should be noted that the radiograph may also depict a central resorption if the defect is located peripherally but exactly on the vestibular or the palatal/lingual aspect. In such cases, an eccentric periapical projection using a horizontal localization will usually provide clarification. Even vital teeth may be affected, due to the growth pressure on retained teeth, abnormal tooth mobility or forced orthodontic treatment. In addition to regressive changes we should also include atrophy of age, even though some authors include such atrophy under the rubric osteopathy. Such age-related conditions should be studied radiographically using the filter effect and whenever possible with dentures in place and the jaws closed. Occlusal films should be used when necessary in such cases for examination and documentation where the mental spine is often considerably enlarged lingually.

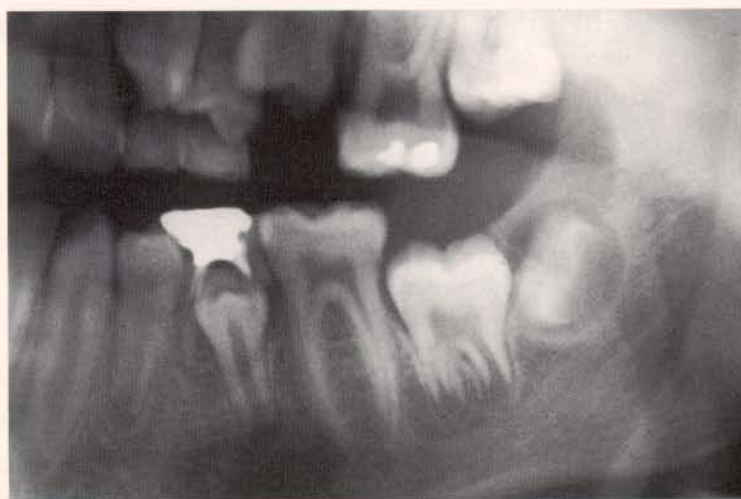398 Generalized abrasion

Left: Section from a panoramic radiograph of a 54-year-old male. Right: This bite-wing film reveals unusual abrasion in another patient.



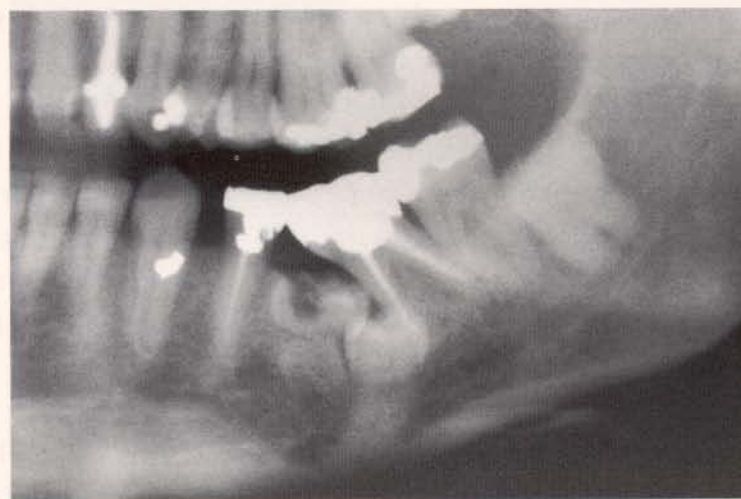399 Resorption of deciduous tooth 75 in a 12-year-old male

Normal physiologic resorption has been effected by previous endodontic treatment.



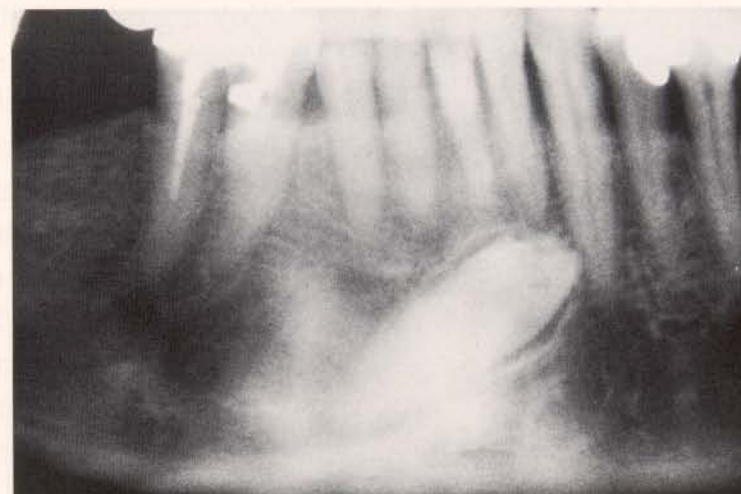
400 Initial resorption of the crown in a 44-year-old female

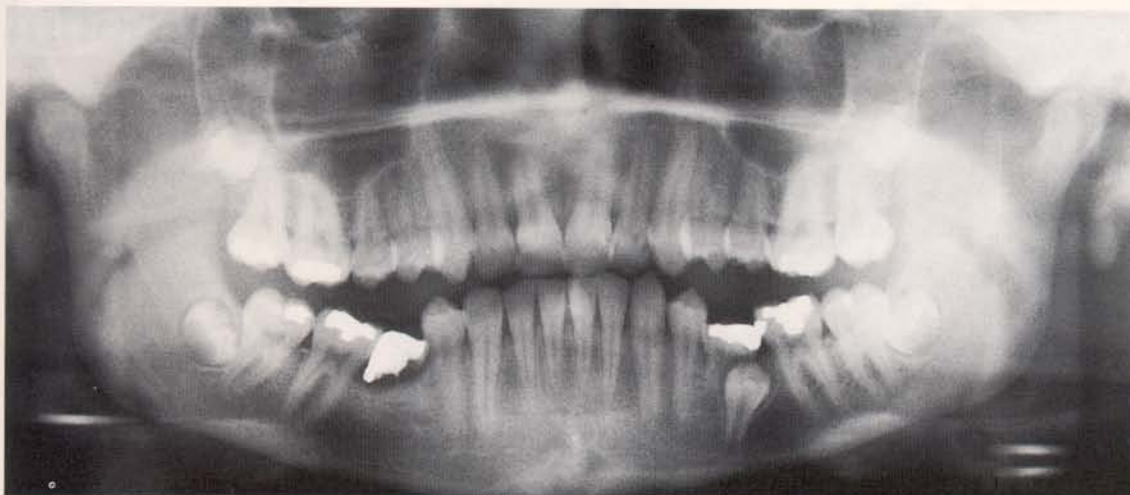
This section of a panoramic radiograph reveals the initial resorption of the crown of impacted deciduous tooth 75, which has forced tooth 35 out of its normal path of eruption.



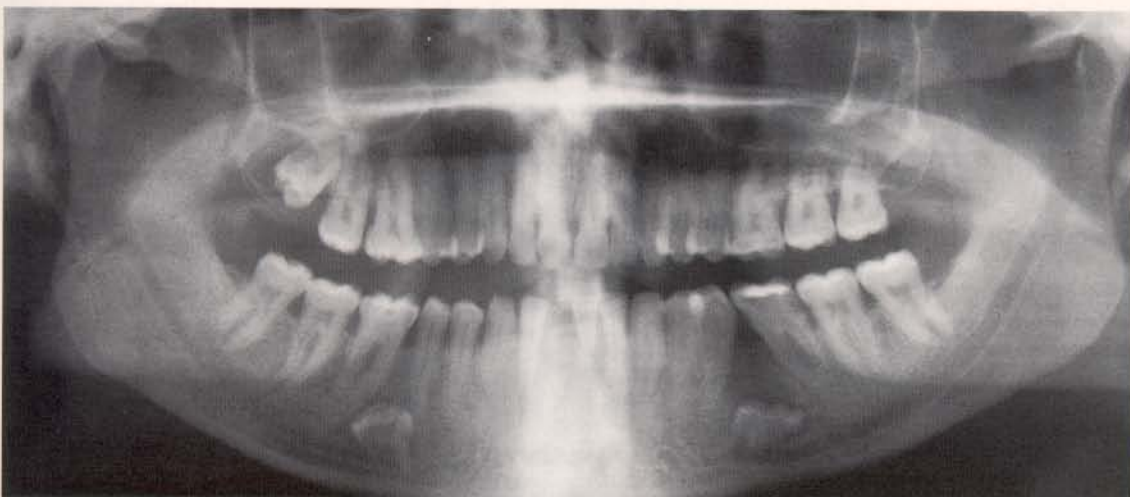401 Resorption of the crown of impacted tooth 43 in a 42-year-old male

It is likely that in early childhood the tooth bud was dislodged from its normal eruption direction through trauma. In this section of the panoramic radiograph, the impacted tooth appears enlarged and distant from the film, indicating that it is lingually displaced.

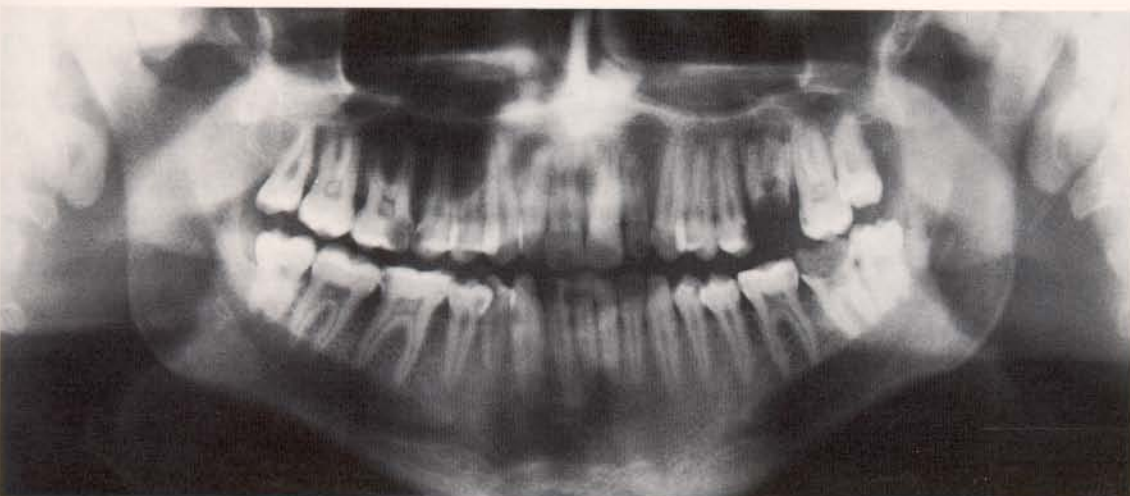



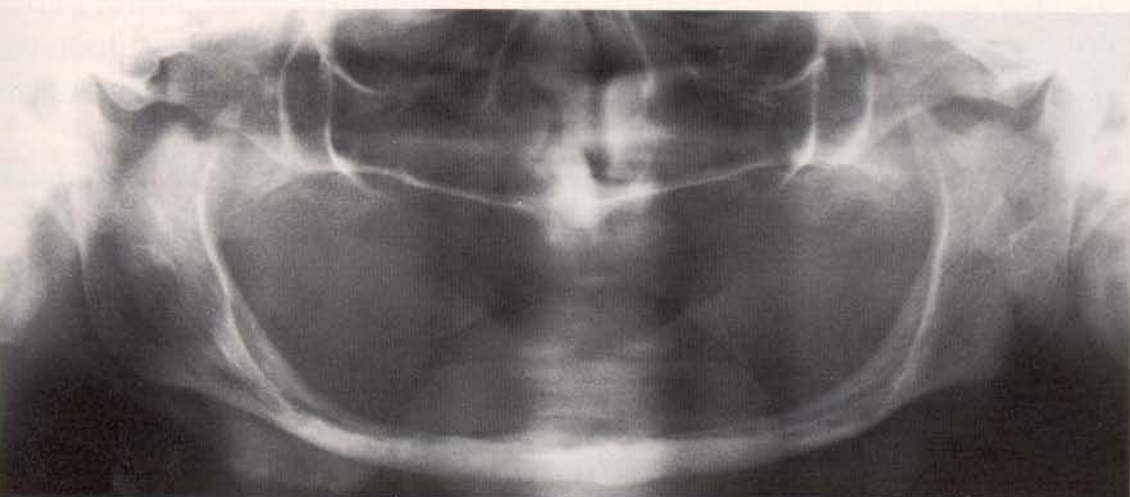402 Resorption of deciduous teeth 75 and 85 in a 14-year-old female
Tooth 45 was congenitally missing.



403 Resorption of deciduous teeth 75 and 85 in a 22-year-old female
Note the eruption cyst on tooth 18.



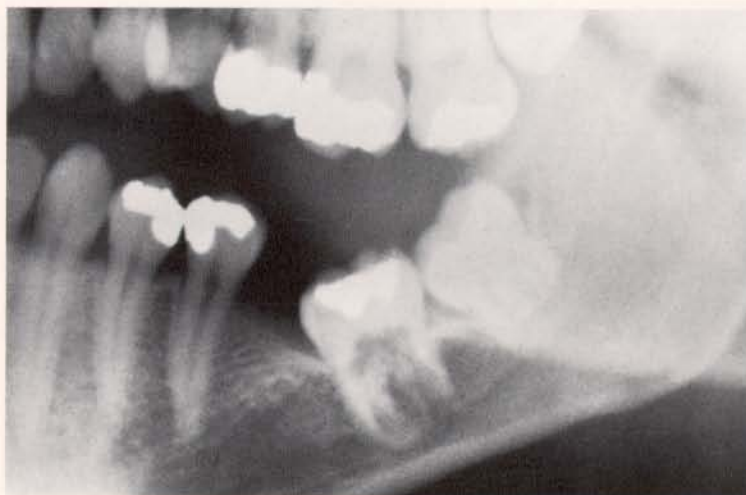
404 Denticles
The radiograph depicts opacities in the pulp chambers of the molars. However, the radiographic picture does not permit differentiation between free or adherent denticles.



405 Senile atrophy of the alveolar processes of both maxilla and mandible in a 77-year-old female
It appears that the mandibular nerve courses superficially in a depression. The alveolar processes can be more clearly depicted when the patient's prostheses remain in situ, especially the maxilla.

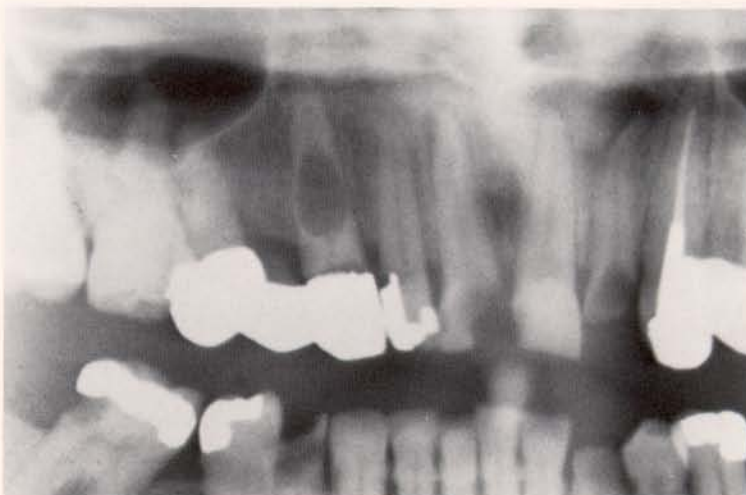406 Idiopathic resorption of the central type on ankylosed tooth 37 in a 25-year-old male

With advanced resorption such teeth become extraordinarily radiolucent and for this reason are often referred to as "ghost teeth."



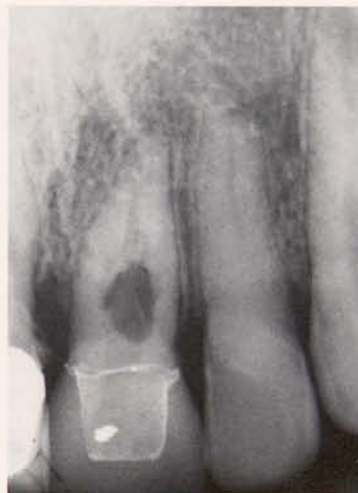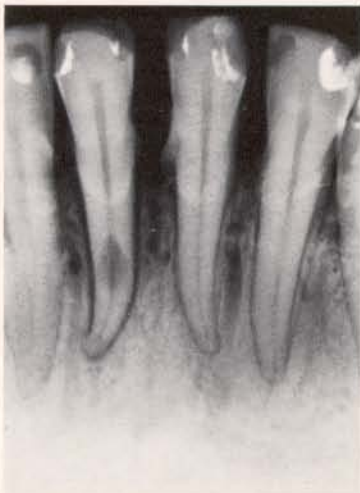407 Idiopathic resorption of the central type following trauma during tooth preparation (?) and recurrent caries on tooth 13 in a 47-year-old female

The lesion is also known under the synonym "internal granuloma."



408 Idiopathic resorption on maxillary and mandibular anterior teeth

Anterior teeth with abnormal mobility or after traumatic tooth preparation frequently exhibit the formation of "internal granuloma." The left figure depicts a central projection of such an internal granuloma located towards the vestibular aspect.

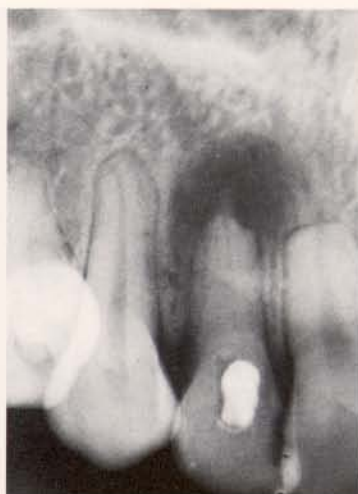
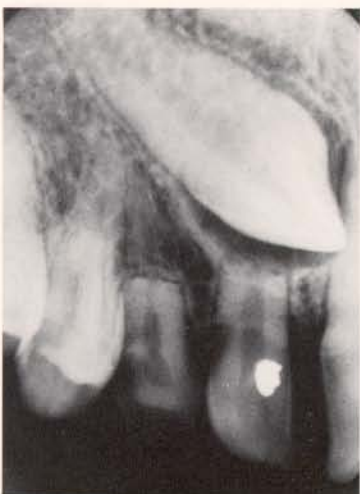
409 Resorption of deciduous tooth 53 and root resorption on tooth 12

Left: The resorption was elicited by growth pressure from impacted tooth 13 and its follicular cyst.

Courtesy Dr. Risk, Geneva

Right: Root resorption in response to pulpal necrosis of tooth 12.



Inflammation of the Jaws and Osteoradionecrosis

The anatomic structures of the functional elements of the jaws and their tooth-supportive alveolar processes provide numerous possibilities for the initiation and spread of infection. The variable trabecular structure of maxillary and mandibular alveolar processes may contribute here as well. Depending upon the cause and the location, the clinical manifestations of inflammatory processes may vary. It would be desirable to achieve comprehensive information from the radiographic examination of such conditions, which might range from a simple dentogenic infection all the way through osteomyelitis and osteoradionecrosis. Unfortunately, however, radiography can only provide basic documentation of the condition of the tissues *at the time the radiograph is taken*; a radiograph permits no speculative interpretation! Furthermore, radiographic findings often do not agree at all with the clinical picture. Nevertheless those radiographic signs that become visible, independent of the classification of the various etiologies, do show similarities with the documentable tissue changes, and this is the reason for discussing these issues under the above title.

Depending upon the virulence of the infectious agent and the location of the attack, inflammatory processes in the jaws and their radiographic signs can be classified simply as acute or chronic. In the case of *acute conditions* the radiograph begins to correspond to the clinical picture only after several days because serous absorption, the resultant edema, the incipient decalcification and finally the inception of necrosis require time to effect changes in the radiographic picture. These changes generally consist of radiolucencies with vague demarcation. In the case of *chronic conditions* one may see not only osteolysis but also reactive sclerosis; depending upon the host response, the virulence of the microorganisms and the length of time the condition persists, lysis and sclerosis may present a changing relationship. The radiographic picture can also be altered by an acute exacerbation or a superinfection. It is extremely important to avoid confusing the radiographic signs of chronic infection with connective tissue or osseous scar formation, and especially with radiographic subtraction effects in bone. The radiograph alone, without knowledge of the clinical situation and without the use of clinical methods of examination, will rarely provide the necessary diagnostic certainty. At best, it permits only speculation about what is possible or probable.

Thanks to early administration of antibiotic therapy, the widespread forms of acute as well as secondary chronic osteomyelitis, which were common previously, have become much more rare today. Most common today is the primary chronic form, which may remain symptom-free for long periods of time.

Osteoradionecrosis, which has also been referred to as radio-osteomyelitis, results from latent damage to bone, and it exhibits a common tendency for sequestrum formation.

Acute and Chronic Apical Periodontitis

As long as no structural alterations have occurred in the periapical tissues, the radiograph will reveal no reaction, despite acute clinical symptoms. Acute inflammatory processes that extend from the root apex often appear on the radiograph as diffuse periapical radiolucencies with apparent widening of the periodontal ligament space. Chronic apical periodontitis that often exhibits acute exacerbations may appear radiographically as sharply demarcated radiolucencies with reactive sclerosis.

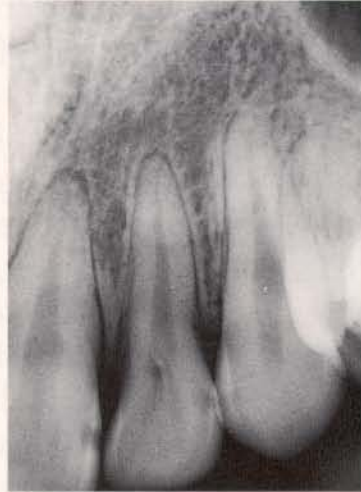If the practitioner suspects participation by a dento-

genic focus of infection, the radiographic examination must be carried out with greatest care:

- A radiograph cannot provide information about the vitality of a tooth except in the case of previously performed endodontic therapy.
- Spreading inflammatory processes will only be detectable radiographically with delays, after osseous reactions have occurred.
- Obvious periapical lesions can, at best, be described by the radiologist as "possible" or "probable" foci of infection.

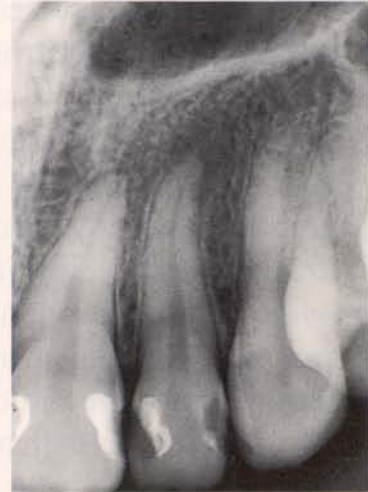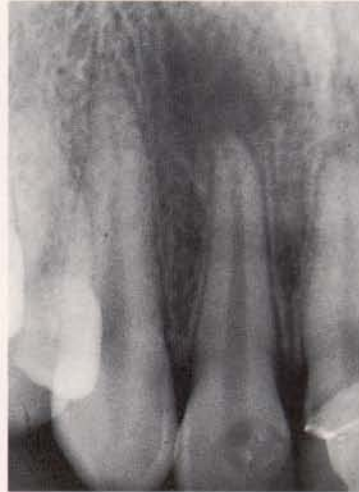410 Fully developed acute pulpitis

No periapical alterations are apparent at the apex of tooth 22, which has undergone trepanation.



411 Subperiosteal abscess

Note the diffuse periapical radiolucency on tooth 12.

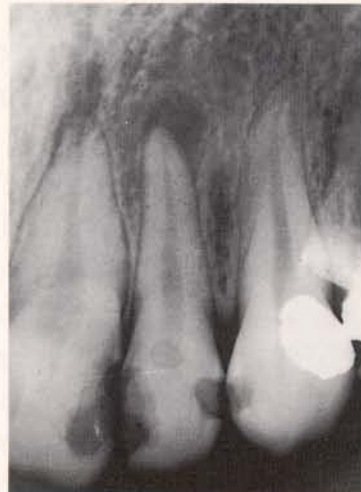

412 Chronic apical periodontitis

The lamina dura is widened apical to the poorly demarcated radiolucency.

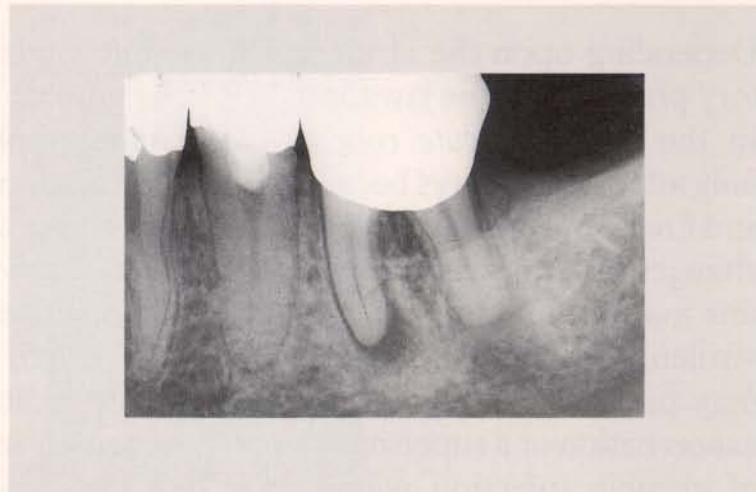413 Chronic apical periodontitis

Obvious periapical osteolysis and radiopaque border of an incapsulated granuloma on tooth 22.



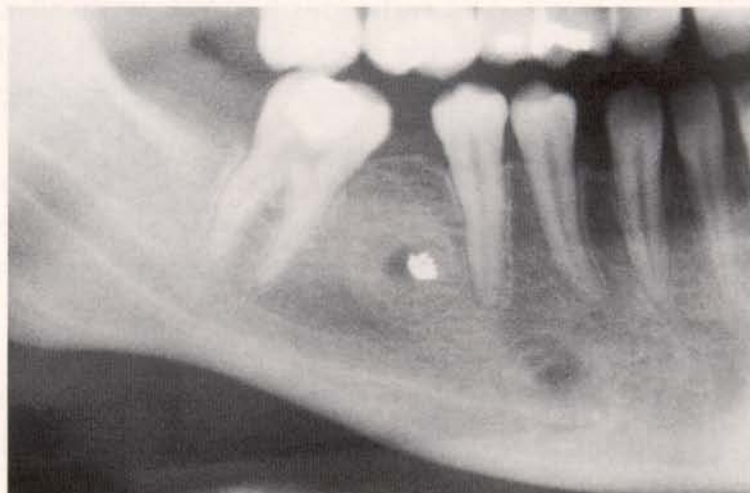414 Chronic apical periodontitis

Reactive sclerosis on the mesial and acute exacerbation on the distal root of tooth 36.



415 Foreign body granuloma

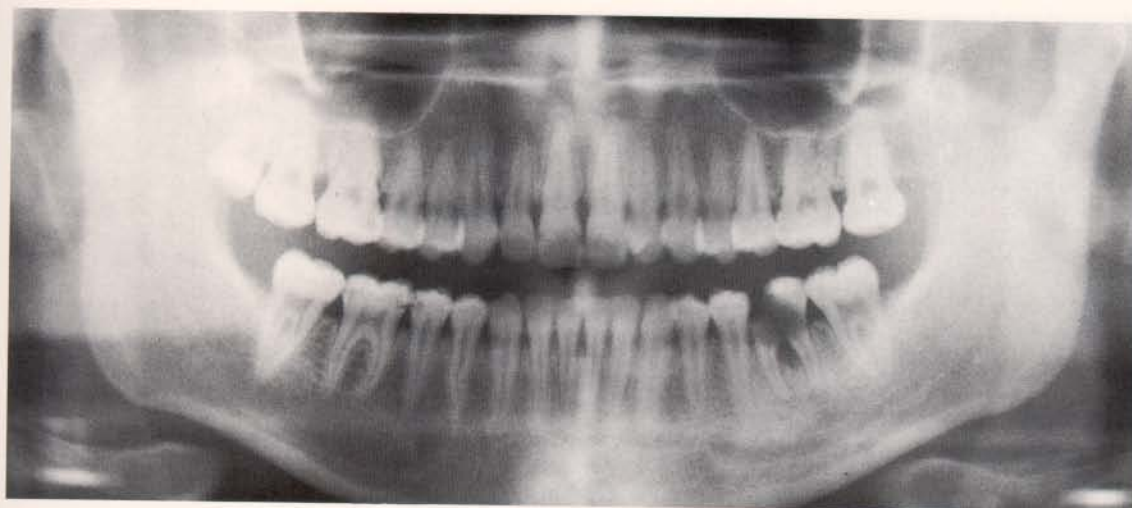
Reaction around the residual amalgam that persisted in the mesial alveolus after extraction of tooth 46. The reactive sclerosis is clearly discernible.



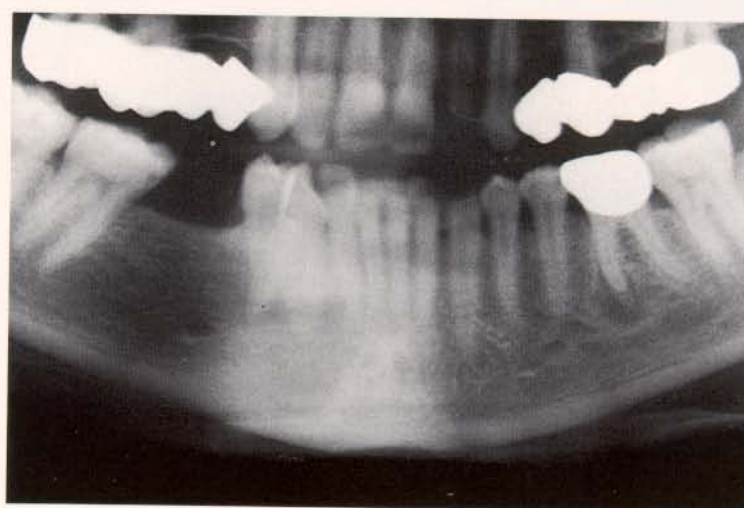
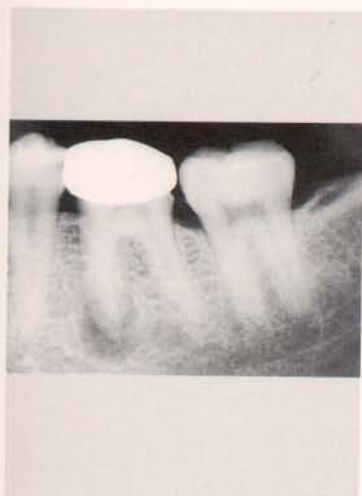Diffuse Sclerosing Osteomyelitis in Chronic Apical and Marginal Periodontitis

The relatively mild bacterial infections typical of chronic apical and marginal periodontitis can lead to a special form of osteomyelitis with diffuse opacities of the surrounding bone, especially in young persons with good host response. For example, the otherwise difficult

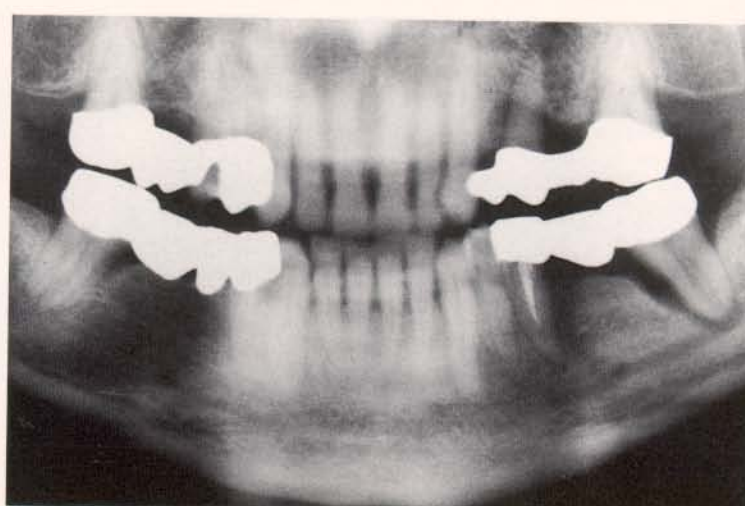
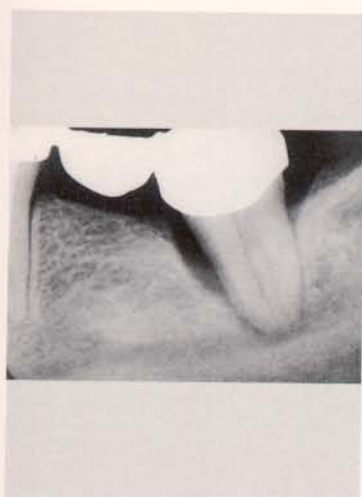to discern mandibular canal becomes easily visible because of its transparent contents and also because of the sclerosis of the canal wall. This form of osteomyelitis can sometimes occur following tooth extraction and delayed wound healing.



416 Diffuse sclerosing osteomyelitis in the left mandible of a 22-year-old female following pulpal necrosis and interradicular osteolysis of tooth 36
Compare the opacities on the left side with the healthy right side.



417 Following trauma during tooth preparation, pulpal necrosis and chronic apical periodontitis of tooth 36 ensued
Comparison between periapical radiograph and panoramic film. The periapical film provides a clear picture of the lesion. Because of the summation effect, the lesion appears smaller radiographically when underexposed.



418 Late stage marginal periodontitis on tooth 37
Comparison between periapical and panoramic films. Note the massive osseous reaction, which extends into the compact bone. The reaction becomes evident after comparison with the left side.

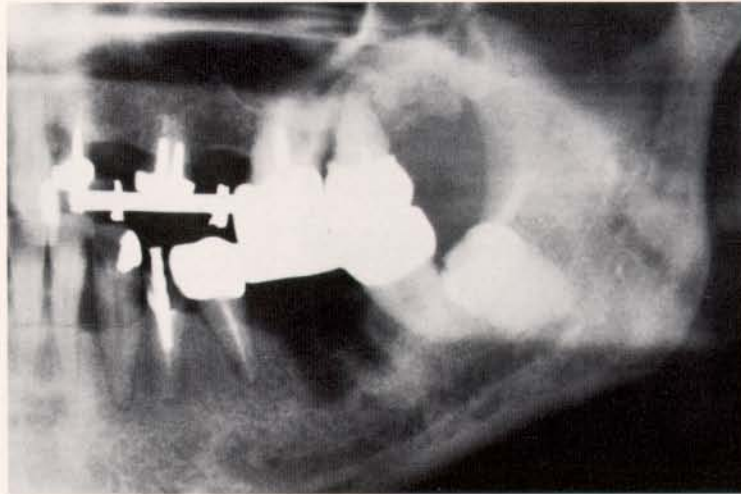
Sclerosing Osteomyelitis and Inflammatory Reactive Osteosis

Following chronic apical or marginal periodontitis, after tooth extraction and in cases of delayed wound healing, focal or a diffuse spreading primary chronic osteomyelitis sometimes ensue. Also often observed is an excessive reactive production of sclerosing bone, as in a bone scar. Such conditions are believed to result from

the stimulation of new bone formation by low grade bacterial infection in the affected region. Because such compact bone formation is almost never resorbed spontaneously, it remains visible in the radiograph over the long term.

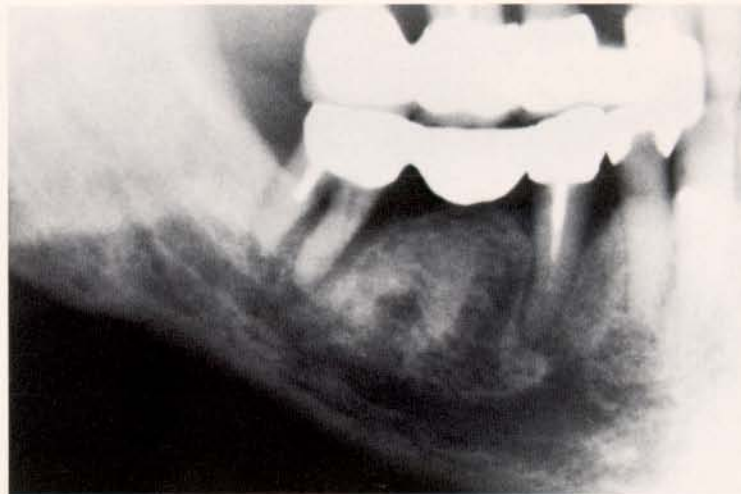419 Localized, primary chronic osteomyelitis

Following tooth extraction and delayed wound healing, this picture persisted four months after placement of the bridge between teeth 35 and 37. Observe the reactive sclerosis around the mandibular canal and the poorly defined alveolar border.



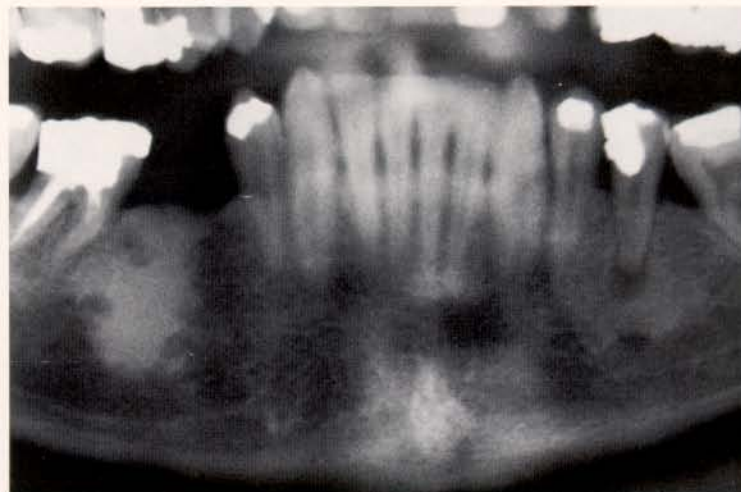
420 Condensing osteitis in the former alveolus of tooth 46

Tooth 47 exhibits a terminal marginal periodontitis with chronic apical periodontitis on the distal root. The extremely wide periodontal ligament space of tooth 45 is a sign of the occlusal overload and resulting mobility.



421 Reactive osteosis in the region of the former alveolus of extracted tooth 46

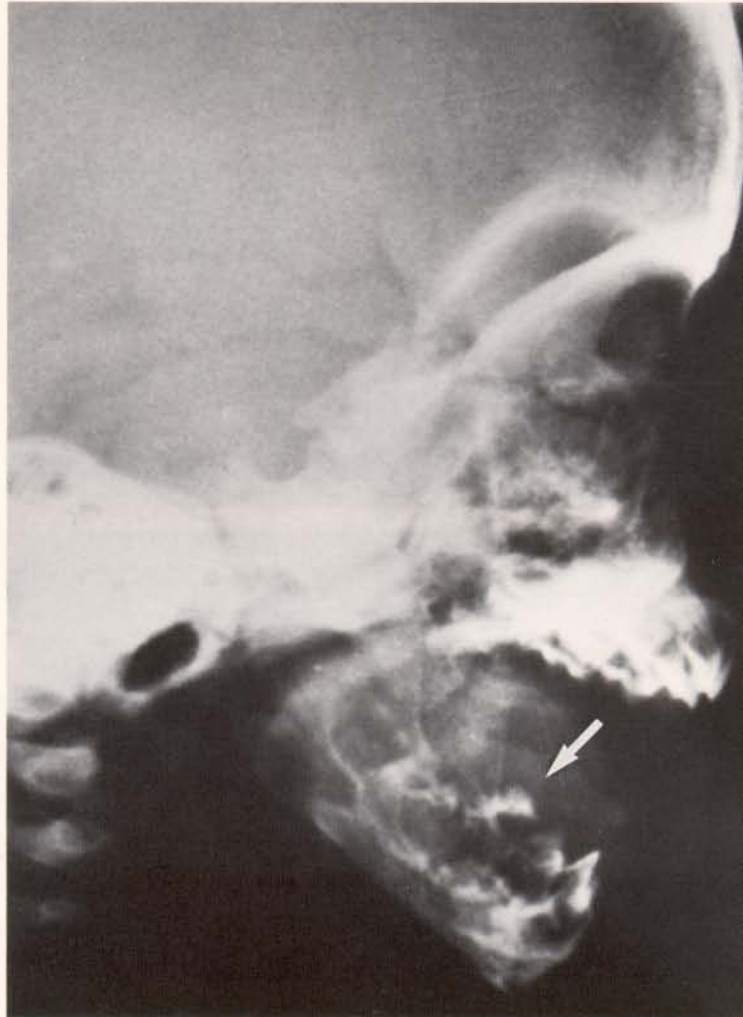Histologically, such cases exhibit compact bone without marrow spaces. As a comparison, note the chronic apical periodontitis on tooth 35, with extensive reactive sclerosis.



Osteomyelitis in Infants and Children

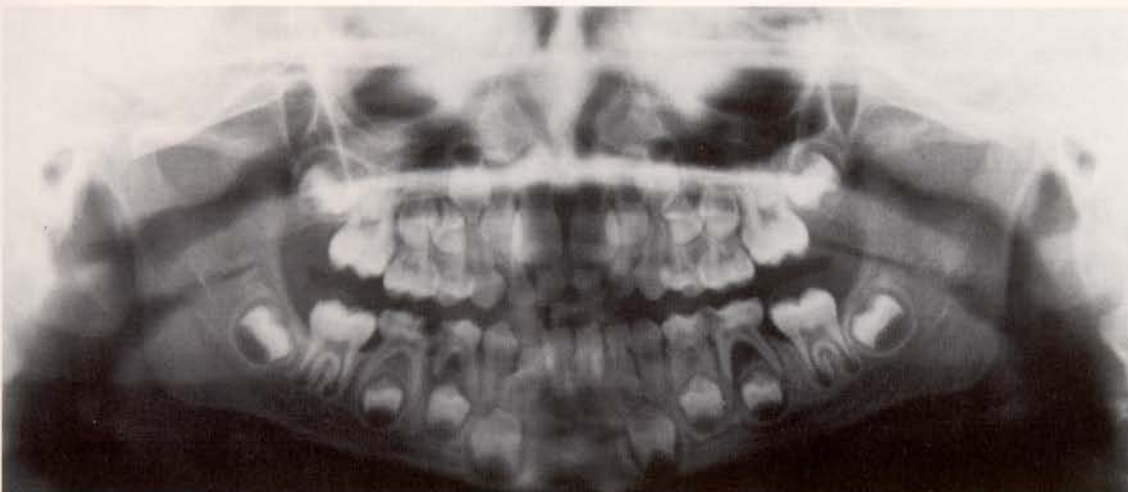
A life-threatening form of osteomyelitis may afflict babies and children. It takes the form of a severe toxic event that begins with a high fever and quickly develops into swelling in the facial area, especially in the maxilla. In the secondary chronic stage, osseous

necrosis often occurs, as well as sequestration of the tooth buds. Preschool children often develop maxillary osteomyelitis following pulpal necrosis of the mandibular deciduous molars; this sometimes results in loss of the permanent premolar tooth buds.



422 A 5-month-old child with osteomyelitis

The arrow depicts the sequestration of a mandibular deciduous molar, as it is often seen in the later stages of this disease.



423 Advanced caries on deciduous tooth 85

Pulpal necrosis was clinically evident on teeth 75 and 84, with interradicular osteolysis and a periapical abscess (84). Note the radiographic signs of local osteomyelitis in the region of teeth 85-83.

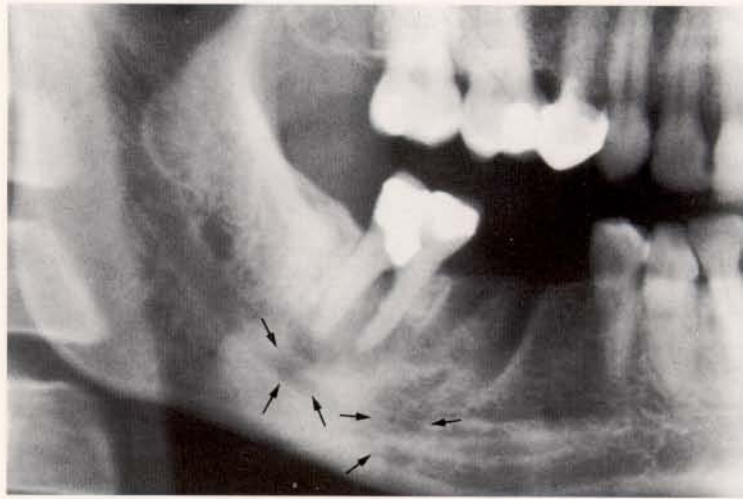
Acute Osteomyelitis

Despite the somewhat spectacular clinical picture that includes compromised general health, fever, swelling of the soft tissues, neurologic disturbances and characteristic “pounding” pain, acute osteomyelitis in its initial stage is not accompanied by any radiographically discernible manifestations. Additional clinical symp-

toms include increasing tooth mobility and a “woody” sound upon percussion of the affected teeth. The radiograph exhibits circumscribed radiolucencies only 1–2 weeks later as the first signs of initial demarcation of the necrotic areas.

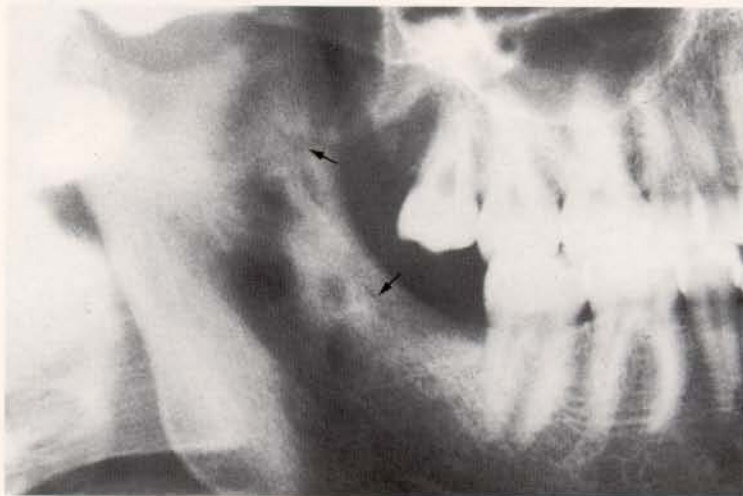
424 Acute osteomyelitis in an early stage, following extraction of tooth 46

In addition to the original signs of existing apical and periodontal lesions, the initial circumscribed radiolucencies are visible (arrows).



425 Acute osteomyelitis in the ascending ramus following extraction of tooth 48 and a fracture (arrows)

Initial and confluent areas of resorption surround the already sclerosed section as demarcation progresses.



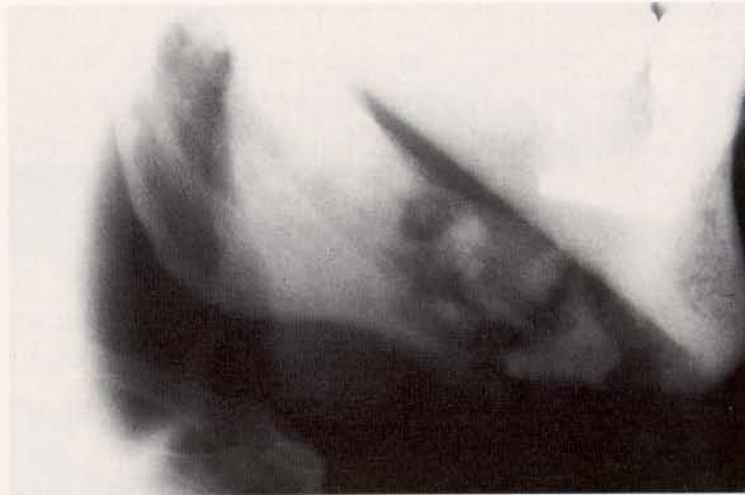Radiographic signs of osteomyelitis

- Acute osteomyelitis: Radiographic signs can only be observed after structural alterations have occurred.
- Secondary chronic osteomyelitis: 1–2 weeks after onset, expansive necroses with pus formation predominate. Lesions become circumscribed and periosteal reactions are observed.
- Primary chronic forms of osteomyelitis: Radiolucencies (bone resorption) and radiopacities (bone formation) present a “cloudy” or “cotton-like” radiographic picture.

Secondary Chronic Osteomyelitis

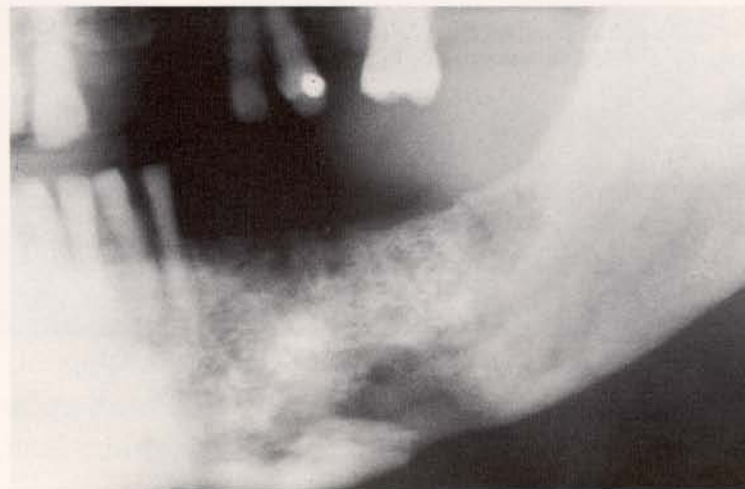If healing of acute, suppurative osteomyelitis does not occur, after approximately 2 weeks the secondary chronic form ensues. The radiographic picture of this form is dependent upon the localization and the effectiveness of therapy. Radiographically one may see con-

fluent areas of bone resorption and demarcation of necrotic areas in the bone. In the absence of appropriate therapy, spontaneous fractures often occur. Thanks to modern antibiotic therapy, this form of osteomyelitis is seldom encountered today.



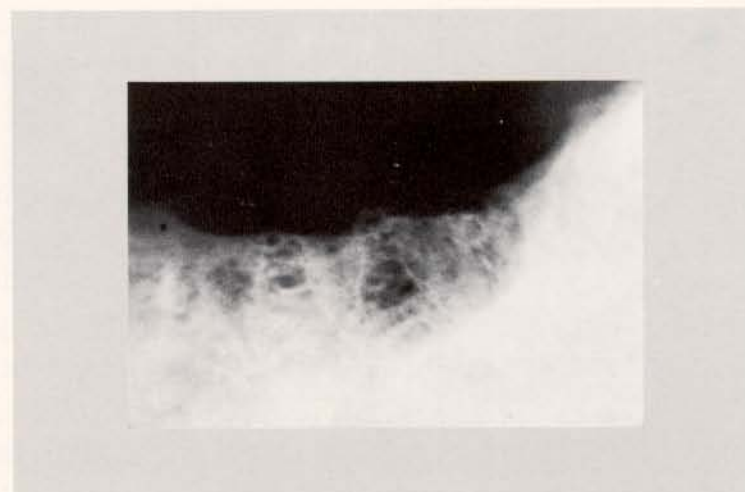
426 Secondary chronic osteomyelitis after extraction of tooth 37 and delayed wound healing

Readily visible are the coalescing, poorly demarcated radiolucencies, which correspond to bone marrow necrosis, in addition to demarcation and sequestrum formation.



427 Secondary chronic osteomyelitis with necrosis and sequestrum formation

The sequestrum is clearly visible near the bottom of this picture.



428 Same case, as seen in a periapical film

This film points up how little can actually be observed in a periapical radiograph when, for example, soft tissue swelling makes it impossible to position the film packet correctly.

Primary Chronic Osteomyelitis, Osteoradionecrosis

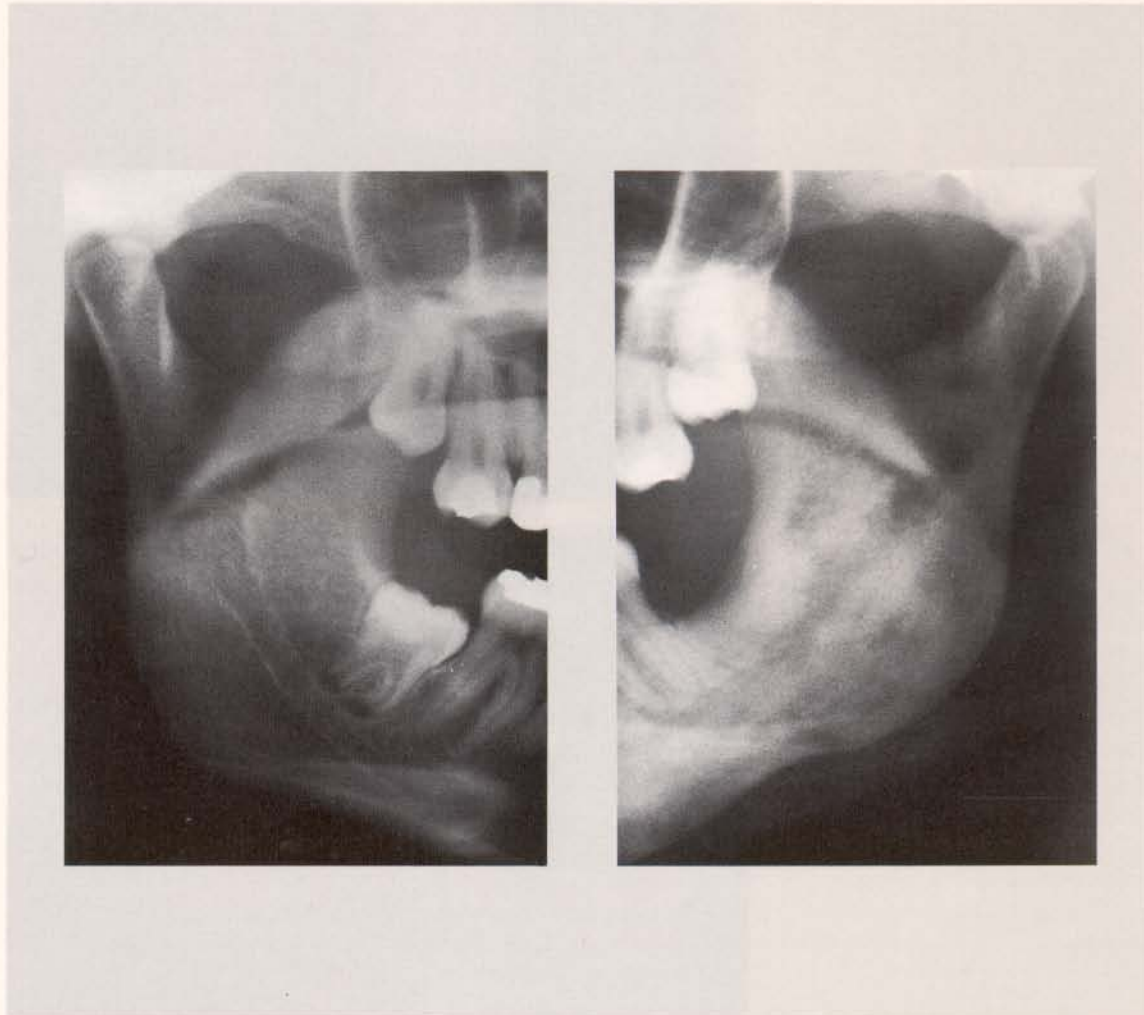
The primary chronic forms of osteomyelitis are often seen today. Symptoms are rare early on, and massive remodeling within bone determines the radiographic diagnostic picture; this can be accompanied by massive distension of the bone that is undergoing vascular

damage. However, the pathologic processes may present in various ways, with structural changes resembling clouds or cotton, as osseous resorption and formation persist and alternate within the bone.

429 Primary chronic osteomyelitis in a left-right comparison following extraction of tooth 38 and delayed wound healing

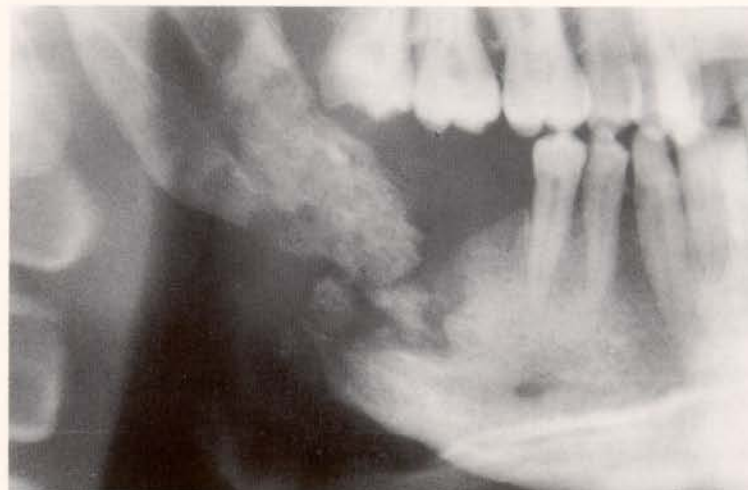Note the dense cloud/cotton-like structure and the loss of normal anatomic picture of the mandibular canal on the right; compare this with the ascending ramus of the mandible on the healthy side. Paresthesia is often reported by these patients, as well as distension of the bone on the affected side.

Courtesy Dr. P. Ledermann,
Herzogenbuchsee



430 Osteoradionecrosis with sequestration and spontaneous fracture

The radiographic appearance in cases of osteoradionecrosis is generally similar to that of secondary chronic osteomyelitis. Of note is that following massive irradiation of the bone, the periosteum is no longer capable of mounting an effective reparative response because of the vascular damage. The periosteal reaction is a typical radiographic sign.



Dentogenic Sinus Pathology

Ninety percent of all sinus disorders are of rhinogenic origin and are therefore not usually treated by the dentist. The maxillary sinuses, on the other hand, represent an exception because the dentist's area of concern is immediately adjacent. Many normally encountered dental problems such as acute and chronic periapical or periodontal lesions in the maxilla can lead to collateral inflammation of the periosteum or to reactive swelling of the sinus mucosa. Foreign body reactions following endodontic therapy and inflammation of the maxillary sinuses accompanying dentogenic cysts, tumors or fractures of the maxilla are certainly possible. While there can be no doubt that the treatment of diseases of the maxillary sinuses resides in the hands of appropriate specialists, one must concede that the dentist is in an excellent position to observe and diagnose dentogenic disorders of the maxillary sinuses, based upon his specific knowledge. On the other hand, it is well known that patients often seek out the dentist first when they experience acute or chronic inflammation of the maxillary sinus, even when such inflammation is not of dentogenic origin. This is because in such conditions the maxillary premolars and molars are painful during chewing. The elevated percussion sensitivity and the reduced reaction to standard vitality tests can lead the dentist initially into diagnostic difficulties if only one vital and restored tooth is involved. If several vital teeth are involved, and if the roots of these teeth exhibit a close anatomic relationship to the floor of the sinus and if no additional clinical signs are observed, the appropriate clinical diagnosis is simplified but the radiographic picture will exhibit no changes, especially in acute or early cases.

Until a few years ago it was difficult, if not impossible, for the dentist to provide a radiologic diagnosis in this area because the periapical radiograph, as a result of its format and the special projection of the central ray, depicted at best only the floor of the maxillary sinus and only from an oblique angle. The typical periapical radiograph is not indicated for examination of the maxillary sinus because of the danger of incorrect interpretation. Only the panoramic radiograph has given us new possibilities in this realm; it can provide an appropriate view of at least the alveolar portion of the maxillary sinuses, which can enhance our clinical examinations in terms of possible dentogenic participation.

More sophisticated radiographic methods are available to the dentist only in special clinics or in particular cases because the techniques for radiographic examination have changed considerably in the last few years. The standard technique that is still used most commonly today is the Waters' projection. This is being replaced more and more by computed tomography, which provides perfect observations of on-going pathology through bone and soft tissue windows. Despite these advances in technology, today's dentist should be aware of the possibilities and limitations of conventional examination methods in order to provide appropriate patient treatment and referral.

Panoramic Radiography of Dentogenic Sinus Pathology

Collateral inflammation radiating from periapical lesions may elicit local osteomyelitis of the maxilla (in addition to periostitis and polyp-like alterations of the sinus mucosa), and can lead to acute and chronic inflammation of the maxillary sinuses. In contrast to inflammation of rhinogenic origin, such dentogenic sinus pathology is usually unilateral, but this rule also has its exceptions.

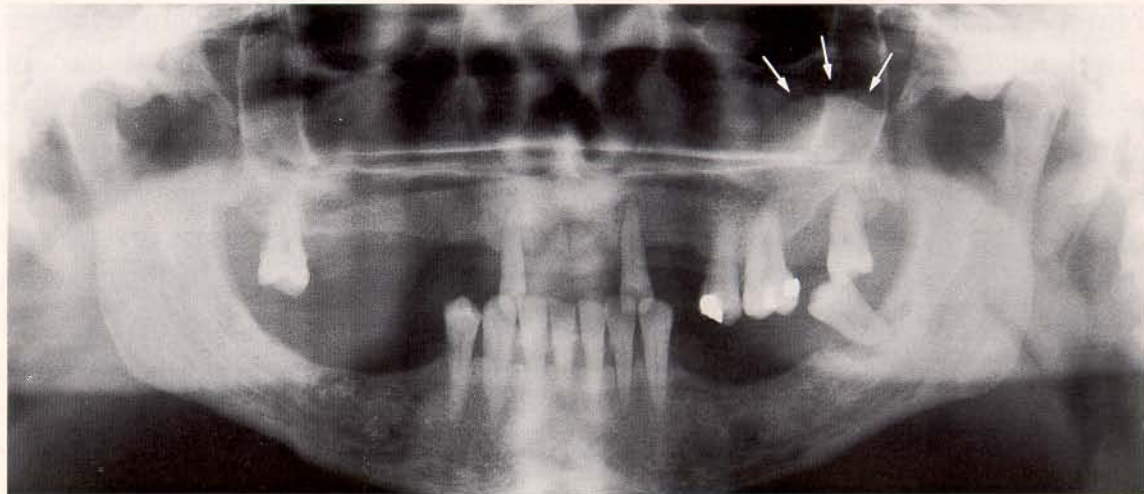
Inflammation radiating from periodontal lesions may also cause periostitis, polyp-like thickening of the

sinus mucosa as well as acute and chronic inflammation of the maxillary sinuses.

In addition to rhinogenic sinus pathology, which will not be discussed here, incorrect positioning of the patient can also lead to masking of the sinus region, and this may lead the inexperienced to a diagnosis of sinusitis. Following thorough dental examination, radiographic evidence of sinus pathology should be referred to the appropriate medical specialist for clarification. The possibility that the teeth may be involved, however,

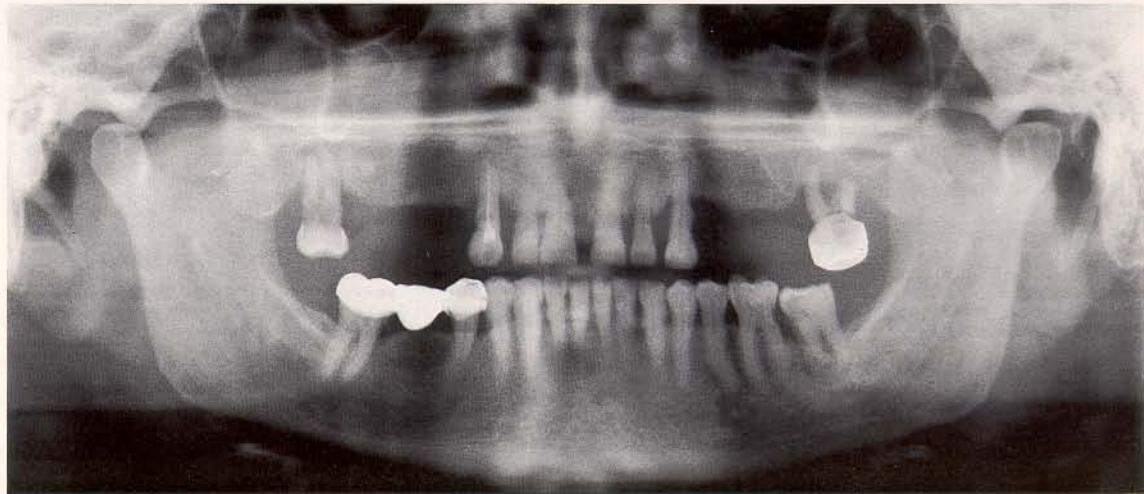
431 Unilateral polyposis of the sinus mucosa, of dentogenic origin

This lesion originated from advanced marginal periodontitis on tooth 28 (arrow).



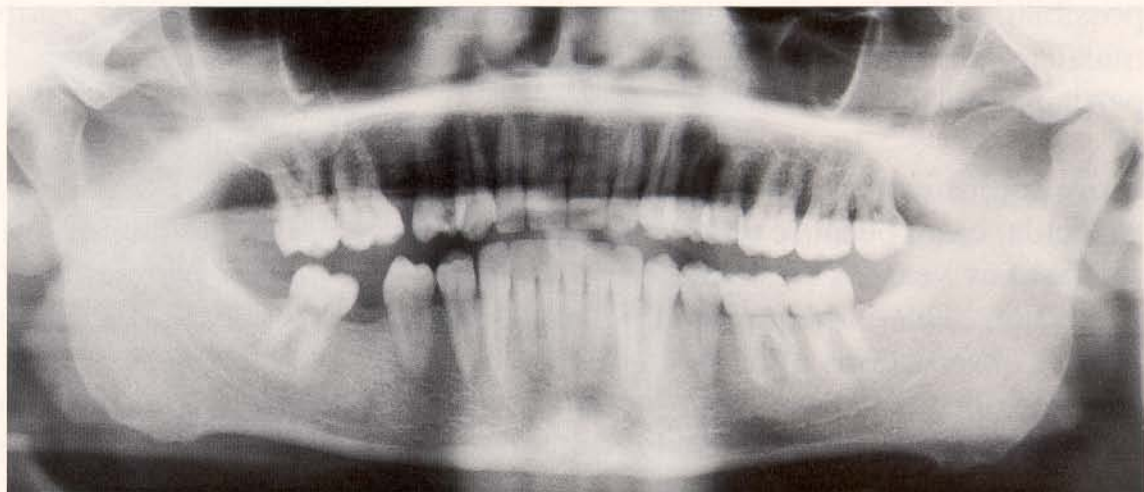
432 Bilateral sinus pathology of dentogenic origin

Tooth 27, with severe periodontal involvement, appears associated with polyp-like thickening of the sinus mucosa, but without sinusitis. The nonvital, periodontally compromised tooth 17 is associated with radiopacity of the entire sinus, presenting as unilateral dentogenic sinusitis.



433 Incorrect positioning of the patient

If the patient's chin is elevated, the radiograph will present a picture resembling radiopacity of the maxillary sinus, which could lead to an incorrect diagnosis.

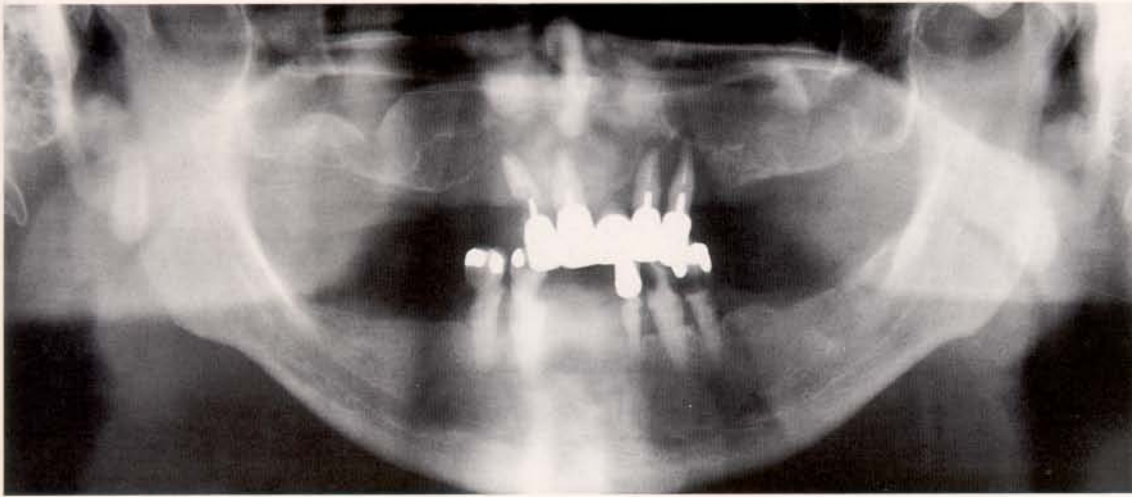


must not lead the dentist to premature devitalization and endodontic therapy. Careful observation may be more appropriate.

During radiographic examination, the following must be noted:

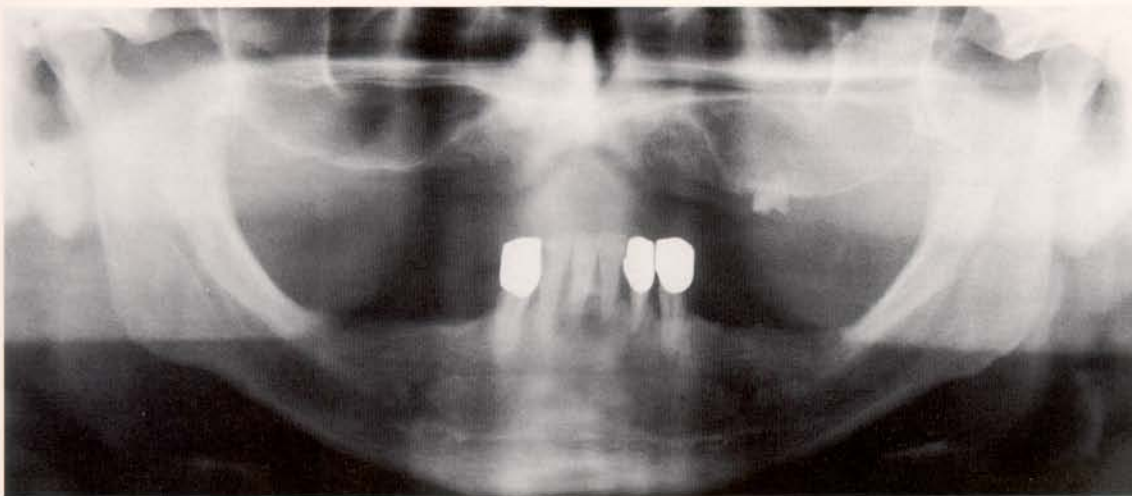
- Only the alveolar recess of the maxillary sinuses can be observed and examined in terms of possible relationship to a dentogenic etiology.

- Care must be exercised during interpretation or observation of *all other* sections of the maxillary sinus.
- Be certain that the patient is properly positioned and the central ray is properly aimed.
- If a *nondentogenic* cause is suspected, referral to the appropriate specialist is indicated.



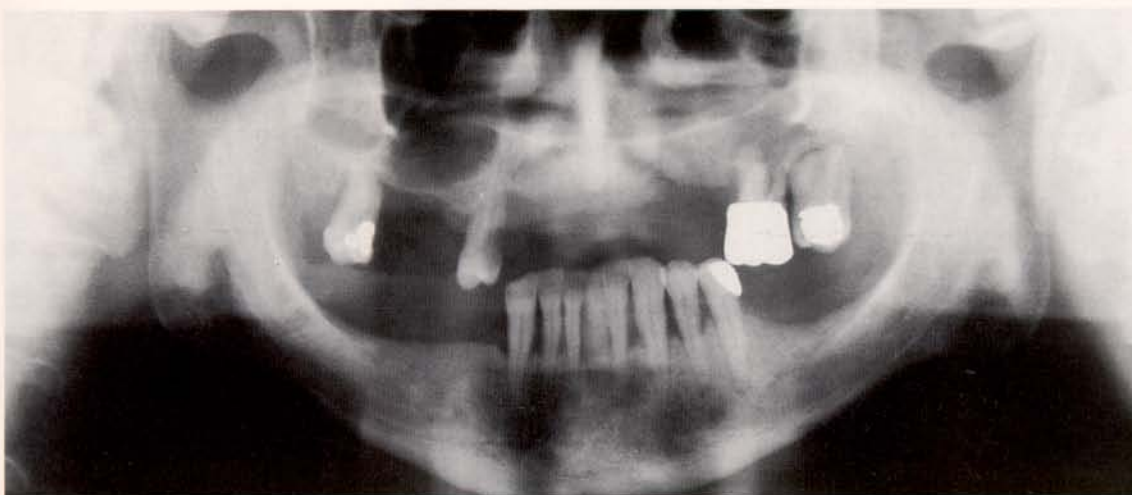434 Polyposis of the maxillary sinus mucosa, of dentogenic origin

The nonvital teeth 12, 11, 22 and 23 are associated with local periapical osteomyelitis. The result is a bilateral polyp-like thickening of the sinus mucosa. Aside from this, however, both maxillary sinuses contain air and are without symptoms.



435 Unilateral acute maxillary sinusitis of dentogenic origin

The retained root tip (tooth 25), displaying an apical radiolucency, has caused a unilateral dentogenic sinusitis. Compare the healthy, air-containing sinus on the right side.



436 Unilateral chronic maxillary sinusitis of dentogenic origin

The chronic apical periodontitis from tooth 27 has caused local osteomyelitis with loss of normal appearance of the inferior border of the sinus; in addition, the massive radiopacity (shadowing) of the left sinus is obvious.

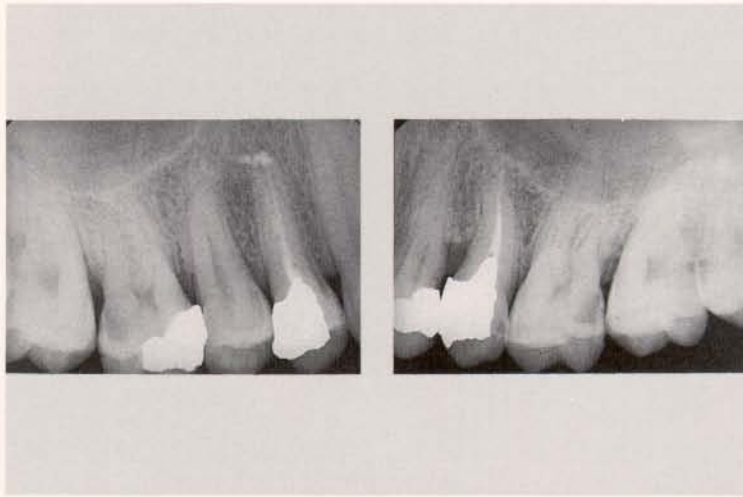
Additional Signs of Dentogenic Infection

Any practical comparison between periapical radiographs and panoramic films will demonstrate that many types of mucosal reactions, e.g., the mucocele, can be satisfactorily depicted only in the panoramic film. The vague radiopacity sometimes seen on periapical films

may lead to a suspicion of pathology, but even panoramic radiography does not permit perfect diagnosis in every case. Therefore it is necessary in any ambiguous situation to supplement with additional examination methods.

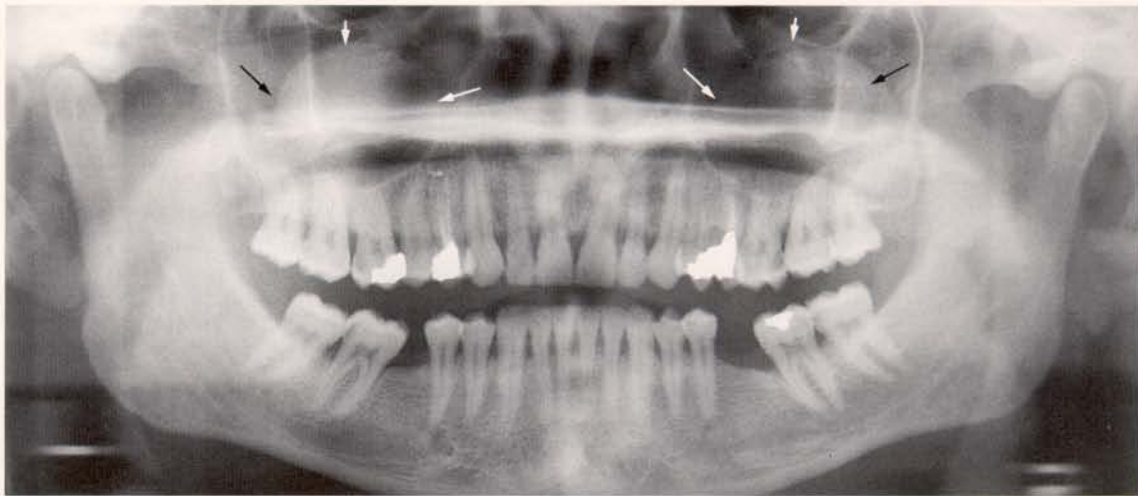437 Periapical radiographs of the premolar-molar region

The film depicts endodontic treatment of teeth 14 and 25, as well as deep proximal caries on the distal surfaces of teeth 16 and 26. The floor of the sinus appears more radiopaque than normal, but interpretation of this observation is not possible without a more comprehensive depiction.



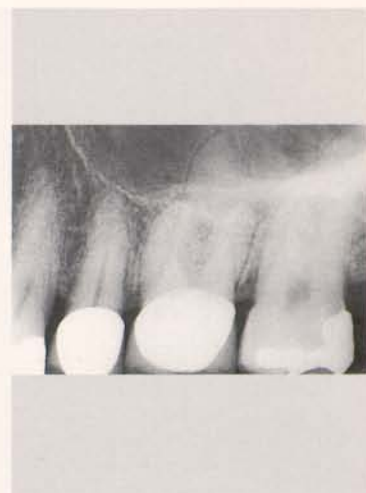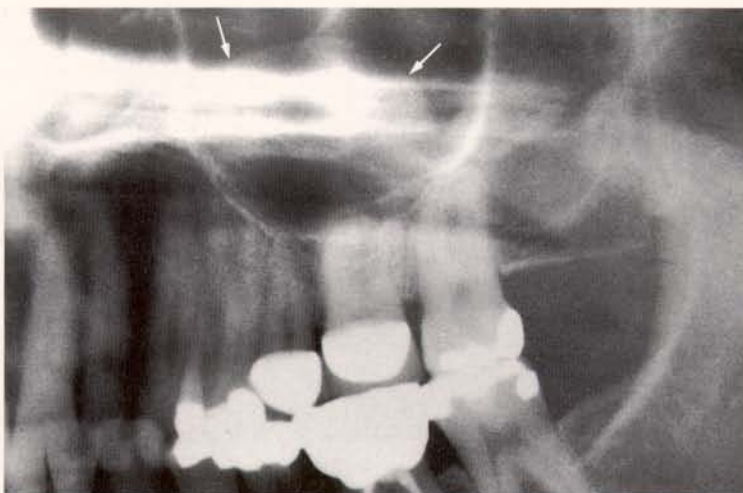
438 Panoramic radiograph of the same case

Massive round opacities in both sinuses (arrows) indicate the presence of mucoceles (mucosal retention cysts). In the periapical films (Fig. 437), these lesions shadow only the floor of the sinus, and thus do not permit a differential diagnosis.



439 Development of a mucocele around the root of nonvital tooth 26, with pulpal necrosis following trauma during tooth preparation

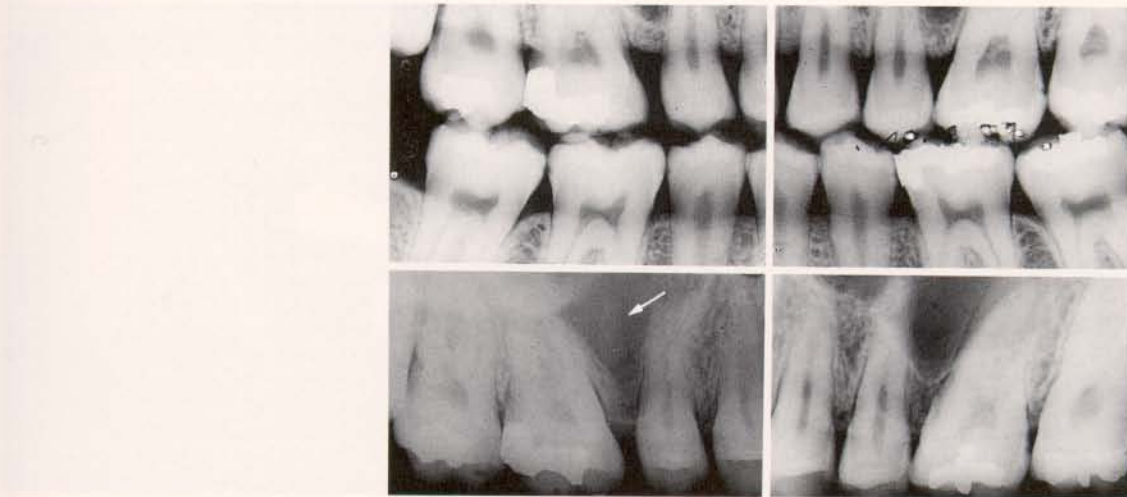
Comparison between the panoramic radiograph (arrows) and the periapical radiograph of the same case.



Incidental Findings and the Significance of the Waters' Projection

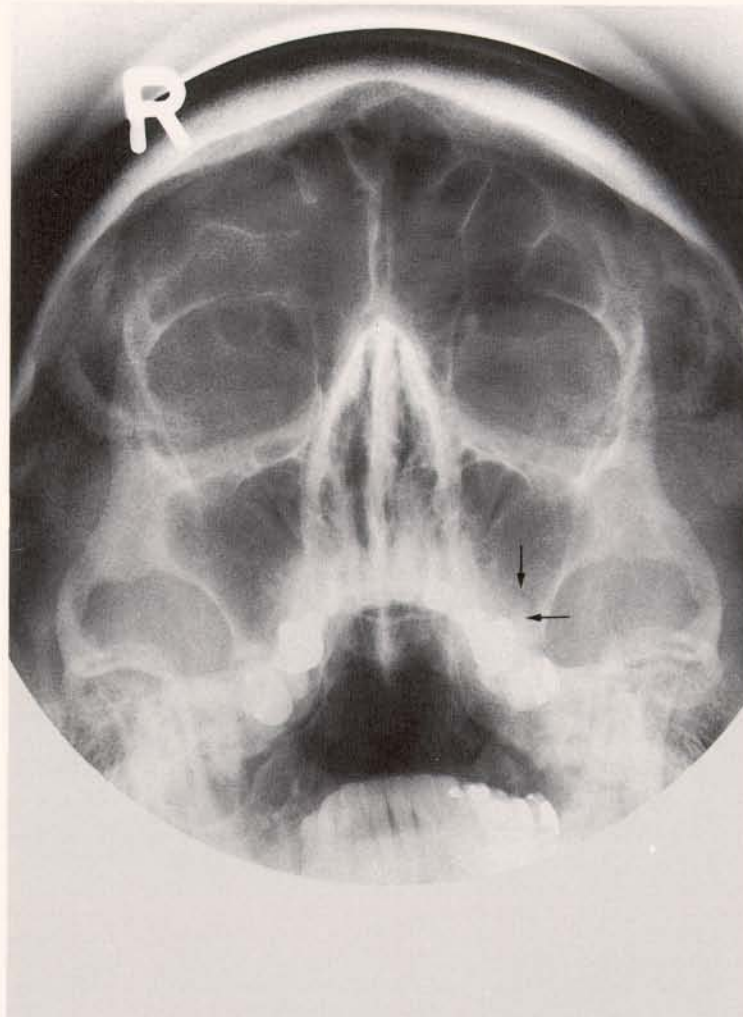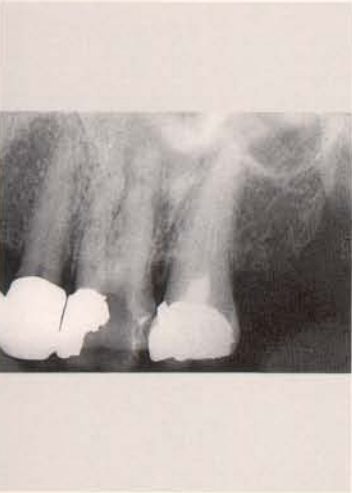Careful examination of routine radiographs such as periapical films or bite-wing radiographs often leads to a suspected diagnosis, which must be corroborated by panoramic radiography and sometimes by the Waters' projection. Despite tomography and CT, the Waters'

view remains the basic film of choice in cases of sinus pathology, although it is noteworthy that the posterior segment of the sinus above the molars is sometimes obscured and may therefore lead to incomplete examination.



440 Retained root tip of tooth 55 as seen in the bite-wing radiograph

Careful observation of the bite-wing film reveals a diastema between teeth 15 and 16. The periapical radiograph of the region reveals a retained root tip of deciduous tooth 55 in a sinus that appears more radiopaque than normal (arrow). After comparing these two radiographic views, it is clear that only a panoramic radiograph will permit a complete diagnosis.



441 Osteomyelitis of the floor of the sinus, without accompanying sinusitis

The periapical film depicts a radiopacity around tooth 26, as well as some structural abnormality resembling local osteomyelitis. The Waters' radiograph subsequently confirmed (arrows) the localized inflammation not affecting the sinus, which presents a normal air-containing appearance. The region of teeth 26 and 27, however, is not depicted in a manner conducive to diagnosis.

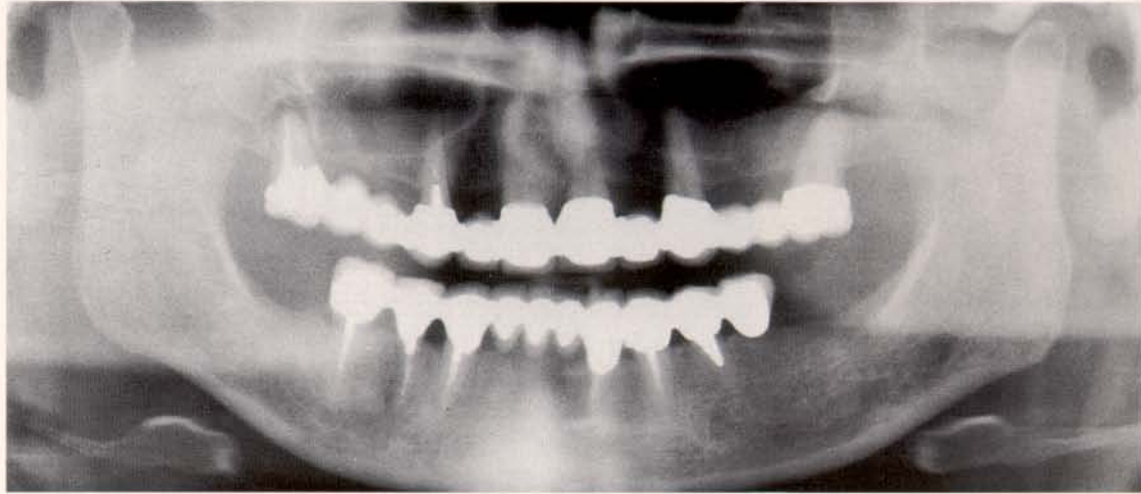
Acute Unilateral Dentogenic Sinusitis

The comparison of both types of films clearly shows the possibilities and limitations of panoramic radiography, and the supplementary diagnostic possibilities provided by the Waters' projection in cases of acute dentogenic sinusitis. On the one hand, in the panoramic radiograph the opacity of the affected sinus is limited to the

posterior segment of the sinus, while the Waters' projection depicts the complete expanse of the acute inflammation as seen in comparison to the healthy and air-containing left side. This is possible because of the posteroanterior central ray projection.

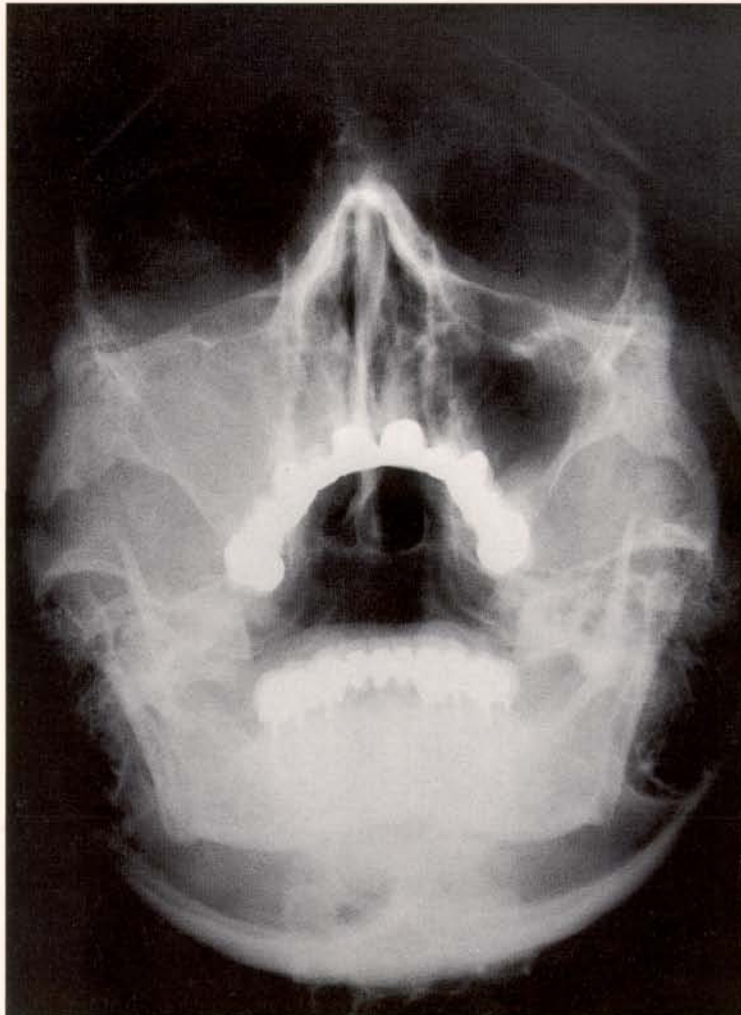442 Acute unilateral dentogenic sinusitis as seen in the panoramic radiograph

The affected tooth 17 reveals acute apical periodontitis. The anterior segment of the sinus appears free of radiopacity. Clinically, this was ascertained to be acute sinusitis in an early stage.



443 Acute unilateral dentogenic sinusitis as viewed in the Waters' film

Same case as in Figure 442. The affected sinus is uniformly radiopaque and the borders of the sinus remain visible. In cases of progressive inflammation, the distinct boundaries of the sinus may disappear. Purulent inflammatory processes appear as a horizontal fluid "level." Chronic conditions are seen as a more or less clear thickening of the borders as a result of reactive sclerosis of the surrounding bone; this is especially apparent in the area of the zygomaticoalveolar crest.

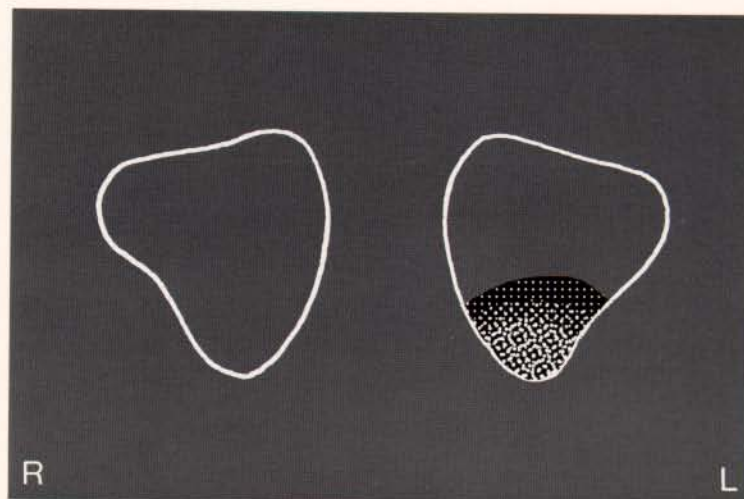


Schematic View of Sinus Diagnosis in the Waters' Projection

Radiographic diagnosis of the maxillary sinus is just as complex as any other region of the human body. It is important to emphasize at this point that radiographic diagnosis of pathologic changes in the maxillary sinuses belongs primarily in the hands of specialists and will therefore not be discussed in detail here. However, in order to provide the dentist with sufficient understanding of the radiographic signs of dentogenic, inflammatory pathology of the maxillary sinus, an attempt is


made here to present a schematic view, despite all of the diagnostic difficulties and without any claim to completeness. It is important to note that it is impossible to depict all combined forms of mucosal and endosseous reactions.

These diagrams are intended to represent the maxillary sinuses schematically as they would be seen in a Waters' projection.



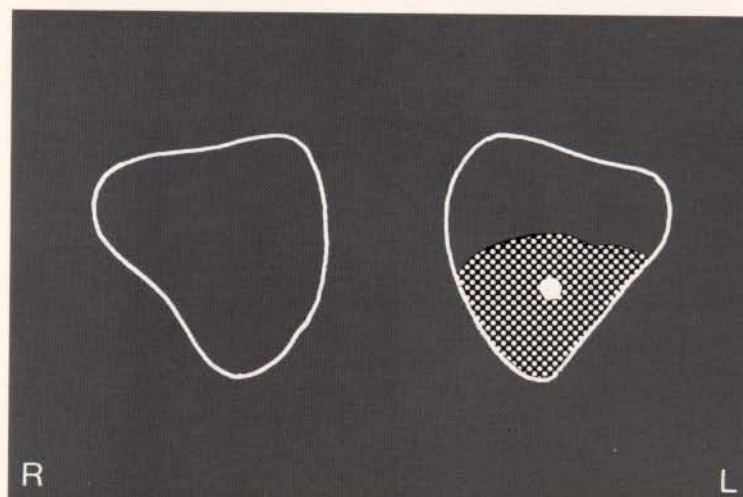
444 Unilateral dentogenic infection

Polyp-like thickening of the mucosa in the alveolar segment of the maxillary sinus. The remainder of the sinus contains air and is therefore without pathology.



445 Mucocele (mucosal retention cyst)

The mucocele often presents in an infected sinus as a radiolucency and in a normal, air-containing sinus as a spherical radiopacity that is often surprisingly large. Mucoceles may result from a reaction to chronic irritation of the maxillary sinus mucosa, or may also occur after radical surgical procedures (e.g., Caldwell-Luc).




446 Foreign body reaction around extruded root canal filling material or other foreign bodies

Unless an accompanying sinusitis develops, the remainder of the sinus is air-containing.


447 Acute unilateral (usually) dentogenic sinusitis

The radiographic diagnosis can only be established after several days. The sinus is evenly radiopaque; the sinus borders are more or less visible and of normal thickness.



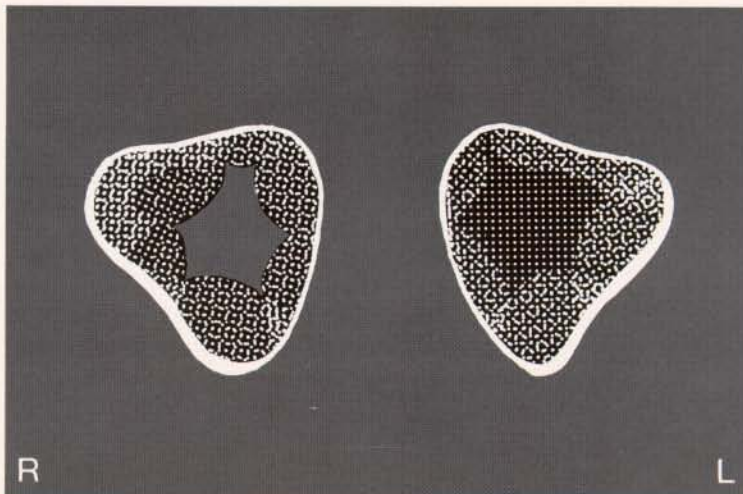
448 Acute bilateral (usually) rhinogenic sinusitis

Radiographic signs as described above are usually bilateral. The uniform radiopacity is caused by mucosal swelling and fluid accumulation.



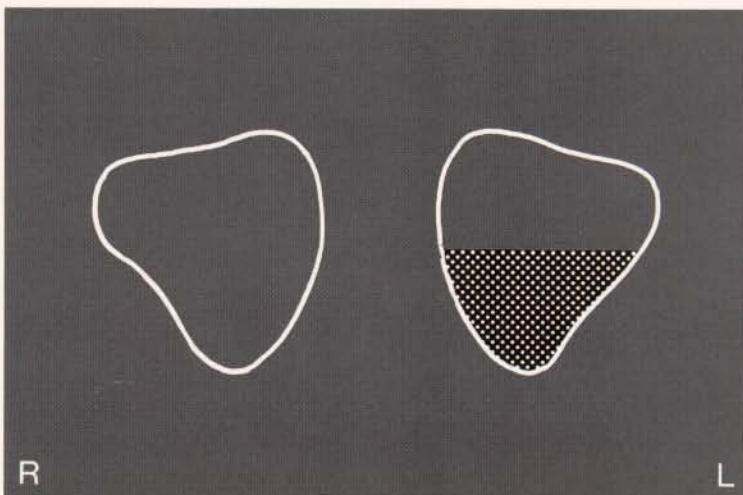
449 Chronic bilateral maxillary sinusitis, with acute exacerbation (left)

Assumption: Presence of rhinogenic chronic maxillary sinusitis, complicated on the left side by an additional dentogenic infection. General signs: The thickened sinus mucosa surrounds the air-containing center. The zygomaticoalveolar crest exhibits reactive sclerosis. On the left side the pathology is superimposed with exudate (empyema).



450 Unilateral fluid level

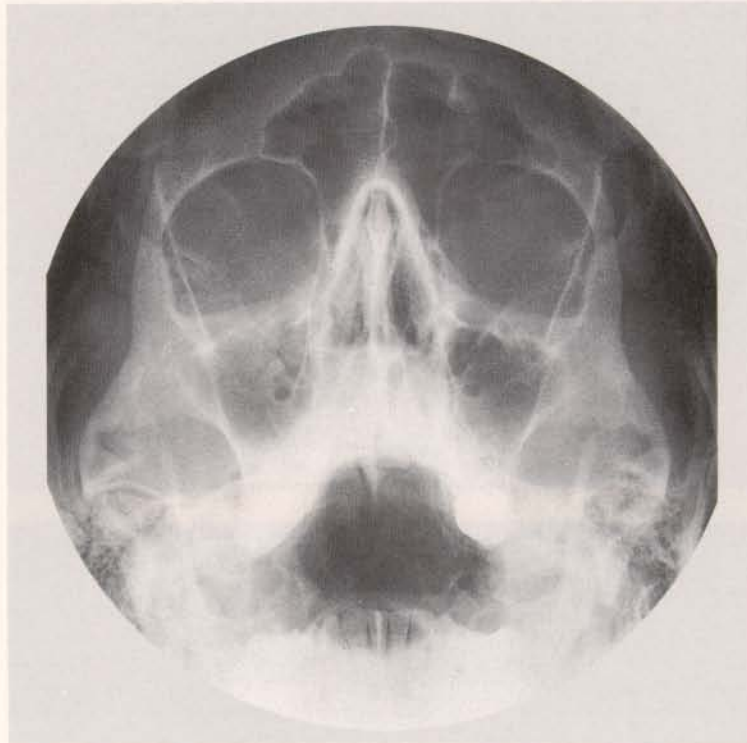If the radiographs are made with the patient in a seated position, the sinus empyema shows itself by the apparent "fluid level." In cases of maxillary fractures similar radiographic signs are observed if the sinus partially fills with blood.



Acute and Chronic Maxillary Sinusitis

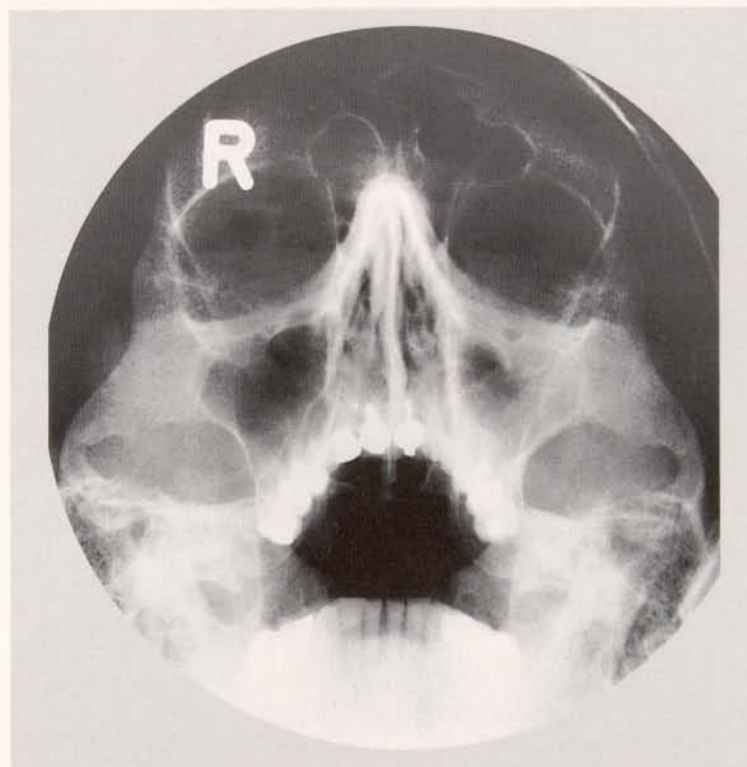
In its initial stages, incipient sinusitis is only discernible (if at all) in low voltage Waters' films. Since even bilateral rhinogenic sinusitis can begin as a unilateral affliction, it is possible to confuse it with a dentogenic infection, especially when nonvital teeth are present. However,

dentogenic chronic sinusitis may appear to arise not only from premolars and molars, but also from anterior teeth. Tomography or CT may be employed as a supplemental diagnostic method.



451 Initial bilateral rhinogenic sinusitis

This low-voltage radiograph depicts a unilateral incipient rhinogenic maxillary sinusitis. The right sinus remains mildly radiopaque and the only radiolucency is the foramen rotundum.



452 Unilateral chronic maxillary sinusitis of dentogenic origin

Clearly visible are the irregular thickening of the mucosa with air-containing central portions and the reactive sclerosis of the zygomaticoalveolar crest. In the anterior region, the nonvital teeth of the maxilla were completely symptom-free following root-tip resection.

Computed Tomography for Supplemental Diagnosis

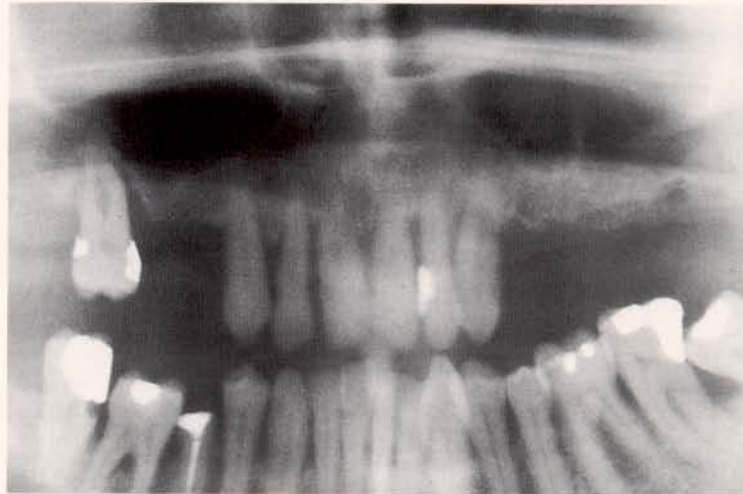
Regardless of its origin, a more or less asymptomatic chronic maxillary sinusitis is not always easy to detect on the panoramic radiograph, where other diagnostic problems assume primary importance. Only a carefully documented medical history and thorough clinical examination will provide the clinician with sufficient

information to justify further radiographic examination. In addition to the radiographs, CT is often employed now to provide an axial depiction of the maxillary sinus without superimpositions; this permits diagnostically important left-right comparison.

453 Chronic dentogenic sinusitis

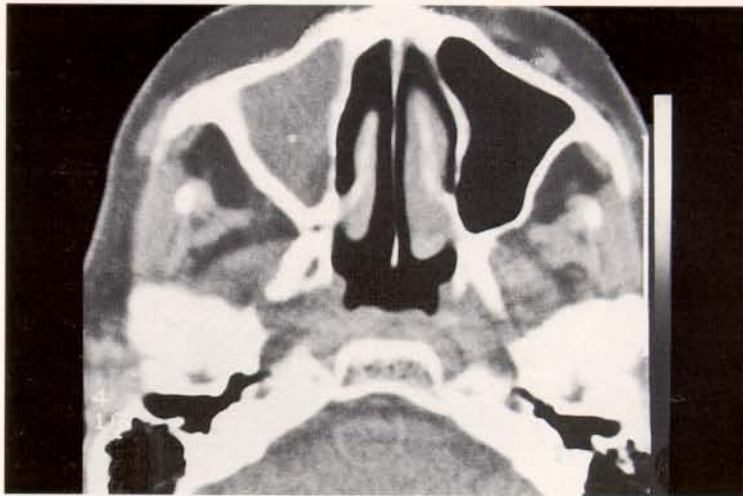
The radiograph compares the alveolar segment and the osseous structure. Only a slight radiopacity of the sinus and sclerosis of the alveolar ridge are visible on the left side.

Courtesy Dr. J. Samson, Geneva



454 Chronic dentogenic sinusitis as viewed by CT

An axial CT with soft tissue window shows almost complete obliteration of the left sinus caused by the thickened mucosa. Clearly visible is the reactive sclerosis of the left sinus wall.



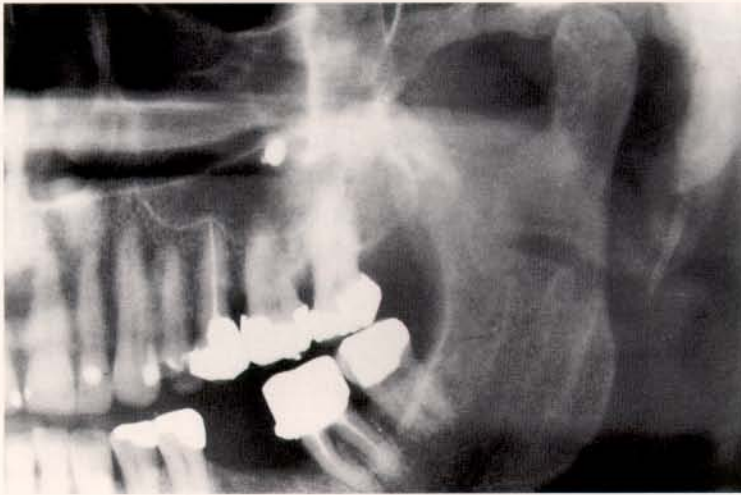
Possibilities of Tomography and Computed Tomography in Sinus Diagnosis

Tomography

- Lateral and, in particular, anterior views for localization of fracture fragments and foreign bodies. Conventional depiction of soft tissue pathology.

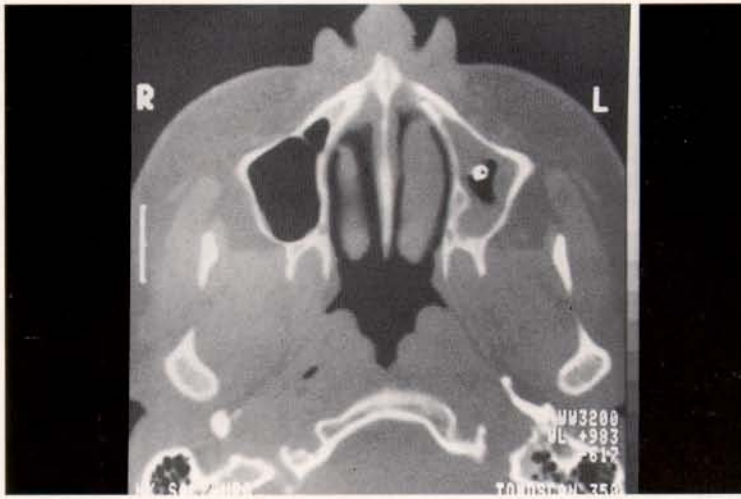
Computed tomography

- Particularly axial depiction in lateral comparison using the bone and soft tissue windows, and the possibility for measuring radiopacity density.



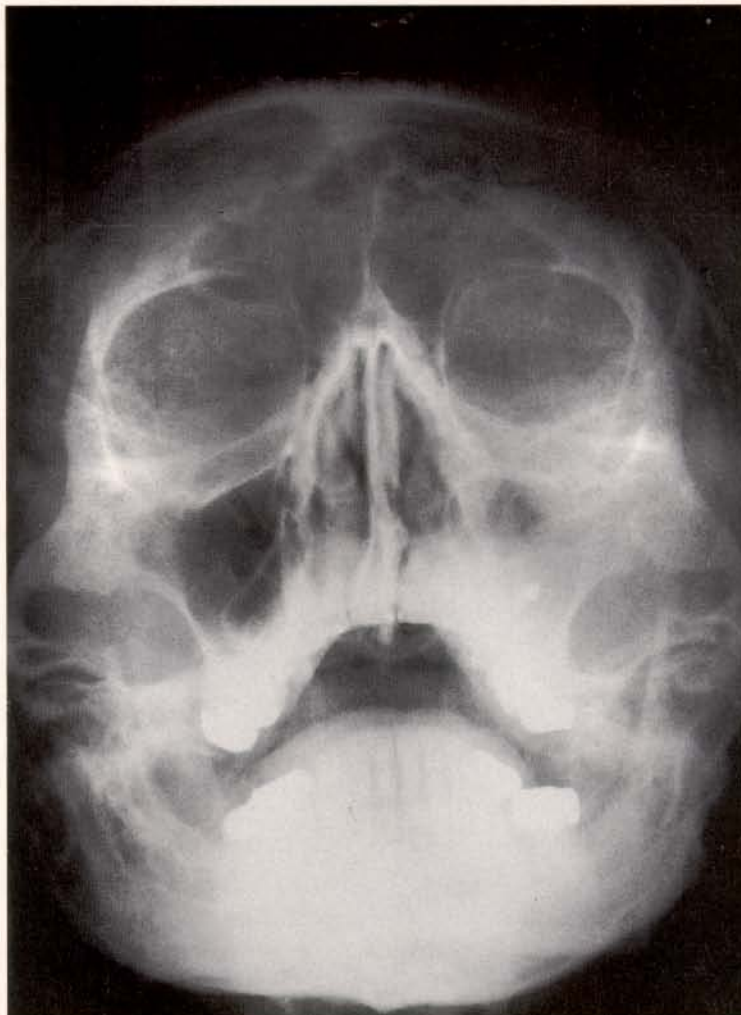
455 Aspergillosis of the maxillary sinus

This section from a panoramic radiograph depicts an opaque residue in the sinus from the overfilled root canal of tooth 25. The maxillary sinus does not appear shadowed.



456 Axial CT with soft tissue window

The computed tomogram of the same case reveals that the left maxillary sinus is almost completely filled with soft tissue structures. In the center of the sinus the opaque remains of the root canal filling can be seen. Reactive sclerosis is obvious in the medial sinus wall.



457 Identical case, Waters' skull film

Surrounding the opaque root canal filling material, the shadow caused by the concentric growth of the mycelium can be seen. As a consequence of this aspergillosis, the patient had suffered for many years from recurrent unilateral sinusitis.

Courtesy Dr. H. Beck-Managetta, Salzburg

Foreign Bodies, Root Fragments and Surgical Defects

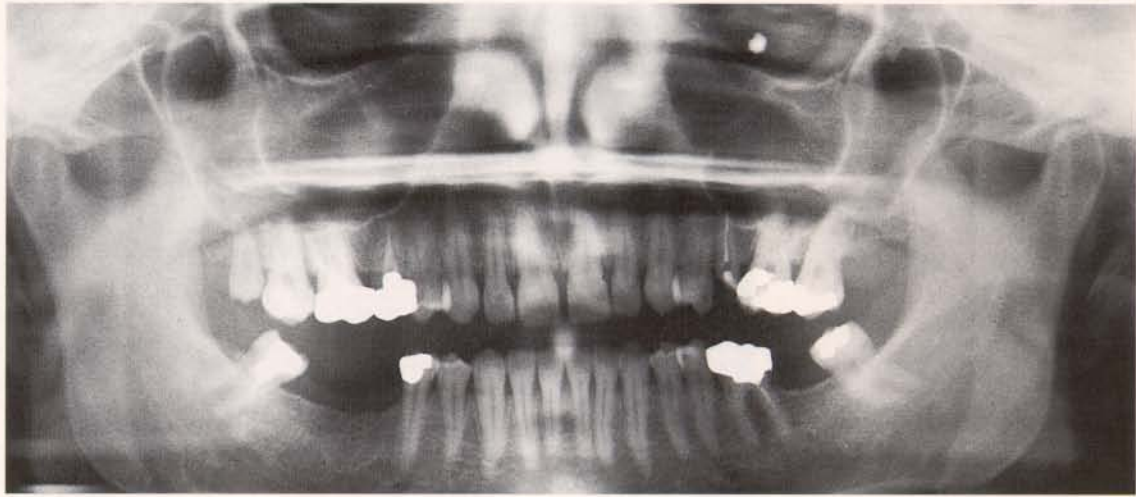
Foreign bodies such as excess root canal filling materials often remain harmlessly in the sinus. Sometimes an aspergillosis ensues, however, which leads to the development of chronic sinusitis.

In general, root fragments are considerably easier to detect on a panoramic radiograph than in a periapical

film, and this can obviate the necessity for additional films to localize the fragment. The oroantral fistula, which can be clinically diagnosed, can also be clearly documented in a panoramic radiograph due to the shadowing in the alveolar segment of the sinus and the frequent loss of clear sinus demarcation.

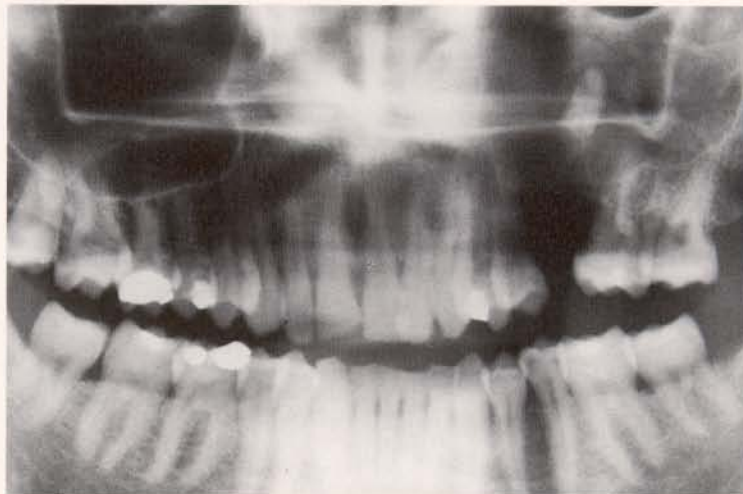
458 Remnants of root canal filling from tooth 25 located dorsally and superiorly in the left maxillary sinus

Note that portions of the maxillary sinus and the orbit overlap in the panoramic radiograph (cf. 25ff.).



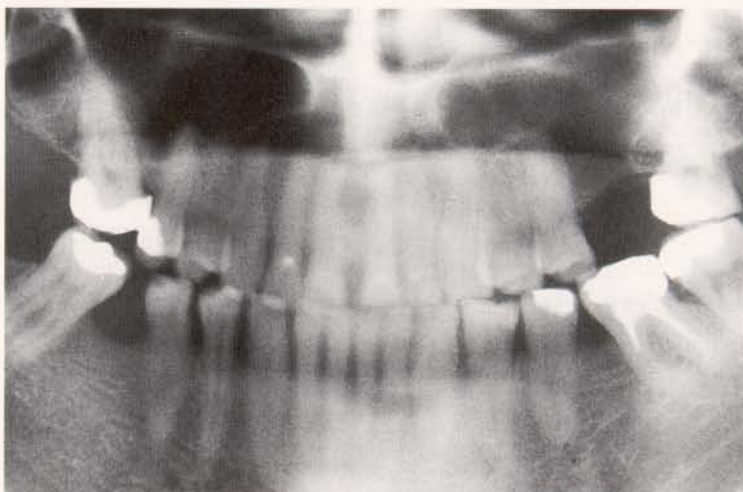
459 Root fragment of tooth 26 in the maxillary sinus

The fragment lies superior to the level of the root tips of other teeth and does not exhibit a periodontal ligament space. The surrounding sinus appears shadowed.



460 Oroantral fistula, left

The slightly opaque left maxillary sinus does not exhibit the demarcation line of the alveolar sinus segment around tooth 26.



Temporomandibular Joint Disturbances

This broad term encompasses a wide range of radiologic findings in the temporomandibular joint that represent deviations from the normal. The possibilities for compromised function of the temporomandibular joints and for pathologic alterations are numerous, and may include:

- Developmental disturbances
- Early childhood trauma
- Spreading inflammation
- Systemic disorders
- Neoplasia
- Accidents
- Occlusal dysharmony

Each of the etiologies listed above may lead to functional disturbance of the affected joint, which may in turn cause the development of degenerative changes in the temporomandibular complex.

In earlier times, the dentist seldom had the opportunity to examine radiographically both the jaws and the teeth at the same time. Today, however, the routine panoramic radiograph provides the opportunity to depict the masticatory organ as a functional entity, and to include all of its components in a comprehensive radiographic interpretation, accepting that the film is not a *precise* representation. The dentist should always examine and treat the masticatory organ as a complete yet complex functionally integrated entity consisting of the jaws, the temporomandibular joints, the occlusal system, and the masticatory muscles. For example, even minor occlusal dysharmony can adversely affect muscle tone and condylar position. Today, such facts may be taken for granted during clinical examinations, but even modern radiographic methods do not offer the opportunity to depict the masticatory system as a functional entity. Only the panoramic radiograph allows appropriate observation and inspection of the masticatory structures and the position of the condyles with sufficient quality, depending upon indication and proper selection of projection technique. It is important to point out, however, that in many cases it will be necessary to employ other radiographic methods of examination in order to accrue all the necessary diagnostic information.

The interpretation of any type of temporomandibular joint radiograph is not an easy matter, especially because clinical findings and the radiographic picture are seldom easy to bring into perfect correlation. Existing clinical symptoms become apparent radiographically only some time after the occurrence of destruction or neoplastic osseous changes; in addition, they are often incorrectly depicted because of the addition effect. It is therefore necessary to recommend that carefully executed tomography, arthrotomography or CT techniques with special positioning be employed to enhance the routine panoramic radiography if uncertainties persist.

Examination of the Masticatory Organ Using Panoramic Radiography

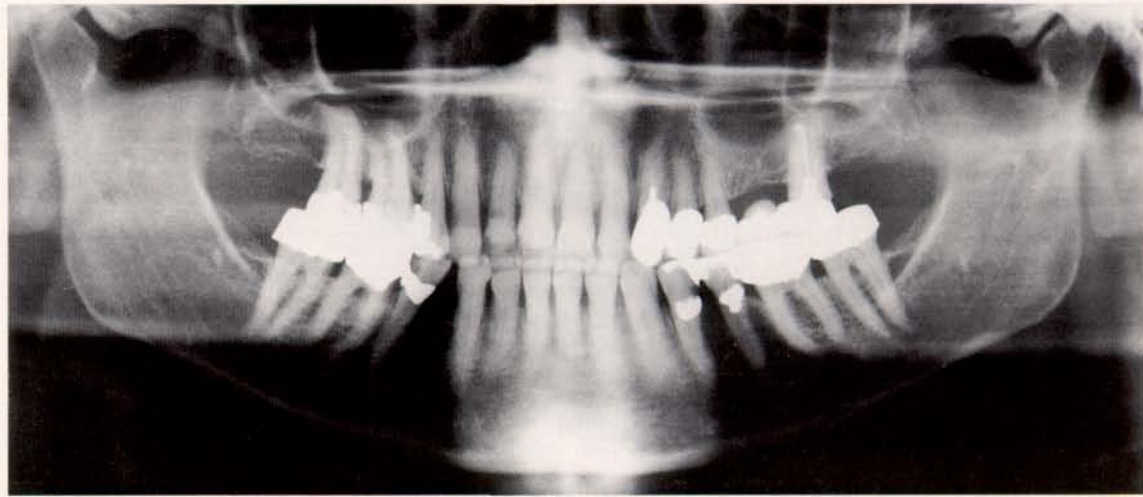
To depict *occlusal relationships* simultaneously with the *position of the condyles*, it is necessary to take the radiograph with the patient in normal occlusion. The positioning of the patient (see p. 13 ff.) demands particular attention: The position of the median sagittal plane at the back of the head must be checked precisely to avoid asymmetries of projection and resultant incorrect diagnosis.

For examination of *shape and structure of the condyles*, the patient is placed in the usual standard position and a bite plane is employed. A radiograph taken in this

way generally depicts the condyles quite well in a zonographic layer of about 20 mm thickness. Perfect diagnosis of the condyles is only possible if the mandible is symmetrically positioned in a protruded position. It is well to remember that before proceeding to relatively more complicated radiographic examination, the possibilities provided by clinical examination, analysis of mounted study models, and panoramic radiographic analysis should be exhausted first. In many cases these will provide sufficient information to address any malocclusion.

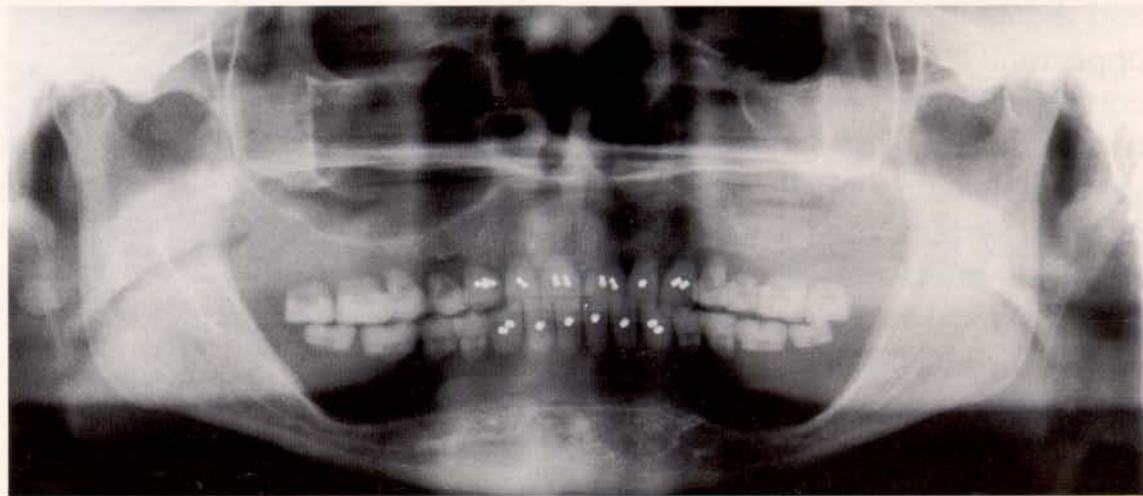
461 Examination of occlusion with regard to condylar position in a fully dentulous patient

It is recommended to take the radiograph at high energy. This figure depicts a case of temporomandibular joint pathology on the right side accompanied by malocclusion. Note the differing positions of the condyles at the articular eminences.



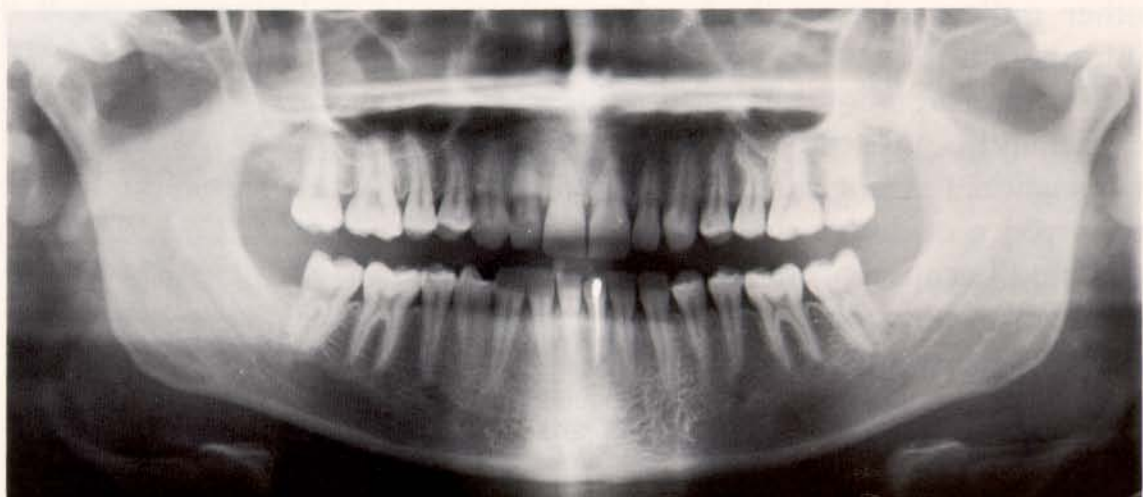
462 Examination of occlusal relationships with regard to condyle position in an edentulous denture wearer

In this case it was necessary to leave the denture in place during exposure of the film. This panoramic film depicts a case with temporomandibular joint problems on the right side, and with poor occlusal support on the left side. Note the differing positions of the condyles at the articular eminences.



463 Examination of the condyles in normal position with a bite plane in place

The slightly open mandible usually positions the condyles so that they can be observed without overlapping structures. In this 18-year-old female, the right condyle exhibits an osteochondral exostosis with a large cartilage component. Care must be taken to avoid asymmetric protrusive positioning of the mandible before taking the film.

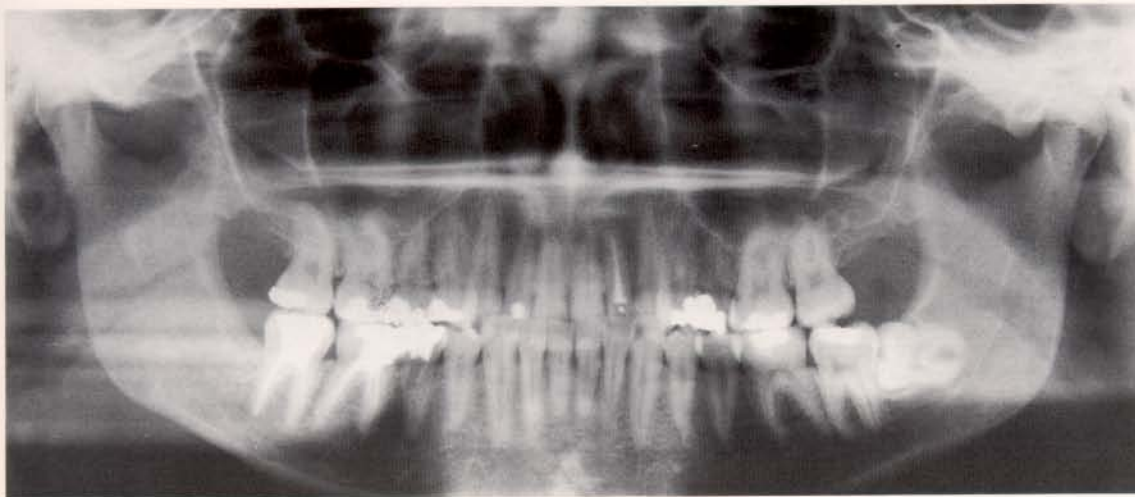


Temporomandibular Joint Pain with Malocclusion

Even the improperly directed force of eruption from a horizontally impacted tooth may cause functional disturbances by way of malocclusion, and temporomandibular joint disturbances may also be elicited. In partially edentulous patients with mesially tipped molars, the inclined occlusal planes of restorations and bridgework are associated with the danger of develop-

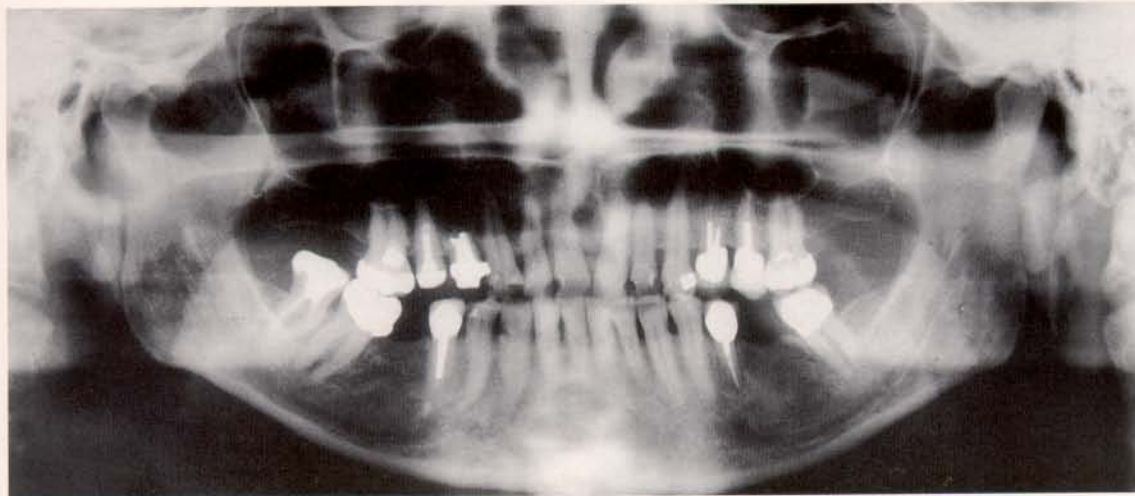
ing functional disturbances. This may be of special concern if any pathologic changes of the condyles also exist.

Young patients with these functional disturbances usually do not exhibit any radiographically detectable abnormality, and thus additional extensive radiographic examinations can be omitted.



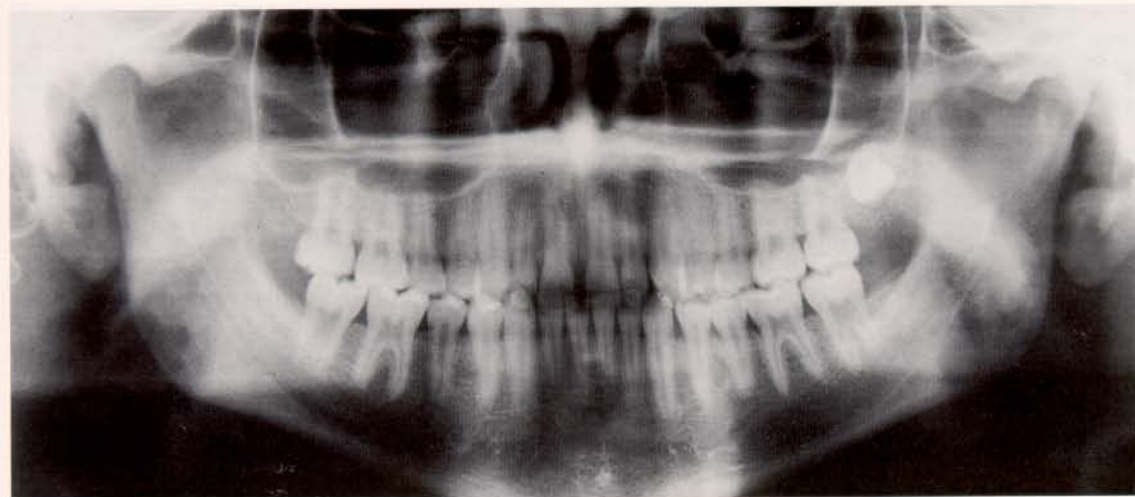464 Temporomandibular joint pain following the loss of tooth 28, with influence from the horizontally positioned and partially impacted 38

Note the malocclusion between teeth 27 and 37 in this 23-year-old female. This situation led to a painful disturbance of function in the left temporomandibular joint.



465 Temporomandibular joint pain following the loss of teeth 17, 18, 28, 36, 38, and 46, with mesial tipping of 47, 48, and 37

Note the "inclined plane" on the crown of tooth 47 in this 47-year-old female.

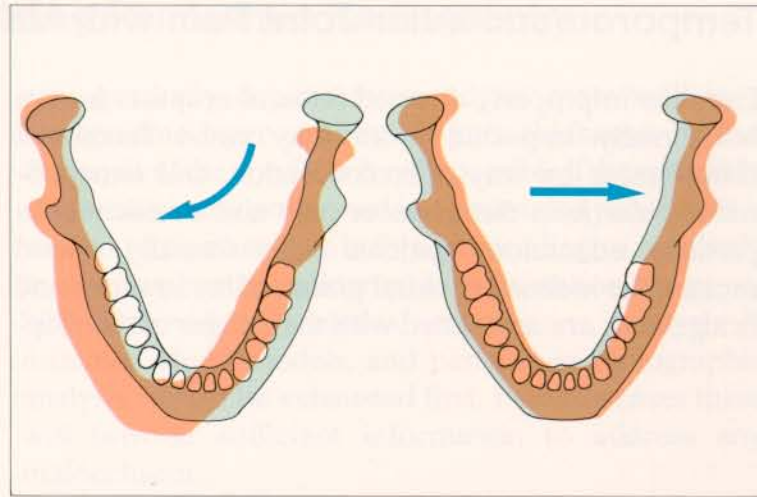


466 Temporomandibular joint disorder with unilateral (right) cross bite

Note the varying intercuspation on the right and left sides in this 16-year-old male; note also the diastema between teeth 11 and 21, and the differing condylar positions in normal occlusion.

Film Tomography of the TMJ

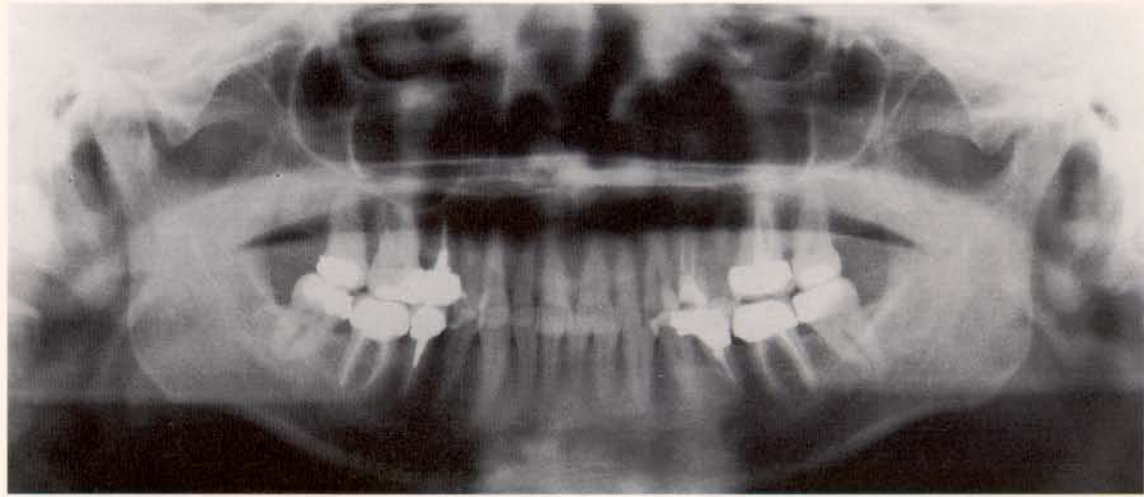
Destructive parafunctions and unorthodox chewing habits as well as improperly contoured restorative work and occlusal wear can result in malocclusion. This can lead to functional disturbances, with ultimate trauma-induced degenerative changes within the TMJ. In this condition, during closure the mandible usually rotates around one of the joints, resulting in anterior, posterior, lateral or medial malpositioning of the condyles; the result is often lesions in the articular disc, with subsequent joint pathology.



467 Schematic representation of the possible rotatory movements or lateral displacement of the mandible during closure

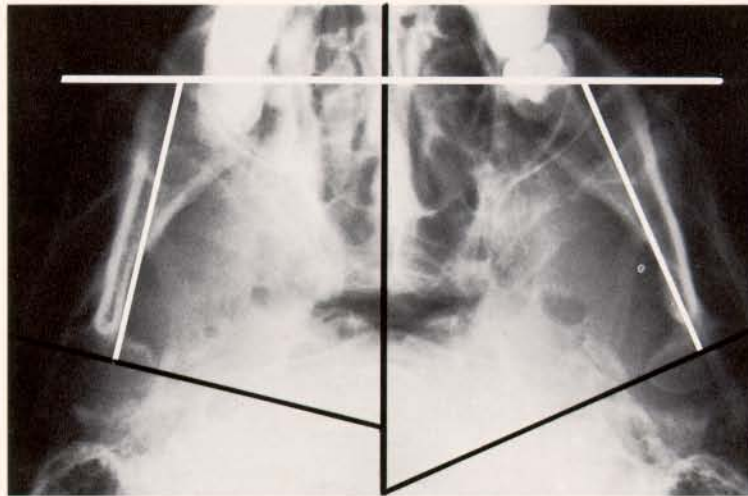
468 Temporomandibular joint disturbance on the left side

The panoramic radiograph of this 43-year-old female reveals abnormal positioning of the condyle during closure, and suggests possible degenerative changes on the left side. The dorsal displacement of the right condyle and the ventral position of the left condyle are clearly visible.



469 Axial skull film of the same case

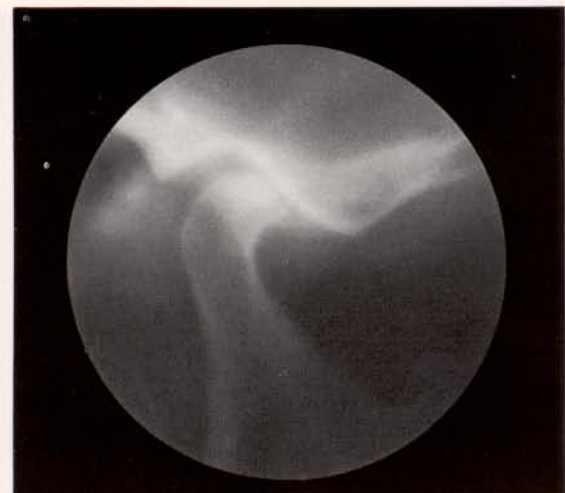
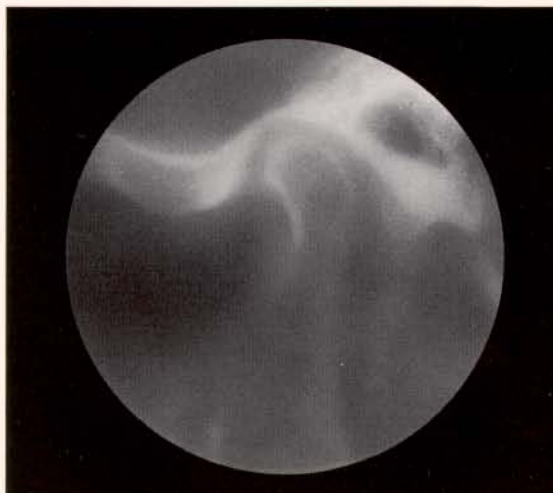Dorsal displacement of the right, and ventral displacement of the left condyle suggest a rotatory movement around the right condyle. After using an axial film to check the inclination of the condylar axis with regard to the median sagittal plane (black) and to the frontal plane (white), axially adjusted and precisely positioned tomography can provide excellent results, and in some cases may even depict the articular disc.

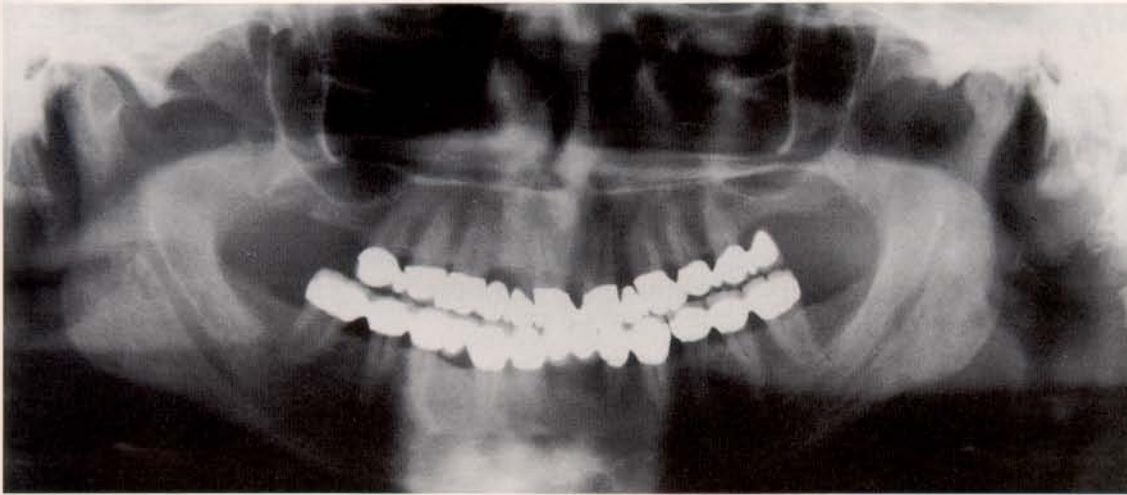


470 Spiral tomography of the same patient

Left: A normally structured and positioned condyle.

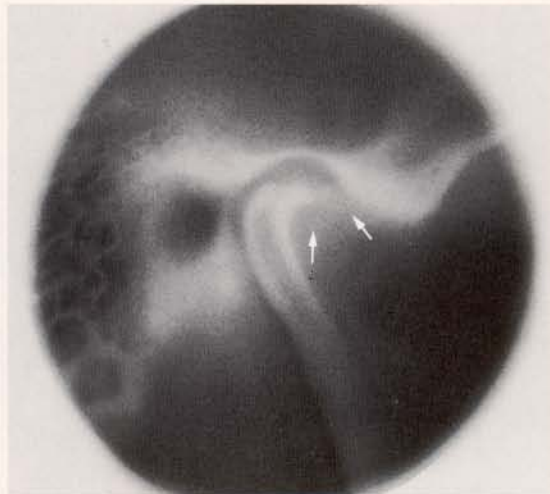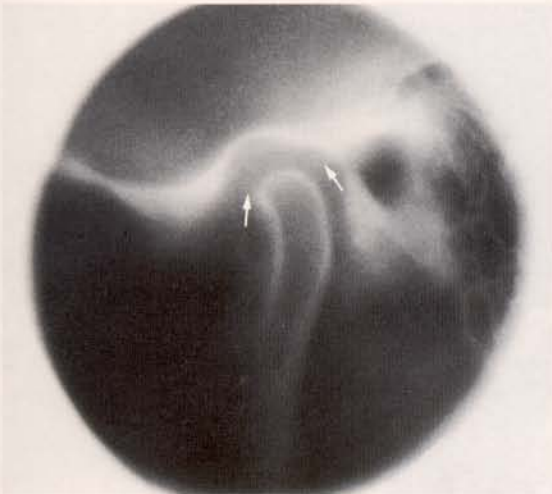Right: The ventral position and the advanced arthrosis of the condyle are clearly visible in this case with perforated disc.





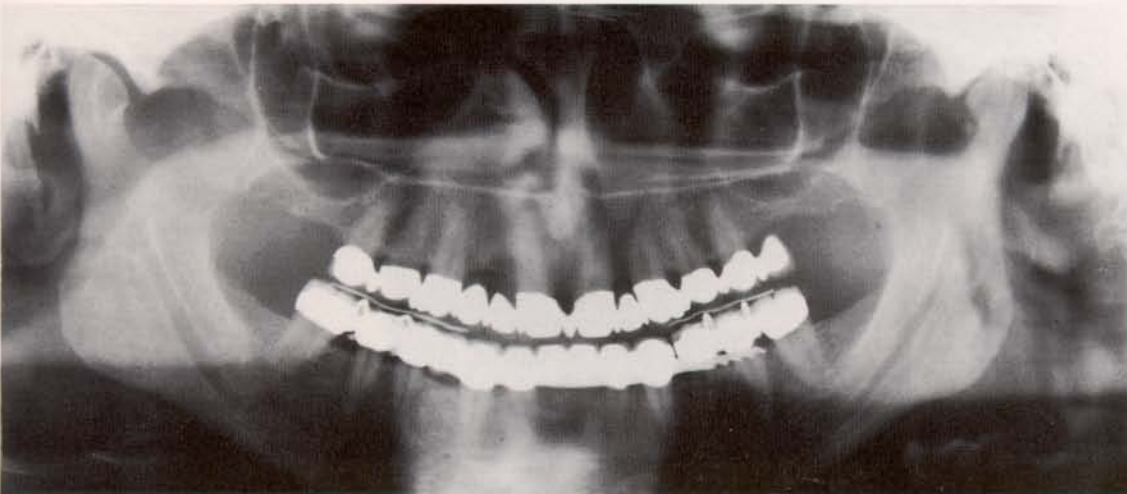
471 Malocclusion and a lesion of the condylar disc following comprehensive dental restoration

This initial panoramic radiograph taken in normal occlusion reveals an open bite on the left side and an asymmetric condylar position with anterior displacement of the left disc, and calcifications.



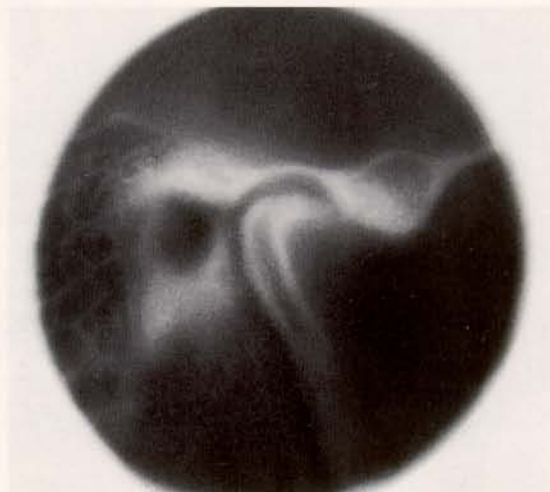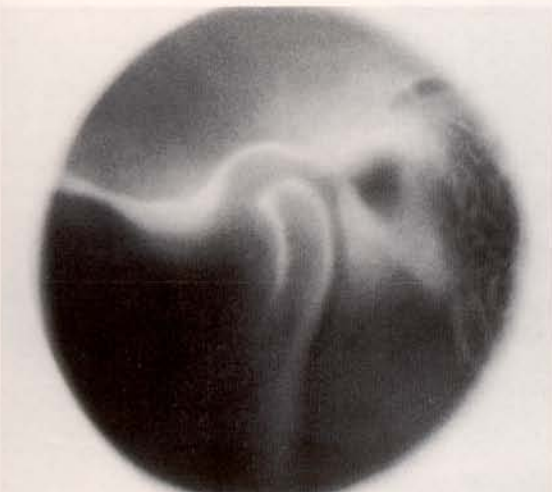472 Spiral tomography of left and right joints in normal occlusion

The left disc resides anteriorly (arrows), and the condyle resides in a "compressed" position deep in the fossa; arthropathy is obvious. The right condyle is normally configured but displaced medially. The disc (arrow) is in its normal position.



473 Confirming radiograph of the same case, taken with a bite plane in situ

Note the positions of the condyles. After wearing the bite plane for 9 months, and after stabilization of the new occlusal position with temporary acrylic bridges, the patient could be dismissed without TMJ symptoms, despite irreversible joint pathology.



474 Same case, depicting follow-up tomography after correction of the malocclusion

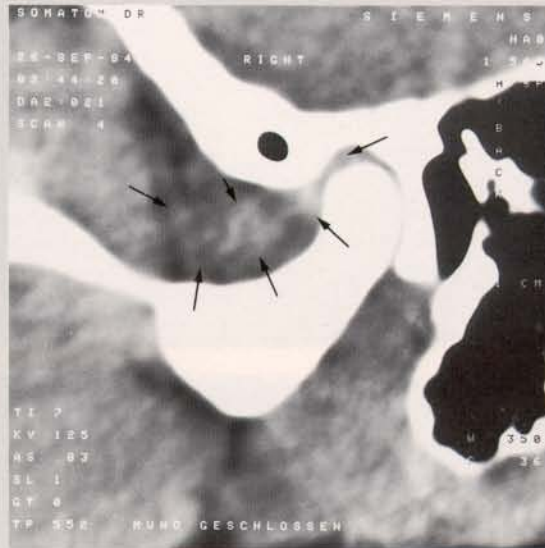
Computed Tomography of the Temporomandibular Joint with Direct Lateral Projection

The composition of sagittal sections of the temporomandibular joint as reconstructed by the computer is qualitatively less than satisfactory to depict details of the bone or the articular disc. Only by special positioning (see p. 123) is it possible to obtain a direct projection of a

lateral view of the temporomandibular joint. Using the soft tissue window it is then often possible to portray the three-dimensional articular disc in the various open positions of the joint in two dimensions.

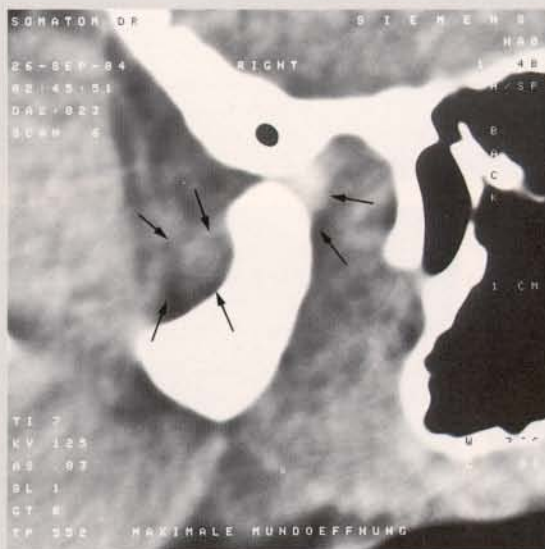475 Perforated articular disc that is positioned anteriorly, as seen in a lateral direct projection using the soft tissue window with the patient in normal occlusion

The condyle is displaced dorsally and the disc is positioned ventrally (arrow).



476 Same patient with maximum jaw opening

The condyle resides at the level of the articular eminence and the disc in a blocked open position (arrows).

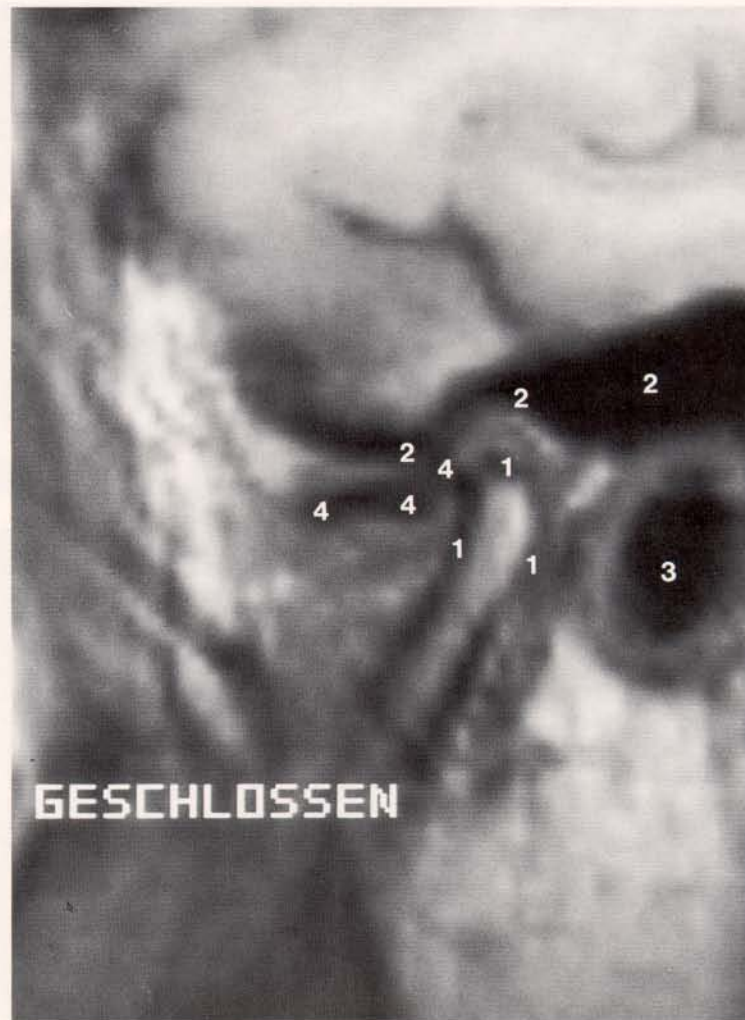

Magnetic Resonance Imaging of the Temporomandibular Joint

As an additional procedure, magnetic resonance imaging (MRI) has assumed an important position in the competition for radiographic diagnostic methods (see p. 124).

Even though the depiction of the bone can never compare with the quality of contemporary computed

tomography, the representation of soft tissue through use of special surface coils can be of significance in the diagnosis of structures (e.g., the articular disc) that do not provoke a signal. Further technical development of this procedure as a noninvasive method is of interest.



477 Articular disc in a fixed position as shown in lateral MRI taken with surface coils designed for the temporomandibular joint

The overlying compact lamella of the condyle is recognizable (black) as a contour that elicits no signal (1). The articular tubercle, the fossa and portions of the petrous bone appear similarly (2). The acoustic orifice is also observed as black (3). With the patient in normal occlusion, the articular disc (which also elicits no signal) is in the anteriorly fixed position (4) in front of the condyle.

Courtesy Drs. E. Steinhäuser and W. Spitzer, Erlangen

Advantages of MRI

- No ionizing radiation
- Enhanced range of contrast (soft tissue!)
- Two-dimensional representation of the articular disc

Disadvantages of MRI

- Osseous alterations are shown better in the CT
- Extended time commitment of the patient
- Not indicated for patients with claustrophobia, cardiac pacemakers or ferromagnetic implants

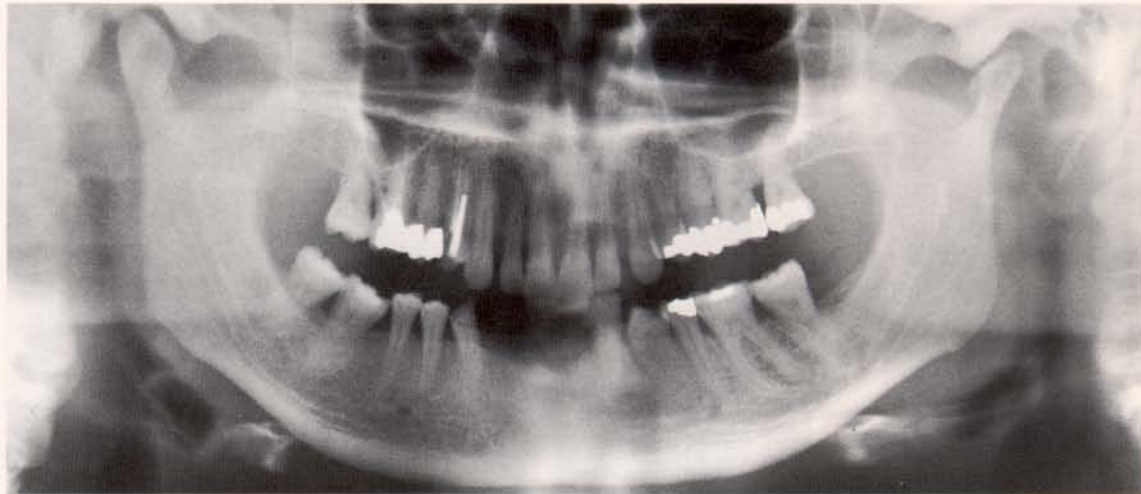
Hypoplasia and Exostosis of the Condyles

Unilateral or bilateral hypoplasia of the condyles may result from early childhood trauma, adjacent spreading infection (e.g., associated with otitis media) or may represent congenital defects (e.g., in cases of otomandibular dysostosis), primarily in women. Depending on

their localization, osteochondral exostoses and developmental disturbances of this type can lead to functional disturbance of jaw movement and may also cause irritation of the masticatory musculature. This could lead, in turn, to compensatory growth disturbance of the jaw.

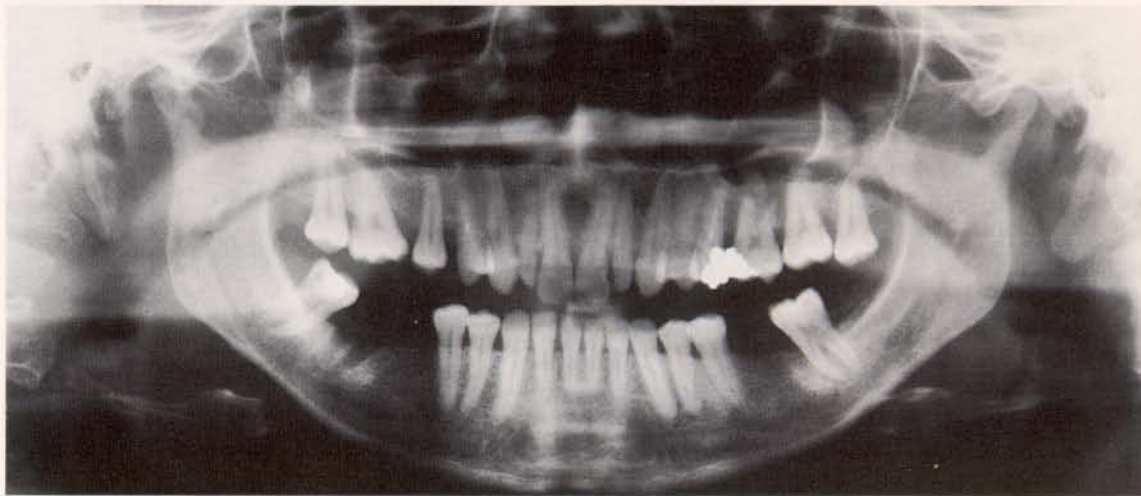
478 Left-sided hypoplasia of the condyle in a 57-year-old female with temporomandibular joint symptoms

Hypoplasia of a condyle is often detected serendipitously; it does not always lead to temporomandibular joint pain. Sometimes, however, in cases of forced orthodontic treatment, following tooth loss or during dental reconstruction, it may lead to clinically significant reactions in the temporomandibular joint area.



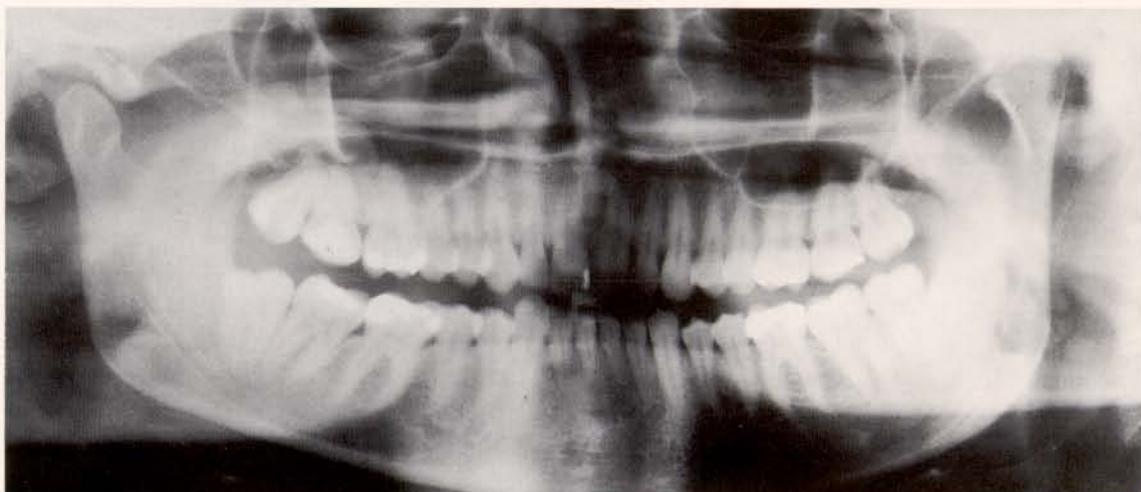
479 Bilateral hypoplasia of the condyles in a 34-year-old female with temporomandibular joint symptoms

Note the effect of tooth loss on the occlusal plane.



480 Unilateral condylar hypertrophy in a case of left-sided hemihypertrophy of the mandible

Observe on the left condyle in the anterior area of the joint surface a bone-like thickening, which appears not as arthrosis but rather as osteochondral exostosis.

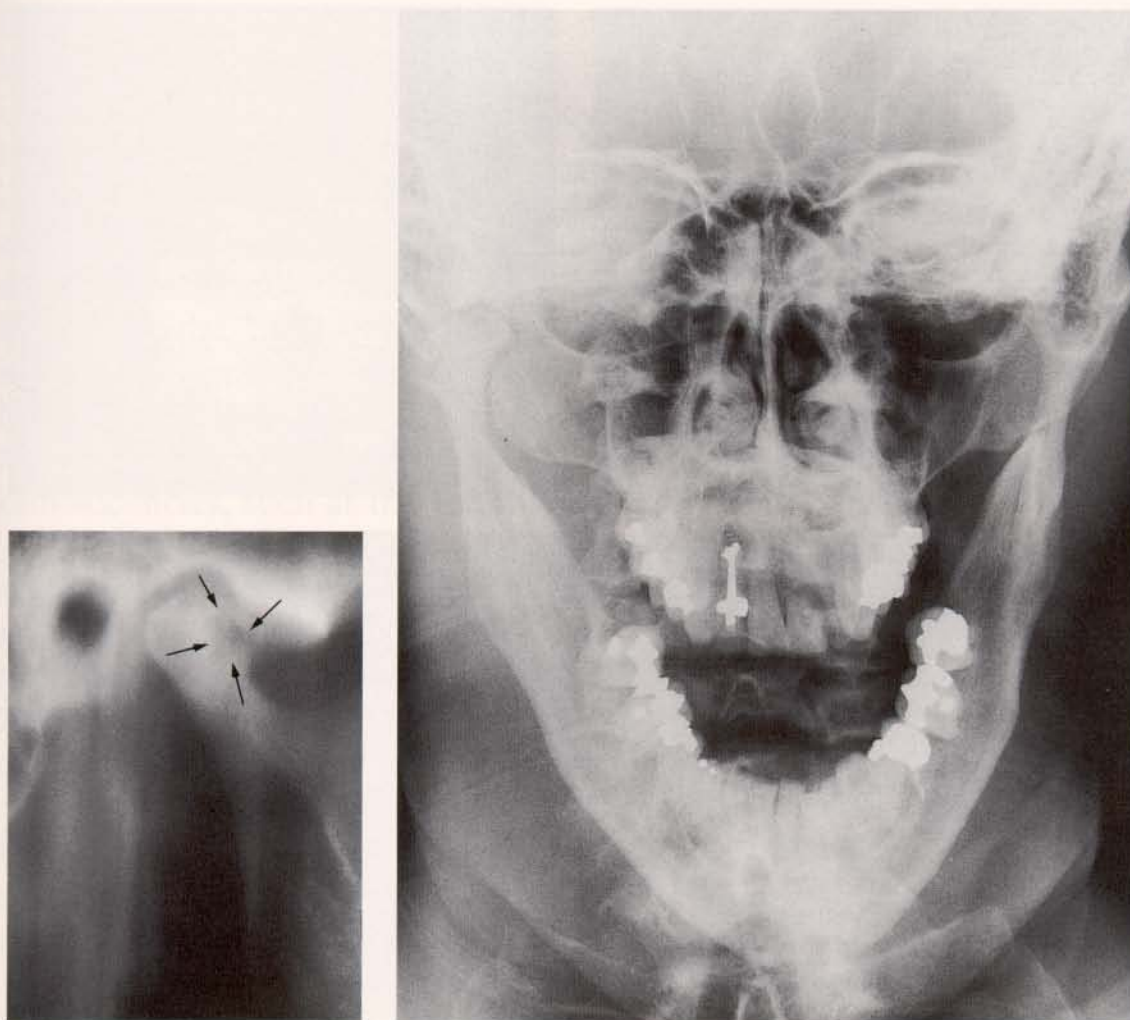


Hyperplasia and Osteochondral Exostoses

One of the causes of abnormal muscular hyperactivity and the often associated asymmetric jaw growth can be the early and unilateral closure of the cranial sutures. Other possible causes include osteochondral exostoses or osteochondromas that form not infrequently on the articular surfaces of the condyle in adolescents. These

lesions can exert irritating and traumatizing effects on the joint and the masticatory musculature.

Temporomandibular joint function is often seriously compromised after the initiation of degenerative changes.

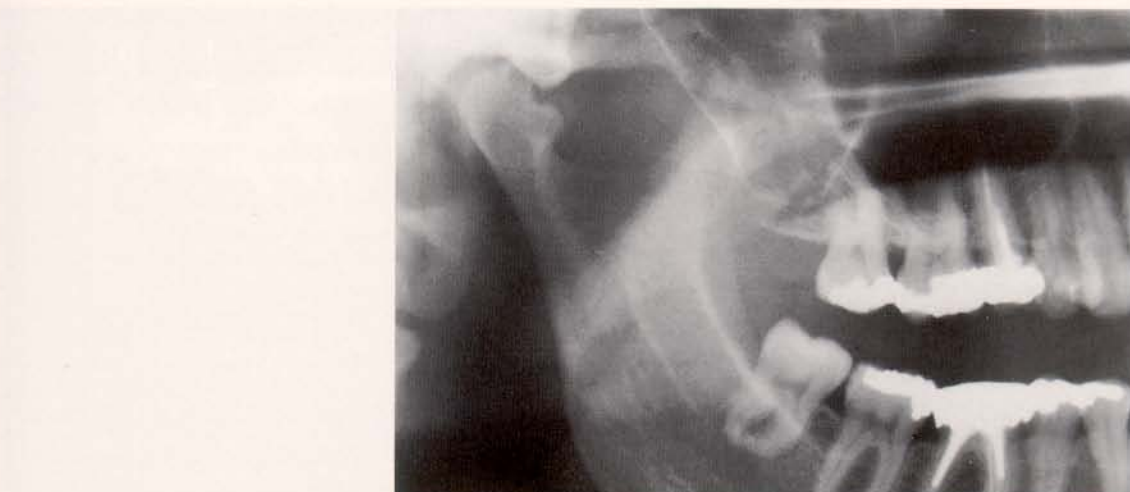

481 Osteochondroma of the left condyle in a 31-year-old female as seen in a reverse Towne projection

The asymmetric opening movement of the mandible is clearly evident. Note that the left temporomandibular joint has remained in a protected position.

482 Identical case as seen in a linear tomograph of the left temporomandibular joint in centric occlusion

The osteochondroma is surrounded by reactive sclerosis, which is a sign of existing arthritis (arrows). Particularly well depicted in this view are the arthritic changes in osseous structure that extend over the condylar fossa.



483 Osteochondroma on the right condyle of a 30-year-old female with temporomandibular joint disturbance

Clearly visible are the "exostoses" on the anterior border of the joint surface. The obvious radiolucencies correspond to elements with a high percentage of chondral tissue, which tend to develop into bone debris. This may appear radiographically as a cyst.

Courtesy Dr. L. Gäumann, Burgdorf

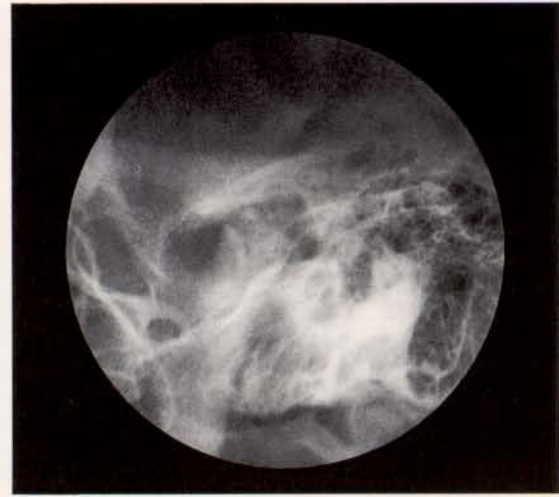
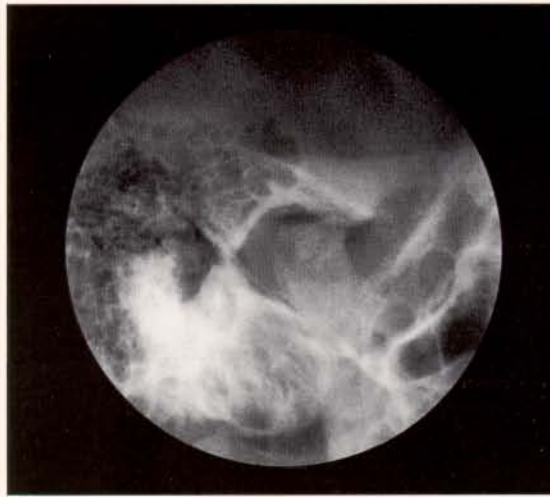
Inflammatory and Degenerative Changes

Arthritis, the inflammatory alteration of the temporomandibular joint, frequently occurs subsequent to inflammation of adjacent structures via hematogenic and traumatic pathways. The condyle is usually primarily affected, and exhibits structural degeneration and reactive sclerosis that resembles changes seen in osteomyelitis. These occur before actual osseous degenera-

tion and replacement by bone of lesser quality and ultimately arthropathy. Under constant influence of functional loading, the radiographic demarcations of the joint become less distinct, and compensatory enlargements of the joint surfaces occur including formation of marginal bulges and spikes.

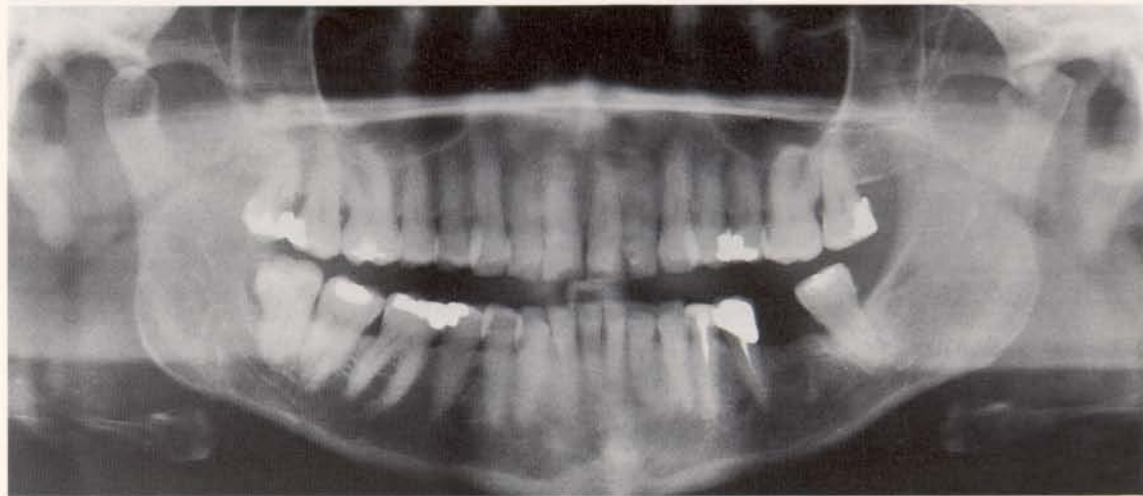
484 Bilateral rheumatic polyarthritis

Both condyles exhibit an acute inflammatory exacerbation and a typical protected position. The condyles exhibit osteomyelitic changes including bone resorption, reactive sclerosis and loss of normal configuration.



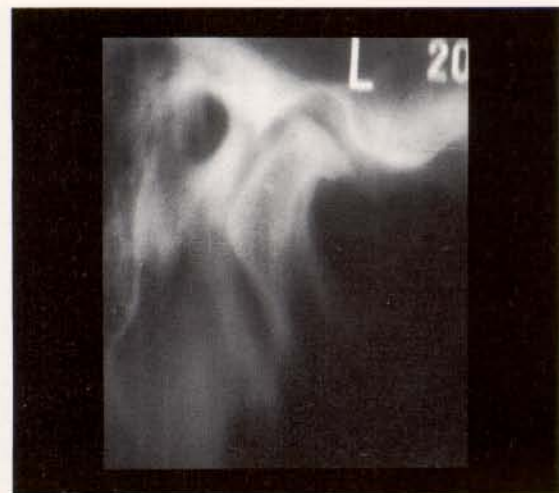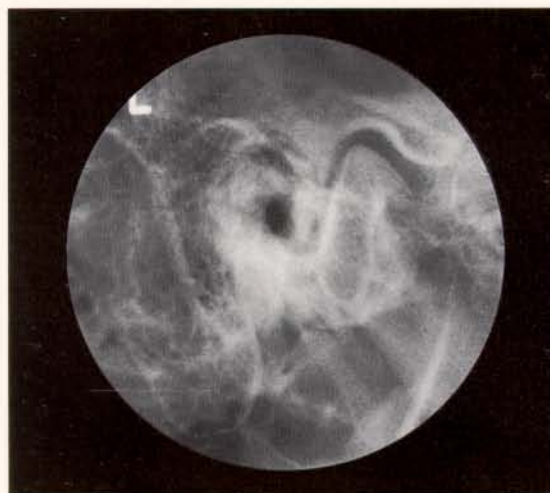
485 Arthropathy (remodelling processes)

The left condyle depicts pathologic alterations following intracapsular fracture of the condyle. The subsequent loss of vertical dimension and the widening of the articular surface can be seen.



486 Formation of marginal spikes due to arthrosis

The Schüller projection and the linear tomograph of the same patient reveal typical marginal spike formation and less clearly demarcated borders between the head of the condyle and the fossa: Typical signs of arthropathy.



Cysts and Pseudocysts

Pathologic cavities are classified as true cysts if they exhibit an epithelial lining when viewed histologically, whereas pseudocysts lack this histologic feature. Radiographically, in the non-inflamed condition cysts and pseudocysts typically appear with a well-delineated border which, however, is lacking when inflammation is present. Their growth is slow and displaces the surrounding anatomic structures depending upon their resistance. One may distinguish between odontogenic and nonodontogenic cyst formation. Other epithelium-lined cysts that develop in the soft tissues, e.g., the nasoalveolar cyst, can only be rendered visible radiographically through use of contrast filling material. Such cysts will therefore not be discussed in this book. Other soft tissue cysts, however, for example the mucocele of the maxillary sinus, can be detected radiographically and will be presented. We will also discuss pseudocysts that are not lined by epithelium, including solitary and aneurysmatic bone cysts as well as other entities that are characterized radiographically by radiolucencies, such as the latent bone cavity of the mandible.

Radicular apical and radicular lateral cysts arise from epithelial remnants, the rests of Malassez, which derive from the Hertwig epithelial sheath. These cells proliferate as a result of inflammatory stimulation that always derives from nonvital teeth. Following nutritional disturbances and dissolution of epithelial layers in the center of the lesion, a cavity forms and typical cystic growth is initiated. *Periodontal cysts* develop similarly, but derive originally from a bony pocket; this is the reason why the involved tooth need not necessarily be nonvital.

Follicular cysts that develop before the formation of dental hard substances, e.g., primordial and keratocysts, arise from the dental lamina. They form near regular or supernumerary teeth, and may sometimes be encountered together with the basal cell nevus syndrome. The epithelium of keratocysts will become cornified.

Follicular cysts, which develop after the formation of dental hard substances, derive their epithelium from the inner and outer enamel epithelia of the tooth primordium. They appear to develop after traumatic stimulation, e.g., the eruption cysts, or as a result of numerous other (unknown) factors. Residual cysts of the odontogenic type may occur anywhere that teeth are extracted and a portion of the cyst is left behind.

Nonodontogenic epithelium-lined cysts develop, depending upon their localization, from epithelial remnants of the Hochstetter epithelial wall, the nasopalatine tract or the palatal suture. Less frequently they occur as odontogenic cysts and, because of the superimposition effect, may lead to diagnostic difficulty and subsequent therapeutic problems.

Pseudocysts are not lined with epithelium, and may result from trauma, marrow hemorrhage, resorptive disturbances, osmotic exclusion, circulatory disturbances and developmental disturbances. They have also been viewed as reparative processes after resolution of bone tumors.

Brief Classification of Cysts of Interest to the Dentist*I. Odontogenic cysts (with epithelial lining)*

1. Radicular cysts
 - apical cyst
 - lateral cyst
2. Periodontal cysts
3. Follicular cysts
 - a. before formation of hard tooth substance
 - primordial cyst
 - keratocyst
 - b. after formation of hard tooth substance
 - eruption cyst
 - coronal cyst
 - lateral cyst
 - cyst with rudimentary tooth
4. Residual cysts of all types

II. Nonodontogenic cysts (with epithelial lining)

1. Nasopalatine cysts
2. Median (fissural) cysts
 - median alveolar cyst
 - median palatal cyst
3. Lateral (fissural) cysts
 - nasoalveolar cyst
 - globulomaxillary cyst
4. Median mandibular cysts
5. Residual cysts of all types

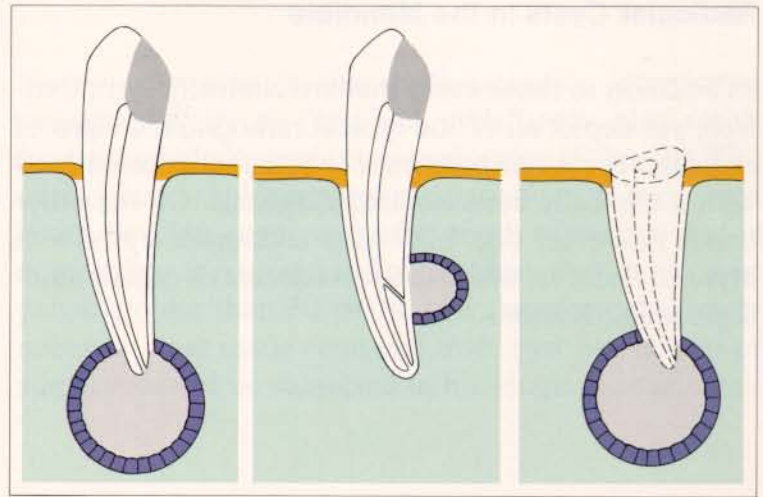
III. Pseudocysts (without epithelial lining)

1. Solitary bone cyst
2. Aneurysmatic bone cyst
3. Latent bone cavity (Stafne)

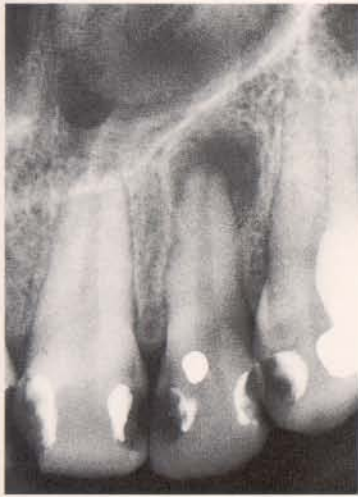Odontogenic Cysts

Radicular Cysts

Radicular cysts develop around the apex of a diseased tooth (apical radicular cyst) or around an accessory canal from the pulp (lateral radicular cyst) (Fig. 487). The root is within the cystic cavity. The radiographic appearance of a clinically symptom-free cyst reveals a clear, opaque delineation border that displaces neighboring structures. An acutely inflamed cyst lacks the radiographic sign of opaque delineation.

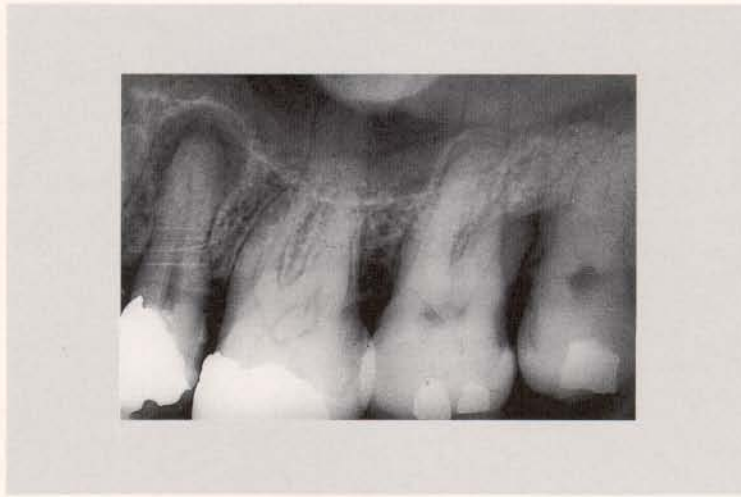


487 Schematic representation of apical, lateral and residual radicular cysts



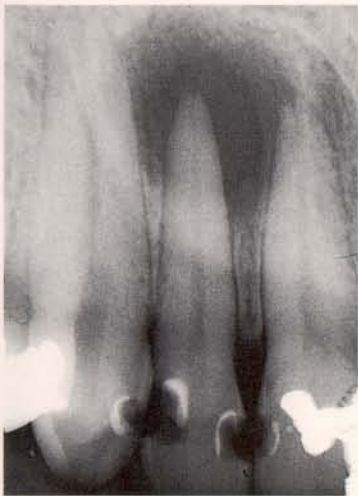488 This small, symptom-free radicular cyst exhibits the typical opaque boundary

Cysts of this size are impossible to distinguish radiographically from a granuloma.



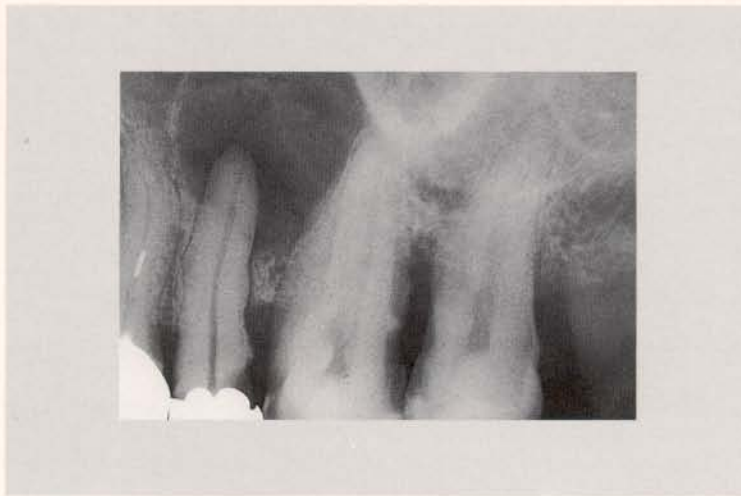
489 Small, clinically symptom-free radicular cyst that is expanding towards the floor of the maxillary sinus

The periodontal ligament space is no longer discernible.



490 Infected radicular cyst

This cyst has lost its typical radiographic signs as a result of serous infiltration of the surrounding tissue. Such cysts present radiographically without the usual sharply demarcated borders and tunneling.



491 This infected radicular cyst emanates from tooth 25 and displaces the floor of the maxillary sinus

The widened periodontal ligament space indicates "elongation" of the tooth, and its mobility. The periodontal ligament space is no longer discernible around the tip of the root penetrating the cystic cavity.

Radiographic Signs of Radicular Cysts

- Round radiolucency with an opaque border
- Apex of the tooth is within the radiolucency
- Adjacent teeth and structures are displaced

Infected cyst:

- Cystic cavity exhibits poorly demarcated borders.
- Background structures become invisible and the defect appears as tunneling.
- Periodontal ligament space around the involved tooth becomes widened.

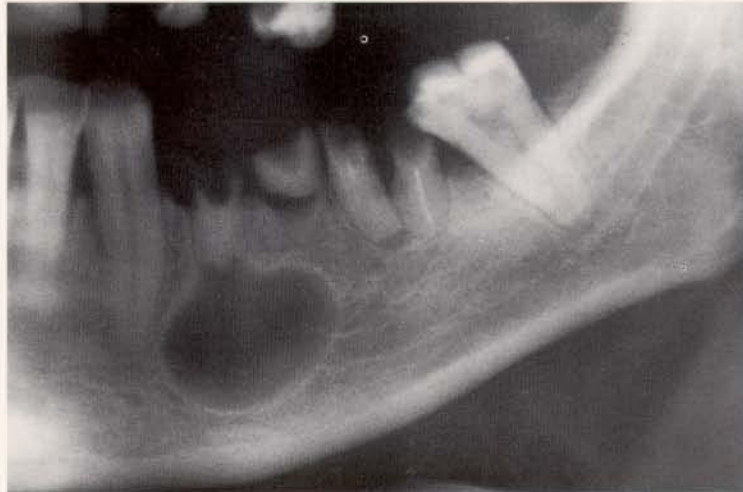Radicular Cysts in the Mandible

In addition to those cases that are clinically symptom-free, yet depict all of the typical radiographic signs of radicular cysts, one sometimes encounters infected cysts with a clinically corroborated diagnosis. On the other hand, however, one may also encounter cysts with atypical features, which are reminiscent of other pathologic manifestations.

The sections from panoramic radiographs again show clearly the degree to which this technique has broadened our basis for information gathering from radiographic examination.

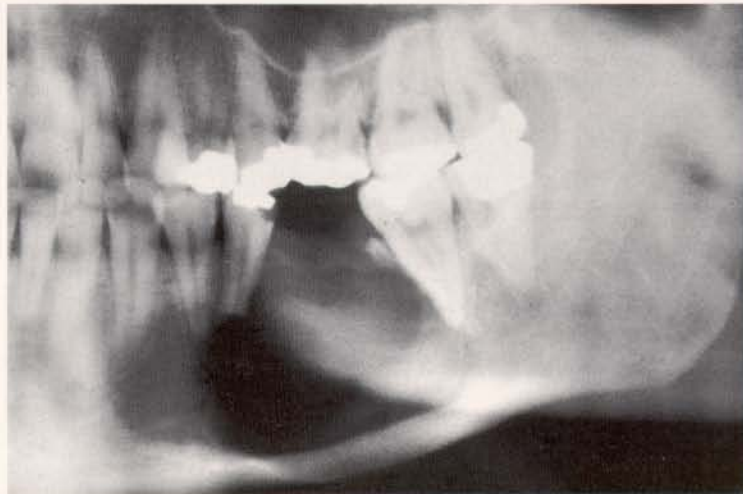
492 Typical manifestation of a radicular cyst

The cyst extends from the residual root tip of tooth 34. The case was clinically symptom-free and was an incidental radiographic finding. Even the extraction of root tips should not be performed without previous radiographic examination. If the cyst is not completely removed, it will serve as the origin for the development of a residual cyst.



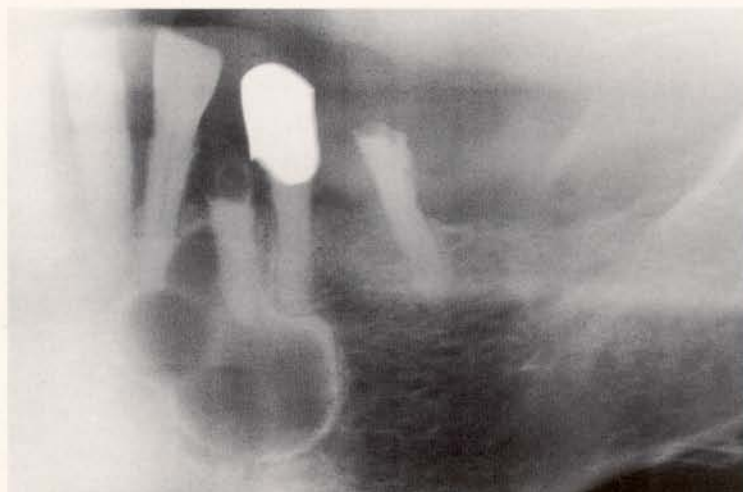
493 Infected radicular cyst

This cyst emanates from tooth 35, which lacks a periodontal ligament space and resides within the cavity. The delineation of the cyst is not sharp, and without knowledge of the clinical findings the radiograph alone is insufficient for unequivocal diagnosis.



494 Atypical manifestation of a radicular cyst

This cyst emanates from the residual root tip of tooth 32. The radiograph mimics a "multi-chambered" process. A radiographic picture with this localization could equally represent an ameloblastoma, a giant cell granuloma or keratocyst.

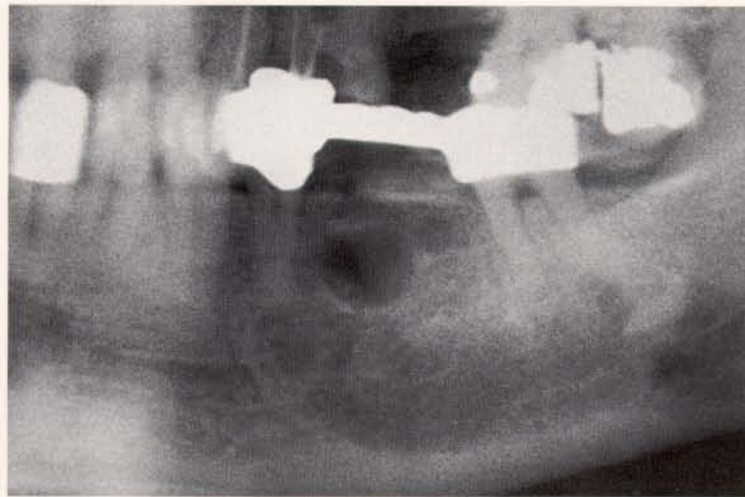


Courtesy Dr. K. Weibel, Baden

Radicular Residual Cysts in the Mandible

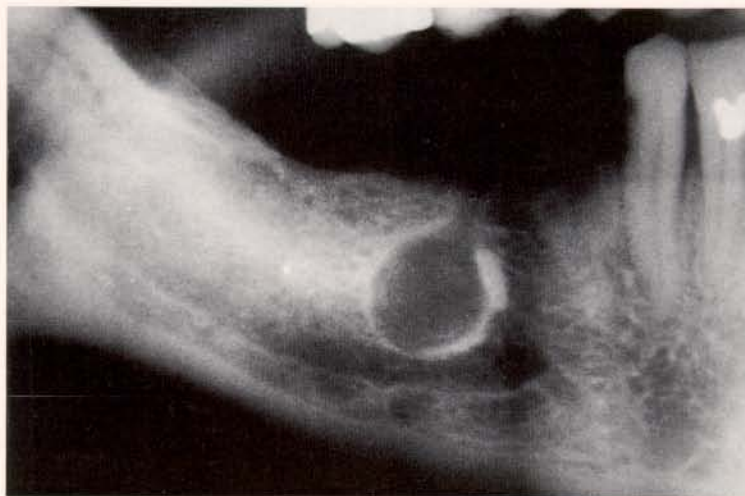
The nonvital tooth whose root tip appears within the sharply demarcated radiolucency is an unequivocal radiographic sign for the existence of a radicular cyst. Radicular residual cysts lack this sign, and it is for this reason that an edentulous space coronal to a radiolucency is the radiographic sign that may be used for a suspected diagnosis. However, because residual cysts may also originate from atypically impacted teeth with follicular cysts, radiographic diagnosis cannot be based upon the localization of a round radiolucency in the jaw.

Noteworthy also is that radiolucencies interpreted radiographically as "residual cysts" may also result from other odontogenic or nonodontogenic lesions. The ameloblastoma deserves particular attention here since it can develop even years after tooth extraction and is responsible for most ameloblastomas that develop in patients older than 30 years. It is therefore absolutely necessary that tissue removed from cyst-like lesions at surgery should be subjected to histologic examination.



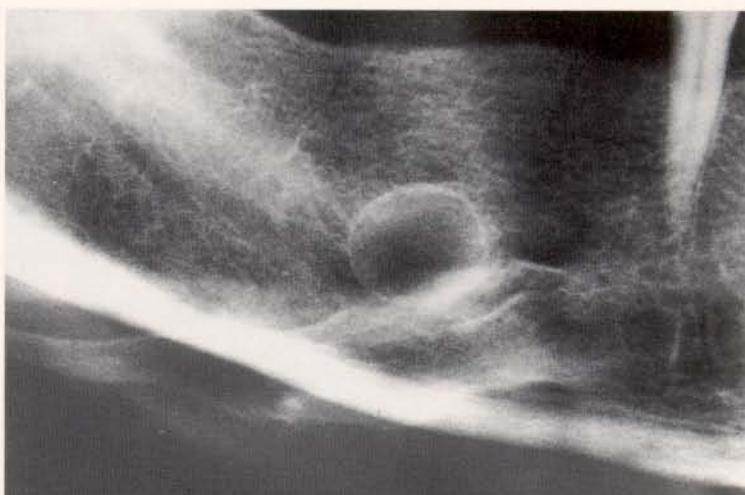495 Radicular residual cyst emanating from missing tooth 35

With this type of localization, it is entirely possible that the lesion is an ameloblastoma. This case serves to point out vividly that the radiographic differential diagnosis can be extremely difficult in practice. For this reason it is highly recommended that tissue removed from cyst-like lesions be examined histologically.



496 Radicular residual cyst emanating from tooth 46

Note the root tip that has been displaced laterally as a result of growth of the cyst.



497 Ossifying fibroma mimicking a radicular residual cyst in a 57-year-old male

Note that the mandibular canal is displaced. Note also the slight radiopacity within the opaque delineation, which may possibly indicate the presence of an ossifying fibroma.

Radicular Cysts in the Maxilla

Epidemiologic studies reveal that radicular cysts occur more often in the maxilla. They often expand toward the maxillary sinuses, achieving dramatic size because of the lack of resistance to their growth and the availability of space. The patient is usually unaware of the presence and growth of such cysts. The vertical expansion of

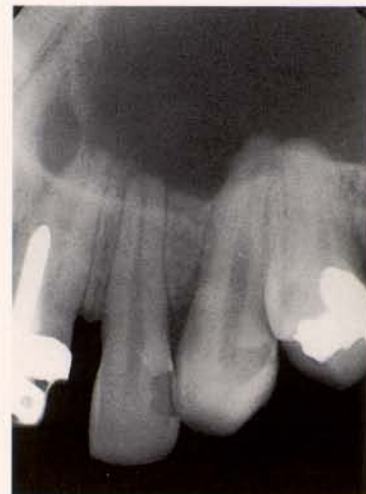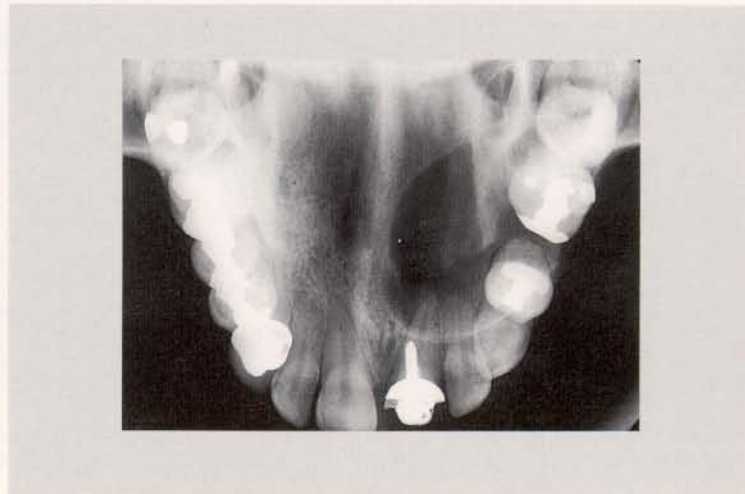
these lesions will be clearly visible in the panoramic radiograph, but depiction of the third dimension will be enhanced by occlusal films. In the case of large maxillary cysts, the use of frontal film tomography or computed tomography is indicated.

498 Radicular maxillary cyst extending from teeth 21 and 22 (occlusal radiograph)

The expansion of the cyst in the horizontal plane is well depicted (with the exception of minor distortions).

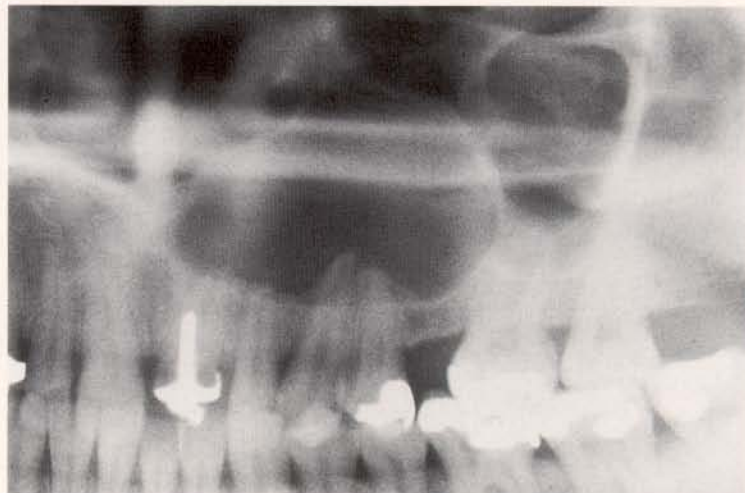
499 Same case (periapical radiograph)

The expansion of the cyst cannot be appropriately depicted on a periapical radiograph.



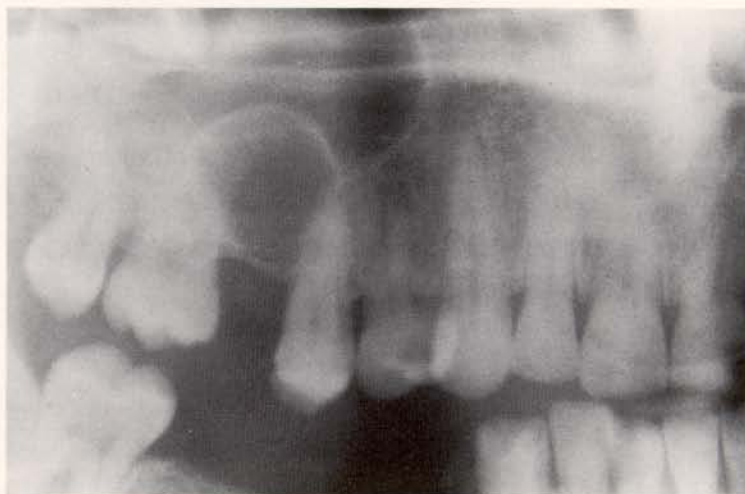500 Section from the panoramic radiograph of the same patient

The lateral projection shown in this section from a panoramic radiograph depicts perfectly the vertical expansion of the cyst, which almost completely fills the left maxillary sinus. Note the fine, opaque line of demarcation, which persists even in the sinus. An occlusal radiograph can serve to document the expansion of the cyst in the horizontal plane. Tomography or computed tomography may also be applied in such cases.



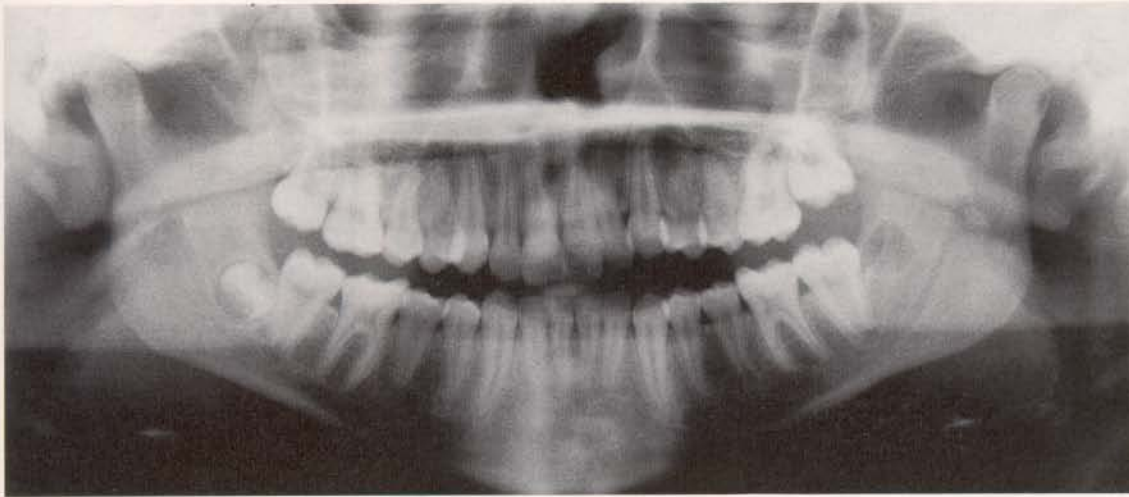
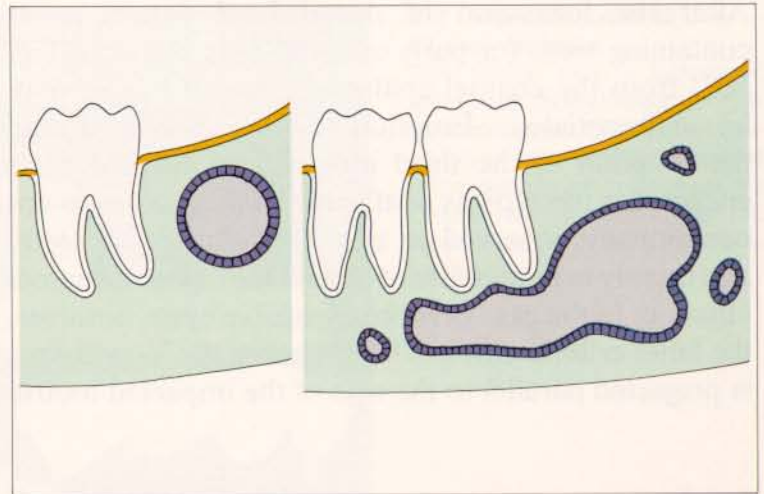
501 Radicular residual maxillary cyst extending from the extraction site of tooth 16

Again the fine, opaque line of demarcation is visible. It is pushed forward by the growing cyst and may, over a long period of time, protect the maxillary sinus from infection and associated sinusitis.



Follicular Cysts

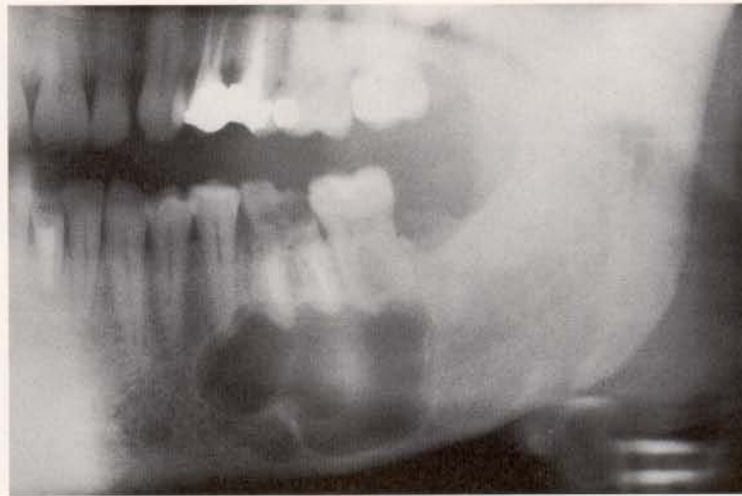
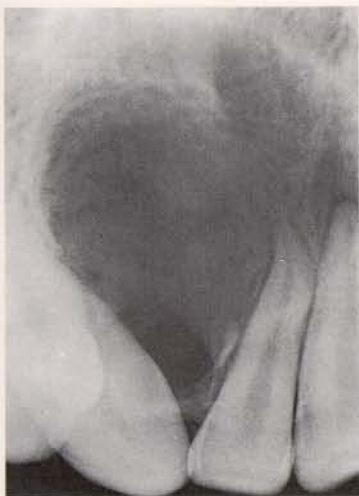These cysts originate before tooth development due to malfunction of the dental primordium. The primordial cyst frequently occurs in place of permanent or supernumerary tooth buds and at the angle of the mandible (Fig. 502, left). The active epithelium has the capacity to produce keratin and develop into a keratocyst. The latter may develop satellite lesions, which cannot be detected radiographically in their early stages (Fig. 502, right). The keratocyst is often observed in conjunction with Gorlin-Goltz syndrome.



502 Diagram of primordial cyst and keratocyst

503 Small primordial cyst

A cyst is visible where the primordium of tooth 38 would normally be seen in this 15-year-old male.



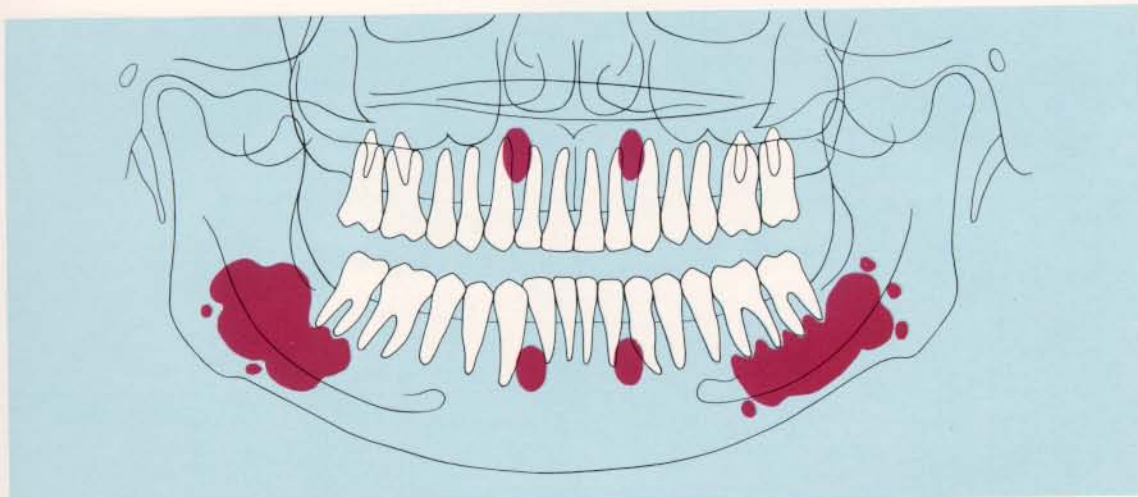
504 Typically formed keratocyst as seen in a panoramic radiograph

This cyst appears to be multichambered.

505 Multichambered keratocyst of the maxilla, mesial to tooth 13

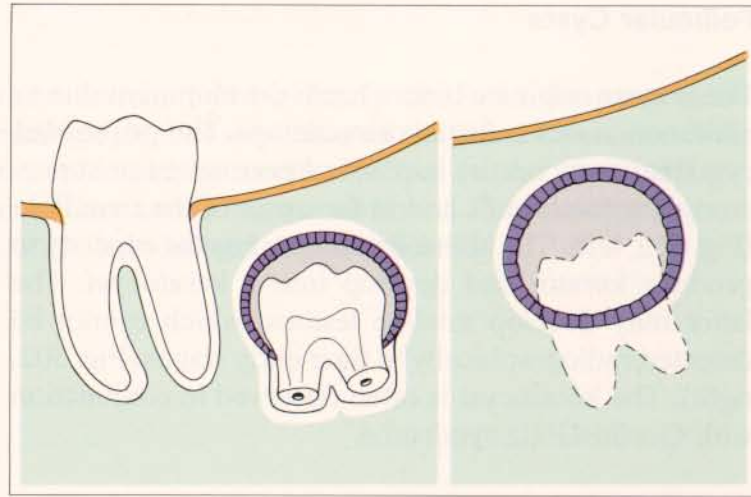
The canine regions of maxilla and mandible are preferred sites for these cysts, as is the mandibular molar region.

Courtesy Dr. J. Pindborg, Copenhagen



506 The most important sites of keratocysts

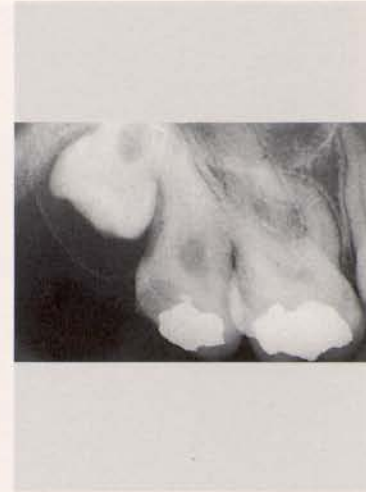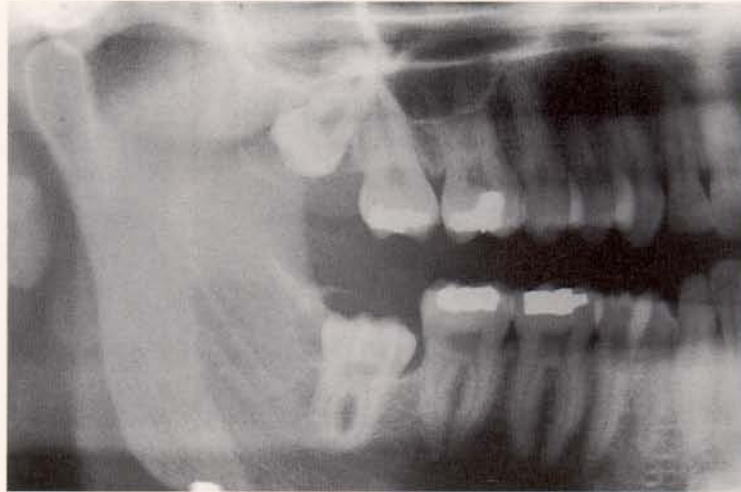
After the formation of dental hard tissues, cysts containing teeth (or parts of teeth) may develop (Fig. 507) from the enamel epithelium. Various types may be differentiated: Eruption cysts develop during the eruption of the third molars, and coronal cysts encompass the crowns of affected teeth. Such cysts are occasionally observed to enclose rudimentary teeth, and usually to be attached at or near the cemento enamel junction. In the case of more expansive cysts, however, the latter criteria may not be obvious if the X-ray beam is projected parallel to the axis of the impacted tooth.



507 Diagram of tooth-containing cysts

508 Eruption cysts on erupting teeth 18 and 48

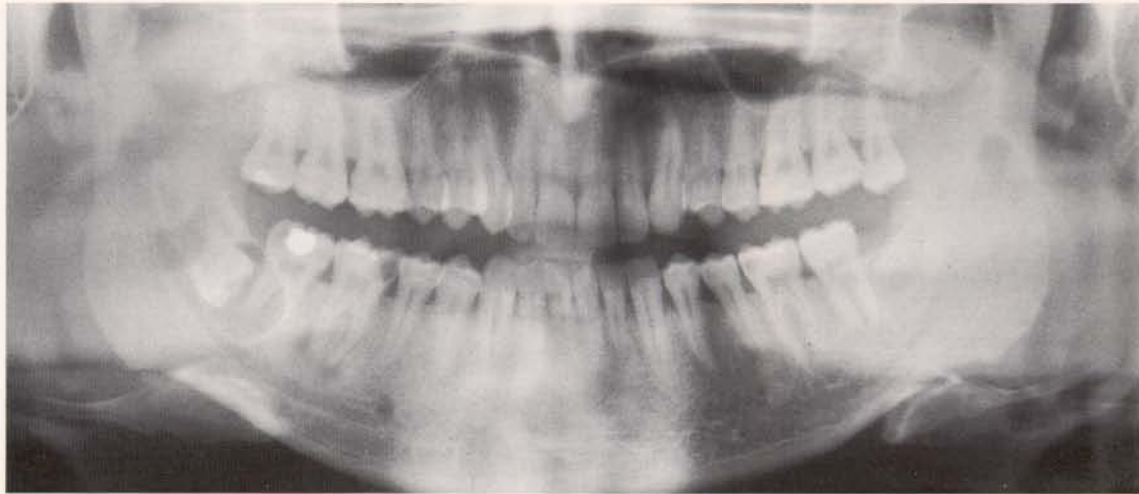
Note the typical attachment of the cyst at the cemento enamel junction.



509 Eruption cyst on tooth 18 as seen in a periapical film

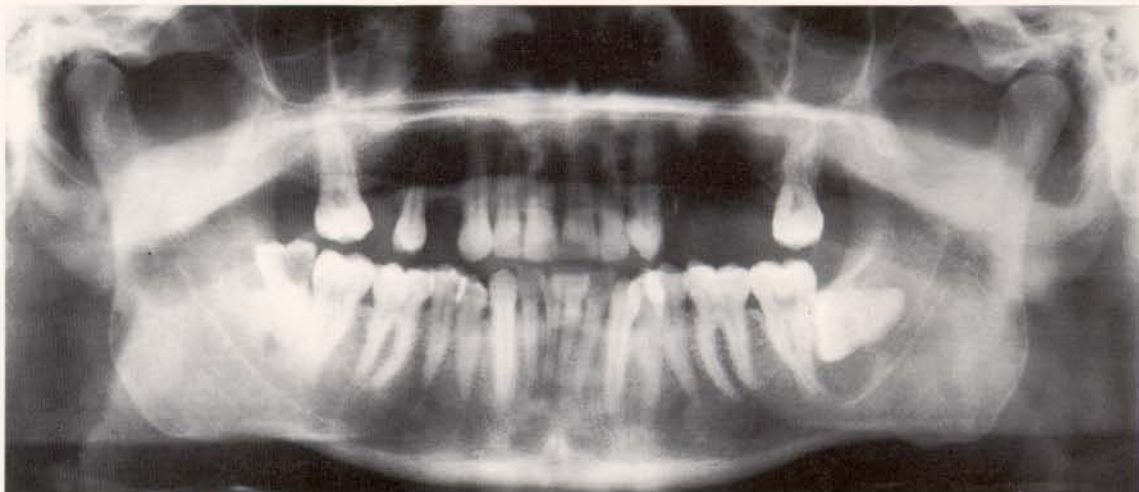
510 Coronal follicular cyst on a completely impacted tooth 48

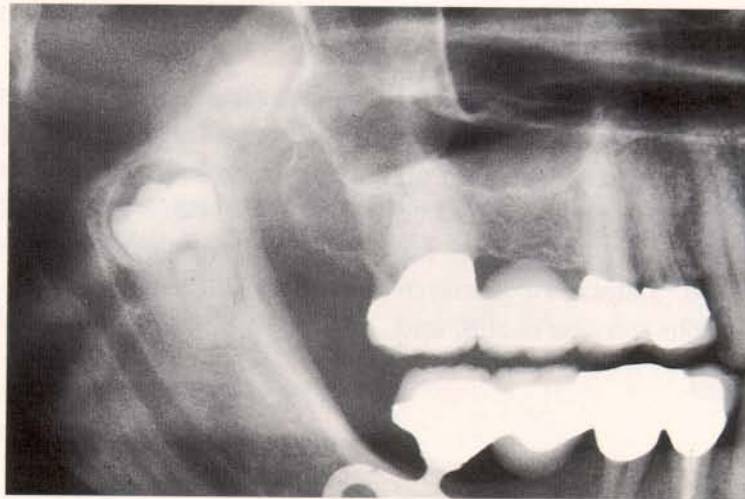
Note the chronic periapical periodontitis on tooth 46 and the elongation of tooth 28 with caries on the mesial surface.



511 Lateral follicular cyst on completely impacted tooth 38

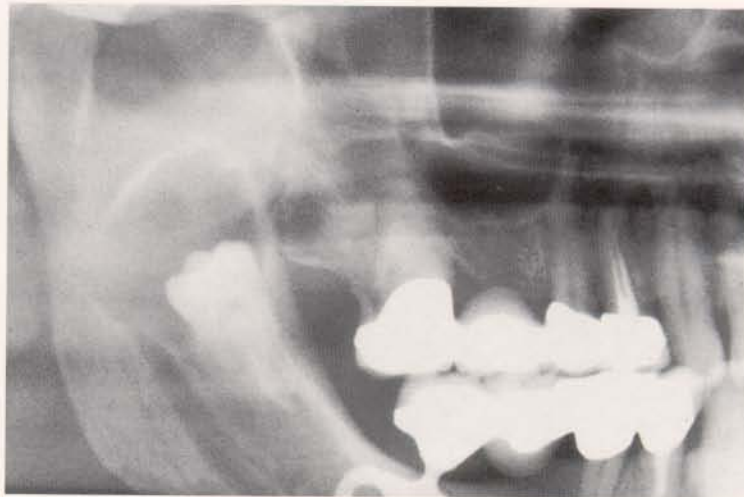Lateral follicular cysts may develop via a pocket around partially retained teeth and are therefore often clinically referred to as periodontal cysts. Note the pericoronal osteolysis, the deep caries and the apical periodontitis on tooth 48 that have led to primary chronic osteomyelitis at the angle of the mandible.





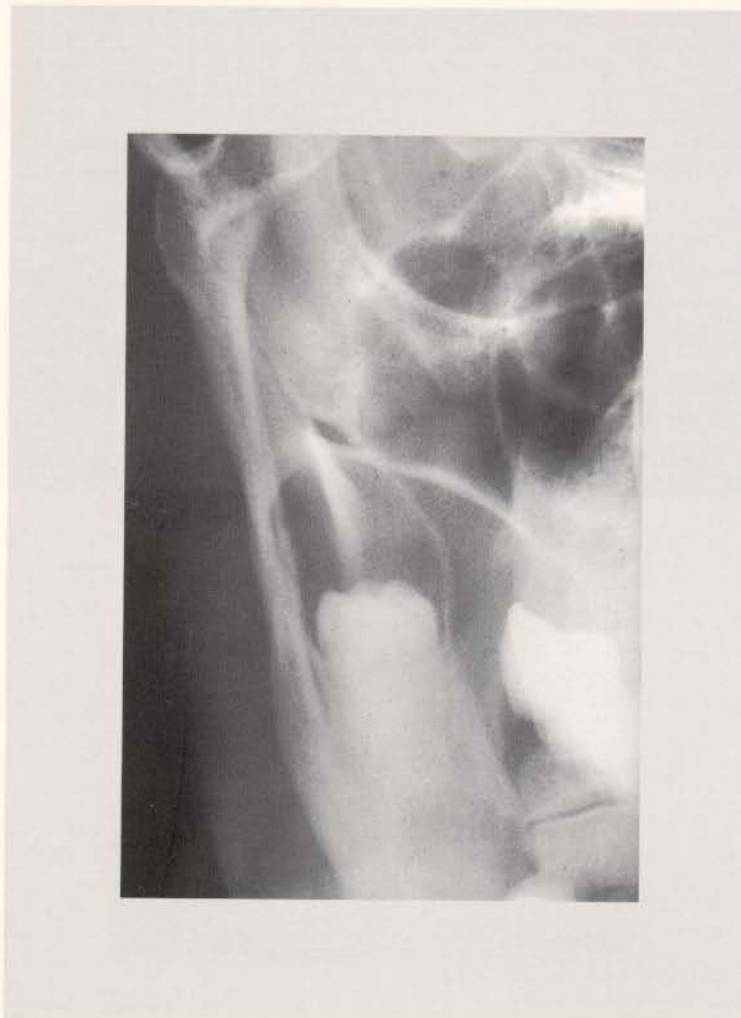512 Impacted tooth 48 in a 52-year-old male

This section from a panoramic radiograph shows the bony border surrounding the follicular sac. Discovery of this condition occurred during the course of placement of a Linkow implant and prosthetic reconstruction in both mandible and maxilla.



513 Same case 5 years later

Clinical findings included parulis in the region of the right mandibular angle. The radiograph reveals the coronal follicular cyst within the ascending ramus. Note the typical attachment of the follicular cyst at the cemento-enamel junction and the border of the cyst that has become less sharply demarcated.



514 Same case in a section from a reverse Towne projection

This follicular cyst has developed in the typical lingual direction. If a mandibular third molar is impacted in the ascending ramus, depiction of cystic expansion in frontal plane can usually be accomplished using the reverse Towne projection with maximum jaw opening (see p. 117). For localization of larger cysts in the body of the mandible or at the mandibular angle, it is extremely important to refer the patient for preparation of axial CT prior to any surgery.

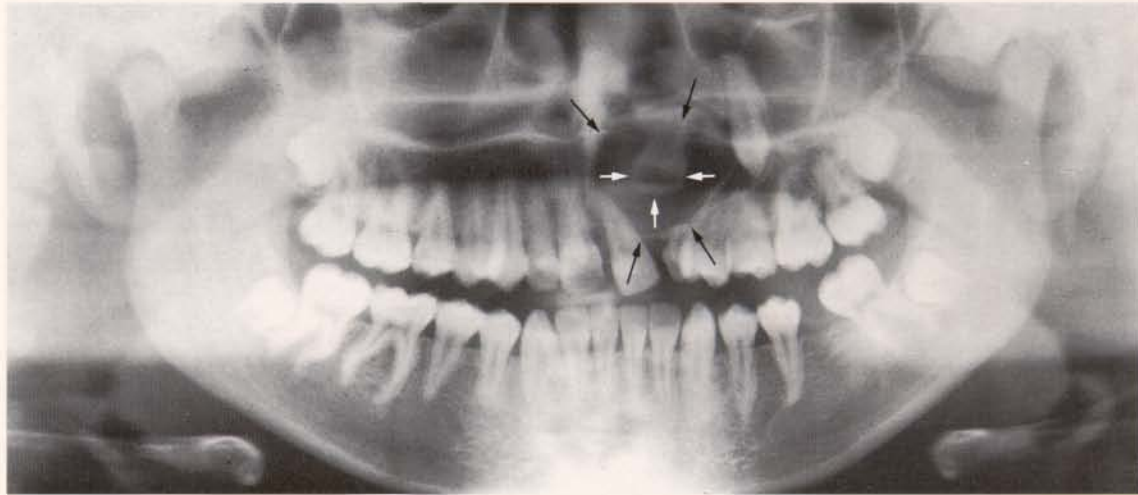
Atypically Localized Follicular Cysts

Atypically localized follicular cysts that could only be diagnosed and localized using panoramic radiography and adjunctive special projections are demonstrated on the previous page and on this page. In the dental practice precisely prepared occlusal films can be helpful for diagnosis of the third dimension. Lateral or postero-anterior cephalometric radiographs may be useful, and

the reverse Towne projection with maximum jaw opening can be recommended. Furthermore, in the case of large cysts in the maxilla it is absolutely necessary that the patient be referred for film tomography or computed tomography in a hospital or radiology clinic.

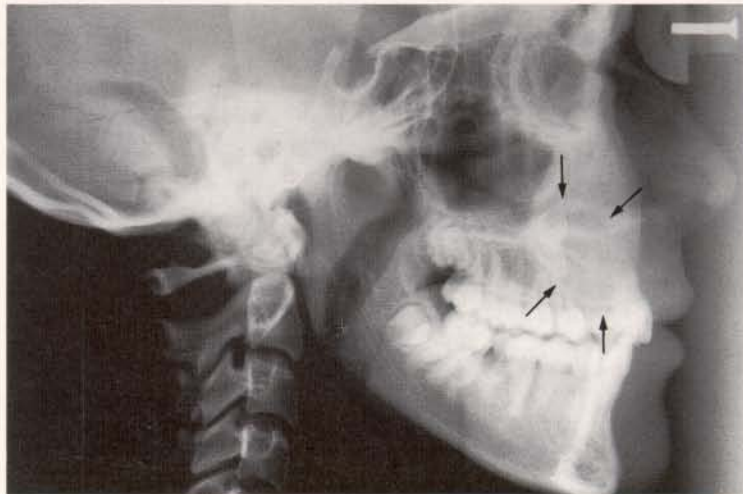
515 Coronal follicular cyst on tooth 22 with displacement of 23 and retention of 63 in a 17-year-old female

Tooth 22 appears enlarged and overexposed, and it is displaced palatally, while tooth 23 is dramatically displaced in the vestibular direction (arrows).



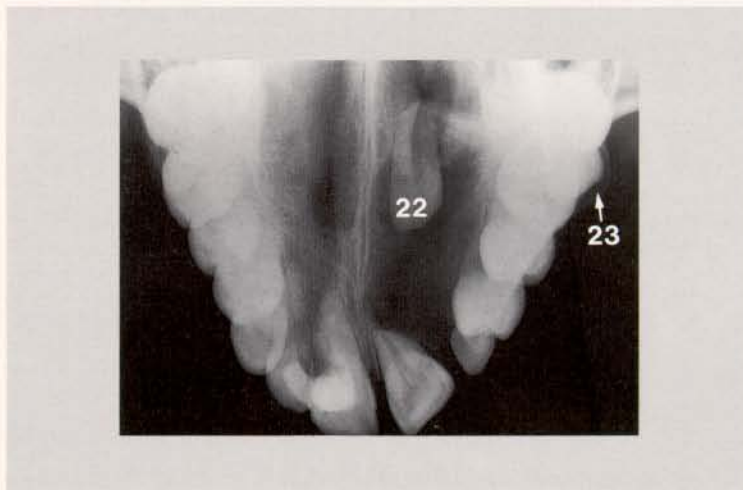
516 Same case as seen in the lateral cephalometric radiograph

Positions of the cyst and teeth as seen from the lateral view (arrows).



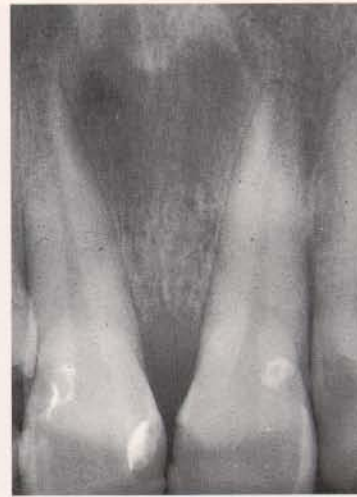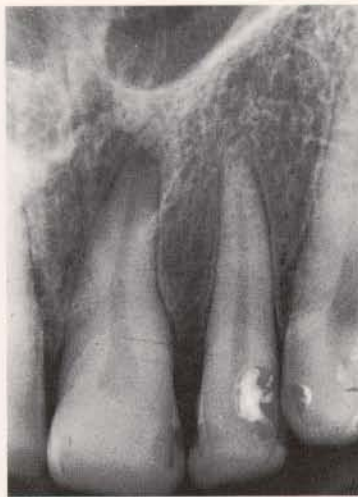
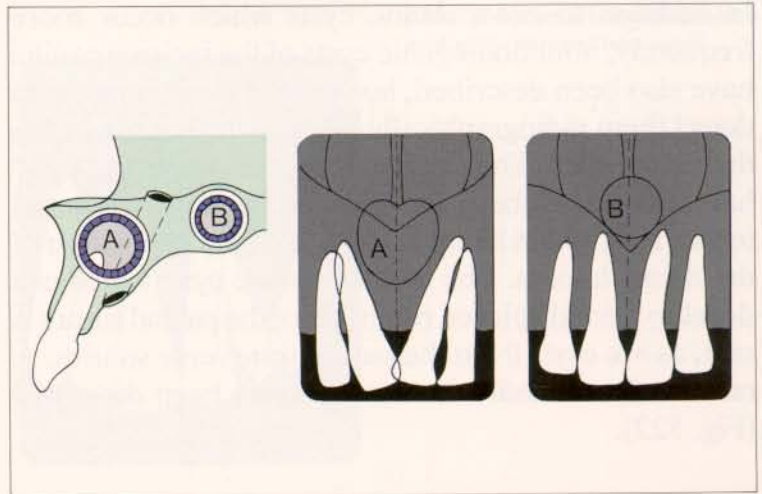
517 Occlusal film of the same patient

Although teeth 22 and 23 (with arrow) appear in this projection to be positioned rather obliquely toward the dorsal, the occlusal view provides a good overview of the third dimension.



Nonodontogenic Cysts

These cysts derive from epithelial remnants of the nasopalatine tract, the embryonic Hochstetter wall and the facial fissures. According to site and expanse, the so-called ductal cysts as well as nasopalatine cysts may develop in the incisive canal; these cysts may expand between the central incisors. The nasal septum and the nasal spine anteriorly force the formation of the typical heart shape. The median fissure palatal cyst may develop in the middle of the palate from remnants of the embryonic palatal processes (Fig. 518).



518 Diagram and schematic radiograph of nasopalatine (A) and the median fissural cysts (B)

519 "Ductal cyst" in the incisal canal

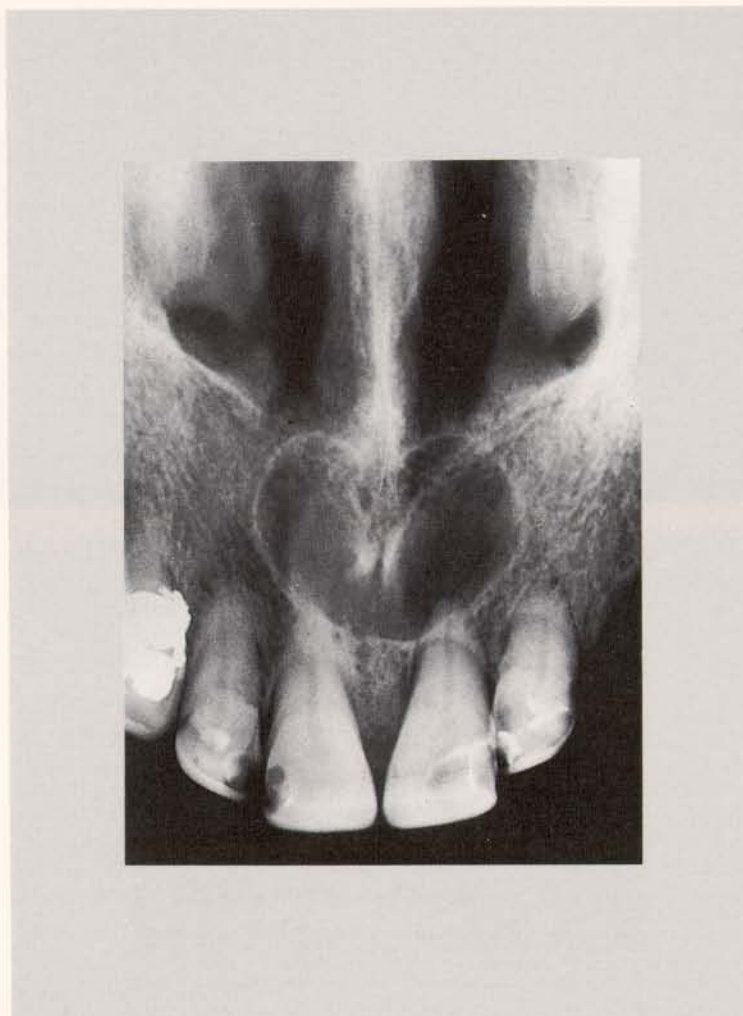
In this periapical radiograph, the cyst is superimposed upon the apex of tooth 21, giving the impression of a periapical lesion (vitality testing!).

520 Nasopalatine cyst in an early stage

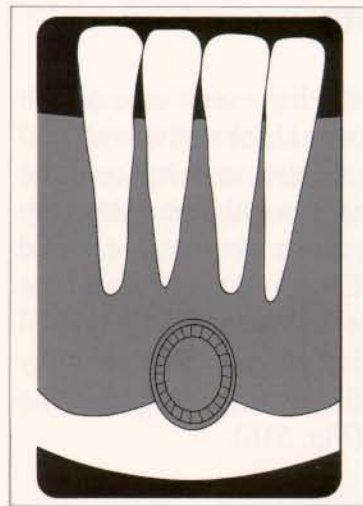
The cyst develops between the roots of teeth 11 and 21, forcing them apart.

521 Nasopalatine cyst

The cyst has developed palatally from the anterior teeth in the nasal portion of the duct. In this position, it does not displace the roots of teeth 11 and 21.



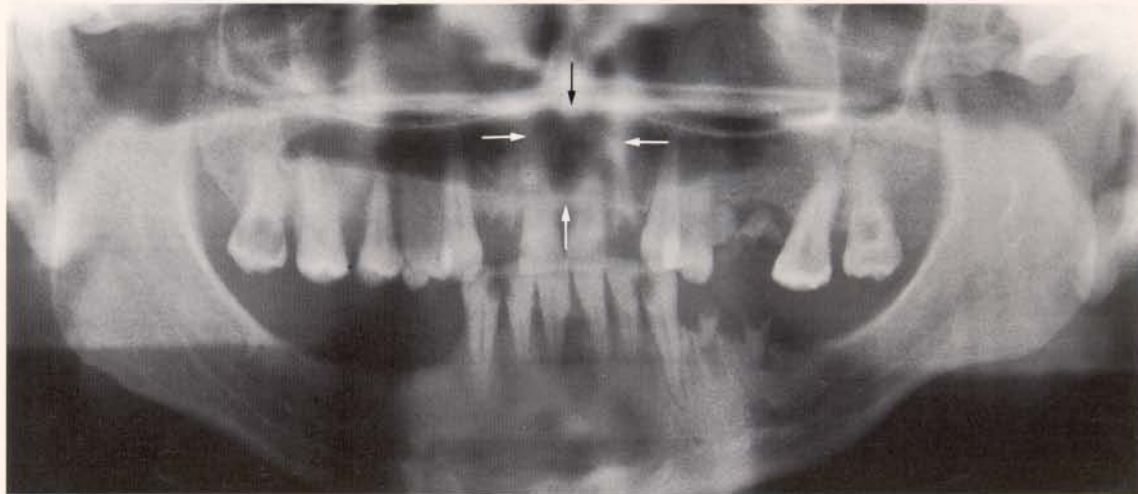
In addition to nasopalatine cysts which occur more frequently, nonodontogenic cysts of the incisive papilla have also been described; however, it is not possible to detect them radiographically because they occur within the soft tissues. The “midline (median) alveolar cyst” has been described between the maxillary central incisors; its origin likely derives from the epithelium of the dental lamina. The median fissure cyst, which can develop from displaced remnants of the palatal suture is rare, as are cysts from the palatal transverse sutures. A rare median mandibular cyst has also been described (Fig. 522).



522 Diagram of a median mandibular cyst

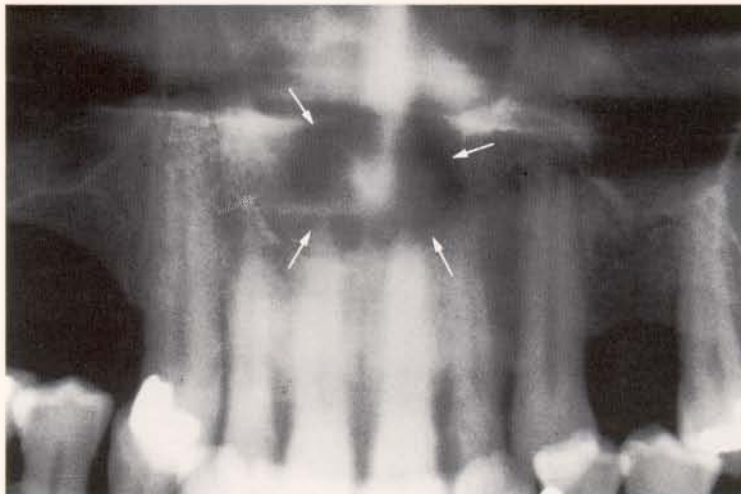
523 Nasopalatine cyst as seen in a panoramic radiograph

Typical heart-shaped cyst, but without displacement of roots of teeth 11 and 21 (arrows). This appearance indicates the cyst has developed palatally from the anterior tooth roots.



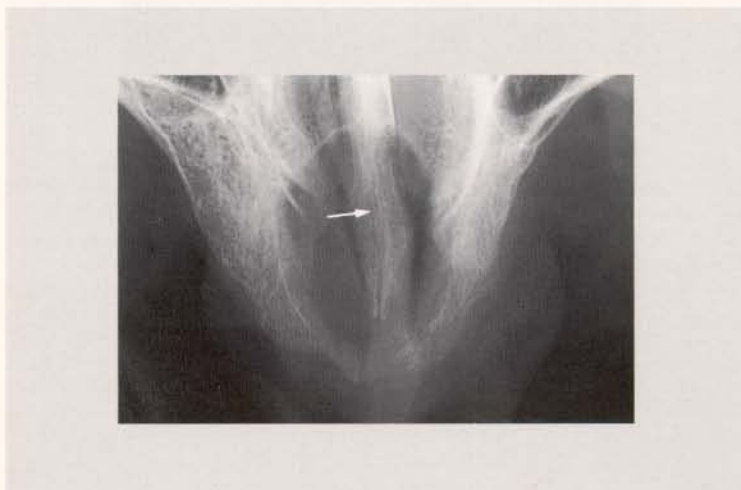
524 Median (fissural) palatal cyst

The cyst distends the floor of the nasal sinus (arrows). The anterior nasal spine, portions of the nasal crest of the maxilla and the vomer (collectively referred to as the osseous nasal septum) remain intact.

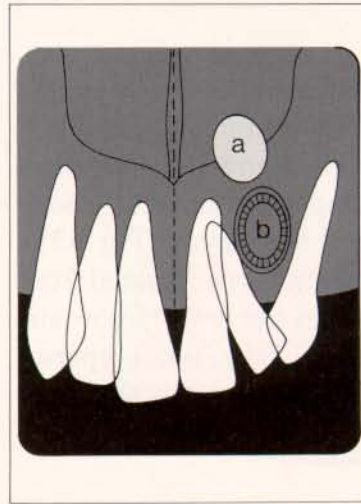


525 Median (fissural) palatal cyst as seen in an occlusal projection

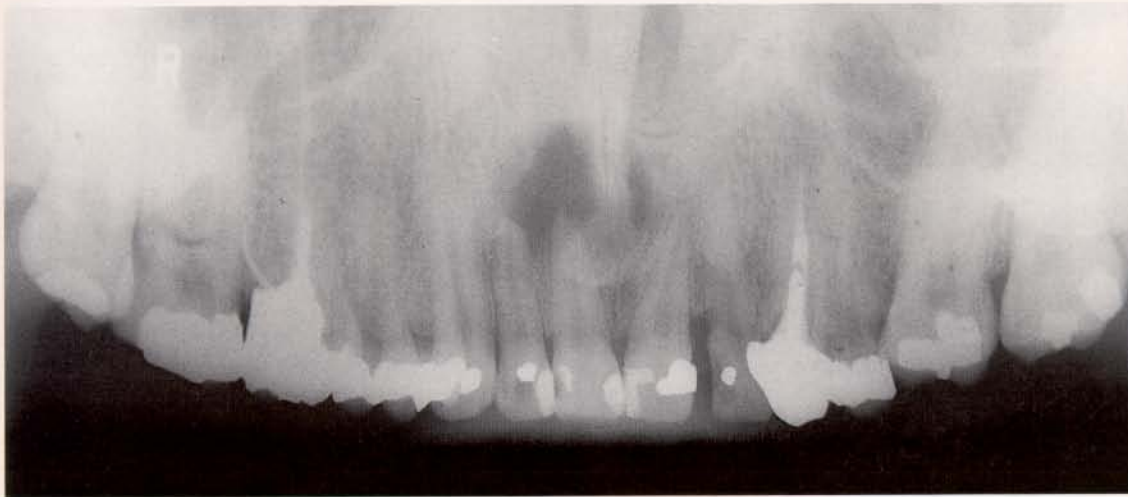Because the caudal portion of the osseous nasal septum in the region of the nasal crest has already been resorbed by the growing cyst, the median suture is no longer visible in its entirety (arrow).



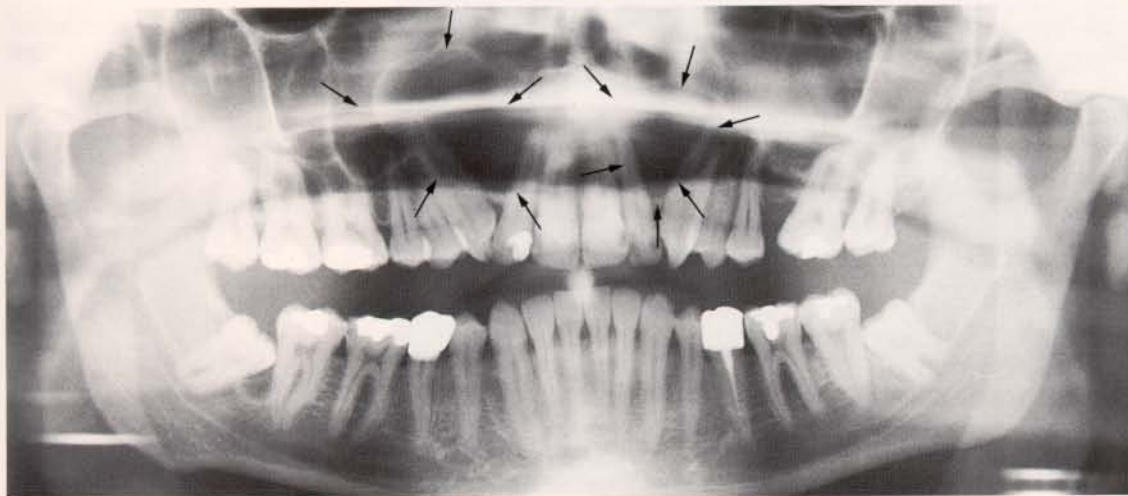
Two cysts may derive from the embryonic Hochstetter epithelial wall. The nasoalveolar cyst resides subperiosteally in the region of the nasolabial groove; it is possible to show this cyst radiographically only by using contrast media (Fig. 526a). The second type of cyst develops between the roots of vital lateral incisors and canines and presents as a globulomaxillary cyst (Fig. 526b), which appears radiographically as a lucent area in the shape of an inverted pear.



526 Diagram of nasoalveolar and globulomaxillary cysts



527 Median palatal cyst
View of the maxilla taken with intraoral source radiography.

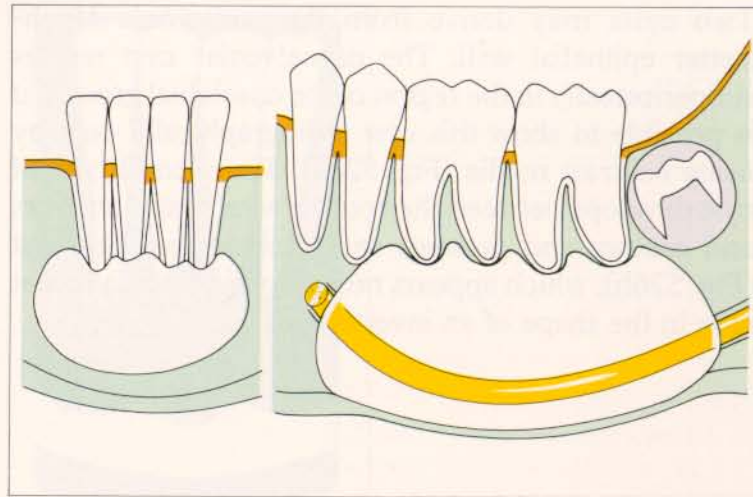


528 Bilateral globulomaxillary cysts
The arrows depict how the cysts displace the roots of lateral incisors and canines, resulting in a cystic cavity with the shape of an inverted pear. Cysts of this kind may also be regarded as an aberrant form of cleft palate.

- Possible causes for radiolucencies in the canine region of the maxilla
- Apical radicular cyst
 - Periodontal cyst
 - Globulomaxillary cyst
 - Keratocyst
 - Adenomatoid odontogenic tumor
 - Osteoblastoma
 - Ameloblastoma

Pseudocysts

The term “pseudocyst” exists because these cavities that are free of epithelium often appear radiographically as cysts. Depending on patient history and contents, these “cystoid” structures may be categorized as solitary bone cysts (Fig. 529) and aneurysmal bone cysts (Fig. 533). Many of the solitary bone cysts can be ascertained from the medical history (trauma); thus the term “traumatic bone cyst” has persisted (Fig. 529, left). When opened surgically, such solitary bone cysts present as an empty cavity.



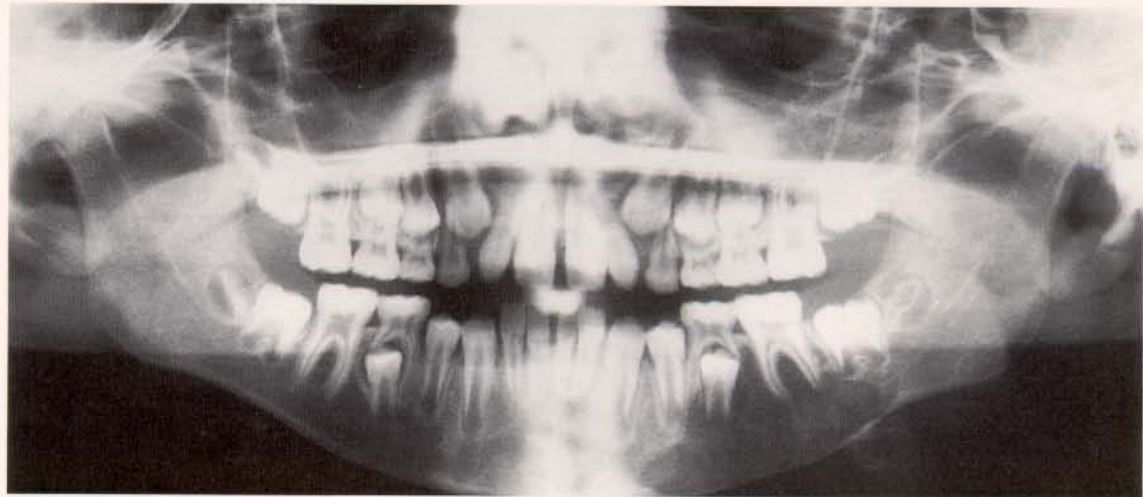529 Diagram of solitary bone cyst in the mandible

The typical localization of the traumatic bone cyst is displayed on the left.

530 Solitary bone cyst in the left mandibular body in a 9-year-old female

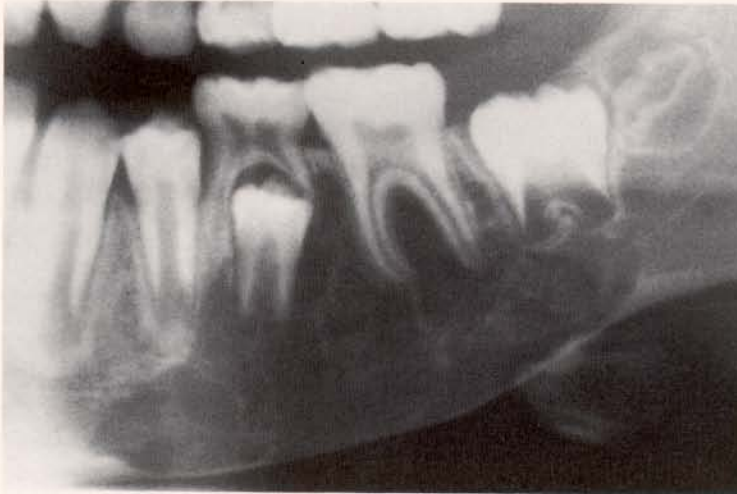Noteworthy is the thinning and distension of the osseous cortical lamella. This radiographic sign is typical for pseudocysts in the horizontal ramus.

Courtesy Dr. G. Nager, Fribourg



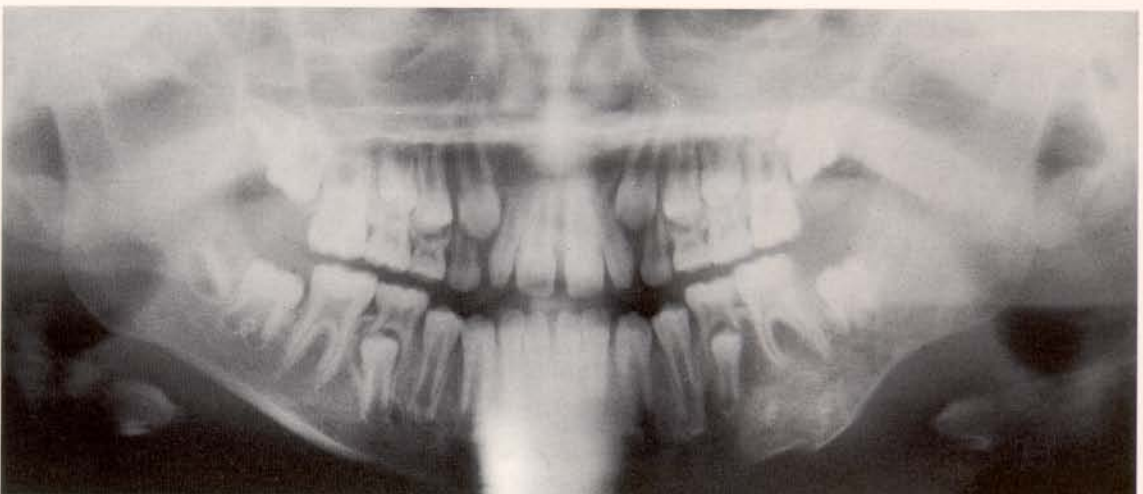
531 Section from a panoramic radiograph of the same patient

Note the radiolucency that is not completely free of trabecular bone, and the distended but thinned cortical bone. The cavity is traversed in the molar area by the mandibular nerve.



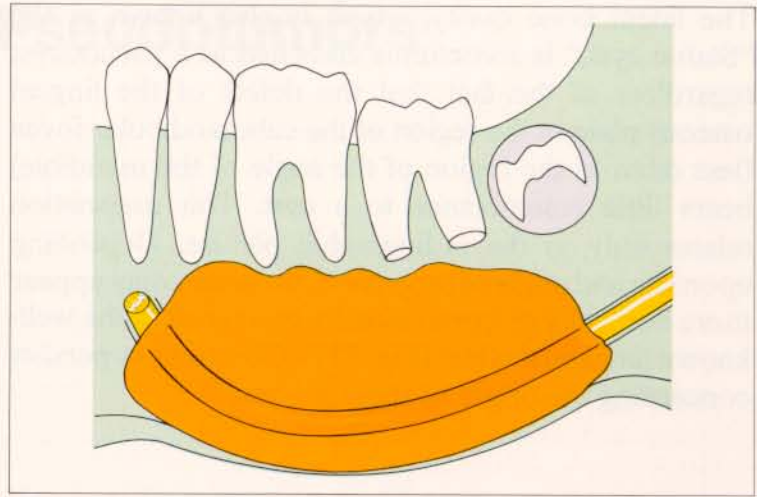
532 Solitary bone cyst

This is a panoramic radiograph of the identical case, postoperatively. Note the *apparent fracture* in the surgical area; the patient moved during exposure.

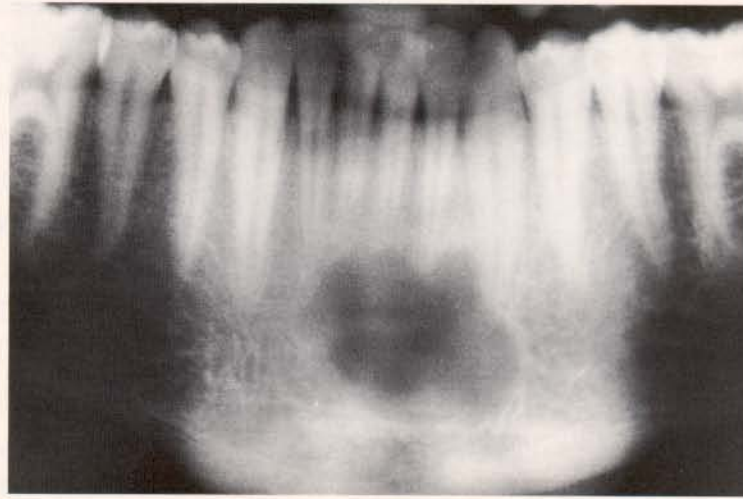
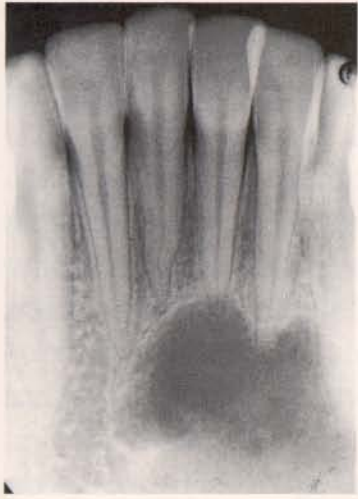

Aneurysmal bone cysts histologically exhibit a fibrous network as well as a rapidly expanding "cystic" lesion filled with a central mass of calcifying osteoid, and endothelium-lined cavities. For this reason the "cyst" presents radiographically as a solitary bone cyst. Radiographic differential diagnosis is therefore impossible.

The preferred site for such lesions is the body of the mandible in 11- to 15-year-old males. These lesions are extremely radiolucent and are therefore more clearly visible in radiographs taken with shorter exposure times (Fig. 533).

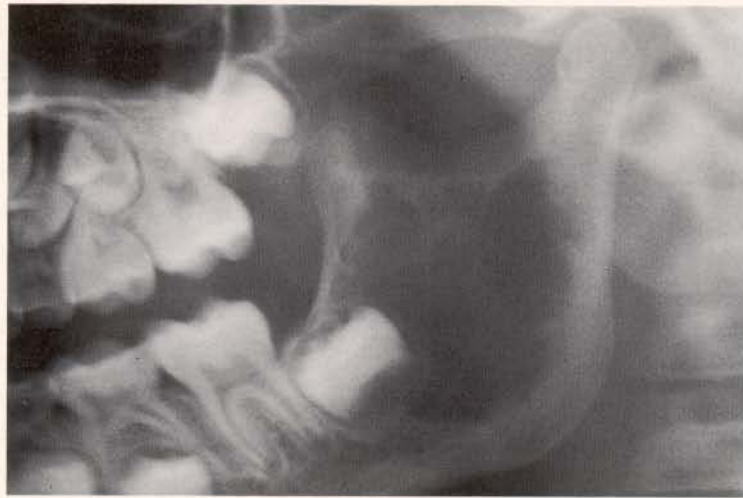

533 Diagram of an aneurysmal bone cyst



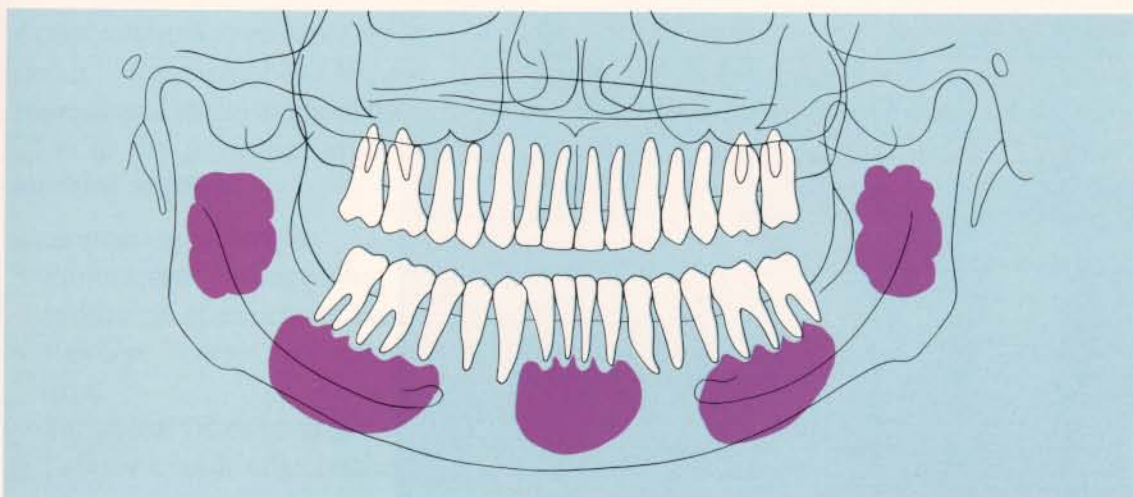
534 Traumatic bone cyst in the mandibular anterior region of an 18-year-old male

Compare the periapical radiograph with the panoramic film. It is extremely difficult to differentiate this lesion from a central giant cell granuloma.



535 Solitary bone cyst in an uncommon location in a 7-year-old female

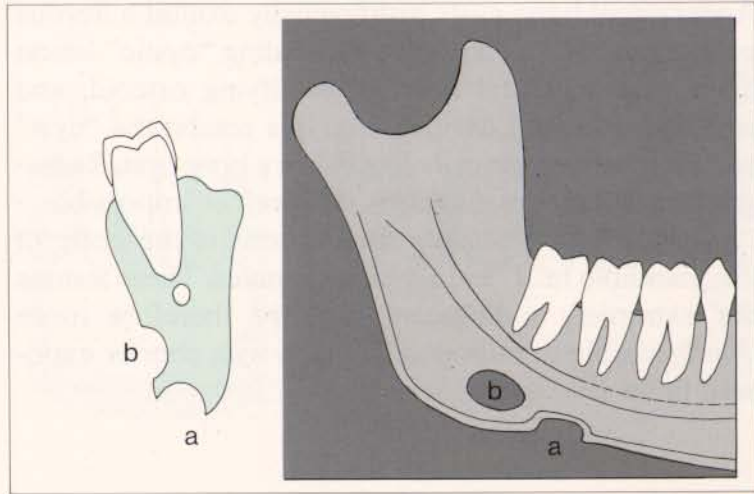
Courtesy Dr. M. Perko, Zurich



536 Typical site of solitary bone cysts

These cysts are most often observed in the first and second decades of life. The aneurysmal bone cyst is usually seen in the horizontal ramus of the mandible in 10- to 15-year-old patients.

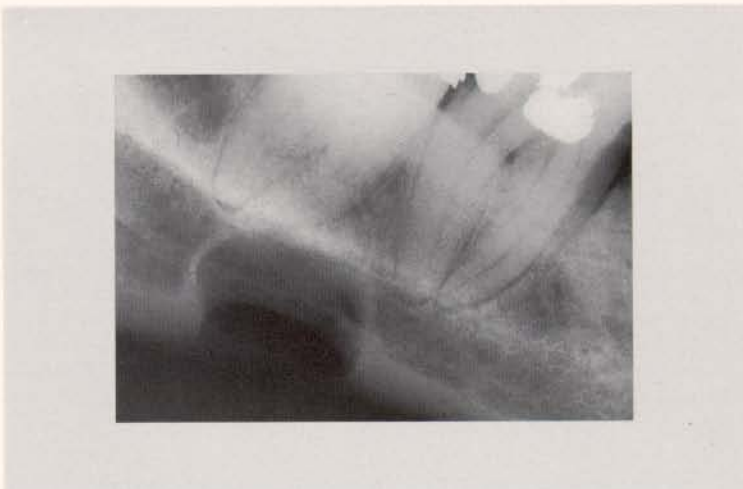
The latent bone cavity, which is also known as the "Stafne cyst," is sometimes classified as a pseudocyst regardless of the fact that the defect of the lingual osseous plate in the region of the submandibular fovea (less often in the region of the angle of the mandible) bears little resemblance to a cyst. This association relates only to the radiographic picture. Depending upon site and angle of projection, the lesion may appear more cortically or open caudally as a result of the well-known tangential effect (Fig. 537). Controversy persists concerning the origin of these lesions.



537 Diagram of a latent bone cavity as it might appear in a periapical radiograph or in a panoramic film

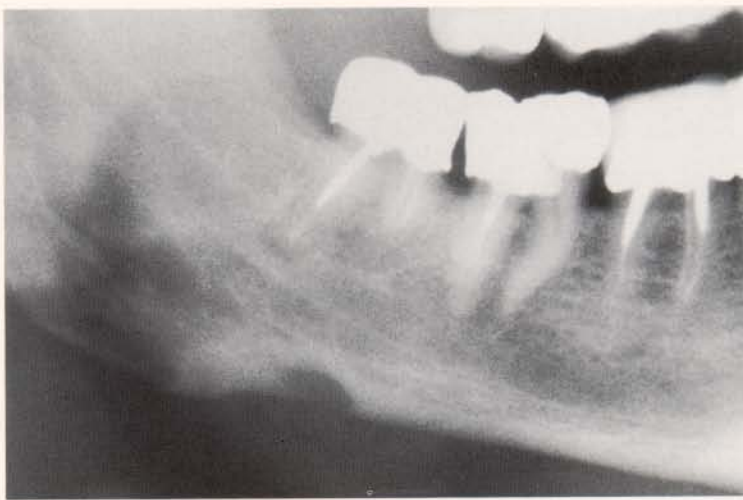538 Latent bone cavity open caudally as viewed in a periapical radiograph

Note the corticalization of the deep defect, which appears open caudally (see also Fig. 537a).



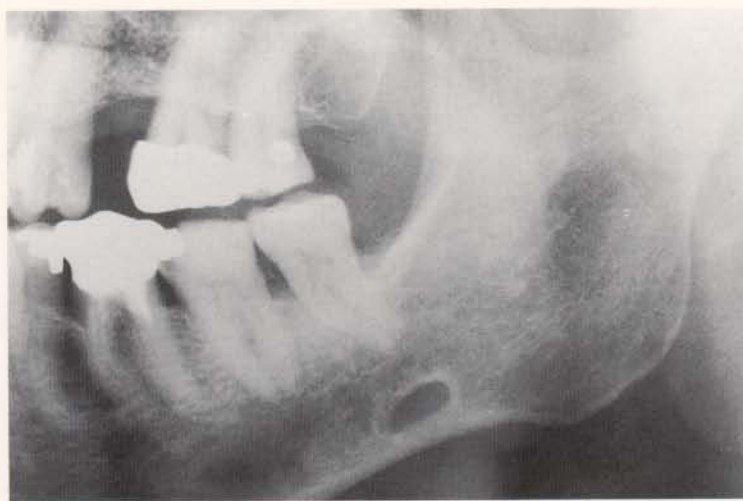539 Latent bone cavity of a similar type, viewed in a panoramic radiograph

Note the thickening of the surrounding cortical bone. It is interesting to note here that an ossifying fibroma, an "angular process" or a peripheral osteoma can develop at the same site.



540 Latent bone cavity, closed type

Note the thickening of the compact bone around the defect, which typically is located below the mandibular canal and usually anterior to the mandibular angle (see Fig. 537b).



Odontogenic Tumors and Pseudotumors

Odontogenic tumors and tumor-like “pseudotumors” develop as neoplasias from the dental lamina. They are usually benign, but several of them have a tendency, albeit seldom, toward malignant transformation. Because growth occurs only slowly, asymptotically and without any change in mucosal appearance, the existence of such lesions in their early stages is usually detected only by chance, or after the development of some structural deformation or obvious asymmetry of the facial skeleton. The growth of such entities, for example the ameloblastoma, can occur invasively, which renders complete surgical excision difficult; it is for this reason that such lesions often recur postoperatively, while other lesions, e.g., the odontoma, are routinely removed surgically without subsequent recurrence. On the other hand, it is seldom necessary to treat surgically lesions characterized by excess cementum formation. With appropriate radiographic follow-up in the second and third decades of life, the potentially negative consequences of such lesions in later life can be obviated for most patients.

Ameloblastoma, which according to the literature is the most common tumor in the jaw region, occurs relatively late, mainly in the fourth decade of life. This is probably an incorrect picture, however, because the painless and slowly growing tumor does not elicit any mucosal changes nor any expansion of the jaw; it is for this reason that before the era of the panoramic radiographic technique such tumors were detected only years later in advanced stages. The tumor affects both sexes equally; it has a tendency to recur and may malignantly transform in approximately 2% of cases. The histologic picture is variable: Solid forms infiltrate, while cystic forms generally remain comparatively benign.

Localization. Approximately 80% of all ameloblastomas occur in the mandible. Of these, 70% occur in the molar regions and at the angle of the mandible, approximately 25% in the premolar area, and the remainder in the anterior segment.

Examination technique

- Panoramic radiography, in later stages utilizing reduction of exposure time
- Reverse Towne projection, using reduced exposure time
- Periapical films to target early lesions
- Lateral mandibular occlusal films, with reduced exposure time

- Computed tomography, indicated for lesions in the maxilla and in later stages.

Radiographic signs. The ameloblastoma may present radiographically as “unilocular” (often even lobular in appearance) or “multilocular.” The multilocular forms exhibit either relatively large, round “soap bubbles” with slender septa and a thin cortical plate (in late stages), or numerous small bubbles resembling a honeycomb and with thick septa. The latter form may present a radiographic picture similar to a central hemangioma. Not infrequently, a tooth may be incorporated in the lesion.

Differential diagnosis

- Odontogenic myxoma, especially at the angle of the mandible
- Central giant cell granuloma, especially in the premolar area of the mandible
- Late stage follicular cysts
- Adenoid odontogenic tumor, unilocular, in the canine region of the maxilla
- Ameloblastic fibroma in late stage.

The *ameloblastic fibroma* is a mixed tumor that occurs during the first and second decades of life, especially in the molar areas of the mandible. In rare cases, the

ameloblastic fibroma can undergo malignant transformation to a sarcoma. The *ameloblastic fibro-odontoma* is classified with the odontomas.

Odontogenic myxoma. Both sexes are equally affected. As a fibromyxoma, this lesion occurs as a benign mesenchymal tumor with little tendency toward recurrence, also in nonoral skeletal components, where it may develop from dissipated mucous-forming connective tissue. As an odontogenic myxoma, it derives from odontogenic mesenchyme, affects young persons and young adults in the second and third decades of life, and commonly recurs in the jaws after surgical excision.

Localization. The odontogenic myxoma is generally observed in the mandible, and typically in the molar regions at the angle. It is seldom seen in the maxilla.

Examination technique

- Panoramic radiography, with reduction of exposure data in late stages
- Reverse Towne projection with reduced exposure data
- Lateral mandibular occlusal films, and with reduced exposed time
- Computed tomography, indicated for lesions in the maxilla, and in later stages

Radiographic signs. Odontogenic myxomas bear a close resemblance to the soap bubble-like picture of ameloblastoma. If it is possible to depict fine structure, one can observe the thin, wispy and “disintegrated” trabecular pattern, with more straight lines. In advanced cases, the cortical bone is thinned and distended. Displacement of teeth with inclusions is possible.

Differential diagnosis

- Ameloblastoma in the region of the angle of the mandible
- Giant cell granuloma in the mandibular premolar region
- Aneurysmal bone cyst in the mandibular premolar region

Cementoma. Today, the term cementoma includes a number of cement-forming changes in the jaws; however, only some of them may be classified as odontogenic tumors whereas others are of mesenchymal origin, or may even be reactive in etiology. This latter group includes the periapical cemental dysplasia that is often observed primarily in middle-aged females. The radiographic picture of this lesion will be discussed here in connection with those of the cementoblastoma and the cement-forming fibroma. Indistinct transition forms

and combined forms render difficult any definitive and radiographically diagnostic or clinically practical classification of these entities. Only histopathologic observation of excised material can provide such information. Because fine tissue examination and appropriate therapy are usually only used in cases where differential diagnosis is doubtful, one is reconciled in practice to recognizing basic diagnostic/radiographic characteristics of such radiographically evident changes.

Periapical cemental dysplasia. Cementomas in the family of periapical dysplasias occur most commonly in middle-aged females, particularly in the anterior region of the mandible. In such cases, especially in younger persons, individual anterior teeth in the maxilla may also be involved. Schematically, such changes can be divided into three stages of development. They usually occur in multiple form, and are most common in non-Caucasian races, sometimes combined with cementoblastomas of the premolar and molar regions of the mandible.

Localization. Mandibular anterior region, sometimes combined with lesions on individual teeth of the maxillary anterior segment or with cementoblastomas in the posterior mandibular regions.

Examination technique

- Panoramic radiography
- Concomitant use of targeted periapical radiographs

Radiographic signs. Periapical radiolucencies and shadows where boundaries are not always sharply demarcated. Three stages of development may be observed:

- Stage of fibrosing, with circumscribed periapical radiolucency
- Stage of initial calcification, with flake-like shadowing
- Terminal stage with evenly dense shadowing; the lesion depicts the typical root contact.

Differential diagnosis

- Chronic apical periodontitis (vitality testing!)
- Hyperparathyroidism
- With shadowing: Infarct of bone
- Paget’s disease of bone, depending upon age and gender

Cementoblastoma. Cementoma, in the general classification of cementoblastoma, occurs in the second and third decades of life, slightly more frequently in males.

Localization. Cementoblastomas are found almost exclusively in the premolar and molar regions of the mandible. They may be observed very rarely in the posterior segments of the maxilla.

Examination technique

- Panoramic radiography
- Concomitant use of targeted periapical films

Radiographic signs. Often difficult to discern, but with well-demarcated shadows. The uniform or spotty shadowing of all grades suggests deposits of material with density similar to calcifying tissue.

Differential diagnosis

- Periapical lesions and bone scars
- Bone infarct
- Paget's disease of bone, depending upon age and gender
- Osteoblastoma, without root contact
- Ossifying fibroma, no root contact

Cement-forming fibroma. Cementomas in the general classification of cement-forming fibromas are radiographically similar to certain forms of cementoblastoma as well as ossifying fibroma; for this reason it is virtually impossible to differentiate them radiographically. Usually only in later stages do these lesions exhibit a detectable expansion with signs of distention and thinning of the cortical bone. These lesions develop frequently in middle-aged females, but also sometimes in young males; for this reason and because of their localization they may be confused with a solitary bone cyst.

Odontoma is a lesion that is viewed today more as a developmental abnormality than as a true tumor even though, for example, the ameloblastic fibro-odontoma could equally well be categorized as a mixed tumor. Depending upon the degree of development of the lesion, it is possible to differentiate two basic forms

which may appear radiographically anywhere from amorphous masses to completely differentiated teeth. The first form always exhibits a poorly organized and very opaque conglomeration of dental elements such as enamel, dentin, cementum and connective tissue; such lesions are called *complex odontoma*. If the lesion consists of one or several rudimentary or fully formed teeth, it is a *compound odontoma*.

Depending on their location, supernumerary tooth buds have the capacity to develop unimpeded, concurrent with certain stages of dental development. Therefore the classification *odontoma* is appropriate for all stages of abnormal dental development, from a scarcely detectable radiolucency caused by a non-calcified tooth primordium to a fully formed supernumerary tooth.

Localization. The several variations of complex odontoma are most commonly observed in the region of the mandibular third molars in males, and in the tuberosity region in females. The compound odontoma is detected almost exclusively in the anterior segment of both mandible and maxilla.

Examination technique

- Panoramic radiography
- Concomitant targeted periapical films
- CT of the mandibular angle (mandibular nerve)
- CT of the tuberosity region (maxillary sinus)

Radiographic signs. The complex odontoma exhibits either a sharply demarcated, amorphous and uniform shadow surrounded by a narrow radiolucent border, or an exceptionally radiopaque shadow with irregular borders created by more highly differentiated enamel segments. Impacted adjacent teeth are a common finding. The compound odontoma exhibits rudimentary or completely formed teeth, which are usually surrounded by a radiolucent border.

Differential diagnosis. With a typical localization, none.

Ameloblastic fibro-odontoma. This tumor is observed most commonly in young individuals of both sexes as a relatively rare form of odontoma.

Ameloblastoma

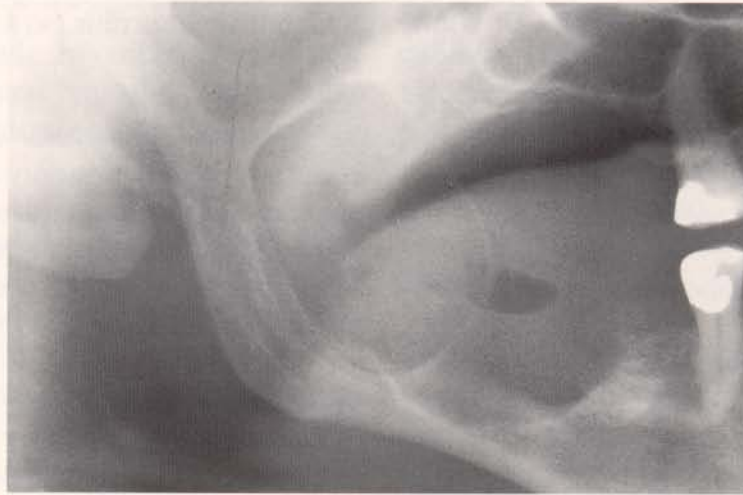In all its forms, ameloblastoma radiographically exhibits sharp demarcation; this may erroneously lead to the suspicion that, histologically, infiltrative growth is occurring. The radiolucencies are generally described as honeycomb or soap bubble in appearance. Impacted or neighboring teeth are displaced, with roots often partially resorbed. The cortical bone is extremely thin but not penetrated. Recurrent lesions frequently reveal a picture that closely mimics the odontogenic myxoma. In younger persons the tissue of origin appears to be

primordial and follicular cysts; in older individuals epithelial remnants resulting from tooth extraction, sometimes years earlier, may represent the etiology. It is for this reason that histologic examination should be performed after removal of any cyst-like lesion.

In the mandible and especially in the third molar region, incipient ameloblastomas can only be detected radiographically after they have reached a certain size, due to the addition effect of remaining osseous structure in the background.

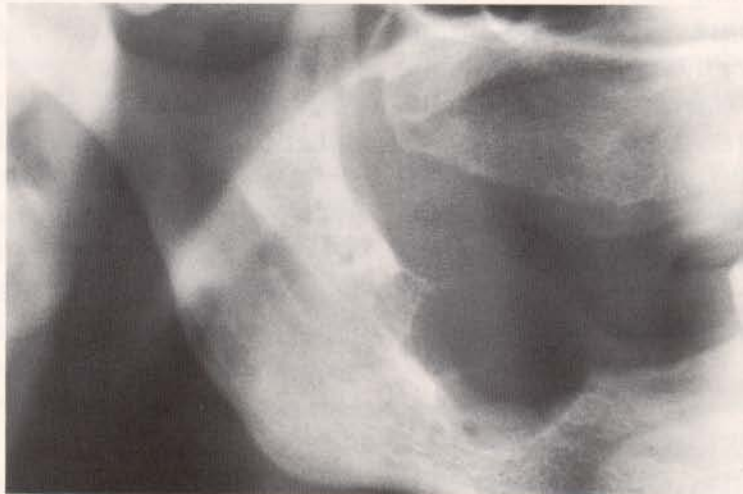
541 Ameloblastoma at the angle of the mandible in a 48-year-old male

Expansive form with oval radiolucencies traversed by a few very thin septa. The osseous ceiling, which is normally shown, is not seen here despite use of a low energy projection. This is a late stage lesion, with clinical signs including distention and fluctuation.



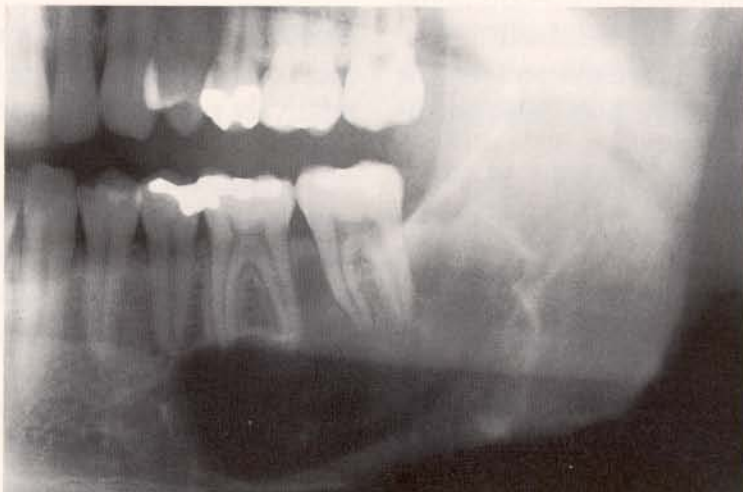542 Soap bubble-like form of an ameloblastoma of the molar region in a 35-year-old female

Recurrent lesion. In addition to the multilocular soap bubble-like shape, note that the mandibular canal is no longer distinguishable, and a reactive sclerosis of the osseous structure is visible at the angle of the mandible.

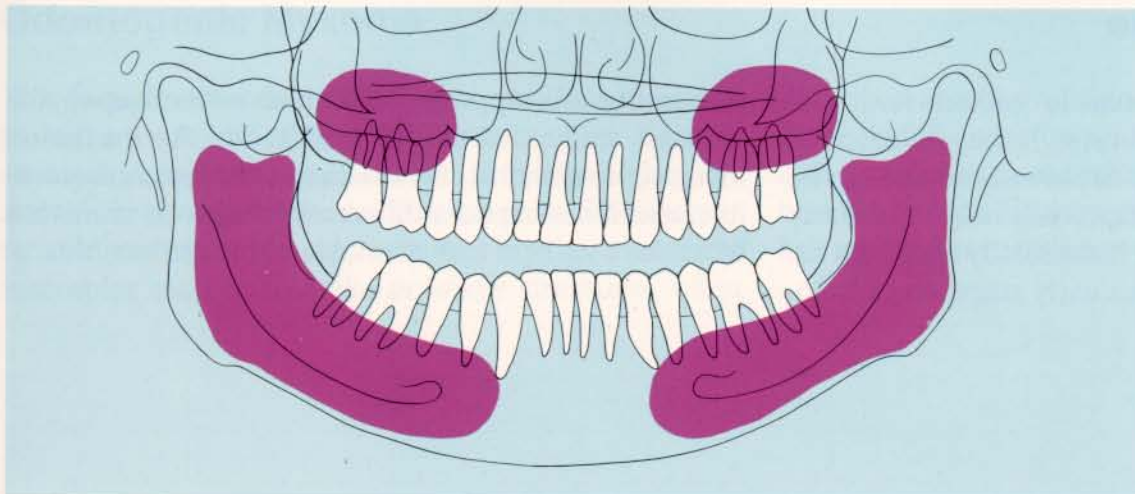


543 Ameloblastoma, resembling a keratocyst, in a 28-year-old male

Relatively early stage with lobular distentions from unilocular radiolucency.

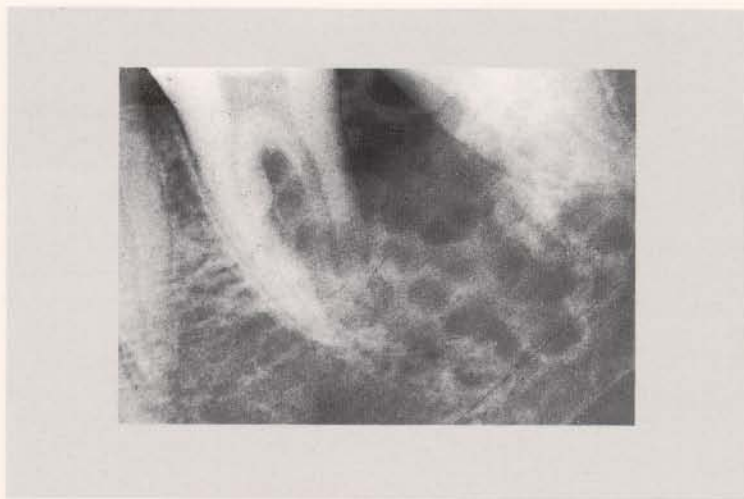


Courtesy Dr. K. Weibel, Baden



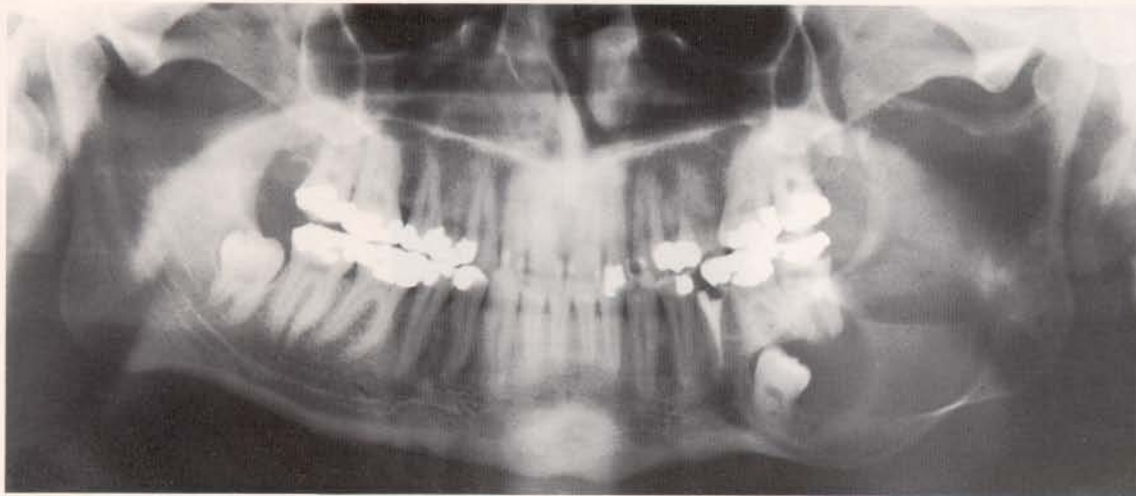
544 Most common ameloblastoma sites

These lesions occur most often in the second and third decades of life, thus in caries-free young adults the exclusive use of bite-wing radiographs will not provide adequate overview of the jaw. The site of 80% of ameloblastomas is in the mandible and only 20% in the maxilla.



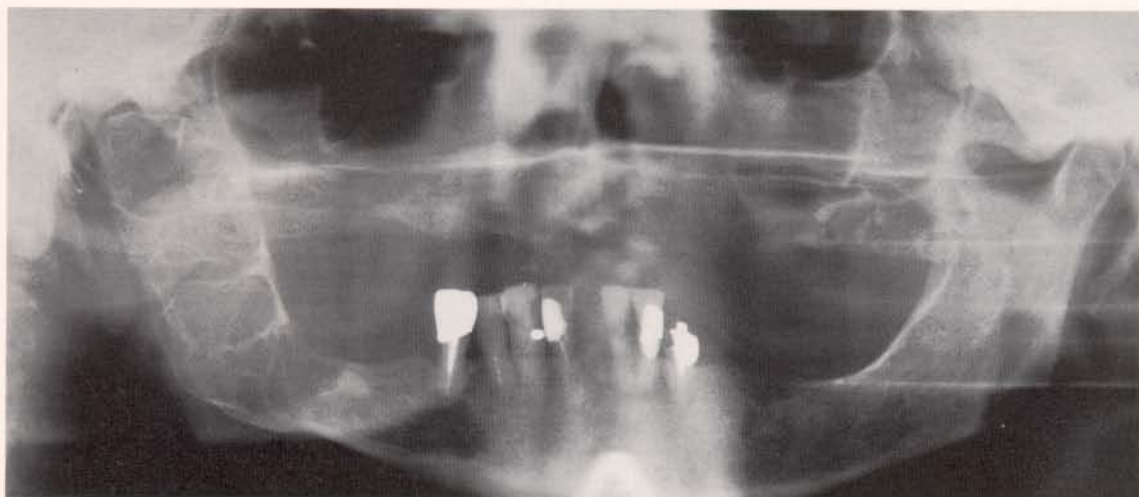
545 Honeycomb-like small ameloblastoma in a 19-year-old female, as seen in a periapical radiograph

Early stage. The relatively thickly bordered "bubbles" elicit a radiographic subtraction effect giving the appearance of root resorption.



546 Large soap bubble-shaped ameloblastoma typically located in the molar region, angle of the mandible and ascending ramus

Late stage. Often a third molar or a second molar is enclosed within the lesion. Note the distention and thinning of the cortical bone, which is only visible with low energy reverse Towne projection or even better in CT.



547 Recurrent ameloblastoma in the right ascending ramus of the mandible

The radiographic picture is similar to a myxoma. The condyle is seldom involved even with such large lesions; however, spontaneous fractures are possible.

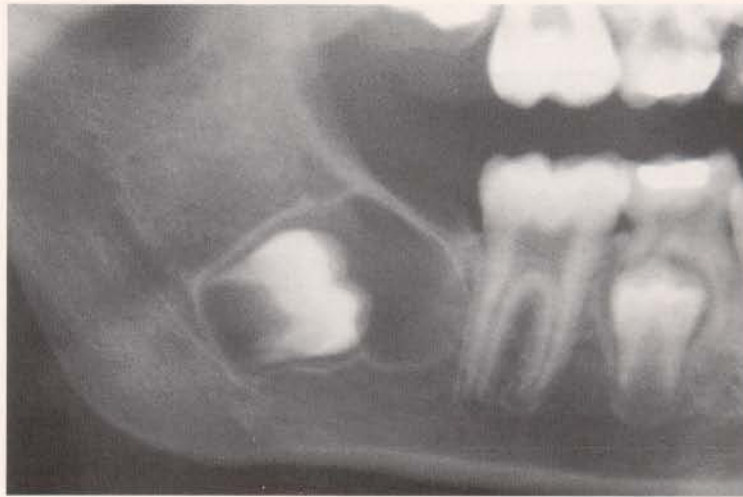Ameloblastic Fibroma

The most common ameloblastic mixed tumor is probably the ameloblastic fibroma. It may be detected as early as the end of the first decade of life and can be definitively diagnosed radiographically only in this early stage. While the follicular cyst is classically located at the cemento-enamel junction, in its early stages the amelo-

blastic fibroma appears to sit like a “hat” upon the occlusal surface of the affected tooth. As the lesion increases in size, this characteristic is no longer discernible, and this can render differential diagnosis vis-à-vis a follicular cyst or a true ameloblastoma impossible.

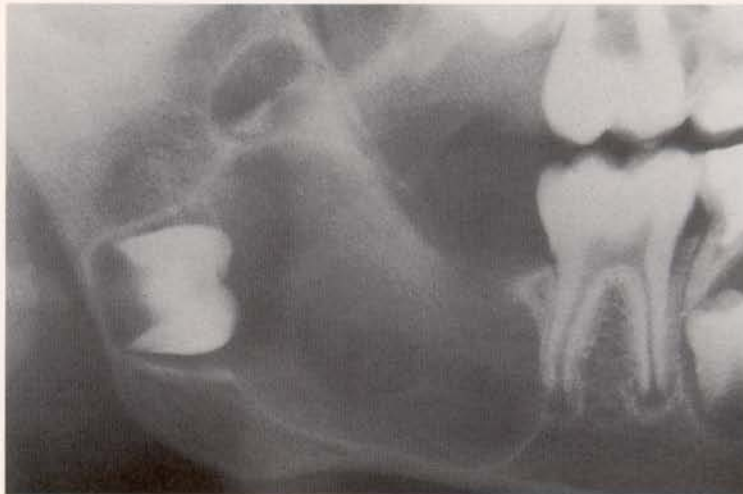548 Ameloblastic fibroma in an 8-year-old male

One can see in this and also in the following radiograph how the ameloblastic fibroma “sits” upon the occlusal surface of the second molar. In contrast, follicular cysts appear to attach to the cemento-enamel junction.



549 Ameloblastic fibroma in an 8-year-old female

This somewhat more advanced case demonstrates how the follicular sac is now opening, and how this obscures the previously clear radiographic sign. Note also the displacement of the tooth bud of tooth 48 in the ascending ramus.



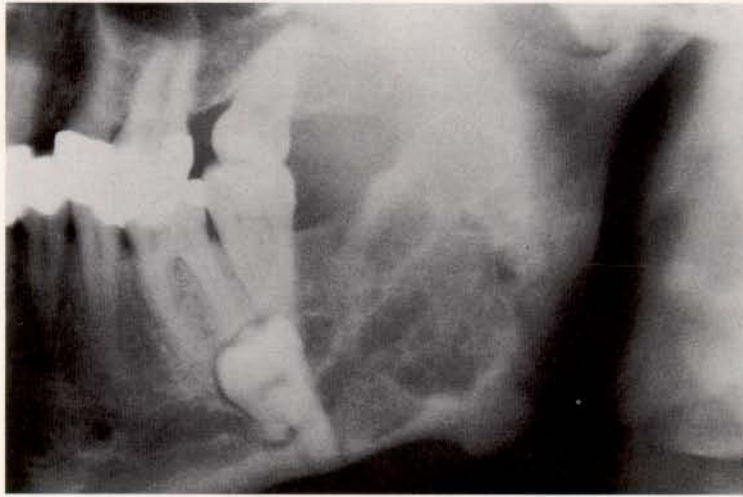
Technical tip for correct projection of large, radiolucent cysts, tumors and tumor-like lesions:

- By using reduced exposure data and appropriate standard projections the normally much thinned osseous demarcation can be rendered visible. The clear depiction of demarcations and structural details is often of decisive importance for differential diagnosis, and above all in comparison with malignant lesions.

Odontogenic Myxoma

This benign, mucous-containing tumor that originates from the tooth bud affects both sexes equally. It grows slowly and, in later stages, leads to distention of the jaws and thinning of the distended cortical plate. The characteristic radiographic appearance in the mandible resembles soap bubble-like or wispy structures, often

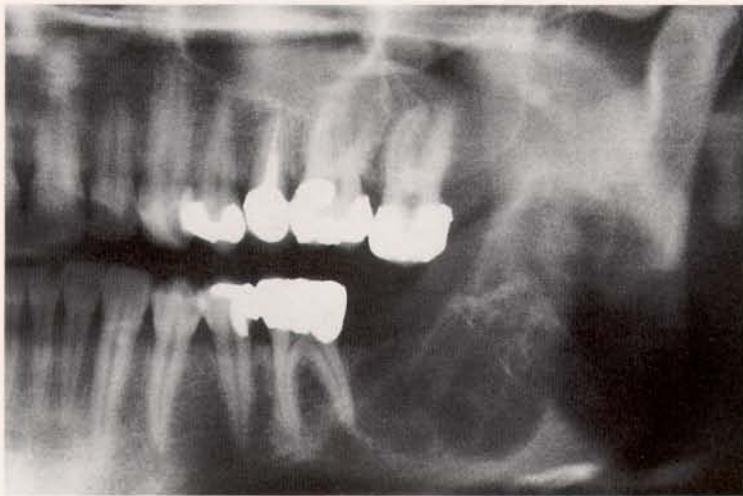
described as a "torn fishing net." In the maxilla, on the other hand, structures are difficult to discern. The radiographic signs are reminiscent of those of an ameloblastoma or a follicular cyst. The odontogenic myxoma has a particular tendency to recur.



550 Odontogenic myxoma in the left mandibular angle

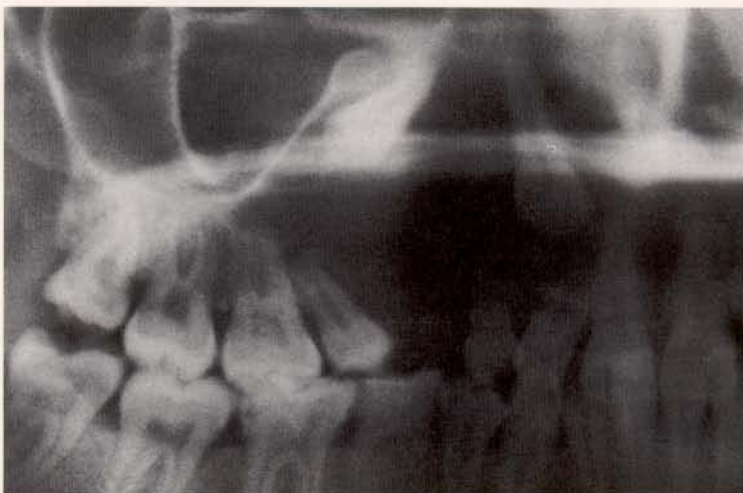
The picture shows very well the infiltrative growth that has dissolved the structures of the mandibular canal. Tooth 38 appears displaced and enclosed.

Courtesy Dr. R. Drommer, Göttingen



551 Recurrent odontogenic myxoma

The structural picture is reminiscent of a multilocular ameloblastoma with soap bubble-like appearance.

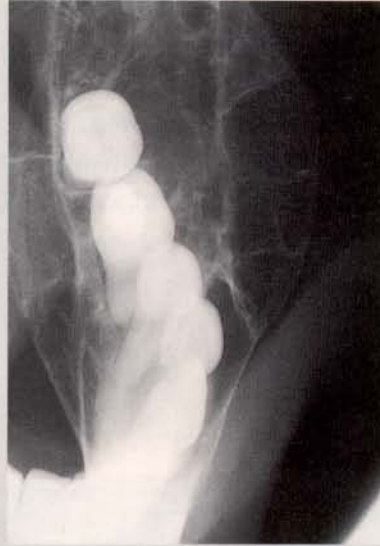

552 Odontogenic myxoma of the maxilla

Only the lack of the demarcation line typical for follicular cysts provides a vague hint about the nature of this radiolucency. It is impossible to distinguish it radiographically from a follicular cyst or an ameloblastoma.

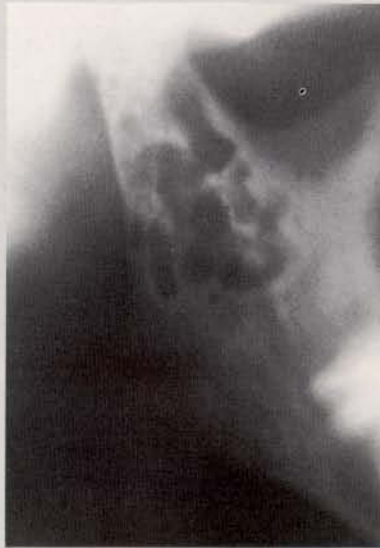553 Odontogenic myxoma of the mandible, viewed in an occlusal film

The radiographic differential diagnosis between myxoma and ameloblastoma localized in the mandibular molar area can possibly be clarified through use of a low energy, lateral occlusal projection. As seen in the figure, this projection is superior to other methods for showing the later stages of the odontogenic myxoma with its typical structure, and including distention, cortical thinning and wispy trabecular pattern.



554 Myxoma in the articular process

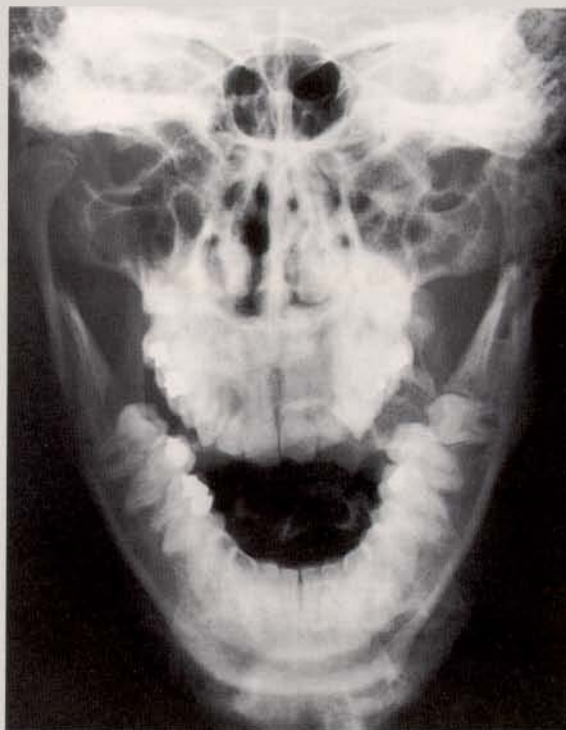Lateral tomography of the ascending ramus exhibits the compartmentalized structure of this non-odontogenic myxoma. This type of myxoma, which also occurs in other parts of the skeleton, tends to behave less aggressively than the odontogenic myxoma, and recurrence is rare.



555 Identical case as seen in a reverse Towne projection

This film depicts the ascending ramus in a frontal plane, and reveals the expanse of the tumor in the third dimension, which is lacking when this lesion is viewed in a typical panoramic radiograph.

Courtesy Dr. R. Drommer,
Göttingen

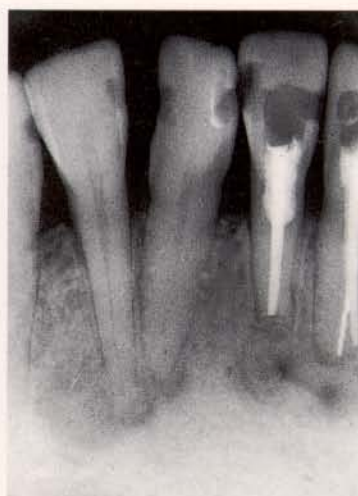
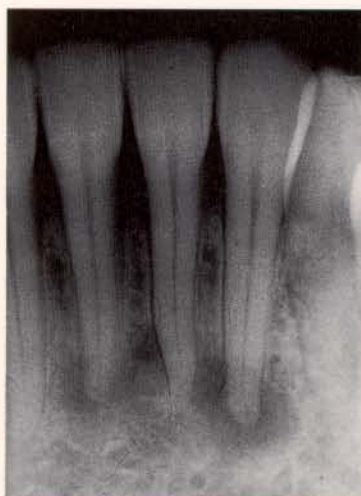
Cementoma

Periapical Cemental Dysplasia

This type of cementoma affects the mandibular anterior teeth in females usually in middle age. An initial "fibrous" stage may be confused with a granuloma (vitality testing!). The initial stage is followed by stages with accumulation of material having the density of cal-

cified tissue. Multiple manifestations in the mandible may sometimes be combined with solitary lesions in the maxilla; cementoblastoma of the premolar and molar regions of the mandible may also occur concomitantly.

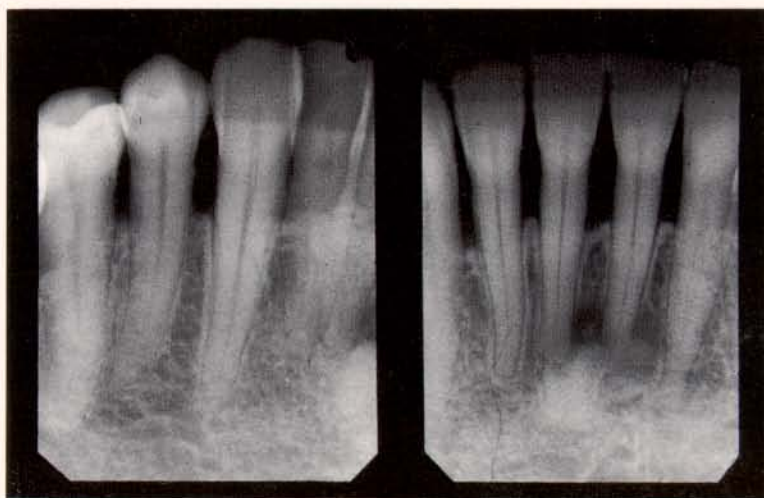

556 Periapical cemental dysplasia

This periapical radiograph depicts an early "fibrous" stage. It is imperative to test the vitality of the apparently affected teeth.

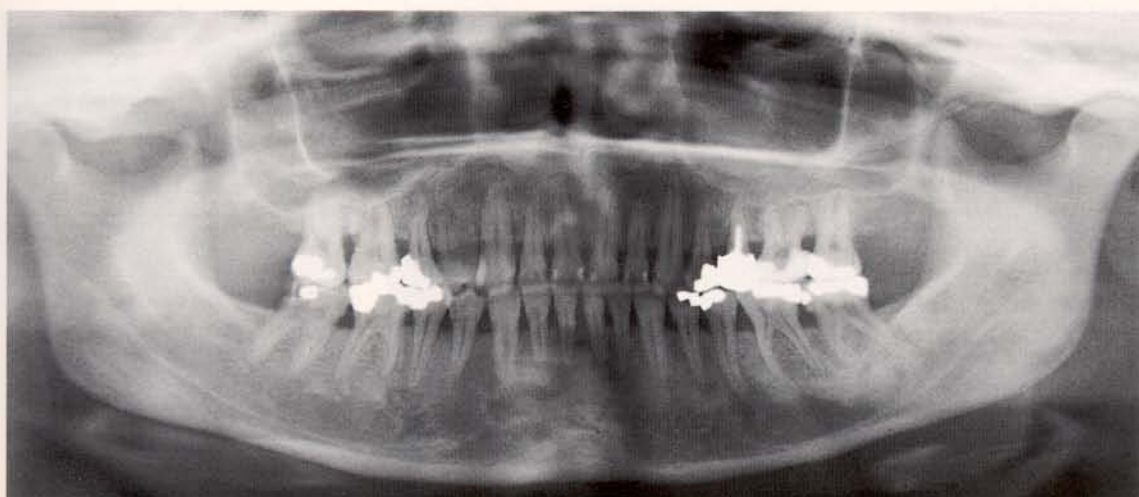
557 Periapical cemental dysplasia

Typical results of an incorrect radiographic interpretation (note root canal treatment on teeth 31 and 32). Teeth 42 and 41 exhibit the second stage described as deposition of material with the density of calcified tissue.



558 Periapical cemental dysplasia

Second and third stages of cementum deposition in two films from the same patient. The affected teeth remained vital during the 4- to 6-year development from the incipient stage.



559 Periapical cemental dysplasia

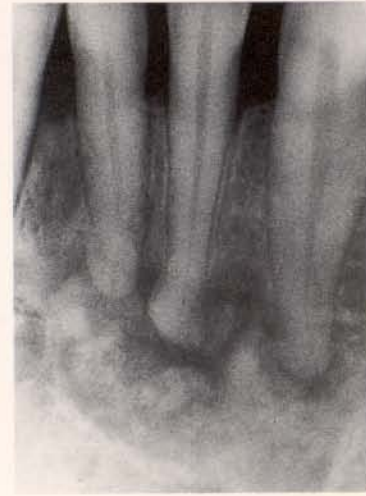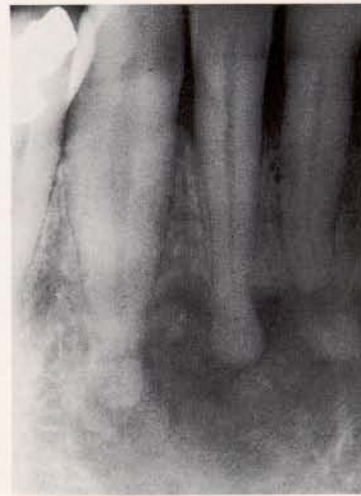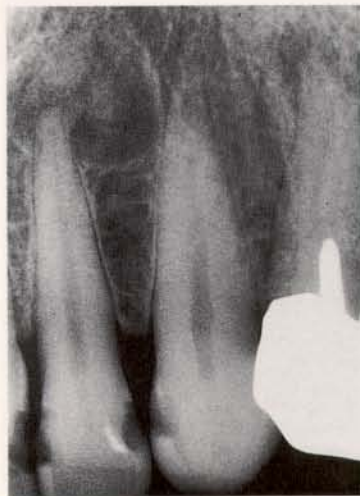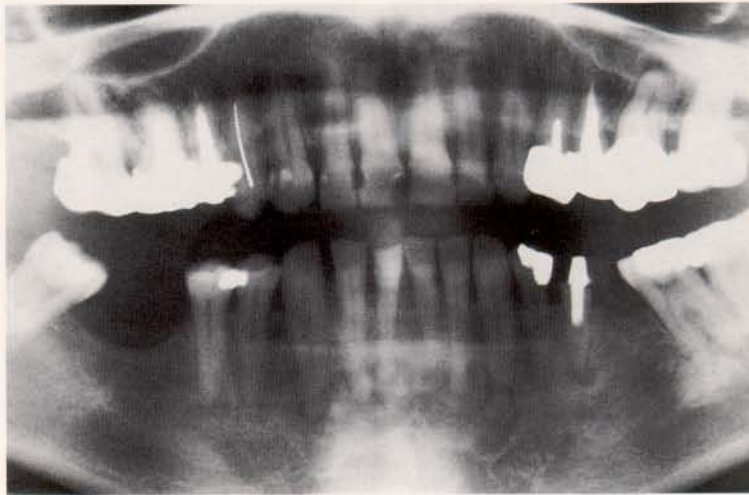Multiple lesions in a 45-year-old female in the mandibular anterior area and in the premolar and molar regions of the mandible. All mandibular teeth reacted positively to the CO₂ vitality test.

In some cases the maxillary anterior teeth may also exhibit radiographic signs of lesion formation besides the classic site in the mandibular anterior segment. It must be kept in mind, however, that osteoblastoma of the maxillary anterior region not infrequently leads to a

similar form, and that the radiologist often makes clinical decisions only on the basis of radiographic characteristics of the root contact. Because the teeth in both cases remain vital, therapy need be instituted in most cases only when clinical manifestations occur.

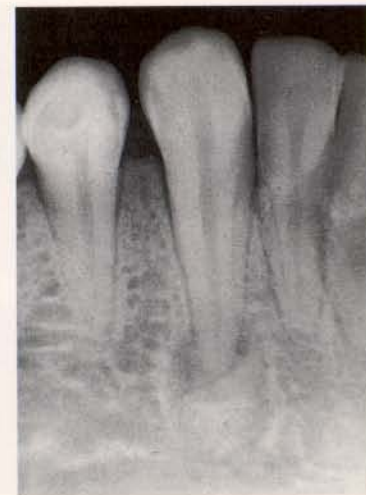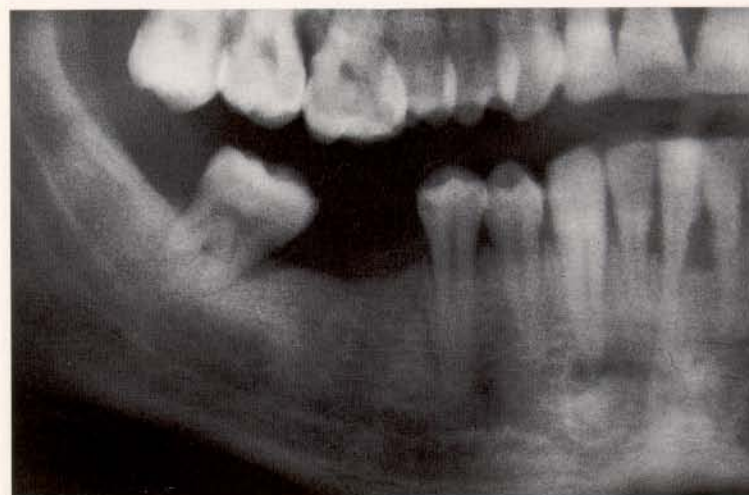560 Periapical cemental dysplasia in a 50-year-old female

The panoramic radiograph and the three following periapical films exhibit the second stage of cementum formation on teeth 33-43 and on teeth 21 and 22. In the mandibular anterior segment, the lesions appear to coalesce and the root tips of the affected teeth exhibit typical root contact with material having the density of calcified tissue.



561 Periapical cemental dysplasia

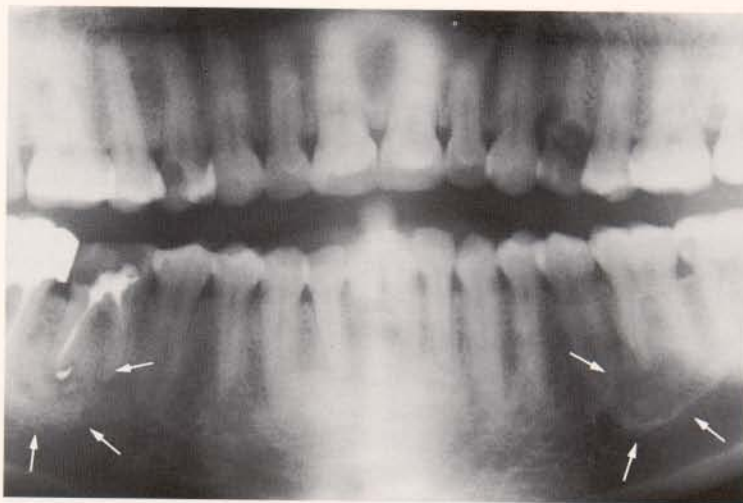
The panoramic radiograph and the periapical film depict the solitary involvement of tooth 43 with signs of complete shadowing in the third stage, as well as the formation of a radiolucent border.



Cementoblastoma

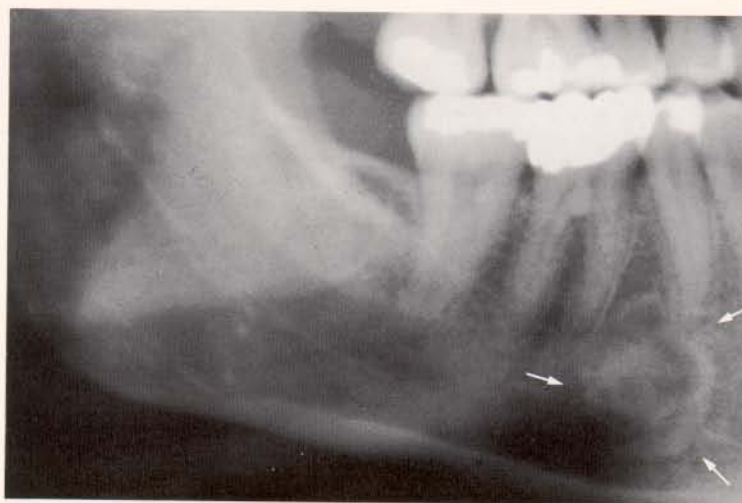This tumor, which is particularly common in young females of non-Caucasian races, preferentially affects the premolar and molar segments of the mandible. It may occur as a solitary lesion or in multiple forms. Radiographically it often depicts only a weakly visible

uniform opacity which, in comparison to the surrounding areas, appears as a radiolucency. It may be difficult to distinguish this lesion from an ossifying fibroma.



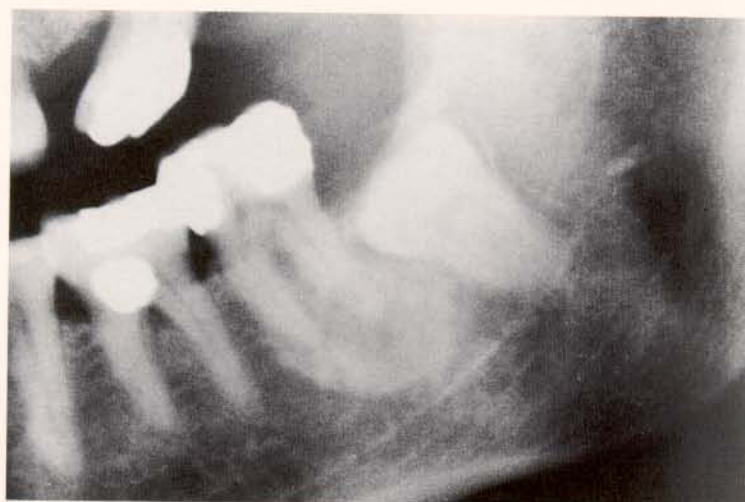562 Cementoblastoma around the root tips of the first permanent molars in the mandible

A slight, uniform opacity is visible (arrows), with opaque borders near tooth 36. The over-filled root canal of tooth 46 exhibits a reactive sclerosis of the surrounding bone.



563 Cementoblastoma

The moderately dense opacity created by this lesion, in contact with the lamina dura and the root of tooth 45 is surrounded by an opaque boundary (arrows).



564 Cementoblastoma

Tooth 37 exhibits a cementoblastoma that encompasses both roots. Following extraction of the tooth, such cementoblastomas remain in the jaw where they are frequently demarcated, resulting in sequestration.

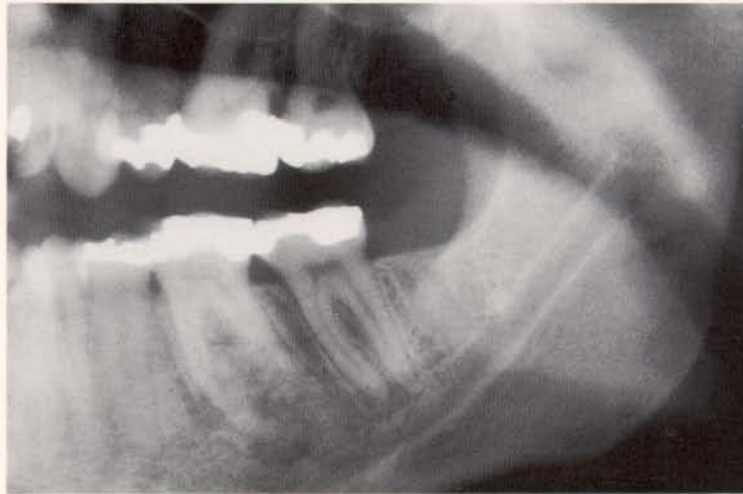
An additional form of the cementoblastoma usually occurs as a solitary lesion in the mandibular first molar area, and affects mostly young males. Early stages appear coarsely structured with radiolucencies due to connective tissue appearing as spots or strands.

In more mature stages, the lesions may achieve remarkable size and a high degree of radiopacity. The roots of the affected tooth may initially be overlaid with radiolucencies, giving the appearance of resorptions.

565 Cementoblastoma on tooth 36

This early stage is characterized by a spotty structure, deposition of material with cementum-like density, and a highly fibrous component.

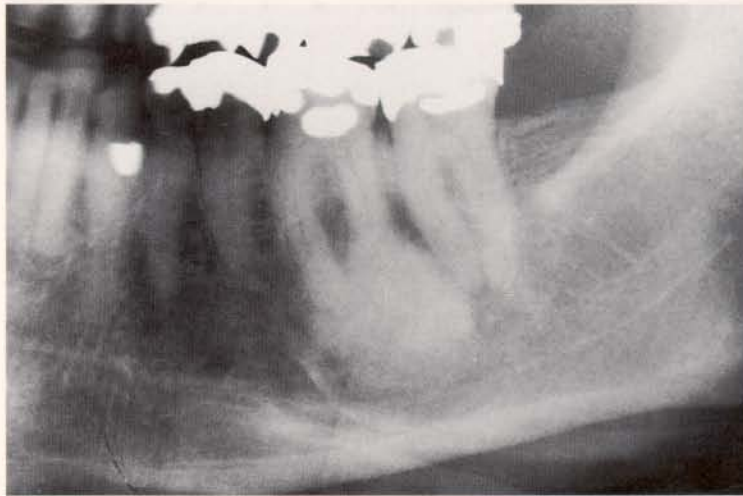Courtesy Dr. P. Zimmerli, Cernier



566 Cementoblastoma

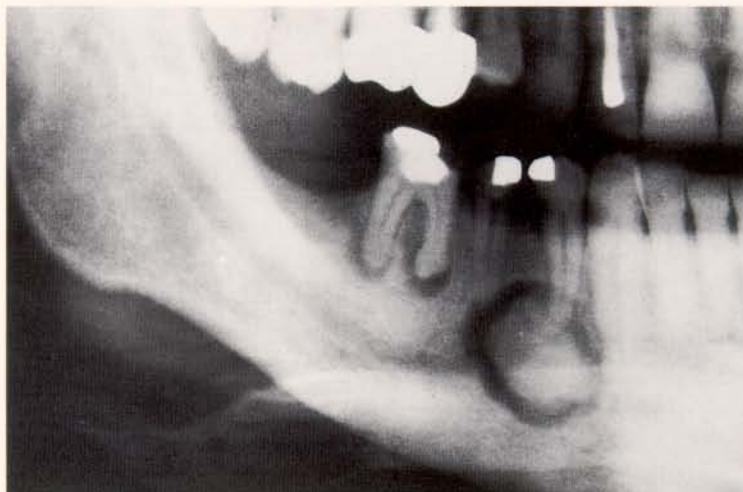The opaque structure of this fully developed lesion is surrounded by a wide radiolucent band and almost completely covers the root tips of tooth 36.

Courtesy Dr. K. Weibel, Baden



567 Cementoblastoma

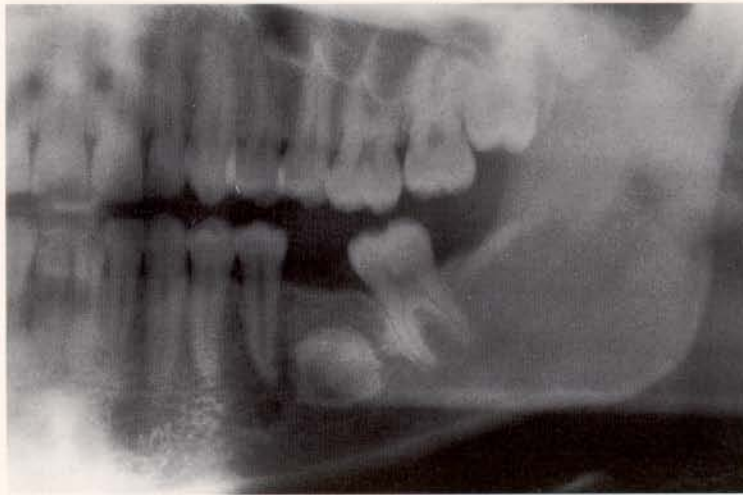The obvious demarcation of the cementoblastoma that developed around the root of tooth 44 is most likely the result of chronic, apical periodontitis on tooth 46. Note the primary chronic osteomyelitis in this section of the mandible, which was probably induced by the lesion.



Cementoblastoma, Cementum-forming Fibroma

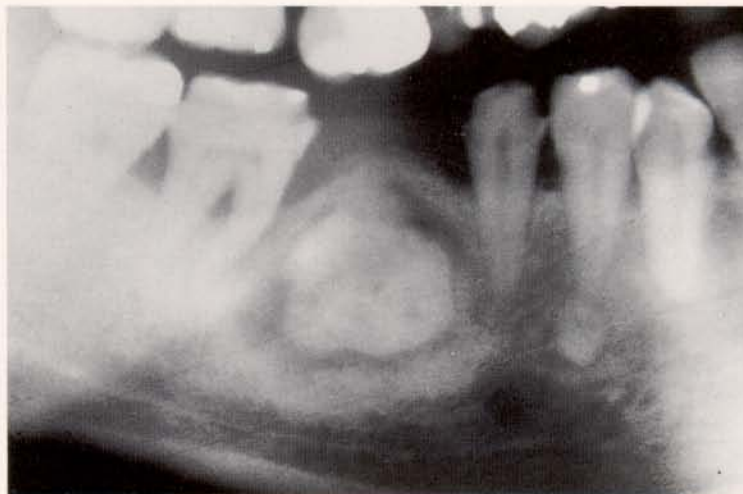Many of the cementoblastomas that are diagnosed persist for years without causing any clinical manifestations. Others, however, may show demarcation and sequestration as a result of inadequate vascularization, trauma, or because of inflammation in the surrounding

tissues. Even a pathologist may encounter difficulty differentiating between osteomyelitis, ossifying fibroma or cementoblastoma, depending on the site of the histologic section.



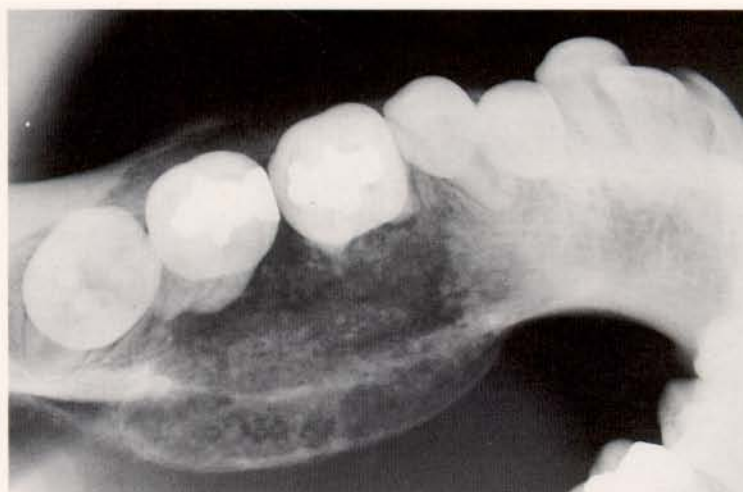568 Cementoblastoma

Following tooth extraction, cementoblastomas that are not removed, for example here in the region of tooth 36 in a 21-year-old female, may remain symptom-free or may sequester after inflammatory stimulation from apical or marginal periodontitis. The radiolucency around the root tips of tooth 35 and tooth 33 indicate that in this region more cementoblastomas exist in the stage of fibrosis.



569 Demarcated cementoblastoma

The expansive cementoblastoma in the extraction site of tooth 46 in a 40-year-old male is surrounded by radiographic signs of chronic inflammation and reactive sclerosis; this lesion is in the sequestration stage. The likely cause was chronic marginal periodontitis on tooth 47. Note the periapical cemental dysplasia on tooth 44.



570 Cementum-forming fibroma

This unilateral occlusal radiograph of the mandible, which was intentionally taken with an occlusal projection, exhibits the structural details of a cementum-forming fibroma in a 19-year-old male. The well-demarcated lesion allows one to easily discern distention and thinning of the cortical bone. Also visible is the deposition of cementum with a radiographic density that is similar to calcified tissue.

Odontoma

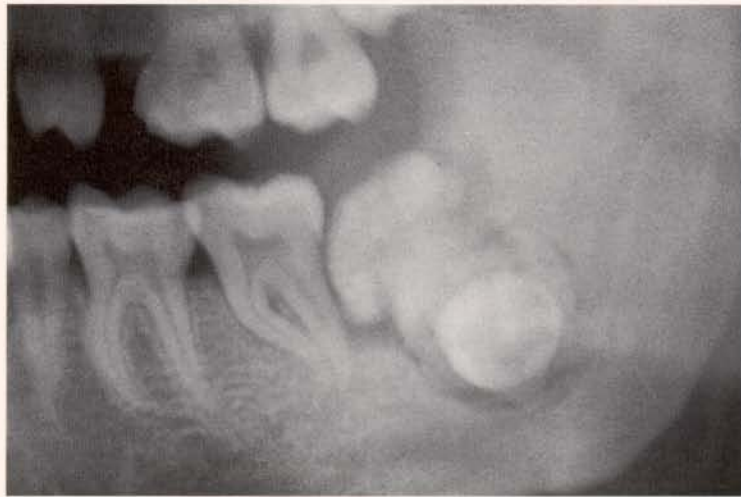Complex Odontoma

The amorphous form of this odontoma occurs most frequently in young males, usually in the area of the mandibular third molars (Fig. 574, violet) and has a tendency to erupt. These lesions are not particularly radiopaque and therefore must be visualized using

low-energy radiographic exposures. Primarily in females, a more highly differentiated and extremely radiopaque form of odontoma develops that exhibits irregular borders in the radiograph. It may be located in either maxilla or mandible (Fig. 574, light violet).

571 Complex odontoma

The low energy radiograph permits easy depiction of the layered masses of the odontoma. The lesion has displaced tooth 38, and is in the process of clinical eruption. In this 25-year-old male, the area surrounding the lesion exhibits reactive sclerosis due to chronic inflammatory irritation.

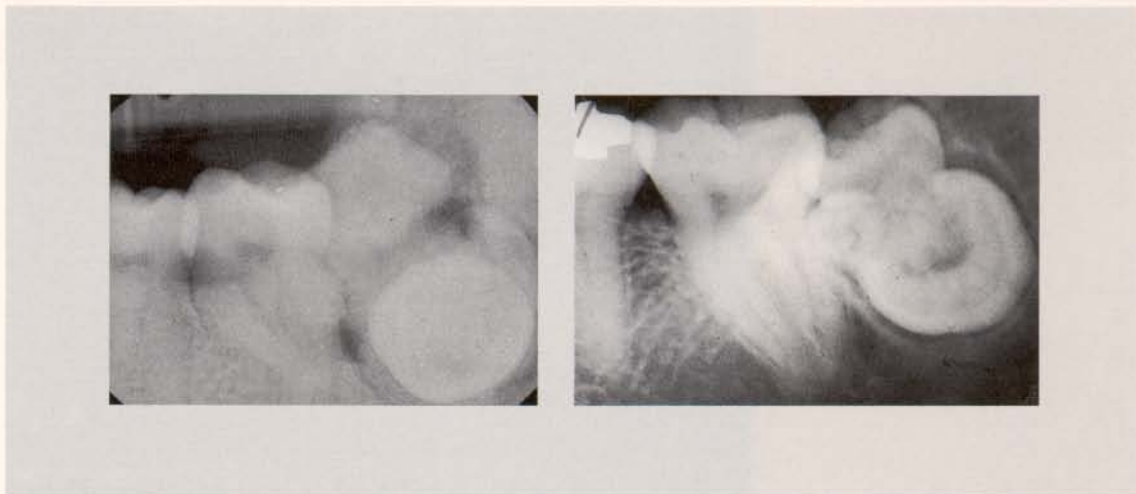


572 Complex odontoma

The periapical radiograph reveals an erupting complex odontoma in the same patient as above.

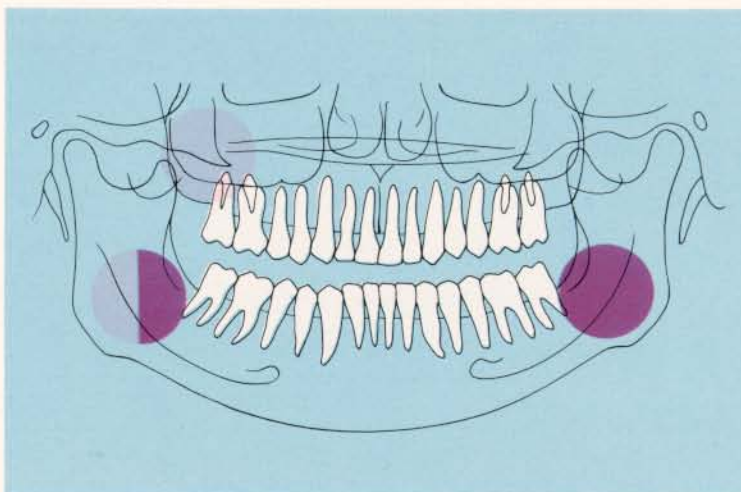
573 Intermediate type odontoma

For comparison, this periapical film exhibits a mixed odontoma.



574 Sites of odontomas

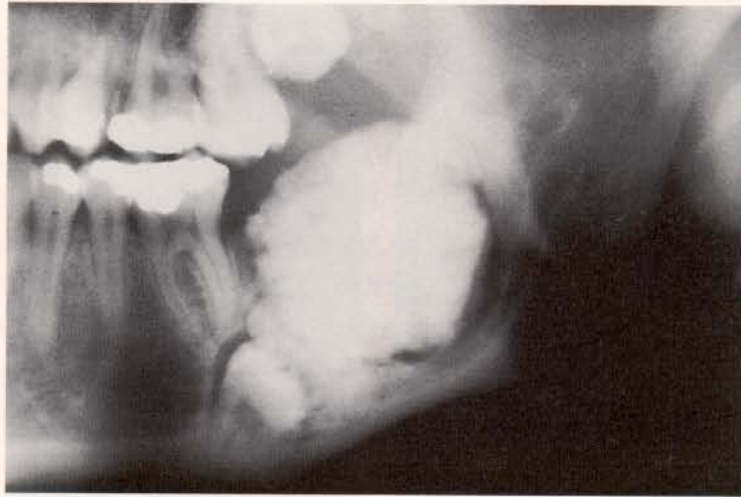The most frequent sites are shown for males (violet) and for females (pale violet).



Transition Forms

In males, the complex odontoma does not always achieve a clinically conspicuous size. In females, these lesions frequently attain a large spherical shape, and usually occur in the tuberosity region but also in the area of the mandibular third molars. In addition to radio-

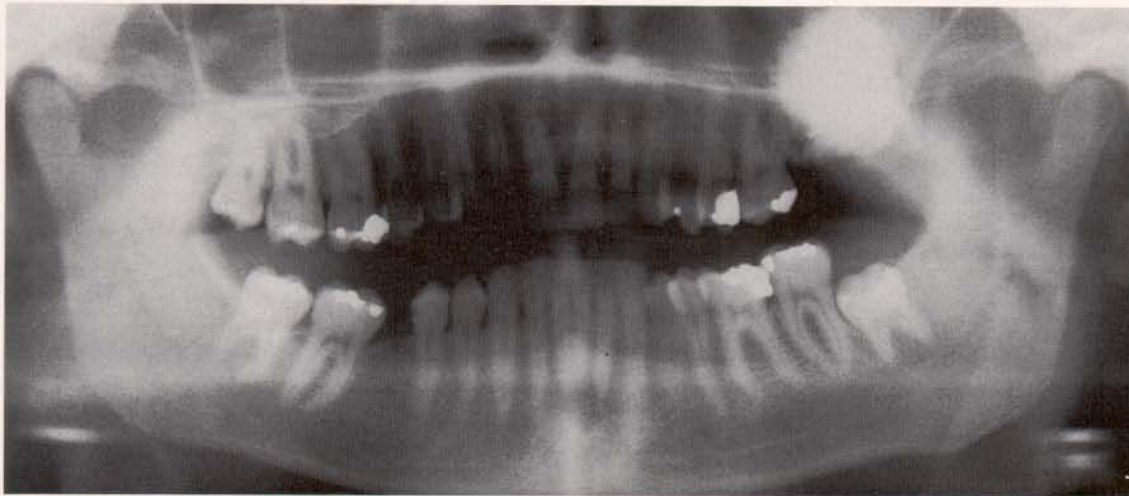
opacity, an irregular border is sometimes also visible. This border often consists of more completely differentiated dental elements that are combined in a composite manner.



575 Complex odontoma at the angle of the mandible

This odontoma is surrounded by a wide radiolucency and exhibits an irregular border, indicating that the lesion is in a transition stage. This is a 25-year-old female.

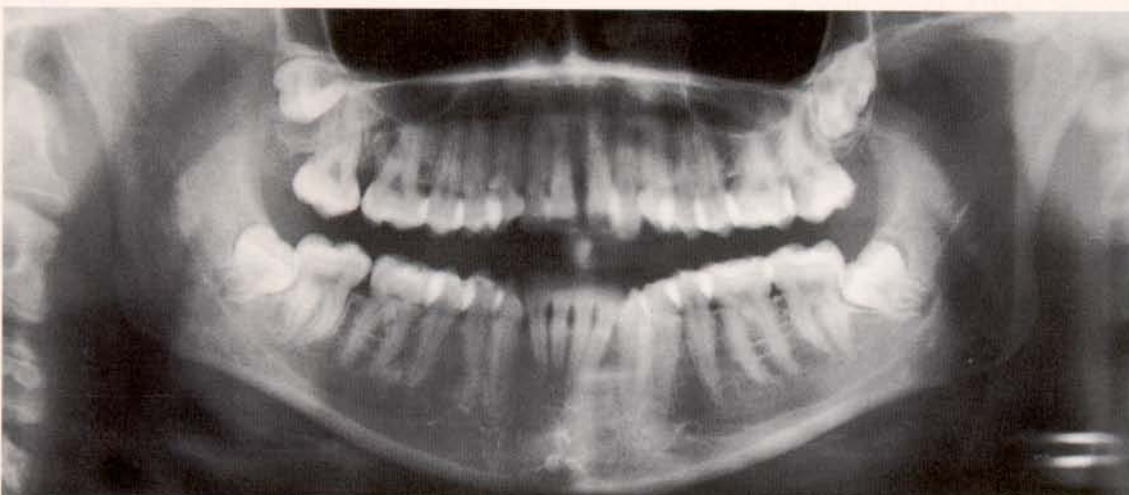
Courtesy Cantonal Hospital of Fribourg, Radiology Service



576 Complex odontoma in the maxillary tuberosity

The radiopacity, size, irregular border contour, site and sex of the patient all indicate that this is a transition stage between a complex and compound odontoma. Shown is a 21-year-old female.

Courtesy Dr. J.-P. Bernard, Geneva



577 Combined odontoma in the maxillary tuberosity

Radiographic picture suggesting a combined odontoma in this 19-year-old female; the clinical picture revealed a compound odontoma. Numerous variations of this tumor suggesting several supernumerary teeth may be seen with this localization.

Compound Odontoma and Fibro-odontoma

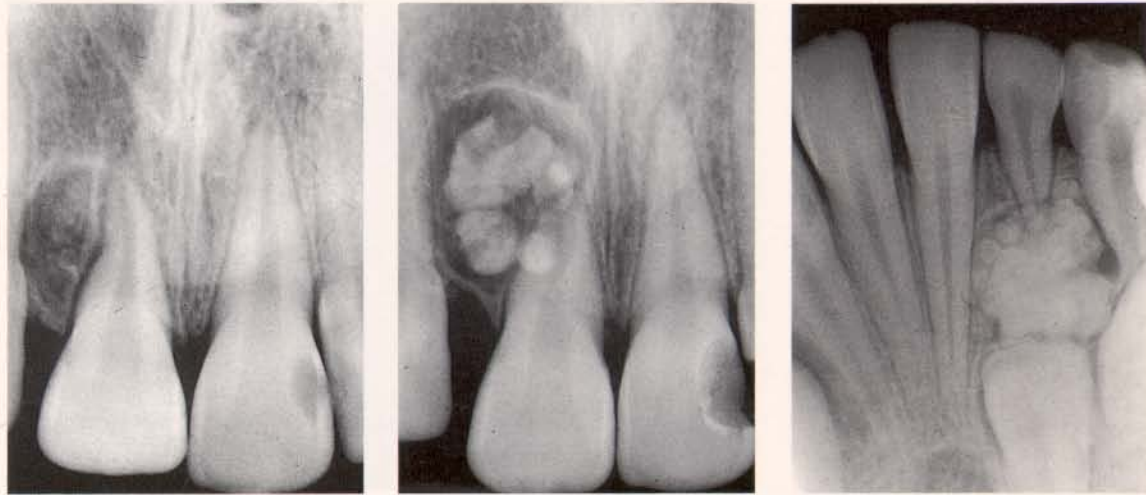
The typical compound odontoma is characterized by an accumulation of fully developed teeth of various sizes and number, surrounded by a radiolucent border. This form of odontoma usually occurs in the anterior region of both mandible and maxilla, and in the tuberosity

region. The odontoma may displace teeth, creating diastemata; it may also impede normal teeth from erupting. The rare ameloblastic fibro-odontoma represents a special type of odontoma.

578 Development of a compound odontoma

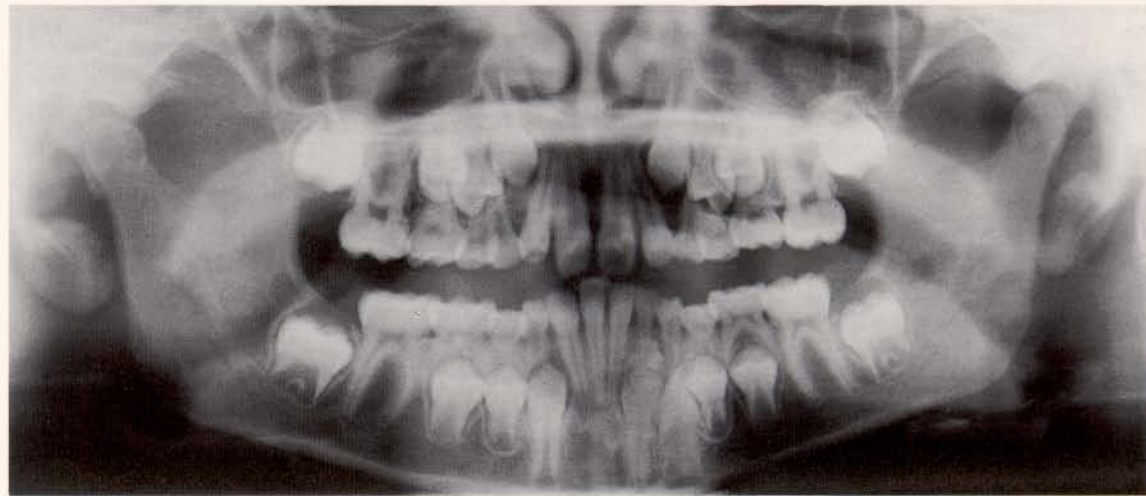The first film (left) was taken immediately after an accident, and reveals, in addition to signs of luxation of tooth 11, an almost completely transparent radiolucency. The latter developed into a combined odontoma over the course of the next 2½ years (center). Note the diastema between teeth 12 and 11.

Courtesy Dr. W. Böse, Worpswede



579 Compound odontoma between teeth 72 and 32

The periapical radiograph (above, right) was taken in addition to the panoramic film (Fig. 580) to reveal the characteristic compound odontoma.



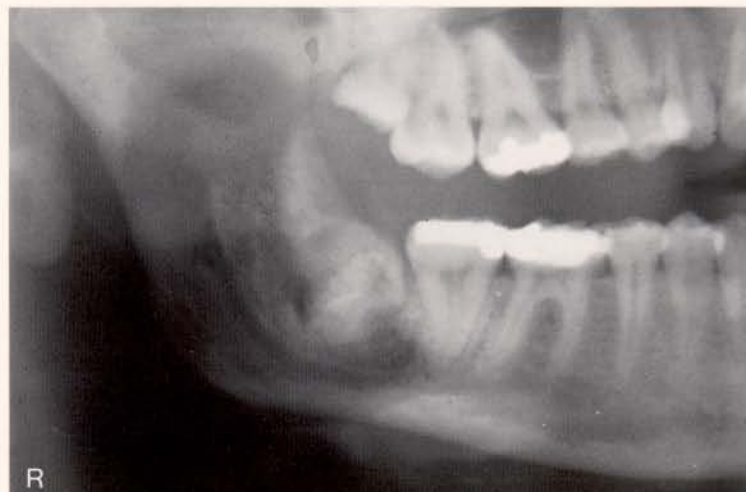580 Compound odontoma between teeth 72 and 32

The panoramic radiograph gives an overview of the situation.

581 Ameloblastic fibro-odontoma

In this 20-year-old female, the tumor appears as an amorphous radiopacity with vague dental structures. The borders are poorly demarcated.

Courtesy Dr. P. Ledermann, Herzogenbuchsee



Nonodontogenic Tumors and Pseudotumors

Benign Lesions

The title of this chapter is a simplified term chosen to describe a summary of the radiographic characteristics of the most often encountered benign and malignant tumors, granulomatous lesions and osteofibrous lesions of the jaws. As in the previous chapter, it must be clearly pointed out how important the experience of the person interpreting the radiograph is for the results of any radiographic examination because in most cases it is fundamentally impossible for the radiologist to provide a "histologic" diagnosis. The age and sex of the patient as well as the site of the lesion will provide important clues, as will the complete description of the clinical situation. Nevertheless, there will always be infrequent manifestations of rare diseases as well as misleading imitations of apparently clearly classifiable radiographic signs. Such radiographic signs may deceive even the experienced radiologist. For these reasons, we would warn against premature radiographic diagnoses.

Central reparative giant cell granuloma. This type of granuloma grows expansively within bone and occurs more frequently in females under the age of 25 than in males. It is characterized by an asymptomatic swelling of the affected jaw that is manifested by facial asymmetry.

Localization. The central reparative giant cell granuloma usually occurs in the mandible, and preferentially in the premolar region. It is less common (3:1) in the maxilla.

Examination technique:

- Panoramic radiography
- Reverse Towne projection with maximum jaw opening
- Lateral mandibular occlusal radiograph, with reduced exposure time
- Computed tomography in late stages and if tumor is sited in the maxilla

Radiographic signs. The isolated or multilocular radiolucencies are sharply demarcated and exhibit soap bubble-like structures with lobulated margin contours. In late stages, the cortical plate of bone may be distended and thinned. The differential diagnosis from ameloblastoma is difficult.

Differential diagnosis:

- Ameloblastoma
- Eosinophilic granuloma
- Odontogenic cyst
- Aneurysmatic and solitary bone cysts

Peripheral reparative giant cell granuloma. The lesion is most frequently found on the gingiva of younger females. Clinically the lesions may resemble normal gingiva or may exhibit brownish to bluish exuberances of firm or soft consistency. They usually exhibit limited expanse (up to 2 cm in diameter), and may erode the alveolar bone.

Localization. These lesions are more often found in the anterior region of the mandible than in the maxilla. A typical characteristic is the proliferation of the lesion along the periodontal ligament space.

Examination technique:

- Panoramic radiography
- Supplemental radiographs, including periapical films taken with reduced exposure time to display the cervical region of the tooth

Radiographic signs. Wedge-shaped expansion of the periodontal ligament space at the entrance to the alveolus; in later stages, localized bowl-like defect.

Differential diagnosis:

- Marginal periodontitis

Histiocytosis X. This term includes three different disease entities that are characterized histologically by the proliferation of histiocytes and by lipid storage. It is possible to differentiate a lethal form in small children (Letterer-Siwe disease), a chronic disseminated form that affects school children (Hand-Schüller-Christian disease), and a relatively moderate localized form known as *eosinophilic granuloma* that is observed in adolescents but also in older patients. The latter disease often leads to tooth mobility and bone destruction, especially in the mandible. Extraction wounds heal particularly poorly.

Localization. In addition to lesions in the skull that appear as punched out areas, in the dental area lesions are observed primarily in the mandible.

Examination technique:

- Panoramic radiography
- Supplemental periapical radiographs

Radiographic signs. The pseudoperiodontal form begins with sharply demarcated radiolucencies in the depth of the interradicular septa. The structural damage, which usually occurs in the molar segment of the mandible leads to loss of the lamina dura, and progresses to confluent areas of osteolysis that often exhibit arcuate demarcations. In the final stages, the typical picture of the tooth “suspended within the radiolucency” may be observed.

Differential diagnosis:

- Marginal periodontitis
- Central reparative giant cell granuloma
- Cherubism

Chondroma. This benign, cartilage-forming tumor occurs relatively frequently in the skeleton but only seldom in the jaws or the temporomandibular joint. All age groups of both sexes are equally affected. However, the chondroma, the chondroblastoma and the osteochondroma appear to predominate especially in the temporomandibular joint region of adolescent patients.

Localization. Most often affected are the anterior segments of the maxilla, the premolar region of the mandible (including mandibular tori) and the region of the condylar joint surface.

Examination technique:

- Panoramic radiography
- Lateral cephalometric radiograph

- In the maxilla, lateral and frontal spiral tomography
- CT if the lesions are expansive (density measurements)

Radiographic signs. Sharply demarcated radiolucencies at the condyle; in the jaw, often pinhead-sized calcification centers within sharply demarcated radiolucencies. The cortical bone may be perforated in late stages.

Differential diagnosis:

- Osteochondroma
- Primary bone tumors

Osteochondroma. This is usually a benign bone tumor. Some authors classify it under cartilaginous exostoses. Because it exhibits segments with pronounced trabeculation, however, it may appear radiographically as a trabecular osteoma. Growth of the lesions usually ceases in puberty. Continuously growing forms in older patients are suspected to undergo malignant transformation in certain sites (e.g., maxilla).

Localization. At the temporomandibular joint at the beginning of the second decade of life, near the condylar joint surface; less frequently in the region of the median suture and in the premolar region of the mandible.

Examination technique:

- Panoramic radiography in normal jaw position (depicting the condyles)
- Lateral cephalometric radiography of the maxilla
- Maxillary occlusal radiograph
- In the maxilla, lateral and frontal spiral tomography
- CT

Radiographic signs. Circumscribed, well-demarcated radiolucency with or without areas of radiopacity (sometimes predominant). If localization is in the maxilla, the panoramic radiograph will show overt thickening and higher density in the region of the anterior nasal spine.

Differential diagnosis:

- If lesions are small, degenerative arthritis of the head of the condyle
- Palatal torus
- Trabecular osteoma

Nonodontogenic (desmoplastic) fibroma. This is a benign, usually well-encapsulated connective tissue tumor of the skeleton with no signs of calcification. It occurs less often in the jawbones of younger patients of both sexes. It may also be observed in elderly adults.

Localization. The molar region of the mandible is more frequently involved than the maxilla.

Examination technique:

- Panoramic radiography
- Reverse Towne projection with maximum jaw opening
- Lateral spiral tomography
- In the maxilla, CT

Radiographic signs. Unilocular, sometimes multilocular, sharply demarcated and not particularly transparent (exposure data!) radiolucencies without calcification. In late stages, the cortical bone may be distended and thinned, sometimes perforated. Root resorptions may be observed.

Differential diagnosis:

- Central reparative giant cell granuloma
- Keratocyst
- Residual cysts in edentulous patients

Ossifying fibroma. Children and adolescents under the age of 15 may be affected by the juvenile ossifying fibroma. As one of the most common tumors of the jaw, the lesion is also observed in adults of all ages, especially in the third and fourth decades of life. The lesions are seen most frequently in females and present as well-demarcated areas with varying degrees of calcification and ossification.

Localization. The juvenile ossifying fibroma has a clear preference for the maxilla. The ossifying fibroma in adults is more often observed in the mandible.

Examination technique:

- Panoramic radiography
- In the maxilla, CT

Radiographic signs. The juvenile form is well demarcated and may displace the structures of the maxilla and the sinuses as a result of its growth. An ossifying fibroma should therefore always be suspected if the radiographs depict milk glass-like areas, calcifications, and ossifications.

Differential diagnosis:

- Fibrous dysplasia (lacks demarcation)
- Late stage osteoblastoma
- Osteoma

Fibrous dysplasia. This condition is characterized by early pain and swelling of the bone, with connective tissue replacement of the spongiosa, fibrosis of the bone marrow and fibrous bone formation of varying degree.

This disease usually affects children and adolescents between 5 and 15 years old. It may occur either monostotic or polyostotic and therefore presents an extremely diverse radiographic picture. One extremely rare form is so-called cherubism.

Localization. In addition to ribs, femur and tibia, the skull and particularly the maxilla, the mandible or both jaws may be affected. The osseous sutures in the maxilla limit the growth of the lesion.

Examination technique:

- Panoramic radiography
- Occlusal radiographs for structural analysis
- CT

Radiographic signs. Lesions originate with oval radiolucencies and structural disturbances in the maxilla, leading soon to a milk glass-like and orange peel-like spotty shadowing of the bone, with thinning and distention of the cortical plate. In the mandible, the usual presentation includes uniform shadowing with multiple cyst-like radiolucencies. After replacement by fibrous bone, extremely opaque or abnormally structured areas dominate. When distention and thinning of the compact bone of the mandible occurs, the demarcation of these lesions is usually unclear.

Differential diagnosis:

- Recurrent chronic osteomyelitis
 - Ossifying fibroma
 - Osteoma
 - Paget's disease of bone
- (to name only a few of the numerous possibilities)

Osteoid osteoma and Osteoblastoma. These are benign tumors of the ground substance of bone; they are relatively rare, usually occurring in females under 25 years old (osteoid osteoma) or in adults over the age of 40 as a fully matured osteoblastoma. Early lesions are virtually impossible to detect radiographically because of addition effects; on the other hand, clinically the patient may complain of diffuse or localized pain (depending upon site).

1. Osteoid osteoma

Localization. These lesions occur more frequently in the body of the mandible than in the maxilla.

Examination technique:

- Panoramic radiography
- Spiral tomography

Radiographic signs. Within the “nidus,” the ovoid and not always sharply demarcated radiolucency, one observes an unstructured opacity of calcified tissue-like density, up to 1 cm in expanse. A strong reactive sclerosis is sometimes observed in the surrounding area.

Differential diagnosis:

- Cementoma
- Osteoma

2. Osteoblastoma

Localization. This tumor occurs in both maxilla and mandible in adults of all ages.

Examination technique:

- Panoramic radiography
- CT, especially in the maxilla for demarcation

Radiographic signs. Initially diffuse, poorly demarcated radiolucency. Later stages are almost always larger than 2 cm, with increasing density, and sharp demarcation and a radiolucent border. The neighboring teeth may be displaced and root resorptions may be in evidence.

Differential diagnosis:

- Cementoblastoma
- Complex odontoma
- Ossifying fibroma

Osteoma. As a pathologic entity, this lesion is difficult to differentiate radiographically from other lesions with pronounced ossification. Exostoses, osteosclerosis and similar alterations will therefore be discussed in connection with osteoma. Osteochondroma or certain forms of fibrous dysplasia may also be components of a differential diagnosis that are difficult to rule out radiographically. The osteoma can occur in all age groups, but has a preference for elderly adults. Clinically these lesions are associated only secondarily with manifestations due to displacement of surrounding tissues.

Localization. Peripheral osteoma may occur as a solitary form in the frontal sinus, the maxillary sinus and on compact bone particularly in the mandible. Central osteoma may occur in the jaws as solitary or multiple lesions, for example in Gardner’s syndrome, or as Paget’s disease of bone.

Examination technique:

- Panoramic radiography
- Lateral or frontal spiral tomography
- CT in the maxilla and to demarcate the borders of larger lesions

Radiographic signs. For the normally well demarcated and extremely opaque lesions, the term compact osteoma is often applied. Especially in the mandible, trabecular forms residing on compact bone have been described.

Differential diagnosis:

- Enostosis
- Cementoma
- Complex odontoma
- Axially projected impacted tooth or root fragment
- Fibrous dysplasia
- Osteochondroma
- Ossifying fibroma
- Gardner’s syndrome
- Paget’s disease of bone

Exostosis and Enostosis. Depending upon its localization and shape, an exostosis is also termed osteoma, hyperplasia or torus. Enostoses may be observed radiographically as “compact islands” of unknown or inflammatory origin; such lesions may also be incorrectly diagnosed due to the addition effect. When examining a panoramic radiograph, one should always consider that *all* radiopacities even though they lie outside the jawbone will be projected in the radiograph. Typical in this regard is the possible existence of sialoliths, phleboliths or calcified lymph nodes. The occlusal radiograph can be of assistance in arriving at the proper diagnosis.

Hyperostoses and Hypertrophies. Rarely, hyperostoses and hypertrophies may be observed in the jaws. Their etiology is for the most part unknown.

Osteoporosis. Characteristically the picture of osteoporosis is increased transparency resulting from reduction of bone density. This can be readily diagnosed in a panoramic radiograph (not overexposed) primarily in the mandible. On the other hand, the radiograph of the jaw provides a superficial hint only in extreme cases and can therefore not replace mandatory supplemental radiographic examination and laboratory findings.

Atrophy of aging. This usually occurs in combination with senile osteoporosis, and generally affects females about five years earlier than males. Endocrine, metabolic, and functional etiologies have been described. The residual, reduced bone mass of the mandible is at risk for fracture.

Bone marrow islands and addition effects of all kinds may occur particularly in panoramic radiographs, but also in periapical radiographs, and these carry the risk of incorrect interpretations.

Osteogenesis imperfecta and Osteopetrosis. Osteogenesis imperfecta and osteopetrosis (also known as marble bone disease) result from disturbance of osteoblast function or from osteoclast insufficiency.

Osteogenesis imperfecta is frequently associated with a disturbance of osteoblast function and exhibits either a very early (*congenita*) or late (*tarda*) tendency toward spontaneous skeletal fractures. Since children with this condition die either before birth or in the first few months of life, the dentist may see only mild forms. The damaged jawbone can often respond to a dentogenic infection with a progressive form of osteomyelitis where the clinical course resembles that of osteoradionecrosis.

Osteopetrosis, also known as marble bone disease or Albers-Schönberg disease, and which is inherited as an autosomal recessive trait, exhibits on the other hand a structureless bone opacity with obliteration of the marrow spaces and delayed dental eruption. If affected children are born alive, they usually die within the first few months of life.

Osteitis deformans. Osteitis deformans, also called osteodystrophy deformans or Paget's disease of bone, is a rare bone disease of unknown etiology, which affects primarily males in the sixth or seventh decade of life. These monostotic or polyostotic lesions affect primarily the cranium, the petrous portion of the temporal bones and the zygoma, but also the jaws, especially the maxilla. In addition to hypercementosis, three developmental stages can be discerned, which are characterized by diffuse radiolucencies with spotty round opacities and confluent, cotton-wool condensation in the apical areas. The affected jaw may increase abnormally in size and dentogenic infection may induce a rapidly expanding osteomyelitis.

Localization. More frequently on the cranium, the petrous portion of the temporal bone and in the zygoma region; less frequently in the jaws. Sometimes the maxilla alone is affected: "macrocranium"; "leontiasis ossea."

Examination technique:

- Panoramic radiography
- Supplemental periapical radiographs
- Lateral cephalometric radiographs (cannot provide a complete overview)
- Posteroanterior skull projection (cephalometric view cannot provide a complete overview)
- CT

Radiographic signs. Hypercementosis on the teeth, milk glass-like cloudiness, diffuse radiolucency in the apical areas. The lamina dura is no longer visible. Cotton-wool opacities, which may become confluent in later stages. Disproportionate increase in opacity and size of the affected bone with disturbed intermaxillary relations in centric occlusion.

Differential diagnosis:

- Recurrent chronic osteomyelitis
- Multiple cementoma
- Periapical cemental dysplasia
- Osteosclerosis

Hemangioma. The hemangioma is a blood vessel tumor that is associated with considerable diagnostic difficulties radiographically in its intraosseous form. The lesion is rare and is most often diagnosed only in adults. Females are preferentially affected. The appearance of these lesions in the jaw bones is extremely variable, and can mimic many other pathologic alterations.

Localization. More common in the mandible than in the maxilla.

Examination technique:

- Panoramic radiography
- CT with a contrasting substance (medical history)

Radiographic signs. The lesions may vary in appearance from a vaguely demarcated osteolysis to a "soap bubble-like" or "radiating" lesion. Small lesions exhibit similarity to the honeycomb form of ameloblastoma, while large lesions may display distention and thinning of the cortical plate, which is, however, not perforated. Hemangioma that persist for long periods of time may exhibit phleboliths.

Differential diagnosis:

- Central giant cell granuloma
- Ameloblastoma
- Aneurysmal or solitary bone cyst
- Chondromatosis

Malignant Lesions

Sarcoma. Depending upon their histology, a sarcoma may be classified as osteoblastic, fibroblastic, chondroblastic or some other form. The tumor cells of the extremely malignant *osteogenic sarcoma*, for example, produce osseous ground substance that can only be radiographically detected once it is calcified. On the other hand, it is not uncommon that, in addition to calcification (sclerosis), cartilage or connective tissue depositions contribute to the radiographic picture of the relatively common mixed form with osteolysis. The most common malignant tumor of the jaw occurs in men in the third and fourth decades of life, with a peak in the second decade. The sarcoma metastasizes via the blood system. It appears that in late adolescence the sarcoma may occur following trauma such as fracture or tooth extraction. Clinical cardinal symptoms include tooth mobility, hemorrhage from poorly healing wounds, soft tissue swelling and paresthesia.

Localization. Most often in the premolar and molar regions of the mandible; less frequently in other regions of the jaws.

Examination technique:

- Panoramic radiography
- Targeted periapical films, and tomography
- CT for radiographic demarcation of the tumor; this technique can *never* depict the expanse within bone marrow

Radiographic signs. In early stages, widening of the periodontal ligament space may be observed. Central forms exhibit relatively early the destruction of normal anatomic structures (e.g., mandibular canal), poorly demarcated boundaries, spotty sclerosis, and osteolysis. The lesions perforate the compact bone and are accompanied by new bone formation including spicules (“sunbeam effect”), which are only visible on low energy radiographs.

Differential diagnosis:

- Other primary bone tumors
- Osteomyelitis (clinical diagnosis!)
- Noninfected odontogenic tumors and cysts with vague boundaries

Ewing sarcoma. An extraordinarily malignant, though rare, tumor is the myelogenic Ewing sarcoma of the jaw in children. In contrast to other malignant tumors, the Ewing sarcoma is often accompanied by severe general symptoms such as pain, soft tissue swelling, high fever, elevated blood cell sedimentation rate, and leuco-

cytosis. The lesion is most often observed in the first through third decades of life, with a peak in the second decade, and occurs more frequently in males.

Localization. Primarily in the mandible.

Examination technique:

- Panoramic radiography
- CT (if technically possible)

Radiographic signs. Moth-eaten appearance of bone destruction with millimeter-size osteolysis and irregular contours. Periosteal reaction such as spicules and onion skin-like periosteal calcification provide typical signs, in addition to intraosseous spread.

Differential diagnosis:

- Acute forms of osteomyelitis
- Osteogenic sarcoma

Carcinoma of the oral mucosa. In addition to the extremely rare primary intraosseous epithelial cell carcinoma of the jaw, which may derive from remnants of the odontogenic epithelium, the radiographic depiction of bony infiltration of the oral mucosa by carcinoma is of significance for the planning of appropriate therapy. This is true even though it is well known that the infiltration of, for example, the lingual portion of the alveolar process can be ascertained radiographically only in later stages.

Localization. Carcinoma of the oral mucosa can infiltrate not only into the hard palate but also into the alveolar process of the maxilla and the mandible.

Examination technique:

- Panoramic radiography. Alterations in the third dimension cannot be visualized in the early stages!
- Supplemental radiographs using periapical films (if the alveolar crest itself is eroded)
- Occlusal radiographs
- CT

Radiographic signs. Undermining destruction without sharp borders, which often leaves bony segments intact. The radiolucency may appear to contain “suspended” yet not displaced teeth.

Differential diagnosis:

- From the clinical point of view, none

Mucoepidermoid tumor. The relatively benign mucoepidermoid tumor may also exhibit invasive and infiltrative growth into the jaw bones, and exhibit not only the radiographic signs of a benign tumor but also those of malignant expansion. Extending from a saliva gland tumor of the parotid, the palatal glands, the submandibular or the ducts of the floor of the mouth, this tumor may invade the maxilla or the mandible. The mucoepidermoid tumor is more often observed in females than in males and preferentially in the third and fourth decades. This tumor, which is radiographically extremely variable, may simulate odontogenic cysts or mesenchymal tumors; malignant forms can metastasize.

Based on these facts, it must be recognized that the radiograph cannot provide a histopathologic diagnosis.

Localization. More frequent in the mandible than in the maxilla.

Examination technique:

- Panoramic radiography
- CT with measurement of density

Radiographic signs. Soap bubble-like, arcuate border with multicystic radiolucencies may be observed in addition to the bone destruction.

Differential diagnosis:

- Odontogenic cysts and tumors
- Benign and malignant mesenchymal tumors

Metastasis. A metastasis is the satellite of a primary tumor which, despite a different anatomic localization exhibits histologic features identical to the primary tumor. If metastasis occurs via the blood system, the mandible is the preferential location with a ratio of 4:1 over the maxilla. This is because the angle of the mandible and the ascending ramus contain red marrow that becomes affected. In males, metastasis occurs most often from lung carcinoma and prostate carcinoma, while females exhibit jaw metastasis mainly from mammary carcinoma. Because they grow slowly and rarely cause clinical symptoms, such metastases were often discovered only after spontaneous jaw fracture before the era of panoramic radiography. Mild discomfort and paresthesia may, however, be initial symptoms.

Localization. The mandible dominates in comparison to the maxilla.

Examination technique:

- Panoramic radiography
- Scintigraphy (in approximately 5% of cases, false positive)
- CT in unclear cases, especially in the maxilla

Radiographic signs. Usually vaguely demarcated osteolysis, sometimes with osteoblastic areas (mammary carcinoma) or sclerosis (prostate carcinoma). Moth-eaten appearance with millimeter size radiolucencies are sometimes also observed. The differential diagnosis is rendered difficult when lesions occur in the bone marrow islands of the mandibular premolar region.

Differential diagnosis:

- Bone marrow island
- Primary bone tumor
- Osteomyelitis

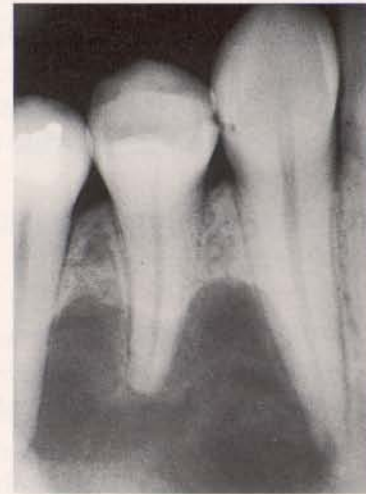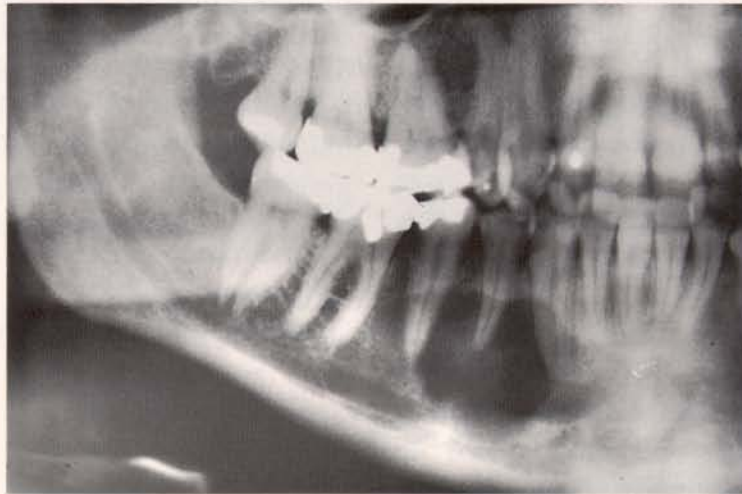
Central Reparative Giant Cell Granuloma

The central giant cell granuloma is most often observed in young females, usually in the mandible with a predilection for localization in the premolar region and sometimes also in the mandibular anterior area. Radiographically, the lesion exhibits a sharply demarcated, soap bubble-like radiolucency with thinning of the compact

bone in advanced cases. For this reason it is hardly possible to differentiate it from the ameloblastoma, although the latter is more common in the molar regions and at the angle of the mandible. The lesion may also be mistaken for a solitary bone cyst.

583 Central giant cell granuloma

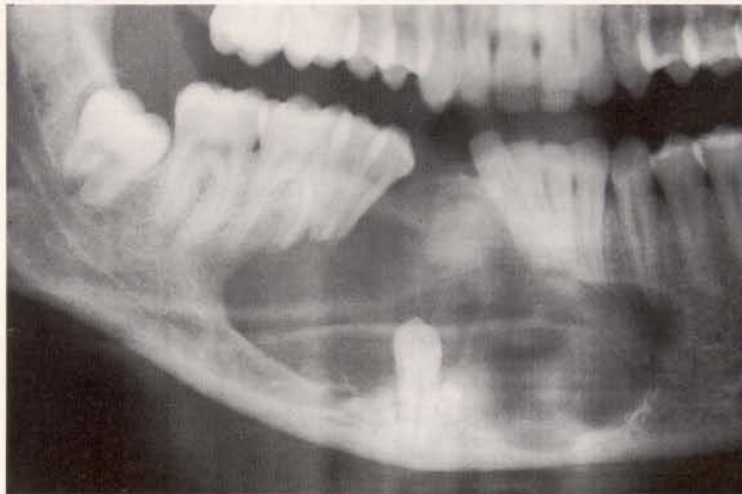
In the panoramic radiograph (left) the soap bubble-like structure is easily seen; this leads to easy confusion with an ameloblastoma. The periapical radiograph (right) cannot provide an overview of the extent of the lesion.



584 Central giant cell granuloma

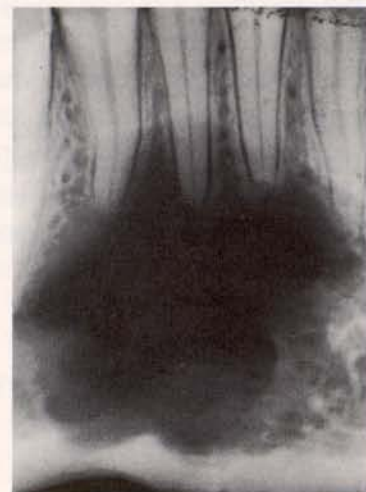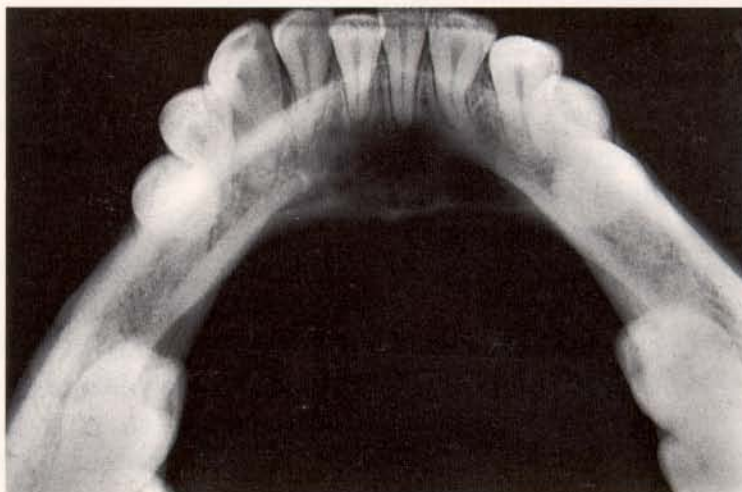The impacted and ankylosed tooth 43 and the displacement of the teeth may also be signs of a follicular cyst; on the other hand, the fine septum and the soap bubble-like contour resemble an ameloblastoma.

Courtesy Dr. K. Weibel, Baden



585 Central giant cell granuloma

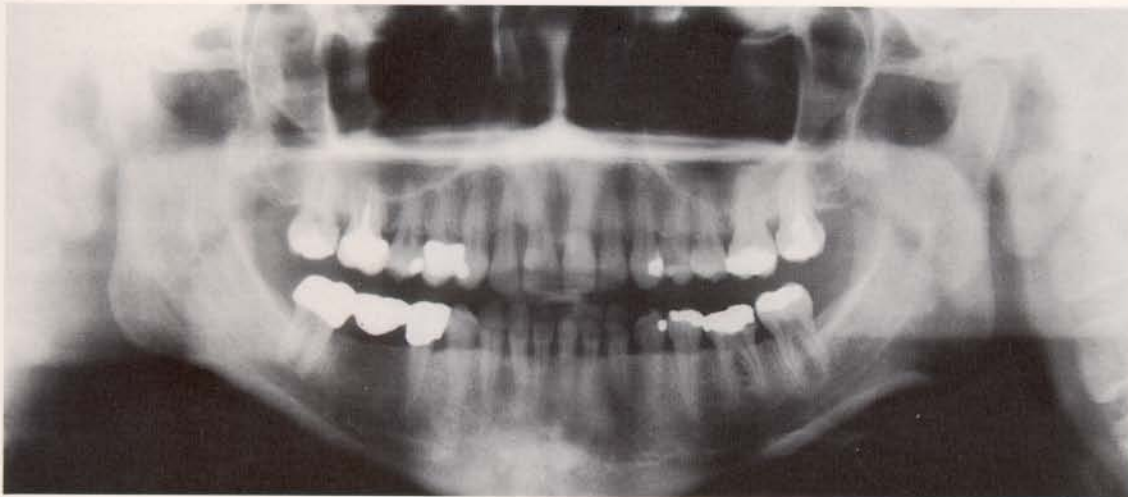
The occlusal radiograph (left) and especially the periapical film (right) depict the multilocular and soap bubble-like character of the lesion. Note the thinned and distended compact bone.



Peripheral Reparative Giant Cell Granuloma

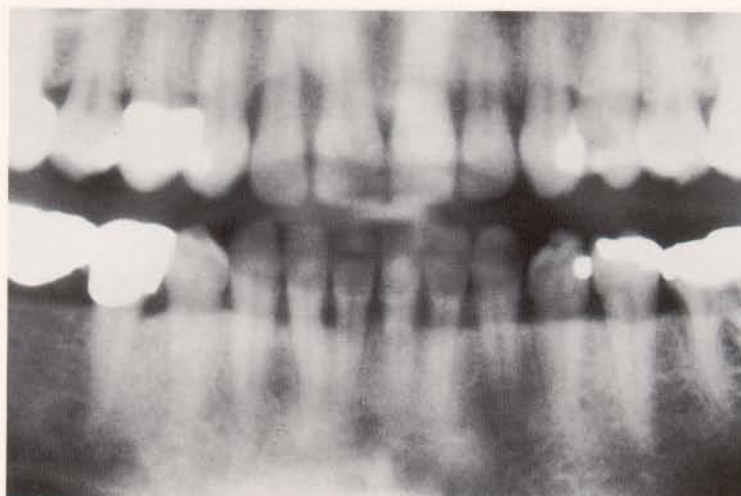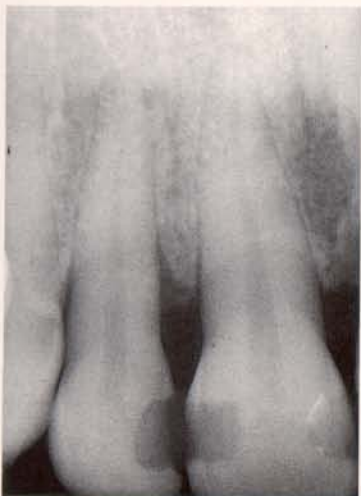The peripheral reparative giant cell granuloma occurs primarily as a gingival tumor in young adult females and may achieve a diameter of up to 2 cm. The lesion may elicit radiographically demonstrable osseous defects in the anterior region of both mandible and maxilla. The lesion grows along the alveolar entrance into the perio-

dontal ligament space, creating bowl-like defects of the alveolar ridge. The lesions tend to recur if incompletely removed. A cursory examination of the radiograph may lead the clinician to a diagnosis of a periodontal lesion.



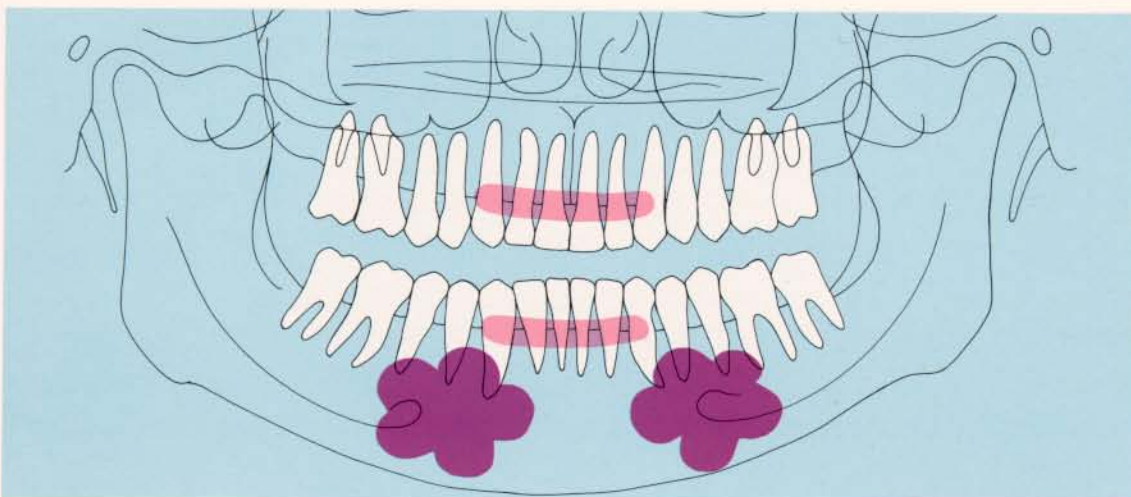
586 Peripheral giant cell granuloma

The panoramic radiograph exhibits a peripheral reparative giant cell granuloma with bowl-like osseous defects in the region of tooth 12 in this 38-year-old female.



587 Peripheral giant cell granuloma

This section from the above panoramic radiograph (right) and the periapical film (left) depict the situation in detail. Note the expansion of the lesion along the periodontal ligament space and the cuff-like expansion of the alveolar entrance.



588 The most common sites for central (dark) and peripheral (light) reparative giant cell granulomas

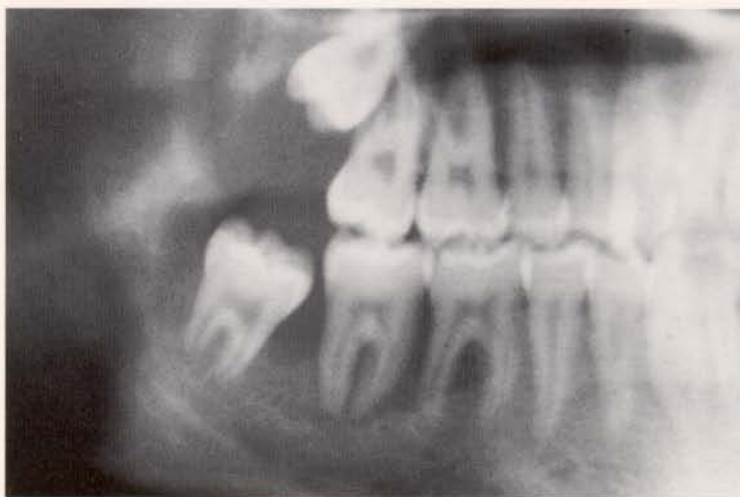Histiocytosis X

Under the rubric “histiocytosis X” are grouped a series of lesions characterized by histiocyte proliferation. To this group of diseases belongs the eosinophilic granuloma, which results from an increased infiltration of eosinophilic granulocytes into tissue exhibiting histiocyte proliferation, Hand-Schüller-Christian disease and the Letterer-Siwe syndrome. The eosinophilic granuloma depicted here may affect all age groups beginning at 20 years, and it may occur as solitary or multiple lesions in the jaws.

A pathognomonic radiographic sign are teeth which “hang in the air,” while the radiolucency often exhibits mildly sclerosed and arcuate bony boundaries. Periapical radiographs may give the appearance of advanced stages of marginal periodontitis, but clinically one observes that the pathologic tooth mobility in such cases occurs before any marginal periodontal changes and not afterwards. An additional important clinical sign is the poor healing tendency following tooth extraction.

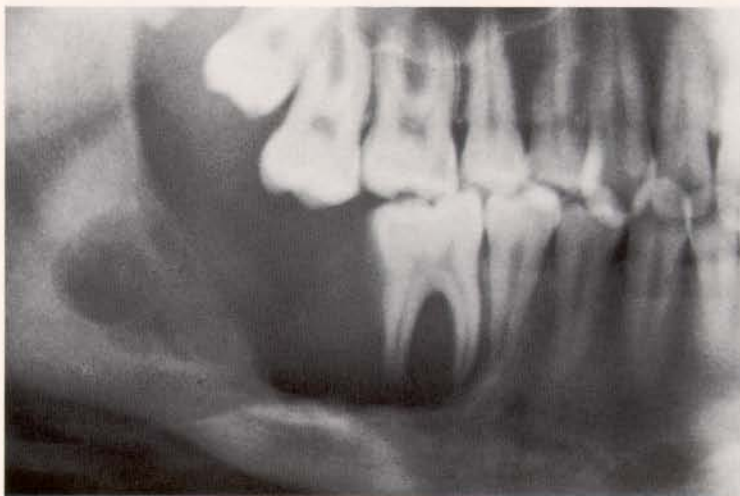589 Eosinophilic granuloma

This section from a panoramic radiograph depicts the right molar region in a 17-year-old male. Note the early expression of the lesion, with diffuse radiolucency. Some of the bony walls persist and therefore the classic picture of a “hanging tooth” is not yet so pronounced.



590 Same patient, two years later

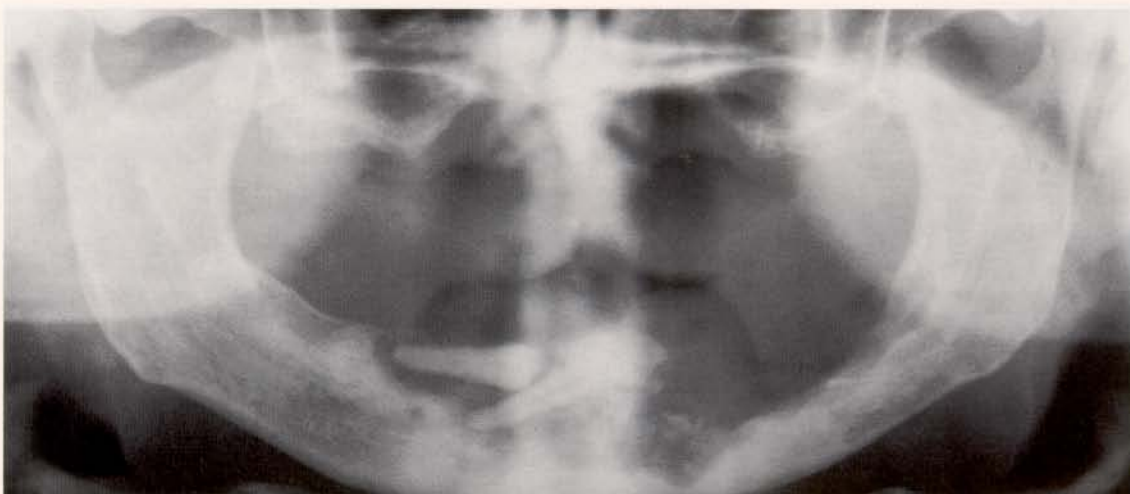
This is the classic radiographic picture. The roundish foci have become confluent, thus forming the arcuate boundary while leaving the tooth “hanging in the air.” The extraction sites have not healed and the granuloma is likely expanding.



591 Eosinophilic granuloma

Panoramic radiograph of a 66-year-old male. The few remaining teeth have tipped dramatically due to chewing forces. Note the arcuate boundary with opaque margins.

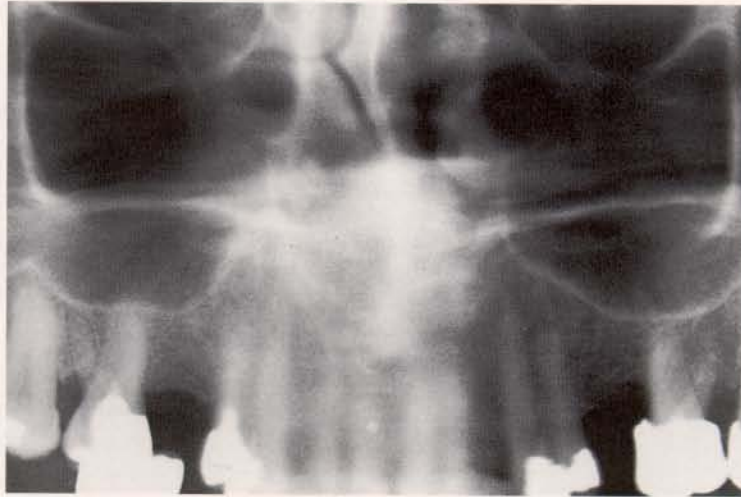
Courtesy Dr. H. Matras, Salzburg



Chondroma

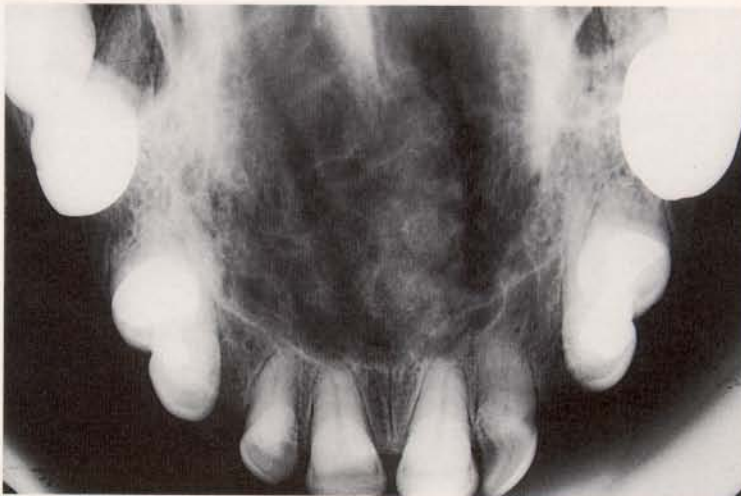
The chondroma may occur at any anatomic location where cartilaginous tissue exists or where cartilage residue from developmental processes persists. Typical locations include the anterior portion of the maxilla, the region of Meckel's cartilage and the condyle. Calcium deposits or newly formed spongiosa often complicate a

specific radiographic diagnosis of chondroma because the tumor may appear as a radiopacity. The chondroma as well as the osteochondroma may undergo malignant transformation to sarcoma, especially in the maxilla and in elderly males.



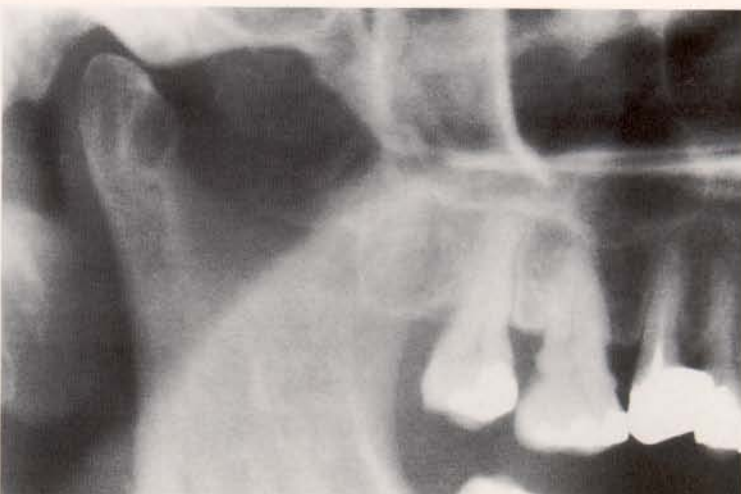592 Chondroma in the anterior portion of the maxilla

The panoramic radiograph provides only a vague picture due to the irregular roundish calcifications of the chondroma. It is for this reason that, in such cases, occlusal radiographs and a lateral cephalometric film must be recommended to supplement the panoramic radiograph.



593 Same case, occlusal radiograph

The transparency is clearly visible here, and appears virtually filled with areas of necrosis as well as roundish spotty calcifications. The palatal suture is still visible between the central incisors.



594 Chondroma of the condyle

The tumor has occurred near the articular surface. Osteochondroma is often encountered in this area. Depending on the percentage composition of bony or cartilaginous substance, the tumor may appear either as a radiolucency or a radiopacity. Patients in the second decade of life are often afflicted (orthodontics!).

Osteochondroma

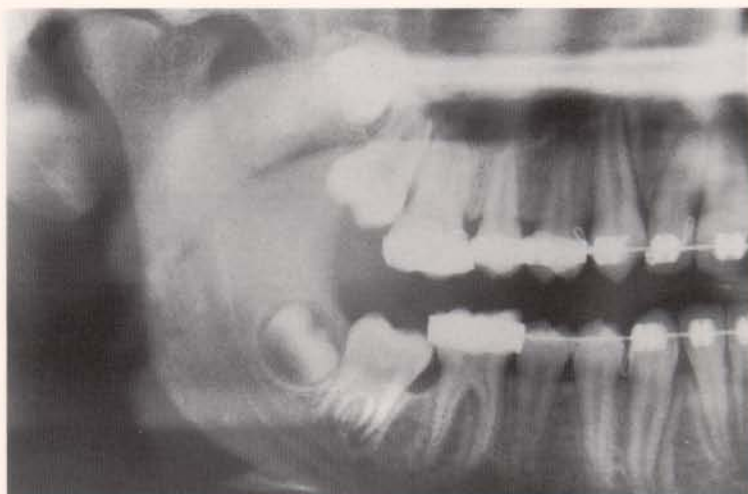The osteochondroma is an osteochondral exostosis and is one of the most common benign tumors of the adolescent skeletal system. It is also one of the most common benign tumors of the condyle, together with the osteoma (a more heavily ossified form) and the chondroma (a more cartilaginous form). Therefore the osteochondroma may appear radiographically as a

radiopacity with the density of bone, or as a radiolucency with some dense areas, and sharply demarcated condylar radiolucencies. Only the relatively recent introduction of panoramic radiography into routine dental screening has enabled the dentist to visualize such tumors.

595 Osteochondroma of the right condyle in a 12-year-old male

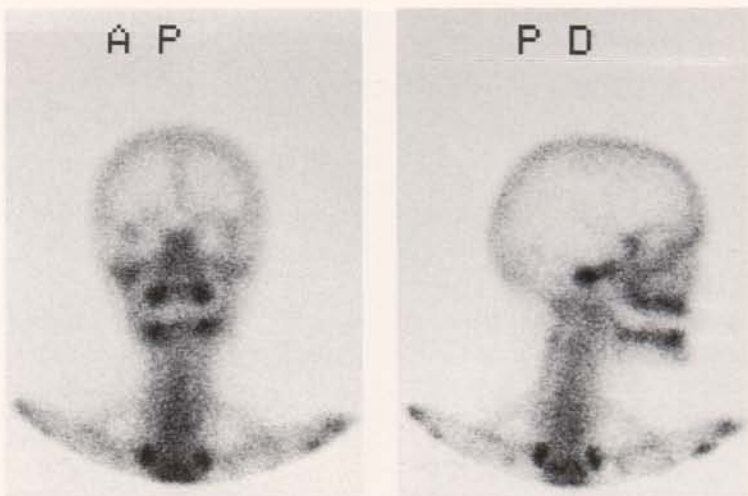
This section from a panoramic radiograph displays an osteoblastic tumor at the anterior border of the articular surface. Also apparent is a vague demarcation with a rather loose spongy bone structure.

Courtesy Dr. J. P. Joho, Geneva



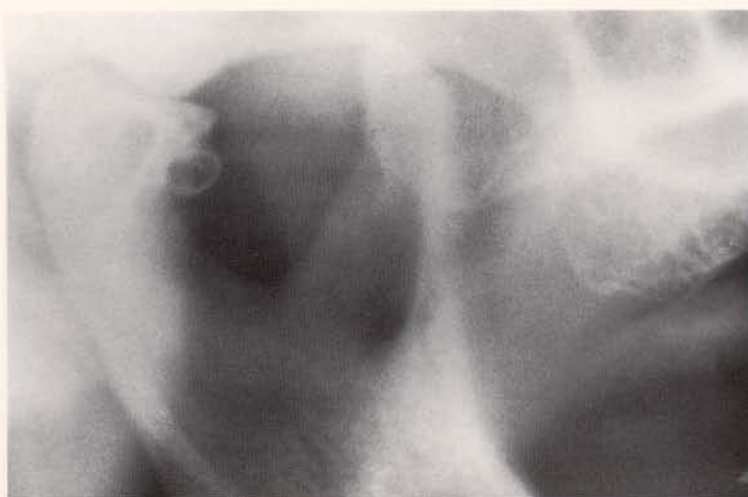596 Scintigraphy of the same case

Both the posteroanterior exposure as well as the lateral film reveal pronounced growth activity on the condyle (technetium label).



597 Osteochondral exostoses on the condyle of a 67-year-old male

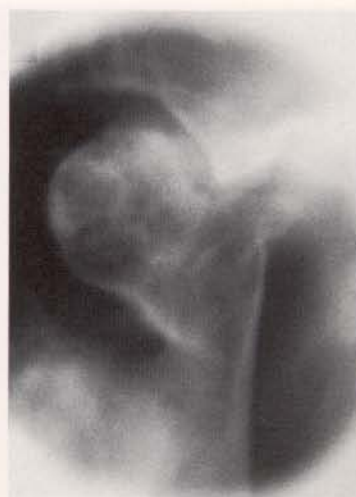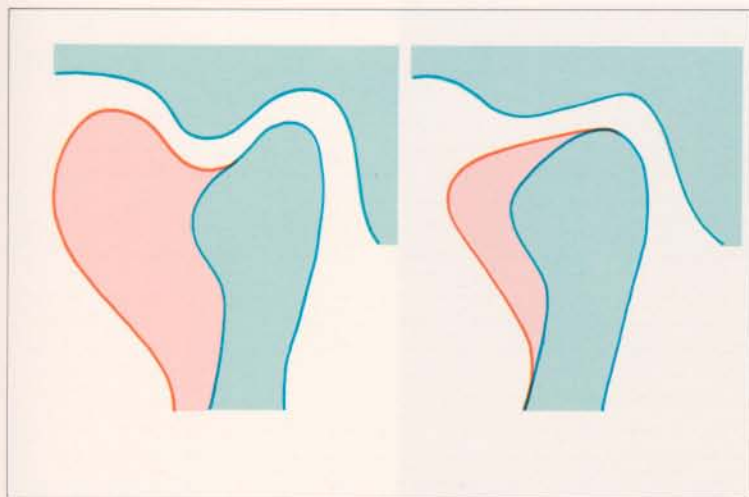
Noteworthy is the "crow's beak," which often simulates an "arthrosis." Small exostoses may occasionally be dislodged; due to the functional demands on the joint these become "free joint bodies."



Osteifying Fibroma

Mainly in females, an exceptionally large osteochondroma may form on the condyle, ventral to the actual articular surface. This tumor may lead to rather grotesque facial asymmetry. The articular eminence, with its usually flat dorsal articular surface appears to

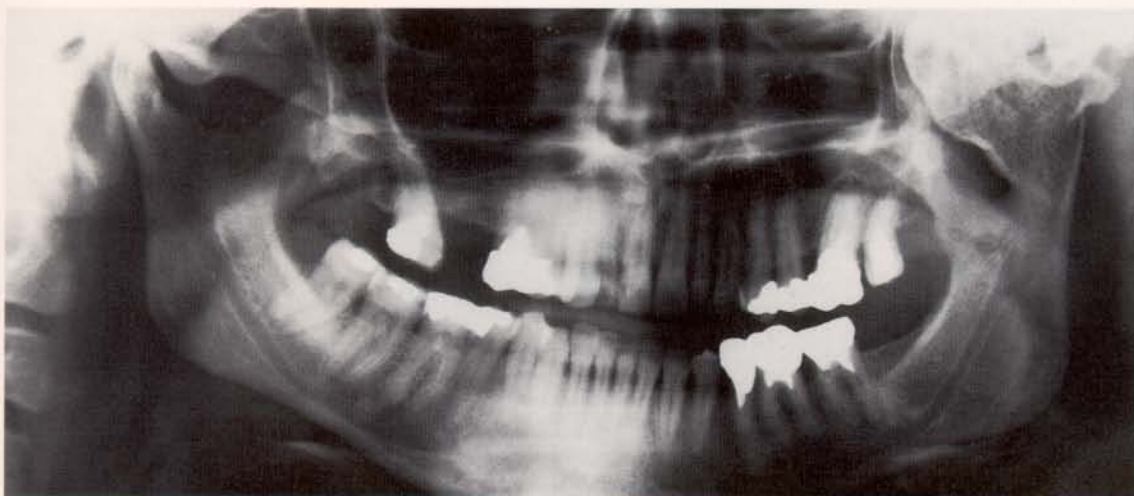
demonstrate that the tumor arises from about the beginning of the second decade of life. Small osteochondromas are frequently observed on the condyle, and may lead sooner or later to traumatic lesions of the disc and to temporomandibular joint disorders.



598 Osteochondroma

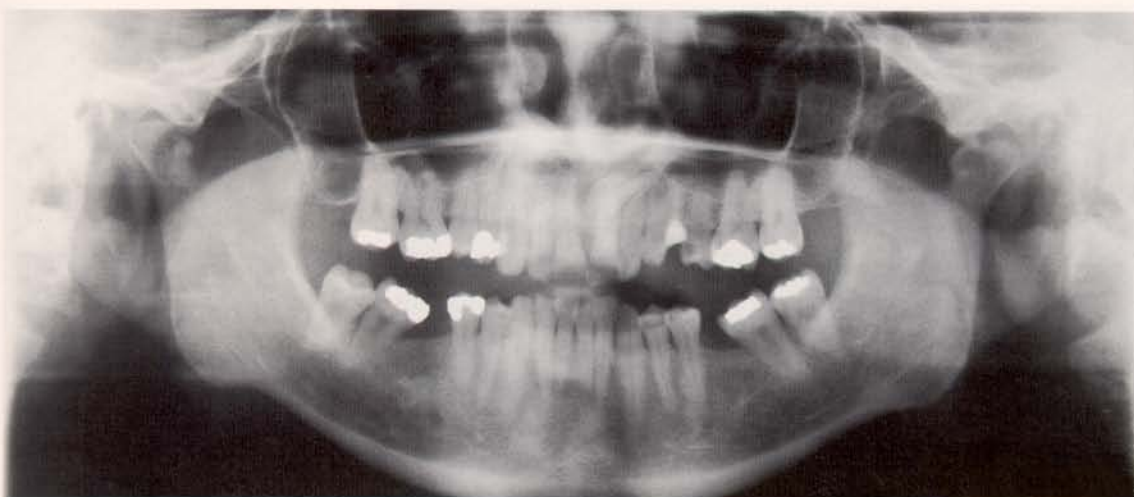
The otherwise sharply demarcated tumor exhibits radiolucencies within its cartilaginous areas. The patient was a 34-year-old female with pronounced facial asymmetry. The diagram (left) depicts two typical shapes of the osteochondroma as they would appear from lateral view on a panoramic radiograph.

Courtesy Dr. J. M. Chausse, Geneva



599 Osteochondroma of the left condyle

Extraordinarily large lesion, accompanied by pronounced development of asymmetry of the jaw. This reveals the exceptional compensatory mechanisms of the jaw musculature and the supportive apparatus. Compare to forms of the so-called facial hemihypertrophy.



600 Small osteochondroma

On the left (and also hypoplastic) condyle, one sees a small osteochondroma on the anterior border of the articular surface. The lesion had led to temporomandibular joint disorder in this 28-year-old male.

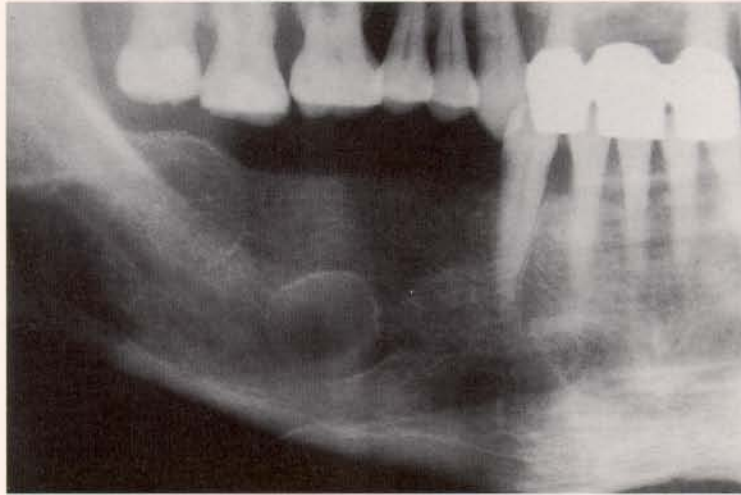
Desmoplastic Fibroma

Desmoplastic fibromas and other lesions that have not ossified contain connective tissue or not yet calcified osteoid; for these reasons, such lesions present diagnostic difficulty in radiology. They present as uni- or multilocular lesions with lobular projections of the normally sharply demarcated border contour; in later

stages the thinned cortical plate may be perforated. The same radiographic appearance can occur with an ossifying fibroma where the bone is poorly calcified, and if high energy exposure was used. For this reason, specific diagnosis can only be made after histologic evaluation of a biopsy.

601 Non-ossifying fibroma in a 52-year-old male

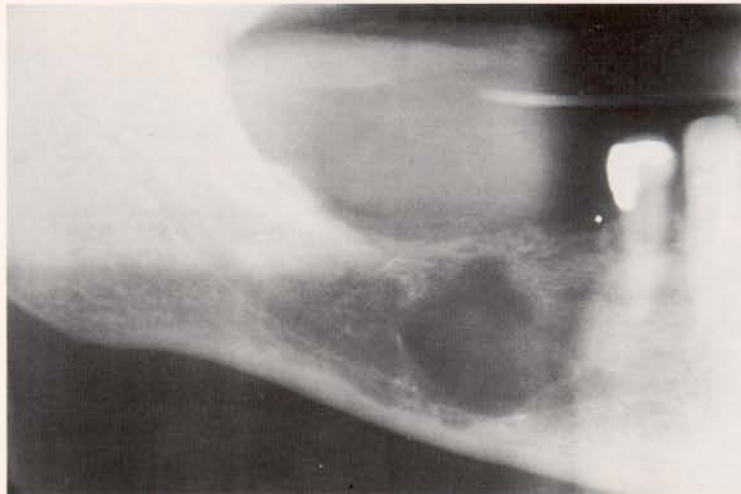
Note the sharp demarcation of this cystoid, round radiolucency, whose site and configuration could lead one to an incorrect diagnosis of apical residual cyst.



602 Recurrent non-ossifying fibroma in a 46-year-old male

Note the loss of regular and sharp demarcation, which is reminiscent of a malignant osteolytic tumor. The multilobular form is still visible and is characteristic for desmoplastic fibroma.

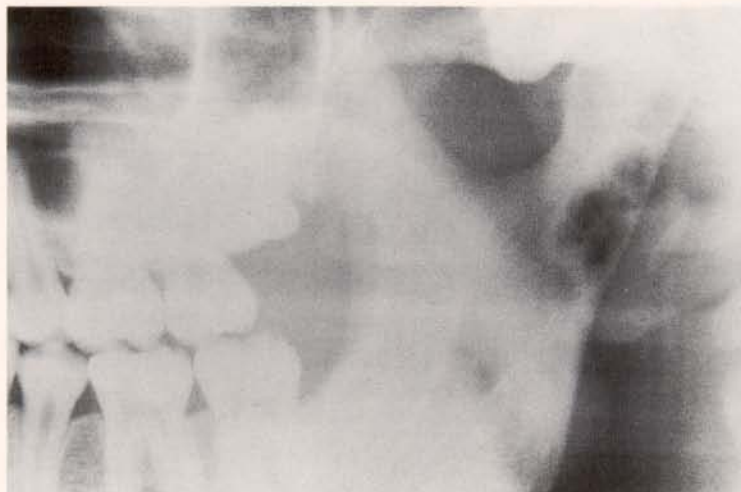
Courtesy Dr. Ph. Zimmerli, Cernier



603 Rare non-ossifying fibroma in the articular process

Note the bubble-like shape, which appears similar in this site to a giant cell granuloma or a myxoma.

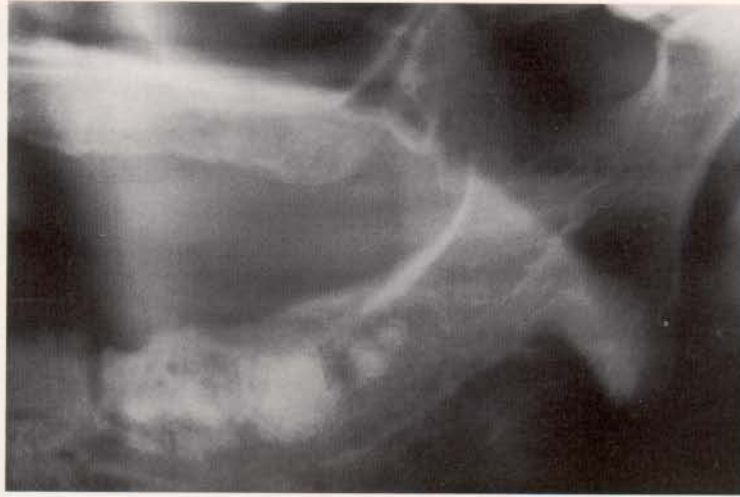
Courtesy Dr. M. Makek, Zurich



Ossifying Fibroma

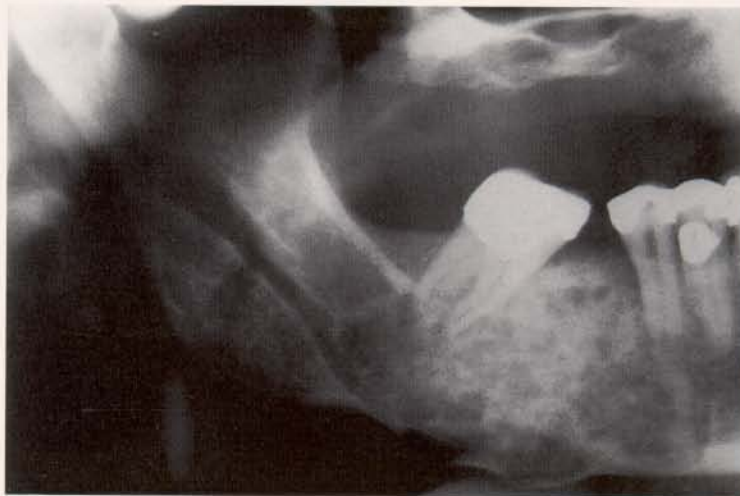The slowly growing ossifying fibroma may achieve considerable mass in edentulous patients without being detected, and from time to time may cause difficulties for patients who wear dentures. The ossifying fibroma of the maxilla, which affects young persons most often, may also enlarge considerably into the maxillary sinuses

and nasal cavity without any external deformation of the face. It therefore remains unnoticed for a long time. Heavily calcified forms viewed in a Waters' projection may be mistaken for expansive osteoma in the maxillary sinus, and may lead secondarily to clinical difficulties.



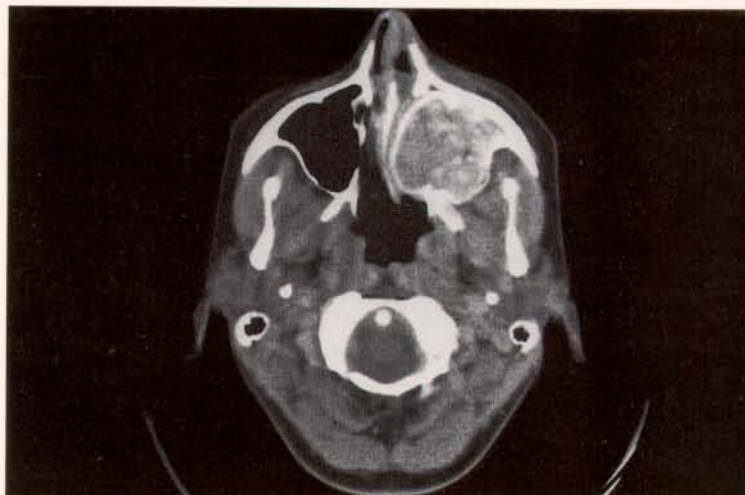604 Ossifying fibroma in a 63-year-old female

Even the histopathologist encounters difficulties in diagnosis and classification of such cases. The spectrum of differential diagnostic possibilities includes tumors that are characterized by ossification or cementum formation.



605 Ossifying fibroma of the mandible

The radiograph reveals a sharply demarcated radiolucency with spotty calcifications in its center.



606 Ossifying fibroma of the maxilla in a 40-year-old female

The axial CT with soft tissue window reveals the size and the clear demarcation, with displacement of the sinus and the nasal cavity. Clearly visible are some heavily calcified foci. Recurrent lesions have a tendency toward malignant transformation into sarcoma.

Courtesy Dr. Ph. Zimmerli, Cernier

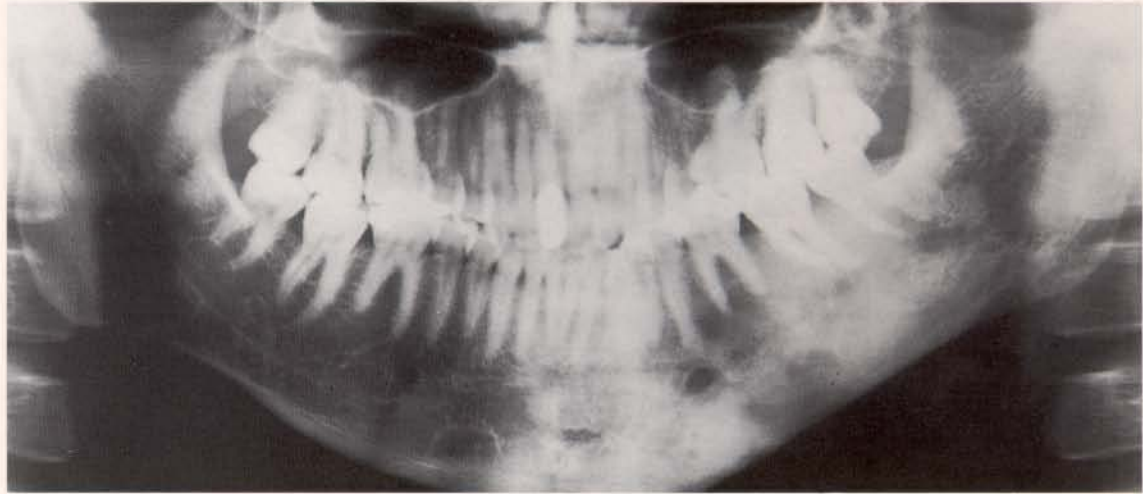
Fibrous Dysplasia (Jaffé-Lichtenstein)

This disease, also known as juvenile osteofibrosis deformans (Uehlinger), originates between 5 and 15 years of age, affects females approximately twice as often, and the clinical course may extend in bursts far beyond puberty. The disease derives from improper differentiation during bone formation. Initially, normal spongiosa and bone marrow are replaced with fibrous ground substance and fibrous bone is formed later. Spontaneous healing or stagnation of the disease process during puberty are possible. The course of this disease may be monostotic or polyostotic, the maxilla is

more frequently affected than the mandible, and osseous sutures limit expansion. Distention and thinning of the cortical plate are often observed especially in the maxilla, and this can result in significant facial asymmetry. In the mandible the poorly demarcated "cystoid" radiolucencies and opacities of various degree are arranged one against the other, reminiscent of chronic recurrent forms of osteomyelitis. The newly formed fibrous bone may develop pronounced opaque areas, in addition to spongy structures.

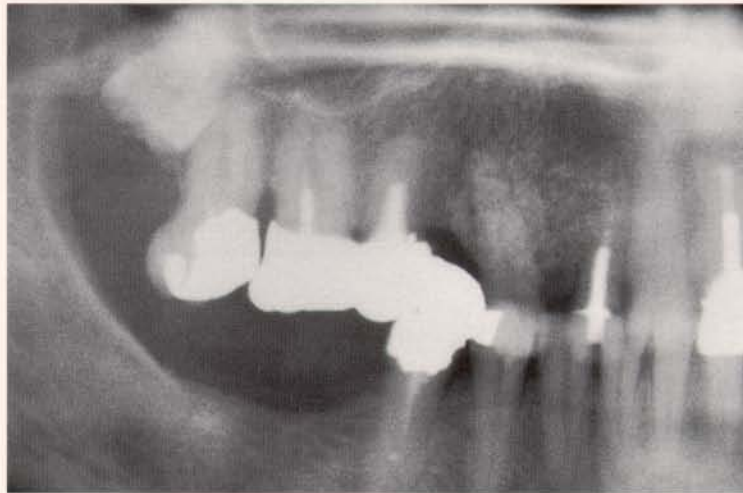
607 Fibrous dysplasia in the mandible of a 28-year-old male

In addition to mild distention of the left mandible, note the milk-glass shadowing with honeycomb-like radiolucencies. The radiographic picture is often difficult to differentiate from the chronic form of osteomyelitis.



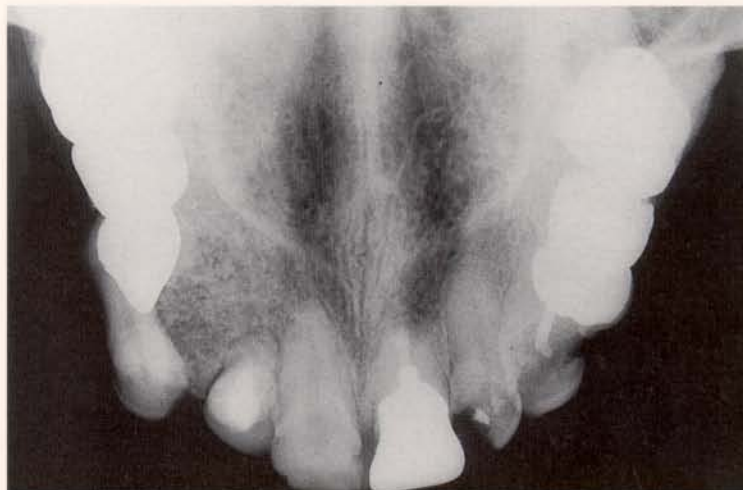
608 Fibrous dysplasia in the maxilla of a 57-year-old female

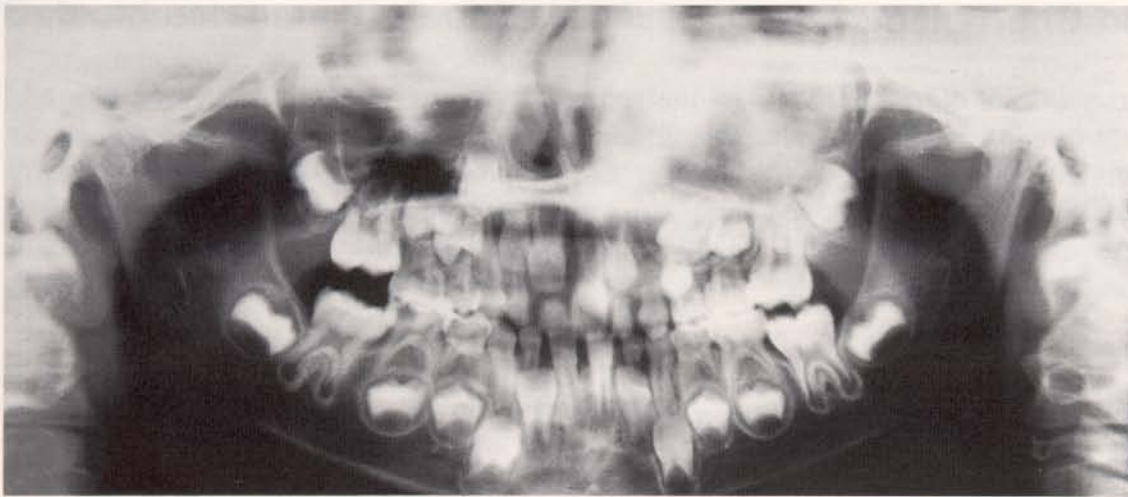
Here also the demarcation between the lesion and healthy bone is vague. The distention is locally demarcated and shows a random spongy bone organization.



609 Same case, occlusal radiograph

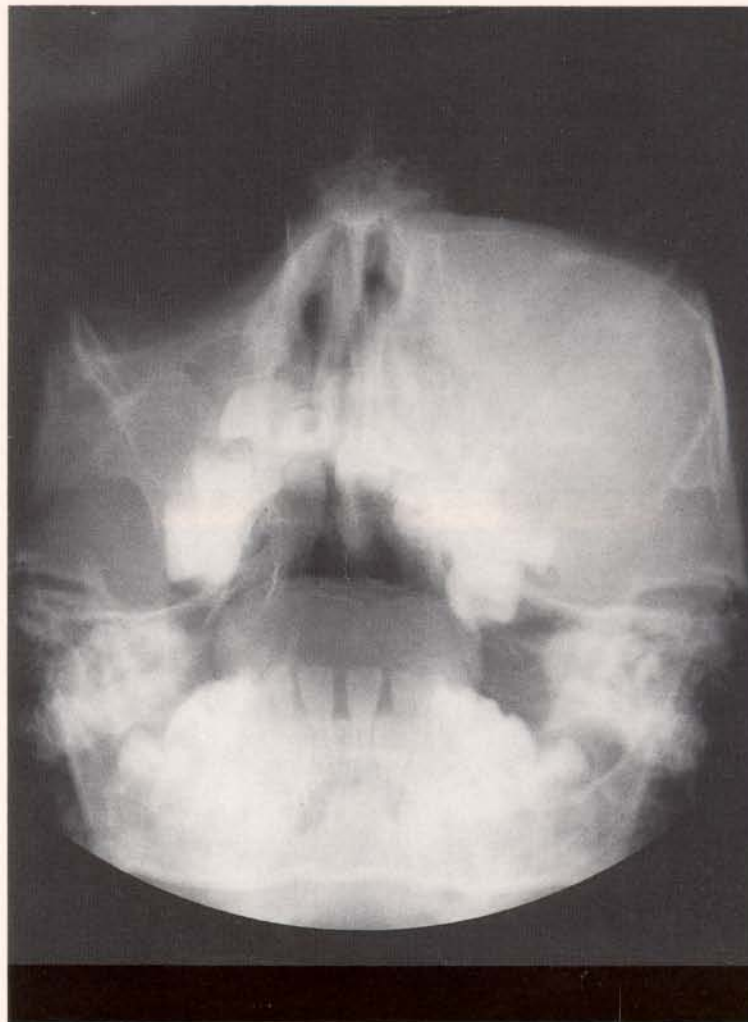
The distention of the bone, the atypical appearance of the spongiosa in the affected region and the impaction of tooth 13 toward the vestibulum can be clearly seen.





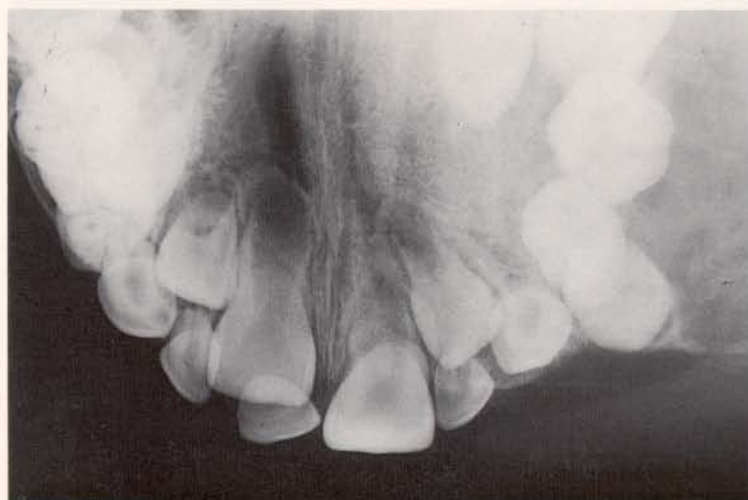610 Fibrous dysplasia as seen in the panoramic radiograph of a 6-year-old female

Despite the high-energy radiographic exposure, the entire left side of the maxilla exhibits radiopacities. The expansive process is made more apparent because of the displacement of the teeth and the tooth buds. The ossifying fibroma may exhibit similar radiopacities in the maxillary sinus when viewed in a panoramic radiograph. However, it usually occurs only later in life, during puberty.



611 Same case as viewed in a Waters' projection

The expansion of the maxilla and the zygoma has displaced the maxillary sinuses and also distended the zygomaticoalveolar crest. Nevertheless the median sagittal plane has not been crossed. Normal bone structure has taken on a milk-glass appearance due to transformation of bone marrow.



612 Same case, occlusal radiograph

Clearly visible is the massive expansion of the maxilla with displacement of tooth buds and the typical milk-glass-like structure, resembling an orange peel. Note that the median suture remains intact.

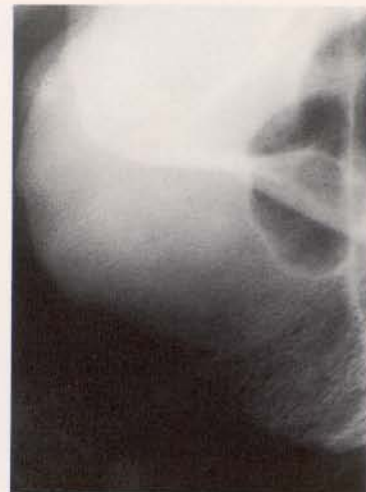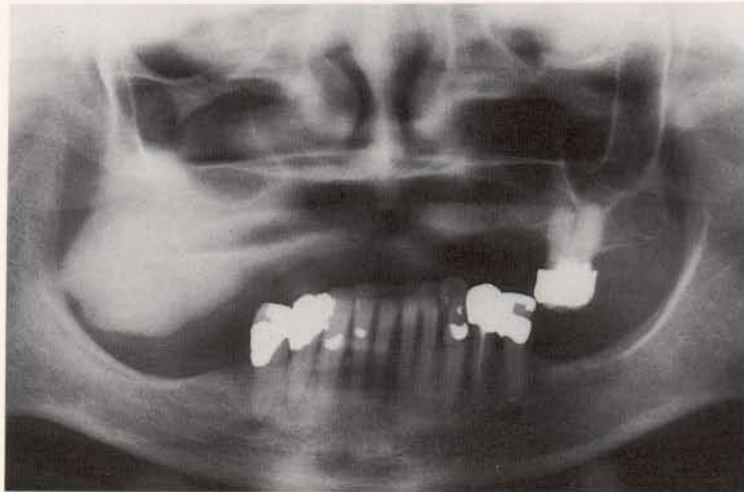
Fibrous Dysplasia and Cherubism

Fibrous dysplasia of the jaw may exhibit quite variable radiographic signs depending upon the age of the patient, thus making the differential diagnosis extremely difficult. Poorly demarcated radiolucencies localized to one side of the jaw may alternate with milk-glass, honey-comb or pumice-like radiopacities. A peculiar dysplasia

is the bilateral involvement of both maxilla and mandible, and is characterized by polycystic, misshapen enlargements, especially at the angle of the mandible and in the maxilla. This results in a clinical appearance called cherubism.

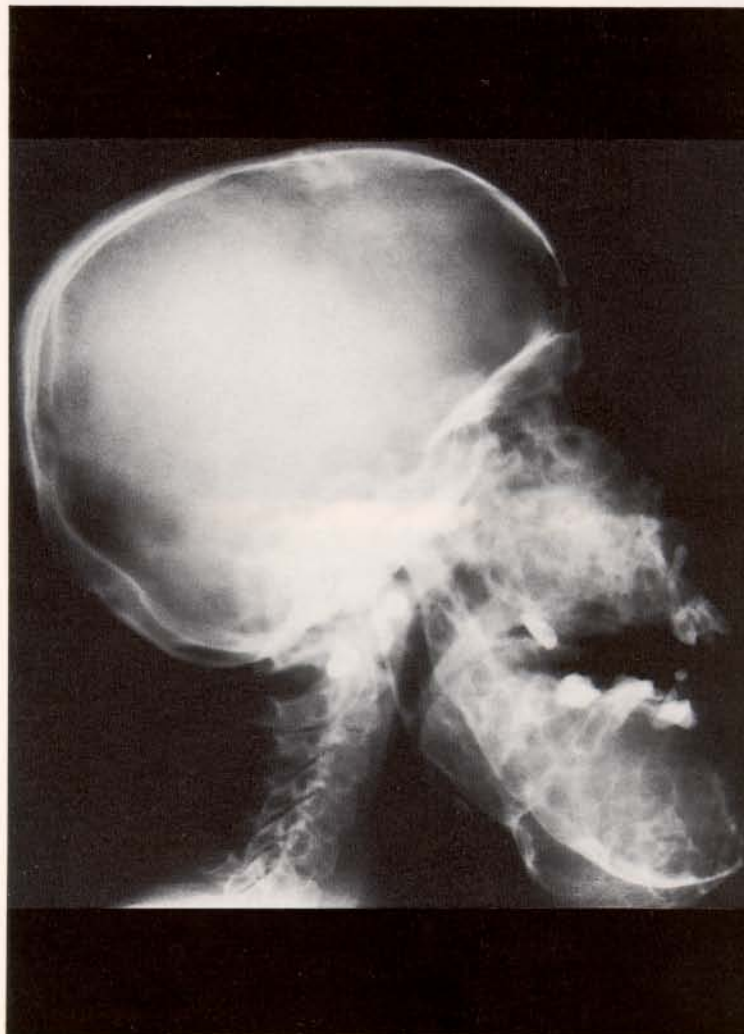613 Fibrous dysplasia in the right maxilla of a 56-year-old female

The panoramic radiograph (left) and the occlusal radiograph (right) both reveal extreme enlargement with displacement of the maxillary sinuses. Note the poorly demarcated borders and the radiopacity, which is typically uniform due to the accumulation of fibrous bone.



614 Cherubism, lateral skull radiograph

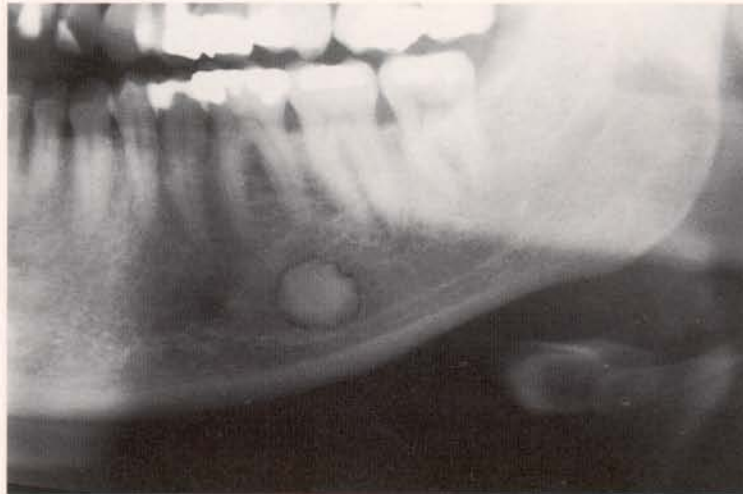
In comparison to the previous examples of fibrous dysplasia, note here the polycystic structure that crosses anatomic boundaries; such lesions usually appear only in the skeleton, especially in the ribs. Particularly obvious is the thickening of the base of the skull. Malpositioning of the teeth and retention of the second and third molars are frequently observed. This condition usually begins during the first decade of life.



Osteoid osteoma, Osteoblastoma

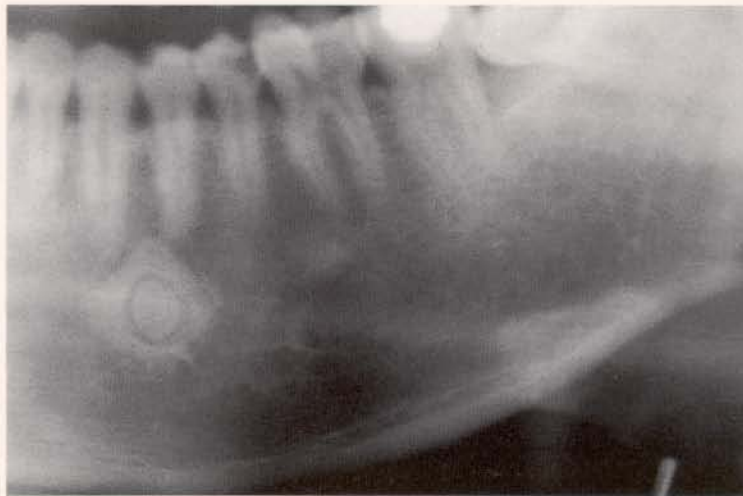
The exceptionally rare osteoid osteoma most often affects the mandible, particularly in young women. Radiographically, it exhibits an opaque nucleus within an oval radiolucency, the "nidus." The lesion is always smaller than 1 cm, and the surrounding tissue frequently exhibits significant reactive sclerosis. The osteo-

blastoma is also relatively rare; it is an osteoid-forming tumor, which occurs in both maxilla and mandible during adulthood. In its initial stage the lesion exhibits radiographically a diffuse radiolucency, which later matures into a very dense radiopacity greater than 2 cm in expanse with an obvious border.



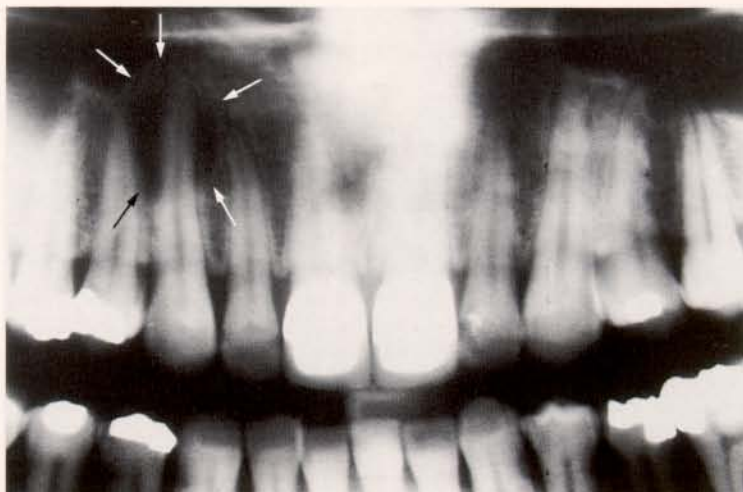
615 Osteoid osteoma of the mandible

Note the "nidus" with its calcified core and the rather bright zone of uncalcified osteoid in this 29-year-old female.



616 Osteoid osteoma of the mandible

The sclerosed marginal zone almost masks the typical nidus with its transparent border in this 43-year-old male. The diameter of the lesion is seldom greater than 1 cm.



617 Osteoblastoma of the maxilla

Note the radiolucent lesion comprised of osteoid, approximately 1.5 cm in diameter in this 23-year-old female in the region of teeth 12, 13 and 14 (arrows). Clinically, this lesion was painful.

Courtesy Dr. J. Samson, Geneva

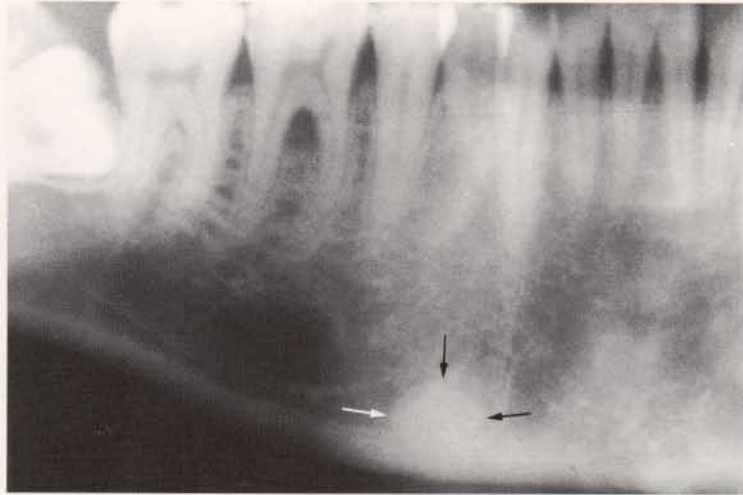
Osteoma

The osteoma may occur as a central or a peripheral lesion and is not always easy to differentiate radiographically from other heavily ossifying and calcifying lesions. The osteoma may occur in all age groups but exhibits a preference for elderly adults. Radiographically it exhibits either a well-demarcated and very

dense radiopacity (compact osteoma) or a more loosely structured trabecular form (spongy osteoma). Osteomas of the peripheral type are frequently found in the frontal sinus and the maxillary sinus, and less often on the compact bone at the angle of the mandible.

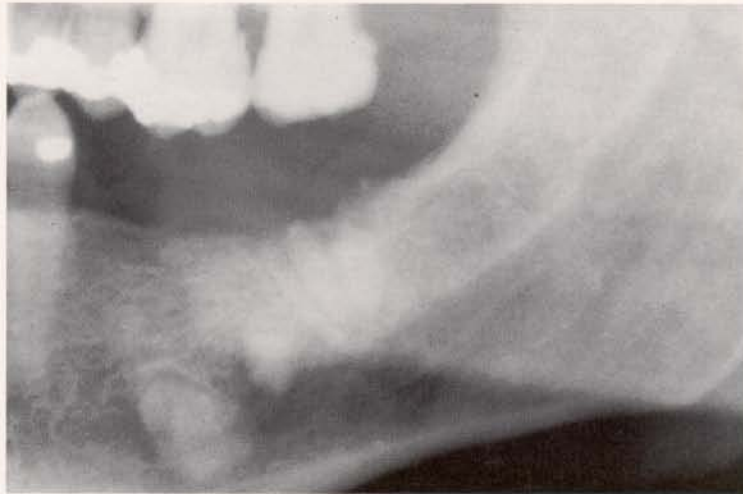618 Central osteoma

At the region of the mental protuberance such as in this 32-year-old male, one can often observe osteoid osteoma and osteoma (arrow).



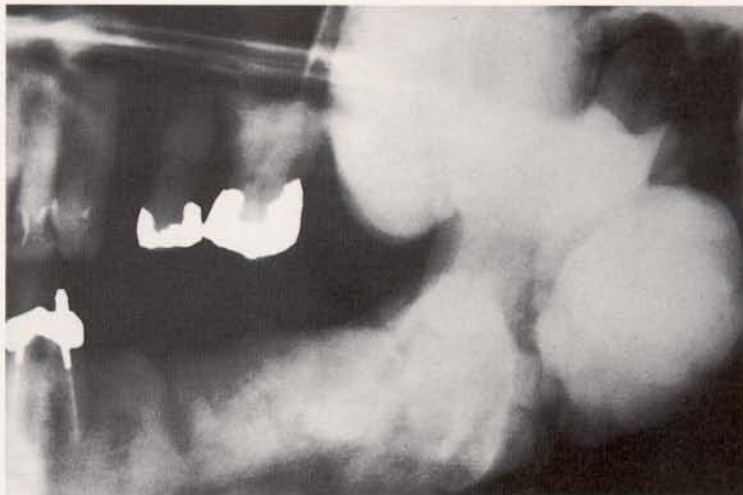
619 Central osteoma

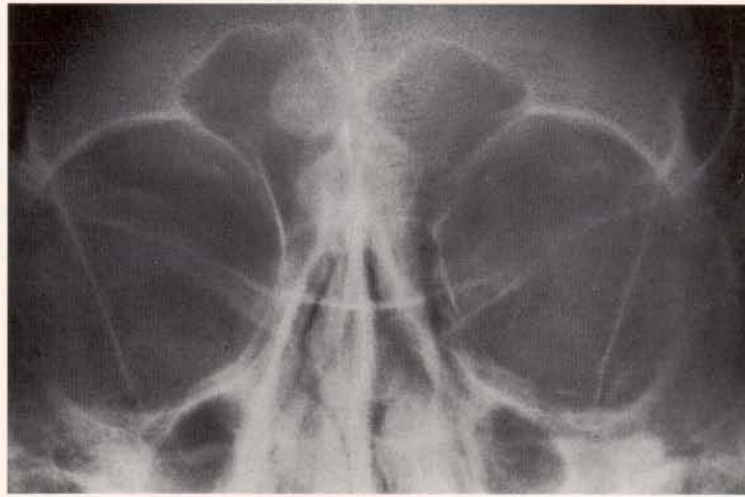
Two osteomas of the compact type can be seen anterior to the root fragment of tooth 37.



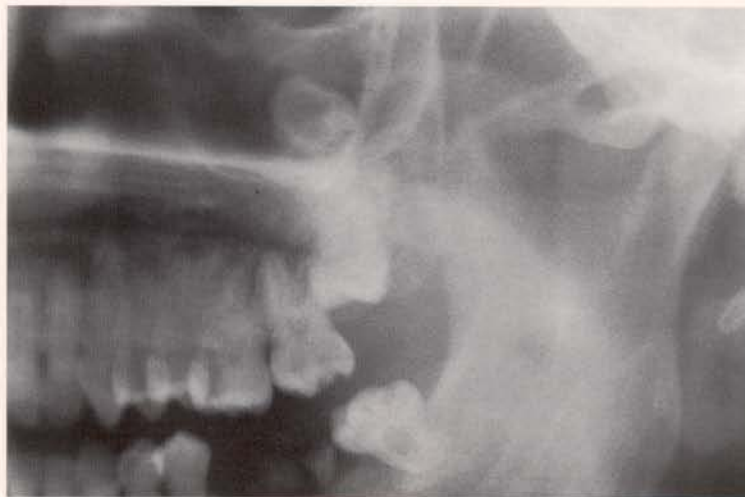
620 Multiple osteoma

In male patients (especially among Blacks) the presence of multiple osteoma should lead one to consider the possibility of Gardner's syndrome, which is accompanied by intestinal polyps that often undergo malignant transformation. This disease is inherited as an autosomal dominant trait.

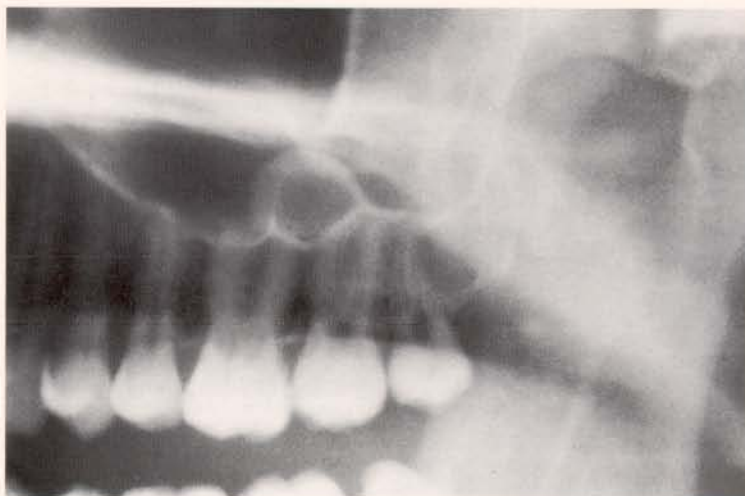




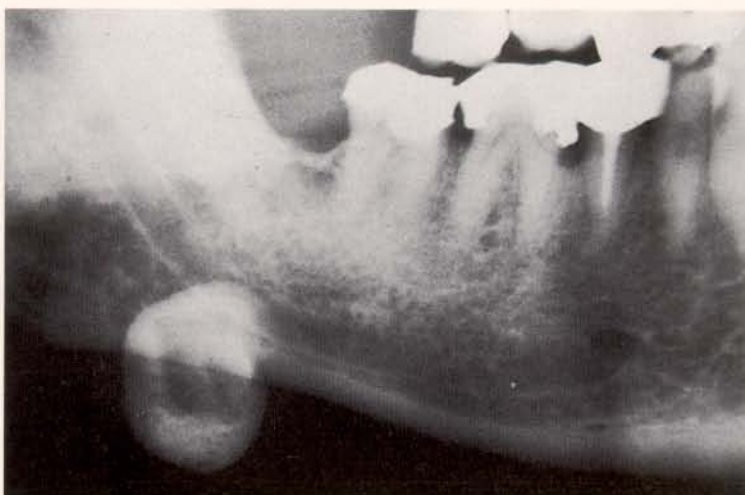621 Peripheral osteoma
This lesion is located on the medial wall of the right frontal sinus.



622 Peripheral osteoma
Approximately 5% of all osteomas of the facial skeleton are observed in the maxillary sinus. In this patient the osteoma developed in the posterior lobe.



623 Peripheral osteoma
The panoramic radiograph clearly depicts the osteoma located in the alveolar recess of the maxillary sinus.



624 Peripheral osteoma at the right angle of the mandible
This peripheral osteoma has a cancellous structure and is located upon compact bone. Such lesions may be confused with calcified lymph nodes.

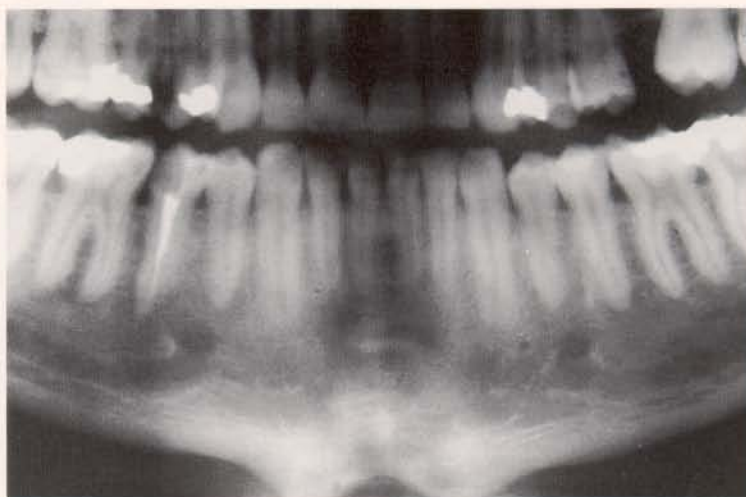
Exostoses and Enostoses

Abnormal enlargements at the mental protuberance and the angular process of the mandible are also classified as exostoses. It is interesting that the site of the latter lesion is also a common site for ossifying fibroma, peripheral osteoma as well as the so-called latent pseudocyst (Stafne). Enostoses may originate from the

compact bone and invade the spongiosa, where they are often described as a radiographic picture of "compact islands." These may derive as inflammatory processes following trauma, or be projected into the jaw from the surrounding tissue (Fig. 630).

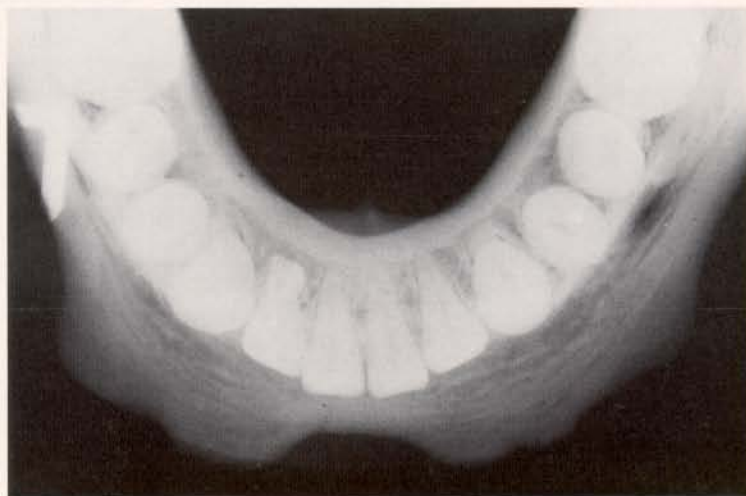625 Exostoses of the mental protuberance

It is noteworthy that osteoid osteoma and osteoma may be observed in the same site.



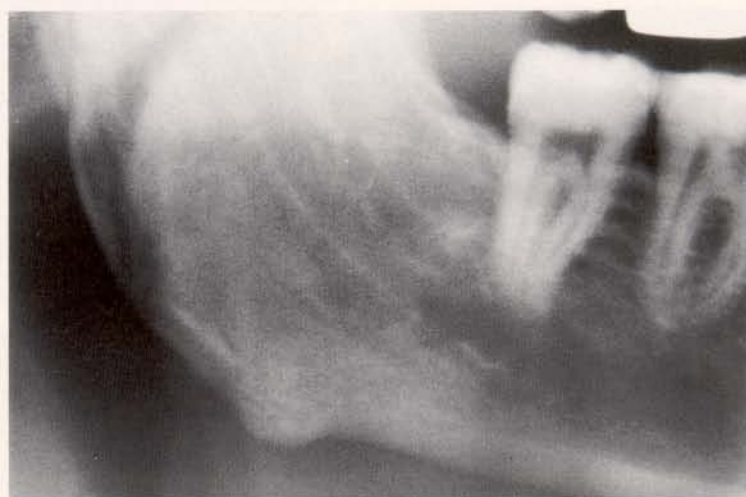626 Multiple vestibular exostoses

These lesions occur frequently on the vestibular aspect of maxillary molars and the mandibular anterior teeth. Because of their usually very loose structure they may be observed in orthoradial radiographs (panoramic films) as mild radiolucencies and only seldom as opaque structures.



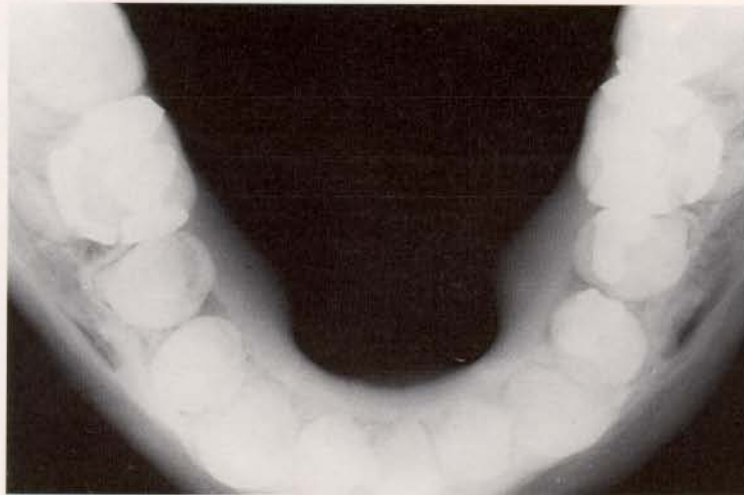
627 Exostosis at the angle of the mandible

This broad-based exostosis originated in the area near the attachment of the anterior portion of the masseter muscle. A similar radiographic picture may be occasioned by a peripheral osteoma or by the angular process of the mandible.

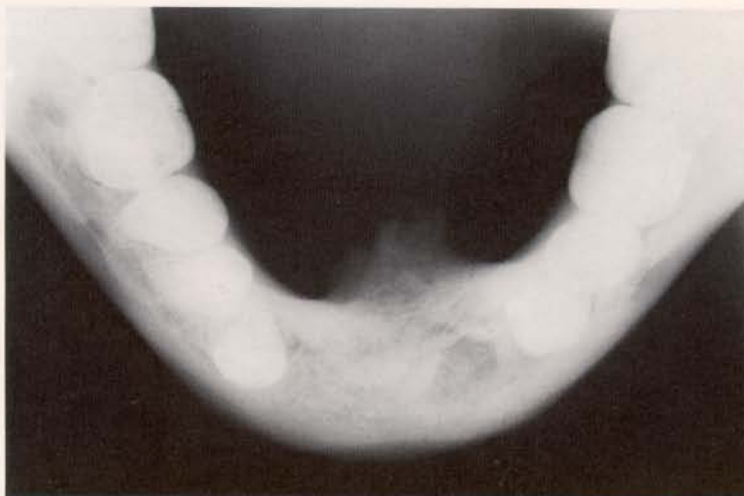

Maxillary and mandibular tori also fall into the classification of exostoses of the jaws. Most common is the mandibular torus, which is best documented using occlusal radiographs. Also common is the palatal torus, which can be readily visualized in panoramic radiographs when it achieves a certain size. Less common

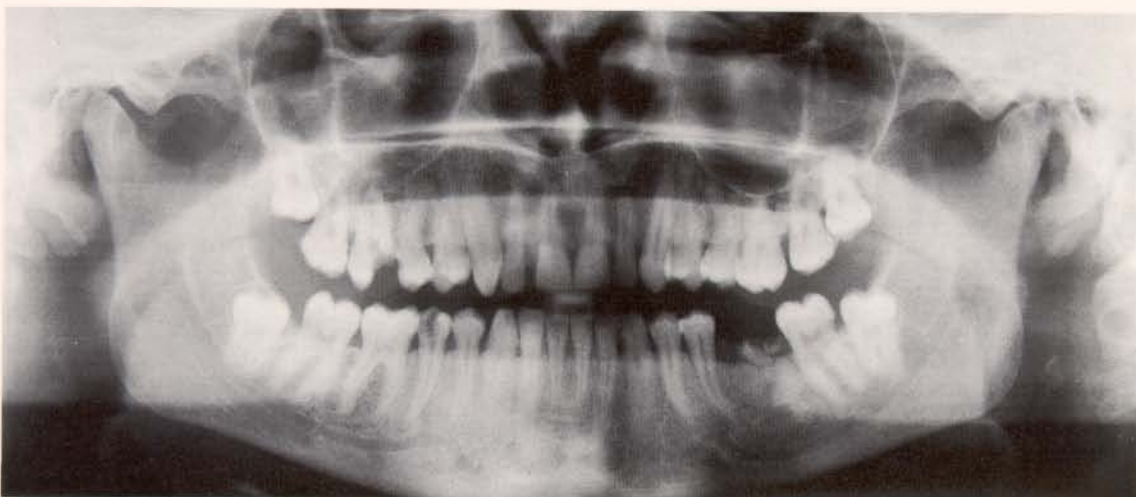in the maxilla and mandible are multiple vestibular exostoses; these often present as radiolucencies. Not infrequently the areas of muscle attachment on the mental spine may calcify, creating a pronounced protuberance that may interfere with wearing dentures.



628 Mandibular torus
Small exostoses are difficult to document radiographically even with occlusal films. The predilection site is the lingual wall of the mandible in the premolar region. In periapical radiographs and panoramic films, they may appear as "intraosseous" radiopacities in the premolar region.



629 Ossification of the muscle attachments on the mental spine
The genioglossus muscle and the geniohyoid muscle may become ossified where they attach to the mental spine, and this may provide difficulties for denture wearers. Such cases may actually represent a form of myositis ossificans, which is a heterotopic accumulation of bone at the attachment of the musculature.



630 Enostoses of post-traumatic inflammatory origin
This panoramic radiograph reveals enostoses that developed following incomplete extraction of tooth 36. Such enostoses often present with irregular radiopaque borders. This sort of bony sclerosis may also occur after eruption difficulties, and may persist as a bony infarct.



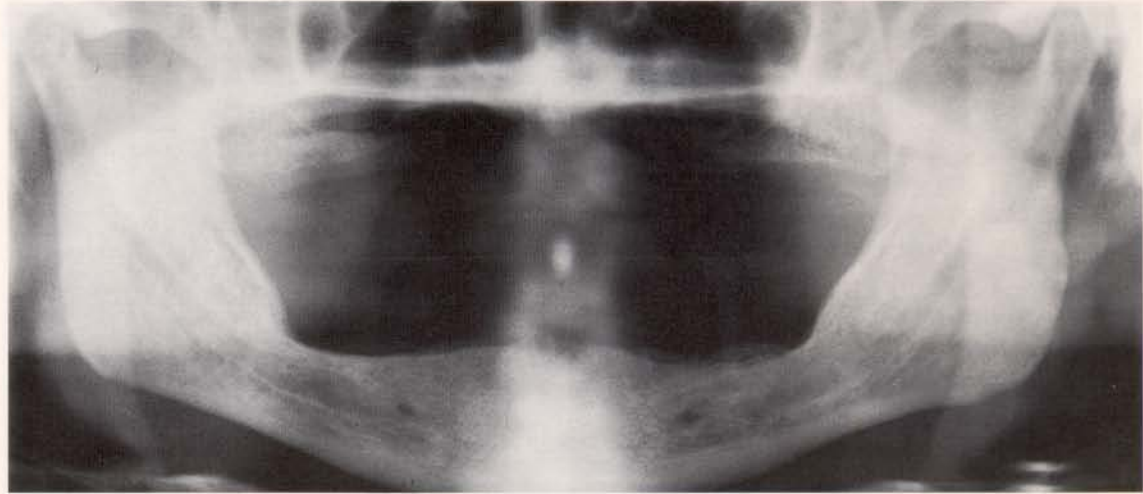
Hyperostoses and Hypertrophies

Hyperostoses are sometimes found in the retromolar area of edentulous patients. The hypertrophies, especially unilateral progressive hypertrophy of the facial skeleton, represent lesions whose etiologies remain unclear. One may also infrequently observe isolated

hypertrophy of the coronoid process or the articular process with abnormal growth of the ascending ramus and the body of the mandible, and posterior open bite. These conditions lead to facial asymmetry and may be traced originally to condylar growth disturbances.

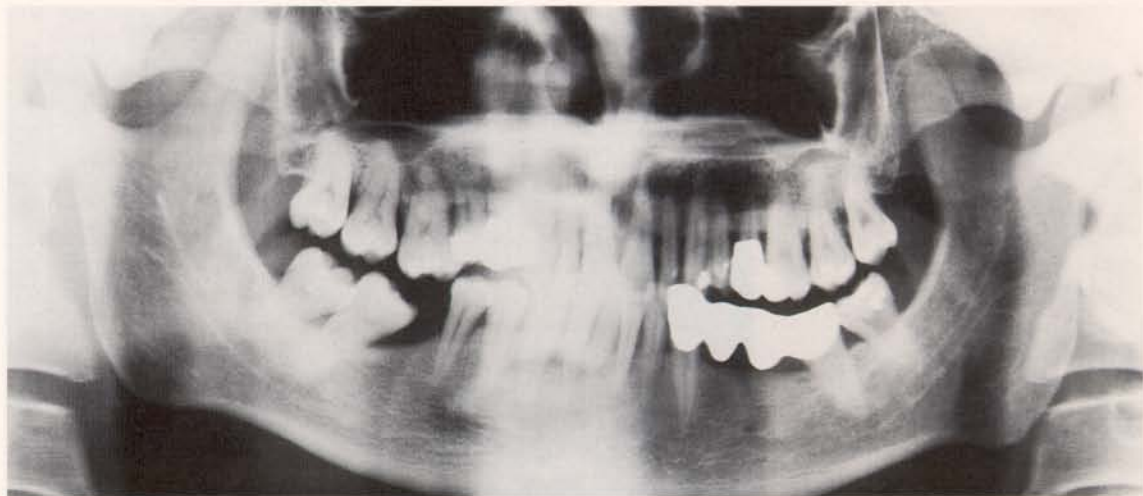
631 Symmetric jaw hyperostosis in the retromolar area

The etiology of this pathology in a 73-year-old male is unknown. One could speculate that the jaw relations and the length of time the patient wore complete dentures led eventually to static accommodation.



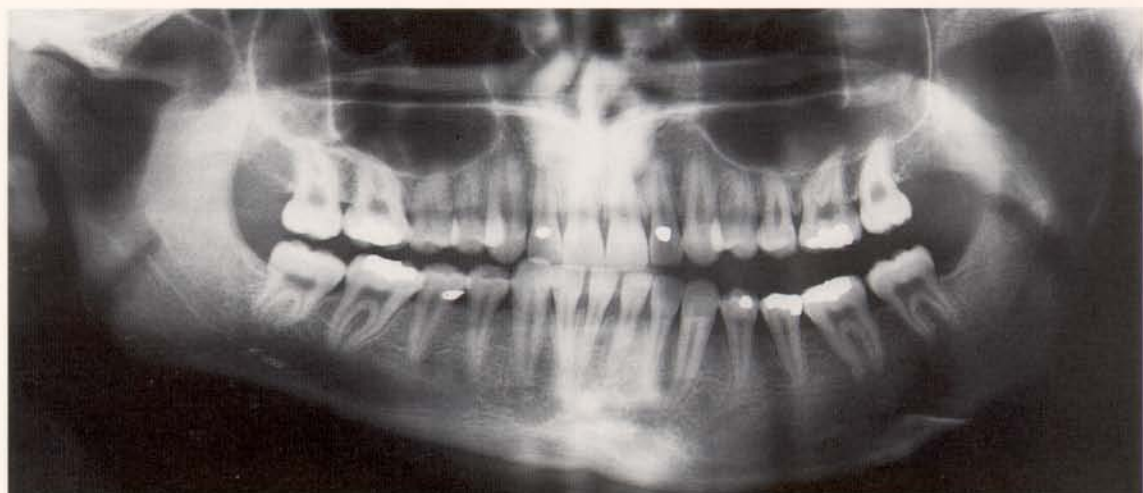
632 Bilateral hypertrophy of the coronoid process

It is possible that the clearly visible malocclusion led to hyperactivity of the temporal muscle and therewith to the abnormal elongation of the coronoid process in this 44-year-old female.



633 Hypertrophy of the condyle

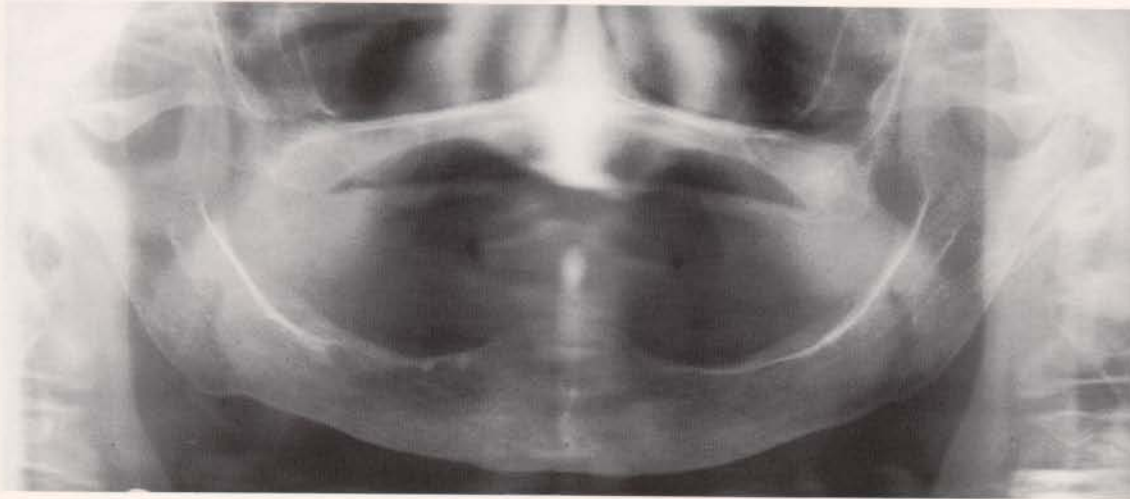
Elongation of the ascending ramus and thickening of the body of the mandible can be seen on the left side in this patient with unilateral left open bite. The patient also exhibited facial hemihypertrophy of unknown etiology. Could this be osteochondral exostoses of childhood?



Osteoporosis and Atrophy

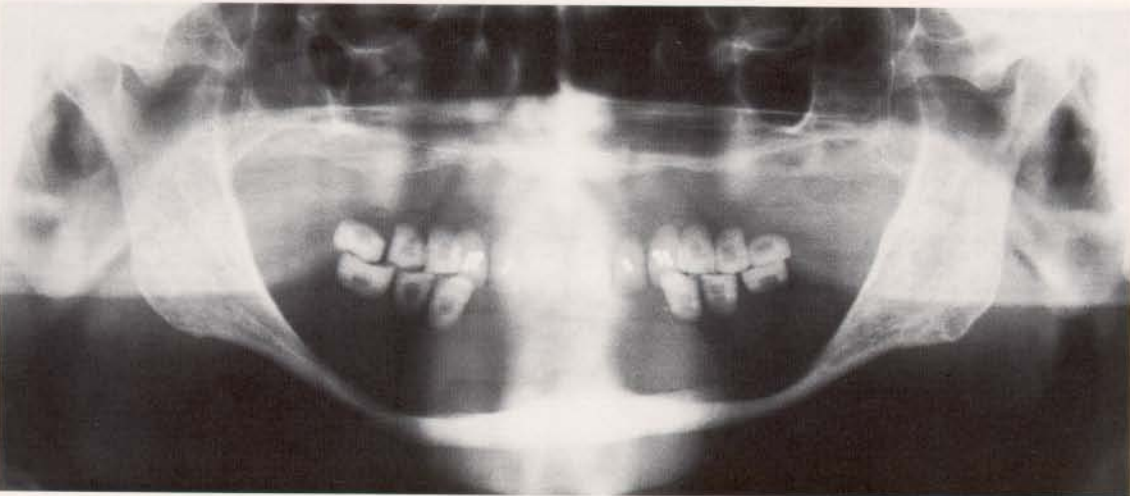
In addition to its supportive functions, the bone also serves as a repository of minerals; as such, it participates in a system for regulating blood content of calcium, phosphates and magnesium, in conjunction with the kidneys and intestines. The normal homeostasis within this system often achieves a negative balance in elderly

individuals, resulting in senile osteoporosis. In conjunction with senile inactivity atrophy of the jaws, this can lead to problems with masticatory function. Such conditions will demand all the skill and knowledge of the dentist in addition to the adaptability of the patient.



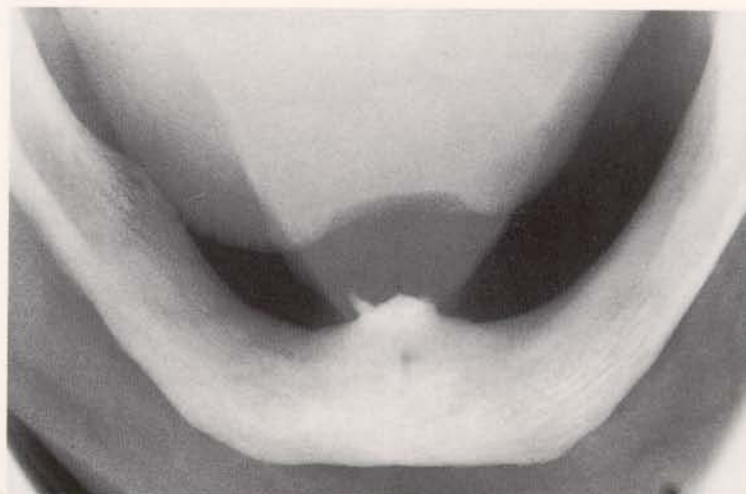
634 Senile osteoporosis in a 93-year-old female

This panoramic radiograph clearly reveals enhanced radiolucency of the jaw, and thinning of the compact bone. The oblique line (represented here by the temporal crest) dominates the picture.



635 Advanced senile osteoporosis and atrophy

This panoramic radiograph of a 79-year-old male reveals the thinned profile of mandibular bone. Both ascending rami exhibit spotty areas of osteoporosis as well as thinning of the compact bone, except for the oblique line, which remains clearly visible.



636 Same cases as viewed axially in an occlusal radiograph

The width of the "prosthesis bed" is well depicted in the occlusal radiograph. Note the thin appearance of the bone. Ossification of the muscle insertions sometimes leads to the mental spine appearing as an exostosis with spur-like projections.

Bone Marrow Islands and Incorrect Interpretations

In patients older than 40 years, especially females, radiolucencies are commonly observed apical to the premolar-molar area in the mandible and at the angle of the mandible. They exhibit poorly demarcated boundaries and are poor in trabeculation. Such features represent bone marrow islands, and can provide difficulty in differential diagnosis (metastases).

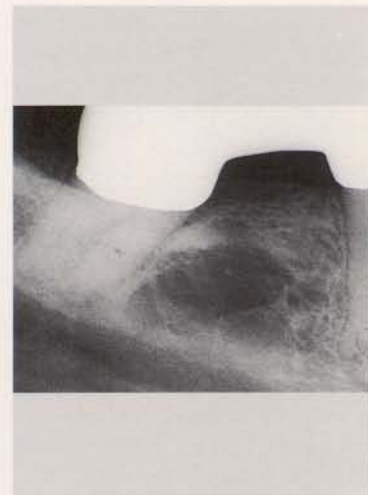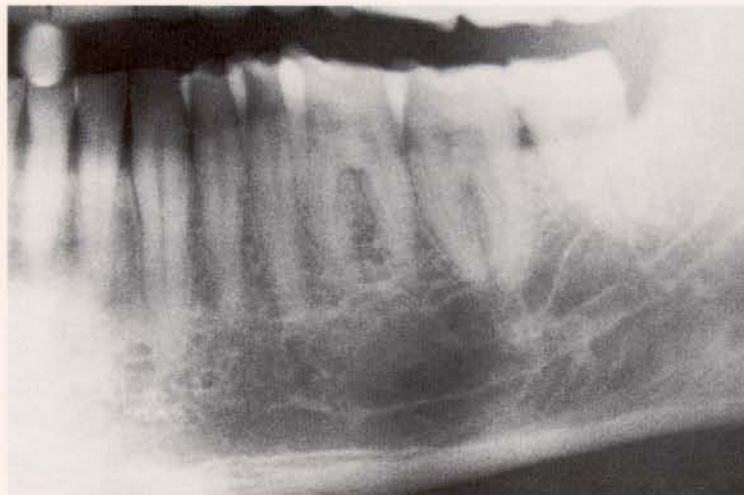The radiographic addition effect caused by the base of the tongue and the soft palate can result in a “technically-elicited radiolucency” at the angle of the jaw. Surgical defects and depressions in the bone may also lead to radiolucencies and to incorrect interpretation when viewed in periapical radiographs.

637 Bone marrow island

The poor trabecular structure in this area also compromises the visibility of the roof of the mandibular canal. The “defect” often appears to enlarge following tooth extraction.

638 Bone marrow island

Periapical radiograph after extraction of teeth 46 and 47 (right).

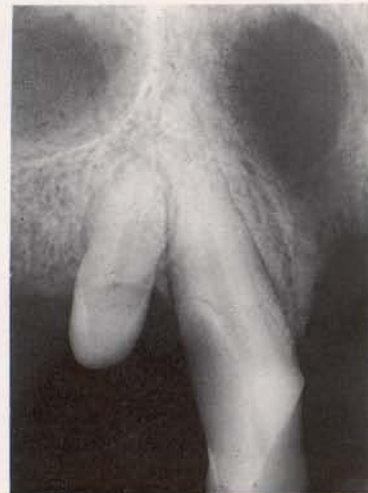
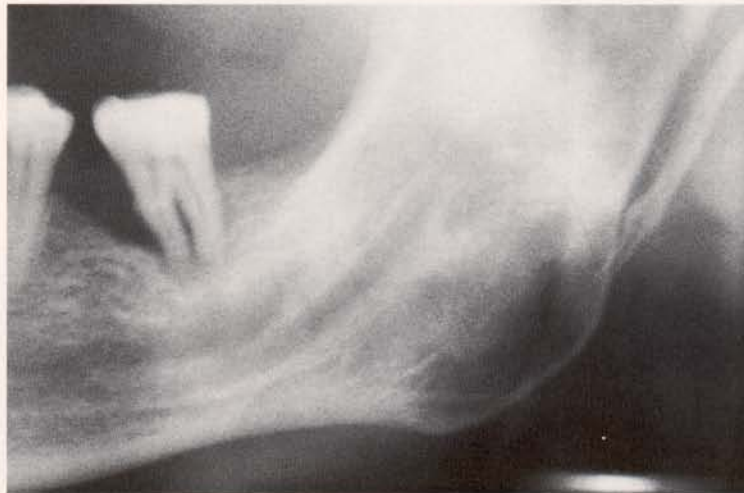
639 Bone marrow island at the angle of the mandible

The oval radiolucency at the angle of the jaw represents a rarified trabecular structure and decreased thickness of the bordering compact bone.

640 Apparent tunnel defect

Tooth 12 was extracted after apicoectomy failed. Note the similar radiographic appearance of the surgical defect (“tunnel”) to the anterior recess of the maxillary sinus apical to the rudimentary premolar.

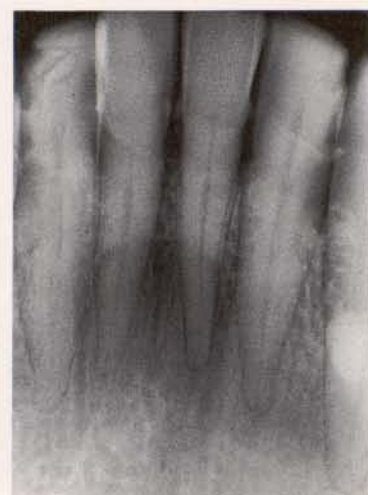
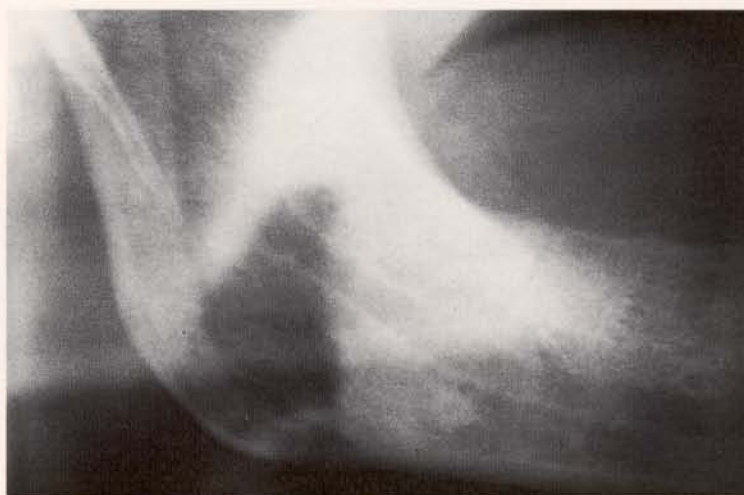
641 Apparent radiolucency at the angle of the mandible, caused by the addition effects of soft tissues

The base of the tongue and the soft palate border this “technically-elicited radiolucency.”

642 Cystoid radiolucency

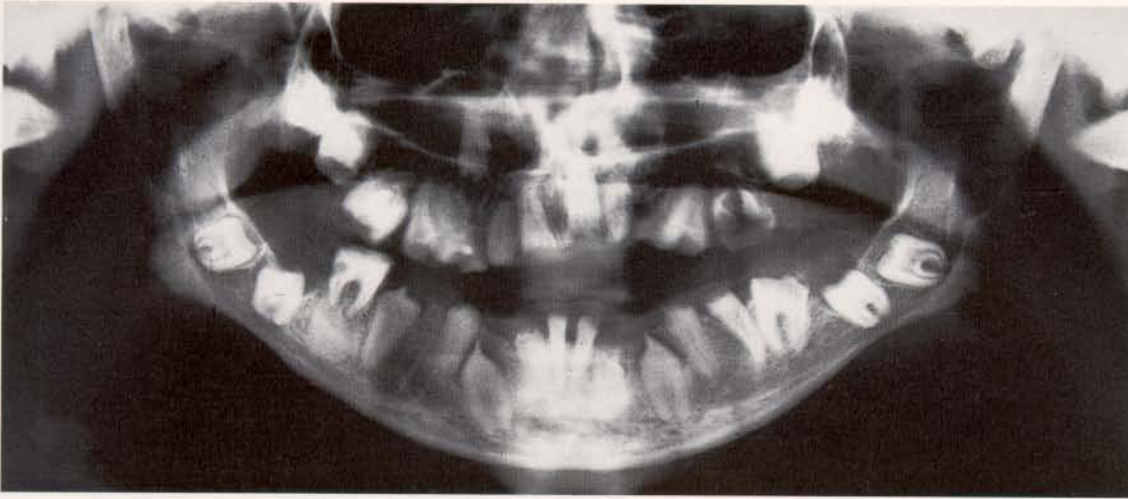
This radiolucency is caused by the mental fovea (right), a depression in the bone, leading to a subtraction effect.



Osteogenesis Imperfecta and Osteopetrosis

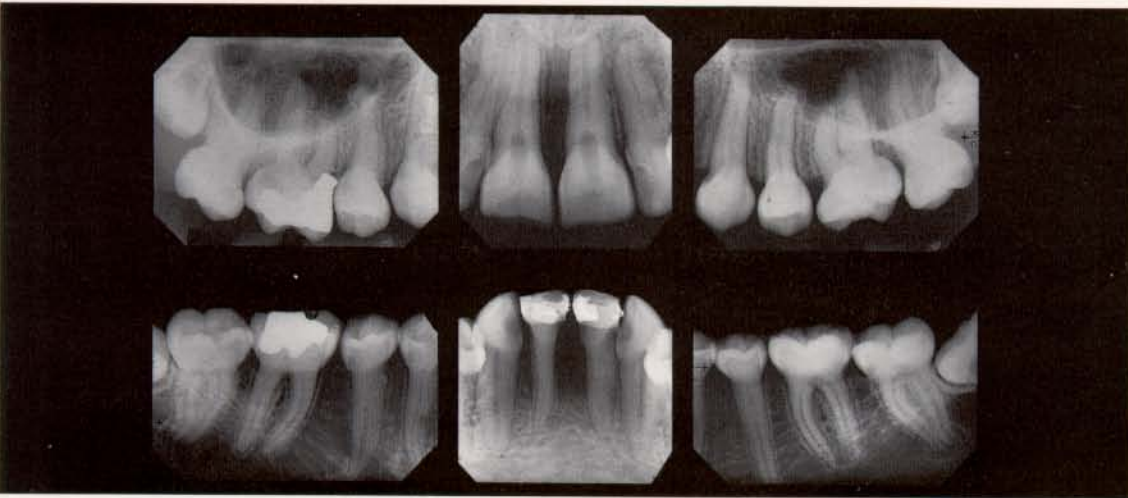
The congenital dysfunction of bone formation caused by genetic inability of osteoblasts and odontoblasts to perform their functions leads to the clinical picture of osteogenesis imperfecta, which is frequently combined with odontogenesis imperfecta. Associated with these conditions in children is an abnormal tendency toward

skeletal fractures. An inherited developmental disturbance of the skeleton may lead to osteosclerosis (osteopetrosis) due to insufficient osteoclastic activity in the bone; this is accompanied by gradual and variable elimination of the marrow spaces, and subsequently leads to anemia and the danger of osteomyelitis.



643 Odontogenesis imperfecta with osteogenesis imperfecta

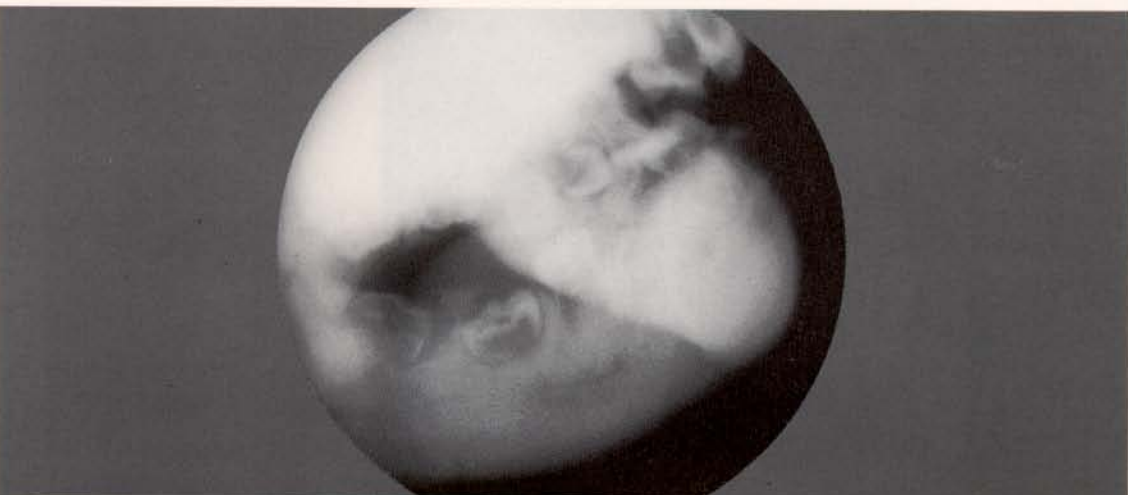Note the numerous retained teeth and obliteration of the pulp chambers.



644 Osteogenesis imperfecta with dentinogenesis imperfecta

In this 14-year-old girl, the 6-film series (Hotz) documents the dentinogenic manifestations. The patient had suffered numerous skeletal fractures.

Courtesy Dr. P. Stöckli, Zurich



645 Osteopetrosis or marble bone disease (Albers-Schönberg)

This disease is inherited as an autosomal dominant trait. Early manifestations in the jaw include a dense sclerosis of the bone with obliteration of the marrow spaces, loss of cortical bone and disturbances of tooth development. This radiograph is from a 1-year-old boy.

Radiographic technique: Lateral mandibular radiograph.

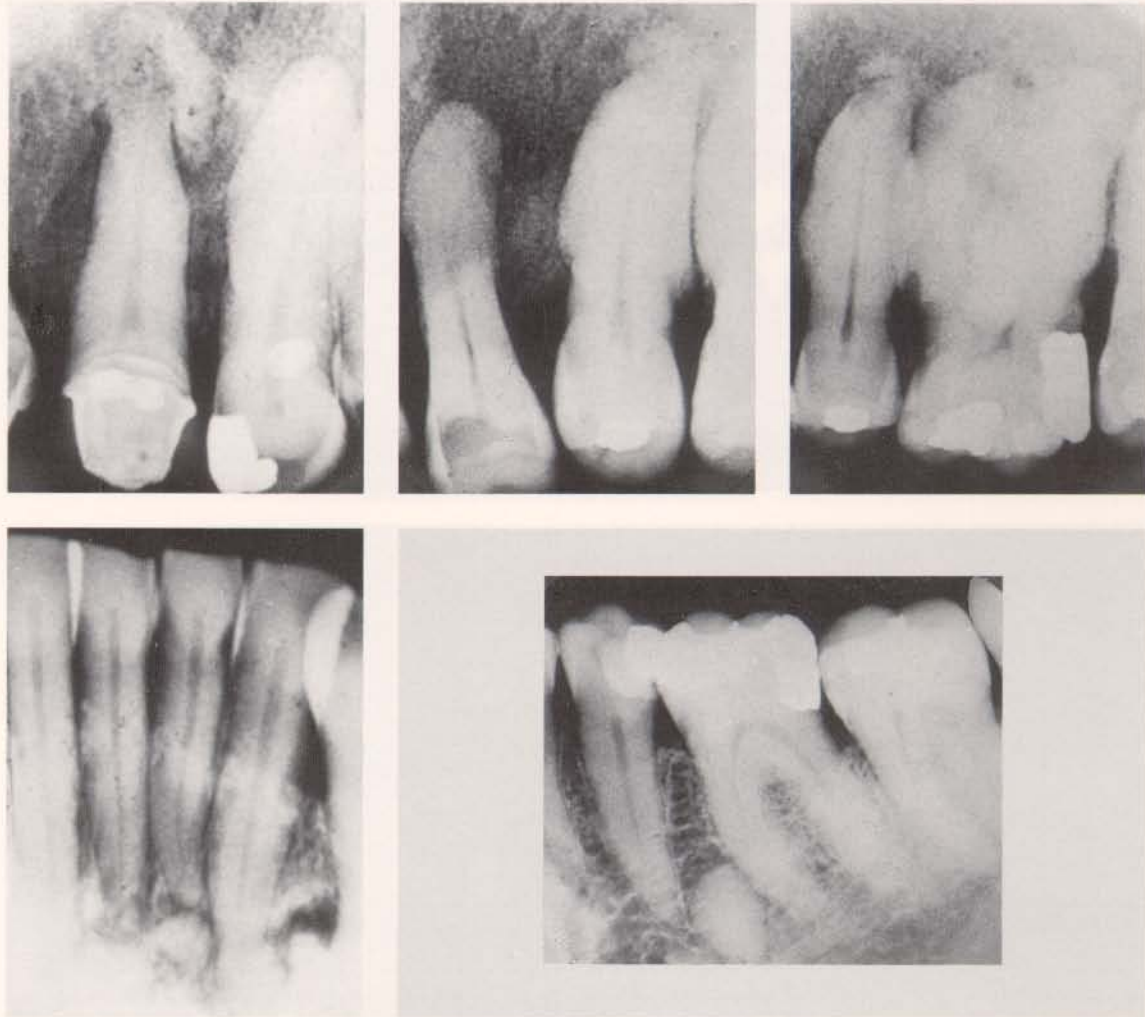
Osteitis Deformans (Paget's Disease of Bone)

This disease, which is most often observed in males in the sixth and seventh decades of life, is of unknown etiology. It usually occurs polyostotic, affecting primarily the vertebrae, the thigh and the roof of the skull, and less frequently the base of the skull. In only about 20% of

cases are the jaws affected. In early stages, diffuse osteolysis can be seen, which is soon followed by osteoblastic phases. Later the cotton wool-like densities predominate, and eventually become confluent. In mild cases the teeth may exhibit only hypercementosis.

646 Osteitis deformans (Paget's disease)

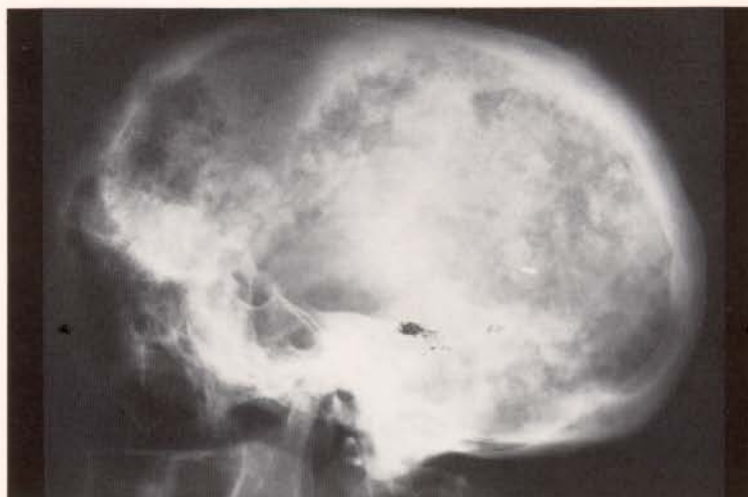The periapical radiographs from a full series depict the typical cotton wool effect around the teeth, with irregular radiolucencies resembling circumscribed osteoporosis. In its second stage, this disease is characterized by spotty and round radiopacities that slowly become confluent. About 1% of cases exhibit a tendency toward development into osteosarcoma.



647 Osteitis deformans (Paget's disease)

This lateral skull radiograph depicts typical findings, with significant thickening of the entire roof of the skull and its base.

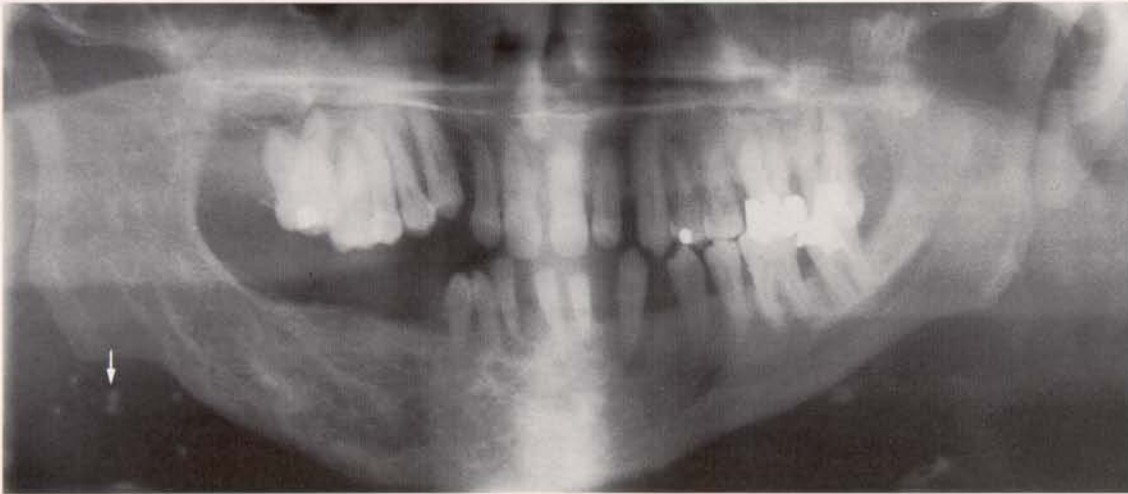
Courtesy Dr. M. Galanski and Dr. P. E. Peters, Münster



Hemangioma

Central hemangioma of the jaw is rare, but when it does occur it is more frequently observed in the mandible than in the maxilla, and females are more frequently affected. The radiographic picture of hemangioma can vary widely. One may observe soap bubble-like

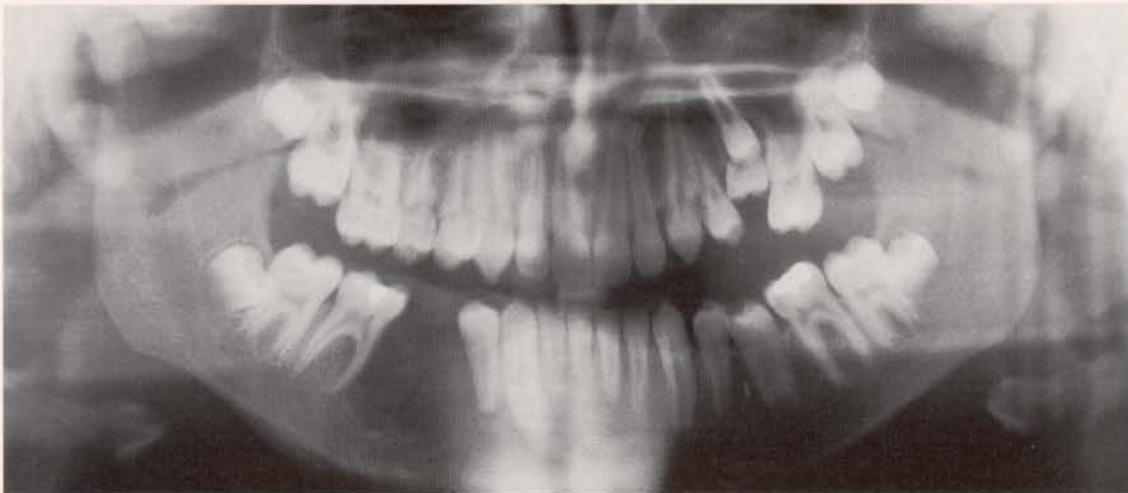
appearances, calcifications, osteolysis, radiating forms and abnormal bony structures with deformation of the cortical plate. These lesions are poorly demarcated. Sometimes phleboliths can be observed. The diagnosis of hemangioma can be verified using angiography.



648 Central hemangioma in the right mandible

This hemangioma extends from the semilunar notch to the region of tooth 43. Compare the stranded structure of the bone to that of the healthy side; note also the numerous phleboliths below the angle of the mandible (arrow).

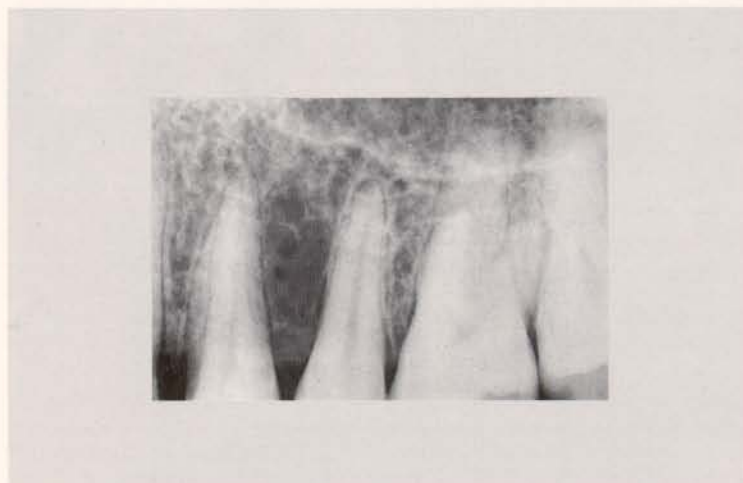
Courtesy Dr. E. Steinhäuser, Erlangen



649 Central hemangioma in the region of tooth 45, with osteolysis and poorly demarcated borders

The region of osteolysis appears vaguely demarcated. The compact bone exhibits lamellar reaction of the periosteum and a slight distention.

Courtesy Dr. E. Steinhäuser, Erlangen



650 Small central hemangioma

This periapical radiograph shows quite well the soap bubble-like structure between teeth 24 and 25. The picture is reminiscent of the honeycomb appearance of ameloblastoma. The widening of the periodontal ligament space is evidence of the increased tooth mobility that is detected clinically in such cases. This radiograph is from a 21-year-old female.

Sarcoma *Norman (Paget's Disease of Bone)*

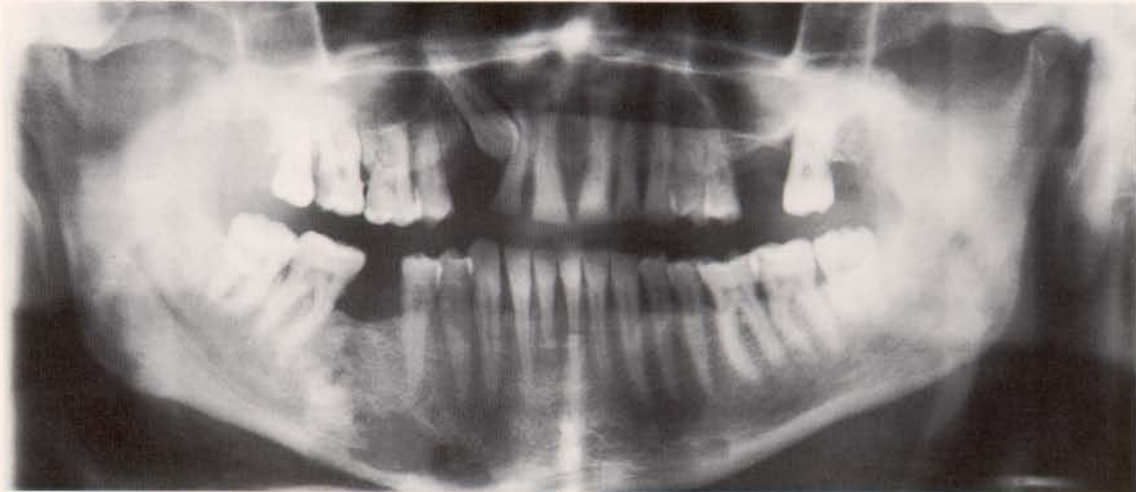
emolgnamoh

This tumor, which affects males twice as frequently as females, exhibits a predilection for the mandible, where it frequently occurs in an osteoblastic-osteolytic mixed form of the osteogenic sarcoma. Sarcoma may destroy the mandibular canal, as does infiltrative carcinoma or osteomyelitis. Paresthesia is therefore a leading clinical

symptom. Radiographically, bone destruction as well as new bone formation and osteolysis can be observed, along with perforation of the compact bone with spicules ("sunray effect") where the lesion borders on the soft tissues.

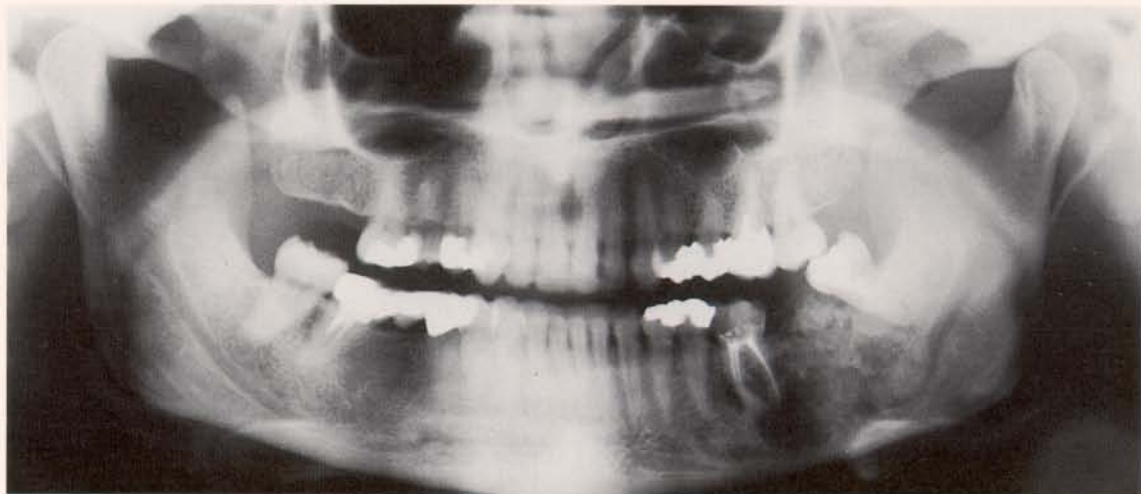
651 Osteosarcoma

Clearly visible are the irregular areas of osteolysis and serrated osteoblastic new bone formations at the extraction site of tooth 46, in this 50-year-old male.



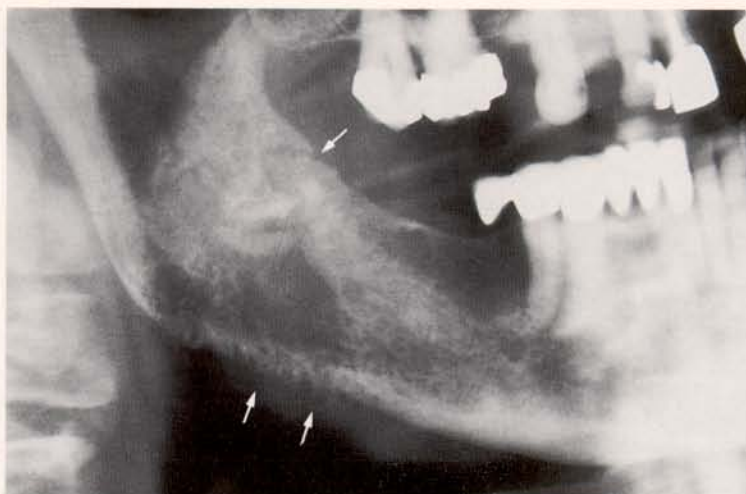652 Osteosarcoma

A mixed form of osteosarcoma has developed at the extraction site of tooth 37. In addition to osteolysis, this panoramic radiograph of a 38-year-old female also exhibits irregular and spotty ossifying new bone formation overgrowing the alveolar crest.



653 Osteosarcoma

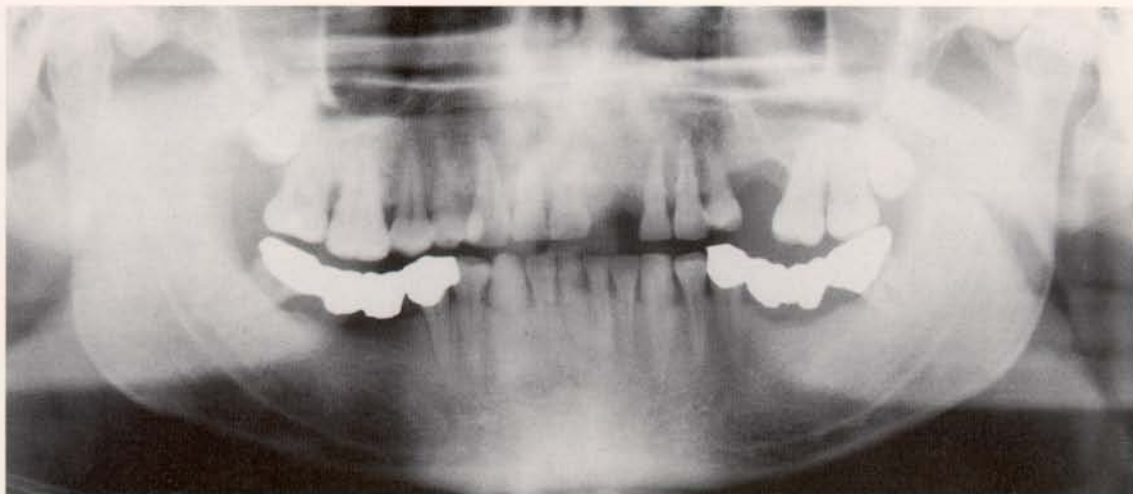
Mixed form. In addition to areas of new bone formation, osteolysis and destruction of the compact bone can be observed. Note the formation of spicules (arrows) and spontaneous fracture (arrow).



Courtesy Dr. K. Weibel, Baden

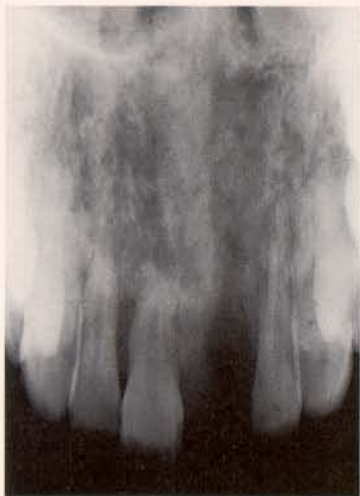Malignant tumors usually occur as solitary lesions and frequently metastasize to the lungs. Such tumors may also develop from otherwise benign tumors, which undergo malignant transformation secondarily. The tumor depicted on this page is an osteogenic osteoblastic sarcoma of the maxilla, which most probably developed as a malignant transformation from an osteo-

chondroma. It is therefore important that any unclear opacity observed in the region of the anterior nasal spine in a panoramic radiograph must always be verified by means of occlusal radiographs and a lateral cephalometric film to detect any structural alterations or abnormal growth.



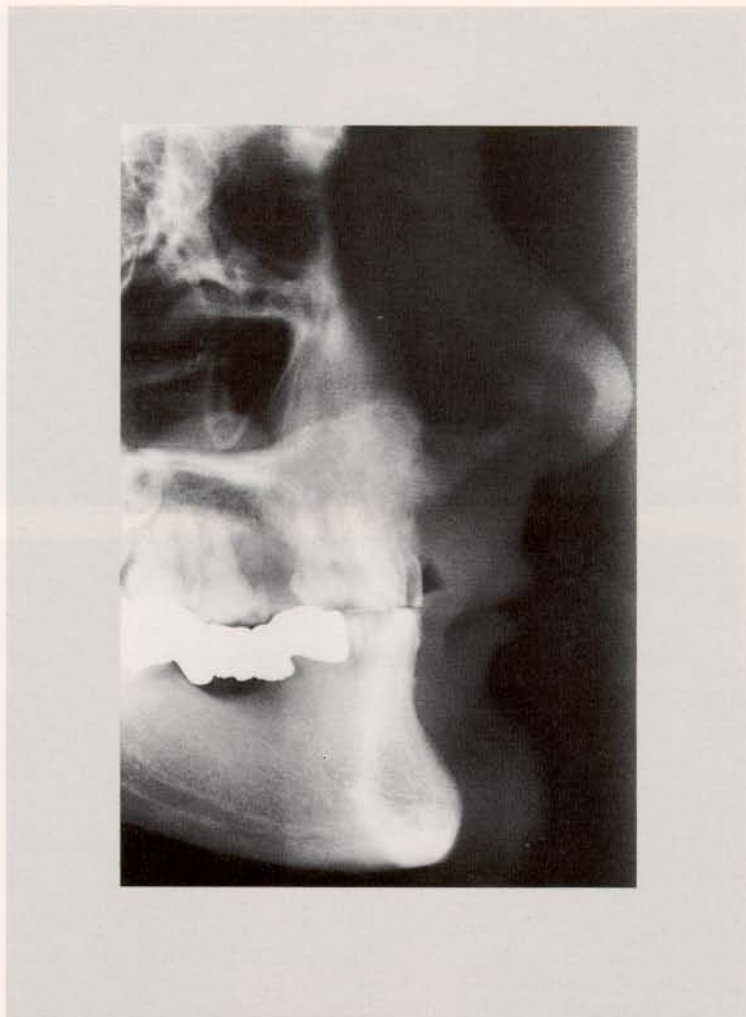
654 Osteosarcoma in the anterior segment of the maxilla

The tumor, which occurred in the same region where osteochondroma is commonly found, is depicted in this panoramic radiograph only as an unclear opacity near the anterior nasal spine in this 40-year-old male.



655 Osteosarcoma seen in an occlusal radiograph (same case)

This film makes it abundantly clear how all anatomic structures can be destroyed by the tumor's tendency to proliferate rapidly. The picture is one of an uneven, moth-eaten structure.



656 Osteosarcoma of the maxilla (same case)

This lateral cephalometric radiograph reveals the bulbous form of an irregularly structured and poorly demarcated radiopacity.

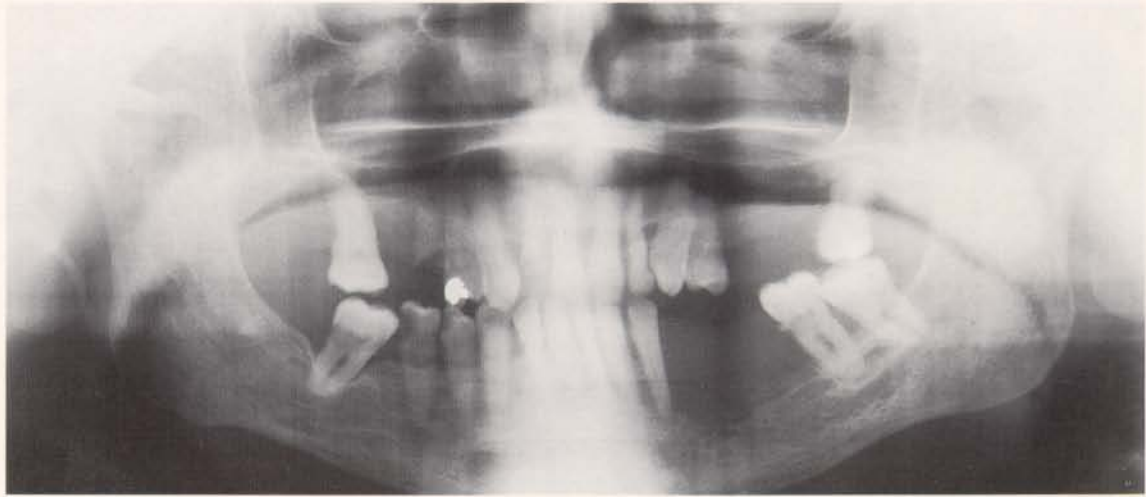
Carcinogenic Invasion

In contrast to benign lesions, malignant tumors do not displace teeth; this is because these tumors grow rapidly and invasively. Loss of the lamina dura and widening of the periodontal ligament space may anticipate tumor growth around the tooth before any other radiographic signs become apparent. In addition to the formation of

defects, irregular osteolysis is also typical in contrast to the normal structural characteristics of bone; affected bone has a moth-eaten appearance with undermining. Destruction of the mandibular canal and the mental foramen is readily seen on radiographs; such destruction often leads to the clinical paresthesia.

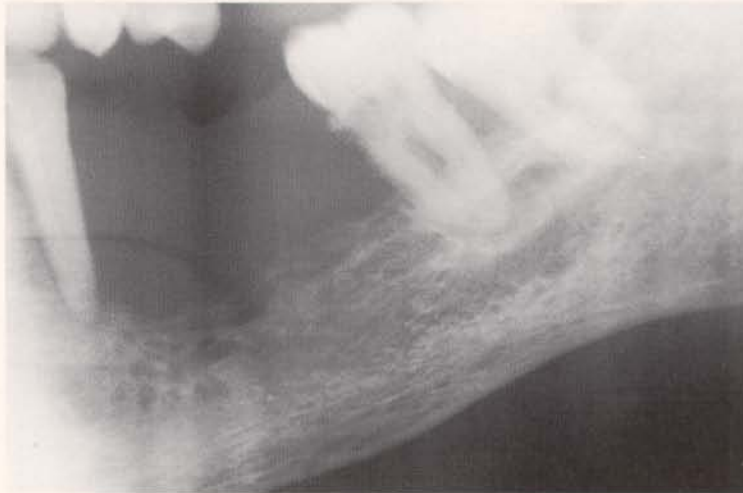
657 Invasive carcinoma of the mucosa of the floor of the mouth

The region of teeth 34, 35 and 36 exhibits an osseous defect with spotty osteolysis in the body of the mandible. A superficial observation without knowledge of the clinical situation may lead to a premature and incorrect diagnosis of "marginal periodontitis, terminal stage."



658 Section from a panoramic radiograph of the same case

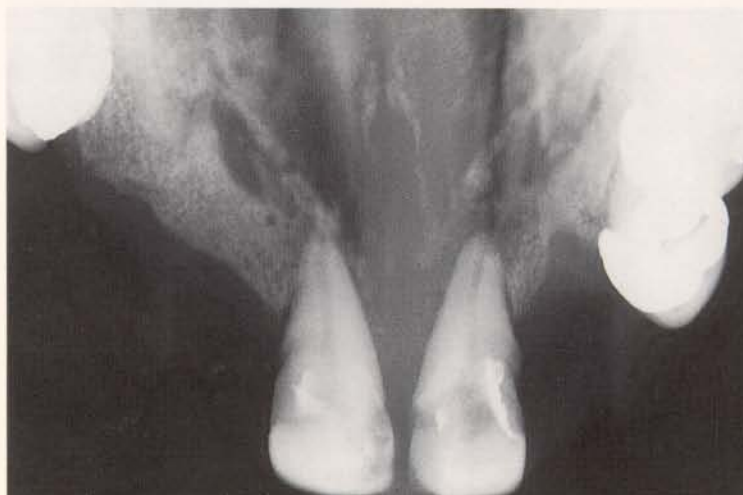This picture shows destruction of the mandibular canal and the mental foramen. The compact bone has a wispy appearance, yet without sclerotic reaction. Distal to tooth 33, the bone has a moth-eaten appearance.



Courtesy Dr. K. Weibel, Baden

659 Invasive carcinoma of the palatal mucosa as seen in an occlusal radiograph

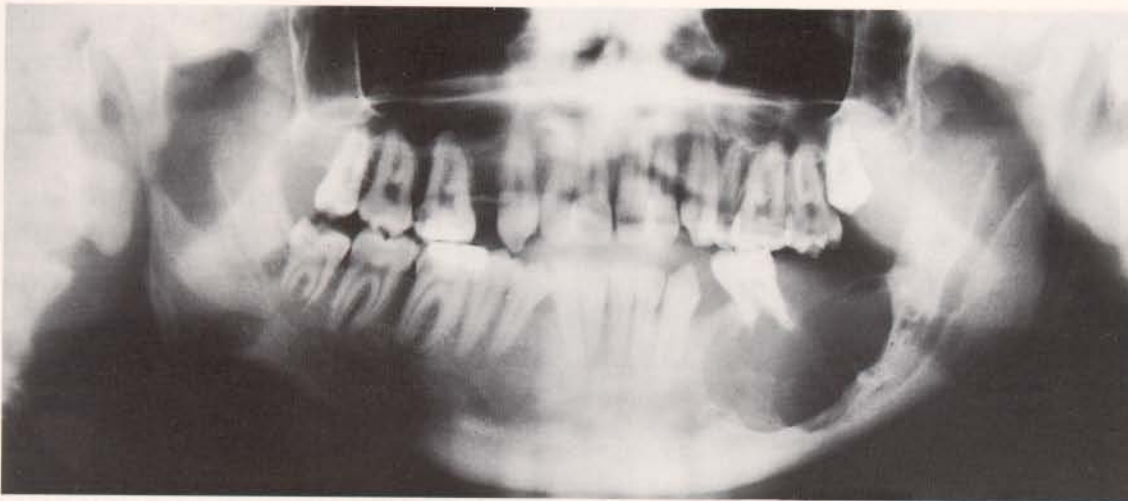
The tumor has destroyed virtually all normal anatomic structures in the anterior segment of the maxilla. The central incisor teeth appear to "hang" within the region of osteolysis. While benign lesions often displace teeth (an exception is the eosinophilic granuloma), teeth maintain their normal positions even in the face of aggressively proliferating malignant tumors.



Mucoepidermoid Tumor

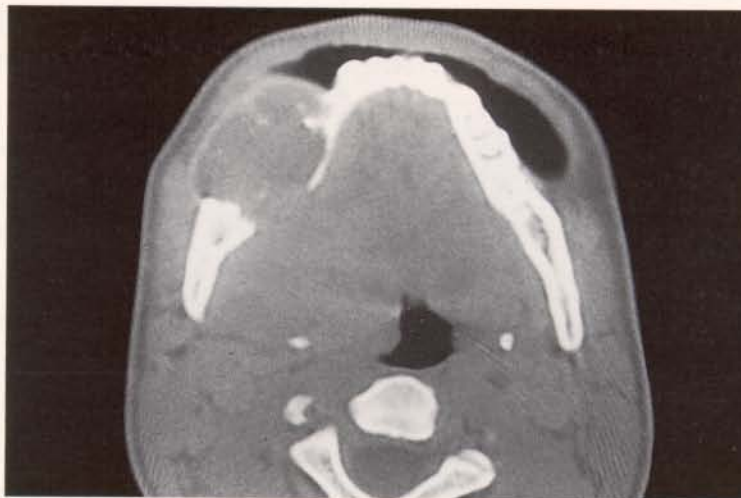Even though it is not classified either in the group of odontogenic tumors or as a mesenchymal tumor of the jaw, the mucoepidermoid tumor is presented here to illustrate another situation where a tumor possesses the capacity to invade tissues in the jaw regions. This tumor may infiltrate into the jaws from the major and minor salivary glands, and may elicit clinical and radiographic

signs of either benign or malignant growth. Radiographically, the mucoepidermoid tumor may imitate various types of cysts and tumors. The mucoepidermoid tumor occupies a high position in the differential diagnosis, and this demonstrates once again the problems associated with specific radiographic diagnosis.



660 Mucoepidermoid tumor, radiographic appearance of benign lesion

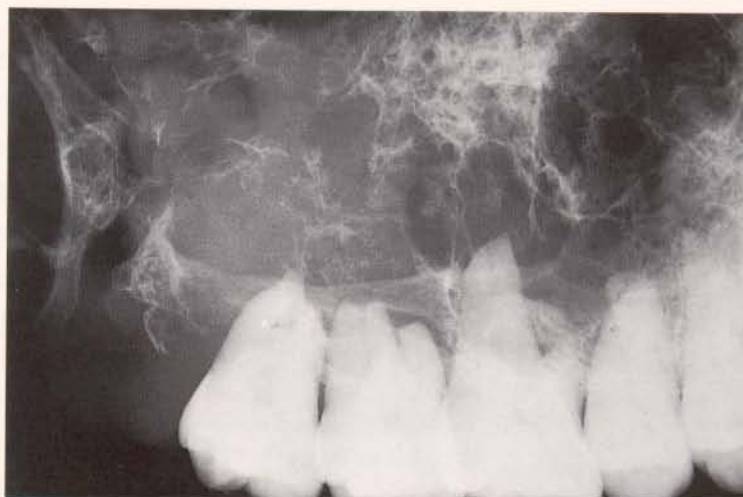Soap bubble-like radiolucency with lobulated borders. Such lesions may be mistaken for ameloblastoma or giant cell granuloma.



661 Mucoepidermoid tumor as seen in an axial CT with bone window

In this view it is clear that the "cavity" is filled with soft tissue.

Courtesy Cantonal Hospital of Lausanne



662 Mucoepidermoid tumor with clinical and radiographic characteristics of malignancy

This radiograph is reminiscent of that seen with a myxoma (p.203), but depicts the undermining and infiltrative growth that is characteristic of malignancy.

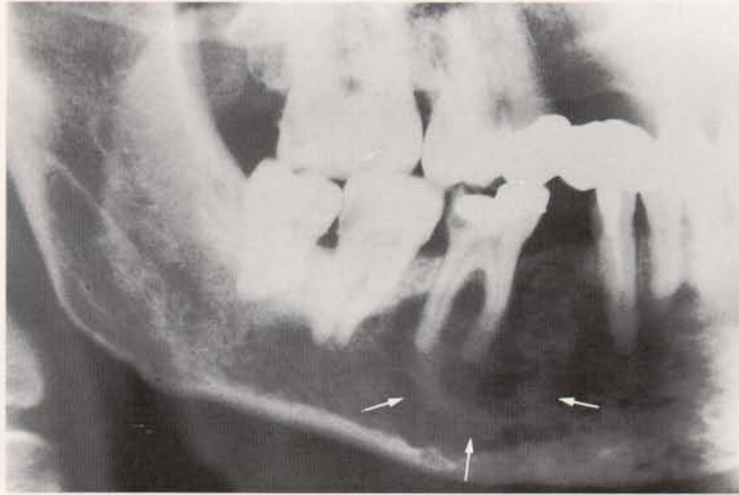
Metastases

Metastasis is the satellite of a primary tumor and exhibits identical histologic characteristics despite the different anatomic location. Because metastases often remain clinically symptom-free for long periods of time, they may achieve considerable size and, before the era of panoramic radiography, were often discovered only

after a spontaneous fracture occurred. Typical radiographic signs are the moth-eaten appearance or spotty osteolysis with poorly demarcated and undermined borders; on the other hand, calcifications typical of these tumors may also occur. The mandible is affected four times more often than the maxilla.

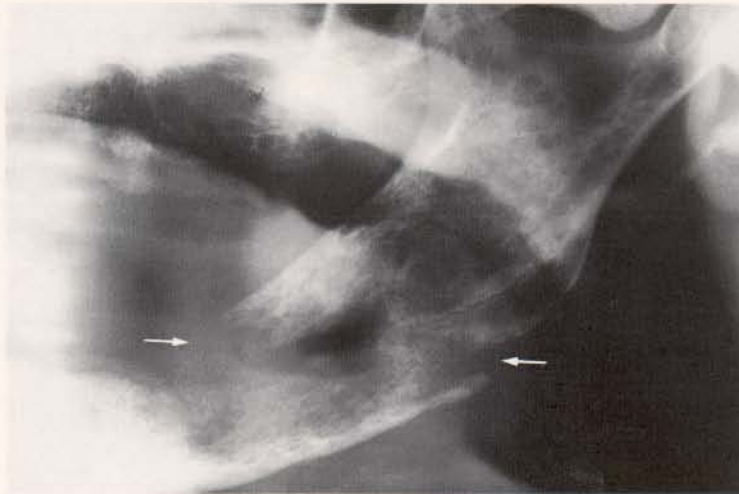
663 Metastasis from a mammary carcinoma

Growth of this tumor within the mandible led to destruction of the lamina dura and to expansive osteolysis with indistinct boundaries. The areas of calcification (arrows) are pathognomonic for mammary carcinoma.



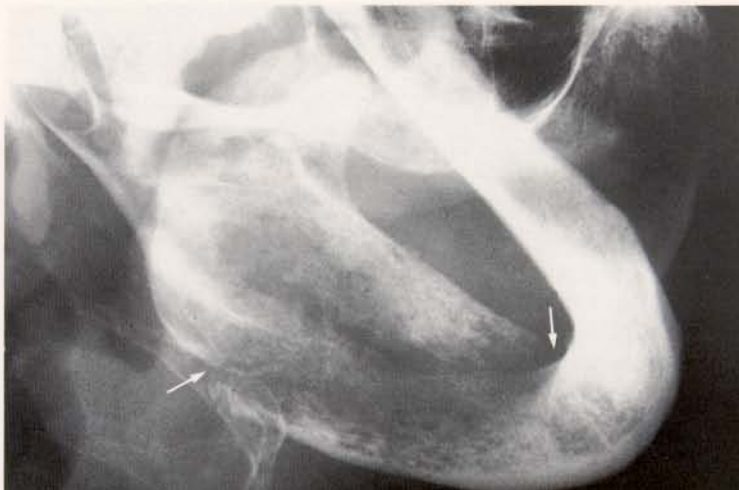664 Metastasis from a bronchial carcinoma, with pathologic fracture

Destruction of the bone extends from the mental foramen up to the semilunar notch and has led to almost total destruction of the mandibular canal. Note the spontaneous fracture (arrows).



665 Metastasis from a bronchial carcinoma, with pathologic fracture

Note the moth-eaten appearance of osteolysis in this lateral oblique projection of the mandible. Note also the spontaneous fractures (arrows).



Traumatology

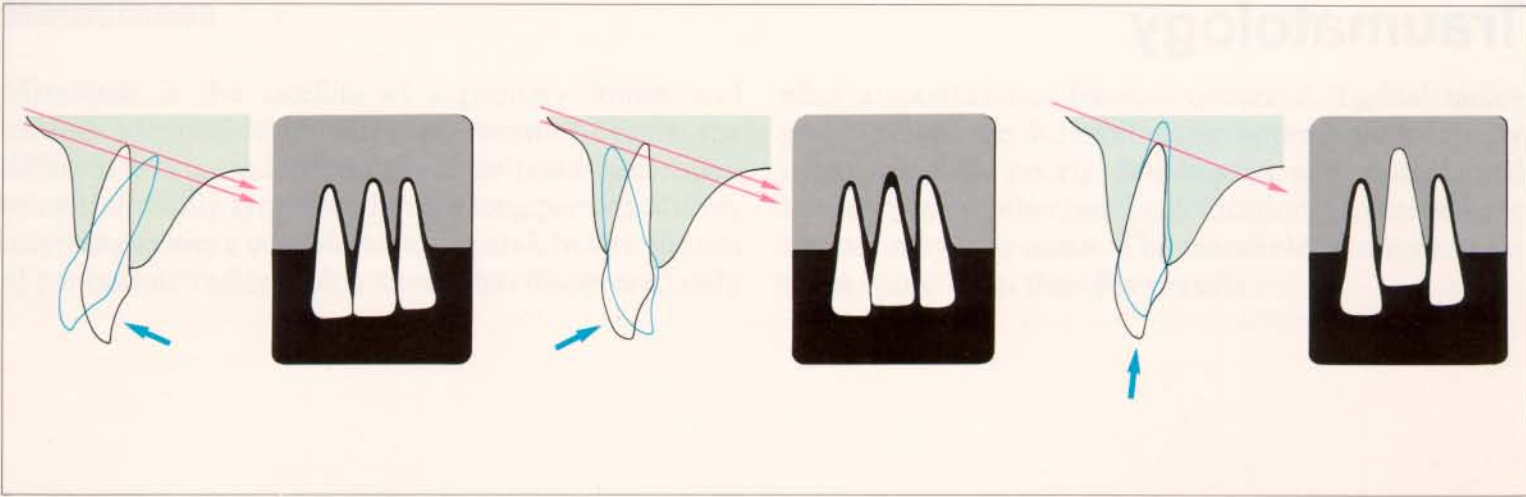
Radiography plays a particularly important role in traumatology. It must satisfy various demands because in such cases it is not only a mechanism for data collection, it also serves to provide documentation for the patient, the physician and other care providers. Forensic indications may also be of importance, as well as protection of the patient from excessive radiation exposure.

Dental radiology is important even for seemingly minor accidents, because such incidents are often followed by unexpected delayed consequences that must eventually be reported to insurance companies. It is worthy of note that fracture lines, regardless of their localization can only be diagnosed with certainty in the radiograph when the line of fracture is parallel to the central X-ray beam or when a dislocation is clearly revealed by the film.

Even if standard radiography does not provide clear evidence of a fracture, this is no guarantee that no fracture exists. The dentist is wise to remember that even in cases of apparently uncomplicated dental accidents in children, panoramic radiography should be employed in an attempt to identify fractures of the articular process of the mandible and greenstick fractures that are difficult to detect clinically; these must be recognized and documented for insurance purposes. Only in this way can incorrect interpretations that may lead later to tooth loss or growth disturbance be precluded. In general, to detect suspected fractures of teeth or condyles the panoramic radiograph is taken in the usual manner; however, in cases of dislocation radiographs taken with the patient in maximum intercuspation are recommended. Dislocations can be expected, especially in the mandible, not only due to the accident itself but also due to secondary muscular tension; such situations are not always readily apparent in panoramic radiographs due to the superimposition effects in the third dimension. Because such third dimension situations often provide unanswerable questions, additional radiographs with various projection angles are obligatory. Furthermore it is wise to note that appropriate soft tissue techniques should be used to search for splinters of glass (pp. 68 and 88). The vitality of traumatized teeth must be tested for at least a 6-month period to ascertain any delayed consequences.

The automobile accidents that are so frequent today often provoke multiple injuries. Polytraumatized or unconscious patients often cannot be effectively examined with conventional methods during initial examination because of problems of positioning. This often makes it necessary to refine and improve the data collection during a second examination. Computed tomography, which can be used successfully to portray injuries in the depth of the facial skeleton, and the Zonarc (p. 23), have provided new diagnostic possibilities.

When it comes to diagnosis of facial fractures, only solid basic knowledge of anatomy and of the possibilities provided by modern imaging technology can lead to success in the diagnosis of fractures.

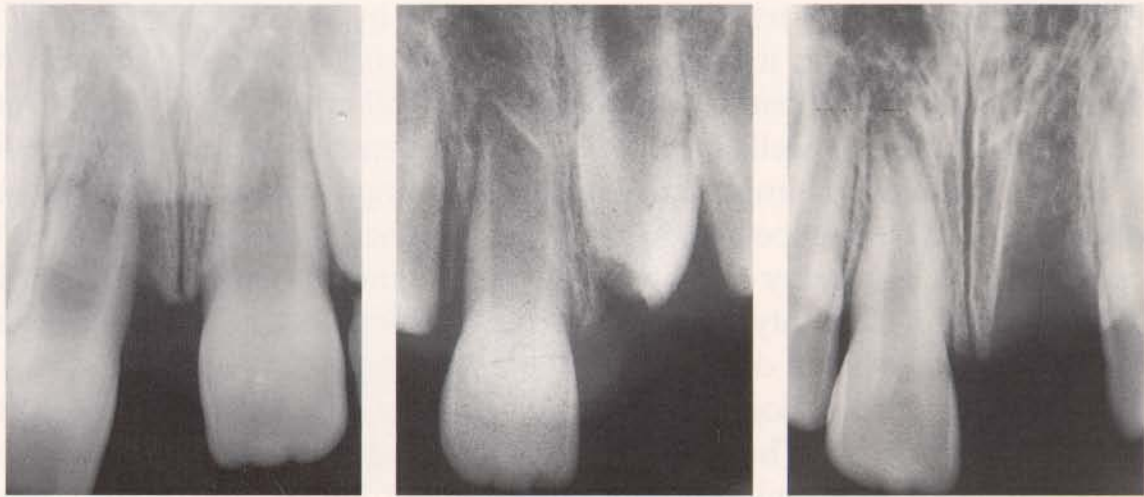


666 Diagram of radiographic signs of subluxation (see text, p. 249)

667 Subluxation of tooth 11, with root fracture

668 Central luxation of tooth 21, with crown fracture

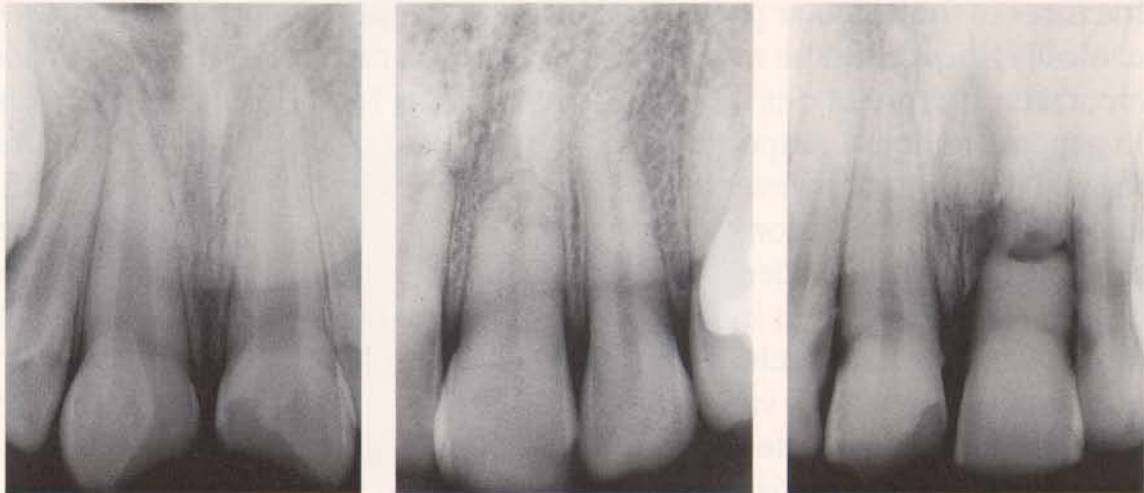669 Subluxation of tooth 11, and complete luxation of tooth 21



670 Crown fracture of teeth 11 and 21, with pulp exposure

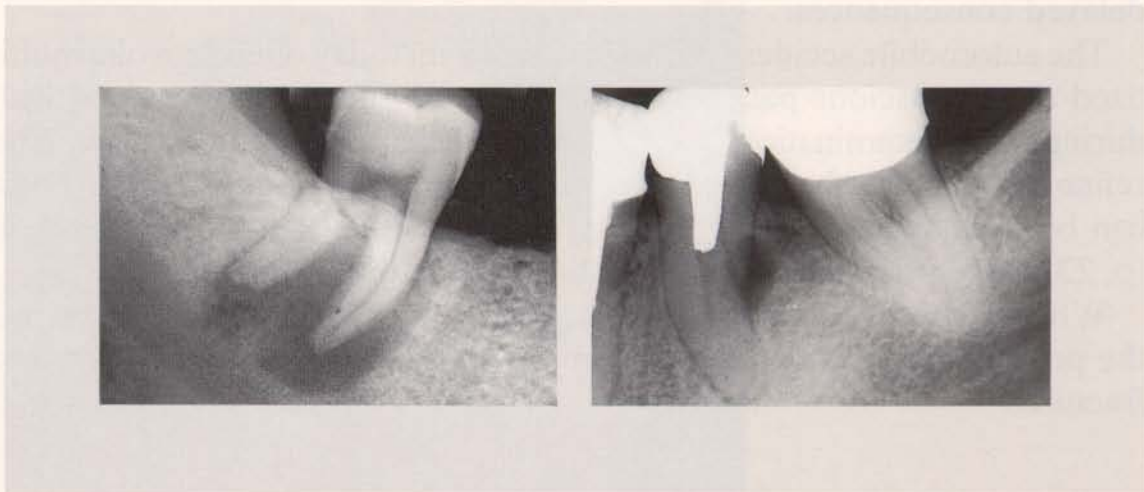
671 Healed transverse root fracture on tooth 21, which remained vital

672 Late result of a transverse fracture of tooth 21, with obliteration of the root canal



673 Late result with a transverse root fracture on tooth 47, which was not diagnosed initially

674 Axial tooth fracture that occurred subsequent to forceful insertion of a post reconstruction



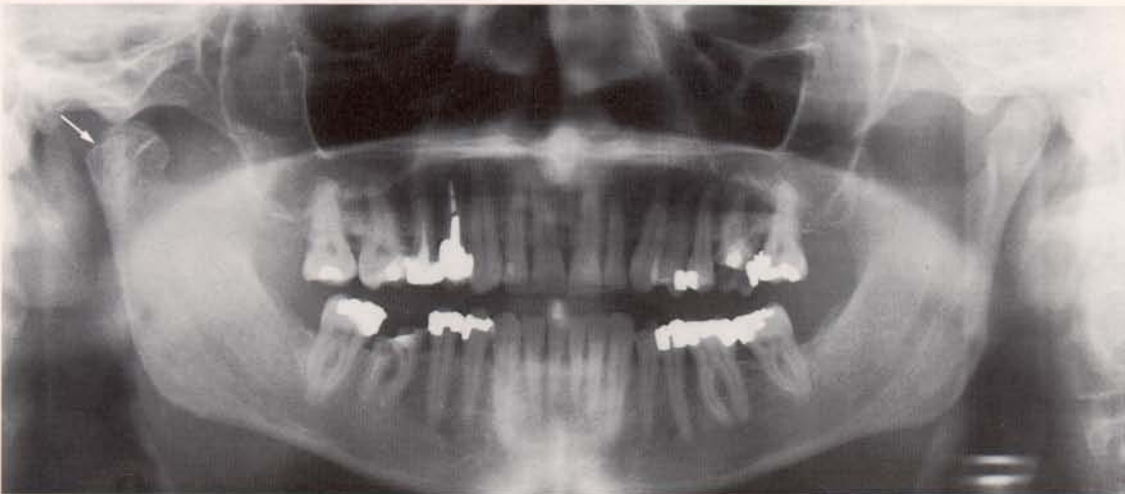
Radiographic Signs of Subluxation

Figure 666 is a diagram of subluxation possibilities of maxillary anterior teeth as well as the normal central ray projection and the results obtained for radiographic documentation. Subluxation in the mandible must be approached with appropriate techniques.

– *Left:* If the tooth crown is displaced vestibularly due to trauma, the root will likely be displaced palatally. Using the normal central ray projection, any subluxation will hardly be detectable radiographically.

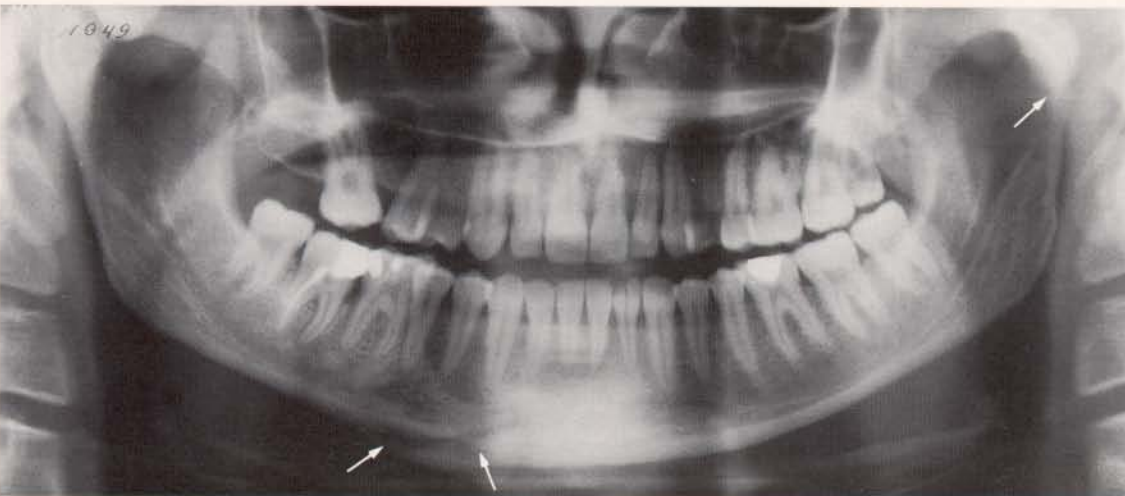– *Center:* If an accident leads to a tooth crown being luxated palatally, the root will be displaced vestibularly. Using normal radiographic methods, the subluxation will be clearly shown.

– *Right:* If an accident causes a tooth to be intruded into its alveolus, the standard radiograph will show the apex of the affected tooth root to be located apical to adjacent teeth. In such cases, the lamina dura and periodontal ligament space are not visible.



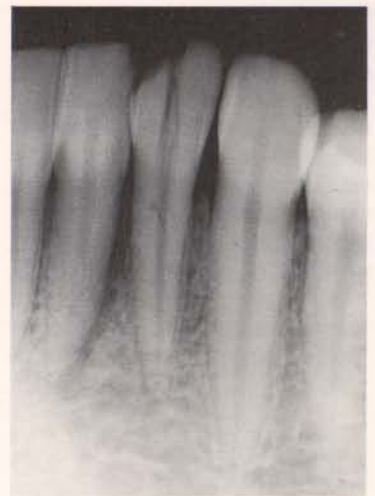675 Crown fracture of 15, 26, 34 and 46; high fracture of the right articular process

Even in a cases of simple tooth fractures one must consider the possibility that condylar fracture has occurred. The fossa on the right side is empty.



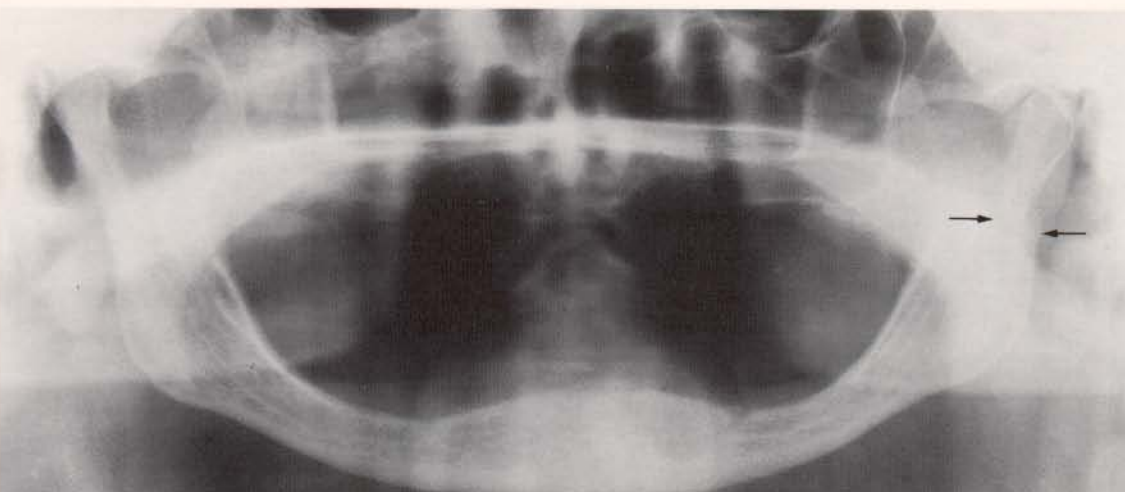
676 Axial fracture of tooth 32, with transverse fracture of the mandible (arrows) and fracture of the left condyle

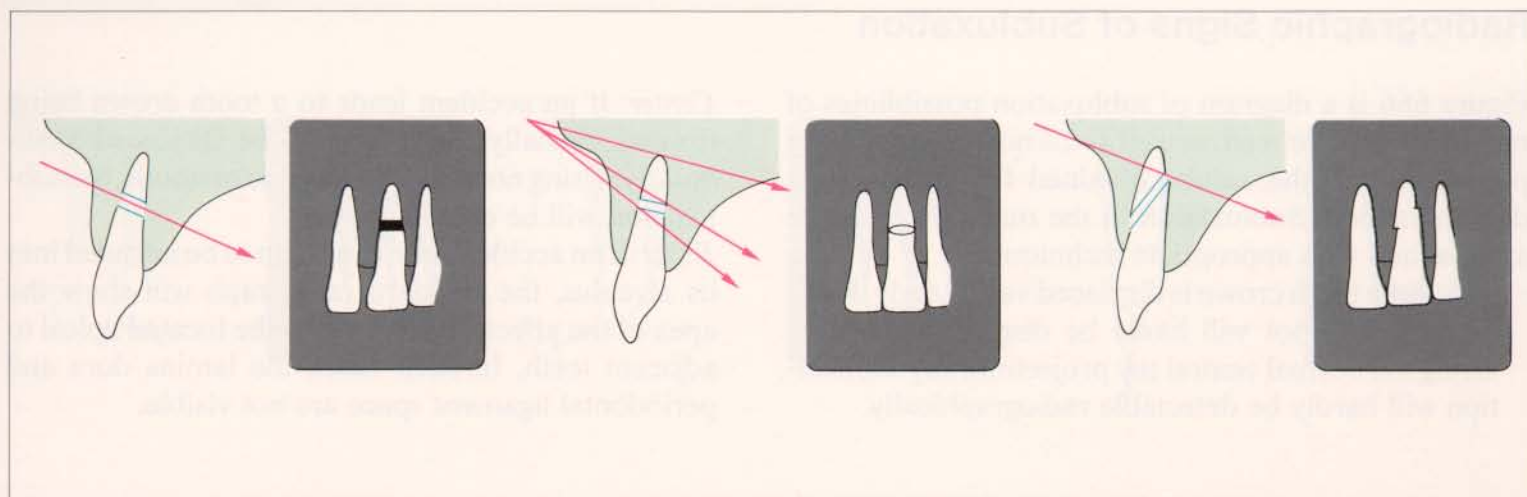
Note the vertical fracture of tooth 32, an oblique mandibular fracture extending from tooth 45 to tooth, and fracture of the left articular process.



677 Deep fracture of the left articular process of the mandible

The condyle is not in its appropriate position, and it is easy to see the step on the dorsal border of the ascending ramus (arrows). Post-traumatic swelling of the soft tissues and the resulting radiographic shadowing can render detection of such fractures of the articular process much more difficult.

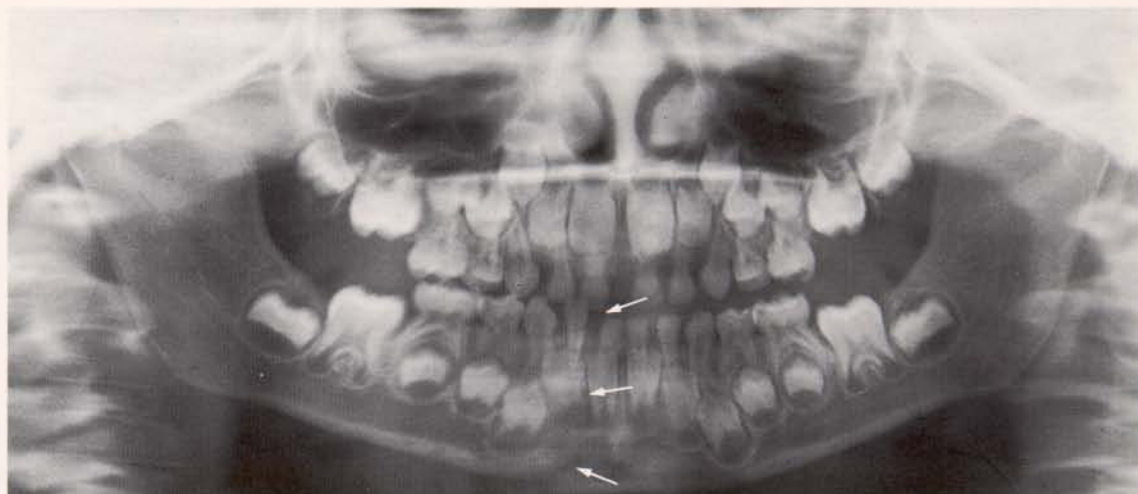




678 Diagram of the radiographic signs of tooth fracture (see text, p. 251)

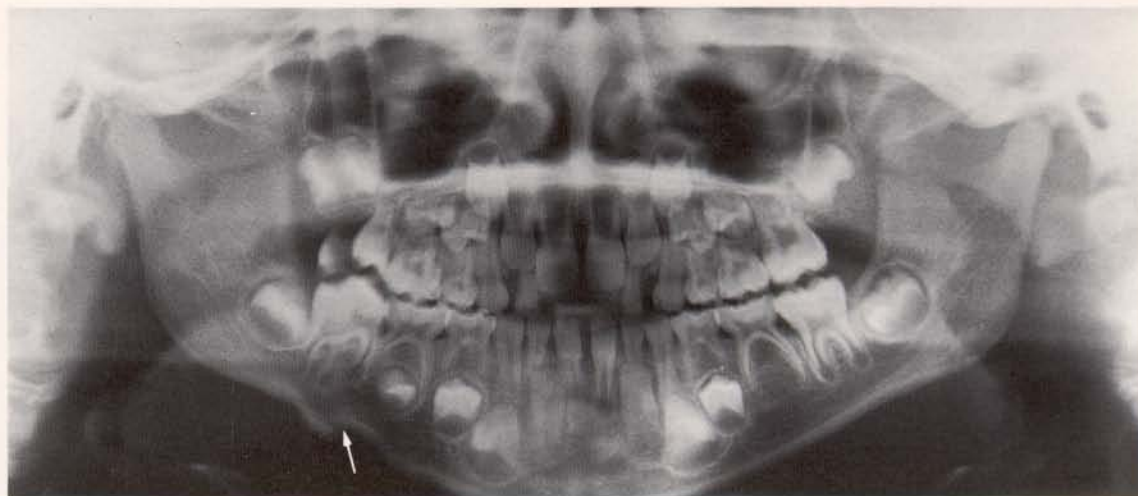
679 Transverse fracture of the mandible

Step formation in the mandibular anterior area, with dislocation of the fragments (arrows) in a 5-year-old female.



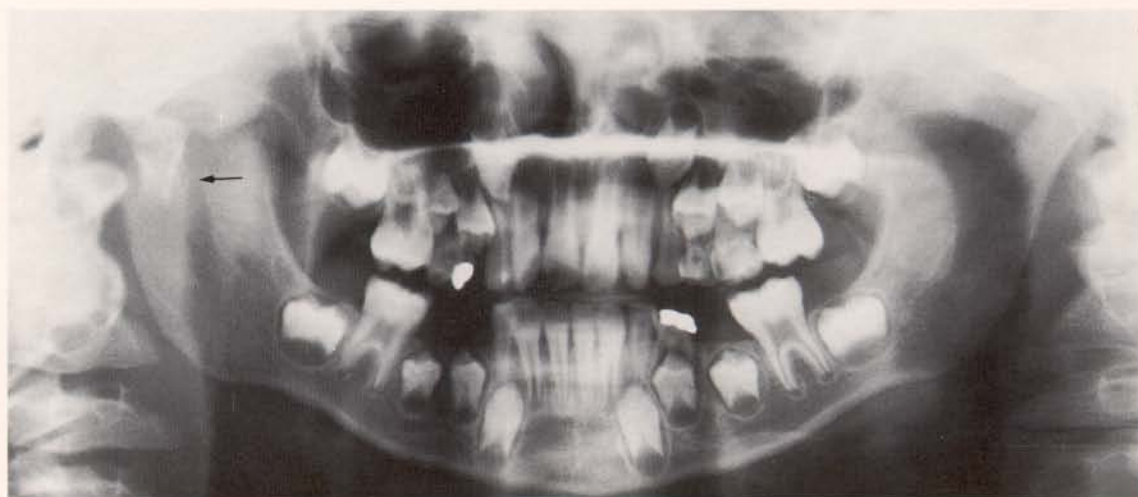
680 Examination of a 6-year-old male following a minor accident

The double appearance of teeth 17, 16 and 46 indicates that the "step" formation of the compact bone is really an artefact caused by movement during the exposure and not a true transverse fracture of the mandible (arrow).



681 Fracture of the neck of the condyle, right (arrow)

Dislocation of a small fragment laterally and anteriorly. Note also that the condyle and the neck of the articular process are not visibly enlarged in this 7-year-old patient.

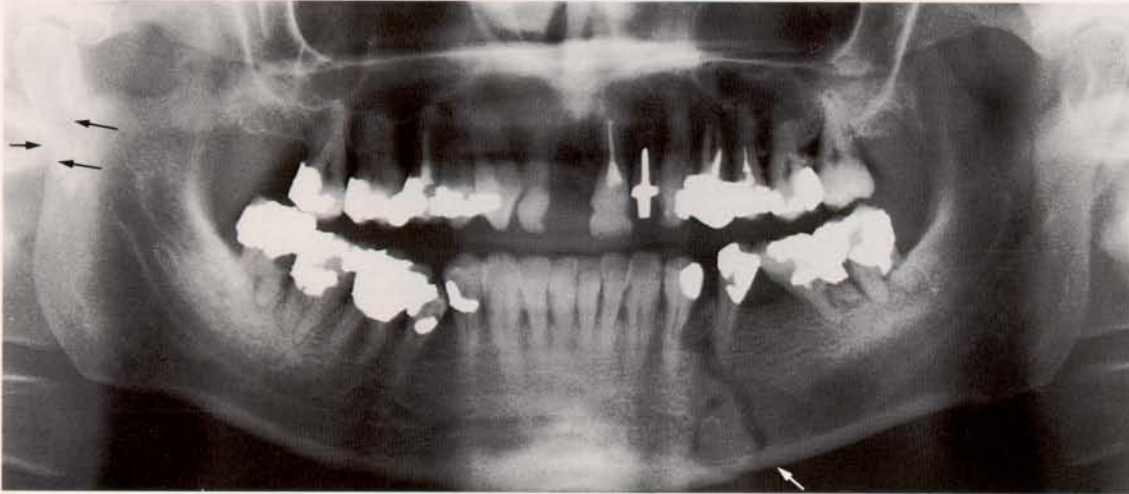


Radiographic Signs of Tooth Fractures

The diagram presented in Figure 678 shows the three most common root fractures of maxillary anterior teeth as well as the result that can be achieved with periapical radiographs using the standard techniques (from *left to right*).

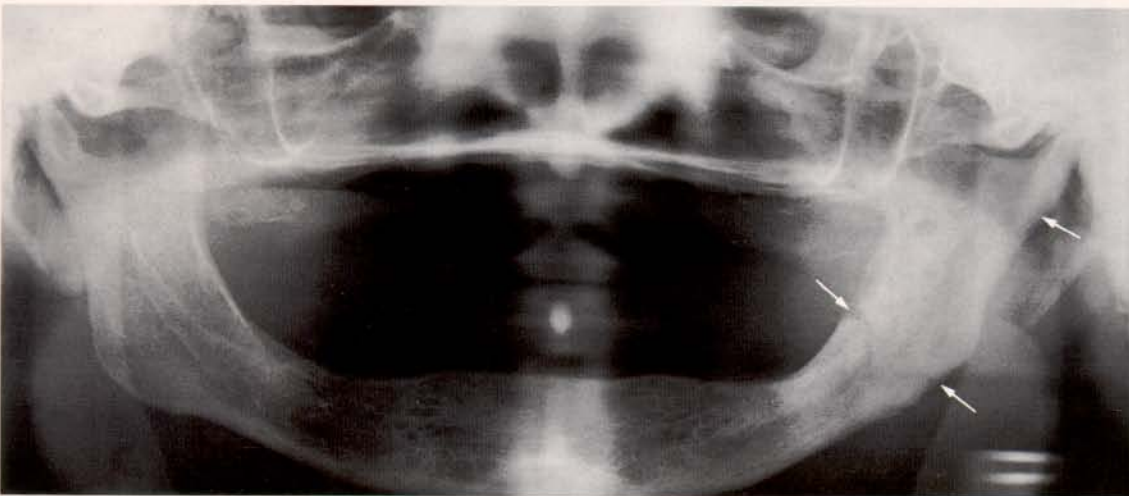
- Only when the central X-ray beam is directed (fortuitously) onto the fracture cleft will it be clearly depicted on the film.
- If the central X-ray projection is directed oblique to the fracture cleft, the film may display several "fracture lines" and therefore simulate a complex fracture.

- Oblique fractures resulting from shearing forces often exhibit only vague radiographic signs. In many cases, only magnification will reveal tiny step formation along the mesial or the distal root surfaces and/or a faintly visible addition effect caused by the superimposed root fragments. Axial root fractures adhere to the same rules: Fractures are only visible on radiographs if the fracture cleft is fortuitously parallel to the central X-ray beam.



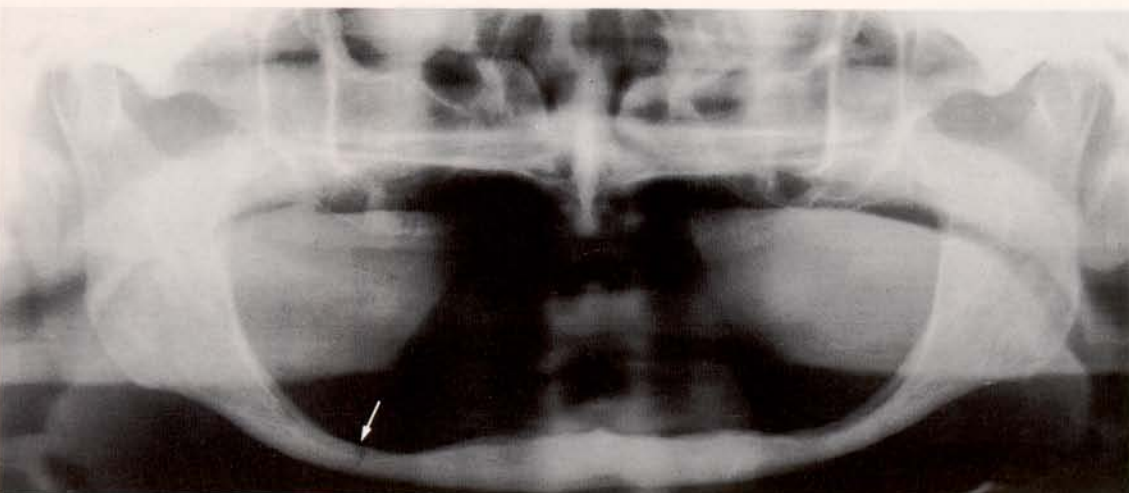
682 Transverse fracture of the mandible, with condylar neck fracture

Superimposed fracture cleft lines (apparent distention fracture) and fracture of the condylar neck of the right side (arrows, with superimposed fragments due to the addition effect).



683 Fracture at the angle of the mandible, with condylar neck fracture on the left side (arrows)

Primary chronic osteomyelitis (so-called fracture cleft osteitis) in the ascending mandibular ramus on the left side. Compare this appearance with the healthy right side. Additional radiographs including the reverse Towne projection with maximum jaw opening are indicated to discern any possible dislocation in such cases.

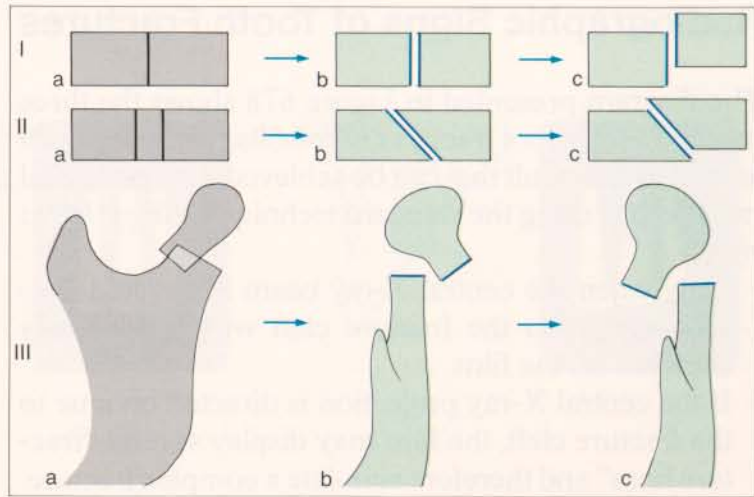


684 Spontaneous fracture of the right mandible

This panoramic radiograph depicts advanced age-related atrophy in a 68-year-old male.

Radiography of Jaw Fractures

The courses of fracture planes, fragment dislocation, and central ray direction determine the radiographic picture. The diagrams of the mandibular body (Ia, IIa) and ramus (IIIa) depict three common radiographic fracture lines (gray). In Ia, the clinical situation may be a smooth, transverse fracture (Ib) or a dislocation (Ic). An oblique fracture (IIb) exists in IIa, which may also be associated with dislocation (IIc). Dislocation of fragments laterally (IIIb) as well as medially (IIIc) exists if the film looks like IIIa.

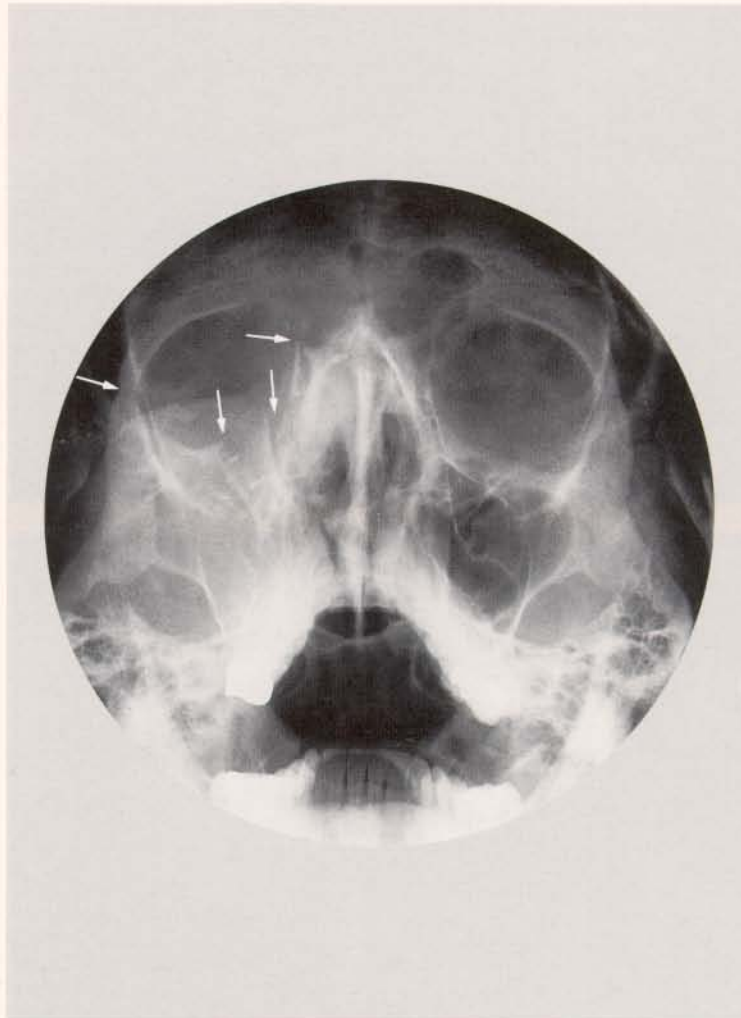

685 Diagram of radiographic signs of jaw fracture (see text, above)

It is absolutely necessary to verify the fracture planes in the third dimension.

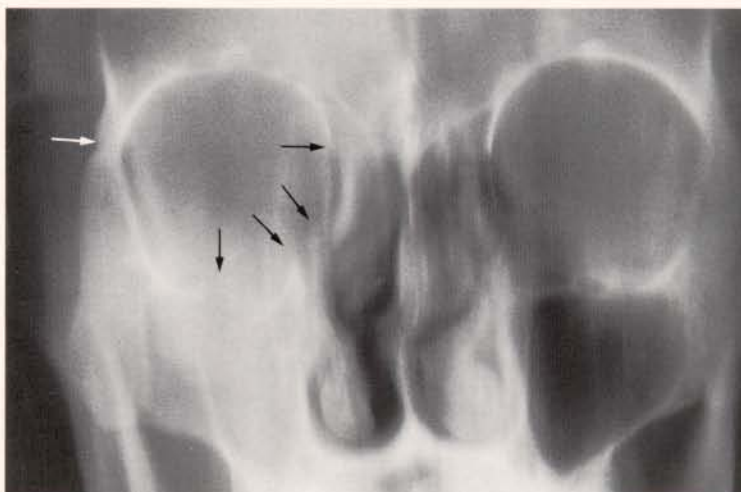
686 Compression fracture of the zygoma, with fracture debris in the region of the right orbit (arrows)

The maxillary sinus and ethmoid sinus on the right side exhibit radiopacity, and therefore suggest the existence of the so-called hematosinus.



687 Same case as viewed with one of the supplemental frontal tomographies

Clear illustration (arrows) of the fracture cleft in the right orbit.

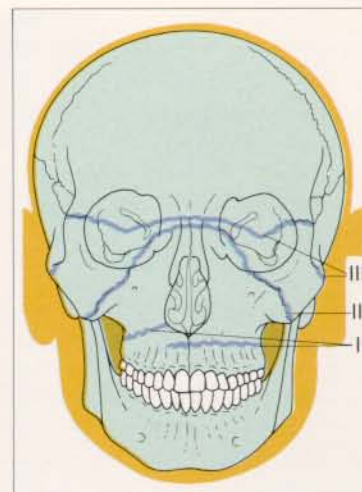


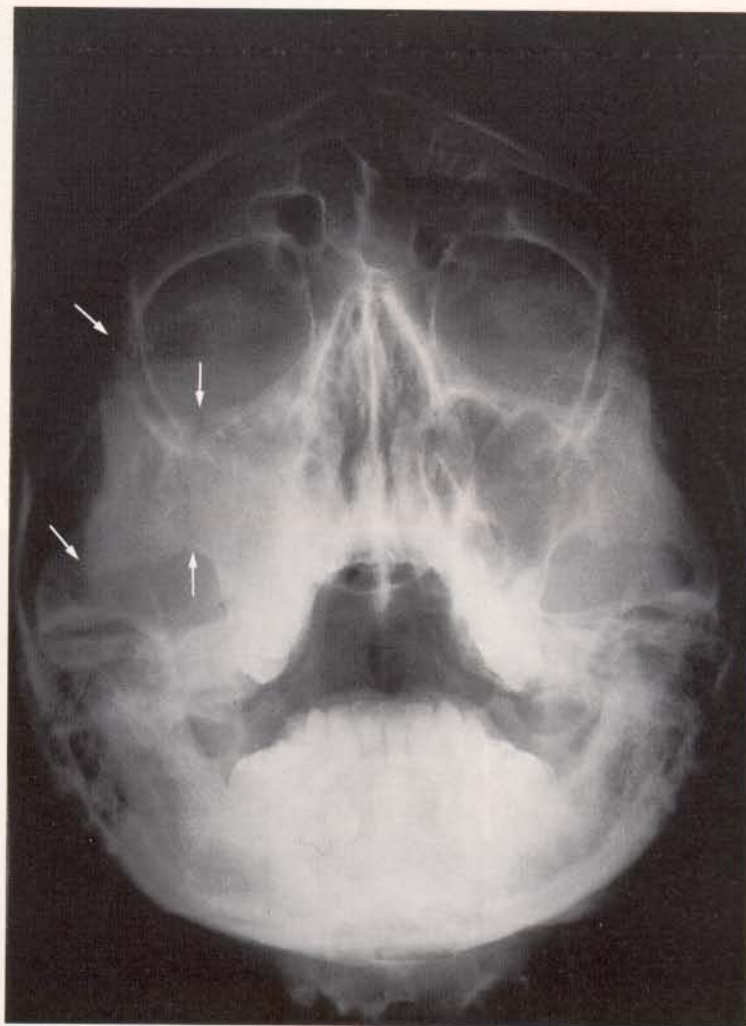
688 Classification of fracture lines according to LeFort (1869–1951, Paris)

The diagram (right) illustrates the classification scheme. Variations may result from combinations.

Left: Multiple fractures of the right orbit.

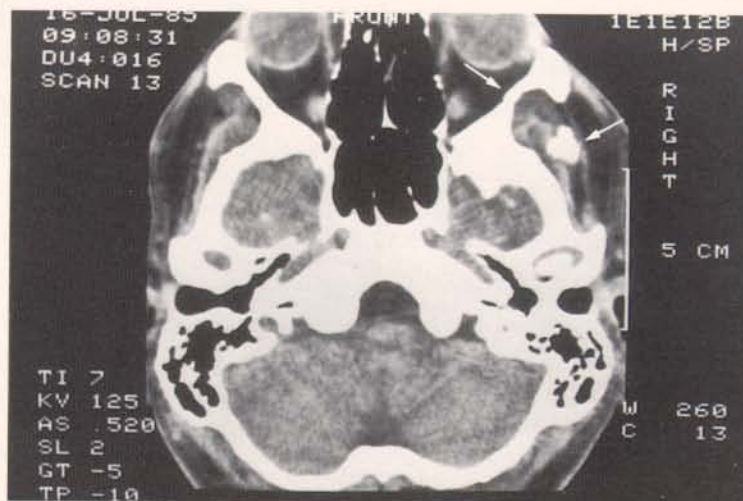
- Right:
- I – LeFort I
 - II – LeFort II
 - III – LeFort III





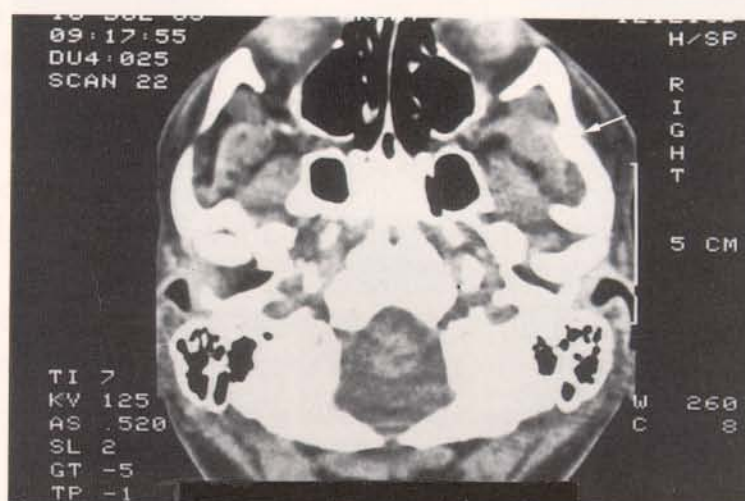689 Fracture of the right zygomatic bone and zygomatic arch

The patient later exhibited definitive hindrance during jaw opening; this was the reason that the follow-up CT examination was performed.



690 Same case, scan 13

This CT picture reveals the zygomatic bone fracture (arrow) and the limitation of movement of the coronoid process by the fragments of the zygomatic bone (arrow).



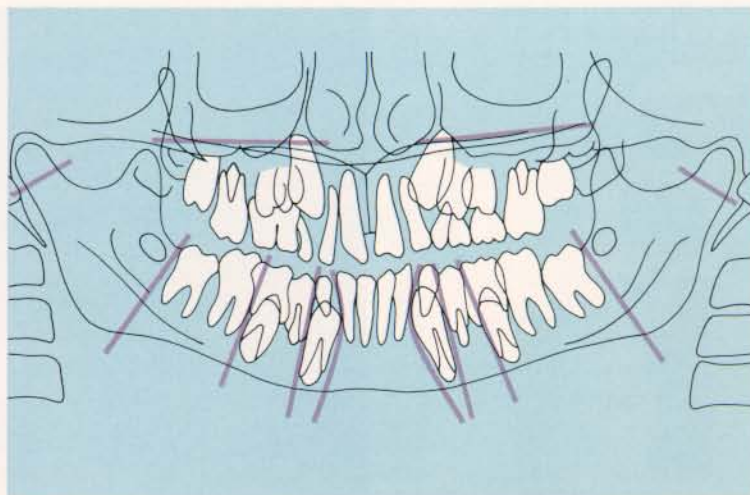
691 Same case, scan 22

Medial position of the zygomatic arch fragments (arrow). An opening movement was attempted by the patient at the same time, and revealed the right condyle in a blocked position.

Courtesy Cantonal Hospital, Winterthur

Mandibular Fractures During Mixed Dentition

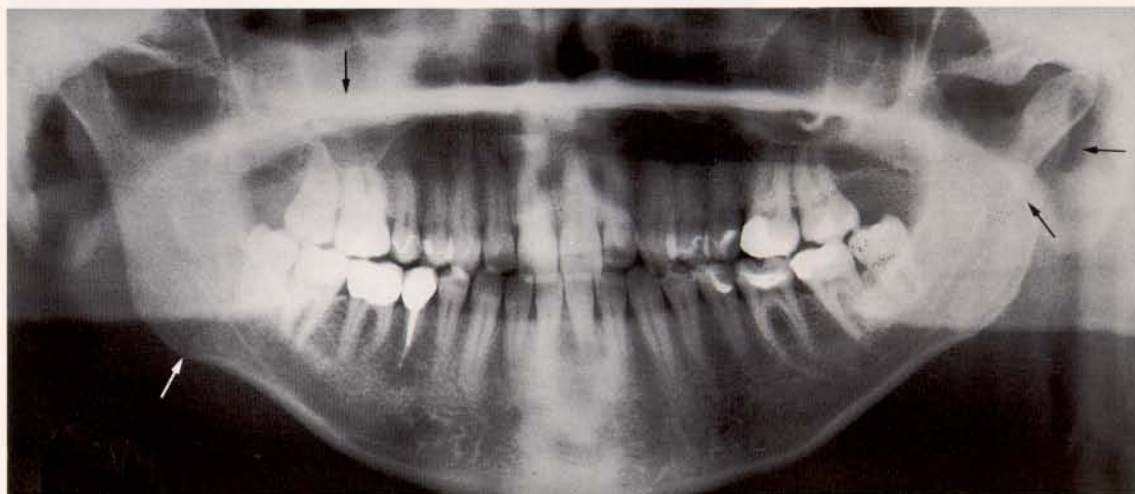
The increasing number of traffic accidents has led to an increase in jaw and facial fractures in children. During the time of transition from the deciduous to the permanent teeth, the jaws are very fragile. The closely spaced and sometimes superimposed periodontal spaces of the deciduous teeth and the tooth buds of the permanent teeth weaken the jaw as development of the dentition progresses, resulting in typical fracture locations. Figure 692 illustrates the possible fracture locations.



692 Diagram of common fracture locations in the mandible during mixed dentition

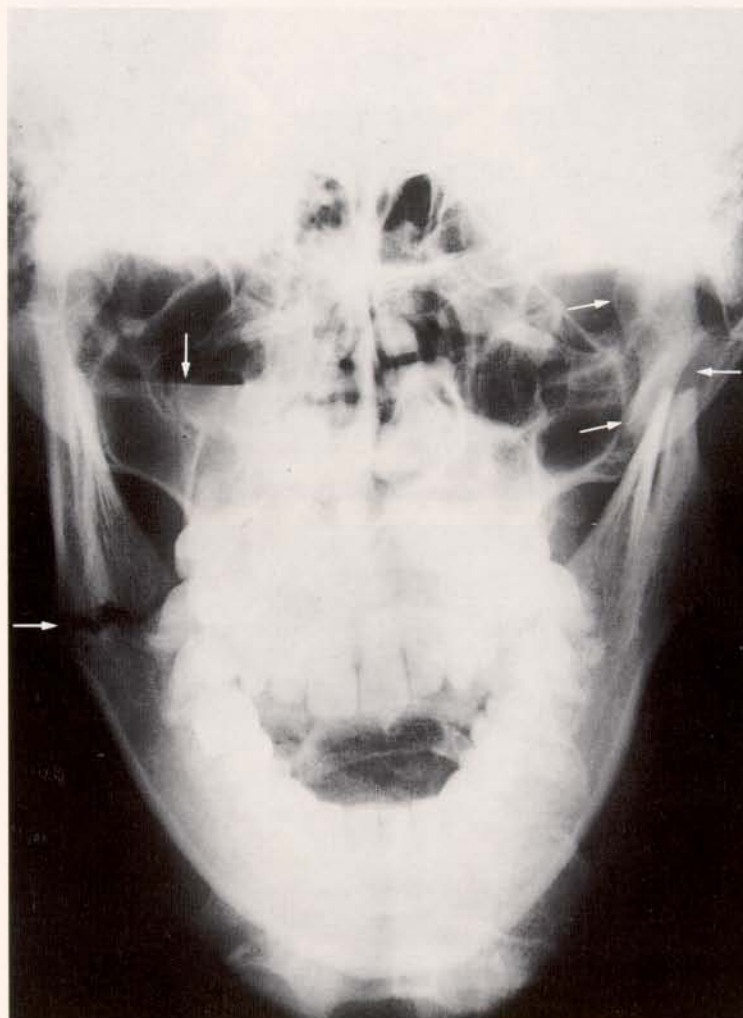
693 Panoramic radiograph of the situation following trauma

Note the dislocation of the left condyle (arrows), a delicate fracture line at the angle of the mandible on the right side (arrow), and a massive radiopacity in the right sinus (arrow).



694 Same case as seen in a reverse Towne projection

This radiograph had to be taken with the mouth fully open, and shows dislocation of the left condyle (arrows), the fracture line at the right angle of the mandible (arrow), and the obvious fluid level in the right maxillary sinus produced by blood (arrow) that resulted from an additional fracture of the maxilla.



Foreign Bodies and Postoperative Conditions

Accidents and surgical procedures can introduce foreign bodies into the facial skeleton or into the soft tissues; in radiographs, such foreign bodies may appear to be located within the jaws because of superimposition. Included in this regard are also all foreign bodies that appear in radiographs of the head and neck region because of improper preparation of the patient (see p. 91, “Errors in Technique That Reduce Radiographic Quality”). On the other hand, therapeutic measures may also result in late sequelae, leaving traces that persist in subsequent radiographs. All such situations must be interpreted during data collection, and many fall into the realm of forensic dentistry. In many cases, the patient is no longer available for clinical examination. For this reason, several typical examples are provided in this chapter.

Foreign bodies may be deposited in the jaws or in the soft tissues as a result of all types of accidents, e.g., work-related, traffic, sport or hunting. Because facilities for xeroradiography are only very seldom available, glass particles often must be documented by means of tangential soft tissue radiographs using extremely low exposure. Even biocompatible filling materials such as those used in cosmetic surgery sometimes show up in panoramic radiographs and can lead to addition effects.

The spectrum of materials that may be deposited during therapy is broad: All kinds of filling materials often appear, e.g., in follow-up radiographs after extended procedures under local anesthesia, and occasionally fragments from dental hand instruments or drills are detected. In nuclear medicine, hollow needles filled with iridium or cesium are implanted during interstitial radiotherapy, and these needles are occasionally visible in panoramic radiographs. More and more frequently today, the radiograph is used to verify the position of implants or osteosynthesis materials. In this regard it should be noted that such therapeutically introduced foreign bodies may possibly elicit reaction in the neighboring tissues. This is usually in the form of chronic inflammation with tissue loss. It is beyond the scope of this atlas to provide a complete description of all the systems in use today for the detection of foreign bodies.

Radiographic examination is also indicated when the dentist is searching for root fragments in the jaws or in the sinus, and to determine the localization of bone fragments and sequestra that may occur after complicated tooth extraction. This chapter will portray the typical healing of defects created by root tip resection (apicoectomy) and other surgical procedures, in order to provide our colleagues outside the field of dentistry some directions to diagnostic criteria as seen by the radiologist.

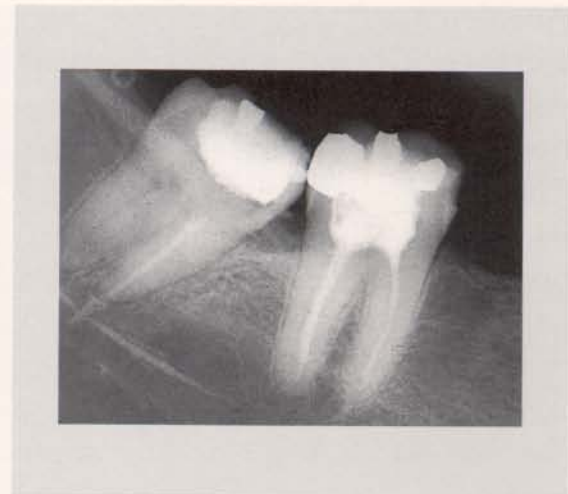
Various Therapeutic Materials Seen in the Radiograph

Root canal filling materials sometimes extrude into the tissues surrounding a tooth through perforation of the floor of the pulp chamber or through the apex of the tooth. Attempts at root canal therapy in third molars frequently result in filling material being deposited in the

mandibular canal. The panoramic radiograph may also depict filling materials used in cosmetic surgery, or the hollow needles implanted in nuclear medicine; these may raise diagnostic questions in the mind of the dentist.

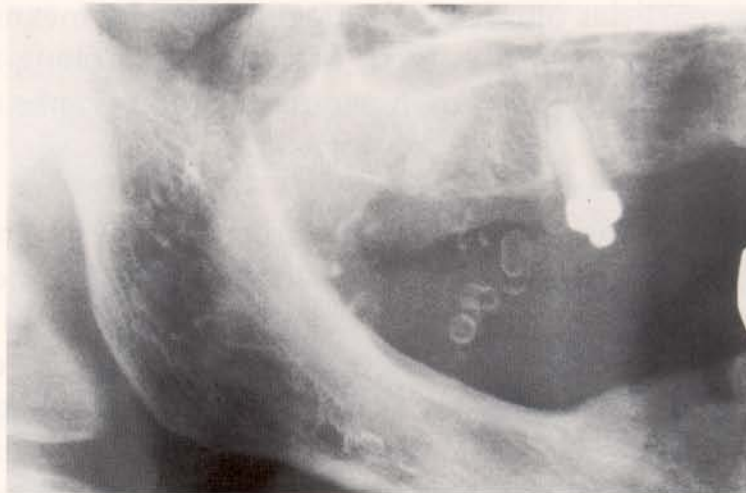
695 Perforation of the furcation and deposition of root canal filling material

696 Overfilling of the mesial canal of tooth 48 with deposition of root canal filling material onto the roof of the mandibular canal



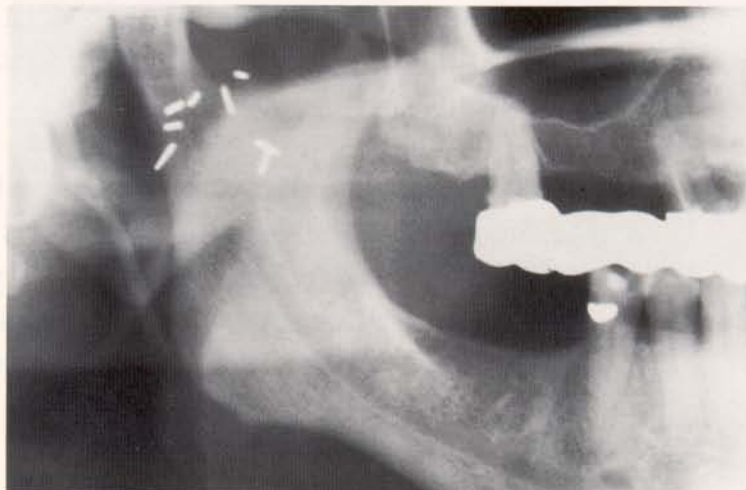
697 Deposition of filling material after cosmetic surgery to improve cheek contour

These spherical bodies are reminiscent of phleboliths, which are observed in similar sites.



698 Hollow needles for radiotherapy of cancer of the parotid gland

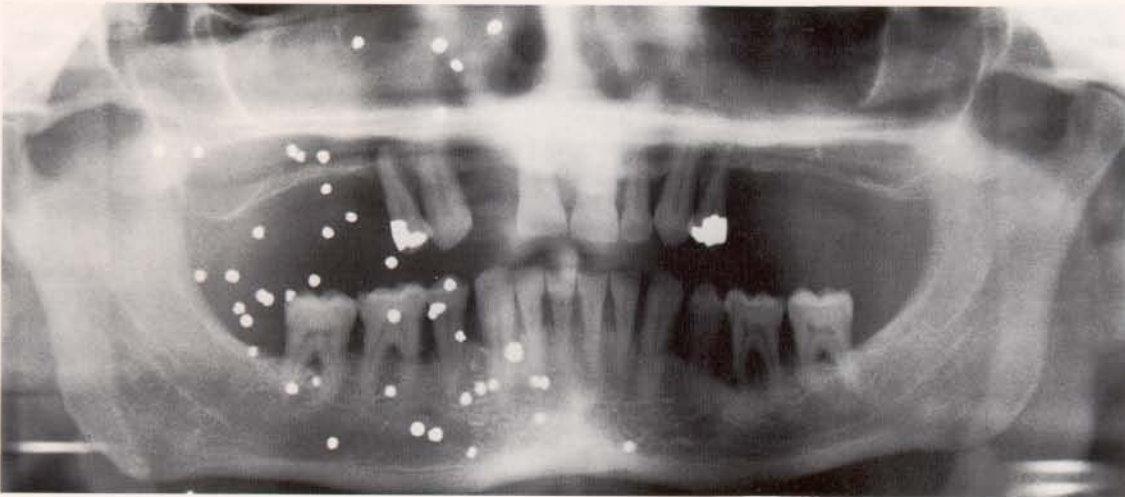
These small hollow needles are filled with cesium or iridium and are implanted for interstitial radiotherapy.



Accidents, Osteosynthesis Material and Implants

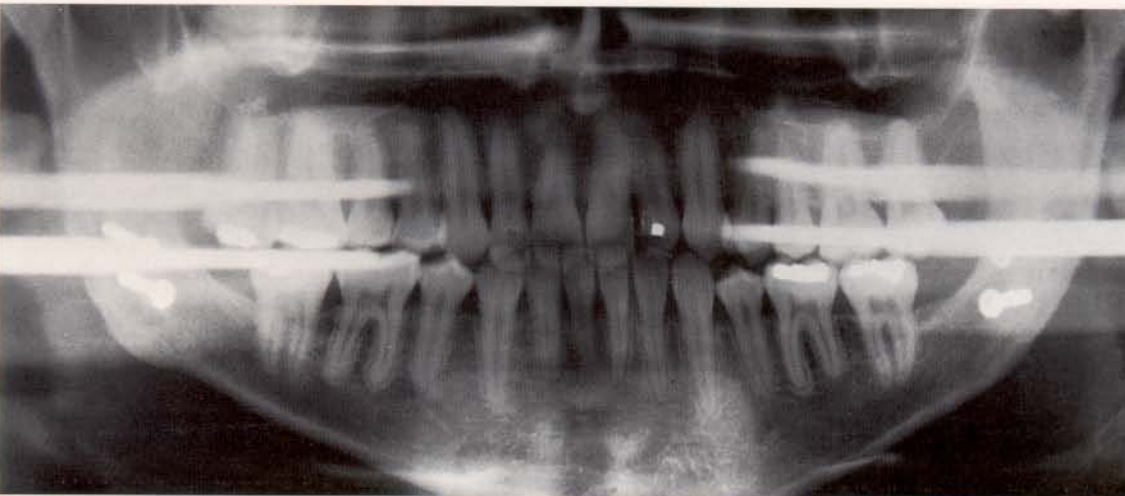
Metal fragments often become lodged in the jaws following accidents; such foreign bodies must be localized using radiography with various projection angles. Particles of glass may be disclosed using radiography or with short exposure soft tissue projection. Osteo-

synthesis materials and implants of all types may be projected onto the contralateral jaw and thus create radiopacities that prevent complete visualization of tissue structures. Under such conditions, artefacts may also occur in computed tomograms.



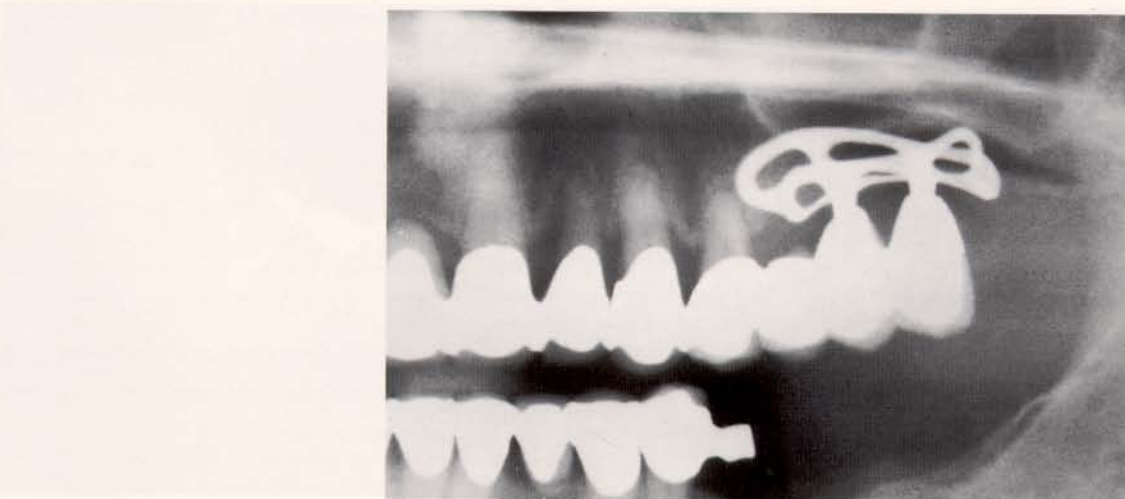699 Condition following a hunting accident

Depending upon the distance from the blast, the small shots usually become lodged in the soft tissues and projects into radiographs of the jaws. The eyes, of course, are at greatest risk.



700 Osteosynthesis material

Materials of all kinds may be observed radiographically at sites of surgical procedures. Often these materials project as interfering radiopacities on the contralateral jaw.



701 Subperiosteal implant as seen in a follow-up radiograph

This implant had been in situ for 34 years and had been used on two separate occasions as a bridge abutment.

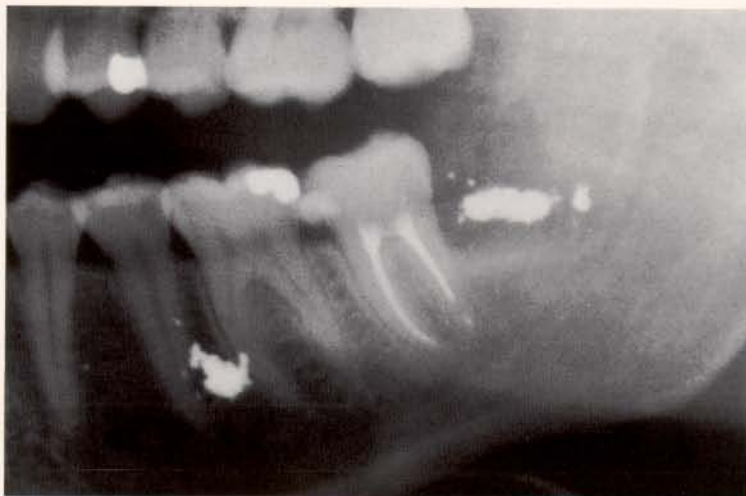Deposition of Filling Materials

The dentist is wise to avoid performing tooth extractions and dental restorations at the same appointment and under the same anesthesia because filling materials can be unknowingly deposited in empty alveoli. In the mandible, excessive root canal filling material can reside within the bone, and in the maxilla it may lodge freely or submucosally in the maxillary sinus. Root

canal filling material expressed beyond the apex usually remains in contact with the treated tooth initially, but with time may migrate and sometimes serves as a nidus for the development of so-called aspergillosis in the sinus, a fungal infection that is readily observed in a panoramic radiograph (p. 169 ff.).

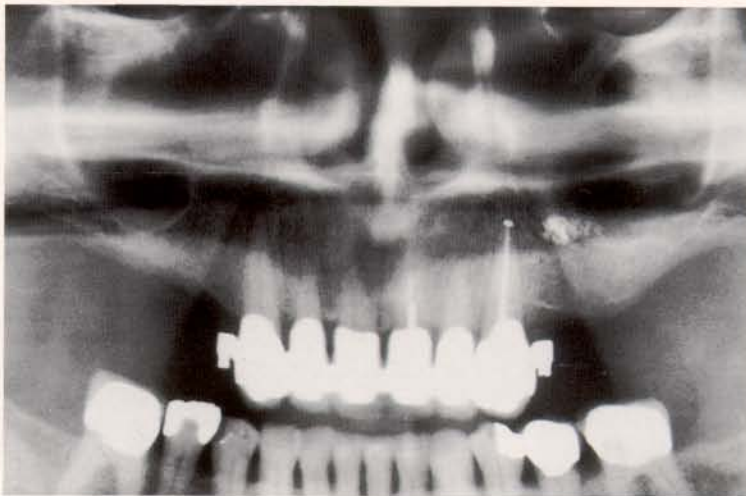702 Deposition of filling material in the vestibulum (near tooth 35) and in the empty alveolus of tooth 38

Note the poorly demarcated borders of the alveolar walls and the reactive sclerosis of the surrounding bone; these are signs of disturbed wound healing.



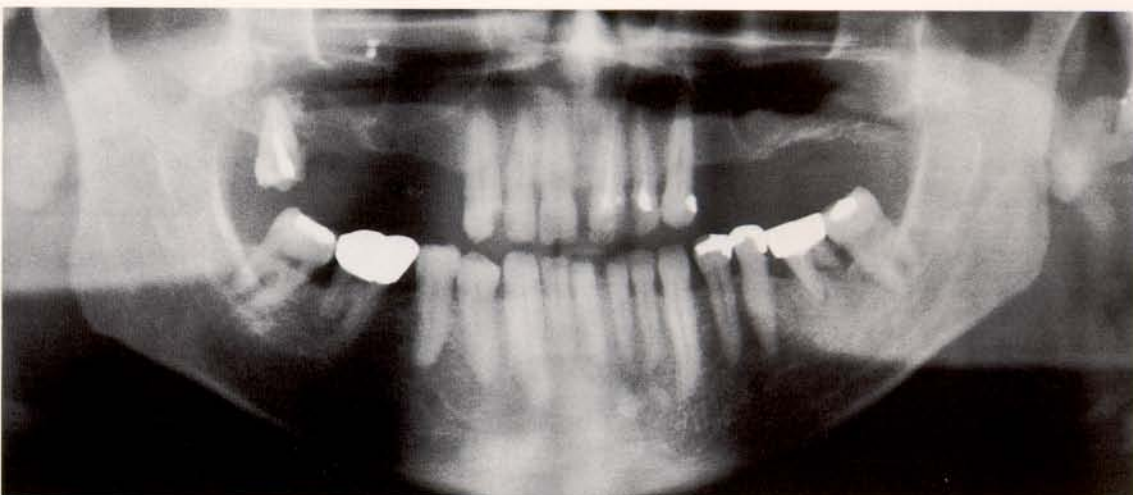
703 Deposition of root canal filling material into the sinus following endodontic treatment of tooth 23

The excessive root canal filling material has already migrated away from the apex of the tooth.



704 Development of aspergillosis following deposition of root canal filling material in the maxillary sinus

Note the mycotic mass surrounding the root canal filling material in the right maxillary sinus.



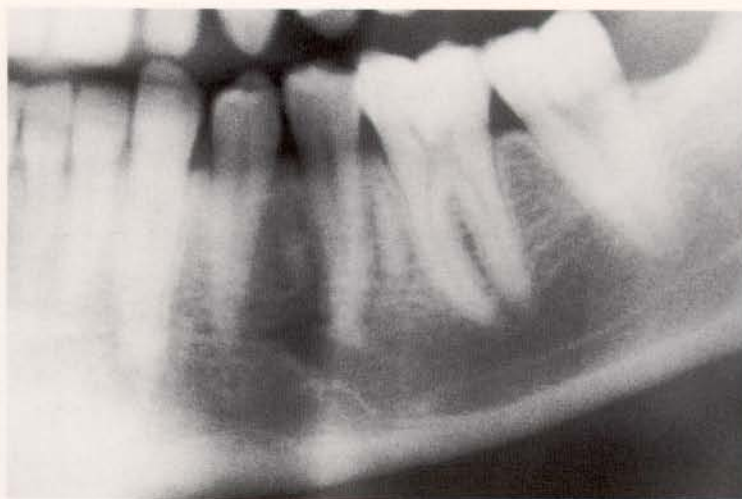
Radiography of Root Fragments

In the Alveolus

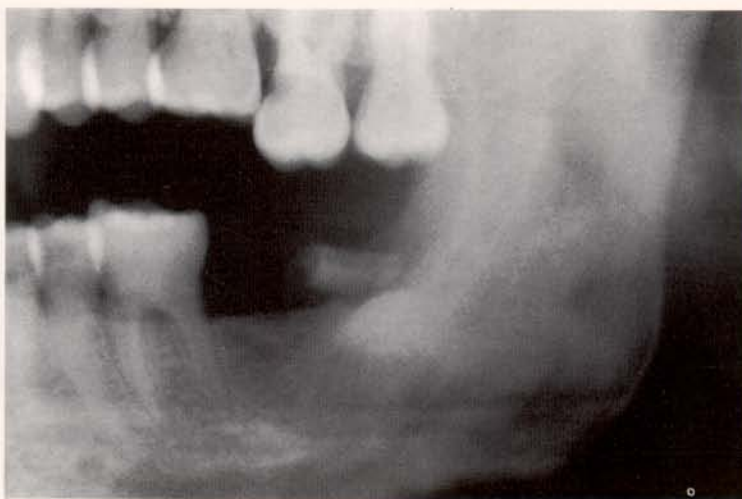- The root fragment may be in its normal location at the "apex line" of adjacent teeth (an exception to this general rule would be root fragments from impacted or retained teeth)
- The periodontal ligament space and lamina dura are preserved (exception: chronic apical periodontitis)
- In most situations the pulp canal is visible radiographically (exception: root fragments from teeth with obliterated root canals).

Outside the Alveolus

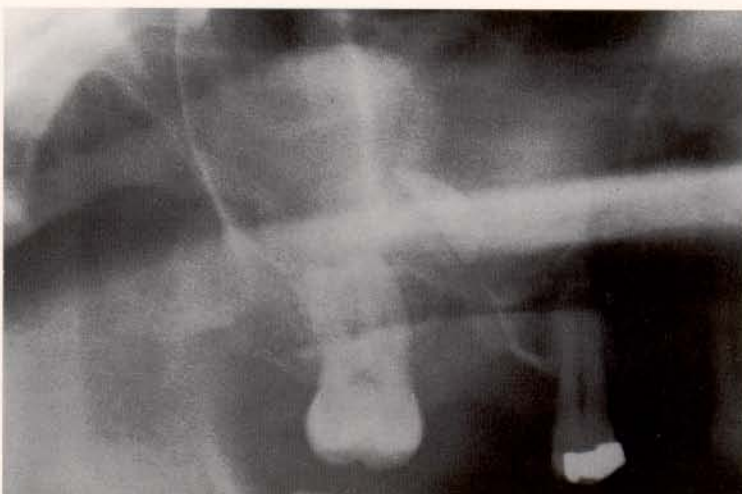- Root fragments that are *not* at their normal anatomic location at the "apex line" of adjacent teeth (exception: root fragments from impacted or retained teeth)
- The periodontal ligament space and the lamina dura are *not* visible
- In most situations the pulp canal is visible radiographically (exceptions: root fragments from teeth with obliterated canals).



705 Root fragments of tooth 75 reside on both sides of tooth 35 in this 26-year-old male



706 Root fragment of tooth 38
The surrounding tissues are chronically inflamed, and this is why the lamina dura cannot be discerned.



707 Root fragment of tooth 16 in the maxillary sinus
The root fragment is located obliquely and apical to the apex line; no lamina dura is apparent. An oroantral fistula is present. The sinus has a radiopaque appearance because of mucosal swelling, and this probably also masks the pulp canal of the root fragment.

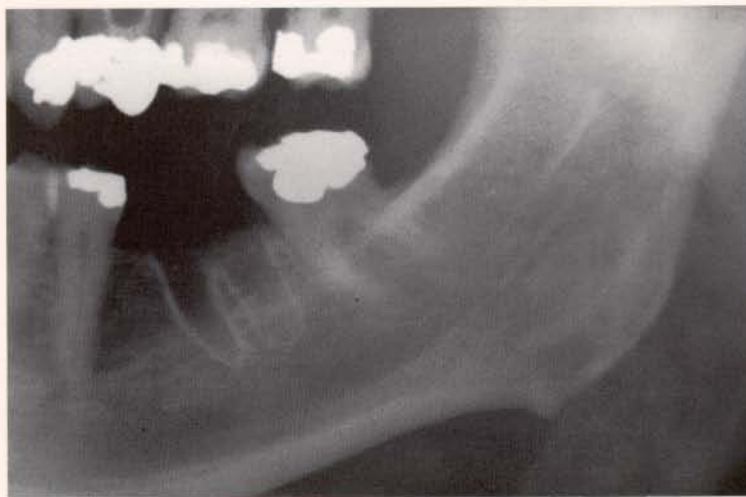Tooth Extraction and Root Fragments

The integrity of the cribriform plate, the condensed alveolar wall that is encountered tangentially by the X-ray beam, is an important diagnostic sign for the health of a tooth and its immediate surrounding tissues. Following tooth extraction, healing may be signaled by the condition of the cribriform plate and the alveolus. Inflammation of the alveolus or disturbances

of healing may dictate the necessity for surgical revision and for the complete removal of any residual root fragments. Excessive production of bone at the base of the alveolus may imitate a radiographic picture similar to a root fragment even long after the extraction has taken place. Root fragments that are actually present may, however, be overlain by areas of surrounding sclerosis.

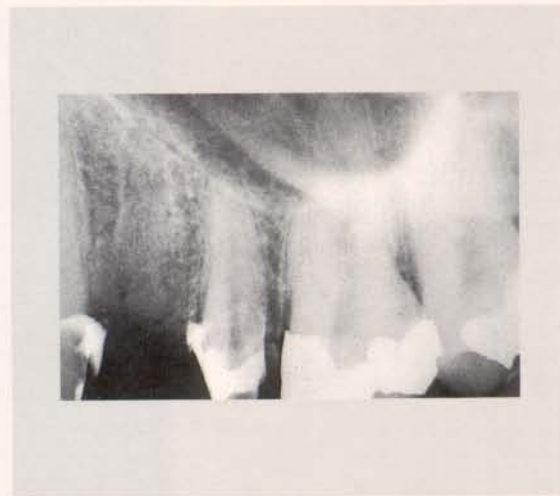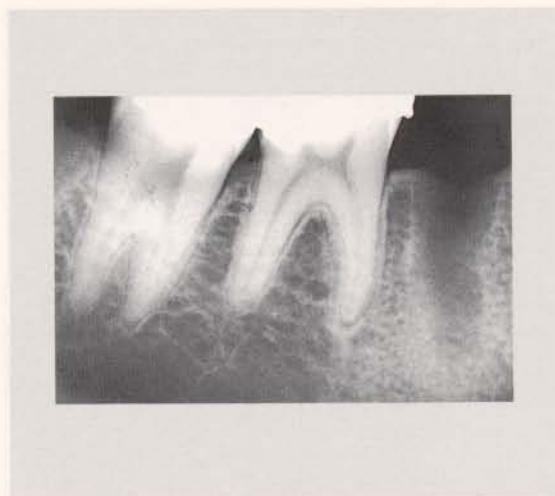708 Empty alveolus with a normal appearance after extraction of tooth 36

Note the intact and sharply demarcated cribriform plate.



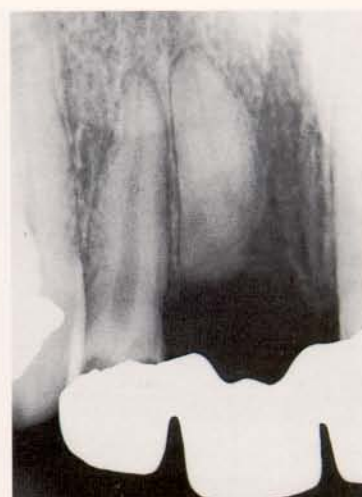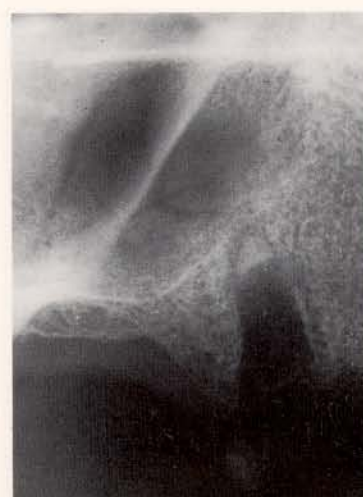709 Alveolus and cribriform plate in a case of dry socket

Note the irregular alveolar walls, with reactive sclerosis of the surrounding area.



710 Excessive reossification of the alveolus of extracted tooth 24

The cribriform plate remains partially intact and is an expression of disturbed healing.

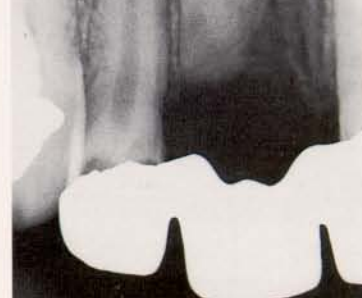
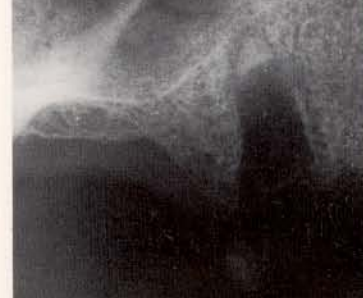

711 Root fragment of tooth 15

Dry socket with signs of inflammatory alterations in the immediate vicinity.

712 "Healed in" root fragment of tooth 11

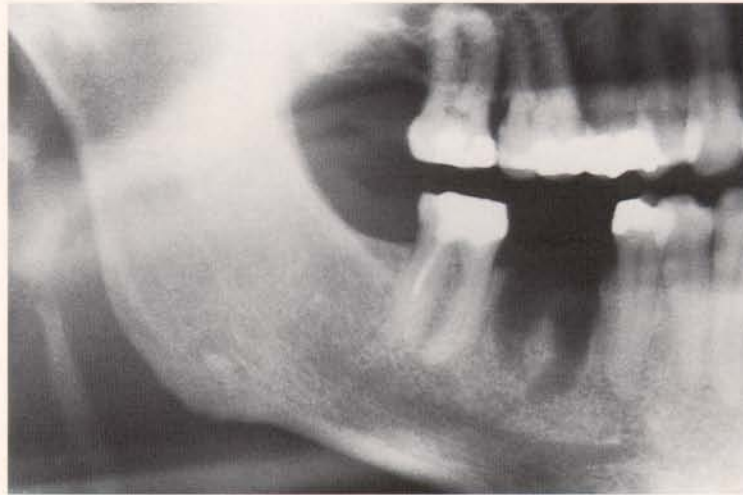
Note that the cribriform plate remains completely intact around this root fragment.



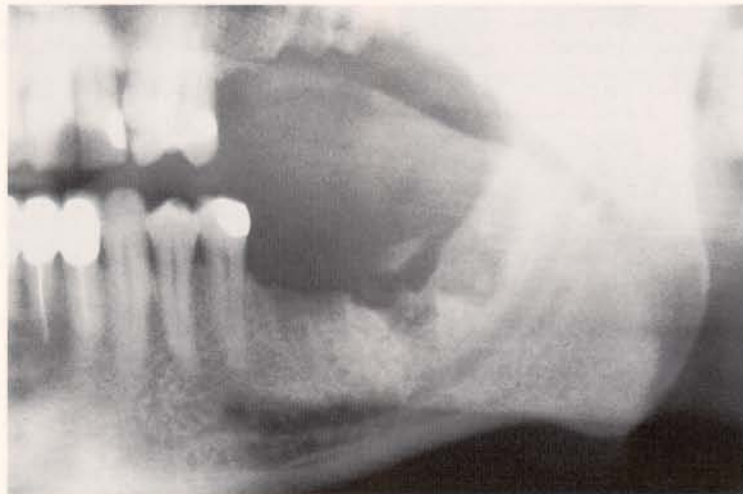Fractured Bone and Sequestra

During complicated surgical removal of teeth, fracture of the surrounding bone sometimes occurs. The interdicular septum and the alveolar margin are often at risk if teeth are extracted using an elevator. Bony segments may be fractured and may remain in the tissue as sequestra, where they elicit delayed healing in the

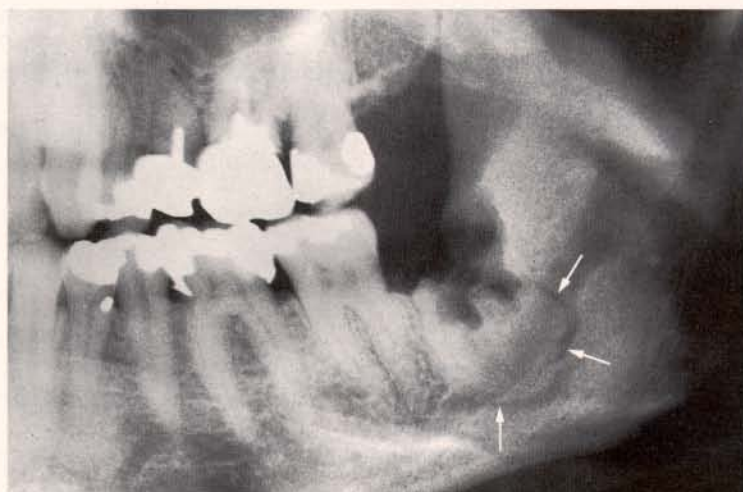
form of a dry socket. In the first few days after tooth extractions, such bony fragments are difficult to detect radiographically because of the superimposition effect; only when a demarcation occurs are these fragments visible in the film.



713 Fracture of the interdicular septum following extraction of tooth 46



714 Fracture of the marginal alveolar bone during extraction of teeth 37 and 38



715 This fracture occurred during an attempt to remove tooth 38 surgically (arrows). Note the position of the mandibular canal.

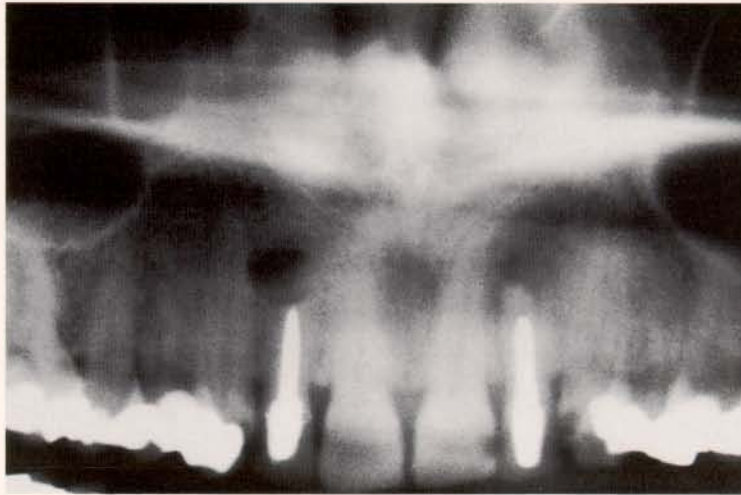
Success and Failure with Root Tip Resection (Apicoectomy)

The success or failure of attempted apicoectomy is not always easy to evaluate radiographically. Some radiographic signs of normal healing include complete reossification, tunnel-like defects with radiating organized marginal structure, and the remains of a sharply demarcated seam of radiolucency that may only be a

millimeter thick; the latter is also known as a “connective tissue scar.” On the other hand, radiographic signs of healing failure include a wide radiolucent seam, and poorly demarcated areas of radiolucency surrounded by reactive sclerosis.

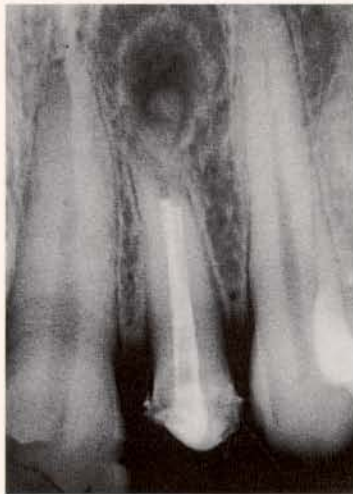716 Success and failure after apicoectomy

Even the panoramic radiograph vaguely shows the sharp demarcation and the tunnel-like defect apical to tooth 12, and the poorly demarcated radiolucency apical to tooth 22. In such cases, additional periapical radiographs are indicated.



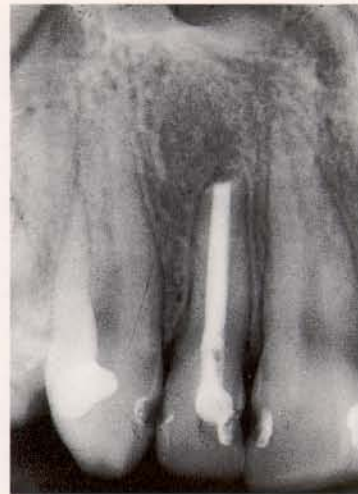717 Failure of an apicoectomy

Incomplete removal of the root tip has left an area of radiolucency and reactive sclerosis as signs of a chronic inflammatory process.



718 Successful apicoectomy

Complete reossification and a small “connective tissue scar.”



Index

Numbers in **boldface type** refer to the Figures.

A

Albers-Schönberg disease 217, 239
Ameloblastoma 197, 200–201, **541–547**
Amelogenesis imperfecta 135, **367–368**
Anatomy
 see radiographic anatomy
Ankylodontia **357–358**
Apical radiographic technique 51–62
Apicoectomy 262, **716–718**
Arthropathy 180, **485, 486**
Aspergillosis 169, **455–457**
Atrophy of aging
 see atrophy, senile
Atrophy, senile 149, 216, 237, **405, 634–636**

B

Bite-wing radiograph 47–50, **88–98**
 – indications 47
Bone marrow islands, incorrect interpretations 217, 238, **637–642**

C

Calcifications 139–146, **379–381**
Calculus 140
 – subgingival 139
 – supragingival 139, **377–378**
Carcinoma, invasive 244, **657–659**
 – oral mucosa 218
Cementoblastoma 199, 207–209, **562–569**
Cementoma 198, 205–206, **556–569**
Cephalometric attachment **16**
Cephalometric radiographs 24, 111, 112
Cephalometry
 see skull films
Cherubism 215, 230, **614**
Chin radiograph 68
Chondroma 214, 223, **592–594**
Clark's technique
 see localization

Computed tomography 122–123
 – skull films **337–341**
Concretions 139–146
Cysts 181–193, **487–540**
 – nonodontogenic 191–193, **518–528**
 – odontogenic 183–190, **487–517**

D

Dens in dente 133, **362**
Dental development,
 – ankylodontia 132, **357–358**
 – anomalies 127–138
 – congenital absence 128, **344**
 – dens in dente 133, **362**
 – enamel pearl 134, **365–366**
 – germination 133, **360**
 – inclusion 128, **346–360**
 – mesiodens 133, **359**
 – persistence 128, **345**
 – resorption 130
 – retention 128–132, **346–360**
 – taurodont 133, **361**
Dental radiographs, apical **105–150**
 – classification **99–104**
 – film holder **99–150**
 – mandibular region **127–146**
 – maxillary region **107–126**
 – patient positioning 54
 – periodontal **97, 99–105**
 – third molars **147–150**
 – standardization 52
Denticles 147, **404**
Dentinogenesis imperfecta 136, **369–371, 374, 644**
Development of films
 see processing technique
Dysplasia, fibrous 215, 228–230, **607–614**
 – odontogenic 137, **373**
 – periapical cemental 198, 205–206, **556–561**

E

Enamel hypoplasia, hereditary 135, **367–368**
Enamel pearl 134, **365–366**
Enostoses 216, 234–235, **630**
Eosinophilic granuloma
 see granuloma
Ewing sarcoma 218
Examination strategies 3–6
 – bite-wing radiograph 47

 – diagnostic regions 4–6, **1–4**
Exostoses 216, 234–235, **625–628**
 – osteochondral 178–179
Exposure techniques, errors **243–288**
 – panoramic radiography
 see panoramic radiography
 – teeth
 see dental radiographs
Extraoral radiographs 69

F

Facial fractures 247–254
Farmer technique 108
Fibroma, ameloblastic 197, 202, **548–549**
 – cementum-forming 199, 209, **570**
 – desmoplastic 214–215, 226, **601–603**
 – nonodontogenic (desmoplastic) 214–215
 – non-ossifying 226, **601–603**
 – ossifying 215, 227, **604–606**
Fibroodontoma, ameloblastic 199, **581**
Film holder 51–53, 69
 – radiographic anatomy 69
Foreign bodies 255–262, **458–460, 695–704**
Foreign body granuloma **415**
Fractures **666–694**
 – of jaw 252–254

G

Germination 133, **360**
Giant cell granuloma **583–588**
 – central 213, 220, **583–585**
 – peripheral 213–214, 221, **586–588**
Granuloma, eosinophilic 214, 222, **589–591**
 – giant cell
 – – see giant cell
 – – granuloma
 – internal 150, **407–408**
Granulomatous lesions 213

H

Hand-Schüller-Christian disease 214, 222

Hemangioma 217
 – central 241, **648–650**
Histiocytosis X 214, 222, **589–591**
Hypercementosis 134, **363–364**
Hyperostosis 216, 236, **631**
Hypertrophy 236, **632–633**
 – jaws 216
Hypodontia **344**
Hypoplasia, of condyles 178

I

Imaging techniques 109–124
Incorrect interpretations
 see bone marrow islands
Inflammations **410–428**
 – jaw 151–158
Intraoral radiographs 69

J

Jaw fractures, radiographic signs 252–254

L

Latent bone cavity 196, **537–540**
Letterer-Siwe disease 214, 222
Localization methods 83–90, **222–242**
 – Clark's technique 83–85, **222–229**
 – panoramic radiography 86, **320–332**
 – skull films 88, **236–242**
Lymph nodes, calcified 140, **379–380**

M

Macroglossia 138, **375**
Magnetic resonance imaging 124, **342–343**
Marble bone disease 217, 239, **645**
Mesiodens 133, **359**
Metastases 246, **663–665**
Mucoepidermoid tumor 219, 245, **660–662**
Myositis ossificans 146, **396**
Myxoma, odontogenic 198, 203–204, **550–555**

-
- N
-
- Nuclear magnetic resonance tomography
see magnetic resonance imaging
-
- O
-
- Occlusal radiographs 63–68, **151–168**
– errors 102
– extraoral 68, **169–172**
– mandibular region 65–67, **163–168**
– maxillary region 64, 66, **151–155, 161–162**
– radiographic anatomy 69–81
Odontogenesis imperfecta 137, **372, 643**
Odontoma 199, 210–212, **571–581**
– combined **577**
– complex 199, 210–211, **571–572, 575–576**
– compound 199, 211–212, **578–580**
Ossifications 139–146, **386, 396–397, 629**
Osteitis deformans 217, 240, **646–647**
Osteoblastoma 215–216, 231, **617**
Osteochondroma 179, 214, 223–225, **481–482, 595–600**
Osteodystrophy deformans 217, 240, **646–647**
Osteofibrosis deformans, juvenile 228
Osteogenesis imperfecta 137, 217, 239, **372, 643–644**
Osteoid osteoma 215–216, 231, **615–616**
Osteoma, central 216, 232, **618–619**
– multiple **619**
– osteoid, see osteoid osteoma
– peripheral 216, 233, **621–624**
Osteomyelitis 153–158, **416–429**
– radiographic signs 156
Osteopetrosis 217, 239, **645**
Osteoporosis 216, 237, **634–636**
Osteoradionecrosis 151, 158, **430**
Osteosarcoma 242, **651–656**
Overdevelopment, reduction 108
-
- P
-
- Paget's disease of bone 217, 240, **646–647**
Panoramic radiography 3–50, **5–39**
– advantages 10
– asymmetry 18, **29**
– center of rotation 10–11, **7–8**
– disadvantages 11
– distortion 11, **11–12**
– film holder 51–53
– functional focus 11
– indications 1–6
– positioning 12–21, **17–37**
– – incorrect 13, 16–18, **25–29**
– – modifications 19–22, **30–37**
– principles 10–11, **5–12**
– tips 92–93
– Zonarc apparatus 9, 23, **38–39**
Parotid gland, calcified **381**
Periapical radiographs, radiographic anatomy 69–81
Periodontal radiographic technique 51–62
Periodontitis 152–153
– apical 152–153, **410–414**
– marginal 153, **418, 420**
Periapical radiographs, errors 97–101
Phlebolith 145, **392, 393**
Postoperative conditions 255–262
Processing technique 103–108, **289–305**
– errors 103–108, **289–305**
– Farmer method 108
– reduction of overdevelopment 108
– tips 104–106
Protection, radiation exposure 3–6
Pseudocysts 181, 194–196, **529–540**
Pseudotumors, nonodontogenic 213–246
– odontogenic 197–212
-
- R
-
- Radiation exposure, protection 3–6
Radio-osteomyelitis 151
- Radiograph, film holder 58–59
– film positioning 58
– mandibular region 58–62
– maxillary region 54–57
– of skull
 see skull radiographs
– special
 see special radiographs
– third molars 62
– tips 94–95
– tube angulation 56–57
Radiographic anatomy 25–41
– addition effect 25
– dental radiographs **173–219**
– dentition 42–46
– eruption of deciduous teeth 45
– eruption of permanent teeth 46
– film holder 69
– jaw development 42–46
– occlusal radiographs 69–81, **220–221**
– panoramic radiographs 25–46, **44–84**
– periapical radiographs 69–81
– subtraction effect 25
– summation effect 9, 25
– tangential effect 25, 69
Radiographic technique, errors **243–288**
Radiography, panoramic
 see panoramic radiography
Reduction, of overdevelopment 108
Regressive alterations **398–409**
– teeth and jaws 147–150
Resorption 148–150, **399–403, 406–409**
Reverse Towne projection 90, 117, 197, 213, **3, 43, 514, 683**
Rhinolith 145, **394–395**
Root fragments **705–707, 711–712**
Root resorption 150, **409**
– idiopathic 138, **376**
-
- S
-
- Sarcoma 218, 242–243, **651–656**
Schüller projections, skull radiographs **330–332**
Sialography 141–142, **382–391**
Sialolith 141–144, **383–391**
Sinus pathology, dentogenic 159–169, **434–460**
Sinusitis 164–167
– dentogenic 164, 166, 168
-
- Skull films, cephalometric **310–312**
– cephalometric attachment 24, **40–43**
– computed tomography 122–123, **337–341**
– conventional 109–124, **306–327, 330–332**
– tomograms 109, 119, 121, **328–329, 333–336**
Special radiographs, indications 4–6, **1–4**
– Reverse Towne projection 90, 117, 197, 213, **3, 43, 514, 683**
– Waters' projection 4, 118, 165, 227, **42, 611**
Stafne cyst 196
Status
 see radiographic status
Stylohyoid ligament **397**
– ossification 146
Subluxation, radiographic signs 248–249
-
- T
-
- Taurodont 133, **361**
Temporomandibular joint disturbances 171–180, **461–486**
Tomography, principles 10, 25
Tooth fractures, radiographic signs 250–251
Traumatology 247–254, **666–694**
Tube shift principle 133
Tumors, nonodontogenic 213–246, **583–665**
– odontogenic 197–212, **541–581**
-
- W
-
- Waters' projection 4, 118, 165, 227, **42, 611**
-
- Z
-
- Zonography 23, 25–26, 121