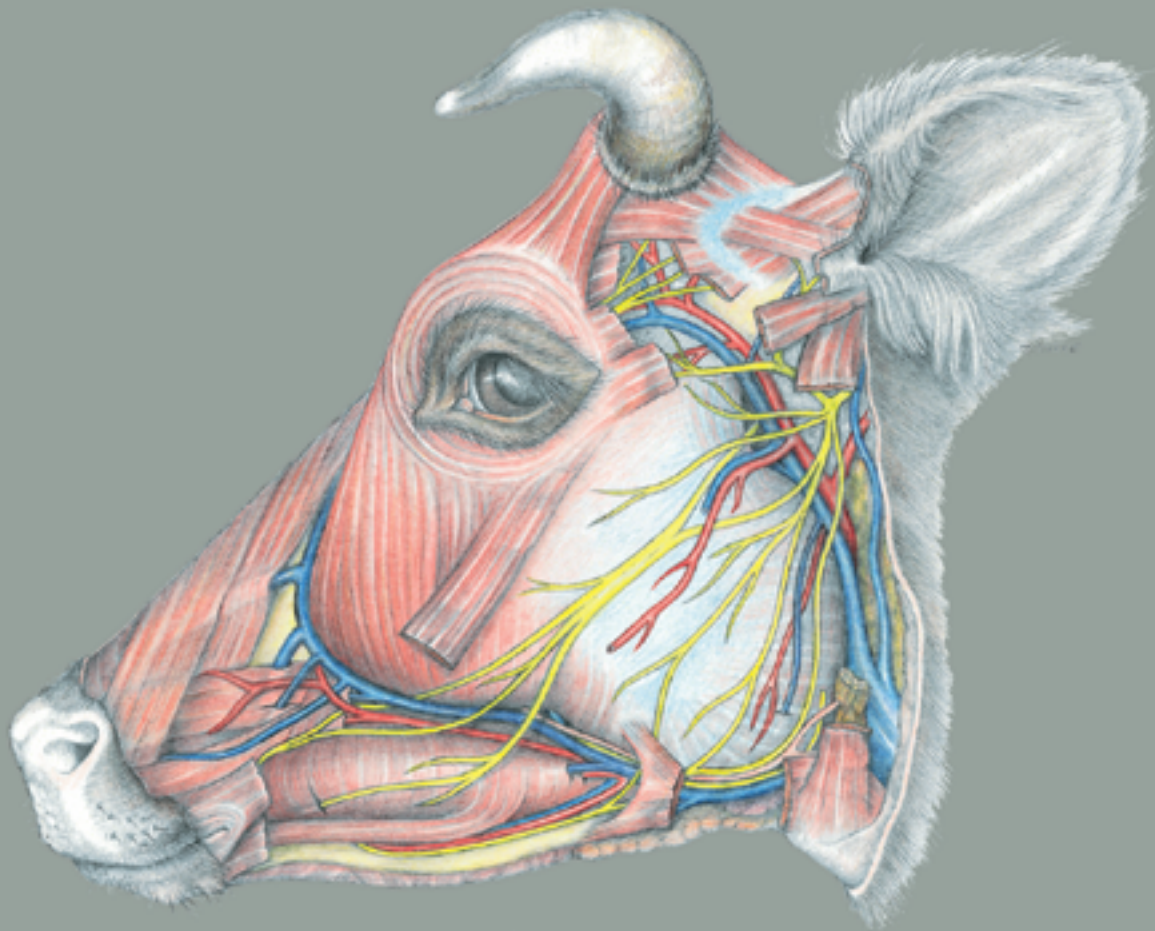


Klaus-Dieter Budras • Robert E. Habel

Bovine Anatomy

An Illustrated Text

First Edition



Scientific Illustration

Gisela Jahrmärker • Renate Richter • Diemut Starke

schlütersche

Klaus-Dieter Budras/Robert E. Habel

BOVINE ANATOMY

An Illustrated Text

BOVINE ANATOMY

An Illustrated Text

FIRST EDITION

Professor Klaus-Dieter Budras

Dr. med. vet. habil.

Institute of Veterinary Anatomy
Free University of Berlin

Professor em. Robert E. Habel

DVM, MVD

Dept. of Biomedical Sciences
College of Veterinary Medicine
Cornell University, Ithaca, New York

Dr Anita Wünsche

Institute of Veterinary Anatomy
Free University of Berlin

Dr Silke Buda

Institute of Veterinary Anatomy
Free University of Berlin

Scientific Illustrators

Gisela Jahrmärker

Renate Richter

Diemut Starke

schlütersche

COLLABORATION ON THE ATLAS OF BOVINE ANATOMY

First edition:

Cover design:
Diemut Starke

Collaborators on the whole project:

Angela Baumeier
Daniela Bedenice
Christina Braun
Anne-Kathrin Frohnes
Constanze Güttinger
Susann Hopf
Claudia Nöller
Susanne Poersch
Eva Radtke
Monika Sachtleben
Thilo Voges

Editor:

Prof. Dr. Klaus-Dieter Budras, Institut für Veterinär-Anatomie, Freie Universität Berlin

Contributions:

PD Dr. Hermann Bragulla, Institut für Veterinär-Anatomie, Freie Universität Berlin
Dr. Silke Buda, Institut für Veterinär-Anatomie, Freie Universität Berlin
Prof. Dr. Reinhard Fries, Dr. Tina Eggers, Institut für Fleischhygiene, Freie Universität Berlin
Prof. Dr. Götz Hildebrandt, Katrin Rauscher, Institut für Lebensmittelhygiene, Freie Universität Berlin
Prof. Dr. Dr. h.c. Horst E. König, Institut für Anatomie, Veterinärmedizinische Universität Wien
Prof. Dr. Dr. h.c. mult. Hans-Georg Liebich, Institut für Tieranatomie, Ludwig-Maximilians-Universität München
Dr. Christoph Mülling, Institut für Veterinär-Anatomie, Freie Universität Berlin
Prof. Dr. Dr. h.c. Paul Simoens, Fakulteit Diergeneeskunde, Universiteit Gent
Dr. Anita Wünsche, Institut für Veterinär-Anatomie, Freie Universität Berlin

Contributions without further identification:

Prof. Dr. Klaus-Dieter Budras and Prof. Dr. Robert E. Habel

Acknowledgement of sources of illustrations:

The figures on p. 23 were drawn by Wolfgang Fricke and published by Dr. Anita Wünsche (1965).
The figure on p. 79 (below) was drawn by Wolfgang Fricke and published by Dr. Wolfgang Traeder (1968).
The figure on p. 80 was modified from Traeder (1968).

Bibliographic information published by Die Deutsche Bibliothek

Die Deutsche Bibliothek lists this publication in the Deutsche Nationalbibliografie; detailed bibliographic data are available on the Internet at <http://dnb.ddb.de>.

All rights reserved. The contents of this book both photographic and textual, may not be reproduced in any form, by print, photoprint, phototransparency, microfilm, video, video disc, microfiche, or any other means, nor may it be included in any computer retrieval system, without written permission from the publisher.

Any person who does any unauthorised act in relation to this publication may be liable to criminal prosecution and civil claims for damages.

© 2003, Schlütersche GmbH & Co. KG, Verlag und Druckerei
Hans-Böckler-Allee 7, 30173 Hannover, Germany
E-mail: info@schluetersche.de

Printed in Germany

ISBN 3-89993-000-2

Preface	1
Topographic Anatomy	
Chapter 1: Thoracic limb (A. Wünsche, R. Habel and K.-D. Budras)	
1. Skeleton of the thoracic limb	2
2. Muscles and nerves of the shoulder, arm, and forearm	4
3. Cutaneous nerves, blood vessels, and lymph nodes of the thoracic limb	6
4. Vessels and nerves of the manus	8
5. Interdigital nerves and vessels, interossei, and fasciae of the manus	10
6. Synovial structures of the thoracic limb	12
Chapter 2: Pelvic limb (A. Wünsche, R. Habel and K.-D. Budras)	
1. Skeleton of the pelvic limb	14
2. Lateral thigh and cranial crural muscles with their nerves	16
3. Medial thigh and caudal crural muscles with their nerves	18
4. Cutaneous nerves, blood vessels, and lymph nodes of the pelvic limb	20
5. Arteries, veins, and nerves of the pes	22
6. Dermis of the hoof (Ch. Mülling and K.-D. Budras)	24
7. The hoof (ungula) (Ch. Mülling and K.-D. Budras)	26
8. Synovial structures of the pelvic limb (Ch. Mülling and K.-D. Budras)	28
Chapter 3: Head (R. Habel, and K.-D. Budras)	
1. Skull and hyoid apparatus (R. Habel and K.-D. Budras)	30
2. Skull with teeth (R. Habel and K.-D. Budras)	32
3. Skull with paranasal sinuses and horns (R. Habel and K.-D. Budras)	34
4. Superficial veins of the head, facial n. (VII), and facial muscles (S. Buda and K.-D. Budras)	36
5. Trigeminal n. (V3 and V2), masticatory mm., salivary gll., and lymphatic system (S. Buda and K.-D. Budras)	38
6. Accessory organs of the eye (P. Simoens and K.-D. Budras)	40
7. The eyeball (bulbus oculi) (P. Simoens and K.-D. Budras)	42
8. Nose and nasal cavities, oral cavity and tongue (S. Buda, R. Habel, and K.-D. Budras)	44
9. Pharynx and larynx (S. Buda, R. Habel and K.-D. Budras)	46
10. Arteries of the head and head-neck junction, the cran. nn. of the vagus group (IX–XI), and the hypoglossal n. (XII) (S. Buda and K.-D. Budras)	48
Chapter 4: Central nervous system and cranial nerves	
1. The brain (R. Habel and K.-D. Budras)	50
2. Cranial nerves I–V (S. Buda, H. Bragulla and K.-D. Budras)	52
3. Cranial nerves VI–XII (S. Buda, H. Bragulla, and K.-D. Budras)	54
4. Spinal cord and autonomic nervous system (S. Buda and K.-D. Budras)	56
Chapter 5: Vertebral column, thoracic skeleton, and neck (A. Wünsche, R. Habel and K.-D. Budras)	
1. Vertebral column, ligamentum nuchae, ribs, and sternum	58
2. Neck and cutaneous muscles	60
3. Deep shoulder girdle muscles, viscera and conducting structures of the neck	60
Chapter 6: Thoracic cavity	
1. Respiratory muscles and thoracic cavity with lungs (Ch. Mülling and K.-D. Budras)	62
2. Heart, blood vessels, and nerves of the thoracic cavity (R. Habel and K.-D. Budras)	64
Chapter 7: Abdominal wall and abdominal cavity	
1. The abdominal wall (R. Habel, A. Wünsche and K.-D. Budras)	66
2. Topography and projection of the abdominal organs on the body wall	68
3. Stomach with rumen, reticulum, omasum, and abomasum (A. Wünsche and K.-D. Budras)	70
4. Blood supply and innervation of the stomach; lymph nodes and omenta (R. Habel, A. Wünsche and K.-D. Budras)	72
5. Spleen, liver, pancreas, and lymph nodes (P. Simoens, R. Habel and K.-D. Budras)	74
6. Intestines with blood vessels and lymph nodes (P. Simoens, R. Habel and K.-D. Budras)	76
Chapter 8: Pelvic cavity and inguinal region, including urinary and genital organs	
1. Pelvic girdle with the sacrosclatic lig. and superficial structures in the pubic and inguinal regions (R. Habel and K.-D. Budras) ..	78
2. Inguinal region with inguinal canal, inguinal lig., and prepubic tendon (R. Habel and K.-D. Budras)	80
3. Lymphatic system, adrenal glands, and urinary organs (K.-D. Budras and A. Wünsche)	82
4. Arteries, veins, and nerves of the pelvic cavity (A. Wünsche and K.-D. Budras)	84
5. Female genital organs (H. G. Liebich and K.-D. Budras)	86
6. The udder (H. Bragulla, H. König, and K.-D. Budras)	88
7. The udder with blood vessels, lymphatic system, nerves, and development (H. Bragulla, H. König, and K.-D. Budras)	90
8. Male genital organs and scrotum (R. Habel and K.-D. Budras)	92
9. Perineum, pelvic diaphragm, ischioanal fossa, and tail (R. Habel and K.-D. Budras)	94
Anatomical aspects of bovine spongiform encephalopathy (BSE)	
(S. Buda, K.-D. Budras, T. Eggers, R. Fries, R. Habel, G. Hildebrandt, K. Rauscher, and P. Simoens)	96
Special Anatomy, Tabular Part	
1. Myology	98
2. Lymphatic system	113
3. Peripheral nervous system	119
References	126
Index	132

NOTES ON THIS ATLAS

Bovine Anatomy, a translation and revision of *Atlas der Anatomie des Rindes*, is volume III of a series of atlas-textbooks on the topographic anatomy of domestic mammals for veterinary students and practitioners. Volume I, *Atlas of the Anatomy of the Dog*, in addition to specific canine anatomy, provides the fundamental concepts of general anatomy required for the study of all mammals. The dog is small and inexpensive enough that a specimen can be allotted to each dissection team, with advantages in ease of dissection, review, and preservation. Volume II, *Atlas of the Anatomy of the Horse*, is an introduction to the many specialized systems of a large herbivore, with an extensive chapter on equine functional and clinical anatomy.

In all three volumes the illustrations were drawn from dissections especially made for that purpose. The boxed information at the top of some text pages is intended to be a dissection guide for students and to give information on the methods used to make the preparations illustrated. Species characteristics of the ox, in contrast to the dog and horse, are printed in italics. Important terms are printed in bold-face type, and when a number is attached to the name, it corresponds to a number in the adjacent illustration. Less important anatomical features are not mentioned in the text, but are listed in the legends of the illustrations. The descriptions are based on normal anatomy. Individual variations are mentioned only when they have clinical importance. The gaps in the numbering of items in the legends of the skeletal system (pp. 3, 15, 31, 33) are caused by omission of features that do not occur in the ox, therefore are not illustrated, but were listed in the German edition for comparison with the dog and horse. The remarks on examination of lymph nodes in meat inspection (pp. 113–118) are translations of German rules and do not necessarily reflect current practice in the United States. The word ox is used in this book to mean “a domestic bovine mammal (*Bos taurus*),”^{*} Ox is the singular of the collective term, cattle, and is the accepted English translation of Ger. *Rind*. The other meaning: “an adult castrated male domestic ox”^{*} can be understood from the context, as in “a span of oxen.” The abbreviations used are those of the *Nomina Anatomica Veterinaria*. Additional abbreviations are explained in the text, the headings, the legends, and in the SPECIAL ANATOMY, TABULAR PART (pp. 98–125). They are listed here for convenience:

The cranial nerves are indicated by Roman numerals I–XII. Vertebral and spinal nerves are indicated by Arabic numerals.

Spinal Nerves

n	— Spinal nerve
nd	— Dorsal branch (br.)
ndl	— Lateral br. of dorsal br.
ndm	— Medial br. of dorsal br.
nv	— Ventral br.
nvl	— Lateral br. of ventral br.
nvm	— Medial br. of ventral br.
cut. br.	— Cutaneous br.

Vertebrae and Spinal Nerves

C	— Cervical (e.g. C1—first cervical vertebra or nerve)
Cd	— Caudal (Coccygeal)
L	— Lumbar
S	— Sacral
T	— Thoracic

^{*} *Collegiate Dictionary*, 1993, 10th ed., Merriam-Webster, Springfield, Mass., U.S.A.

PREFACE TO THE FIRST ENGLISH EDITION

This combination of topographic color atlas and concise textbook of *Bovine Anatomy* is the third volume of a series on the anatomy of domestic mammals. The first edition of the *Atlas and Textbook of the Anatomy of the Dog* appeared 20 years ago. It was followed 12 years ago by the second volume, the *Anatomy of the Horse*. In several German and foreign language editions they aroused world-wide interest. Therefore our next project was an *Atlas and Textbook of Bovine Anatomy* following the proven model and thereby closing a previously existing gap: no comparable work on bovine anatomy was available. The special features of the ox are presented to students in a well-grounded survey of topographic anatomy. **Special anatomy** is summarized as brief data in tables of muscles, lymph nodes, and nerves, with references to the corresponding pages in the text. **Comparative anatomy** is addressed through references to the horse and dog. In addition the text-atlas is intended to provide a valuable introduction to the **Anatomy of the Living Animal**. The authors were concerned with the preparation of a clear and graphic reference book of important anatomical facts for veterinarians in practice and research as well as anyone interested in morphology. This book can also serve as a dictionary of English anatomical nomenclature illustrated in color. An appendix on Applied Anatomy, included in the first and second volumes of the series, was omitted from this edition. Because of its extraordinary relevance for the practical instruction of students it will be provided in the next edition.

Our work on the ox has an unexpected urgency for three reasons: 1. Specialized textbooks for each individual species are required for curriculum revision with the trend to premature specialization and the accompanying formation of species-specific clinics. 2. In the present time of economic and social change, new diseases like bovine spongiform encephalopathy (BSE) attain enormous importance through their catastrophic effects. To determine the neuronal pathways of infection, including the autonomic nervous system, and the lymphatic system, and to judge the risk of noxious substances in the nervous system and in many organs of the body cavities, a graphic survey of bovine anatomy is necessary. 3. A licensed veterinarian is legally qualified to serve in a wide variety of positions: in private practice with small mammals, birds, horses, ruminants, and swine; in public health work to prevent transmission of diseases of animals to man; in governmental control of diseases of livestock; and in teaching and research with many species of experimental animals. To maintain public confidence in the profession, students should be required to master the basic as well as clinical sciences for food animals. This places high demands on teachers and students because a very broad and important body of information must be transmitted even though our teaching time has undergone an ill-advised reduction. Nevertheless, we are forced to accept the challenge, even with our compressed text-atlas, to reach the intended goal – to cover a huge amount of subject matter in the short time available.

This English edition is the responsibility of Professor Habel. His translation and scientific engagement in the production of this atlas and the writing and revision of many chapters are his personal service. His collaboration in the community of authors is a great enrichment.

Our thanks are due also to Prof. Dr. Dr. h.c. Simoens (Ghent) for his contributions of text and illustrations on the eye of the ox, to Prof. Dr. Dr. h.c. König (Vienna) for his article on the mammary glands, and to Prof. Dr. Dr. h.c. mult. Liebich (Munich) for his collaboration on the article, “Female genital organs.” Coauthors Dr. Wünsche, Dr. Buda, PD Dr. Bragulla, and Dr. Mülling also had their part in the completion of the book. We had additional professional support from Professors Dr. Berg (St. Kitts, West Indies), Dr. Böhme (Berlin) and Dr. Hashimoto (Sapporo). The many suggestions and the completion of many separate tasks on this atlas by the scientific, student, and technical coworkers of our Berlin Institute (see the list of coworkers) were a great help.

Finally, without the prodigious effort of our excellent artists, Renate Richter, Gisela Jahrmärker, and Diemut Starke, the Atlas in its present form would be inconceivable. Mrs. Poersch deserves thankful recognition for her careful computer composition, and the coworkers Mrs. Claudia Nöller and Mr. Thilo Voges for the preparation of subjects to be illustrated, together with computer processing, and for making the Index. Our thanks are also due to the Schlütersche Verlag, Publisher and Printer, Hannover, and especially to Dr. Oslage for always providing support and understanding cooperation in the development of this book.

The provisional completion of our common effort offers the originator and editor, after 30 years of persistent work, the opportunity for a brief reflection. The enormous expense for the production of a book, together with the revision and improvement of many new editions, and the necessity of intensive anatomical preparation of subjects for illustration, were at first greatly underestimated. After overcoming many challenges, the dominant emotion is the joy of an unexpected success that came about through fruitful collaboration with the closest coworkers of our Berlin Institute, with the student body, with the readers, and with German and foreign colleagues across national and continental borders. The experience gained thereby is of inestimable value. The editor feels richly rewarded by the achievement of a professional life-work.

Berlin/Ithaca, May, 2003

The authors

TOPOGRAPHIC ANATOMY

CHAPTER 1: THORACIC LIMB

1. SKELETON OF THE THORACIC LIMB

The **thoracic and pelvic limb** of the ox, a heavy herbivore, are quite similar in basic structure to those of the horse.

a) On the **SCAPULA** is a large, half-moon-shaped **scapular cartilage** (14). The **supraspinous fossa** (6) is remarkably narrow. It is cranial to the **scapular spine** (5). On the distal end of the spine is a prominent sharp-edged **acromion** (8), as in the dog.

b) On the proximal end of the compact **HUMERUS** the lateral **major tubercle** (25) and the medial **minor tubercle** (29) are divided into cranial and caudal parts, as in the horse. Distal to the cranial part of the major tubercle is the **crest of the major tubercle** (26), and distal to the caudal part lies the round **surface for the infraspinatus** (26') where the superficial part of the tendon terminates. The **inter-tubercular groove** (28) is covered *craniolaterally by the major tubercle, so that it is not visible in lateral view. The intermediate tubercle is insignificant, unlike that of the horse.* On the medial surface of the **body of the humerus** (31) is the raised **tuberosity of the teres major** (32'). Laterally the hooked **teres minor tuberosity** (27') and the crest-like **deltoid tuberosity** (32) stand out. On the distal end of the humerus, the articular surface is the **humeral condyle** (35). The **lateral epicondyle** (38) and the **medial epicondyle** (39) include areas for attachment of the collateral ligg. and caudal projections for the origins of flexor mm. The caudally located **olecranon fossa** (40) and the cranial **radial fossa** (41) are like those of the horse.

c) The two **BONES OF THE FOREARM (ANTEBRACHIUM)** remain complete, and, except for a **proximal** (62') and a **distal** (62'') **interosseous space**, are joined by syndesmosis in youth and by a **synostosis** in later life. The **radius** is flattened and relatively short. The articular circumference of carnivores is reduced to two small caudal **articular facets** (44) in ungulates. The slightly elevated **radial tuberosity** (46) lies farther distally than in the dog and horse. On the distal end the radius bears the **radial trochlea** (48), with tendon grooves on the cranial surface, and the **medial styloid process** (50) medially. The proximal end of the **ulna**, the **olecranon tuber** (52), is a crest with two tubercles, projecting above the radius. The distal end, the pointed **lateral styloid process** (61), extends distally beyond the radius, with which it is fused, and articulates with the ulnar carpal bone.

d) The proximal row of **CARPAL BONES** consists of the **radial** (63), **intermediate** (63'), **ulnar** (64), and the thick, bulbous **accessory** (65), **carpal bones**. Of the bones of the distal row, C I is always missing, C II and C III (66) are fused, and C IV (66) is a relatively large, separate bone.

e) Of the **METACARPAL BONES**, Mc I and Mc II are absent, and Mc V is a much reduced, rod-like bone articulating with Mc IV. The weight-bearing main metacarpal bones (**Mc III and Mc IV**) are not completely fused, as shown by the **dorsal and palmar longitudinal grooves** with the perforating **proximal and distal metacarpal canals**, and by the **intercapital notch** (69') between the two separate distal heads (**capita**, 69). Internally there is an incomplete bony septum between the marrow cavities. On the proximal base (67) the flat articular surface is partially divided by a palmar notch into a larger medial part and a smaller lateral part.

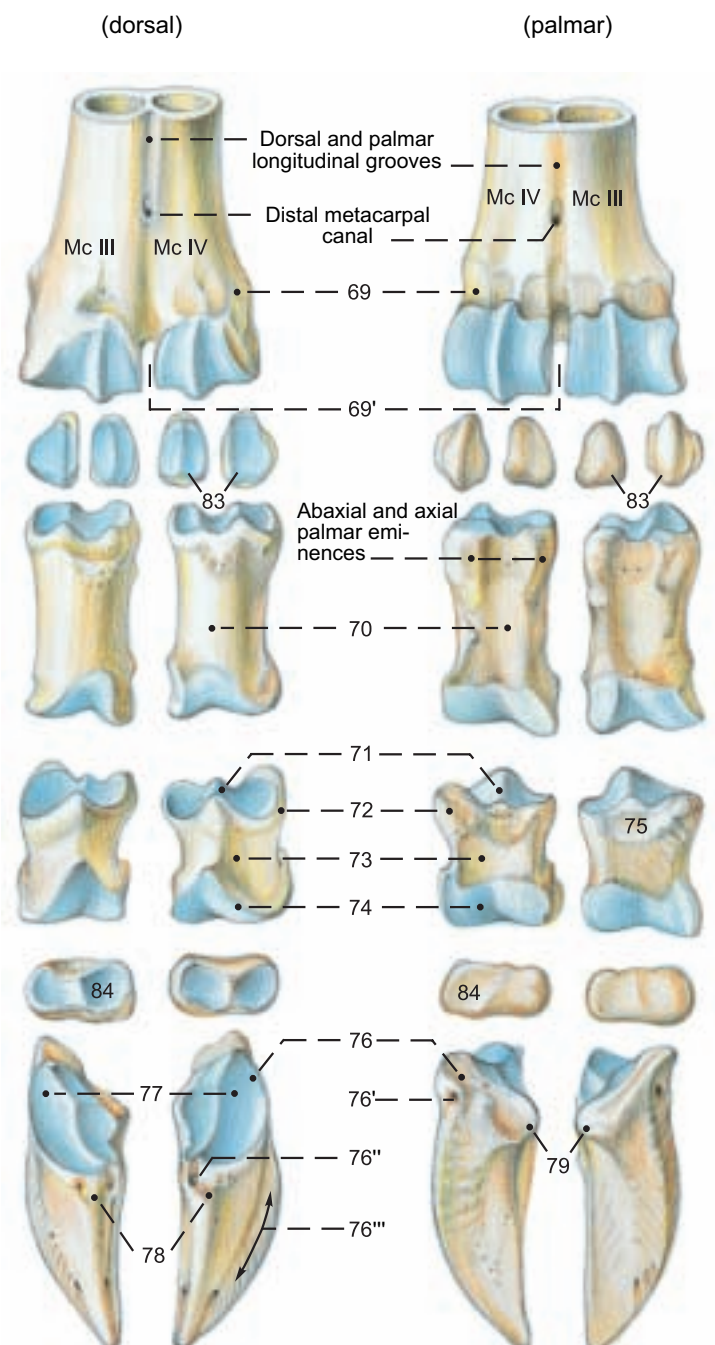
f) The **PHALANGES** form two main **digits (III and IV)** and two **dewclaws (paradigiti II and V)**. The sides of the digits are designated axial and abaxial with reference to the long axis of the limb, and the joints are called, for the sake of brevity, the **fetlock, pastern, and coffin joints**, as in the horse. Only on digits III and IV are three phalanges present: the **proximal** (70), **middle** (71), and **distal** (76) **phalanges**. They are somewhat prismatic, being flattened on the interdigital surface. The prominent **abaxial palmar eminence** (see text figure) of the prox. phalanx is a landmark for the fetlock joint. *The dorsal border of the distal phalanx extends from the extensor proc. (78) to the apex.* The dewclaws, which do not reach the ground, except on soft footing, lack the proximal phalanx, and sometimes also the middle phalanx, and are attached to the main digits by fascial ligaments only.

In small ruminants, the dewclaws often lack phalanges; they are then purely cutaneous structures.

Superficial details of the phalanges of the main digits are similar to those of the horse.

g) The **SESAMOID BONES**. The four **proximal sesamoid bones** (83) are in the palmar part of the fetlock joints, and the **distal sesamoid (navicular) bone** (84) is in the palmar part of each coffin joint. They are not present in the dewclaws.

Digital Bones of the Manus



Bones

Scapula

- Costal surface (1)
- Serrated surface (2)
- Subscapular fossa (3)
- Lateral surface (4)
- Scapular spine (5)
- Tuber of scap. spine (5') + -
- Supraspinous fossa (6)
- Infraspinous fossa (7)
- Acromion (8)
- Caudal border (10)
- Cranial border (11)
- Scapular notch (12)
- Dorsal border (13)
- Scapular cartilage (14)
- Caudal angle (15)
- Cranial angle (16)
- Ventral angle (17)
- Glenoid cavity (18)
- Neck of scapula (19)
- Supraglenoid tubercle (21) + -
- Coracoid process (22)

Humerus

- Head of humerus (23)
- Neck of humerus (24)
- Major tubercle (25)
- Cranial part (25')
- Caudal part (25'')
- Crest of major tubercle (26) + -
- Infraspinatus surface (26')
- Triceps line (27)
- Teres minor tuberosity (27')
- Intertubercular groove (28)
- Minor tubercle (29)
- Cranial part (29')
- Caudal part (29'')
- Body of humerus (31)
- Deltoid tuberosity (32)
- Teres major tuberosity (32')
- Crest of humerus (33)
- Brachialis groove (34)
- Condyle of humerus (35)
- Lateral epicondyle (38)
- Lateral supracondylar crest (38')
- Medial epicondyle (39)
- Olecranon fossa (40)
- Radial fossa (41)

Radius

- Head of radius (43)
- Articular facets (44)
- Neck of radius (45)
- Radial tuberosity (46)
- Body of radius (47)
- Trochlea of radius (48)
- Medial styloid process (50)

Ulna

- Olecranon (51)
- Olecranon tuber (52)
- Anconeal process (53)
- Trochlear notch (54)
- Medial coronoid process (55)
- Lateral coronoid process (56)
- Radial notch (57)
- Body of ulna (58)
- Head of ulna (59)
- Lateral styloid process (61)
- Prox. interosseous space (62')
- Dist. interosseous space (62'')

Carpal bones

- Radial carpal bone (63)
- Intermediate carpal bone (63')
- Ulnar carpal bone (64)
- Accessory carpal bone (65)
- Carpal bones II and III fused (66)
- Carpal bone IV (66)

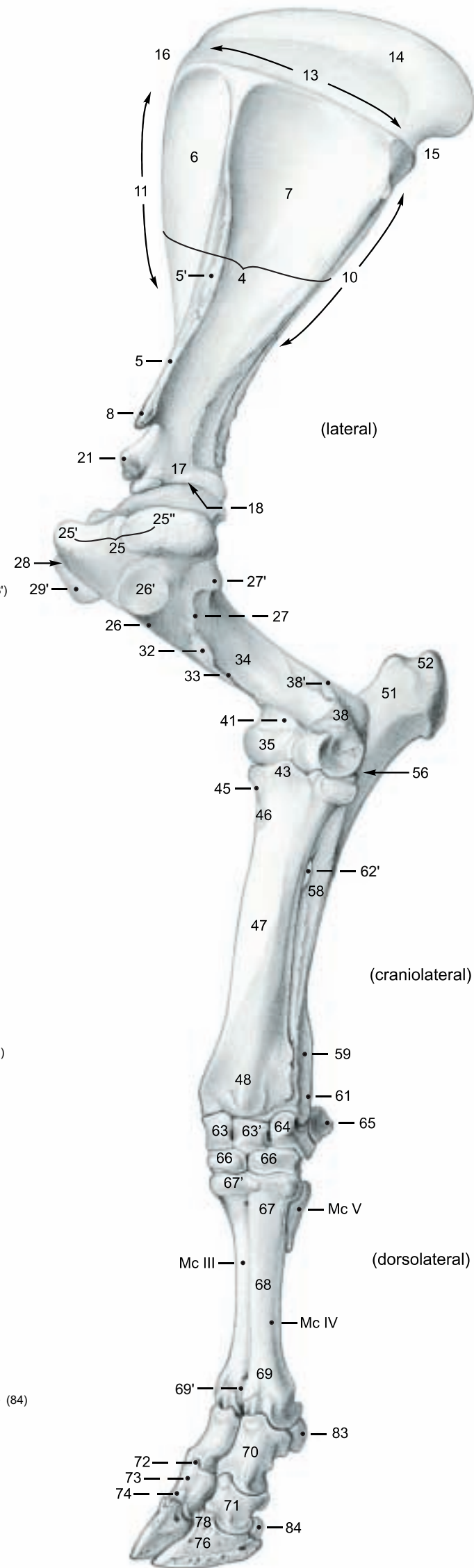
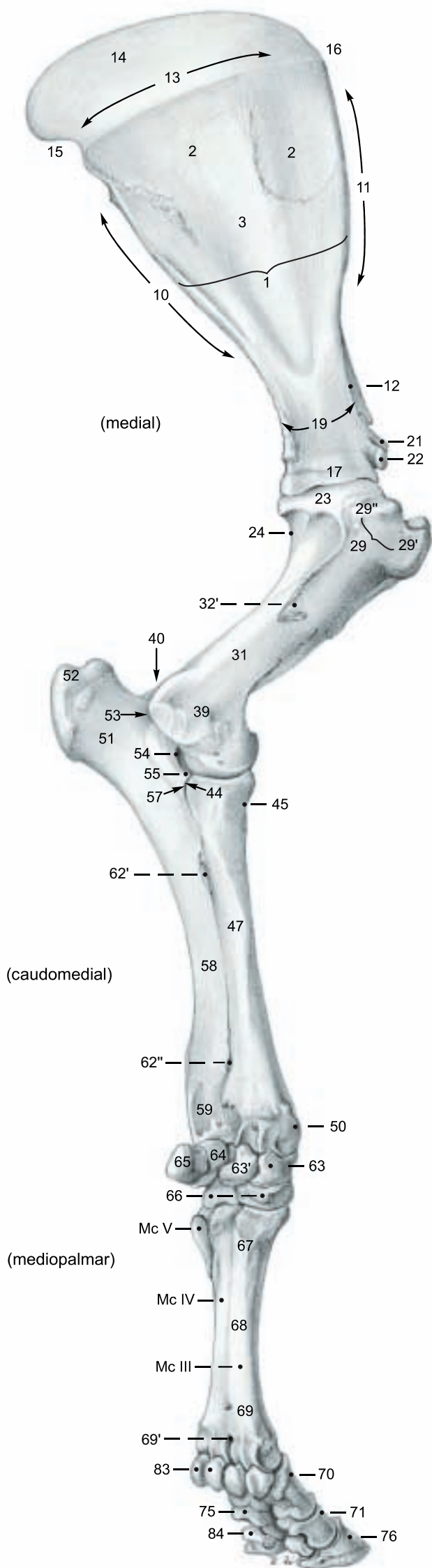
Metacarpal bones III and IV, V

- Base (67)
- Tuberosity of Mc III (67')
- Body (68)
- Heads (capita, 69)
- Intercapital notch (69')

Digital bones

- Proximal phalanx (70)
- Middle phalanx (71)
- Base (72)
- Body (73)
- Head (74)
- Flexor tuberosity (75)
- Distal phalanx (coffin bone 76)
- Abaxial foramen (76')
- Axial foramen (76'')
- Parietal groove (76''')
- Articular surface (77)
- Extensor process (78)
- Flexor tubercle (79)
- Proximal sesamoid bones (83)
- Distal sesamoid (navicular) bone (84)

(See also p. 2 text figure)



2. MUSCLES AND NERVES OF THE SHOULDER, ARM, AND FOREARM

The thoracic limb is skinned down to the hoofs as carefully as possible to preserve the cutaneous nn. and superficial vessels. At the carpus the precarpal subcutaneous bursa should be examined. The skin is carefully cut around the dewclaws to leave them on the limb. In the following nerve and muscle dissection, the pectoral mm. are removed with attention to the cranial and caudal pectoral nn. The blood vessels are spared for their subsequent demonstration. The scapular part of the deltoideus is removed, except for a small stump on the scapula, sparing the cutaneous branch of the axillary n. The tensor fasciae antebrachii is transected at its attachment to the fascia, and the lateral head of the triceps is transected over the superficial branch of the radial n. and reflected distally.

a) The **NERVES AND MUSCLES OF THE SHOULDER AND ARM**. The nerves are supplied by the brachial plexus. The **roots of the plexus (5)** come from the ventral branches of C6–T2. *The number of nerves that arise from the plexus is the same in all species of domestic mammals.*

The **suprascapular n. (8)**, from C6–C7; motor, passes laterally between the cranial border of the subscapularis and the **supraspinatus (1)** and innervates the latter as well as the strongly tendinous **infraspinatus (11)**. The 1–4 **subscapular nn. (4)**, from C7–C8; motor, are the main nerves of the **tripartite subscapularis (4)**. Small caudal parts of it are innervated by the **axillary n. (13)**, from C7–C8; mixed. This nerve passes laterally across the cranial border of the tendon of the **teres major (2)**, which it innervates, to the three parts of the deltoideus: **scapular (6)**, **acromial (7)**, and **clavicular (23)** [cleidobrachialis]. The axillary n. also innervates the **teres minor (12)**, emerges through the scapular part of the deltoideus, runs distally on the extensor carpi radialis as the **cranial cutaneous antebrachial n. (30)**, and ends in the proximal half of the forearm. The **thoracodorsal n. (3)**, from C7–C8; motor, ends in the **latissimus dorsi (3)**, the distal stump of which has been retained. The **median n. (14)** C8–T2, forms the axillary loop under the axillary a. with the musculocuta-

neous n., as in the horse. *The median n. is also bound by connective tissue to the ulnar n. in the upper arm, and runs at first undivided craniomedially to the level of the elbow joint.* The **musculocutaneous n. (9)**, from C6–C8; mixed, gives off the **proximal muscular br.(b)**, which passes between the parts of the **coracobrachialis (16)**, innervating them and the **biceps brachii (26)**. The nerve separates from the median n. in the middle of the arm, and gives off the **distal muscular br. (d)**, which passes deep to the biceps and innervates the **brachialis (21)**. The musculocutaneous n. is continued as the **medial cutaneous antebrachial n. (31)**, which becomes subcutaneous over the lacertus fibrosus (*thin, unlike that of the horse*), and runs distally medial to the cephalic v. The **radial n. (15)**, from C7–T1; mixed, passes laterally between the **medial (19)** and **long (18)** heads of the **triceps brachii** and gives off branches to them, as well as to the **lateral head (17)**, **tensor fasciae antebrachii (22)**, and **anconeus (25)**. The anconeus is difficult to separate from the lateral head of the triceps, and *an accessory head is incompletely separable from the medial head.* The radial n. follows the spiral course of the brachialis around the humerus from caudal to lateral, and *occasionally it supplies the distal part of the brachialis*, as in the horse. While still under the lateral head of the triceps, the nerve divides into deep (20) and superficial (32) branches.

At the carpal joint the tendon sheaths of the digital extensors, ext. carpi obliquus, and flexor carpi radialis should be examined. The med. and lat. cutaneous antebrachial nerves must be preserved. To demonstrate the nerves and vessels, the pronator teres is transected. The flexor carpi ulnaris and -radialis are transected in the middle of the forearm.

b) **NERVES AND MUSCLES ON THE CRANIOLATERAL SURFACE OF THE FOREARM**. The muscles are innervated by the **deep branch (20)** of the radial n. Its **superficial branch (32)** becomes the occasionally double **lateral cutaneous antebrachial n. (33)**, which runs distally on the extensor carpi radialis, lateral to the cephalic v., with the medial cutaneous antebrachial n. on the medial side of the vein, and gives off several branches to the lateral side of the forearm and carpus. On the metacarpus it divides into dorsal common digital nn. II and III.

The origins of the digital and carpal extensors are predominantly on the lateral epicondyle of the humerus.

The **common digital extensor (40)** has two bellies and two tendons, which cross the carpus in the same synovial sheath. The larger, more cranial one is the **medial digital extensor (proper extensor of digit III)**. Its flat tendon ends mainly on the *extensor process and dorsal surface of the middle phalanx*, but a thin abaxial branch descends vertically to a termination *below the articular margin of the distal phalanx*. At the fetlock joint an axial band of the tendon goes to the proximal end of the *proximal phalanx of the other main digit*. Deep to this band and the tendon, *a fibrous dorsal sesamoid body is embedded in the joint capsule*.* Above the pastern joint the tendon is joined by **axial and abaxial (l) extensor branches** of interosseus III. The small caudal belly of the common digital extensor is the **common extensor of digits III and IV**. Its tendon bifurcates above the fetlock joint, and each branch, provided with a synovial sheath, ends on the extensor process of the respective distal phalanx.

The tendon of the **lateral digital extensor (41, proper extensor of digit IV)** receives the extensor branches of interosseus IV (l) and ends in the same way as the medial digital extensor. Each proper extensor has a synovial bursa at the fetlock joint.

The tendon of the large **extensor carpi radialis (35)** is almost surrounded by a synovial bursa on the carpus, and terminates on the tuberosity of Mc III.

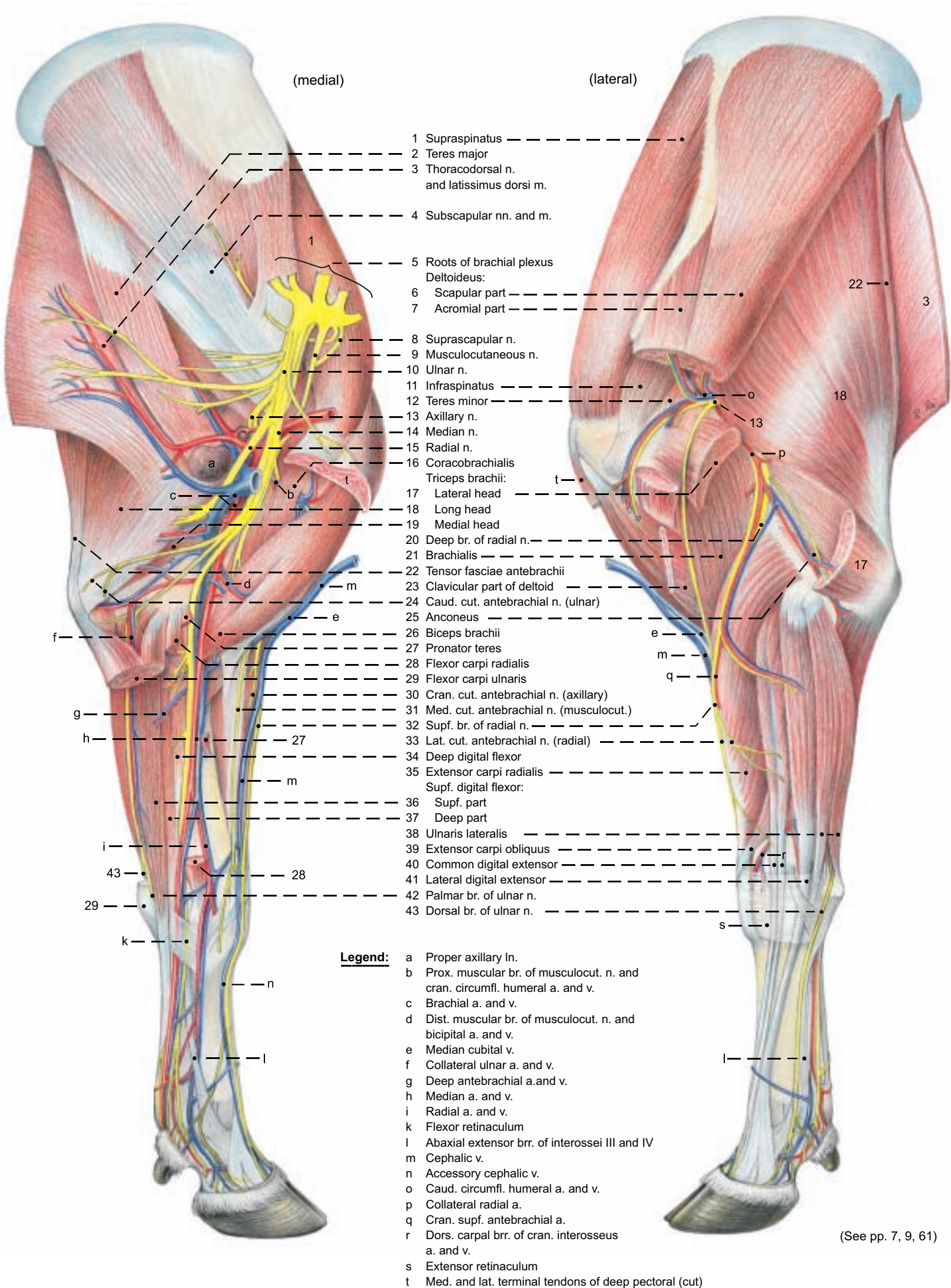
The **ulnaris lateralis (38)** [extensor carpi ulnaris] is on the latero-caudal surface of the forearm. It terminates with a *phylogenetically older accessory tendon on the rudimentary Mc V, and with a newer main tendon on the accessory carpal bone, making the muscle a flexor of the carpus.*

The tendon of the **extensor carpi obliquus (39)** [abductor pollicis longus], enclosed in a synovial sheath, runs across the tendon of the extensor carpi radialis and ends on Mc III. *The supinator is absent.*

c) **NERVES AND MUSCLES OF THE CAUDOMEDIAL SURFACE OF THE FOREARM**. The muscles are innervated by the ulnar n. and **median n. (14)** from C8–T2; mixed. The latter courses, accompanied by the brachial a. and v., deep to the **pronator teres (27)** and **flexor carpi radialis (28)**, giving off muscular branches to them and to the **humeral and radial heads of the deep digital flexor (34)**. *The pronator quadratus is absent.* The nerve continues in the forearm, accompanied by the median a. and v. It supplies the skin on the medial surface of the carpus and the proximal third of the metacarpus, and, *without division, unlike that of the horse*, passes through the carpal canal on the medial border of the deep tendon of the supf. dig. flexor. In the metacarpus it divides into palmar common digital nn. II and III and the communicating br. to the supf. palmar br. of the ulnar n. Palmar common dig. n. III divides into axial palmar dig. nn. III and IV. The **ulnar n. (10)**, from C8–T2; mixed, while still in the upper arm, gives off the double **caudal cutaneous antebrachial n. (24)** to the caudomedial and caudolateral surfaces of the forearm and carpus. The ulnar n., accompanied by the collateral ulnar a. and v., passes to the caudal surface of the elbow joint. It gives branches to the **flexor carpi ulnaris (29)** and **supf. digital flexor (36, 37)**, as well as to the **ulnar and humeral heads of the deep dig. flexor (34)**. Between the flexor carpi ulnaris and ulnaris lateralis it divides into the **dorsal branch (43)**, which in the metacarpus becomes dorsal common dig. n. IV, and the **palmar branch (42)**, which passes through the carpal canal and runs lateral to the tendons of the supf. dig. flexor. It divides into a **deep branch** for the tendons of the interossei, and a **superficial branch**, which runs distally in the lateral groove between the deep flexor tendon and interosseus IV to form, with the communicating br. of the median n., palmar common digital n. IV.

The supf. dig. flexor is composed of two parts. The tendon of the supf. part passes between the two layers of the flexor retinaculum (k). The tendon of the deep part passes through the carpal canal with the tendon of the deep flexor. The two tendons of the supf. flexor join in the distal part of the metacarpus.

Thoracic limb



3. CUTANEOUS NERVES, BLOOD VESSELS, AND LYMPH NODES OF THE THORACIC LIMB

a) The **CUTANEOUS INNERVATION** of the dorsal part of the scapular region is supplied by the dorsal branches of C8 and T1 to T5, which come over the dorsal border of the scapular cartilage. The **supraclavicular nn.** innervate the craniolateral surface of the shoulder and arm, and the **intercostobrachial n.** supplies the caudolateral surface to the level of the olecranon (see text figure).

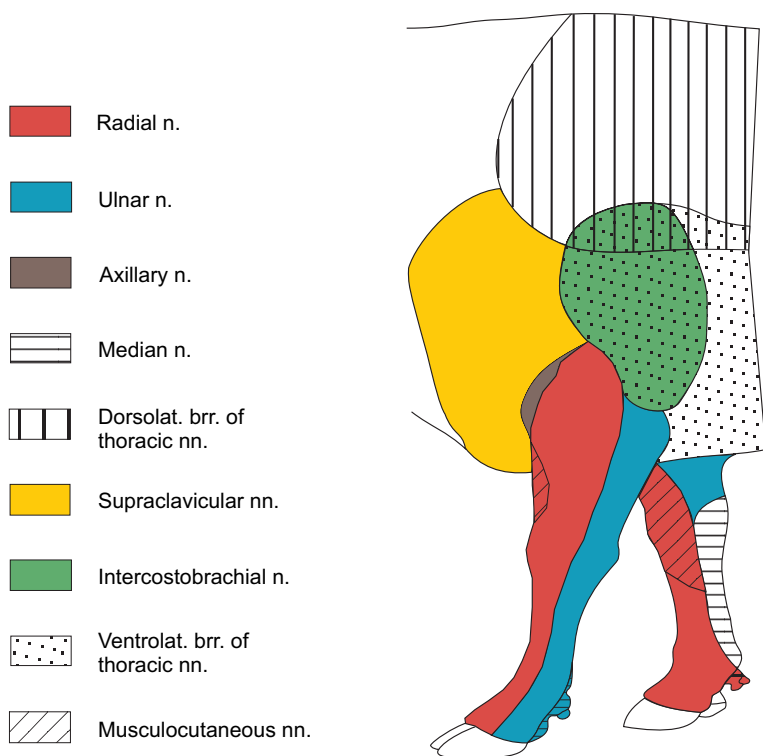
The small **cranial cut. antebrachial n.** (25, axillary) supplies the arm and extends down to the middle of the forearm. The skin of the forearm is also innervated by the large **lateral cut. antebrachial n.** (27, supf. br. of radial), running on the cranial surface of the extensor carpi radialis lateral to the cephalic v. and accompanied medial to the vein by the **medial cut. antebrachial n.** (30, musculocutaneous). The **caudal cut. antebrachial n.** (7, ulnar) ends at the accessory carpal bone.

The skin of the carpus and metacarpus is innervated on the dorsal surface by the lat. cut. antebrachial n. and its branches: **dorsal common digital nn. II (34) and III (35)**, from the supf. br. of the radial n. The lat. cut. antebrachial n. communicates above the carpus with the medial cut. antebrachial n., which supplies the dorso-medial surface. The dorsolateral surface is innervated by the dorsal br. of the ulnar n. and its continuation, **dorsal common digital n. IV (33)**.

On the palmar surface the skin is innervated by the median n. and its branches, **palmar common digital nn. II (18) and III (17)**, and by the supf. palmar br. of the ulnar n. (p. 9, 8) which receives the **communicating br. (f)** from the median n. and continues as the short **palmar common digital n. IV**.

The digits are supplied by the dorsal and palmar proper digital nn. from the corresponding common digital nn. (See p. 8).

Nerves of the thoracic limb



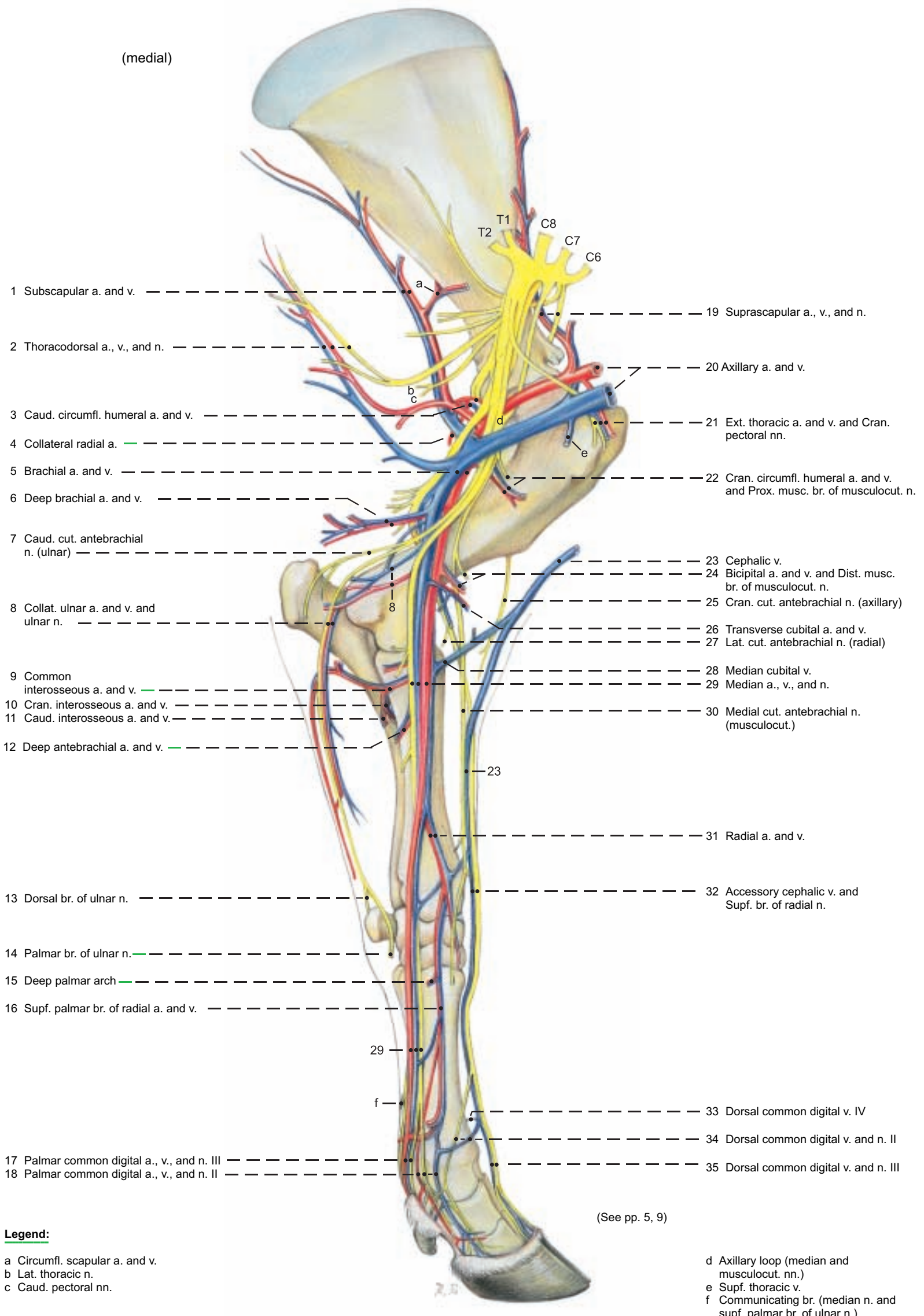
b) The **BLOOD VESSELS** of the thoracic limb come from the **subclavian a. and v.** and the external jugular v., from which the **cephalic v. (23)** originates. The latter, as in the horse, but unlike the dog, has no anastomosis with the axillary v. Distal to the cranial border of the first rib, where the subclavian vessels become the **axillary a. and v. (20)**, the latter vessels give off the **external thoracic a. and v. (21)**, as well as the **suprascapular a. and v. (19)** for the lateral muscles of the shoulder and for the shoulder joint, and the large **subscapular a. and v. (1)**, which run along the caudal border of the scapula and supply most of the muscles of the shoulder joint, and the long head of the triceps. One branch of the axillary a. is the **caudal circumflex humeral a. (3)**, which gives off the **collateral radial a. (4)**, from which arises the **cranial supf. antebrachial a. (p. 9, 1)**. This ends in the **small dorsal common digital aa. II and III (p. 9; 9, 12)**. The caudal circumflex humeral v. ends in the region of the

shoulder joint. Distal to the origin of the **cranial circumflex humeral a. (22)** – *the vein comes from the subscapular v.* – the axillary vessels become the **brachial a. and v. (5)**. These first give off the **deep brachial a. and v. (6)** to the caudal muscles of the elbow joint. The next branches are the **collateral ulnar a. and v. (8)**, of which the artery continues indirectly to the **small dorsal common digital a. IV**, while the vein ends at the elbow joint, mostly in the caudomedial muscles of the forearm. Distal to the collateral ulnar vessels, the **bicipital a. and v. (24)** arise and supply the biceps. They may originate from the next distal vessels, the **transverse cubital a. and v. (26)**. The last branches of the brachial vessels are the **common interosseus a. and v. (9)**, arising distal to the elbow joint. These divide into the large **cranial interosseus a. and v. (10)** and the **insignificant caudal interosseus a. and v. (11)**, which usually do not reach the carpus. The cranial interosseus a. and v. pass laterally through the proximal interosseous space and run on the lateral surface of the radius and ulna to the distal interosseous space, where they are continued by the **interosseous br.**, passing medially through the space to become the **palmar br.** These divide into **deep and superficial br.** (p. 9, 8) The ulnar a. and v. are absent, as in the horse. The **cephalic v. (23)**, on the surface of the cleidobrachialis, gives off the **median cubital v. (28)**, a long oblique anastomosis to the brachial v. at its point of transition to the median v. The cephalic v. continues distally on the extensor carpi radialis to the distal third of the forearm, where it gives off the **accessory cephalic v. (32)**. This continues the direction of the cephalic v. to the dorsal surface of the metacarpus and becomes **dorsal common digital v. III (35)**. Inconstant **dorsal common digital vv. II (34) and IV (33)** are given off the main trunk and *end in the distal deep palmar arch*. The cephalic v. turns medially and joins the radial v. above the carpus. The brachial a. and v. are continued medially in the forearm by the **median a. and v. (29)**, which give off in their course several branches: the **deep antebrachial aa. and vv. (12)** to the caudal muscles of the forearm, and the **radial a. and v. (31)** in the middle of the forearm. The sometimes double radial vein receives the cephalic v. proximal to the carpus. At the carpus the radial a. and v. join their respective **dorsal carpal networks**, which also receive the cranial interosseous a. and v. and the dorsal carpal br. of the collateral ulnar a. (without the corresponding v.). **Dorsal metacarpal a. III** comes from the arterial dorsal carpal network. It is accompanied in the dorsal groove of the metacarpal bone by **dorsal metacarpal v. III** from the venous dorsal carpal network. On the palmar surface of the metacarpal bone the radial a. and v. and the deep palmar branches of the cranial interosseus a. and v. form the **deep palmar arches (15)**, which give off the deep **palmar metacarpal aa. and vv. II–IV**. Palmar metacarpal v. II is the direct continuation of the radial v. The continuing median a. and v. pass through the carpal canal on the palmaromedial surface of the deep flexor tendon and the tendon of the deep part of the supf. flexor, to the metacarpus. Here the median a., the supf. palmar br. of the cranial interosseus a., and the supf. palmar br. of the radial a. are connected across the surface of the flexor tendons by the zigzag **superficial palmar arch**, which gives off **palmar common digital aa. II (18) and IV**. **Palmar common digital a. III (17)** is the direct continuation of the median a. distal to the arch, and it is the main blood supply to the large digits. It courses to the interdigital space, crossing the medial branch of the supf. flexor tendon, where the pulse is palpable. It is accompanied by **palmar common digital v. III (17)**. The **interdigital a. and v. (p. 11, 5')** connect the palmar with the dorsal digital vessels. *The palmar common digital veins II and IV originate from the distal deep palmar venous arch.* (See also pp. 8–11.)

c) **LYMPHATIC STRUCTURES.** The large **proper axillary ln. (p. 5, a)** lies caudal to the shoulder joint at the level of the second intercostal space between the thoracic wall and the medial surface of the teres major. Small **axillary lnn. of the first rib** are associated with the axillary vessels on the lateral surface of the rib. *Both groups of lnn. are examined in meat inspection in special cases. In the hanging split carcass the proper axillary node is drawn cranially by the weight of the limb, and may be conveniently found by an incision from the inside of the thoracic wall in the middle of the first intercostal space.* The afferent lymphatics come from the bones, joints, and muscles of the shoulder, and from the arm and forearm. The efferent lymphatics go to the lnn. of the first rib, proper axillary ln., and caudal deep cervical lnn., which are drained on the left side by the thoracic duct and on the right by the right tracheal duct. The lymphatic drainage of the manus goes to the supf. cervical ln.

Arteries, Veins, and Nerves of thoracic limb

(medial)



- 1 Subscapular a. and v. -----
- 2 Thoracodorsal a., v., and n. -----
- 3 Caud. circumfl. humeral a. and v. -----
- 4 Collateral radial a. -----
- 5 Brachial a. and v. -----
- 6 Deep brachial a. and v. -----
- 7 Caud. cut. antebrachial n. (ulnar) -----
- 8 Collat. ulnar a. and v. and ulnar n. -----
- 9 Common interosseous a. and v. -----
- 10 Cran. interosseous a. and v. -----
- 11 Caud. interosseous a. and v. -----
- 12 Deep antebrachial a. and v. -----
- 13 Dorsal br. of ulnar n. -----
- 14 Palmar br. of ulnar n. -----
- 15 Deep palmar arch -----
- 16 Supf. palmar br. of radial a. and v. -----
- 17 Palmar common digital a., v., and n. III -----
- 18 Palmar common digital a., v., and n. II -----
- 19 Suprascapular a., v., and n. -----
- 20 Axillary a. and v. -----
- 21 Ext. thoracic a. and v. and Cran. pectoral nn. -----
- 22 Cran. circumfl. humeral a. and v. and Prox. musc. br. of musculocut. n. -----
- 23 Cephalic v. -----
- 24 Bicipital a. and v. and Dist. musc. br. of musculocut. n. -----
- 25 Cran. cut. antebrachial n. (axillary) -----
- 26 Transverse cubital a. and v. -----
- 27 Lat. cut. antebrachial n. (radial) -----
- 28 Median cubital v. -----
- 29 Median a., v., and n. -----
- 30 Medial cut. antebrachial n. (musculocut.) -----
- 31 Radial a. and v. -----
- 32 Accessory cephalic v. and Supf. br. of radial n. -----
- 33 Dorsal common digital v. IV -----
- 34 Dorsal common digital v. and n. II -----
- 35 Dorsal common digital v. and n. III -----

Legend:

- a Circumfl. scapular a. and v.
- b Lat. thoracic n.
- c Caud. pectoral nn.

- d Axillary loop (median and musculocut. nn.)
- e Supf. thoracic v.
- f Communicating br. (median n. and supf. palmar br. of ulnar n.)

(See pp. 5, 9)

4. VESSELS AND NERVES OF THE MANUS

The dissection is done on the embalmed limbs provided and on fresh specimens of the metacarpus and digits. The skin is carefully removed down to the hoofs, preserving the nerves and vessels.

a) The **PALMAR NERVES** come predominantly from the median n., but also from the palmar br. of the ulnar n. (For vessels, see p. 6.)

The **median n. (4)**, accompanied by the **median a. and v.**, passes through the carpal canal, medial to the flexor tendons, to the mediopalmar surface of the metacarpus, where it is covered by deep fascia. (See p. 10.) Here the nerve lies between the **small superficial br. of the radial a. and v. (6)** medially, and the **large median a. and the usually double median v.** on the other side. In the middle of the metacarpus the nerve divides under the proximal ligament of the medial dewclaw into palmar common digital nn. II and III. **Palmar common digital n. II (13)** runs in the medial groove between interosseus III and the flexor tendons, accompanied from the distal third of the metacarpus by **palmar common digital a. and v. II (13)**. They divide proximal to the fetlock joint into the **axial palmar a., v., and n. of digit II (18, dewclaw)** and the continuing **abaxial palmar digital a., v., and n. III (19)** for deep digital structures and the dermis of the bulb and wall as far as the apex of the hoof. (Axial and abaxial digital nerves and vessels are understood to be “proper”, and this adjective may be omitted.) **Palmar common digital n. III (15)** is usually double. The branches are accompanied on each side by the branches of the also double **palmar common digital v. III**, and between them by **palmar common digital a. III**, proceeding in the direction of the interdigital space (see p. 10).

The **ulnar n.** divides near the middle of the forearm into dorsal and palmar branches. The **palmar br. (p. 7. 14)** crosses deep to the tendon of the flexor carpi ulnaris and runs between the deep part of the superficial digital flexor and the accessory carpal bone. Just distal to the carpus it gives off the **deep br.** to the interossei and continues as the **supf. br. (8)**, which runs in the lateral groove between interosseus IV and the digital flexor tendons, accompanied by the **supf. palmar br. of the cranial interosseous a. (8)**. Distal to the **communicating br. (10)** from the median n., the supf. br. of the palmar br. of the ulnar becomes the short **palmar common digital n. IV**, accompanied by the corresponding a. and v. Proximal to the fetlock joint of the fourth digit they divide into the **axial palmar digital a., v., and n. of digit V (22, dewclaw)** and the **abaxial palmar digital a., v., and n. IV (24)**, with distribution like that of the corresponding structures of digits II and III. **Deep palmar metacarpal nn. like those of the dog and horse do not exist.** Deep **palmar metacarpal aa. and vv. II - IV** from the deep palmar arches run distally on the metacarpal bone and anastomose proximal to the fetlock joint with the supf. palmar vessels (see p. 6).

b) The **DORSAL NERVES** come mainly from the supf. br. of the radial n. (lat. cut. antebrachial n.) and also from the dorsal br. of the ulnar. (Vessels, see p. 6.)

The **dorsal br. of the ulnar n. (5)** emerges between the ulnaris lateralis and the flexor carpi ulnaris, about 2 cm proximal to the accessory carpal bone and runs distally across the bone. It continues on the lateral surface of the carpus to the groove between the metacarpal bone and interosseus IV, where it becomes **dorsal common digital n. IV (7)**. On the dorsolateral surface of the fetlock joint it gives off the small **axial dorsal digital n. V (23)**. (The dewclaws have migrated to the palmar surface from their original lateral and medial positions.) Common digital n. IV is continued by **abaxial dorsal digital n. IV (25)** to the dorsolateral coronary region of the fourth digit.

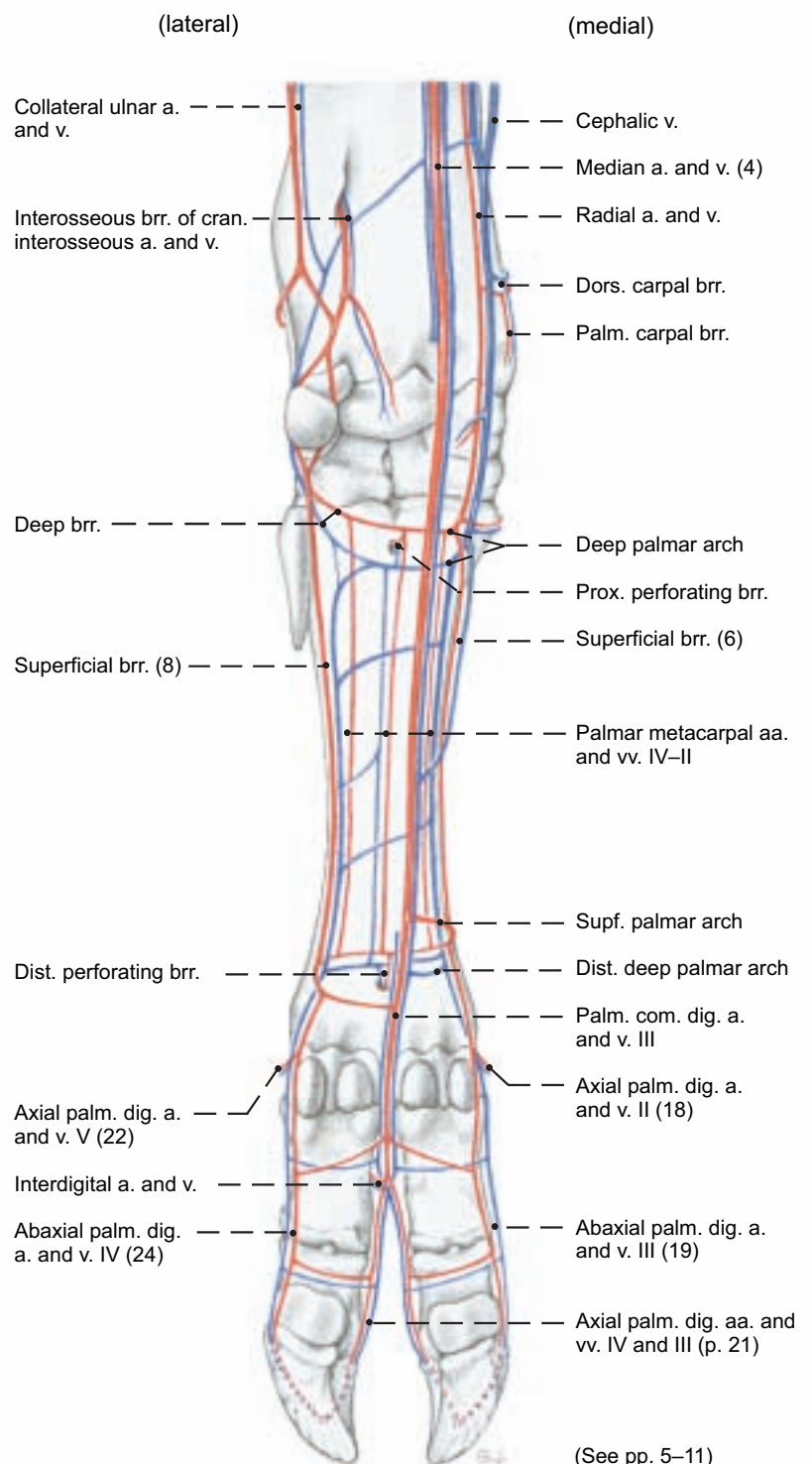
The **supf. br. of the radial n. (3, lat. cut. antebrachial n.)**, accompanied medially by the **accessory cephalic v. (2)** and the often double **cranial supf. antebrachial a. (1)** passes across the dorsomedial surface of the carpus. Just distal to the middle of the metacarpus the nerve can be palpated on the bone medial to the three digital extensor tendons. Here it divides into **dorsal common digital nn. III (12) and II (9)**. The latter is small. It crosses under **dorsal common digital v. II (11)** if that is present, reaches the medial surface of the fetlock joint with the small **dorsal common digital a. II (9)**, and divides into **axial dorsal digital n. II** to the dewclaw (16), and **abaxial dorsal digital n. III (17)** to the dorsomedial coronary region of the third digit. *As they cross the fetlock joints the abaxial dorsal and palmar digital nn. course on opposite borders of the abaxial palmar digital v.*

They may be connected by a communicating br. at the level of the proximal phalanx.

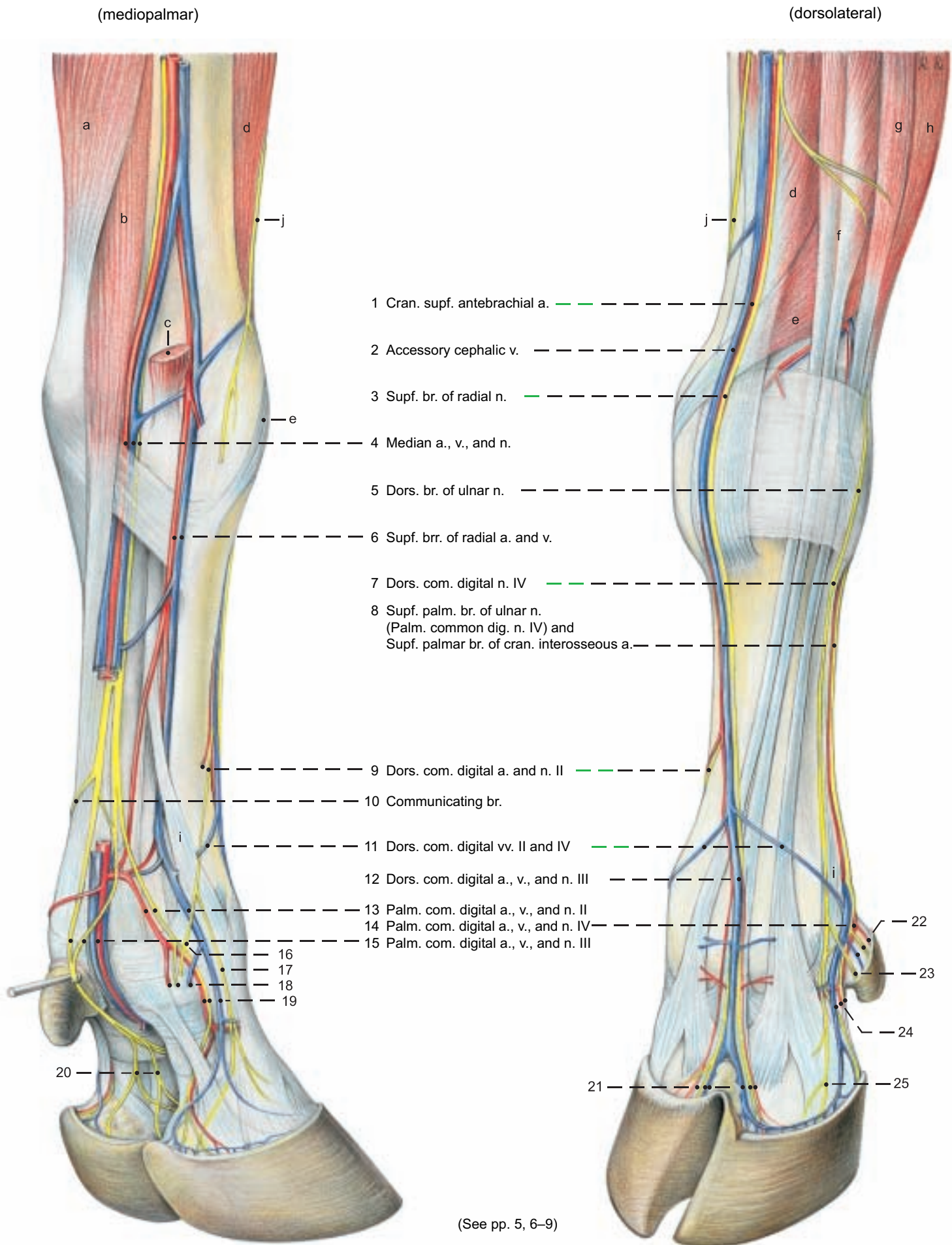
The continuing **dorsal common digital a., v., and n. III (12)** cross the tendon of the medial digital extensor (p. 5, 40) and the medial branch of the tendon of the common extensor of digits III and IV (p. 5, 41) to reach the interdigital space where they divide into the **axial dorsal aa., vv., and nn. of digits III and IV**.

There are no deep dorsal metacarpal nn., unlike the system in the metatarsus. Deep dorsal vessels are reduced to the **dorsal metacarpal a. III and (inconstant) v. III (p. 11, 4)**, running in the dorsal longitudinal groove of the bone to the interdigital space, where they anastomose with the superficial dorsal common digital vessels.

Arteries and Veins of the Manus (palmar)



Arteries, Veins, and Nerves of the Manus



Legend:

- | | | | |
|---|---|--|--|
| 16 Axial dors. digital n. II | 21 Axial dors. digital aa., vv., and nn. III and IV | a Flexor carpi ulnaris | g Lat. digital extensor |
| 17 Abaxial dors. digital n. III | 22 Axial palm. digital a., v., and n. V | b Supf. digital flexor | h Ulnaris lateralis |
| 18 Axial palm. digital a., v., and n. II | 23 Axial dors. digital n. V | c Flexor carpi radialis (resected) | i Abaxial extensor branches Interosseus III and IV |
| 19 Abaxial palm. digital a., v., and n. III | 24 Abaxial palm. digital a., v., and n. IV | d Extensor carpi radialis | j Med. cut. antebrachial n. (musculocutaneous) |
| 20 Axial palm. digital nn. III and IV | 25 Abaxial dors. digital n. IV | e Extensor carpi obliquus | |
| | | f Common digital extensor
Medial digital extensor
Common extensor of digits III and IV | |

5. INTERDIGITAL NERVES AND VESSELS, INTEROSSEI, AND FASCIAE OF THE MANUS

a) The **INTERDIGITAL NERVES AND VESSELS** of the manus come primarily from the **palmar common digital a., v., and n. III (5)**, whose branches communicate with the corresponding dorsal nerves and vessels (see p. 8).

On the pes the main blood supply of the digits is the **dorsal metatarsal a. III (11 and p. 21, 12)**. This difference is important surgically. The digital vessels and nn. of the pes have the same connections as on the manus. Usually the branches of the double palmar common digital n. III unite for a short distance at the beginning of the interdigital space, and divide again into **axial palmar digital nn. III (6) and IV (7)**. If there is no common trunk, the branches are continued by the axial palmar digital nn., which give off communicating branches to the **axial dorsal digital nn. III and IV**. **Palmar common digital a. III (5)** gives off branches to the proximal phalanges. These branches pass between the deep flexor tendon and the bone and anastomose with the abaxial palmar digital aa. A dorsal branch, the **interdigital a. (5')**, anastomoses with the **dorsal metacarpal a. III (4)** and the **small dorsal common digital a. III (1)** and supplies the **axial dorsal digital aa. III (3) and IV (2)**. Distal to the interdigital a., palmar common digital a. III divides into **axial palmar digital aa. III (6) and IV (7)**. **Palmar common digital v. III (5)**, often double, unites at the middle of the proximal phalanx, where it receives the anastomotic branches of the abaxial palmar digital vv. and gives off the **interdigital v. (5')** and the **axial palmar digital vv (6, 7)**. The interdigital v. has connections with dorsal digital vv. corresponding to the arteries. The axial dorsal digital aa., vv., and nn. supply the dorsal coronary and interdigital regions of the third and fourth digits. The axial palmar (plantar) aa., vv., and nn. supply the interdigital deep structures and dermis of the bulb and hoof of the third and fourth digits. (For the supply of the abaxial surface of the digits, see p. 8.) The axial palmar (plantar) a. and v. enter the axial foramen in the distal phalanx and anastomose in the bone with the abaxial palmar a. and v., which enter through the abaxial foramen, to form the terminal arches.

b) The **INTEROSSEI III AND IV** (see p. 18) provide support for the fetlock joints of the ox comparable to that of interosseus III (medius) in the horse. These muscles originate from the proximal end of the metacarpal (metatarsal) bone and the deep palmar (plantar) carpal lig. In young animals they are relatively fleshy, and in older animals, predominantly tendinous. Interossei III and IV are fused along their axial borders in the metacarpus (metatarsus), but they separate and terminate on the corresponding digits. *In the middle of the metacarpus (metatarsus) the interossei give off the accessory lig., which bifurcates and joins the branches of the supf. digital flexor tendon at the level of the fetlock joints in the formation of the sleeves (manicae flexoriae) through which the branches of the deep flexor tendon pass.* Proximal to the fetlock joints each interosseus divides into two tendons (h), each with two **extensor branches (p. 5, l; p. 9, i)**. The two tendons are attached to the sesamoid bones (i) of the corresponding digit. A flat **abaxial extensor branch (g)** passes across the surface of the sesamoid bone, to which it is attached, and joins the tendon of the proper digital extensor. The **axial extensor branches (f)** remain fused together until they pass through the intercapital notch in the end of the metacarpal (metatarsal) bone. Then they separate and join the tendons of their respective proper digital extensors. The interosseus, sesamoid bones, and sesamoid ligg. of each digit form a suspensory apparatus which aids the digital flexor tendons in the support of the fetlock joint. In addition, the extensor branches oppose the tension of the deep flexor tendon on the distal phalanx when the weight is on the foot.

c) On the carpus the **FASCIA OF THE MANUS** is thickened dorsally to form the **extensor retinaculum (p. 5, s)** and especially on the palmar surface to form the **flexor retinaculum (p. 5, k)**.

On the dorsal surface of the metacarpus (metatarsus) the fascia is thin, but on the palmar surface, in continuation of the flexor retinaculum, it is thick, forming the **proximal ligg. of the dewclaws**. These come from the borders of the metacarpal (metatarsal) bone and have been cut to expose the palmar (plantar) nerves and vessels. At the level of the fetlock joints, the **transverse lig.** connects the dewclaws, and a palpable **distal lig.** runs from each dewclaw to the fascia on the abaxial surface of the coffin joint, resembling in its course the lig. of the ergot in the horse. It also blends with the abaxial end of the distal interdigital lig. (see below). The whole system of ligaments of both dewclaws forms a letter H.

On the fetlock joints the fascia around the digital flexor tendons of each digit is thickened to form the **palmar annular lig. (12)**, which joins the **collateral sesamoid ligg.** and the **proximal scutum** – the fibrocartilaginous bearing surface for the flexor tendons, formed on the sesamoid bones and the **palmar (plantar) lig.** between them, and extending proximal to the sesamoid bones.

Distal to the fetlock joint the fascia is reinforced in the **proximal (13) and distal (15) digital annular ligg.**, attached to the proximal phalanx. The main digits are connected by the proximal and distal interdigital ligg. The **proximal interdigital lig. (14)** is short and thick; it is attached on the axial surfaces of the proximal halves of the proximal phalanges, and is supplemented by the crossed **interdigital phalangos sesamoid ligg.** These extend from the sesamoid bones of one digit to the axial tubercle of the proximal phalanx of the other digit. The **distal interdigital lig. (16)** has greater mechanical advantage in resisting the spread of the digits. It consists of superficial and deep parts. The **superficial part** is palpable. Its crossed fibers extend from the abaxial eminence of the flexor tuberosity of the middle phalanx (see p. 3, 71), around the palmar surface of the deep flexor tendon to the navicular bone of the other digit. It serves to hold the deep flexor tendon in place. The crossed fibers of the **deep part** pass from the axial surface of the distal end of the middle phalanx of one digit to the distal phalanx and navicular bone of the other digit. The attachment to the navicular bone is by means of the **distal scutum** – a plate of fibrocartilage that covers the flexor surface of the bone and extends proximal to it. The terminal branches of the deep and supf. flexor tendons have **common digital synovial sheaths**, which begin between the middle and distal thirds of the metacarpus and end just above the coffin joint.

They form **six pouches for each main digit**: two abaxial pouches and one palmar (plantar) pouch proximal to the palmar (plantar) annular lig., two between the two digital annular ligg., and one distal to the superficial part of the distal interdigital lig.

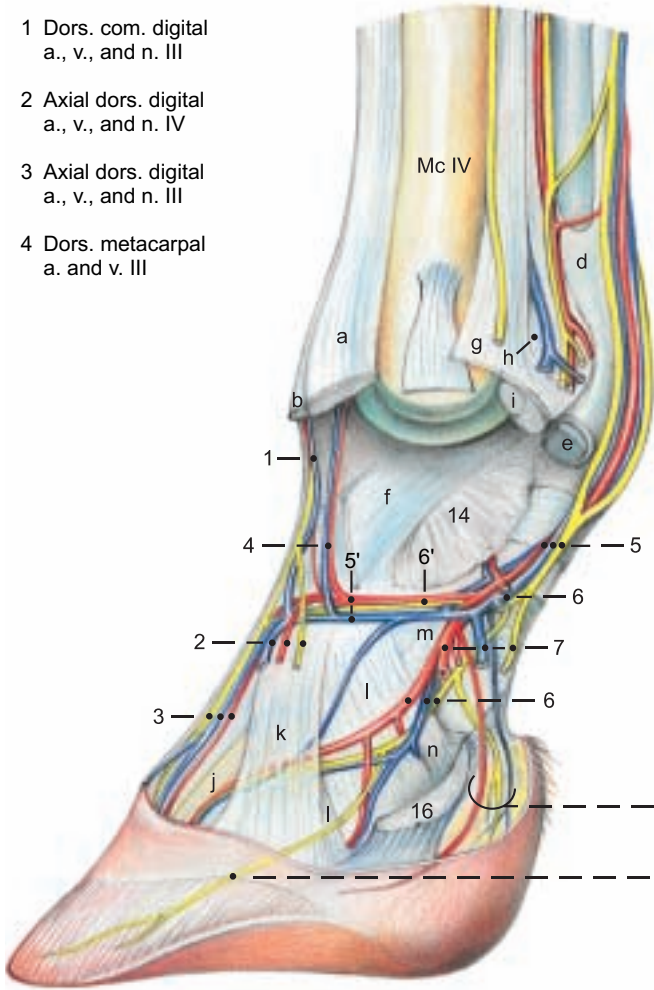
Of the three pouches proximal to the palmar (plantar) annular lig., (I) is between the interossei and the accessory lig.; (II) lies along the accessory lig., partially surrounding the deep flexor tendon; and III is on the palmar (plantar) surface of the supf. flexor tendon. Abaxial (IV) and axial (V) pouches bulge between the two digital annular ligg. The sixth pouch (VI) is distal to the supf. part of the distal digital annular lig. The sheaths of both digits may communicate with each other where they are in contact.

Digital Arteries, Veins, and Nerves

Digit III, left manus, axial surface

Legend:

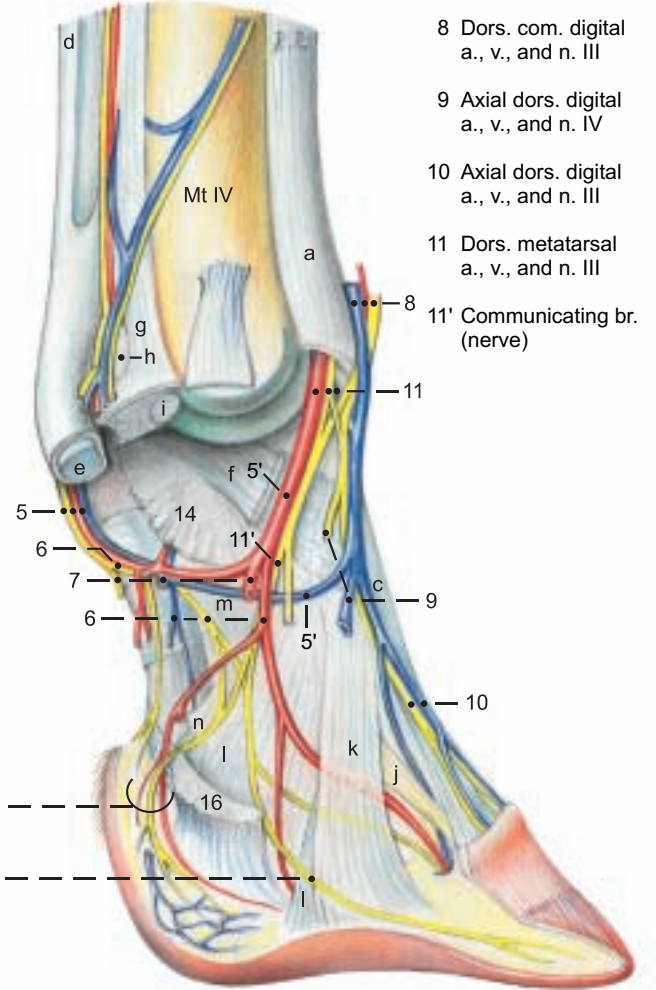
- 1 Dors. com. digital a., v., and n. III
- 2 Axial dors. digital a., v., and n. IV
- 3 Axial dors. digital a., v., and n. III
- 4 Dors. metacarpal a. and v. III



(axial)

- 5 Palm. (plant.) com. dig. a., v., and n. III
- 5' Interdigital a. and v.
- 6 Axial palm. (plant.) digital a., v., and n. III
- 6' Communicating br. (nerve)
- 7 Axial palm. (plant.) digital a., v., and n. IV

Digit III, right pes, axial surface*



(See pp. 17, 21, 23)

- 8 Dors. com. digital a., v., and n. III
- 9 Axial dors. digital a., v., and n. IV
- 10 Axial dors. digital a., v., and n. III
- 11 Dors. metatarsal a., v., and n. III
- 11' Communicating br. (nerve)

Legend:

(See pp. 5, 7, 9)

Tendons:

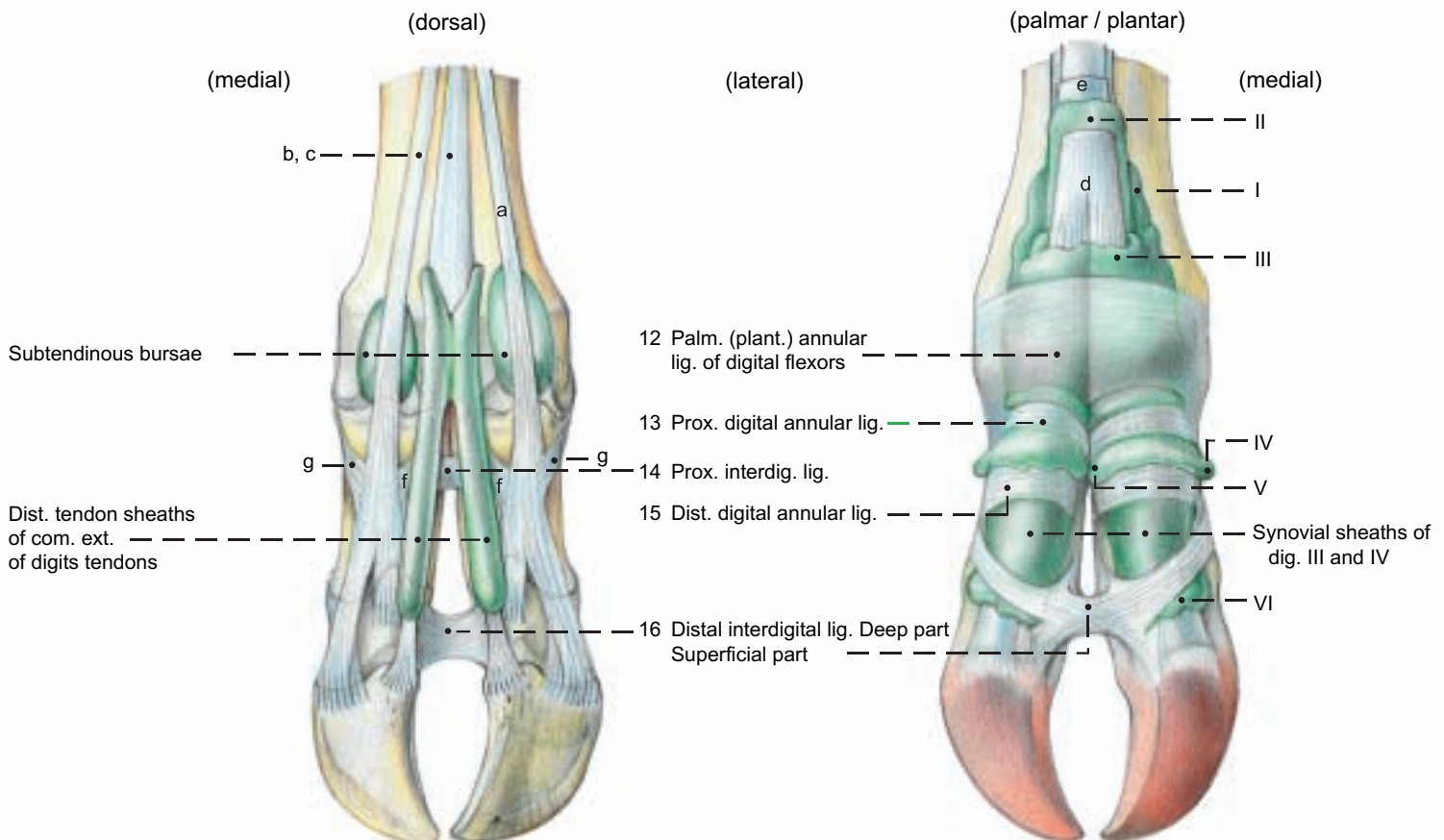
- a Lateral digital extensor
- b, c Common digital extensor or Long digital extensor (Med. dig. ext., and common (long) ext. of digits III and IV)

- d Supf. digital flexor
- e Deep digital flexors
- Interossei III and IV:
- f Axial extensor branches

- g Abax. extensor branches
- h Tendon to sesamoid bone
- i Prox. sesamoid bone of dig. IV
- j Dorsal lig.

- k Axial common collat. lig.
- l Axial collat. ligg.
- m Axial palm. (plant.) lig. of pastern joint
- n Axial collat. sesamoid lig.

Digital fascia, Fibrous and synovial digital sheaths of manus and pes



* Nerves and vessels of the upper right figure are described on p. 22.

6. SYNOVIAL STRUCTURES OF THE THORACIC LIMB

a) JOINTS OF THE THORACIC LIMB

NAME	BONES involved	TYPE OF JOINT	FUNCTION	REMARKS
I. Shoulder joint	Glenoid cavity of scapula and head of humerus	Simple spheroidal	Restricted to flexion and extension	Infraspinatus and subscapularis act as contractile ligaments
II. Elbow joint		Composite joint		
a) Humeroulnar joint	Humeral condyle and ulna	Simple hinge joint	a-b) Flexion and extension, snap joint	Because the collateral ligg. are attached to the humerus prox. to axis of rotation of the condyle they are stretched in the neutral position of joint and tend to snap it into extension or flexion. Pronator teres is feebly muscular.
b) Humeroradial joint	Humeral condyle and head of radius	Simple hinge		
c) Proximal radioulnar joint	Articular circumference of radius and radial notch of ulna	Simple rotating	c) No movement	
III. Distal radioulnar joint:	Absent			Synostosis
JOINTS OF THE MANUS				
IV. Carpal joint		Composite joint		
a) Antebrachio-carpal joint	Radial trochlea and ulnar styloid process with carpal bones	Composite cochlear	Flexion and extension to 95°	Collateral ligg. have long supf. parts and prox., middle, and distal short deep parts. Med. collat. lig. is stronger. Synovial sac of a) rarely communicates with b); b) and c) always communicate*
b) Midcarpal joint	Prox. and dist. rows of carpal bones	Composite condylar	Flexion and extension to 45°	
c) Carpometacarpal joint	Carpal II-IV and metacarpal bones III and IV	Composite plane joint	Little movement	
d) Intercarpal joints	Carpal bones of same row	Composite plane joints	Little movement	
V. Fetlock (metacarpophalangeal) joints	Metacarpal III and IV, prox. phalanges, and prox. sesamoid bones	Composite hinge joint	Flexion and extension	The ox has two fetlock joints, whose capsules communicate. In their dorsal walls are fibrocartilaginous sesamoid bodies.
VI. Pastern (prox. interphalangeal) joints	Prox. and middle phalanges	Simple saddle joint	Flexion, extension, and small lateral and rotational movements	There is no communication between pastern joints. Their dorsal pouches extend to the coffin joint pouches.
VII. Coffin (dist. interphalangeal) joints	Middle and dist. phalanges and navicular (dist. sesamoid) bones	Composite saddle joint	Flexion, extension, and small lateral and rotational movements	

b) SYNOVIAL BURSAE

The large (up to 8 cm in diameter, Schmidtchen**) **infraspinatus bursa** lies deep to the flat superficial part of the tendon, which terminates on the distinct infraspinatus surface (p. 3, 26') distal to the major tubercle. (The deep part of the tendon ends on the proximal border of the tubercle). The voluminous **intertubercular bursa** on the medial surface of the major tubercle lies deep to the tendon of origin of the biceps and on both sides of it. At the level of the **transverse humeral retinaculum** the bursa surrounds the tendon. As in the horse, the bursa is separate from the joint capsule. The **bursa of the triceps brachii** lies under the terminal tendon on the olecranon tuber. The inconstant **subcutaneous olecranon bursa** lies on the caudal surface of the olecranon in old cattle.

The **subcutaneous precarpal bursa** develops in adults and enlarges with age. It may reach the size of an apple. It extends on the dorsal surface from the midcarpal joint to a point just below the metacarpal tuberosity, covering the termination of the extensor carpi radialis. It usually does not communicate with underlying synovial structures and can be surgically removed when enlarged (hygroma). The **subtendinous bursae of the ext. carpi obliquus, ext. carpi radialis, ulnaris lateralis, and the supf. and deep digital flex-**

ors lie under the respective tendons on the medial, dorsal, lateral, and palmar surfaces of the carpal joint.

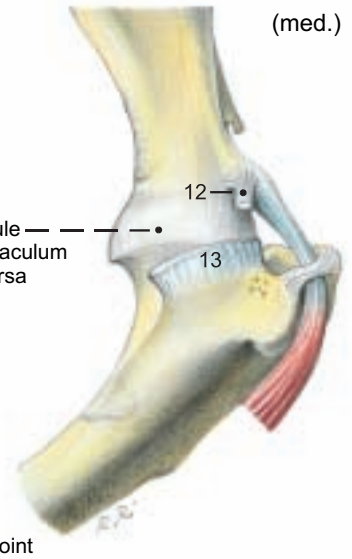
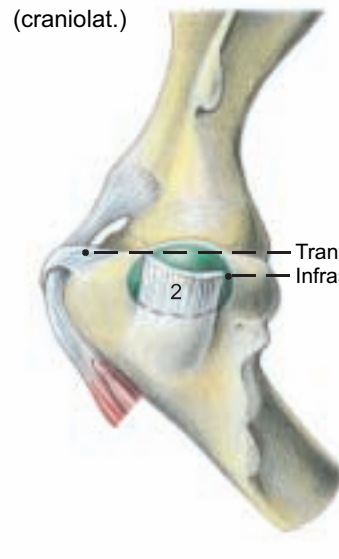
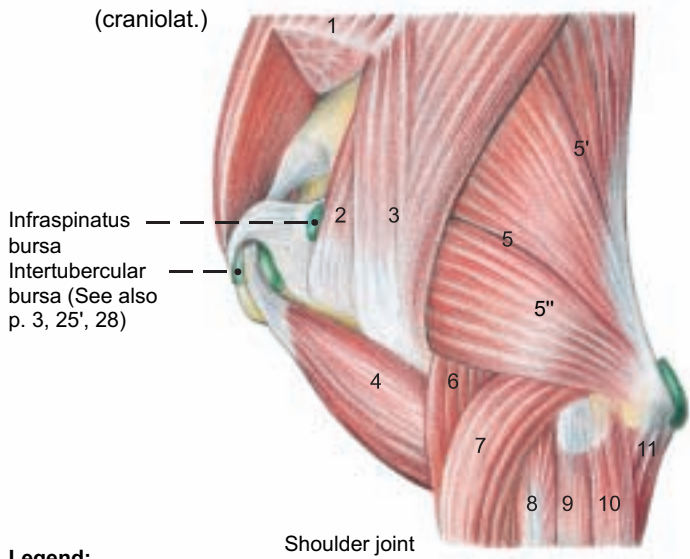
The **subtendinous bursae of the medial and lateral proper digital extensors** lie dorsally on the fetlock joints. The **navicular bursae** are between the terminal branches of the deep flexor tendon and the navicular bones. Inflammations of the bursae have the same clinical signs as in the horse.

c) TENDON SHEATHS (VAGINAE SYNOVIALES)

On the **dorsal and lateral surfaces of the carpus** the extensor carpi obliquus and the digital extensors have synovial sheaths; the tendons of the ext. carpi radialis and ulnaris lat. do not. On the **medial surface**, only the flexor carpi radialis has a synovial sheath.

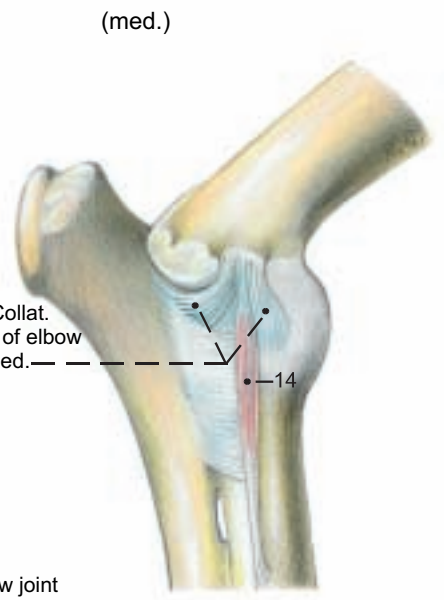
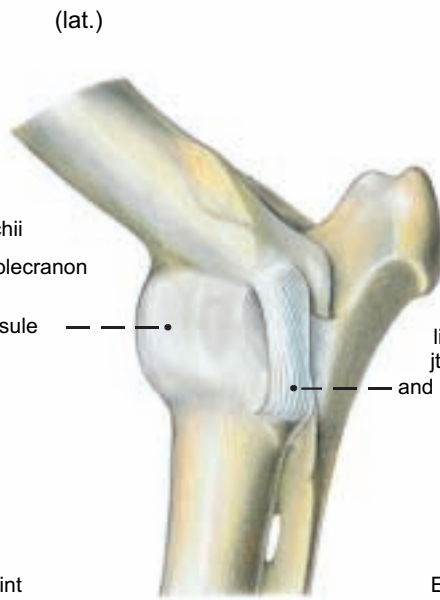
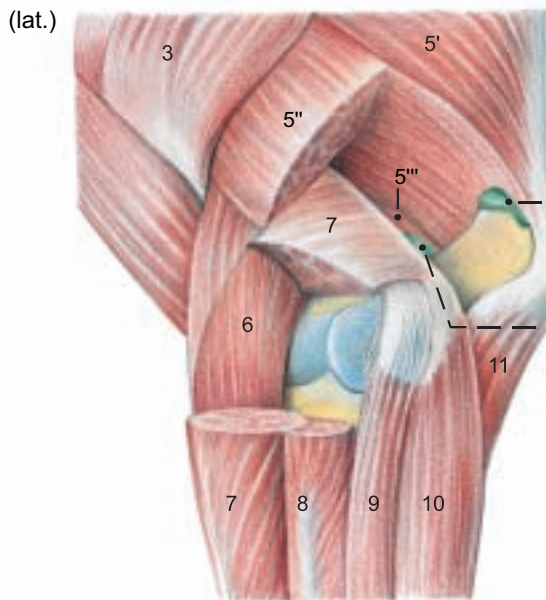
On the **dorsal surface of the phalanges** the terminal branches of the tendon of the common extensor of digits III and IV have synovial sheaths. On the **palmar surface** is the **common synovial sheath** of the supf. and deep digital flexor tendons. They are held in position at the fetlock joint and on the proximal phalanx by annular ligg., and in the region of the pastern joint by the supf. part of the distal interdigital lig.

Joint, Bursa, and Synovial Sheaths



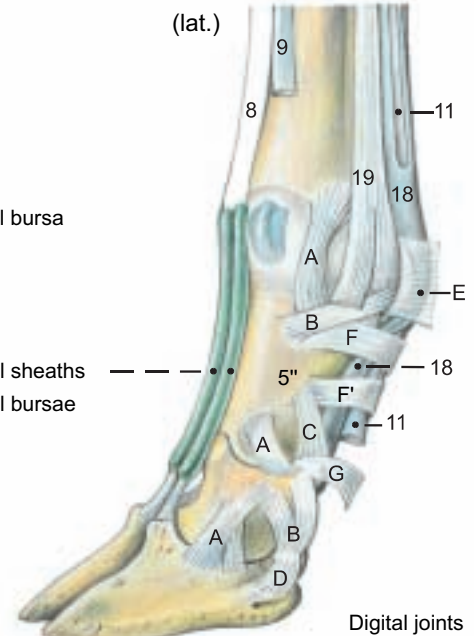
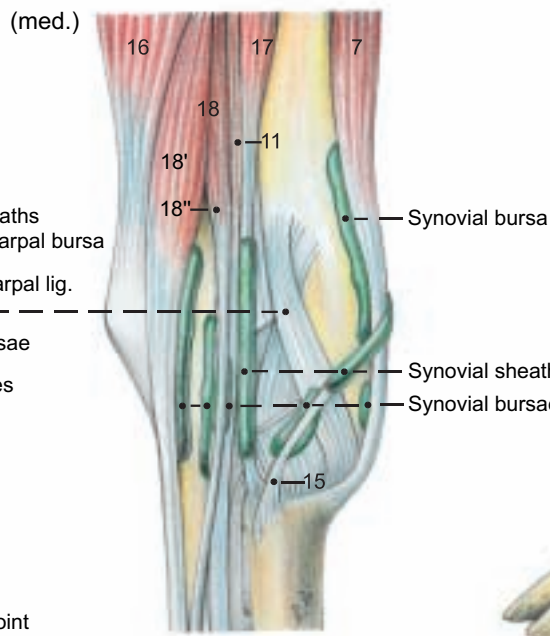
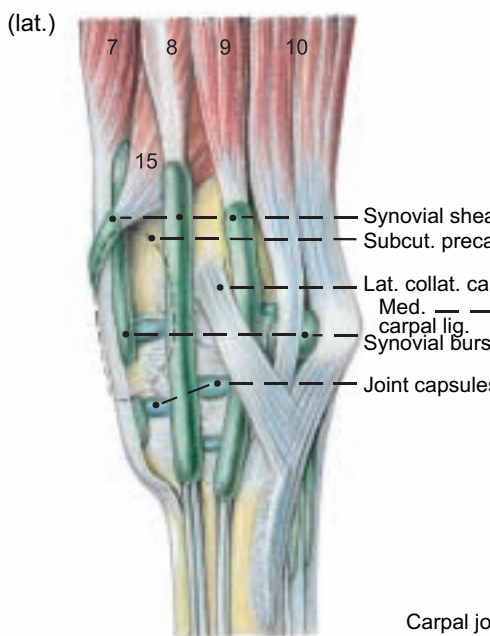
Legend:

- | | | | |
|------------------|-------------------|-------------------------|---------------------|
| 1 Supraspinatus | 5 Triceps brachii | 6 Brachialis | 10 Ulnaris lat. |
| 2 Infraspinatus | 5' Long head | 7 Ext. carpi radialis | 11 Deep dig. flexor |
| 3 Deltoideus | 5'' Lat. head | 8 Com. digital extensor | 12 Coracobrachialis |
| 4 Biceps brachii | 5''' Med. head | 9 Lat. digital extensor | 13 Subscapularis |



Legend:

- | | | | |
|------------------------|--------------------------|----------------------|-------------------|
| 14 Pronator teres | 16 Flexor carpi ulnaris | 18 Supf. dig. flexor | 18'' Deep part |
| 15 Ext. carpi obliquus | 17 Flexor carpi radialis | 18' Supf. part | 19 Interosseus IV |



Legend:

- | | | | |
|-----------------------------------|-------------------------------------|---------------------------|--|
| A Abax. collat. ligg. | C Abax. palm. lig. of pastern joint | E Palmar annular lig. | F' Dist. digital ann. lig. |
| B Abax. collateral sesamoid ligg. | D Abax. distal sesamoid ligg. | F Prox. digital ann. lig. | G Dist. interdigital lig. (Supf. part) |

CHAPTER 2: PELVIC LIMB

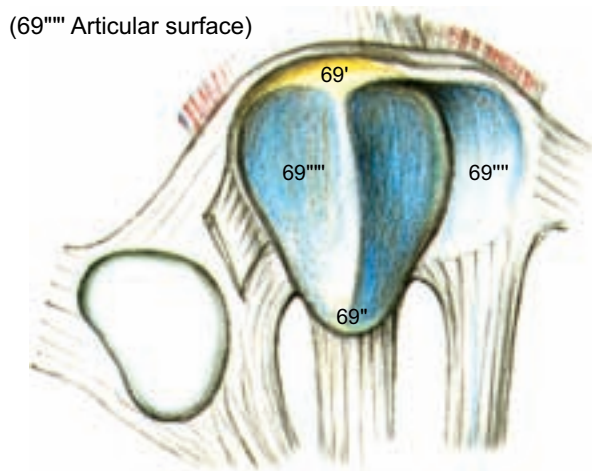
1. SKELETON OF THE PELVIC LIMB

The skeleton of the pelvic limb includes the bones of the pelvic girdle, described with the pelvis (pp. 78–79).

a) The **FEMUR** has a proximal **head** (1), *the articular surface of which presents a condyloid lateral extension on the upper surface of the neck* (3). The **fovea** (2) is *small and almost centrally located*. The **major trochanter** (4) is, in contrast to that of the horse, undivided, and borders a **deep trochanteric fossa** (5). The **rounded caudomedially directed minor trochanter** (6) is connected to the major trochanter by a **distinct intertrochanteric crest** (4'). The small rounded **tuberosity for the deep gluteal m.** is distal to the major trochanter. *The third trochanter is absent in the ox.* The **body of the femur** (8) is *rounded and relatively slender and straight*, compared to that of the horse. Distolaterally, as in the horse, there is a **supracondylar fossa** (13), but *it is shallow in the ox.* On the distal end of the femur are the **nearly parallel medial** (14) and **lateral** (17) condyles, separated by a **deep intercondylar fossa** (20). Cranial to the lateral condyle is the **extensor fossa**. On the cranial surface of the distal end of the femur is the **trochlea** (21), the medial ridge of which is larger and extends farther proximally, where it is thickened to form a **tubercle** (21').

The **patella** (69) is a sesamoid bone in the terminal tendon of the quadriceps femoris. The broad proximal **base** (69') has *blunt, rough borders*, and a **cartilaginous process** (69'') for attachment of the **med. parapatellar fibrocartilage** (69'''), as in the horse. The distal **apex** (69'') is *more acutely pointed than in the horse.*

Left patella



(See p. 29)

b) The **BONES OF THE CRUS (LEG, SHANK)** are the strong tibia and the vestigial fibula, reduced to its proximal and distal extremities.

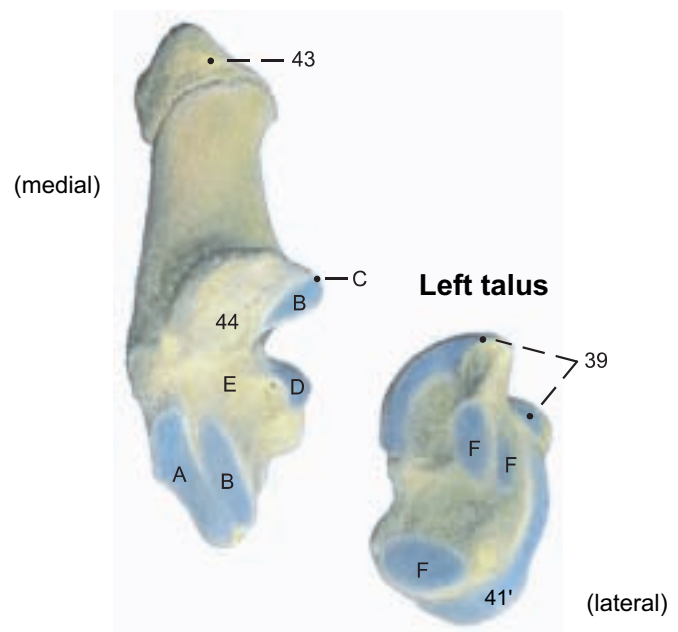
I. The **tibia** with its **medial condyle** (23) and its laterally extended **lateral condyle** (25) presents *proximal articular surfaces almost on the same level*, between which the **intercondylar eminence** (24) rises. On the **body of the tibia** (28) is the **broad proximocranial tibial tuberosity** (29) with the laterally adjacent **extensor groove** (27). On the distal **tibial cochlea** (30) the articular ridge and grooves are *almost sagittal* like those of the dog, but unlike those of the horse. The **lateral surface of the cochlea** has *two articular facets for the distal end-piece of the fibula, the lateral malleolus*. The **medial malleolus** (31) has a characteristic distally directed process.

II. The **fibula** is *more or less reduced, depending on the individual*. The **head of the fibula** (32) *fuses with the lateral condyle of the tibia as a distally directed process*. Rarely is it an isolated bone as in the horse. A **body of the fibula** can be present as an exception, but *it is usually replaced by a fibrous strand; therefore there is usually no interosseous space in the crus.*

The distal end of the fibula persists as an independent bone, the lateral malleolus (35), and *articulates proximally with the tibia, medially with the talus, and distally with the calcaneus.*

c) The **TARSAL BONES** make up, in proximal, middle, and distal rows, a total of only five bones. The **talus** (37) in the proximal row is *longer and more slender* than in the horse. The ridges of the **proximal trochlea** (39) are sagittal, unlike those of the horse, and articulate with the tibial cochlea medially and with the lateral malleolus. The *proximal trochlea is joined by the roughened neck* (40) to the **distal trochlea** (41'), which articulates with the central and fourth tarsal bone. A distal trochlea of the talus is characteristic of the order *Artiodactyla*, the even-toed ungulates. The **calcaneus** (42) is also *longer and more slender* than in the horse. Its proximal **tuber**

Left calcaneus



Legend:

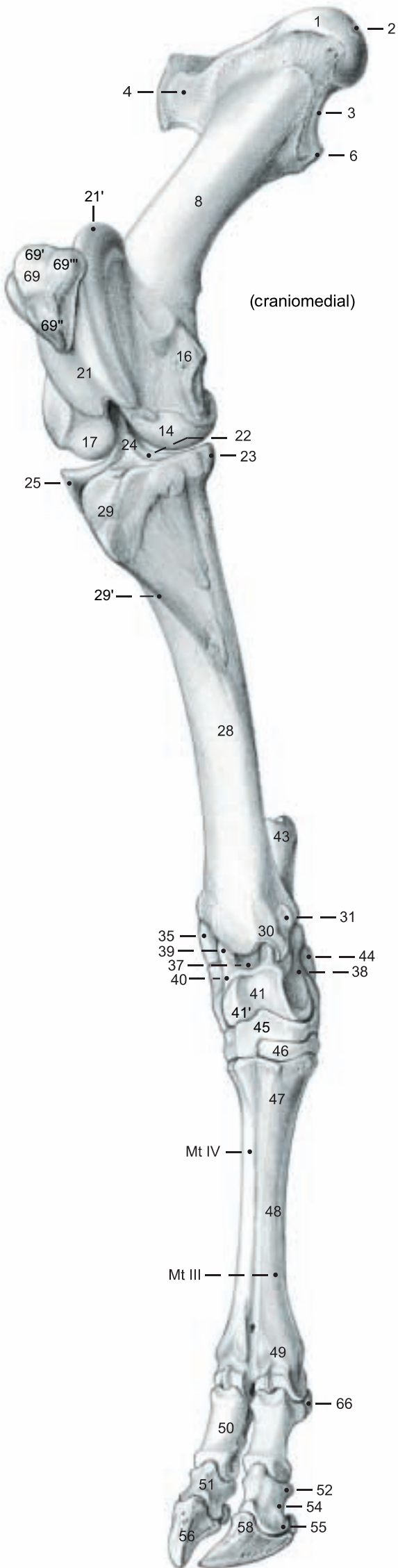
A Artic. surface for T C and T IV
B Artic. surfaces for talus
C Coracoid process

D Artic. surface for malleolus
E Tarsal sinus
F Artic. surfaces for calcaneus

calcanei (43) is *roughened dorsocranially, divided by a transverse crest, and hollowed out in a plantar groove*. The **compact sustentaculum tali** (44) is hollowed to form a tendon groove on the plantar surface. *Distally the calcaneus articulates with the central and fourth tarsal bone*. The single bone of the middle row, *the central tarsal, is fused with the fourth tarsal of the distal row to form one bone, the central and fourth tarsal* (45'), characteristic of *Ruminantia*. It occupies the full width of the tarsus, and *jogs upward proximomedially*. The remaining **tarsal bones** of the distal row occupy the distomedial part of the tarsus. The rounded **T I** is medioplantar. **T II and T III** are *always fused to form one flat bone, also characteristic of Ruminantia*. The **tarsal canal** passes between the two large distal tarsal bones and the mt. bone. It connects with the **proximal mt. canal**, which, unlike the proximal mc. canal, opens on the proximal surface of the base of the mt. bone. The tarsus, metatarsus, and digits are homologous to the human foot (pes) and correspond to the manus of the thoracic limb.

d) The **METATARSAL BONES, PHALANGES, and SESAMOID BONES** of the pes exhibit only minor differences from the bones of the manus. Metatarsal bone III and IV is longer and more slender, and square in cross section; metatarsal bone III and IV is transversely oval. A **small, discoid metatarsal sesamoid** (70) is located *proximoplantar to Mt. III in the fused tendons of origin of the interossei.*

Bones of the p



Femur

- Head of the femur (1)
- Fovea capitis (2)
- Neck of the femur (3)
- Major trochanter (4)
- Intertrochanteric crest (4')
- Trochanteric fossa (5)
- Minor trochanter (6)
- Body of femur (8)
- Rough surface (9)
- Popliteal surface (12)
- Fossa supracondylaris (13)
- Medial condyle (14)
- Medial epicondyle (16)
- Lateral condyle (17)
- Lateral epicondyle (19)
- Intercondylar fossa (20)
- Femoral trochlea (21)
- Tubercle of femoral trochlea (21')

Tibia

- Prox. articular surface (22)
- Medial condyle (23)
- Intercondylar eminence (24)
- Lateral condyle (25)
- Extensor groove (27)
- Body of tibia (28)
- Popliteal line (28')
- Tibial tuberosity (29)
- Cranial border (29')
- Tibial cochlea (30)
- Medial malleolus (31)

Fibula

- Head of the fibula (32)
- Lateral malleolus (35)

Tarsal bones

- Talus (37)
- Body of talus (38)
- Prox. trochlea (39)
- Neck (40)
- Head (41)
- Distal trochlea (41')
- Calcaneus (42)
- Tuber calcanei (43)
- Sustentaculum tali (44)
- Central + 4th tarsal bone (45)
- T II + T III, dorsal view, and T I, in plantar view (46)

Metatarsal bones III and IV

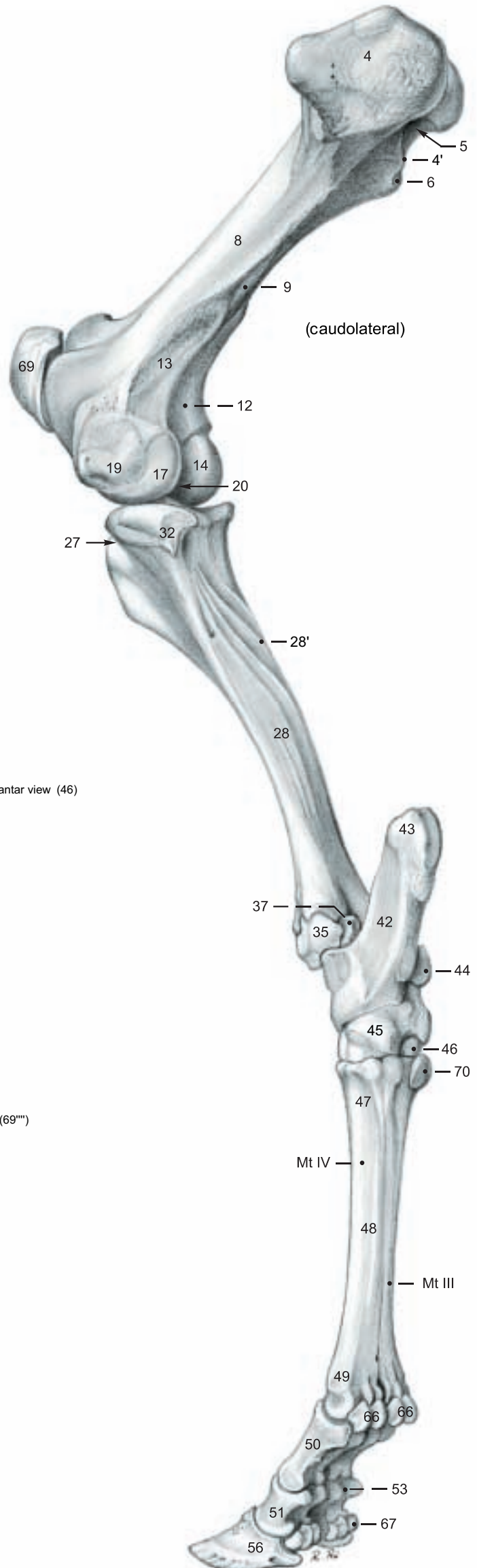- Base (47)
- Body (48)
- Head (49)

Digital bones (see text fig. p. 2)

- Proximal phalanx (50)
- Middle phalanx (51)
- Base (52)
- Flexor tuberosity (53)
- Body (54)
- Head (55)
- Distal phalanx (coffin bone - 56)
- Extensor process (58)

Sesamoid bones

- Proximal sesamoid bones (66)
- Distal sesamoid bone (67)
- Patella (69)
- Base (69')
- Apex (69'')
- Cartilaginous process (69''')
- Medial parapatellar fibro-cartilage (69''')
- Articular surface (69''')
- Metatarsal sesamoid bone (70)



2. LATERAL THIGH AND CRANIAL CRURAL MUSCLES WITH THEIR NERVES

The skin of the pelvic limb is removed down to the middle of the metatarsus, with attention to the inconstant subcutaneous calcanean bursa, sparing all of the superficial blood vessels and nerves, and noting the cutaneous nerves. Dorsolaterally on the pelvic limb the muscles of the rump and caudal thigh are demonstrated, and the tensor fasciae latae, gluteus medius, and biceps femoris [gluteobiceps] are severed at their origin and termination and removed. The underlying nerves and vessels, iliacus muscle, the distinct gluteus accessorius with its strong terminal tendon, the gluteus profundus, and the sacrosciatic lig. are preserved.

a) **LATERALLY ON THE THIGH** and on the rump the **cranial gluteal n. (2)** supplies the *especially large and fleshy tensor fasciae latae (5)* (which includes the cranial part of the gluteus supf.), *the thin gluteus medius (1), which causes the characteristic bovine flattening of the rump*, the **gluteus accessorius (3)**, (see above, considered a part of the gluteus medius), and the fleshy **gluteus profundus (4)**. Each terminal tendon of the deep, middle, and accessory gluteal muscles has a synovial bursa on the major trochanter.

The **caudal gluteal n. (16)** supplies the *vertebral head* of the **biceps femoris [gluteobiceps, 7]**, which includes the caudal part of the gluteus supf. The *ischial head* is innervated by the tibial n. The *vertebral heads of the semitendinosus and semimembranosus, seen in the horse, are absent in the ox.*

The wide **sciatic n. (17)** passes over the gluteus profundus, and, at the hip joint, gives off **muscular br. to the gemelli and quadratus femoris**. (The internal obturator is absent in the ox.) Here the sciatic n. divides into the common peroneal [fibular] n. cranially and the tibial n. caudally.

The **tibial n. (19)** gives off proximal muscular br. to the ischial head of the biceps femoris and to the semitendinosus and semimembranosus, which originate from the tuber ischiadicum only, as in the dog.

In the course of the nerve toward the gastrocnemius the **caudal cutaneous sural nerve (19')** is given off in the middle of the thigh and runs with the lateral saphenous v. to the middle of the latero-plantar surface of the metatarsus.

The **biceps femoris [gluteobiceps, 7]** has a large trochanteric bursa on the trochanter major, over which the muscle passes. The bursa is clinically important as a cause of lameness when inflamed. Distal to the trochanter the biceps is divided into two parts as in the dog, but unlike the three parts in the horse. It ends with the fascia cruris on the patella, lateral patellar lig., and the cranial border of the tibia, and has another synovial bursa under its tendon at the level of the femoral condyle (see p. 29). Its tarsal tendon (34) ends on the tuber calcanei.

The **semitendinosus (20)** passes over the medial head of the gastrocnemius and ends, with a synovial bursa, on the cranial border of the tibia and by its tarsal tendon (see p. 19) on the tuber calcanei. *Characteristic of the muscle is a transverse tendinous intersection at the beginning of its middle third.*

The **semimembranosus (18)** is indistinctly divided near the end into a larger part ending on the medial femoral condyle, and a smaller part ending on the medial condyle of the tibia.

b) **ON THE CRUS** the **common peroneal [fibular] n. (6)** sometimes gives off in the middle of the crus a **lateral cutaneous sural n. (21)** toward the hock. The common peroneal n. runs over the lateral head of the gastrocnemius, passes under the peroneus [fibularis] longus, and runs between the latter and the lateral digital extensor to divide in the middle of the tibia into **superficial (14)** and **deep (9) peroneal [fibular] nn.** They innervate the flexors of the tarsus and extensors of the digits.

The *fleshy peroneus [fibularis] tertius (10)*, absent in the dog and entirely tendinous in the horse, originates in the extensor fossa of the femur with the long digital extensor, which it largely covers proximomedially. Its terminal tendon is perforated by that of the cranial tibial and ends on Mt III and Mt IV and under the medial collateral lig. on T II and T III.

The **cranial tibial muscle (8)** is *smaller than in the horse* and is covered by the peroneus tertius and long digital extensor. *It is fused with the vestigial long extensor of digit I.* It is sometimes possible to separate the two tendons, which end on T I and medially on Mt III and Mt IV.

The **peroneus [fibularis] longus (11)**, which also occurs in the dog, but not in the horse, is narrow, forms its tendon in the middle of the crus, crosses the tendon of the lateral extensor, passes under the lateral collateral lig., runs across the plantar surface of the tarsus and ends on T I.

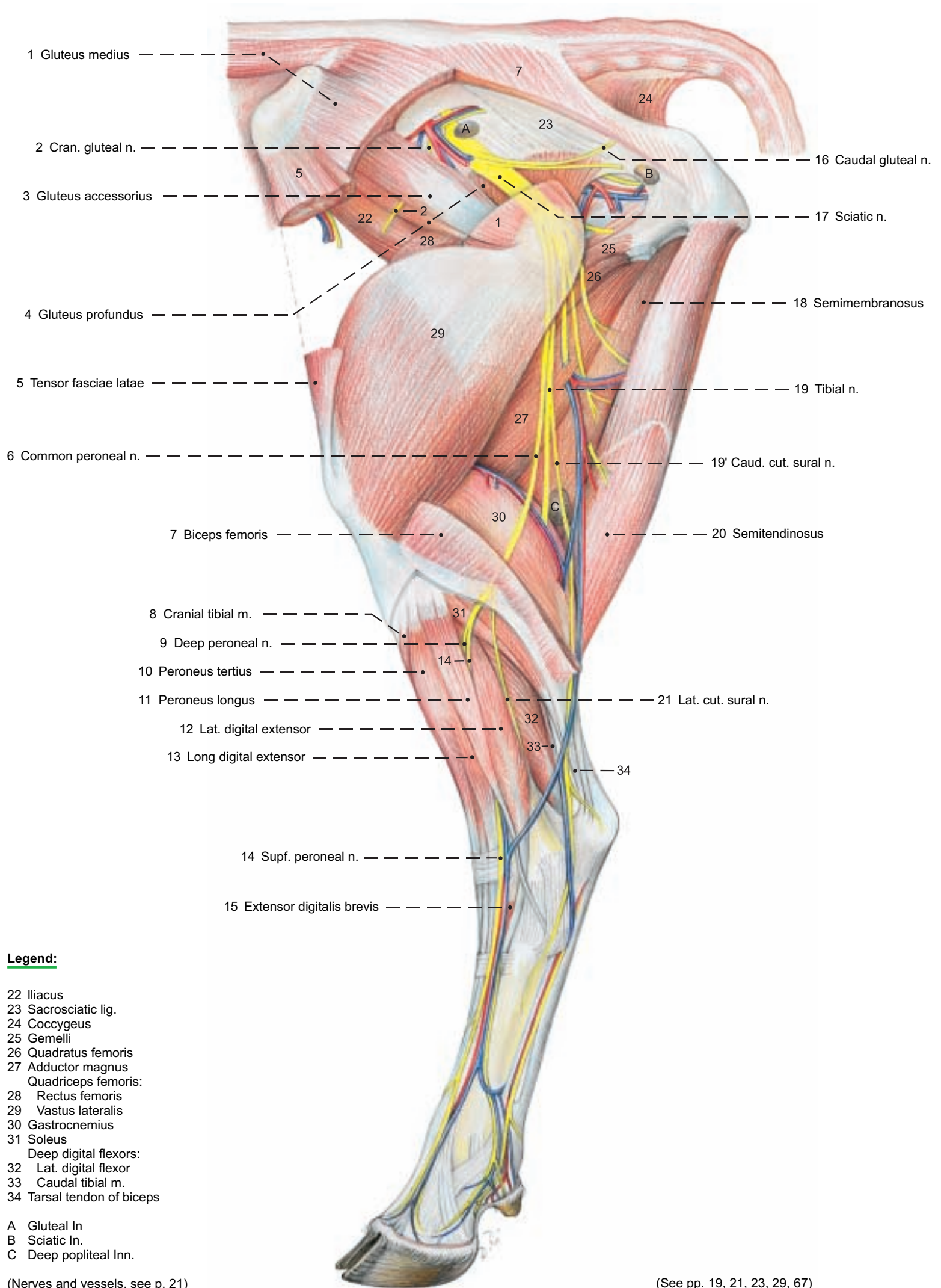
The **long digital extensor (13)** (See also the cranial tibial m.) *has a superficial lateral belly (extensor of digits III and IV) and a deep medial belly (medial digital extensor, extensor of digit III).*

Both tendons pass under the crural retinaculum with the tendons of the cranial tibial and peroneus tertius; whereas only the long digital extensor tendons pass under the metatarsal retinaculum. They are arranged in the pes like the corresponding tendons of the common digital extensor in the manus. *The tarsal extensor retinaculum of the horse is absent in the ox.*

The **lateral digital extensor (extensor of digit IV, 12)** originates from the lateral collateral lig. of the stifle and the lateral condyle of the tibia. It is a *relatively large muscle* that passes under the tendon of the peroneus longus and laterally over the tarsus to digit IV. Its tendon is arranged here like that of the muscle of the same name in the manus. The **extensor digitalis brevis (15)** is *small*; a peroneus brevis is absent as in the horse.

Pelvic Limb

(lateral)



3. MEDIAL THIGH AND CAUDAL CRURAL MUSCLES WITH THEIR NERVES

Medially on the thigh the gracilis is detached from the symphyseal tendon and removed, except for a short distal stump. At the tarsus the two retinacula, the tendon sheaths, and the bursae are examined. After demonstration of the tarsal tendons of the biceps and semitendinosus, the medial head of the gastrocnemius is severed near its origin to expose the superficial digital flexor.

a) **MEDIALY ON THE THIGH** the muscles are innervated by the obturator n. only, or by the femoral and saphenous nn., or by the saphenous and obturator nn.

The **obturator n. (6)** runs with the obturator v. medially on the body of the ilium, passes through the obturator foramen, and innervates the following muscles:

The **external obturator in the ox has an additional intrapelvic part (7) that originates inside around the obturator foramen, but is not homologous to the internal obturator of other domestic animals.**

The **adductor magnus (et brevis, 9)** originates from the ventral surface of the pelvis and from the symphyseal tendon as in the horse, but is more closely bound to the semimembranosus by connective tissue. It terminates on the caudal surface of the femur, but does not extend to the epicondyle.

The **pectineus (et adductor longus, 8)** is more robust than in the horse. Its adductor part is innervated by the obturator n.; its pectineus part by the saphenous n. The tendons of origin come from the iliopubic eminence and pecten pubis, cross the median plane, and form with the tendons of the contralateral pectineus, the bulk of the prepubic tendon. Each pectineus terminates on the caudomedial surface of the body of the opposite femur. The **gracilis (10)** is innervated by the obturator n. supplemented by the saphenous n. It takes origin from the pelvic symphysis and the prepubic tendon. Its tendon forms, with that of the other side, the distinctive symphyseal tendon, which is *bean-shaped in the cow and equilaterally triangular in the bull*, indicating the sex of a split carcass.

At the level of the pecten pubis the **femoral n.** gives off the **saphenous n. (4)** (skin innervation, see p. 20), which not only supplies the last two muscles, but also is the sole innervation of the **sartorius (3)**. *This muscle originates by two heads: the cranial one from the tendon of the psoas minor and the iliac fascia, and the caudal one from the body of the ilium dorsocaudal to the tubercle for the psoas minor. The cran. head of the sartorius, the iliopsoas, and the femoral n. pass through the muscular lacuna. The caud. head passes through the vascular lacuna (p. 78).** The femoral n. enters the **quadriceps femoris**, whose *four clearly separate* heads it innervates. The **rectus femoris (1)** and the **vastus lateralis,—medialis (2), and —intermedius** conform in origin and termination to the relationships in the horse. (See p. 17.) The *femoral a. and v. and saphenous n. pass between the two origins of the sartorius* on their way to the **femoral triangle**. The **sartorius forms the medial wall of the triangle**, the proximal border of which is formed by the pelvic tendon of the external oblique, the caudal border by the gracilis and pectineus, and the cranial border by the rectus femoris.

b) **ON THE CRUS** the **tibial nerve (12)** gives off its distal muscular br. to the extensors of the tarsus and flexors of the digits, passes between the heads of the gastrocnemius, and reaches the medial side of the crus, at the distal end of which it divides into the **lateral (13)** and **medial (14) plantar nn.**

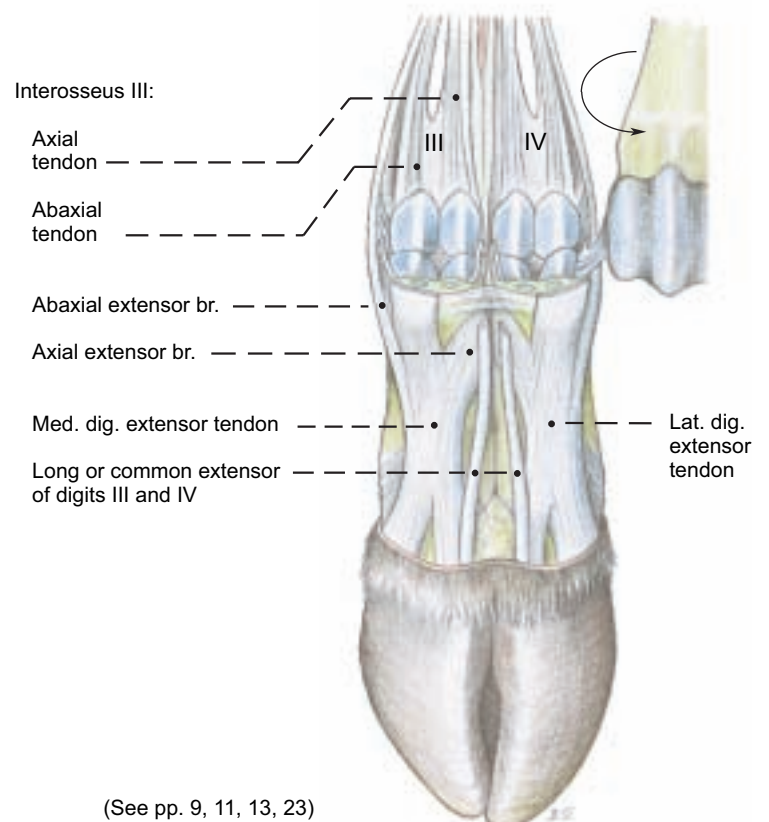
The **politeus** (special flexor of the stifle) lies caudal to the stifle joint (see p. 29.4). The **gastrocnemius (11)** originates by two heads from the sides of the supracondylar fossa of the femur and terminates on the calcanean tuber. *It is very tendinous, and an intermediate fleshy tract connects the origin of the lateral head to the terminal tendon of the medial head, which is therefore bipartite. The tendon of the lateral head takes a deeper course and passes through a sheath formed by the tarsal tendons of the biceps and semitendinosus.*** The **gastrocnemius tendons (24)** are separate until shortly before their attachment to the tuber calcanei. The robust **soleus** (see p. 17) fuses with the lateral head of the gastrocnemius and forms with the two heads the triceps surae. The **superficial digital flexor** lies between the heads of the gastrocnemius and is fused with the lateral head at its origin from the supracondylar fossa. Its thick terminal tendon (22) passes from the deep surface of the gastrocnemius tendon around the medial side to expand superficially over the tuber calcanei, to which it is attached. The spiral groove between the tendons is palpable in the live animal. The tendons of the gastrocnemius and supf. flexor, and tarsal tendons of the biceps and semitendinosus make up

the **common calcanean tendon**—the hamstring of quadrupeds. On the pes the superficial flexor tendon is arranged as in the thoracic limb. The **deep digital flexors** include three muscles as in the horse: the **caudal tibial** (see p. 17) is the smallest; its belly is short and flat and its long narrow tendon lies on the caudal surface of the largest muscle—the **lateral digital flexor** (see p. 17). The tendons of these two muscles pass together over the sustentaculum tali; whereas the tendon of the **medial digital flexor**, as in the horse, passes over the medial surface of the tarsus (p. 29) and joins the other two in the proximal metatarsus to form the common deep flexor tendon, which is arranged as in the thoracic limb.

c) The **INTEROSSEI III AND IV** (see text figure) have the same supportive function for the main digits of the ox as the interosseus medius (III) in the horse. When the weight is on the foot and the fetlock joints are overextended, the interossei, through the sesamoid bones and distal sesamoid ligaments, aid the digital flexor tendons in support of the fetlock joints. Through their **extensor branches** attached to the med. and lat. (proper) digital extensor tendons they oppose the action of the deep flexor tendons on the coffin joints and guarantee that the hoofs are planted on the solar surface. They have the same structure as on the thoracic limb (see p. 10, b). These muscles originate from the long plantar tarsal ligament and the proximal part of the metatarsal bone. In young animals they are relatively fleshy and in older animals predominantly tendinous. Interossei III and IV are fused along their axial borders in the metatarsus, but they separate and terminate on the corresponding digits. *In the middle of the metatarsus the interossei give off the accessory lig., which bifurcates and joins the branches of the supf. digital flexor tendon at the level of the fetlock joints in the formation of the sleeves (manicae flexoriae) through which the branches of the deep flexor tendon pass.*

Proximal to the fetlock joints each interosseus divides into two tendons, each with two **extensor branches**. The two tendons are attached to the sesamoid bones. A flat **abaxial extensor branch** passes across the surface of the sesamoid bone, to which it is attached, and joins the tendon of the proper digital extensor. The **axial extensor branches** remain fused together until they pass through the intercapital notch in the metatarsal bone. Then they separate and join the tendons of their respective proper digital extensors.

(Dorsal aspect)



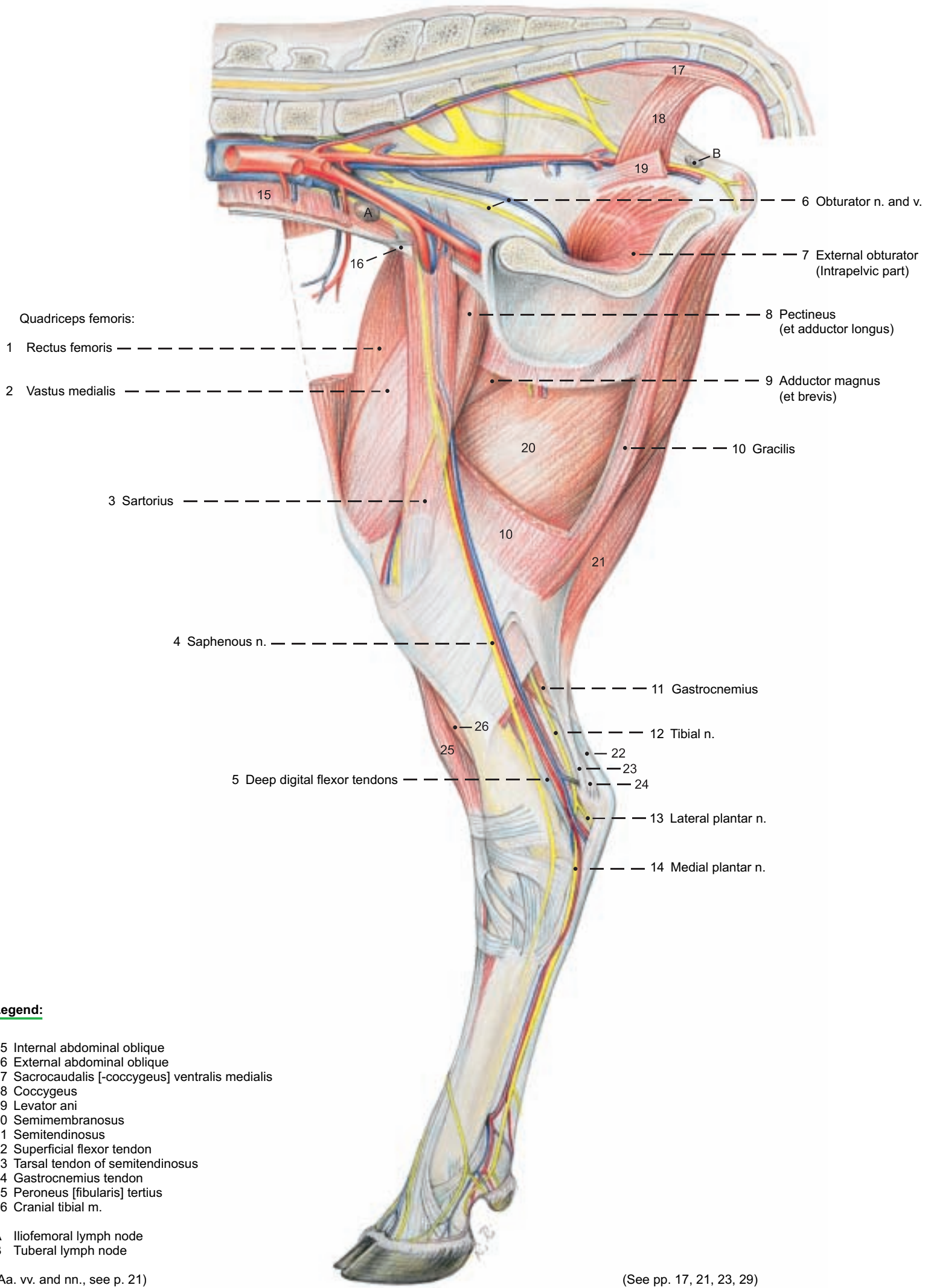
(See pp. 9, 11, 13, 23)

* Traeder, 1968

** Pavaux, Lignereux, and Sautet, 1983

Pelvic Limb

(medial)

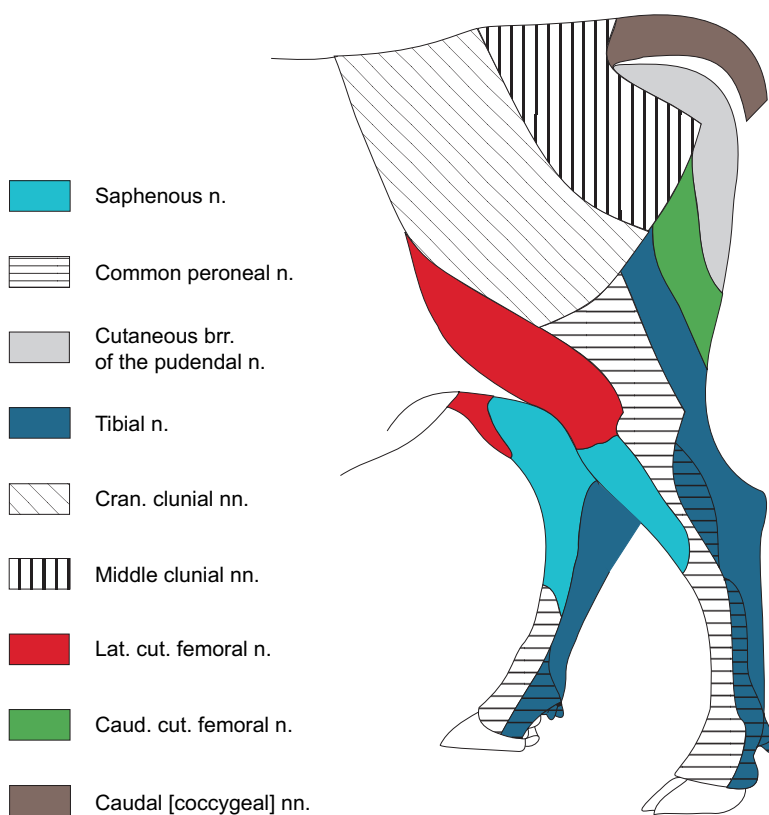


4. CUTANEOUS NERVES, BLOOD VESSELS AND LYMPH NODES OF THE PELVIC LIMB

a) The **CUTANEOUS INNERVATION** of the lateral rump and thigh regions is supplied, in craniocaudal order, by the cranial clunial nn. (dorsolat. cut. brr. of L4 to L6), middle clunial nn. (dorsolat. cut. brr. of S1 to S3), and in the region of the tuber ischiadicum and major trochanter by caudal clunial nn. (cut. brr. of the pudendal n., k) and the caudal cutaneous femoral n. (i), *the cutaneous br. of which may be absent*. In addition, the region of the biceps groove is supplied by cutaneous brr. of the tibial n. (p) and the common peroneal [fibular] n. (o). A large area of skin in the craniolateral thigh region is supplied by the **lateral cutaneous femoral n. (3)**. On the medial surface of the thigh the nerves are the **iliohypogastric (1)**, **ilioinguinal (2)**, and **genitofemoral (4)** (see also p. 91).

The innervation of the crus down to the hock is provided mainly medially, but also craniolaterally, by the **saphenous n. (11)**; mainly caudolaterally by the **caudal cutaneous sural n. (24)** from the tibial n., and laterally also by the **lateral cutaneous sural n. (25)** from the common peroneal [fibular] n. The pes (see p. 23) is innervated dorsally by dorsal common digital nn. II–IV from the **superficial peroneal (o'')**, and in the interdigital region by dorsal metatarsal n. III (from the **deep peroneal (o')**, see p.11) and plantar common digital n. III (see p. 11). Plantar common digital nn. II–IV are branches of the **medial (29) and lateral (28) plantar nn.**

Nerves of the pelvic limb



b) The **BLOOD VESSELS** of the pelvic limb come primarily from the external iliac a. and v., and to a lesser extent from the **internal iliac a. and v. (14)**. The latter give off, caudodorsal to the body of the ilium, the **cranial gluteal a. and v. (15)** for the gluteal muscles and the *gluteobiceps*. The internal iliac a. and v. terminate in the region of the lesser sciatic foramen by dividing into the **caudal gluteal a. and v. (16)** and the internal pudendal a. and v. The **obturator v. (17)** originates from the internal iliac immediately after the cranial gluteal v. An obturator a. is absent as in the dog. The **external iliac a. and v. (13)** leave the abdominal cavity through the vascular lacuna and become the femoral a. and v. While still in the abdomen they give off the **deep femoral a. and v. (18)** with the origin of the arterial **pudendoepigastric trunk (19)**, whereas the **pudendoepigastric v. (19)** may come directly from the ext. iliac v. as in the dog. Distal to the hip joint the deep femoral a. and v. give off

the **medial circumflex femoral a. and v. (20)** to the adductors and caudal thigh muscles. They also give off obturator branches that ascend through the obturator foramen. The medial circumflex femoral v. supplies the **lateral saphenous v. (21)**, which, without an accompanying artery, emerges in the popliteal region between the gluteobiceps and semitendinosus. It runs with the caud. cut. sural n. along the lateral surface of the common calcanean tendon and divides in the distal third of the crus (unlike that of the horse) into a cranial branch and a **caudal branch (27)**. The caudal branch, before it reaches the tarsus, sends an anastomotic br. to the medial saphenous v. Distal to the tarsal joint, the caudal branch is connected with the small lateral plantar v. to form the proximal deep plantar arch. The **cranial branch (26)** runs with the supf. peroneal n. along the dorsolateral surface of the tarsus and, in the distal half of the metatarsus, becomes the dorsal common digital v. III. The insignificant dorsal common digital v. II and the large dorsal common digital v. IV, branch off and terminate in the venous distal deep plantar arch (see p. 23).

The **femoral a. and v. (6)** pass between the two origins of the sartorius into the femoral triangle and give off cranially, between the vastus medialis and rectus femoris, the **lateral circumflex femoral a. and v. (5)** for the quadriceps femoris; then they cross the femur medially toward the popliteal region and give rise to the **saphenous a. (11)** and the **medial saphenous v. (11)**, which emerge around the caudal border of the sartorius and run distally on the gracilis. The artery and vein continue imperceptibly into their respective caudal branches *without giving off cranial branches in the ox*, unlike the dog and horse. The caudal branches descend on the craniomedial surface of the common calcanean tendon, accompanied by the tibial n., to the sustentaculum tali. En route, the venous br. receives the anastomosis from the caud. br. of the lat. saphenous v., and at the level of the tarsal joint the arterial and venous branches divide into the **medial (29) and lateral (28) plantar aa. and vv.**

Distal to the femoral triangle the femoral a. and v. give off the **descending genicular a. and v. (7)** to the stifle, and caudally the origins of the **caudal femoral a. and v. (22)** mark the transition between the femoral vessels and the **popliteal a. and v. (23)**. The latter vessels pass between the heads of the gastrocnemius and give off the small **caudal tibial a. and v. (8)** cranial to the popliteus. Distal to that muscle they are continued as the large **cranial tibial a. and v. (10)**. Before these pass distal to the tibiofibular synostosis to the craniolateral surface of the tibia, *they give off the crural interosseus a. and v. (9) to the deep digital flexors*. These vessels are absent in the dog and horse. On the dorsolateral surface of the tarsal joint the cranial tibial a. and v. become the large **dorsal pedal a.** and the small **dorsal pedal v. (12)**, which, together with the deep peroneal [fibular] n., pass deep to the extensor retinaculum to the metatarsus (see p. 23).

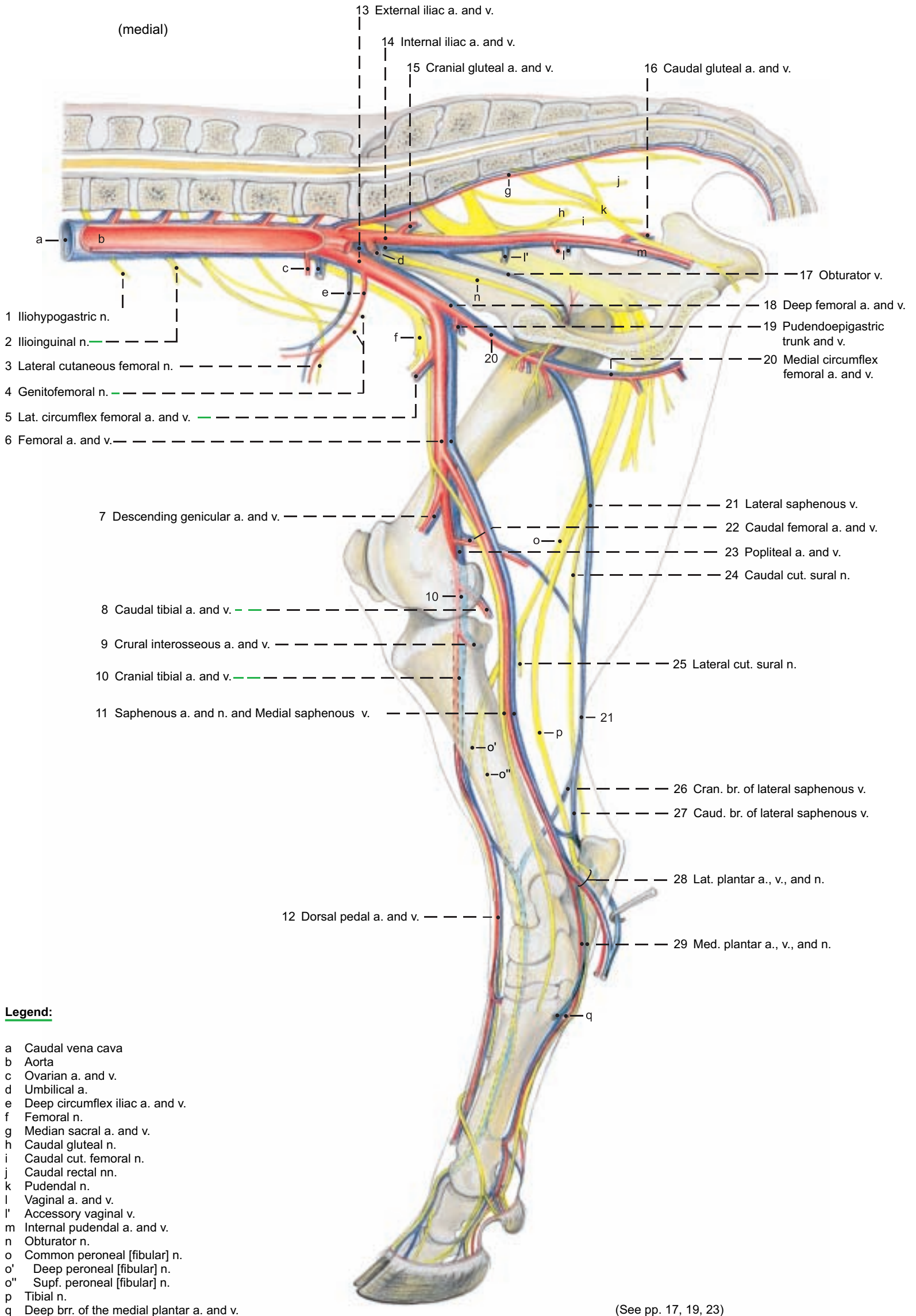
c) The **LYMPH NODES** of the rump and pelvic limb belong to various lymphocenters.

The **deep popliteal ln.**, 3–4 cm long (see p. 17) in the popliteal space between the gluteobiceps and the semitendinosus collects the lymph from the pes and a large part of the crus. The supf. popliteal ln. is absent.

The **sciatic ln.**, 2–3 cm in diameter (see p. 17) lies on the lateral surface of the sacroscliotic ligament at the lesser sciatic foramen and receives lymph from the caudal femoral muscles.

The conspicuous **iliofemoral (deep inguinal) ln.** (see p. 19) drains the pelvis, thigh, crus, and the associated bones and joints. The **subiliac ln.** (p. 67, 5) may reach a length of 10 cm. It drains the skin of the rump, thigh, stifle, and crus. *In meat inspection all of these lymph nodes are examined in retained carcasses*. In addition, the **coxal ln.** (not shown) lies medial to the tensor fasciae latae, and the following lnn. are *present in the ox*, but not in the dog and horse: **gluteal ln.** (see p. 17) *at the greater sciatic notch*, and the **tuberal ln.** (see p. 19) *on the medial surface of the tuber ischiadicum*. The lymph is drained through the sacral, sciatic, iliofemoral, medial and lateral iliac, lnn. and through the lumbar trunks to the cisterna chyli.

Arteries, Veins, and Nerves of the pelvic limb



5. ARTERIES, VEINS, AND NERVES OF THE PES

The dissection is done as on the thoracic limb (see p. 8).

a) The **PLANTAR NERVES** of the tarsus and metatarsus come from the tibial nerve alone. (See the palmar nerves, p. 8. For blood vessels, see p. 20.)

The **tibial n.** divides into the medial and lateral plantar nn. at the distal end of the crus, as in the dog and horse. The **medial plantar n. (3)** passes over the medial side of the tarsus to the metatarsus, covered by fascia and accompanied by the **medial plantar a. and v.** In the metatarsus it runs in the palpable medial groove between the interosseus and the deep flexor tendon, accompanied by the **superficial branches of the medial plantar a. and v.**, to the distal third of the metatarsus, where it divides with the vessels into **plantar common digital aa., vv., and nn. II (9) and III (8)**.

Plantar common digital n. II (9) and the vessels of the same name give off proximal to the fetlock joint the small **axial plantar digital a., v., and n. II (11)** to the medial dewclaw, and the continuing **abaxial plantar digital a., v., and n. III (17)**. This nerve and the artery on its plantar side cross deep to the distal ligament of the dewclaw, while the more dorsal vein crosses it superficially, to the abaxial bulb and hoof regions of the third digit to the apex.

The large **plantar common digital n. III (8)** turns across the plantar surface of the medial branch of the supf. dig. flexor tendon, crosses the artery of the same name, and runs between this and the medially located vein to the interdigital space. The nerve may occasionally be double, or it may divide over a short distance and reunite. At the middle of the proximal phalanx, it and the accompanying vessels divide into the **axial plantar digital aa., vv., and nn. III (20) and IV (19)**. These supply the axial bulb and hoof regions of the third and fourth digits, as the corresponding abaxial structures do (see also p. 11, upper right fig.).

Before their distribution *the nerves each receive a communicating branch from the junction of the superficial and deep dorsal nn.*, and the **plantar common digital a. and v. III (8)** anastomose at their bifurcation with dorsal mt. a. and v. III via the **interdigital a. and v.** (Compare the corresponding vessels of the manus, p. 10.)

The **lateral plantar n.** accompanied by the **lateral plantar a. and v.**, if present, cross distolaterally deep to the long plantar tarsal lig. and reach the metatarsus (see p. 21). The nerve, after reaching the lat. border of the deep flexor tendon just distal to the tarsus, gives off its **deep branch** to the interossei III and IV and becomes **plantar common digital n. IV (5)**. The latter, accompanied by **plantar common digital a. IV (5)**, takes a course like that of plantar common dig. n. II, and divides with the vessels into **axial plantar digital a., v., and n. V (10) and abaxial plantar digital a., v., and n. IV (18)**, which are distributed as the corresponding structures of digits II and III are. **Plantar common digital v. IV** comes from the **distal deep plantar arch**, and is very short.

A communicating branch between the lateral and medial plantar nn., present in the horse, is absent in the ox. Deep plantar mt. nn., present in the dog and horse, are absent in the ox, as are corresponding nn. in the thoracic limb. The deep plantar vessels, **plantar mt. aa. and vv. II–IV**, vary in size. They are similar to the deep palmar vessels on the manus.

b) The **DORSAL NERVES** of the pes come from the **superficial and deep peroneal [fibular] nn.** (For blood vessels see p. 20.)

The **superficial peroneal n. (2)** is distributed as in the dog, but unlike that of the horse, it supplies superficial digital nn. In the crus it gives off **dorsal common digital n. IV (6)**. This crosses distolaterally, deep to the large **cranial br. of the lat. saphenous v. (2)** and the insignificant supf. br. of the dorsal pedal a., runs lateral to the tendon of the lat. dig. extensor in the proximal half of the metatarsus, and in the distal half crosses deep to the large **dorsal common dig. v. IV (6)**. The nerve then runs on the dorsal side of plantar common dig. v. IV to the level of the fetlock joint, where it divides into the small **axial dorsal dig. n. V (14)** to the lateral dewclaw, and the continuing **abaxial dorsal dig. n. IV (15)** to the dorsolateral coronary and bulbar regions of the fourth digit.

The remaining trunk of the supf. peroneal n. courses medial to the cranial br. of the lat. saphenous v. to the dorsal surface of the metatarsus. Separated by the vein from the parallel dorsal common

dig. n. IV, it divides at the end of the proximal third of the mt. into the large dorsal common dig. n. III and the small **dorsal common dig. n. II (4)**. This crosses obliquely mediolaterally over mt. III, without accompanying vessels, to the dorsomedial side of the fetlock joint and divides into **axial dorsal dig. n. II (12)** and **abaxial dorsal dig. n. III (13)**. These nerves are distributed like the corresponding nerves of the fifth and fourth digits. The continuing **dorsal common dig. n. III (7)**, accompanied laterally by **dorsal common dig. v. III (7)**, runs on the tendon of the lateral belly (common extensor of digits III and IV, see p. 16) of the long digital extensor to the interdigital space. Distal to the fetlock joint it divides into **axial dorsal dig. nn. III (21) and IV (22)**. Just before the division it sends a **communicating br.** to the (deep) dorsal mt. n. III (to be described).

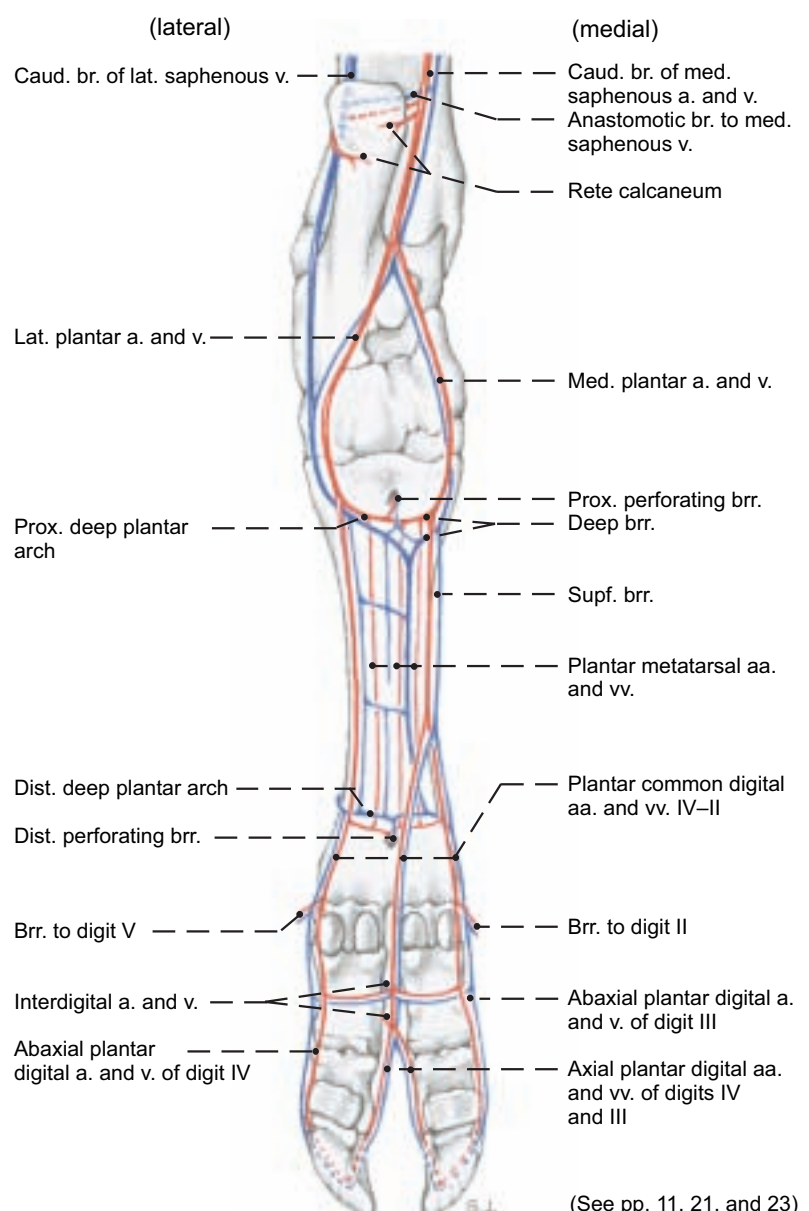
The **deep peroneal n.**, accompanied by the **large dorsal pedal a.** and the **small dorsal pedal v.**, runs on the flexion surface of the tarsus deep to the long and lat. dig. ext. tendons and the **crural and metatarsal extensor retinacula** to the metatarsus. Here the nerve and vessels become **dorsal mt. a., v., and n. III (1)**. They run along the dorsal longitudinal groove on the metatarsal bone to the interdigital space.

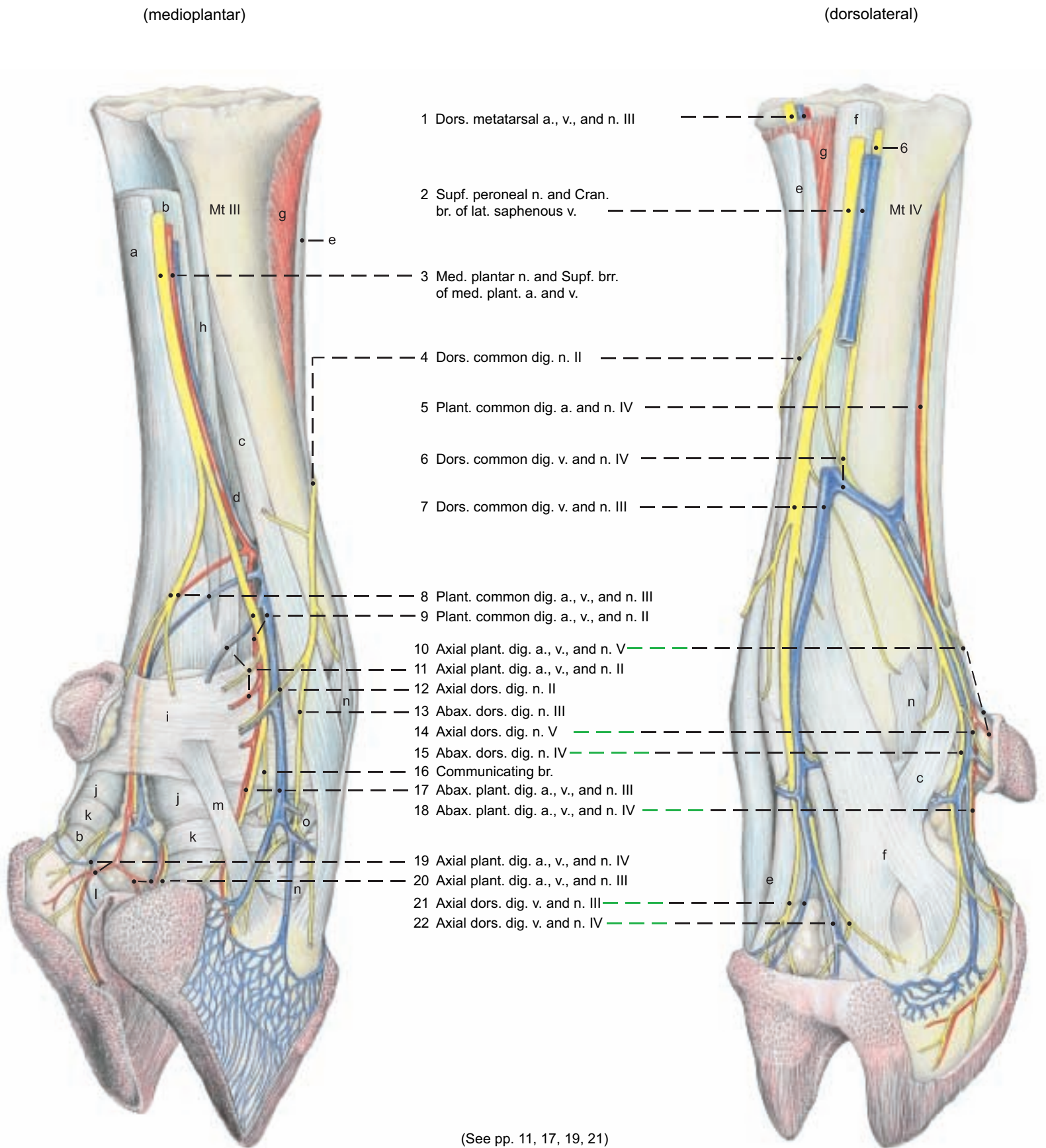
Dorsal mt. n. III receives the communicating br. from the dorsal common dig. n. III, and the resulting short common trunk divides into **communicating brr.** to the axial plantar dig. n.

The dorsal vessels are distributed like the corresponding vessels of the manus. (See p. 11, upper right fig.)

The dorsal and plantar abaxial dig. nn. may be connected by a communicating br. as in the thoracic limb.

Arteries and Veins of the Pes (plantar)





Legend:

Tendons:
 a Supf. dig. flexor
 b Deep dig. flexors and Interossei III and IV:
 c Abax. extensor br.
 d Tendon of interosseus III

Tendons:
 e Long dig. extensor
 Com. ext. of digits III and IV
 Medial extensor of dig. III
 f Lateral dig. extensor
 g Extensor digitalis brevis

h Accessory lig. of interossei
 i Plantar annular lig.
 j Prox. dig. annular lig.
 k Dist. dig. annular lig.

l Supf. part of dist. interdig. lig.
 m Dist. lig. of dewclaw
 n Collateral lig.
 o Abax. plant. lig. of pastern joint

6. DERMIS OF THE HOOF

a) **THE HOOFS** are fully developed on both main digits (3 and 4). They are composed of modified skin with a thick, strongly cornified epidermis. The hoof surrounds the skeletal and soft structures of the distal part of the digit. The main hoofs have an elongated half-round form, and together they serve the same function as the equine hoof, giving rise to the false concept of the “cloven hoof.”

The terms of direction used on the equine hoof—dorsal and palmar or plantar, as well as proximal and distal—apply to the bovine hoof, but medial and lateral are replaced by axial and abaxial with reference to the long axis of the limb, which passes between the main digits.

The Dewclaws are reduced digits II and V that are attached, without synovial joints, by fascial ligaments at the level of the fetlock joint (see p. 10). They do not reach the ground, except in soft footing. The short conical dewclaws are, in principle, composed of the same modified skin layers as the main hoofs. They usually have only two phalanges, sometimes only the distal one.

The hairless skin covering the end of the digit is distinctly modified in its three layers—subcutis, dermis, and epidermis—compared to the haired skin (common integument). These three layers are modified in different parts of the hoof to form five segments: periople, corona, wall, sole, and bulb (see also p. 27).

The **Subcutis** is absent in two segments (wall and sole), but in the other segments forms relatively firm immovable cushions that consist of a three-dimensional network of transverse, longitudinal, and oblique robust connective tissue fibers with enclosed fat lobules. In the bulb there is an especially thick cushion that absorbs the shock when the foot is planted.

The **Dermis** consists of a deep reticular layer and a more superficial papillary layer. The papillary layer, with the exception of the wall segment, bears dermal papillae. These papillae arise either from a smooth surface or from parallel dermal ridges. The wall segment presents parallel dermal lamellae directed from proximal to distal. In some places (proximally and distally) the lamellae bear a row of cap papillae on their free edge.

The deep layers of the **Epidermis** conform to the dermal papillae and lamellae, producing tubular horn in all segments except the wall, and lamellar horn in the wall segment. (See p. 25, middle and lower figures.)

b) **THE SEGMENTS OF THE HOOF** can be clearly distinguished on the dermal surface when the horn capsule is removed after maceration in warm water. The perioplic segment is next to the haired skin. The coronary and wall segments follow distally. The horn formed in these segments moves from proximal to distal and makes up the **horny wall (paries corneus)**. *This turns from the abaxial surface to the axial surface at the dorsal border (Margo dorsalis) of the hoof.* The horn formed in the sole and bulbar segments makes up the ground surface of the hoof. *In clinical practice the entire ground surface is often called the sole.*

I. The **perioplic segment (Limbus, 1)** is about 1 cm wide. Dorsally and abaxially the subcutis forms a slightly convex **perioplic cushion**, absent on the axial surface. On the palmar/plantar surface it expands and is continuous with the digital cushion in the bulb. The **perioplic dermis (6)** covers the subcutis and bears fine distally directed **perioplic papillae** about 2 mm long and relatively sparse. *Abaxially it is separated by a shallow groove from the dermis of the haired skin.* The **periople (Epidermis limbi, 1)** covers the dermis

and forms **horn tubules (12)** on the dermal papillae. The soft perioplic horn grows distally as the external layer of the wall. It usually does not reach the distal border because it flakes off easily. When moist it is markedly swollen.

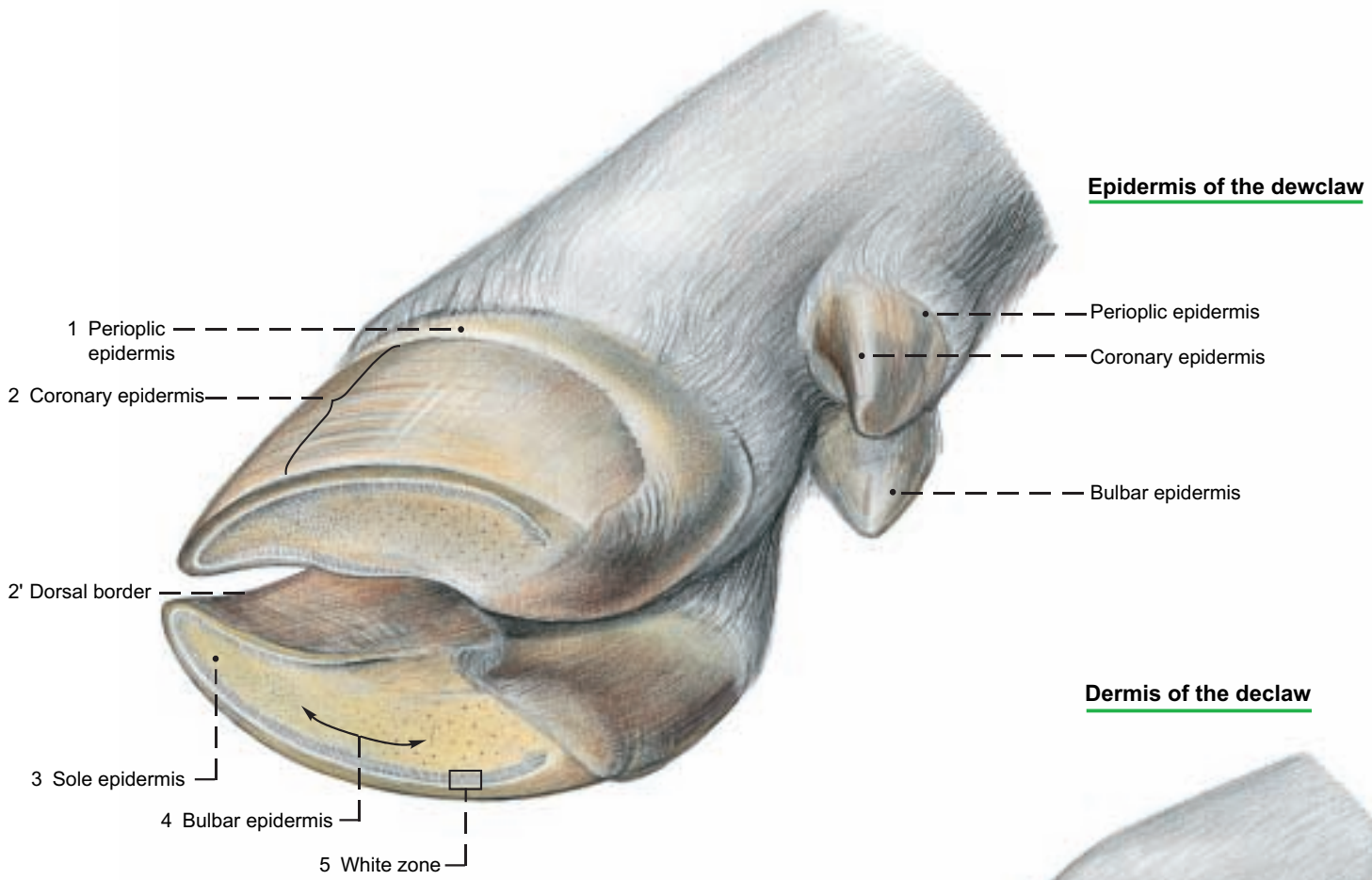
II. **Coronary segment (Corona):** The coronary segment is distal to the perioplic segment and *extends to a level about halfway down the hoof*, unlike that of the horse. The subcutis forms the **coronary cushion**, which is wide and only slightly convex. Its width and thickness decrease on both sides of the hoof in the palmar/plantar direction. The **coronary dermis (7)** bears fine conical **coronary papillae**, rounded off at the ends. *At their base they are thicker and project horizontally, whereas the apical portion is inclined distally in the direction of growth.* The inflection of the coronary segment that forms part of the bar in the horse is slightly indicated at the abaxial end of the lamellar dermis. The **coronary epidermis (2)** forms **horn tubules (13)** which correspond to the dermal papillae and make up the middle layer of the wall. *The thickest, mostly unpigmented, tubules are in the middle layer of the coronary horn, whereas thinner tubules in the outer layer and indistinct or distally absent tubules in the inner layer are typical.*

III. The **Wall segment (Paries)** is distal to the coronary segment and *of about equal width.* The inflection of the wall that forms part of the bar in the horse is only slightly indicated. The subcutis is absent from the wall segment. The **lamellar (parietal) dermis (8)** bears proximodistally oriented **dermal lamellae**. *These are smooth; unlike those of the horse, no secondary lamellae are present.* The **wall epidermis (11)** bears **epidermal lamellae (14)** between the dermal lamellae. The epidermal lamellae are cornified in their middle layers to form the horny lamellae. Unfortunately two different meanings of the word wall complicate the description of the hoof. The horny wall (lamina, hoof plate, Paries corneus) is the more common, broader concept. Homologous to the human fingernail, it is the part of the hoof capsule that includes three layers formed by the perioplic, coronary, and wall segments. The wall *segment* might better be called the lamellar segment, keeping in mind the distinction between the lamina and its lamellae.

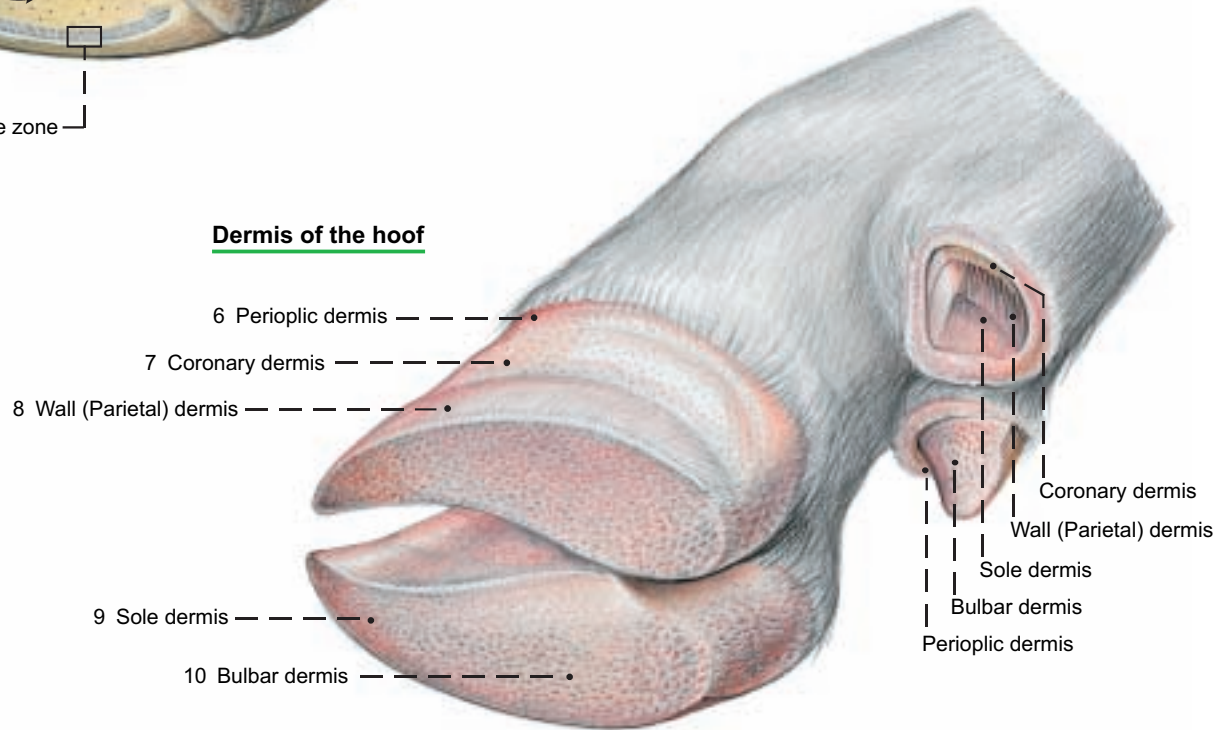
IV. **Sole segment (Solea):** *In artiodactyls this is a narrow crescent inside the white zone (5).* It is divided into a dorsal **body** and **axial** and **abaxial crura** (see text fig. p. 26). The **subcutis** is absent. The **solear dermis (9)** bears low transverse ridges topped by **dermal papillae**, with the result that the papillae are arranged in rows. The **solear epidermis (3)** contains **horn tubules (15)**.

V. **Bulbar segment (Torus ungulae):** The bulbar segment lies palmar/plantar to the sole and between its crura. It extends back to the haired skin. The subcutis forms the **digital cushion**, which distinguishes the bulb from the sole. In the apical part of the bulb the cushion is 5 mm thick; in the basal part it is up to 20 mm thick. *These two parts maybe demarcated by an imaginary line connecting the ends of the white zone (see text fig., p. 26).* The digital cushion is covered by the **bulbar dermis (10)**, which bears **dermal papillae**. These arise in part from discontinuous low, wavelike ridges. Upon the dermis lies the **bulbar epidermis (4)**, containing **horn tubules (16)**. The harder bulbar horn between the crura of the sole presents a flat ground surface. This apical portion is more prominent and more obviously part of the bulb in the sheep, goat, and pig. The horn in the base of the bulb is, depending on the state of hoof care, more or less markedly split into scale-like layers of soft-elastic rubbery consistency. (For segments of the hoof, see also p. 27.)

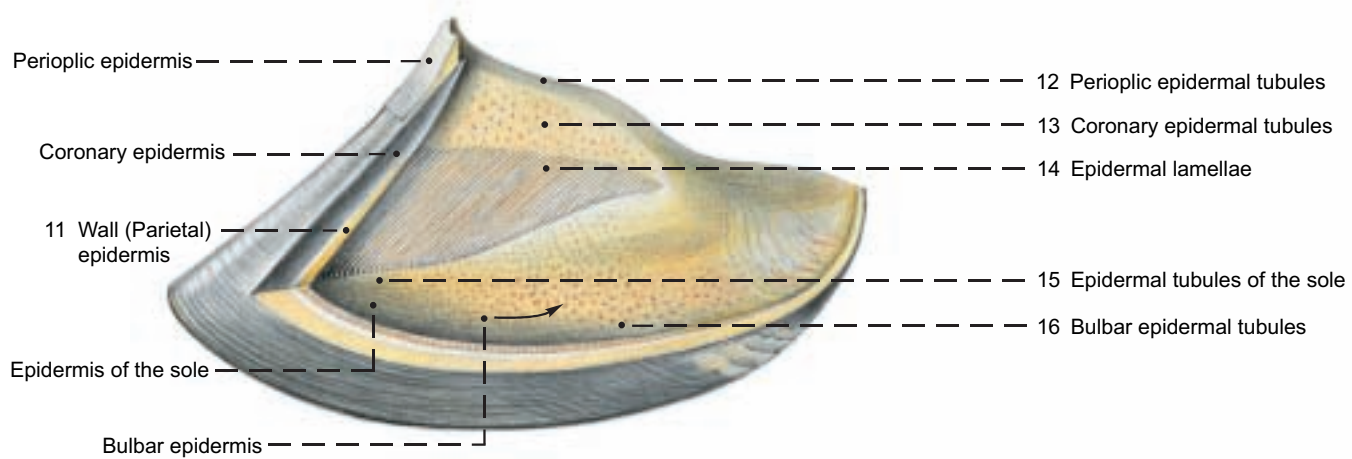
Hoof and Dewclaw



Dermis of the dewclaw



Epidermis (Capsule) of the hoof



7. THE HOOF (UNGULA)

a) The **HOOF CAPSULE** surrounds: the distal end of the **middle phalanx (C)**, the **distal interphalangeal joint (L)**, and the **distal phalanx (coffin bone, D)** with the **terminations of the common dig. extensor tendon (H)** on the extensor process and the **deep dig. flexor tendon (K)** on the flexor tubercle. Also enclosed is the **distal sesamoid (navicular) bone (E)**, which serves as a trochlea for the deep dig. flexor tendon. The **navicular bursa (M)** reduces friction between them.

The **cornified hoof capsule** consists of the lamina (horny wall) with an abaxial part, a dorsal border, and an axial part facing the interdigital space, as well as the horny sole and horny bulb. The capsule has a thickness of about 10 mm in the dorsal part and about 5 mm in the axial part. The growth of the epidermis pushes the cornified masses distally at a rate of about 5 mm per month. After an exungulation the renewal of the entire hoof capsule would require up to 20 months. Horn formation is more intensive in calves than in adults and more active on the pelvic than on the thoracic limb. In the last third of pregnancy and in very high milk production, horn formation is reduced. That is shown on the superficial surface of the hoof by the formation of semicircular grooves.

When cattle are kept on soft footing with little or no possibility of exercise the horn grows faster than it is worn off and therefore the hoofs must be trimmed regularly.

I. The **lamina (Pariet corneus)** consists of external, middle, and internal layers, which are bonded together and formed by the periploic, coronary, and wall segments respectively. The external layer is very thin; the middle layer constitutes the bulk of the lamina; and the internal layer bears the horny lamellae that make up the junctional horn.

II. The junctional horn is part of the **suspensory apparatus of the coffin bone**. This term includes all of the tissues that attach the coffin bone (distal phalanx) to the inside of the lamina. The suspensory apparatus of the coffin bone consists of a connective tissue (dermal) part and an epidermal part. Collagenous fiber bundles anchored in the outer zone of the coffin bone run obliquely proximodorsally in the reticular layer and then in the lamellae of the dermis. The collagen fibers are attached to the basement membrane. The tension is then transmitted through the living epidermal cell layers by desmosomes and bundles of keratin filaments to the junctional (lamellar) horn, which is attached to the lamina. The pressure exerted on the coffin bone by the body weight is transformed by the shock absorbing suspensory apparatus of the coffin bone into tension; the tension is transformed in the lamina to pressure; this pressure weighs upon the ground at the solear border of the lamina. One part of the body weight is not transformed, but falls directly on a support of solear and apical bulbar horn. In the basal bulbar segment the elastic horn and the thick subcutaneous cushion act as a shock absorbing mechanism of the hoof. The chambered cushions work in a manner comparable to the gel cushion system of modern running shoes. With the exception of a non-weightbearing concavity at the axial end of the white zone, the sole and bulb horn form a flat ground surface.

The suspensory apparatus of the coffin bone actuates the **hoof mechanism** by traction on the internal surface of the lamina and by pressure on the sole and bulb. This can be measured with strain gauges. It concerns the elastic changes in form of the hoof capsule that occur during loading and unloading. In weight bearing, the space inside the lamina is reduced, while the palmar/plantar part of the capsule expands and the interdigital space is widened. During unloading, the horny parts return to their initial form and position.

III. The **rate of horn formation** differs greatly among the individual hoof segments. In the coronary segment horn formation is very intensive. In the proximal half of the wall segment the rate of horn

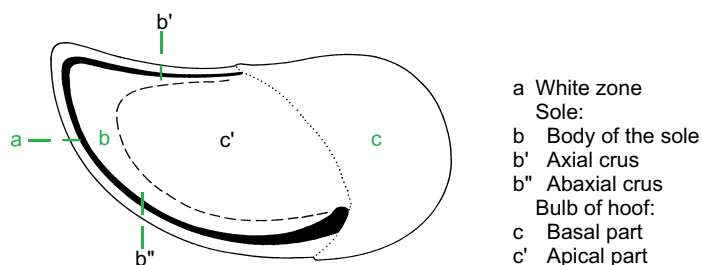
formation is low. In the distal half, on the other hand, horn is formed in measurable amounts and at an increasing rate toward the apex of the hoof. (The term sterile bed, used in older textbooks for the wall segment is therefore incorrect.) Proximally in the wall segment the beginnings of the dermal lamellae bear **proximal cap papillae**. From the epidermis on these papillae, nontubular **proximal cap horn** is produced. This is applied to the sides of the proximal parts of the horny lamellae. Distal to the cap horn, as far as the middle of the wall, not much lamellar horn is added. In the distal half of the wall segment the horny lamellae become markedly higher, up to 5 mm, and, beginning with their middle portion, become flanked by amorphous **distal cap horn** that is applied cap-like over the edges of the dermal lamellae. It is formed on the **distal cap papillae** by the living epidermis there (see p. 27, right figure).

Distally on the wall-sole border the almost vertically directed dermal lamellae bend into horizontally directed dermal ridges of the sole segment. At the bend the lamellae are split into **terminal dermal papillae** which have a remarkable diameter of 0.2–0.5 mm. They are covered by living epidermis from which **terminal tubular horn** is formed. As a part of the white zone the terminal horn fills the spaces between the horny lamellae (see p. 27, right figure).

IV. The **white zone** (white line) consists only of horn produced by the wall segment, and presents external, middle, and internal parts. The **external part (a)** appears to the naked eye as a shining white millimeter-wide stripe. It consists of the basal sections of the horny lamellae and the flanking proximal cap horn, and borders the mostly nonpigmented inner coronary horn, which does not belong to the zona alba. The **middle part (b)** of the white zone is formed by the intermediate sections of the horny lamellae with the distal cap horn that lies between them. The **internal part (c)** of the white zone consists of the crests of the horny lamellae and, between them, the terminal tubular horn. They cornify in the distal half of the wall or at the wall-sole border.

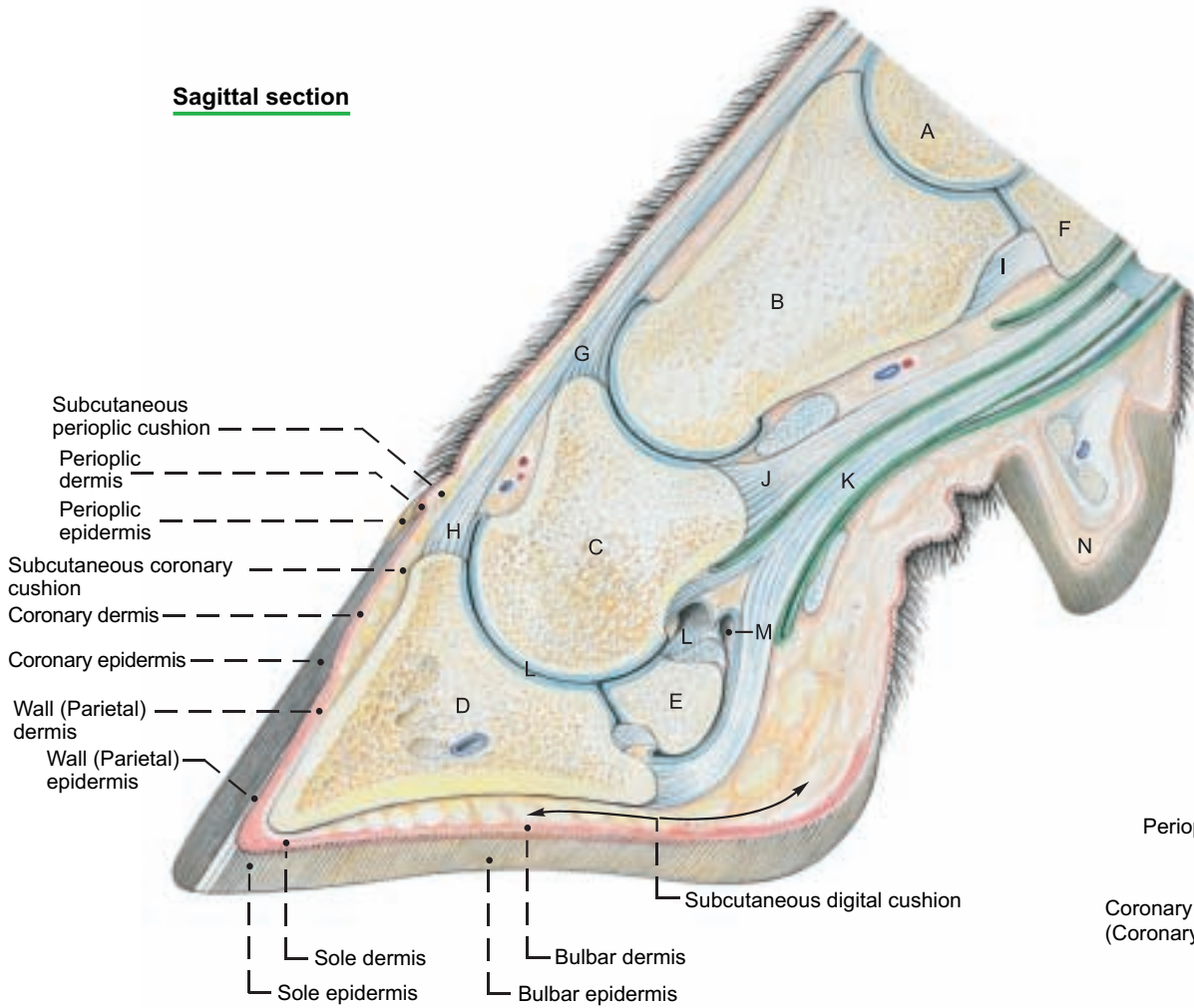
The white zone has abaxial and axial crura (b", b'), which lie between the mostly unpigmented coronary horn and the sole horn. The axial crus ends halfway between the apex of the hoof and the palmar/plantar surface of the bulb. The abaxial crus extends farther, to the basal part of the bulb, where the end of the white zone becomes distinctly wider and turns inward. (See p. 25 above and text illustration.) The whole white zone and especially the wider abaxial end are predisposed to "white line disease," which by ascending infection can lead to "purulent hollow wall." The way for ascending microorganisms is opened by crumbling cap and terminal tubular horn, which technical material testing proves to be masses of soft horn.

V. **Horn quality** is the sum of the characteristics of the biomaterial horn, including hardness or elasticity, resistance to breakage, water absorption, and resistance to chemical and microbial influences. Horn quality is adapted to the biomechanical requirements of the different parts of the hoof. Accordingly, hard horn is found in the lamina; soft elastic horn in the proximal part of the bulb. Horn quality can be determined by morphological criteria in combination with data from physicochemical material testing.

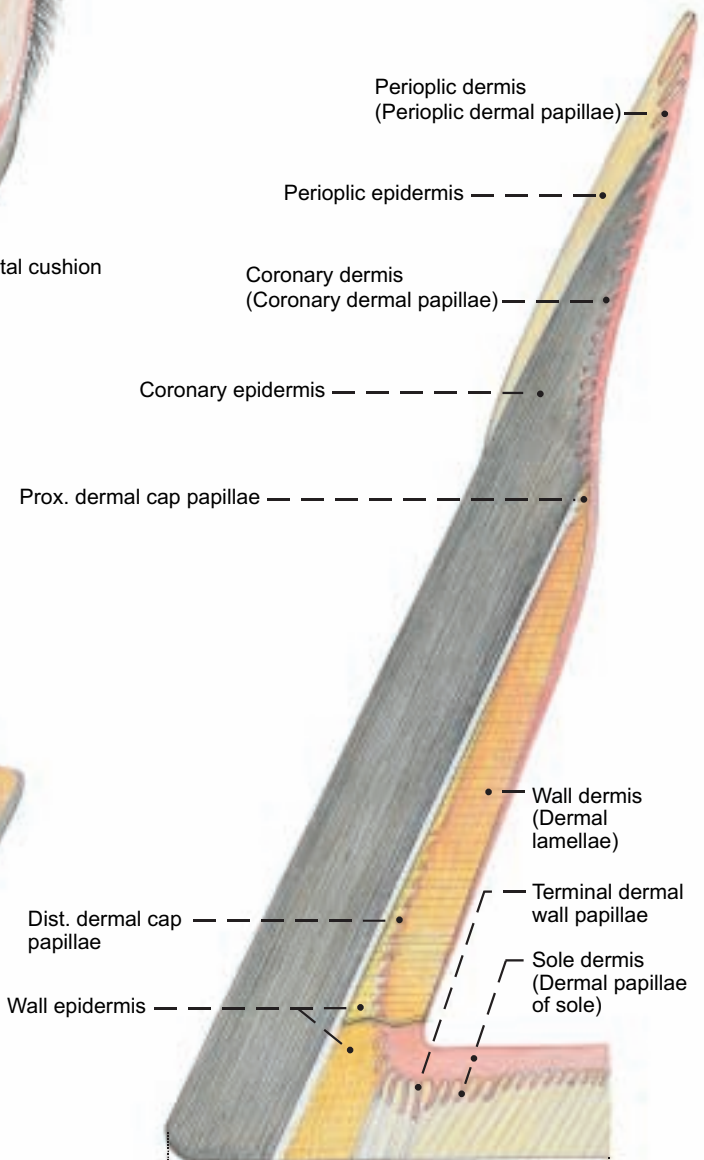


Hoof

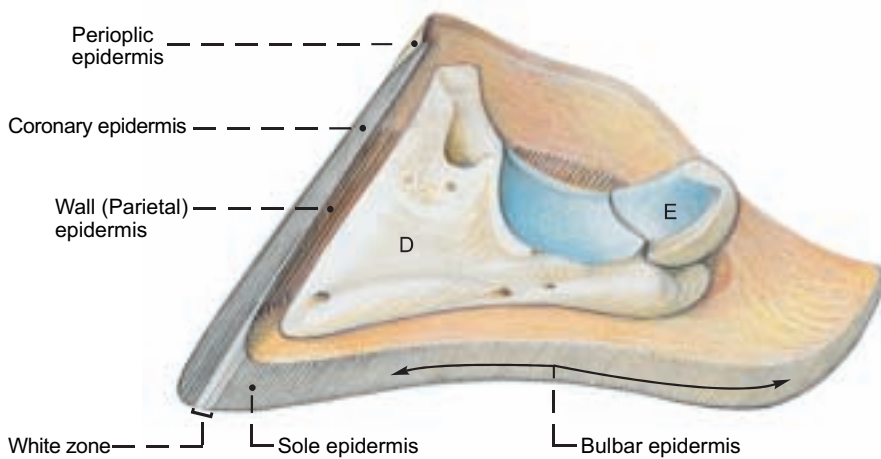
Sagittal section



Sagittal section



Hoof capsule and Distal phalanx (Coffin bone)

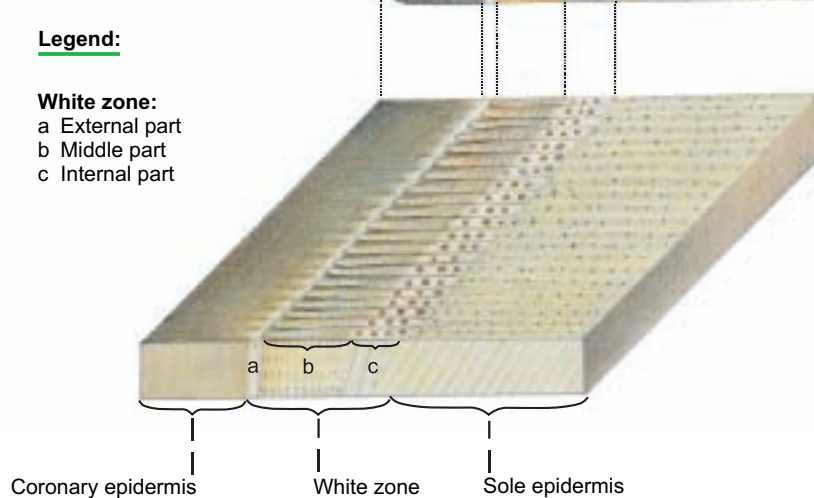


Legend: (See figure above.)

- A Metacarpal bone IV
- B Proximal phalanx
- C Middle phalanx
- D Distal phalanx (coffin bone)
- E Distal sesamoid (navicular) bone
- F Axial prox. sesamoid bone
- G Tendon of lat. dig. extensor
- H Tendon of com. dig. extensor
- I Cruciate sesamoid lig.
- J Tendon of supf. dig. flexor
- K Tendon of deep dig. flexor
- L Distal interphalangeal (coffin) joint
- M Navicular bursa
- N Dewclaw

Legend:

- White zone:**
- a External part
 - b Middle part
 - c Internal part



8. SYNOVIAL STRUCTURES OF THE PELVIC LIMB

a) JOINTS OF THE PELVIC LIMB

NAME	BONES involved	TYPE OF JOINT	FUNCTION	REMARKS
I. Hip joint (Art. coxae)	Ilium, ischium, pubis in acetabulum, and head of femur	Composite spheroidal	Restricted to flexion and extension	Ligaments: transverse acetabular, labrum acetabulare, lig. of head of femur. Accessory lig. absent.
II. Stifle (Art. genus)		Composite joint		
a) Femorotibial joint	Tibial condyles and femoral condyles	Simple condylar	Mainly flexion and extension restricted by ligaments	Ligg.: collateral, cruciate, transverse, meniscotibial, meniscofemoral. Injection: Med. sac, same as II b. Lat. sac in extensor groove of tibia on border of tendon of peroneus tertius; does not communicate with any other sac.*
b) Femoropatellar joint	Femoral trochlea and patella	Simple sesamoid	Tendon guide	Ligg.: med., middle, and lat. patellar, and med. and lat. fem.-patel. Injection: 4 cm. prox. to tibial tuberosity, between med. and middle patellar ligg. Communicates with med. fem.-tibial sac.
III. Prox. tibiofibular joint.	Present in exceptional cases only. Usually the rudimentary fibula is fused with the lateral tibial condyle.			
IV. Distal tibiofibular joint	is a tight joint. Its cavity communicates with the tarsocrural joint.			
V. Tarsal joint (hock)		Composite joint		
a) Tarsocrural joint	Tibial cochlea, prox. trochlea of talus, calcaneus, and lat. malleolus	Composite cochlear joint	Flexion and extension, snap joint	The collateral ligg. each have long and short parts. Long plantar lig. is divided into medial and lat. branches. Many other ligg. are blended with the fibrous joint capsule.
b) Prox. intertarsal joint	Distal trochlea of talus, calcaneus, and T IV + T C.	Composite trochlear joint	Flexion and extension	Injection: Into dorsomed. pouch between med. collat. lig. and med. branch of tendon of cran. tibial muscle
c) Dist. intertarsal joint	T C and T I-T III	Composite plane joint	Slight movement	
d) Tarsometatarsal joint	T I-T IV and metatarsal III and IV	Composite plane joint	Slight movement	
e) Intertarsal joints.	Vertical, slightly moveable joints between tarsal bones in the same row.			
VI. Digital joints.	See thoracic limb.			

b) SYNOVIAL BURSAE

Of the inconstant bursae, the **iliac (coxal) subcutaneous bursa**, unilateral or bilateral over the tuber coxae, and the **ischial subcutaneous bursa** lateral on the tuber ischiadicum, are clinically important. Of the important bursae related to the major trochanter, the inconstant **trochanteric bursa of the gluteus medius** is on the summit and mediodistal surface of the trochanter. The constant **trochanteric bursa of the gluteus accessorius** is on the lateral surface of the femur just distal to the major trochanter. The clinically important, but inconstant **trochanteric bursa of the biceps femoris** is between the vertebral head of the biceps and the terminal part of the gluteus medius on the major trochanter. This bursa may be the cause of a dislocation of the vertebral head of the biceps behind the major trochanter.

The large, up to 10 cm long, constant **distal subtendinous bursa of the biceps femoris** lies between the lat. femoral condyle and the thick terminal tendon of the biceps attached to the patella and the lat. patellar lig. Occasionally it communicates with the lat. femorotibial joint. When inflamed it produces a decubital swelling on the stifle.

The inconstant **subcutaneous bursa of the lat. malleolus**, when inflamed, produces a decubital swelling on the tarsus.

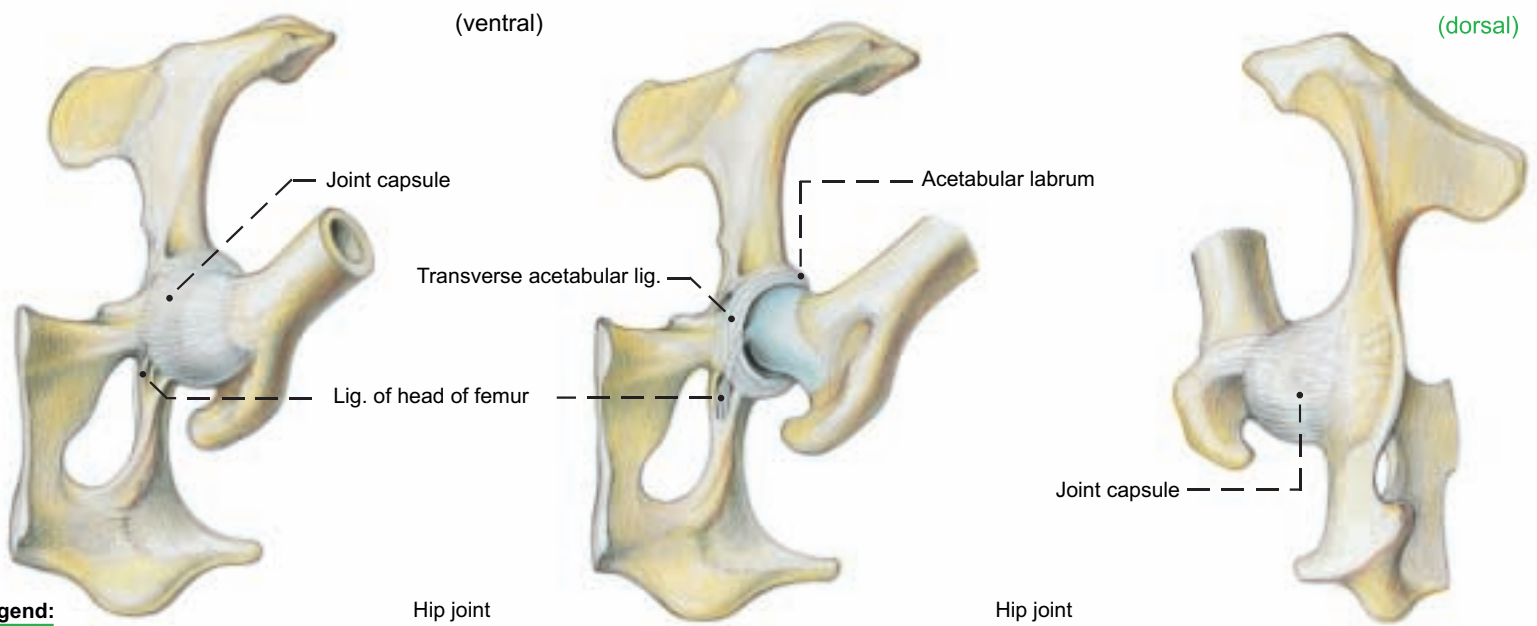
The multilocular **subcutaneous calcanean bursa** on the calcanean expansion of the supf. digital flexor tendon is also inconstant and occurs only in older animals.

The constant, extensive **subtendinous calcanean bursa of the supf. digital flexor** lies between that tendon and the termination of the gastrocnemius on the tuber calcanei. The **navicular (podotrochlear) bursae** (p. 27, M) between the terminal branches of the deep digital flexor tendon and the navicular bones are like those of the thoracic limb.

c) SYNOVIAL SHEATHS

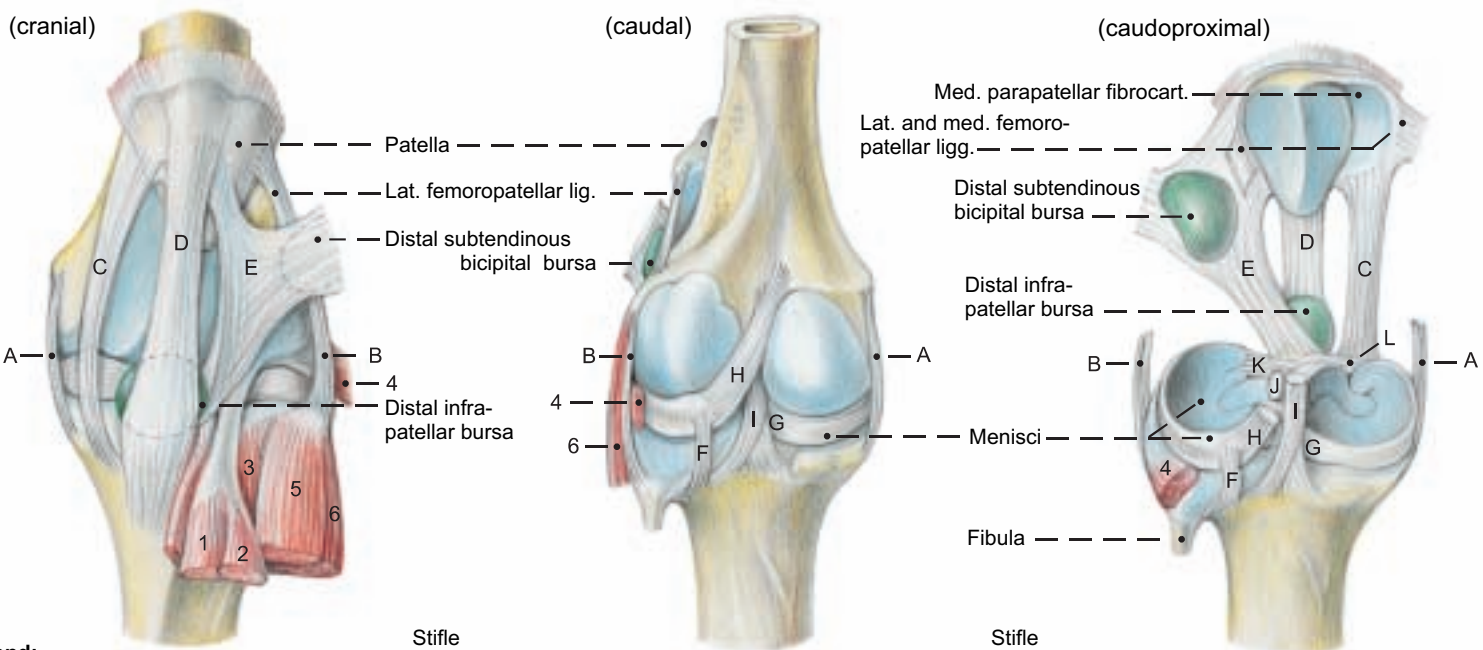
Dorsally on the hock the tendons of the peroneus longus and the digital extensors are surrounded by synovial sheaths. The sheaths of the digital extensors communicate partially with the sheath of the cranial tibial and the sheath-like bursa of the peroneus tertius. On the **plantar aspect of the hock** the lat. digital flexor and the caudal tibial m. have a common sheath, and the med. digital flexor has a separate sheath. The tendon sheaths in the **digits** are like those of the thoracic limb.

Joint, Bursa, and Synovial Sheaths of the Pelvic Limb



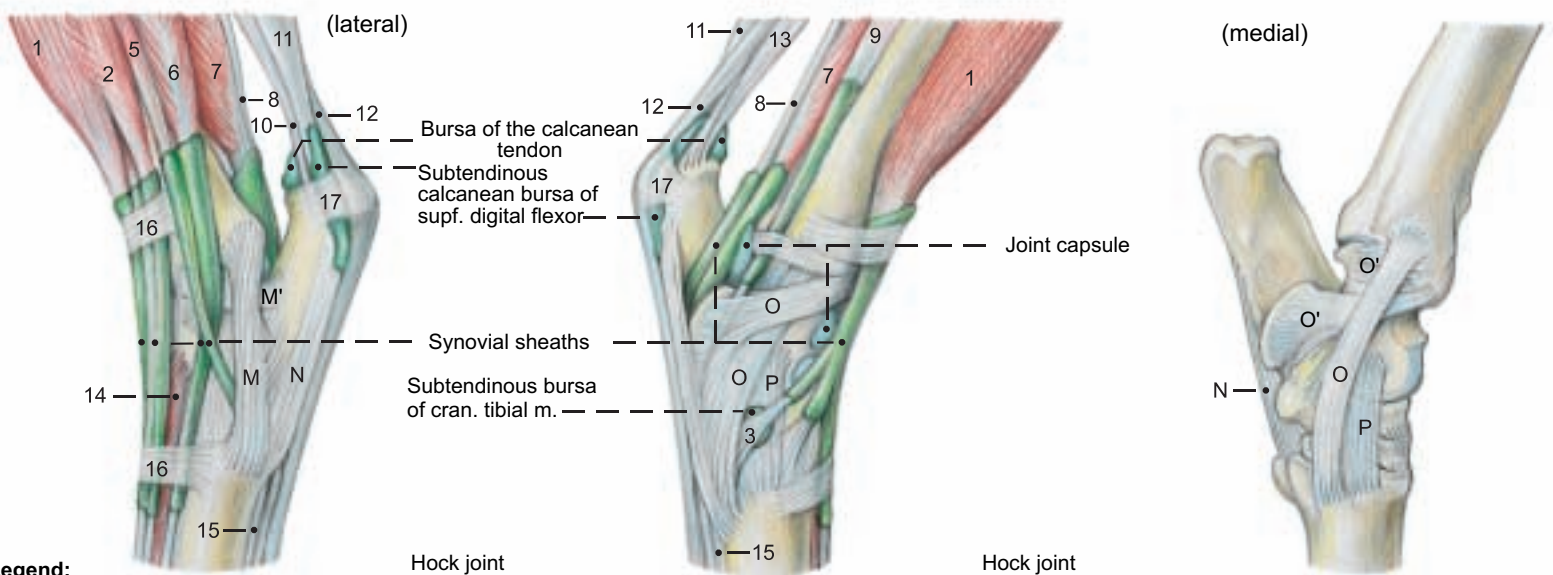
Legend:

- A Med. collateral lig.
- B Lat. collateral lig.
- C Med. patellar lig.
- D Middle patellar lig.
- E Lat. patellar lig.
- F Cd. tibial lig. of lat. meniscus
- G Cd. tibial lig. of med. meniscus
- H Meniscofemoral lig.
- I Cd. cruciate lig.
- J Cr. cruciate lig.
- K Cr. tib. lig. of lat. meniscus
- L Cr. tib. lig. of med. meniscus



Legend:

- M Lat. long collateral tarsal lig.
- M' Lat. short collateral tarsal lig.
- N Long plantar lig.
- O Med. long collateral tarsal lig.
- O' Med. short collateral tarsal lig.
- P Dorsal tarsal lig.
- 1 Peroneus [fibularis] tertius
- 2 Long digital extensor
- 3 Cranial tibial m.
- 4 Popliteus
- 5 Peroneus [fibularis] longus
- 6 Lat. digital extensor



Legend:

- 7 Lat. digital flexor
- 8 Caud. tibial m.
- 9 Med. digital flexor
- 10 Tarsal tendon of biceps femoris
- 11 Gastrocnemius
- 12 Supf. digital flexor
- 13 Tarsal tendon of semitendinosus
- 14 Short digital extensor (in part)
- 15 Interossei III and IV
- 16 Extensor retinaculum
- 17 Flexor retinaculum

CHAPTER 3: HEAD

1. SKULL AND HYOID APPARATUS

The bovine skull undergoes marked changes in shape as it grows from the newborn calf to the adult—changes that are caused in part by the development of the horns. In the process, the roof of the cranium, the occipital surface, and the lateral surfaces alter their relative positions significantly.

a) On the **CRANIUM**, the roof (*Calvaria*) is formed by the **rectangular frontal bones (I)★**. They extend back to the caudal surface of the **intercornual protuberance (3)★■** where they are fused with the **parietal (II)■** and **interparietal (III)■** bones. These are united with the **occipital (VI)■●** bone, but no sutures are visible here in the adult. The **external occipital protuberance (31)■●**, the point of attachment of the funicular lig. nuchae, is about 6 cm ventral to the top of the skull. The **nuchal line (m)■**, arching laterally from the external occipital protuberance, corresponds to the nuchal crest of the horse and dog. On the caudolateral angle of the frontal bone is the **cornual process (3')★■** with its rough body and smoother neck with vascular grooves.

Projecting from the middle of the lateral border of the frontal bone is the **zygomatic process (1)★■**, which joins the **frontal process (56)★■** of the zygomatic bone (IX)★■. The **temporal line (k)★** is the dorsal boundary of the **temporal fossa (j)★**. It is a sharp, palpable ridge running from the zygomatic process back to the horn and serves as a landmark for cornual nerve block (see pp. 34, 40, and 53).

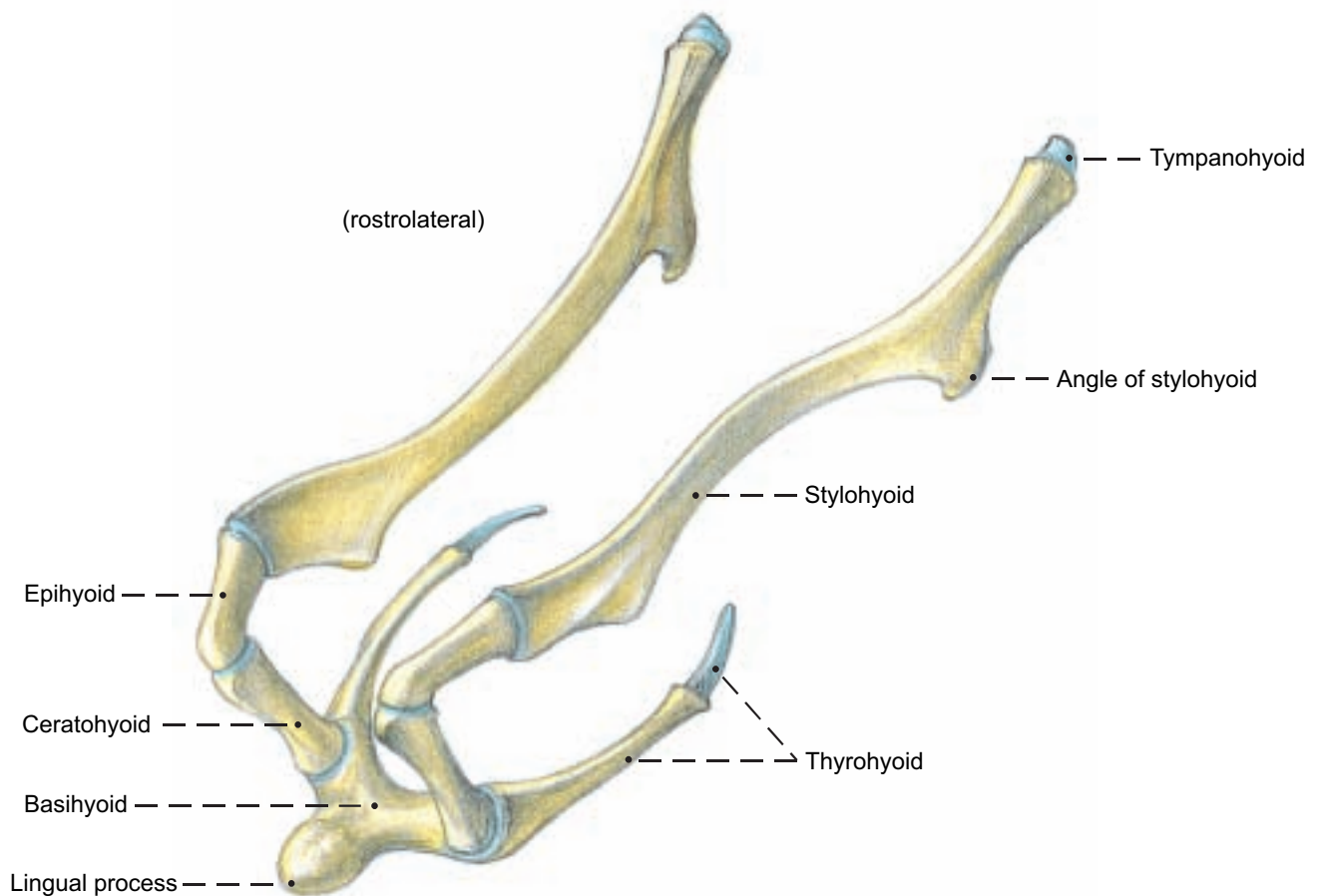
b) The **FACIAL ASPECT**. The **facial crest (57')★** begins on the zygomatic bone and curves across the maxilla to the **facial tuber (57'')★■**. The often double **infraorbital foramen (59)★** is dorsal to the first cheek tooth (p. 2). Caudal to the **nasoincisive notch (X'')★** a fissure persists between the dorsal **nasal bone (X)★** and the ventral **incisive (XII)**, **maxillary (XI)**, **lacrimal (VIII)**, and **frontal (I)** bones. The nasal bone has two rostral processes (X').

c) The **FORAMINA** of the skull are important for the passage of nerves and vessels, and for nerve block anesthesia. Caudolaterally on the skull between the occipital condyle (33)■ and the jugular process (36)■ is the double **canal for the hypoglossal n. (35)■**. Dorsal to the petrous temporal bone is the internal opening of the **temporal meatus (e)●**. There is a lateral opening (e)★ in the temporal fossa. The ox does not have a **foramen lacerum**; it has an **oval foramen (45)★■●** for the mandibular n., connected by the **petro-occipital fissure (q')●** with the **jugular foramen (q)**, which conducts cranial nerves IX, X, and XI. Before the internal carotid a. is occluded at three months of age, it goes through the fissure. In the caudal part of the orbit are three openings: from dorsal to ventral, the **ethmoid for. (2)★**, the **optic canal (52)★●**, and the **for. orbitorotundum (44'')★** (the combined orbital fissure and round for. of the horse and dog.) The pointed projection lat. to these is the **pterygoid crest (46)★■**. On the dorsal surface the frontal bone is pierced medial to the zygomatic process by the **supraorbital canal (1'')★**, often double, which opens in the orbit. The palpable **supraorbital groove (1')★** runs rostrally and caudally from the canal.

d) The **MANDIBLE (XVII)**. See p. 33.

e) The **HYOID APPARATUS** (Text figure). The **body (basihyoid)** gives off a **stubby median lingual process**. The **thyrohyoid** fuses later with the body and articulates with the rostral horn of the thyroid cartilage of the larynx. The **ceratohyoid** articulates with the body and with the **rod-shaped epihyoid**, which in turn articulates with the long, flattened **stylohyoid**. The last three joints are synovial. The proximal end of the stylohyoid is joined by the fibrocartilaginous **tympanohyoid** to the styloid process. The **angle of the stylohyoid is drawn out in the form of a hook**.

Hyoid apparatus



Cranium

- External lamina (a) ●
- Diploe (b) ●
- Internal lamina (c) ●
- Temporal meatus (e) ★ ●
- Retroarticular foramen (h) ■
- Temporal fossa (j) ★
- Temporal line (k) ★ [External frontal crest]
- Nuchal line (m) ■
- Temporal crest (m') ★ ■
- Jugular foramen (q) ●
- Petrooccipital fissure (q') ●

Neurocranial bones

I. Frontal bone ★

- Zygomatic process (1) ★ ■
- Supraorbital groove (1') ★
- Supraorbital canal (1'') ★
- Ethmoid foramen (2) ★
- Intercornual protuberance (3) ★ ■
- Cornual process (3') ★ ■

II. Parietal bone ■

III. Interparietal bone ■

IV. Temporal bone ★ ■

- a. Petrous part (6) ■ ●
- Mastoid process (7) ■
- Internal acoustic meatus
- Internal acoustic pore (8) ●
- Facial canal (9) ●
- Stylomastoid foramen (10) ■
- Styloid process (10') ■
- Petrotympenic fissure (12) ■
- Cerebellar fossa (13) ●
- b. Tympanic part (15) ★
- External acoustic meatus
- External acoustic pore (16) ★ ■
- Tympanic bulla (17) ■
- Muscular process (17'') ■
- c. Squamous part (18) ★
- Zygomatic process (19) ★ ■
- Lateral opening of temporal meatus (e) ★
- Mandibular fossa (20) ■
- Articular surface (21) ■
- Retroarticular process (22) ■

VI. Occipital bone ■ ●

- Squamous part (30) ■
- External occipital protuberance (31) ■ ●
- Internal occipital protuberance (31') ●
- Lateral part (32) ■ ●
- Occipital condyle (33) ■ ●
- Condylar canal (34) ■ ●
- Hypoglossal nerve canal (35) ■ ●
- Jugular and paracondylar process (36) ★ ■ ●
- Basilar part (37) ■ ●
- Foramen magnum (38) ■ ●
- Muscular tubercle (40) ■ ●

VII. Sphenoid bone ■ ●

Basisphenoid bone

- Body (41) ■ ●
- Sella turcica (42) ●
- Wing [Ala] (43) ■ ●
- Groove for ophthalmic and maxillary nn. (44') ●
- Foramen orbitorotundum (44'') ★
- Oval foramen (45) ★ ■ ●
- Pterygoid crest (46) ★ ■

Presphenoid bone

- Body (50) ■ ●
- Wing [Ala] (51) ■
- Orbitosphenoid crest (51') ●
- Optic canal (52) ★ ●

Face

- Pterygopalatine fossa (A) ■
- Major palatine canal
- Caudal palatine foramen (B) ■
- Major palatine foramen (C) ■
- Minor palatine canals
- Caudal palatine foramen (B) ■
- Minor palatine foramina (D) ■
- Sphenopalatine foramen (E) ■ ●
- Choanae (F) ■
- Orbit (G) ★ ■
- Palatine fissure (H) ★ ■

Facial bones

VIII. Lacrimal bone ★

- Fossa for lacrimal sac (54) ★
- Lacrimal bulla (54') ★ ■

IX. Zygomatic bone ★ ■

- Temporal process (55) ★ ■
- Frontal process (56) ★ ■

X. Nasal bone ★

- Rostral process (X') ★
- Nasoincisive notch (X'') ★

XI. Maxilla ★ ■

- Body of maxilla (57) ★ ■
- Facial crest (57') ★
- Facial tuber (57'') ★ ■
- Infraorbital canal
- Infraorbital foramen (59) ★
- Lacrimal canal (see p. 35 D)
- Zygomatic process (63) ★ ■
- Palatine process (64) ■
- Alveolar process (65) ★ ■

XII. Incisive bone ★ ■ ●

- Body of incisive bone (66) ★ ■ ●
- Alveolar process (67) ★ ■ ●
- Palatine process (68) ★ ■ ●
- Nasal process (69) ■ ●

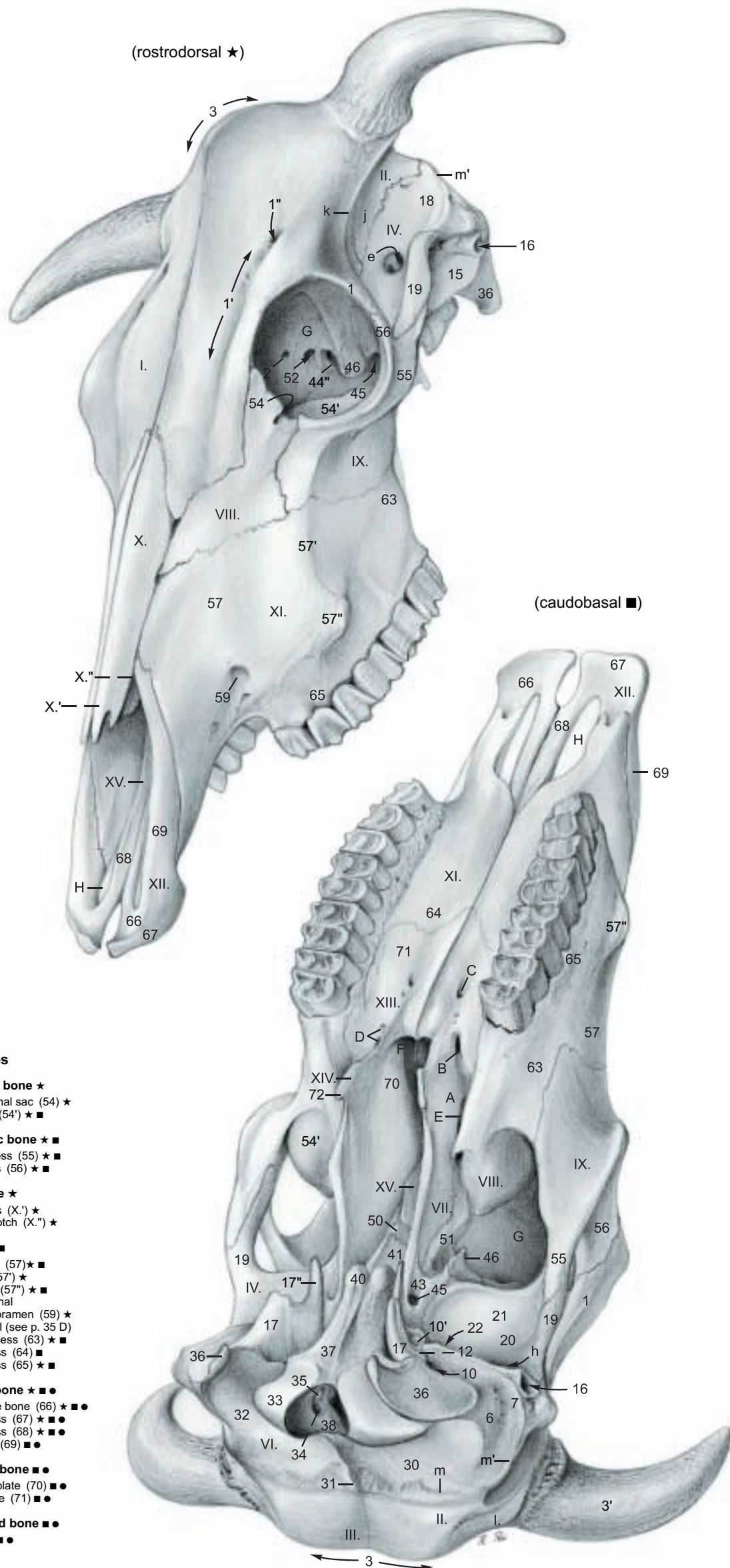
XIII. Palatine bone ■ ●

- Perpendicular plate (70) ■ ●
- Horizontal plate (71) ■ ●

XIV. Pterygoid bone ■ ●

- Hamulus (72) ■ ●

XV. Vomer ●



2. SKULL WITH TEETH

DENTITION.

The formula for the permanent teeth is:

$$2 \left(I \frac{0}{3} C \frac{0}{1} P \frac{3}{3} M \frac{3}{3} \right) = 32$$

where I = incisor, C = canine, P = premolar, and M = molar.

The formula for the deciduous teeth (milk teeth) is:

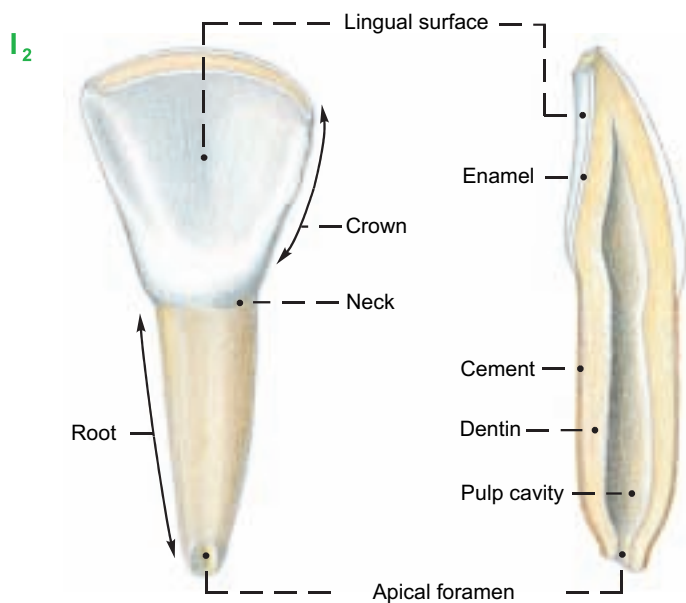
$$2 \left(Di \frac{0}{3} Dc \frac{0}{1} Dp \frac{3}{3} \right) = 20$$

where Di = deciduous incisor, Dc = deciduous canine, and Dp = deciduous premolar.

In domestic ruminants the missing upper incisors and canines are replaced by the **dental pad** (p. 45, a) a plate of connective tissue covered by cornified epithelium.

The individual **TEETH** have a **crown**, **neck**, and **root**. They consist of **dentin** (ivory), **enamel**, and **cement**. The five **surfaces** of a tooth are: **lingual**, **vestibular** (labial or buccal), **occlusal**, and two **contact surfaces**. The **mesial contact surface** of the incisors is toward the median plane; on all other teeth it is directed toward the incisors. The opposite contact surface is **distal**. Although the upper incisors and canines are absent after birth, the primordia are present in the embryo.

The **canine teeth** (C) have the shape of incisors (I1, 2, 3) with a definite neck and a shovel-shaped crown; therefore they are commonly counted as the fourth incisors. When these teeth erupt, the crown is covered briefly by a thin pink layer of gingival mucosa, and neighboring teeth overlap, but by the end of the first month they have rotated so that they stand side by side. The permanent incisors erupt at about the following ages: I1, 1½–2 yrs.; I2, 2–2½ yrs.; I3, 3 yrs.; C, 3½–4 yrs. At first the crown is completely covered by enamel; lingual and labial surfaces meet in a sharp edge. The lingual surface is marked by **enamel ridges** extending from the occlusal border about two thirds of the way to the neck. As the tooth wears, the thin lingual enamel is abraded faster than the thick labial plate, keeping the tooth beveled to a sharp edge (see text fig.). The darker, yellowish **dentin** is exposed and forms most of the occlusal surface. The dental star appears, filled with secondary dentin. The lingual border of the occlusal surface is notched between the ridges on the lingual surface. When the tooth wears down to the point where the ridges disappear, the lingual border of



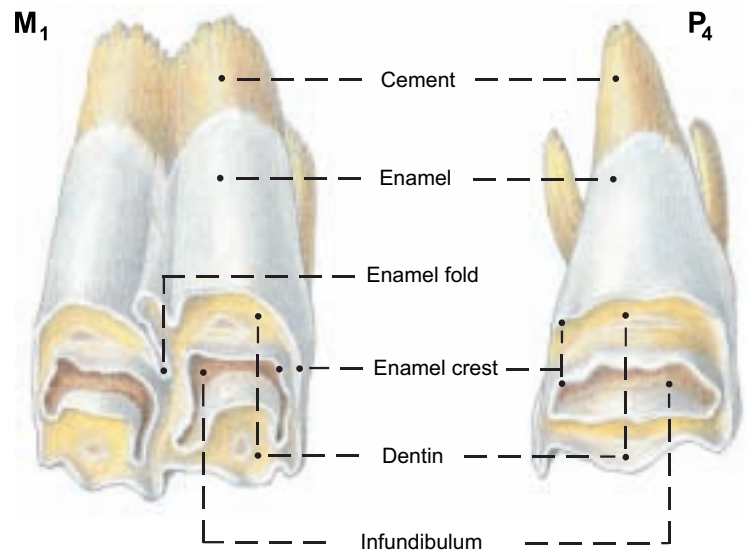
the occlusal surface is a smooth curve and the tooth is said to be level. This usually occurs in sequence from I1 to C at 6, 7, 8, and 9 years. Deciduous incisors and canines are smaller than permanent teeth and have narrower necks. The first premolar is missing, so

that the first cheek tooth is P2. Between the canines and the premolars in the lower jaw there is a space, the **diastema** (J), with no teeth. The size of the cheek teeth increases greatly from rostral to caudal. The incisors and canines are brachydont teeth; they do not grow longer after they are fully erupted, and they do not have infundibula. The cheek teeth are hypsodont; they continue to grow in length after eruption, but to a lesser extent than in the horse.

The **infundibula** of the cheek teeth develop by infolding of the enamel organ. (See text fig.) When tooth erupts the central enamel of each infundibulum is continuous with the external enamel in a crest. As the crest wears off the infundibulum is separated from the external enamel and the **dentin** is exposed between them. In ruminants the sections of the infundibula visible on the occlusal surface are crescentic. The infundibula are partially filled by **cement** and blackened feed residue. The outside of the newly erupted tooth is also coated with cement.

The **upper premolars** have one infundibulum and three roots. The **upper molars** have two infundibula and three roots. The horns of the crescents of all the infundibula of the upper cheek teeth point toward the buccal surface. The **lower premolars** (P2, 3, 4) are irregular in form. P2 is small and has a simple crown, usually without enamel folds. P3 and P4 have two vertical enamel folds on the lin-

(Upper teeth, lingual surface)



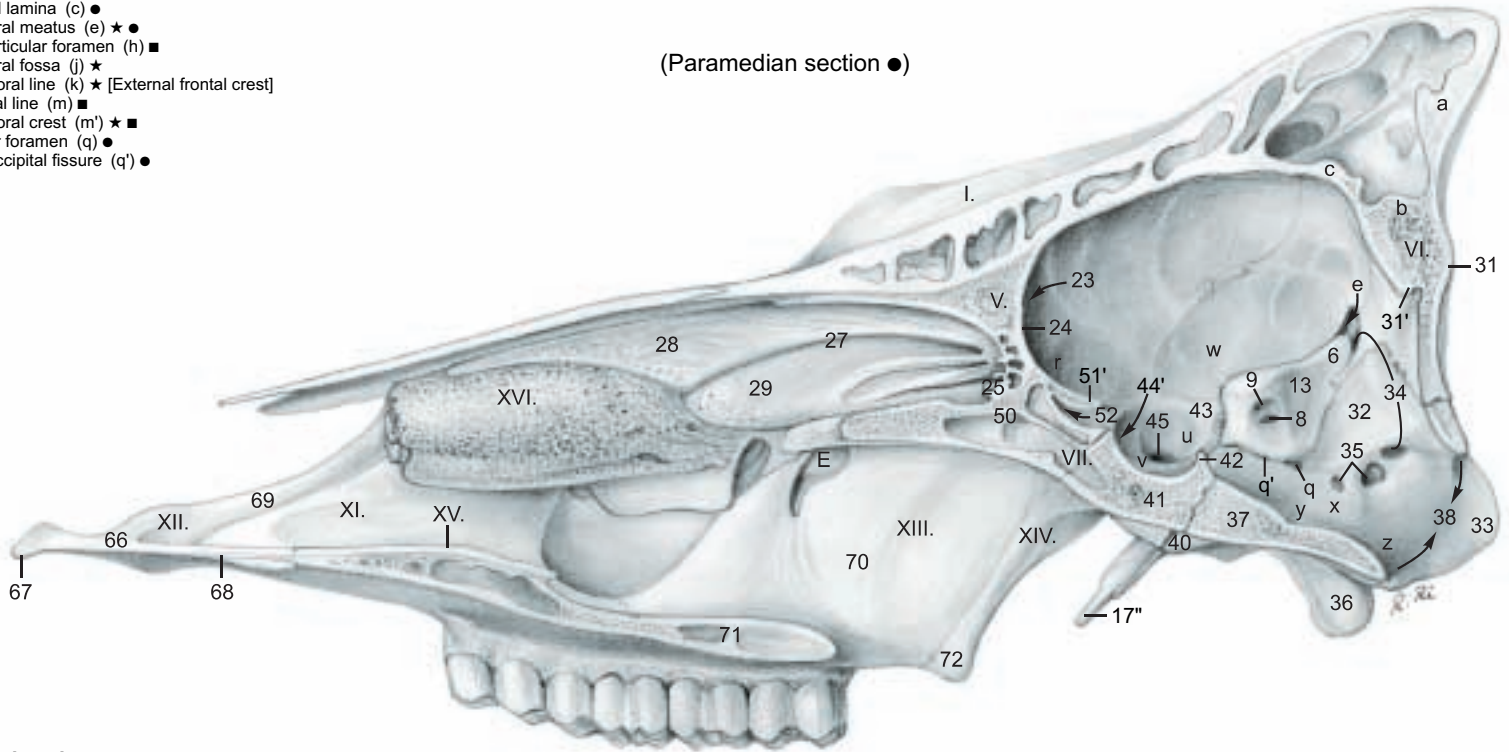
gual surface. On P4 the caudal one may be closed to form an infundibulum. The lower premolars have two roots. The **lower molars** (M1, 2, 3) have two infundibula and two roots. The horns of the infundibula point toward the lingual surface.

The lower jaw is narrower than the upper jaw, and the occlusal surface of the upper cheek teeth slopes downward and outward to overlap the buccal edge of the lower teeth, but the lateral motion of the mandible in chewing, first on one side and then on the other, wears the occlusal surfaces almost equally.

Cranium

- External lamina (a) ●
- Diploë (b) ●
- Internal lamina (c) ●
- Temporal meatus (e) ★ ●
- Retroarticular foramen (h) ■
- Temporal fossa (j) ★
- Temporal line (k) ★ [External frontal crest]
- Nuchal line (m) ■
- Temporal crest (m') ★ ■
- Jugular foramen (q) ●
- Petrooccipital fissure (q') ●

(Paramedian section ●)



Cranial cavity

- Rostral cran. fossa (r) ●
- Middle cran. fossa (u) ●
- Hypophysial fossa (v) ●
- Piriform fossa (w) ●
- Caudal cran. fossa (x) ●
- Pontine impression (y) ●
- Medullary impression (z) ●

Neurocranial bones

II. Parietal bone ★ ■

III. Interparietal bone ■

IV. Temporal bone ★ ■

- a. Petrous part (6) ■ ●
- Mastoid process (7) ■
- Internal acoustic meatus
- Internal acoustic pore (8) ●
- Facial canal (9) ●
- Stylomastoid foramen (10) ■
- Styloid process (10') ■
- Petrotympic fissure (12) ■
- Cerebellar fossa (13) ●

- b. Tympanic part (15) ★
- External acoustic meatus
- External acoustic pore (16) ★ ■
- Tympanic bulla (17) ■
- Muscular process (17'') ■ ●

- c. Squamous part (18) ★
- Zygomatic process (19) ★ ■
- Mandibular fossa (20) ■
- Articular surface (21) ■
- Retroarticular process (22) ■

V. Ethmoid Bone ●

- Cribriform plate (23) ●
- Crista galli (24) ●
- Ethmoid labyrinth (25) ●
- Ethmoturbinates
- Ectoturbinates (not shown)
- Endoturbinates (27) ●
- Dorsal nasal concha (28) ●
- Middle nasal concha (29) ●

VI. Occipital bone ■ ●

- Squamous part (30) ■
- External occipital protuberance (31) ■ ●
- Internal occipital protuberance (31') ●
- Lateral part (32) ■ ●
- Occipital condyle (33) ■ ●
- Condylar canal (34) ■ ●
- Hypoglossal nerve canal (35) ■ ●
- Jugular and paracondylar process (36) ★ ■ ●
- Basilar part (37) ■ ●
- Foramen magnum (38) ■ ●
- Muscular tubercle (40) ■ ●

VII. Sphenoid bone ■ ●

Basisphenoid bone

- Body (41) ■ ●
- Sella turcica (42) ●
- Wing [Ala] (43) ■ ●
- Groove for ophthalmic and maxillary nn. (44') ●
- Foramen orbitotundum (44'') p. 31 ★
- Oval foramen (45) ★ ■ ●
- Pterygoid crest (46) ★ ■

Presphenoid bone

- Body (50) ■ ●
- Wing [Ala] (51) ■
- Orbitosphenoid crest (51') ●
- Optic canal (52) ★ ●

Face

Facial bones

- Sphenopalatine foramen (E) ■ ●

XII. Incisive bone ■ ●

- Body of incisive bone (66) ★ ■ ●
- Alveolar process (67) ★ ■ ●
- Palatine process (68) ★ ■ ●
- Nasal process (69) ★ ■ ●

XIII. Palatine bone ■ ●

- Perpendicular plate (70) ■ ●
- Horizontal plate (71) ■ ●

XIV. Pterygoid bone ■ ●

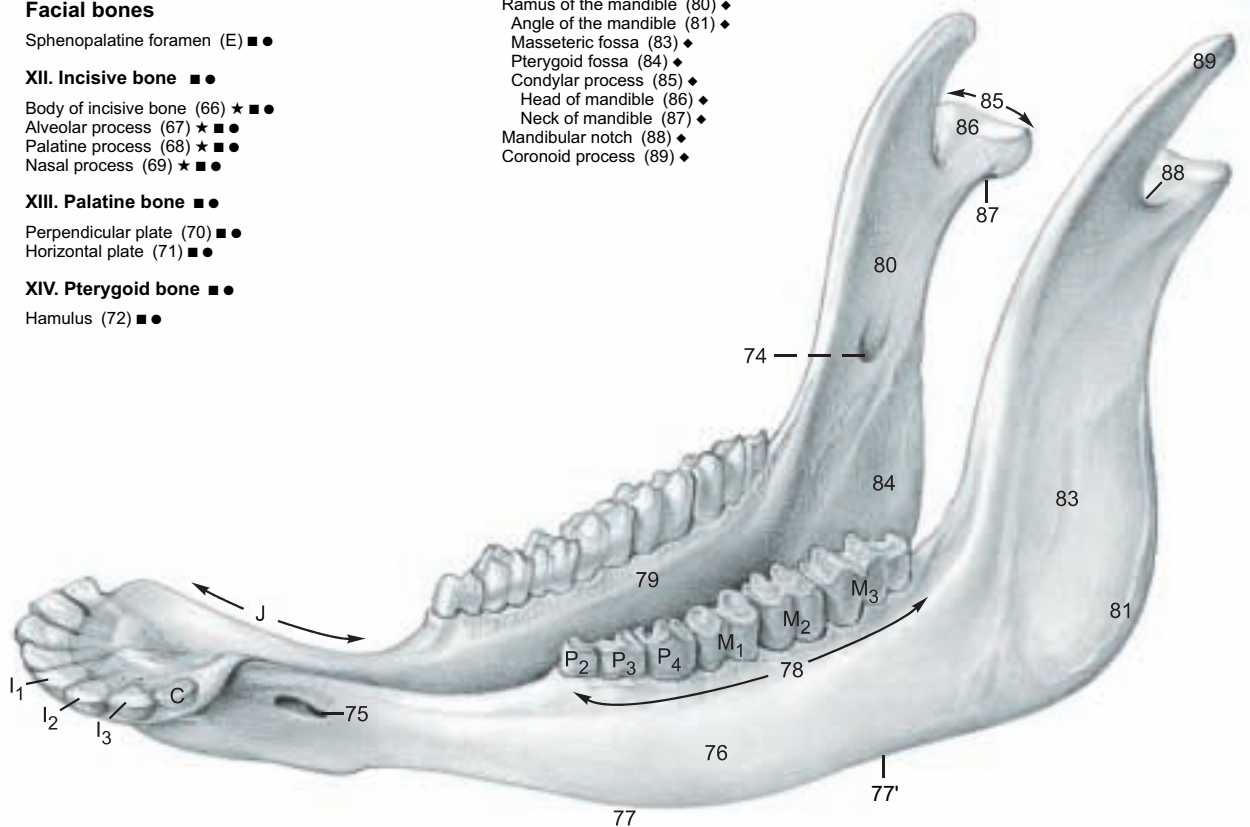
- Hamulus (72) ■ ●

XV. Vomer ●

XVI. Ventral nasal concha ●

XVII. Mandible ◆

- Mandibular canal
- Mandibular foramen (74) ◆
- Mental foramen (75) ◆
- Body of the mandible (76) ◆
- Diastema (J) ◆
- Ventral border (77) ◆
- Vascular groove (77') ◆
- Alveolar border (78) ◆
- Mylohyoid line (79) ◆
- Ramus of the mandible (80) ◆
- Angle of the mandible (81) ◆
- Masseteric fossa (83) ◆
- Pterygoid fossa (84) ◆
- Condylar process (85) ◆
- Head of mandible (86) ◆
- Neck of mandible (87) ◆
- Mandibular notch (88) ◆
- Coronoid process (89) ◆



XVII. Mandible ◆

3. SKULL WITH PARANASAL SINUSES AND HORNS

a) The **PARANASAL SINUSES** (see also p. 45) may be studied from prepared skulls, but many of the clinically important septa are not solid bone; they are completed by membranes that do not survive maceration. The paranasal sinuses develop by evagination of the nasal mucosa into the spongy bone (diploë, b, p. 33)● between the **external** and **internal plates** (a, c)● of the cranial and facial bones. Therefore each sinus is lined by respiratory epithelium and, except for the lacrimal and palatine sinuses, which are diverticula of the maxillary sinus, each has a direct opening to the nasal cavity. Unfortunately, when inflammation occurs, the mucous membrane swells and closes the aperture, blocking normal drainage of the sinus. This condition may require surgical drainage.

The paranasal Sinuses of the Ox

Group I	Group II
Maxillary	Frontal
Lacrimal	Caudal
Palatine	Rostral
Conchal	Medial
Dorsal	Intermediate
Ventral	Lateral
	Sphenoid
	Ethmoid cells
	Middle conchal sinus

I. The **first group of sinuses** open into the middle nasal meatus (p. 45, 6)

1. The **maxillary sinus** (7) occupies the maxilla and extends back under the orbit into the thin-walled **lacrimal bulla** (E) and into the zygomatic bone, thereby surrounding the orbit rostrally and ventrally. The **nasomaxillary opening** is high on the medial wall just ventral to the **lacrimal canal** (D) and midway between the orbit and the facial tuber. It opens into the middle nasal meatus.

The maxillary sinus communicates with the **lacrimal sinus** (5) and through the **maxillopalatine opening** (F) over the **infraorbital canal** (G) with the **palatine sinus** (10). See also p. 45, j.

There is a large opening in the bony wall between the ventral nasal meatus and the palatine sinus, but this is closed in life by the apposition of their mucous membranes.

2. Also opening into the middle nasal meatus is the **dorsal conchal sinus** (6) in the caudal part of the dorsal concha, and

3. the **ventral conchal sinus** in the caudal part of the ventral concha (XVI) p. 33●. See also p. 45.

II. The **second group of sinuses** open into ethmoidal meatuses in the caudal end of the nasal cavity.

1. The **frontal sinuses** are variable in size and number. In the newborn calf, they occupy only the frontal bone rostradorsal to the brain. *In the aged ox the caudal frontal sinus is very extensive, invading also the parietal, interparietal, occipital, and temporal bones.* Left and right frontal sinuses are separated by a **median septum** (B). The **caudal frontal sinus** (1) is bounded rostrally by an **oblique transverse septum** (B') that runs from the middle of the orbit caudomedially to join the median septum in the transverse plane of the caudal margin of the orbit. The caudal boundary is the occipital bone and the lateral boundary is the **temporal line** (k)*. There is an extension into the zygomatic process. The **supraorbital canal** (C), conducting the frontal vein, passes through the caudal frontal sinus in a plate of bone that appears to be a septum, but is always perforated. The caudal frontal sinus has three clinically important diverticula: the **nuchal** (H), **cornual** (J), and **postorbital** (K) diverticula. The caudal frontal sinus has only one aperture: at its rostral extremity there is a small outlet to an ethmoid meatus. *There is no frontomaxillary opening in any domestic animal except the Equidae.* The **rostral frontal sinuses** (2, 3, 4) lie between the rostral half of the orbit and the median plane. Each has an opening at

its rostral end to an ethmoid meatus. A part of the **dorsal nasal concha** (6) projects caudally between two of the rostral frontal sinuses. The lateral rostral frontal sinus is separated by a thin septum from the lacrimal sinus.

2. The **sphenoid sinus** (8), when present, opens into an ethmoid meatus.

3. The **ethmoid cells** (9) in the medial wall of the orbit, and

4. The **sinus of the middle concha** (p. 45, g) open into ethmoid meatuses.

b) The **HORNS** (CORNUA) project from the caudolateral angle of the frontal bone in both sexes, (except for hornless breeds, which have only a knob-like thickening of the bone.) Round, and tapering conically to a small apex, their form is not only species and breed specific, but is also quite variable individually. In the cow they are slender and long—in the bull, thick and short, and in the steer also thick, but longer. We recognize a **base**, a **body**, and an **apex**. The osseous core of the horn is the cornual process of the frontal bone (p. 31, 3'), which until shortly before birth is a rounded thickening. This elongates after birth to become a massive bony cone, and beginning at six months is pneumatized from the caudal frontal sinus. This is clinically important in deep wounds of the horns and in dehorning methods.

The bony process, like the distal part of the digit, is covered by greatly modified skin.

I. The subcutis is absent and the periosteum is fused with the dermis.

II. The **dermis** bears distinct papillae, which become longer on the base and especially toward the body, and lie step-wise over each other parallel to the surface. On the apex they are large free vertical tapering papillae. The dermis forms the positive die on which the living epidermis is molded.

III. The **epidermis of the horn** produces from its living cells the cornified horn sheath (stratum corneum) as **horn tubules** corresponding to the dermal papillae. The tubules are bound together by intertubular horn. **Longitudinal growth** of the horns occurs under the previously formed conical horn sheath through the production of a new cone of horn by the living epidermal cells, pushing the horny substance toward the apex. This can be seen on a longitudinal section. The horn consists of a stack of cones, each produced during a growth period, the horn sheath becoming thicker toward the apex. Radial growth pressure inside the rigid sheath compresses and flattens the tubules so that they are not recognizable in the body. On the apex of the cornual process additional tubular horn is formed over the free papillae. Growth is mainly longitudinal; growth in diameter is of lesser importance.

The formation of horn substance is steady in the bull; therefore the horns appear smooth on the surface. In the cow, growth is periodical and variable in rate, causing superficial rings and grooves. The **rings** are the product of regular, and the **grooves** the product of irregular horn formation, which is explained primarily by repeated pregnancies, but also by nutritional deficiencies and possibly diseases.

On the base of the horn at the transition from the skin to the horn sheath there is an epidermal zone called the **epikeras** that is comparable to the periople of the equine hoof.

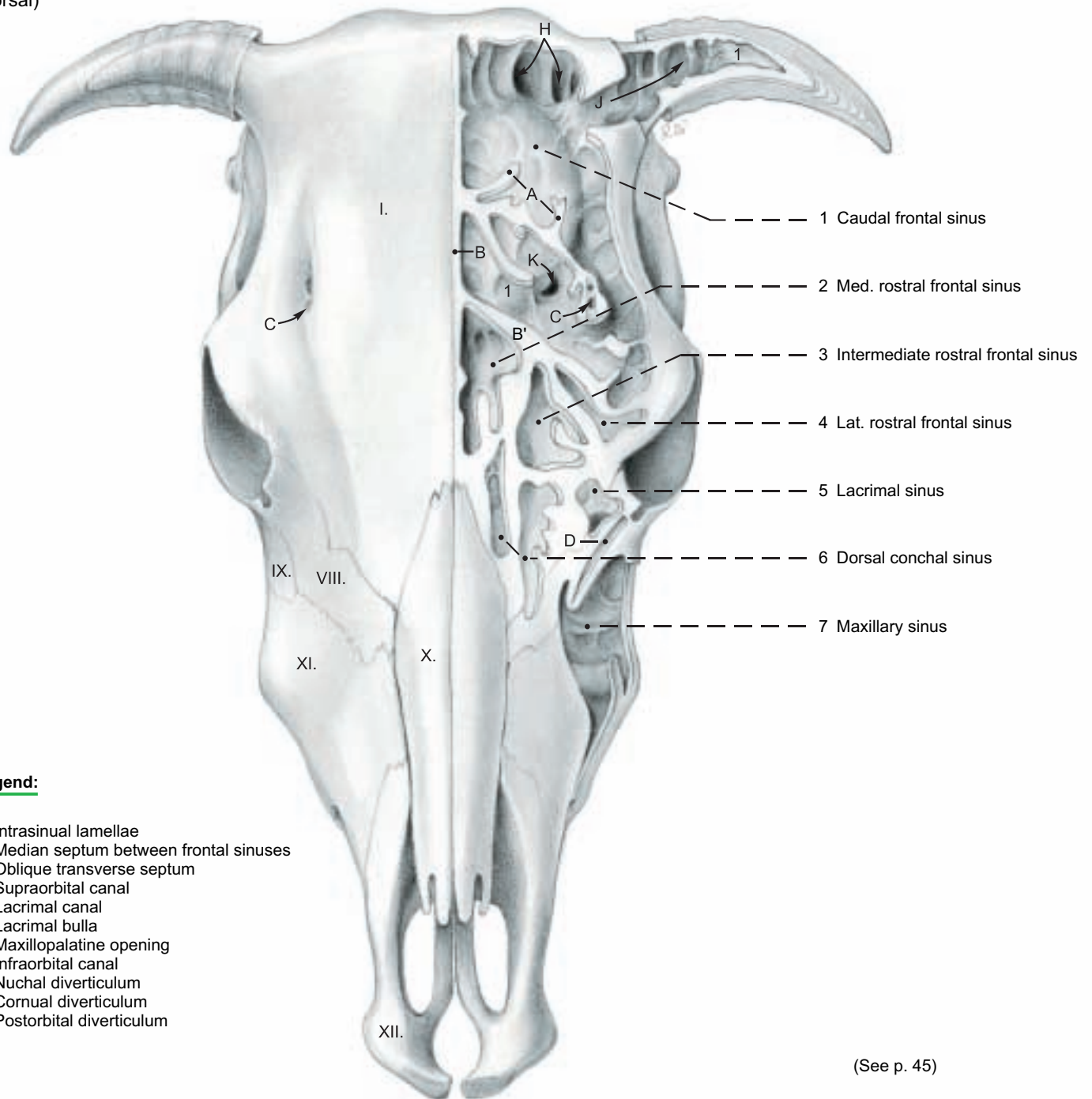
The **blood supply** of the horns comes from the cornual aa. and vv. from the supf. temporal a. and v.

The **innervation** is supplied by the cornual br. of the zygomaticotemporal br. (see p. 40) and also the supraorbital and infratrochlear nn., all from the ophthalmic n.

The **lymph** is drained to the parotid ln.

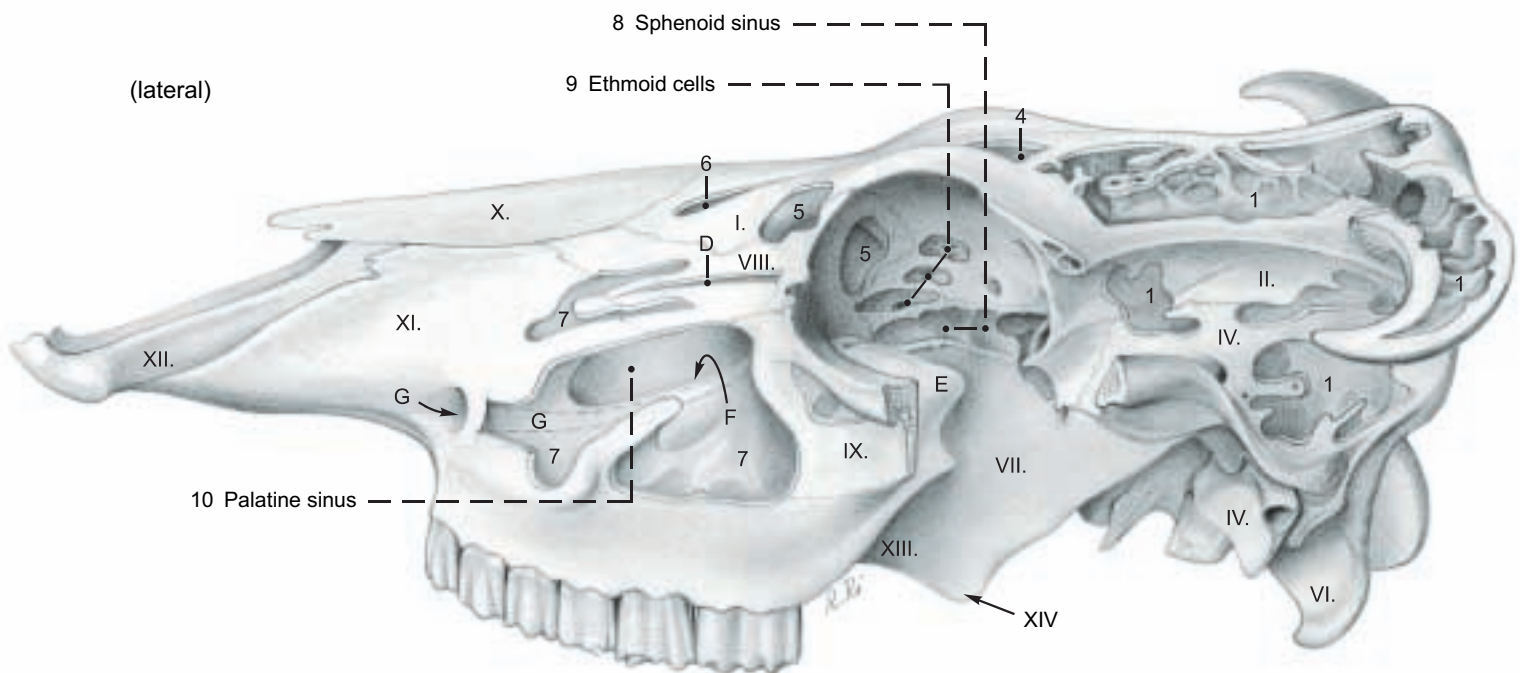
Paranasal Sinuses and Horns

(dorsal)



(See p. 45)

(lateral)



4. SUPERFICIAL VEINS OF THE HEAD, FACIAL N. (VII), AND FACIAL MUSCLES

To demonstrate the superficial veins and nerves, the head is split in the median plane and the skin is removed, except for a narrow strip of skin around the horn, eye, nose, and mouth, noting the cutaneous faciei (A) and the frontalis, which is spread superficially over the frontal region. The parotidoauricularis and zygomaticoauricularis are transected and reflected to expose the parotid gland. The dorsal part of the gland above the maxillary v. is removed piecemeal, sparing the vessels and nerves in the gland, and the large parotid lymph node ventral to the temporo-mandibular joint.

a) The **SUPERFICIAL VEINS** (refer to p. 37) are drained by the **external jugular v. (k)** whose main branches, the **linguofacial** and **maxillary vv.**, cross the lateral surface of the mandibular gland. The **linguo-facial v. (16)**, after giving off the **lingual v.**, is continued as the **facial v. (8)**. The **lingual v.** gives off the **sublingual v.** as in the dog. The **sternomandibularis (F)** must be reflected to see the **facial v.** where it crosses the ventral border of the mandible in the vascular groove with the **facial a. (f)**, **ventr. buccal br. (33) of the facial n., parotid br. (h) of the buccal n. (V3),*** and **parotid duct (j)**. On the lateral surface of the mandible the **supf. and deep vv. of the lower lip (28)** are given off. From the caudal side of the facial v. at this level, the **deep facial v. (27)** passes deep to the masseter to the **deep facial plexus (text fig. b)** and to the orbit. The facial vessels continue dorsally, supplying **deep and superficial vessels of the upper lip (21)**. The vein supplies the **lat. nasal v. (9)** and **dorsal nasal v. (7)**, and is continued by the **v. of the angle of the eye (6)**. The latter *passes dorsomedial to the orbit and becomes the frontal v.*, which courses in the supraorbital groove (p. 31, 1') to the supraorbital foramen.

Caudal to the angle of the mandible, medial to the parotid gl., the **maxillary v. (15)** gives off the **caud. auricular v. (14)** and the **ventral masseteric v. (34)**. (The occipital v. comes from the int. jugular v.) Before the maxillary v. turns deep to the ramus of the mandible it gives rise to the large **supf. temporal v. (31)**, which gives off the **short transverse facial v. (30)**, the **rostral auricular v. (18)**, and the **cornual v. (17)**, and turns rostrally into the orbit to become the **dorsal ext. ophthalmic v. (19)**.

b) The **FACIAL N. (VII)** as it leaves the stylomastoid foramen, gives off the **caud. auricular n.** and **internal auricular br., which does not give off the cutaneous brr. that go to the base and inner surface of the auricle in the horse and dog;** these are supplied exclusively by the auricular branch of the vagus n. Dorsally, the facial n. gives off the **auriculopalpebral n. (29)**, which divides into the rostral auricular brr. and the zygomatic br. The latter runs forward on the surface of the zygomatic arch to the eyelids and ends in palpebral brr. In the parotid gland the facial n. divides into dorsal and ventral buccal brr. The **dorsal buccal br. (32)** emerges at the ventral

end of the parotid ln. under the parotid gland. It is joined by a large branch of the sensory auriculotemporal n. (V3, g) and courses toward the upper lip, supplying facial muscles and cutaneous sensation. The **ventral buccal br. (33)** is more slender than the dorsal br. *It follows the caudal and ventral borders of the masseter (unlike that of the horse) to the vascular groove, whence it runs along the ventral border of the buccinator and depressor labii inferioris to the lower lip. The cervical br. (Ramus colli) is absent in the ox.*

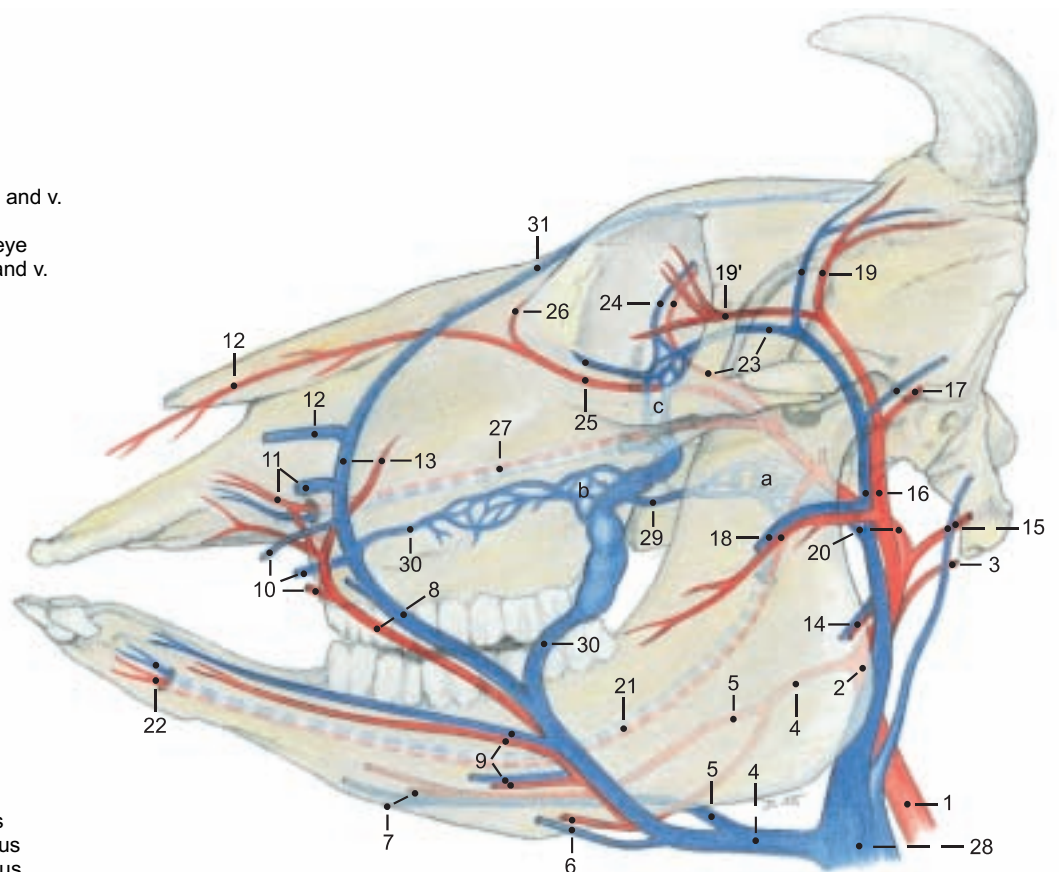
c) The **FACIAL MUSCLES** include lip and cheek muscles, the muscles of the eyelids and nose, and ear muscles. The **levator nasolabialis (5)** is a broad thin muscle originating from the frontal bone *and the frontalis*. Between its superficial and deep layers pass the **levator labii superioris (22)** and **caninus (23)**. These two muscles and the **depressor labii superioris (24)** originate close together from the facial tuber. The levator labii superioris covers the ventral part of the infraorbital foramen, which is nevertheless palpable. The **depressor labii inferioris (25)** originates deep to the masseter from the caudal part of the alveolar border of the mandible. The **zygomaticus (11)** originates from the masseteric fascia ventral to the orbit and runs obliquely across the masseter and buccinator to the **orbicularis oris (10)** at the corner of the mouth. The **buccinator (26)** forms the muscular layer of the cheek. The **molar part** is covered by the masseter and the depressor labii inferioris. The **buccal part** is a thin layer of mostly vertical fibers.

The muscles of the eyelids are the **orbicularis oculi (4)**, **frontalis (1)**, **levator palpebrae superioris** (see p. 41, 13), and **malaris (20)**. *The frontalis (not present in the horse) takes over the function of the absent retractor anguli oculi lat., and augments the action of the levator palpebrae superioris.* Of the ear muscles, the **parotidoauricularis (13)** extends on the surface of the parotid gland from the ventral part of the parotid fascia to the intertragic notch. The **zygomaticoauricularis (12)** begins on the zygomatic arch and runs back to end at the intertragic notch. The **cervicoscutularis (2)** originates from the lig. nuchae and the skull behind the intercornual protuberance. *The short interscutularis (3) comes from the cornual process and the temporal line, and has no connection with the contralateral muscle.*

Arteries and Veins of the Head

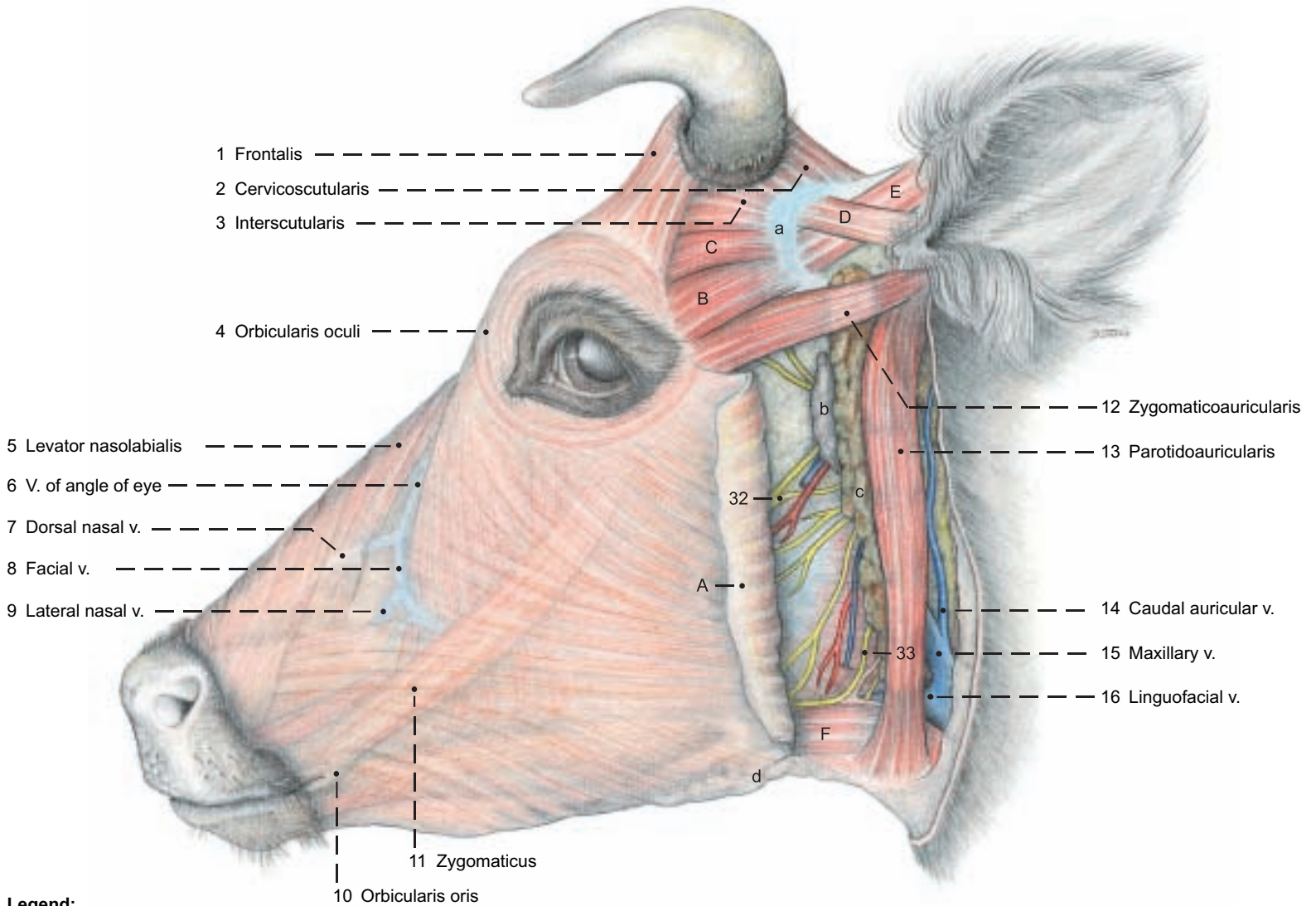
Legend: (Numbers differ from those in text.)

- | | |
|--|---------------------------|
| 1 Common carotid a. | 24 Supraorbital a. and v. |
| 2 External carotid a. | 25 Malar a. and v. |
| 3 Occipital a. | 26 A. of angle of eye |
| 4 Linguofacial tr. and v. | 27 Infraorbital a. and v. |
| 5 Lingual a. and v. | 28 Ext. jugular v. |
| 6 Submental a. and v. | 29 Buccal v. |
| 7 Sublingual a. and v. | 30 Deep facial v. |
| 8 Facial a. and v. | 31 Frontal v. |
| 9 Supf. and deep inf. labial a. and v. | |
| 10 Superior labial a., supf. and deep sup. labial v. | |
| 11 Rostral lat. nasal a. and lat. nasal v. | |
| 12 Dors. nasal a. and v. | |
| 13 Arterial br. and v. of angle of eye | |
| 14 Ventr. masseteric br. and v. | |
| 15 Caud. auricular a. and v. | |
| 16 Supf. temporal a. and v. | |
| 17 Rostr. auricular a. and v. | |
| 18 Transverse facial a. and v. | |
| 19 Cornual a. and v. | |
| 19' Inf. and sup. palpebral aa. | |
| 20 Maxillary a. and v. | |
| 21 Inferior alveolar a. and v. | |
| 22 Mental a. and v. | a Pterygoid plexus |
| 23 Ext. ophth. a., dors. ext. ophth. v. | b Deep facial plexus |
| | c Ophthalmic plexus |



* V = Trigeminal n., V1 = Ophthalmic n. V2 = Maxillary n. V3 = Mandibular n.

Arteries and Veins of the head, Facial n. and Facial muscles



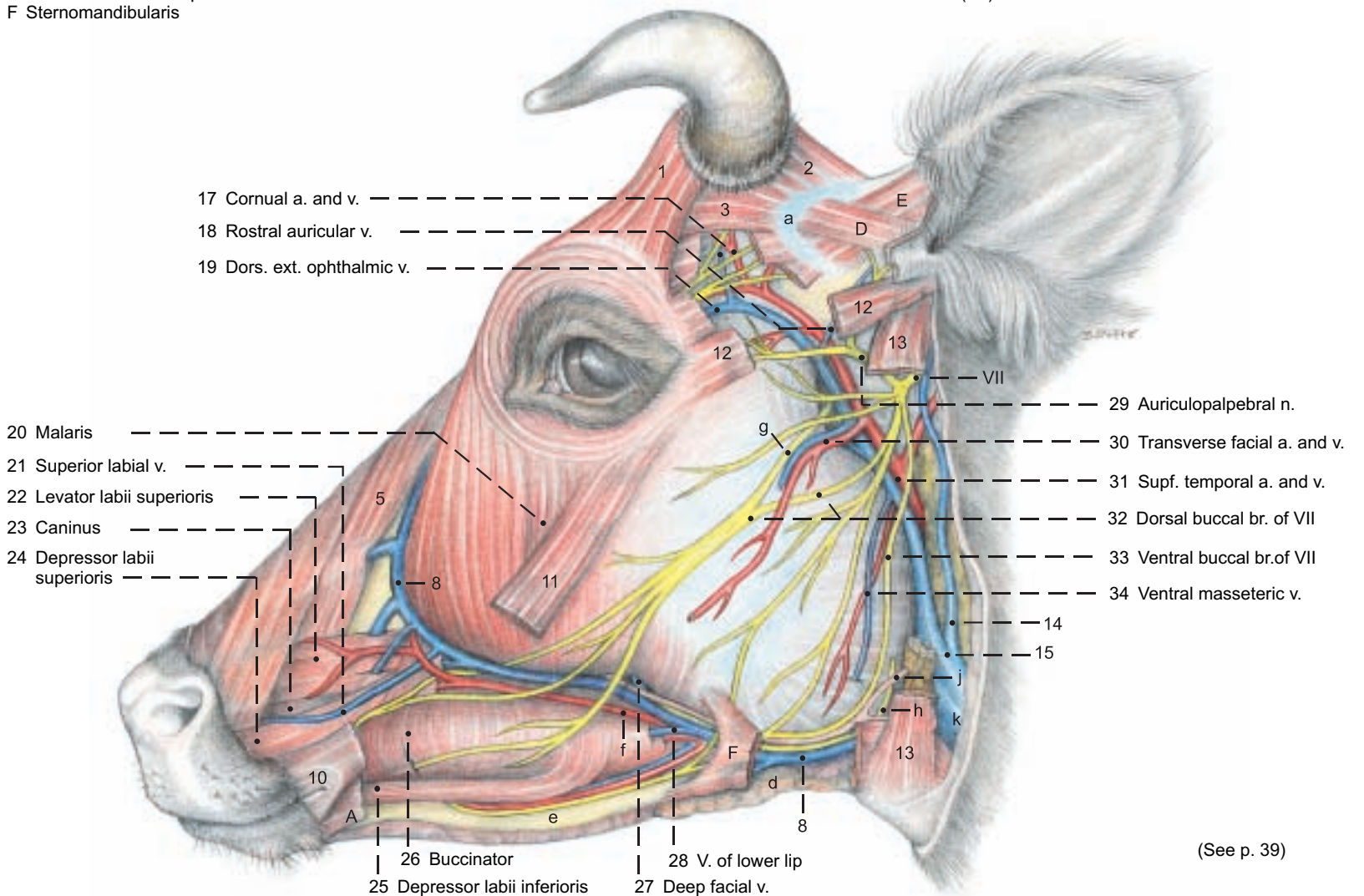
Legend:

A Cutaneous faciei
 B Zygomaticoscutularis
 C Frontoscutularis
 D Scutoloauricularis supf. dors.
 E Scutoloauricularis supf. accessorius
 F Sternomandibularis

a Scutiform cartilage
 b Parotid ln.
 c Parotid gl.
 d Mandibular gl.

e Mandible
 f Facial a.
 g Communicating br. between auriculotemporal n. (V3) and dorsal buccal br. (VII)

h Parotid br. of buccal n. (V3)
 j Parotid duct
 k External jugular v.



(See p. 39)

5. TRIGEMINAL N. (V3 AND V2), MASTICATORY MM., SALIVARY GLL., AND LYMPHATIC SYSTEM

For the dissection of the temporalis and masseter the covering facial muscles and superficial nerves and vessels are removed. The masseter is removed in layers, showing its tough tendinous laminae, its almost horizontal and oblique fiber directions and its innervation by the masseteric n. (V3) passing through the mandibular notch. Medial to the masseter is the large **deep facial venous plexus** (2). To remove the zygomatic arch three sagittal cuts are made: I. at the temporomandib. joint, II. through the zygomatic bone rostral to its frontal and temporal processes, and III. through the zygomatic process of the frontal bone. In the course of disarticulation of the temporomandib. joint the temporalis is separated from its termination on the coronoid proc., whereby its innervation from the deep temporal nn. is demonstrated. The mandible is sawed through rostral to the first cheek tooth. After severing all structures attached to the medial surface of the mandible, the temporomandib. joint is disarticulated by strong lateral displacement of the mandible while the joint capsule is cut. The fibrocartilaginous **articular disc** compensates for the incongruence of the articular surfaces.

a) The **TRIGEMINAL N. (V)** of the ox exhibits no marked differences in its branches from that of the dog and horse.

I. The **mandibular n. (V3)** is sensory to the teeth, oral mucosa, and skin of the lower jaw, as well as the tongue, parotid gl., and part of the ear. Unlike the other divisions of the trigeminal n. (V1 and V2) it also has somatic motor components. These are in the following branches: the **masticatory n. (20)** divides into the **deep temporal nn. (18)** and **masseteric n. (19)** which innervate the corresponding muscles. Branches to the pterygoids, tensor tympani, and tensor veli palatini have corresponding names. The inferior alveolar n. gives off, before entering the mandibular foramen, the **mylohyoid n. (29)** for the muscle of that name and for the rostral belly of the digastricus, and sends cutaneous branches to the rostral part of the intermandibular region. The following branches of the mandibular n. have no somatic motor components: The **many-branched buccal n. (4)** conducts sensory fibers and receives parasympathetic fibers from the glossopharyngeal n. (IX) via the **large oval** otic ganglion to the oral mucosa and the buccal salivary glands. Its **parotid br. (16)**, which occurs only in ruminants, turns around the rostral border of the masseter and runs back to the parotid gland close to the duct. The **auriculotemporal n. (26)** turns caudally to the ear, skin of the temporal region, and parotid gland, supplying sensory branches and parasympathetic innervation (from IX via the otic ganglion). The nerve then turns rostrally and joins the dorsal buccal br. of VII as the **communicating br. with the facial n. (1)** thereby supplying sensation to the skin of the cheek. The **lingual n. (30)** is sensory to the sublingual mucosa and tongue. From the **chorda tympani (VII —27)** it receives taste fibers for the rostral 2/3 of the tongue, and parasympathetic fibers for the sublingual and mandibular glands. Its **sublingual n. (33)** runs as in the dog but not as in the horse, on the lat. surface of the sublingual gll. to the floor of the mouth. The sensory **inferior alveolar n. (28)** passes through the **mandibular foramen** to the mandibular canal. It supplies the lower teeth and after emerging from the mental foramen as the **mental n. (5)** it supplies the skin and mucosa of the lower lip and chin.

II. The **maxillary n. (V2—21)** is sensory and contains parasympathetic components from VII via the pterygopalatine ganglion. It gives off the zygomatic n. and the pterygopalatine n. with the major palatine, minor palatine, and caudal nasal nn. Its rostral continuation is the **infraorbital n. (6)** which gives off sensory brs. in the infraorbital canal for the upper teeth, and after emerging from the foramen divides into numerous branches for the dorsum nasi, nostril, planum nasolabiale, upper lip, and the nasal vestibule. (For the ophthalmic n., V1, see p. 40.)

b) The **MASTICATORY MM. INCLUDING THE SUPERFICIAL INTERMANDIBULAR MM.** are innervated by the mandibular n. (V3). The caudal belly of the digastricus is innervated by the facial n. (VII). Of the **external masticatory mm.**, as in the horse, the **masseter (13)** is larger than the temporalis (17), and, covered by a glistening aponeurosis, presents a superficial layer with almost horizontal muscle fibers, and a deep layer with caudoventral fiber direction. The **internal masticatory mm.**: the **medial pterygoid (22)** and the **lateral pterygoid (22)**, are clearly separate. The **superficial intermandibular mm.** are the **mylohyoideus (25)** **digastricus (31)**. There is no **occipitomandibularis** in the ox. The digastricus, which does not perforate the stylohyoideus, terminates rostral to the vascular groove on the medial surface of the ventral border of the mandible. Right and left digastrici are connected ventral to the lingual process of the basihyoid by transverse muscle fibers.

c) The **LARGE SALIVARY GLANDS** are the parotid, mandibular, monostomatic sublingual, and polystomatic sublingual gll.

I. The **parotid gland (14, p. 37, c)** is elongated and thick. It lies along the caudal border of the masseter from the zygomatic arch to the

angle of the mandible. Numerous excretory ducts converge to the **parotid duct (15)** at the ventral end of the gland. *The duct runs with the facial vessels from medial to lateral through the vascular groove in the ventral border of the mandible*, ascends in the groove along the rostral border of the masseter, and enters the oral vestibule opposite the fifth upper cheek tooth (M2). The deep surface of the gland is related to the maxillary and linguofacial vv., the end of the ext. carotid a., the mandibular gl., and the parotid ln. The facial n. with the origin of its buccal branches is enveloped by the parotid gland.

II. The **mandibular gland (9)** is curved, lying medial to the angle of the mandible and extending from the paracondylar process to the basihyoid. *Its enlarged bulbous end is palpable in the intermandibular region, where it is in contact with the contralateral gland.* The deep surface is related to the lat. retropharyngeal ln., common carotid a., pharynx, and larynx. The **mandibular duct (32)** leaves the middle of the concave border of the gland and courses deep to the mylohyoideus and dorsal to the monostomatic sublingual gl. to the sublingual caruncle on the floor of the oral cavity rostral to the frenulum of the tongue.

III. The **monostomatic sublingual gl. (24)** is about 10 cm long. Its **major sublingual duct** ends near the mandibular duct under the sublingual caruncle.

IV. The **polystomatic sublingual gl. (23)** extends in a chain of lobules from the palatoglossal arch to the incisive part of the mandible. The microscopic sublingual ducts open under the tongue on each side of a row of conical papillae extending caudally from the sublingual caruncle.

The **small salivary glands:**

The **buccal gll.** are developed best in the ox.

The superficial layer of the **dorsal buccal gll. (3)** is on the surface of the buccinator. The deep layer is covered by the muscle. They extend from the angle of the mouth to the facial tuber and are covered caudally by the masseter. *The middle buccal gll. (7) are found in ruminants between two layers of the buccinator and dorsal to the vein of the lower lip.* The **ventral buccal gll. (8)** lie on the mandible from the angle of the mouth to the rostral border of the masseter. They are ventral to the vein of the lower lip and covered, except the caudal part, by the buccinator. Small salivary gll. are present throughout the oral mucosa. Total secretion of saliva in the ox is about 50 liters in 24 hours.*

d) The **LYMPHATIC SYSTEM.** *Ruminant lymph nodes differ from those of the horse; they are usually single large nodes rather than groups of small nodes. All of the following nodes are routinely incised in meat inspection.* The **parotid ln. (12)** lies between the rostral border of the parotid gl. and the masseter, ventral to the temporomandibular joint. It is palpable in the live animal. The **mandibular ln. (10)** lies ventral to the mandible, halfway between the rostral border of the masseter and the angle of the mandible, in contact with the facial vein. It is covered laterally by the sternomandibularis and the facial cutaneous m., but is palpable in the live animal; it is lateral to the bulbous ventral end of the mandibular gl., which is in contact with the contralateral gl. and should not be mistaken for the mandibular ln.

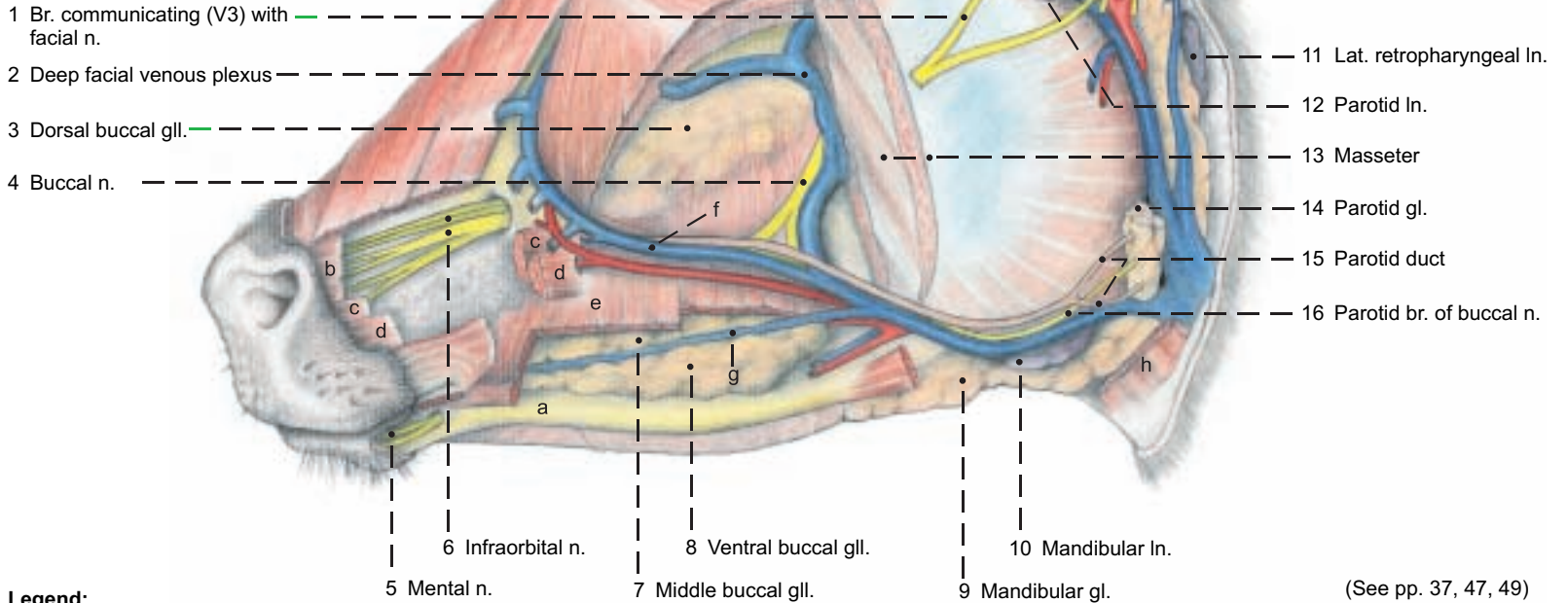
The **medial retropharyngeal ln.** is in the fat between the caudodorsal wall of the pharynx, through which it can be palpated, and the longus capitis. Its lateral surface is related to the large (1.5 x 0.5 cm) **cranial cervical ganglion** and cranial nn. IX to XII.

The **lateral retropharyngeal ln. (11)** receives all of the lymph from the other lymph nodes of the head and is drained by the tracheal trunk. It lies in the fossa between the wing of the atlas and the mandible, covered laterally by the mandibular gland.

Mandibular n. (V3), Maxillary n. (V2), and Salivary glands

Legend:

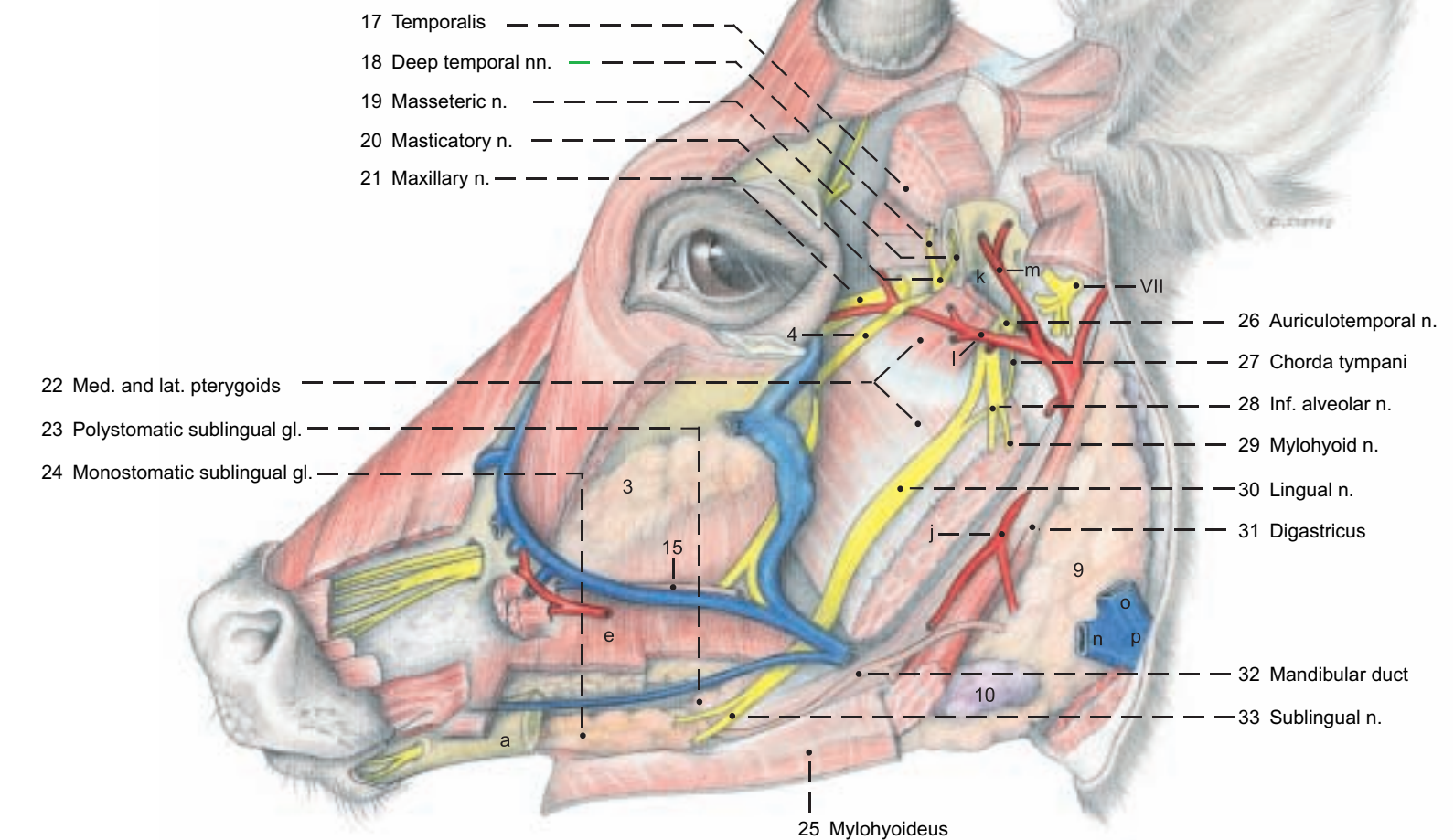
- a Mandible
- b Levator labii superioris
- c Caninus
- d Depressor labii superioris
- e Buccinator
- f Facial vein
- g Vein of lower lip
- h Sternomandibularis



Legend:

- j Linguofacial trunk
- k Articular disc
- l Maxillary a.
- m Supf. temporal a.
- n Linguofacial v.
- o Maxillary v.
- p Ext. jugular v.

(See pp. 37, 47, 49)



6. ACCESSORY ORGANS OF THE EYE

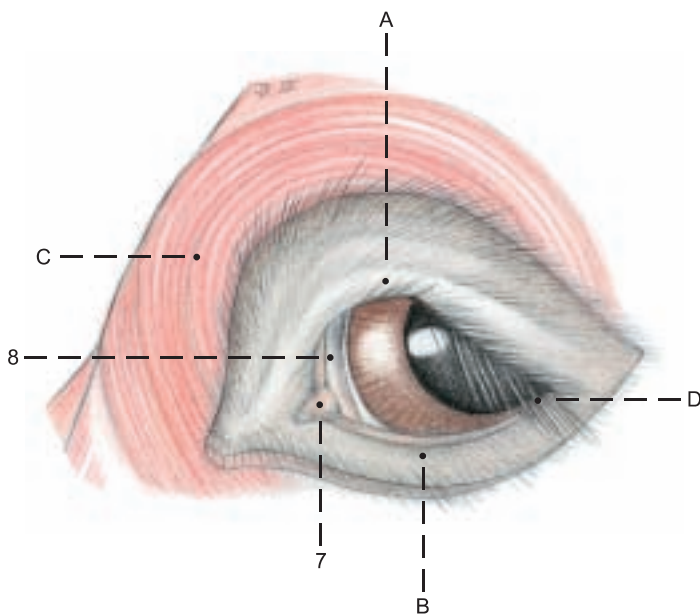
The **ACCESSORY ORGANS** include the eyelids and conjunctiva, the lacrimal apparatus, and the cone of striated bulbar muscles with their fasciae and nerves. They will be described in the order in which they are exposed (see also the text figure and p. 43).

I. The **upper and lower eyelids** (*palpebra superior*, **A**, and *inferior*, **B**) consist of an outer layer of haired skin, a middle fibromuscular layer, and the palpebral conjunctiva. The fibrous part of the middle layer is attached to the osseous orbital margin and increases in density toward the free border to form the **tarsus**, which contains the **tarsal glands**.

The **eyelashes** (*cilia*, **D**) of the lower lid are fewer and shorter than those of the upper lid, but they are present in the ox.

The striated muscles are: the strong **orbicularis oculi** (**C**), and in the upper eyelid, the termination of the **levator palpebrae superioris** (**13**) and *fibers of the frontalis*. The upper and lower **tarsal mm.** are parts of the smooth muscle system of the orbit, which retracts the eyelids and protrudes the eyeball under sympathetic stimulation. The **palpebral conjunctiva** (**10**) is continuous at the **fornix** (**11**) with the **bulbar conjunctiva** (**12**), which ends at the **limbus of the cornea**.

The **third eyelid** (**8**) consists of a fold of conjunctiva in the medial angle, enclosing the T-shaped outer end of the **cartilage of the third eyelid**.



The deep part of the cartilage is surrounded by the **gland of the third eyelid**, *larger than in the horse*, extending about 5 cm straight back into the fat medial to the eyeball and discharging tears through orifices on the bulbar side of the third lid.

II. The **lacrimal apparatus**. The **lacrimal gl.** (**9**) lies in the dorsolateral quadrant of the orbit, with the *broad dorsal part* under the root of the zygomatic proc., and a *long thin tail* which extends around the lateral margin of the orbit.

The lacrimal ducts pass from the ventral end of the gland to orifices in the lateral fornix. The gland of the third eyelid is the largest accessory lacrimal gland. The tears collect around the **lacrimal caruncle** (**7**) in the **lacrimal lake** in the medial angle anterior to the third eyelid. They are drained through the **upper** (**5**) and **lower** (**6**) **lacrimal puncta** and **lacrimal canaliculi** (**4**) which join at the **lacrimal sac** (**3**). This is drained by the **nasolacrimal duct** (**2**) to the **nasolacrimal orifice** (**1**) *concealed on the medioventral surface of the alar fold*.

III. The **bulbar muscles** are surrounded by the **periorbita** which, in the osseous part of the orbit, is the periosteum, containing the **trochlea** (**19**), but caudolaterally where the bony orbit is deficient in domestic mammals, the periorbita alone forms the wall of the orbit. It is a tough, fibrous, partially elastic membrane stretched from the lateral margin of the orbit to the **pterygoid crest**. The lacrimal gland and the levator palpebrae superioris are covered only by the periorbita. The remaining structures are also enveloped in the **deep orbital fasciae**: the **fasciae of the muscles** and the **bulbar fascia** (*vagina bulbi*).

The **ophthalmic n.** (**V 1**) (see p. 53) divides while still in the for. orbitorotundum into the following three nerves:

1. The usually double **lacrimal n.** runs along the lateral surface of the lateral rectus and gives off branches to the lacrimal gl. and the upper eyelid. *The two strands of the lacrimal n. then unite and the zygomaticotemporal br. so formed* perforates the periorbita and turns caudally under the zygomatic proc. of the frontal bone to the temporal region, where it sends twigs to the skin and *continues ventral to the temporal line as the cornual branch to the skin on the cornual process*.

2. The **frontal n.** gives rise to the **nerve to the frontal sinuses**, which perforates the wall of the orbit. The frontal n. then passes around the dorsal margin of the orbit (unlike that of the horse) and becomes the **supraorbital n.** to the frontal region.

3. The **nasociliary n.** gives off the **long ciliary nn.**, which penetrate the sclera and supply sensation to the vascular tunic (see p. 42) and cornea; the **ethmoidal n.**, with sensory and autonomic fibers to the caudal nasal mucosa; and the **infratrochlear n.** The last turns around the mediodorsal margin of the orbit to the skin of the medial angle of the eye and the frontal region.

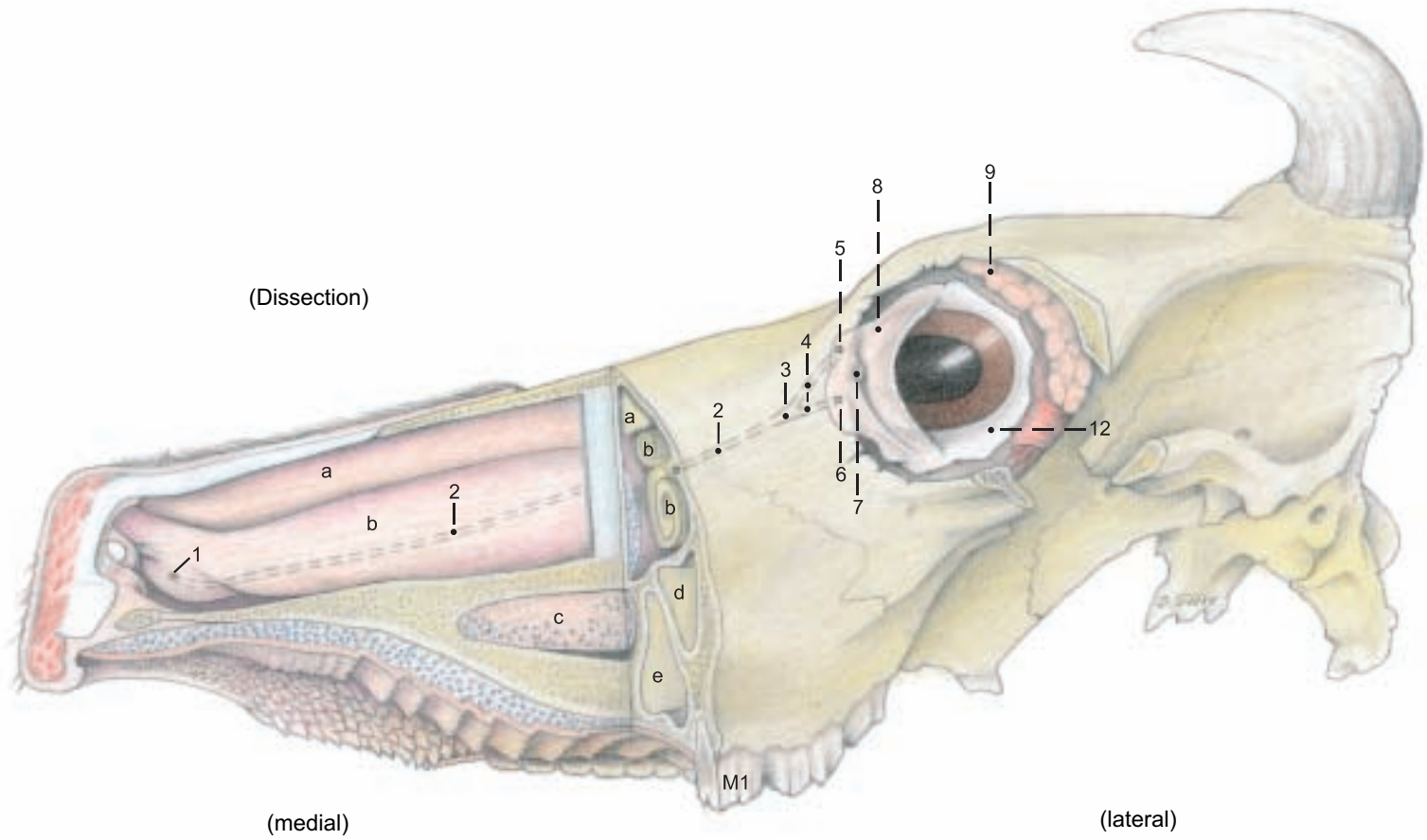
Almost all of the striated bulbar muscles: **dorsal** (**16**), **medial** (**14**), and **ventral** (**17**) **recti**; **ventral oblique** (**20**), **levator palpebrae sup.** (**13**), and **retractor bulbi** (**21**), except its lateral part, are innervated by the **oculomotor n.** (**III**).

Only the **dorsal oblique** (**18**) is innervated by the **trochlear n.** (**IV**).

The **lateral rectus** (**15**) and the **lateral part of the retractor bulbi** (**21**) are served by the **abducent n.** (**VI**).

The bulbar muscles originate around the optic canal, with the exception of the ventral oblique, which comes from a fossa on the medial wall of the orbit just above the lacrimal bulla. With the exception of the levator palpebrae sup. all of the bulbar muscles terminate on the sclera.

Lacrimal apparatus



(See pp. 45, 47)

Legend:

- 1 Nasolacrimal orifice
- 2 Nasolacrimal duct
- 3 Lacrimal sac

- 4 Lacrimal canaliculi
- 5 Superior lacrimal punctum
- 6 Inferior lacrimal punctum

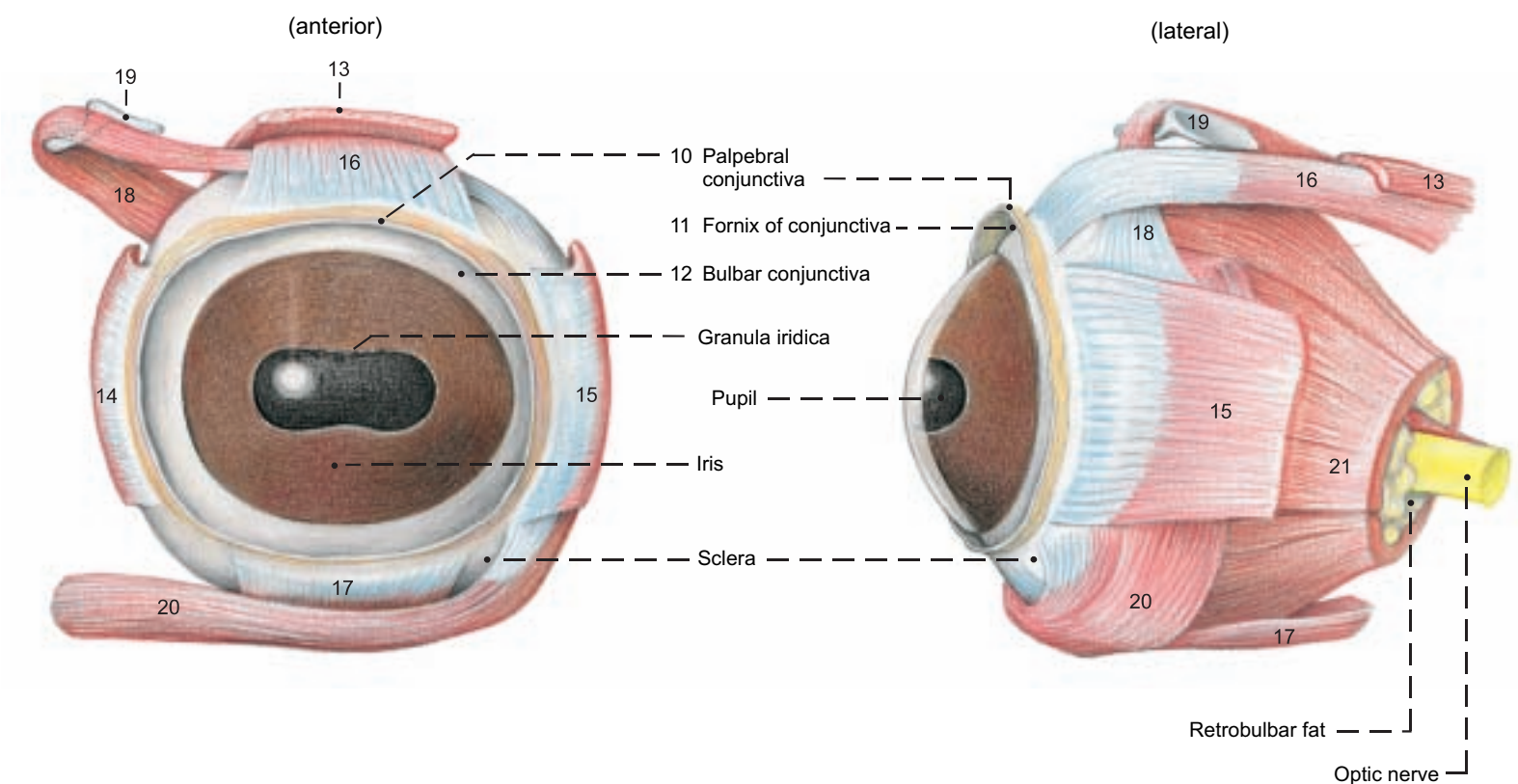
- 7 Lacrimal caruncle
- 8 Third eyelid
- 9 Lacrimal gland

Legend:

- a Dorsal nasal concha
- b Ventral nasal concha
- c Venous plexus

- d Maxillary sinus
- e Palatine sinus

Bulbar muscles (Left eye)



Legend:

- 13 Levator palpebrae superioris
- 14 Medial rectus

- 15 Lateral rectus
- 16 Dorsal rectus

- 17 Ventral rectus
- 18 Dorsal oblique

- 19 Trochlea
- 20 Ventral oblique

- 21 Retractor bulbi

7. THE EYEBALL (BULBUS OCULI)

The eyeball of the ox is smaller than that of the horse, and is not flattened so much anteroposteriorly. For orientation, the pupil and the optic nerve are taken as reference points. The pupil is at the anterior pole, and the optic n. is below and slightly lateral to the posterior pole. Like other ungulates, the ox has a transversely elliptical pupil (5). When it dilates, it becomes round. The black projections (**granula iridica**, 5) on the upper and lower margins of the pupil are vascular appendages covered by pigmented epithelium from the back of the iris. Those on the lower margin are small. On eyeballs sectioned on the equator and meridionally, one can study the external (fibrous) tunic, the middle (vascular) tunic, and the internal tunic (retina).

I. The **fibrous tunic** comprises the **sclera** (1), enclosing the greater part of the bulb in its dense white connective tissue, and the transparent **cornea** (3). These parts join at the **corneal limbus** (2).

II. The **vascular tunic** consists of the choroid, ciliary body, and iris.

The **choroid** (15) is highly vascular and pigmented. In its posterior part, just above the optic disc, is the blue-green, reflective **tapetum lucidum** (16), a fibrous structure of roughly semicircular outline with a horizontal base.

The **ciliary body**, containing the weak **ciliary m.** (J), is the anterior continuation of the choroid. Its most prominent feature is the **ciliary crown** (**corona ciliaris**, 10), composed of vascular, radial **ciliary processes** (10), from which the **zonular fibers** (9) extend to the equator of the lens. Posterior to the ciliary processes is the **ciliary ring** (**orbiculus ciliaris**, 11), a zone bearing minute **ciliary folds** (11). It is narrower medially than elsewhere. The posterior epithelium is the pars ciliaris retinae.

Between the ciliary body and the pupil is the **iris** (4) with the **sphincter** (G) and **dilator** (H) mm. of the pupil. The bovine iris is dark because of the heavy pigmentation of the posterior epithelium (pars iridica retinae).

III. The **retina** lines the entire vascular coat, so that each part of the vascular coat has a double inner layer derived from the two-layered ectodermal optic cup of the embryo. The greater part of the retina is the **optical part** (12), extending from the **optic disc** (20) to the ciliary body at the **ora serrata** (13). It contains the visual elements in its **nervous layer** and has an outer **pigmented layer**, which adheres to the vascular tunic when the nervous layer is detached. The outer layer is free of pigment over the tapetum.

The **blind part** (**pars caeca**, 14) of the retina lines the iris and ciliary body. In the **iridial part** the outer layer contributes the sphincter and dilator mm., and the inner layer is pigmented; in the **ciliary part**, the outer layer is pigmented.

At the **optic disc** (20) the nerve fibers of the retina exit through the **area cribrosa** of the sclera, acquire a myelin sheath, but no neurolemma, and form the **optic n.** (17), which is morphologically a tract of the brain, covered by a thin **internal sheath** (18) corresponding to the pia mater and arachnoidea, and a thick **external sheath** (19) corresponding to the dura mater.

IV. The **lens** (6) is surrounded by the elastic **lens capsule** (j), which is connected to the ciliary body by the zonular fibers. Under the capsule, the anterior surface of the lens is covered by the lens epithelium. Toward the **equator** (k) the epithelial cells elongate to form the lens fibers—the substance of the lens. The fibers, held together by an amorphous cement, meet on the anterior and posterior surfaces of the lens in three sutures (**radii lentis**), which are joined to form a Y (the lens star), best seen in the fresh state.

V. Inside the eyeball the anterior and posterior chambers lie before the lens and the vitreous body lies behind it. The **anterior chamber** (7) is between the cornea and iris. It communicates freely through the pupil with the **posterior chamber** (8) which is between the iris and the lens with its zonula. Viewed from the anterior chamber the circular **pectinate ligament** (h) is seen in the **iridocorneal angle** (g), attaching the iris by delicate radial trabeculae to the **scleral ring** at the corneal limbus. Between these trabeculae are the **spaces of the iridocorneal angle** (of Fontana), through which the **aqueous humor** drains to the circular **venous plexus of the sclera** (42).

The **vitreous chamber** (22) lies between the lens and the retina, and is filled by the vitreous body. Its stroma is a network that holds in its meshes a cell-free jelly, the water content of which determines the intraocular pressure.

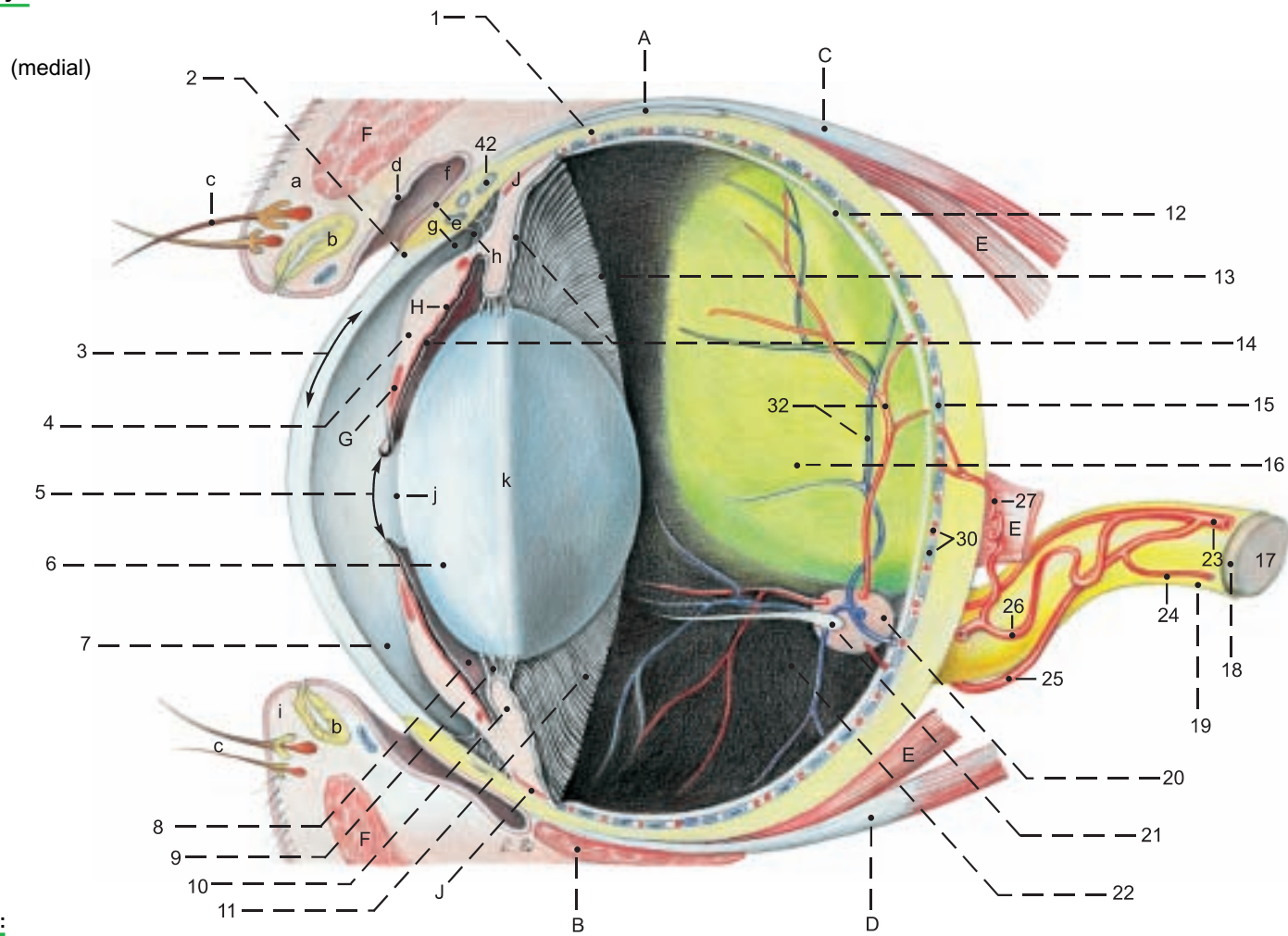
VI. The **blood supply** of the eye comes from the int. and ext. ophthalmic aa. and the malar a. The small **int. ophthalmic a.** (24) comes from the **rostral epidural rete mirabile** (see p. 50), accompanies the optic n., and anastomoses with the ext. ophthalmic a. and the post. ciliary aa. The **ext. ophthalmic a.** (23), from the maxillary a., forms the **ophthalmic rete mirabile deep in the orbit on the ventral surface of the dorsal rectus**. The **supraorbital a.** arises from the rete, gives off in the orbit the **ext. ethmoidal a.** and **ant. conjunctival aa.**, and enters the supraorbital canal, supplying the frontal sinus and emerging to supply the frontalis m. and skin. Also arising from the rete are the **muscular br.** (28) and the **lacrimal a.** The muscular br. supply the eye muscles and give off **ant. ciliary aa.** (33) and **posterior conjunctival aa.** (35). The ext. ophthalmic a. divides into two **long post. ciliary aa.** (25, 26), which give off **short post. ciliary aa.** (27) near the eyeball, and continue to the equator of the eyeball before they enter the sclera. In the ciliary region of the iris they form the **major arterial circle of the iris** (36). Near the bulbar end of the optic n. the long post. ciliary aa. supply small **choroidoretinal aa.** (31), which accompany the optic n. and supply the **four retinal arteries seen with the ophthalmoscope in the fundus of the eye**. Accompanied by the corresponding veins, they appear near the center of the disc and spread out over the interior of the retina in a pattern characteristic of the ox, with the largest vessels directed dorsally. The venous blood of the eyeball is drained through the **vorticose vv.** (38–41), **ciliary vv.** (27–33), and the **choroidoretinal vv.** (31) to the intraorbital ophthalmic venous plexus.

Legend: (See figures on p. 43)

23 Ext. ophthalmic a.	33 Ant. ciliary a. and v.	Muscles of the eye:	a Upper eyelid (palpebra superior)
24 Int. ophthalmic a.	34 Aa. and vv. of ciliary body	A Dorsal oblique	b Tarsal gll.
25 Lat. long post. ciliary a.	35 Post. conjunctival a. and conjunctival v.	B Ventral oblique	c Eyelashes (cilia)
26 Med. long post. ciliary a.	36 Major arterial circle of the iris	C Dorsal rectus	d Palpebral conjunctiva
27 Short post. ciliary a., and post. ciliary v.	37 Aa. and vv. of the iris	D Ventral rectus	e Bulbar conjunctiva
28 Muscular br.	38 Lat. dorsal vorticose v.	E Retractor bulbi	f Fornix of conjunctiva
29 Episcleral a.	39 Lat. ventral vorticose v.	F Orbicularis oculi	g Iridocorneal angle
30 Choroid aa. and vv.	40 Med. dorsal vorticose v.	G Sphincter pupillae	h Pectinate lig.
31 Choroidoretinal a. and v.	41 Med. ventral vorticose v.	H Dilator pupillae	i Lower eyelid (palpebra inferior)
32 Retinal arteries and veins	42 Venous plexus of the sclera	J Ciliaris	j Lens capsule
			k Equator of lens

Organ of vision

Right eye



Legend:

Fibrous tunic:

- 1 Sclera
- 2 Limbus of cornea
- 3 Cornea
- 4 Iris
- 5 Pupil with granula iridica

6 Lens

- 7 Anterior chamber
- 8 Posterior chamber
- 9 Zonular fibers
- Ciliary body:
 - 10 Ciliary crown and ciliary processes
 - 11 Ciliary ring (orbiculus ciliaris) and ciliary folds

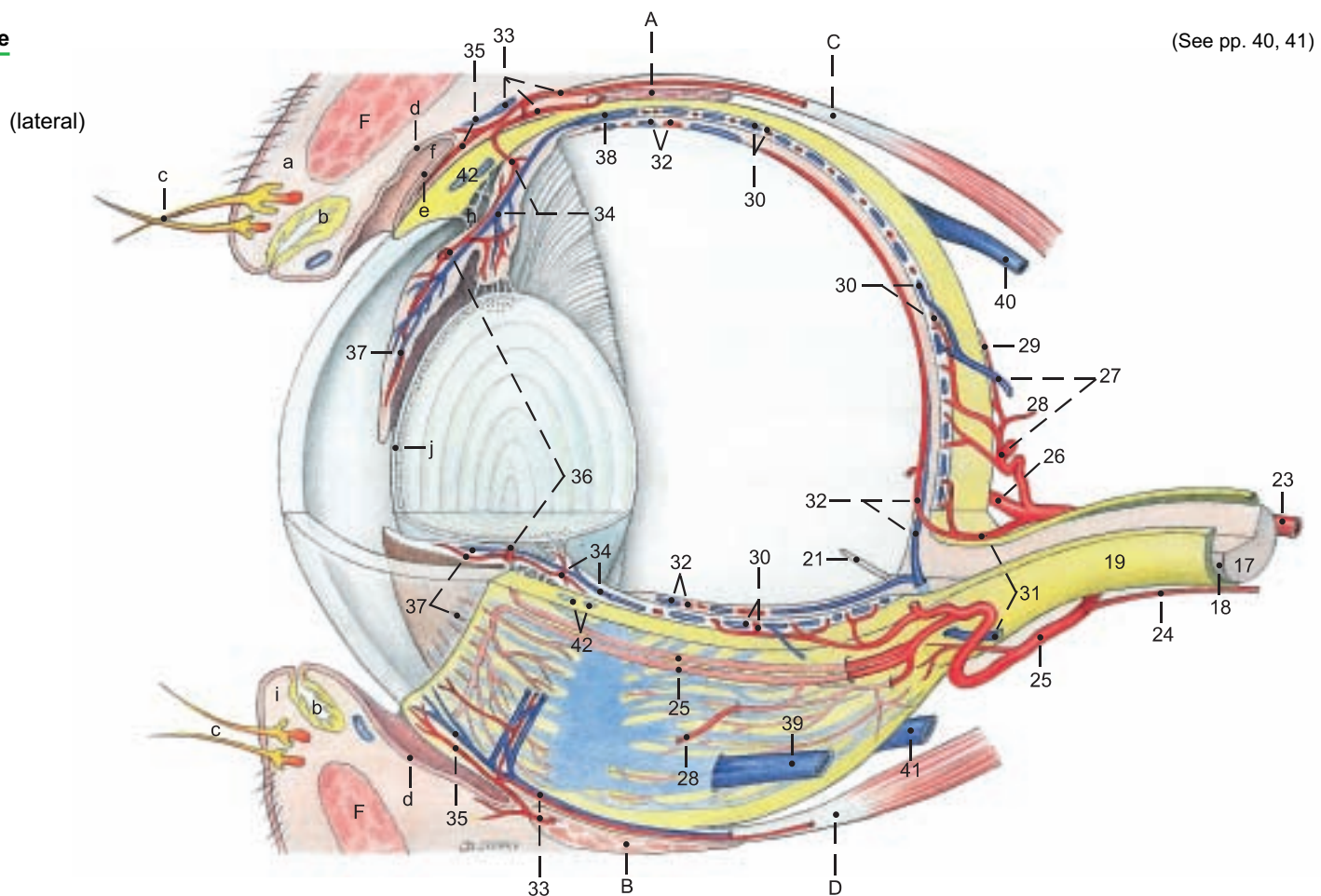
Retina:

- 12 Optical part of retina
- 13 Ora serrata
- 14 Blind part of retina (pars ceca)
- 15 Choroid
- 16 Tapetum lucidum

17 Optic n.

- 18 Internal sheath of optic n.
- 19 External sheath of optic n.
- 20 Optic disc
- 21 Hyaloid process
- 22 Vitreous chamber

Left eye



8. NOSE AND NASAL CAVITIES, ORAL CAVITY

The nasal septum is removed to expose the nasal cavity.

a) NOSE.

I. The end of the nose and the upper lip are covered by hairless skin—the **planum nasolabiale** (22), where the skin is marked by minute grooves and raised areas with the openings of **serous nasolabial glands**. Incision reveals a thick layer of glandular tissue. The **nostril** (23) is rounded medioventrally and extends dorsolaterally as the **alar groove** (24) between the lateral border of the nostril and the wing of the nose (**ala nasi**, 24). The wing is med. in the horse, dorsomed. in ruminants, and lat. in man and dog. In the ox it is held up by the rostral part of the **dorsal lat. nasal cartilage** (26). The **alar cartilage** and **nasal diverticulum** of the horse are absent in the ox. The ventrolateral border of the nostril is supported by the **lateral accessory nasal cartilage** (27), attached to the dorsal lateral nasal cartilage. In addition, a **medial accessory nasal cartilage** (25) and a **ventral lateral nasal cartilage** (28) are present.

II. Each **nasal cavity** begins with the **vestibule** (12), a narrow zone of hairless skin and stratified squamous epithelium. The rest of the nasal cavity is lined by respiratory epithelium, except the olfactory region in the caudal part. The **dorsal concha** (5) is between the **dorsal** (4) and **middle** (6) **meatuses**. The caudal part of the middle meatus is divided into dorsal and ventral channels by the **middle concha** (2). The **ventral concha** (7) is between the middle and **ventral** (8) **meatuses**. The **common meatus** (3) is next to the nasal septum and connects the other three meatuses. Because the vomer is not attached to the caudal half of the hard palate, the right and left **ventral meatuses** communicate caudal to the plane of the second cheek tooth. The ventral concha is continued rostrally by the **alar fold** (11) to the wing of the nose. The **nasolacrimal orifice** (10) is just caudal to the mucocutaneous border, concealed on the medioventral surface of the alar fold, but in the live ox the wing can be drawn dorsolaterally to cannulate the nasolacrimal duct. The **basal fold** (13) extends from the floor of the ventral meatus to the alar fold. The ventral meatus is the only one through which a stomach tube can be passed. The dorsal nasal concha is connected to the nostril by the **straight fold** (9). **Cavernous venous plexuses** (29) are present in the three nasal folds, in the conchae, and on the sides of the vomer and ventral border of the **nasal septum**. In aged cattle the rostral end of the nasal septum is ossified. A nasal concha is the whole shell-like structure, including the inner and outer mucous membranes, the submucosa containing cavernous venous plexuses, and the middle lamina, or **os conchae**, of thin, partly cribriform, bone. The caudal part of the nasal cavity, lined by olfactory epithelium, contains the **ethmoid conchae** (1), which include the **middle concha** (2). The bones of the ethmoid conchae are called **turbinates**. The caudal part of the ventral concha encloses a single cavity—the **ventral conchal sinus** (h). The rostral part forms **dorsal and ventral**

scrolls (7) which enclose several smaller cavities (h'). The **dorsal concha** forms a single **dorsal conchal sinus** (f).

The **incisive duct** runs rostroventrally from the floor of the nasal cavity through the palatine fissure to open into the mouth at the **incisive papilla** just caudal to the dental pad (a).

The **vomer** lies on the floor of the nasal cavity lateral to the nasal septum. Its duct opens into the incisive duct within the hard palate, and its caudal end is rostral to the first cheek tooth.

The **lateral nasal gland** is absent in the ox. (See the paranasal sinuses, p. 34.)

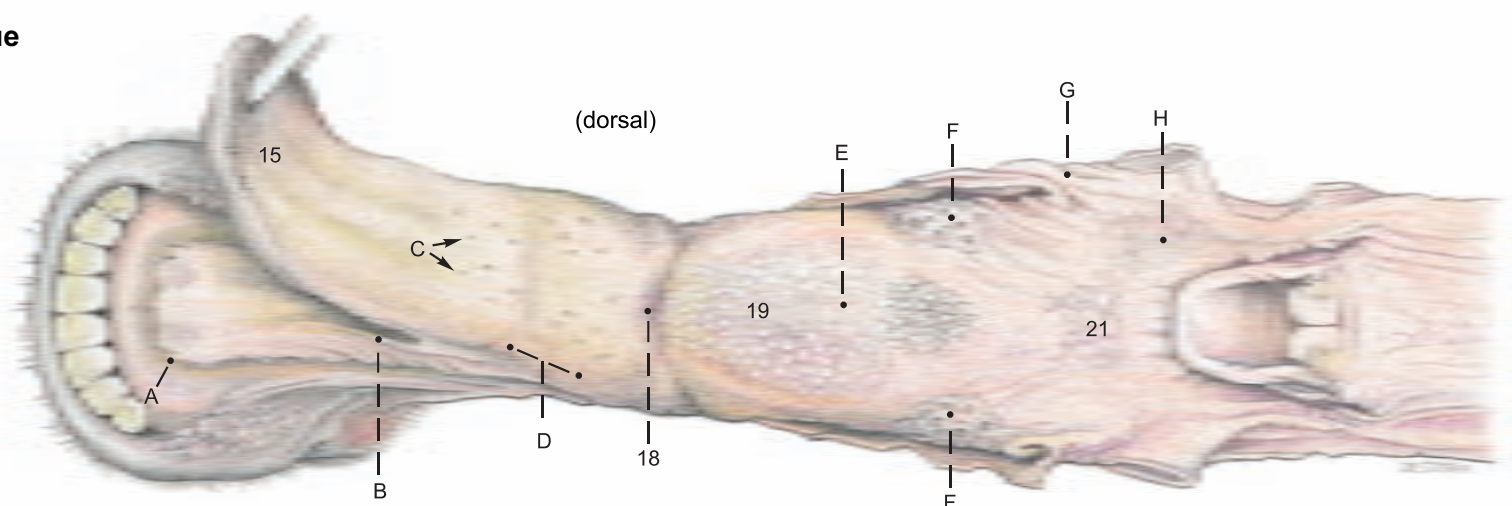
b) ORAL CAVITY.

The **lips** are not so mobile and selective as in the horse; they accept nails and pieces of fence wire that cause **traumatic reticulitis**. Near the angle of the mouth the **cornified labial papillae** (b) become long and sharp and directed caudally like the **buccal papillae** (b) inside the cheek. Together they serve to retain the cud during the wide lateral jaw movements of rumination. The **oral vestibule** (14) is the space between the teeth and the lips and cheeks. The **oral cavity proper** (17) is enclosed by the teeth and **dental pad** (a) (see also p. 32), except at the diastema and at the palatoglossal arches, where it opens into the pharynx. On the rostral two-thirds of the **hard palate** (c, d, 16) are the transverse **palatine ridges** (16) whose raised caudal borders bear a row of minute caudally directed spines. The **palatine venous plexus** (c) is thickest between the premolars and just rostral to them. Attached to the floor of the oral cavity (see text figure) is the broad, **double frenulum of the tongue** (B). Rostrolateral to the frenulum is the large, flat **sublingual caruncle** (A), which conceals the orifices of the ducts of the mandibular gl. and the monostomatic sublingual gl. Caudal to the caruncle on each side is a row of conical papillae. Med. and lat. to the papillae are the minute orifices of the polystomatic sublingual gl. (p. 38).

c) TONGUE.

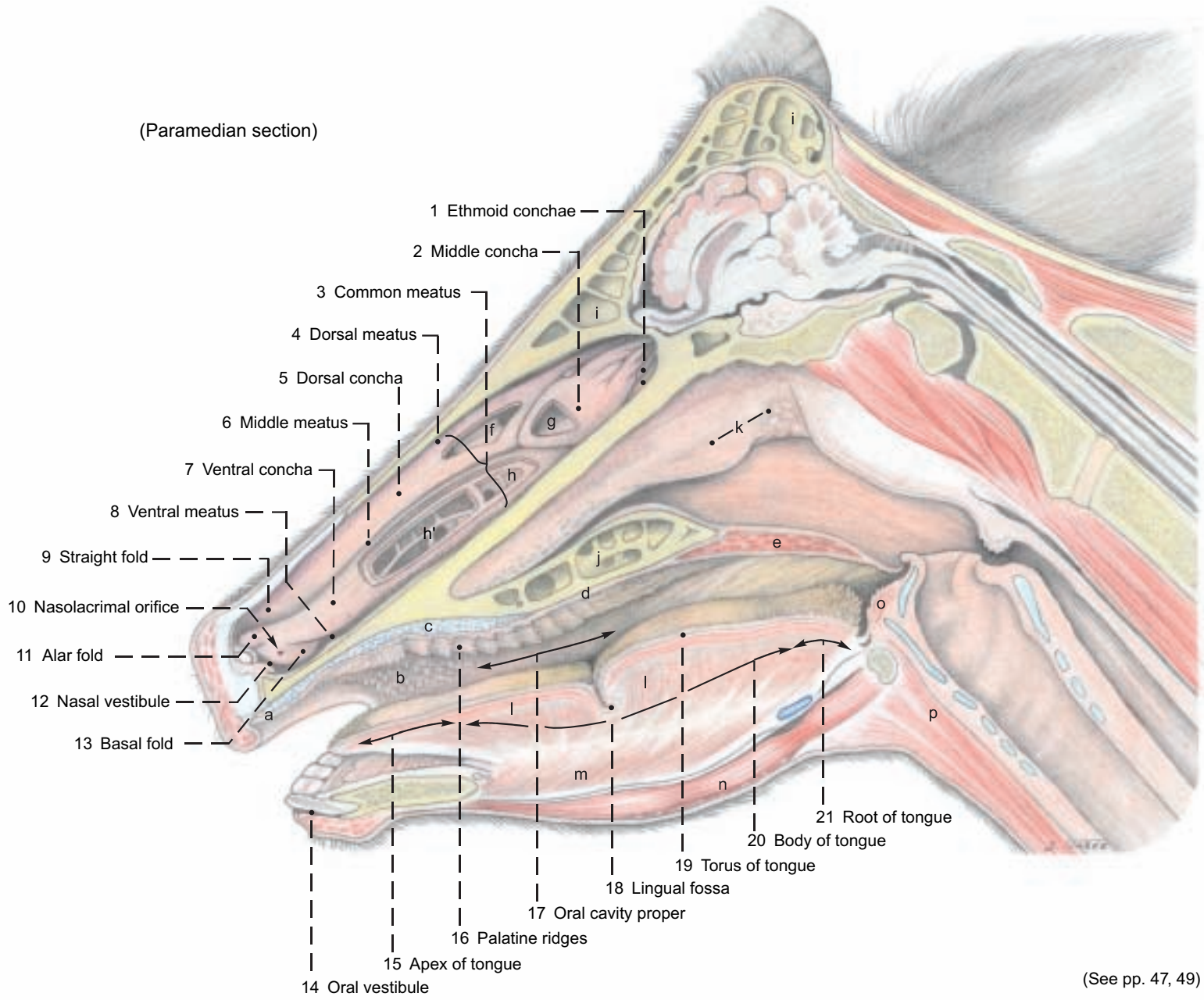
The **dorsal surface** (**dorsum linguae**) is divided by the **transverse lingual fossa** (18) into a flat apical part and a high, rounded **torus linguae** (19). The tip (**apex**, 15) of the tongue is pointed. The apical half of the tongue is covered on the dorsum and margin by fine, sharp **filiform papillae** (D) directed backward and adapted to the use of the tongue as an organ of prehension in grazing. Scattered among the filiform papillae are round **fungiform papillae** (C), which bear taste buds, as do the **vallate papillae** (F). The latter form an irregular double row of about twelve on each side of the caudal part of the torus, which is covered by large **conical and lentiform papillae** (E). **Foliate papillae** are absent. The **palatoglossal arches** (lat. to G) are attached to the sides of the root of the tongue (21). On the root and on both sides of the **median glossoepiglottic fold** are many small orifices of the crypts of the **lingual tonsil** (H) and its glands.

Tongue



Nasal cavity, Oral cavity, and External nose

(Paramedian section)

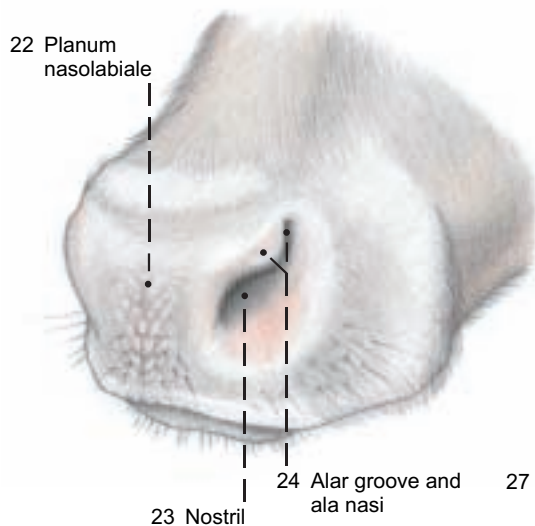


(See pp. 47, 49)

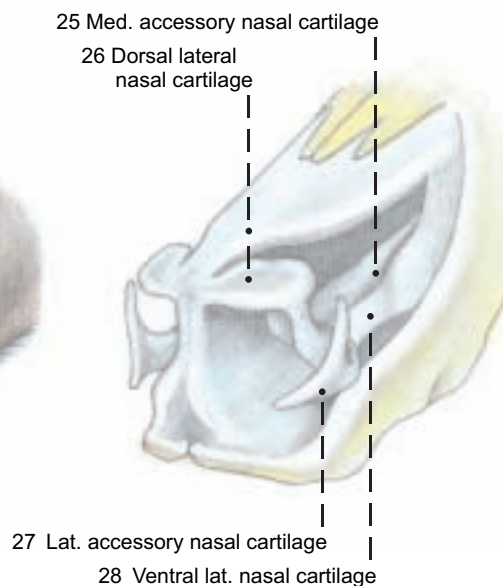
Legend:

- | | | | |
|---|-------------------------|---|-------------------------|
| a Dental pad | e Soft palate | h' Bulla and cells of ventral concha | l Proper lingual muscle |
| b Labial and buccal papillae (See also text figure) | f Dorsal conchal sinus | i Frontal sinus | m Genioglossis |
| c Palatine venous plexus | g Middle conchal sinus | j Palatine sinus | n Geniohyoideus |
| d Hard palate | h Ventral conchal sinus | k Pharyngeal septum and pharyngeal tonsil | o Hyoepiglotticus |
| | | | p Sternohyoideus |

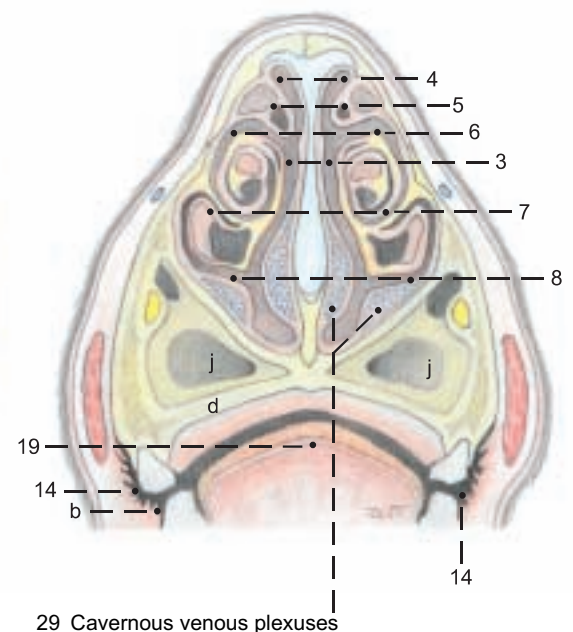
External nose



Nasal cartilages



Nasal conchae



9. PHARYNX AND LARYNX

Dissection and study are carried out from the medial cut surface as well as the lateral side. Laterally, the pterygoids, digastricus, stylohyoideus, and occipitohyoideus are removed, as well as the remnants of the mandibular and parotid glands.

a) The cavity of the **PHARYNX** consists of three parts: the oropharynx, laryngopharynx, and nasopharynx. The **oropharynx (pars oralis, B)** communicates with the oral cavity through the **isthmus of the fauces**, which is bounded dorsally by the soft palate (velum palatinum), ventrally by the tongue, and laterally by the **palatoglossal arches** (p. 44, text fig.). The oropharynx extends to the base of the epiglottis, and its lateral wall contains the palatine tonsil (4, 14). The **laryngopharynx (pars laryngea, D)** lies below the **intraparyngeal ostium**, which is surrounded by the free border of the **soft palate (3)** (raised by forceps) and the right and left **palatopharyngeal arches**. The arches meet on the caudal wall over the arytenoid cartilages. When the animal is breathing, the larynx projects through the ostium into the nasopharynx, and the cavity of the laryngopharynx is obliterated, except for the lateral **piriform recesses**, which conduct saliva around the larynx to the esophagus without the necessity of swallowing. In swallowing, the intraparyngeal ostium and the larynx are closed, and the function of the laryngopharynx changes from **respiratory** to **digestive**. The caudal part of the laryngopharynx (D) joins the **esophagus** over the cricoid lamina without visible demarcation. The **nasopharynx (pars nasalis, A)** extends from the **choanae (p. 31, F)** to the intraparyngeal ostium, and is separated from the oropharynx by the **soft palate (3)**. The choanae are divided dorsally by the crest of the vomer, covered by mucosa with a thick submucosal cavernous venous plexus. *Caudal to the vomer in ruminants, the membranous pharyngeal septum (2) divides the dorsal part of the nasopharynx lengthwise, and extends to the caudodorsal wall, where it contains the pharyngeal tonsil (p. 45, k).* On the wall of the nasopharynx lateral to the tonsil, is a slit—the **pharyngeal orifice of the auditory tube (1)**, leading to the middle ear.

I. The **pharyngeal muscles** are identified from the lateral surface, sparing the arteries and the pharyngeal branches of cranial nerves IX and X, which innervate the muscles and the mucosa. (See p. 49.)

Muscles of the soft palate: The **tensor veli palatini (11)**, has a superficial part originating from the muscular process of the temporal bone and terminating in a tendon that passes around the hamulus of the pterygoid bone. The deep part originates on the pterygoid bone and works in the opposite direction to open the auditory tube by pulling on its cartilage.* The **levator veli palatini (12)** also originates from the muscular process. With the contralateral muscle it forms a sling in the soft palate. The **palatinus** (not illustrated) comes from the choanal border of the *palatine bones and runs through the median line of the soft palate.** The **palatopharyngeus** (p. 49, e) forms a thin band in the palatopharyngeal arch and acts as a constrictor of the intraparyngeal ostium. It may also be classed with the:

Rostral pharyngeal constrictors: The **pterygopharyngeus (13)**, comes from the hamulus of the pterygoid bone and passes caudally lateral to the levator. The **rostral stylopharyngeus** (not illustrated) lies on the lateral wall of the pharynx rostral to the stylohyoid bone. It is inconstant in most species, *but constant in ruminants.* It arises from the medial surface of the distal half of the bone and terminates with the pterygopharyngeus.

Middle pharyngeal constrictor: The **hyopharyngeus (16)** originates mainly from the thyrohyoid, but also from the keratohyoid and the ventral end of the stylohyoid.

Caudal pharyngeal constrictors: The **thyropharyngeus (17)** comes from the oblique line on the thyroid cartilage. The **cricopharyngeus (18)** comes from the lateral surface of the cricoid. All pharyngeal constrictors terminate on the pharyngeal raphe.

The only **dilator of the pharynx** is the **caudal stylopharyngeus (15)**, originating from the proximal half of the stylohyoid, it passes between the rostral and middle constrictors, and *in the ox, terminates mainly on the dorsal border of the thyroid cartilage, so that it draws the larynx upward and forward.* Another part turns around the rostral border of the hyopharyngeus to terminate on the lateral pharyngeal wall and act as a dilator of the pharynx.

II. The **pharyngeal lymphatic ring** consists of the palatine, pharyngeal, lingual, and tubal tonsils, and the tonsil of the soft palate.

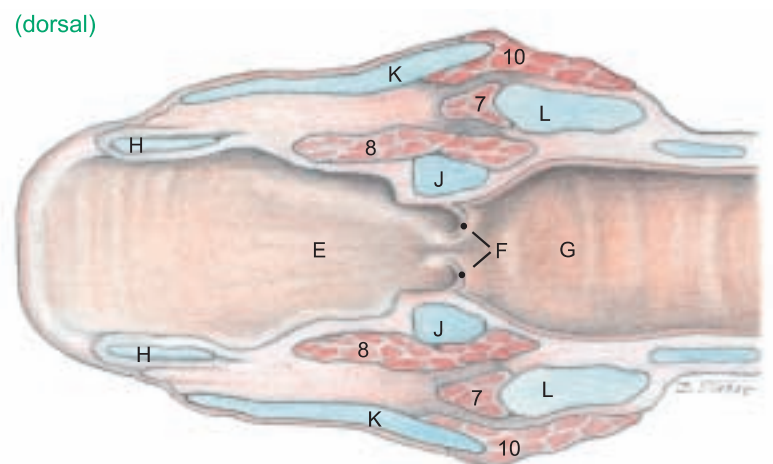
The **palatine tonsil (14)** is concealed outside the mucosa of the lateral wall of the oropharynx. Only the orifice of the **central tonsillar sinus (4)**, into which the crypts of the follicles open, is visible. The sides of the **pharyngeal tonsil** (see p. 45) are marked by long ridges and grooves, in which the openings of mucous glands can be seen. The **lingual tonsil** has been described (p. 44). The **tubal tonsil**, in the lateral wall of the pharyngeal orifice of the auditory tube, is flat and nonfollicular. The **tonsil of the soft palate**, on the oral side, consists of some lymphatic tissue and a few follicles. On the medial surface, the paired **medial retropharyngeal lnn. (p. 49, a)**, important clinically and in meat inspection, lie in the fat between the caudal wall of the pharynx and the longus capitis (f).

III. The **auditory tube** connects the middle ear with the nasopharynx. The tubal cartilage, *unlike that of the horse, does not extend into the mucosal flap that closes the pharyngeal orifice.* The latter is in a transverse plane just rostral to the temporomandibular joint, and at the level of the base of the ear. The tube is medial to the tensor veli palatini. *Of the domestic mammals, only the Equidae have a diverticulum of the tube (guttural pouch).*

b) The **LARYNX** (see also text fig.) *Because there are no laryngeal ventricles or vestibular folds, the wall of the the laryngeal vestibule (E) is smooth. The vestibular lig. of the horse is represented by a flat, fan-shaped sheet of fibers.*

The **vocal fold (F)** is only a low ridge containing the **vocal ligament (5)**. The **glottis (F)** is composed of the vocal folds, arytenoid cartilages, and the **glottic cleft (rima glottidis)**. Behind the glottis is the **infraglottic cavity (G)**.

I. The **cartilages of the larynx** show the following species differences in the ox: *The epiglottic cartilage (H) is broad and rounded. The corniculate, vocal, and muscular processes of the arytenoid cartilages (J) resemble those of the dog and horse, but there is no cuneiform process. The thyroid cartilage (K) has a rostral notch (K'), absent in other species, and the caudal notch is not palpable in the live animal. The laryngeal prominence (K'') a landmark, is not at the rostral end of the cartilage, as is the human "Adam's apple", but two-thirds of the way toward the caudal end. The lamina of the cricoid cartilage (L) is short.*



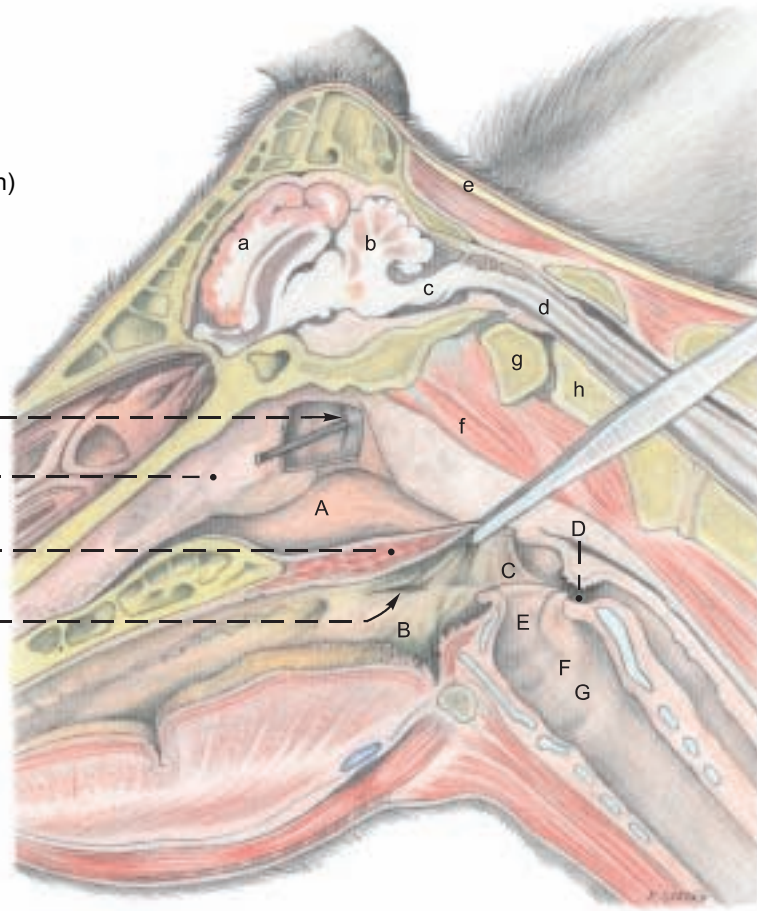
II. The **LARYNGEAL MUSCLES** act like those of the dog and horse. The **cricoarytenoideus dorsalis (9)** is the primary dilator of the glottis. *Because there is no lateral ventricle, the ventricularis and vocalis are combined in the thyroarytenoideus (8).* Other constrictors of the glottis are the **cricoarytenoideus lateralis (7)**, **cricothyroideus (10)**, and **arytenoideus transversus (6)**.

The **innervation of the larynx** by the cranial and recurrent laryngeal nn. from the vagus n. corresponds to that of the horse and dog.

Pharynx and Larynx

(Paramedian section)

- 1 Pharyngeal orifice of auditory tube
- 2 Pharyngeal septum
- 3 Soft palate
- 4 Sinus of palatine tonsil



Legend:

(Brain, see p. 51)

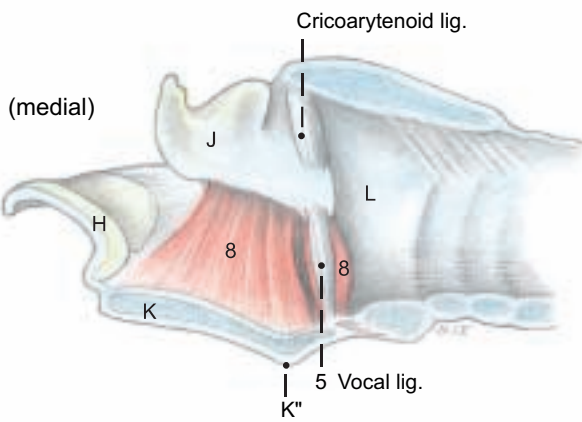
- a Cerebrum
- b Cerebellum
- c Medulla oblongata
- d Medulla spinalis (Spinal cord)
- e Lig. nuchae
- f Longus capitis
- g Atlas
- h Axis

Pharyngeal cavity

- A Nasopharynx
- B Oropharynx
- C Palatopharyngeal arch
- D Laryngopharynx

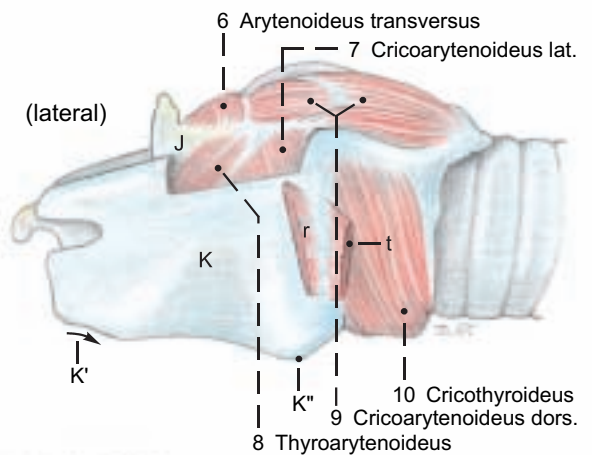
Laryngeal cavity

- E Laryngeal vestibule
- F Glottis and vocal fold
- G Infraglottic cavity



Laryngeal cartilages

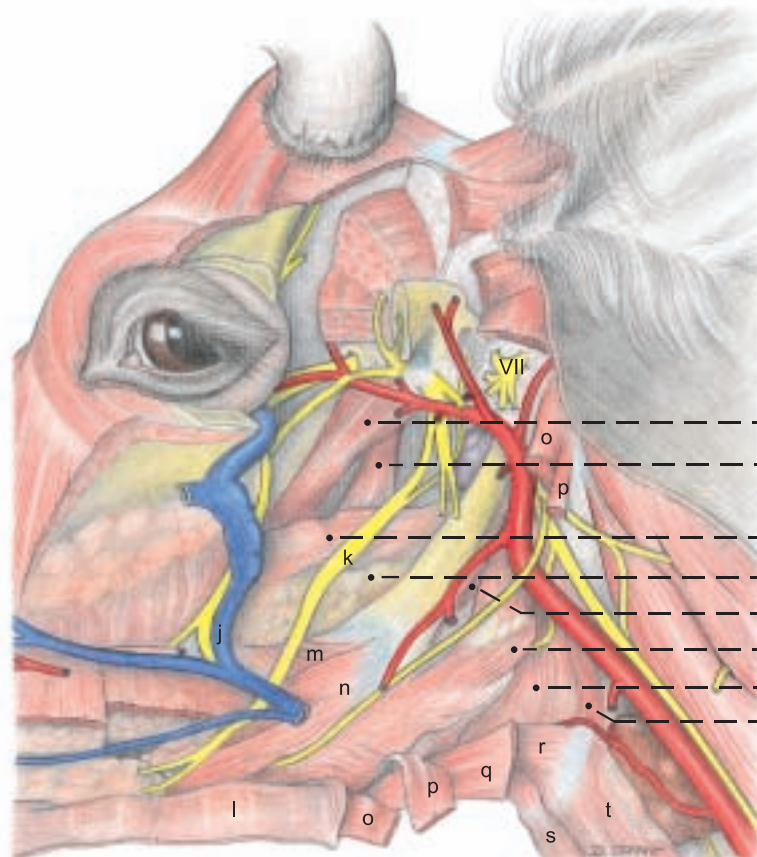
- H Epiglottic
- J Arytenoid
- K Thyroid
- K' Rostral notch
- K'' Laryngeal prominence
- L Cricoid



(lateral)

Legend:

- j Deep facial v.
- k Lingual n. (V2)
- l Mylohyoideus
- m Hyoglossus
- n Styloglossus
- o Digastricus
- p Stylohyoideus
- q Omohyoideus
- r Thyrohyoideus
- s Sternohyoideus
- t Sternothyroideus



- 11 Tensor veli palatini
- 12 Levator veli palatini
- 13 Pterygopharyngeus
- 14 Palatine tonsil
- 15 Stylopharyngeus caudalis
- 16 Hyopharyngeus
- 17 Thyropharyngeus
- 18 Cricopharyngeus

(See pp. 36, 37, 39, 45, 49)

10. ARTERIES OF THE HEAD AND HEAD-NECK JUNCTION, THE CRANIAL NN. OF THE VAGUS GROUP (IX–XI), AND THE HYPOGLOSSAL N. (XII)

For the demonstration of these aa. and nn.: laterally the dorsocaudal third of the stylohyoid bone, and medially the rectus capitis ventralis and longus capitis are removed.

a) The **ARTERIES OF THE HEAD** show species-specific characteristics different from the dog and horse (for veins and arteries of the head, see text fig. p. 36).

The **common carotid a.** (16, see also p. 61) reaches the head-neck junction accompanied dorsally by the vagosympathetic trunk, and ventrally by the recurrent laryngeal n. Here it gives off the **sternomastoid brr.** (15). At the thyroid gl. it gives off, as in the horse, the **inconstant caud. thyroid a.** and the **cran. thyroid a.** (17). The latter gives rise to the **caud. laryngeal br.** which accompanies the caud. laryngeal n. The **cran. laryngeal a.** with its laryngeal and pharyngeal brr. *comes either directly from the common carotid a.* or, as in the horse, from the cran. thyroid a. *Shortly before its termination the common carotid a. gives off the ascending pharyngeal a. for the soft palate, tonsils, and pharynx.*

The common carotid a. is continued by its largest terminal br., the external carotid a., whose origin is marked by the origin of the **occipital a.** (9) *because the smaller terminal br., the internal carotid a., undergoes atrophy of its extracranial part in the ox. By three months after birth it is completely closed.*

The **external carotid a.** (11), as it turns dorsally, gives off the **linguofacial trunk** (4) rostroventrally. This divides into the facial and lingual aa. The **lingual a.** (5) runs medial to the mandible along the stylohyoid bone, gives off the sublingual a., and passes medial to the hyoglossus into the tongue. The **facial a.** (6) also runs first medial to the mandible, and then turns at the vascular groove, *covered by the sternomandibularis*, onto the lateral surface at the rostral border of the masseter. After giving off the **caudal auricular a.** (8) caudodorsally, the **masseteric br.** (2) rostroventrally, and the **supf. temporal a.** (7) dorsally, the external carotid is continued by the **maxillary a.** (1) directed rostrorodorsally toward the base of the skull.

b) The **THYROID GL.** (18) consists of *two flat lobulated irregularly triangular lobes* connected by a *parenchymatous* isthmus. The lobes are lateral to the trachea, esophagus, and cricoid cartilage, and the isthmus passes ventral to the trachea at the first or second cartilage. *In old cattle the isthmus may be reduced to a fibrous band.*

c) The **PARATHYROID GLL.** The **external parathyroid gl.** is 6–10 mm long and reddish-brown. *It is always cranial to the thyroid gl., usually dorsomedial to the common carotid a., about 3 cm caudal to the origin of the occipital a.* It may be on the caudal border of the mandibular gl. The **internal parathyroid gl.** is 1–4 mm long, and brown. *It is on the tracheal surface of the lobe of the thyroid gl., near the craniodorsal border, embedded in the parenchyma.*

d) The **ESOPHAGUS** (23, see also p. 60) in the cranial third of the neck, is dorsal to the trachea; between the third and sixth vertebrae it lies on the left side of the trachea; and at the thoracic inlet it is in a left dorsolateral position.

e) The **TRACHEA** (24, see also p. 60) *of the ox changes the shape of its cross section in life and after death* mainly by the state of contraction of the trachealis muscle attached to the inside of the tracheal cartilages. *It is relatively small (4 x 5 cm).*

f) **CRANIAL NERVES OF THE VAGUS GROUP (IX–XI)** emerge through the jugular foramen, as in the horse and dog.

I. The **glossopharyngeal n.** (IX, 3) innervates mainly the tongue

with its large **lingual br.** Before it divides into dorsal and ventral brr., the lingual br. in the ox *bears a lateropharyngeal ganglion* medial and rostroventral to the stylohyoid. The **pharyngeal br.** supplies several branches to the pharynx.

II. The **vagus n.** (X, 20) has the widest distribution of all the cranial nn. Its nuclei of origin are in the nucleus ambiguus of the medulla oblongata for the motor fibers and in the parasympathetic nucleus of the vagus for the parasympathetic fibers. The sensory nuclei are in the nucleus of the solitary tract and in the nucleus of the spinal tract of C. N. V (see pp. 54, 55). The pseudounipolar nerve cells of the afferent fibers are in the proximal ganglion and in the distal ganglion of the vagus, which is very small in the ox, and lies near the jugular foramen. The vagus, after leaving the skull, first gives off the **pharyngeal brr.** (21), whose cranial brr. join those of C. N. IX in the pharyngeal plexus, supplying pharyngeal muscles and mucosa. The caudal continuation innervates the thyropharyngeus and cricopharyngeus and becomes the **esophageal br.** This is motor to the cran. part of the cervical esophagus, and joins the caud. laryngeal n. The **cranial laryngeal n.** (13) originates from the vagus caudal to the pharyngeal brr., and runs cranioventrally, crossing lateral to the pharyngeal br. *Its external br. usually joins the pharyngeal br., then separates again to innervate the cricothyroideus.* The **internal br.** of the cran. laryngeal n. enters the larynx through the thyroid fissure and innervates the mucosa. *It then courses caudally inside the thyroid lamina and emerges caudal to the larynx to join the esophageal br. or the caudal laryngeal n.* (19) which comes from the recurrent laryngeal n. In the thorax the vagus gives off the **recurrent laryngeal n.**, which, on the right side, turns dorsally around the caudal surface of the subclavian a. and runs cranially between the common carotid a. and the trachea. On the left side, the recurrent n. turns medially around the aorta and the lig. arteriosum, passes medial to the great arteries, and runs cranially between the esophagus and trachea. Both nerves terminate as the **caudal laryngeal nerves** which pass deep to the cricopharyngeus to innervate all of the laryngeal muscles except the cricothyroideus.

After giving off the recurrent laryngeal n., the vagus still carries parasympathetic and visceral afferent fibers serving the heart, lungs, and abdominal organs as far as the descending colon. The visceral afferents greatly predominate (see pp. 65, 73).

III. The **accessory n.** (XI, 10) divides at the level of the atlas into a **dorsal br.** to the **cleidooccipitalis** and trapezius, and a **ventral br.** to the **cleidomastoideus** and **sternocephalicus** (see p. 60).

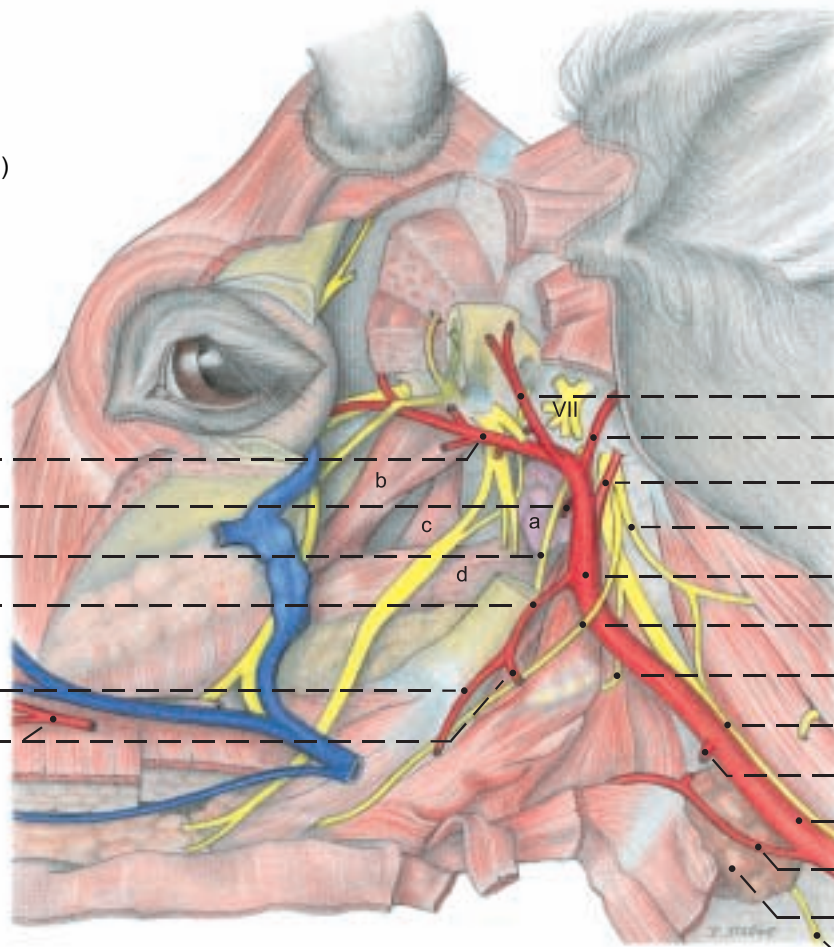
g) The **HYPOGLOSSAL N.** (XII, 12) emerges through the hypoglossal canals. It innervates the **proper (intrinsic) muscle of the tongue** (f) and the following extrinsic muscles: styloglossus, hyoglossus, and genioglossus. The **geniohyoideus** (h) and **thyrohyoideus** (see p. 47) are also supplied by the hypoglossal n. with a variable contribution from the first cervical n. via the **ansa cervicalis**.

h) From the **SYMPATHETIC TRUNK** of the autonomic system, fibers pass in the region of the thoracic inlet through the cervicothoracic ganglion (p. 65) and middle cervical ganglion and then in the **vagosympathetic trunk** (14) to the head. Here in the **cran. cervical ganglion** (22), large in the ox, the fibers synapse with ganglion cells whose postganglionic sympathetic fibers run in perivascular (mainly periarterial) plexuses in the adventitia of the large vessels of the head to their distribution in glands and internal eye muscles.

Arteries of the head and Cranial nn. IX, X, XI, XII

(lateral)

- 1 Maxillary a.
- 2 Masseteric br.
- 3 Glossopharyngeal n. (IX)
- 4 Linguofacial trunk
- 5 Lingual a.
- 6 Facial a.



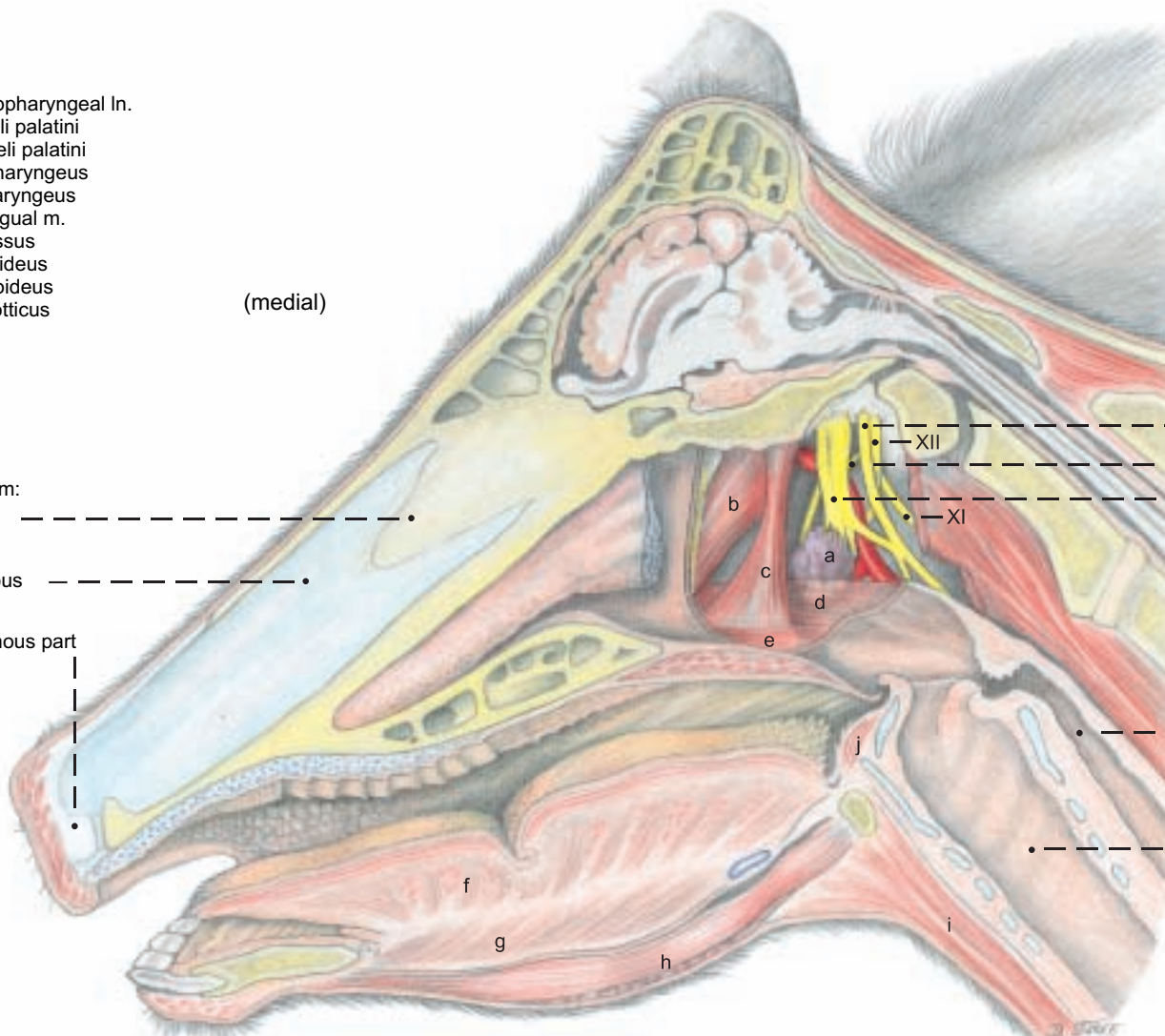
- 7 Supf. temporal a.
- 8 Caud. auricular a.
- 9 Occipital a.
- 10 Accessory n. (XI)
- 11 External carotid a.
- 12 Hypoglossal n. (XII)
- 13 Cran. laryngeal n.
- 14 Vagosympathetic trunk
- 15 Sternomastoid brr.
- 16 Common carotid a.
- 17 Cran. thyroid a.
- 18 Thyroid gl.
- 19 Caud. laryngeal n.

Legend:

- a Med. retropharyngeal ln.
- b Tensor veli palatini
- c Levator veli palatini
- d Pterygopharyngeus
- e Palatopharyngeus
- f Proper lingual m.
- g Genioglossus
- h Geniohyoideus
- i Sternohyoideus
- j Hyoepiglotticus

(medial)

- Nasal septum:
- Bony part
 - Cartilaginous part
 - Membranous part



- 20 Vagus n. (X)
- 21 Pharyngeal br.
- 22 Cranial cervical ganglion
- 23 Esophagus
- 24 Trachea

(See pp. 39, 45, 47, 51)

CHAPTER 4: CENTRAL NERVOUS SYSTEM AND CRANIAL NERVES

1. THE BRAIN

To remove the half-brain from the bisected head, the cut end of the spinal cord is first lifted from the dura mater, cutting the attachments of the denticulate lig. and the cervical nn. Then the brain is detached by identifying and cutting the cranial nn. in caudorostral order, midway between the brain and the dura. The roots of the **hypoglossal n. (XII)** emerge from the ventrolateral groove, lateral to the **decussation of the pyramids**, and exit through the dura, and to the hypoglossal canals. The nerves of the vagus group (IX, X, XI) emerge from the lateral funiculus of the medulla oblongata. The **accessory n. (XI)** has a long **spinal root**, which begins at the fifth cervical segment and runs up to unite with the small **cranial root**. The **glossopharyngeal (IX)** and **vagus (X)** nerves originate by a continuous series of rootlets and pass out through the jugular foramen with the accessory n. The **vestibulocochlear (VIII)** and **facial (VII)** nerves also arise close together from the medulla, between the cerebellum and the trapezoid body, with VIII dorsolateral to VII, and run dorsolaterally to the internal acoustic meatus. The small **abducent n. (VI)** passes out through the trapezoid body at the lateral edge of the pyramid, and enters a hole in the dura on the floor of the cranium in the transverse plane of the internal acoustic meatus. The large **trigeminal n. (V)** comes from the end of the pons just rostral to the facial n. and runs rostroventrally to the largest aperture in the dura. Nn. IV and III come from the midbrain (13, 14). The **trochlear n. (IV)**, the only one to emerge from the dorsal surface of the brain stem, arises behind the caudal colliculus, decussates with the contralateral nerve, and passes around the lateral surface of the midbrain, on or in the free border of the tentorium cerebelli, to the floor of the cranium. The larger **oculomotor n. (III)** arises from the crus cerebri, caudolateral to the hypophysis, which should be carefully dissected out of the Sella turcica (p. 31, 42) while maintaining its connection with the brain. The internal carotid a. will be cut between the rete mirabile and the arterial circle of the cerebrum. Nerves III, IV, VI, and the ophthalmic and maxillary nerves join outside the dura and leave the cranium through the orbitoround for. in ruminants and swine. The **optic n. (II)** is cut distal to the optic chiasm. The optic tract connects the chiasm to the diencephalon. To free the cerebral hemisphere, the median dorsal fold of the dura (falx cerebri) is removed and preserved for study of the enclosed sagittal sinus, and the membranous tentorium cerebelli is cut at its dorsal attachment. (There is no osseous tentorium in ruminants.) The half-brain is lifted out of the dura by inserting scalpel handles between the cerebrum and the dura dorsally and between the olfactory bulb and the ethmoidal fossa, severing the **olfactory nn. (I)**.

a) The **BRAIN** is relatively small. Because species-specific differences are of minor significance among domestic mammals, reference to a general textbook description is advised. Only a few features of the bovine brain will be mentioned here; greater importance will be given to the illustrations.

I. The dorsal part of the **rhombencephalon**, the **cerebellum (17)**, is much more complex and irregular than in man, and the **vermis (H)** is not very prominent.

II. The **midbrain (mesencephalon)** exhibits four dorsal eminences, the **rostral and caudal colliculi**. The caudal pair is smaller. On the ventral surface is the **cerebral crus**.

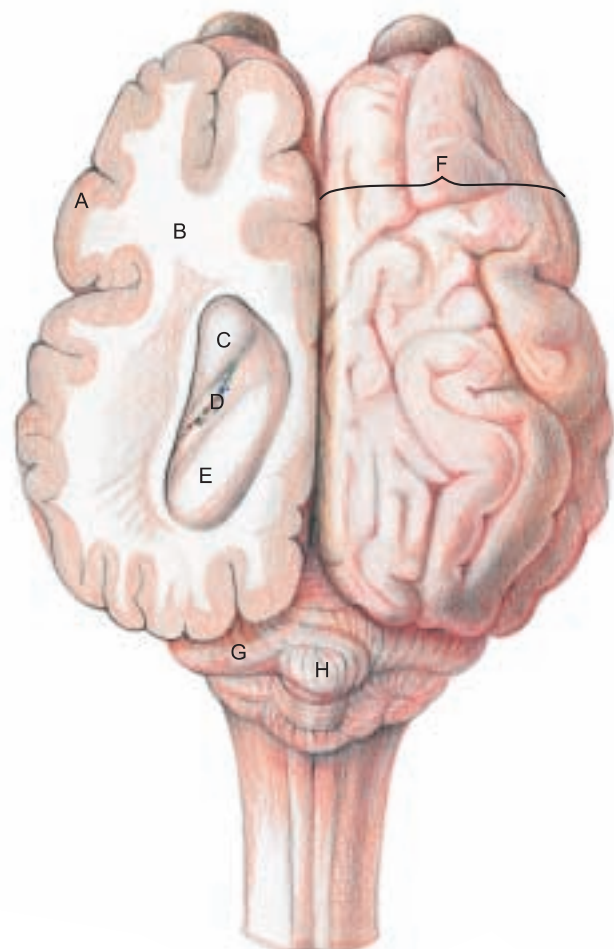
III. The **diencephalon** is connected through its **hypothalamus (9)** with the **infundibulum (10)** of the **hypophysis (11)**. Caudal to the infundibulum is the **mammillary body (12)**. The **pineal gl. (8)** projects dorsocaudally from the diencephalon.

IV. The greatest part of the **telencephalon (cerebrum)** is the **hemisphere (F)**. It consists of the **cortex (A)** and the **white matter (B)**. It is markedly convoluted on the surface, bearing **gyri (folds) and sulci (grooves)**. The herbivora have additional variable and inconstant sulci which make the brain more complex than the brains of carnivores. On the **rhinencephalon (3)** the **olfactory bulb** is smaller than in the dog and horse. It is continuous caudally with the **olfactory peduncle**, which branches into **lateral and medial olfactory tracts**.

b) The **VENTRICULAR SYSTEM**. In the roof of the **fourth ventricle (h)** the **caudal medullary velum (j)** is invaginated by a **choroid plexus**. The **third ventricle (a)** is in the median plane; it encircles the

interthalamic adhesion (7), and with its **choroid plexus (a')**, extends over the pineal gl. as the **suprapineal recess (d)**. The third ventricle also extends into the pineal gl. The **cerebral aqueduct (g)** connects the third and fourth ventricles. Rostrally, the third ventricle communicates on each side through an **interventricular foramen (f)** with a **lateral ventricle**, which contains a **choroid plexus** continuous with that of the third ventricle. A long process of the lateral ventricle extends into the olfactory bulb.

Section of cerebrum (dorsal)

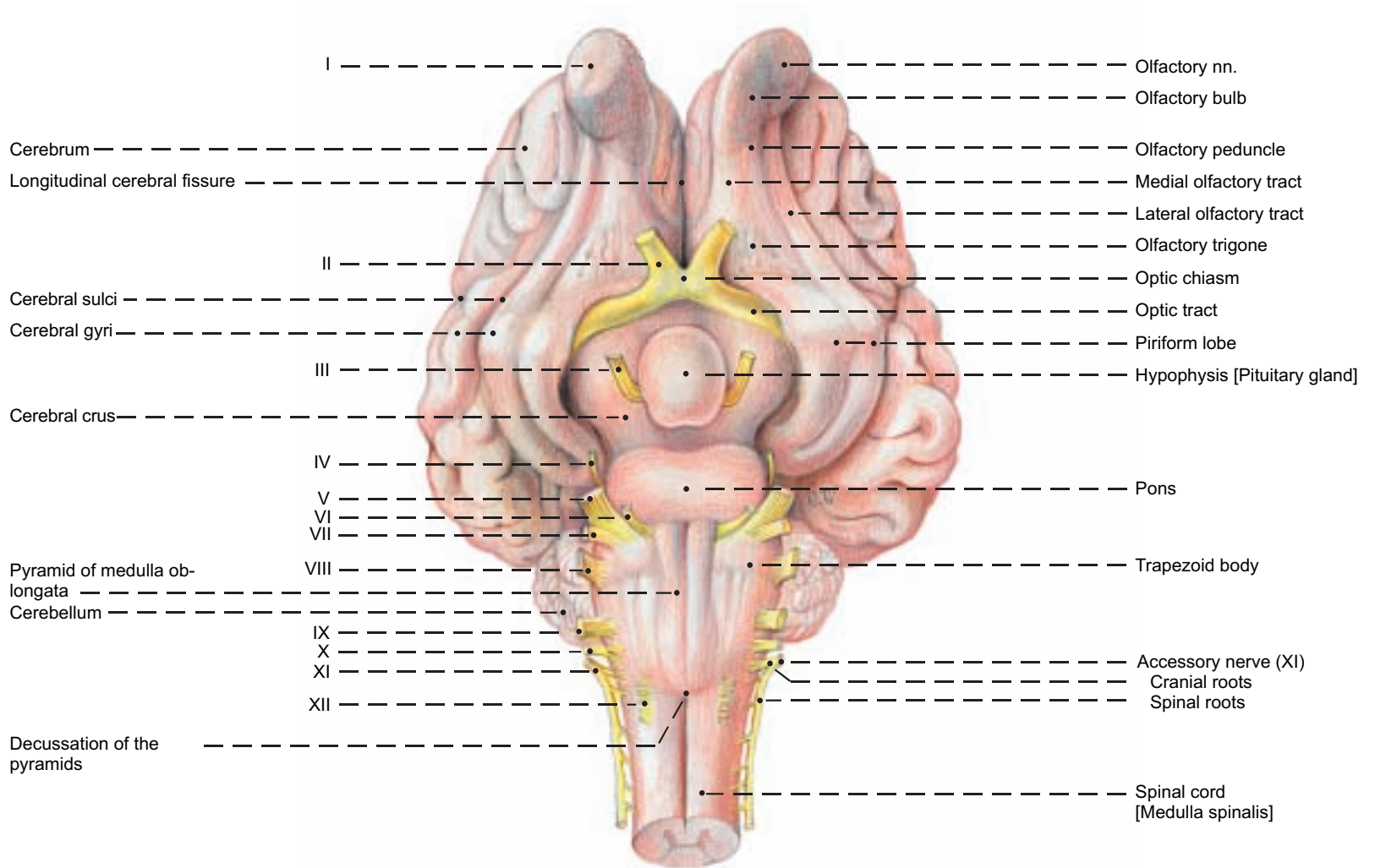


Legend:

A Cerebral cortex [Gray matter]	E Hippocampus
B White matter	F Cerebral hemisphere
C Head of caudate nucleus	G Cerebellar hemisphere
D Choroid plexus of lateral ventricle	H Vermis

Brain [Encephalon] and Cranial Nerves

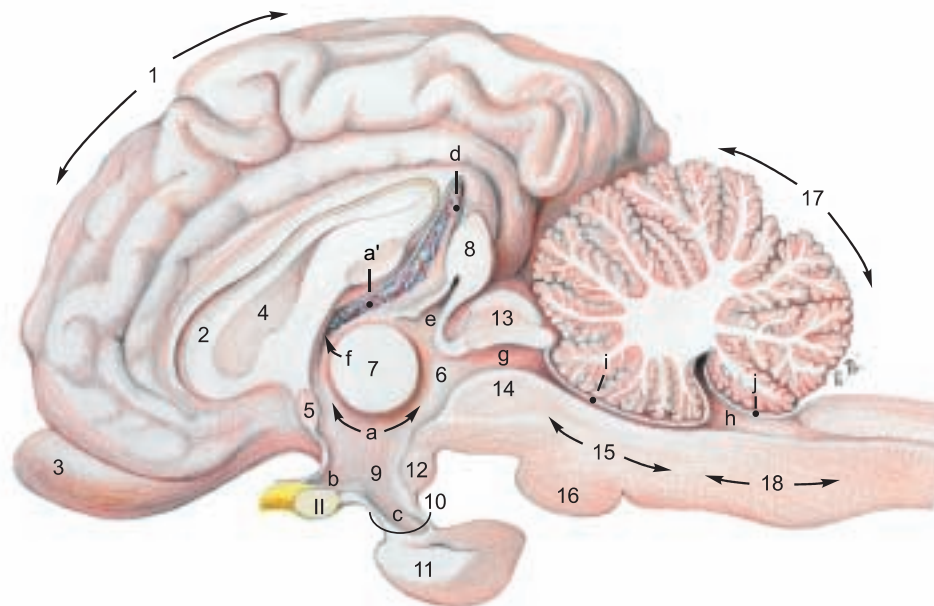
Base of brain (ventral)



Median section of the brain

Legend:

- a Third ventricle
- a' Choroid plexus of third ventricle
- b Optic recess
- c Infundibular recess
- d Suprapineal recess
- e Pineal recess
- f Interventricular foramen
- g Cerebral aqueduct
- h Fourth ventricle
- i Rostral medullary velum
- j Caudal medullary velum



Cerebrum:

- 1 Hemisphere
- 2 Corpus callosum
- 3 Rhinencephalon
- 4 Septum pellucidum
- 5 Rostral commissure

Diencephalon:

- 6 Thalamus
- 7 Interthalamic adhesion [Intermediate mass]
- 8 Epiphysis [Pineal gland]
- 9 Hypothalamus
- 10 Infundibulum
- 11 Hypophysis [Pituitary gl.]
- 12 Mamillary body

Mesencephalon [Midbrain]:

- Tectum
- 13 Lamina tecti [Rostral and caudal colliculi]
- 14 Tegmentum

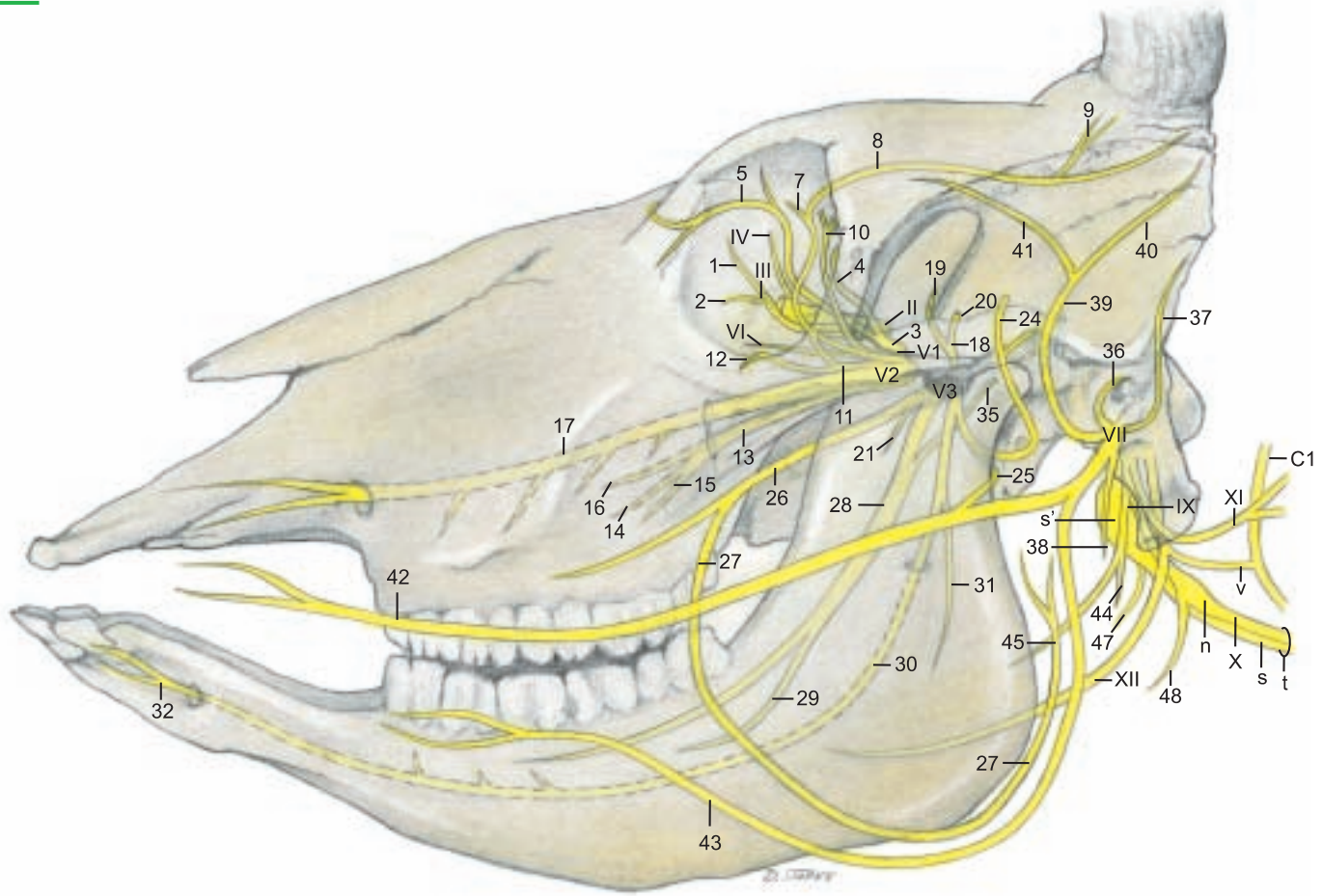
Rhombencephalon:

- 15 Metencephalon
- 16 Pons
- 17 Cerebellum
- 18 Myelencephalon [Medulla oblongata]

2. CRANIAL NERVES I–V

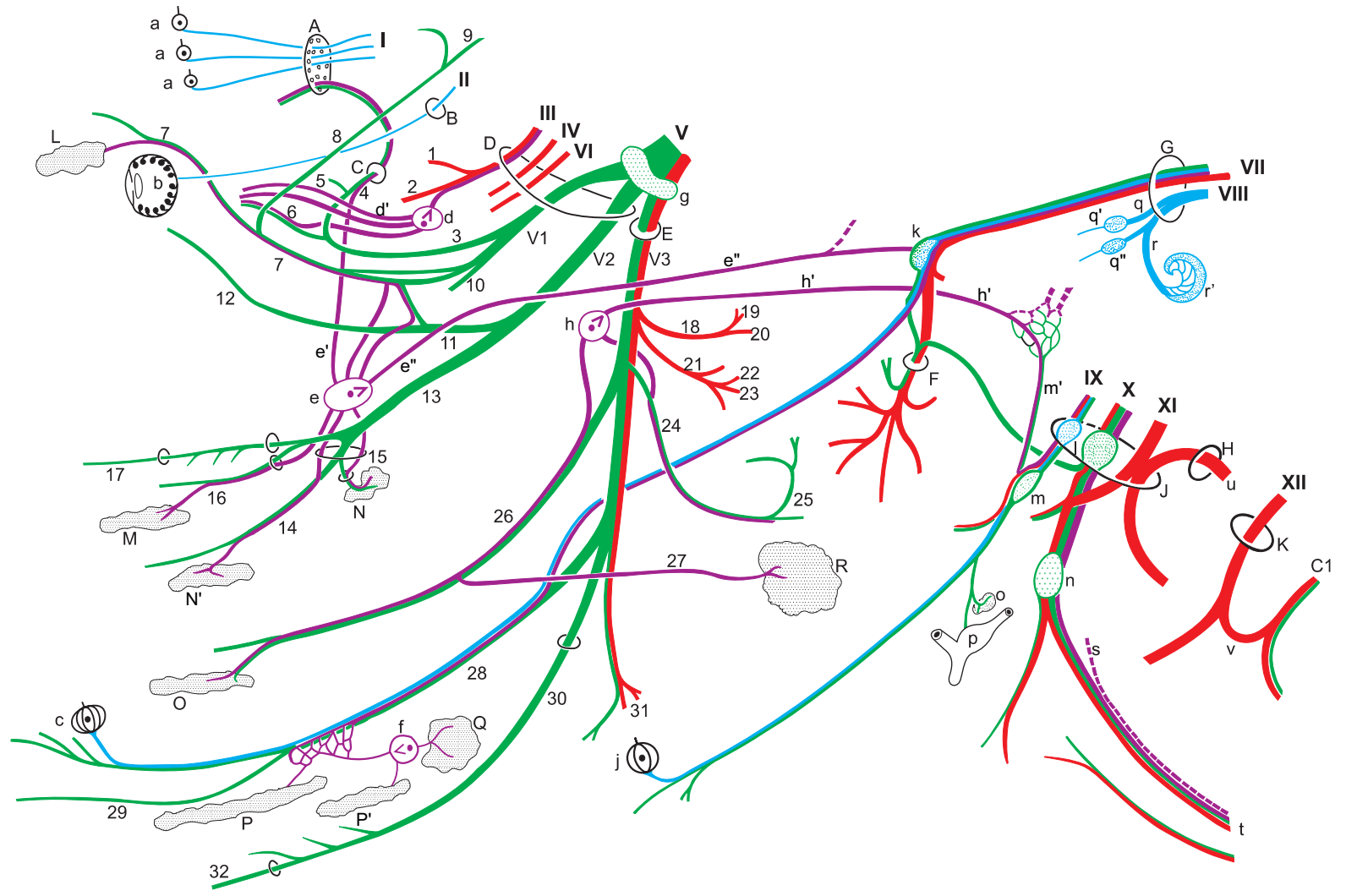
NERVE	PAGE	NAME/FIBER FUNCTION	DISTRIBUTION	REMARKS
I	50	Olfactory nn. (special sensory)	Olfactory region in caud. nasal cavity	1st neuron in olfactory mucosa, synapse in olfactory bulb
II	42, 50	Optic n. (special sensory)	Optical part of retina	Evagination of diencephalon
III	40, 50	Oculomotor n. (m., psy.)*		Orig. mesencephalon, exits by for. orbitorotundum
	(1)	• Dorsal br. (m.)	Dors. rectus, levator palpebrae superioris, retractor bulbi	
	(2)	• Ventr. br. (m., psy.)	Med. and ventr. recti, ventral oblique	Psy. neurons synapse in ciliary gangl. and pass in ciliary nn. to eyeball
IV	40, 50	Trochlear n. (m.)	Dorsal oblique	Orig. mesencephalon, exits skull by for. orbitorotundum
V	38, 50	Trigeminal n.		Orig. rhombencephalon and mesencephalon. Nerve of 1st pharyngeal arch
V1	40	• Ophthalmic n. (s.)	Dorsum nasi, ethmoid bone, lacrimal gl., upper eyelid	Exits skull by foramen orbitorotundum
	(3)	•• Nasociliary n. (s.)		
	(4)	••• Ethmoid n. (s.)	Dorsal nasal mucosa	Enters nasal cavity through ethmoid for. and cribriform plate
	(5)	••• Infratrochlear n. (s.)	Conjunctiva, 3 rd lid, lacrimal caruncle, skin of med. angle of eye	Crosses dors. margin of orbit below trochlea; may reach corneal process
	(6)	••• Long ciliary nn. (s., psy.)	Iris and cornea, ciliary muscle	Psy. fibers from ciliary ganglion
	(7)	•• Lacrimal n. (s., psy., sy.)	Lacrimal gl., skin and conjunctiva of lat. angle of eye	Thin lat. and med. br., which, after junction with r. communicans from zygomatic n., join to form zygomaticotemporal br.
	(8)	••• Zygomaticotemporal br.	Skin of temporal region	
	(9)	•••• Cornual br.	Cornual dermis	Dehorning anesthesia!
	(10)	•• Frontal n. (s.)	Skin of frontal region and upper eyelid	Ends as supraorbital n. in skin of frontal region
V2	38	• Maxillary n. (s.)		Exits skull from for. orbitorotundum
	(11)	•• Zygomatic n. (s., psy.)		Communicating br. with lacrimal n. (V1)
	(12)	••• Zygomaticofacial br. (s.)	Lower eyelid	Exits orbit at lat. angle of eye
	(13)	•• Pterygopalatine n. (s., psy.)		Psy. fibers from pterygopalatine ganglion
	(14)	••• Major palatine n. (s., psy.)	Mucosa and gll. of the hard palate	Goes through caudal palatine for., palatine canal, and major palatine for.
	(15)	••• Minor palatine nn. (s., psy.)	Soft palate with its glands	Exit palatine canal through minor palatine foramina
	(16)	••• Caud. nasal n. (s.)	Ventr. parts of nasal cavity, palate	Enters nasal cavity through sphenopalatine for.
	(17)	•• Infraorbital n. (s.)	Skin of dorsum nasi, nares, and upper lip	Traverses maxillary for. and infraorbital canal and for.
V3	38	• Mandibular n. (s., m.)		Exits skull by oval foramen
	(18)	•• Masticatory n. (m.)		
	(19)	••• Deep temporal nn. (m.)	Temporalis	
	(20)	••• Masseteric n. (m.)	Masseter	Goes through mandibular notch
	(21)	•• Med. and lat. pterygoid nn. (m.)	Med. and lat. pterygoid mm.	The otic gangl. (s., psy.) at root of buccal n., is large in the ox
	(22)	•• Tensor tympani n. (m.)	Tensor tympani	Enters tympanic cavity
	(23)	•• Tensor veli palatini n.	Tensor veli palatini	
	(24)	•• Auriculotemporal n. (s., psy., sy.)	Skin of auricle and temporal region, Parotid gl.	Turns around the neck of the mandible, psy. fibers from otic ganglion
	(25)	••• Communicating br. with facial n. (s.)		Connection with dors. buccal br. (VII)
	(26)	•• Buccal n. (s. psy.)	Mucosa of cheek and buccal gll.	Psy. fibers from otic gangl.
	(27)	••• Parotid br. (psy.)	Parotid gl.	Follows parotid duct backward through vascular groove
	(28)	•• Lingual n. (taste, s., psy.)	Sensory to floor of mouth and tongue, taste from rostral 2/3 of tongue	Receives taste, s., and psy. fibers from chorda tympani (VII). (Psy. fibers synapse in mandibular ganglion.)
	(29)	••• Sublingual n. (s., psy.)	Mucosa of rostral floor of mouth	Carries psy. fibers to mandibular and sublingual gll.
	(30)	•• Inferior alveolar n. (s.)	Inferior teeth and gingiva	Traverses mandibular foramen and canal
	(31)	••• Mylohyoid n. (m.)	Mylohyoid, rostral belly of digastricus	
	(32)	••• Mental n. (s.)	Skin and mucosa of chin and lower lip	Leaves the mandib. canal at the mental foramen

Cranial nerves



Legend:

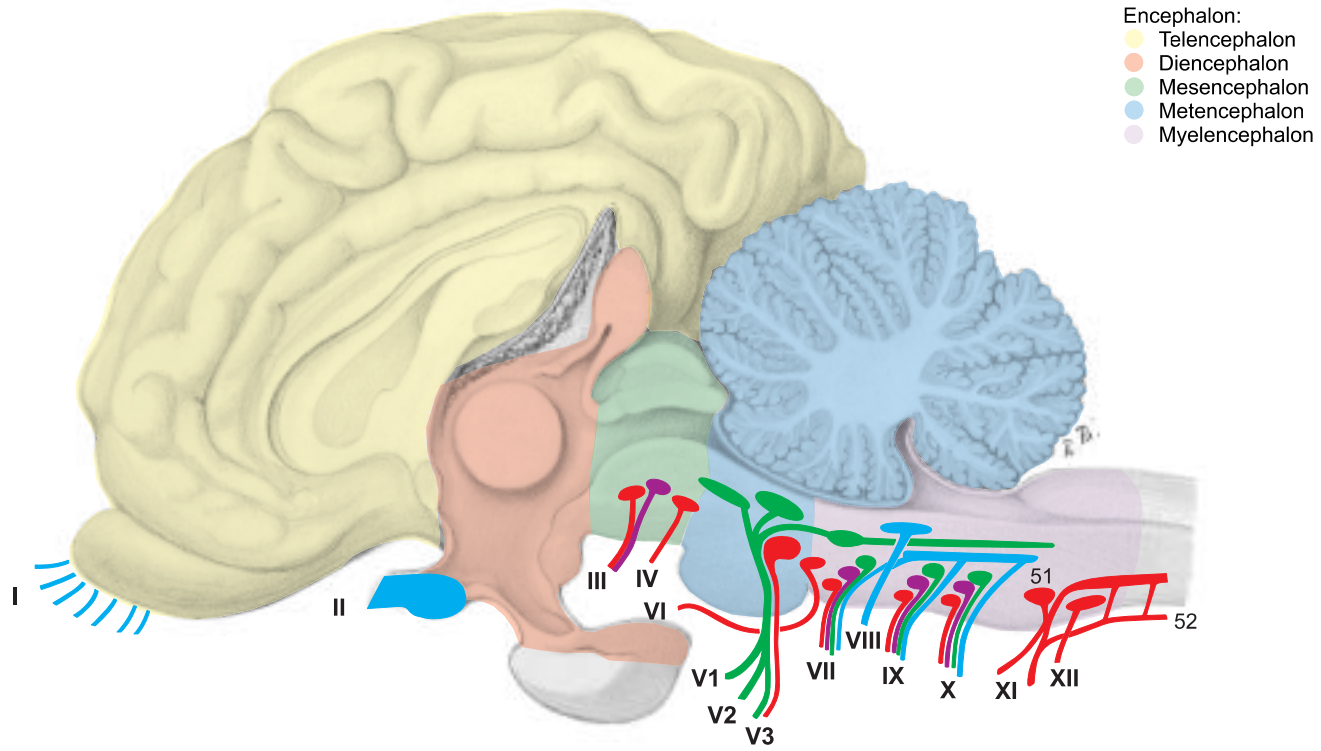
- | | | | | |
|------------------------|--------------------------------|--|----------------------------|-------------------------------|
| A Cribriform plate | L Lacrimal gl. | a Olfactory region | h' Minor petrosal n. | r' Spiral gangl. of cochlea |
| B Optic canal | M Nasal gl. | b Retina | j Vallate papillae | s Sympathetic trunk |
| C Ethmoid foramen | N Palatine gl. (soft palate) | c Fungiform papillae | k Geniculate ganglion | s' Cranial cervical gangl. |
| D For. orbitotundum | N' Palatine gl. (hard palate) | d Ciliary ganglion | l Proximal ganglia | t Vagosympathetic trunk |
| E Oval foramen | O Buccal gl. | d' Short ciliary nn. | m Distal gangl. (petrosal) | u Spinal root of accessory n. |
| F Stylomastoid for. | P Monostomatic sublingual gl. | e Pterygopalatine gangl. | m' Tympanic n. | v Ansa cervicalis |
| G Int. acoustic meatus | P' Polystomatic sublingual gl. | e' Orbital br. | n Distal gangl. (nodose) | |
| H Foramen magnum | Q Mandibular gl. | e'' N. of pterygoid canal
(major and deep petrosal nn.) | o Carotid glomus | |
| J Jugular foramen | R Parotid gl. | f Mandibular ganglion | p Carotid sinus | |
| K Hypoglossal canal | | g Trigeminal ganglion | q Vestibular n. | |
| | | h Otic ganglion | q' Sup. vestibular gangl. | |
| | | | q'' Inf. vestibular gangl. | |
| | | | r Cochlear n. | |



UQLiqNyNzKjvWvGT8zRmLENm5w==|1287791586

3. CRANIAL NERVES VI–XII

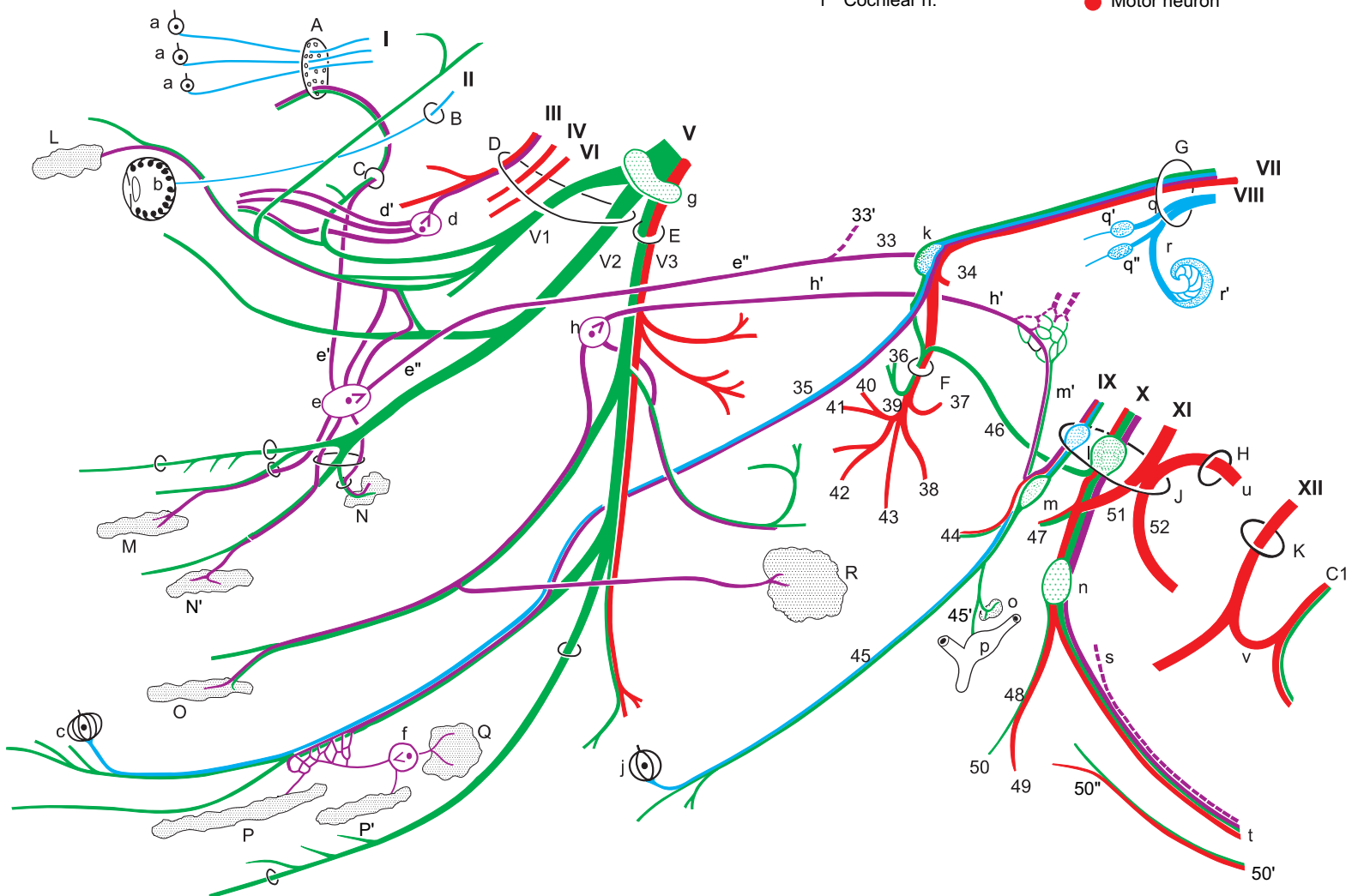
NERVE	PAGE	NAME/FIBER FUNCTION	DISTRIBUTION	REMARKS
VI	40, 50	Abducent n. (m.)	Lat. rectus, lat. part of retractor bulbi	Orig.: Rhombencephalon; exits skull at for. orbitorotundum
VII	36, 50	Facial n. (intermediocardial n.) (taste, m., psy.)*	Mm. of face and ear, lacrimal and salivary gl.	Goes through int. acoustic meatus into facial canal and leaves through stylomastoid for.; nerve of 2nd pharyngeal arch
(33)		• Major petrosal n. (psy.)	Gll. of nose and palate, and lacrimal gl.	Joins the deep petrosal n. (sy.) to form the n. of the pterygoid canal, which goes to pterygopalatine ganglion
(34)		• N. to stapedius (m.)	Stapedius	
(35)	38	• Chorda tympani (taste, psy.)	Mandibular and sublingual gl., rostral 2/3 of tongue, taste	Leaves petrous temporal bone through petrotympanic fissure and joins lingual n. (V3)
(36)	36	• Int. auricular br. (s.)	Int. surface of auricle	Passes through auricular cartilage
(37)	36	• Caud. auricular n. (m.)	Auricular mm.	Communicates with the dors. br. of first 2 cervical nn.
(38)		• Digastric br. (m.)	Caud. belly of digastricus	
		• Parotid plexus (psy.)	Parotid gl.	Impulses from auriculopalpebral n. (V3)
(39)	36	• Auriculopalpebral n. (m.)		Communicates with auriculotemporal n. (V3)
(40)		•• Rostral auricular br. (m.)	Rostral auricular mm.	
(41)		•• Zygomatic br. (m.)	Orbicularis oculi, levator anguli oculi med., frontalis	Ends with palpebral br.
(42)	36	• Dorsal buccal br. (m.)	Mm. of upper lip, planum nasale, and nostril	Communicating br. (s.) with auriculotemporal n. (V3)
(43)	36	• Ventral buccal br. (m.)	Buccinator, depressor labii inferioris	Passes through vascular groove with facial a. and v.
VIII	50	Vestibulocochlear n. (special sensory)		Orig.: Medulla oblongata; enters int. acoustic pore
		• Cochlear n. (hearing)	Spiral organ of the cochlea	1st neuron: in spiral gangl. of cochlea; 2nd neuron: in rhombencephalon
		• Vestibular n. (equilibrium)	Ampullae of semicircular ducts, maculae of utriculus and sacculus	1st neuron: in vestibular gangl.; 2nd neuron in rhombencephalon
IX	48, 50	Glossopharyngeal n. (taste, s., m. psy.)	Mucosa of tongue and pharynx, tonsils, tympanic cavity	Orig.: medulla oblongata; exits skull through jugular for. Nerve of 3rd pharyngeal arch; 1st n. of vagus group
(44)	48	• Pharyngeal br. (s., m.)	Pharyngeal mucosa, caud. stylopharyngeus	Forms pharyngeal plexus with pharyngeal br. of vagus (X)
(45)		• Lingual br. (taste, s., psy.)	Mucosa of soft palate and root of tongue with its taste buds	Before it divides into dorsal and ventr. br. this n. bears the lateropharyngeal ganglion
X	48, 50	Vagus n. (s., m., psy.)	Viscera of the head, neck, thorax, and abdomen	Orig.: medulla oblongata; exits skull from jugular foramen; n. of 4th pharyngeal arch; 2nd n. of vagus group
(46)		• Auricular br. (s.)	Skin of ext. acoustic meatus	Enters the facial canal and joins the facial n. (VII)
(47)	48	• Pharyngeal br. (s., m.)	Pharyngeal mm. and mucosa	Caud. contribution to pharyngeal plexus, ends as esophageal br.
(48)	48	• Cran. laryngeal n. (s., m.)		Branches off from distal ganglion and crosses lat. to pharyngeal br.
(49)	48	•• External br. (m.)	Cricothyroideus	Joins pharyngeal br.
(50)	48	•• Internal br. (s.)	Laryngeal mucosa rostral to the rima glottidis	Passes through the thyroid fissure
	48, 60	• Recurrent laryngeal n. (s., m., psy.)	Branches to cardiac plexus, trachea, and esophagus	Separates from the vagus in the thorax and turns cranially
	48	•• Caud. laryngeal n. (s., m.)	All laryngeal mm. except cricothyroid, laryngeal mucosa caud. to rima glottidis	
XI	48, 50	Accessory n. (m.)		Exits skull through jugular for.; 3rd n. of vagus group
(51)		• Cran. root: int. br. (m.)		Orig.: medulla oblongata, joins vagus n. and gives it motor fibers
(52)		• Spinal root: ext. br. (m.)		Orig. cervical spinal cord
	48	•• Dorsal br. (m.)	Trapezius and cleidooccipitalis	
	48	•• Ventral br. (m.)	Cleidomastoideus and sternocleidomastoideus	
XII	48, 50	Hypoglossal n. (m.)	Proper lingual m., genio-, stylo-, and hyoglossus; together with ventr. br. of 1st cervical n.: genio- and thyrohyoideus	Orig.: Medulla oblongata, leaves the skull via hypoglossal canal, forms the ansa cervicalis with 1st cervical n.



Encephalon:
 ● Telencephalon
 ● Diencephalon
 ● Mesencephalon
 ● Metencephalon
 ● Myelencephalon

Legend:

- | | | | | |
|------------------------|--------------------------------|---|----------------------------|-------------------------------|
| A Cribriform plate | L Lacrimal gl. | a Olfactory region | h' Minor petrosal n. | r' Spiral gangl. of cochlea |
| B Optic canal | M Nasal gl. | b Retina | j Vallate papillae | s Sympathetic trunk |
| C Ethmoid foramen | N Palatine gl. (soft palate) | c Fungiform papillae | k Geniculate ganglion | s' Cranial cervical gangl. |
| D For. orbitotundum | N' Palatine gl. (hard palate) | d Ciliary ganglion | l Proximal ganglia | t Vagosympathetic trunk |
| E Oval foramen | O Buccal gl. | d' Short ciliary nn. | m Distal gangl. (petrosal) | u Spinal root of accessory n. |
| F Stylomastoid for. | P Monostomatic sublingual gl. | e Pterygopalatine gangl. | m' Tympanic n. | v Ansa cervicalis |
| G Int. acoustic meatus | P' Polystomatic sublingual gl. | e' Orbital br. | n Distal gangl. (nodose) | |
| H Foramen magnum | Q Mandibular gl. | e'' N. of pterygoid canal (major and deep petrosal nn.) | o Carotid glomus | |
| J Jugular foramen | R Parotid gl. | f Mandibular ganglion | p Carotid sinus | ● Special sensory neuron |
| K Hypoglossal canal | | g Trigeminal ganglion | q Vestibular n. | ● Sensory neuron |
| | | h Otic ganglion | q' Sup. vestibular gangl. | ● Parasympathetic neuron |
| | | | q'' Inf. vestibular gangl. | ● Sympathetic neuron |
| | | | r Cochlear n. | ● Motor neuron |



4. SPINAL CORD AND AUTONOMIC NERVOUS SYSTEM

Demonstration specimens are provided for the study of the spinal cord. The arches of the vertebrae and portions of the meninges have been removed to show the dorsal surface of the cord. Transverse sections are studied to see the distribution of gray and white matter, the course of the central canal, and the positions of the fiber tracts.

The following statements concern only a few specific characteristics of the ox. For the rest, the generally applicable textbook descriptions and the detailed illustrations in the neurological literature may be consulted.

a) The **SPINAL CORD (MEDULLA SPINALIS)** is surrounded by the meninges in the vertebral canal. In animals it has a greater biological importance than in man, and in the ox its mass is almost as great as that of the brain. The spinal cord presents a **cervical enlargement** and a **lumbar enlargement**. The central canal is predominantly transversely oval, as in the horse. The cord ends as the **conus medullaris (16)**, containing the sacral and caudal segments. This extends in the two-month-old calf through vert. S3, and at ten months, through vert. S2*, but in the adult the conus extends only into vert. S1. The difference is caused by the so-called “ascent of the cord,” really by the continued growth of the vertebral column after the growth of the cord has slowed. This results in a longer course of the spinal nerves within the vertebral canal before they reach their intervertebral foramina, forming the **cauda equina (18)**, which is composed of the conus medullaris, the **terminal filament (17)** of connective tissue, and the sacral and caudal nerves. The clinical importance is in the danger of injury to the cord by lumbosacral puncture. The space between the spine of vert. L6 and the sacral crest overlies the intervertebral disc and the cranial part of the body of vert. S1. In the mature ox, although the sacral segments of the cord are all in vert. L6, the caudal segments, the last lumbar nerve, the sacral nerves, and some caudal nerves are vulnerable. Epidural anesthesia is performed in the ox by injection between the first and second caudal vertebrae, and lumbosacral puncture is restricted to diagnostic withdrawal of cerebrospinal fluid.

b) **THE AUTONOMIC NERVOUS SYSTEM** includes the sympathetic part, the parasympathetic part, and the intramural intestinal plexuses.

The efferent nerve fibers:

I. The **sympathetic part** consists mainly of **efferents** with pre- and postsynaptic neurons, and also contains **afferents** with only one neuron. It is also called the thoracolumbar nervous system because the nerve cell bodies of the efferents are in the lateral horns of the corresponding segments of the spinal cord. However, the **sympathetic trunk (12)** extends farther caudally, to the first caudal vertebra, where the paired ganglia unite in the ganglion impar. The thoracolumbar body parts and organs are supplied by **relatively short communicating br.** to the ganglia of the sympathetic trunk.

1. The **thoracic organs** are supplied by **postsynaptic unmyelinated neurons** that come from the **cervicothoracic ggl. (5)** or from the **ansa subclavia (4)** or from the **middle cervical ggl. (3)** and go, e.g. as cardiac nn. or pulmonary nn., to the corresponding organs. They form with branches of the vagus n. (e.g. cardiac br. or pulmonary br.) autonomic plexuses for the thoracic organs (e.g. **cardiac plexus, 7**).

2. The **abdominal organs** are mainly supplied through the **major splanchnic n. (13)**, which leaves the sympathetic trunk at the level of vert. T10, and passes over the lumbocostal arch of the diaphragm to the **celiac ggl. and cran. mesenteric ggl. (14)**. In addition, the minor splanchnic nn. and the lumbar splanchnic nn. from the lumbar sympathetic trunk go to the **solar plexus** or to the **caud. mesenteric ggl. (15)**. The **myelinated presynaptic first neurons** come mainly without synapse through the ggl. of the sympathetic trunk,

and most of the neurons synapse first in the following **prevertebral ggl.:** **celiac ggl. (14), cran. (14), and caud. (15) mesenteric ggl.** The **unmyelinated postsynaptic second neurons** reach the areas they supply through periarterial plexuses of the visceral aa., e.g. those of the intestinal wall.

The communicating br. to the somatic thoracic and lumbar nn. (white communicating br.) synapse in the **ggl. of the sympathetic trunk (12)**, and the second neurons (gray communicating br.) conduct sympathetic impulses to those nn. The **body parts and organs (Nos. 3–6)** cranial or caudal to the thoracolumbar body segments are supplied by **relatively long (longitudinal) nerves**.

3. The **head** is supplied by efferent sympathetic neurons from the **cervicothoracic ggl.** that pass through the ansa subclavia and the middle cervical ggl. and the **vagosympathetic trunk (2)** to the **cran. cervical ggl. (1)**. This ggl. at the level of the base of the skull is the last synaptic transfer station. From here only postsynaptic unmyelinated neurons, as perivascular plexuses, reach, with blood vessels of the same name, their areas of innervation in the head (e.g. int. carotid plexus, maxillary plexus).

4. The **neck** is supplied by the **vertebral n. (11)**. It leaves the **cervicothoracic ggl.** and passes through the foramina transversaria of the cervical vertebrae as far as the third. It gives gray rami communicantes to the 2nd to 6th cervical nn.

5. The **pelvic cavity** receives sympathetic neurons over two different pathways. The dorsal path goes through the lumbar and sacral sympathetic trunk and into the **sacral splanchnic nn.** which run together with the **pelvic n. (10)** to the **pelvic plexus (9)**. The ventral path goes from the lumbar sympathetic trunk through the **lumbar splanchnic nn. (15)** to the **caud. mesenteric ggl. (15)** and over the **hypogastric n. (18)** to the mixed autonomic pelvic plexus. Here at the pelvic inlet, on the lateral wall of the rectum, is the transfer to the postsynaptic neurons which supply the pelvic organs and the descending colon.

6. The **limbs** are supplied by postganglionic unmyelinated neurons. From the **cervicothoracic ggl.** at the cran. end of the thoracic sympathetic trunk, they reach the thoracic limb, and from the caud. end of the lumbar sympathetic trunk they reach the pelvic limb. They first pass through the brachial plexus or lumbosacral plexus in the somatic nn., and more distally enter the adventitia of blood vessels.

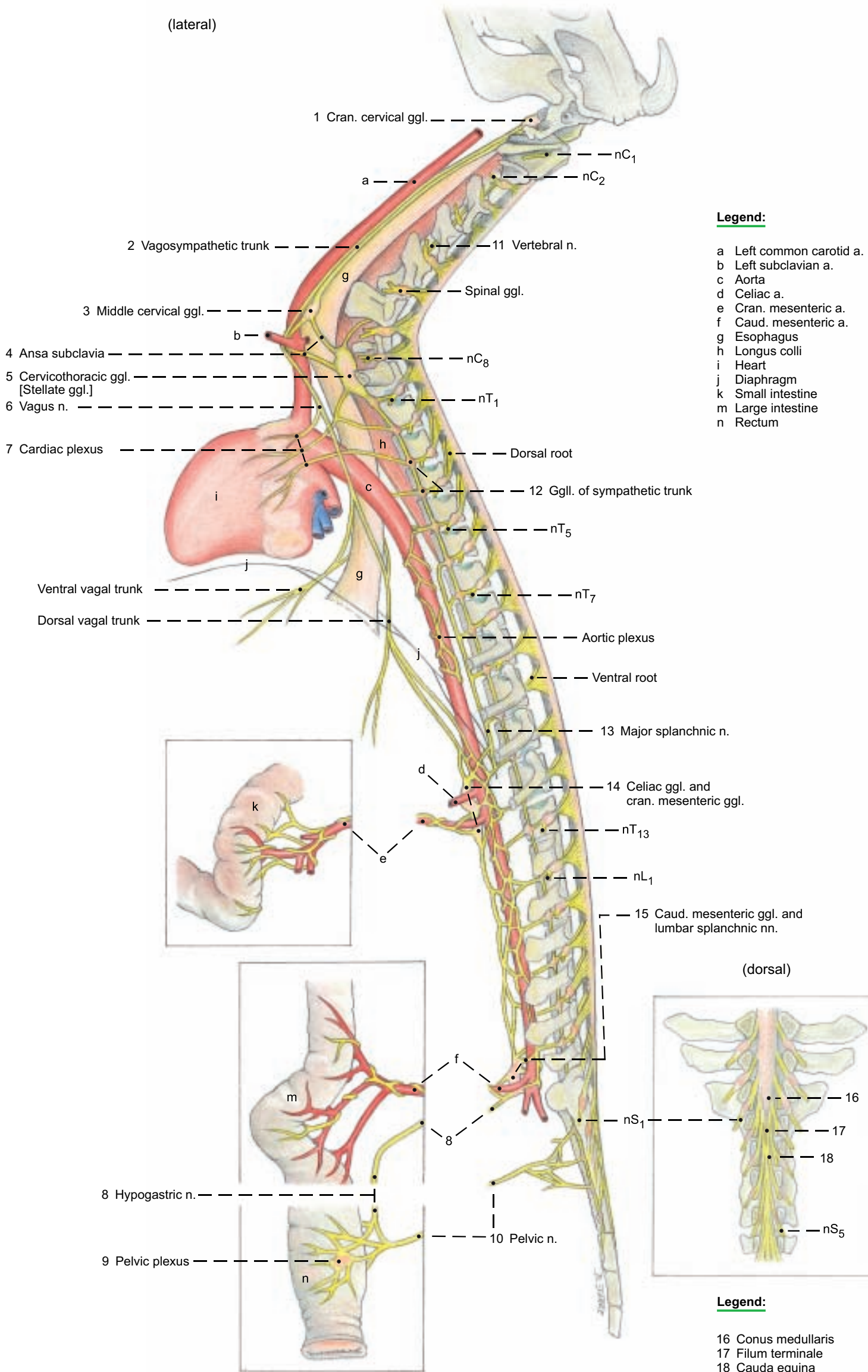
II. The **parasympathetic part** to which **cranial nn. III, VII, IX, and X** and the **pelvic n. (10)** belong, supplies with its efferents the glands and smooth muscle cells in e.g. the gut, and also in the eye and in the salivary and lacrimal ggl. The efferents are connected through two neurons in series to carry the impulse from the CNS to the target organ. In the vagus, the presynaptic axon is very long, extending from the CNS to the synapse with the second neuron in the target organ. Vagal fibers extend as far as the transverse colon. For the origin and distribution of the vagus, see pp. 48, 54, and 72.

The afferent nerve fibers:

The **sympathetic and parasympathetic nn.** contain afferents of sensory neurons that measure the contraction or distention of hollow organs and transmit pain. The vagus at the diaphragm contains more than 80 % afferent fibers. The cell bodies of the sympathetic afferents lie in the spinal ganglia, and those of the vagus are in the proximal (jugular) and distal (nodose) ganglia near the base of the skull (see p. 48).

Spinal cord and Autonomic nervous system

(lateral)



Legend:

- a Left common carotid a.
- b Left subclavian a.
- c Aorta
- d Celiac a.
- e Cran. mesenteric a.
- f Caud. mesenteric a.
- g Esophagus
- h Longus colli
- i Heart
- j Diaphragm
- k Small intestine
- m Large intestine
- n Rectum

(dorsal)

Legend:

- 16 Conus medullaris
- 17 Filum terminale
- 18 Cauda equina

CHAPTER 5: VERTEBRAL COLUMN, THORACIC SKELETON, AND NECK

1. VERTEBRAL COLUMN, LIGAMENTUM NUCHAE, RIBS, AND STERNUM

Review the basic parts of the bones on individual bones and mounted skeletons, and study the special features in the ox mentioned below.

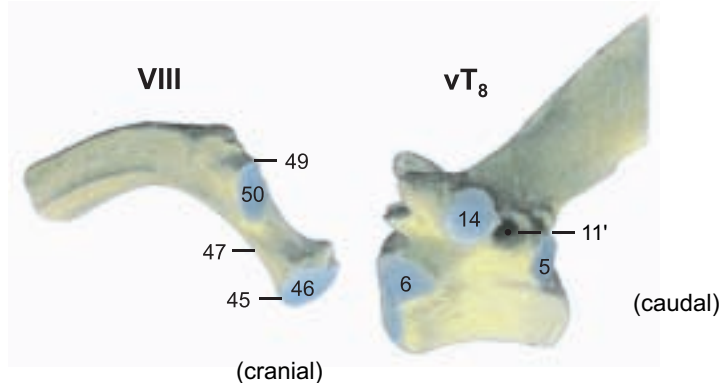
a) The **VERTEBRAL COLUMN** is composed of seven cervical vertebrae, thirteen (12–14) thoracic vertebrae, six (7) lumbar vertebrae, five sacral vertebrae, and eighteen to twenty (16–21) caudal vertebrae.

The vertebrae are joined by fibrocartilaginous intervertebral discs, and surround the **vertebral canal** (7). The basic parts: **body** (1), **arch** (8), and **processes** are developed differently according to function.

I. The cervical vertebrae (C1–C7) are generally shorter than in the horse. The **spinous process** (12) is longer than in the horse, and inclined cranially. Only on the seventh is it almost vertical, and *on the third and fourth cervical vertebrae the free end is split*. On the first, the spinous process is represented by a tubercle (29'). The **massive transverse process** (13) of the third to the fifth bears a cranial **ventral tubercle** (13') and a caudal **dorsal tubercle** (13'') as in the dog and horse. On the sixth cervical vertebra the ventral tubercle is replaced by a sagittal quadrilateral plate, the **ventral lamina** (13'). The **cranial** (16) and **caudal** (17) **articular processes** are *very small* compared to those of the horse. The **atlas** (C1) *lacks a transverse foramen* (15); the **dorsal arch** bears a large **dorsal tubercle** (29'); and the **ventral arch**, a large **ventral tubercle** (30'), *which is sometimes bifid*. The **axis** (C2) is *shorter than in the horse*; its **dens** (32) is *semicylindrical*; the spinous process (12) is a high and straight crest, but not split caudally as it is in the horse. The **lateral vertebral foramen** (31'), absent in the dog, is *very large*.

II. The thoracic vertebrae (T1–T13) have relatively long bodies compared to the dog and horse. The **spinous process** (12) of the first to the fifth thoracic vertebra is broad with sharp cranial and caudal borders, and provided on the free end with a cartilaginous cap until about the third year. These ossify by the eighth year. The **withers (interscapular region)** is *not as high as in the horse*. The seventh to eleventh thoracic spines are strongly inclined caudally. *The spine is vertical on the last thoracic (anticlinal) vertebra. In most thoracic vertebrae the caudal vertebral notch (11) is closed by a bridge of bone to form a lateral vertebral foramen (11')*. The **mamillary processes** (20) are not very prominent; on the last two thoracic vertebrae they merge with the **cranial articular processes** (16).

Costovertebral articulations



III. The lumbar vertebrae (L1–L6) have a *long body* and a *flat arch* with an *almost square, cranially and caudally extended, spinous process* (12). The horizontal **transverse processes** (13) are *curved cranially* and separated by wide spaces. The cranial lumbar vertebrae often have *lateral vertebral foramina* as in the thoracic vertebrae. The mamillary processes are always fused with the cranial articular processes.

IV. The sacral vertebrae (S1–S5) are completely fused to form the **sacrum** after 3–4 years. Depending on breed, the sacrum is more or less arched dorsally. Ventrally it has a distinct groove for the median sacral artery. The spinous processes are fused to form a **median sacral crest** (35) (as in the dog, but unlike the horse) with an occasional interruption between the fourth and fifth vertebrae. The **sacral promontory** (38) is the cranial ventral prominence of the first sacral vertebra. It is palpable per rectum. The *auricular surfaces of the alae face caudodorsally*. The fused articular processes form a ridge, the **intermediate sacral crest** (37), *which bridges over the narrow dorsal sacral foramina (39), and lies medial to the last sacral foramen. This is very large and not divided into dorsal (39) and ventral (40) foramina because the last two transverse processes are not completely fused*.

V. The caudal [coccygeal] vertebrae (Cd1+) and their processes are significantly larger and better developed than in the horse. The progressively narrowing **vertebral canal** (7) *extends to the fifth caudal vertebra*. The paired **hemal processes** (21) (present as in the dog, unlike the horse) *may be closed to form hemal arches (22) from the second to the fifth caudal vertebra*.

b) Of the thirteen **RIBS**, eight are **sternal ribs** (41) and five are **asternal** (42). They increase in length to the tenth rib and, especially in the middle of the thorax, they are *flat toward the sternal end with sharp caudal borders, and wider than in the dog and horse*, whereby the intercostal spaces become narrower. The **head** (45) and the **tubercle** (49) are well developed and separated by a long **neck** (47). The **knee [genu costae, 53]** *is at the costochondral junction*.

c) The body of the **STERNUM**, formed by five **sternebrae** (56), is *slightly arched dorsally and flattened dorsoventrally*. The **triangular manubrium sterni** (54) *is raised craniodorsally and has no manubrial cartilage. It is attached to the body of the sternum by a true joint*. The **xiphoid process** (57) is smaller than in the horse. A sternal crest is absent, as in the dog.

d) The elastic **NUCHAL LIGAMENT** is generally better developed than in the dog and horse. It consists of a paired **funiculus** (A) and a **lamina** (B), which is paired in the cranial part and unpaired in the caudal part.

The funiculus is divided into right and left halves attached to the external occipital protuberance. They extend, without attachment to the cervical vertebrae, to the withers, and become gradually wider to form the sagittally positioned, flat, wide parts *lateral to the first to fifth thoracic spinous processes, but not capping them*. The *wide parts gradually become narrower and unite to form the supraspinous ligament* (C), which extends to the sacrum. It is elastic cranially, but becomes collagenous in the midlumbar region. The lamina arises with its cranial paired part from spinous processes C2–C4 and fuses with the funiculus. The caudal unpaired part, *also elastic*, which in the horse is thin and contains few elastic fibers, arises from vertebrae C5–C7 and terminates on the first thoracic spinous process under the wide parts of the funiculus. A **supraspinous bursa** may be present between the first few thoracic spines and the wide parts of the funiculus.

Vertebral column, Thoracic skeleton, and Nuchal ligament

Vertebral column and Bones of the thorax

- Cervical vertebrae (C1–C7)
- Thoracic vertebrae (T1–T13, 14)
- Lumbar vertebrae (L1–L6)
- Sacral vertebrae (S1–S5)
- Caudal [Coccygeal] vertebrae (Cd1–Cd16, 21)
- Body of vertebra (1)
- Ventral crest (2)
- Cranial end (3)
- Caudal end (4)
- Caud. costal fovea (5)
- Cran. costal fovea (6)
- Vertebral canal (7)
- Vertebral arch (8)
- Intervertebral foramen (9):
- Cran. vertebral notch (10)
- Caud. vertebral notch (11)
- Lat. vertebral foramen (11')
- Spinous process (12)
- Transverse process (13)
- Ventral tubercle (C3–C5) (13') [Ventral lamina C6]
- Dorsal tubercle (C3–C5) (13'')
- Costal fovea (T1–T13) (14)
- Transverse foramen (C2–C6) (15)
- Cran. articular process (16)
- Caud. articular process (17)
- Costal process (18)
- [Transverse proc.] (L1–L6)
- [Ventr. tubercle] (C3–C5)
- Mamillary process (T+Cd) (20)
- Hemal process (Cd2–Cd15) (21)
- Hemal arch (Cd4 + Cd5) (22)
- Intercuate space:
- Lumbosacral (23)
- Sacrococcygeal (24)

Atlas [C1]

- Lateral mass
- Transverse proc. [Wing of atlas, Ala] (26)
- Alar foramen (27)
- Lat. vertebral foramen (28)
- Dorsal arch (29)
- Dorsal tubercle (29')
- Ventral arch (30)
- Ventral tubercle (30')

Axis [C2]

- Lat. vertebral foramen (31')
- Dens (32)

Sacrum [S1–S5]

- Wing [Ala] of sacrum (33)
- Median sacral crest (35)
- Lat. sacral crest (36)
- Intermediate sacral crest (37)
- Promontory (38)
- Dorsal sacral foramen (39)
- Ventral sacral foramen (40)

Ribs [Costae]

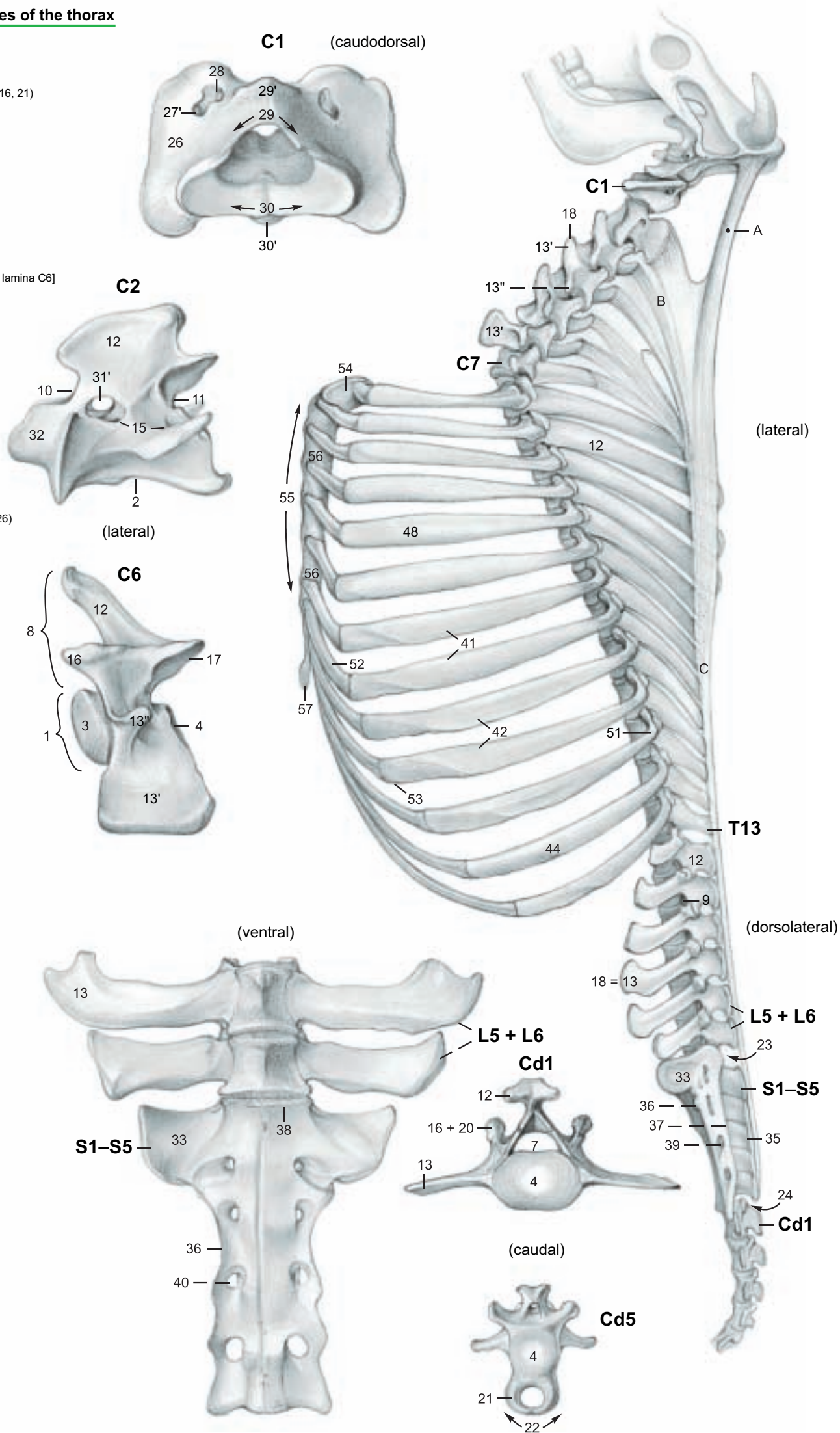
- Sternal ribs (41)
- Asternal ribs (42)
- Costal bone [Os costale] (44)
- Head of rib (45)
- Artic. surface of head (46)
- Neck of rib (47)
- Body of rib (48)
- Costal tubercle (49)
- Artic. surf. of tubercle (50)
- Angle of rib (51)
- Costal cartilage (52)
- Knee of rib [Genu costae] (53)

Sternum

- Manubrium (54)
- Body of sternum (55)
- Sternebrae (56)
- Xiphoid process (57)

Legend:

- Nuchal ligament:
- A Funiculus nuchae
- B Lamina nuchae
- C Supraspinous lig.



2. NECK AND CUTANEOUS MUSCLES

A dorsomedian skin incision is made from the skull to the level of the last rib, and laterally along the last rib to its costochondral junction. A skin incision from the cranial end of the first incision is directed ventrally behind the base of the ear and across the angle of the mandible to the ventromedian line. The skin is reflected ventrally, sparing the cutaneous muscles, ext. jugular v., and cutaneous nerves, and continuing to the ventromedian line of the neck, on the lateral surface of the limb to the level of the sternum, and to a line extending from the axilla to the last costochondral junction. This flap of skin is removed. Note the dewlap [Paelear], a breed-variable ventromedian fold of skin on the neck and presternal region.

a) Of the **CUTANEOUS MUSCLES**, the *cutaneus colli* is thin and often impossible to demonstrate. It originates from the ventro-median cervical fascia. The **cutaneus trunci** resembles that of the horse; whereas the cranially attached **cutaneus omobranchialis**, absent in the dog, is thinner than in the horse, and occasionally unconnected to the *cutaneus trunci*. For the preputial muscles, see p.66.

b) The SUPERFICIAL SHOULDER GIRDLE MUSCLES (TRUNK—THORACIC LIMB MUSCLES):

The **trapezius** with its **cervical part (11)** and **thoracic part (11')** is significantly better developed than in the horse. This fan-shaped muscle originates from the funicular nuchal lig. and supraspinous lig. between the atlas and the 12th (10th) thoracic vertebra and ends on the spine of the scapula. The cervical part is connected ventrally to the **omotransversarius (8)**, which, as in the dog, extends between the acromion and the transverse process of the atlas (axis), where it is fused with the tendon of the splenius. The **brachiocephalicus** consists of the **cleidobrachialis** (clavicular part of deltoideus, p. 4) and the **cleidocephalicus**. The two parts of the latter in the ox are the **cleido-occipitalis** and the **cleidomastoideus**. The **cleido-occipitalis (7)**, and the **cleidomastoideus**, originate from the clavicular intersection—an indistinct line of connective tissue across the **brachiocephalicus** cranial to the shoulder joint. The **cleido-occipitalis** is joined to the **cleidomastoideus** as far as the middle of the neck, separates from it, adjoins the ventrocranial border of the **trapezius**, and ends on the funicular nuchal lig. and occipital bone. The **cleidomastoideus (6)** lies ventral to the **cleidooccipitalis**, is partially covered by it, and ends as a thin muscle with a slender tendon on the mastoid process and the tendon of the **longus capitis**. The **sternocephalicus** consists of the **sternomastoideus** and **sternomandibularis**.

The **sternomastoideus mm. (4)** originate from the the manubrium sterni only, are fused in the caudal third of the neck, and terminate in common with the **cleidomastoideus**. The **sternomandibularis (5)** originates laterally from the manubrium and from the first rib; and, crossing the **sternomastoideus**, runs ventral to the jugular groove and ends with a thin tendon on the rostral border of the masseter and aponeurotically on the mandible and the depressor labii inferioris. The **sternomastoideus** and **cleidomastoideus** are homologous to the human sternocleidomastoideus.

The **latissimus dorsi (12)** arises from the thoracolumbar fascia and from the 11th and 12th ribs. The fibers run cranioventrally to a common termination with the **teres major** and an aponeurotic connection with the **coracobrachialis** and **deep pectoral** as well as the long head of the **triceps**.

Of the **superficial pectoral muscles**, the **flat transverse pectoral (25')** originates from the sternum and ends on the medial deep fascia of the forearm. The **descending pectoral (25)** is a thick muscle originating from the manubrium and ending with the **brachiocephalicus** on the crest of the humerus. It is not as visible under the skin as in the horse.

c) **JUGULAR GROOVE AND LATERAL PECTORAL GROOVE:** The **jugular groove** is bounded dorsally by the **cleidomastoideus**, ventrally by the **sternomandibularis**, and, in the cranial half of the neck, medially by the **sternomastoideus**. The **ext. jugular vein (3)** lies in the groove. At the junction of the head and neck it bifurcates, giving rise to the **maxillary (2)** and **linguofacial (1)** veins. At the thoracic inlet it gives off a dorsal branch, the **superficial cervical vein (21)**; and gives off the **cephalic vein (10)** to the lateral pectoral groove between the **brachiocephalicus** and the **descending pectoral muscle**.

3. DEEP SHOULDER GIRDLE MUSCLES, VISCERA AND CONDUCTING STRUCTURES OF THE NECK

The superficial shoulder girdle muscles and the **sternomastoideus** and **sternomandibularis** are transected near their attachments on the limb and sternum and removed, leaving short stumps. The accessory n. (c) and the roots of the phrenic nerve (C5 to C7, q) must be spared in the dissection.

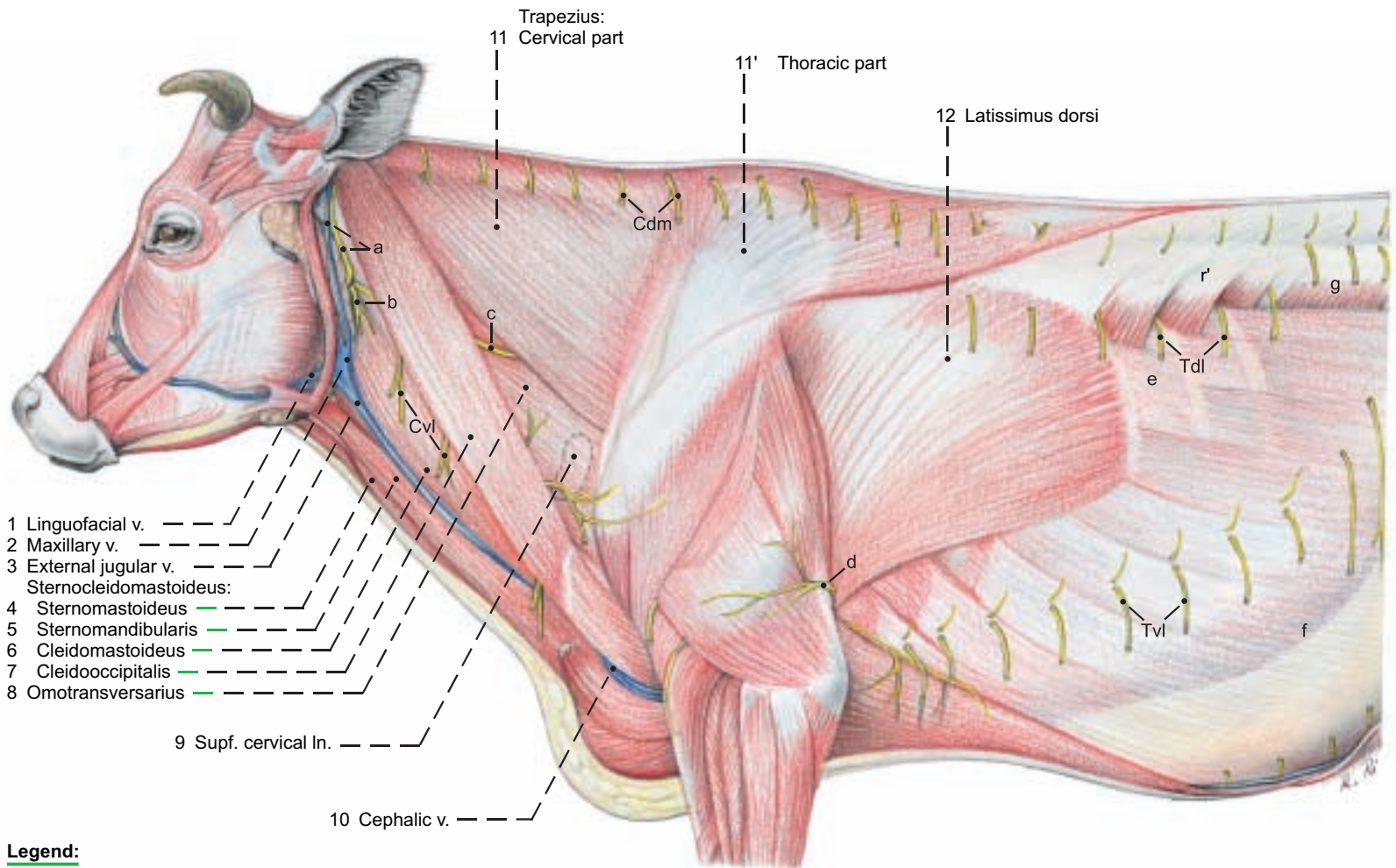
a) **DEEP SHOULDER GIRDLE MUSCLES:** The **rhomboideus** consists of the **rhomboideus cervicis (28)** and **thoracis (28')** but no **rhomboideus capitis**, unlike the dog. These are covered by the **trapezius**, originate from the funicular nuchal lig. and supraspinous lig. between C2 and T7 (T8), and terminate on the medial surface of the scapular cartilage. The **deep pectoral (26 and p. 5, t)** is a strong unified muscle which ends primarily on the major and minor tubercles. A branch of the tendon fuses with the **latissimus dorsi** and ends on the tendon of origin of the **coracobrachialis**. The **subclavius (26')**, absent in the dog, is not well developed. It extends from the first costal cartilage to the deep surface of the clavicular intersection. The **serratus ventralis** extends from the 2nd (3rd) cervical vertebra to the 9th rib, and is clearly divided into **serratus ventralis cervicis (27)** and **thoracis**. The **serratus ventralis thoracis (27')** arises by distinct muscle slips and is interspersed with strong tendinous layers. It is attached not only to the **facies serrata** of the scapula, but penetrates with a thick broad tendon between the parts of the **subscapularis** to end in the **subscapular fossa**.

b) **LONG HYOID MUSCLES:** The **sternohyoideus (14)**, **sternothyroideus (15)**, and **omohyoideus** do not belong to the shoulder girdle muscles, but are long muscles of the hyoid bone and thyroid cartilage. The first two resemble those of the horse, but do not have a tendinous intersection; they are, however, connected by a tendinous band in the middle of the neck. The **omohyoideus (13)** is thin and does not come from the shoulder, but from the deep cervical fascia, and thereby indirectly from the transverse processes of the 3rd and 4th cervical vertebrae. In the angle between the **sternomastoideus** and **sternomandibularis**, and crossed laterally by the **external jugular vein**, it passes medially under the **mandibular gland** to end with the **sternohyoideus** on the **basihyoid**.

c) **VISCERA AND CONDUCTING STRUCTURES OF THE NECK:** In the middle of the space for the viscera and conducting structures is the **trachea (19)**. In life the **tracheal cartilages** are arched to give it a vertical oval section, but after death it has a tear-drop shape. Dorsolateral to the trachea is the **common carotid artery (16)**, with the **vagosympathetic trunk (17)**. The latter is accompanied by the small **int. jugular v.** This may be absent. The **esophagus (18)** is dorsal in the first third of the neck; in the other two thirds it is on the left side of the trachea and at the thoracic inlet it is dorsolateral. The **left recurrent n. (18)** accompanies the **esophagus** ventrally; the **right recurrent n.** accompanies the **trachea** dorsolaterally.

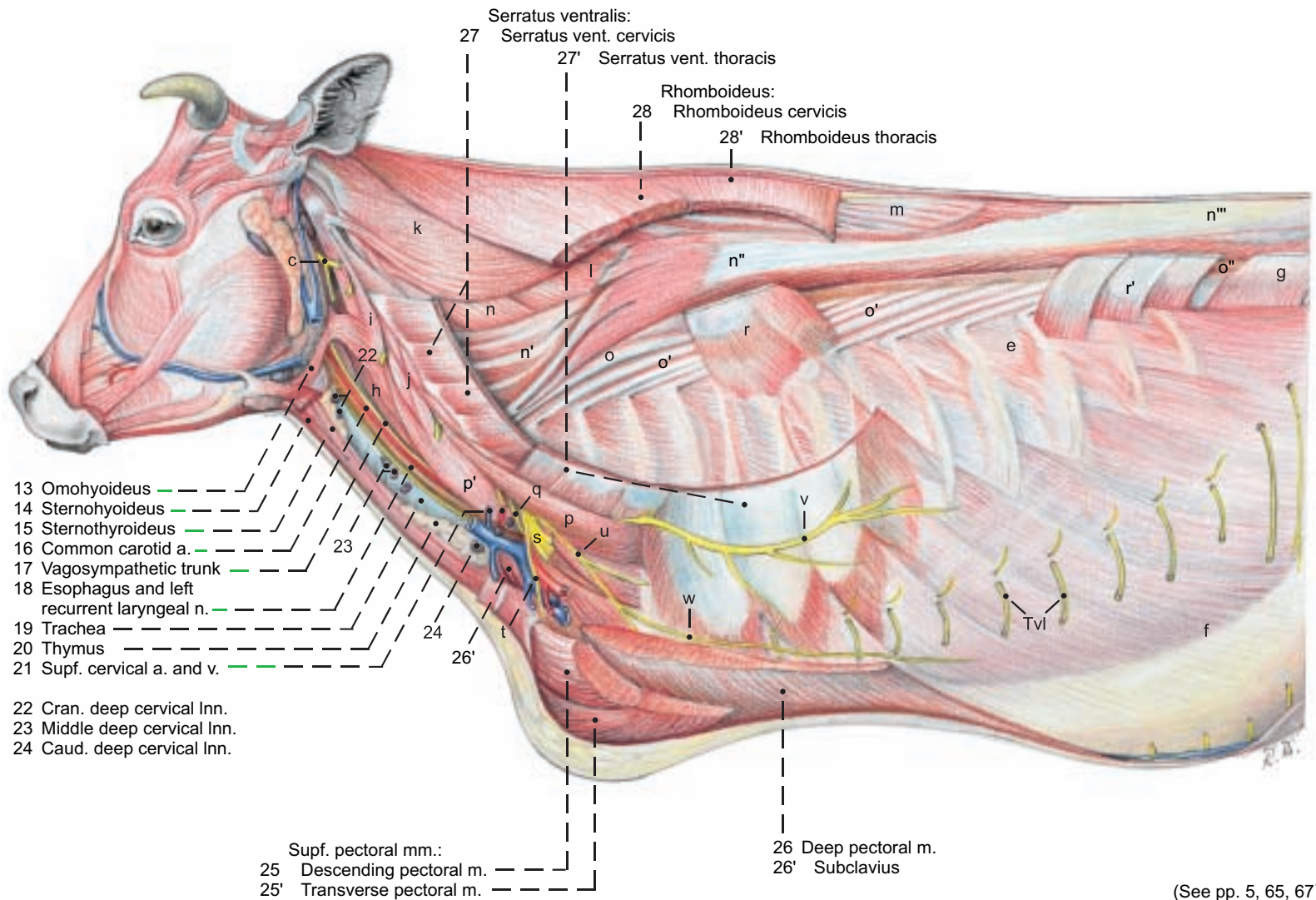
d) **LYMPHATIC SYSTEM AND THYMUS:** The **superficial cervical lymph node (9)** lies in the groove cranial to the **supraspinatus**, covered by the **omotransversarius** and **cleido-occipitalis**. It receives lymph from the neck, thoracic limb, and thoracic wall back to the 12th rib. Its efferent lymphatics go to the **tracheal trunk**; on the left, also to the **thoracic duct**. The **cranial deep cervical lnn. (22)** lie near the thyroid gland; the **middle deep cervical lnn. (23)**, in the middle third of the neck on the right of the trachea and on the left of the esophagus. The **caudal deep cervical lnn. (24)** are placed around the trachea near the first rib. They receive lymph from the cervical viscera, ventral cervical muscles and preceding lymph nodes of the head, neck, and thoracic limb. (See the table of lymph nodes.) Some of their efferents have the same termination as those of the superficial cervical lnn.; others end in the cran. vena cava. The **thymus (20)** is fully developed only in the fetus. It consists of an **unpaired left thoracic part** (may be maintained to six years of age), a V-shaped paired cervical part with the unpaired apex directed toward the thoracic cavity, and a paired cranial part (already retrogressed at birth).

Regions of the neck and chest



Legend:

- | | | | | |
|---|---------------------------------------|---|---------------------------|----------------------------|
| a Great auricular n. and caud. auricular v. | g Internal oblique abd. m. | m Spinalis et semispinalis thoracis et cervicis | llicostalis: | q C6 root of phrenic n. |
| b Transverse n. of the neck | h Longus capitis | Longissimus: | o Iliocostalis cervicis | r Serratus dors. cranialis |
| c Accessory n. | i Intertransversarius longus | n Longissimus capitis et atlantis | o' Iliocostalis thoracis | r' Serratus dors. caudalis |
| d Intercostobrachial n. | j Ventral cervical intertransversarii | n' Longissimus cervicis | o'' Iliocostalis lumborum | s Brachial plexus |
| e External intercostal mm. | k Splenius | n'' Longissimus thoracis | Scalenus: | t Cran. pectoral nn. |
| f External oblique abd. m. | l Semispinalis capitis | n''' Longissimus lumborum | p Scalenus dorsalis | u Caud. pectoral nn. |
| | | | p' Scalenus ventralis | v Long thoracic n. |
| | | | | w Lat. thoracic n. |



(See pp. 5, 65, 67)

CHAPTER 6: THORACIC CAVITY

1. RESPIRATORY MUSCLES AND THORACIC CAVITY WITH LUNGS

The deep shoulder girdle muscles and the vessels and nerves of the limb, with attention to their roots, are cut as close as possible to the thoracic wall, and the limb is removed. The **diaphragmatic line of pleural reflection**, where the costal pleura is reflected as the diaphragmatic pleura, is clinically important as the caudoventral boundary of the pleural cavity. In the dorsal end of the 11th intercostal space, a small opening is made through the intercostal muscles into the pleural cavity; then the caudoventral limits of the **costodiaphragmatic recess (7)** are probed and marked on the ribs as the intercostal muscles are removed. The line extends from the knee of the 7th or 8th rib, through the middle of the 11th, to the angle of the 13th rib at the lateral border of the muscles of the back. The **basal border of the lung** is also marked on the ribs. After study of the **lung field**, the ribs, with the exception of the 3rd, 6th, and 13th, are cut above the line of pleural reflection and removed, sparing the diaphragm and noting the slips of origin of the ext. oblique abdominal muscle.

a) The **RESPIRATORY MUSCLES** (see appendix on myology) belong partly to the muscles of the back and partly to those of the thorax. They function as **expiratory muscles** in the contraction of the thorax or as **inspiratory muscles** in the expansion of it. The obligate respiratory muscles are aided by the auxiliary respiratory muscles. The **diaphragm** is the primary respiratory muscle and the partition between the thoracic and abdominal cavities.

The **line of diaphragmatic attachment** rises steeply, running across the ribs from the knee of the 8th, across the 11th rib below its middle to the vertebral end of the 13th rib. In ruminants the two **costal parts (3)** of the diaphragm are clearly separated from the 13–15 cm wide **sternal part (not illustrated)** by clefts between muscle fibers. The **lumbar part (2)** resembles that of the horse in its relation to the aortic hiatus and esophageal hiatus, but sends muscle fiber bundles from the right and left crura, sometimes with fibrocartilaginous inlays, to the foramen venae cavae (5). This lies on the right in a relatively large **tendinous center (4)**, which on inspiration is at the level of the 7th rib.

b) The **THORACIC CAVITY** is protected by the bony thoracic cage [thorax] and extends from the especially narrow cranial thoracic aperture [thoracic inlet] to the diaphragm. It contains the two **pleural cavities** of unequal size. The pleural sacs project into the thoracic inlet as the **cupulae pleurae (15)**. The left one does not extend beyond the first rib. The right one projects 4–5 cm cranial to the first rib. The **parietal pleura** includes the **costal pleura (6)**, **diaphragmatic pleura (8)**, and the **mediastinal pleura (16)**, where right and left pleural sacs adjoin and where they cover the **pericardium** as **pericardial pleura (18)**. The **visceral pleura** covers the lungs as the **pulmonary pleura**, which is connected to the mediastinal pleura by the short pulmonary ligament. This is present only in the caudal area. The **mediastinal recess (9)** is a diverticulum of the right pleural cavity containing the accessory lobe of the right lung.

The **costodiaphragmatic recess (7)** is the potential space between the **basal border of the lung** and the **diaphragmatic line of pleural reflection**. The latter runs slightly craniodorsal to the line of diaphragmatic attachment, dipping ventrally at every intercostal space.

c) The **MEDIASTINUM** is thicker than in the horse. The heart occupies the **middle mediastinum** and divides the rest of the mediastinum into **cranial (16)**, **caudal**, **dorsal**, and **ventral parts**. The mediastinum is composed of the two mediastinal pleural layers and the fibrous substantia propria between them. It encloses the usual organs and structures: the esophagus, trachea, blood and lymph vessels, lymph nodes, nerves, and the pericardium. The **cranial mediastinum** is pushed against the left thoracic wall in the first and second intercostal spaces, ventral to the great vessels, by the **cranial lobe of the right lung**. The **caudal mediastinum**, containing the left **phrenic nerve**, is attached to the left side of the diaphragm. Together with a fold on the right, the **plica venae cavae (h)**, they enclose the **mediastinal recess (9)**, containing the accessory lobe of the right lung. *Perforations of the mediastinum, allowing communication between right and left pleural cavities, as described in the dog and horse, do not occur in the ox.*

d) The **LUNGS** are accessible for percussion and auscultation in a **cranial and a caudal lung field**. The total area is relatively small.

The **cranial lung field** is of lesser significance for clinical examination. It lies cranial to the thoracic limb in the first three intercostal spaces. The **caudal lung field** is bounded cranially by the tricipital line and dorsally by the muscles of the back. The **basal border** as determined by percussion or auscultation is 3–4 cm above the actual border of the lung, which is too thin for clinical examination. It is *almost straight in contrast to the curvature in the dog and horse*. It intersects the cranial border at the knee of the 6th rib. In the 7th intercostal space it intersects the dorsal plane through the shoulder joint. In the 11th space it meets the dorsal border.

The **right lung** is considerably larger than the left lung. The interlobar and intralobar fissures are distinctly marked so that both the **right and left cranial lobes** are divided into **cranial (19)** and **caudal (20) parts**, unlike the dog and horse. In addition to the **caudal lobe (30)** of both lungs, the right lung has an **accessory lobe (29)**, as in all domestic mammals, and a **middle lobe (23)**, absent in the horse. *In addition, the right cranial lobe has a special tracheal bronchus (22) that comes from the trachea cranial to the bifurcation (26). Also, the bovine lung has a distinctly visible lobular structure outlined by an increase in the amount of connective tissue.*

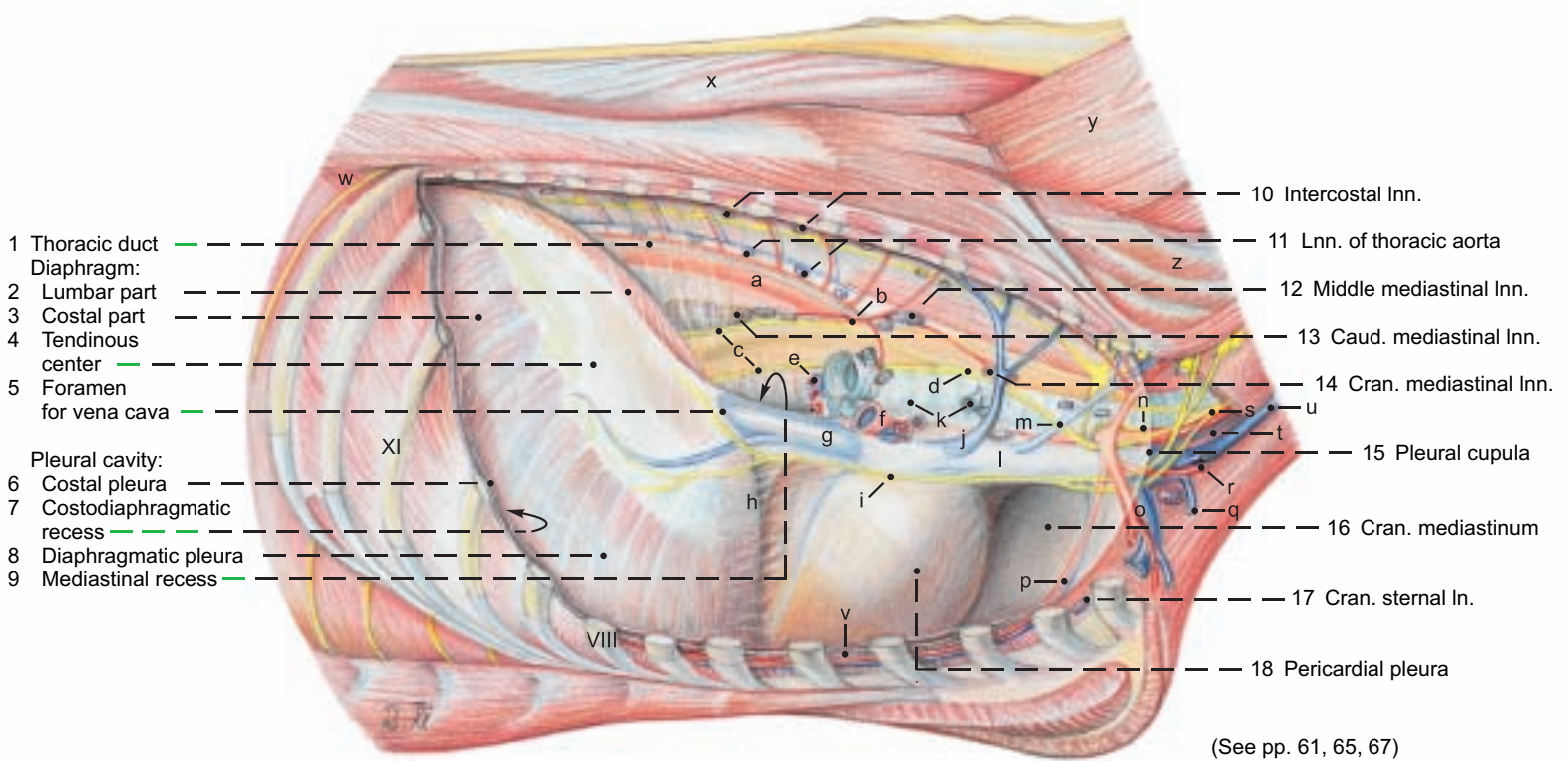
e) The **LYMPHATIC SYSTEM** is not only clinically important (as in the dog and especially in the horse), but also of great practical interest in meat inspection; therefore a knowledge of it is indispensable. (See the appendix on the lymphatic system.) *Lymph nodes routinely examined in meat inspection are: the left (24), middle (27), and cranial (21) tracheobronchial lnn., the latter lying cranial to the origin of the tracheal bronchus; and the small, inconstant right tracheobronchial lnn. (25), called the supervisor's node. Routinely palpated for enlargement are the pulmonary lnn. (28) concealed in the lung near the main bronchi. Also routinely examined are the cranial (14), middle (12), and caudal (13) mediastinal lnn. The latter consist of a group of small nodes between the esophagus and aorta and one 15–25 cm long ln. that extends dorsal to the esophagus to the diaphragm and drains a large area on both sides of the latter. Finally, included in the routine examination are the thoracic aortic lnn. (11) dorsal to the aorta and medial to the sympathetic trunk.*

In special cases the following are examined: the intercostal lnn. (10) lateral to the sympathetic trunk, and the cranial sternal ln. (17) dorsal to the manubrium sterni and ventral to the internal thoracic vessels.

The caudal sternal lnn. and the **phrenic ln. on the thoracic side of the foramen venae cavae** are unimportant for meat inspection.

Most of the lymphatic drainage passes through the mediastinal lnn. and the terminal part of the tracheal duct, as well as the thoracic duct (1), which does not go through the aortic hiatus, but through the right crus of the diaphragm. At T5 it crosses to the left side of the esophagus and trachea. It may be enlarged to form an ampulla before it opens into the jugular trunk.

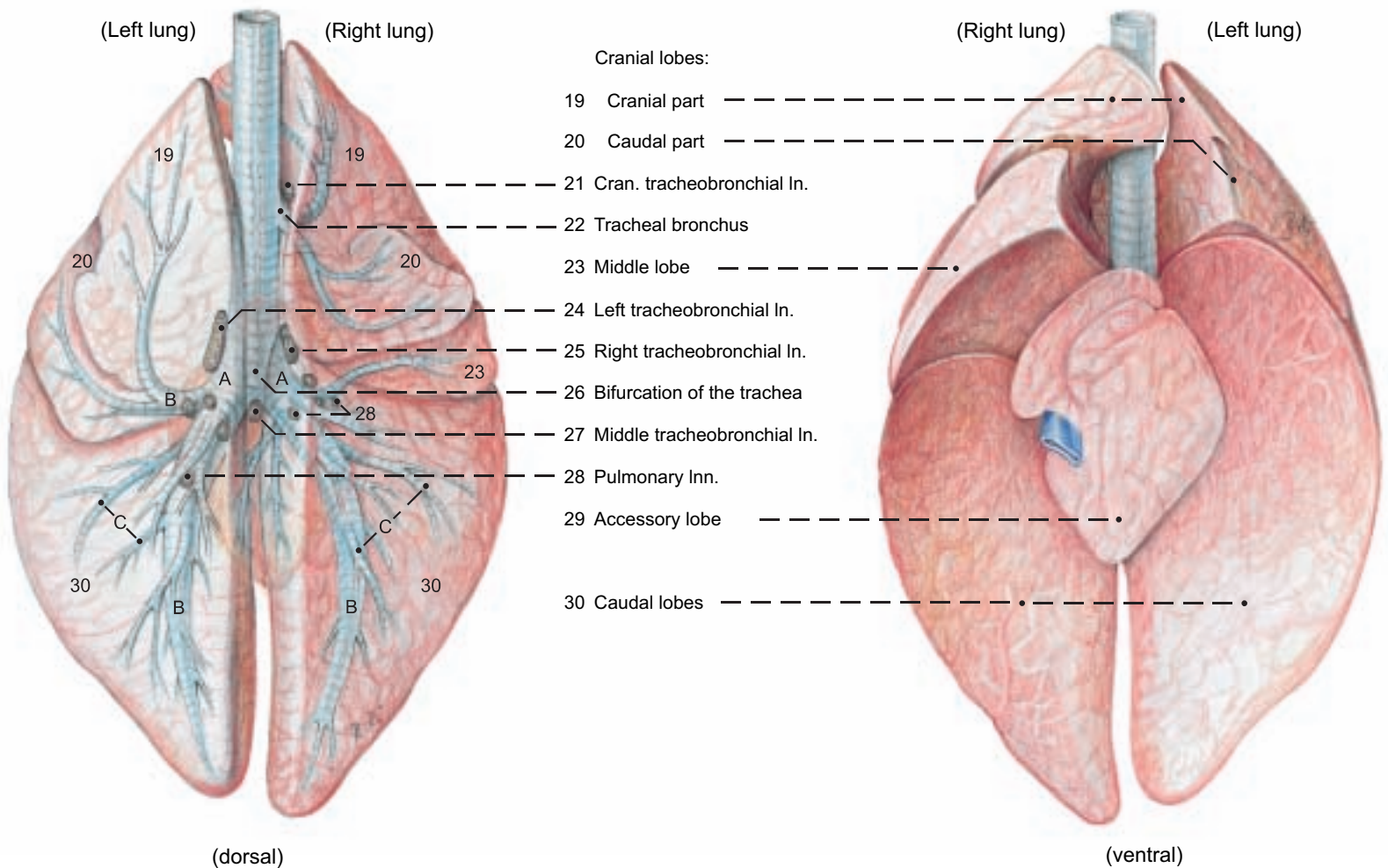
Right thoracic cavity and Lungs



Legend:

A Main bronchus	d Right vagus n.	j Right azygos v.	p Internal thoracic a. and v.	v Transverse thoracic m.
B Lobar bronchus	e Pulmonary vv.	k Trachea and tracheal bronchus	q Cephalic v.	w Retractor costae
C Segmental bronchus	f Pulmonary a.	l Cran. vena cava	r Supf. cervical a. and v.	x Spinalis et semispinalis cervicis et capitis
a Thoracic aorta	g Caud. vena cava	m Costocervical v.	s Vagosympathetic trunk	y Semispinalis capitis
b Bronchoesophageal a.	h Plica venae cavae	n Right recurrent laryngeal n.	t Common carotid a. and internal jugular v.	z Longissimus cervicis
c Dors. and vent. vagal trunks	i Phrenic n.	o Right subclavian a. and v.	u External jugular v.	

Lungs and Bronchial Inn.



2. HEART, BLOOD VESSELS, AND NERVES OF THE THORACIC CAVITY

The surface of the heart is studied *in situ*; the internal relations are studied on isolated hearts. The visible blood vessels and nerves are identified.

a) The **HEART (COR)** is relatively small in comparison to that of the horse. Its weight varies between 0.4 and 0.5 percent of the body weight. Its absolute weight in cows averages 2.4 kg and in bulls 2.6 kg.

The **heart is located** between the planes of the 3rd and 5th intercostal spaces in the ventral half of the thoracic cavity. The inclination of the **cardiac axis** is relatively steep, with the **base** of the heart directed craniodorsally. The **apex (x)** of the heart is directed caudoventrally, but does not reach the sternum. The greater part of the heart lies on the left of the median plane and brings the pericardium into contact with the left thoracic wall in the 3rd and 4th intercostal spaces. Its **left ventricular border (w)** presses the pericardium into contact with the left side of the diaphragm close to the median plane, and *this is clinically significant because of the proximity of the reticulum, with its penetrating hardware*. The **heart field**, clinically important for auscultation and percussion, is an outline of the heart projected on the left thoracic wall from the 3rd to the 5th intercostal space. On the surface of the heart in addition to the **paraconal (16)** and **subsinuosal (18)** **interventricular grooves**, there is an **intermediate groove on the left ventricular border that does not reach the apex**. Also species-specific are the distinctly **dentate margins of the auricles**, which overhang the base of the heart, but are smaller than those of the horse. The **friable white structural fat (suet)** that can make up as much as 24 percent of the weight of the heart lies in four interconnected lobes **on the right and left atria between the great vessels and in the coronary grooves**.

The **pericardium** is attached by two divergent **sternopericardiac ligaments (14)** to the sternum at the level of the notches for the 6th costal cartilages.

Of the **coronary arteries**, the **left coronary a. (15)** is *substantially larger (left coronary supply type as in the dog, but unlike the horse and pig)*. It gives off the **paraconal interventricular branch (16)** in the groove of the same name, as well as the **circumflex branch (17)** which runs around the caudal surface of the heart in the coronary groove, and ends as the **subsinuosal interventricular branch (18)** in the groove of the same name. The small **right coronary a. (19)** takes a circumflex course in the **coronary groove** between the right atrium and ventricle.

The **heart bones** are remarkable features of the **heart skeleton**—the fibrous rings around and between the valves. *The large, 3–6 cm, three-pronged right heart bone (g) and the small, 2 cm, left heart bone (g')* are in the aortic ring.

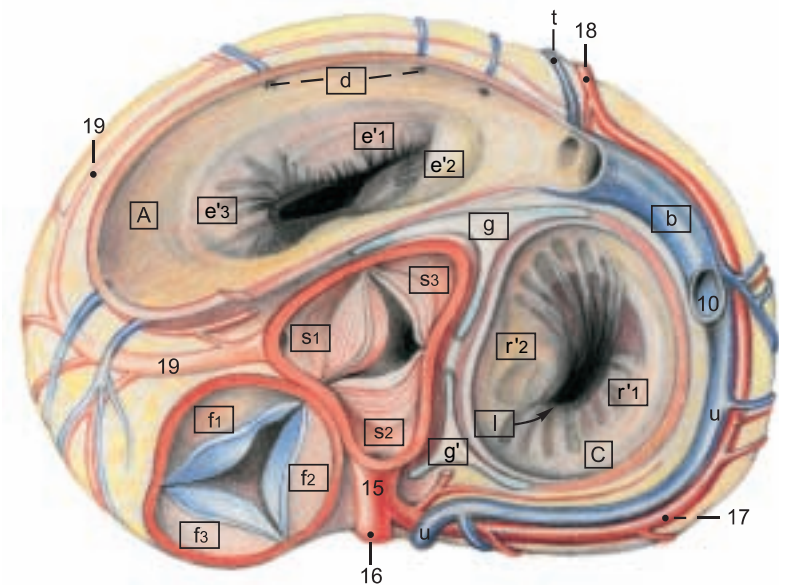
b) The remaining **BLOOD VESSELS** show greater differences from the dog than from the horse.

The first branch of the **aortic arch**, as in the horse, is the **brachiocephalic trunk (13)**, the common trunk of the vessels to cranial parts of the thorax, to the thoracic limbs, and to the head and neck. It gives off first the left subclavian a., then the right subclavian a., and continues as the **bicarotid trunk** for the **left (4)** and **right (see p. 63) common carotid aa.** The **left (6)** and **right (see p. 63) subclavian aa.** give off cranially the **costocervical trunk (3)** for vessels to the vertebrae, spinal cord, and brain (**vertebral a. 2**); to the neck (**deep cervical a., 2** and **dorsal scapular a., 1**); and to the ribs (**supreme intercostal a.**, which can also originate from the subclavian a. or the aorta). Dorsocranially the subclavian gives off the **superficial cervical a. (5)**, and caudally, the **internal thoracic a. (7)**, which is the last branch before the subclavian turns around the first rib and becomes the axillary a. The **thoracic aorta (8)** gives off dorsal intercostal aa. and on the right, dorsal to the base of the heart, the **bronchoesophageal a.**, whose **bronchial (12)** and **esophageal (11)** branches may originate as separate arteries from the aorta or an intercostal a. The tracheal bronchus is supplied by its own branch, either from the aorta or from the bronchial branch.

The **veins** show a distribution similar to that of the arteries. A **right azygos v.**, (see p. 63), present in the dog and horse, is *only rarely developed as far as the last thoracic vertebra in the ox, and may be absent caudal to the 5th dorsal intercostal v.* The **left azygos v. (10)** is always present. It drains into the coronary sinus of the right atrium. It does not occur in the dog and horse.

c) The **NERVES** in the thoracic cavity are the same as in the dog and horse. The **greater splanchnic n. takes origin from the sympathetic trunk (9) at the 6th to 10th ganglia**, unlike the dog and horse, and separates from the trunk just before they pass over the diaphragm in the **lumbocostal arch**.

Section through the Base of the Heart

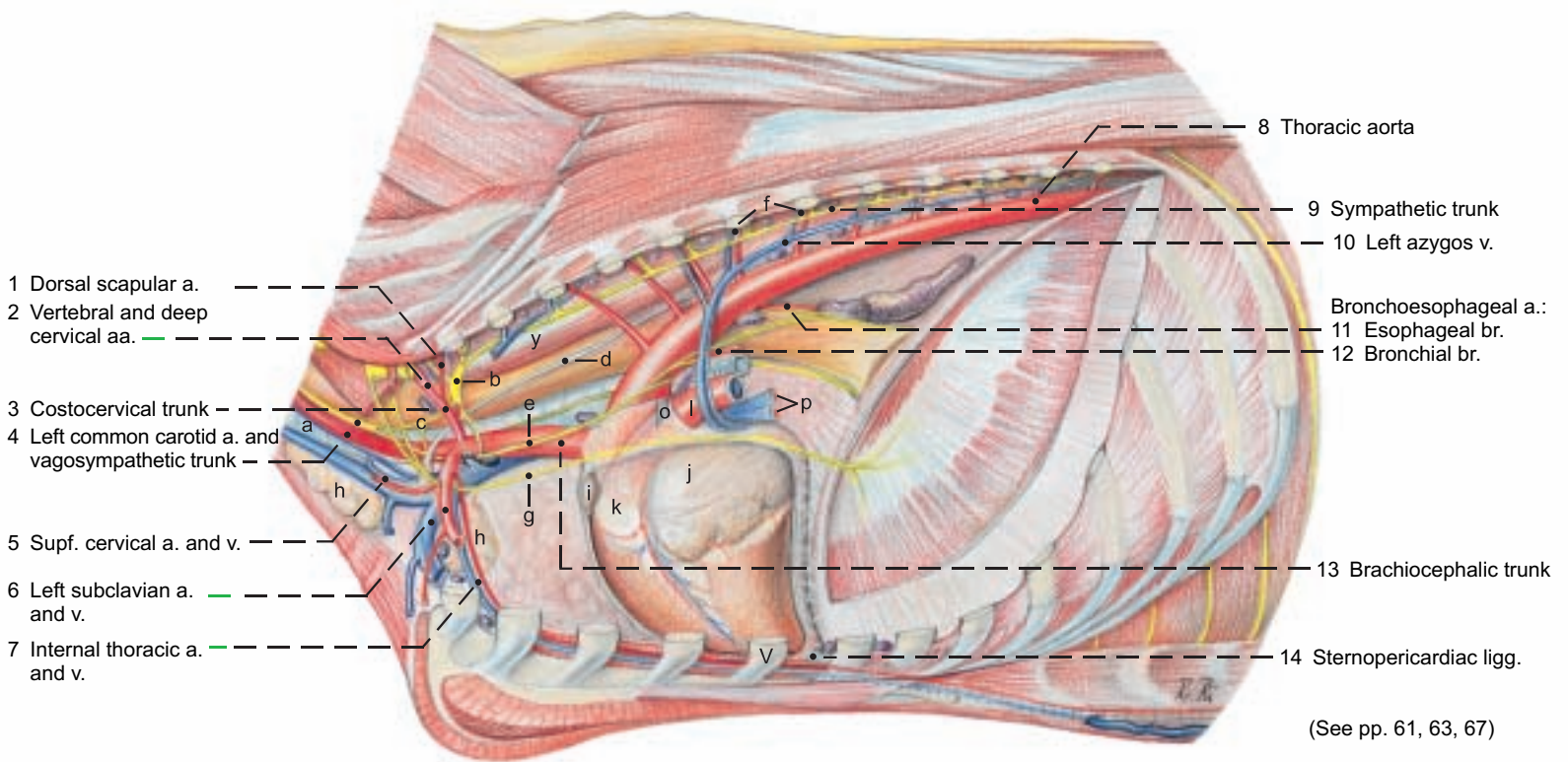


Legend:*

A Right atrium	C Left atrium
a Sinus of venae cavae	Pulmonary vv. (See p. 65 p)
b Coronary sinus	
c Pectinate mm.	
d Veins of right heart	
	g Right heart bone
	g' Left heart bone
	h Fossa ovalis
	i Epicardium
	j Myocardium
	k Endocardium
B Right ventricle	D Left ventricle
e Right atrioventricular valve [Tricuspid valve]	r Left atrioventricular valve [Mitral valve]
e'1 Parietal cusp	r'1 Parietal cusp
e'2 Septal cusp	r'2 Septal cusp
e'3 Angular cusp	r"1 Subauricular papillary m.
e"1 Small papillary mm.	r"2 Subatrial papillary m.
e"2 Great papillary m.	s Aortic valve
e"3 Subarterial papillary m.	s1 Right semilunar valve
f Pulmonary valve	s2 Left semilunar valve
f1 Right semilunar valve	s3 Septal semilunar valve
f2 Left semilunar valve	
f3 Intermediate semilunar valve	
	l Atrioventricular orifice
	m Interventricular septum
	n Septomarginal trabeculae
	o Trabeculae carneae
	p Tendinous cords

* The letters in this legend are framed in the heart illustrations (pp. 64, 65).

Left Thoracic cavity and Heart



Legend: (Lnn. see p. 63)

a Trachea and int. jugular v.
b Cervicothoracic ganglion
c Middle cervical ganglion
d Thoracic duct
e Vagus n.

f Intercostal aa. and vv.
g Left phrenic n.
h Thymus
i Right auricle
j Left auricle

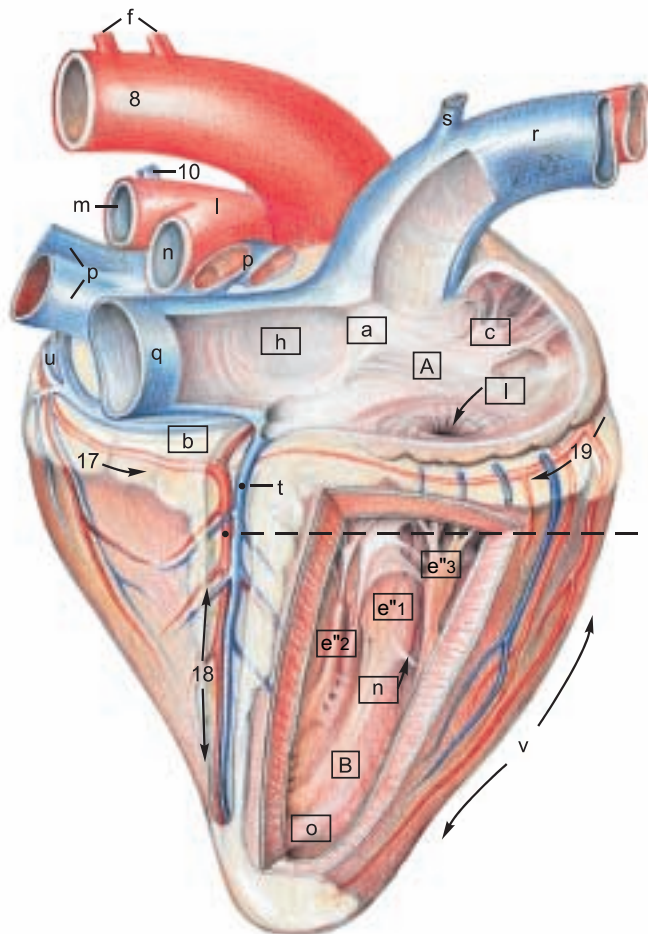
k Conus arteriosus
l Pulmonary trunk
m Left pulmonary a.
n Right pulmonary a.
o Lig. arteriosum

p Pulmonary vv.
q Caud. vena cava
r Cran. vena cava
s Costocervical v.
t Middle cardiac v.

u Great cardiac v.
v Right ventricular border
w Left ventricular border and intermediate groove
x Apex of heart
y Longus colli m.

Right atrium and Right ventricle

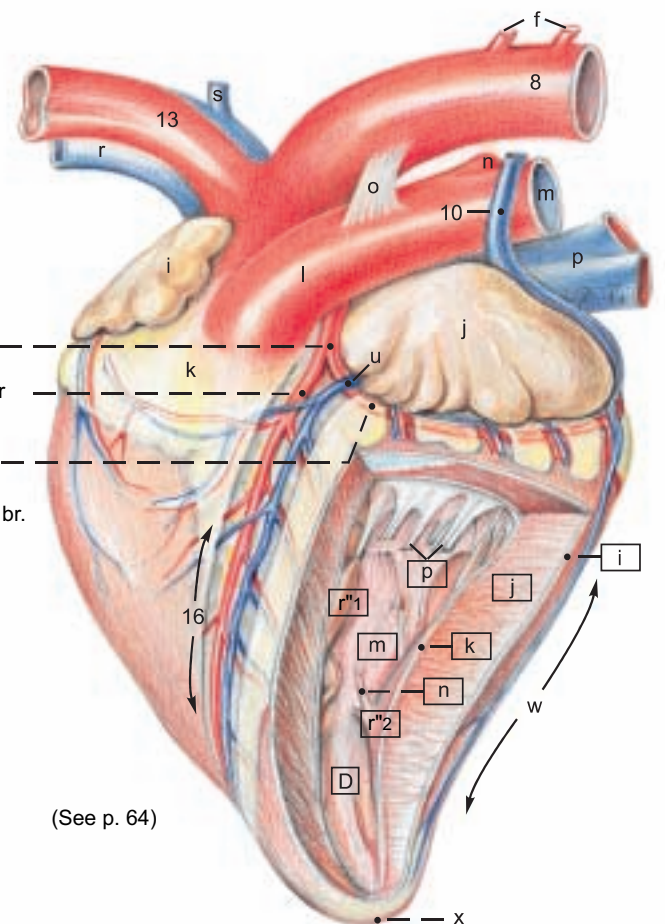
(Atrial surface)



- 15 Left coronary a.
- 16 Paraconal interventricular br. and groove
- 17 Circumflex br.
- 18 Subsinuosal interventricular br. and groove
- 19 Right coronary a. and coronary groove

Left auricle and Left ventricle

(Auricular surface)



(See p. 64)

CHAPTER 7: ABDOMINAL WALL AND ABDOMINAL CAVITY

1. THE ABDOMINAL WALL

For demonstration of the five layers of the abdominal wall (a, b, d, e, f), the remaining skin is cut along the dorsomedian line and along the transverse plane of the tuber coxae, and reflected ventrally to the base of the udder or prepuce. Remnants of the cutaneus trunci, abdominal muscles, and internal fascia of the trunk are cut just ventral to the iliocostalis lumborum and reflected ventrally, one after the other, to the subcutaneus abdominal vein and the lateral border of the rectus abdominis.

a) The **SKIN (1)** of the lateral abdominal wall (flank) is easily moveable. Dorsally the *surgically important triangular paralumbar fossa (b)* is outlined by the ends of the transverse processes of the lumbar vertebrae, the last rib, and the prominent ridge formed by the part of the internal oblique that extends from the tuber coxae to the knee of the last rib. Ventrally, the subcutaneous **cranial superficial epigastric v. ("milk vein"—3) in the cow, is conspicuous, meandering, and 2–3 cm thick.** It comes from the int. thoracic v. and emerges from the "milk well" (*anulus venae subcutaneae abdominis*) at the second tendinous intersection of the rectus, ventral to the 7th to 9th intercostal spaces. It joins the **cranial mammary v. (caudal superficial epigastric v., p. 91, 12) at the udder.**

b) The **SYSTEM OF THE EXTERNAL FASCIA OF THE TRUNK** includes the superficial fascia and deep fascia.

I. The **superficial fascia of the trunk** envelops the **cutaneus trunci** and the cranially related **cutaneus omobranchialis**, which are essentially the same as in the horse. The **strong cranial preputial muscles**, present in the dog, but not in the horse, *originate mainly from the region of the xiphoid cartilage and secondarily from the ventral border of the cutaneus trunci, and form a loop around the preputial orifice.* The **caudal preputial muscles** (see text figure p. 80) are inconspicuous in the dog and absent in the horse and polled breeds of cattle.* *They originate from the deep fascia, mainly lateral to the tunica vaginalis, but often also medial to it, and terminate at the loop formed by the cranial preputial muscles.*

The 8–12 cm long **subiliac lymph node (5)**, absent in the dog, differs from the multiple nodes of the horse. *It is a single large node above the patella on the abdominal wall near the cranial border of the tensor fasciae latae, easily palpable in the live ox. A small accessory node may be present.*

II. The **deep fascia of the trunk** covers the external oblique, and on the ventrolateral abdomen is also known as the **yellow abdominal tunic (4)** due to the inclusion of yellow elastic fibers. With its collagenous laminae the deep fascia completely envelops the two abdominal obliques; whereas it covers only the external surface of the rectus and transversus. On both sides of the ventral median line the yellow tunic gives off the elastic **medial laminae** of the udder, or in the bull, radiates into the prepuce. The **linea alba** is the ventromedian fixation and interwoven seam of the fasciae and aponeuroses of the abdominal muscles. It extends from the sternum *through the prepubic tendon* to the pecten pubis and passes around both sides of the umbilicus.

c) The **NERVES OF THE ABDOMINAL WALL**

I. The **dorsal branches** of spinal nerves T12–L3 divide into medial and lateral mixed motor and sensory branches. The lateral brr. (Tdl, Ldl) pass out between the longissimus and iliocostalis muscles and divide into **dorsomedial cutaneous brr.** and **dorsolateral cutaneous brr.** The latter innervate the skin of the abdomen down to the level of the patella. On p. 67 the small dorsomed. cut. brr. are mislabeled Ldl. The dorsolat. cut. brr. are cut off short. Those of T13 and L1 and L2 cross the paralumbar fossa to a line from the ventral end of the last rib to the patella, but cannot be traced that far by gross dissection. They must be blocked with the ventral brr. to provide anesthesia for flank incisions.

II. The **ventral branches** of spinal nerves T12–L2 innervate the skin, abdominal mm., and peritoneum. The ventral br. of L1 is the **iliohypogastric n.** The ventral br. of L2, together with a communication from L3, forms the **ilioinguinal n.** The ventral brr. give off **lateral cutaneous branches (Tvl, Lvl)** which emerge through the external oblique on a line extending from the knees of the ribs to a point ventral to the tuber coxae at the level of the hip joint. Passing caudoventrally, they innervate the skin of the ventrolateral

abdomen. The ventral brr. of T12–L2 communicate with each other at the origins of the lateral cutaneous brr. and continue ventrally on the external surface of the transversus. Near the milk vein they give off **ventral cutaneous branches (Tvc, Lvc)**** extending to the ventral midline and cranial portions of the prepuce or udder, and terminate in the rectus and parietal peritoneum. The relations of nerves T13–L2 to the transverse processes of the vertebrae are of great clinical importance for anesthesia of the abdominal wall. The **lateral cutaneous femoral n. (11)** comes from L3 and L4 through the lumbar plexus. It accompanies the caudal branches of the deep circumflex iliac a. and v., *at first medial then craniolateral to the tensor fasciae latae, down to the stifle.* (For the innervation of the udder see p. 90.)

d) The **SKELETAL MUSCLE LAYER** consists of four broad muscles.

I. The **external oblique abdominal m. (2)**. The lumbar part originates on the last rib and thoracolumbar fascia and runs to the tuber coxae, and caudoventrally to the inguinal lig. and prepubic tendon (see p. 80). *The costal part begins with its digitations on the last 8–9 ribs, touching part of the ventral border of the latissimus dorsi.* It ends with the aponeurosis mainly on the linea alba, but also on the prepubic tendon by means of its abdominal and pelvic tendons (see pp. 79, 80). *The transition of the muscle to its aponeurosis follows the curve of the costal arch and continues to the tuber coxae. The aponeurosis is a component of the external lamina of the sheath of the rectus.*

II. The **internal oblique abdominal m. (10)** originates mainly from the tuber coxae and the iliac fascia (see p. 81). It also takes origin from the thoracolumbar fascia and the lumbar transverse processes. The dorsal part ends on the last rib, and the portion running from the tuber coxae to the knee of the last rib forms the caudoventral border of the paralumbar fossa. The main termination is by its aponeurosis on the linea alba; the caudal border of the aponeurosis joins the abdominal and pelvic tendons of the ext. oblique and the tendon of the rectus in the prepubic tendon. The aponeurosis, unlike that of the dog, is involved only in the external lamina of the sheath of the rectus. (For its contribution to the deep inguinal ring see p. 80.)

III. The **transversus abdominis (7)** originates with a tendinous lumbar part from the lumbar transverse processes, and a fleshy costal part interdigitating with the diaphragm *on the last 7–8 costal cartilages.* It terminates on the linea alba, its aponeurosis forming the internal lamina of the sheath of the rectus. Its caudal extent is at the transverse plane of the tuber coxae.

IV. The **rectus abdominis (6)** takes origin from the 4th–9th costal cartilages *and has five tendinous intersections. The terminal tendons of the recti become abruptly narrower near the inguinal region and turn their inner surfaces toward each other, forming in the cow a narrow median trough. Near the prepubic tendon the rectus tendons twist into sagittal planes and fuse by decussation caudal to the intertendinous fossa (see p. 78 c). They form a common median tendon incorporated in the prepubic tendon and continuous with the symphyseal tendon.*

e) The **INTERNAL FASCIA OF THE TRUNK** (see p. 80) lines the transversus and rectus on the lateral and ventral abdominal wall as the **fascia transversalis**. Dorsally it covers the psoas and iliacus as iliac fascia. It joins the pelvic fascia on the pelvic wall.

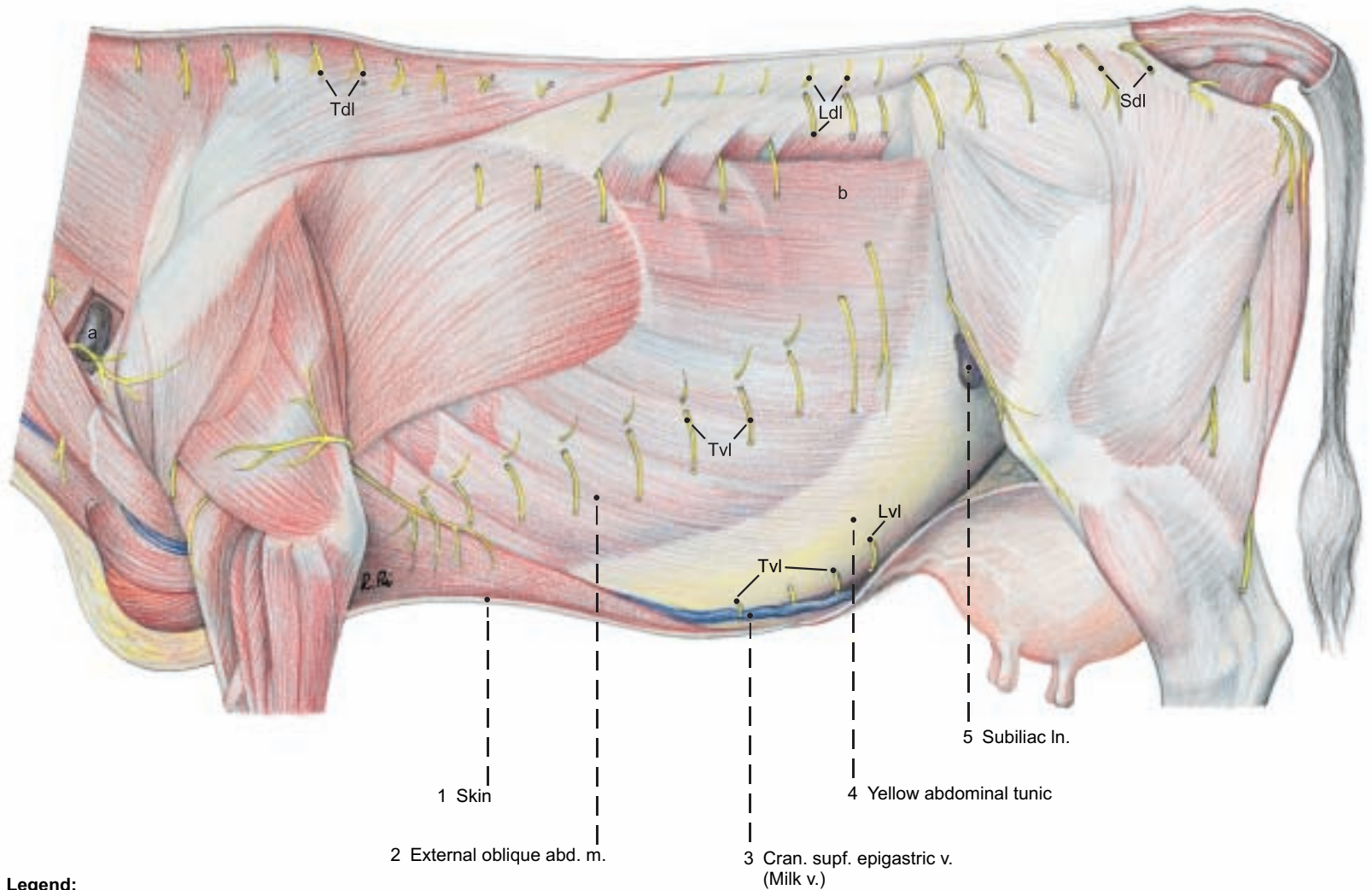
f) The **PERITONEUM** (see also p. 80). The peritoneum extends into the pelvic cavity as the rectogenital, vesicogenital, and pubovesical pouches (excavations) and in the bull is evaginated *into the scrotum as the vaginal tunic.*

* Long, and Hignett, 1970

** Schaller, 1956

Pectoral and abdominal regions

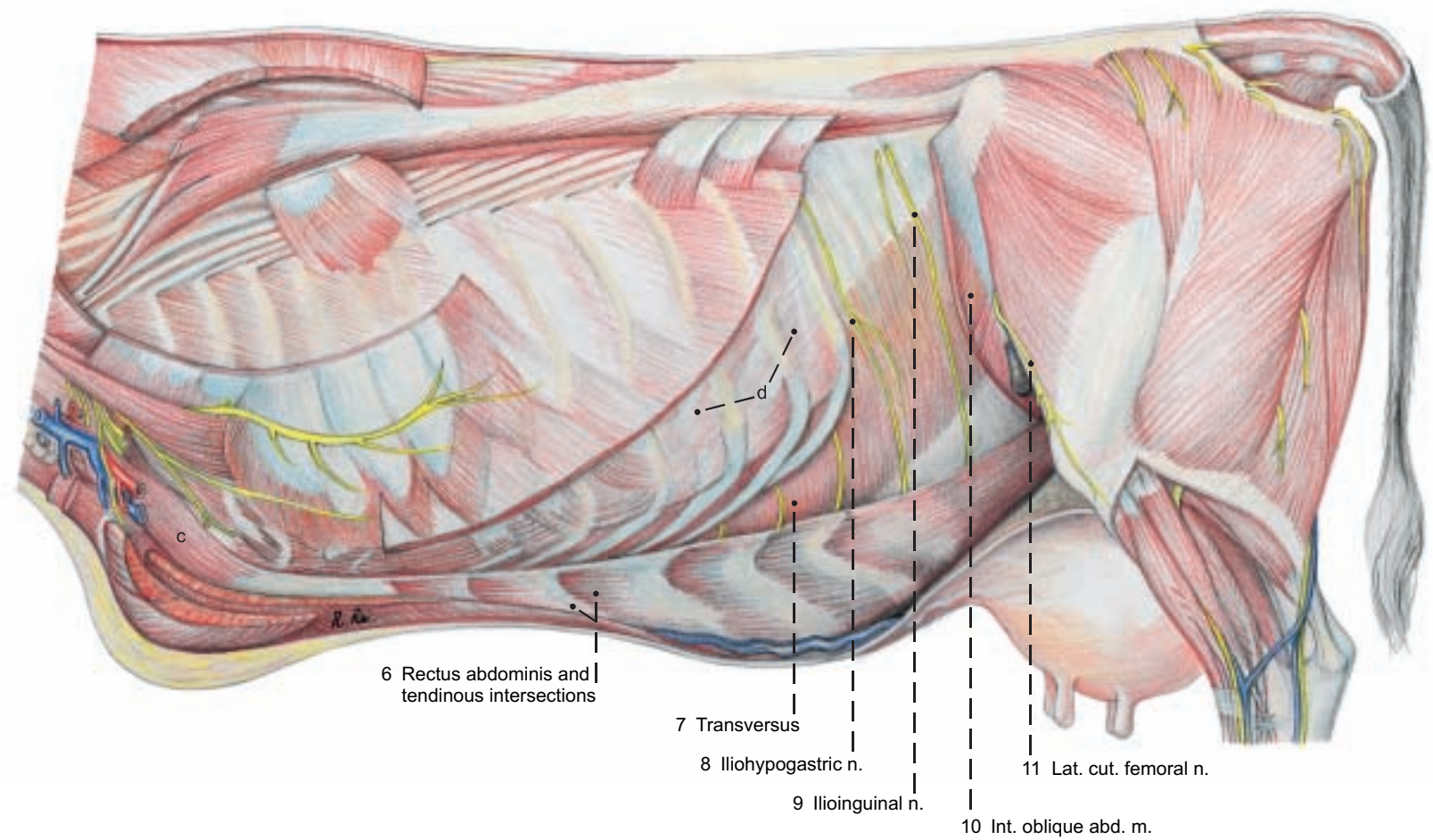
(lateral)



Legend:

- a Supf. cervical In.
- b Paralumbar fossa
- c Rectus thoracis
- d Int. intercostal mm.

(See p. 61)



2. TOPOGRAPHY AND PROJECTION OF THE ABDOMINAL ORGANS ON THE BODY WALL

The costal part of the diaphragm is detached from the ribs on both sides. A dorsoventral incision is made through the diaphragm on the right of the caudal vena cava and on the left of the adhesion with the spleen, and the severed parts of the diaphragm are removed. In the process, the falciform ligament and the round ligament of the liver, still intact in the young animal, can be seen on the right.

A knowledge of the topographic relations of the abdominal organs to the body wall is essential for their examination from the exterior as well as for laparotomy and rectal examination. The abdominal wall is divided into cranial, middle, and caudal regions, and these are subdivided on each side as follows: I. The large **cranial abdominal region** consists of a) left, and b) right caudoventral parts of the costal regions and the hypochondriac regions (covered by the costal cartilages), and c) the xiphoid region between the costal arches. II. The **middle abdominal region** consists of the a) left and b) right lateral abdominal regions (flanks) with the paralumbar fossae, and the c) umbilical region. III. The **caudal abdominal region** consists of right and left inguinal regions and the pubic region. In the costal and hypochondriac regions the intrathoracic abdominal organs are not in contact with the thoracic wall, but are separated from it by the lungs and diaphragm. The rumen extends from the diaphragm to the pelvic inlet. It takes up most the left half of the abdominal cavity. Its extension to the right and toward the pelvic inlet depends on the age of the animal, the kind of feed, and, if pregnant, the stage of gestation. These factors also affect the position and relations of all other abdominal organs.

I. a) In the **left costal and hypochondriac regions** the **atrium (3)** and **recess (6) of the rumen** are projected on the thoracic wall, as well as the **spleen (4)**, adherent to the dorsolateral surface of the atrium from the vertebral ends of the 12th and 13th ribs, over the middle of the 10th rib, to the level of the knees of the 7th and 8th ribs. The **reticulum (2)** is in contact with the left abdominal wall in the ventral third of the 6th and 7th intercostal spaces. Near the median plane it may extend caudally as far as the transverse plane of the 9th intercostal space, and ventrally to the level of the xiphoid cartilage. Of the **liver (1)**, only the left border is projected in the narrow space between the diaphragm and reticulum in the ventral 3rd of the 6th intercostal space. The **fundus of the abomasum (5)** lies on the left side between the reticulum and the atrium of the rumen.

I. b) In the **right costal and hypochondriac regions** the **liver (25)**, covered by the diaphragm, and mostly also by the lung, is projected on the thoracic wall, its border forming a caudally convex curve. It lies almost entirely on the right side, including the **left lobe (1)**, **right lobe (25)**, and **caudate process (24)**. It extends from the ventral end of the 6th intercostal space to the dorsal end of the 13th rib. The percussion field of the liver, however, is limited to a zone about a hand's breadth wide along the border of the lung in the last four intercostal spaces.

Ventral to the caudate process is the cranial part of the **descending duodenum (13)** with the **right lobe of the pancreas (15)** in the mesoduodenum. Ventral to the descending duodenum, covered by the **greater omentum**, are cranial loops of the **jejunum (19)** and cranial to them, the **gall bladder (27)** in the ventral part of the 10th intercostal space. Directly cranial to the gall bladder is the **cranial part of the duodenum (26)**, continuous ventrocaudally with the **pylorus**,

which varies in position from the ventral end of the 9th to that of the 12th intercostal space.

Cranial to the **pyloric part of the abomasum (28)** is the **omasum (30)**, covered by the lesser omentum, between the transverse planes of the 7th and 11th ribs, but because of its spherical shape, it presses the lesser omentum against the thoracic wall in the 7th–9th intercostal spaces only.

II. a) In the **left lateral abdominal region** only rumen compartments adjoin the abdominal wall. The **dorsolateral abdominal wall** in the region of the **paralumbar fossa** is in contact with the **dorsal sac (7)** and the **caudodorsal blind sac (8)**. The **ventrolateral abdominal wall** is indirectly in contact, through the **superficial wall (21)** of the greater omentum, with the **ventral sac (9)** and the **caudoventral blind sac (10)** of the rumen.

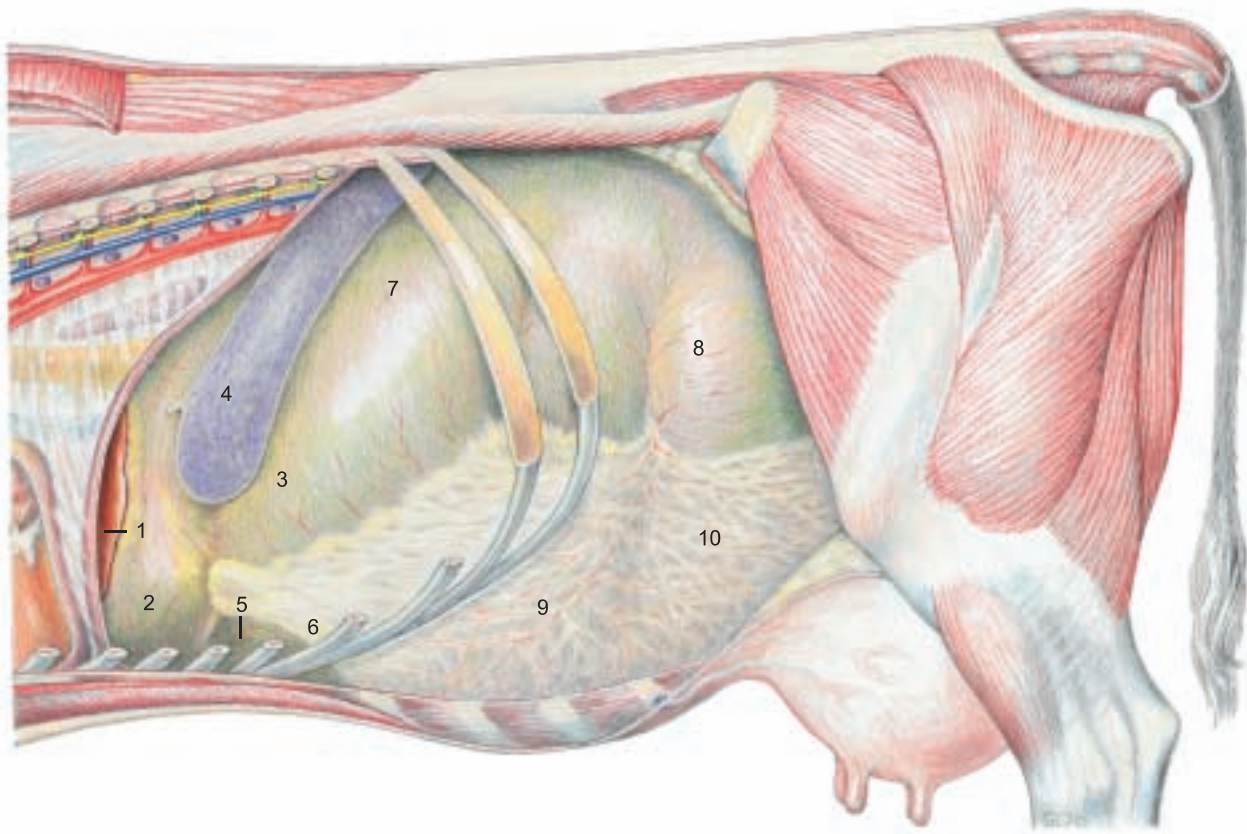
II. b) In the **right lateral abdominal region**, projected from dorsal to ventral on the dorsolateral abdominal wall, are the **right kidney (14)** from the last rib to the 3rd lumbar vertebra, the **right lobe of the pancreas (15)** with the **descending duodenum (13)**, which passes into the **caudal flexure (12)** at the level of the tuber coxae, and immediately caudal to that, the **sigmoid part of the descending colon (11)**. Ventral to the duodenum, in the **supraomental recess (23)** of the greater omentum, are the **proximal loop of the ascending colon (16)** and the **cecum (17)**. The latter extends from the middle of the lumbar region to the pelvic inlet. The apex of the cecum projects caudally from the supraomental recess. (Relations between the descending duodenum and the parts of the large intestine may vary but are not necessarily abnormal.) The **ventrolateral abdominal wall** covers the **pyloric part of the abomasum (28)** ventrally along the right costal arch back to the knee of the 12th rib, and middle and caudal parts of the **jejunum (19)** from the last rib to the plane of the last lumbar vertebra. The jejunum overreaches the greater omentum caudally and passes into the straight **ileum (18)** just ventral to the cecum.

III. Ventrally in the **xiphoid region**, are the **reticulum (2)** cranially, more on the left than on the right; the **fundus of the abomasum (5)** caudal to the reticulum; the **omasum (30)** ventral to the right costal arch, covered by the lesser omentum, between the transverse planes of the 7th and 11th intercostal spaces; the **fundus of the abomasum** caudal to the reticulum; and the **atrium of the rumen on the left**. Ventrally in the middle abdominal region the **body of the abomasum (29)** lies on the median line with more of it on the left than on the right. At the **angle of the abomasum** the pyloric part (28) curves to the right around the omasum, with the greater curvature crossing the median line at the transverse plane of the last rib. The **jejunum (19)** is caudal to the abomasum on the right as far caudally as the last lumbar vertebra, partly within the supraomental recess. On the left of the median plane, caudally and also slightly to the right, the **ventral sac (9)** and **caudoventral blind sac (10)**, covered by the greater omentum, lie on the abdominal floor.

Study of the abdominal organs is carried out by the students on both sides of the body at the same time. On the left side the stomach and spleen are studied and the adhesions of the organs with the abdominal wall and with other organs and structures are noted. The interior relations of the compartments of the stomach are exposed by fenestration of the dorsal sac of the rumen from the lumbar transverse processes to the left longitudinal groove of the rumen, and removal of the contents. Prepared demonstrations of the stomach are also studied. On the right side, before the study of the liver and intestines, the special relations of the greater omentum are examined and the omental foramen is explored. Then the superficial wall (21) of the greater omentum is cut ventral and parallel to the descending duodenum, opening the caudal recess of the omental bursa (22). The duodenum with the mesoduodenum and pancreas are carefully reflected dorsally to the ventral surface of the right kidney. After study of the liver and its vessels, nerves, and ducts, the common bile duct, hepatic a., portal v., portal lnn., and nerves are severed at the porta of the liver, and the hepatic ligaments and caudal vena cava, cranial and caudal to the liver, are cut and the liver is removed. After complete transection of the superficial wall down to the pylorus, the deep wall of the greater omentum is cut ventral to the distal loop of the ascending colon and the transverse colon, and the supraomental recess (23) is opened for study of the remaining intestines. The blood vessels, nerves, and lymph nodes are identified with attention to species-specific peculiarities. For final exenteration the duodenum between the cranial and descending parts, and the rectum caudal to the caudal mesenteric a. are double-ligated and cut. Also the cranial and caudal mesenteric aa. ventral to the aorta, and the splenic and gastroduodenal vv. at the portal v. are cut. While separating the mesentery and mesocolon from the dorsal abdominal wall, the intestinal mass is removed from the abdominal cavity and the parts of the intestines are identified on the isolated intestinal tract.

Abdominal cavity and Digestive system

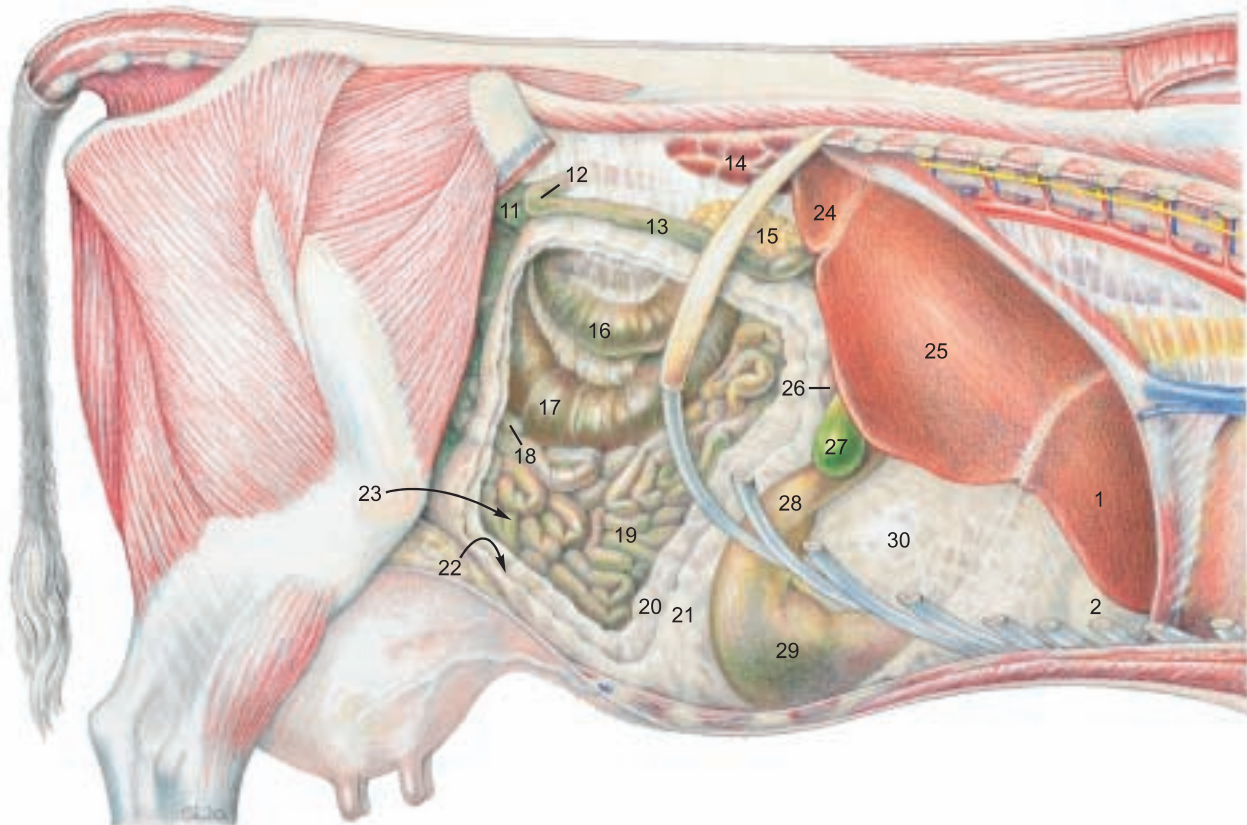
(Left side)



Legend:

- | | | | |
|----------------------|---|---|-------------------------------------|
| 1 Left lobe of liver | 5 Fundus of abomasum | 8 Caudodorsal blind sac of rumen | 11 Sigmoid part of descending colon |
| 2 Reticulum | 6 Recess of ventral sac of rumen covered by omentum | 9 Ventral sac of rumen covered by omentum | 12 Caudal flexure of duodenum |
| 3 Atrium of rumen | 7 Dorsal sac of rumen | 10 Caudoventral blind sac of rumen covered by omentum | 13 Descending duodenum |
| 4 Spleen | | | 14 Right kidney |
| | | | 15 Right lobe of pancreas |

(Right side)



(See pp. 17, 63, 65, 67)

Legend:

- | | | | |
|----------------------------------|------------------|-----------------------------|-------------------------------------|
| 16 Prox. loop of ascending colon | Greater omentum: | 23 Supraomental recess | 27 Gall bladder |
| 17 Cecum | 20 Deep wall | 24 Caudate process of liver | 28 Pyloric part of abomasum |
| 18 Ileum | 21 Supf. wall | 25 Right lobe of liver | 29 Body of abomasum |
| 19 Jejunum | 22 Caudal recess | 26 Cranial part of duodenum | 30 Omasum covered by lesser omentum |

3. STOMACH WITH RUMEN, RETICULUM, OMASUM, AND ABOMASUM

The ruminant stomach is one compartmentalized complex stomach which consists of three nonglandular compartments lined with stratified squamous epithelium (rumen, reticulum, and omasum) and one compartment with glandular mucosa (abomasum). The individual compartments all develop from one spindle-shaped gastric primordium like that of the simple stomach. The total capacity of the stomach varies with body size from 100 to 200 l.

At about 18 months the compartments have reached the following approximate percentages of total stomach capacity: rumen 80 percent, reticulum 5 percent, omasum 7 percent, and abomasum 8 percent.* These postmortem measurements on isolated stomachs are not reliable indications of capacity in the live animal.

a) The capacity of the **RUMEN (A)** is 102–148 l. Most of the interior bears **papillae (21)**. Its **parietal surface** lies against the left and ventral abdominal wall and its **visceral surface** is in contact with the intestines, liver, omasum, and abomasum. The wide **ruminoreticular orifice (22)** and close functional relationship has given rise to the term ruminoreticulum. The **dorsal curvature (1)** is adherent to the internal lumbar muscles, right and left crura of the diaphragm, spleen, pancreas, and left adrenal gland. The left kidney with its fat capsule, almost completely surrounded by peritoneum, and pendulous, is pushed over to the right of the median plane by the rumen. The **ventral curvature (2)** lies on the ventral abdominal wall.

The surfaces of the rumen are divided by **right (16)** and **left (3) longitudinal grooves** connected by **cranial (5)** and **caudal (6) grooves** into a **dorsal sac (7)** and a **ventral sac (9)**. The dorsal sac contains a large gas bubble during life and its dorsal wall is free of papillae. The right longitudinal groove gives off dorsally a **right accessory groove (17)** that rejoins the main groove and with it surrounds an elongated bulge, the **insula ruminis (18)**. The left longitudinal groove gives off a dorsal branch, the **left accessory groove (4)**. Dorsal and ventral rumen sacs communicate through the wide **intraruminal orifice (19)**.

At the caudal end of the rumen on both sides the two rumen sacs are divided by **dorsal (11)** and **ventral (12) coronary grooves** from the **caudodorsal (13)** and **caudoventral (14) blind sacs**, both of which extend about the same distance toward the pelvis.

At its cranial end there are no coronary grooves; however the **atrium of the rumen (8)** can be recognized craniodorsal to the cranial groove, and the large **recess of the rumen (10)** is the cranial part of the ventral sac.

The external grooves of the rumen correspond to the internal muscular **pillars (20)** of the same names, covered by nonpapillated mucosa. The **ruminoreticular groove (15)** forms the internal **ruminoreticular fold (23)**.

b) The **RETICULUM (B)** has its cranial **diaphragmatic surface** in contact with the diaphragm and left lobe of the liver. Its caudal **visceral surface** is in contact with the rumen, omasum, and abomasum. Its **greater curvature** lies against the left abdominal wall, while its **lesser curvature** contains the reticular groove. The **fundus of the reticulum** is in the xiphoid region.

The mucosa forms a network of **crests (29)** in three orders of height. The crests contain muscle, are covered with **papillae**, and enclose four- to six-sided **cells (29)**, which become smaller and more irregular toward the reticular groove.

c) The **GASTRIC GROOVE** is the shortest route between the esophagus and the pylorus. It consists of three segments: the **reticular groove, the omasal groove, and the abomasal groove**.

It begins at the **cardia (24)**, which opens caudally, as determined by transruminal palpation in the live ox. Boluses expelled from the esophagus go directly over the ruminoreticular fold (23) into the atrium (8). From the cardia the 15–20 cm long **reticular groove (25)** runs ventrally along the lesser curvature (right wall) of the reticulum. Its muscular **right (26)** and **left (27) lips**, are named for their relation to the cardia, over which they are continuous. As the lips descend, the right lip becomes caudal and the left lip cranial, and they run parallel and straight to the **reticulo-omasal orifice (28)**, where the right lip overlaps the left. The **floor of the reticular groove** has longitudinal folds that increase in height toward the omasum and at the orifice bear long sharp **claw-like papillae** which continue into the omasum.

d) The **OMASUM (C)** is almost spherical with slightly flattened sides and lies on the right on the floor of the intrathoracic part of the abdominal cavity. The **parietal surface** is cranioventrolateral (see p. 69); the **visceral surface** is caudodorsomedial; and the **curvature (30)** is between them facing dorsally, caudally, and to the right. All of the omasum except the ventral part of the parietal surface is covered on the right by the lesser omentum (p. 69, 30). Cranioventrally the **base of the omasum (31)**, containing the omasal groove, contacts the reticulum, rumen, and abomasum. Cranially and dorsolaterally the omasum adjoins the liver, and medially, the rumen. From the externally visible **neck of the omasum** the internal **omasal groove (35)** leads to the **omasoabomasal orifice (36)**. This is bounded by two folds of mucosa, the **vela abomasica (45)**, which are covered on the omasal side by stratified squamous epithelium and on the abomasal side by glandular mucosa. The thick muscular **omasal pillar** runs across the floor of the groove.

About 100 **omasal laminae (32)** in four orders of size project from the curvature and the sides of the omasum toward the omasal groove. The groove and the free borders of the largest laminae form the **omasal canal**. Between the laminae are the **interlaminae recesses (33)**. The laminae are covered by conical **papillae (34)**.

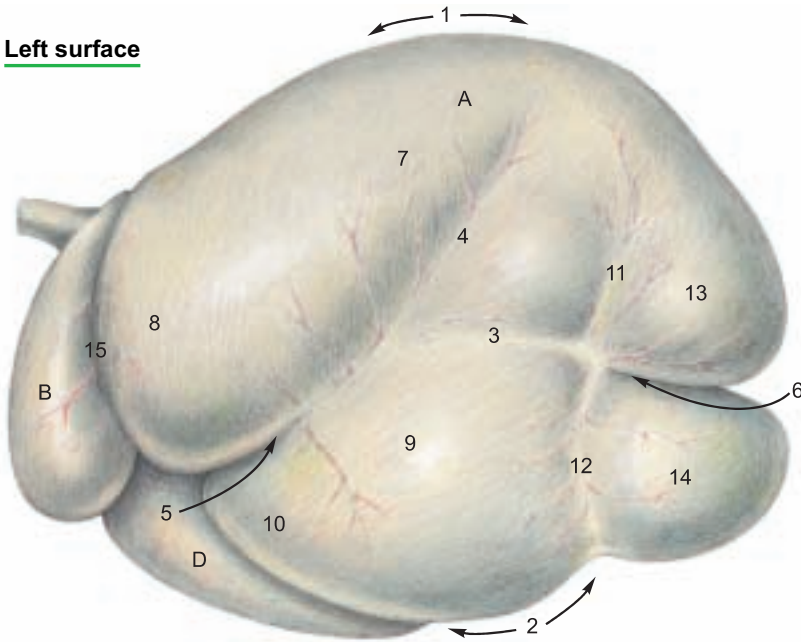
e) The **ABOMASUM** is *thin-walled and capable of great distension and displacement*. It has a capacity of up to 28 l. *The drawing of the right surface of the stomach (p. 71) shows the organ after removal from the abdominal cavity and inflation, which distorts the relation of abomasum to omasum.* Its **parietal surface** and part of the **greater curvature (37)** lie on the ventral abdominal wall. The caudal part of the greater curvature is separated from the intestines by the greater omentum. The **visceral surface** is in contact with the rumen. The **lesser curvature (38)** bends around the omasum. The **fundus of the abomasum (39)** is a cranial recess in the left xiphoid region. It is continuous with the **body of the abomasum (40)** and both have internal permanent oblique, but not spiral, **abomasal folds (44)** of reddish-gray mucosa containing proper gastric glands. The folds begin at the omasoabomasal orifice and from the sides of the **abomasal groove (46)** and reach their greatest size in the body. The more lateral folds diverge toward the greater curvature, whereas the folds near the abomasal groove run more nearly parallel to it. The folds diminish toward the **pyloric part** which begins at the **angle of the abomasum** and consists of the **pyloric antrum, pyloric canal, and pylorus**. It is lined by wrinkled yellowish mucosa containing pyloric glands.

The **pyloric sphincter (43)** and the **torus pyloricus (42)** that bulges from the lesser curvature into the pylorus can close off the flow from the abomasum to the duodenum.

The abomasal groove runs along the lesser curvature, bordered by low mucosal folds, from the omasoabomasal orifice to the **pylorus**.

Stomach [Ventriculus]

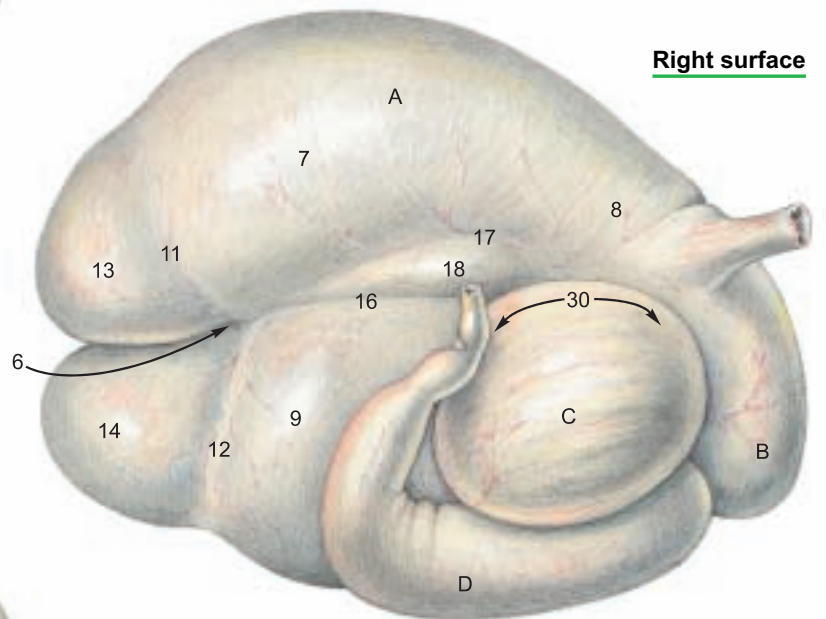
Left surface



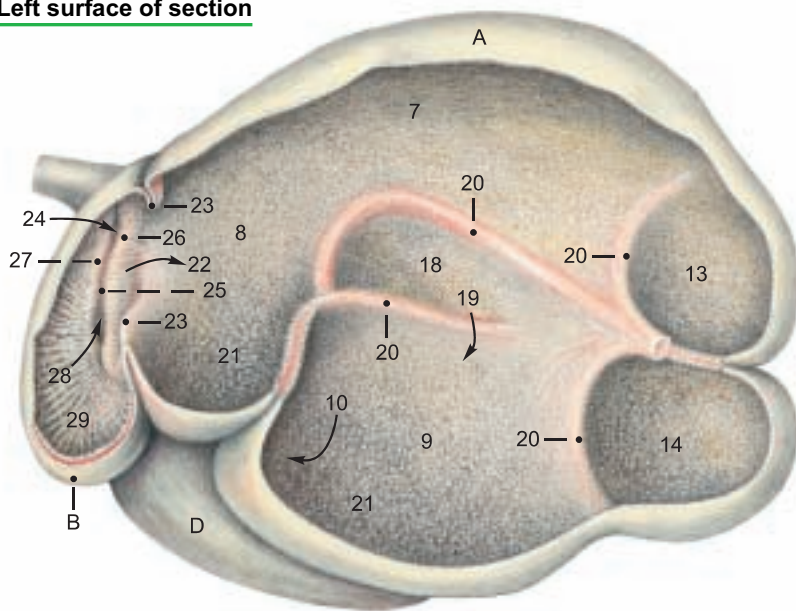
Legend:

- | | |
|----------------------------------|------------------------------|
| A Rumen | 11 Dorsal coronary groove |
| 1 Dorsal curvature | 12 Ventral coronary groove |
| 2 Ventral curvature | 13 Caudodorsal blind sac |
| 3 Left longitudinal groove | 14 Caudovernal blind sac |
| 4 Left accessory groove | 15 Ruminoreticular groove |
| 5 Cranial groove | 16 Right longitudinal groove |
| 6 Caudal groove | 17 Right accessory groove |
| 7 Dorsal sac | 18 Insula |
| 8 Atrium | 19 Intraruminal orifice |
| 9 Ventral sac | 20 Pillars |
| 10 Recess of ventr. sac of rumen | 21 Papillae |

Right surface



Left surface of section



Legend:

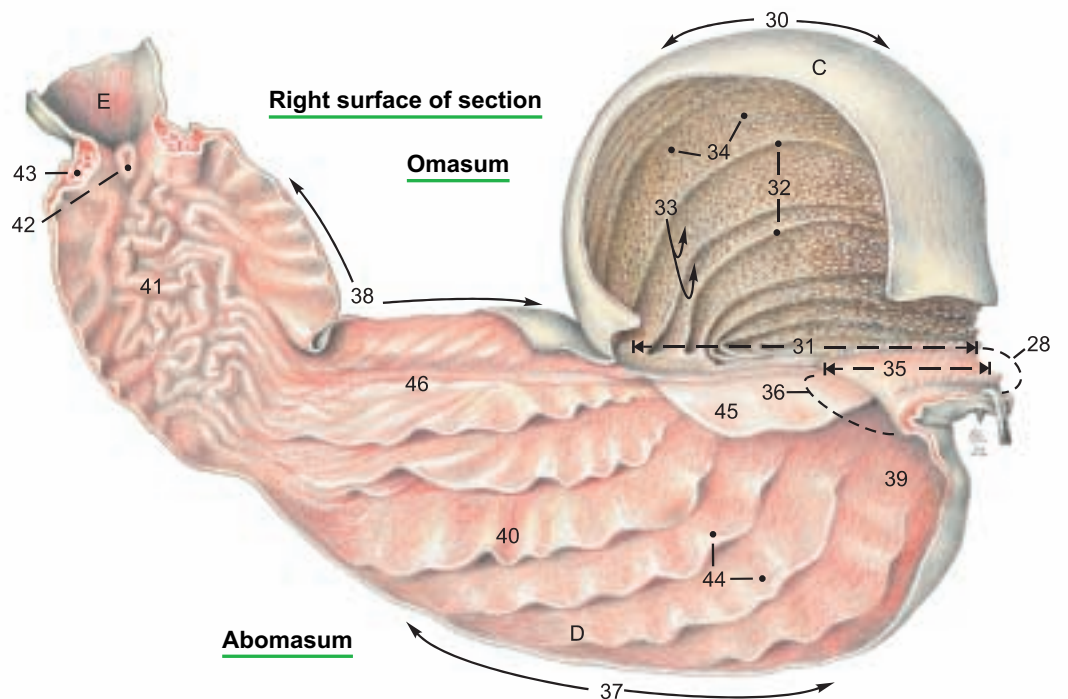
- B Reticulum**
- 22 Ruminoreticular orifice
 - 23 Ruminoreticular fold
 - 24 Cardia
 - 25 Reticular groove
 - 26 Right lip
 - 27 Left lip
 - 28 Reticulo-omasal orifice
 - 29 Reticular crests and cells

Legend:

- D Abomasum**
- 37 Greater curvature
 - 38 Lesser curvature
 - 39 Fundus
 - 40 Body
 - 41 Pyloric part
 - 42 Torus pyloricus
 - 43 Pyloric sphincter
 - 44 Abomasal folds
 - 45 Velum
 - 46 Abomasal groove
- E Duodenum**

Legend:

- C Omasum**
- 30 Curvature
 - 31 Base
 - 32 Omasal laminae
 - 33 Interlaminal recesses
 - 34 Papillae
 - 35 Omasal groove
 - 36 Omasoabomasal orifice



(See pp. 69, 73)

4. BLOOD SUPPLY AND INNERVATION OF THE STOMACH; LYMPH NODES AND OMENTA

a) The **CELIAC A.** (1) originates from the aorta at the level of the first lumbar vertebra. *It has a relatively long course*, and after giving off phrenic arteries and adrenal branches, divides on the right dorsal surface of the rumen into hepatic, splenic, and left gastric aa. The arteries of the rumen and reticulum correspond to small branches of the splenic and left gastric aa. on the simple stomach.

The **splenic a.** (3) enters the dorsal part of the spleen. Near its origin it gives off the large **right ruminal a.** (4) to the right accessory groove as the main artery of the rumen. This gives off right dorsal and ventral coronary aa., goes through the caudal groove, and comes out on the left side of the rumen, where it gives off left dorsal and ventral coronary aa. and anastomoses with the **left ruminal a.** (5), which passes through the cranial groove of the rumen from right to left. Near its origin it gives off the **reticular a.** (6), which passes over the rumen, then ventrally in the ruminoreticular groove on the left side, and through the groove from left to right. The right and left ruminal aa. may originate either from the splenic or left gastric aa.

The **left gastric a.** (8) supplies the omasum and goes to the lesser curvature of the abomasum, where it anastomoses with the **right gastric a.** (11) from the **hepatic a.** (2). On the greater curvature of the abomasum, the **left** (9) and **right** (12) **gastroepiploic aa.** anastomose. They come from the left gastric a. and the gastroduodenal a. (a br. of the hepatic), respectively. The **accessory reticular a.** (10) arises from the left gastric or from the first part of the left gastroepiploic. It runs dorsally on the diaphragmatic surface of the lesser curvature of the reticulum. The veins, branches of the portal v., have a predominantly corresponding course.

b) The innervation by **AUTONOMIC NERVES** is accomplished in general as in the dog and horse.

The dorsal and ventral trunks of the vagus nn. are of special clinical interest in regulating the functions of each compartment of the stomach. The rumen is innervated mainly by the **dorsal vagal trunk** (a), but the atrium of the rumen and the other three compartments are innervated by both vagal trunks. Individual br. of these nerves may vary in location or extent. The dorsal vagal trunk supplies the right side of the atrium (h), the br. to the celiac plexus (c), the dorsal ruminal br. (d), and the right ruminal br. (b), which runs back in the right accessory groove, giving br. to the dorsal and ventral sacs, and passing around in the caudal ruminal groove to the left side. A branch of the dorsal trunk is also given off to the cranial ruminal groove and left longitudinal groove (e) and to the greater curvature of the abomasum (g). Branches of the dorsal trunk (f) pass over the omasum and the visceral side of the lesser curvature of the abomasum, innervating the right lip of the reticular groove, the caudal (visceral) surface of the reticulum, both sides of the omasum, and the visceral surface of the abomasum to the pylorus.

The **ventral vagal trunk** (j) gives branches to the left side of the atrium (l), the diaphragmatic surface of the reticulum (k), and branches that run in the lesser omentum to the liver, cranial part of the duodenum, and pylorus (p). Branches of the ventral trunk (m) innervate the left lip of the reticular groove (see p. 70, c), and continue across the parietal side of the neck of the omasum and run in the lesser omentum along the parietal surface of the base of the omasum and the lesser curvature of the abomasum to the pylorus, innervating the parietal surface of the omasum and abomasum.

c) The **LYMPH NODES** of the stomach and spleen include the following: **Celiac Inn.** (p. 76, A) 2–5 are found with the cran. mesenteric lnn. (p. 77) at the origin of the aa. of the same names. **Splenic (or atrial) Inn.** (E) 1–7 are grouped dorsocranial to the spleen between the atrium of the rumen and the left crus of the diaphragm. Among the numerous gastric lymph nodes, the **reticuloabomasal** (A), **ruminoabomasal** (B), **left ruminal** (C), **right ruminal** (D), **cranial ruminal** (not illustrated), **reticular** (F), **omasal** (not illustrated), **dorsal abomasal** (G), and **ventral abomasal** (H) lie in the grooves and in the omental attachments of the stomach compartments. Their efferent lymphatic vessels go to the splenic nodes or nodes preceding them, gastric trunks, visceral trunks, or the cisterna chyli (p. 74).

d) **OMENTA.** The embryonic dorsal mesogastrium and ventral mesogastrium undergo important changes in form and position with the development of the four compartments of the stomach. *After the rotation of the spindle-shaped stomach primordium through about 90° to the left, with the axis of the stomach directed at first from craniodorsal to caudoventral, three protuberances appear on the greater curvature. In craniocaudal order they are the primordia of the rumen, reticulum, and greater curvature of the abomasum. The craniodorsal end of the rumen tube is divided by the future caudal groove into the future dorsal and ventral caudal blind sacs.*

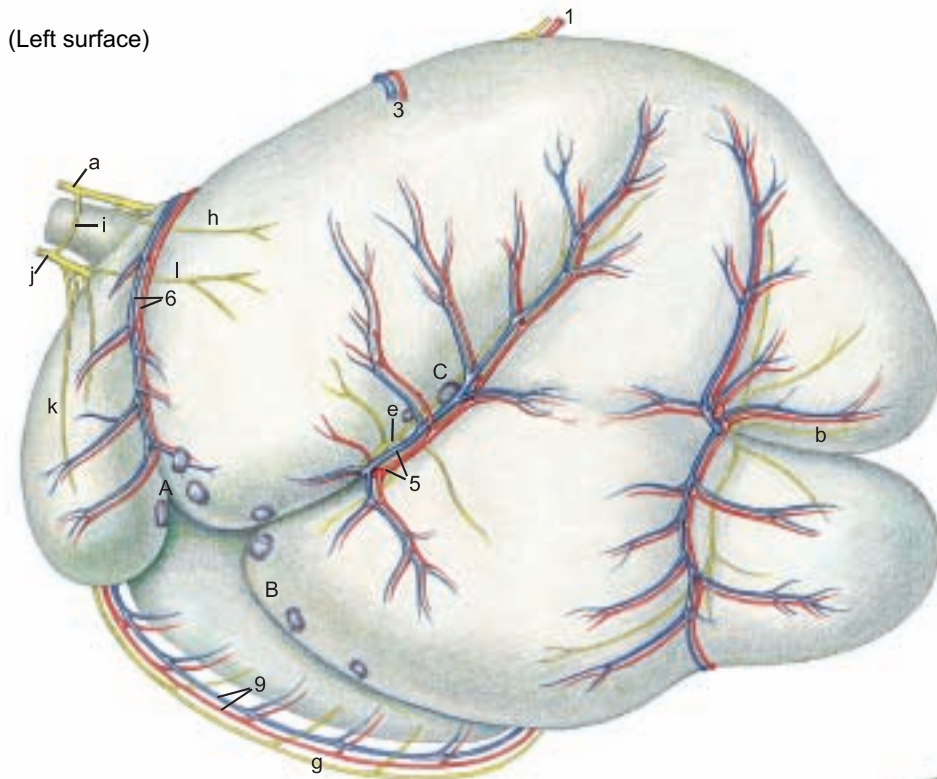
The only protuberance on the lesser curvature is the primordium of the omasum. In the course of further development the reticulum moves cranially; the two blind sacs of the rumen turn dorsally and then caudally, so that cranial and caudal blind sacs become dorsal and ventral. The caudal groove is extended on both sides of the rumen as the right and left longitudinal grooves, and a flexure in the rumen tube becomes the cranial groove. The abomasum approaches the rumen and reticulum, and its greater curvature becomes ventral as it continues the rotation clockwise as viewed from the head. The omasum comes up on the right side.

In spite of these complicated translocations, the attachments of the dorsal and ventral mesogastria to the greater and lesser curvatures of the stomach primordium are maintained. The line of attachment of the **dorsal mesogastrium** on the stomach in the adult runs from the dorsal surface of the esophagus at the hiatus to the right longitudinal groove, through the caudal groove and the left longitudinal groove of the rumen, across a part of the left surface of the atrium and reticulum, and along the greater curvature of the abomasum to the cranial part of the duodenum.

The **greater omentum** (see the lower left figure) with its **deep wall** (15) and **superficial wall** (14), together with the **omental bursa**, is the main derivative of the dorsal mesogastrium. It extends caudally, ventrally, and to the right. **Caudally** near the pelvis, as in the dog, the deep wall is reflected as the supf. wall, forming a fold enclosing the **caudal recess of the omental bursa** (16). **Ventrally**, because the attachment of the dorsal mesogastrium to the rumen followed the right longitudinal, caudal, and left longitudinal grooves, the ventral sac is enclosed by the greater omentum and forms a part of the wall of the omental bursa. **On the right**, the greater omentum is adherent to the medial surface of the mesoduodenum from the cranial flexure, along the descending part, to the caudal flexure of the duodenum (p. 69, 12). In the sling formed by the deep and supf. walls of the greater omentum between the mesoduodenum and the right longitudinal groove of the rumen, is the **supraomental recess** (13), open caudally and containing the bulk of the intestines. The deep wall of the greater omentum passes from the mesoduodenum, ventral to the intestines, to its attachment in the right longitudinal groove of the rumen, whereas the supf. wall passes ventral to the intestines and the ventral sac of the rumen to the left longitudinal groove. Both walls of the omentum meet in the caudal groove. Cranial parts of the dorsal mesogastrium disappear or are shortened in the adult by expansion of the atrium and adhesion with its surroundings. The spleen on the left and the left lobe of the pancreas are held between the rumen and the diaphragm by adhesions. The line of origin of the dorsal mesogastrium is displaced to the right and runs obliquely craniocaudally from the level of the esophageal hiatus through the origin of the celiac a. to the level of the distal loop of the ascending colon.

The **ventral mesogastrium** is divided by the developing liver into the **lesser omentum** on the visceral surface of the liver and the **falciform lig.** (see p. 75, 13) on the diaphragmatic surface. The lesser omentum extends, as the **hepatogastric lig.**, from the porta of the liver ventrally to the esophageal hiatus, the lesser curvature of the reticulum, the base of the omasum, and the lesser curvature of the abomasum, covering the right surface of the omasum (p. 69, 30). The lesser omentum ends as a free border, the **hepatoduodenal lig.**, from the porta of the liver to the cranial flexure of the duodenum. It contains the portal vein and forms the ventral border of the **omental (epiploic) foramen**, which leads to the **vestibule of the omental bursa**. The vestibule opens into the caudal recess.

Gastric Vessels, Nerves, and Lymph nodes



Legend:

- A Reticuloabomasal Inn.
- B Ruminoabomasal Inn.
- C Left ruminal Inn.
- D Right ruminal Inn.
- E Splenic (or atrial) Inn.
- F Reticular Inn.
- G Dorsal abomasal Inn.
- H Ventral abomasal Inn.

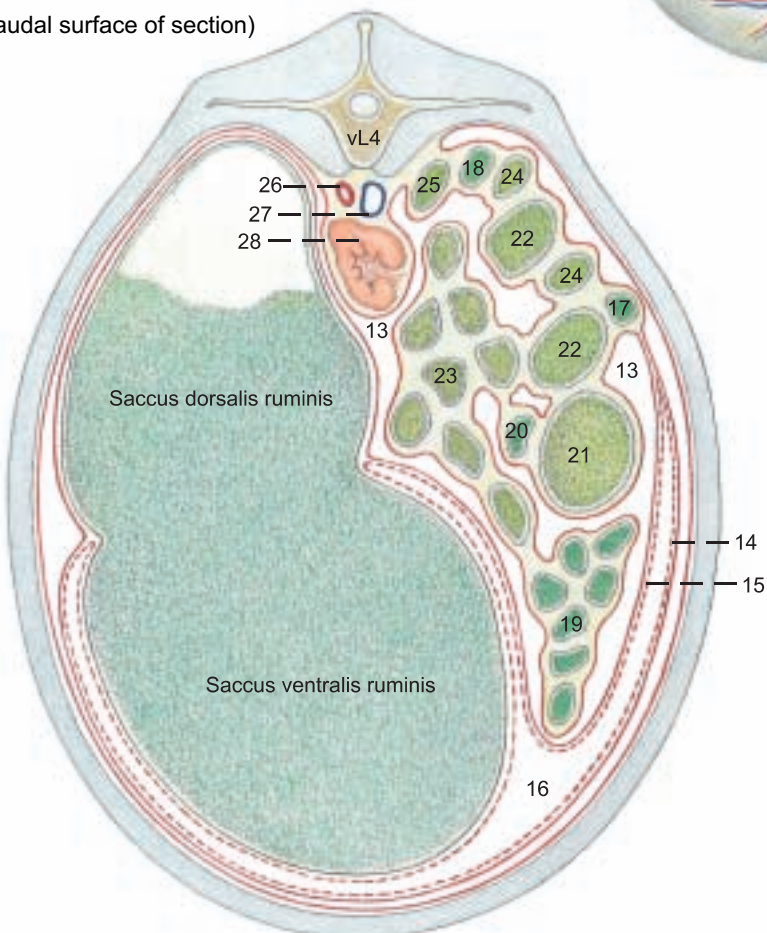
- a Dorsal vagal trunk
- b Right ruminal br.
- c Br. to celiac plexus
- d Dorsal ruminal br.
- e Left ruminal br.
- f Br. of the dorsal vagal trunk
- g Br. to greater curvature of abomasum
- h Atrial br.
- i Communicating br.
- j Ventral vagal trunk
- k Cran. reticular br.
- l Atrial br.
- m Br. of the ventral vagal trunk
- n Omasal br.
- o Parietal abomasal br.
- p Long pyloric br.

Legend:

- 1 Celiac a.
- 2 Hepatic a.
- 3 Splenic a. and v.
- 4 Right ruminal a. and v.
- 5 Left ruminal a.
- 6 Reticular a. and v.
- 7 Caud. esophageal br.
- 8 Left gastric a. and v.
- 9 Left gastroepiploic a. and v.
- 10 Accessory reticular a. and v.
- 11 Right gastric a. and v.
- 12 Right gastroepiploic a. and v.

Greater omentum and Viscera

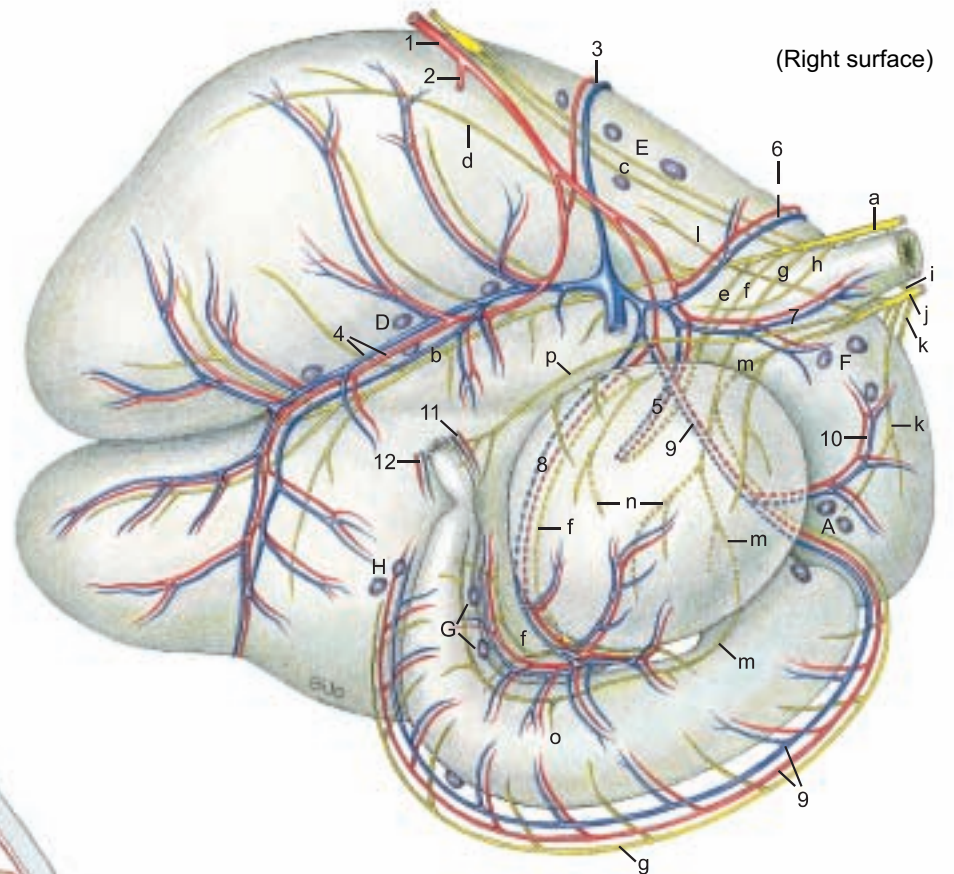
(Caudal surface of section)



Legend:

- 13 Supraomental recess
- Greater omentum:
- 14 Superficial wall
- 15 Deep wall
- Omental bursa:
- 16 Caudal recess
- Duodenum:
- 17 Descending part
- 18 Ascending part
- 19 Jejunum
- 20 Ileum
- 21 Cecum
- Ascending colon:
- 22 Proximal loop
- 23 Spiral loop
- 24 Distal loop
- 25 Descending colon
- 26 Aorta
- 27 Caudal vena cava
- 28 Left kidney

(See pp. 65, 67)



5. SPLEEN, LIVER, PANCREAS, AND LYMPH NODES

a) The **SPLEEN** is relatively small, red-brown in the bull and blue-gray in the cow. It is up to 50 cm long and its average weight varies with sex, age, and body size from 390 to 2000 g. It is an elongated oval, tongue-shaped organ of about equal width throughout. Its position is almost vertical (see p. 69, 4). The **dorsal end** (2) is near the vertebral column and the **ventral end** (6) is a hand's breadth dorsal to the 7th–8th costochondral junction. The **cranial** (4) and **caudal** (5) **borders** are rounded in the bull, acute in the cow. The spleen does not extend caudal to the line of pleural reflection. The **diaphragmatic surface** is applied to the diaphragm; the **visceral surface**, dorsomedially to the atrium of the rumen and cranioventrally to the reticulum. Both surfaces of the dorsal part are more or less extensively fused with the surroundings, so that a **phrenicosplenic lig.** (1) and a **gastrosplenic lig.** are only vestigial. The rather small **hilus** (3) is in the dorsal third of the cranial border in the area of adhesion to the rumen.

b) The **LIVER** reaches its adult size by the third year and after that its weight ranges from 4–10 kg depending on breed, age, and nutritional condition. The weight is relatively greater in the calf. Its color varies from yellowish in the calf to reddish-brown in the adult. *Because of the enlargement of the rumen it is almost entirely displaced to the right (see p. 69), except for a small portion ventral to the esophagus.*

The right lobe is caudodorsal and the left lobe is cranioventral. The thick **dorsal border** (28) is almost in the median plane. Here the caudal vena cava (h) runs in a groove inclined ventrally to the foramen venae cavae. Between the caudate lobe and the left lobe is the esophageal impression (w), distinct only in fixed livers. The acute **ventral border** (27) is *caudoventral on the right*. The fixed specimen shows a large omasal impression (q) and ventral to it, a reticular impression (r). In contrast to the dog and horse the liver is not distinctly lobated. Except for the **fissure for the round ligament** (p), *interlobar notches are absent*. The left lobe (26) is not divided. The gallbladder fossa separates the **right lobe** (17), undivided as in the horse, from the **quadrate lobe** (22). The **caudate lobe** lies between the vena cava and the left (intrahepatic) branch of the portal vein. As in the dog it has a **papillary process** (24), which overlaps the left branch of the portal vein. The short **caudate process** (15) overlaps the right lobe and is partially fused with it. Together they form the renal impression for the cranial end of the right kidney. On the visceral surface is the **porta hepatis** where the portal v., hepatic a., and autonomic nn. enter the liver, and the bile-carrying hepatic duct and lymph vessels leave the liver. Of the hepatic ligaments, the **right triangular lig.** (7) goes to the dorsal abdominal wall, and dorsomedial to it, the **hepato-renal lig.** (8) connects the caudate process to the right kidney. The **left triangular lig.** (14) is found on the diaphragm near the esophageal hiatus. The **coronary lig.** (21) attaches the liver to the diaphragm and connects the triangular ligg. and the falciform lig. Its line of attachment to the liver passes from the left triangular lig. around ventral to the caud. v. cava and along the right side of the caud. v. cava. On the right lobe it divides into two laminae that surround the **area nuda** (16). The **falciform lig.** (13) with the **round lig.** in its free border is attached to the diaphragmatic surface of the liver on a line from the coronary lig. at the foramen venae cavae to the fissure for the round lig. It is attached to the diaphragm on a horizontal line from the foramen venae cavae to the costochondral junction. Unlike that of the horse, it does not go to the umbilicus. The diaphragmatic attachment is a secondary adhesion resulting from the displacement of the liver to the right, and in many adults the falciform and round ligg. have disappeared. The **gallbladder** (25) is pear-shaped with a total length of 10–15 cm. It extends beyond the ventral (right) border of the liver. The right and left hepatic ducts join to form the **common hepatic duct** (18), which receives the **cystic duct** (20) and becomes the short, wide **common bile duct** (19, ductus choledochus), which opens into the duodenum about 60 cm from the pylorus on the oblique **greater duodenal papilla**. Hepatocystic ducts open directly into the gall bladder.

c) *The main duct of the bovine PANCREAS is the accessory pancreatic duct (m), which opens in the descending duodenum 30–40 cm from the greater duodenal papilla. The pancreatic duct is represented in the ox by small ducts that open into the common hepatic duct in its course across the pancreas.* The left lobe (10) extends to the spleen and is attached by connective tissue to the rumen and the left crus of the diaphragm. The **body of the pancreas**

(12) lies between the liver and the omasum ventral to the portal vein, which passes dorsally through the **pancreatic notch** (11) to the liver. The **right lobe** (9) is enclosed in the mesoduodenum descends and extends to the plane of the right kidney.

d) The **LYMPH NODES** of the spleen, liver, and pancreas.

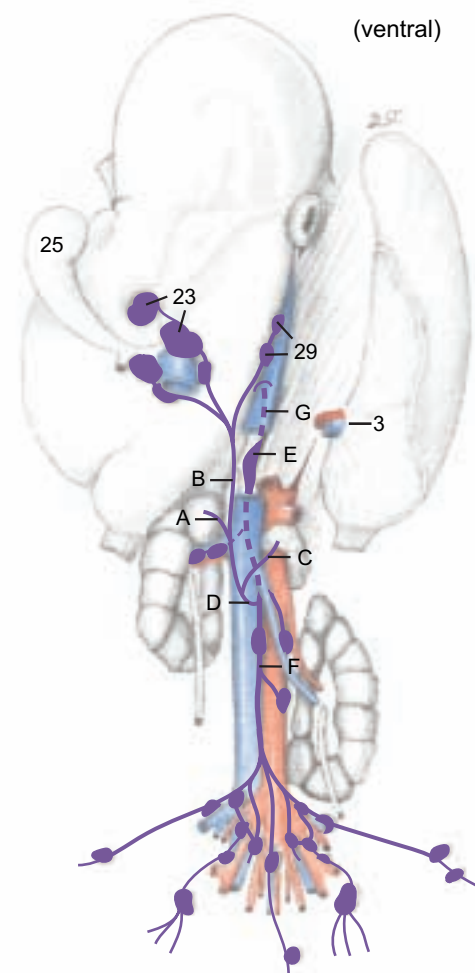
The 1–7 **splenic lnn.** (p. 73) lie dorsocranial to the spleen between the atrium of the rumen and the left crus of the diaphragm, and *are regularly examined in meat inspection.*

The 6–15 **hepatic (portal) lnn.** (23) are grouped around the porta of the liver and *are regularly examined in meat inspection.* The **accessory hepatic lnn.** (29) are found on the dorsal border of the liver near the caudal vena cava. The outflow of lymph occurs, together with that of the dorsal and ventral abomasal lnn., through the hepatic trunk. The **pancreaticoduodenal lnn.** (see p. 76, I) lie between the pancreas and descending duodenum and between the pancreas and transverse colon.

The lymph drainage is through the **intestinal trunk** (A) which joins the **hepatic trunk** (B), and after receiving the **gastric trunk** (C) with lymph from the stomach and spleen, becomes the **visceral trunk** (D) and enters the **cisterna chyli** (E). The valveless cisterna chyli receives the **lumbar trunk** (F), which drains the lymph from the pelvic limbs, genital organs, and the pelvis.

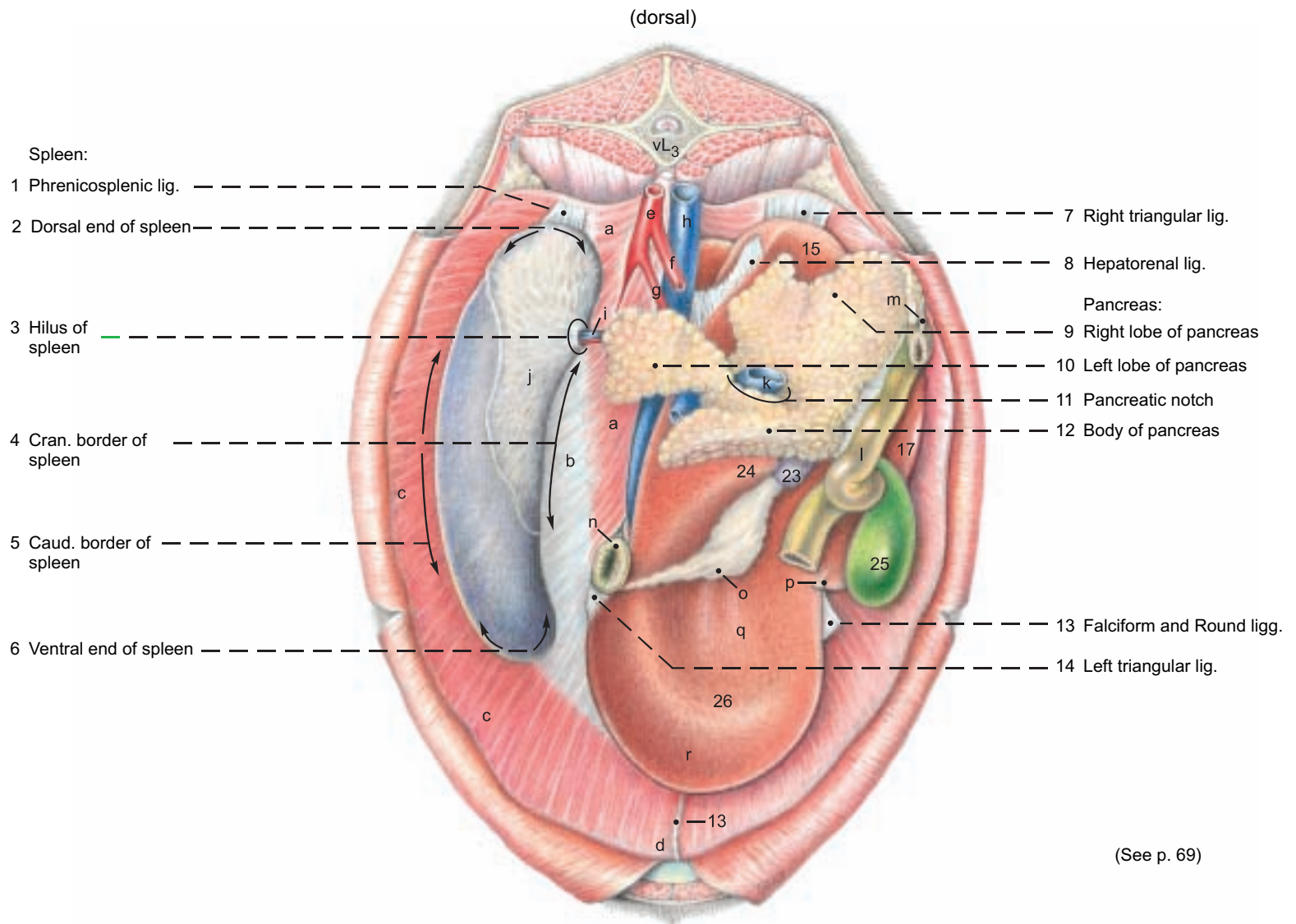
The **thoracic duct** (G), *emerging cranially from the cisterna chyli, passes in the ox through a slit in the muscle of the right crus of the diaphragm into the thorax. It does not pass through the aortic hiatus as in the horse and dog.* For lymph nodes of the pelvic cavity, see also pp. 82–83.

Lymph nodes and Lymphatic vessels*



(See p. 82)

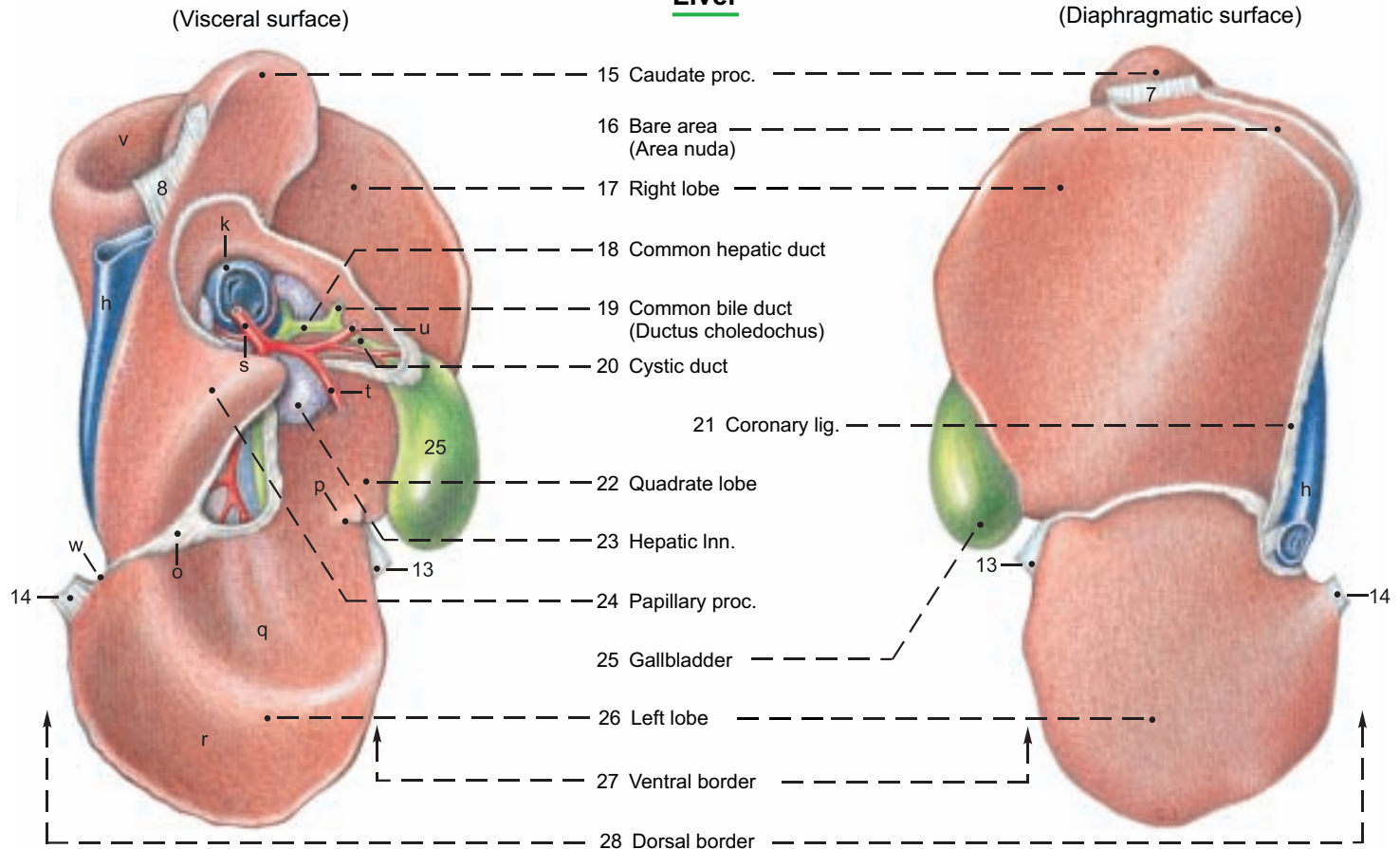
Spleen, Liver, and Pancreas (Abdominal surface of diaph)



Legend:

- | | | | | |
|--------------------|-----------------------|-----------------------------|--------------------------|------------------------------------|
| Diaphragm: | e Aorta | j Splenico-ruminal adhesion | o Lesser omentum | t Right gastric a. |
| a Lumbar part | f Cran. mesenteric a. | k Portal v. | p Fissure for round lig. | u Gastroduodenal a. |
| b Tendinous center | g Celiac a. | l Duodenum | q Omasal impression | v Renal impression |
| c Costal part | h Caud. vena cava | m Accessory pancreatic duct | r Reticular impression | w Esophageal impression (cut edge) |
| d Sternal part | i Splenic a. and v. | n Esophagus | s Hepatic a. | |

Liver



6. INTESTINES WITH BLOOD VESSELS AND LYMPH NODES

a) The **INTESTINAL TRACT** is displaced to the right half of the abdominal cavity by the enormous expansion of the stomach, primarily the rumen, on the left. Most of the intestines, attached by the mesentery, lie in the supraomental recess. The intestinal tract has considerable length – 33–59 m, whereas the lumen, especially of the large intestine, is small compared to the horse.

The **small intestine** has a total length of 27–49 m. The **duodenum** begins ventrally on the right at the pylorus with the **cranial part (1)**, which runs dorsally to the porta of the liver. Here it forms the **sigmoid flexure (1)**, turns caudally at the **cranial flexure**, and continues as the **descending part of the duodenum (2)** (see also p. 69). This runs caudodorsally, accompanied at first by the right lobe of the pancreas, to the plane of the tuber coxae. Here it turns sharply medially around the caudal border of the mesentery at the **caudal flexure (3)**, and continues cranially as the **ascending part of the duodenum (4)**. The **descending colon (17)** is dorsal to the ascending duodenum and adherent to it. The caudal free border of this adhesion is the **duodenocolic fold (5)**. Under the left lobe of the pancreas and on the left side of the cranial mesenteric a., the ascending duodenum passes through the duodenojejunal flexure into the **jejunum (6)**. This surrounds the disc of the coiled colon like a wreath. It begins cranially at the liver and pancreas and runs caudoventrally through many loops until it passes without a clear boundary into the ileum cranial to the pelvic inlet. The **caudal part, called the “flange”** is of clinical significance because of its longer mesentery. The **ileum (7)** is described as the part of the small intestine attached to the **ileocecal fold (8)**, but in the ox the fold extends on the left side of the mesentery to the apex of the flange.* Therefore by this definition the bovine ileum has a convoluted part as well as the 1 m long straight part near the cecum. The ileum opens into the large intestine at the **ileal orifice**, on the **ileal papilla** (p. 77, lower figure) which marks the boundary between the cecum and colon at the transverse plane of the 4th lumbar vertebra.

The **large intestine** including the cecum, colon, and rectum has neither bands nor sacculations, unlike that of the horse. The **cecum** is cylindrical, 50–70 cm long, and slightly curved. It lies in the dorsal part of the right abdominal cavity and extends to the pelvic inlet with a free, rounded blind apex (10). The **body of the cecum (9)** is attached by the common mesentery to the proximal and distal loops of the colon, and is continuous with the colon, with no change in the lumen, at the **cecocolic orifice** (p. 77, lower figure). The **colon** is about 7–9.5 m long, and consists of the ascending colon, transverse colon, and descending colon.* The **ascending colon**, the longest part of the large intestine, has three parts. The **proximal loop (11)** runs cranially for a short distance to the plane of the right kidney, where it doubles back dorsal to the first part and the cecum. It then turns mediadorsally around the caudal border of the mesentery and runs cranially on the left side of the mesentery. Near the left kidney it becomes narrower and turns ventrally into the elliptical coil formed by the **spiral loop**. This is variable, but usually consists of 1.5–2 **centripetal gyri (12)**, the **central flexure (13)**, and the same number of **centrifugal gyri (14)**. The last (outer)

centrifugal gyrus passes into the narrow **distal loop (15)** at the plane of the first lumbar vertebra. The distal loop runs first dorso-caudally on the left side of the mesentery, ventral to the ascending duodenum and dorsal to the proximal loop. At the plane of the 5th lumbar vertebra it turns sharply around the caudal border of the mesentery and runs forward on the right to the short **transverse colon (16)**. It turns around the cranial mesenteric a. from right to left and becomes the **descending colon (17)** that runs caudally ventral to the vertebral column. Its fat-filled mesocolon lengthens at the last lumbar vertebra, and the **sigmoid colon (18)** forms at the pelvic inlet. The **rectum (19)** begins at the pelvic inlet with a shortened mesorectum, but no structural transition.

b) The **MESENTERY**. The derivatives of the primitive dorsal mesentery that are attached to the parts of the small and large intestines are fused in the intestinal mass to form a **common mesentery**. Only the transverse and sigmoid colons have a free mesocolon. The proximal and distal loops and the cranial part of the descending colon are adherent to the cranial part of the cecum and ascending duodenum in a fat-filled mass around the root of the mesentery.

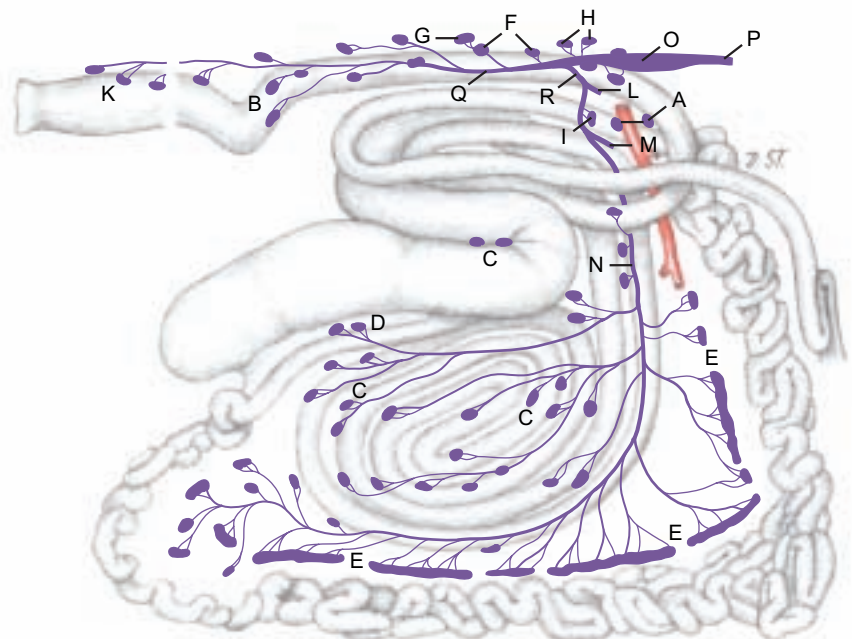
c) The **BLOOD SUPPLY** to the intestines comes from the cranial and caudal mesenteric aa. The long **cran. mesenteric a. (a)** gives off **pancreatic brr.** directly to the right lobe of the pancreas, and the **caud. pancreaticoduodenal a. (b)**. It also gives off the **middle colic a. (c)** directly. From the proximal part of the **ileocolic a. (d)** the **right colic aa. (e)** are given off to the distal loop of the colon and to the centrifugal gyri. From the distal part of the ileocolic a. the **colic branches (f)** go to the proximal loop of the colon and the centripetal gyri. All of the arteries of the spiral loop may originate from the ileocolic a. by a common trunk. They anastomose via collateral branches. The **cecal a. (g)** passes to the left of the ileocolic junction into the ileocecal fold and can give off an **antimesenteric ileal branch (h)**, which is constant in the dog. In addition, the **cranial mesenteric a. gives off a large collateral branch (i)**, peculiar to the ox, that runs in the jejunal mesentery along the last centrifugal gyrus, to which it gives branches, and rejoins the cranial mesenteric a. Both give off **jejunal aa. (f')** and finally anastomose with the **ileal aa. (k)**. The **mesenteric ileal branch (h')** from the ileocolic a. or cecal a. also supplies several branches to the neighboring parts of the spiral colon. The **caudal mesenteric a. (l)** gives off the **left colic a. (m)** to the descending colon, and the **cranial rectal a. (n)** and **sigmoidal aa. (o)**. The **portal v.** and its main branches are generally similar to those of the horse and dog. The veins predominantly follow the course of the corresponding arteries.

d) The **LYMPH NODES**. The **cranial mesenteric and celiac lnn. (A)** lie at the origin of the cranial mesenteric a. The following are regularly examined in meat inspection: the **jejunal lnn. (E)** are in the mesentery of the jejunum and ileum near the intestinal border, unlike the dog and horse. The **cecal lnn. (D)** are inconstant. Three groups of **colic lnn. (C)** are most numerous on the right surface of the spiral loop; others are present on the proximal and distal loops. The **caudal mesenteric lnn. (B)** are on the sides of the descending colon. The lymph drainage goes into the cisterna chyli.

Lymph nodes and Lymphatic vessels

Legend:

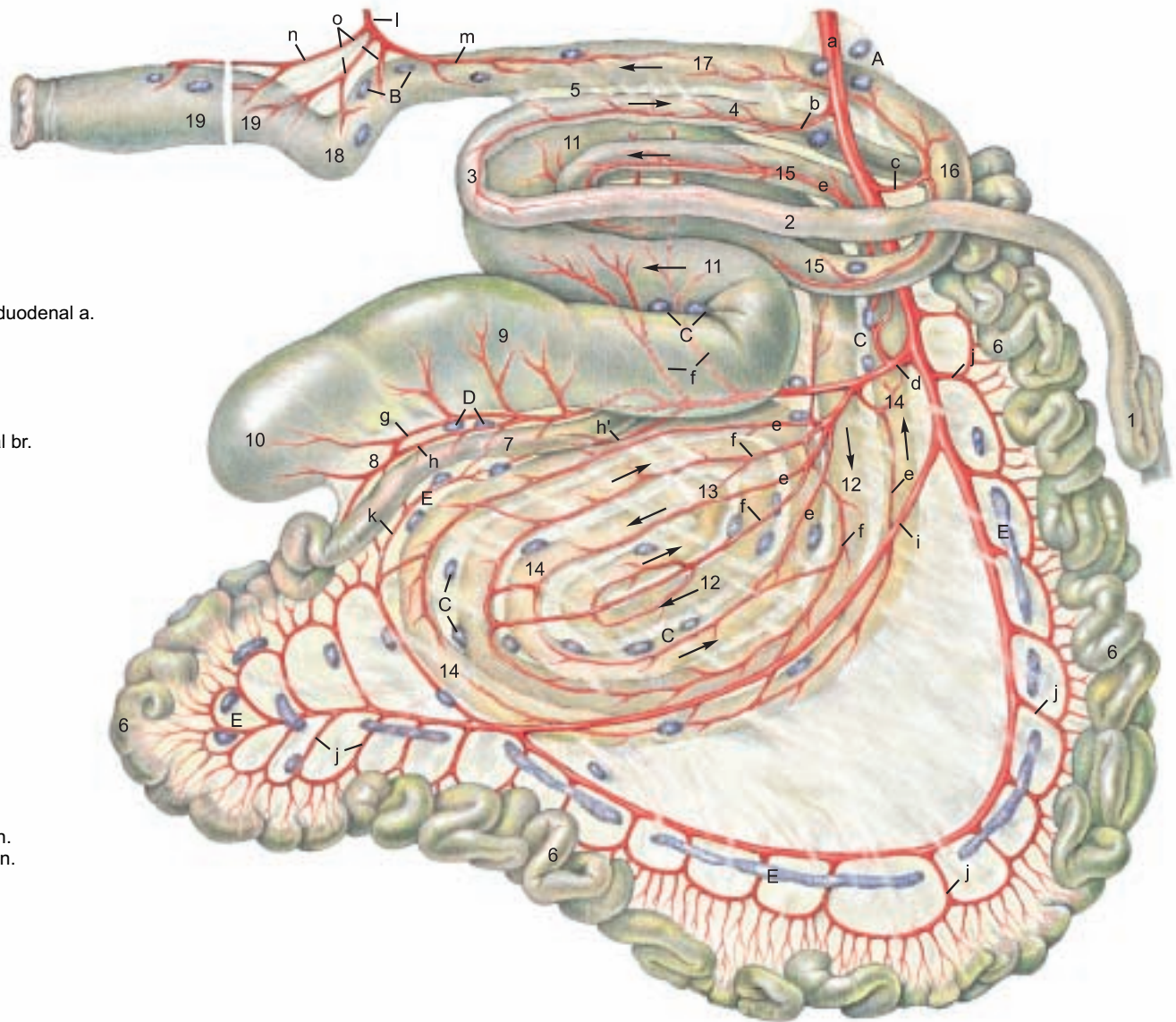
- A Celiac and cran. mesenteric lnn.
- B Caud. mesenteric lnn.
- C Colic lnn.
- D Cecal lnn.
- E Jejunal lnn.
- F Aortic lumbar lnn.
- G Proper lumbar lnn.
- H Renal lnn.
- I Pancreaticoduodenal lnn.
- K Anorectal lnn.
- L Gastric trunk
- M Hepatic trunk
- N Intestinal trunk
- O Cisterna chyli
- P Thoracic duct
- Q Lumbar trunk
- R Visceral trunk



* Smith, 1984

** see also Baum, 1912

Intestines (Right surface)



Legend:

- a Cran. mesenteric a.
- b Caud. pancreaticoduodenal a.
- c Middle colic a.
- d Ileocolic a.
- e Right colic a.
- f Colic branches
- g Cecal a.
- h Antimesenteric ileal br.
- h' Mesenteric ileal br.
- i Collateral br.
- j Jejunal aa.
- k Ileal a.
- l Caud. mesenteric a.
- m Left colic a.
- n Cran. rectal a.
- o Sigmoidal aa.

Legend:

- A Cran. mesenteric Inn.
- B Caud. mesenteric Inn.
- C Colic Inn.
- D Cecal Inn.
- E Jejunal Inn.

Legend:

Duodenum:

- 1 Cran. part and Sigmoid loop
- 2 Descending part
- 3 Caud. flexure
- 4 Ascending part
- 5 Duodenocolic fold

Jejunum

- 6 Jejunum
- 7 Ileum
- 8 Ileocecal fold

Cecum:

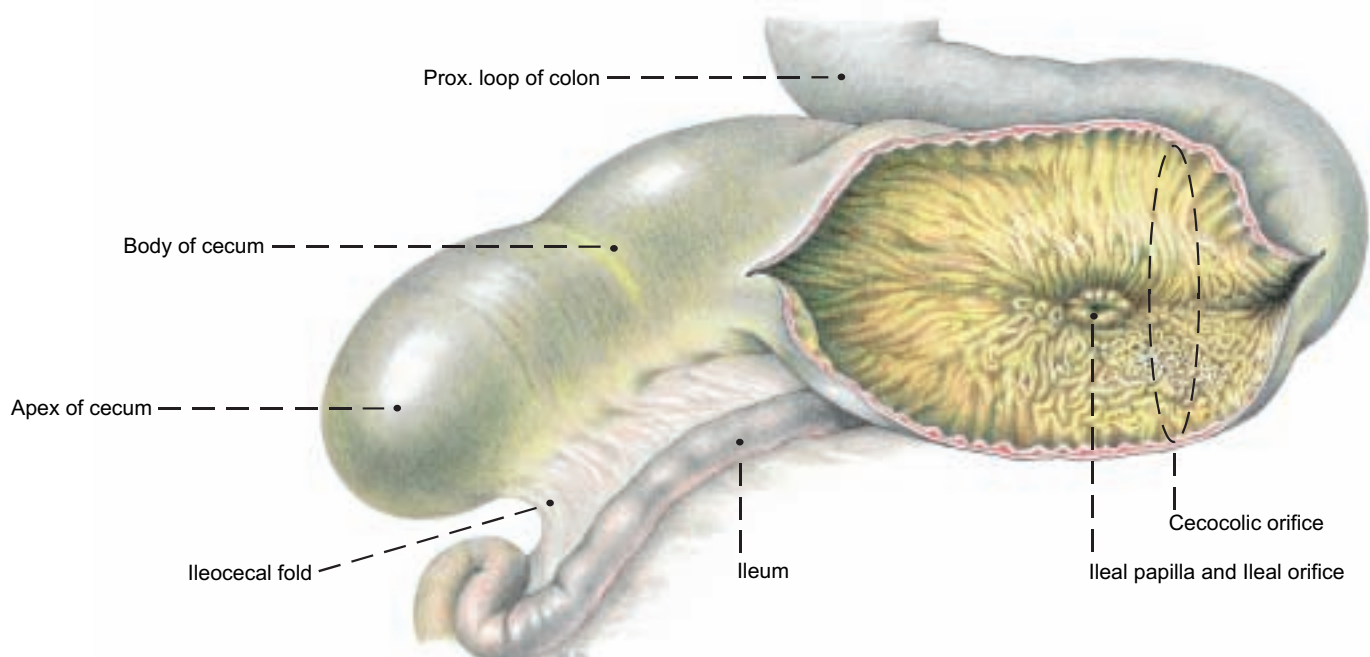
- 9 Body of cecum
- 10 Apex of cecum

Colon:

- Ascending colon:**
- 11 Prox. loop of colon
- Spiral loop of colon
- 12 Centripetal gyri
- 13 Central flexure
- 14 Centrifugal gyri

- 15 Distal loop of colon
- 16 Transverse colon
- 17 Descending colon
- 18 Sigmoid colon
- 19 Rectum

Cecum, Ileum, and Prox. loop of colon (cut open)



1. PELVIC GIRDLE WITH THE SACROSCIATIC LIG. AND SUPERFICIAL STRUCTURES IN THE PUBIC AND INGUINAL REGIONS

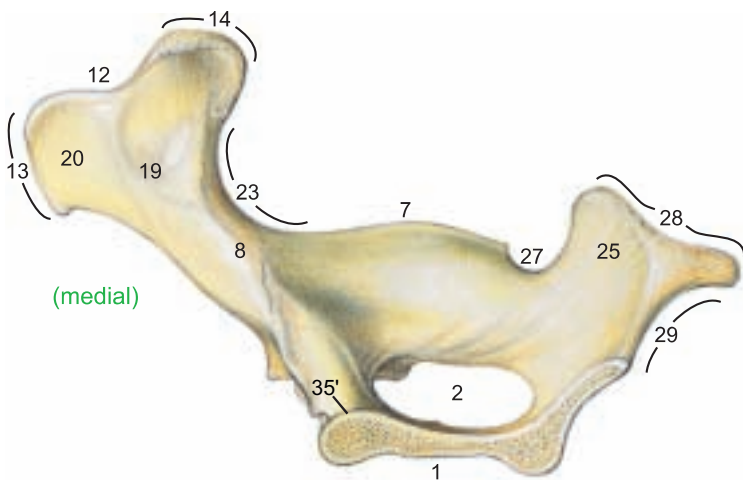
a) The **PELVIC GIRDLE** consists of the two hip bones (ossa coxarum), each composed of the fused ilium, pubis, and ischium. The two hip bones are joined in the pelvic symphysis, which ossifies progressively with age.

I. On the **ilium** the **tuber coxae** (13) is thick in the middle and undivided, and the **gluteal surface** (17) faces dorsolaterally. The **wing of the ilium** (10) is broad, but smaller than in the horse. On the **sacropelvic surface** (18) the **auricular surface** (19) and the **iliac surface** (20) are separated by a sharp crest.

II. On the **ischium** the **ischial tuber** (28) has three processes, and the **ischial arch** (29) is deep.

III. The right and left **pubic bones** join in the pubic symphysis to form a **ventral pubic tubercle** (35) and an **elongated dorsal pubic tubercle** (35'). The **iliopubic eminence** (34) is an imposing large rough tubercle. The **pelvic symphysis** (1) is composed of the pubic symphysis and the ischial symphysis. The latter is marked by a **ventral symphyseal crest** (1') with a prominent caudal tubercle. The **sciatic spine** (7) is high, with a sharp edge, and inclined slightly medially. In the **acetabulum** (3) the **lunar surface** (6) is divided by an additional cranioventral notch into a **lateral greater part** (6') and a **medial lesser part** (6''). The oval **obturator foramen** (2) is especially large, with a sharp margin. The pelvic floor slopes medioventrally, is excavated by a deep transverse trough, and rises caudodorsally. Sexual dimorphism is not as striking as in the horse. The transverse trough is broader in the cow.

Hip bone



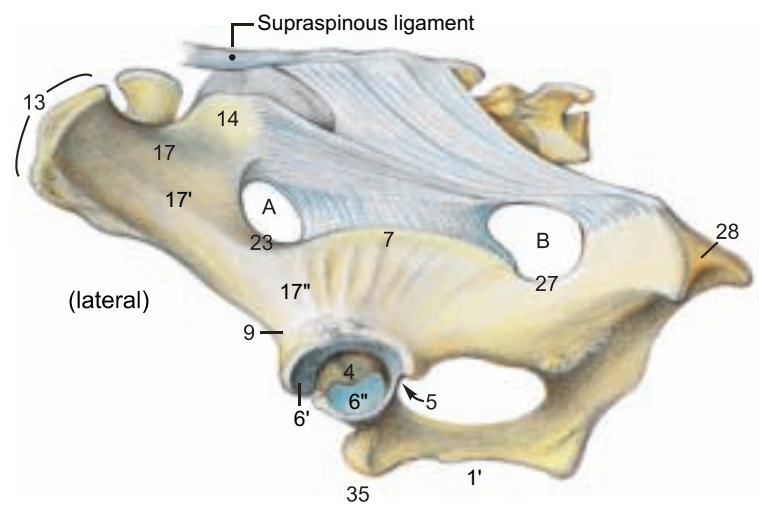
The bony pelvis is the solid framework of the birth canal which is evaluated by measurements (pelvimetry). The **transverse diameter** between the right and left **psaos tubercles** (22) is significant because constriction occurring there is a hindrance to the birth process. The **vertical diameter** extends from the cranial end of the pelvic symphysis to the dorsal wall of the pelvis. The farther caudally the vertical diameter meets the dorsal wall, the more this tight passage in the birth canal can be enlarged by drawing the pelvic floor cranially. (The pelvic ligg. are relaxed in parturition.) On the whole, the pelvis of the cow is not as well adapted to parturition as that of the mare.

b) The **SACROSCIATIC LIGAMENT (LIG. SACROTUBERALE LATUM)** extends from the lateral part of the sacrum to the ilium and ischium. The cranial part is attached to the **sciatic spine** (7) as far as the **greater sciatic notch** (23). Ventral to the sacral tuber it leaves the **greater sciatic foramen** (A) free for passage of the sciatic nerve and the cranial gluteal a., v., and n. The caudal (sacrotuberous) part of the ligament extends to the dorsal process of the tripartite **ischial tuber** (28). Cranial to that, in the **lesser sciatic notch** (27), is the **lesser sciatic foramen** (B) for the passage of the caudal gluteal a. and v. Because of the absence of vertebral heads of the caudal thigh muscles, the caudal part of the sacrosciatic lig. is the dorsolateral boundary of the ischiorectal fossa between the root of the tail and the ischial tuber. The fossa is also present in the dog, but not in the horse.

c) **SUPERFICIAL STRUCTURES IN THE PUBIC AND INGUINAL REGIONS**

The **intertendinous fossa** (2), open ventrally, is cranial to the ventral pubic tubercle and contains the terminal part of the linea alba (b). The fossa lies between bilateral semiconical pillars converging toward the symphyseal tendon at the apex of the prepubic tendon. These pillars are covered by the yellow abdominal tunic (a) and are formed by the abdominal tendons of the external oblique muscles sheathing the ventral borders of the rectus tendons. The latter fuse and terminate in the symphyseal tendon and on the symphyseal crest (1').

Sacrosciatic ligament



The **gracilis muscles** (5) originate mainly from the symphyseal tendon. The **external pudendal a. and v.** (1) pass through the **superficial inguinal ring** (8) as in the dog and horse. The caudomedial angle of the ring is close to the median plane.

The **lacuna vasorum** (9) is a space between the caud. border of the pelvic tendon of the ext. oblique and the ilium. It conducts the **femoral a. and v.** (4) through its lateral part and the **caudal (larger) head of the sartorius** (14) through its medial part. Cranial and caudal heads of the muscle embrace the femoral vessels and then unite below them to form a single muscle belly. The femoral a. and v. and saphenous n. pass laterally through the sartorius into the **femoral triangle** (p. 18, a) and are therefore covered medially by the muscle and not by fascia alone as in the dog and horse. (The lacuna vasorum was formerly called the femoral ring, and the femoral triangle was called the femoral canal by many veterinary anatomists, but the terms femoral ring and femoral canal are preempted for their meaning in human anatomy: the ring is in the medial angle of the lacuna vasorum, covered by transversalis fascia and peritoneum, and leads to the canal, which is only 1.25 cm long in man and contains nothing but fat and a lymph node. In adult domestic mammals the femoral ring is usually obscured by the **deep femoral (h) and pudendoepigastric (g) vessels.**) The large deep femoral vessels (h) usually originate from the external iliac vessels, give off the pudendoepigastric trunk and vein (g) in the abdominal cavity (p. 81, s, t), and pass out through the medial part of the lacuna vasorum, but the origin of the deep femoral vessels is variable. They may come from the femoral vessels in the femoral triangle, so that the pudendoepigastric a. and v. must pass back into the abdominal cavity through the femoral ring to reach the inguinal canal. They divide into the **caudal epigastric a. and v.** (p. 81, u) and the external pudendal a. and v. (1). The latter vessels always exit through the inguinal canal.

Through the **lacuna musculorum** (10) between the inguinal lig. and the ilium pass the iliopsoas, the smaller cranial head of the **sartorius** (14), the **femoral n.** (13), divided into its branches, and the **saphenous n.** (6). Ventrally the lacuna musculorum is covered by the yellow abdominal tunic and by the tendinous **femoral lamina** (12) from the **external oblique** (7), as in the horse.

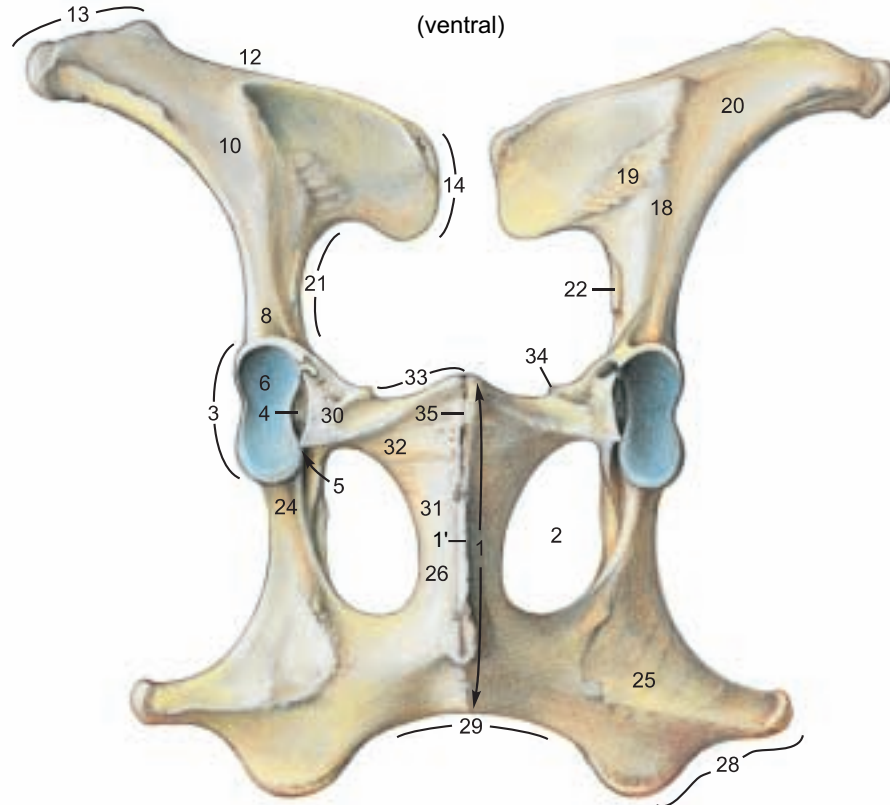
Bones of the pelvic girdle

Hip bone (Os coxae)

- Pelvic symphysis (1)
- Symphysial crest (1')
- Obturator foramen (2)
- Acetabulum (3)
- Acetabular fossa (4)
- Acetabular notch (5)
- Lunar surface (6)
- Greater part (6')
- Lesser part (6'')
- Sciatic spine (7)

Ilium

- Body of the ilium (8)
- Ventr. caud. iliac spine (9)
- Wing of the ilium (10)
- Iliac crest (12)
- Tuber coxae (13)
- Sacral tuber (14)
- Gluteal surface (17)
- Ventr. gluteal line (17')
- Caud. gluteal line (17'')
- Sacropelvic surface (18)
- Auricular surface (19)
- Iliac surface (20)
- Arcuate line (21)
- Tubercle of psoas minor (22)
- Greater sciatic notch (23)



Ischium

- Body of the ischium (24)
- Tabula of the ischium (25)
- Ramus of the ischium (26)
- Symphysial surface
- Lesser sciatic notch (27)
- Ischial tuber (28)
- Ischial arch (29)

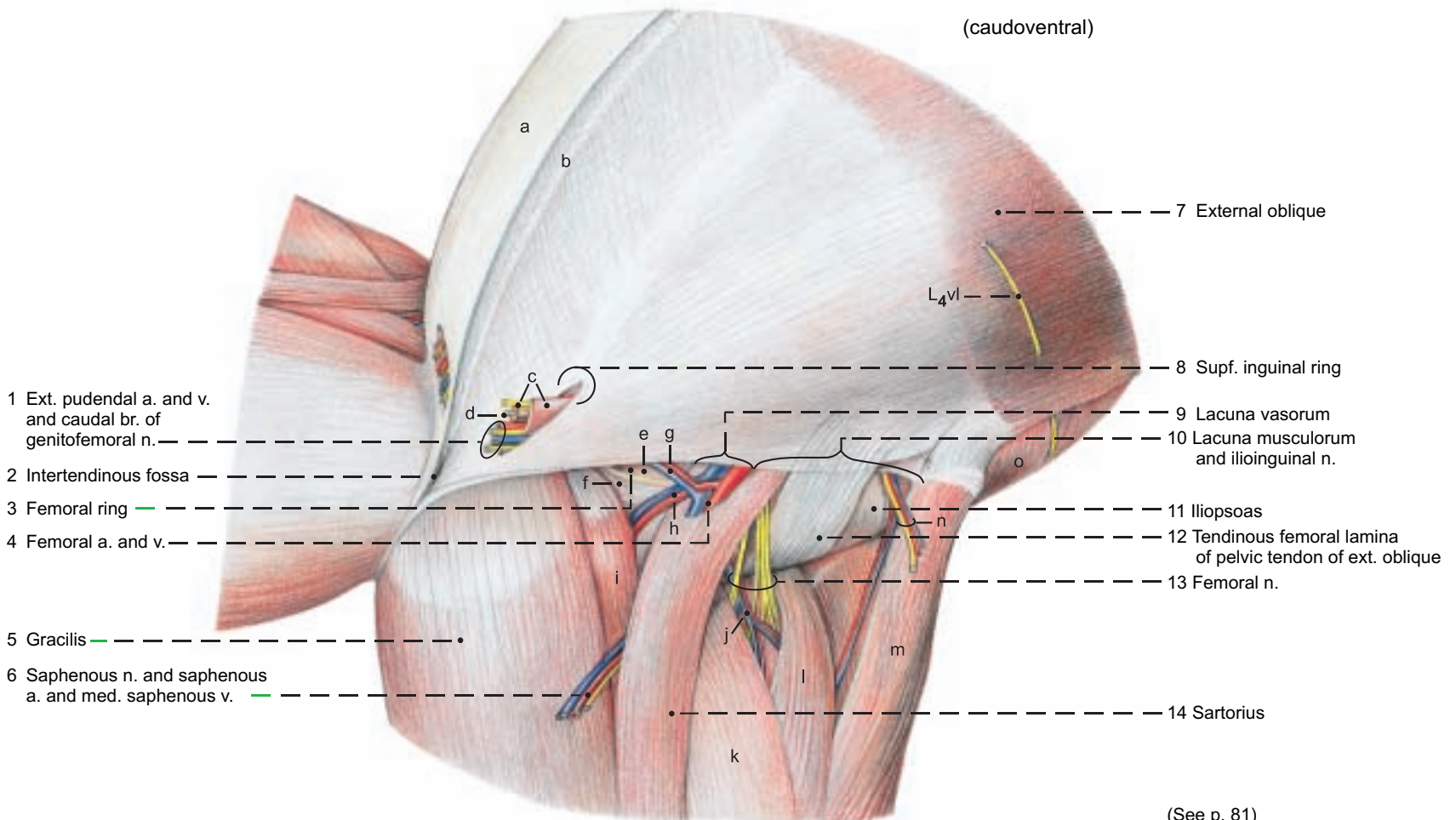
Pubis

- Body of the pubis (30)
- Caud. ramus of the pubis (31)
- Symphysial surface
- Cran. ramus of the pubis (32)
- Pecten pubis (33)
- Iliopubic eminence (34)
- Ventr. pubic tubercle (35)
- Dors. pubic tubercle (35')

Pubic and inguinal regions

Legend:

- | | | | |
|--|-------------------------------|---------------------------------|---------------------------------|
| a Yellow abdominal tunic | e Transversalis fascia | i Pectineus (and long adductor) | m Tensor fasciae latae |
| b Linea alba | f Transverse acetabular lig. | j Cran. femoral a. and v. | n Deep circumflex iliac a. |
| c Cremaster m. and cranial br. of genitofemoral n. | g Pudendoepigastric a. and v. | k Vastus medialis | and v. and lat. cut. femoral n. |
| d Tunica vaginalis | h Deep femoral a. and v. | l Rectus femoris | o Internal oblique m. |



(See p. 81)

2. INGUINAL REGION WITH INGUINAL CANAL, INGUINAL LIG., AND PREPUBIC TENDON

a) The **INGUINAL CANAL** extends from the **deep inguinal ring** (13) to the **superficial inguinal ring** (8). In the bull the **vaginal tunic** (18) with its contents and the **cremaster muscle** (19) pass through the canal. *In the cow the vaginal tunic and the cremaster are absent.* The round lig. of the uterus, unlike that of the bitch and mare, *ends on the internal surface of the abdominal wall near the inguinal canal without passing through it.* In both sexes, the inguinal canal, as in the dog and horse, conducts the external pudendal a. and v., the lymphatics, and the **genital branch of the genitofemoral n.** from L2, L3, L4. The latter is divided into **cranial** (19) and **caudal** (11) branches. *In the ox the angles of the deep inguinal ring are medial and dorsolateral; whereas those of the superficial ring are caudal and cranial.* The distance between the inguinal rings is much shorter medially than craniolaterally.

The length of the inguinal canal, as in the horse, is about 15 cm from the dorsolateral angle of the deep ring to the caudal angle of the superficial ring.

I. The **skin** is not involved in the formation of the inguinal canal. It is continuous with the skin of the scrotum or vulva.

II. The **yellow abdominal tunic** (7) is the deep elastic lamina of the external fascia of the trunk. At the level of the superficial inguinal ring it gives off the **elastic external spermatic fascia** (7'), *reinforces both angles of the ring*, and ensheathes the structures that pass through the ring. In the bull the **caudal preputial muscle** (see p. 66) *originates on the deep (spermatic) fascia mainly lateral to the vaginal tunic.* In the cow the yellow abdominal tunic forms the medial laminae and part of the lateral laminae of the **suspensory apparatus of the udder** (see p. 88). In the bull it gives off the **fundiform lig.** (from Latin: *funda* = sling): bilateral elastic bands that pass around the penis and blend with the scrotal septum. From the fascia on the lateral crus of the superficial inguinal ring, the **fascial femoral lamina** (10)* is given off toward the thigh as in the horse. *In the bull it is thick and elastic; in the cow it is thin and collagenous.* In the inguinal groove the fascia passes to the medial surface of the thigh as the femoral fascia. The **linea alba** (6) enters the prepubic tendon and splits into a dorsal (internal) part to the pecten pubis and a ventral (external) part to the symphyseal tendon and crest.

III. The aponeurosis of the **external oblique abdominal m.** (3) is divided by the **superficial inguinal ring** (8) into an abdominal tendon whose border is the **medial crus** of the ring, and a pelvic tendon whose border is the **lateral crus** of the ring. The two tendons overlap and join the prepubic tendon.

The aponeurosis of the **internal oblique abdominal m.** (12) and the abdominal tendon of the **external oblique** (5) form the cranial border of the **deep inguinal ring** (13). The caudal border is the pelvic tendon of the **external oblique** (4). The vaginal tunic with its contents and the cremaster pass through the **dorsolateral angle** (14) which is fixed by the origin of the internal oblique from the iliac fascia near the external iliac vessels. The ext. pudendal vessels and the genital branches of the genitofemoral n. go through the ring more medially. The **medial angle** (15) *lies close to the median line against the prepubic tendon.* The label, 2, marks only the caudal part of the prepubic tendon, which extends to the junction of the aponeurosis of the int. oblique (12) and the fused tendons of the **rectus abdominis mm.** (17). (See c) Prepubic tendon.) The caudal border of the **transversus** (16) is in the plane of the tuber coxae and has no relation to the inguinal canal.

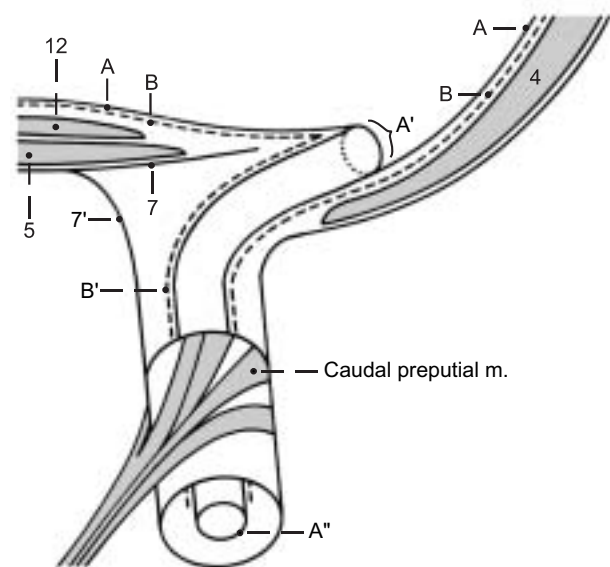
The **cremaster** (19) originates from the inguinal ligament and runs parallel to the caudal border of the internal oblique.

IV. The **fascia transversalis** (B) evaginates at first as the covering of the vaginal process of the peritoneum—the **internal spermatic fascia** (B') and after a short course becomes loose connective tissue. The bull lacks the annular thickening peculiar to the horse at the beginning of the evagination.

V. The **peritoneum** (A) evaginates at the **vaginal ring** (A') as the **vaginal process of the peritoneum** (A''), becoming the vaginal tunic after descent of the testis, passing through the inguinal canal into the scrotum, and covering the testis and epididymis.

b) The **INGUINAL LIG.** (20)** *consists of a twisted cord of fibers of the tendon of origin of the internal oblique that begins at the tuber coxae, is interwoven with the iliac fascia in its course, and, giving origin to the cremaster, ends lateral to the passage of the ext. iliac a. and v. through the lacuna vasorum.* Unlike the condition in the dog and horse, the inguinal lig. does not join the caudal border of the pelvic tendon of the ext. oblique at this point to form a continuous inguinal arch from the tuber coxae to the prepubic tendon.

Inguinal canal (transverse section)



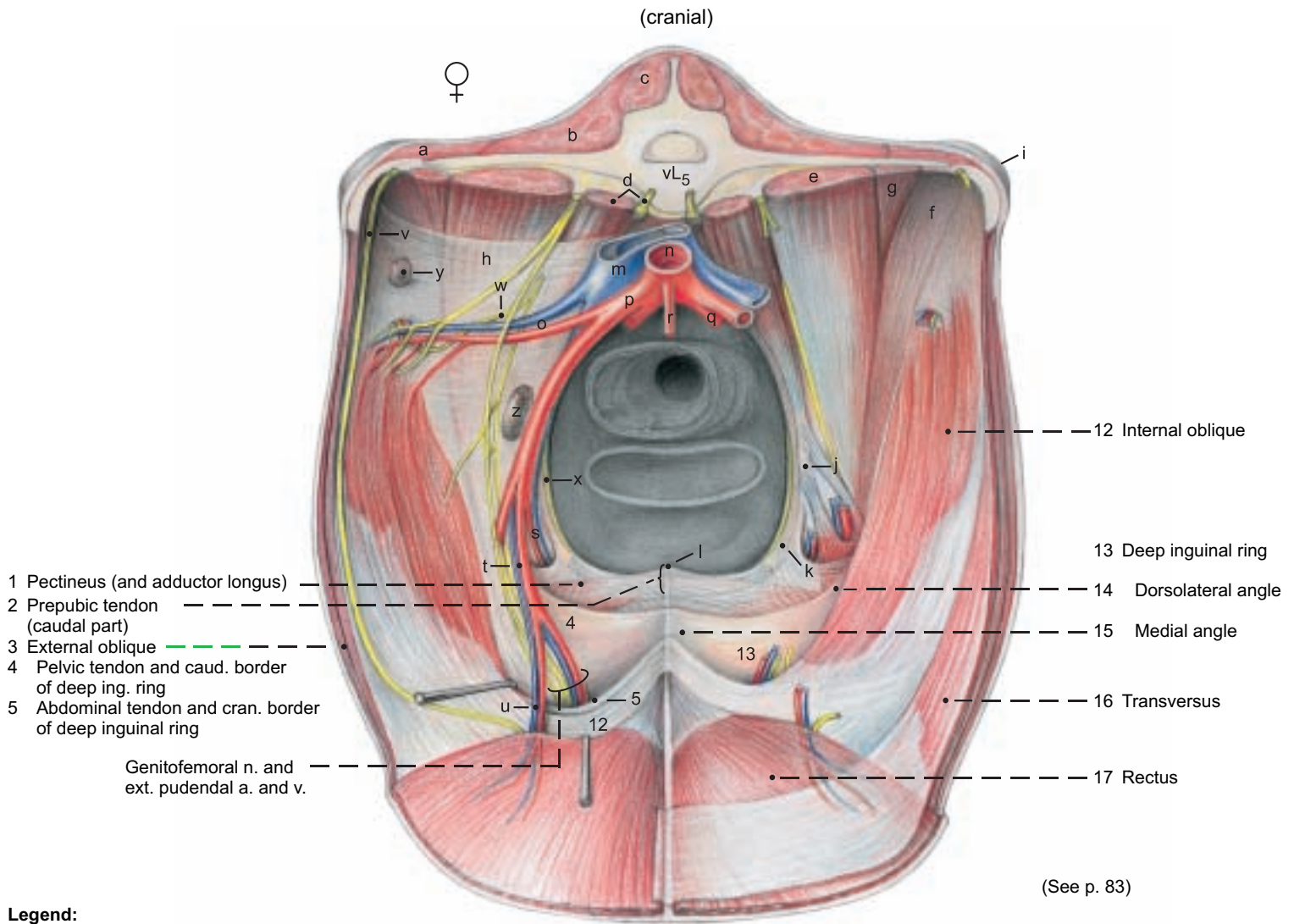
Ligamentous fibers that radiate into the pelvic tendon as in the dog and horse do not exist in the ox. In this region only the thickened caudal border of the pelvic tendon is functionally important.

c) The **PREPUBIC TENDON** (2) is attached to the pubic bones, primarily on the iliopubic eminences and the ventral pubic tubercle. It is also attached to the symphyseal tendon. It extends to junction of the aponeurosis of the **int. oblique** (12) and the fused tendons of the **recti** (17), but is not visible interiorly, except for its attachment on the pelvis. It consists of the crossed and uncrossed tendons of origin of the pectineus muscles and of the cranial parts of the gracilis muscles, and the pubic and symphyseal tendons of the recti and oblique abdominal muscles. The linea alba and the yellow abdominal tunic are also incorporated in it. Contrary to some authors, transverse ligamentous fibers connecting *right and left iliopubic eminences do not exist.* ***

* No tendinous lamina radiates from the lateral crus (it is composed of fascia).

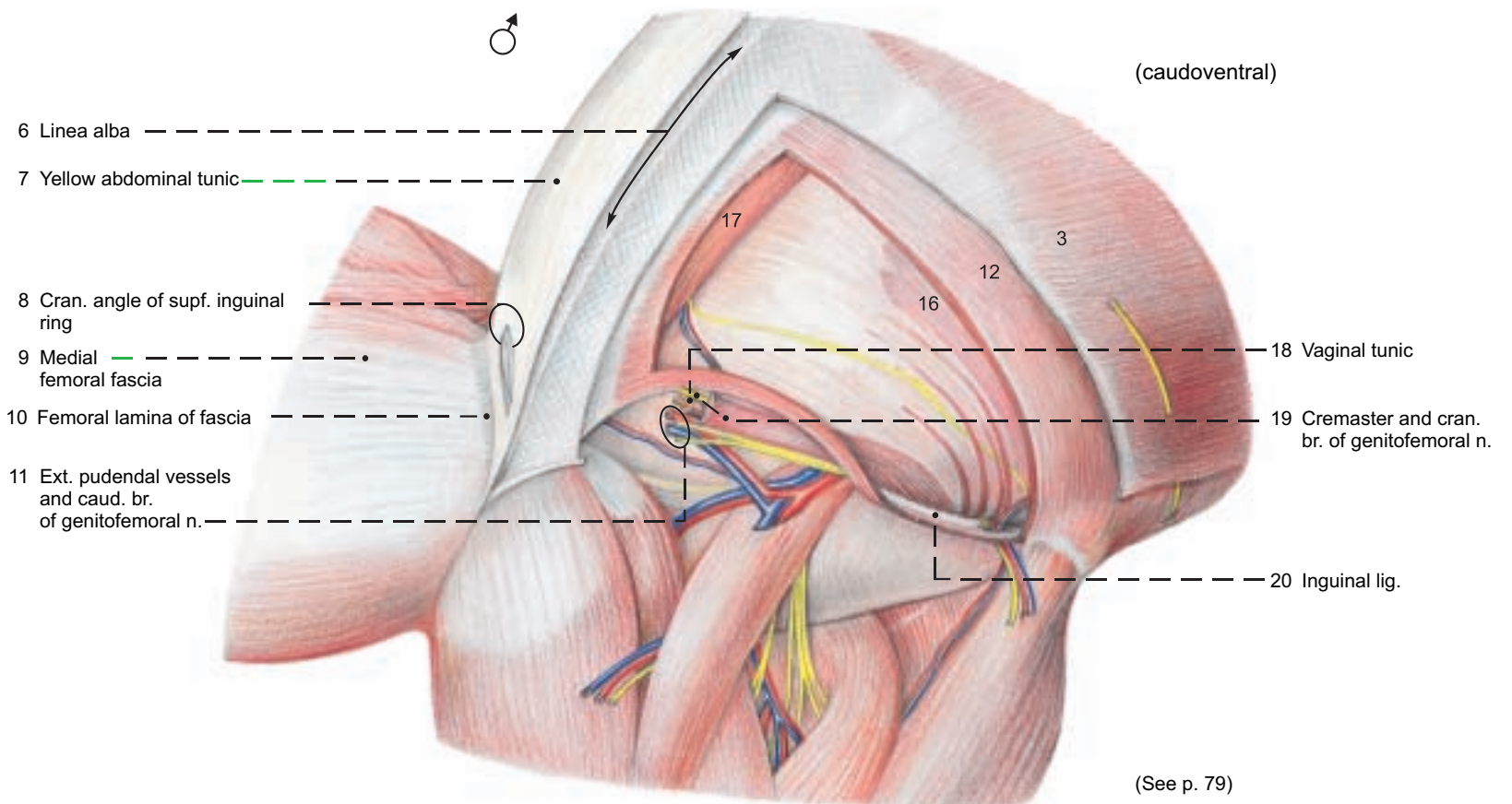
** Traeder, 1968 *** Habel and Budras, 1992

Inguinal canal, Inguinal lig., and Prepubic tendon



Legend:

- | | | | |
|---|-------------------------|---------------------------------|-------------------------------|
| a Iliocostalis | g Quadratus lumborum | n Aorta | u Caudal epigastric a. and v. |
| b Longissimus dorsi | h Internal iliac fascia | o Deep circumflex iliac vessels | v Iliohypogastric n. |
| c Multifidus | i Tuber coxae | p External iliac a. | w Lat. cut. femoral n. |
| d Psoas minor and sympathetic trunk iliopsoas | j Psoas minor tubercle | q Internal iliac a. | x Obturator n. |
| e Psoas major | k Iliopubic eminence | r Caudal mesenteric a. | y Lat. iliac ln. |
| f Iliacus | l Dorsal pubic tubercle | s Deep femoral a. and v. | z Iliofemoral ln. |
| | m Caudal vena cava | t Pudendoepigastric vessels | |



UQLiqNyNzKjvWvGT8zRmLEn5w==|1287792626

3. LYMPHATIC SYSTEM, ADRENAL GLANDS, AND URINARY ORGANS

After the study of the topography of the lymph nodes, adrenals, and urinary organs, the kidneys are removed with attention to their coverings, and their peculiarities in the ox are studied.

a) The **LYMPHATIC SYSTEM** in the dorsal abdominal and pelvic cavities includes the following lymph nodes.

The 12–15 small **lumbar aortic lnn.** (8) lie dorsal and ventral to the aorta and caudal vena cava and are *examined in meat inspection in special cases*. There are also *up to 5 inconstant unilateral or bilateral proper lumbar lnn. between the lumbar transverse processes*. The 1–4 **renal lnn.** (9) are found on both sides between the **renal a. and v.** (2). *They are routinely examined in meat inspection*. The lymph drainage is through the lumbar trunk or directly into the *cisterna chyli*. The **medial iliac lnn.** (4), 1–5 in number, lie at the origin of the **external iliac aa.** (f). The **lateral iliac ln.** (12) at the bifurcation of the **deep circumflex iliac a.** (11) may be double. *Both groups are routinely examined in meat inspection*. The **sacral lnn.** (5), 2–8 in number, lie in the angle between the **internal iliac aa.** (h). The **sciatic ln.** (p. 17, B) is in the lesser sciatic foramen or dorsal to it on the outside of the sacrosciatic ligament. The **anorectal lnn.** (p. 77) are dorsal and lateral to the rectum and anus. The **iliofemoral ln.** (6) is up to 9 cm long and located in the angle between the deep circumflex iliac and external iliac vessels. It is clinically important because it receives lymph from the superficial inguinal (mammary) lnn. and can be palpated per rectum cranial to the shaft of the ilium. *It is examined in meat inspection in cases of mastitis*. The lymph drainage from the iliac, sacral, sciatic, anorectal, and iliofemoral lnn. passes through the medial iliac lnn., the iliofemoral ln., or the lumbar trunk into the **cisterna chyli**, which is 1.5–2 cm long and extends from the last thoracic vertebra to the 1st or 2nd lumbar vertebra, dorsal to the vena cava and aorta.

b) The **ADRENAL GLANDS** (7) are 5–8 cm long, flattened, relatively smooth, and reddish brown to dark gray, sometimes also with black spots. Each weighs 15–23 g. They are retroperitoneal and covered ventrally by fat. The **right adrenal** is more or less heart-shaped and located at the 12th intercostal space craniomedial to the right kidney. It is partly covered ventrally by the caudal vena cava and attached to it by connective tissue. The **left adrenal** is comma-shaped and larger and heavier than the right. It lies in the plane of the 1st lumbar vertebra on the left side of the vena cava, to which it also is attached by connective tissue. It is usually several cm cranial to the left kidney.

c) The **URINARY ORGANS**

I. The **kidneys** differ remarkably in position as a result of the developmental expansion of the rumen.

The flat elongated oval **right kidney** (1) is retroperitoneal and extends from the 12th intercostal space to the 2nd or 3rd lumbar vertebra. The pit-like **hilus** is medial. The cranial end is in contact with the liver (see p. 75, v). The **dorsal surface** is applied to the right crus of the diaphragm and the lumbar muscles. The **ventral surface** lies on the pancreas, cecum, and ascending colon.

The **left kidney** (10) is not illustrated in its normal position. In the live ox *it is pushed to the right side by the rumen. It is almost completely surrounded by peritoneum and therefore pendulous, and lies ventral to lumbar vertebrae 2–5, and caudal to the right kidney, from which it is separated by the descending mesocolon. Because the left kidney undergoes a 90-degree rotation on its long axis, its hilus (24) is dorsal*. Medially it adjoins the rumen and laterally, the intestinal mass.

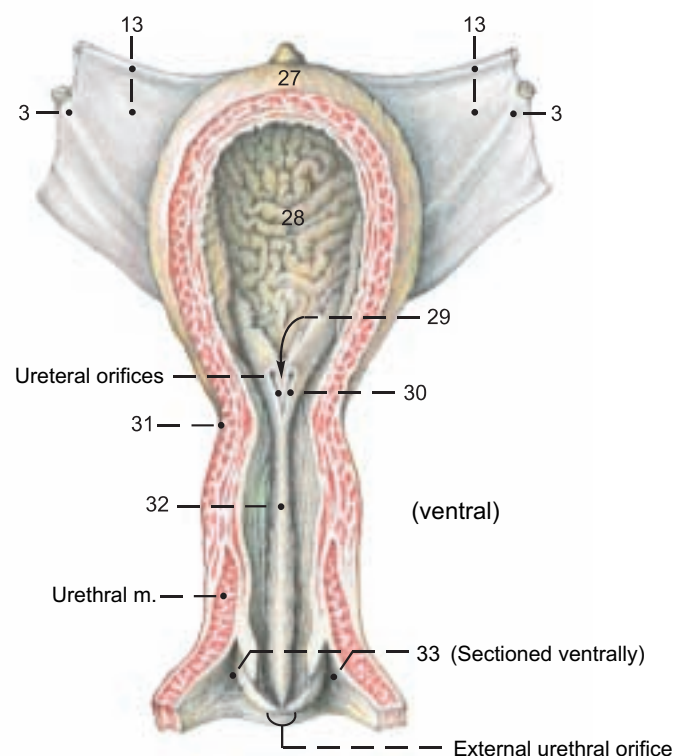
The kidneys are red-brown; their combined weight is 1200–1500 g. *They are marked on the surface by the renal lobes (26), unlike any other domestic mammal. In the ox, two or more fetal lobes remain distinct; others are partially or completely fused in the cortex, resulting in 12–15 simple or compound lobes of various sizes*. The actual boundaries of the lobes can be seen only by the course of the **interlobar aa. and vv.** (19). On the cut surface the reddish light brown **renal cortex** (23) with its distinct **renal columns** (21) *contrasts with the dark red external zone (17) and the light internal zone (18) of the renal medulla (15)*. The **renal pyramids** (16) *project with their prominent renal papillae (20) into the urine collecting renal calices (25)*. *These open into cranial and caudal collecting ducts which join within the irregular fat-lined renal sinus to form the ureter. The ox lacks a renal pelvis.*

II. In the standing live ox the **right ureter** (3) takes a course on the ventral surface of its kidney and *dorsal to the left kidney* toward the pelvic cavity. The **left ureter** *runs along the dorsal surface of the caudal half of its kidney, inclines to the left of the median plane and enters the urinary bladder.**

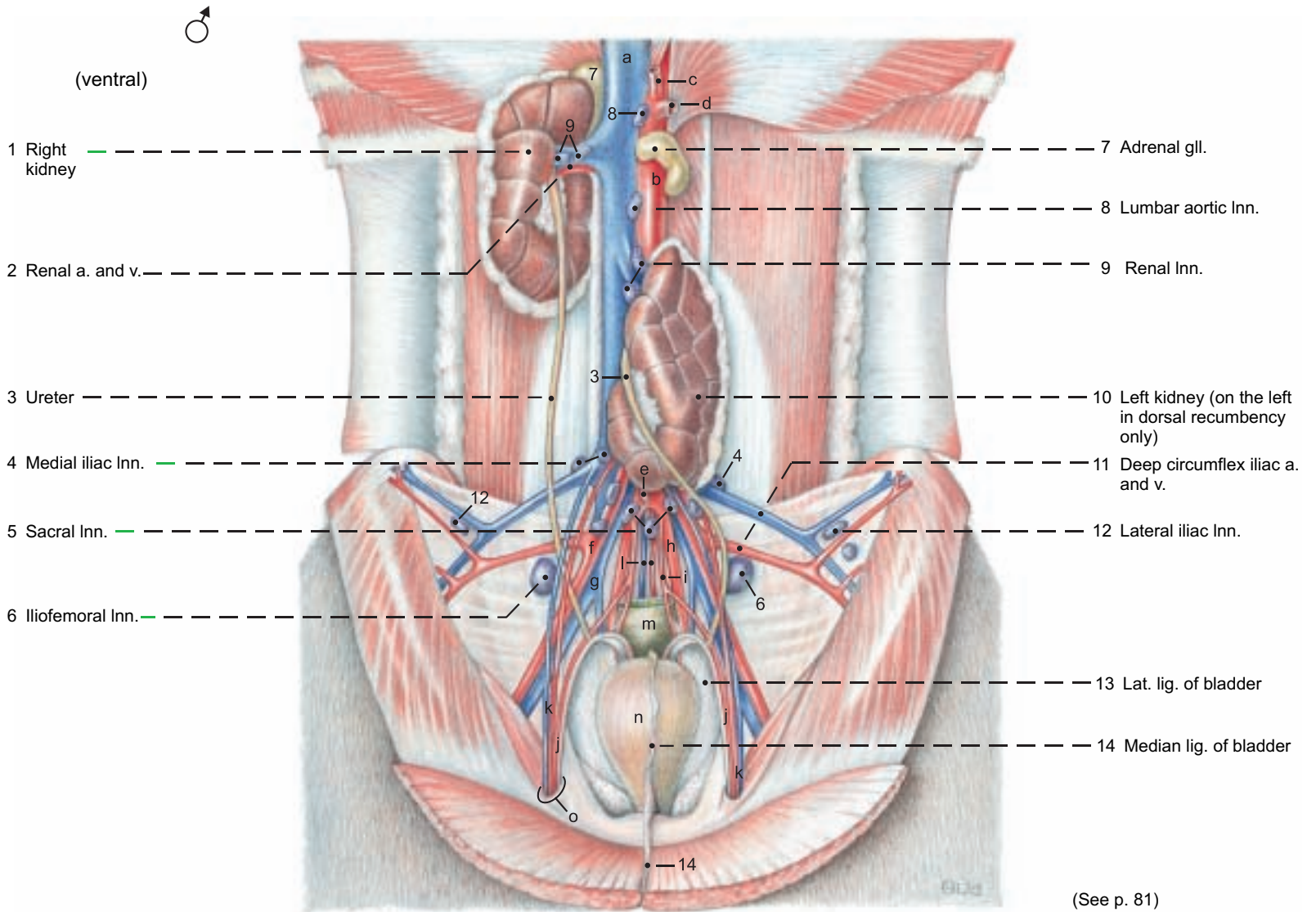
III. The **urinary bladder** (n) (see also text figure) is relatively large. When moderately filled it extends into the ventral abdominal cavity farther than in the horse. The **apex** (27) and **body** (28) are covered with peritoneum. The **neck** (31) is extraperitoneal and attached to the vagina by connective tissue. On the apex there is a distinct conical vestige of the urachus, which in the three-month-old calf can still be as long as 4 cm. The ureters open close together in the middle of the neck of the bladder. The **ureteric folds** (30) run caudally from there inside the bladder and converge to form the **narrow vesical triangle** (29). The **lateral ligaments of the bladder** (13) contain in their free border the *small, in old age almost obliterated, umbilical artery (round lig. of the bladder; p. 87, t)*. The **middle lig. of the bladder** (14) runs from the ventral wall of the bladder to the pelvic symphysis and to the ventromedian abdominal wall.

IV. The **male urethra** (see p. 92, K) consists of a **pelvic part** surrounded by a stratum spongiosum, and a **penile part** surrounded by the **corpus spongiosum penis**. The pelvic part is also surrounded by the disseminate prostate (see p. 92), and *ventrally and laterally* by the thick striated urethral muscle (93, g). Just inside the ischial arch is the **urethral recess**, *present in ruminants and swine; it opens caudally and practically prevents catheterization. The recess is dorsal to the urethra and separated from it by a fold of mucosa that bifurcates caudally into lateral folds on which the ducts of the bulbourethral glands open. The lumen of the urethra passes through the narrow slit between the folds.*

V. The **female urethra** (see text figure) *is about 12 cm long and attached to the vagina by connective tissue and the urethral muscle. The urethral crest (32), 0.5 cm high, passes through the urethra on its dorsal wall to the slit-like urethral orifice, which is on the cranial side of the neck of the clinically important, blind, suburethral diverticulum (33). The latter extends cranially for 2 cm from its common opening with the urethra on the floor of the vestibule, and must be avoided in catheterization. (See p. 87, x.)*



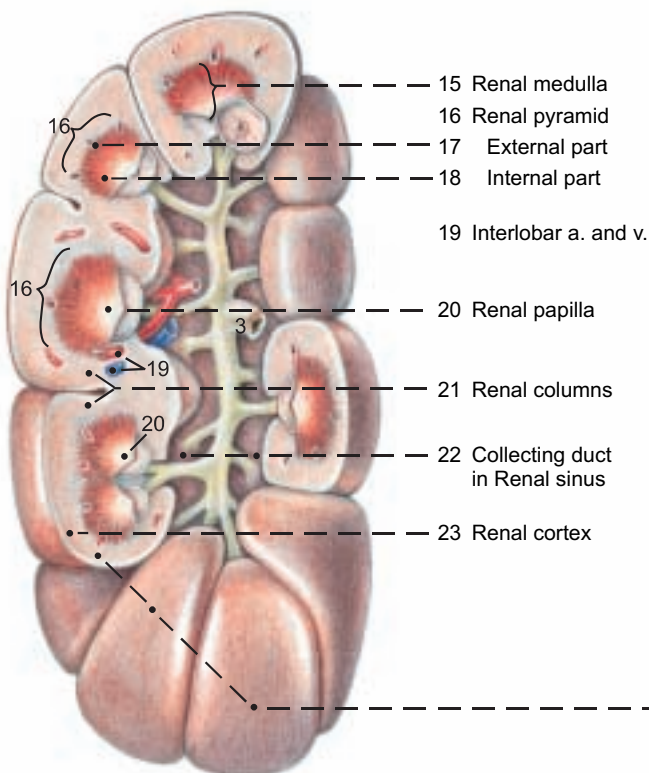
Abdominal cavity and Urinary organs as seen at autopsy, in dorsal recumbency with stomach and intestines removed



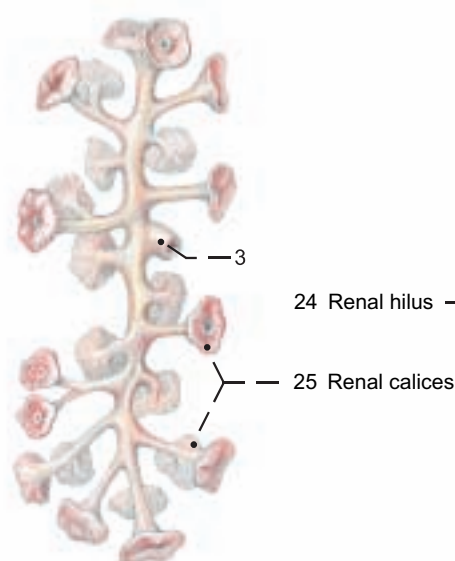
Legend:

- | | | | | |
|-------------------|-----------------------|-------------------|--|-------------------|
| a Caud. vena cava | d Cran. mesenteric a. | g Common iliac v. | j Ductus deferens and A. ductus deferentis | m Rectum |
| b Aorta | e Caud. mesenteric a. | h Int. iliac a. | k Testicular a. and v. | n Urinary bladder |
| c Celiac a. | f Ext. iliac a. | i Umbilical a. | l Median sacral a. and v. | o Vaginal ring |

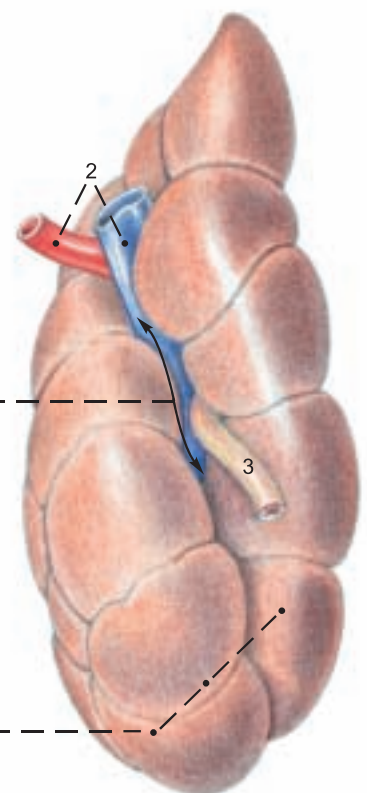
Right kidney (Sectioned)



Ureter and Calices (Right kidney)



Left kidney



5. ARTERIES, VEINS, AND NERVES OF THE PELVIC CAVITY

a) The **ABDOMINAL AORTA** (1) gives off the paired external iliac aa. at the level of the 6th lumbar vertebra, and the paired internal iliac aa. and the dorsally directed unpaired **median sacral a.** (13) at the level of the sacral promontory.

The **external iliac a.** (5), while still in the abdominal cavity, gives off the **deep circumflex iliac a.** (6) and shortly before entering the femoral triangle, it gives origin to the **deep femoral a.** with the attached **puddendoepigastric trunk** (7), which divides into the **caudal epigastric a.** (8) and the **external pudendal a.** (9). The latter passes through the inguinal canal and gives off branches to the scrotum or udder (see also p. 91). The **internal iliac a.** (15) is, in contrast to that artery in the dog and horse, *a long vessel that extends to the lesser sciatic notch and ends there by dividing into the caudal gluteal and internal pudendal aa.* Its first branch is the **umbilical a.** (17), which gives off the **a. of the ductus deferens** in the bull and the **uterine a.** (18) in the cow, and in both sexes the **cranial vesical a.** (19) with the obliterated termination of the umbilical a. as the **round lig. of the bladder.**

Also originating from the internal iliac a. are the iliolumbar a. (16) and the cranial gluteal a. (i). The **vaginal a.** (23) or **prostatic a.** originates at the level of the hip joint. Together with the internal pudendal a. their branches supply most of the pelvic viscera. The vaginal or prostatic a. supplies the **uterine br.** (24) or the **br. to the ductus deferens**, the **caudal vesical a.** (25) (which can also come indirectly from the int. pudendal a.), the **urethral br.** (27), the **middle rectal a.** (28), and, in the cow, the **dorsal perineal a.** (28), which ends as the **caudal rectal a.** (30). The dorsal perineal a. may give off the mammary br. (37).

The **int. pudendal a.** (32) gives off the **urethral a.** (33), the **vestibular a.** (34), the dorsal perineal a. in most bulls, and the **ventral perineal a.** (36) with its **mammary br.** (37), and ends as the **a. of the clitoris** or **a. of the penis** (35). *The obturator a. is absent.*

The **caudal gluteal a.** (31) *emerges from the pelvis through the lesser sciatic foramen. It supplies the deep gluteal m., cran. part of the gluteobiceps, the gemelli, and the quadratus femoris.*

b) The **VEINS** run generally parallel to the corresponding arteries; therefore only the important exceptions will be mentioned here.

The terminal division of the **caudal vena cava** (1) into paired common iliac vv. *occurs at the level of the first sacral vertebra.* The **median sacral v.** (13) comes from the caudal vena cava, and the **deep circumflex iliac v.** (6) comes from the **common iliac v.** The **left common iliac v.** gives off the **left ovarian** or **testicular v.** (2). *Medial to the ilium the common iliac v. divides into the external and internal iliac vv.*

Shortly before its entry into the femoral triangle the **external iliac v.** (5) gives off the **puddendoepigastric v.** (7) which may arise from the **deep femoral v.** The **internal iliac v.** (15) gives off the **obturator v.** (20), which runs to the obturator foramen, and the **accessory vaginal vein** (22) *neither has an accompanying artery.* (See e) veins of udder.)

The **v. of the ductus deferens** (24) comes from the prostatic v.; the **uterine br.** (24), from the vaginal v., from which the **caudal vesical v.** (25) also arises.

The blood supply of the penis, uterus, and udder follows.

c) The **BLOOD SUPPLY OF THE PENIS** is provided by the internal pudendal a. It ends as the **a. of the penis** (35) and this gives off the **a. of the bulb of the penis** (38) for the corpus spongiosum and bulb; the **deep a. of the penis** (39), which enters the corpus cavernosum at the root of the penis; and the **dorsal a. of the penis** (40), which runs to the apex of the penis. The veins ramify in the same way as the arteries of the same name.

d) The **BLOOD SUPPLY OF THE UTERUS** is provided mainly by the **uterine a.** (18), *which originates from the first part of the umbilical a., near the internal iliac a.* It runs on the mesometrial border of the uterine horn in the parametrium. Its branches form anastomotic arches with each other and cranially with the **uterine br.** (2') of the **ovarian a.** and caudally with the **uterine br.** (24) of the **vaginal a.** In the cow the uterine a. is palpable per rectum after the third month of pregnancy as an enlarged vessel with a characteristic thrill (fremitus) in addition to the pulse. The **uterine v.** is an insignificant vessel that comes from the internal iliac v. and accompanies the uterine a. The main veins are the **uterine br. of the ovarian v.** (2), the **uterine br. of the vaginal v.** (24), and the **accessory vaginal v.** (22), *which comes from the internal iliac v. and has no accompanying a.*

e) The **BLOOD SUPPLY OF THE UDDER** comes mainly from the external pudendal a. (9), and additionally from the internal pudendal a. (32) via the ventral perineal a. (36). The external pudendal a., with a sigmoid flexure, enters the base of the udder dorsally and divides into the cranial and caudal mammary aa. The **cran. mammary a. (caud. supf. epigastric a., 10)** supplies the cranial and caudal quarters, including the teats. The **caud. mammary a. (11)** goes mainly to the caudal quarter. A third (middle) mammary artery may be present, arising from the other two or from the external pudendal a. at its bifurcation. There are many variations in all three arteries.

The cranial and caudal mammary vv. are branches of the external pudendal. The **cranial mammary v. (10)** *is also continuous with the caud. supf. epigastric v., which joins the cran. supf. epigastric v. to form the large, sinuous milk vein (subcutaneous abdominal v.).* The **caudal mammary v. (11)** *joins the large ventral labial v. (37), which is indirectly connected to the internal pudendal v.* Further details of the mammary vessels will be discussed with the udder (p. 90).

f) The **SACRAL PLEXUS** is joined to the lumbar plexus in the lumbosacral plexus. The **cranial gluteal n. (i)** issues cranially from the **lumbosacral trunk** at the greater sciatic foramen and runs with the branches of the cran. gluteal vessels to the middle, accessory, and deep gluteal muscles, as well as the tensor fasciae latae, fused with the supf. gluteal muscle.

The **caudal gluteal n. (j)** arises caudodorsally from the lumbosacral trunk near the greater sciatic foramen, but emerges through the lesser sciatic foramen and innervates the parts of the gluteobiceps that originate from the sacrosacral ligament.

The **caudal cutaneous femoral n. (k)** *is small in the ox.* It arises from the lumbosacral trunk just caudal to the caudal gluteal n. and runs outside the sacrosacral lig. to the lesser sciatic foramen, where it divides into medial and lateral br. The medial br. (communicating br.) passes into the foramen and joins the pudendal n. or its deep perineal br. *In the ox the lateral br. of the caud. cut. femoral n. may be absent; it may join the proximal cutaneous br. of the pudendal n.; or it may contribute to the cutaneous innervation of the caudolateral thigh, which is supplied mainly by the proximal and distal cutaneous br. of the pudendal n.*

The **sciatic n. (f)** is the direct continuation of the lumbosacral trunk. It runs caudally over the deep gluteal m. and turns ventrally behind the hip joint to supply the pelvic limb. It is the largest nerve in the body.

The **pudendal n. (h)** originates from sacral nn. 2–4. It runs caudoventrally on the inside of the sacrosacral lig., and near the lesser sciatic foramen gives off two cutaneous br. (p. 95): the **proximal cutaneous br.** emerges through, or caudal to, the gluteobiceps, and runs distally on the semitendinosus; the **distal cutaneous br.** emerges from the ischioanal fossa and runs distally on the semimembranosus. It also supplies the **supf. perineal n.** to the skin of the perineum. In the bull, this provides the dorsal scrotal nn., and in the cow, the labial nn., and branches that extend on the ventral labial v. to the caudal surface of the udder.

The pudendal n. gives off the **deep perineal n.** (p. 95) to the striated and smooth perineal muscles, and continues with the internal pudendal vessels around the ischial arch, and ends by dividing into the **dorsal n. of the clitoris** and the **mammary br.** The latter is closely associated with the loops of the ventral labial v. In the bull the pudendal n. divides into the **dorsal n. of the penis** and the **preputial and scrotal br.**

The **caudal rectal nn.** (30) are the last branches of the sacral plexus. They have connections with the pudendal n. and supply the rectum, skin of the anus, and parts of the perineal musculature.

g) **AUTONOMIC NERVOUS SYSTEM.** The sympathetic division includes the **caudal mesenteric ganglion** on the caudal mesenteric a. cranial to the pelvic inlet. The paired **hypogastric nn.** leave the ganglion and run on the dorsolateral pelvic wall to the level of the vaginal or prostatic a. to join the pelvic plexus. The **sympathetic trunk** in the sacral region has five vertebral ganglia and in the coccygeal region, four or five ganglia.

The **parasympathetic nn.** from sacral segments 2–4 leave the vertebral canal with the ventral roots of the pudendal n. and form the **pelvic nn.**, which, from a dorsal approach, join the **pelvic plexus** with its contained ganglion cells. (See also p. 56.)

Pelvic arteries, veins, and nerves (left side)

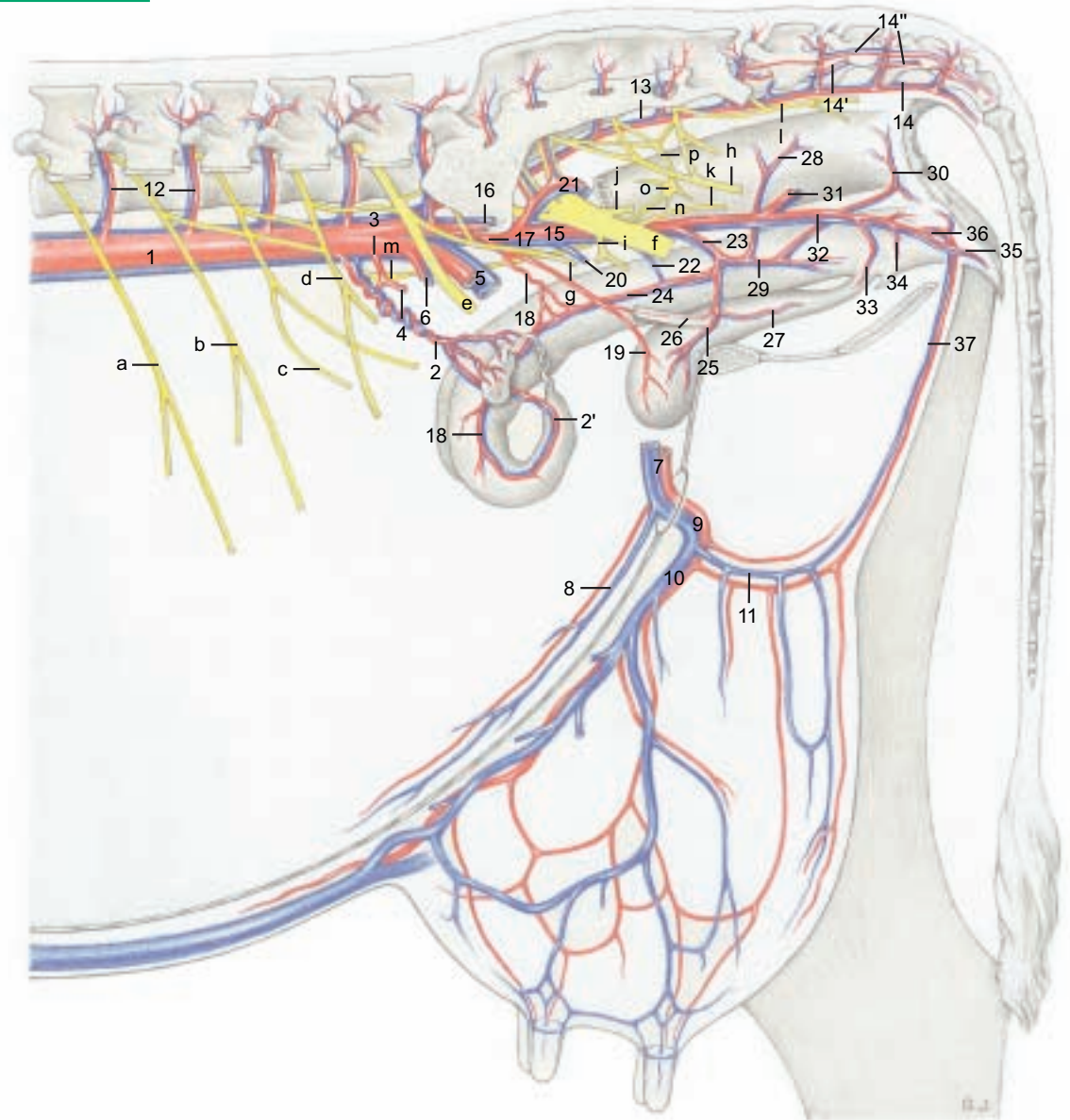
Legend:

Arteries, veins:

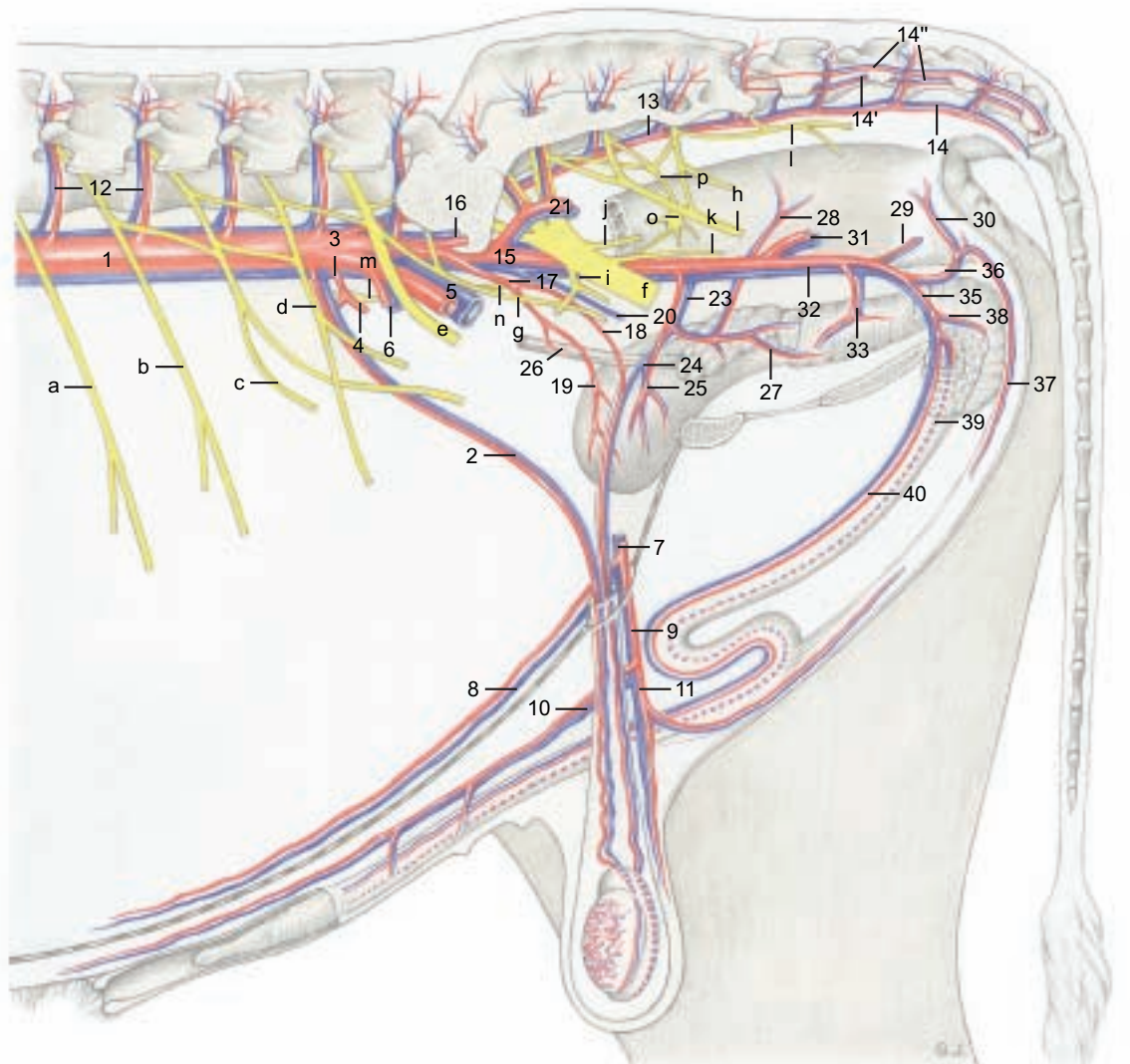
- 1 Abd. aorta and caud. vena cava
- 2 Ovarian or testicular a. and v.
- 2' Uterine br.
- 3 Caud. mesenteric a. and v.
- 4 Cran. rectal a. and v.
- 5 Ext. iliac a. and v.
- 6 Deep circumflex iliac a. and v.
- 7 Pudendoepigastric trunk and v.
- 8 Caud. epigastric a. and v.
- 9 Ext. pudendal a. and v.
- 10 Caud. supf. epigastric a. and v.
(Cran. mammary a. and v.)
- 11 Caud. mammary a. and v. or
Ventr. scrotal br. and v.
- 12 Lumbar aa. and vv.
- 13 Median sacral a. and v.
- 14 Median caud. a. and v.
- 14' Ventrolat. caudal a. and v.
- 14'' Dorsolat. caudal a. and v.
- 15 Int. iliac a. and v.
- 16 Iliolumbar a. and v.
- 17 Umbilical a.
- 18 Uterine a. or a. of ductus deferens
- 19 Cran. vesical a.
- 20 Obturator v.
- 21 Cran. gluteal a. and v.
- 22 Accessory vaginal v.
- 23 Vaginal or prostatic a. and v.
- 24 Uterine br. and v. or v. of ductus deferens
- 25 Caud. vesical a. and v.
- 26 Ureteric br.
- 27 Urethral br.
- 28 Middle rectal a. and v.
- 29 Dors. perineal a. and v.
- 30 Caud. rectal a. and v.
- 31 Caud. gluteal a. and v.
- 32 Int. pudendal a. and v.
- 33 Urethral a. and v.
- 34 Vestibular a. and v.
- 35 A. and v. of clitoris or penis
- 36 Ventr. perineal a. and v.
- 37 Ventr. labial v. and mammary br.
of ventr. or dors. perineal a.
In bull, br. and v. from ventr. perineal vessels
- 38 A. and v. of bulb of penis
- 39 Deep a. and v. of penis
- 40 Dors. a. and v. of penis

Nerves:

- a Iliohypogastric n.
- b Ilioinguinal n.
- c Genitofemoral n.
- d Lat. cut. femoral n.
- e Femoral n.
- f Sciatic n.
- g Obturator n.
- h Pudendal n.
- i Cran. gluteal n.
- j Caud. gluteal n.
- k Caud. cut. femoral n.
- l Caud. rectal nn.
- m Caudal mesenteric plexus
- n Hypogastric n.
- o Pelvic plexus
- p Pelvic n.



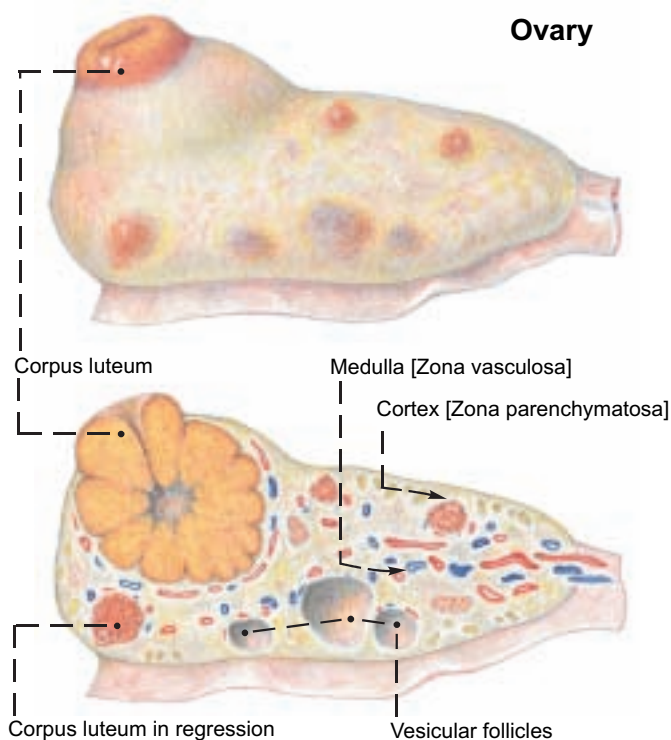
(See pp. 17, 19, 21, 91)



5. FEMALE GENITAL ORGANS

a) The **OVARY** (6) has a different position from that of the bitch and mare because of the *longer developmental "descent" of the ovary and parietal attachment of the mesovarium (2) toward the pelvis*. This results in the spiral of the uterine horn and gives the long axis of the ovary an obliquely transverse direction. The tubal end of the ovary is dorsolateral and the uterine end is ventromedial. The ovary lies near the lateroventral part of the pelvic inlet, cranial to the external iliac a. In the pregnant cow it is drawn cranioventrally. The mesovarium contains the ovarian a., coming from the aorta, and gives off laterally the thin **mesosalpinx** (3) for the uterine tube. The cranial border of the mesovarium is the **suspensory lig. of the ovary** (1). Caudally the mesovarium is continuous with the **mesometrium** (4). The mesovarium, mesosalpinx, and mesometrium together form the **broad ligament (lig. latum uteri)** which contains smooth muscle.

The **ovary** measures 3.5 x 2.5 x 1.5 cm, about the size of the distal segment of the human thumb. Compared to that of the mare it is relatively small. It is covered by peritoneum on the mesovarian margin only, and by the superficial epithelium elsewhere. There is no ovarian fossa, which is a peculiarity of the mare. The **cortex** and **medulla** are arranged as in the bitch. On the irregularly tuberculated surface there are always follicles and **corpora lutea** of various stages of the estrous cycle which can be palpated per rectum. A follicle matures to about 2 cm; a corpus luteum can reach the size of a walnut. The single corpus luteum changes color during the cycle from yellow or ochre-yellow to dark red, red-brown, gray-white, and black. This can be seen on a section through the ovary.



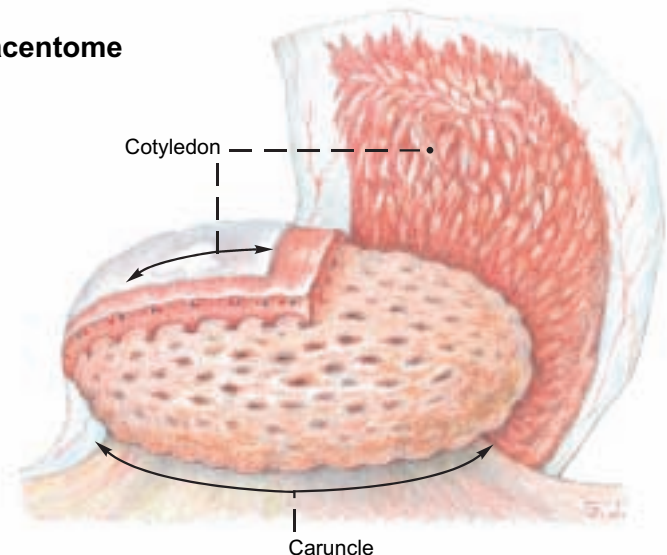
b) The **UTERINE TUBE** (14) is somewhat tortuous and at 28 cm, relatively long. The **mesosalpinx** (3) with the uterine tube surrounds the ovary cranially and laterally like a mantle and forms with the mesovarium the flat voluminous **ovarian bursa** (13) with a wide cranioventromedial opening. The **infundibulum of the tube** (16) with its fimbriae surrounds the ovary. It funnels into the **abdominal orifice of the tube** (15). The ampulla and isthmus of the tube do not show any great difference in the size of the lumen. The uterine tube ends, unlike that of the bitch and mare, *without a uterine papilla at the uterine orifice of the tube* (7) in the apex of the uterine horn. Here the **proper ligament of the ovary** (8) ends and the **round lig. of the uterus** begins. The latter is attached by a serosal fold to the lateral surface of the mesometrium and extends to the region of the inguinal canal. Both ligaments develop from the **gubernaculum of the ovary**. (The mammalian uterine tube differs in form and function from the oviduct of lower animals.)

c) The **UTERUS**, as in all carnivores and ungulates, is a uterus bicornis. The horns of the uterus (**cornua uteri**, 9) are 30–40 cm long, rolled through cranioventral to caudodorsal, and fused caudally into a 10–15 cm long double cylinder. Cranial to the union the

horns are connected by the dorsal and ventral intercornual ligg. (11). Internally the true, undivided **body of the uterus** (12) is only 2–4 cm long. The neck of the uterus (**cervix uteri**, 26) with the **cervical canal** (26) begins at the **internal uterine orifice** (27) and ends at the **external uterine orifice** (25) on the vaginal part of the cervix (**portio vaginalis**, 25). The cervix is 8–10 cm long and can be distinguished from the body of the uterus and the vagina by its firm consistency.

The three layers of the wall of the uterus are formed by the peritoneum (perimetrium), the muscular coat (myometrium), and the mucosa (endometrium). The mucosa of the uterus forms longitudinal and transverse folds and in each uterine horn four rows of 10–15 round or oval **caruncles** (10)* of various sizes. These project dome-like on the internal surface, and in the pregnant uterus can reach the size of a fist. The total number of caruncles in the uterus, including the body, is about 100.

Placentome



During pregnancy they form, together with the **cotyledons**,** the **placentomes**. **Cotyledons** are bunches of villi on the fetal amnio-chorion and allanto-chorion that invade the caruncles. (See text figure.) The cervical mucosa presents **longitudinal folds** and, with the support of the musculature, bulges into the lumen, usually in **four characteristic circular folds**, and closes the cervical canal. This is clinically important. The last **circular fold** projects into the vagina as the **portio vaginalis cervicis** (25).

d) The **Vagina** (18), 30 cm long, is longer than in the mare, hollow and its **fornix** (17) arches over the portio vaginalis cervicis dorsally. The cranial part of the vagina is covered by peritoneum in the area of the **rectogenital excavation** (5) which extends caudally to the middle of the pelvic cavity or to the first caudal vertebra. Caudally the vagina joins the **vestibule** (23), sometimes *without a distinct boundary*, sometimes with only a faint transverse fold, the **hymen** (19). The **external urethral orifice** (20) opens into the cranial end of the vestibule 7–11 cm from the ventral commissure of the labia. The **suburethral diverticulum** (x) lies ventral to the urethral orifice.

The openings of the vestigial deferent ducts (remnants of the caudal parts of the mesonephric ducts) are found on each side of the urethral orifice. The ducts run between the mucosa and the musculature and can reach a considerable length. They end blindly and can become cystic. The **major vestibular gland** (w) is cranial to the **constrictor vestibuli** (m). It is 3 cm long and 1.5 cm wide, and has 2–3 ducts that open in a small pouch (24) lateral to the urethral orifice. The microscopic minor vestibular glands open on the floor of the vestibule cranial to the clitoris.

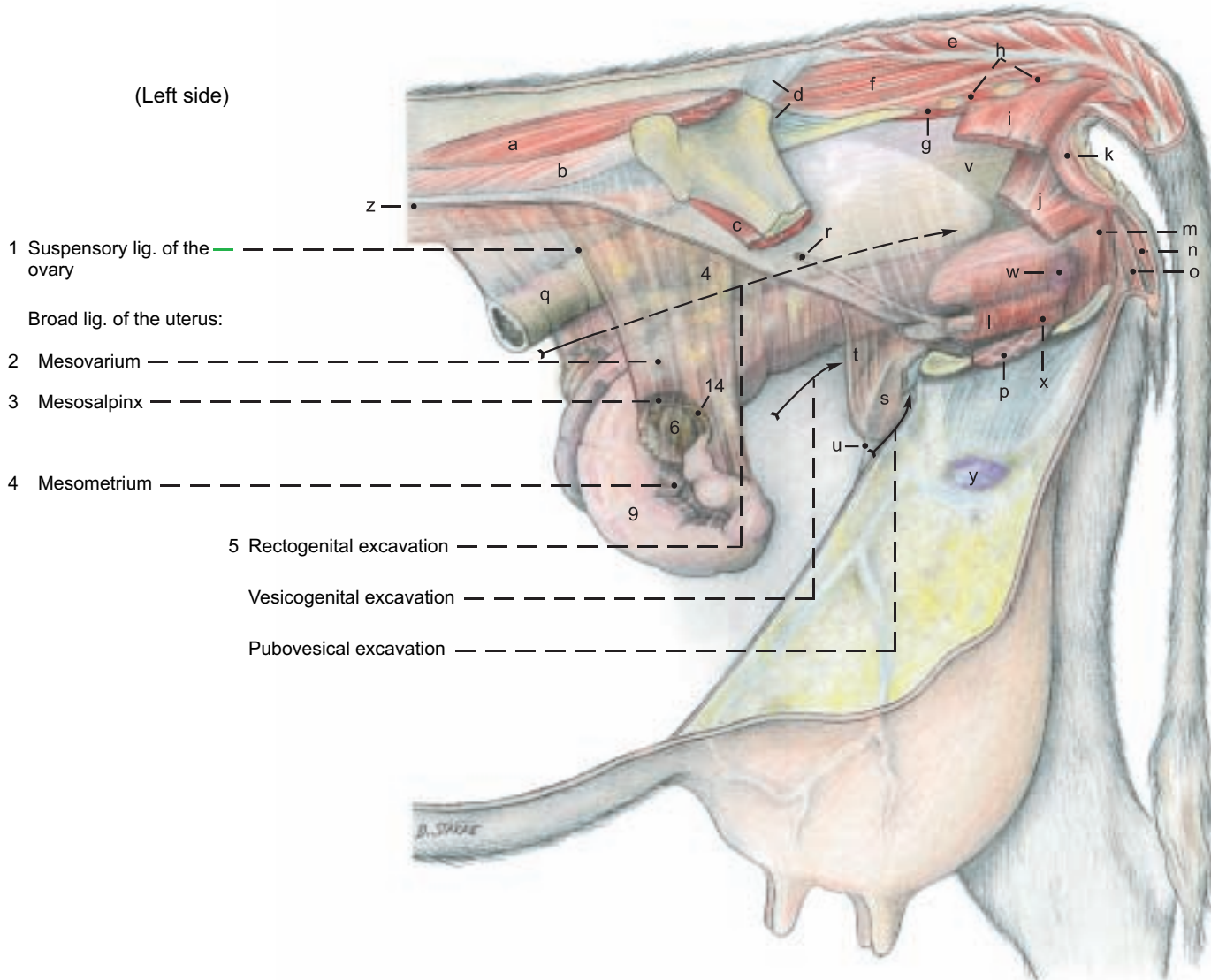
e) The **VULVA** surrounds with its thick **labia** (22) the **labial fissure** (**rima pudendi**). The **dorsal commissure** of the labia is, in contrast to the mare, more rounded, and the **ventral commissure** is pointed, with a tuft of long coarse hairs.

The **clitoris** (21) is smaller than in the mare, although 12 cm long and tortuous. The end is tapered to a cone. The **glans** is indistinct. The **prepuce** is partially adherent to the apex of the clitoris so that an (open) **fossa clitoridis** is almost absent.

* Caruncula -ae, L. = papilla

** Cotyledo(n) -onis L., Gr. = cup

Female genital organs

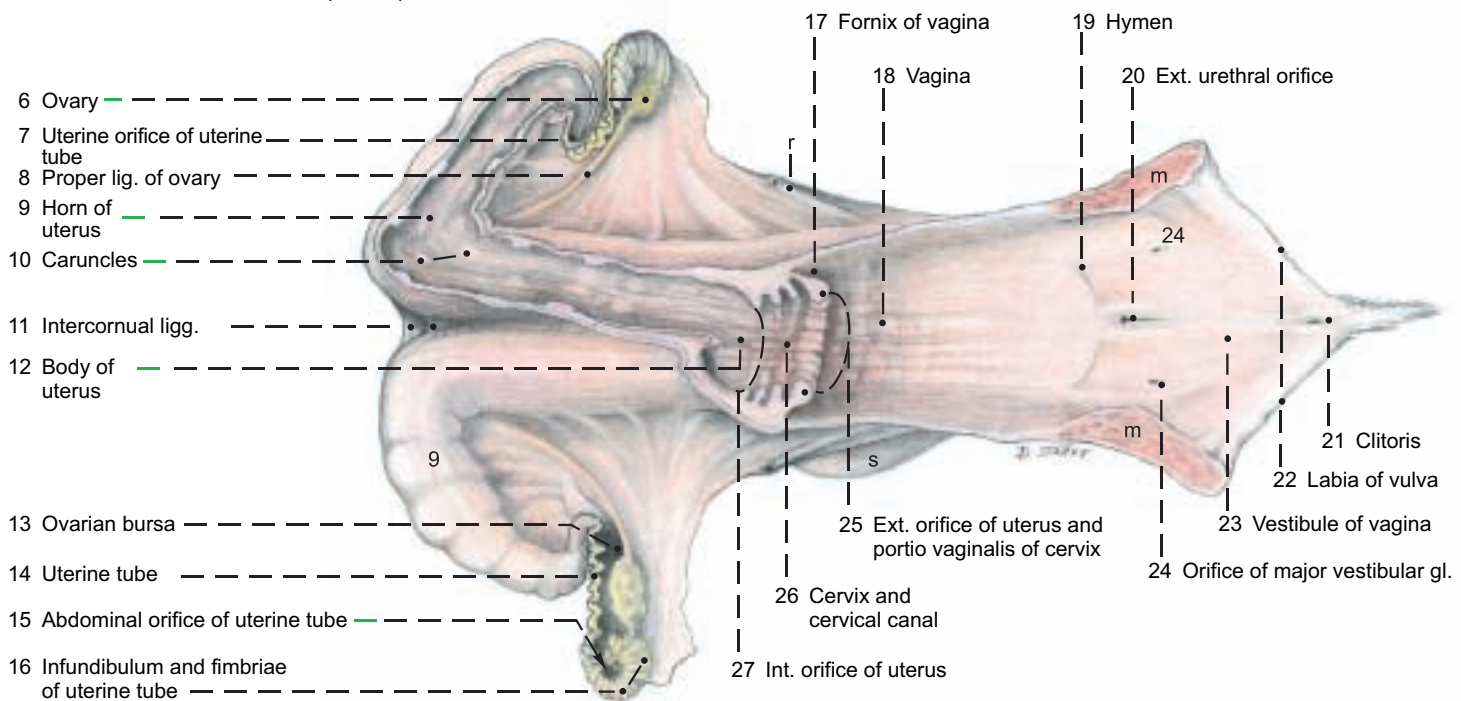


(See pp. 17, 19, 93)

Legend:

- | | | | | |
|-----------------------------------|-------------------------------------|--------------------------------------|--------------------------|----------------------------|
| a Middle gluteal m. | f Sacrocaudalis dorsalis lateralis | l Urethralis | q Descending colon | v Rectum |
| b Longissimus lumborum | g Sacrocaudalis ventralis lateralis | Bulbospongiosus: | r Ureter | w Major vestibular gl. |
| c Iliacus | h Intertransversarii | m Constrictor vestibuli | s Urinary bladder | x Suburethral diverticulum |
| d Sacroiliac ligg. | i Coccygeus | n Constrictor vulvae | t Lat. lig. and round | y Supf. inguinal Inn. |
| e Sacrocaudalis dorsalis medialis | j Levator ani | o Retractor clitoridis | u Median lig. of bladder | z Peritonum (Sectio) |
| | k Ext. anal sphincter | p Intrapelvic part of ext. obturator | | |

(dorsal)



6. THE UDDER

The **udder** is composed of four **mammary glands**—modified skin glands that occur in this form only in true mammals (Eutheria). The mammary secretion is **milk (lac)**. The first milk secreted after parturition is **colostrum**, containing a high concentration of antibodies, which give the newborn passive immunity. Cow's milk and also milk from sheep and goats, is a valuable human foodstuff. It contains proteins, fats, sugar, and minerals (for example, calcium and phosphorus). Therefore milk production is of great economic significance in agriculture. Diseases of the udder lead directly to reduced milk production that persists throughout the lactation period. For that reason early treatment of udder diseases is especially important in veterinary practice. The diagnosis of udder diseases and the possible need for surgery, such as removal of half of the udder (mastectomy) or the amputation of a teat, require anatomical knowledge of the structure of the udder, its suspensory apparatus, blood vessels, lymph drainage, and innervation.

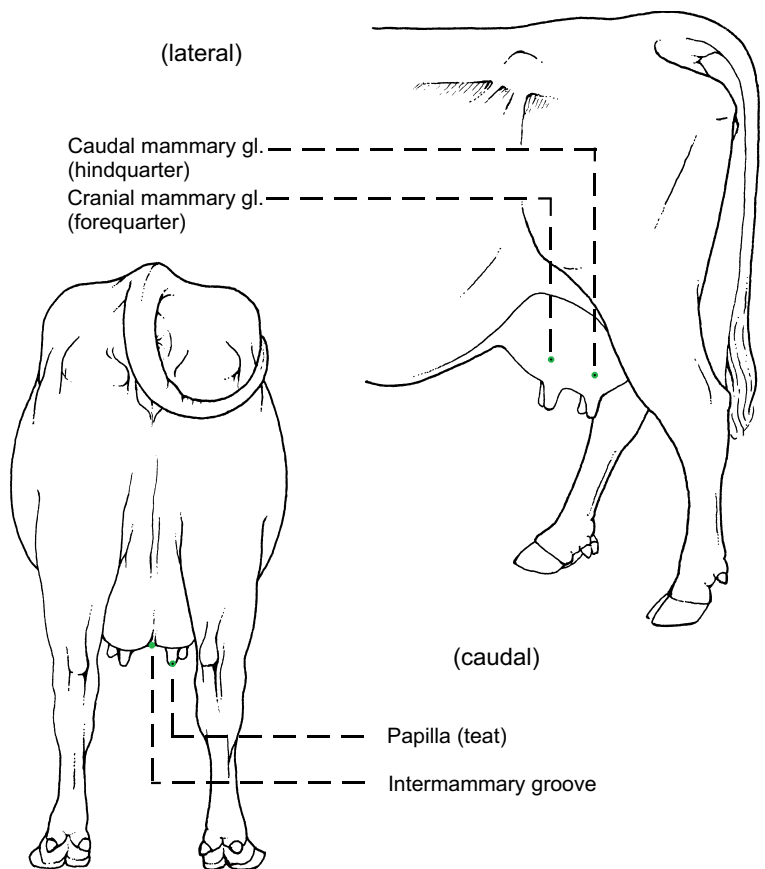
The four **mammary glands** of the bovine udder are attached to the body in the inguinal region and are commonly called quarters. At the height of lactation each quarter may reach enormous size.

Each mammary gland consists of a **teat (papilla mammae, 5)** and a **body (corpus mammae, 4)**. The size of the body and the length of the teat vary with the individual cow, functional status, and form. The teats are about as thick as the thumb and as long as the index finger. The teat canal, with its orifice on the end of the teat, may be incompletely closed, permitting ascending bacterial inflammation of the udder (mastitis). A narrow, partly blocked teat canal will restrict the flow of milk. Rudimentary accessory glands and teats occur and are not rare. They are usually caudal to the normal teats, but may be between them or cranial to them. Rudimentary teats occur in the bull cranial to the scrotum. The right and left halves of the udder are divided by a **median intermammary groove**. The udder is covered by modified skin that is hairless and without skin glands on the teat, and sparsely haired elsewhere. The skin of the healthy udder is easily slipped on the subcutis, but this mobility is lost in inflammation, and together with pain, edema, and heat serves to diagnose mastitis. **Suspensory apparatus:** **lateral laminae (1)** of fascia pass over the surface of the udder from the symphyseal tendon and the lateral crus of the superficial inguinal ring in a mainly cranioventral direction. The **medial laminae (2)** separate the right and left halves of the udder. (This median separation can be demonstrated by blunt dissection between the medial laminae from their caudal borders.) Composed mostly of elastic tissue, they originate as a paired paramedian **suspensory lig. (2)**. This comes from the yellow abdominal tunic on the exterior surface of the prepubic tendon (p. 66) at its junction with the symphyseal tendon.* From both the lateral and the medial laminae, thin **suspensory lamellae (3)** penetrate the mammary gland, separating the parenchyma into curved, overlapping **lobes (7)**.** When filled with milk the udder has considerable weight, which stretches the suspensory apparatus, especially the medial laminae. Therefore the teats of the tightly filled udder project laterally and cranially because the elastic medial laminae are stretched more than the lateral laminae, which consist mainly of regular dense collagenous tissue.

In contrast to the bitch and mare, each mammary gland of the cow contains only one duct system and the associated glandular tissue. In addition the gland contains interstitial connective tissue with nerves, blood vessels, and lymphatics. The duct system ends on the apex of the teat with the **orifice (5')** of the narrow **teat canal (papillary duct, 5')**, surrounded by the **teat sphincter (b)**.

The teat canal drains the lactiferous sinus with its **papillary part (teat sinus, 9')** and **glandular part (gland sinus, 9)**. The boundary between the parts is marked by the **annular fold (9')** of mucosa, containing a venous circle (of Fuerstenberg). A **venous plexus (a)** in the wall of the teat forms an erectile tissue that makes hemostasis difficult in injuries or surgery. The mucosa of the teat canal bears **longitudinal folds (11)**, and the proximal ends of the folds form a radial structure called Fuerstenberg's rosette at the boundary between the teat sinus and the teat canal.

In the gland sinus are the openings of several large **collecting ducts (ductus lactiferi colligentes, 8)**. Each of these receives milk from one of the numerous lobes through **small lactiferous ducts (14)** and **alveolar lactiferous ducts (13)**, which drain the **lobules (10)**. A lobule resembles a bunch of grapes, measures 1.5 x 1.0 x 0.5 mm, and consists of about 200 alveoli.*** Many alveoli are connected directly, and this construction has led to the term, "storage gland". The alveoli are surrounded by septa containing nerves and vessels. The duct systems are separate for each quarter, as demonstrated by injections of different colored dyes, even though quarters on the same side have no septum between them. Therefore ascending infections may be limited to one quarter. The separate medial laminae make it possible to amputate one lateral half of the udder. The teat canal has a defensive mechanism in its lining of stratified squamous epithelium that produces a plug of fatty desquamated cells in the canal between milkings. This is *an important factor in resistance to infection.*****



* Habel and Budras, 1992

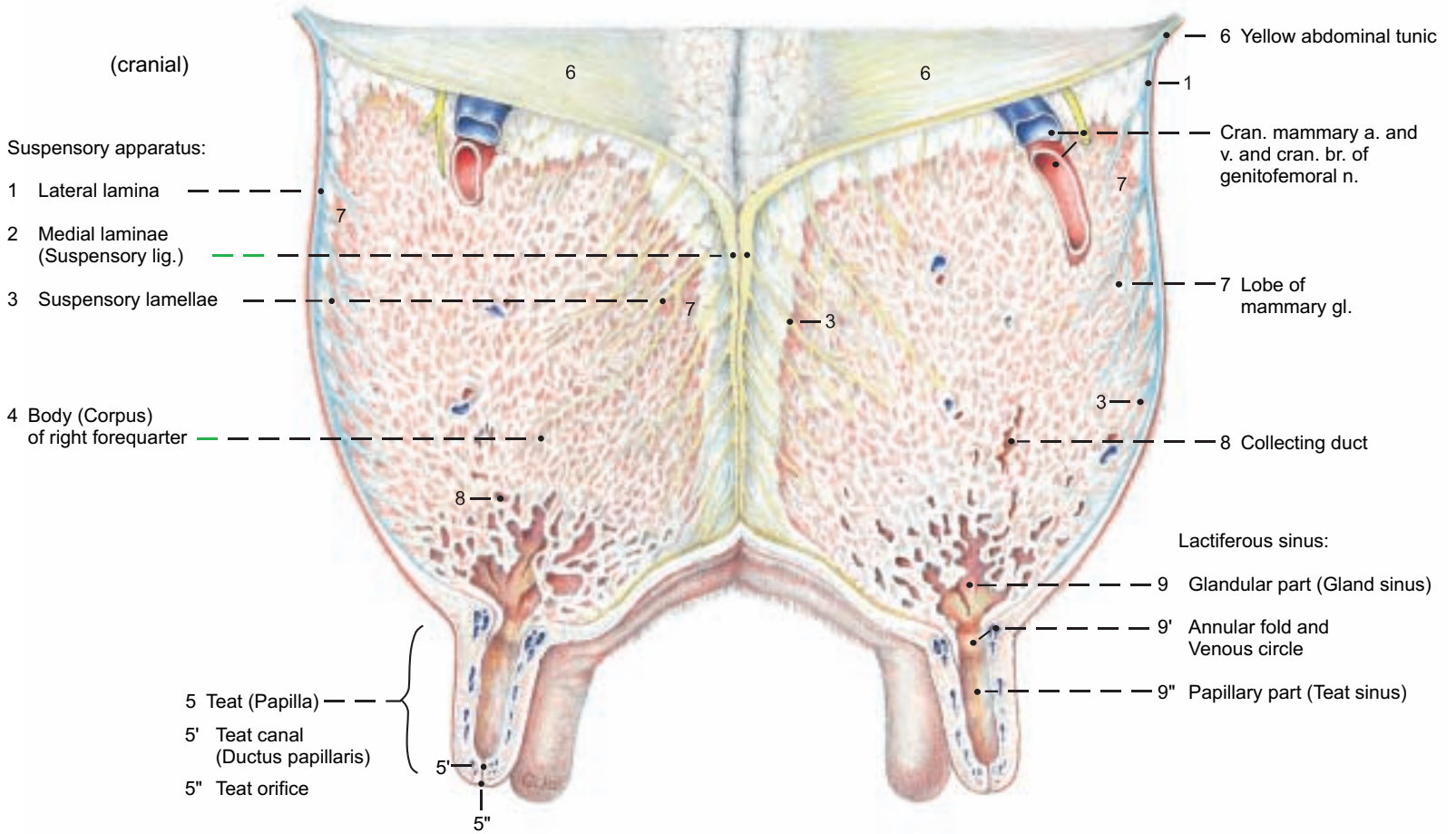
*** Weber et al., 1955

** Ziegler and Mosimann, 1960

**** Adams and Rickard, 1963

Udder

Transverse section through forequarters, cranial surface



Mammary gland and Teat

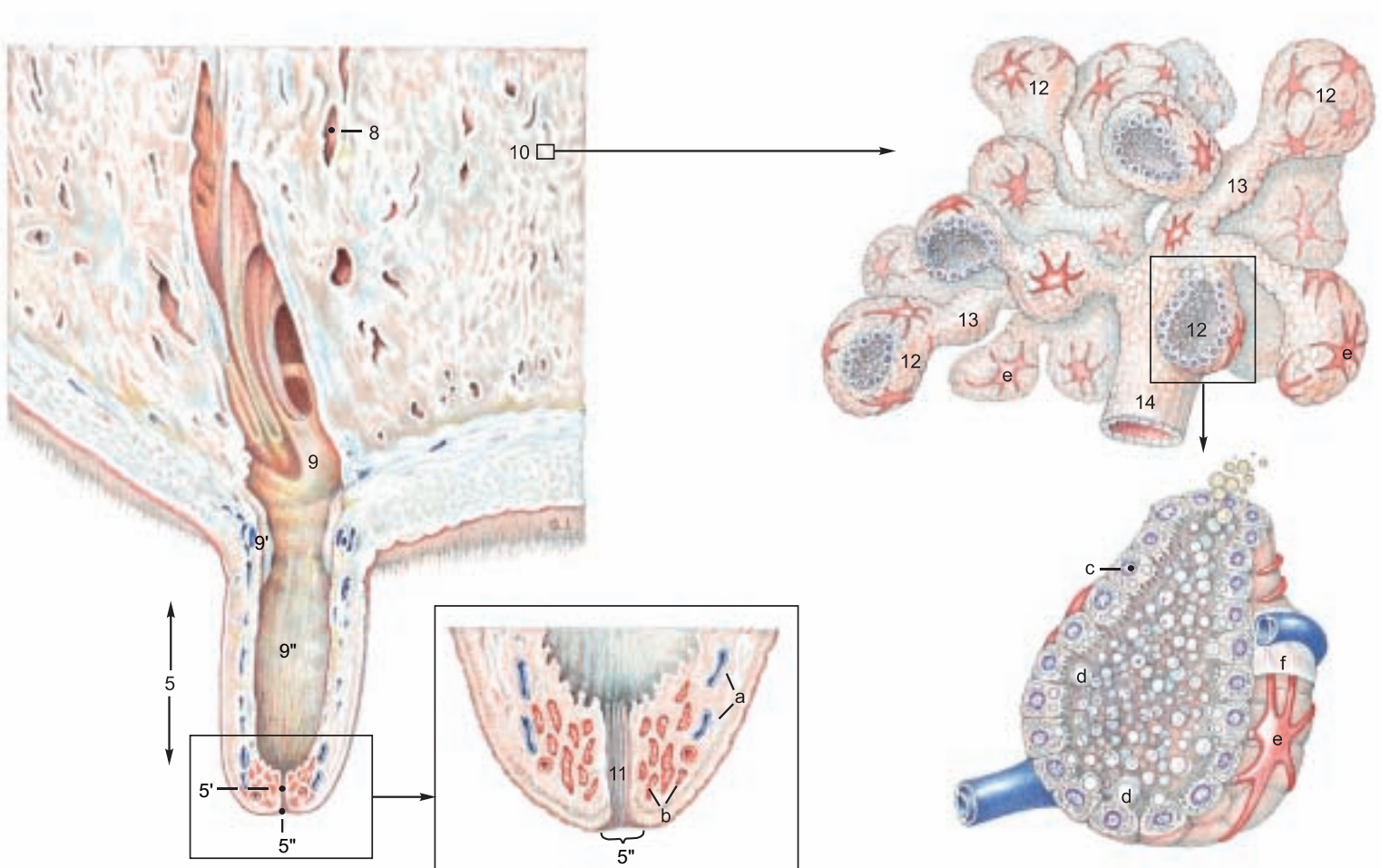
Legend:

10 Lobule
11 Longitudinal folds

12 Alveoli
13 Alveolar lactiferous ducts
14 Lactiferous duct

a Venous plexus of the teat
b Teat sphincter muscle
c Lactocyte

d Fat droplet
e Myoepithelial cell
f Basement membrane



7. THE UDDER WITH BLOOD VESSELS, LYMPHATIC SYSTEM, NERVES, AND DEVELOPMENT

I. The **blood vascular system** is adapted to the high milk production of the udder. Up to 600 liters of blood must flow through the udder to produce one liter of milk. Therefore the blood vessels are remarkable for their large calibre, and they have received additional names. The ext. pudendal a. and v. bifurcate into the **cran. (12) and caud. (11) mammary a. and v.** The cran. mammary vessels are also known as the caud. supf. epigastric vessels. The caud. mammary a. and v. are continuous with the **mammary br. and ventral labial v. (5)**, which usually come from the ventral perineal vessels, but in some cows they come from the dorsal perineal vessels (see p. 95, 16).

The **cran. supf. epigastric vein** in milk cows can be seen bulging under the skin of the ventral abdominal wall. It is therefore called the **subcutaneous abdominal v. (18)**. The place where it perforates the abdominal wall in the xiphoid region from the int. thoracic v. is the "milk well" [anulus venae subcutaneae abdominis]. The **caud. supf. epigastric v.** is also called the **cran. mammary v. (12)**. The caudal and cranial supf. epigastric vv. anastomose end-to-end and form the "milk vein". This is enlarged during the first lactation and its valves become incompetent, making blood flow possible in either direction. The right and left cran. mammary vv. anastomose on the cran. border of the udder. This connection, with that of the caudal mammary vv., completes the venous ring around the base of the udder. Many veins of the udder join this ring. The **vent. labial v.** is large and tortuous in the dairy cow (see p. 95, 16). In most of its extent the valves indicate that blood flows toward the **caud. mammary v.**

II. The **lymph** from the udder is conducted to 1–3 **supf. inguinal lnn. (mammary lnn., B)**. They lie caudally on the base of the udder (the surface applied to the body wall) and can be palpated between the thighs about 6 cm from the skin at the caudal attachment of the udder. Small intramammary lnn. may be present. The lymph flows to the **iliofemoral ln. (deep inguinal ln., A)**. *These lnn. are routinely incised in meat inspection.*

III. The **innervation** of the udder is sensory and also autonomic (sympathetic). The skin and teats of the forequarters and the cranial part of the base of the udder are supplied by the **iliohypogastric n. (a), ilioinguinal n. (b), and the cran. br. of the genitofemoral n. (c')**. The skin and teats of the hindquarters are innervated by the **caud. br. of the genitofemoral n. (c'')** and the **mammary br. of the pudendal n. (f)**. The cran. and caud. br. of the genitofemoral n. pass through the inguinal canal into the body of the udder. The sensory innervation of the teats and skin of the udder is the afferent pathway of the **neurohormonal reflex arc**, which is essential for the initiation and maintenance of milk expulsion from the mammary glands. The stimulus produced by sucking the teats and massaging the mammary gll. is conducted by the afferent nerves to the CNS, where, in the nuclei of the hypothalamus, the hormone oxytocin is produced. The afferent nervous stimulus causes the hormone to be released through the neurohypophysis into the blood, which carries it into the mammary gll. Here oxytocin causes contraction of the myoepithelial cells on the alveoli, by which milk is pressed into the lactiferous ducts and sinus. This expulsion of milk is disturbed under stress by secretion of the hormone adrenalin, which suppresses the action of oxytocin on the myoepithelial cells. (For details, see textbooks of histology and physiology.)

IV. The **prenatal development of the udder** begins in the embryo in both sexes on the ventrolateral body wall between the primordia of the thoracic and pelvic limbs. This linear epidermal thickening is the **mammary ridge**. It is shifted ventrally by faster growth of the

dorsal part of the body wall. Local epithelial sprouts grow down into the underlying mesenchyme from the ridge, forming the **mammary buds** in the location and number of mammary glands of each species. The mesenchyme surrounding the epithelial sprout is called the areolar tissue. Each mammary bud is bordered by a slightly raised ridge of skin. The teat develops in ruminants, as in the horse, by the growth of this areolar tissue, as a proliferation teat. The surrounding skin ridge is completely included in the formation of the teat. (For details see the textbooks of embryology.)

Postnatally the mammary glands are inconspicuous in calves of both sexes because the teats are short and the mammary glands are hardly developed. The duct system consists only of the teat canal, the sinus, and the primordia of the collecting ducts, which are short solid epithelial cords. Normally, the male udder remains in this stage throughout life. During puberty some bull calves can undergo a further temporary growth of the mammary glands under the influence of an elevated level of estrogen, as is natural in females. In young heifers during pubertal development ovarian follicles ripen and cause the level of estrogen in the blood to rise. In the udder this results in an increase of connective and adipose tissue, and also further proliferation of the epithelial buds as primordia of the lactiferous ducts, which divide repeatedly, producing the small collecting ducts. The mammary gland primordia rest in this stage of proliferation until the first pregnancy.

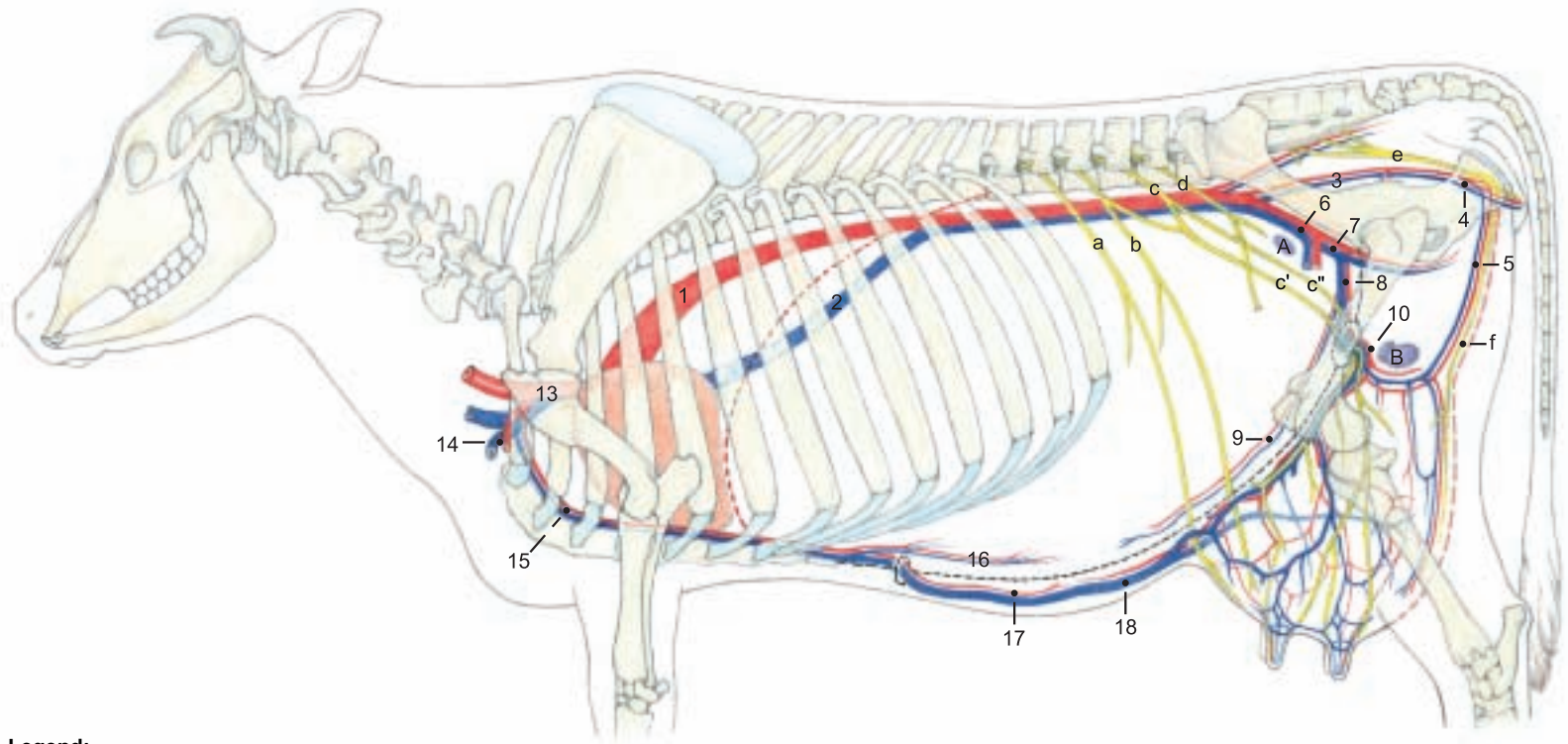
During the first pregnancy further generations of lactiferous ducts develop by growth and division of the epithelial cords. In the second half of pregnancy the still partially solid glandular end-pieces are formed, while space-occupying adipose tissue is displaced. Toward the end of gestation (about 280 days) under the influence of progesterone and estrogen, a lumen develops in these glandular end-pieces, and under the influence of prolactin the lactocytes begin the secretion of milk (lactogenesis). In the first five days after parturition the milk secreted is colostrum. This is rich in proteins; it contains immunoglobulins, and it may be reddish due to an admixture of erythrocytes. In addition to the passive immunization of the newborn, colostrum has another function: it has laxative properties that aid in the elimination of meconium (fetal feces). Lactation can begin a few days or a few hours before parturition, and the first drops of milk on the end of a teat are taken as an indication of impending birth.

After birth milk secretion is maintained only in the quarters that the suckling uses. The unused quarters rapidly undergo involution. This occurs naturally when the calf is weaned by the dam, but in U.S. dairy practice the calf is removed from the dam and fed artificially, beginning with colostrum from the dam. Milk secretion is maintained by milking twice a day. After about ten months, lactation is stopped by decreasing the ration and reducing the milking to provide a dry period of about 60 days before calving.* During involution the secretory cells in the alveoli and in the alveolar lactiferous ducts degenerate. The glandular tissue is replaced by fat and connective tissue. This is important for the clinical evaluation of the consistency of individual quarters. The size of the udder decreases, but never returns to the small size of an udder that has not yet produced milk.

Accessory (supernumerary) mammary gll. may be present on the udder, a condition called hypermastia. The presence of supernumerary teats is called hyperthelia (Gk. thele, nipple). They may be located before, between, or behind the main teats. If they occur on a main teat *they interfere with* milking and must be removed.

Arteries, Veins, and Nerves of the Udder

Left side

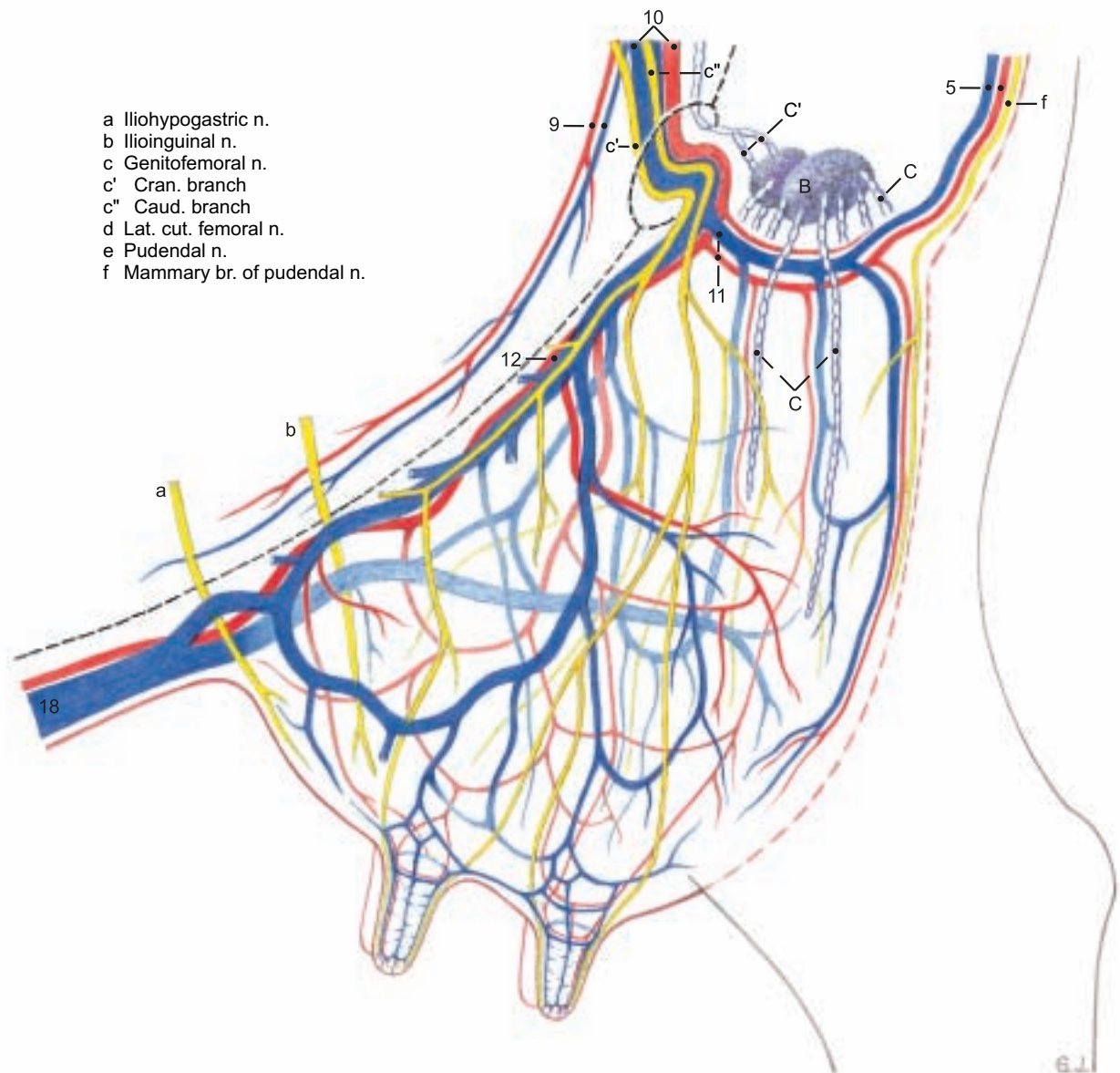


Legend:

- 1 Aorta
- 2 Caud. vena cava
- 3 Int. iliac a. and v.
- 4 Int. pudendal a. and v.
- 5 Vent. labial v. and mammary br. of vent. perineal a.
- 6 Ext. iliac a. and v.
- 7 Deep femoral a. and v.
- 8 Pudendoepigastric vessels
- 9 Caud. epigastric a. and v.
- 10 Ext. pudendal a. and v.
- 11 Caud. mammary a. and v.
- 12 Cran. mammary a. and v. [Caud. supf. epigastric a. and v.]
- 13 Brachiocephalic trunk and cran. vena cava
- 14 Left subclavian a. and v.
- 15 Int. thoracic a. and v.
- 16 Cran. epigastric a. and v.
- 17 Cran. supf. epigastric a.
- 18 Subcutaneous abdominal v. [Cran. supf. epigastric v.]

- A Iliofemoral ln. [Deep inguinal ln.]
- B Mammary ln. [Supf. inguinal ln.]
- C Afferent lymphatic vessels
- C' Efferent lymphatic vessels

Left cran. and caud. mammary gli.



- a Iliohypogastric n.
- b Ilioinguinal n.
- c Genitofemoral n.
- c' Cran. branch
- c'' Caud. branch
- d Lat. cut. femoral n.
- e Pudendal n.
- f Mammary br. of pudendal n.

8. MALE GENITAL ORGANS AND SCROTUM

a) The **SCROTUM** (5) is attached in the cranial pubic region. It is elongated dorsoventrally and bottle-shaped. It is generally flesh-colored and fine-haired, and bears two rudimentary teats on each side of the cranial surface of the neck.

b) The elongated oval **TESTES** (4 and 16) hang vertically in the scrotum and weigh about 300 g each. The **capital end** is proximal and the **caudate end** is distal. (Names derived from the head and tail of the epididymis.) In ruminants the **epididymal border** of the testis is medial or caudomedial and the **free border** is lateral. The part of the **mesorchium** (p) between the vaginal ring and the testis contains the testicular vessels and nerves. It is covered by the visceral lamina of the vaginal tunic, which is attached to the parietal lamina along the caudomedial surface. The ductus deferens runs in the **mesoductus deferens** (q), a narrow fold attached to the cranial surface of the mesorchium. This location is important for vasectomy. The **spermatic cord** (10) extends from the **vaginal ring** (d) to the testis and consists of the mesorchium and its contents, the ductus deferens, and the mesoductus deferens. The mesorchium continues distally along the epididymal border of the testis. At the tail of the epididymis the mesorchium ends in a short free fold, the **lig. of the tail of the epididymis** (o), the vestige of the distal part of the gubernaculum testis. Between the testis and the tail of the epididymis is the very short **proper lig. of the testis** (n), the vestige of the proximal part of the gubernaculum.

c) The **EPIDIDYMISS** begins with a **long head (caput, 12)** on the capital end and adjacent free border of the testis. The head consists of a descending limb, and an ascending limb that crosses the mesorchium to the slender body of the epididymis (14). This descends medial to the testis along the caudal side of the mesorchium to the prominent tail of the epididymis (19). Between the body of the epididymis and the testis is the **testicular bursa** (17), often obliterated by adhesion.

d) The **DUCTUS DEFERENS** (e) ascends in its mesoductus on the medial side of the testis, cranial to the mesorchium, to the **spermatic cord** (10), which is longer and narrower than in the horse. After it enters the abdominal cavity the duct crosses the lateral lig. of the bladder and the **ureter** (f) and enters the genital fold. It ends in the urethra on the **colliculus seminalis** in a common orifice with the duct of the vesicular gland.

e) The **ACCESSORY GENITAL GLANDS** are all present as in the horse, but fully developed only in the bull—not in the steer. The bilateral **vesicular gland** (11) is the largest accessory genital gland in the bull. It is a lobated gland of firm consistency—not vesicular. It is 10–20 cm long and lies dorsal to the bladder and lateral to the ureter and the **ampulla of the ductus deferens** (13). The ductus deferens narrows again caudal to the ampulla and, with the duct of the vesicular gland, passes under the body of the prostate. The two ducts open on the **colliculus seminalis** (see above). The **body of the prostate** (15) projects on the dorsal surface of the urethra between the vesicular glands and the urethral muscle. The **disseminate part of the prostate**, 12–14 cm long, is concealed in the wall of the urethra and covered ventrally and laterally by the urethral muscle. The bilateral **bulbourethral gland** (18) is the size of a walnut. It lies on each side of the median plane dorsal to the urethra in the transverse plane

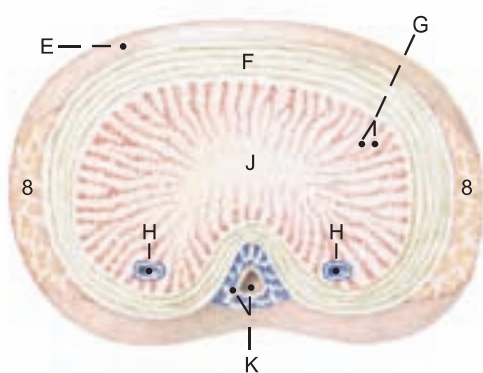
of the ischial arch. It is mostly covered by the **bulbospongiosus muscle**. Its duct opens on the lateral fold that extends caudally from the septum between the urethra and the urethral recess (see p. 82).

f) The **PENIS** of the bull belongs to the **fibroelastic type**. It extends from its **root** (h) at the ischial arch to the **glans penis** (A) in the umbilical region. It is covered by skin, is about one meter long, and in the **body [corpus penis (i)]**, has a **sigmoid flexure (j)** that is caudal to the scrotum. The proximal bend is open caudally and the distal bend, open cranially, can be grasped through the skin caudal to the thighs. The penis is sheathed by telescoping fascia. The short collagenous **suspensory ligg. of the penis** (l) are attached close together on the ischial arch, and the dorsal nn. and vessels of the penis pass out between them. They should not be confused with the fundiform lig. of the penis (p. 80). The penis consists of the dense **corpus cavernosum penis**, which begins at the junction of the **crura penis** (7), attached to the ischial arch. It is surrounded by a thick **tunica albuginea** (F) containing cartilage cells. The **cavernae** are mainly peripheral, and axially there is a dense **connective tissue strand** (J). The **free part of the penis** (k), 8 cm long, is distal to the attachment of the internal lamina of the **prepuce** (2). It is twisted to the left as indicated by the oblique course of the **raphe of the penis** (D) from the **midventral raphe of the prepuce** (D") to the **external urethral orifice** (B) on the right side. Just before ejaculation an added left-hand spiral of the free part of the penis is caused by the internal pressure acting against the right-hand spiral of the collagenous fibers of the subcutaneous tissue and tunica albuginea, and against the **apical lig.** The latter originates dorsally from the **tunica albuginea**, beginning distal to the sigmoid flexure.* **Midventral on the penis is the penile urethra**, surrounded by the **corpus spongiosum penis** (K). The **urethral process** (C) lies in a shallow groove between the raphe and the cap-like **glans penis** (A), which is connected to the corpus spongiosum, but contains little erectile tissue. The **prepuce** consists, as in the dog, of an **external lamina** (1) and an **internal lamina** (2), and has bristle-like hairs at the **preputial orifice** (3). The **frenulum of the prepuce** (D') connects the raphe of the prepuce to the raphe of the penis. The **muscles of the penis**: The **ischiocavernosus** (7) extends from the medial surface of the ischial tuber to the body of the penis, covering the crus penis. The **bulbospongiosus** (6) covers the bulb of the penis and a large part of the bulbourethral gland and extends to the beginning of the body of the penis. During erection both muscles regulate the inflow and outflow of blood. The paired smooth muscle **retractor penis** (8) originates from the caudal vertebrae, receives reinforcing fibers from the **internal anal sphincter**, extends across the first bend of the sigmoid flexure and is attached to the second bend. The two muscles then approach each other on the ventral surface and terminate on the **tunica albuginea** 15–20 cm proximal to the glans. In erection these muscles relax, permitting the extension of the sigmoid flexure and elongation of the penis.

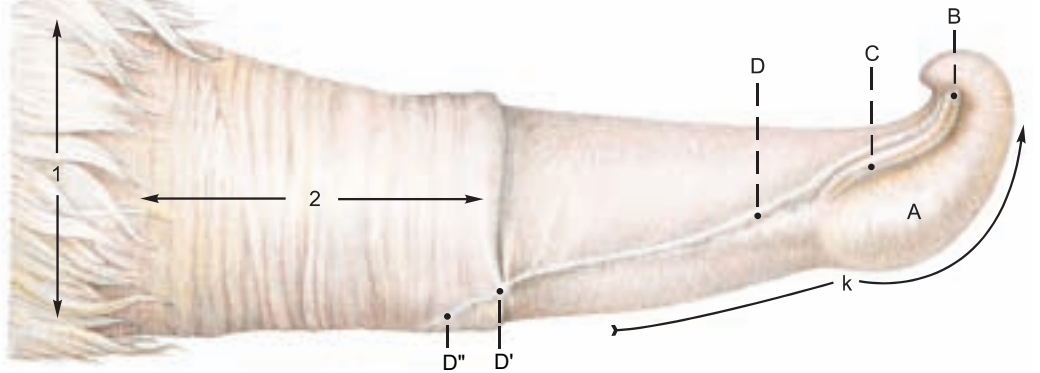
The **lymphatic vessels** of the scrotum, penis, and prepuce drain to the **superficial inguinal lnn.** (9) which lie dorsolaterally on the penis at the transverse plane of the pecten pubis, just caudal to the spermatic cord. The lymph vessels of the testes go to the medial iliac lnn. (p. 82).

Penis

(Cross section cranial to sigmoid flexure)



(Right surface)



Legend:

A Glans penis
B Ext. urethral orifice
C Urethral process

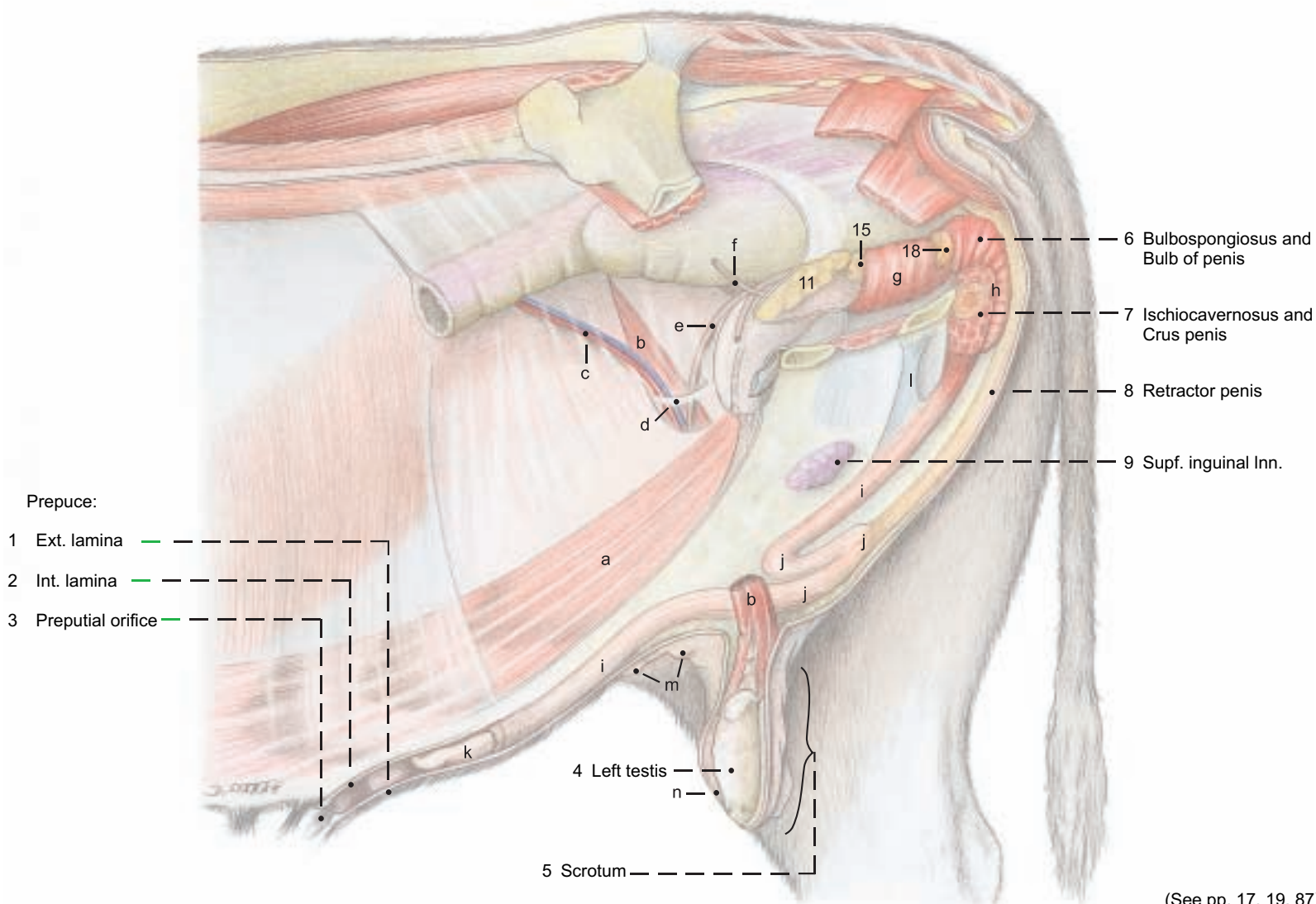
D Raphe of penis
D' Frenulum of prepuce
D'' Raphe of prepuce
E Fascia of penis

F Tunica albuginea
G Trabeculae of J
H Deep veins of penis

J Corpus cavernosum
K Corpus spongiosum and urethra
k Free part of penis

Male genital organs

(Left side)

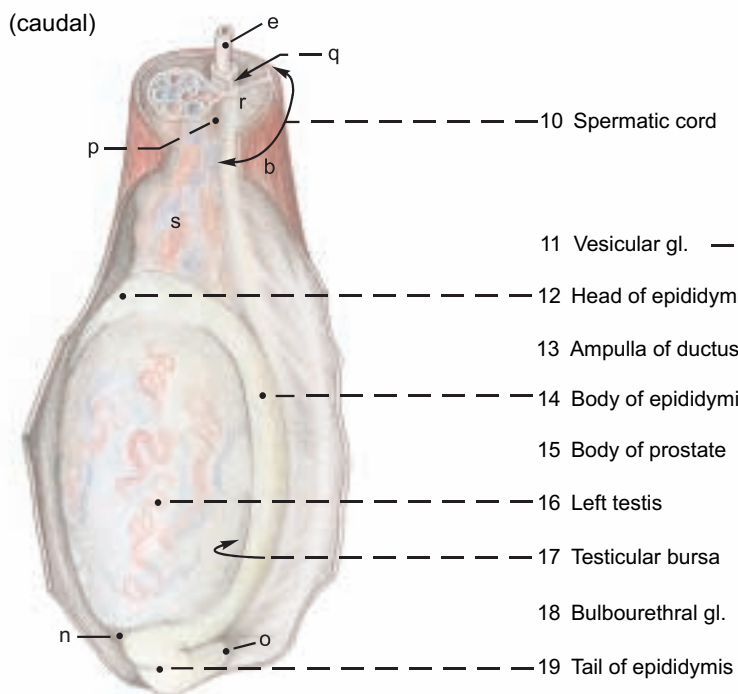


(See pp. 17, 19, 87)

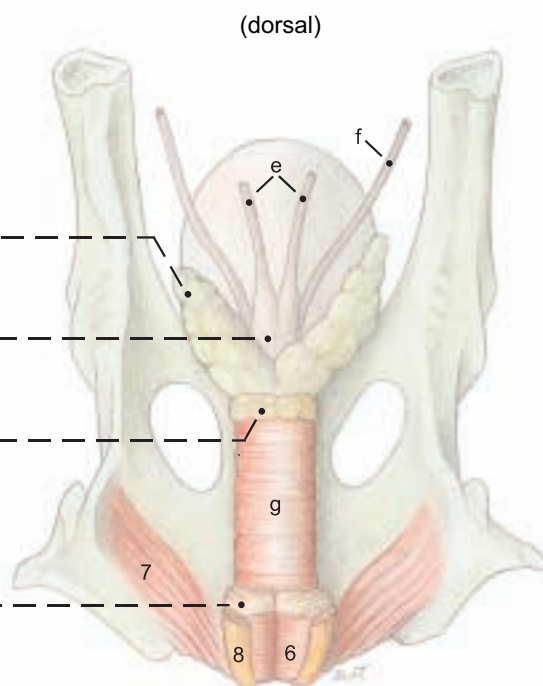
Legend:

- | | | | |
|------------------------|---------------------|-----------------------------|--------------------------------------|
| a Rectus abdominis | f Ureter | j Sigmoid flexure | o Lig. of the tail of the epididymis |
| b Cremaster | g Urethralis | k Free part of penis | p Mesorchium |
| c Testicular a. and v. | Penis: | l Suspensory ligg. of penis | q Mesoductus deferens |
| d Vaginal ring | h Root of the penis | m Male mammary gl. | r Mesofuniculus |
| e Ductus deferens | i Body of the penis | n Proper ligg. of testis | s Pampiniform plexus |

Testis and Epididymis



Accessory genital gl.



9. PERINEUM, PELVIC DIAPHRAGM, ISCHIORECTAL FOSSA, AND TAIL

The clinically important perineum is studied by first removing the skin from the perineal region to see the superficial muscles, nerves, and vessels. The fat is removed from the ischiorectal fossa, exposing the **distal cutaneous br. of the pudendal n. (19)** where it emerges on the medial surface of the tuber ischiadicum and supplies the **superficial perineal nn. (4)**. The **caudal rectal a. (21)** is exposed in its course along the lateral border of the ext. anal sphincter, and branches of the **dorsal and ventral perineal aa.** are seen. The superficial fascia is incised from the labia to the udder to expose the large, convoluted, and often double **ventral labial v. (16)**, draining blood from the perineum to the **caudal mammary v.** The **mammary brr. of the pudendal nn.** are traced on the lateral borders of the vein. The corresponding nerve in the bull is the preputial and scrotal br., and the vein is the ventral scrotal. In deeper dissections the fascia is removed from the terminations of the **coccygeus (2)** and **levator ani (3)** and from the **constrictor vestibuli (13)** and **constrictor vulvae (14)**. The smooth muscle **retractor clitoridis (15)** is seen between the constrictor vestibuli and constrictor vulvae in the cow, and the **retractor penis** between the bulbospongiosus and ischiocavernosus in the bull.

a) The **PERINEUM and PERINEAL REGION**. The **perineum** is the part of the body wall that closes the pelvic outlet, bounded by the first caudal vertebra, the **sacrosciatic ligg. (1)**, the **tubera ischiadica (b)**, and the ischial arch. The part of the perineum dorsal to a line connecting the tubera ischiadica is the anal triangle, surrounding the anal canal and closed by the pelvic diaphragm. The part of the perineum ventral to the line is the urogenital triangle, surrounding the urogenital tract and closed by the perineal membrane. A more restricted definition includes only the perineal body between the anus and the urogenital tract. The **perineal region** is the surface area over the perineum and adjacent parts. In the ox it is bounded dorsally by the root of the tail and ventrally by the attachment of the scrotum or udder. The lateral border is formed by the sacrosciatic ligament, tuber ischiadicum, and a line from the tuber to the scrotum or udder. The perineal region is divided into anal and urogenital regions by a line connecting the medial processes of the tubers. *The urogenital region is greatly elongated in ruminants by the ventral position of the scrotum and udder.*

b) The **ANAL TRIANGLE**. The **pelvic diaphragm** is composed of right and left **coccygeus (2)** and **levator ani (3)** muscles and the **external anal sphincter (12)**, together with the deep fascia on their external and internal surfaces. Each half of the diaphragm is oblique, extending caudomedially from the origin of the muscles on the medial surface of the sciatic spine, to the termination of the coccygeus on the caudal vertebrae and of the levator ani on the external anal sphincter. The **perineal body [centrum tendineum perinei]**, is the fibromuscular mass between the anus and the urogenital tract.

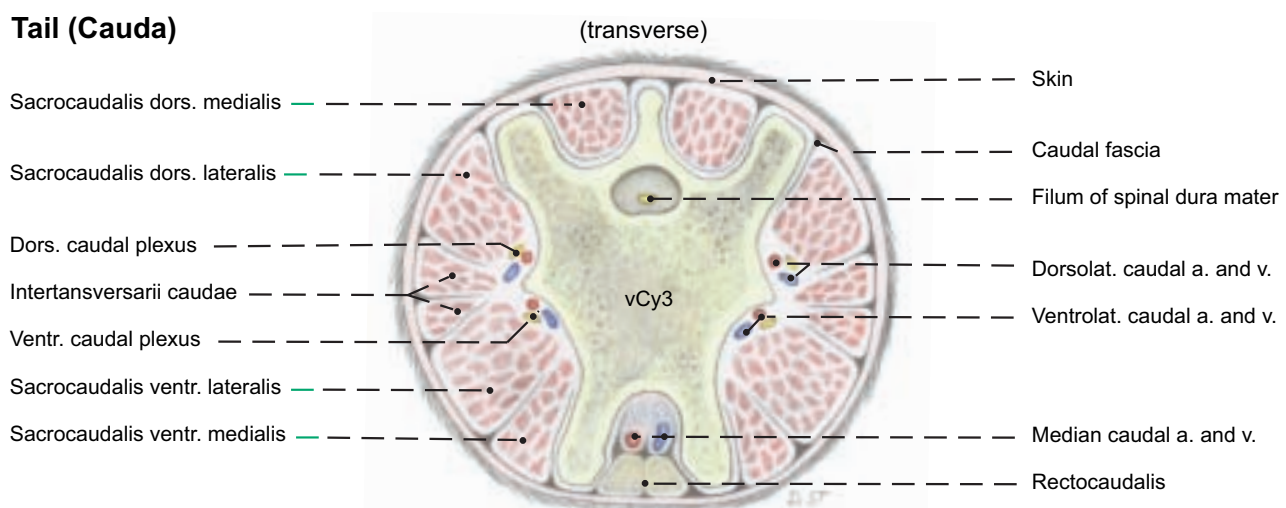
c) The **UROGENITAL TRIANGLE**. The **perineal membrane** in the cow is a strong sheet of deep perineal fascia extending from the ischial arch to the ventral and lateral walls of the vestibule, cranial to the **constrictor vestibuli (13)** and caudal to the **major vestibular gland (10)**. Together with the urogenital muscles it closes the urogenital triangle, joining the pelvic diaphragm at the level of the perineal body and anchoring the genital tract to the ischial arch.

d) The **ISCHIORECTAL FOSSA** is a fat-filled, wedge-shaped space lateral to the anus. The laterodorsal wall is the **sacrosciatic lig.**, the caudal border of which, the **sacrotuberous lig (1)**, is easily palpable. The lateroventral wall is the tuber ischiadicum and the obturator fascia. The medial wall is the deep fascia covering the coccygeus, levator ani, and constrictor vestibuli. In the ox, unlike the horse, the sacrotuberous lig. and tuber ischiadicum are subcutaneous (see p. 16).

e) **NERVES AND VESSELS**. For the intrapelvic origins of the perineal nerves and vessels, see pp. 84–85. The **pudendal n. (9)** gives

off the **proximal and distal cutaneous branches** and the **deep perineal n. (20)**, and continues caudally on the pelvic floor with the **internal pudendal a. and v. (9)**, supplying the vestibule and the **mammary br. (25)** and terminating in the clitoris. In the bull, the pudendal n. gives off the **preputial and scrotal brr.** and continues as the **dorsal n. of the penis**. The deep perineal n. supplies the vagina, major vestibular gland, and perineal muscles, and ends in the labium and the skin lateral to the perineal body. The **caudal rectal n. (17)**, which may be double, supplies branches to the rectum, coccygeus, levator ani, ext. anal sphincter, retractor clitoridis (penis), perineal body, constrictor vestibuli, roof of the vestibule, and labium. Anesthesia of the penis and paralysis of the retractor penis, or anesthesia of the vestibule and vulva can be produced by blocking bilaterally the pudendal and caudal rectal nn. and the communicating br. of the caud. cutaneous femoral n. (p. 84) inside the sacrosciatic lig.* The **internal iliac a. (6)**, at the level of the sciatic spine, gives off the vaginal or prostatic a. (These arteries may originate from the internal pudendal a.) The internal iliac ends by dividing at the lesser sciatic foramen into the caud. gluteal a. and **internal pudendal a. (9)**. The latter supplies the coccygeus, levator ani, ischiorectal fossa, vagina, urethra, vestibule, and major vestibular gl. The internal pudendal a. ends by dividing into the **ventral perineal a. (23)** and the **a. of the clitoris (24)**. The ventral perineal a. usually gives off the **mammary branch (25)**. In some cows the ventral perineal a. and mammary br. are supplied by the dorsal labial br. of the dorsal perineal a. The **vaginal a. (7)**, after giving off the uterine br., divides into the middle rectal a. and the **dorsal perineal a. (8)**. The latter divides into the **caud. rectal a. (21)** and the **dorsal labial br. (22)**, which gives off the perineal br. seen on the tuber ischiadicum, and runs ventrally in the labium. It may also supply the mammary br. and the ventral part of the perineum. The dorsal labial br. may be cut in episiotomy. In the male, the **prostatic a.** gives branches to the urethra, prostate, and bulbourethral gl., and may terminate as the dorsal perineal a., but the latter usually comes from the internal pudendal a.**

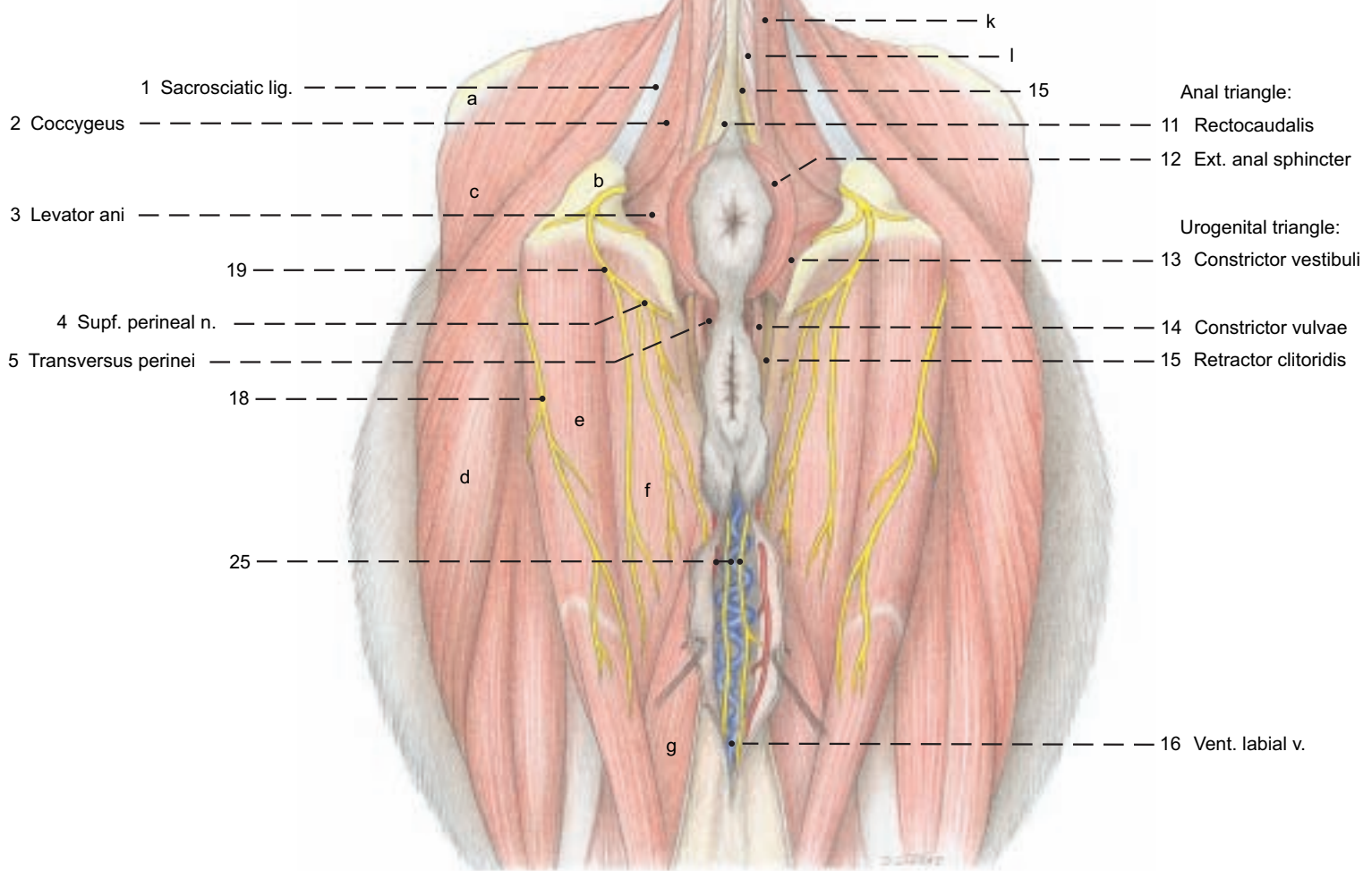
f) The **TAIL** contains 16–21 caudal vertebrae. The **rectocaudalis** is longitudinal smooth muscle from the wall of the rectum, attached to caud. vertebrae 2 and 3. The smooth muscle retractor clitoridis (penis) originates from caud. vertebrae 2 and 3 or 3 and 4. The **caudal nerves** in the cauda equina run in the vertebral canal. The **median caudal a. and v.** on the ventral surface are convenient for the veterinarian working behind stanchioned cows. The pulse is best palpated between the vertebrae or about 18 cm from the root of the tail to avoid the hemal processes. Tail bleeding is done by raising the tail and puncturing the median caudal v. between hemal processes.



Perineal region



(Caudal aspect)

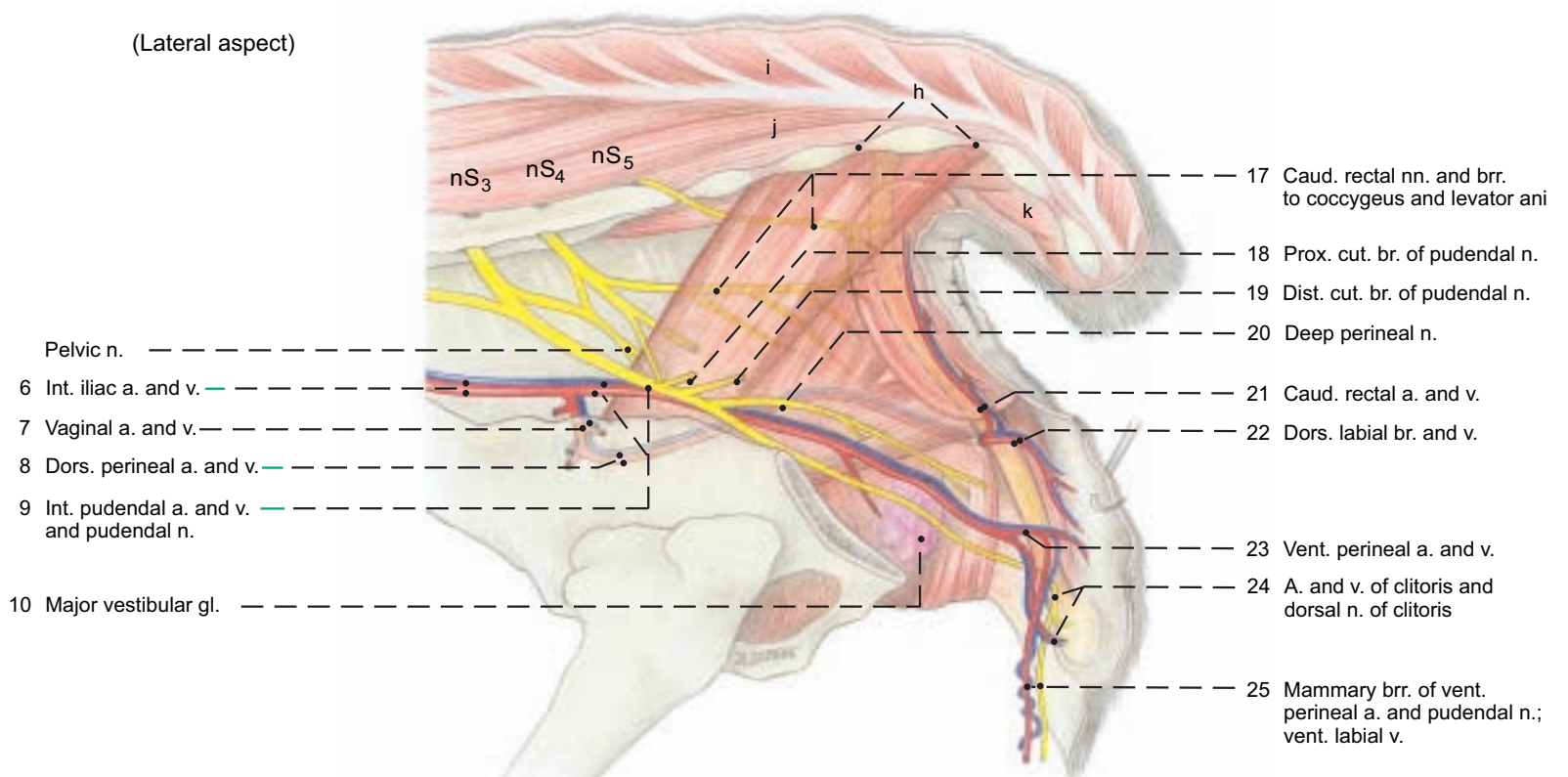


(See pp. 85, 91)

Legend:

- | | | | |
|------------------------|-------------------|----------------------------|----------------------------|
| a Tuber coxae | d Biceps femoris | g Gracilis | j Sacrocaudalis dors. lat. |
| b Tuber ischiadicum | e Semitendinosus | h Intertransversarii | k Sacrocaudalis vent. lat. |
| c Gluteus medius | f Semimembranosus | i Sacrocaudalis dors. med. | l Sacrocaudalis vent. med. |
| c Retractor clitoridis | | | |

(Lateral aspect)

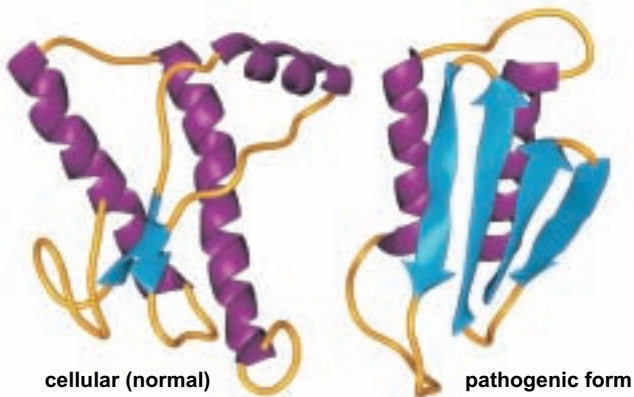


ANATOMICAL ASPECTS OF BOVINE SPONGIFORM ENCEPHALOPATHY (BSE)

NATURE OF THE DISEASE

The term spongiform encephalopathy refers to spongy changes in the brain. BSE is one of a group of diseases called transmissible spongiform encephalopathies (TSE), of which scrapie of sheep has been known for a long time, is widely distributed, and has been intensively investigated. The TSE are caused by **prion proteins (PrP)** – minute proteinaceous infectious particles 4–6 nm in diameter. They occur in normal and pathogenic forms on the surface of nerve cells and various cells of lymphatic tissue. In normal PrP the amino acid chains are predominantly wound up in **alpha-helices**. By unknown processes, often by mutation in the controlling gene, pathogenic PrP develop, whose amino acids in some regions of the molecule are refolded from alpha helices into **beta-sheets** layered antiparallel on each other.* The misfolded, pathogenic PrP cause BSE by imposing their structure on normal PrP, thereby multiplying the pathogen. They enter the lysosomes of nerve cells, where they are not decomposed, but accumulate in amyloid plaques and cause the death of the nerve cells.**

Models of prion proteins (purple = alpha-helix structure, blue = beta sheet structure)



SPECIES DISTRIBUTION OF PRION DISEASES

Prion diseases have been found in sheep, goats, cattle, zoo and wild ruminants, mink, great cats, and rhesus monkeys. Human prion diseases are Creutzfeldt-Jakob disease, Gerstmann-Straeussler syndrome, fatal familial insomnia, and kuru. BSE is of great importance because:

1. Its causative agent can overcome the species barrier and become very dangerous to man.
2. Cattle are significant sources of human food, and an undiagnosed BSE infection is a danger to man.

THE SIGNS OF BSE DISEASE

The average age of cattle affected with BSE is about 3 years, but the first signs may appear at 20 months. As a result of the brain disorder, the following signs appear: hypersensitivity to stimuli (e. g. noise), anxiety, aggression, and locomotor disturbance progressing to collapse. The terminal stage is prostration until death. There is no cure.

DIAGNOSIS OF BSE

A suspected clinical diagnosis is possible in the terminal stage, but a certain diagnosis can be made only after death. For the rapid test, parts of the brainstem are removed, homogenized, and digested by proteinases. After digestion, only the pathogenic PrP remain intact, and can be identified by a specific antibody. If the results are doubtful, further tests by immunohistological or cytological (E/M) methods are required.

POSSIBLE CAUSES FOR THE APPEARANCE OF NEW PRION DISEASES

The PrP of scrapie in sheep could have mutated in cattle to the PrP of BSE. Scrapie was widely distributed in Great Britain, and carcasses of affected sheep were rendered in plants to fat and tankage in large autoclaves (tanks). The tankage (meat and bone meal) was a common source of protein in animal feed, including cattle feed. Transmission by feed was later made highly probable by the success of a ban on tankage in animal feed.**

In Germany BSE was probably spread by feeding calves a milk substitute made by replacing milk fat with tallow from adult bovine mesenteric and abdominal fat.

Failure to observe proper procedures in the operation of the tank (addition of lye and detergents and maintenance of heat at 130 °C for 20 min.) could have led to survival of pathogenic PrP.

PATHWAYS OF INFECTION

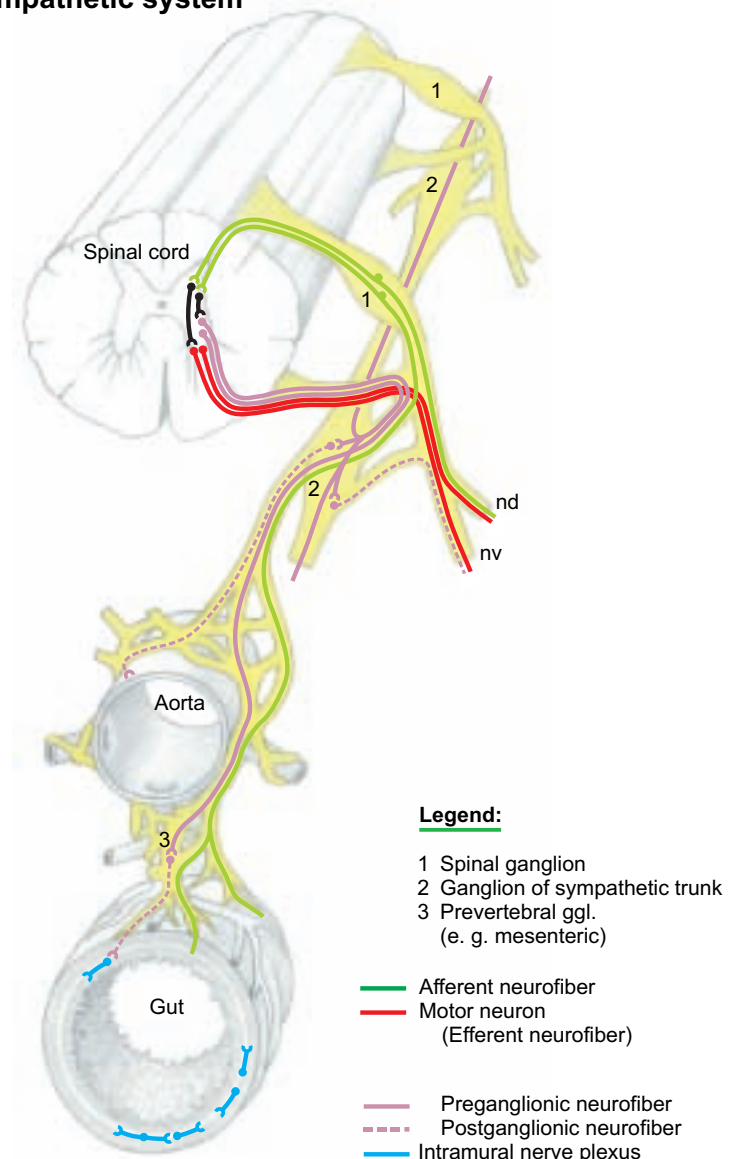
The probable mode of infection in sheep and cattle is intestinal. Precise information on infection of cattle is not available, but inferences can be drawn from experiments on rodents, which have a much shorter incubation period. Also, possible parallels can be drawn to scrapie in sheep.

TRANSPORT THROUGH THE AUTONOMIC SYSTEM

At least three routes to the CNS have been proposed on the basis of experiments on rodents: ***

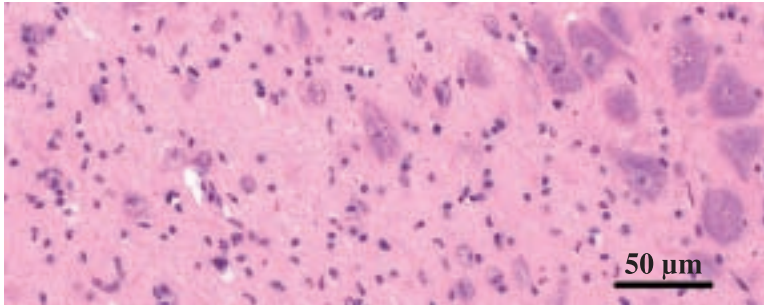
1. The vagus conducts **parasympathetic fibers** that bypass the spinal cord. The vagal efferents have their nerve cell bodies in the dorsal motor nucleus in the obex region of the medulla. Vagal afferents have their nerve cell bodies in the proximal and distal vagal ganglia. They send their short axons to the obex region.
2. An alternative route goes from the enteric plexuses through prevertebral ganglia and the **splanchnic nerves** to the **sympathetic trunk**, thence through the communicating branches and spinal nerve roots to the tracts of the spinal cord leading to and from the brain.
3. A third possibility is passage from the sympathetic trunk through the cervicothoracic ganglion, ansa subclavia, and **vago-sympathetic trunk** to the head.

Sympathetic system

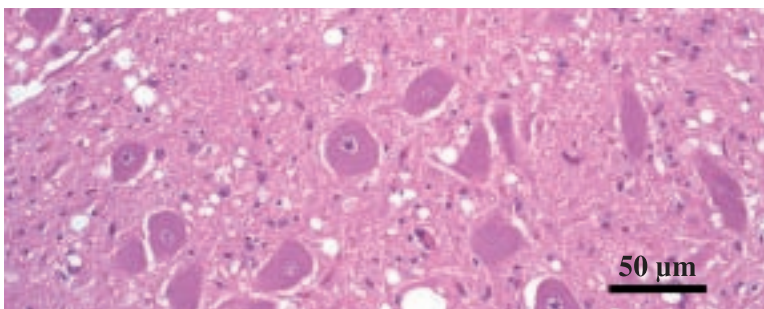


AREAS OF HIGHEST CONCENTRATION IN THE BRAIN

The primary site of pathogenic prions is the region of the obex between the medulla oblongata and the spinal cord. The dorsal vagal nucleus and other important nuclei here show typical spongiform changes. Other regions of the brainstem display lesions. Spongiform encephalopathy of the cerebellar cortex explains the locomotor disturbances and ataxia. Insoluble amyloid forms in the nerve cells, with high concentration of pathogenic prions and spongiform changes. Neighboring glia cells are also affected.



Normal nervous tissue in the region of the obex (dorsal vagal nucleus).
Preparation: Prof. G. Boehme, Inst. of Vet. Anatomy, FU-Berlin



Nervous tissue of the region of the obex in BSE.
Preparation: Prof. F. Ehrensperger, Inst. of Vet. Pathology, Zürich

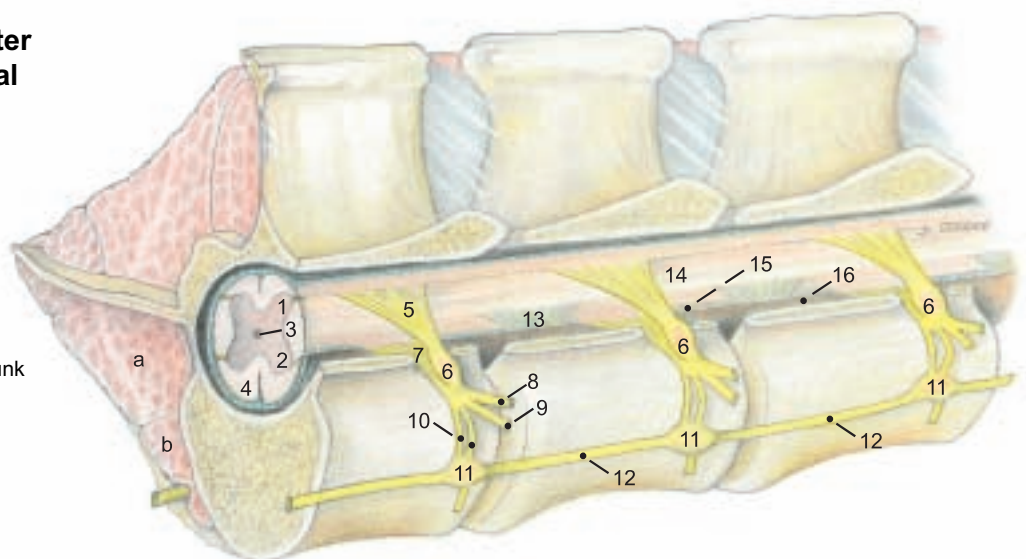
Another TSE, chronic wasting disease (CWD) of North American deer and elk, discovered in Colorado in 1967, has been found in wild or farmed deer and elk in Wyoming, Nebraska, South Dakota, Oklahoma, Montana, Wisconsin, and one case in Illinois. (The North American elk, a misnomer, is *Cervus canadensis*, not *Alces alces*—the European Elk and the North American moose.) There is no evidence that other species, including man, are infected through contact with CWD.**** In experimental deer inoculated orally with infective deer brain, pathogenic PrP were first found in lymphoid tissues of the alimentary system and then in autonomic nerves leading from the gut to the brainstem, where they appeared first in the dorsal motor nucleus of the vagus. Other peripheral nerves, such as the brachial plexus and sciatic nerve, were tested and found negative.*****

The U. S. government has prohibited importation of live ruminants and most ruminant products from Europe and Canada. The U. S. Food and Drug Administration prohibits the feeding of most mammalian protein to ruminants. The U. S. Dept. of Agriculture has prohibited importation of all rendered animal products of any species. There is no evidence of BSE in the United States after a decade of testing for it.*****

Spinal cord and sympathetic trunk after removal of the left side of the vertebral arches and the musculature

Legend:

Gray matter	10 Communicating br.
1 Dorsal horn	white and gray
2 Ventral horn	11 Ganglia of sympathetic trunk
3 Central canal	12 Sympathetic trunk
4 White matter	13 Denticulate lig.
5 Dorsal root	14 Pia mater
6 Spinal ganglion	15 Arachnoidea
7 Ventral root	16 Dura mater
8 Dorsal br.	a Psoas major
9 Ventral br.	b Psoas minor



REMOVAL OF THE BRAINSTEM FOR LABORATORY TESTS

After slaughter and decapitation, brainstem tissue can be removed with a curette through the foramen magnum. If the head is bisected, the myelencephalon and metencephalon are separated from the more rostral parts of the brain (see p. 51, below by a transverse cut through 13 and 14, and by cutting the roots of cranial nn. V-XII and the cerebellar peduncles to release the sample of the brainstem. The material of the obex region is used for the BSE rapid test. If the results are positive, histopathologic, immunohistochemical, and E/M investigations follow, for which more rostral parts of the brainstem are used.

TRANSMISSION OF BSE TO MAN

Human infection with the agent of BSE and consequent illness with the variant of Creutzfeldt-Jacob disease (vCJD) is highly probable. In vCJD the multiplication of the agent also occurs outside the brain and spinal cord in the lymphatic organs (e.g. tonsils); whereas in the sporadic (classical) CJD the pathological changes remain restricted to the CNS. The likelihood of transmission from BSE-infected cattle to man is supported by the fact that the agents of BSE and vCJD are biologically and biochemically identical. The connection of time and place between occurrences of BSE and vCJD in Great Britain supports this probability. Apparently a genetically determined susceptibility plays a role in transmission because, so far, only a few people have contracted vCJD, and only a few of the cattle in a herd contract BSE.

DANGERS OF EATING MEAT AND MEAT PRODUCTS FROM BSE-INFECTED CATTLE OR CATTLE SUSPECTED OF EXPOSURE TO BSE

The risks increase with the amount of infective material consumed and its concentration of pathogenic misfolded prions. Of the components of nervous tissue, the perikarya and therefore the ganglia and nuclei may present a greater danger than axons, and thus more than nerves and fiber tracts. The perikarya occupy a much larger volume and have a concentration of prions in the lysosomes, which are not present in the processes. The danger is increased, the nearer the ganglia lie to valuable cuts of meat; for example, the sympathetic trunk and ganglia are closely associated with the tenderloin (iliopsoas and psoas minor (see p. 81, upper fig.)) The spinal ganglia lie in the intervertebral foramina and are included with the bone in steaks cut from the rib and loin regions (see text fig.). Regarding the concentration of pathogenic misfolded prions the following list presents the opinion of the European Union on the possible risk of infectivity in various tissues (including experiments with scrapie).

1. **Highly infectious tissues:** brain and spinal cord together with surrounding membranes, eyes, spinal ganglia.
2. **Tissues of intermediate infectivity:** intestine, tonsils, spleen, placenta, uterus, fetal tissue, cerebrospinal fluid, hypophysis, and adrenal gl.
3. **Tissues of lower infectivity:** liver, thymus, bone marrow, tubular bones, nasal mucosa, peripheral nerves.
4. **Infectivity was not demonstrated in the following tissues and organs:** skeletal muscle, heart, kidneys, milk, fat (except mesenteric fat), cartilage, blood, salivary gll., testis, and ovary.

SPECIAL ANATOMY, TABULAR PART

1. MYOLOGY

MUSCLE / FIG.	ORIGIN	TERMINATION	INNERVATION	FUNCTION	REMARKS
MEDIAL MUSCLES OF THE SHOULDER AND ARM (p. 4)					
Teres major (5.2)	Caudal border of scapula and subscapularis	Teres major tuberosity of humerus	Axillary n.	Flexor of shoulder joint	Joined by terminal tendon of latissimus dorsi
Subscapularis (5.4)	Subscapular fossa of scapula	Minor tubercle of humerus	Subscapular and axillary nn.	Mainly an extensor of shoulder jt.	3–4 distinct parts; tendon acts as med. collat. lig. of shoulder joint
Coracobrachialis (5.16)	Coracoid process of scapula	Small part prox. and large part dist. to teres major tuberosity of humerus	Musculocutaneous n.	Extensor of shoulder joint and adductor and supinator of brachium	Two bellies; synovial bursa under tendon of origin
Articularis humeri	Inconstant in the ox.				
Biceps brachii (5.26)	Supraglenoid tubercle of scapula	Radial tuberosity, cranial surface of radius, fleshy on med. collat. lig. of elbow joint	Musculocutaneous n.	Extensor of shoulder joint, flexor of elbow joint	Intertubercular bursa under tendon of origin; thin lacertus fibrosis of antebrachial fascia
Brachialis (5.21)	Caud. surface of humerus, close to neck	<i>Radial tuberosity and med. collat. lig. of elbow joint</i>	Musculocutaneous n.; for distal parts, radial n.	Flexor of elbow joint	Spiral course in brachialis groove of humerus, added innervation from radial n. in 50 %
Tensor fasciae antebrachii (5.22)	Caud. border of scapula, latissimus dorsi	Medially on olecranon and antebrachial fascia	Radial n.	Tensor of fascia of forearm and extensor of elbow joint	
LATERAL MUSCLES OF SHOULDER AND ARM (p. 4)					
Deltoides			Axillary n.		
Clavicular part (Cleido-brachialis) (5.23)	Clavicular intersection	Crest of humerus		Advances limb	Part of brachiocephalicus; see p. 60
Scapular part (5.6)	Caud. border of scapula, aponeurosis from scapular spine	Deltoid tuberosity of humerus, <i>fascia of triceps</i>		Flexor of shoulder joint	Small flat muscle
Acromial part (5.7)	Acromion	Deltoid tuberosity of humerus		Flexor of shoulder joint	Interspersed with tendinous strands
Teres minor (5.12)	Distal half of cd. border of scapula	Prox. to deltoid tuberosity of humerus on <i>teres minor tuberosity</i>	Axillary n.	Flexor of shoulder joint	
Supraspinatus (5.1)	Supraspinous fossa, cran. border of scapula	Major and minor tubercles of humerus	Suprascapular n.	Extensor and stabilizer of shoulder jt.; also flexor dependent on state of joint	Tendon of origin of biceps passes between the terminal tendons
Infraspinatus (5.11)	Infraspinous fossa and spine of scapula	Deep part on prox. border and med. surface of major tubercle; supf. part distal to tubercle	Suprascapular n.	Abductor and lateral rotator of arm; acts as lat. collateral lig.	Largely tendinous, flat; supf. tendon passes over infraspinatus bursa
Triceps brachii		All heads together on olecranon	Radial n.	Extensor of elbow joint; long head also flexes shoulder joint; stabilizer of elbow	Relatively flat
Long head (5.18)	Caud. border of scapula				
Lat. head (5.17)	Lateral on humerus				
Med. head (5.19)	Medial on humerus				
Accessory head	Caudal on humerus				Partially separable from med. head
Anconeus (5.25)	Borders of olecranon fossa	Lateral on olecranon	Radial n.	Extensor of elbow joint	Separable with difficulty from lat. head of triceps

MUSCLE / FIG.	ORIGIN	TERMINATION	INNERVATION	FUNCTION	REMARKS
CRANIOLATERAL MUSCLES OF THE FOREARM					
Generally extensors, which originate predominantly on the lateral epicondyle of the humerus (p. 4)					
Common digital extensor (5.40)			Radial n.		Extensor of the digits and carpus
<i>Medial head (Proper extensor of digit III, Med. digital extensor)</i>	<i>Lateral epicondyle of humerus</i>	<i>Middle and distal phalanges of digit III</i>		<i>Extensor of fetlock and pastern joints of digit III</i>	<i>Receives extensor branches of interosseus III</i>
<i>Lateral head (Common extensor of digits III and IV)</i>	<i>Lateral epicondyle of humerus, head of ulna</i>	<i>Branches to extensor processes of dist. phalanges of digits III & IV</i>		<i>Extensor of coffin joints</i>	<i>Narrow muscle; humeral and ulnar heads unite in a common tendon</i>
Lateral digital extensor (Proper extensor of digit IV) (5.41)	Proximal on radius and ulna	<i>Middle and distal phalanges of digit IV</i>	Radial n.	<i>Extensor of fetlock and pastern joints of digit IV</i>	Unified; corresponds to medial dig. extensor, with extensor branches from interosseus IV
Extensor carpi radialis (5.35)	Lat. supracondylar crest and radial fossa of humerus	Tuberosity of Mc III	Radial n.	Extensor and stabilizer of carpus	Has synovial bursae on carpus and at termination; may have rudimentary extensor digiti I
Ulnaris lateralis (Extensor carpi ulnaris) (5.38)	Lateral epicondyle of humerus	Accessory carpal bone and Mc V	Radial n.	Flexor (!) of the carpus	
Ext. carpi obliquus (Abductor pollicis longus) (5.39)	Craniolat. in middle third of radius	Mc III	Radial n.	Extensor of the carpus	Terminal tendon has synovial bursa
CAUDOMEDIAL MUSCLES OF THE FOREARM					
Generally FLEXORS, which originate predominantly on the medial epicondyle of the humerus (p. 4)					
Superficial digital flexor (5.36 and 5.37)	Med. epicondyle of humerus	Flexor tuberosities of middle phalanges	Ulnar n.	Flexor of the carpus and digits	Larger supf. belly supf. to flexor retinaculum; deep belly within carpal canal

MUSCLE / FIG.	ORIGIN	TERMINATION	INNERVATION	FUNCTION	REMARKS
Deep digital flexor (5.34)		Flexor tubercles of distal phalanges		Flexor of coffin jts.; support of fetlock jts.	The single deep flexor tendon is surrounded by a synovial bursa in the carpal canal
Humeral head	Med. epicondyle of humerus		Ulnar and median nn.		The humeral head is tripartite and interspersed with many tendinous strands
Ulnar head	Olecranon		Ulnar n.		Ulnar head is small
Radial head	Caudomedial on prox. third of radius		Median n.		
Flexor carpi ulnaris (5.29)		Accessory carpal bone	Ulnar n.	Flexor of carpus	
Humeral head	Medial epicondyle of humerus				
Ulnar head	Medially on olecranon				Ulnar head is small
Flexor carpi radialis (5.28)	Medial epicondyle of humerus	<i>Proximopalmar on Mc III</i>	Median n.	Flexor of carpus	Surrounded by a tendon sheath in carpal canal
Pronator teres (5.27)	Medial epicondyle of humerus	Craniomedial on radius	Median n.	Pronator of forearm and manus	Weakly muscular
METACARPUS (p. 4 and 18)					
Interflexorii	Muscle fibers connecting the supf. and deep digital flexors as well as their tendons, in and near the carpal canal		Median n.	Auxiliary flexors of the digits	
Interosseus III and Interosseus IV (p. 18)	Prox. end of mtc. bone; deep palmar carpal lig.	Prox. sesamoid bones; branches to proper extensor tendons; accessory lig. to supf. flexor	Palmar branch of ulnar n.	Support fetlock joints; oppose tension of deep flexor on distal phalanx	Predominantly tendinous in older cattle
MUSCLES OF THE HIP JOINT (p. 16)					
Tensor fasciae latae (17.5)	Tuber coxae	By the fascia lata on the patella, lat. patellar lig., and cran. border of tibia	Cran. gluteal n.	Flexor of hip joint, advances limb; extensor of stifle; tensor of fascia lata	Includes cran. parts of gluteus supf.; especially robust in cattle
Gluteus superficialis	Tuber coxae (gluteal fascia)	Cran. part of biceps femoris and fascia lata	Cran. and caud. gluteal nn.	<i>Extensor of hip joint; retractor of limb</i>	Not separable from the total mass of the gluteobiceps
Gluteus medius (17.1)	<i>Gluteal surface of ilium</i>	Major trochanter of femur	Cran. gluteal n.	Extensor of hip joint; abductor of limb	Has a lumbar process on the longissimus lumborum
Gluteus accessorius (17.3)	Gluteal surface of ilium	<i>Craniolat. on femur just distal to maj. trochanter</i>	Cran. gluteal n.	Same as gluteus medius	Clearly separable from gluteus medius; trochanteric bursa under terminal tendon
Gluteus profundus (17.4)	Sciatic spine, lat. on body of ischium, sacrosciatic lig.	<i>Craniolat. on femur, distal to gluteus accessorius</i>	Cran. gluteal n.	Abductor of limb	Synovial bursa under terminal tendon

MUSCLE / FIG.	ORIGIN	TERMINATION	INNERVATION	FUNCTION	REMARKS
CAUDAL THIGH MUSCLES (p. 16)					
Gluteobiceps (Biceps femoris) (17.7)	Vertebral head: caud. part of <i>median sacral crest</i> and last transverse processes; sacrosciatic lig.; and <i>tuber ischiadicum</i> . Pelvic head: tuber ischiadicum	Patella; <i>lat. patellar lig.</i> ; cran. border of tibia (by fascia cruris and fascia lata); common calcanean tendon	Vert. head: caud. gluteal n. Pelvic head: tibial n.	Extensor of hip and stifle; with caud. part, flexor of stifle; abductor of limb; extensor of hock	Not clearly separable into cran. and caud. parts; almost complete fusion with gluteus supf.
Semitendinosus (17.20)	<i>Tuber ischiadicum</i>	Cran. border of tibia, <i>terminal aponeurosis of gracilis</i> , common calcanean tendon	<i>Tibial n.</i>	In supporting limb: extensor of hip, stifle and hock; in swinging limb: flexor of stifle; also adductor and retractor of limb	No vertebral head; transverse intersection between prox. and middle thirds.
Semimembranosus (17.18)	<i>Tuber ischiadicum</i>	Med. condyles of femur and tibia	<i>Tibial n.</i>	In supporting limb: extensor of hip and stifle; in swinging limb: retractor, adductor, and pronator of limb	No vertebral head. Belly divides into two branches
DEEP MUSCLES OF THE HIP JOINT (p. 16, 18)					
Gemelli (17.25)	Lesser sciatic notch	Trochanteric fossa of femur	Muscular brr. of sciatic n.	Rotate thigh laterally	Thick, unified muscle plate
<i>Internal obturator is absent in the ox.</i>					
Quadratus femoris (17.26)	Ventral surface of ischium	Lat. surface of body of femur	Muscular brr. of sciatic n.	Supinator of thigh, auxiliary extensor of hip joint	
External obturator (19.7)	Outer and inner surface of ischium around obturator for.	Trochanteric fossa of femur	Obturator n.	Supinator of thigh; adductor of limb	The intrapelvic part is small and not homologous to internal obturator
MEDIAL THIGH MUSCLES: Adductors (p. 18)					
Gracilis (19.10)	<i>Prepubic tendon; by symphyseal tendon from pelvic symphysis</i>	<i>Fascia cruris</i>	Obturator and saphenous nn.	Adductor (and extensor of stifle jt.)	Right and left tendons of origin fused to form symphyseal tendon; terminal tendon fused with that of sartorius
Adductor magnus (et brevis) (19.9)	Symphyseal tendon; ventrally on pelvis	Facies aspera of femur	Obturator n.	Adductor and retractor of the limb	Joined by connective tissue with semimembranosus; on split carcass cut surface of adductor in bull is triangular; in cow it is bean-shaped
Pectineus (et adductor longus) (19.8)	Contralateral pubis: iliopubic eminence; ilium up to tubercle of psoas minor	Caudomedial on femur	Adductor part: obturator n.; pectineus part: saphenous n.	Adductor of limb, flexor of hip	More robust than in horse; crossed tendons of origin form the bulk of the prepubic tendon
EXTENSORS OF THE STIFLE (p. 18)					
Sartorius (19.3)	<i>Cranial: iliac fascia and tendon of psoas minor; caudal: iliopubic eminence and adjacent ilium</i>	Fascia cruris	Saphenous n.	Flexor of hip joint; protractor and adductor of limb; extensor of stifle	Lacuna vasorum for femoral vessels lies between the two tendinous heads
Quadriceps femoris		By middle patellar lig. on the tibial tuberosity	Femoral n.	Flexor of the hip joint (rectus); extensor and stabilizer of the stifle	Very large and clearly four heads
Rectus femoris (19.1)	Ilium: <i>main tendon from med. fossa cran. to acetabulum; small tendon from lat. area near acetab.</i>				
Vastus lateralis (17.29)	Proximolateral on femur				
Vastus medialis (19.2)	Proximomedial on femur				
Vastus intermedius	Proximocranial on femur				

MUSCLE / FIG.	ORIGIN	TERMINATION	INNERVATION	FUNCTION	REMARKS
SPECIAL FLEXOR OF THE STIFLE: Caudal to the stifle (p. 18)					
Popliteus (29.4)	Lateral femoral condyle	Proximomedial on caud. surface of tibia	Tibial n.	Flexor of stifle	
EXTENSORS OF THE HOCK AND FLEXORS OF THE DIGITS: Caudal on the crus (p. 18)					
Gastrocnemius (19.11) Lateral head Medial head	On both sides of supracondylar fossa of the femur	By the common calcanean tendon on calcanean tuber	Tibial n.	Extensor of the hock, flexor of the stifle	Very tendinous; intermediate fleshy tract connects origin of lat. head to tendon of med. head
Soleus (17.31)	Prox. rudiment of the fibula	Joins common calcanean tendon	Tibial n.	Auxiliary extensor of the hock	Fused with the lat. head of gastrocnemius
Supf. digital flexor (19.22)	Supracondylar fossa of femur	Flexor tuberosities of middle phalanges	Tibial n.	Extensor of hock; digital flexor; and flexor of the stifle	Very tendinous, fused proximally with lat. head of gastroc.; tendon caps calcaneus
Deep digital flexors		Distal phalanges	Tibial n.	Flexors of coffin joints; support of hock and fetlock joints	Tendons join to form the common deep flexor tendon in the metatarsus
Lat. digital flexor (17.32)	Lat. condyle and caud. surface of tibia				Passes over sustentaculum tali
Caudal tibial m. (17.33)	Lat. condyle of tibia				Passes over sustentaculum tali
Med. digital flexor (19.5)	Lat. condyle of tibia				Crosses hock separately
FLEXORS OF THE HOCK AND EXTENSORS OF THE DIGITS: Craniolateral on the crus (p. 16)					
Tibialis cranialis (17.8)	<i>Cran. border and proximolat. surface of tibia; prox. rudiment of fibula and replacement ligament</i>	<i>T I; proximomedial on Mt III and Mt IV</i>	Deep peroneal n.	Flexor of hock	Smaller than in horse; perforates terminal tendon of peroneus tertius; smaller head corresponds to extensor digiti I
Peroneus tertius (17.10)	<i>Extensor fossa of femur</i>	<i>Prox. on Mt III and Mt IV; T II and T III</i>	Deep peroneal n.	Flexor of hock	<i>Large and fleshy; completely fused at origin with long digital extensor</i>
Long digital extensor (17.13) <i>Medial head (Proper extensor of digit III, Med. digital extensor)</i> <i>Lateral head (Extensor of digits III and IV)</i>	<i>Extensor fossa of femur</i>	<i>Middle and distal phalanges of digit III</i> <i>Branches to extensor processes of distal phalanges of digits III and IV</i>	Deep peroneal n.	Extensor of digits and flexor of hock	Mostly covered by peroneus tertius <i>Receives extensor branches of interosseus III</i>

MUSCLE / FIG.	ORIGIN	TERMINATION	INNERVATION	FUNCTION	REMARKS
Lateral digital extensor (Proper extensor of digit IV) (17.12)	Lat. collateral lig. of stifle; lat. condyle of tibia	<i>Middle and distal phalanges of digit IV</i>	Deep peroneal n.	Extensor of digit IV and flexor of hock	Relatively large and pennate; receives extensor branches from interosseus IV
Extensor digitalis brevis (17.15)	<i>Ligamentous mass on dorsal surface of tarsus</i>	Joins tendon of long digital extensor	Deep peroneal n.	Digital extensor	Small
Peroneus longus (17.11)	Lat. condyle of tibia, rudiment of fibula	Tendon crosses lat. surface of hock and tendon of lat. dig. ext. and plantar surface of hock to T I	Deep peroneal n.	Flexor of hock	Small, with long thin tendon

METATARSUS:

Interossei III and IV: (see Muscle tables, p. 100 and p. 18)

MUSCLES INNERVATED BY THE FACIAL NERVE (p. 36 and 37)

Cervicoauricularis superficialis	Nuchal lig.	Dorsolat. surface of auricle	Caud. auricular n. from facial nerve	Raises auricle	
Cervicoauricularis profundus and medius	Nuchal lig. and cervical fascia	Caudolat. and caud. surface of auricle	Caud. auricular n. from facial nerve	Turn intertragic notch laterally	
Cervicoscutularis (37.2)	<i>Nuchal lig., parietal bone caud. to intercornual protuberance</i>	Caud. border of scutiform cartilage	Caud. auricular n. from facial nerve	Raises auricle and tenses scutiform cartilage	Broad muscle plate
Interscutularis (37.3)	<i>Cornual proc., temporal line</i>	Medially on scutiform cartilage	Rostral auric. br. of auriculopalpebral n. from facial n.	Tensor of scutiform cartilage	<i>Has no connection to contralateral muscle</i>
Frontoscutularis	Temporal line and zygomatic proc. of frontal bone	Scutiform cartilage	Rostral auric. br. of auriculopalpebral n. from facial n.	Tensor of scutiform cartilage	Two distinct parts according to origin
Zygomaticoscutularis (37.B)	Zygomatic arch	Rostrally on scutiform cartilage	Rostral auric. br. of auriculopalpebral n. from facial n.	Tensor of scutiform cartilage	
Scutuloauricularis superficialis et profundus (37.D, E)	Scutiform cartilage	Rostromedial on auricle	Rostral auric. br. of auriculopalpebral n. from facial n.	Levator and protractor of auricle	Two muscles crossed on scutiform cartilage
Zygomatocauricularis (37.12)	Zygomatic arch	Auricular concha, at intertragic notch	Rostral auric. br. of auriculopalpebral n. from facial n.	Turns intertragic notch rostrally	
Parotidoauricularis (37.13)	Parotid fascia	Auricular concha, at intertragic notch	Auriculopalpebral n. from facial nerve	Depressor and retractor of auricle	
Styloauricularis	Cartilage of acoustic meatus	Rostromedial border of auricle	Caud. auricular n. from facial nerve	Muscle of the acoustic meatus	May be absent

MUSCLES OF THE LIPS AND CHEEKS (p. 36)

Orbicularis oris (37.10)	Surrounds the opening of the mouth, <i>except the middle of the upper lip</i>		Buccal br. of facial nerve	Closes rima oris	<i>Contralat. fibers do not join in the upper lip</i>
Buccinator (37.26)	Between coronoid process of mandible and angle of the mouth		Buccal br. of facial nerve	Muscular substance of cheek; presses food from vestibule into oral cavity proper	Separable into a molar part with rostroventral fiber course, and buccal part with dorsoventral fiber course
Zygomaticus (37.11)	<i>Parotidomasseteric fascia</i>	In orbicularis oris at angle of mouth	Auriculopalpebral n. from facial n.	Retractor of angle of mouth	Well developed
Caninus (37.23)	<i>Rostrally on facial tuber</i>	<i>With 3 tendons on lat. rim of nostril</i>	Buccal br. of facial nerve	Dilates nostril and raises upper lip	Passes through levator nasolabialis; lies between levator and depressor of upper lip

MUSCLE / FIG.	ORIGIN	TERMINATION	INNERVATION	FUNCTION	REMARKS
Levator labii superioris (37.22)	<i>Facial tuber</i>	<i>Planum nasolabiale dors. and med. to nostril</i>	Buccal br. of facial nerve	Levator and retractor of upper lip and planum nasolabiale	Passes through levator nasolabialis; right and left tendons may join between nostrils
Depressor labii superioris (37.24)	<i>Rostrally on facial tuber</i>	<i>Upper lip and planum nasolabiale</i>	<i>Buccal br. of facial nerve</i>	<i>Depressor of upper lip and planum nasolabiale</i>	<i>Lies ventral to caninus</i>
Depressor labii inferioris (37.25)	<i>Caudal alveolar border of mandible</i>	<i>Lower lip</i>	Buccal br. of facial nerve	Depressor and retractor of lower lip	

MUSCLES OF THE EYELIDS AND NOSE (p. 36)

Orbicularis oculi (37.4)	The muscular ring around the eye in the eyelids		Auriculopalpebral n. from facial n.	Narrowing and closure of the palpebral fissure	
Levator nasolabialis (37.5)	Frontal bone	<i>Deep part on nasal proc. of incisive bone and lat. nasal cartilages; supf. part between nostril and upper lip</i>	Auriculopalpebral n. from facial n.	Levator of upper lip, dilator of nostril	Broad and thin; levator labii superioris and caninus pass between supf. and deep parts
Malaris (37.20)	Lacrimal bone and parotidomasseteric fascia	Cheek; orbicularis oculi near medial angle of eye	Buccal br. of facial n.	Levator of the cheek	Can be divided into rostral and caudal parts
Frontalis (37.1)	<i>Base of horn and intercornual protuberance</i>	<i>Upper eyelid and frontal region</i>	<i>Auriculopalpebral n. from facial n.</i>	<i>Levator of upper eyelid and medial angle of eye</i>	<i>Much reduced in other domestic mammals</i>

The retractor anguli oculi lat. is absent and the levator anguli oculi med. is replaced in the ox by the frontalis.

MUSCLES INNERVATED BY THE MANDIBULAR NERVE (p. 38)

SUPERFICIAL MUSCLES OF THE INTERMANDIBULAR REGION

Digastricus (39.31)	Tendinous on paracondylar process	<i>Medially on vent. border of mandible rostral to vascular groove</i>	Caud. belly: digastric br. of facial n.; rostral belly: mylohyoid n. from mandib. n.	Opens the mouth	Two bellies not distinctly divided; connected to contralat. m. by fibers on lingual proc. of hyoid bone
Mylohyoideus (39.25)	<i>Rostral part from angle of chin to first cheek tooth; caud. part from 3rd to beyond last cheek tooth</i>	Lingual proc. of hyoid bone	Mylohyoid n. from mandib. nerve	Raises the floor of the mouth and elevates the tongue against the palate	The two parts have different fiber directions

LATERAL MUSCLES OF MASTICATION

Temporalis (39.17)	Temporal fossa	Coronoid proc. of mandible	Deep temporal nn. from masticatory n. from mandibular n.	Masticatory m.: raises and presses mandible to maxilla, closing the mouth	Relatively poorly developed
Masseter (39.13)			Masseteric n. from masticatory n. from mandibular n.	Masticatory m.: raises and presses mandible to maxilla; closes the mouth; unilat. contraction pulls mandible laterally	Very tendinous
Supf. Part	<i>Facial tuber</i>	Angle and caud. border of mandible			
Deep part	<i>Facial crest; zygomatic arch</i>	Lat. surface of ramus of mandible			

MEDIAL MUSCLES OF MASTICATION

Pterygoideus (39.22)	Pterygoid bone and surroundings	Pterygoid fossa medial on ramus of mandible; condylar proc. of mandible	Pterygoid nn. from mandibular n.	Synergists of masseter; unilateral contraction pulls mandible laterally	Br. of mandibular n. pass between pterygoid mm.
—medialis					
—lateralis					

MUSCLE / FIG.	ORIGIN	TERMINATION	INNERVATION	FUNCTION	REMARKS
EYE MUSCLES: (See pp. 40, 41)					
PHARYNGEAL MUSCLES (p. 46)					
Stylopharyngeus caudalis (47.15)	Medially on prox. half of stylohyoid	<i>Mainly on thyroid cart.; dorsolat. wall of pharynx</i>	Glossopharyngeal n.	Only dilator of pharynx; elevator of larynx	
MUSCLES OF THE SOFT PALATE (p. 46)					
Tensor veli palatini (47.11)	Muscular proc. of tympanic part of temporal bone, hamulus of pterygoid bone	Tendinous on soft palate, laterally on auditory tube	Mandibular n.	Tensor of soft palate, dilator of auditory tube	
Levator veli palatini (47.12)	Muscular proc. of tympanic part of temporal bone; laterally on auditory tube	Soft palate	Pharyngeal plexus (IX, X)	Levator of soft palate	
Palatinus	Choanal border of palatine bones	Soft palate	Pharyngeal plexus (IX, X)	Shortens the soft palate	<i>A small strand of muscle (m. uvulae) is present near the palatine arch</i>
ROSTRAL PHARYNGEAL CONSTRICTORS (p. 46)					
<i>Stylopharyngeus rostralis</i>	<i>Mediodistal half of stylohyoid</i>	<i>Pharyngeal raphe</i>	<i>Pharyngeal plexus (IX, X)</i>	<i>Constrictor of pharynx</i>	<i>Regularly present</i>
Pterygopharyngeus (47.13)	Pterygoid bone and palatine aponeurosis	Pharyngeal raphe	Pharyngeal plexus (IX, X)	Constrictor and protractor of pharynx	
MIDDLE PHARYNGEAL CONSTRICTOR (p. 46)					
Hyopharyngeus (47.16)	<i>Thyrohyoid, ceratohyoid, and stylohyoid</i>	Pharyngeal raphe	Pharyngeal plexus (IX, X)	Constrictor of pharynx	
CAUDAL PHARYNGEAL CONSTRICTORS (p. 46)					
Thyropharyngeus (47.17)	Thyroid cartilage	Pharyngeal raphe	Pharyngeal plexus (IX, X)	Constrictor of pharynx	
Cricopharyngeus (47.18)	Cricoid cartilage	Pharyngeal raphe	Pharyngeal plexus (IX, X)	Constrictor of pharynx	
LARYNGEAL MUSCLES (Intrinsic muscles of the larynx, p. 46)					
Cricothyroideus	Ventrolaterally on cricoid arch	Caudally on thyroid cartilage	Cran. laryngeal n. (X)	Narrows rima glottidis, tenses vocal cords	
Cricoarytenoideus dorsalis (47.9)	Dorsolaterally on cricoid lamina	Muscular proc. of arytenoid cartilage	Caud. laryngeal n. (X)	Widens rima glottidis	
Cricoarytenoideus lateralis (47.7)	Cranio-laterally on cricoid arch	Muscular proc. of arytenoid cartilage	Caud. laryngeal n. (X)	Narrows rima glottidis	
Arytenoideus transversus (47.6)	Arcuate crest rostral to both arytenoid cartilages	Muscular procc. of arytenoid cartilage	Caud. laryngeal n. (X)	Narrows cartilaginous rima glottidis	Unpaired muscle with a dorsomedian raphe
Thyroarytenoideus (47.8)	<i>Thyroid cart., base of epiglottis, cricothyroid lig.</i>	<i>Muscular and vocal procc. of arytenoid cartilage</i>	<i>Caud. Laryngeal n. (X)</i>	<i>Narrows rima glottidis</i>	<i>Not divided into ventricularis and vocalis</i>
MUSCLES OF THE TONGUE AND HYOID (radiate from the basihyoid into the tongue, p. 45)					
Lingualis proprius (45.1)	Intrinsic muscle of tongue		Hypoglossal n.	Changes shape of tongue	Longitudinal, transverse, and perpendicular fibers

MUSCLE / FIG.	ORIGIN	TERMINATION	INNERVATION	FUNCTION	REMARKS
EXTRINSIC MUSCLES OF TONGUE (pp. 45, 47)					
Styloglossus (47.n)	Stylohyoid	Apex of tongue (streaming in from each side)	Hypoglossal n.	Draws tongue caudodorsally; Unilat. contraction draws it lat.	
Hyoglossus (47.n)	Basihyoid, lingual proc., thyrohyoid	Tongue, dorso-median to apex	Hypoglossal n.	Draws tongue caudoventrally	
Genioglossus	Medially on mandible in angle of chin	Tongue, back to hyoid bone	Hypoglossal n.	Draws tongue rostroventrally	Lingual septum divides right and left mm.
MUSCLES OF HYOID APPARATUS					
M. geniohyoideus	Incisive part of mandible	Lingual process of basihyoid	Hypoglossal n.	Draws hyoid apparatus (and tongue) rostrally	
M. thyrohyoideus	Thyroid cartilage	Thyrohyoid bone	Hypoglossal n.	Draws larynx and thyrohyoid toward each other	
Mylohyoideus (See Superficial muscles of the intermandibular region, pp. 38, 39, 104)					
Styhlohyoideus	Tendinous, from angle of stylohyoid	Fleshy on thyrohyoid	Facial n.	Draws hyoid bone and larynx caudodorsally	The termination is not perforated by digastricus
Occipitohyoideus	Paracondylar process	Caudodorsal end of stylohyoid	Facial n.	Lowers root of tongue and larynx	
Hyoideus transversus	Ceratohyoid	On median raphe, joined to contralateral muscle	Glossopharyngeal n.	Levator of root of tongue	
Ceratohyoideus	Ceratohyoid, epihyoid, and vent. end of stylohyoid	Thyrohyoid	Glossopharyngeal n.	Raises thyrohyoid, drawing larynx rostradorsally	Fills triangle between cerato- and thyrohyoid
Hyoepiglotticus (45.o)	Basihyoid	Rostral surface of base of epiglottis	Hypoglossal n.	Draws epiglottis rostroventrally	
LONG HYOID MUSCLES (p. 60)					
Sternothyroideus (61.15)	Manubrium sterni	Laterally on thyroid cartilage	Medial br. of vent. br. of C1	Synergist of sternohyoideus and retracts thyroid cart.	Sternothyroideus and -hyoideus have no tendinous intersection, unlike the horse, but are joined in the middle of the neck
Sternohyoideus (61.14)	Manubrium sterni	Basihyoid	Medial br. of vent. br. of C1	Retractor of hyoid bone and tongue	
Omohyoideus (61.13)	<i>Indirectly by deep cervical fascia from 3rd (4th) cervical vertebra</i>	Basihyoid	Medial br. of vent. br. of C1	Synergist of sternohyoideus	Thin in the ox; fused with sternohyoideus deep to mandibular gland
CUTANEUS MUSCLES (pp. 37, 60, 66)					
Platysma:					
Cutaneus faciei (37.A)	From supf. fascia of laryngeal region	Angle of mouth	Auriculopalpebral n. (VII)	Tenses and moves skin of face; retracts angle of mouth	
Cutaneus colli	Ventrally on supf. fascia of the neck	Directed cranially to skin	Auriculopalpebral n. (VII)	Tenses and moves skin of ventral neck	Thin and often not demonstrable in the ox

MUSCLE / FIG.	ORIGIN	TERMINATION	INNERVATION	FUNCTION	REMARKS
Cutaneus trunci	Supf. fascia of trunk and thigh on a line from withers to fold of flank; minor tubercle of humerus	Skin over ribs, hypochondrium, and lower flank	Lat. thoracic n.	Tenses and moves skin of the trunk	Joined to omo-brachialis; becomes aponeurotic along a line from fold of flank to dorsal third of last rib. Vent. border covers milk vein
Cutaneus omobrachialis	Supf. fascia of scapular and brachial regions	Skin of scapular and brachial regions	Lat. thoracic n.	Tenses and moves skin of scapular and brachial regions	Thin; partly without connection to cutaneus trunci
Preputialis cranialis	Xiphoid proc. with a portion from ventral border of cutaneus trunci	On the prepuce	Vent. brr. of last thoracic and 1st lumbar nn.	Protractor of the prepuce	Paired; forms with contralat. m. a loop around caud. border of preputial orifice
Preputialis caudalis (80 text fig.)	Fascia lateral and medial to vaginal tunic	On the internal lamina of the prepuce	Vent. brr. of last thoracic and 1st lumbar nn.	Retractor of internal lamina of prepuce	Paired; absent in polled breeds

VERTEBRAL COLUMN MUSCULATURE:

(A) Dorsal (epaxial) vertebral column muscles: (pp. 61, 63, 87)

Splenius (61.k)	<i>Spinous procc. of T1-T3 (4); thoraco-lumbar fascia</i>		Dorsal brr. of corresponding spinal nn.	Extension, elevation, and lat. flexion of head and neck	
—capitis		<i>Dorsolat. on occipital bone</i>			
—cervicis		<i>Wing of atlas and transverse proc. of axis</i>			
Iliocostalis				Fixation of loin and ribs; extends vert. column and bends it laterally; assists in expiration	
—cervicis (61.o)	Ends as continuation of iliocostalis thoracis on transverse process of C7		Dorsal brr. of corresponding spinal nn.		
—thoracis (61.o')	<i>Transv. proc. of L1-L4, mainly on L3.</i>	Angles of ribs and transverse procc. of thoracic vertebrae	Dors. brr. of corresponding spinal nn.		M. fiber bundles cross over up to 7 ribs
—lumborum (61.o'')	<i>Tendinous from iliac crest</i>	<i>Caud. border of last rib</i>	<i>Dors. brr. of corresponding spinal nn.</i>		
M. longissimus			Dors. brr. of corresponding spinal nn.	Fixation and extension of vert. column; raises cranial part of trunk; raises neck and head; unilat. contraction bends neck	
—atlantis et capitis (61.n)	Artic. procc. of C3-T2	Wing of atlas, mastoid proc. of temporal bone, temporal line			
—cervicis (61.n')	Transv. procc. of first 6-7 thor. vertt.	Transv. procc. of last 4 cervical vertebrae			
—thoracis (61.n'')	Spinous procc. of last thor. vertt.	Transv. procc. of C7 (6);			A short thin tongue of gluteus medius lies on the longissimus lumborum
—lumborum (61.n''')	lumbar, and sacral vertt.; iliac crest, and tuber coxae	vert. ends of ribs; transv. procc. of thor. and lumbar vertt.; artic. and mamillary procc. of lumbar vertebrae			
Semispinalis capitis (61.l)	Transv. procc. of T1-T8 (9); artic. procc. of C3-C7; lig. nuchae	Occipital bone; laterally on lig. nuchae	Dorsal brr. of corresponding spinal nerves	Lifting and lat. bending of head and neck. Has great active role in the horn thrust	Thicker dorsomed. biventer cervicis can be distinguished from thinner, ventrolateral, purely fleshy complexus

MUSCLE / FIG.	ORIGIN	TERMINATION	INNERVATION	FUNCTION	REMARKS
Spinalis et semispinalis thoracis et cervicis (61.m)	Spinous procc. of L1 and T (10) 11–T13; supraspinous lig.; transv. procc. of T9–T12 (<i>semispinalis part</i>); spinous proc. of T1	Spinous procc. of T1–T6 and C4–C7	Dorsal br. of corresponding spinal nerves	Fixation of back and neck; raising and lat. bending of neck; synergist of <i>longissimus</i>	Fleshy <i>semispinalis part</i> is present; it lies on <i>longissimus thoracis</i> from T5–T13 like a cap
Multifidus		Spinous procc. of the more cran. vertebrae, including axis	Dorsal br. of corresponding spinal nerves	Fixes and rotates vert. column; raises neck and bends it laterally	The fiber bundles cross over as many as 5 vertebrae
—cervicis	Artic. procc. of C(3) 4–C7				
—thoracis	Transv. prod. of T1; mamillary and artic. procc. of last thoracic and lumbar vertt.				
—lumborum	Sacrum; Cd1	L5 and L6			
Interspinales: <i>In the ox they are muscular only in the neck. In thoracic and lumbar regions they are replaced by interspinal ligaments.</i>					
Intertransversarii (87.h)	Artic. procc. of C3–C7 and cran. artic. proc. of T1; transv. procc. of all lumbar and caud. vertebrae	Transv. procc. of C2–C7; transverse procc. and costal tubercles of preceding segments; lumbar segments end on prox. end of last rib; caud. segments on caud. transv. processes	Dorsal and ventral br. of corresponding spinal nn.	Fixation and lateral bending of vertebral column	<i>Ventrolat. bundles in neck form intertransversarius longus cervicis, dorsolat. to longus capitis and ending on wing of atlas</i>
Sacrocaudalis [—coccygeus] dorsalis medialis (87.e)	Between spinous and mamillary procc. of 2–3 last sacral and first caudal vertebrae		Dorsal br. of corresponding spinal nerves	Raises tail and bends it laterally	Considered the caudal continuation of the multifidus
Sacrocaudalis [—coccygeus] dorsalis lateralis (87.f)	Laterally on the sacrum and transv. procc. of 1st caudal vertebrae	Tendinous on 5th to last caud. vertebrae	Dorsal br. of corresponding spinal nerves	Raises tail and bends it laterally	Caudal continuation of <i>longissimus</i>
B) Ventral vertebral column muscles (pp. 47, 61, 87)					
Scaleni			Ventral br. of spinal nn.		
Scalenus dorsalis (61.p)	Ribs (2) 3–4	Transv. procc. of C4–C6		When neck is fixed, levator of first ribs; when ribs are fixed, draws neck ventrally or bends it laterally	More supf. than dorsal; absent in horse
Scalenus medius	Cran. border of first rib	Transv. procc. of C4–C7		Draws neck laterally	Dorsal to brachial plexus
Scalenus ventralis (61.p')	Cran. border of first rib	Transv. procc. of C3–C7		Bends neck laterally	Ventral to brachial plexus; is very robust
Longus capitis (61.h)	Transv. procc. of C2–C6	Muscular tubercle on base of skull	Ventral br. of spinal nn.	Flexes head and neck and bends them laterally	Thin triangular muscle
Longus colli	Cervical part: transv. procc. and bodies of C3–C7. Thoracic part: bodies and transv. procc. of C6–C7; bodies of T1–T6	Ventral crest of more cran. vertebrae and vent. tubercle of atlas	Ventral br. of spinal nn.	Flexor of the neck	Relatively thick; fiber bundles often cross over one segment

MUSCLE / FIG.	ORIGIN	TERMINATION	INNERVATION	FUNCTION	REMARKS
Sacrocaudalis [—coccygeus] ventralis			Ventral br. of spinal nn.	Draws tail ventrally; unilateral action draws tail lat.	
—medialis (95.l)	Last sacral segment to end of tail (ventral on caud. vertebrae)	Second following hemal proc.			Connected with terminal tendons of sacrocaudalis vent. lateralis
—lateralis (95.k)	Ventrally from S2–S3; transv. procc. of 1st caud. vertebrae	Ventrolat. on caudal vertebrae			Thicker than the med. muscle
Rectus capitis ventralis	Ventral arch of atlas	Base of skull, caud. to longus capitis	Ventral br. of 1st spinal n.	Flexor of the atlanto-occipital joint	More robust than in other domestic animals
Rectus capitis lateralis	Ventral arch and vent. surf. of wing of atlas	Paracondylar process	Ventral br. of 1st spinal n.	Flexor of the atlanto-occipital joint; rotates head	Relatively weak and covered by rectus capitis ventralis
C) DORSAL MUSCLES ACTING ON THE HEAD					
Rectus capitis dorsalis major	Spinous process of axis	Occipital bone, medial to obliquus cap. cran.	Dorsal br. of C1	Levator of the head	
Rectus capitis dorsalis minor	Dorsal arch of atlas	Occipital bone dorsal to foramen magnum	Dorsal br. of C1	Levator of the head	More robust than in carnivores
Obliquus capitis cranialis	Cran. border of wing of atlas and atlantal fossa	Occipital squama, base of jugular proc.	Dorsal br. of C1	Extensor and rotator of head	
Obliquus capitis caudalis	Spinous process and cd. artic. proc. of axis	Cran. border of wing of atlas	Dorsal br. of C2	Rotator of atlas around dens of axis	Very robust
DORSAL TRUNK-LIMB MUSCLES (p. 60)					
Trapezius	<i>Dorsally on funiculus nuchae and supra-spinous lig. from C1–T12</i>	Spine of scapula	Dorsal br. of accessory n.	Fixation of scapula, protractor and abductor of limb	Well developed; cervical and thoracic parts separated by tendinous strip on scapular spine
Pars cervicalis (61.11) Pars thoracica (61.11')					
Omotransversarius (61.8)	Acromion; brachial fascia	Wing of atlas (partly also transverse proc. of axis)	Medial br. of vent. br. of cervical nn.	Protractor of limb and lat. flexor of neck	Supf. cervical ln. lies deep to omotransversarius and cleido-brachialis
Rhomboideus	<i>Dorsomedian on funiculus nuchae and supraspinous lig. from C2–T8</i>	<i>Medially on scapular cartilage</i>		Fixes, raises, and retracts the limb; raises neck	The rhomboideus capitis is absent as in the horse
—cervicis (61.28) —thoracis (61.28')			Med. br. of vent. br. of cervical nn. of thoracic nn.		
Latissimus dorsi (61.12)	Thoracolumbar fascia; ribs 11 and 12	<i>Teres major tuberosity and deep pectoral, coracobrachialis, and long head of triceps</i>	Thoracodorsal nerve	Retractor of limb, flexor of shoulder joint, protractor of trunk when limb is fixed	Relatively thin; course over the caud. angle of scapula fixes scapula on thoracic wall
VENTRAL TRUNK-LIMB MUSCLES (p. 60)					
Pectorales superficiales			Cran. and caud. pectoral nerves	Connect limb to trunk; adductors, protractors, and retractors of limb	Thinner than in horse; the two muscles are less distinct
Pectoralis transversus (61.25')	1st to 6th costal cartilage; ventrally on sternum	Antebrachial fascia, humerus			
Pectoralis descendens (61.25)	Manubrium sterni	Crest of major tubercle of humerus and brachial fascia			

MUSCLE / FIG.	ORIGIN	TERMINATION	INNERVATION	FUNCTION	REMARKS
Pectoralis profundus [Pectoralis ascendens] (61.26)	<i>Sternum from 2nd rib caudally and sternal costal cartilages; tunica flava</i>	Major and minor tubercles of humerus; <i>coracoid proc. of scapula</i>	Cran. and caud. pectoral nerves	Supports trunk; retracts limb; fixes shoulder joint	Unified; no accessory part like that of the dog; gives a flat muscular strap to the supraspinatus
Subclavius (61.26')	<i>Cartilage of 1st rib</i>	Clavicular intersection on deep surface of brachiocephalicus	Cran. pectoral nerves		Rudimentary
Serratus ventralis				Most important supporter of trunk, raises neck when limb is fixed, auxiliary inspiratory muscle	The parts are distinctly divided
—cervicis (61.27)	<i>Transverse procc. of C(3)4–C7</i>	<i>Cranially on facies serrata of scapula</i>	Med. br. of vent. br. of cervical nn.		
—thoracis (61.27')	<i>Ribs 1 to 7, 8, or 9</i>	<i>Caudally on facies serrata; subscapular fossa</i>	Long thoracic nerve		Digitations of origin markedly tendinous
Sternomandibularis (61.5)	Manubrium sterni and 1st rib	Rostral border of masseter, mandible, and depressor labii inferioris	Ventral br. of accessory n.	Opens mouth; fixes mandible and pharynx in swallowing	Courses ventral to jugular groove as a thick muscular cord
Sternomastoideus (61.4)	<i>Manubrium sterni</i>	<i>Mastoid proc. of temporal bone; with cleidomastoideus and longus capitis, on muscular tubercle of occipital bone</i>	<i>Ventral br. of accessory n.</i>	<i>Fixes and draws head and neck ventrally</i>	<i>Flat band lat. to trachea; in upper half of neck separates ext. jugular v. from com. carotid a. With sternomandibularis, makes up sternocephalicus</i>
Cleidomastoideus (61.6)	Clavicular intersection	Mastoid proc. of temporal bone; and, with <i>sternomastoideus</i> and <i>longus capitis</i> , on muscular tubercle of occipital bone	Ventral br. of accessory n.	Protractor of limb; draws head ventrally or laterally	Joins cleidooccipitalis in the middle of neck to form cleidocephalicus which joins the cleidobrachialis (p. 4)
Cleido-occipitalis (61.7)	<i>Clavicular intersection</i>	<i>Funiculus nuchae and occipital bone</i>	<i>Dorsal br. of accessory n.</i>	<i>Protractor of limb, raises head</i>	<i>Adjoins cranial border of trapezius</i>
EXPIRATORY MUSCLES (pp. 61, 63, 67) Compress thorax by drawing ribs mediocaudally					
Serratus dorsalis caudalis (61.r')	Thoracolumbar fascia	Caud. border of ribs 10–13	Intercostal nerves	Expirator	Interdigitates with ext. abd. obl. and ext. intercostal mm.
Intercostales interni (67.d)	Fiber bundles run cranioventrally in intercostal spaces		Intercostal nerves	Expirators	
Retractor costae	<i>Transverse processes of L1–L3</i>	Caud. border of last rib	Intercostal nerves	Expirator	
Transversus thoracis (63.v)	<i>Costal cartilages 2–7</i>	<i>Sternebrae 2–7; 8th costal cartilage</i>	Intercostal nerves	Expirator	Right and left halves separated on median line
INSPIRATORY MUSCLES (pp. 61, 63, 67) Expand thorax by drawing ribs craniolaterally					
Serratus dorsalis cranialis (61.r)	Supraspinous ligament	<i>Cran. border of ribs 5–9</i>	Intercostal nerves	Inspirator	Weak
Rectus thoracis (67.c)	First rib	Costal cartilages 2–4 (6)	Intercostal nerves	Inspirator	

MUSCLE / FIG.	ORIGIN	TERMINATION	INNERVATION	FUNCTION	REMARKS
Intercostales externi (61.e)	Fiber bundles run caudoventrally in intercostal spaces		Intercostal nerves	Inspirators	Very tendinous fiber tracts; pass into ext. abd. obl. near the last ribs
Levatores costarum	<i>Transverse and mamillary procc. of T1–T12</i>	<i>Cran. border of next rib</i>	Dorsal brr. of thoracic nn.	Inspirators	10–12 muscles; same fiber direction as ext. intercostals
Diaphragm (63.2–63.5)			Phrenic n.	Inspirator; main respiratory muscle	
Costal part (63.3)	From knee of 8th rib, across the middle of 11th to ventral end of 12th rib	Tendinous center			More steeply inclined than in other dom. Mammals
Sternal part	Xiphoid process	Tendinous center			Clearly divided from the costal part
Lumbar part (63.2)	Ventral surfaces of L1–3 (4)	Tendinous center			Forms right and left crura of diaphragm
<i>The subcostales are not present in the ox.</i>					
ABDOMINAL MUSCLES (p. 66)					
External abdominal oblique (67.2)	Costal part: ribs (4) 5–13 <i>along vent. border of latissimus dorsi.</i> Lumbar part: last rib, thoracolumbar fascia	Abdominal tendon: linea alba and prepubic tendon. Pelvic tendon: tuber coxae, inguinal lig., and prepubic tendon	Vent. brr. of corresponding intercostal and lumbar nn.	As a whole: contractile sling adaptable to weight and volume of abd. organs; reinforced by strong tunica flava of abdomen	<i>Inguinal canal:</i> abd. and pelvic tendons bound ext. ing. ring; pelvic tend. is caud. border of deep ring <i>Sheath of rectus: abdominal tendon is in ext. lamina</i>
Internal abdominal oblique (67.10)	<i>Thoracolumbar fascia; transverse procc. of lumbar vertebrae, tuber coxae, inguinal ligament</i>	Linea alba and last rib	Vent. brr. of corresponding intercostal and lumbar nn.	Abd. press in urination, defecation, and parturition, with inspiratory position of diaphragm fixed by closed glottis. Flexion of vert. column by rectus abdominis. Auxillary exspirators; <i>straight strapping:</i> rectus and transversus; <i>oblique strapping:</i> ext. and int. abd. obl.	<i>Inguinal canal:</i> cran. border of deep ring; <i>Sheath of rectus:</i> aponeurosis is <i>only</i> in ext. lamina. Costochondral crus is caudovent. border of paralumbar fossa <i>Sheath of rectus: int. lamina is formed by transversus alone</i>
Transversus abdominis (67.7)	Costal part: <i>last 7–8 costal cartilages;</i> Lumbar part: transverse process of lumbar vertebrae	Linea alba	Vent. brr. of corresponding intercostal and lumbar nn.		
Rectus abdominis (67.6)	Fourth to ninth costal cartilages	Prepubic tendon, <i>symphyseal tendon and symphyseal crest</i>	Vent. brr. of corresponding intercostal and lumbar nn.		Has 5 tendinous intersections; near the 2nd is the “milk well” where the subcutaneous abd. v. perforates the abd. wall to int. thoracic v.
INTERNAL LUMBAR MUSCLES (p. 81)					
Quadratus lumborum (81.g)	Proximoventral on last rib; <i>T10–T13</i> and transv. procc. of lumbar vertebrae	Ventrally on wing of sacrum	Vent. brr. of intercostal and lumbar nn.; lumbar plexus	Stiffens lumbar vert. column and arches it dorsally	All 4 internal lumbar mm. show about the same relations as in horse; very tendinous

MUSCLE / FIG.	ORIGIN	TERMINATION	INNERVATION	FUNCTION	REMARKS
Psoas major (81.e)	Fleshy on cran. border of last rib; body and transverse processes of all lumbar vertebrae	The iliacus and psoas major end together as the iliopsoas on minor trochanter of femur	Vent. brr. of intercostal and lumbar nn.; lumbar plexus	Protractor of pelvic limb; flexor and supinator of hip joint; stabilizer of vertebral column when limb is fixed	The iliopsoas and psoas minor form the tenderloin (filet)
Iliacus (81.f)	<i>Ventrally from body of L6</i> ; ventral surface of wing of ilium; wing of sacrum; tendon of psoas minor				
Psoas minor (81.d)	T12–T13, L1, and crura of diaphragm	Psoas minor tubercle of ilium	Vent. brr. of intercostal and lumbar nn.; lumbar plexus	Rotates pelvis forward at sacroiliac joint when vert. col. is fixed; stabilizes and arches lumbar vertebral column when pelvis is fixed	Strong tendon at termination
PERINEAL MUSCLES (p. 94)					
Pelvic diaphragm:					
Levator ani (95.3)	Spine of ischichium and med. surface of sacrosclatic lig.	External anal sphincter, caudal fascia	Pudendal and caud. rectal nn. from vent. brr. of sacral nerves	Holds anus against contraction of rectum; aids coccygeus	
Coccygeus (95.2)	Spine of ischium and medial surface of sacrosclatic lig.	Transv. procc. of first 3 caud. vertebrae	Pudendal and caud. rectal nn. from vent. brr. of sacral nerves	Unilat. contr. draws tail laterally; bilat. contr. draws tail ventrally	
Muscles of anal region					
External anal sphincter (95.12)	Fiber bundles completely encircle anus, cross ventral to anus in perineal body, and continue in constrictor vulvae		Pudendal and caud. rectal nn. from vent. brr. of sacral nerves	Closes the anus	Voluntary striated muscle
Internal anal sphincter	Thickened annular muscle layer of rectum		Caud. rectal nn.	Closes the anus	Involuntary smooth muscle
Rectococcygeus (95.11)	Continuation of dorsal longitudinal muscle of rectum	<i>Ventromedian on caudal vertebrae 1–3</i>	Caud. rectal nn. from vent. brr. of sacral nn.	Supports and stabilizes anal canal and rectum	Smooth muscle. Ventral fibers of rectum cross in the perineal body and enter the labia and vestibule
Urogenital muscles (bull, p. 92; cow, p. 87)					
Bulbospongiosus (93.6)	Continuation of urethralis caud. to urogenital membrane; median dorsal raphe	Tunica albuginea on sides of bulb of penis	Deep perineal n. from pudendal n. (S2–S4)	Forces the flow of urine, semen, and blood	Very thick; ca. 17 cm long from bulbourethral gll. to junction of crura penis
Constrictor vestibuli (87.m)	Vent. border of levator ani and fascia on levator	Tendons of rt. and left muscles join vent. to vestibule	Pudendal and caud. rectal nn. from vent. brr. of sacral nerves	Narrows the vestibule of the vagina	Bilateral, embracing the vestibule
Constrictor vulvae (87.n)	External anal sphincter in perineal body	Subcut. in labia; fascia of semimembranosus	Caud. rectal nn. from vent. brr. of S4–S5	Constricts vulva	Striated muscle of labia vulvae
Retractor penis (93.8)	Caud. vertebrae 1 and 2; rectum, ext. anal sphincter, levator ani	1. distal bend of sigmoid flexure 2. on tunica albuginea 15–20 cm. prox. to glans	Deep perineal n. and dorsal n. of penis from pudendal n.; caud. rectal n. from vent. brr. of sacral nerves	Retracts penis by folding sigmoid flexure	Smooth muscle, paired
Retractor clitoridis (87.o)	Caud. vertebrae 2 and 3 or 3 and 4; rectum, ext. anal sphincter, levator ani	Body of clitoris, vestibule, fascia of semimembranosus	Pudendal and caud. rectal nn. from vent. brr. of sacral nn.	Retracts clitoris	Smooth muscle, paired
Ischiocavernosus (93.7)	Medial surface of tuber ischiadicum	Body of penis or clitoris at junction of crura	Deep perineal n. from pudendal n. (vent. brr. of S2–S4)	Rhythmic pumping of blood into corpus cavernosum in erection	Broad, paired muscle covering crura; rudimentary in the cow

2. LYMPHATIC SYSTEM

LYMPHOCENTER LYMPH NODE	LOCATION	AFFERENTS FROM	EFFERENTS TO	REMARKS
PAROTID LYMPHOCENTER (p. 38)				
Parotid ln. (39.12)	Ventrolat. to temporomandib. jt.; between rostral border of parotid gl. and masseter	Skin and mm. of whole dors. part of head, skull bones, parotid gl.; ext. ear, eyelids, lacrimal app., rostral half of nasal cavity, hard palate, chin	Lat. retropharyngeal ln.	6–9 cm long. Regularly incised in meat inspection
MANDIBULAR LYMPHOCENTER (P. 38)				
Mandibular ln. (39.10)	Ventr. to mandible midway between rostr. border of masseter and angle of mandible; covered by sternomandibularis	Skin of head, facial and masticatory mm., rostr. nasal cavity, oral and nasal mucosa, paranasal sinuses, tongue mm., pharynx, larynx, salivary gl.	Lat. retropharyngeal ln.	3–4.5 cm long, palpable. Regularly incised in meat inspection
Pterygoid ln.	On rostral border of ramus of mandible; med. to med. pterygoid m.	Hard palate	Mandibular ln.	Inconstant
RETROPHARYNGEAL LYMPHOCENTER (p. 38)				
Lat. retropharyngeal ln. (39.11)	Under the wing of atlas; covered by dorsal end of mandib. gland	Skin of head-neck union, lips, salivary gll., buccal mucosa, mandib. mucosa in diastema, masticatory mm., tongue and parts of hyoid mm., mandible, part of thymus, nearby neck mm., ear mm.	The efferents join to form tracheal trunk	4–5 cm long, smooth, oval; palpable if enlarged; may be associated with 1–3 small ln. Regularly incised in meat inspection
Med. retropharyngeal ln. (49.a)	Between caudodors. wall of pharynx and longus capitis; med. to stylohyoideus	Tongue, hyoid mm., oral mucosa, palate, tonsils, maxillary and palatine sinuses, mandible, caudal half of nasal cavity, larynx and pharynx, mandibular and sublingual gll., longus capitis	Lat. retropharyngeal ln.	3–6 cm long, oval, surrounded by fat; rarely double; palpable from pharynx. Regularly incised in meat inspection
Rostral hyoid ln.	Lat. to thyrohyoid	Apex of tongue	Lat. and med. retropharyngeal lnn.	Inconstant; 1–1.5 cm in diameter
Caud. hyoid ln.	Lat. to angle of stylohyoid	Mandible	Lat. retropharyngeal ln.	Inconstant; 1–1.5 cm in diameter
SUPERFICIAL CERVICAL LYMPHOCENTER (p. 60)				
Supf. cervical ln. (61.9 and 67.a)	In the groove cranial to supraspinatus above shoulder jt., covered by omotransversarius and cleido-occipitalis	Skin of neck, thoracic limb, thoracic wall back to level of 12th rib. Shoulder girdle mm. and mm. dors. to scapula, antebrachial fasciae, manus	Left side: thoracic duct or left tracheal trunk. Rt. side: tracheal trunk	7–9 cm long, 1–2 cm thick, palpable; Examined in suspected cases in meat inspection
DEEP CERVICAL LYMPHOCENTER (p. 60)				
Deep cervical lnn.:				To be considered in suspected cases in meat inspection. 4–6 lnn., 1–2.5 cm each; rarely absent
Cran. deep cerv. lnn. (61.22)	From thyroid gl. to 7th tracheal ring	Ventr. cervical mm., flexors of neck, thyroid gl., larynx and pharynx, cervical trachea and esophagus, cervical thymus	Left side: thoracic duct or end of tracheal trunk, may go directly to angle between bijugular trunk and subclavian v. Right side: caud. part of right tracheal trunk	1–7 lnn., 0.5–3 cm long
Middle deep cerv. lnn. (61.23)	In the middle 1/3 of neck, on the right of the trachea and on the left of esophagus			
Caud. deep cerv. lnn. (61.24)	On the trachea just cran. to the 1st rib			2–4 separate lnn.

LYMPHOCENTER LYMPH NODE	LOCATION	AFFERENTS FROM	EFFERENTS TO	REMARKS
Costocervical ln.	Cran. to costocerv. trunk craniomed. to 1st rib	Supraspinatus, infraspinatus, dors. shoulder girdle mm. extensors of neck and back, flexors of neck, omohyoideus, pleura, trachea	Left side: thoracic duct and caud. deep cerv. lnn. or cran. mediastinal lnn. or angle between bijugular tr. and subclavian v. Right side: rt. tracheal trunk or vas efferens of supf. cerv. ln.	1.5–3 cm long, often merged with caud. deep cerv. lnn. Adjoins common carotid a. ventrally, esophagus and trachea medially. To be considered in suspected cases in meat inspection
AXILLARY LYMPHOCENTER (p. 6)				
Proper axillary ln.	6–10 cm caud. to shoulder jt. at level of 2nd intercostal space, med. to teres major	Mm. of shoulder and brachium, parts of shoulder girdle mm., cutaneous omobrachialis, bones of thoracic limb down to the carpus	Axillary lnn. of 1st rib, caud. deep cervical lnn.	2.5–3.5 cm long single ln. To be considered in suspected cases in meat inspection
Axillary lnn. of 1st rib	On the lat. surface of the rib and 1st intercostal space; covered by the lat. part of deep pectoral m.	Pectoral mm., transversus thoracis, serratus ventr., scalenus, shoulder and brachial mm., bones of thoracic limb down to carpus	Caud. deep cervical lnn. or on the left side to thoracic duct; on the rt. side to rt. tracheal trunk	2–3 separate lnn. To be considered in suspected cases in meat inspection
Accessory axillary ln.	At the level of the 4th rib		Proper axillary ln.	Inconstant small single ln.
Infraspinatus ln.	On the caudal border of that m., covered by the cran. border of latissimus dorsi	Latissimus dorsi	Proper axillary ln.	0.5–1 cm long; occurs very rarely
DORSAL THORACIC LYMPHOCENTER (p. 62)				
Thoracic aortic lnn. (63.11)	Dorsolat. to aorta and med. to sympathetic trunk. Right side: dorsal to thoracic duct. Left side: ventr. to left azygos v. (p. 65)	Subscapularis, shoulder girdle mm., thoracic mm. extensors of back, diaphragm, heart, possibly spleen, pleura, and peritoneum, mediastinum, ribs	Right side: thoracic duct; left side: caud. lnn. through caud. media- stinal lnn.; cran. lnn. through cran. mediastinal lnn. or directly into the angle between bijugular tr. and subclavian v.	1–3.5 cm long, number of lnn. varies. To be considered in suspected cases in meat inspection
Intercostal lnn. (63.10)	Subpleural at level of heads of the ribs, lat. to sympathetic trunk	Mm. of lat. and dorsal thoracic wall, extensors of the back, longus colli, subscapularis, ext. abd. oblique, pleura, parts of perito- neum, ribs, thoracic vertebrae	Right side: IC spaces 1–3 to cran. and middle mediastinal lnn. Left side: IC spaces 1–2 (3) to costocerv. lnn. IC spaces 3–4 to cran. mediastinal lnn. All other IC to thoracic aortic lnn.	0.4–2 cm long; 1, rarely 2 or 0 lnn. in each IC space
VENTRAL THORACIC LYMPHOCENTER (p. 62)				
Cran. sternal ln. (63.17)	Dors. to manubrium sterni, ventr. to int. thoracic a. and v. at 1st IC space	Sternum, costal cartilage, trans- versus thoracis, mm. of thoracic wall, pleura, pericardium	Caud. mediastinal lnn. or tracheal tr. or the end of thoracic duct	Usually paired, 1.5–2.5 cm long. To be considered in suspected cases in meat inspection
Caud. sternal lnn.	Ventr. to transversus thoracis along int. thoracic a. and v. other lnn. dors. to transversus thor. just cran. to attachment of diaphragm	Diaphragm, pericardium, pleura, peritoneum, ribs, sternum, mm. of thoracic wall, ventr. mm. of shoulder girdle, abd. mm., liver	Cran. sternal ln.	1–5 lnn. on both sides of median line, and 2–5 lnn. just cran. to attachment of diaphragm on sternum. To be considered in suspected inspection

LYMPHOCENTER LYMPH NODE	LOCATION	AFFERENTS FROM	EFFERENTS TO	REMARKS
MEDIASTINAL LYMPHOCENTER (p. 62)				
Cranial mediastinal lnn. (63.14)	Right and left variable in cran. mediastinum, on aortic arch, brachiocephalic tr., trachea, and esophagus	Thoracic esophagus and trachea, thymus, lungs, pericardium, heart, pleura	On the left, to thoracic duct; on the right, to the end of the right tracheal trunk	Regularly incised in meat inspection
Middle mediastinal lnn. (63.12)	On dors. and right surfaces of esophagus over the heart	Thoracic esophagus and trachea, lungs	Thoracic duct or right cran. mediastinal lnn. or a vas efferens of caud. mediastinal lnn.	2–5 lnn., each 0.5–5 cm long, visible only on the right. Regularly incised in meat inspection
Caudal mediastinal lnn. (63.13)	In caud. mediastinum; dors. to esophagus, extending to diaphragm	Lung, thoracic esophagus, pericardium, diaphragm, mediastinum, peritoneum, spleen, and liver	Thoracic duct, occasionally to left tracheobronchial ln.	A very long (15–20 cm) ln., sometimes divided; possible cause of irritation of vagal trunks. Regularly incised in meat inspection
Phrenic ln.	On thoracic side of for. venae cavae	Diaphragm, mediastinum	Caud. mediastinal lnn.	1–4 small lnn. Inconstant
BRONCHIAL LYMPHOCENTER (p. 62)				
Left tracheobronchial ln. (63.24)	Caud. to lig. arteriosum, between arch of aorta and left pulmonary a.	Thoracic esophagus, bifurcation of trachea, heart	Caud. and cran. mediastinal lnn., thoracic duct	2.5–3.5 cm long. Regularly incised in meat inspection
Right tracheobronchial ln. (63.25)	Between apical and middle lobes on lat. surface of rt. main bronchus	Lung; pulmonary lnn.	Middle mediastinal lnn.	1–3 cm long. Present in 75 % of cattle. Regularly incised in meat inspection (supervisor's node)
Middle tracheobronchial ln. (63.27)	Dorsal to the bifurcation of the trachea	Lung	Right tracheobronchial ln.	0.75–1 cm long; present in 50 % of cattle. Regularly incised in meat inspection
Cran. tracheobronchial ln. (63.21)	On right side of trachea, cran. to origin of tracheal bronchus	Lung; pulmonary lnn.	Cran. mediastinal lnn.	2–5 cm long. Regularly incised in meat inspection
Pulmonary lnn. (63.28)	Around both main bronchi, covered by lung tissue	Lung, except right apical lobe	Right and left tracheobronchial lnn., more rarely, caud. mediastinal lnn.	1 or 2 lnn., 0.5–1.5 cm in size; present in 50 % of cattle

LYMPHOCENTER LYMPH NODE	LOCATION	AFFERENTS FROM	EFFERENTS TO	REMARKS
LUMBAR LYMPHOCENTER (p. 82)				
Aortic lumbar lnn. (83.8)	Dors. and ventr. to aorta and caud. vena cava, ventr. to lumbar vertt.	Hypaxial lumbar mm., extensors of the back, thoracolumbar fascia, lumbar vertebrae, peritoneum, kidneys, adrenal gl.	Lumbar trunk	12–15 small lnn. to be considered in suspected cases in meat inspection
Proper lumbar lnn. (76.G)	Near the intervert. foramina of lumbar vertebrae	Extensors of back, (latissimus dorsi), abdominal mm.	Aortic lumbar lnn.	Separate, about 0.5 cm; on one side or bilateral or absent
Renal lnn. (83.9)	Close to renal a. and v.	Kidneys, adrenal gl.	Cysterna chyli	Not sharply distinct from aortic lumbar lnn. Regularly examined in meat inspection
CELIAC LYMPHOCENTER (p. 72, 74)				
Celiac lnn. (77.A)	On celiac a.	Spleen	Visceral trunk or directly into cisterna chyli	Cannot be sharply delimited from nearby lnn.
Splenic (or atrial) lnn. (73.E)	Between atrium ruminis and left crus of diaphragm, dorsocranial to the spleen	Spleen, rumen, reticulum; lymph from all other gastric lnn.	Variable, usually gastric trunk	1–7 lnn. Regularly examined in meat inspection
Right ruminal lnn. (73.D)	Subserous, in right longitudinal groove of rumen	Rumen	Splenic lnn. or gastric trunk	1–4 more lnn. in the cran. groove of rumen
Left ruminal lnn. (73.C)	Subserous in left longitudinal groove	Rumen	Cran. ruminal lnn., partly to right ruminal lnn.	1–2 inconstant, 1–2 cm long lnn.
Cran. ruminal lnn.	In the cran. groove of rumen	Rumen	Right ruminal lnn., splenic lnn.	2–8 lnn., 0.5–1.5 cm each
Reticular lnn. (73.F)	On the diaphragmatic and visceral surfaces of the reticulum	Reticulum	Splenic lnn., rarely directly into the gastric trunk	1–7 small, 0.5–1.5 cm lnn.
Omasal lnn.	On the visceral surface of the omasum	Omasum	Splenic lnn.	6–12 lnn., 0.5–4 cm each
Ruminoabomasal lnn. (73.B)	On the left, cranially on rumen and greater curvature of abomasum	Rumen, omasum, abomasum	Reticuloabomasal lnn. or reticular lnn.	2–7 lnn., 0.5–4 cm long
Reticuloabomasal lnn. (73.A)	On the left, between reticulum, abomasum, and atrium ruminis	Rumen, reticulum, and abomasum	Reticular lnn.	2–8 lnn., 0.5–4 cm long
Dors. abomasal lnn. (73.G)	Near the lesser curvature of abomasum	Duodenum, omasum, abomasum	Hepatic lnn.	3–6 lnn., 0.5–4 cm each
Ventr. abomasal lnn. (73.H)	Near the greater curvature of the abomasum, in the greater omentum	Duodenum, abomasum	Hepatic lnn.	1–4 lnn., inconstant
Hepatic lnn. (75.23)	Porta hepatis	Liver, pancreas, duodenum	Hepatic trunk	6–15 lnn., 1–7 cm long. Regularly incised in meat inspection
Accessory hepatic lnn. (74.29)	On dors. border of liver, near the caud. vena cava	Liver	Hepatic trunk	Several small lnn.

LYMPHOCENTER LYMPH NODE	LOCATION	AFFERENTS FROM	EFFERENTS TO	REMARKS
Pancreaticoduodenal lnn.	On visceral surf. of pancreas near portal v., between pancr. and duod., and between pancr. and transverse colon	Pancreas, duodenum, nearby parts of colon	Intestinal trunk	Varying number of small lnn. Regularly incised in meat inspection
CRANIAL MESENTERIC LYMPHOCENTER (p. 76)				
Cran. mesenteric lnn. (77.A)	At the origin of cran. mesenteric a.	Spleen	Visceral trunk or directly into cisterna chyli	Not clearly separate from celiac and nearby lnn.
Jejunal lnn. (77.E)	In the mesojejunum along the collateral br. of cran. mesenteric a., near jejunum, outside spiral colon	Jejunum, ileum	Intestinal trunk and colic lnn.	10–50 lnn., each 0.5–12 cm long. Regularly considered in meat inspection
Cecal lnn. (77.D)	In ileocecal fold	Ileum, cecum	Colic lnn. or directly to the intestinal trunk	1–3 lnn., 0.5–2 cm long, inconstant. Regularly examined in meat inspection
Colic lnn. (77.C)	1. Between limbs of the prox. loop 2. Between prox. and distal loops dorsocran. to the spiral loop 3. On the right surf. of the spiral loop	Ascending colon, ileum, cecum	Intestinal trunk	1. 1–6 lnn. 2. 1–4 lnn. 3. 7–30 lnn., only 0.5–4 cm each. Regularly considered in meat inspection
CAUDAL MESENTERIC LYMPHOCENTER (p. 76)				
Caud. Mesenteric lnn. (77.B)	On the sides of the descending colon	Descending colon	Lumbar trunk	Routinely examined in meat inspection
ILIOSACRAL LYMPHOCENTER (p. 82)				
Medial iliac lnn. (83.4)	At the termination of aorta and origin of deep circumflex iliac a.	Hip jt., hypaxial lumbar mm., pelvic and femoral mm., testis and spermatic cord; or ovary, uterine tube, uterus, bladder, kidneys, female urethra	Lumbar trunk	1–4 lnn. 0.5–5 cm long. Considered in suspected cases in meat inspection
Lat. iliac ln. (83.12)	At the bifurcation of deep circumflex iliac a. and v.	Pelvic bones, fascia lata, abd. mm., deep gluteal m., peritoneum; subiliac and coxal lnn.	Lumbar trunk, med. iliac lnn., in part iliofemoral ln.	1–2 lnn., 1.25–2.5 cm long, may be absent. Considered in suspected cases in meat inspection
Sacral lnn. (83.5)	In the angle between right and left int. iliac aa.	Iliopsoas, gluteal mm., and mm. of tail, intrapelvic urogenital organs, including their mm.	Med. iliac lnn., iliofemoral ln. or directly into lumbar trunk	A second, inconstant group lies on the internal surf. of the sacrosclatic lig. at the level of the lesser sciatic foramen
Anorectal lnn. (76.K)	On the anus and rectum	Descending colon, rectum, anus	Med. iliac lnn.	12–17 lnn. 0.5–3 cm long
ILIOFEMORAL LYMPHOCENTER (p. 20 and 82)				
Iliofemoral ln. (83.5)	In the angle between ext. iliac and deep circumflex iliac vessels	Femoral and crural mm., abd. mm., bones and joints of pelvis and pelvic limb down to the hock, intra-abdominal urogenital organs	Med. iliac lnn., lumbar trunk	3.5–9.5 cm long. Considered in suspected cases in meat inspection

LYMPHOCENTER LYMPH NODE	LOCATION	AFFERENTS FROM	EFFERENTS TO	REMARKS
SUPERFICIAL INGUINAL LYMPHOCENTER (p. 90 and 92)				
Supf. inguinal lnn.			Iliofemoral ln.	
Scrotal lnn. (93.9)	Caud. to spermatic cord, dorsolat. to penis at level of pecten pubis	Scrotum, prepuce, penis, skin of thigh, crus, and stifle		Considered in meat inspection
Mammary lnn. (91.B)	Med. to caud. border of lat. laminae of suspensory apparatus of udder	Udder, vulva, vestibule, clitoris, skin of thigh, crus, and stifle		1–3 lnn., 6–10 cm long; palpable caudally between the thighs, dorsal to the caud. quarters. Regularly examined in meat inspection
Subiliac ln. (67.5)	At cran. border of tensor fasciae latae above the level of the stifle	Skin of abd. wall, pelvis and hind limb, prepuce	Iliofemoral lnn., med. iliac lnn., in part, coxal ln.	6–11 cm long, palpable; to be considered in suspected cases in meat inspection
Coxal ln.	Med. to tensor fasciae latae at the tuber coxae	Fascia lata, quadriceps femoris	Lat. iliac ln. or med. iliac lnn.	1.5–2 cm long; inconstant
SCIATIC LYMPHOCENTER (p. 20)				
Sciatic ln. (17.B)	On the sacrosciatic lig. dors. to lesser sciatic for. or in the foramen	Skin of the pelvic region and tail, gluteal mm., hip jt., rectum, anus, urogenital organs at pelvic outlet	Sacral lnn.	2.5–3.5 cm long. To be considered in suspected cases in meat inspection
Gluteal ln. (17.A)	On the sacrosciatic lig. at the greater sciatic foramen	Pelvic bones, hip jt., deep gluteal m., thoracolumbar fascia	Sacral lnn.	1 or 2 lnn., up to 1 cm each; inconstant
Tuberal ln. (19.B)	On the med. surface of the tuber ischiadicum and on the attachment of the sacrosciatic lig.	Skin of pelvic region and tail, gluteobiceps	Sciatic ln., rarely sacral lnn.	2–3 cm long, inconstant
POPLITEAL LYMPHOCENTER (p. 20)				
Deep popliteal ln. (17.C)	In the space between gluteobiceps and semitendinosus and the heads of the gastrocnemius	Pes, crus, and caud. thigh mm.	Iliofemoral and sacral lnn.	3–4.5 cm long. To be examined in suspected cases in meat inspection. A supf. popliteal ln. is absent in ruminants.

3. PERIPHERAL NERVOUS SYSTEM

NERVE	INNervation	REMARKS
SPINAL NERVE		
• Dorsal branch (nd)		Leaves the vertebral canal through an intervertebral for. (exceptions C1; C2; S1–S5)
•• Lateral branch (ndl)	Skin of dors. third of lat. surf. of trunk	Sensory; except cervical nn.: motor
•• Medial branch (ndm)	Epaxial mm. of trunk	Motor; except cervical nn.: sensory
• Ventral branch (nv)		
•• Lateral branch (nvl)	Skin of ventr. body wall and limbs	Except nerves of plexuses
•• Medial branch (nvm)	Hypaxial trunk mm. and mm. of limbs	Except nerves of plexuses
I. CERVICAL NERVES: C1–C8 (p. 57, 61)		
• Dorsal branches		C1 leaves the vert. canal through the lat. vert. for. of atlas; C2 through the lat. vert. for. of axis
•• Lateral branches	Cervical part of the dorsal mm. of the trunk	C3d–C6d form the dorsal cervical plexus
•• Medial branches	Skin of dorsolat. part of neck	Motor
• Ventral branches		Sensory; C2dm, as the major occipital n. , innervates the skin of the nape
•• Lateral branches	Skin of lat. and ventr. cervical region; mm. cutanei colli, facies and labiorum	C2vl, as the transverse cervical n. innervates the cutaneous mm. on the head and neck, and as the great auricular n. supplies sensation to lat. parts of the auricle; br. of C5vl as the supraclavicular nn. innervate the skin over the cranial thorax and shoulder joint
•• Medial branches	Long hyoid mm. and hypaxial mm. Mm. omotransversarius, rhomboideus, and serratus ventralis cervicis	C4 and C5 form the ventr. cervical plexus; br. of C5v to C7v course through the thoracic inlet as the phrenic n. to the diaphragm; C6v, C7v, and C8v, together with T1v and T2v form the brachial plexus
II. THORACIC NERVES: T1–T13 (p. 61, 67)		
• Dorsal branches		
•• Lateral branches	Skin over the dorsal thoracic wall down to parts of the lateral thoracic and abdominal wall	Also known as the first cutaneous branch
•• Medial branches	Thoracic part of the epaxial muscles of the trunk	See Muscle Tables (Vertebral column Musculature: epaxial muscles)
• Ventral branches	Internal and external intercostal muscles	Course ventrally under the pleura (except for the last n.) as intercostal nn. in the costal groove
•• Lateral branches	Musculature of the lateral thoracic and abdominal wall	
••• Lateral cutaneous branches	Skin of the lateral thoracic and abdominal wall	Second cutaneous br.; lat. cut. br. of T1v–T3v and a br. of lat. thoracic n. form the intercostobrachial n. It innervates the cutaneous omobranchialis and skin over the triceps.
•• Medial branches	Musculature and skin of the ventr. thoracic and abdominal wall	In the region of the sternal ribs they innervate the internal intercostal mm. and transversus thoracis; in the region of the asternal ribs, the ext. and int. oblique, rectus, and transversus abd. mm. T13v, as the costoabdominal n. , innervates parts of the psoas mm. and the quadratus lumborum
••• Ventral cutaneous branches	Skin lat. and ventr. to the sternum, and of the abdomen to the udder or prepuce	Also known as the third cutaneous branch

NERVE	INNervation	REMARKS
III. LUMBAR NERVES: L1–L6 (p. 85)		
• Dorsal branches		
•• Lateral branches		
••• Lat. and med. cutaneous branches	Skin on the lat. abd. wall down to the level of the patella; and lumbar and cran. gluteal regions	Important in anesthesia of the paralumbar fossa; also include cran. clunial nn.
•• Medial branches	Lumbar part of the epaxial mm.	
• Ventral branches		Form the roots of the lumbar plexus (see p. 122)
•• Lateral branches	Skin and muscles of the lateral and ventral abdominal wall and pelvic limb	
•• Medial branches		
IV. SACRAL NERVES: S1–S5 (p. 85)		
• Dorsal branches		Leave vert. canal through dorsal sacral foramina
•• Lateral branches	Skin of caud. gluteal region and thigh	Known as the middle clunial nn.
•• Medial branches	Caud. parts of multifidus and dorsal muscles of the tail	
• Ventral branches	Muscles of the pelvic limb	Leave vert. canal through ventral sacral foramina
•• Lateral branches		
•• Medial branches		Form the roots of the sacral plexus (see p. 123)
V. CAUDAL [COCCYGEAL] NERVES: Cd1–Cd5		
• Dorsal branches	Dorsal sacrocaudal mm., intertransversarii; skin of dorsal surface of tail	Form the cauda equina (see p. 57.18) Form the dorsal caudal plexus
• Ventral branches	Med. and lat. ventral sacrocaudal mm. and intertransversarii; skin of ventral surface of tail	Form the ventral caudal plexus
BRACHIAL PLEXUS		
Ventr. br. of the 6th to 8th cervical nn. and the 1st and 2nd thoracic nn. form the roots of the plexus, which pass between the scalenus mm. to the craniomedial side of the shoulder joint. Supplies the thoracic limb, parts of the shoulder girdle mm., and the thoracic wall.		
Suprascapular nn. 5.8	Supraspinatus and infraspinatus	Fibers from C6v and C7v; it passes directly over the cran. border of the scapula from med. to lat.
Subscapular n. 5.4	Subscapularis	Fibers mostly from C7v, additionally from C8v
Axillary n. 5.13		Fibers mostly from C7v and C8v; main parts pass between subscapularis and teres major to the lat. side of the thoracic limb
• Muscular branches	Shoulder joint; caud. parts of the subscapularis; teres major, teres minor, deltoideus	
• Cran. cutaneous antebrachial n.	Skin over the shoulder to the craniolateral surface of the middle of the antebrachium	

NERVE	INNERVATION	REMARKS
Musculocutaneous nerve (5.9)		Fibers from C6v–C8v; forms the ansa axillaris with the median n.
• Proximal muscular br. (5.b)	Coracobrachialis and biceps brachii	Crosses deep to coracobrachialis en route to biceps
• Distal muscular branch (5.d)	Brachialis	
• Med. cutaneous antebrachial n. (5.31)	Skin on the med. side of the forearm; cran. surface of elbow joint capsule	Communicates prox. to carpus with supf. br. of radial n.
Radial nerve (5.15)		Fibers from C7v, C8v, and T1v; passes between the med. and long heads of triceps to the lat. side and over the lat. supracondylar crest of the humerus, where it may be crushed, causing radial paralysis
• Muscular branches	Triceps brachii, tensor fasciae antebrachii, anconeus; distal parts of brachialis	
• Caud. lat. cutaneous brachial n.	Lat. parts of brachial skin	
• Deep branch (5.20)		
•• Muscular branches	Extensor carpi radialis, ext. carpi ulnaris, ext. digitalis communis, ext. digitalis lat., ext. carpi obliquus	
• Superficial branch (5.32)		Communicates prox. to carpus with med. cut. antebrachial n. of musculocutaneous n.
•• Lat. cut. antebrachial nerve (5.33)	Skin on lat. side of forearm almost down to carpus	
•• Dorsal common digital n. II (7.34)		
••• Axial dors. digital n. II	Dorsomed. region of med. dewclaw	
••• Abaxial dors. digital n. III	Skin of digit III to dorsomed. bulbar and coronary regions; digital joints	The nerve may be connected at the level of the fetlock jt. with the corresponding palmar nerve
•• Dorsal common digital n. III		
••• Axial dors. digital nn. III and IV	Skin of digits III and IV in the dors. coronary regions; digital joints	Each n. receives an interdigital communicating br. from the corresponding palmar nn.
Median nerve (7.29)		Fibers from C8–T2; forms the ansa axillaris with the musculocutaneous n.; gives sensory br. to the med. pouch of the elbow jt.; runs with the median a. deep to the pronator teres and flexor carpi rad. to the carpus; passes through the carpal canal on the med. border of the deep belly of the supf. digital flexor (without dividing into med. and lat. palmar nn., unlike horse)
• Muscular branches	Pronator teres, flexor carpi radialis, humeral and radial heads of deep digital flexor, interflexorii	
• Palmar common digital n. II (7.18)		
•• Axial palmar digital n. II	Mediopalmar region of med. dewclaw	
•• Abaxial palmar digital n. III	Skin of digit III on mediopalmar bulbar and coronary regions to the apex of the digit; digital joints	The nerve may be connected at the level of the fetlock jt. with the corresponding dorsal nerve
• Communicating branch (7.f)	To palmar common digital n. IV, of the ulnar n.	
• Palmar common digital n. III (7.17)	Usually double; the br. may unite at the beginning of the interdigital space to form a common trunk (see p. 10)	
•• Axial palmar digital nn. III and IV	Skin of the axial palmar digital regions of digits III and IV to the apices of the digits; digital joints	Each n. gives off an interdigital communicating br. to the corresponding dorsal nerve

NERVE	INNervation	REMARKS
Ulnar nerve (5.10)		Fibers from C8v–T2v; runs caud. to brachial a. and v., medially on the brachium over the med. head of the triceps (covered by the tensor fasciae antebrachii) to the caud. surface of the elbow jt. and into the groove between the ulnaris lat. and flexor carpi ulnaris; gives off sensory fibers to elbow and carpal joints
• Caud. cut. antebrachial nerve (5.24)	Skin on the caudomed. and caudolat. sides of the forearm and carpus	
• Muscular branches	Flexor carpi ulnaris, supf. digital flexor, humeral and ulnar heads of deep digital flexor	
• Dorsal branch (5.43)		Passes laterally over the carpus and in the metacarpus becomes the dorsal common digital n. IV
•• Dorsal common digital n. IV		
••• Axial dors. digital n. V	Laterodorsal region of lat. dewclaw	
••• Abaxial dors. digital n. IV	Skin of digit IV to the laterodorsal coronary and bulbar regions; digital joints	At the level of the fetlock jt. the n. may be connected to the corresponding palmar n.
• Palmar branch (7.14)		Passes over the carpus lateral to the tendons of the supf. digital flexor
•• Deep branch	Interosseus III and IV	The deep branch is given off from the palmar br. distal to the carpus
•• Superficial branch		Passes distally lat. to the flexor tendons, receives the communicating br. from the median n., and becomes palmar common digital n. IV
••• Palmar common digital n. IV		Has a short course.
•••• Axial palmar digital n. V (9.22)	Lateropalmar region of the lat. dewclaw	
•••• Abaxial palmar digital n. IV (9.24)	Skin of digit IV on the lateropalmar coronary and bulbar regions to the apex of the digit; digital joints	At the level of the fetlock jt. the n. may be connected to the corresponding dorsal n.
Cran. and caud. pectoral nerves (61.t and 61.u)	Supf. and deep pectoral mm. and subclavius	Fibers from the cran. roots of the plexus
Long thoracic nerve (61.v)	Serratus ventralis thoracis	Fibers mainly from C7v and C8v
Lateral thoracic nerve (61.w)	Cutaneus trunci and, together with intercostal nn., skin on ventral thorax and abdomen	Fibers from C8v–T2v; see also intercostobrachial n. under THORACIC NN. (p. 119)
Thoracodorsal nerve (5.3)	Latissimus dorsi	Fibers from C7v and mainly from C8v
LUMBAR PLEXUS	Ventral br. of L2–L6 form the roots of the plexus	Forms, with the sacral plexus, the lumbosacral plexus
Iliohypogastric nerve (67.8)		Fibers from L1v; no communication with other spinal nn., therefore not a plexus n.
• Lateral ventral branch	Ext. and int. abdominal oblique mm., transversus abdominis	Perforates the abd. mm. and ends in the lat. and ventr. cutaneous br.
•• Lateral cutaneous br.	Skin of the flank back to the craniolateral surface of stifle	
•• Ventral cutaneous br.	Skin on the ventr. abdominal wall, prepuce or udder, skin on medial surface of thigh	
• Medial ventral br.	Caud. parts of all abd. mm.; peritoneum cran. to inguinal region	Courses subperitoneally to the vicinity of the internal inguinal ring

NERVE	INNervation	REMARKS
Ilioinguinal nerve (67.9)		Fibers from L2v and L3v
• Lateral ventral branch	See also iliohypogastric n.	Perforates the abdominal wall
•• Lateral cutaneous branch	Skin of paralumbar fossa, over the cran. surface of thigh to lat. surface of stifle	The field of innervation adjoins that of the iliohypogastric n. caudally
•• Ventral cutaneous branch	See iliohypogastric n.	
• Medial ventral branch	Peritoneum of the inguinal region, skin of the prepuce or udder	Perforates transversus, rectus, and aponeuroses of oblique abd. muscles
Genitofemoral n. (91.c)		Fibers from L2v–L4v, crosses the deep circumflex iliac a. and v. Extremely variable
• Genital branch (81.11 and 81.19)	Cremaster, tunica vaginalis, skin of the prepuce or udder	Passes through the caudomedial angle of the supf. inguinal ring with the ext. pudendal a. and v.
• Femoral branch	Skin on the med. surface of thigh and the prepuce or udder	Passes through the lacuna vasorum
Lateral cutaneous femoral n. (67.11)	Psoas major, skin of the fold of the flank, cranial, and in part medial, surfaces of thigh; stifle joint	Fibers from L3v and L4v; accompanies caud. branch of deep circumflex iliac a. and v.; after perforating the abd. wall runs at first medial, then craniolat. on the thigh down to the stifle
Femoral n. (21.f)		Fibers from L4v–L6v; passes between psoas minor and cran. head of sartorius and iliopsoas through lacuna musculorum; gives off saphenous n. here
• Muscular branches	Sartorius, quadriceps femoris	
• Saphenous n. (21.11)		Runs with femoral a. and v. in the femoral triangle; sensory to stifle jt.; supplies the pectineus part of the pectineus (et adductor longus)
•• Muscular branches	Sartorius, pectineus (et adductor longus), gracilis; sensory to stifle joint	
•• Cutaneous branches	Skin of med. surface of limb down to hock	
Obturator n. (21.n)	Pectineus (et adductor longus), gracilis, adductor magnus (et brevis); obturator externus (with intrapelvic part)	Fibers from L4v–L6v, but also from S1; runs in obturator groove to obturator for.; supplies adductor longus part of pectineus (et adductor longus)
SACRAL PLEXUS		Roots from sacral nerves
Cranial gluteal n. (17.2)	Middle, deep, and accessory gluteal mm., tensor fasciae latae	Fibers from L6v–S2v; branches off cranially from lumbosacral trunk
Caudal gluteal n. (17.16)	Gluteobiceps	Fibers from L6v–S2v; branches off caudally from lumbosacral trunk
Caudal cutaneous femoral nerve (21.i)	Skin on the gluteal region and caudal thigh	Fibers from S1v and S2v; arises from lumbosacral tr. caud. to caud. gluteal n.; runs outside sacrosiatic lig. and divides at minor sciatic for.; med. br. enters for. and joins pudendal n; lat. (cutaneous) br. may be absent
Caudal clunial nn.	Skin of the gluteal region	May be replaced by the prox. and dist. brr. of the pudendal n.
Sciatic n. (17.17)		Fibers from L5v–S2v; direct continuation of lumbosacral trunk; emerges through major sciatic for. to lat. surface of sacrosiatic lig., passes over the deep gluteal, then between the sciatic spine and major trochanter over the hip joint
• Muscular branches	Deep gluteal, gemelli, quadratus femoris	

NERVE	INNervation	REMARKS
• Common peroneal n. (17.6)		Runs over lat. head of gastrocnemius, passes under peroneus longus, runs between that and the lat. dig. extensor and divides in the middle of the crus into supf. and deep peroneal nn.
•• Lat. cutaneous sural n. (17.21)	Skin lat. to the stifle and crus	Perforates the terminal tendon of the biceps femoris
•• Supf. peroneal n. (17.14)		Originates from the common peroneal n. in the middle of the crus
••• Cutaneous branches	Skin on the dorsolat. surface of the metatarsus	
••• Dorsal common dig. n. IV (23.6)		Origin from supf. peroneal n., usually in the crus, crosses deep to the cran. br. of the lat. saphenous v. and runs down the metatarsus
•••• Axial dors. dig. n. V (23.14) and Abaxial dors. dig. n. IV (23.15)	Distributed like corresponding nn. on the manus which originate from the ulnar n. (see p. 9)	
••• Dorsal common dig. n. II (23.4)		Smaller terminal br. of supf. peroneal n.; divides distal to prox. third of metatarsus
•••• Axial dors. dig. n. II (23.12) and Abax. dors. dig. n. III (23.13)	Distributed like corresponding nn. on the manus which originate from the radial n. (see p. 9)	
••• Dorsal common dig. n. III (23.7)		Larger terminal br. of supf. peroneal n. in prox. third of metatarsus; runs to the interdigital space, exchanges communicating brr. with dors. metatarsal n. III (see. p. 11)
•••• Axial dors. dig. nn. III (23.21) and IV (23.22)	Skin of digits III and IV to the dorsal coronary region, digital joints	
•• Deep peroneal n. (17.9)		Origin from com. peroneal n. in middle of crus; runs on lat. border of extensor digit. longus, deep to the extensor retinacula, to the flexion surface of the tarsus
••• Muscular brr.	Tibialis cran., long, lat., and short extensors, peroneus tertius, peroneus longus	
••• Dorsal metatarsal n. III (23.1)		Runs on the metatarsus with vessels of the same name in the dors. mtt. groove to the interdigital space; after exchanging communicating brr. with dors. com. dig. n. III, ends in communicating brr. to each plantar axial digital n.
• Tibial nerve (17.19)		Passes between the two heads of the gastrocnemius and divides at the dist. end of the crus into med. and lat. plantar nn.
•• Prox. muscular brr.	Semitendinosus and semimembranosus and ischial head of biceps femoris	
•• Caud. cutaneous sural n. (17.19')	Skin on caudolat. surface of crus down to hock	Supplies lat. part of capsule of stifle joint; runs with lat. saphenous v. and passes distally on the lat. side of the common calcanean tendon
•• Dist. muscular brr.	Popliteus, extensors of the hock, and flexors of the digits	
•• Medial plantar n. (19.14)		Runs with supf. brr. of the med. plantar a. and v. on the med. border of the deep flexor tendon to the distal third of the metatarsus, where it divides
••• Plantar common digital n. II (23.9)		
•••• Axial plant. dig. n. II (23.11) and Abax. plant. dig. n. III (23.17)	Distributed like the corresponding palmar nn. on the manus which come from the median n. (see p. 9)	
••• Plantar common digital n. III (23.8)		Runs over the med. br. of the supf. dig. flexor tendon to the interdigital space; may be double or divide and reunite
•••• Axial plant dig. nn. III (23.20) and IV (23.19)	Like the corresponding palmar nn. on the manus, except that each receives a communicating br. from the union of the supf. and deep dors. nn. (see. p. 11)	
•• Lateral plantar n. (19.13)		Crosses deep to the long plantar lig. of the tarsus to the lat. border of the interosseus

NERVE	INNervation	REMARKS
••• Deep branch	Interossei III and IV	
••• Plant. common dig. n. IV		
•••• Axial plant. dig. n. V and Abax. plant. dig. n. IV	Like the corresponding palmar nn. of the manus which come from the ulnar n.	
Branch to coccygeus Branch to levator ani (95.17)	Corresponding muscles	Fibers from S3 and S4, possibly also from the pudendal n. or caudal rectal nerves
Pudendal nerve (95.9)	Rectum, internal and external genital organs	S2–S4; accompanies int. pudendal a. and v. caudally on pelvic floor and over ischial arch
• Proximal cutaneous branch	Skin on semitendinosus	Emerges through biceps just cran. to dors. process of tuber ischiadicum or through sacrotuberous lig.
• Distal cutaneous branch	Skin on semimembranosus	Emerges from ischiorectal fossa
•• Supf. perineal br.	Skin of perineum	
••• Dorsal scrotal nn. or dors. labial nn.	Scrotum or labia and skin of caud. surface of udder	
• Deep perineal n.	Perineal muscles, vagina, vulva, major vestibular gl., skin of perineum	Communicating br. with caud. rectal nn.
• Dorsal n. of penis or clitoris	Penis or clitoris	
• Preputial and scrotal branch or mammary branch	Prepuce and scrotum or udder	The mammary br. is closely associated with the convoluted ventral labial v.
Caudal rectal nerves (97.17)		Fibers from S4, S5; communicate with deep perineal n.
• Muscular branches	Caud. part of rectum, ext. anal sphincter, retractor penis (clitoridis), coccygeus, levator ani, constrictor vestibuli	
• Cutaneous branches	Skin of anal region	

REFERENCES

Monographs, textbooks, reference books

- Ashdown, R.R. and S. Done, 1984: Color Atlas of Veterinary Anatomy. The Ruminants. Univ. Park Press, Baltimore
- Barone, R., 1976-1996: Anatomie comparée des mammifères domestiques. T. 1-5, Laboratoire d'Anatomie, Ecole Nationale Vétérinaire, Lyon; Vigot Frères, Paris
- Baum, H., 1912: Das Lymphgefäßsystem des Rindes. A. Hirschwald, Berlin
- Benzie, D. and A.J. Phillipson, 1957: The alimentary tract of the ruminant. Oliver and Boyd, Edinburgh
- Berg, R., 1995: Angewandte und topographische Anatomie der Haustiere. Gustav Fischer, Jena, Stuttgart
- Budras, K.-D., McCarthy, P., W. Fricke and R. Richter, 2002: Anatomy of the Dog. 4th ed., Schlütersche, Hannover
- Budras, K.-D., W.O. Sack and S. Röck, 2001: Anatomy of the Horse, 4th ed., Schlütersche, Hannover
- De Lahunta, A. and R.E. Habel, 1986: Applied Veterinary Anatomy. W.B. Saunders Co., Philadelphia
- Dyce, K.M. and C.J.G. Wensing, 1983: Anatomie van het Rund. Bohn, Scholtema and Holkema, Utrecht
- Dyce, K.M., W.O. Sack and C.J.G. Wensing, 1987: Textbook of veterinary anatomy. W.B. Saunders, Philadelphia
- Dyce, K.M., W.O. Sack and C.J.G. Wensing, 1991: Anatomie der Haustiere. Lehrbuch für Studium und Praxis. Ferdinand Enke Verlag, Stuttgart
- Ellenberger, W. und H. Baum, 1943: Handbuch der vergleichenden Anatomie der Haustiere. 18. Aufl., J. Springer, Berlin
- Ensminger, M.E., 1977: Animal Science, 7. ed., Danville, Illinois. Interstate Printers and Publishers
- Frewein, J., R.E. Habel and W.O. Sack, editors, 1994: Nomina Anatomica Veterinaria. 4th ed., Internat. Com. Vet. Gross Anat. Nomenclatur, Zürich and Ithaca, New York
- Fürstenberg, M.H.F., 1868: Die Milchdrüsen der Kuh, ihre Anatomie, Physiologie und Pathologie. Leipzig
- Getty, R., 1975: Sisson and Grossman's The Anatomy of the Domestic Animals. 5th ed., W.B. Saunders Co., Philadelphia
- Ghoshal, N.G., T. Koch, and P. Popesko, 1981: The venous drainage of the domestic animals. W.B. Saunders Co. Philadelphia
- Habel, R.E., 1992: Guide to the Dissection of Domestic Ruminants. 4th ed., Published by author, Ithaca, New York
- Hofmann, R.R., 1969: Zur Topographie und Morphologie des Wiederkäuermagens im Hinblick auf seine Funktion. Nach vergleichenden Untersuchungen an Material ostafrikanischer Wildarten. Parey, Berlin, Hamburg
- Hofmann, R.R. und B. Schnorr, 1982: Die funktionelle Morphologie des Wiederkäuer-Magens. Schleimhaut und Versorgungsbahnen. Enke, Stuttgart
- King, A.S., 1999: The Cardiorespiratory System. Blackwell Science Ltd., Oxford
- Koch, T. und R. Berg, 1992: Lehrbuch der Veterinär-Anatomie. Bd. 1-3. 5. Aufl., Fischer, Jena, Stuttgart
- König, H.E. und H.-G. Liebich, 1999: Anatomie der Haussäugetiere. Lehrbuch und Farbatlas für Studium und Praxis. Bd. 1 u. 2, Schattauer, Stuttgart, New York
- Martin, P. und W. Schauder, 1938: Lehrbuch der Anatomie der Haustiere. Bd. 3: Anatomie der Hauswiederkäuer. 3. Aufl., Schickhardt u. Ebner, Stuttgart
- Montané, L. et E. Bourdelle, 1917: Anatomie régionale des animaux domestiques. 2e vol.: Ruminants. J.-B. Bailière et Fils, Paris.
- Nickel, R., A. Schummer und E. Seiferle, 1992-2001: Lehrbuch der Anatomie der Haustiere. Bd. 1-4, Parey, Berlin
- Pavaux, Cl., 1982: Farbatlas der Anatomie des Rindes. Splanchnologie. Schober, Hengersberg
- Popesko, P., 1998: Atlas der topographischen Anatomie der Haustiere. Enke, Stuttgart
- Preuss, F. und E. Henschel, 1974: Praktikum der angewandten Veterinär-anatomie. Teil II Wiederkäuer. Selbstverlag
- Prince, H., C.D. Diesem, J. Eglitis and al. 1960: Anatomy and Histology of the Eye and Orbit in Domestic Animals. Charles C. Thomas, Springfield, Ill.
- Schaller, O., 1992: Illustrated Veterinary Anatomical Nomenclature. Enke, Stuttgart
- Schmaltz, R., 1895: Topographische Anatomie der Körperhöhlen des Rindes. Schoetz, Berlin
- Ziegler, H. und W. Mosimann, 1960: Anatomie und Physiologie der Rindermilchdrüse. Paul Parey, Berlin und Hamburg
- Baum, H., 1911: Die Lymphgefäße der Gelenke der Schultergliedmaße des Rindes. Anat. Hefte 44: 439-456
- Baum, H., 1911: Die Lymphgefäße der Muskeln und Sehnen der Schultergliedmaße des Rindes. Anat. Hefte 44: 623-656
- Bruchmann, W., 1965: Untersuchungen über die Punktionsmöglichkeiten am Schulter-, Ellenbogen- und Hüftgelenk des Rindes. Diss. med. vet. Hannover
- Cuq, P., 1962: Les articulations du carpe ou genou chez le boeuf. Rec. Méd. Vét. 138: 849-868
- Desrochers, A., G. St.-Jean, W.C. Cash, et al. 1997: Anatomic communications among the antebrachio-carpal, middle carpal, and carpometacarpal joints in cattle. Am. J. Vet. Res. 58: 7-10
- De Vos, N., 1964: Description topographique des artères du pied chez le boeuf. Econ. Méd. anim. 5: 367-401
- De Vos, N., 1964: Vergelijkende studie van de arteries van het voorste lidmaat bij de huisdieren. Mededel. Veeartsenijschool Rijksuniv. Gent 8: 1-176
- Fölger, A.F., 1906: Über die unteren Sehnenscheiden des Rindes. Mh. prakt. Tierheilkd. 17: 445-452
- Frewein, J., 1963: Die Vv. communicantes an den Schultergliedmaßen einiger Säugetiere (Rind, Pferd, Schwein, Hund und Katze). Verh. Anat. Ges., Jena 59: 304-309
- Frewein, J., 1967: Die Faszien an den Schultergliedmaßen von Schwein, Rind und Pferd. Anordnung, Struktur und Bedeutung für den Einbau der Leitungsbahnen. Acta anat., Suppl. 53: 1-100
- Frewein, J. und M.-B. Morcos, 1962: De arteries van de voorvoet bij het rund. Vlaams diergeneesk. Tijdschr. 31: 161-170
- Funk, Kl., 1966: Röntgenanatomische Untersuchungen am Karpalskelett des Rindes. Diss. med. vet. Hannover
- Ghoshal, N.G. and R. Getty, 1967: Innervation of the forearm and foot in the ox, sheep and goat. Iowa State Univ. Vet. 29: 19-29
- Ghoshal, N.G. and R. Getty, 1970: Comparative morphological study of the major arterial supply to the thoracic limb of the domestic animals (Bos taurus, Ovis aries, Capra hircus, sus scrofa domestica, Equus caballus). Anat. Anz. 127: 422-443
- Habel, R.E., 1950: The nerves and arteries of the bovine foot. Proc. Amer. Vet. Med. Assoc., 78. meet., Miami Beach, 323-327
- Habermehl, K.H., 1961: Dorsale Corpora sesamoidea an den Zehen einiger Wiederkäuer. Festschr. für Schreiber, Wien. Tierärztl. Monatschr.: 213-224
- Hartung, O., 1923: Das Verbindungsgewebe zwischen Radius und Ulna bei den Haustieren mit besonderer Berücksichtigung von Schwein und Rind. Diss. med. vet. Berlin
- Horowitz, A., 1964: The veins of the thoracic limb of the ox. Speculum, Ohio State Univ. 17(2): 21-30
- Langer, P., R. Nickel, 1953: Nervenversorgung des Vorderfußes beim Rind. Dtsch. Tierärztl. Wschr. 60: 307-309
- Lauwers, H., en N.R. De Vos, 1967: Systematische en topografische beschrijving van de venen van de voor- en achtervoet bij het rund. Vlaams diergeneesk. Tijdschr. 36: 81-90
- Münster, W. und R. Schwarz, 1968: Venen der Schultergliedmaße des Rindes. Zbl. Vet. Med. A 15: 677-717
- Nickel, R. und P. Langer, 1953: Zehengelenke des Rindes. Berl. Münch. Tierärztl. Wschr. 66: 237-246
- Nickel, R. und H. Wissdorf, 1964: Vergleichende Betrachtung der Arterien an der Schultergliedmaße der Haussäugetiere (Katze, Hund, Schwein, Rind, Schaf, Ziege, Pferd). Zbl. Vet. Med. A 11: 265-292
- Peters, E., 1965: Zur Anatomie der gemeinsamen digitalen Sehnenscheide am Vorder- und Hinterfuß des Rindes. Diss. med. vet. Hannover
- Richter, H., 1927: Querschnittformen vom Metacarpus und Metatarsus bei einigen unguigraden und digitigraden Haustieren und Wild. (equus, bos, canis, tarandus rangifer (Rentier) und alces alces (Elch) mit Erklärung in physiologischer und biologischer Hinsicht. Anat. Anz. (Erg. H) 63: 220-228
- Richter, B. und Riessner, 1973: Morphologische Untersuchungen an den Venen der Vorder- und Hintergliedmaße des Rindes im Hinblick auf den Blutrückfluß. Diss. med. vet. Berlin
- Schmidchen, P., 1906: Die Sehnenscheiden und Schleimbeutel des Rindes. Mschr. prakt. Tierheilk. 18: 1-60
- Schraml, O., 1931: Untersuchung am Carpalgelenk des Rindes. Diss. med. vet. München
- Schreiber, J., 1956: Die anatomischen Grundlagen der Leitungsanaesthesie des Rindes. III. Teil: Die Leitungsanaesthesie der Nerven der Vorderextremität. Wien. Tierärztl. Mschr. 43: 273-287
- Shively, M.J. and J.E. Smallwood, 1979: Normal radiographic and xerographic anatomy of the bovine manus. Bovine Pract. 14: 74-83
- Simoens, P., N.R. De Vos, H. Lauwers et al., 1980: Illustrated anatomical nomenclature of the arteries of the thoracic limb in the domestic mammals. Mededel. Fac. Diergeneesk., Rijksuniv. Gent 22: 1-50
- Sussdorf, M. von, 1889: Die Verteilung der Arterien und Nerven an Hand und Fuß der Haussäugetiere. Festschr. 25j. Regierungsjubiläum S.M. König Karl von Württemberg. Verlag W. Kohlhammer, Stuttgart

Chapter 1. Thoracic limb

- Badawi, H. und H. Wilkens, 1961: Zur Topographie der Arterien an der Schultergliedmaße des Rindes, unter besonderer Berücksichtigung der Versorgung des Vorderfußes. Zbl. Vet. Med. A 8: 533-550

- Taylor, J.A., 1960: The applied anatomy of the bovine foot. *Vet. Rec.* 72: 1212-1215
- Vollmerhaus, B., 1965: Topographisch-anatomische Darstellungen mit Hinweisen zu Injektionstechnik an Gelenken, Sehnenscheiden und Schleimbeuteln bei Pferd, Rind und Hund. Farbwerke Hoechst AG, Marburg
- Wilkens, H., 1955: Arterien des Unterarms in vergleichender Betrachtung beim Menschen und bei unseren Haussäugetieren. *Zbl. Vet. Med.* A2: 193-198
- Zniniewicz, V., 1908: Beiträge zur Anatomie und Mechanik des Schultergelenks beim Pferd und Rind. *Diss. med. vet.* Bern
- Chapter 2. Pelvic limb**
- Barone, R. et M. Lombard, 1968: Le jarret du boeuf et son fonctionnement. *Rev. Méd. Vét.* 31: 1141-1166
- Baum, H., 1896: Besteht beim Rinde eine Verbindung zwischen der Kniescheibenkapsel und der Kapsel des Femoro-Tibialgelenkes, bzw. zwischen den beiden Säcken der letzteren? *Arch. wiss. prakt. Thierheilk.* 22: 333-337
- Bragulla, H. und Ch. Mülling, 1997: Veränderungen der Architektur der Hornzellen und des Hornzellverbandes bei Klauenerkrankungen. *Anat. Histol. Embryol.* 26: 51-52
- Bragulla, H., Reese, S., Mülling, Ch. et al., 1997: Die hinfallige Klauenkapsel des Rindes. *Anat. Histol. Embryol.* 26: 62
- Bruchmann, W., 1965: Untersuchungen über die Punktionsmöglichkeiten am Schulter-, Ellenbogen- und Hüftgelenk des Rindes. *Diss. med. vet.* Hannover
- Budras, K.-D. und Ch. Mülling, 1997: Die Hornbildungsrate im Wandsegment der Rinderklaue. *Anat. Histol. Embryol.* 26: 52
- Cervený, C., 1965: Die Gelenkbänder am Sprunggelenk des Rindes. (Dtsch. Zus.fassg.) *Vet. Med.* 10 (38): 111-118
- Desrochers, A., G.St. Jean, W.C. Cash, et al. 1996: Anatomic communications between the femoropatellar joint and lateral and medial femorotibial joints in cattle. *Am. J. Vet. Res.* 57: 798-802
- Dirks, Cl., 1985: Makroskopische, Licht- und elektronenmikroskopische Untersuchungen über den Rückenteil der Rinderklaue. *Diss. med. vet.* Freie Universität Berlin
- Dottrens, E., 1946: Les phalanges osseuses de *Bos taurus domesticus*. *Rev. Suisse Zool.* 53: 739
- Engel, E., 1919: Vergleichend-anatomische Untersuchungen über die Zehenknochen von Pferd, Rind, Ziege und Schaf. *Diss. med. vet.* Leipzig
- Fürst, A., 1992: Makroskopische und mikroskopische Anatomie der Rinderklaue. *Diss. med. vet.* Zürich
- Fürst, C.M., 1914: Über die Entwicklung und Reduktion der Fibula beim Rinde. *Z. Morph. Anthropol.* 18: 93-110
- Hagenbuch, K., 1938: Das Sprunggelenk des Rindes. *Bau und Bewegungsart.* *Diss. med. vet.* München
- Heinze, W. und H. Kantor, 1972: Morphologisch-funktionelle Untersuchungen über das Blutgefäßsystem der Rinderklaue. *Morph. Jb.* 117: 472-482, 118: 139-159
- Hirschberg, R., 1999: Die Feinstruktur der Blutgefäße an der gesunden und erkrankten Rinderklaue. *Diss. med. vet.* Freie Universität Berlin
- Hirschberg, R.M., Ch. Mülling and H. Bragulla, 1999: Microvasculature of the bovine claw demonstrated by improved micro-corrosions casting technique. *Microsc. Res. Techn.* 45: 184-197
- Hochstetter, T., 1998: Die Hornqualität der Rinderklaue unter Einfluß einer Biotinsupplementierung. *Diss. med. vet.* Freie Universität Berlin
- Howlett, C.R., 1971: Anatomy of the arterial supply to the hip joint of the ox. *J. Anat.* 110: 343-348
- Ippensen, E., 1969: Venen der Beckengliedmaße des Rindes. *Diss. med. vet.* Hannover
- Kolesnikow, W.W., 1932: Zur vergleichenden Anatomie des *M. gluteo-biceps* der Säugetiere. *Z. Anat. Entw.gesch.* 99: 538-570
- Lauwers, H., en N.R. De Vos, 1967: Systematische en topografische beschrijving van de venen van de voor- en achtervoet bij het rund. *Vlaams diergeneesk. Tijdschr.* 36: 81-90
- Müller-Calgan, H., 1954: Interosseus-Apparat bei Wiederkäuern. *Diss. med. vet.* Gießen
- Mülling, Ch., 1993: Struktur, Verhornung und Hornqualität in Ballen, Sohle und Weißen Linie der Rinderklaue und ihre Bedeutung für Klauenerkrankungen. *Diss. med. vet.* Freie Universität Berlin
- Mülling, Ch., Bragulla, H., Budras, K.-D. et al., 1997: Der Aufbau der Weißen Linie der Rinderklaue in Abhängigkeit von der Papillarkörperform. *Anat. Histol. Embryol.* 26: 71
- Mülling, Ch. und K.-D. Budras, 1998: Der Interzellularkitt (Membrane Coating Material MCM) in der Epidermis der Rinderklaue. *Wien. Tierärztl. Mschr.* 85: 216-223
- Nickel, R. und P. Langer, 1953: Zehengelenke des Rindes. *Berl. Münch. Tierärztl. Wschr.* 66: 237-246
- Pavaux, C., H. Chahrasbi et J.Y. Sautet et al., 1981: Les rameaux musculaires distaux du nerf tibial chez le boeuf (*Bos taurus*). *Anat. Histol. Embryol.* 10: 15-25
- Pavaux, C., Y. Lignereux, and J.Y. Sautet, 1983: Anatomie comparative et chirurgical du Tendon calcanéen commun des mammifères domestiques. *Anat. Histol. Embryol.* 12: 60-69
- Peters, E., 1965: Zur Anatomie der gemeinsamen digitalen Sehnenscheide am Vorder- und Hinterfuß des Rindes. *Diss. med. vet.* Hannover
- Petersen, G., 1921: Untersuchungen über das Fußskelett des Rindes. *Morph. Jb.* 51: 291-337
- Pötschke, H.-P., 1969: Der Plexus lumbosacralis des Rindes und die Blockstellen für die Paravertebralanästhesie sowie für die Anästhesie der Nerven der Dammgegend. *Diss. med. vet.* Freie Universität Berlin
- Prentice, D.E., 1973: Growth and wear rates of hoof horn in Ayrshire cattle. *Res. Vet. Sci.* 14: 285-290
- Reimers, H., 1913: Plexus lumbalis und sacralis von Rind und Schwein. *Diss. med. vet.* Leipzig
- Reinsfeld, R., 1932: Die Mechanik des Kniegelenkes vom Rinde. *Diss. med. vet.* München u. Z. *Anat. Entw.gesch.* 97: 487-508
- Richter, H., 1927: Querschnittformen vom Metacarpus und Metatarsus bei einigen unguligraden und digitigraden Haustieren und Wild (equus, bos, canis, tarandus rangifer (Rentier) und alces alces (Elch) mit Erklärung in physiologischer und biologischer Hinsicht. *Anat. Anz. (Erg. H)* 63: 220-228
- Richter, B. und Riessner, 1973: Morphologische Untersuchungen an den Venen der Vorder- und Hintergliedmaße des Rindes im Hinblick auf den Blutrückfluß. *Diss. med. vet.* Berlin
- Schmidtchen, P., 1906: Die Sehnenscheiden und Schleimbeutel des Rindes. *M Schr. prakt. Tierheilk.* 18: 1-60
- Schreiber, J., 1956: Die anatomischen Grundlagen der Leitungsanaesthesie des Rindes. IV. Teil: Die Leitungsanaesthesie der Nerven der Hinterextremität. *Wien. Tierärztl. Mschr.* 43: 673-705
- Smallwood, J.E. and M.J. Shively, 1981: Radiographic and xeroradiographic anatomy of the bovine tarsus. *Bovine Pract.* 2: 28-46
- Smith, R.N., 1956: The proximal metatarsal sesamoid of the domestic ruminants. Is it the vestige of a second metatarsal? *Anat. Anz.* 103: 241-245
- Stuhlenmiller, M., 1922: Untersuchungen am Hüftgelenk des Rindes. *Diss. med. vet.* München
- Sussdorf, M. von, 1889: Die Verteilung der Arterien und Nerven an Hand und Fuß der Haussäugetiere. *Festschr. 25j. Regierungsjubiläum S.M. König Karl von Württemberg*, Verlag W. Kohlhammer, Stuttgart
- Szenes, J., 1923: Zur Anatomie des Sprunggelenks des Rindes mit Beziehung auf die Wirkung seiner Bänder und Muskeln. (Dtsch. Zus.fassg.) *Diss. med. vet.* Budapest
- Taylor, J.A., 1960: The applied anatomy of the bovine foot. *Vet. Rec.* 72: 1212-1215
- Vollmerhaus, B., 1965: Topographisch-anatomische Darstellungen mit Hinweisen zu Injektionstechnik an Gelenken, Sehnenscheiden und Schleimbeuteln bei Pferd, Rind und Hund. Farbwerke Hoechst AG, Marburg
- Wackwitz, B., 1967: Beiträge zur topographischen Anatomie der Extremitas pelvina des Rindes. *Diss. med. vet.* Berlin (Humboldt-Univ.)
- Westerfeld, I., 2003: Struktur und Funktion des bovinen Klauenbeinträgers. *Diss. med. vet.* Berlin
- Wilkens, H., 1964: Zur makroskopischen und mikroskopischen Morphologie der Rinderklaue mit einem Vergleich der Architektur von Klauen- und Hufhörchen. *Zbl. Vet. Med. A* 11: 163-234
- Wilkens, H. und H. Badawi, 1962: Beitrag zur arteriellen Blutgefäßversorgung vom Fuß der Beckengliedmaße des Rindes. *Berl. Münch. Tierärztl. Wschr.* 75: 471-476
- Wünsche, A., 1966: Die Nerven des Hinterfußes vom Rind und ihre topographische Darstellung. *Zbl. Vet. Med. A* 13: 429-443
- Chapter 3. Head**
- Baldwin, B.A., 1964: The anatomy of the arterial supply to the cranial regions of the sheep and ox. *Amer. J. Anat.* 115: 101-118
- Barzt, W., 1910: Über die Epithelkörperchen, die Thyreoidea und die Nebenschilddrüsen beim Rind, Schaf, Schwein und Hund. *Diss. med. vet.* Bern
- Baum, H., 1898: Die Nasenhöhle und deren Nebenhöhlen beim Rinde. *Arch wiss. prakt. Thierheilk.* 24: 337-374
- Baum, H., 1928: Die Lymphgefäße des Kehlkopfes der Haustiere (Pferd, Rind, Schwein und Hund). *Festschr. E. Fröhner*, Stuttgart, Enke Verlag
- Brandt, K., 1928-29: Die Entwicklung des Hornes beim Rinde bis zum Beginn der Pneumatisation des Hornzapfens. *Gegenb. Morph. Jb.* 60: 428-468
- Butler, W.F., 1967: Innervation of the horn region in domestic ruminants. *Vet. Rec.* 80: 490-492
- Cummings, J.F. and R.E. Habel, 1965: The blood supply of the bovine hypophysis. *Amer. J. Anat.* 116: 91-114
- Dahmen, E., 1970: Die embryonale Entwicklung des Waldeyer'schen Rachenringes beim Rind. *Diss. med. vet.* München

- Davies, R., M. Kare, R. Cagan, 1979: Distribution of taste buds in fungiform and circumvallate papillae of bovine tongue. *Anat. Rec.* 195: 443-446
- Dougherty, R.W., K.J. Hill, F.L. Campeti, R.C. Mc Clure and R.E. Habel, 1962: Studies of pharyngeal and laryngeal activity during eructation in ruminants. *Amer. J. Vet. Res.* 23: 213-219
- Egehøj, J., 1934: Das Lymphsystem des Kopfes beim Rinde. *Dtsch. Tierärztl. Wschr.* 42: 333-336
- Forster, A., 1934: L'articulation temporomaxillaire chez les ruminants (mouton, chèvre, bovins) et les solipèdes (cheval). Étude d'anatomie comparée. *Arch. d'Anat.* 18: 327-371
- Godinho, H.P. and R. Getty, 1971: The branches of the ophthalmic and maxillary nerves to the orbit of goat, sheep and ox. *Arquivos da Escola de Veterinaria (Brazil)* 23: 229-241
- Hauser, H., 1937: Über Bau und Funktion der Wiederkäuerparotis. *Zschr. mikrosk.-anat. Forsch.* 41: 177-228
- Heinze, W., 1963: Die Morphologie der Kaumuskulatur des Rindes, der Ziege und des Schafes sowie Erörterungen einiger myologischer Fragen. *Anat. Anz.* 112: 101-128
- Helm, F.Chr., 1957: Die Gefäßverzweigung in der Schilddrüse des Rindes. *Zbl. Vet. med.* A4: 71-79
- Himmelreich, H.A., 1964: Der M. tensor veli palatini der Säugetiere unter Berücksichtigung seines Aufbaus, seiner Funktion und seiner Entstehungsgeschichte. *Anat. Anz.* 115: 1-26
- Iwanoff, St., 1940/41: Das Relief des harten Gaumens beim Rind unter Berücksichtigung der Variabilität der Gaumenstaffeln. (Dtsch. Zus.fassg.) *Jb. Univ. Sofia, Vet. med. Fak.* 17: 555-572
- Lassoie, L., 1952: Les sinus osseux de la tête, chez la bête bovine. *Ann. Méd. Vét.* 96: 300-322
- Lauwers, H. and N.R. De Vos, 1966: Innervatie van de hoorn bij het rund in verband met het verloop van de N. ophthalmicus. *Vlaams Diergenesk Tijd.* 35: 451-464
- Lechner, W., 1941: Die A. alveolaris mandibulae beim Wiederkäuer. *Anat. Anz.* 91: 273-320
- Le Roux, J.M.W., 1959: Die Venen am Kopf des Rindes. *Diss. med. vet. Hannover*
- Le Roux, J.M.W. and H. Wilkens, 1972: Zur Angiographie der Kopfarterien des Rindes. *Dtsch. tierärztl. Wschr.* 79: 342-346
- Mc Cormack, J.E., 1974: Variations of the ocular fundus of the bovine species. *Scope* 18: 21-28
- Modes, E., 1936: Das Blutgefäßbild des Augenhintergrundes bei den Haussäugetieren. *Arch. wiss. prakt. Tierheilk.* 70: 449-472
- Mosimann, W., 1954: Die sensiblen Nerven von Horn und Ohrmuschel beim Rind und die Möglichkeit ihrer Anaesthetie. *Schweiz. Arch. Tierheilk.* 96: 463-469
- Müller, A., 1969: Das Bild des normalen Augenhintergrundes beim Rind. *Berl. Münch. Tierärztl. Wschr.* 82: 181-182
- Nickel, R. and R. Schwarz, 1963: Vergleichende Betrachtung der Kopfarterien der Haussäugetiere (Katze, Hund, Schwein, Rind, Schaf, Ziege, Pferd). *Zbl. Vet. Med.* A10: 89-120
- Paulli, S., 1923: Ein Os rostri bei Bos taurus. *Anat. Anz.* 56: 249-252
- Peters, J., 1904: Untersuchungen über die Kopfspeicheldrüsen bei Pferd, Rind und Schwein. *Diss. med. vet. Gießen*
- Pichler, Fr., 1941: Über die Gaumenkeilbeinhöhle des Rindes. *Wien. Tierärztl. Mschr.* 28: 413-414
- Prodinger, F., 1940: Die Artmerkmale des Kehlkopfes der Haussäugetiere (Pferd, Rind, kleine Wiederkäuer, Schwein, Hund, Katze, Kaninchen). *Z. Anat. Entwickl.gesch.* 110: 726-739
- Salomon, S., 1930: Untersuchungen über das Nasolabiogramm des Rindes. *Diss. med. vet. Hannover*
- Schachtschabel, A., 1908: N. facialis und trigeminus des Rindes. *Diss. med. vet. Leipzig*
- Schmidt, K., 1910: Die arteriellen Blutgefäße des Rindes. *Diss. med. vet. Zürich*
- Schmidt, W.J. und H. Sprankel, 1954: Bildet sich im Stratum corneum des Rinderhornes Röhrchenstruktur aus? *Z. Morph. u. Ökol. der Tiere* 42: 449-470
- Schmuck, U., 1986: Die Zunge der Wiederkäuer. Vergleichend-anatomische und histologische Untersuchungen an 42 Haus- und Wildwiederkäuerarten (*Ruminantia scopdi 1777*). *Diss. med. vet. Gießen*
- Schreiber, J., 1955: Die Leitungsanästhesie der Kopfnerven beim Rind. *Wien. Tierärztl. Mschr.* 42: 129-153
- Schreiber, J., 1959: Das Ganglion cervicale superius von Bos taurus. *Morph. Jb.* 99: 821-837
- Somers, M., 1957: Saliva secretion and its function in ruminants. *Australian Vet. J.* 33: 297-301
- Steven, D.H., 1964: The distribution of external and internal ophthalmic arteries in the ox. *J. Anat.* 98: 429-435
- Vollmerhaus, B., 1957: Über tonsilläre Bildungen in der Kehlkopfschleimhaut des Rindes. *Berl. Münch. Tierärztl. Wschr.* 70: 288-290
- Wilhelm, J., 1924: Zur Entwicklungsgeschichte der Hinterhautschuppe des Rindes. *Anat. Anz.* 59: 1-11
- Wilkens, H., 1958: Zur Topographie der Nasenhöhle und der Nasennebenhöhlen beim Rind. *Dtsch. Tierärztl. Wschr.* 65: 580-585, 632-637
- Zhedenov, V.N., 1937: On the question of the obliteration of the internal carotid artery in cattle. (russ.) *Ark. Anat. Histol. Embryol.* 16: 490-508
- Ziegler, H., 1927: Beiträge zum Bau der Unterkieferdrüse der Haussäugetiere: Rind, Ziege und Schaf. *Zschr. Anat.* 82: 73-121
- Zietzschmann, O., 1906: Traubenkörner der Haussäugetiere. *Arch. mikrosk. Anat.* 65: 611-622
- Zietzschmann, O., 1942: Horn und Geweih. *Dtsch. Tierärztl. Wschr.* 50: 55-57

Chapter 4. Central nervous system

- Dellmann, H.D., 1960: Zur makroskopischen Anatomie der subkortikalen Kerne des Telencephalon und des Pallidum beim Rind. *Zbl. Vet. med.* 7: 761-768
- Frewein, J., 1962: Die Partes abdominalis, pelvina und coccygea systematis autonomici und deren periphere Geflechte bei Bos taurus L. *Morph. Jb.* 103: 361-408
- Goller, H., 1958: Vergleichende Rückenmarkstopographie unserer Haustiere. *Tierärztl. Umschau* 4: 107-110
- Goller, H., 1962: Segmentquerschnitte des Rinderrückenmarkes. *Zbl. Vet. Med.* 9: 943-960
- Goller, H., 1965: Zytoarchitektonik der Medulla oblongata des Rindes. Paul Parey, Berlin
- Hopkins, G.S., 1935: The correlation of anatomy and epidural anesthesia in domestic animals. *Ann. Report NYS Vet. College 1934-35:* 46-51
- Kaufmann, J., 1959: Untersuchungen über die Frühentwicklung des Kleinhirns des Rindes. *Diss. med. vet. Bern*
- Lang, K., 1959: Anatomische und histologische Untersuchungen der Epiphysis cerebri von Rind und Schaf. *Diss. med. vet. München*
- Seiferle, E., 1939: Zur Rückenmarkstopographie von Pferd und Rind. *Z. Anat. u. Entwickl.gesch.* 110: 371-384
- Weber, W., 1942: Anatomische-klinische Untersuchungen über die Punktions- und Anästhesiestellen des Rückenmarkes und die Lage des Gehirns beim Rind. *Schweizer Arch. Tierheilk.* 84: 161-173

Chapter 5. Skeleton of the trunk and neck

- Bölk, G., 1961: Ein Beitrag zur Topographie des Rinderhalses. *Diss. med. vet. Berlin*
- Donat, K., 1972: Der M. cucullaris und seine Abkömmlinge (M. trapezius und M. sternocleidomastoideus) bei den Haussäugetieren. *Anat. Anz.* 131: 286-297
- Frewein, J., 1970: Die Haemapophysen an den Schwanzwirbeln von Katze, Hund und Rind. *Zbl. Vet. Med.* A17: 565-572
- Hagström, M., 1921: Die Entwicklung des Thymus beim Rind. *Anat. Anz.* 53: 545-566
- Luckhaus, G., 1966: Die Pars cranialis thymi beim fetalen Rind. *Morphologie, Topographie, äußere Blutgefäßversorgung und entwicklungsgeschichtliche Betrachtungen.* *Zbl. Vet. Med.* A13: 414-427
- Mietzner, C., 1920: Die Dornfortsätze des Rindes. *Diss. med. vet. Leipzig*
- Smuts, M.M.S., 1974: The foramina of the cervical vertebrae of the ox. Part I: Atlas and Axis. *Zbl. Vet. Med.* C3: 289-295
- Smuts, M.M.S., 1975: The foramina of the cervical vertebrae of the ox. Part II: Cervical vertebrae 3-7. *Zbl. Vet. Med.* C4: 24-37
- Smuts, M.M.S., 1976: Mm. intertransversarii cervicis of the ox (Bos taurus L.). *Zbl. Vet. Med.* C5, 135-146
- Smuts, M.M.S. and J.M.W. le Roux, 1975: Mm. scaleni of the ox (Bos taurus L.). *Zbl. Vet. Med.* C4: 256-267
- Smuts, M.M.S. and J.M.W. le Roux, 1976: Areas of muscular attachment and their correlation with foraminous area of the cervical vertebrae of the ox (Bos taurus L.). *Zbl. Vet. Med.* C5: 253-266
- Stuckrad, U. v., 1954: Zur Statik der Wirbelsäule des Rindes. (Speziell über den Richtungswechsel des Dornfortsatzes des 7. Halswirbels). *Diss. med. vet. Freie Universität Berlin*

Chapter 6. Thoracic cavity

- Agduhr, E., 1927/28: Morphologische Beweise für das Vorhandensein intra-vitaler Kommunikationen zwischen den Kavitäten der Pleurasäcke bei einer Reihe von Säugetieren. *Anat. Anz.* 64: 276-298
- Barone, R., 1956: Bronches et vaisseaux pulmonaires chez le boeuf (Bos taurus). *C.R. Assoc. Anat. Lisbonne*
- Barone, R. et A. Collin, 1951: Les artères du coeur chez les ruminants domestiques. *Rev. Méd. Vét.* 102: 172-181
- Baum, H., 1911: Die Lymphgefäße der Pleura costalis des Rindes. *Z. f. Infektionskrankh. d. Haust.* 9: 375-381
- Bühling, H., 1943: Die Venae pulmonales des Rindes. *Diss. med. vet. Hannover*
- Bürgi, J., 1953: Das grobe Bindegewebsgerüst in der Lunge einiger Haussäuger (Rind, Schwein, Pferd, Ziege, Schaf, Hund und Katze) mit besonderer Berücksichtigung der Begrenzung des Lungenläppchens. *Diss. med. vet. Zürich*

- Calka, W., 1967: Bronchial arteries with extrapulmonary course in domestic cattle. *Folia Morph.* Warszawa 26: 359-367
- Calka, W., 1969: Präkapilläre Anatomosen zwischen der A. bronchialis und der A. pulmonalis in den Lungen von Hausrindern. *Folia morphol.* Warszawa 28: 65-74
- Calka, W., 1969: The blood supply of the lungs through direct branches of the aorta in domestic cattle. *Folia Morphol.* Warszawa 28: 442-450
- Fize, M., 1965: Anatomie der Lungen und des Bronchialgefäßbaumes bei Wiederkäuern. Thèse doct. vét. Lyon.
- Grau, H., 1933: Beiträge zur vergleichenden Anatomie der Azygosvenen bei unseren Haustieren (Pferd, Hund, Rind, Schwein) und zur Entwicklung der Azygosvenen des Rindes. *Z. Anat. Entwicklgesch.* 100: 119-148, 256-276, 295-329
- Hausotter, E., 1924: Das Herzskelett der Haussäuger Pferd, Rind, Schaf, Schwein, Hund u. Katze. *Wien. Tierärztl. Mschr.* 11: 311
- Hegazi, A. el H., 1958: Die Blutgefäßversorgung des Herzens von Rind, Schaf und Ziege. *Zbl. Vet. Med.* 5: 776-819
- Koch, T. und R. Berg, 1961: Die mediastinalen Pleuraumschlagslinien am Sternum und das Lig. sterno- bzw. phrenicopericardiacum bei einigen Haustieren. *Anat. Anz.* 110: 116-126
- Palmgren, A., 1928: Herzgewicht und Weite der Ostia atrioventricularia des Rindes. *Anat. Anz.* 65: 333-342
- Schorno, E., 1955: Die Lappen und Segmente der Rinderlunge und deren Vaskularisation. *Diss. med. vet.* Zürich
- Schmack, K.-H., 1975: Die Ventilebene des Herzens bei Pferd, Rind und Hund. *Diss. med. vet.* Gießen
- Seiferle, E., 1956: Grundsätzliches zu Bau und Benennung der Haussäugerlunge. *Okajima's Folia Anat. Jap.* 28: 71-81
- Simoens, P., N.R. De Vos and H. Lauwers, 1978/79: Illustrated anatomical nomenclature of the heart and the arteries of head and neck in the domestic mammals. *Mededel. Fac. Diergeneesk. Rijksuniv. Gent*, 21: 1-100
- Stamp, J.T., 1948: The distribution of the bronchial tree in the bovine lung. *J. Comp. Path.* 58: 1-8
- Stroh, G., 1923: Untersuchungen an Rinderherzen über das Offenbleiben des Foramen ovale. *Münch. Tierärztl. Wschr.* 74: 293-297
- Strubelt, H., 1925: Anatomische Untersuchungen über den Verschluss und die Rückbildung des Ductus Botalli bei Kälbern und Rindern. *Diss. med. vet.* Berlin
- Vaerst, G., 1888: Vorkommen, anatomische und histologische Entwicklung der Herzknochen bei Wiederkäuern. *Dtsch. Z. Thiermed. vergl. Path.* 13: 46-71
- Ziegler, H. und H. Hauser, 1939: Anatomie für die Praxis. II. Zur Lage der Speiseröhre und intrathorakalen Bauchorgane beim Rind. *Schweiz. Arch. Tierheilk.* 81: 366-390
- Zsebök, Z., A. Székely und E. Nagy, 1955: Beiträge zur Anatomie des Bronchialsystems und der Lungenangioarchitektur des Rindes. *Acta vet. acad. sci. Hung.* 5: 307-332
- Chapter 7. Abdominal wall and abdominal cavity**
- Arnold, J.P. and R.L. Kitchel, 1957: Experimental studies of the innervation of the abdominal wall of cattle. *Amer. J. Vet. Res.* 18: 229-240
- Baum, H., 1911: Die Lymphgefäße der Milz des Rindes. *Z. f. Infektionskh. d. Haust.* 10: 397-407
- Christ, H., 1930: Nervus vagus und die Nervengeflechte der Vormägen der Wiederkäuer. *Z. Zellforsch.* 11: 342-374
- Dietz, O. et al., 1970: Untersuchungen zur Vagusfunktion, zur Vagusbeeinflussung und zu Vagusausfällen am Verdauungsapparat des erwachsenen Rindes. *Arch. Exp. Veterinärmed.* 24: 1385-1439
- Eichel, J., 1925: Maße, Formen und Gewichte der Lebern von Rindern und Schafen. *Diss. med. vet.* Berlin
- Florentin, P., 1953: Anatomie topographique des viscères abdominaux du boeuf et du veau. *Rev. Méd. Vét.* 104: 464-493
- Geyer, H., G. Aberger und H. Wissdorf, 1971: Beitrag zur Anatomie der Leber beim neugeborenen Kalb. Topographische Untersuchungen mit Darstellung der Gallenwege und der intrahepatischen Venen. *Schweiz. Arch. Tierheilk.* 113: 577-586
- Ghoshal, N.G. and R. Getty, 1968: The arterial blood supply to the appendages of the ox (*Bos taurus*). *Iowa State J. Sci.* 43: 41-70
- Grau, H., 1955: Zur Funktion der Vormägen, besonders des Netzmagens der Wiederkäuer. *Berl. Münch. Tierärztl. Wschr.* 15: 271-278
- Grau, H. und P. Walter, 1957: Über die feinere Innervation der Vormägen der Wiederkäuer. *Acta anat.* 31: 21-35
- Grossman, J.D., 1949: Form, development and topography of the stomach of the ox. *J. Amer. Vet. Med. Assoc.* 114: 416-418
- Habel, R.E., 1956: A Study of the innervation of the Ruminant Stomach. *The Cornell Vet.* 46 (4): 555-633
- Harms, D., 1966: Über den Bau und Verschluss des Ductus arteriosus Botalli der Rinder. *Z. Zellforsch.* 72: 344-363
- Hofmann, R.R., 1976: Zur adaptiven Differenzierung der Wiederkäuer; Untersuchungsergebnisse auf der Basis der vergleichenden funktionellen Anatomie des Verdauungstraktes. *Prakt. Tierarzt* 57: 351-358
- Hummel, R. und B. Schnorr, 1982: Das Blutgefäßsystem des Dünndarms vom Wiederkäuer. *Anat. Anz.* 151: 260-280
- Jones, R.S., 1962: The position of bovine abomasum. An abattoir survey. *Vet. Rec.* 74: 159-163
- Koch, T., 1954: Die Innervation der Bauchdecke des Rindes. *Mhefte Vet.-Med.* 9: 541-544
- Lagerlöf, N., 1929: Investigations of the topography of the abdominal organs in cattle and some clinical observations and remarks in connection with the subject. *Skand. Veterinärtidskr.* 19: 253-265
- Lambert, P.S., 1948: The development of stomach in the ruminant. *Vet. J.* 104: 302-310
- Lauwers, H., N.R. De Vos et H. Teuchy, 1975: La vascularisation du feuillet du boeuf. *Zbl. Vet. Med. C* 4: 289-306
- Maala, C.P. and W.O. Sack, 1981: The arterial supply to the ileum, cecum and proximal loop of the ascending colon in the ox. *Zbl. Vet. Med. C Anat. Histol. Embryol.* 10: 130-146
- Maala, C.P. and W.O. Sack, 1983: The venous supply of the cecum, ileum and the proximal loop of the ascending colon in the ox. *Zbl. Vet. Med. C Anat. Histol. Embryol.* 12: 154-166
- Martin, P., 1890: Zur Entwicklung der Bursa omentalis und der Mägen beim Rinde. *Österr. Mschr. Tierheilk.* 14: 49-61
- Martin, P., 1890/91: Die Entwicklung des Wiederkäuermagens und -Darmes. *Festschr. f. K.W. Naegeli u. A. v. Kölliker, Albert Müllers Verlag, Zürich*
- Martin, P., 1895: Zur Entwicklung des Netzbeutels der Wiederkäuer. *Österr. Mschr. Tierheilk.* 19: 145-154
- Martin, P., 1896: Die Entwicklung des Wiederkäuermagens. *Österr. Mschr. Tierheilk.* 21: 385-400, 433-444
- Moritz, A., 1957: Verlauf und Verbreitung der Nervi vagi am Rindermagen. *Diss. med. vet.* Wien
- Morrison, A.R. and R.E. Habel, 1964: A quantitative study of the distribution of vagal nerve endings in the myenteric plexus of the ruminant stomach. *J. Comp. Neurol.* 122: 297-309
- Nickel, R. u. H. Wilkens, 1955: Zur Topographie des Rindermagens. *Berl. Münch. Tierärztl. Wschr.* 68: 264-271
- Pernkopf, E., 1931: Die Entwicklung des Vorderdarmes, insbesondere des Magens der Wiederkäuer. *Z. Anat. Entwickl.gesch.* 94: 490-622
- Pospieszny, N., 1979: Die Versorgung des Magens und einiger Lymphknoten durch den Nervus vagus beim Schaf in der pränatalen Periode. *Anat. Anz.* 146: 47-59
- Sack, W.O., 1971: Das Blutgefäßsystem des Labmagens von Rind und Ziege. *Diss. med. vet. München, Zbl. Vet. Med. C1*: 27-54 (1972)
- Schaller, O., 1956: Die periphere sensible Innervation der Haut am Rumpfe des Rindes. *Wien. Tierärztl. Mschr.* 43: 346-368, 534-561
- Schnorr, B. u. B. Vollmerhaus, 1967: Das Oberflächenrelief der Pansenschleimhaut bei Rind und Ziege. I. Mitteilung zur funktionellen Morphologie der Vormägen der Hauswiederkäuer. *Zbl. Vet. Med. A14*: 93-104
- Schnorr, B. und B. Vollmerhaus, 1968: Das Blutgefäßsystem des Pansens von Rind und Ziege. IV. Mitt. zur funktionellen Morphologie der Vormägen der Hauswiederkäuer. *Zbl. Vet. Med. A* 15: 799-828
- Schreiber, J., 1953: Topographisch-anatomischer Beitrag zur klinischen Untersuchung der Rumpfeingeweide des Rindes. *Wien. Tierärztl. Mschr.* 40: 131-144
- Schreiber, J., 1955: Die anatomischen Grundlagen der Leitungsanaesthesie des Rindes. II. Teil: Die Leitungsanaesthesie der Rumpfnerven. *Wien. Tierärztl. Mschr.* 42: 471-491
- Schummer, A., 1932: Zur Formbildung und Lageveränderung des embryonalen Wiederkäuermagens. *Diss. med. vet. Gießen Z. Anat. Entwickl.gesch.* 99: 265-303
- Schwarz, E., 1910: Zur Anatomie und Histologie des Palters der Wiederkäuer. *Diss. med. vet. Bern*
- Seidler, D., 1966: Arterien und Venen der Körperwand des Rindes. *Diss. med. vet. Hannover*
- Smith, D. F., 1984: Bovine intestinal surgery, Part I, *Mod. Vet. Pract.*, 65: 705-710
- Smith, R.N. and G.W. Meadows, 1956: The arrangement of the ansa spiralis of the ox colon. *J. Anat.* 90: 523-526
- Spörri, H., 1951: Physiologie der Wiederkäuer-Vormägen. *Schweiz. Arch. Tierheilk.* 93: 1-28
- Walter, P., 1959: Die Innervation der Flankengegend des Rindes. *Tierärztl. Umschau* 14: 302-304
- Warner, E.D., 1958: The organogenesis and early histogenesis of the bovine stomach. *Am. J. Anat.* 102: 33-63
- Warner, R.G. and W.P. Flatt, 1965: Anatomical development of the ruminant stomach. In: *Physiology of digestion in the ruminant.* Butterworth Inc., Washington, D.C.
- Wass, W.M., 1965: The duct systems of the bovine and porcine pancreas. *Am. J. Vet. Res.* 26: 267-272
- Wensing, C.J.G., 1968: Die Innervation des Wiederkäuermagens. *Tijdschr. Diergeneesk.* 93: 1352-1360
- Wester, J., 1930: Der Schlundrinnenreflex beim Rind. *Berl. Tierärztl. Wschr.* 46: 397-402

- Williamson, M.E., 1967: The venous and biliary systems of the bovine liver. M.S. Thesis, Cornell Univ. Ithaca
- Ziegler, H., 1934: Anatomie für die Praxis. I. Von den Vormägen des Rindes. Schweiz. Arch. Tierheilk. 76: 449-461
- Chapter 8. Pelvic cavity, inguinal region, and urogenital organs**
- Amselgruber, W. und F.-H. Feder, 1986: Licht- und elektronenmikroskopische Untersuchungen der Samenblasendrüse (Glandula vesicularis) des Bullen. Anat. Histol. Embryol. 15: 361-379
- Ashdown, R.R., 1958: The arteries and veins of the sheath of the bovine penis. Anat. Anz. 105: 222-230
- Ashdown, R.R., 1971: Angioarchitecture of the sigmoid flexure of the bovine corpus cavernosum penis and its significance in erection. J. Anat. 106: 403-404
- Ashdown, R.R. and M.A. Coombs, 1968: Experimental studies on spiral deviation of the bovine penis. Vet. Rec. 82: 126-129
- Ashdown, R.R. and H. Gilanpour, 1974: Venous drainage of the corpus cavernosum penis in impotent and normal bulls. J. Anat. 117: 159-170
- Ashdown, R.R. and H. Pearson, 1973: Studies on "corkscrew" penis in the bull. Vet. Rec. 93: 30-35
- Ashdown, R.R.; S.W. Ricketts and R.C. Wardley, 1968: The fibrous architecture of the integumentary covering of the bovine penis. J. Anat. 103: 567-572
- Ashdown, R.R. and J.A. Smith, 1969: The anatomy of the corpus cavernosum penis of the bull and its relationship to spiral deviation of the penis. J. Anat. 104: 153-160
- Barone, R., 1957: La vascularisation utérine chez quelques mammifères. Assoc. Anat. C.R. 44: 124-131
- Barone, R. und B. Blavignac, 1964: Les vaisseaux sauguins des reins chez le boeuf. Bull. Soc. Vét., Lyon 66: 114-130
- Becker, R.B. and P.T. Dix Arnold, 1942: Circulatory system of the cow's udder. Fla. Agric. Exp. Sta. Bull. 379: 1-18
- Bjoerkman, N. and G. Bloom, 1957: On the fine structure of the fetal-maternal junction in the bovine placentome. Z. Zellforsch. 45: 649-659
- Blavignac, B., 1964: Recherche sur la vascularisation et l'innervation des reins chez le boeuf. Thèse doct. vét. Lyon
- Böhm, A., 1969: Zur Innervation der Glans penis beim Rind. Diss. med. vet. München
- Bressou, C. et J. le Gall, 1936: Contribution à l'étude de la vascularisation de l'utérus des ruminants. Recueil Méd. vét. 112: 5-9
- Brown, R.E. and R.E. Carrow, 1963: Vascular anatomy of the bovine tail. J. Amer. vet. med. Ass. 156: 1026-1029
- Budras, K.-D., F. Preuss, W. Traeder et al., 1972: Der Leistenspalt und die Leistenringe unserer Haussäugetiere in neuer Sicht. Berl. Münch. Tierärztl. Wschr. 22: 427-431
- Comuri, N., 1972: Untersuchungen über zyklusabhängige Strukturveränderungen am distalen Gangsystem der Milchdrüse des Rindes. Diss. med. vet. Gießen
- Daigo, M., Y. Sato, M. Otsuka et al., 1973: Stereoroentgenographical studies on the peripheral arteries of the udder of the cow. Bull. Nippon vet. zootech. Coll. 22: 31-39
- Desjardins, C. and H.D. Hafs, 1969: Maturation of bovine female genitalia from birth through puberty. J. Anim. Sci. 28: 502-507
- Dohm, H., 1936: Anatomische Unterschiede an den Geschlechtsorganen von Kalb und Kuh. Diss. med. vet., Leipzig
- Drothler, G., 1977: Makroskopisch-morphologische Grundlagen des Descensus testicularum beim Rind (Fotografischer Atlas des bovines Hodenabstiegs). Diss. med. vet. Gießen
- Edwards, M.J., 1965: Observations on the anatomy of the reproductive organs of cows. With special reference to those features sought during examination per rectum. New Zealand Vet. J. 13: 25-37
- Egli, A., 1956: Zur funktionellen Anatomie der Bläschrüse (Glandula vesiculosa) des Rindes. Acta anat. 28: 359-381
- El Hagri, M.A.A.M., 1945: Study of the arterial and lymphatic system in the udder of the cow. Vet. J. 101: 27-33, 51-63, 75-88
- Erasha, A.M.M., 1987: Topographisch-anatomische Untersuchung zur Homologisierung der Arterien des Perineums beim Rind. Diss. Med. vet. Hannover
- Erickson, B.H., 1966: Development and senescence of the postnatal bovine ovary. J. Anim. Sci. 25: 800-805
- Fabisch, H., 1968: Die operative Entfernung von Harnleitersteinen bei Kühen. Wien. Tierärztl. Mschr. 55: 409-411
- Fehér, G. und A. Haraszti, 1964: Beiträge zur Morphologie und zu den altersbedingten Veränderungen der akzessorischen Geschlechtsdrüsen von Stieren. Acta vet., Budapest 14: 141-145
- Fricke, E., 1968: Topographische Anatomie der Beckenorgane bei Haussäugetieren (Pferd, Rind, Schaf, Ziege, Schwein, Hund, Katze). Diss. med. vet. Berlin
- Garcia, O.S.; M. de Almeida and J. Biondini, 1965: Anatomical study of the terminal parts of the excretory ducts of the vesicula seminalis and the ductus deferens in cattle. Arqu. Esc. Vet. 17: 76-82
- Geiger, G., 1954: Die anatomischen Grundlagen des "Hymenalringes" beim Rinde. Tierärztl. Umschau 9: 398-403
- Ghoshal, N.G., and R. Getty, 1967: Applied anatomy of the sacrococcygeal region of the ox as related to tail-bleeding. Vet. Med.-SAC 62: 255-264
- Glättli, H., 1924: Anatomie des Venensystems des Kuheuters. Diss. med. vet. Zürich
- Godina, G., 1939: Le fosse ischio-rettale dei bovini. Nouvo Ercolani 44: 353-363
- Goyal, H.O., 1985: Morphology of the bovine epididymis. Amer. J. Anat. 172: 155-172
- Habel, R.E., 1956: A source of error in the bovine pudendal nerve block. J. Amer. Vet. Med. Assoc. 128: 16-17
- Habel, R.E., 1966: The topographic anatomy of the muscles, nerves and arteries of the bovine female perineum. Am. J. Anat. 119: 79-96
- Habel, R.E. and K.-D. Budras, 1992: Anatomy of the praepubic tendon in the horse, cow, sheep, goat and dog. Am. J. Vet. Res. 53: 2183-2195
- Hampl, A., 1965: Lymphonodi intramammarii der Rindermilchdrüse. I. Makroskopisch-anatomische Verhältnisse. Anat. Anz. 116: 281-298
- Hampl, A., 1967: Die Lymphknoten der Rindermilchdrüse. Anat. Anz. 121: 38-54
- Harris, G.W., 1958: The central nervous system, neurohypophysis and milk ejection. Proc. Roy. Soc. B 149: 336-353
- Heinemann, K., 1937: Einige Muskeln des männlichen Geschlechtsapparates der Haussäugetiere (M. bulbocavernosus, M. ischiocavernosus, M. retractor penis). Diss. vet. med. Hannover
- Heinze, W. und W. Lange, 1965: Beitrag zum artifiziellen Penisprolaps unter besonderer Berücksichtigung der anatomischen Verhältnisse beim Bullen. Mh. Vet. Med. 20: 402-412
- Heinze, W. und W. Ptak, 1976: Vergleichende morphologische Untersuchungen am Blutgefäßsystem des Hodens von Rind, Schwein, Pferd und Hund unter funktionellen Aspekten. Arch. exp. Vet. Med. 30: 669-685
- Henneberg, B., 1905: Abortivzitzen des Rindes. Anat. Hefte 1: 25
- Hilliger, H.-G., 1957: Zur Uterus-Karunkel des Rindes und ihrer Vaskularisation unter Berücksichtigung der zuführenden Uterusgefäße. Diss. med. vet. Berlin u. Zbl. Vet. Med. A5: 51-82 (1958)
- Höfliger, H., 1943: Die Ovarialgefäße des Rindes und ihre Beziehungen zum Ovarialzyklus. Berl. Münch. Tierärztl. Wschr. 1943: 179
- Höfliger, H., 1948: Das Ovar des Rindes in den verschiedenen Lebensperioden unter besonderer Berücksichtigung seiner funktionellen Feinstruktur. Acta anat., Suppl. 5: 1-196
- Höfliger, H., 1952: Drüsenaplasie und -hypoplasie in Eutervierteln des Rindes - eine erblich bedingte Entwicklungsanomalie. Schweiz. Arch. Tierheilkd. 94: 824-833
- Hofmann, R.R., 1960: Die Gefäßarchitektur des Bullenhodens, zugleich ein Versuch ihrer funktionellen Deutung. Zbl. Vet. Med. A7: 59-93
- Kainer, R.A.; L.C. Faulkner and R.M. Abdel-Raouf, 1969: Glands associated with the urethra of the bull. Am. J. Vet. Res. 30: 963-974
- Koch, T., 1956: Die Milchdrüse (Glandula lactifera, Mamma) des Rindes. Mhefte Vet.-Med. 11: 527-532
- Küng, W.B., 1956: Weiterer Beitrag zur Kenntnis einer erblich bedingten Drüsenaplasie - und -hypoplasie in Eutervierteln des Rindes. Diss. med. vet. Zürich
- Lamond, D.R. and M. Drost, 1974: Blood supply to the bovine ovary. J. Anim. Sci. 38: 106-112
- Larson, L.L., 1953: The internal pudendal nerve block for anesthesia of the penis and relaxation of the retractor penis muscle. J. Amer. Vet. Med. Ass. 123, 18-27
- Larson, L.L. and R.L. Kitchel, 1958: Neural mechanisms in sexual behavior. II. Gross neuroanatomical and correlative neurophysiological studies of the external genitalia of the bull and ram. Am. J. Vet. Res. 19: 853-865
- Lewis, J.E.; D.F. Walker; S.D. Beckett and R.I. Vachon, 1968: Blood pressure within the corpus cavernosum penis of the bull. J. Reprod. Fertil. 17: 155-156
- Le Roux, J.M.W. and Wilkens, 1959: Beitrag zur Blutgefäßversorgung des Euters der Kuh. Dtsch. tierärztl. Wschr. 66: 429-435
- Linzell, J.L., 1960: Valvular incompetence in the venous drainage of the udder. J. Physiol. 153: 481-491
- Long, S.E., and P.G. Hignett, 1970: Preputial eversion in the bull - a comparative study. Vet. Rec. 86: 161-164
- Mac Millan, K.L. and H.D. Hafs, 1969: Reproductive tract of Holstein bulls from birth through puberty. J. Anim. Sci. 28: 233-239
- Meissner, R., 1964: Beiträge über den anatomischen Bau des elastisch-muskulösen Systems der Rinderzitze. Diss. med. vet. Berlin
- Merkt, H., 1948: Die Bursa ovarica der Katze. Mit einer vergleichenden Betrachtung der Bursa ovarica des Hundes, Schweines, Rindes und Pferdes sowie des Menschen. Diss. med. vet. Hannover
- Mosimann, W., 1949: Zur Anatomie der Rindermilchdrüse und über die Morphologie ihrer sezernierenden Teile. Diss. med. vet. Bern, Acta anat. 8: 347-378

- Mosimann, W., 1969: Zur Involution der bovinen Milchdrüse. Schweiz. Arch. Tierheilkd. 111: 431-439
- Neuhaus, U., 1956: Die Bedeutung des Oxytocins für die Milchsekretion. Dtsch. Tierärztl. Wschr. 63: 467-496
- Nickel, R., 1954: Zur Topographie der akzessorischen Geschlechtsdrüsen bei Schwein, Rind und Pferd. Tierärztl. Umschau 9: 386-388
- Nitschke, Th. und F. Preuss, 1971: Die Hauptäste der A. iliaca interna bei Mensch und Haussäugetieren in vergleichend-anatomisch häufiger Reihenfolge. Anat. Anz. 128: 439-453
- Oelrich, T.M., 1980: The urethral sphincter muscle in the male. Am. J. Anat. 158: 229-246
- Oelrich, T.M., 1983: The striated urogenital sphincter muscle in the female. Anat. Rec. 205: 223-232
- Otto, A., 1930: Beiträge zur Anatomie der Cervix uteri des trächtigen Rindes. Diss. med. vet. Hannover
- Pastea, E., 1973: Contribution à l'étude macroscopique de l'innervation et de la vascularisation des glandes surrénales chez le boeuf. Anat. Anz. 134: 120-126
- Perk, K., 1957: Über den Bau und das Sekret der Glandula bulbourethralis (Cowperi) von Rind und Katze. Diss. med. vet. Bern
- Popesko, P., 1965: Vaskularisation des Hodens des Bullen: A. spermatica interna. (slowak.) Folia vet. 9: 137-146
- Porthan, L., 1928: Morphologische Untersuchungen über die Cervix uteri des Rindes mit besonderer Berücksichtigung der Querfaltenbildung und des Kanalverlaufs. Diss. med. vet. Leipzig
- Preuss, F., 1953: Beschreibung und Einteilung des Rinderuterus nach funktionellen Gesichtspunkten. Anat. Anz. 100: 46-64
- Preuss, F., 1954: Die Tunica albuginea penis und ihre Trabekel bei Pferd und Rind. Anat. Anz. 101: 64-83
- Preuss, F., 1959: Die A. vaginalis der Haussäugetiere. Berl. Münch. Tierärztl. Wschr. 72: 403-406
- Reuber, H.W. and M.A. Emerson, 1959: Arteriography of the internal genitalia of the cow. J. Am. Vet. Med. Assoc. 134: 101-109
- Röder, O., 1898: Über die Gartnerschen Gänge beim Rind. Arch. wiss. prakt. Tierheilk. 24: 135-141
- Rubeli, O., 1913: Besonderheiten im Ausführungsgangsystem der Milchdrüsen des Rindes. Mitt. nat.forsch. Ges. Bern
- Rubeli, O., 1914: Bau des Kuheuters. Verl. Art. Inst. Orell Füssli, Zürich
- Ruoss, G., 1965: Beitrag zur Kenntnis der Euterarterien des Rindes mit besonderer Berücksichtigung der Beziehung zwischen Feinbau und Funktion. Diss. med. vet. Zürich
- Schenker, J., 1950: Zur funktionellen Anatomie der Prostata des Rindes. Acta anat. 9: 69-102
- Schlumperger, O.-R.V., 1954: Der Nebenhoden und seine Lage zum Hoden bei Rind, Schaf und Ziege. Diss. med. vet. Hannover
- Schummer, A. und B. Vollmerhaus, 1960: Die Venen des trächtigen und nichtträchtigen Rinderuterus als Blutstrom regulierendes funktionelles System. Wien. Tierärztl. Mschr. 47: 114-138
- Seidel, G.E., and R.H. Foote, 1967: Motion picture analysis of bovine ejaculation. J. Dairy Sci. 50: 970-971
- Seiferle, E., 1933: Über Art- und Altersmerkmale der weiblichen Geschlechtsorgane unserer Haussäugetiere: Pferd, Rind, Kalb, Schaf, Ziege, Kaninchen, Meerschweinchen, Schwein, Hund und Katze. Z. ges. Anat. 101: 1-80
- Seiferle, E., 1949: Neuere Erkenntnisse über Bau und Funktion der Milchdrüse der Kuh. Schriften d. Schweiz. Vereinigung f. Tierzucht, Euter u. Milchleistung. Banteli AG, Bern-Bümpliz
- Skjervold, H., 1961: Überzählige Zitzen bei Rindern. Hereditas, Lund 46: 1960, Landw. Zbl.: 1156
- Smollich, A., 1958: Gestalt, Topographie, Masse und Gewichtsverhältnisse der Nebennieren des Rindes. Anat. Anz. 105: 205-221
- St. Clair, L.E., 1942: The nerve supply to the bovine mammary gland. Amer. J. Vet. Med. Assoc. 129: 405-409
- Tgetgel, B., 1926: Untersuchungen über den Sekretionsdruck und über das Einschleusen der Milch in das Euter des Rindes. Diss. med. vet. Zürich
- Thon, H., 1954: Zur Struktur der Hodensackwand des Rindes. Diss. med. vet. München
- Traeder, W., 1968: Zur Anatomie der Leistengegend des Rindes. Diss. med. vet. Freie Universität Berlin
- Überschär, S., 1961: Zur makroskopischen und mikroskopischen Altersbestimmung am Corpus luteum des Rindes. Diss. med. vet. Hannover
- Vau, E., 1960: Die Blutabflußwege des Kuheuters. Wien. Tierärztl. Mschr., Festschr. Prof. Schreiber: 312-319
- Vierling, R., 1956: Das Zwischenhirn-Hypophysensystem und die Laktation. Z. Tierzüchtg., Zücht. – Biol. 66: 317-322
- Vollmerhaus, B., 1963: Die Arteria und Vena ovarica des Hausrindes als Beispiel einer funktionellen Koppelung viszeraler Gefäße. Anat. Anz. 112: Erg. H. 258-264
- Vollmerhaus, B., 1964: Gefäßarchitektonische Untersuchungen am Geschlechtsapparat des weiblichen Hausrindes (Bos primigenius f. taurus, L. 1758.) Teil I u. Teil II Zbl. Vet. Med. A 11: 538-596, 597-646
- Weber, A.F., 1955: The identity and characterization of the smallest lobule unit in the udder of the dairy cow. Am. J. Vet. Res. 16: 255-263
- Wille, K.-H., 1966: Das Blugefäßsystem der Niere des Hausrindes. (Bos primigenius f. taurus, L., 1758) Diss. med. vet. Gießen
- Wille, K.-H., 1968: Gefäßarchitektonische Untersuchungen an der Nierenkapsel des Rindes. (Bos primigenius f. taurus, L.). Zbl. Vet. Med. A15: 372-381
- Yamauchi, S. and F. Sasaki, 1970: Studies on the vascular supply of the uterus of a cow. Jap. J. Vet. Sci. 32: 59-67
- Ziegler, H., 1954: Zur Hyperthelie und Hypermastie (überzählige Zitzen und Milchdrüsen) beim Rind. Schweiz. Arch. Tierheilkd. 96: 344-350
- Ziegler, H., 1959: Das Lymphgefäßsystem der Rindermilchdrüse und dessen Bedeutung für die Milchsekretion. Bull. Schweiz. Akad. med. Wiss. 15: 105-120
- Zietzschmann, O., 1910: Bau und Funktion der Milchdrüse. In: Grimmer, W. (Ed.): Chemie und Physiologie der Milch. Paul Parey Berlin
- Zietzschmann, O., 1917: Die Zirkulationsverhältnisse des Euters einer Kuh. Dtsch. Tierärztl. Wschr. 25: 361-365
- Zingel, S., 1959: Untersuchungen über die renkulare Zusammensetzung der Rinderniere. Zool. Anz. 162: 83-99
- Zwart, S.G., 1911: Beiträge zur Anatomie und Physiologie der Milchdrüse des Rindes. Diss. med. vet. Bern

Anatomical aspects of bovine spongiform encephalopathy

- Borchers, K., 2002: TSE, Alte Krankheiten mit neuer Brisanz. Berl. Münch. Tierärztl. Wschr.; 115: 81-90
- Editorial, Jour. Am. Vet. Med. Assoc. 2002; 221: 1670
- Eggers, T., S. Buda, K.-D. Budras, R. Fries, G. Hildebrandt und K. Rauser, 2001: Ganglien als Risikomaterial in der Fleischgewinnung. Proc. 42. Arbeitstagung des Arbeitsgebietes Lebensmittelhygiene der Deutschen Veterinärmedizinischen Gesellschaft, Garmisch-Partenkirchen, 25.-28.09.2001
- Hörnlimann, B., D. Riesner, H. Kretzschmar (Hrsg.), 2001: Prionen und Prionkrankheiten. DeGruyter
- Mabbott, N.A., and M.E. Bruce, 2001: The immunobiology of TSE diseases. Journal of General Virology, 82: 2307 – 2318
- McBride, P.A., W.J. Schulz-Schaeffer, M. Donaldson, M. Bruce, H. Diringer, H.A. Kretzschmar, M. Beekes, 2001: Early spread of scrapie from the gastrointestinal tract to the central nervous system involves autonomic fibers of the splanchnic and vagus nerves. J Virol. Oct; 75 (19): 9320-7
- Sigurdson, C.J., T.R. Spraker, M.W. Miller, 2001: PrP^{CWD} in the myenteric plexus, vagosympathetic trunk, and endocrine glands of deer with chronic wasting disease. Jour. General Virology 82: 2327-2334
- U.S. Dept. of Agriculture, Animal and Plant Health Inspection Service, 2001: Washington, D.C. 20250
- Venturini, M., P. Simoens, C. de Jaeger, 2000: Obductie van Runderherseenen voor het BSE-Onderzoek. Vlaams diergeneesk. Tijdschr. 69: 377-381

INDEX

- A**
- Abdominal muscles 111
- Abdominal organs 68
- Abdominal wall 66
- dorsolateral 68
 - ventrolateral 68
- Abomasum
- abomasal folds 70
 - abomasal groove 70
 - angle 68, 70
 - body 68, 70
 - fundus 68, 70
 - greater curvature 70
 - lesser curvature 70
 - parietal surface 70
 - pyloric antrum 70
 - pyloric canal 70
 - pyloric part 68, 70
 - pylorus 70
 - visceral surface 70
- Accessory genital glands
- ampulla of the ductus deferens 92
 - bulbourethral gland 92
 - prostate 92
 - body 92
 - disseminate part 92
 - vesicular gland 92
- Accessory organs of eye 40
- Acromion 2
- Adhesion, interthalamie 50
- Adrenal glands 82
- Age indicated by teeth 32
- Anal triangle 94
- Angle, iridocorneal 42
- Aorta 20
- Apex linguae 44
- Aqueduct, cerebral 50
- Arch
- deep palmar 6
 - palatoglossal 6
 - palatopharyngeal 44, 46
 - supf. palmar 46
- Area cribrosa 42
- Artery(ies)
- abdominal aorta 84
 - accessory reticular 72
 - adrenal br. 72
 - alveolar, inf. 36
 - antebrachial
 - cran. supf. 5, 6, 9
 - deep 6
 - Aorta 20
 - arch 64
 - auricular, caudal 36, 48
 - axillary 6
 - bicarotid trunk 64
 - bicipital 4, 6
 - brachial 6
 - deep brachial 6
 - brachiocephalic trunk 64
 - bronchoesophageal
 - bronchial branch 64
 - esophageal branch 64
 - carotid
 - common 48, 60
 - external 36, 48
 - internal 48, 50
 - carpal
 - dorsal br. 5
 - dorsal network 6
 - caudal pancreaticoduodenal 76
 - caudal epigastric 78
 - caudal gluteal 84
 - caudal mesenteric 76
 - caudal rectal 94
 - caudal superficial epigastric 84
 - caudal vesical 84
 - cecal
 - antimesenteric ileal br 76
 - celiac 72
 - choroid 43
 - choroidoretinal 42
 - ciliary 42
 - circle, major, of iris 42
 - circumflex humeral 6
 - circumflex scapular 7
 - collateral radial 5, 6
 - collateral ulnar 4, 6
 - common carotid 36, 60, 64
 - common digital
 - dorsal 6, 8
 - palmar 6, 8
 - conjunctival 42
 - cornual 34, 36, 39
 - coronary
 - left 64
 - paraconal interventricular br. 64
 - circumflex br. 64
 - subsinuosal interventricular br. 64
 - right 64
 - costocervical trunk 64
 - cranial mesenteric
 - pancreatic br. 76
 - cranial gluteal 84
 - cranial rectal 76
 - cranial vesical 84
 - deep cervical 64
 - deep circumflex iliac 82, 84
 - deep femoral 84
 - digital
 - abaxial, plantar 22
 - axial, plantar 22
 - common, plantar 22
 - dorsal 10
 - palmar 8, 10
 - dorsal labial 94
 - dorsal nasal 36
 - dorsal pedal
 - dorsal metatarsal 22
 - dorsal perineal 94
 - mammary branch 84
 - dorsal scapular 64
 - episcleral 43
 - ethmoidal 42
 - external iliac 82, 84
 - external pudendal 78, 84
 - facial 36, 48
 - femoral 20, 78
 - circumflex 20
 - caudal 20
 - deep 20
 - gastric
 - left 72
 - right 72
 - gastroepiploic 72
 - genicular, descending 20
 - gluteal 20
 - hepatic 72
 - ileal 76
 - ileocolic
 - colic br. 76
 - mesenteric ileal br. 76
 - iliac 20
 - circumflex, deep 20
 - iliolumbar 84
 - infraorbital 36
 - interdigital 10, 22
 - interlobar 82
 - internal iliac 82, 84, 94
 - internal pudendal 84, 94
 - internal thoracis 64
 - jejunal 76
 - lacrimal 42
 - laryngeal 48
 - lateral nasal 36
 - left colic 76
 - lingual 36, 48
 - linguofacial trunk 36, 39, 48
 - main artery of digits: manus vs. pes 10
 - malar 36
 - mammary
 - cranial 84, 90
 - caudal 84, 90
 - masseteric br. 36, 48
 - maxillary 36, 39, 48
 - median 6, 8, 9
 - median caudal 94
 - mental 36
 - metacarpal 6, 10
 - middle colic 76
 - middle rectal 84, 94
 - obturator 84
 - occipital 48
 - of angle of eye 36
 - of iris 43
 - of the clitoris 84, 94
 - of the ductus deferens 84
 - of the head 48
 - of the penis
 - deep 84
 - of the bulb 84
 - dorsal 84
 - of upper lip 36
 - ophthalmic 36, 42
 - ovarian 84
 - uterine branch 84
 - palmar
 - deep 6
 - palpebral 36
 - pedal, dorsal 20
 - pharyngeal, ascending 48
 - phrenic 72
 - plantar 20, 22
 - deep plantar (metatarsal) 22
 - plantar arch, deep 20
 - popliteal 20
 - prostatic 94
 - branch to the ductus deferens 84
 - urethral branch 84
 - pudendal, internal 21
 - pudendoepigastric trunk 84
 - radial 6, 8
 - supf. br. 9
 - rete mirabile, ophthalmic 42
 - rete mirabile, rostral epidural 42
 - reticular 72
 - retinal 42
 - retic colic 76
 - ruminal 72
 - sacral, median 21
 - saphenous 20
 - saphenous, medial 21
 - caudal br. 22
 - rete calcaneum 22
 - lateral plantar 22
 - prox. deep plantar arch 22
 - prox. perforating br. 22
 - dist. deep plantar arch 22
 - dist. perforating br. 22
 - medial plantar 22
 - deep br. 22
 - supf. br. 22
 - sigmoideal 76
 - splenic 72
 - subclavian
 - left 64
 - right 64
 - sublingual 36, 48
 - submental 36
 - subscapular 6
 - superficial cervical 64
 - superficial temporal 39, 48
 - supraorbital 36, 42
 - suprascapular 7
 - thoracic, external 6
 - thoracodorsal 7
 - thyroid 48
 - tibial 20
 - caudal 20
 - cranial 20
 - transverse cubital 6
 - transverse facial 36
 - ulnar
 - supf. palmar br. 9
 - umbilical 82, 84
 - urethral 84
 - uterine 84
 - vaginal 84
 - urethral branch 84
 - uterine branch 84, 94
 - ventral perineal 84
 - mammary branch 94
 - vestibular 84

Articulatio, see Joint 12, 28

Atlas 58

 - dorsal arch 58
 - dorsal tubercle 58
 - ventral arch 58
 - ventral tubercle 58

Autonomic nerves 72

Autonomic nervous system 56, 84

 - afferents 56
 - efferents 56
 - parasympathetic part 56
 - sympathetic part 56

Axis 58

 - dens 58
 - lateral vertebral foramen 58

B

Blood supply of the penis 84

Blood supply of the udder 84

Blood supply of the uterus 84

Bone(s)

 - basisphenoid 31
 - carpal 2
 - caudal [coccygeal] vertebrae
 - hemal arches 58
 - hemal process 58
 - vertebral canal 58
 - cervical vertebrae
 - cran. articular process 58
 - caud. articular process 58
 - dorsal tubercle 58
 - spinous process 58
 - transverse process 58
 - ventral lamina 58
 - ventral tubercle 58
 - concha, nasal 33, 44
 - cribriform plate 33
 - crista galli 33
 - digital, of manus 2
 - digital, of pes 15
 - ethmoid 33
 - facial 31
 - frontal 30
 - heart 64
 - hip
 - sciatic spine 78
 - hyoid (see hyoid apparatus) 30
 - ilium
 - auricular surface 78
 - gluteal surface 78
 - greater sciatic foramen 78
 - greater sciatic notch 78
 - iliac surface 78
 - psoas tubercles 78
 - sacropelvic surface 78
 - tuber coxae 78
 - wing 78
 - incisive 30, 33
 - interparietal 30, 33
 - ischium
 - arch 78
 - lesser sciatic foramen 78
 - lesser sciatic notch 78
 - processes 78
 - tuber 78
 - lacrimal 30
 - lumbar vertebrae
 - spinous process 58
 - transverse processes 58
 - mandible 30, 33
 - maxilla 31
 - maxillary 30
 - metacarpal 2, 3
 - metatarsal 14
 - nasal 30
 - navicular 2
 - neurocranial 33
 - occipital 30, 33
 - of thoracic limb 2
 - palatine 31, 33
 - parietal 30, 33
 - pelvic girdle 78
 - presphenoid 31
 - pterygoid 31, 33
 - pubic
 - acetabulum 78
 - lunar surface 78
 - greater part 78
 - lesser part 78
 - dorsal tubercle 78
 - iliopubic eminence 78
 - obturator foramen 78
 - pelvic symphysis 78
 - sciatic spine 78
 - symphyseal crest 78
 - ventral tubercle 78
 - ribs
 - asternal 58
 - head 58
 - knee [genu costae] 58
 - sternal 58
 - tubercle 58
 - sacral vertebrae 58
 - dorsal sacral foramina 58
 - intermediate sacral crest 58
 - median sacral crest 58
 - sacral promontory 58
 - sesamoid
 - distal 2
 - metatarsal 14
 - of pes 15
 - proximal 2

- sphenoid 31
sternum
 manubrium stern 58i
 sternebrae 58
 xiphoid process 58
tarsal 14
temporal 31
 squamous part 33
 tympanic part 33
thoracic vertebrae
 cranial articular process 58
 mamillary process 58
 spinous process 58
 withers 58
turbines 33
vomer 31, 33
zygomatic 30
- Bovine spongiform encephalopathy** 96
- Brachial plexus** 4, 120
- Brachyodont** 32
- Brain** 50, 51
 base of 51
 median section 51
- BSE**
 diagnosis 96
 pathways of infection 96
 rapid test 97
 signs 96
 transmission 97
- Bulb, olfactory** 50
- Bulla**
 lacrimal 31, 35
 of concha 45
 tympanic 33
- Bursa(ae)**
 calcaneal 16
 distal bicipital 16
 of digits 11
 of thoracic limb 12
 subcutaneous precarpal 4
 synovial
 iliac 28
 infrapatellar 29
 ischial 28
 navicular 27
 of pelvic limb 28
 subcutaneous
 of lat. malleolus 28
 calcaneal 28
 subtendinous
 of biceps femoris, distal 28
 calcaneal, of supf. dig. flexor 28
 trochanteric [prox. bicipital] 16
 of gluteus medius 28
 of gluteus accessorius 28
 of biceps femoris 28
- C**
 Calcaneus 14
 Calvaria 30
 Canal of Schlemm (see venous plexus of sclera) 42
 Canal(s)
 carpal 4, 6, 8
 condylar 31
 facial 33
 hypoglossal 30
 infraorbital 31, 34
 lacrimal 34
 mandibular 33
 metacarpal 2
 optic 30, 33
 palatine 31
 supraorbital 30, 34
 tarsal 14
 Canine teeth 32
 Cartilage(s)
 arytenoid 46
 cricoid 46
 epiglottic 46
 nasal 44, 45
 of larynx 46
 scapular 2
 thyroid 46
 Caruncle, sublingual 44
 Caruncles of uterus 86
 Cauda equina 56
 Cavity
 glenoid 3
 infraglottic 46
 nasal 44
 oral 44
 Cecocolic orifice 76
 Cecum 68
 apex 76
 body 76
 Cells, of conchal bullae 45
 Cement 32
 Centrum tendineum perinei 94
 Cerebellum 47, 50
 Cerebrum 47, 50
 Cervical mucosa of uterus
 longitudinal folds 86
 Chambers of eyeball 42
 Cheek teeth 32
 Chiasm, optic 51
 Choanae 31, 46
 Choroid 42
 Chronic wasting disease (CWD) 97
 Ciliary
 body 42
 crown 42
 processes 42
 ring 42
 Cisterna chyli 72, 74, 76, 82
 Cleft, glottic 46
 Clitoris
 fossa clitoridis 86
 glans 86
 prepuce 86
 Cochlea
 tibial 14
 Colon 68, 76
 ascending 68
 proximal loop 68
 spiral loop 68
 centripetal gyri 68
 central flexure 68
 centrifugal gyri 68
 distal loop 68
 sigmoid 68
 descending 68, 76
 transverse 76
 Commissure, rostral 51
 Concha(e), nasal 34, 41, 45
 Conchae, ethmoid 44
 Condyle
 occipital 30
 of femur 14
 of humerus 2
 of tibia 14
 Conjunctiva 40
 Cor 64
 Cord, spinal 51
 Cornea 42
 Corpus callosum 51
 Cortex, cerebral 50
 Cotyledons 86
 Cranium 30
 Crest
 facial 30
 frontal, external 31
 intertrochanteric 15
 of humerus 3
 of major tubercle 2
 orbitosphenoid 31
 pterygoid 30, 40
 supracondylar 2
 temporal 31
 Creutzfeld-Jacob-Disease 97
 Crus, cerebral 50, 51
 Cutaneous muscles 106
- D**
 Dental pad 32, 44
 Dental star 32
 Dentin 32
 Dentition 32
 Dermis of the horn 34
 Development of the udder
 after birth 90
 first pregnancy 90
 prenatal 90
 postnatal 90
 Dewclaws (paradigiti II,V) 2
 Diameter
 transverse 78
 ventral 78
 Diaphragm
 attachment 62
 costal part 62
 right and left crura 62
 sternal part 62
 tendinous center 62
 Diastema 32, 44
 Diencephalon 50
 Digit(s) of manus 2
 Diploë 31, 34
 Disc, optic 42
 Diverticula of frontal sinus
 cornual 34
 nuchal 44
 postorbital 34
 Dorsal muscles acting on the head 109
 Dorsal trunk-limb muscles 109
 Dorsal vagal trunk 72
 Dorsum linguae 44
 Duct (us)
 accessory pancreatic 74
 choledochus 74
 common bile 74
 common hepatic 74
 cystic 74
 deferens 92
 ampulla 92
 incisive 44
 mandibular 39
 pancreatic 74
 thoracic 74
 Duodenocolic fold 76
 Duodenum
 ascending part 76
 caudal flexure 68, 76
 cranial flexure 76
 cranial part 68, 76
 descending part 68, 76
 sigmoid flexure 76
- E**
 Enamel 32
 Endometrium 86
 Epicondyle 2
 Epicondyles of femur 15
 Epidermis of the horn 34
 Epididymis
 body 92
 head 92
 tail 92
 testicular bursa 92
 Epikeras 34
 Eruption of teeth 32
 Esophagus 46, 48, 60
 Expiratory muscles 110
 External spermatic fascia 80
 Extrinsic muscles of tongue 106
 Eye 40
 Eyelashes 40
 Eyelids 40
- F**
 Falx cerebri 50
 Fascia(ae)
 bulbar 40
 deep of the trunk 66
 internal of the trunk 66
 internal spermatic 80
 of manus 10
 orbital 40
 superficial of the trunk 66
 transversalis 80
 Fauces 46
 Femoral lamina 78
 Femoral triangle 78
 Femur 14
 Fibrocartilage, parapatellar 29
 Fibula 14
 malleolus, lateral 14
 Fissure
 cerebral, longitudinal 51
 orbital 30
 palatine 31
 petro-occipital 30
 petrotympanic 33
 Fold
 alar 44
 basal 44
 glossoepiglottic 44
 straight 44
 vocal 46
 Foramen
 apical of tooth 32
 ethmoid 30
 infraorbital 30
 interventricular 50
 jugular 30
 magnum 31
 mandibular 33
 mental 33
 orbitorotundum 30
 oval 30
 palatine 31
 retroarticular 31
 round 30
 sphenopalatine 31, 33
 stylo mastoid 33, 36
 Fornix of conjunctiva 40
- Fossa**
 cerebellar 33
 cranial 33
 ethmoidal 50
 for lacrimal sac 31
 hypophysial 33
 infraspinous 3
 intercondylar 14
 lingual 45
 mandibular 33
 masseteric 33
 olecranon 2
 paralumbur 66, 68
 piriform 33
 pterygoid 33
 pterygopalatine 31
 radial 2
 subscapular 3
 supracondylar 14
 supraspinous 2, 3
 temporal 31
 trochanterica 15
 Fovea capitis 15
 Frenulum of the tongue 44
 Fuerstenberg's rosette 88
- G**
 Gall bladder 68, 74
 Ganglion(a)
 caud. mesenteric 56, 84
 celiac 56
 cervicothoracic 56
 cran. cervical 48, 56
 cran. mesenteric 56
 middle cervical 56
 of the sympathetic trunk 56
 otic 38
 prevertebral 56
 Gastric groove
 reticular groove 70
 floor 70
 claw-like papillae 70
 reticulo-omasal orifice 70
 right and left lips 70
 Gastric trunk 72, 74
 Genital organs
 female 86
 male 92
 Gland(s)
 buccal 38
 lacrimal 40
 mammary 88
 accessory (supernumerary) 90
 mandibular 38
 nasolabial 44
 of third eyelid 40
 parathyroid 48
 parotid 38
 salivary 38
 sublingual, polystomatic 38, 44
 tarsal 40
 thyroid 48
 vestibular 86, 94
 Glottis 46
 Granula iridica 41, 42
 Groove [Sulcus]
 alar 44
 brachialis 3
 for ophthalmic and maxillary nn. 31
 intertubercular 2
 metacarpal 2
 supraorbital 30, 36
 vascular, of mandible 33, 36
 Growth of horn 34

- H**
Hamulus of pterygoid bone 18, 33
Head of femur 15
Head, supf. dissection 36
Heart
apex 64
base 64
bone 64
cardiac axis 64
field 64
groove 64
paraconal 64
subsinusoidal 64
interventricular 64
intermediate 64
skeleton 64
Hemisphere
cerebral 50
cerebellar 50
Hepatic trunk 74
Hippocampus 50
Hoof [Ungula] 24
bulb 24
cap horn 26
cap papillae 26
capsule 26
coronary segment 24
cushion, digital 24
function 26
dermis 24
dermal papillae 24
dewclaws [digits II and V] 24
digital joints and tendons 26
epidermis 24
hoof mechanism 26
horn of hoof
growth 26
junctional 26
quality 24
tubules 24
lamina 24
periople 24
shock absorption 26
sole 24
subcutis 24
suspensory apparatus of distal phalanx (coffin bone) 26
wall (lamina) 24, 26
lamellae 24
dermal 24
epidermal 24
white zone 24, 26
Humerus 2
Humor, aqueous 42
vitreous 42
Hyoid apparatus 30
basihyoid 30
ceratohyoid 30
epihyoid 30
stylohyoid 30
thyrohyoid 30
tympanohyoid 30
Hypophysis 50
Hypothalamus 50
Hypsodont 32
- I**
Ileocecal fold 76
Ileum 68
orifice 76
papilla 76
Impression
medullary 33
pontine 33
Incisors 32
Infundibula 32, 50
Inguinal canal 80
Inguinal region 80
Inguinal ring
deep 80
dorsolateral angle 80
medial angle 80
superficial 80
medial crus 80
lateral crus 80
Innervation of the udder 90
Inspiratory muscles 110
Intercondylar eminence of tibia 15
Intertendinous fossa 78
Internal lumbar muscles 111
Intestinal tract 76
Intestinal trunk 74
Iris 41, 42
Ischiorectal fossa 94
Isthmus of the fauces 46
- J**
Jejunum 68, 76
Joint(s) 2
coffin 2
fetlock 2
pastern 2
Joint(s) of pelvic limb 28
Digital, see thoracic limb 12
Hip [Articulatio coxae] 28
labrum, acetabular 28
Stifle [Articulatio genus] 28
femoropatellar joint 28
femorotibial joint 28
Tibiofibular joints 28
Tarsal [Hock] joints 28
tarsocrural 28
intertarsal 28
tarsometatarsal 28
Joint, temporomandibular 36
Joints of thoracic limb 12
Jugular groove 60
- K**
Kidneys
collecting ducts 82
dorsal surface 82
external zone 82
hilus 82
internal zone 82
renal columns 82
renal cortex 82
renal lobes 82
renal medulla 82
renal papillae 82
renal pyramids 82
renal sinus 82
ureter 82
ventral surface 82
- L**
Lac 88
Lacertus fibrosus 4
Lacrimal apparatus 40
canaliculi 40
caruncle 40
lake 40
puncta 40
sac 40
Lacuna musculorum 78
Lacuna vasorum 78
Lamellae, intrasinual 35
Large intestine 76
Laryngopharynx 46
Larynx 46
Lateral pectoral groove 60
Lens 42
Ligament(s)
accessory, of interossei 10, 18, 23
annular digital 23
collateral 23, 28
coronary 74
cricoarytenoid 47
cruciate 28
dorsal tarsal 29
falciiform 72, 74
femoropatellar 28
fundiform 80
gastrosplenic 74
hepatoduodenal 72
hepatogastric 72
hepatorenal 74
inguinal 80
intercornual 86
interdigital 23
latum uteri 86
left triangular 74
nuchae 47
of dewclaw 23
of digits 10
of head of femur 28
of menisci 28
of pelvic limb 28
of the bladder
round 82, 84
middle 82
of the ovary
proper 86
suspensory 86
of the uterus
round 86
patellar 28
pectinate 42
phrenicosplenic 74
plantar abaxial, of pastern joint 23
plantar tarsal 28
right triangular 74
round 74
sacrosciatic 16, 78, 94
sacroteruberous 94
sesamoid 10
suspensory of the udder 88
transverse, of stifle 28
vocal 46
Limbus of cornea 40, 42
Line
mylohyoid 33
nuchal 30
temporal 30, 34
triceps 3
Linea alba 66, 80
Lips (labia oris) 44
Liver 74
area nuda 74
dorsal border 74
fissure for the round ligament 74
lobe 68, 74
caudate 74
papillary process 74
caudate process 68, 74
left 68, 74
quadrate 74
right 68, 74
porta hepatis 74
ventral border 74
Lobe
piriform 51
Long hyoid muscles 106
Lumbar nerves: L1–L6
dorsal branches 120
lateral branches 120
medial branches 120
ventral branches 120
lateral branches 120
medial branches 120
Lumbar plexus 122
Lumbar trunk 74
Lung 62
basal border 62
bifurcation 62
caudal field 62
cranial field 62
lobes 62
accessory 62
left caudal 62
left cranial 62
caudal part 62
cranial part 62
middle (right) 62
right caudal 62
right cranial 62
caudal part 62
cranial part 62
tracheal bronchus 62
Lymph node(s) 72, 74, 113–118
abomasal
dorsal 72, 116
ventral 72, 116
accessory hepatic 74, 116
anorectal 82, 117
aortic lumbar 116
axillary
accessory 6, 114
proper 5, 6, 114
of first rib 6, 114
caudal deep cervical 60, 113
caudal hyoid 113
caudal mesenteric 76, 117
caudal sternal 114
cecal 76, 117
celiac 72, 76, 116
colic 76, 117
costocervical 114
coxal 20, 118
cranial deep cervical 60
cranial mesenteric 76, 117
cranial ruminal 116
cranial sternal 62, 114
deep inguinal 90
deep popliteal 118
deep cervical 60, 113
gluteal 20, 118
hepatic (portal) 74, 116
iliofemoral [deep inguinal] 19, 20, 82, 90, 117
infraspinatus 114
intercostal 62, 114
jejunal 76, 117
lateral iliac 82, 117
left ruminal 116
lumbar aortic 82
lumbar trunk 20
mammary 90
mandibular 39, 113
medial iliac 82, 92, 117
mediastinal
caudal 62, 115
cranial 62, 115
middle 115
of thoracic limb 6
omasal 72, 116
pancreaticoduodenal 74, 117
parotid 38, 113
phrenic 62, 115
popliteal, deep 20
proper lumbar 116
pterygoid 113
pulmonal 62, 115
renal 82, 116
reticular 72, 116
reticuloabomasal 72, 116
retropharyngeal 38, 46, 49, 113
rostral hyoid 113
ruminal
left and right 72, 116
cranial 72
ruminoabomasal 72, 116
sacral 20, 82, 117
sciatic 20, 82, 118
splenic (or atrial) 72, 74, 116
sternal 62
subiliac 20, 66, 118
superficial cervical 60, 113
superficial inguinal 90, 92
scrotal 118
mammary 118
thoracic aortic 62, 114
tracheobronchial
left 62, 115
right 62, 115
cranial 62, 115
middle 62, 115
tuberal 19, 20, 118
Lymphatic ring, pharyngeal 46
Lymphatic system 60, 62
Lymphatic vessels 74
cisterna chyli 74, 76
Lymphocenter 113
axillary 114
bronchial 115
caudal mesenteric 117
celiac 116
cranial mesenteric 117
deep cervical 113
dorsal thoracic 114
iliofemoral 117
iliosacral 117
lumbar 116
mandibular 113
mediastinal 115
parotid 113
politeal 118
retropharyngeal 113
sciatic 118
superficial cervical 113
superficial inguinal 118
ventral thoracic 114
- M**
Mammary buds 90
Mammary glands
corpus mammae 88
papilla mammae 88
sinus 88
collecting ducts 88
ductus lactiferi colligentes 88
small lactiferous ducts 88
alveolar lactiferous ducts 88

- lobules 88
 alveoli 88
 teat 88
 apex 88
 canal 88
 annular fold 88
 fuerstenberg's rosette 88
 glandular part 88
 longitudinal folds 88
 pappillary part 88
 venous plexus 88
 orifice 88
 papillary duct 88
 sinus 88
 sphincter 88
 Mammillary body 50
 Mandibular gl. 37
 Manus 8
 Meatus
 acoustic 33
 nasal 44
 temporal 30
 Mediastinum
 caudal 62
 cranial 62
 middle 62
 plica venae cavae 62
 Medulla oblongata 47
 Mesencephalon 50
 Mesentery, common 76
 Mesoductus deferens 92
 Mesogastrium
 dorsal 72
 ventral 72
 Mesometrium 86
 Mesorchium 92
 Mesosalpinx 86
 Mesovarium 86
 Metatarsus 103
 Midbrain 50
 Milk 88
 Milk well 90
 Molars 32
 Muscle(s)
 adductor magnus (et brevis) 17, 18, 101
 anconeus 4, 98
 articularis humeri 98
 arytenoideus transversus 46, 105
 biceps brachii 4, 13, 98
 biceps femoris 16, 101
 brachialis 4, 13, 98
 brachiocephalicus 60
 buccinator 36, 39, 103
 bulbar 40
 bulbospongiosus 92, 112
 caninus 36, 103
 caudal stylopharyngeus 46
 caudal thigh 101
 ceratohyoideus 106
 cervicoauricularis profundus and medius 103
 cervicoauricularis superficialis 103
 cervicoscutularis 36, 103
 ciliary 40
 cleidobrachialis (clavicular part of deltoid) 4
 cleidomastoideus 60, 110
 cleido-occipitalis 60, 110
 coccygeus 17, 19, 94, 112
 common digital extensor 4, 9, 13, 99
 constrictor vestibuli 86, 94, 112
 constrictor vulvae 94, 112
 coracobrachialis 4, 13, 98
 cremaster 80
 cricoarytenoideus dorsalis 46, 105
 cricoarytenoideus lateralis 46, 105
 cricopharyngeus 46, 105
 cricothyroideus 46, 105
 cutaneus trunci 60, 66, 107
 cutaneus faciei 36
 cutaneus omobrachialis 60, 66, 107
 deep digital flexors 4, 13, 17, 18, 100
 caudal tibial 17, 18, 102
 lateral digital flexor 17, 18, 102
 medial digital flexor 18, 102
 deltoideus 4, 13, 98
 acromial part 98
 clavicular part 4
 scapular part 98
 depressor labii inferioris 36, 104
 depressor labii superioris 36, 104
 descending pectoral 60
 diaphragm
 costal part 111
 sternal part 111
 lumbar part 111
 digastricus 38, 47, 104
 digital extensors 4
 extensor br. of interossei 4, 9
 extensor carpi obliquus [abductor pollicis longus] 4, 9, 99
 extensor carpi radialis 4, 9, 13, 99
 extensor digitalis brevis 16, 103
 extensors of the digits 102
 extensors of the hock 102
 extensors of the stifle 101
 external anal sphincter 94, 112
 external oblique abdominal 66, 78, 80, 111
 external obturator 101
 flexor carpi radialis 4, 9, 100
 flexor carpi ulnaris 4, 9, 100
 flexors of the digits 102
 flexors of the hock 102
 frontalis 36, 40, 104
 frontoscutularis 37, 103
 gastrocnemius 17, 18, 102
 gemelli 17, 101
 genioglossus 45, 49, 106
 geniohyoideus 45, 49, 106
 gluteobiceps 16, 101
 gluteus
 accessorius 16, 100
 medius 16, 100
 profundus 16, 100
 superficialis 100
 gracilis 18, 101
 hyoepiglotticus 45, 49, 106
 hyoglossus 47, 106
 hyoideus transversus 106
 hyopharyngeus 46, 105
 iliacus 16, 112
 iliocostalis
 cervicis 107
 thoracis 107
 lumborum 107
 infraspinatus 4, 13, 98
 intercostales externi 111
 intercostales interni 110
 interflexorii 100
 intermandibular 38
 internal obturator 101
 internal anal sphincter 112
 internal oblique abdominal 66, 80, 111
 interossei III and IV 4, 10, 18, 100, 103
 interscutularis 36, 103
 interspinales 108
 intertransversarii 108
 ischiocavernosus 92, 112
 laryngeal 46, 105
 lateral digital extensor 4, 9, 13, 16, 99, 103
 latissimus dorsi 4, 60, 109
 levator ani 19, 94, 112
 levator labii sup. 36, 39, 104
 levator nasolabialis 36, 104
 levator palpebrae sup. 36, 40
 levator veli palatini 46, 49, 105
 levatores costarum 111
 lingualis proprius 105
 long digital extensor 16, 102
 extensor of digits III and IV 16
 medial digital extensor 16
 long extensor of digit I (vestigial) 16
 longissimus
 atlantis et capitis 107
 cervicis 107
 lumborum 107
 thoracis 107
 longus capitis 108
 longus colli 108
 malaris 36, 104
 masseter 39, 104
 masticatory 38
 medial digital extensor 4, 9, 16
 multifidus
 cervicis 108
 lumborum 108
 thoracis 108
 mylohyoid 38, 39, 47, 104, 106
 obliquus capitis caudalis 109
 obturator, external 18
 occipitohyoideus 106
 of hyoid apparatus 106
 of the eye 40, 105
 dilator pupillae 42
 oblique 40
 rectus 40
 retractor bulbi 40
 sphincter pupillae 42
 of the eyelids and nose 104
 of the lips and cheeks 103
 of the penis 92
 of the soft palate 46, 105
 of the tongue and hyoid 105
 omohyoideus 47, 60, 106
 omotransversarius 60, 109
 orbicularis oculi 36, 40, 104
 orbicularis oris 36, 103
 palatinus 46, 105
 palatopharyngeus 46, 49
 parotidoauricularis 36, 103
 pectineus (et adductor longus) 18, 101
 pectorales superficiales
 pectoralis descendens 109
 pectoralis transversus 109
 pectoralis ascendens 110
 pectoralis profundus 5, 60, 110
 pelvic diaphragm 112
 peroneus [fibularis]
 longus 16, 103
 tertius 16, 19, 102
 pharyngeal 105
 pharyngeal constrictors 46, 105
 pharyngeal dilator 46, 105
 platysma
 cutaneus colli 106
 cutaneus faciei 106
 popliteus 102
 preputialis 66, 80, 107
 pronator teres 4, 100
 proper digital extensors 4
 proper lingual 45, 49
 psoas major 112
 psoas minor 112
 pterygoid 38, 104
 pterygopharyngeus 46, 49, 105
 quadratus femoris 17, 101
 quadratus lumborum 111
 quadriceps femoris 17, 18, 101
 rectus 18, 101
 vastus 18, 101
 intermedius 18, 101
 lateralis 17, 18, 101
 medialis 18, 101
 rectococcygeus 112
 rectus
 abdominis 66, 80, 111
 capitis dorsalis major 109
 capitis dorsalis minor 109
 capitis lateralis 109
 capitis ventralis 109
 capitis 110
 thoracis 110
 retractor anguli oculi lateralis 104
 retractor clitoridis 94, 112
 retractor costae 110
 retractor penis 92, 94, 112
 rhomboideus 60, 109
 cervicis 60
 thoracis 60
 rostral stylopharyngeus 46
 sacrocaudalis [-coccygeus] dorsalis lateralis 108
 sacrocaudalis [-coccygeus] dorsalis medialis 108
 sacrocaudalis [-coccygeus] ventralis lateralis 109
 sacrocaudalis [-coccygeus] ventralis medialis 109
 sartorius 18, 78, 101
 scaleni
 scalenus dorsalis 108
 scalenus medius 108
 scalenus ventralis 108
 scutuloauricularis superficialis et profundus 103
 scutuloauricularis supf. accessorius 37
 scutuloauricularis supf. dors. 37
 semimembranosus 16, 101
 semispinalis capitis 107
 semitendinosus 16, 101
 serratus dorsalis caudalis 110
 serratus dorsalis cranialis 110
 serratus ventralis 60, 110
 cervicis 60
 thoracis 60
 soleus 17, 18, 102
 special flexor of the stifle 102
 spinalis et semispinalis thoracis et cervicis 108
 splenius
 capitis 107
 cervicis 107
 sternocephalicus 60
 sternohyoideus 45, 47, 49, 60, 106
 sternomandibularis 36, 39, 60, 110
 sternomastoideus 60, 110
 sternothyroideus 47, 60, 106
 styloauricularis 103
 styloglossus 47, 106
 stylohyoideus 47, 106
 stylopharyngeus caudalis 105
 stylopharyngeus rostralis 105
 subclavius 60, 110
 subscapularis 4, 13, 98
 superficial pectoral 60
 supf. dig. flexor (pelvic limb) 17, 18
 supf. digital flexor 4, 9, 10, 99, 102
 supraspinatus 4, 13, 98
 tarsal 40
 teat sphincter 88
 temporal 39, 104
 tensor fasciae antebrachii 4, 98
 tensor fasciae latae 16, 100
 tensor veli palatini 46, 49, 105
 teres major 4, 98
 teres minor 4, 98
 thyroarytenoideus 46, 105
 thyrohyoideus 47, 106
 thyropharyngeus 46, 105
 tibialis
 caudalis 18, 102
 cranialis 16, 102
 transversus abdominis 66, 111
 transversus thoracis 110
 trapezius 60, 109
 triceps brachii 4, 13, 98
 ulnaris lat. [extensor carpi ulnaris] 4, 9, 13, 99
 zygomaticoauricularis 36, 103
 zygomaticoscutularis 37, 103
 zygomaticus 36, 103
 Muscles of anal region 112
 Myology 98-112
 Myometrium 86
 N
 Nasolacrimal duct 40, 44
 Nasolacrimal orifice 40
 Nasopharynx 46
 Neck 58, 60
 Neck viscera 60
 Nerve(s)
 abducent (VI) 40, 50, 54
 accessory (XI) 48, 50, 54
 alveolar, inferior 38
 ansa axillaris 4, 7
 antebrachial, cutaneous 4, 6
 auriculotemporal (V3) 37, 38
 axillary 4, 6, 120
 brachial plexus 4, 120
 buccal 38
 parotid br. 38
 caud. cut. sural 16
 caudal [coccygeal] 20
 dorsal br. 120
 ventral br. 120
 caudal clunial 123
 caudal cutaneous femoral 84, 123
 caudal gluteal 84, 123
 caudal rectal 84, 94, 125
 cervical nerves: C1-C8 40, 119
 dorsal br. 119
 lateral br. 119
 medial br. 119
 ventral br. 119
 lateral br. 119
 medial br. 119
 chorda tympani 38

- ciliary 40
- clunial 20
- common digital 6, 8
- common digital of pelvic limb 20
- common digital of manus
 - dorsal 6, 8
 - palmar 8, 10
- communicating br. in metacarpus 6, 7, 9
- cornual (br.) 34, 40
- cranial 48
- cranial and caudal pectoral 122
- cranial gluteal 84, 123
- cutaneous antebrachial 4, 5, 6, 9
- cutaneous femoral 20
- cutaneous sural 20
- cutaneous, of rump and thigh 20
 - deep 16
 - superficial 16
- deep perineal 94
 - mammary br. 84
- digital [proper]
 - dorsal 10
 - palmar 8
- ethmoidal 40, 52
- facial (VII) 36, 50, 54
 - auricular br. 36
 - auriculopalpebral 36
 - buccal br. 36
 - palpebral br. 36
 - zygomatic br. 36
- femoral 18, 21, 78
 - muscular br. 123
 - saphenous nerve 123
- frontal 40
- genitofemoral 20
 - caudal br. 90
 - cranial br. 90
 - femoral br. 123
 - genital br. 80, 123
- glossopharyngeal (IX) 38, 48, 54
- gluteal 16
- gluteal, caudal 21
- greater splanchnic 56, 64
- hypogastric 84
- hypoglossal (XII) 48, 50, 54
- iliohypogastric 20, 90, 122
- ilioinguinal 20, 66, 90, 123
- infraorbital 38
- infratrochlear 40, 52
- intercostobrachial 6
- interdigital 10
- lacrimal 40
- laryngeal 48
- lateral cutaneous sural 16
- lateral cutaneous femoral 66, 123
- lateral thoracic 122
- lingual 38, 47
- long thoracic 122
- lumbar splanchnic 56
- lumbosacral trunk 84
- mandibular 38, 52
- masseteric 38
- masticatory 38
- maxillary (V) 38, 50, 52
- median 4, 6, 8, 9, 121
- mental 38
- metatarsal III, dorsal 20
- musculocutaneous 4, 7
- mylohyoid 38
- nasociliary 40, 52
- nuclei, of vagus 48
- obturator 18, 21, 123
- oculomotor (III) 40, 50, 52
- of larynx 46
- of the abdominal wall 66
- of the cauda equina 94
- of the clitoris 84
- of the frontal sinuses 40
- of the penis 84, 94
- of the pes 22
- olfactory (I) 50, 52
- ophthalmic (V1) 40, 50, 52
- optic (II) 42, 50, 52
- palmar 8, 10
- parasympathetic 56, 84
- parotid br. of buccal (V3) 36
- pectoral 7,61
- pelvic 56
- peroneal [fibular]
 - common 16, 20
 - deep 21, 22
 - superficial 21, 22
- pharyngeal br. 49
- plantar 18, 20
 - medial 21
 - lateral 21
- pudendal 21
 - cutaneous br. 20
 - deep perineal nerve 125
 - distal cutaneous br. 84, 94, 125
 - superficial perineal br. 125
 - dorsal nerve of penis or clitoris 125
 - mammary br. 84, 90, 94
 - preputial br. 84, 94
 - proximal cutaneous br. 84, 94, 125
 - scrotal br. 84, 94
- radial 4, 8, 121
 - supf. br. 9
- rectal, caudal 21
- recurrent 60
- sacral splanchnic 56
- saphenous 18, 20, 78
- sciatic 16, 84, 123
 - common peroneal nerve 16, 20, 124
 - lateral cutaneous sural nerve 16, 124
 - tibial nerve 124
- spinal ganglia 97
- spinal
 - dorsal br. 66
 - lateral br. 66
 - dorsolateral cutaneous 66
 - dorsomedial cutaneous 66
 - ventral br. 66
 - lateral cutaneous 66
 - ventral cutaneous 66
- sublingual 39
- subscapular 4, 120
- superficial perineal 84, 94
- supraclavicular 6
- supraorbital 40
- suprascapular 4, 7, 120
- sympathetic trunk 48, 84, 96
- temporal, deep 38
- thoracic 6, 7, 61
- thoracodorsal 4, 7, 122
- tibial 16, 18, 20, 22
 - caudal cutaneous sural nerve 124
 - communicating br. 22
- digital 22
 - common, dorsal 22
 - abaxial, dorsal 22
 - axial, dorsal 22
 - common, plantar 22
 - abaxial, plantar 22
 - axial, plantar 22
- plantar 22
 - lateral plantar nerve 124
 - medial plantar nerve 124
 - plantar common digital nerve II 124
 - plantar common digital nerve III 124
- trigeminal (V) 38, 50, 52
- trochlear (IV) 40, 50, 52
- ulnar 4, 6, 8
 - caudal cutaneous antebrachial nerve 122
 - dorsal br. 122
 - dorsal common digital nerve 122
 - supf. palmar br. 9
- vagosympathetic trunk 48, 96
- vagus (X) 48, 54
 - auricular br. 36
 - parasympathetic fibers 96
- vagus group (IX–XI) 48, 50, 54
- vertebral 56
- vestibulocochlear (VIII) 50, 54
- zygomaticotemporal br. 40
- Neurohormonal reflex arc 90
- Neurons, presynaptic myelinated 56
- Neurons, postsynaptic unmyelinated 56
- Nose 44
- Nostril 44
- Notch [Incisura]
 - intercapital 3
 - intertragic 36
 - mandibular 33
 - radial, of ulna 3
 - scapular 3
 - trochlear, of ulna 3
- Nuchal ligament
 - funiculus 58
 - lamina 58
- Nucleus(i)
 - caudate 50
- O**
- Obex 97
- Omasum 68
 - base 70
 - neck 70
 - omasal groove 70
 - omasal laminae 70
 - interlaminal recesses 70
 - papillae 70
 - omasoabomasal orifice 70
 - parietal surface 70
 - visceral surface 70
- Omental (epiploic) foramen 72
- Omentum
 - greater 68, 72
 - bursa 72
 - vestibule 72
 - caudal recess 72
 - supraomental recess 68, 72
 - deep wall 72
 - superficial wall 72
 - lesser 72
- Opening
 - frontomaxillary (absent) 34
 - nasomaxillary 34
 - maxillopalatine 34
- Ora serrata 42
- Orbit 31, 40
- Organ, vomeronasal 44
- Oropharynx 44
- Ostium, intrapharyngeal 46
- Ovary
 - broad ligament 86
 - corpora lutea 86
 - cortex 86
 - decent of 86
 - gubernaculum 86
 - medulla 86
 - suspensory ligament 86
- P**
- Palate, hard 44
- Palate, soft 45, 46
- Palatine ridges 44
- Pancreas
 - body 74
 - notch 74
 - right lobe 68, 74
- Papilla(e)
 - buccal 44
 - greater duodenal 74
 - labial 44
 - lingual 44
- Paradigiti II,V 2
- Paranasal sinus(es) 34
 - conchal 34, 45
 - ethmoidal cells 34, 45
 - frontal 34
 - caudal 34
 - rostral 34
 - lacrimal 34
 - maxillary 34, 41
 - palatine 34, 41
 - sphenoid 34
- Parapatellar fibrocartilage 14
- Parotid duct 36
- Parotid gl. 36
- Parotid ln. 37
- Patella 14
- Peduncle, olfactory 50
- Pelvic diaphragm 94
- Pelvic plexus 84
- Penis
 - apical ligament 92
 - body 92
 - connective tissue strand 92
 - corpus 92
- corpus cavernosum 92
- corpus spongiosum 82, 92
- crura 92
- external urethral orifice 92
- free part 92
- glans 92
- penile urethra 92
- raphe 92
- root 92
- sigmoid flexure 92
- suspensory ligaments 92
- tunica albuginea 92
- urethral process 92
- Pericardium 62
 - sternopericardiac ligament 64
- Perimetrium 86
- Perineal body 94
- Perineal membrane 94
- Perineal muscles 94, 112
- Perineal region 94
- Perineum 94
- Periorbita 40
- Peritoneum 66, 86
 - vaginal process 80
- Phalanx (phalanges) 2, 3
- Pharynx 46
- Placentomes 86
- Planum nasolabiale 44
- Pleura
 - costal 62
 - cupulae 62
 - diaphragmatic 62
 - mediastinal 62
 - parietal 62
 - pericardial 62
 - recess 62
 - mediastinal 62
 - costodiaphragmatic 62
 - reflection, diaphragmatic line of 62
 - visceral 62
- Pleural cavities 62
- Plexus
 - cardiac 56
 - pelvic 56
 - choroid 50
 - venous, palatine 44
- Pons 51
- Pore, acoustic 33
- Premolars 32
- Prepubic tendon 80
- Prepuce
 - external lamina 92
 - frenulum 92
 - internal lamina 92
 - preputial orifice 92
- Prion proteins (PrP) 96
- Process
 - alveolar 31, 33
 - of incisive bone 31
 - of maxilla 31
 - cartilaginous, of patella 15
 - condylar, of mandible 33
 - coracoid 3
 - cornual 30, 34
 - coronoid 3
 - coronoid, of mandible 33
 - frontal 30
 - hyaloid 42
 - jugular 30
 - lingual 30
 - mastoid 33
 - muscular 33
 - nasal 31, 33
 - palatine 31, 33
 - paracondylar 31
 - retroarticular 33
 - styloid
 - lateral 2
 - medial 2
 - styloid, of temporal bone 33
 - zygomatic
 - of frontal bone 30
 - of maxilla 31
 - of temporal bone 31
- Prominence, laryngeal 46
- Protuberance
 - intercornual 30
 - occipital 30
- Pulp cavity 32
- Pupil 41, 42
- Pylorus 68

- sphincter 70
torus 70
Pyramids, decussation of 50
- R**
Radius 2
Recess
 infundibular 51
 optic 51
 pineal 51
 piriform 46
 suprapineal 51
Rectum 76
Region
 caudal abdominal 68
 cranial abdominal 68
 hypochochriac 68
 left costal 68
 left lateral abdominal 68
 middle abdominal 68
 right costal 68
 right lateral abdominal 68
 xiphoid 68
Removal of the brainstem 97
Respiratory muscles
 inspiratory muscles 62
 expiratory muscles 62
Reticulum 68
 diaphragmatic surface
 visceral surface 70
 fundus 70
 cardia 70
Retina 42
Retinaculum
 extensor
 crural 22
 metatarsal 22
 transverse humeral 12
Rhinencephalon 50
Rhombencephalon 50
Rima glottidis 46
Ring, scleral 42
Rings and grooves of horn 34
Root of tongue 44
Rumen
 atrium 68, 70
 dorsal curvature 70
 groove 70
 ruminoreticular 70
 cranial 70
 caudal 70
 right accessory 70
 left accessory 70
 dorsal coronary 70
 ventral coronary 70
 insula ruminis 70
 intraruminal orifice 70
 longitudinal groove 70
 papillae 70
 parietal surface 70
 pillars 70
 recess 68, 70
 ruminoreticular fold 70
 ruminoreticular orifice 70
 sac 68, 70
 dorsal 68, 70
 ventral 68, 70
 caudodorsal blind 68, 70
 caudoventral blind 68, 70
 visceral surface 70
 ventral curvature 70
- S**
Sacral nerves: S1–S5
 dorsal branches 120
 lateral branches 120
 medial branches 120
 ventral branches 120
 lateral branches 120
 medial branches 120
Sacral plexus 84, 123
Sclera 41
Scrolls of ventral concha 44
Scrotum, lymphatic vessels 92
Scutiform cartilage 37
Scutum 10
Sella turcica 33
Septum
 interventricular 51
 nasal 44, 49
- of frontal sinus 34
 median 34
 oblique transverse 34
 pellucidum 51
 pharyngeal 45, 46
Sesamoid body, dorsal 4
Sheaths of optic n. 42
Sheaths, synovial
 carpal 12
 digital 10, 12
Sinus(es)
 conchal 44
 paranasal
 frontal 45
 maxillary 41
 palatine 41, 45
 sagittal 50
Skin 66, 80
Skull 32–35
Sleeves [manicae flexoriae] 10
Small intestine 76
Spaces, iridocorneal (of Fontana) 42
Spermatic cord 92
Spinal cord 47, 92, 97
 cervical enlargement 56
 lumbar enlargement 56
 terminal filament 56
Spinal nerve
 dorsal branch (nd) 119
 lateral branch (ndl) 119
 medial branch (ndm) 119
 ventral branch (nv) 119
 lateral branch (nvl) 119
 medial branch (nvm) 119
Spine, scapular 3
Spleen 68
 caudal border 74
 cranial border 74
 diaphragmatic surface 74
 dorsal end 74
 ventral end 74
Stomach 70, 72
 development 72
 greater curvature 72
 lesser curvature 72
Sulci 50
Superficial inguinal ring 78
Suspensory apparatus of digit 10
Suspensory apparatus of the udder 80
Sustentaculum tali 14
Sympathetic trunk 56, 64
Synovial sheaths of pelvic limb 28
Synovial sheaths of thoracic limb 12
- T**
Tail 94
Talus 14
Tapetum lucidum 42
Tarsus of eyelid 40
Tectum 51
Teeth 31–33
 crown 32
 deciduous 32
 neck 32
 permanent 32
 root 32
 surfaces 32
 wear 32
Tegmentum 51
Telencephalon 50
Tendon
 of supf. dig. flexor 19
 symphyseal 18
 tarsal, of semitendinosus 19
 tarsal, of biceps femoris 16
Tendons of pelvic limb
 digital extensor 23
 digital flexor 23
 of interossei 23
Tentorium cerebelli 50
Testes
 capital end 92
 caudate end 92
 epididymal border 92
 free border 92
 lig. of the tail of the epididymis 92
 proper lig. of the testis 92
Thalamus 51
Thoracic cavity 62
Thoracic duct 62
Thoracic limb 2, 13
- Thoracic nerves: T1–T13 119
 dorsal br. 119
 lateral br. 119
 medial br. 119
 ventral br. 119
 lateral br. 119
 medial br. 119
Thoracic skeleton 58
Thymus 60
Tibia 14
Tongue 44
Tonsil
 lingual 44, 46
 of soft palate 46
 palatine 46
 pharyngeal 45, 46
 tubal 46
Torus linguae 44
Trachea 48, 60
Tract
 olfactory 51
 optic 51
Trapezoid body 51
Triangle, femoral 18
Trigone, olfactory 51
Trochanter 14
Trochlea
 of femur 14
 of orbit 40
 of radius 2
 of talus 14
Tube, auditory 46
Tuber
 calcanei 14
 facial 30
 of scapular spine 3
 olecranon 2
Tubera ischiadica 94
Tubercle
 flexor, of distal phalanx 2, 3
 muscular 31
 of humerus 2
 supraglenoid 3
Tuberosity
 deltoid 2
 flexor, of middle phalanx 2, 3
 radial 2
 teres 2
 tibial 14
Tunics of eyeball 42
- U**
Udder 90
 lobes 88
 median intermammary groove 88
 suspensory apparatus 88
 lateral laminae 88
 medial laminae 88
 suspensory ligament 88
 suspensory lamellae 88
Ulna 2
Urethra
 female 82
 suburethral diverticulum 82, 86
 urethral crest 82
 male 82
 pelvic part 82
 penile part 82
 urethral arch 82
Urinary bladder
 apex 82
 body 82
 lateral ligaments 82
 neck 82
 ureteric folds 82
 vesical triangle 82
Urinary system 82
Urogenital muscles 112
Urogenital region 94
Urogenital triangle 94
Uterine tube
 abdominal orifice 86
 infundibulum 86
 ovarian bursa 86
 uterine orifice 86
Uterus
 body 86
 cervical canal 86
 cervix uteri 86
 cornua uteri 86
 external uterine orifice 86
- internal uterine orifice 86
neck 86
portio vaginalis 86
- V**
Vagina bulbi 40
Vagina
 external urethral orifice 86
 fornix 86
 hymen 86
 vestibule 86
Vaginal ring 80, 92
Vaginal tunic 80
Vagosympathetic trunk 56, 60
Vein(s)
 accessory cephalic 6, 8
 accessory vaginal 84
 alveolar, inf. 36
 antebrachial, deep 6
 auricular 36
 axillary 6
 azygos
 left 64
 right 64
 bicipital 4, 6
 brachial 6
 buccal 36
 carpal, dorsal br. 5
 caudal epigastric 78
 caudal mammary 84, 90, 94
 caudal superficial epigastric 66, 90
 caudal vesical 84
 cava caudalis 20, 84
 cephalic 6, 60
 choroid 43
 choroidoretinal 42
 ciliary 42, 43
 circumflex humeral 6
 circumflex scapular 7
 collateral ulnar 4, 6
 common digital dorsal 6, 8
 common digital palmar 6, 8, 10
 common iliac 84
 conjunctival 43
 cornual 34, 36, 39
 cranial mammary 66, 84, 90
 cranial superficial epigastric 66, 90
 deep circumflex iliac 84
 deep facial 36, 47
 deep facial plexus 36, 39
 deep femoral 78, 84
 digital 10
 dorsal carpal network 6
 external jugular 60
 external iliac 84
 external pudendal 78
 facial 36, 39
 femoral 20, 78
 circumflex 20
 caudal 20
 deep 20
 frontal 36
 genicular, descending 20
 gluteal 20
 iliac circumflex, deep 20
 infraorbital 36
 interdigital 10
 interlobar 82
 internal iliac 84
 internal pudendal 84, 94
 interosseous, crural 20
 interosseus 6
 jugular 60
 external 6, 36, 39, 60
 internal 36
 labial (of lips) 36
 lingual 36
 linguofacial 36, 39, 60
 malar 36
 mammary
 caudal 90
 cranial 90
 masseteric, ventr. 36
 maxillary 36, 39, 60
 median 6, 8, 9,
 median caudal 94
 median cubital 6
 median sacral 84
 mental 36
 metacarpal 6, 10
 milk 66

nasal, dorsal 36
nasal, lateral 36
obturator 20, 84
occipital 36
of angle of eye 36
of head, supf. 36
of iris 43
of lower lip 39
of the ductus deferens 84
ophthalmic plexus 36
ophthalmic, ext., dors. 36
ovarian 20, 84
uterine branch 84
palpebral 36
pedal, dorsal 20
plantar 20
plantar arch, deep 20
plexus, cavernous, of nose 44
plexus, deep facial 36
plexus, of sclera (canal of schlemm) 42
plexus, ophthalmic, intraorbital 42
plexus, palatine 44
popliteal 20
portal 76
pterygoid plexus 36
pudendal, internal 21
pudendoepigastric 20, 84
radial 6, 8
supf. br. 9
retinal 42
sacral, median 21
saphenous 20
saphenous, lateral 21, 22
caudal br. 22
anastomotic br. to med. saphenous 22
cranial br. 22
saphenous, medial 21
caudal br. 22
lateral plantar 22
prox. deep plantar arch 22
prox. perforating br. 22
dist. deep plantar arch 22
dist. perforating br. 22
medial plantar 22
deep br. 22
supf. br. 22
rete calcaneum 22
subclavian 7
subcutaneous abdominal 84, 90
sublingual 36
submental 36
subscapular 6
superficial cervical 60
supraorbital 36
suprascapular 7
temporal, supf. 36
testicular 84
thoracic external 6
thoracic, supf. 7
thoracodorsal 7
tibial
caudal 20
cranial 20
transverse cubital 6
transverse facial 36
uterine 84
vaginal 21
accessory 21
uterine branch 84
veins of eyeball 42
ventral labial 84, 90
Velum palatinum 46
Velum, medullary 50
Ventral trunk–limb muscles 109
Ventral vagal trunk 72
Ventral vertebral column muscles 108
Ventricles, of brain 50
Vermis 50
Vertebrae
arch 58
body 58
processes 58
Vertebral canal 58
Vertebral column 58
Vertebral column, musculature 107
Vestibule
laryngeal 46
nasal 44
oral 44
Visceral trunk 72, 74
Vomer 46
Vulva
dorsal commissure 86
labia 86
labial fissure 86
rima pudendi 86
ventral commissure 86

W
Wing (ala)
of nose 44
of sphenoid bone 33

Y
Yellow abdominal tunic 66, 80