


A PRACTICAL MANUAL OF  
**LAPAROSCOPY**  
AND MINIMALLY INVASIVE  
GYNECOLOGY

**A Clinical Cookbook**

**Second Edition**



*Resad P. Pasic, M.D., Ph. D.*  
*Ronald L. Levine, M.D.*

**informa**  
healthcare

---

**A PRACTICAL MANUAL  
OF LAPAROSCOPY AND  
MINIMALLY INVASIVE  
GYNECOLOGY**

---



---

# **A PRACTICAL MANUAL OF LAPAROSCOPY AND MINIMALLY INVASIVE GYNECOLOGY:**

## **A CLINICAL COOKBOOK SECOND EDITION**

**RESAD P. PASIC, M.D., PhD.**

Associate Professor of Obstetrics, Gynecology & Women's Health  
Director, Section of Operative Gynecologic Endoscopy  
University of Louisville School of Medicine  
Louisville, KY, USA

**RONALD L. LEVINE, M.D.**

Professor of Obstetrics, Gynecology & Women's Health  
University of Louisville School of Medicine  
Louisville, KY, USA

**informa**  
healthcare

---

.....

© 2007 Informa UK Ltd

First published in the United Kingdom in 2007 by Informa Healthcare, 4 Park Square, Milton Park, Abingdon, Oxon OX14 4RN. Informa Healthcare is a trading division of Informa UK Ltd. Registered Office: 37/41 Mortimer Street, London W1T 3JH. Registered in England and Wales number 1072954.

Tel: +44 (0)20 7017 6000  
Fax: +44 (0)20 7017 6699  
Email: [info.medicine@tandf.co.uk](mailto:info.medicine@tandf.co.uk)  
Website: [www.informahealthcare.com](http://www.informahealthcare.com)

All rights reserved. No part of this publication may be reproduced, stored in a retrieval system, or transmitted, in any form or by any means, electronic, mechanical, photocopying, recording, or otherwise, without the prior permission of the publisher or in accordance with the provisions of the Copyright, Designs and Patents Act 1988 or under the terms of any licence permitting limited copying issued by the Copyright Licensing Agency, 90 Tottenham Court Road, London W1P 0LP.

Although every effort has been made to ensure that all owners of copyright material have been acknowledged in this publication, we would be glad to acknowledge in subsequent reprints or editions any omissions brought to our attention.

A CIP record for this book is available from the British Library.  
Library of Congress Cataloging-in-Publication Data

Data available on application

ISBN-10: 1 84214 330 1  
ISBN-13: 978 1 84214 330 8

Distributed in North and South America by  
Taylor & Francis  
6000 Broken Sound Parkway, NW, (Suite 300)  
Boca Raton, FL 33487, USA

*Within Continental USA*  
Tel: 1 (800) 272 7737; Fax: 1 (800) 374 3401  
*Outside Continental USA*  
Tel: (561) 994 0555; Fax: (561) 361 6018  
Email: [orders@crcpress.com](mailto:orders@crcpress.com)

Distributed in the rest of the world by  
Thomson Publishing Services  
Cheriton House  
North Way  
Andover, Hampshire SP10 5BE, UK  
Tel: +44 (0)1264 332424  
Email: [tps.tandfsalesorder@thomson.com](mailto:tps.tandfsalesorder@thomson.com)

Composition by Scribe Design Ltd, Ashford, Kent, UK  
Printed and bound in India by Replika Press Pvt Ltd

.....

**W**e dedicate this book to the memory of Dr Kurt Semm. All gynecologists who perform laparoscopy owe a great debt to this forward thinking physician. In the 1970s and early 1980s, Dr Semm generated a great deal of controversy as many gynecologists in the United States and in his native Germany refused to accept his ideas on minimally invasive gynecology. Without his contributions, advanced operative laparoscopy could not have progressed to its present state of prominence.

We can directly trace the development of many of the instruments and procedures that we describe in this book to innovative inventions and techniques that Dr Semm pioneered. He not only designed new instruments, but was actively engaged in the manufacturing and distribution of his inventions. His list of inventions and “firsts” is long and important.

- His early magnificent photos and movies set new standards in laparoscopy and became the foundation for several books.
- He developed the first trainer for laparoscopy that he called the “Pelvi Trainer.”
- He invented and developed the first electronic insufflators, the morcellator, the endo-coagulator, needle holders, endosuture and the loop ligature among others.
- He performed the first laparoscopic appendectomy and described several innovative operative procedures including such things as the “curling iron” technique of removing an ovarian cyst.

Personally, I will always be thankful for my wonderful experience with Dr Semm in Kiel in 1983. It was a thrill to be in the operating theatre with this giant in our specialty.

It is only fitting that we dedicate this *Manual of Laparoscopy* to the memory of “the father of modern day laparoscopy,” Dr Kurt Semm.



# CONTENTS

	List of Contributors	ix
	Foreword	xv
	Preface	xvii
	Acknowledgements	xix
1	Patient preparation <i>Ronald L Levine</i>	1
2	Pelvic anatomy seen through the laparoscope <i>Robert M Rogers Jr</i>	7
3	Instrumentation and equipment <i>Ronald L Levine</i>	19
4	Anesthesia in laparoscopy <i>Laura Clark</i>	39
5	Creation of pneumoperitoneum and trocar insertion techniques <i>Resad Pasic</i>	57
6	Energy systems in laparoscopy <i>Andrew Brill</i>	75
7	All you need to know about laparoscopic suturing <i>Resad Pasic</i>	97
8	Laparoscopic tubal sterilization <i>Ronald L Levine</i>	109
9	Endometriosis <i>Dan C Martin</i>	117



10	Laparoscopic surgery for adhesions <i>Harry Reich, Lisa M Roberts, and Enda McVeigh</i>	129
11	Ectopic pregnancy <i>Danielle E Luciano, Gerard Roy, and Anthony Luciano</i>	155
12	Endoscopic surgery for chronic pelvic pain <i>David L Olive</i>	169
13	Laparoscopic management of the adnexal mass <i>C William Helm and Resad Pasic</i>	179
14	Laparoscopic presacral neurectomy <i>Ceana Nezhat and Deidre Fisher</i>	191
15	Laparoscopic hysterectomy <i>Robert S Furr and CY Liu</i>	197
16	Laparoscopic supracervical hysterectomy <i>Thomas L Lyons, Assia Stepanian, and Wendy K Winer</i>	211
17	Laparoscopic myomectomy and laparoscopically assisted myomectomy <i>Ceana Nezhat and Deidre Fisher</i>	223
18	Laparoscopic occlusion of uterine arteries <i>Kirsten Hald and Olav Istre</i>	231
19	Tissue retrieval in endoscopic surgery <i>Eric Heinberg and Resad P Pasic</i>	239
20	Retroperitoneal dissection of the pelvic sidewall for benign disease <i>Grace M Janik</i>	251
21	Lower urinary tract endoscopy <i>Sam H Hessami and David Shin</i>	261
22	Laparoscopic paravaginal repair and burch urethropexy <i>Robert D Moore and John R Miklos</i>	271
23	Tension free vaginal tape and TOT sling for stress urinary incontinence <i>Robert D Moore and John R Mikos</i>	287
24	Pelvic floor surgery <i>Timothy B McKinney</i>	295

25	Laparoscopic sacralcolpopexy and enterocele repair with mesh <i>Robert D Moore and John R Miklos</i>	309
26	Use of mesh in vaginal pelvic reconstructive surgery <i>Sam H Hessami</i>	327
27	Pediatric laparoscopy <i>Claire Templeman and S Paige Hertweck</i>	339
28	Endoscopic diagnosis and correction of malformations of female genitalia <i>Leila V Adamyan and Katerina L Yarotskaya</i>	347
29	Laparoscopic bowel surgery <i>Jeff W Allen and Benjamin D Tanner</i>	365
30	Gasless laparoscopy <i>Daniel Kruschinski, Bernd Bojahr, and Miroslav Kopjar</i>	377
31	Laparoscopic radical hysterectomy: traditional and nerve-sparing technique <i>Javier F Magrina, Rosanne Kho, and Wojciech Pawlina</i>	391
32	Laparoscopic lymphadenectomy in gynecologic oncology <i>Farr Nezhat and Tanja Pejovic</i>	407
33	Robotics: the clinical nuts and bolts to applications in minimally invasive gynecologic surgery <i>Arnold P Advincula</i>	415
34	Complications of laparoscopy <i>Barbara Levy and Michael Traynor</i>	427
	Index	445



---

# CONTRIBUTORS

**LEILA V. ADAMYAN, M.D.**

Professor of Obstetrics and Gynecology  
Academician of the Russian Academy  
of Medical Sciences  
Chief of the Department of Operative Gynecology  
Scientific Center for OB/GYN & Perinatology  
Chair of the Department of Reproductive  
Medicine and Surgery  
Moscow State University of Medicine and Dentistry  
Moscow, Russia

**ARNOLD P. ADVINCULA, M.D.**

Assistant Professor  
Department of Obstetrics and Gynecology  
Director of Minimally Invasive Surgery  
Program & Fellowship  
University of Michigan Medical Center  
Ann Arbor, MI, USA

**JEFF W. ALLEN, M.D.**

Associate Professor of Surgery  
University of Louisville School of Medicine  
Louisville, KY, USA

**BERND BOJAHN, M.D.**

Department for Gynaecology and Obstetrics  
University of Greifswald, Germany

**ANDREW I. BRILL, M.D.**

Professor of Obstetrics and Gynecology  
Director, Gynecologic Endoscopy  
The University of Illinois at Chicago  
Chicago, IL, USA

**LAURA CLARK, M.D.**

Associate Professor of Anesthesiology  
University of Louisville School of Medicine  
Louisville, KY, USA

**DEIDRE T. FISHER, M.D.**

Fellow of Advanced Pelvic Surgery  
Atlanta Center for Special Pelvic Surgery  
Atlanta, GA, USA

**ROBERT S. FURR, M.D.**

Fellow of Advanced Gynecologic Endoscopy  
Chattanooga Women's Laser Center  
Chattanooga, TN, USA

**KIRSTEN HALD, M.D.**

Consultant of Gynecology & Obstetrics  
Ullevål University Hospital  
Oslo, Norway

**ERIC M. HEINBERG, M.D., MPH**

Fellow of Advanced Gynecologic Endoscopy  
Obstetrics, Gynecology & Women's Health  
University of Louisville School of Medicine  
Louisville, KY, USA

**C. WILLIAM HELM, M.D.**

Associate Professor of Obstetrics,  
Gynecology & Women's Health  
Division of Gynecologic Oncology  
University of Louisville School of Medicine  
Louisville, KY, USA

---

**S. PAIGE HERTWECK, M.D.**

Associate Professor of Obstetrics,  
Gynecology & Women's Health  
Director of Pediatric and Adolescent Gynecology  
University of Louisville School of Medicine  
Louisville, KY, USA

**SAM H. HESSAMI, M.D.**

Associate Clinical Professor of Obstetrics  
and Gynecology  
Associate, Urology Specialty Care  
Mount Sinai School of Medicine, New York  
Chief, Division of Urogynecology & Pelvic Surgery  
Hackensack University Hospital and St. Joseph's  
Medical Center  
Fair Lawn, NJ, USA

**OLAV ISTRE, M.D., PH.D.**

Consultant of Gynecology & Obstetrics  
Ullevål University Hospital  
Oslo, Norway

**GRACE JANIK, M.D.**

Reproductive Specialty Center  
Milwaukee, WI, USA

**ROSANNE M. KHO, M.D.**

Senior Associate Consultant of Gynecology  
Mayo Clinic Scottsdale  
Scottsdale, AZ, USA

**MIROSLAV KOPJAR, M.D.**

Department for Gynaecology and Obstetrics  
General Hospital Zabok, Croatia

**DANIEL KRUSCHINSKI, M.D.**

EndoGyn®  
Institute for Endoscopic Gynaecology  
Seligenstadt, Germany

**RONALD L. LEVINE, M.D.**

Professor of Obstetrics,  
Gynecology & Women's Health  
Section of Operative Gynecologic Endoscopy  
University of Louisville School of Medicine  
Louisville, KY, USA

**BARBARA LEVY, M.D., P.S.**

Assistant Clinical Professor  
Yale University School of Medicine  
University of Washington School of Medicine  
Federal Way, WA, USA

**C.Y. LIU, M.D.**

Director of Chattanooga Women's Laser Center  
Chattanooga, TN, USA

**ANTHONY LUCIANO, M.D.**

Professor of Obstetrics and Gynecology  
University of Connecticut School of Medicine  
Director of the Center for  
Fertility & Women's Health  
New Britain General Hospital  
New Britain, CT, USA

**DANIELLE E. LUCIANO, M.D.**

Fellow in Advanced Gynecologic Endoscopy  
Department of Obstetrics and Gynecology  
University of Connecticut School of Medicine  
Center for Fertility & Women's Health  
New Britain General Hospital  
New Britain, CT, USA

**THOMAS L. LYONS, M.D.**

Director of Health South Surgery Center  
Center for Women's Care & Reproductive Surgery  
Atlanta, GA, USA

**JAVIER F. MAGRINA, M.D.**

Professor of Obstetrics and Gynecology  
Barbara Woodward Lips Professor  
Mayo Clinic Scottsdale  
Scottsdale, AZ, USA

**DAN C. MARTIN, M.D.**

Clinical Professor of Obstetrics and Gynecology  
University of Tennessee, Memphis  
University of Tennessee Health Sciences Center  
Memphis, TN, USA

**TIM B. McKINNEY, M.D.**

Associate Professor of Obstetrics and Gynecology  
 Chief of Urogynecology and Pelvic Reconstruction  
 Surgery at UMDNJ-SOM  
 Director of Fellowship in Urogynecology at Athena  
 Women's Medical Center  
 Medical Director and founder/owner of T-DOC LLC  
 Moorestown, NJ, USA

**ENDA McVEIGH, M.D.**

Senior Fellow in Reproductive  
 Medicine & Medical Director  
 Oxford Fertility Unit  
 Oxford University  
 Headington, Oxford, UK

**JOHN R. MIKLOS, M.D.**

Director of Urogynecology  
 Atlanta Center for Laparoscopic Urogynecology  
 & Reconstructive Vaginal Surgery  
 Clinical Instructor  
 Medical College of Georgia  
 Atlanta, GA, USA

**ROBERT D. MOORE, DO**

Director of Advanced Pelvic Surgery  
 Co-Director Urogynecology  
 Atlanta Urogynecology Associates  
 Atlanta Center for Laparoscopic Urogynecology  
 Alpharetta, GA, USA

**CEANA NEZHAT, M.D.**

Director of Obstetrics & Gynecology  
 Atlanta Center for Special Pelvic Surgery,  
 Atlanta, GA, USA

**FARR NEZHAT, M.D.**

Director of Gynecologic Minimally Invasive Surgery  
 Department of Gynecology Oncology  
 Mount Sinai School of Medicine  
 New York, NY, USA

**DAVID L. OLIVE, M.D.**

Vice Chairman of Obstetrics and Gynecology  
 University of Wisconsin  
 Madison, WI, USA

**RESAD P PASIC, M.D., PH.D.**

Associate Professor of Obstetrics,  
 Gynecology & Women's Health  
 Director, Section of Operative  
 Gynecologic Endoscopy  
 University of Louisville School of Medicine  
 Louisville, KY, USA

**WOJCIECH PAWLINA, M.D.**

Associate Professor and Chair  
 Department of Anatomy  
 Mayo Clinic College of Medicine  
 Rochester, MN, USA

**TANJA PEJOVIC, M.D., PH.D.**

Department of Obstetrics and Gynecology  
 Division of Gynecologic Oncology  
 Oregon Health & Science University  
 Portland, OR, USA

**HARRY REICH, M.D.**

Attending Physician, Wyoming Valley  
 Health Care System  
 Wilkes-Barre, Pennsylvania  
 Community Medical Center, Scranton, Pennsylvania  
 St. Vincent's Hospital and Medical Center  
 of New York  
 Shavertown, PA, USA

**LISA M. ROBERTS, M.D.**

Fellow of Advanced Gynecologic  
 Endoscopic Surgery  
 Shavertown, PA, USA

**ROBERT ROGERS, JR., M.D.**

Clinical Assistant Professor of OB/Gyn  
 University of Pennsylvania  
 Philadelphia, PA  
 Attending Physician  
 The Reading Hospital & Medical Center  
 Reading, PA, USA

**GERARD ROY, M.D.**

Attending Physician  
 Clinical Instructor of Obstetrics and Gynecology  
 Center for Fertility and Women's Health  
 New Britain General Hospital  
 New Britain, CT, USA

**DAVID SHIN, M.D.**

Associate, Urology Specialty Care  
Mount Sinai School of Medicine, New York  
Hackensack University Hospital and St. Joseph's  
Medical Center  
Fair Lawn, NJ, USA

**ASSIA STEPANIAN, M.D.**

Fellow of Advanced Endoscopic Surgery  
Center for Women's Care and Reproductive Surgery  
and Emory University School of Nursing  
Atlanta, GA, USA

**BENJAMIN D. TANNER, M.D.**

Fellow in Minimally Invasive Surgery  
Department of Surgery  
University of Louisville School of Medicine  
Louisville, KY, USA

**CLAIRE TEMPLEMAN, M.D.**

Assistant Professor of Obstetrics,  
Gynecology & Surgery  
Keck School of Medicine  
University of Southern California  
Children's Hospital of Los Angeles  
Division of Pediatric Surgery  
Women and Children's Hospital  
Los Angeles, CA, USA

**MICHAEL P. TRAYNOR, M.D., MPH**

Northwest Kaiser Permanente  
Mt. Talbert Medical Office  
Clackamas, OR, USA

**WENDY WINER, RN, BSN**

Endoscopic Surgery Specialist  
Center for Women's Care and Reproductive Surgery  
and Emory University School of Nursing  
Atlanta, GA, USA

**KATERINA L. YAROTSKAYA, M.D.**

Senior Researcher of Operative Gynecology  
Scientific Center for Obstetrics,  
Gynecology & Perinatology  
of the Russian Academy of Medical Sciences  
Professor of Reproductive Medicine and Surgery  
Moscow State University of Medicine and Dentistry  
Moscow, Russia

# FOREWORD

With their most recent edition of *A Practical Manual of Laparoscopy: A Clinical Cookbook*, Drs Pasic and Levine present technical innovations, while offering enhanced knowledge, wisdom, and surgical pearls. They augment their prior book with excellent photographs, which, in combination with the vast illustrations and descriptions, help solidify surgical concepts and clarify the related anatomy.

This book is written and edited with the unique insight of two well-respected colleagues. The Senior Editor, Dr Resad Pasic, is an internationally acclaimed expert in advanced endoscopic surgery and has operated with and trained innumerable physicians worldwide. Dr Ronald Levine, considered the “father of American endoscopy,” epitomizes the life-long learner, always seeking new skills, techniques, and approaches. He has educated and mentored literally thousands of surgeons throughout the world. Together they have assembled many of the world’s finest endoscopic surgeons to present their insight, “tricks of the trade,” and share their surgical experience. Their love of laparoscopy exudes from the pages.

In this cookbook, Drs Pasic and Levine present the recipe with which a novice can learn the basics and the expert can tailor, modify, and expand their endoscopic approaches. This book reminds one of the rewards and joy of challenging one’s abilities to achieve new levels of expertise.

JAMES M. SHWAYDER, M.D., J.D.  
University of Louisville





# PREFACE

The first edition of this book was received exceptionally well by both practicing gynecologists and by residents in training. In the first edition, we presented material by eminent laparoscopists in an easy to read format accompanied by digital drawings in order to supply the optimal information to the reader regarding the various procedures.

We have again tried to maintain that format but with the enhancement of colored digital illustrations. We have also added several chapters on newer techniques especially in Urogynecology.

We believe that the information contained in this volume will enhance the skills of the practicing gynecologic surgeon while developing the base for the novice laparoscopists and for all individuals who believe in the concepts of minimally invasive gynecology.

**Resad P Pasic**  
**Ronald L Levine**



---

# ACKNOWLEDGEMENTS

As in previous texts of this “Clinical Cookbook” series, we must first and foremost acknowledge the multiple outstanding gynecologists who have contributed to our chapters. A work such as this can only be meaningful if the contributors are the leaders in endoscopic surgery. We also must thank the many members of industry, whose support has made our work possible:

Boston Scientific, Ltd.  
Ethicon Women’s Health and Urology  
Gyrus ACMI  
I-Flow Corporation  
Karl Storz Endoscopy  
SurgRx, Inc.  
Tyco Healthcare/US Surgical/Valley Lab

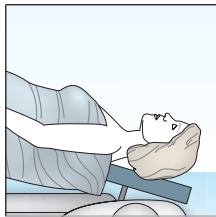
We are also thankful for working in the educational environment of the University of Louisville School of Medicine, Department of Obstetrics, Gynecology and Women’s Health. The students, residents and faculty have all been wonderful guides on the difficult path towards better surgical training.

We are indebted to the talents of our illustrator and graphic designer Branko Modrakovic for his creativity and guidance. Producing a book is an extremely difficult task, one that would not be possible without the wisdom and hard work of our editorial assistant, Ms Leta Weedman and our executive assistant, Ms Laura Lukat who have been a continuing source of ideas and patience.

---



# PATIENT PREPARATION



***Ronald L. Levine, M.D.***

**M**inimally invasive, laparoscopic surgery is, and must always be, considered major surgery. Therefore, it is important to carefully prepare the patient for surgery both psychologically as well as physically. The surgeon must also be prepared by adequate training and practice in the techniques that are necessary to complete the procedure in a safe and efficient manner. Patient preparation begins with the initial decision to perform laparoscopic surgery, and although it is tempting to convert most procedures to a minimally invasive route, the surgeon must consider if the particular pathology should be approached in this manner and is in the best interest of the patient. Just as importantly, the surgeon must honestly evaluate his/her own ability and training.

## PATIENT EVALUATION

Initial patient evaluation considers the indications and contraindications of laparoscopic surgery. There are no hard and fast rules and even the term “absolute contraindication” must be considered as a guideline, rather than a final decree.

## ABSOLUTE CONTRAINDICATIONS

There are very few absolute contraindications as previously noted. With increased anesthesia ability, even some of these may not be considered absolute.

- Severe cardiac disease: (Class IV) these patients may not tolerate the deep Trendelenburg positions necessary during most operative laparoscopy to maintain an adequate pneumoperitoneum that is frequently required for satisfactory vision and instrument movement (See Chapter 4).

- A hemodynamically unstable patient with the need for control of bleeding probably should be approached by laparotomy. However, many surgeons believe that they can rapidly enter an abdomen safely laparoscopically, even in the face of a ruptured ectopic, for example.

- Intestinal obstruction with distended bowel is best approached by laparotomy, however, with some of the open laparoscopy techniques, it may be possible to utilize laparoscopy even in these conditions.

## RELATIVE CONTRAINDICATIONS

- Multiple previous major surgeries must be considered a possible contraindication, depending upon both the entry technique and the skill of the operating surgeon. However, utilization of left upper quadrant insufflation techniques or open laparoscopy may afford safe entry even in the event of

multiple previous surgeries (See Chapter 5).

- Morbid obesity may be daunting to the inexperienced laparoscopist, however, with the use of operative techniques described in Chapter 5, patients as heavy as 350 to 400 lbs often may be candidates for laparoscopy.

- Pregnancy beyond five months gestation must be approached with a great deal of caution as the pelvis is almost completely filled with the enlarged uterus. Some surgeons have used gasless laparoscopy in more advanced pregnancies. However, some studies have shown that the CO<sub>2</sub> gas of the pneumoperitoneum does not harm the fetus.

- Severe, chronically ill patients may present anesthesia problems, but may still be approached cautiously with laparoscopic surgery. It is important not to compromise the respirations with a pneumoperitoneum that is too large.

- The patient should not be compromised by laparoscopic surgery if malignancy is a possibility. If a mass is known to be malignant and the surgeon does not have the skills necessary for complete removal without rupture of the mass, then laparoscopy is not the operation of choice. Some gynecologic oncologists have the skills not only to remove a mass, but also to perform lymph node dissections. In the hands of such surgeons, laparoscopy is acceptable.

## INFORMED CONSENT

Good informed consent actually provides much more than merely a legal requirement. The patient who has a full understanding of the surgical procedure is much less anxious than one who is fearful because of lack of knowledge. We highly recommend the use of videotapes or movies to explain the surgery. Plastic models or pictures may also be used so that the patient has a full comprehension of her pathology and of the proposed operation. The patient should be given time to ask any questions that may be of concern to her. It is always best, if possible, to have a member of the family or a close friend present during these discussions. Because of nervousness and apprehension, patients frequently forget the information that has been explained to them and the support person may be able to fill in the blanks.

The patient should be honestly informed of the alternative procedures. She should be told that general anesthesia is usually required and this will necessitate the use of a tube being placed into her throat. This may give her a slight sore throat. She should be seen preoperatively by the anesthesiologist who will explain the procedure and risks to her. She should be told how she will be positioned during surgery and of the method used to create a pneumoperitoneum. She should also understand about the placement of trocars and the possibility of injury to bowel or urinary tract. She must be apprised of the risks of injury up to and including death. It is advisable to

design an informed consent sheet that is specific for laparoscopy. This should be written in layman's language. Never promise that the surgery will be accomplished by laparoscopy. It is best to say that if surgery can be performed by laparoscopy, then the patient will usually have certain advantages: quicker recovery time, less pain and less scarring. The patient should be informed at this time regarding her expected postoperative course. She should be advised of the degree of pain that may or may not be expected. She should be encouraged to call regarding any pain that is present for more than 48 hours postoperatively.

## PREOPERATIVE ROUTINE

The patient should be seen within 1-2 weeks of the surgery at which time a review of the history and a physical exam should be conducted that at least covers the following:

1. Weight;
2. Blood pressure and pulse;
3. Auscultation of the lungs and heart;
4. Palpation of the abdomen for organomegaly and hernias.
5. Complete bimanual pelvic examination including PAP smear if indicated.

Many hospitals require laboratory tests within one or two weeks of the surgical procedure. Most laparoscopy requires a minimum of laboratory tests usually consisting of only hemoglobin and hematocrit and urinalysis. A coagulation profile may be needed for any patient with a history of bleeding problems. Patients who have



other medical problems may also need further evaluation by their general medical doctor who may require other laboratory testing such as a multi-panel test.

Patients who are over 40 years old often benefit from a chest X-ray if one has not been obtained within the last 2 years. It is important to review her medicines and to inquire about the use of aspirin. Many patients do not consider aspirin a drug and neglect to inform the doctor of its chronic use. If the patient has been taking aspirin it should be discontinued for 3 or 4 days prior to surgery.

We recommend that all patients eat lightly for 24 hours and be NPO at least 12 hours prior to surgery. A Fleet enema is helpful the night before most laparoscopic surgery and if extensive dissection is anticipated, an oral preparation such as Golytely™ (Braintree Laboratories, Braintree, MA) is recommended the afternoon before. An empty bowel permits better visualization during surgery, and in the event of a bowel injury, decreases the possibility of complications.

## DAY OF SURGERY

Since most laparoscopic surgery is performed on an outpatient basis, it is recommended that surgery be started in the morning if possible. The patient is instructed to arrive at least 1.5 hours prior to surgery to allow adequate time for the anesthesiologist to see the patient, and for all laboratory results to be checked. Before the patient receives any medication for anesthesia, review the anticipated surgery with her and again allow opportunity for any questions.

When the surgery is completed and the patient is awake, she is given written instructions regarding follow-up visits and how to take care of herself. The instructions should cover when she should bath (anytime), begin to drive (after 24 hours), perform household duties, and when she may return to work. It should be carefully worded to explain expected postoperative discomfort and to differentiate it from severe pain that requires her to contact either the surgeon or a designated contact person with a telephone number that is answered 24 hours a day.

Patients should be discharged with all the appropriate instructions and medication or a prescription for pain relief.

.....

---

SUGGESTED READING:

Pasic R, Levine R, Wolfe W. Laparoscopy in morbidly obese patients.  
J AAGL 1999;6:307-312

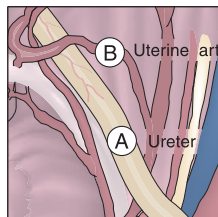
Laparoscopic Surgery. Ballantyne GH, Leahy PF, Modlin IM, eds.  
Philadelphia: W.B. Saunders, 1994

Levine RL, Pasic R. Set up. In: Clinical Gynecology.  
Bieber E, Sanfilippo J, Horowitz I, eds.  
New York, Elsevier Science Publishing, 2006

---



# PELVIC ANATOMY SEEN THROUGH THE LAPAROSCOPE



***Robert M. Rogers, Jr., M.D.***

**F**or laparoscopists, female pelvic anatomy is that of surfaces and underlying abdominal and retroperitoneal structures. Surface landmarks on the anterior abdominal wall locate safe areas in which to pass laparoscopic trocars to establish ports through which laparoscopic instruments can be passed into the pelvic cavity to perform the planned surgery. Superficial peritoneal landmarks within the pelvis alert the operator to key anatomic structures in the retroperitoneal spaces. A sure knowledge of surgical and laparoscopic anatomy is a requisite for performing laparoscopic procedures that are safe for the patient and achieve the desired goal of the surgery. The three-dimensional field of pelvic anatomy as seen through the two-dimensional plane of the laparoscope is a difficult challenge to master. The diligent laparoscopic gynecologist must always study and then observe carefully in order to gain this sure, working knowledge. Just as technical skills can be consistently improved through frequent and proper practice, so can one's working knowledge of gynecologic surgical pelvic anatomy.

The following will be discussed: the anterior abdominal wall; the presacral space; the area of the pelvic brim; the sidewall of the pelvis; the

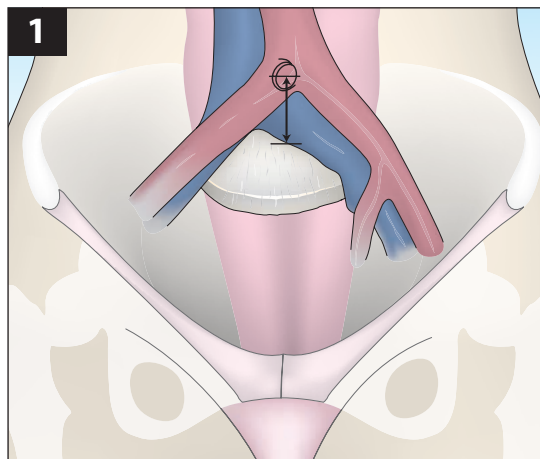
area at the base of the broad ligament; the various spaces within the pelvis; and the anatomy of the retropubic space (space of Retzius).

## THE ANTERIOR ABDOMINAL WALL

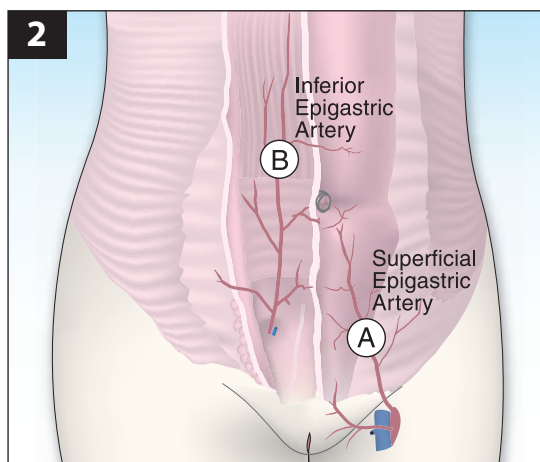
The various ports needed to perform laparoscopic surgery must traverse the anterior abdominal wall, thus knowledge of this anatomy is important to avoid a primary complication of injury to the arteries and veins contained therein. Landmarks of interest are the umbilicus, the anterior superior iliac spines, and pubic symphysis. In addition, landmarks on the interior abdominal wall will assist the laparoscopist in safely placing trocars in order to avoid injuring deeper vascular structures such as the aorta, common iliac vessels, and the external iliac vessels.

Depending upon the habitus and weight of the patient, the umbilicus may lie slightly above, at, or below the bifurcation of the aorta. In all patients, the left common iliac vein crosses the midline approximately 3-6 cm inferior to the bifurcation of the aorta and, therefore, inferior to the level of the umbilicus (Figure 1). In the thinner patient especially, the surface of the anterior-abdominal wall is significantly closer to these great vessels.

In placement of lower lateral abdominal trocars, the surgeon must avoid lacerating the inferior and/or superficial epigastric arteries and veins and their



Left common iliac vein crosses the midline approximately 3-6 cm inferior to the level of the umbilicus.



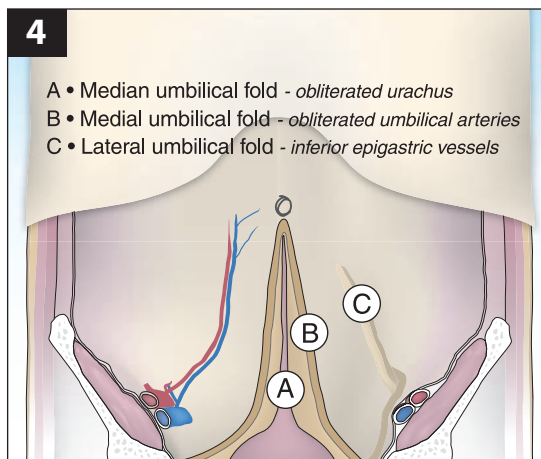
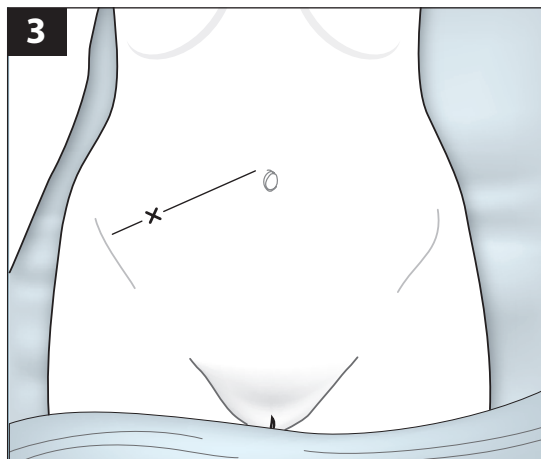
branches. The inferior epigastric artery and vein travel on the posterior surface of the rectus abdominis muscle on its lateral third, particularly in the lower quadrants of the abdomen (Figure 2). The superficial epigastric arteries and veins travel within the subcutaneous tissue of the anterior abdominal wall in variable locations lateral to the umbilicus. The superficial vessels can be seen by transillumination of the anterior abdominal

wall, while the inferior epigastric vessels cannot be seen due to shadowing from the rectus abdominis muscles. These latter vessels must be seen directly through the laparoscope.

Most injuries to these vessels within the abdominal wall itself can be avoided by placing the lateral ports approximately 8 cm from the midline and 8 cm superior to the pubic symphysis. This area also happens to be known as McBurney's point, which is anatomically located at one-third of the distance from the anterior superior iliac spine along the line from that spine to the umbilicus (Figure 3).

## SUPERFICIAL PERITONEAL ANATOMY

All laparoscopic procedures must begin with a systematic inspection of the surface areas of both the pelvis and upper abdomen. Such examinations should not only visually document the condition of the pelvic viscera and the surfaces within the pelvis, but also include inspection of the appendix, ascending colon, falciform ligament, liver and gall bladder, omentum, transverse colon, stomach, right and left hemidiaphragms, and the descending colon. The operating laparoscopist must visually search for evidence of adhesions, inflammation, endometriosis, cul-de-sac fluid, peritoneal studding, tumors or distortion of any pelvic or abdominal anatomy and structures. All laparoscopic procedures must begin with a systematic inspection of the surface areas of both the pelvis and upper abdomen.



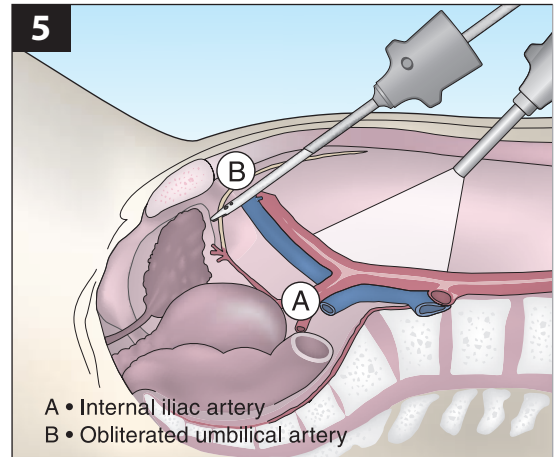
Only through the laparoscope can the operating surgeon appreciate the structures on the undersurface of the anterior abdominal wall. Running from the dome of the bladder underneath a peritoneal fold is the obliterated urachus, known as the median umbilical fold. Just lateral to the median umbilical fold are the medial umbilical folds (Figure 4). These are formed by the peritoneum covering the obliterated umbilical arteries. Each obliterated umbilical artery, when followed back underneath the round ligament,

into the broad ligament, will lead the surgeon to the superior vesicle artery and then back to the terminus of the internal iliac artery (Figure 5). Lateral to the medial umbilical fold is the lateral umbilical fold, which is formed by the tenting of the peritoneum over the inferior epigastric artery and vein. These latter vessels exit the external iliac artery and vein just medial to the exit of the round ligament from the body through the internal inguinal ring. Direct identification through the umbilical laparoscope will allow the laparoscopist to place lateral trocars through the anterior abdominal wall well lateral of these epigastric vessels.

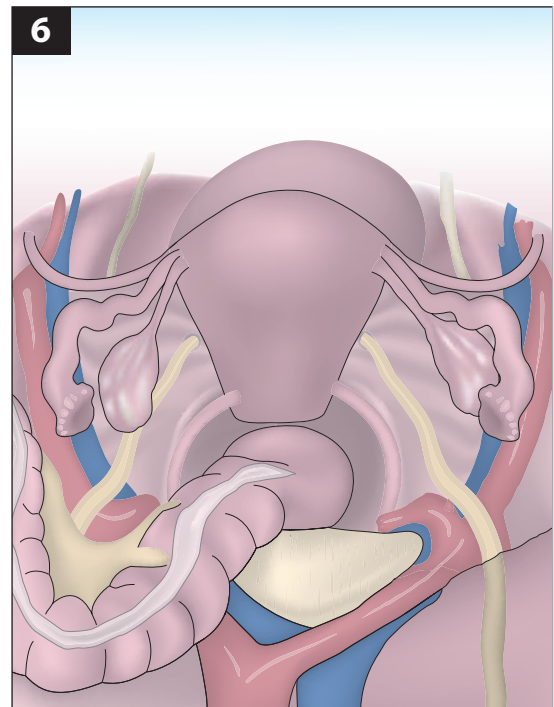
Anterior traction on the uterus will place the uterosacral ligaments on tension and lead the surgeon to visualization of the ureters in the pelvic sidewall. The dome of the bladder is a semilunar outline overlying the pubic symphysis (Figure 6).

## PRESACRAL SPACE

The presacral space is important to laparoscopic surgeons performing 'presacral neurectomies' for the hopeful alleviation of central and chronic pelvic pain. At this time, presacral neurectomy is considered a controversial procedure. The space is bounded anteriorly by the parietal peritoneum. Posteriorly it is bounded by the periosteum and anterior longitudinal ligament over the lower two lumbar vertebrae and the promontory of the sacrum. The middle sacral artery and a plexus of veins are attached to the poste-



Pulling on the obliterated umbilical artery allows laparoscopic surgeon to locate the internal iliac artery and the origin of the uterine artery.

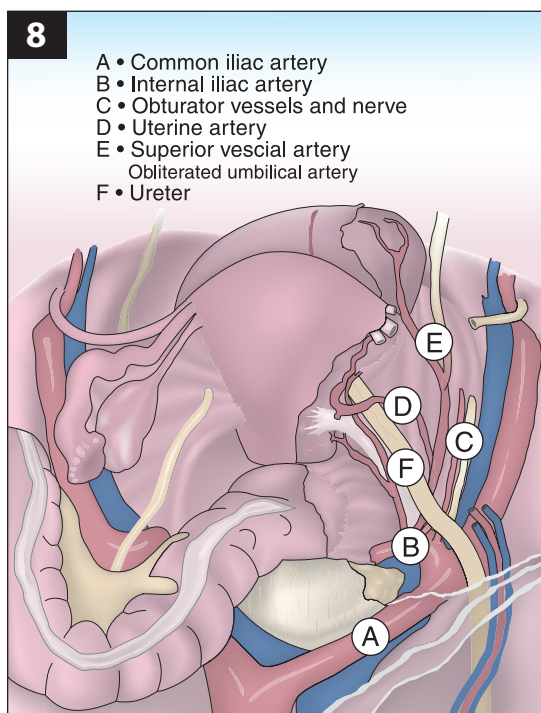
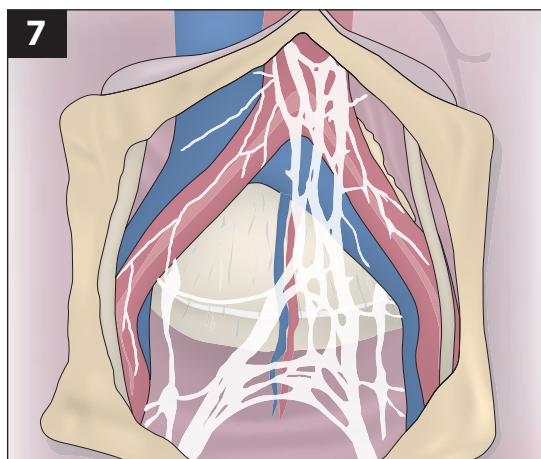


rior boundary of the space. The superior extension of the visceral endopelvic fascia in this area embeds fatty areolar tissue, presacral lymph nodes and tissue,

and visceral nerves (Figure 7). There is not one presacral nerve but a multitude of finer visceral nerves that have great variability in their course and distribution within this space. These 'presacral nerves' are simply the multiple afferent and efferent visceral nerve fibers of the superior hypogastric plexus. The right lateral boundary of this space is the right common iliac artery and ureter. The left lateral border is the left common iliac vein and left ureter, as well as the inferior mesenteric artery and vein traversing the mesentery of the sigmoid colon. Great care must be taken by even experienced laparoscopic surgeons in order to dissect safely within this space. Great damage to the ureter and the possibility of massive hemorrhage exist here.

## PELVIC BRIM

The pelvic brim region at the location over the sacroiliac joint is the important location for the entry of multiple structures into the pelvic cavity. These structures course over the pelvic brim in a vertical manner and then will rotate in a 90° fashion to form the structures of the pelvic sidewall. From the peritoneal surface working posteriorly to the sacroiliac joint, the following structures are found coursing one over the other: the peritoneum; the ovarian vessels in the infundibulopelvic ligament; the ureter traversing over the bifurcation of the common iliac artery; the common iliac vein; the medial edge of the psoas muscle and, in the same plane, the obturator nerve overlying the parietal fascia just



over the capsule of the sacroiliac joint (Figure 8). In the same plane as the obturator nerve, but more medial, the lumbosacral trunk is found coursing from the lumbar plexus of nerves to the sacral plexus of nerves that are found overlying



the piriformis muscle in the pelvis. When ligating the ovarian vessels in the infundibulopelvic ligament, the surgeon must lift the infundibulopelvic ligament well away from the course of the ureter in order to avoid injuring it (Figure 9).

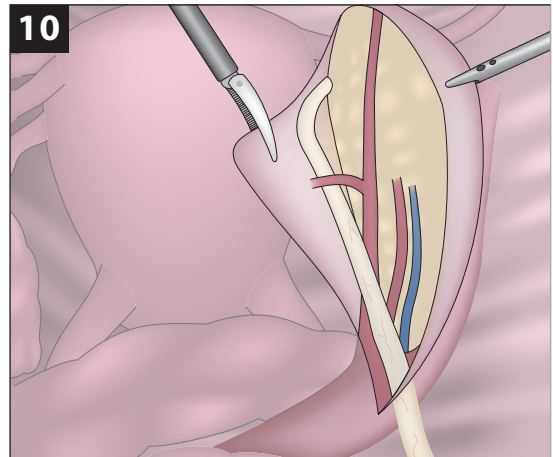
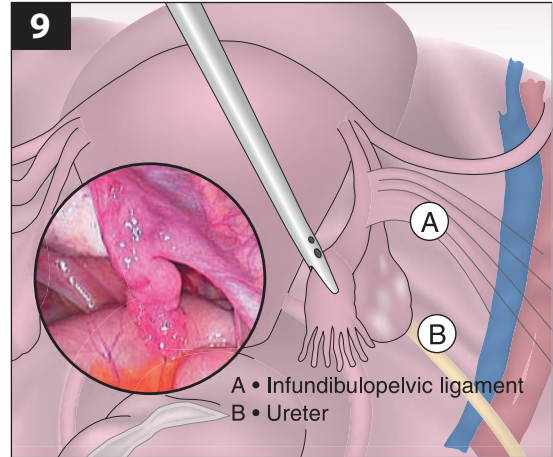
### THE PELVIC SIDEWALL REGION

Based on avascular planes, the pelvic sidewall consists of three surgical layers. Medially, the first layer is the parietal peritoneum with the attached ureter in its own visceral fascial capsule. When this peritoneum is incised and retracted medially the ureter comes with it (Figure 10).

The second surgical layer consists of the internal iliac artery and vein and their visceral anterior branches, all enveloped within the surrounding visceral fascia containing the lymph tissue and the visceral hypogastric nerves.

The third surgical layer consists of the parietal fascia over the obturator internus muscle with the obturator artery, nerve and vein allowed to remain on this muscle. However, during obturator space dissections, the nerve can be retracted safely medially. In addition, the third layer consists of the external iliac artery and vein on the medial aspect of the psoas muscle at the bony arcuate line of the ileum or linea terminalis (Figure 11).

Blunt dissection by the laparoscopic surgeon easily separates the first surgical layer from the second surgical layer, and the second surgical layer from the third surgical layer. The second surgical layer of the pelvic sidewall can also easily be



found by tracing the course of the obliterated umbilical artery back to the superior vesical artery within the broad ligament, back to the terminal root of the internal iliac artery. The medial offshoot at this junction is the uterine artery.

### THE BASE OF THE BROAD LIGAMENT

The base of the broad ligament is that anatomic region where the cardinal liga-

## FIRST LAYER OF PELVIC SIDEWALL

PARIETAL PERITONEUM  
AND URETER.

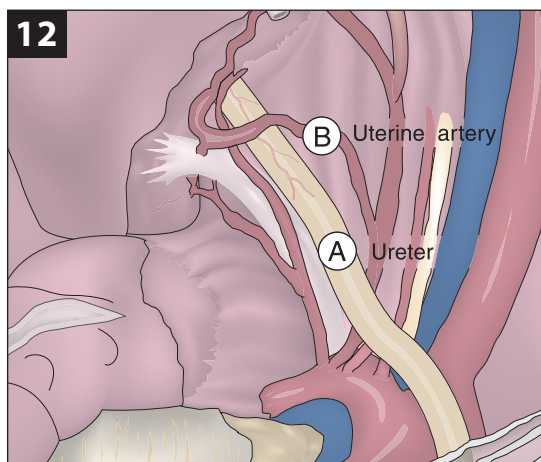
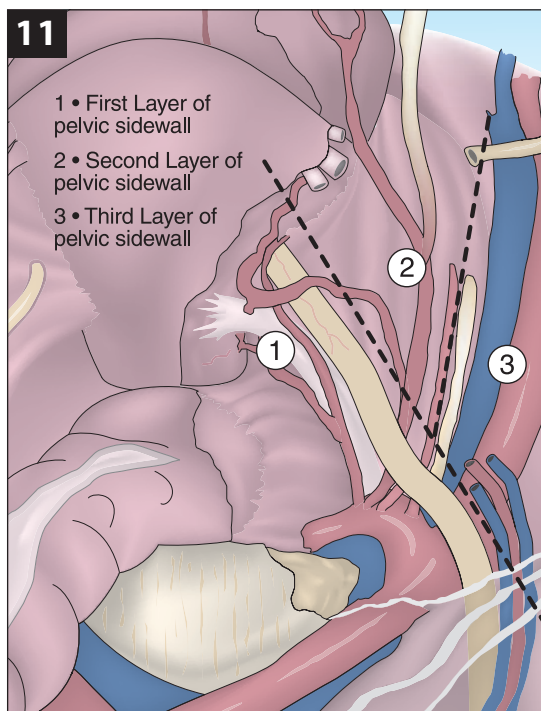
## SECOND LAYER OF PELVIC SIDEWALL

INTERNAL ILIAC VESSELS AND  
THEIR TRIBUTARIES: UTERINE,  
SUPERIOR VESICAL, INFERIOR VESI-  
CAL, VAGINAL, INTERNAL PUDEN-  
DAL, AND INFERIOR GLUTEAL  
ARTERY AND VEIN.

## THIRD LAYER OF PELVIC SIDEWALL

OBTURATOR INTERNUS MUSCLE,  
OBTURATOR NERVE, ARTERY AND  
VEIN. EXTERNAL ILIAC ARTERY  
AND VEIN.

ment inserts into the pericervical ring of endopelvic fascia for upper vaginal support. It contains the ureter traveling underneath the uterine artery in an oblique fashion, approximately 1.5 cm lateral to the side of the cervix. This region is an important anatomic area where the ureter makes a 'knee-bend' in order to turn anteriorly and medially across the anterolateral fornix of the vagina to enter the bladder. It is approximately 2 cm medial and anterior from the ischial spine. It is also called the parametrium. The area located lateral to the vagina is called the upper paracolpium (Figure 12).



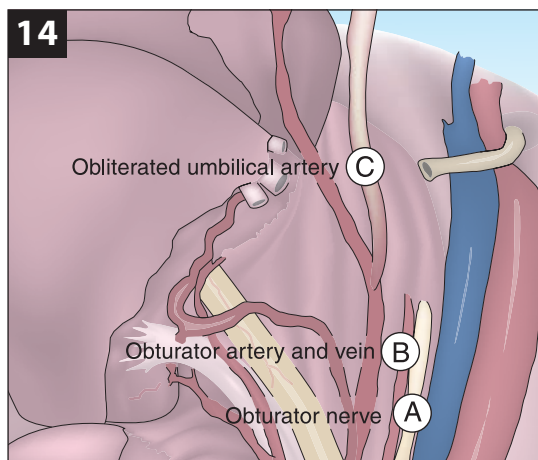
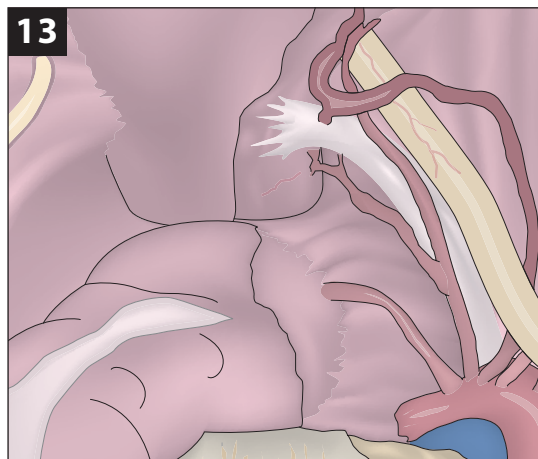
Posterior to the base of the broad ligament is the pararectal space, which is easily developed by dissecting the ureter medially toward the rectum, away from the internal iliac artery and vein, posterior to the origin of the uterine artery. The

anterior border of this space is the base of the broad ligament. The lateral and medial borders are the internal iliac artery and the ureter, respectively. This space also contains the uterosacral ligament laterally as it passes posteriorly toward the sacrum (Figure 13).

The paravesical space is found anterior to the base of the broad ligament and is bounded medially by the bladder and laterally by the obturator internus muscle fascia. The paravesical space simply leads into the lateral space of Retzius. The space within the paravesical space lateral to the obturator nerve is known as the obturator space (Figure 14). From this region above the level of the obturator nerve, the operating laparoscopic gynecologist will harvest the obturator lymph nodes.

## SPACE OF RETZIUS

The space of Retzius or retropubic space is a potential space containing much areolar tissue between the back of the pubic bone and the anterior portion of the bladder. Surrounding the bladder is a visceral bladder capsule that contains the rich network of perivesical venous sinuses that are very fragile and bleed easily when surgery is performed in this space. Centrally over the urethra is the deep dorsal vein of the clitoris that feeds into these venous channels. The lateral border of the space of Retzius is the obturator internus muscle and its parietal fascia, with the obturator nerve, artery, and vein just beneath the bony ridge of the ilium on its anterior border. The pos-



terior border (toward the sacrum) is a visceral fascial sheath surrounding the internal iliac artery and vein and their anterior branches. Remember in the standing female patient, the internal iliac artery starts at the bifurcation at the pelvic brim over the sacroiliac joint and travels in a vertical direction along the anterior border of the greater sciatic foramen down towards the ischial spine (Figure 15).

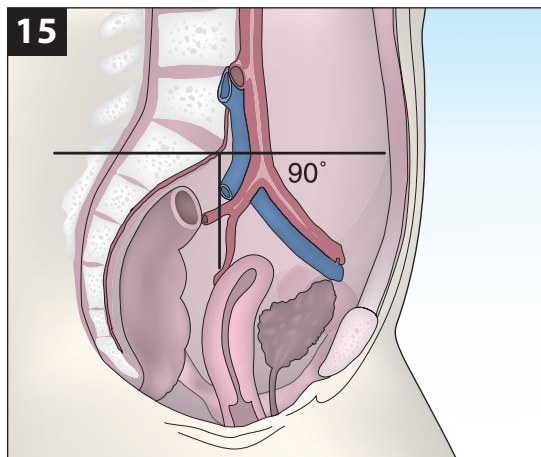
The floor of the space of Retzius is simply the pubocervical fascia inserting

into the lateral fascial white line. The fascial white line (arcus tendineus fasciae pelvis) is a thickening of the parietal fascia overlying the levator ani muscles and travels from the pubic arch straight back to the ischial spine. Just anterior to this fascial white line is a more variable and thinner thickening of the parietal fascia overlying the obturator internus muscle called the muscle white line (arcus tendineus levator ani). The muscle white line is the origin of the levator ani muscles from the lateral and posterior aspects of the pubic bone in a curvilinear fashion back toward the ischial spine that meets with the fascial white line (Figure 16).

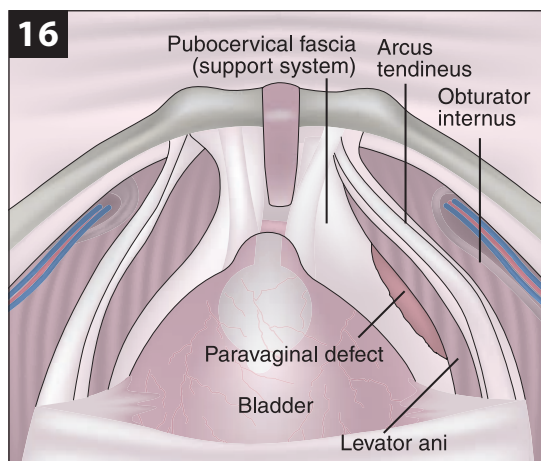
When working in this space and performing a paravaginal defect repair or a Burch retropubic colposcopic suspension through the laparoscope, the surgeon must clear the areolar tissue off the white glistening pubocervical fascia before placing sutures directly into its thickness, which is attached to the underlying vaginal epithelium.

## THE VESICOVAGINAL SPACE

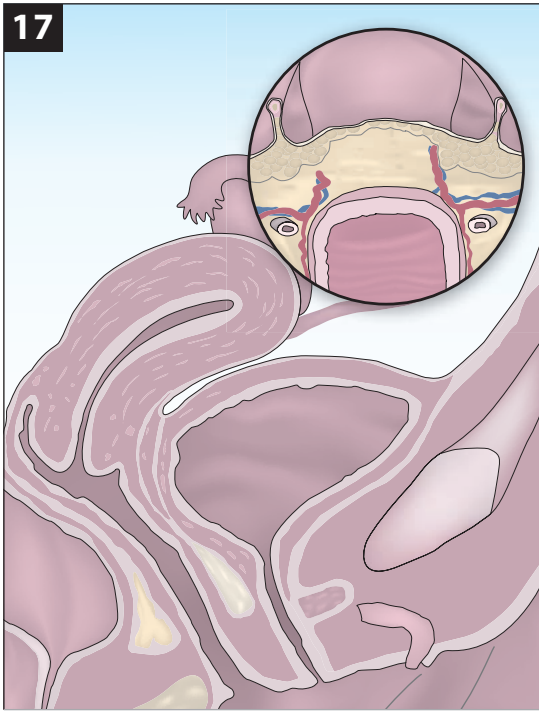
The vesicovaginal space is found between the anterior surface of the vagina and the posterior aspect of the bladder down to the trigone. This space is bordered laterally by the bladder 'pillars', that allow for the passage of the inferior vesical arteries, veins, and ureter to the bladder (Figure 17). This space is important to the surgeon performing a hysterectomy since he/she must incise through the vesicouterine peritoneal fold. This potential space is created by dissect-



In the standing patient, internal iliac artery travels in a vertical direction over the sacroiliac joint toward the ischial spine.

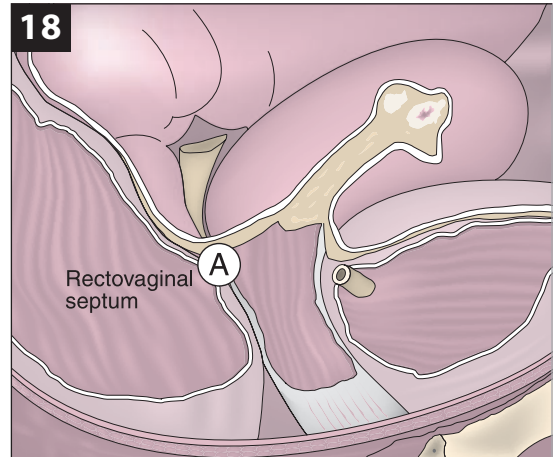


ing between the visceral fascial coat around the bladder and the pubocervical fascia, found on top of the cervix and anterior vaginal wall, down to the level of the trigone. Care must be taken not to dissect too vigorously and laterally to avoid injury to the ureter and vasculature found within the bladder pillars.



## RECTOVAGINAL SPACE

The rectovaginal space is bounded superiorly by the cul-de-sac peritoneum and the uterosacral ligaments, laterally by



the iliococcygeus muscles of the levator ani, posteriorly by the visceral fascial capsule surrounding the anterior surface of the rectum, and anteriorly by the visceral fascial capsule surrounding the posterior aspect of the vagina. The rectovaginal septum is found just behind the vagina, somewhat adherent to it and yet dissectable away from it (Figure 18). The rectovaginal fascia is more and more commonly being used for repair of rectoceles.

---

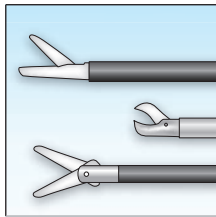
SUGGESTED READING:

Atlas of Human Anatomy. Editor: Frank H. Netter.  
Publisher Ciba-Geigy, 1989

Hurd WW, Bude RO, DeLancey JOL, Newman JS. The location of abdominal wall  
blood vessels in relationship to abdominal landmarks apparent at laparoscopy.  
Am J Obstet Gynecol 1994;171:642-6



# INSTRUMENTATION AND EQUIPMENT



***Ronald L. Levine, M.D.***

**M**any modern operating rooms have been designed to accommodate operative endoscopies; however, there are some variations depending upon the individual requirements of the operating surgeon. Herein, we describe the general requirements of both the setup and the basic equipment that is necessary to perform safe and efficient gynecologic endoscopic surgery. However, there are expanding technologies that are more appropriate for advanced surgery. Some of the most advanced instruments are the robotic surgical equipment and newer forms of energy application. The use of this equipment will also be discussed in other chapters.

## **GENERAL ROOM SETUP**

The setup should be designed to optimize efficiency using the team concept. The team usually consists of the surgeon, a first assistant, a scrub nurse and a circulating nurse. The most recent addition to the traditional team is the biomedical technician. He/she may not be required for the entire case, but it is helpful if they are in attendance at the start, as well

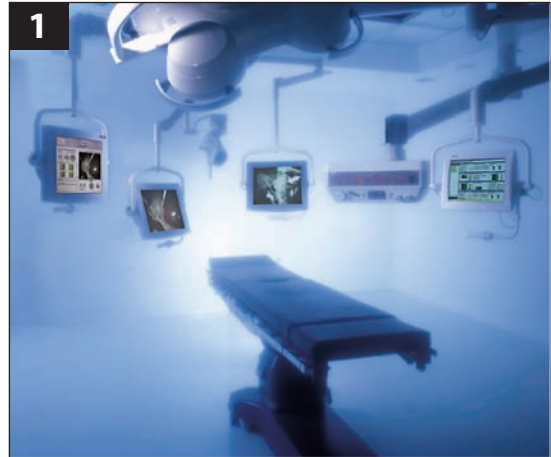

as intermittently, and at the end of the case. The technician should be trained and skilled in the use of all electronic equipment, the video camera, laser equipment, and other electronic supplies and be able to possess on-site trouble shooting skills. Since operative endoscopy is completely dependent on high tech equipment, all should be thoroughly checked prior to the start of each case.

**ALWAYS CHECK THE INSTRUMENTS AND THE EQUIPMENT BEFORE EACH PROCEDURE.**

The circulating nurse is the main coordinator of the team and he/she will be responsible during the procedure for running the video, checking suction and irrigation equipment, and generally providing support and maintaining the steady rhythm of the operating team.

The operating room set-up requires an operating table that can be placed in deep Trendelenburg position. It must have rails that will accommodate the stirrups, shoulder braces, and other possible equipment. Most gynecologic surgeons perform laparoscopy from the left side; however, this is an individual idiosyncrasy that started when laparoscopy was performed without a camera and therefore required holding the scope with one hand while leaving the right to manipulate instruments. Generally, if the surgeon is right handed then he/she should stand on the patient's left side in order to



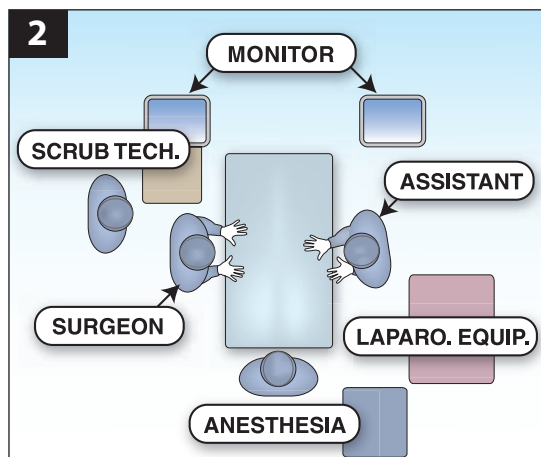
introduce the Veress needle and trocars with the dominant hand. In the ideal OR, to decrease the floor clutter and to allow more room for lasers, fluid monitors, and other large equipment, monitors, and most electronic equipment may be suspended from the ceiling along with all gas lines and electric outlets. Many of the commands in the modern futuristic operating rooms can be voice operated and controlled by the surgeon's voice with the help of the HERMES™ system (Stryker Endoscopy, Santa Clara, CA) or OR1™ (Karl Storz Endoscopy, Tuttlingen Germany) (Figure 1). This technology uses the latest in electronic control systems to seamlessly integrate devices and environmental components of the operating room, including overhead mounting systems, lighting, operating room tables, endoscopic equipment, cameras, image capture systems and information networks. It brings all of these technologies under the direct control of the surgical team.

The operating room set-up is seen in Figure 2. Ideally, two monitors would be available with one to each side of the legs; however, if only one monitor is available it should be between the legs.

The back table should hold all of the hand-held instruments that may be needed during the case. They should be grouped in an orderly manner just as the back table is arranged during open surgery. A Mayo stand can either be placed between the legs or adjacent to a leg with the equipment that will be frequently exchanged during the procedure, i.e. suction irrigator, scissors and several different types of graspers. After the patient is positioned on the table, anesthetized, prepped, and draped she is then catheterized. The multiple instruments that may be utilized for safe and efficient endoscopic surgery are now described.

## VIDEO IMAGING AND CAPTURING

Modern video cameras are based on the solid-state microprocessor chip. There are one or three-chip cameras with a head that attaches to the eyepiece of the laparoscope and connects to the camera controller by a cable (Figure 3). The signal is then fed into the monitor to display the image. Another type of camera is a combination of scope and camera built together with the camera chip integrated at the distal end of the scope so that there are no optical lenses. With this type of system there is direct digital image transmission from the distal tip. The

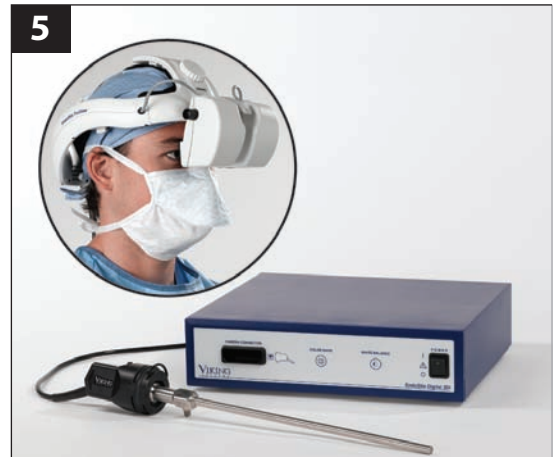
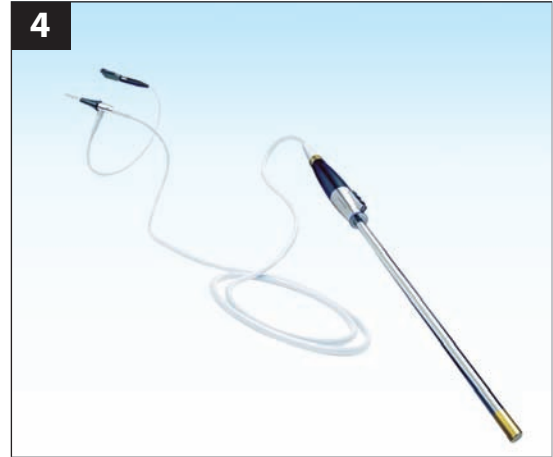
EndoEye™ video laparoscope, (Olympus Surgical America, Orangeburg, NY) is shown in Figure 4.

The quality of the video display has advanced along with technology. It is important to realize that the image as seen on the monitor is related to the resolution of the camera and the monitor. If one has a resolution capability of 750 lines and the other 500 lines, you will only be able to visualize at the lower level. High definition endoscopic cam-

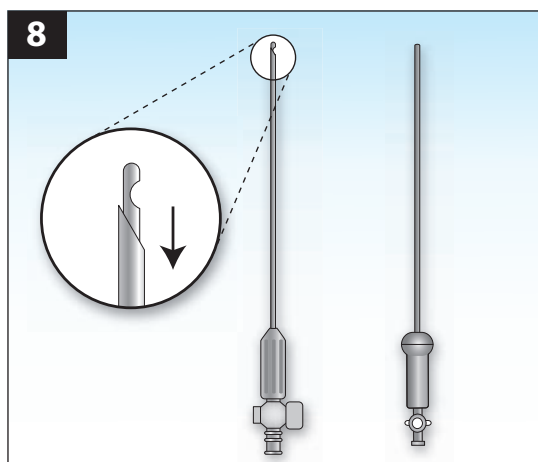
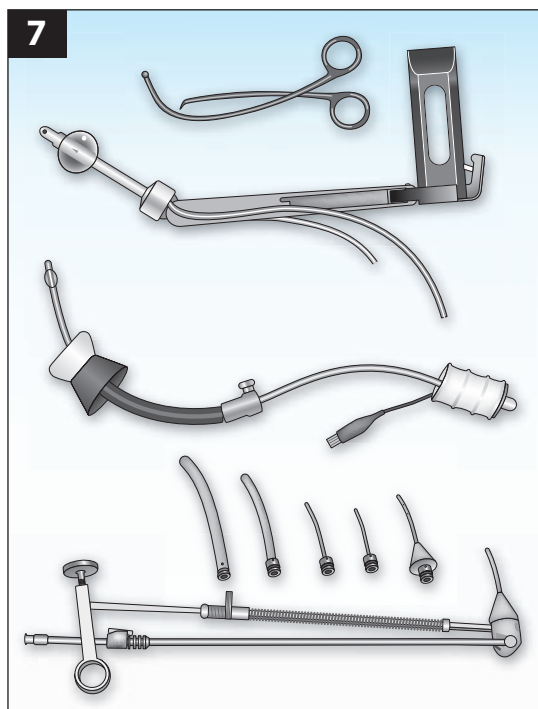
eras are also available. The HDTV camera and monitor have more than twice the number of scanning lines than the frame of the conventional videos, making the images more clear. These high-definition systems may prove quite useful in diagnosing endometriosis and early metastatic spread. No perusal of instrumentation would be complete without a look at what is development for the future. There are some limitations to using the two-dimensional view of the surgical field. Depth perception allows surgeons to acquire laparoscopic skills quickly. Although there have been some attempts at using 3-D imaging it has not been well accepted. This is due primarily to the fact that current technology has been limited by the projection systems used to bring the image of the surgical field to the surgeon. New instruments such as the EndoSite Digital Camera™ utilize a personal monitor attached to a headband in front of the user's eye so the end result is similar to that used by surgeons who wear magnifying binoculars during surgery. The special scopes that are needed come in 0° and 30° 10 mm size (Figure 5).

Video capturing has also become an important part of supplying documentation for record keeping. A high definition capture system such as the Stryker SDC HD™ (Figure 6) is designed to capture and route the high definition images without the loss of quality. This equipment allows the surgeon to document their cases on several types of media such as CD or DVD as well as routing pictures directly to a printer.



## UTERINE MOBILIZATION

Most laparoscopic surgery is expedited by the use of a good uterine manipulator. This device should be capable of anteverting and positioning the uterus as needed depending upon the procedure. If a standard uterine manipulator is not available, one may insert a uterine sound high into the fundus and attach it with tape or rubber bands to a tenaculum previously placed on the anterior lip of the cervix. There are many types of commercial manipulators that are reusable such as the Semm vacuum cannula, Hulka Uterine Elevator™ (Richard Wolf Medical Instruments, Vernon Hills, VT), Pelosi (Apple Medical Corp. Bolton, MA) and the Valtchev Uterine Mobilizer™ (Konkin Surgical Instruments, Toronto, Canada). Partially disposable manipulators, such as the Rumi™ (Cooper Surgical, Shelton CT), have disposable tips that are available in different lengths from 6 cm to 10 cm (Figure 7). Completely disposable manipulators, such as the Vcare™ (ConMed Corp Utica, NY) can also be adjusted for the length of the tip. Ideally, the manipulator should also have the ability to chromopertubate. The tip of the manipulator is usually held in place by a small balloon that may be inflated with a few milliliters of sterile water.



## INSUFFLATION INSTRUMENTS

The various techniques of insufflation are addressed in Chapter 5. Most techniques utilize Veress needle. These spring-loaded needles are available as reusable

instruments, partially disposable, or completely disposable. It is a delicate instrument that has a sharp outer sleeve and contains an inner sleeve with a dull tip on a spring mechanism that retracts back when a resistance is encountered.

Without resistance, the dull tip springs forward to protect intraabdominal structures from the sharp tip (Figure 8). If the reusable needle is sharpened frequently it is as functional as, and certainly less expensive than, the disposable type. The disposable Veress needle has an advantage in always being sharp which enhances its use. The spring mechanism should be checked prior to insertion, even with the disposable instruments.

## INSUFFLATORS

There are multiple insufflators on the market (Figure 9). The ideal insufflator can deliver rapid, accurate flow rates of CO<sub>2</sub> gas up to 15 L/min. However, it is obvious that the gas flow supplied at the outlet of the machine is not what is delivered intraabdominally owing to the diameter and the distance of the connecting tube. In actual measurements, the true amount delivered at the end of the tube may be only 60%-70% of the capable flow rate of the insufflator. Some insufflators such as



Thermoflator® (Karl Storz Endoscopy, Tuttlingen, Germany and Turbo Flow 8000™ Insufflator, Gyrus ACMI, Maple Grove, MN) have heating capability to warm the gas, thus decreasing the intraabdominal hypothermic effect of cold CO<sub>2</sub> gas and decreasing fogging of the distal lens of the laparoscope. The Insuflow® device (Lexion Medical, St. Paul, MN) is relatively inexpensive equipment that can be attached to the insufflator that will both hydrate and warm the gas.

## ABDOMINAL ACCESS INSTRUMENTS

An entire chapter could be used to address this highly debated issue. There are several categories in which all of the instruments may be grouped.

THE BASIC INFORMATION THAT SHOULD BE SUPPLIED BY THE READ-OUT OF THE INSUFFLATOR IS:

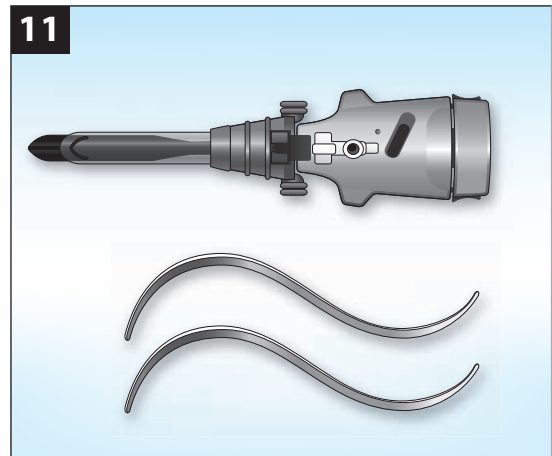
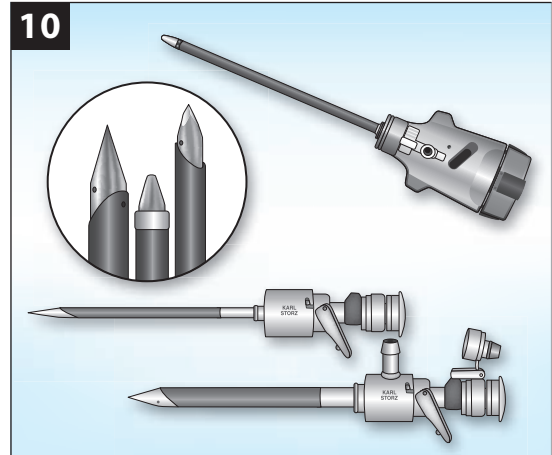
1. INSUFFLATION PRESSURE
2. INTRAABDOMINAL PRESSURE
3. INSUFFLATION VOLUME PER MINUTE
4. TOTAL AMOUNT OF GAS USED (THE LEAST IMPORTANT)

1. Disposable or reusable
2. Open or closed technique
3. Mini-entry techniques or direct view

1. The argument of disposable versus reusable equipment may be focused on trocars and sheaths (Figure 10). The traditional disposable trocars have become popular mainly because the tips are always sharp, thus requiring a much smaller force to achieve penetration than the reusable instruments. The shield that springs out over the tip after entry into the abdominal cavity plays little, if any, role in safety. There has been a continuing area of contention regarding the style of the trocar tip in reusable instruments. Some surgeons favor the pyramidal tip while others extol the virtues of the conical tip. Most trocars today use the pyramidal style tip. There are advantages to each, but sharpness is of most importance in the closed technique. Reusable trocars and sheaths have a distinct economic advantage; however, the necessity of frequent sharpening and cleaning may offset the savings.

Trocars are available in many sizes, from 3 mm up to 12 mm and greater. Most standard laparoscopy is performed using a 10 or 12 mm umbilical port for the laparoscope and 5 mm lower abdominal ports for the secondary instruments. There are even smaller trocars that may be used for 3 mm instruments.

2. Most closed technique instruments have sharp tips, which may potentially injure bowel or large blood vessels. One alternative is to use a Hasson cannula




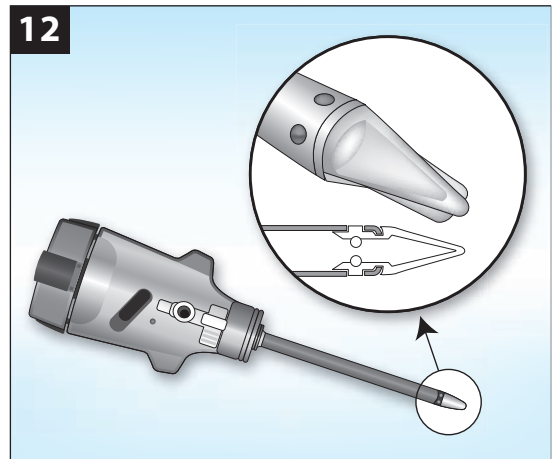
while performing the open technique invented by Dr. Harrith Hasson (See Chapter 5). This instrument requires opening into the peritoneal cavity prior to the insertion of the sheath and does not develop a pneumoperitoneum prior to its use (Figure 11). The use of vision directed trocars such as the Endopath™ bladeless trocar, a disposable instrument produced by Ethicon Endosurgery, (Cincinnati, OH) (Figure 12) is a hybrid that combines a bit of each technique. Another innovation using visual access is

the ENDOTIP™ device which is a reusable threaded port that dilates the tissue as it is threaded in (Karl Storz Endoscopy, Culver City, CA) (Figure 13). With each of these methods, a 10 mm 0° laparoscope is inserted into the trocar and as the trocar is advanced through the abdominal wall layers, the passage into the abdomen is constantly monitored and, thus, damage to bowel or blood vessels may be avoided.

Expandable sheath technology, Step™ (InnerDyne Medical, Sunnyvale, CA) permits the passage of a Veress needle type instrument that has a sheath, which can then be expanded allowing passage of larger sheaths without potential damage, particularly to major vessels. Another dilating trocar uses an asymmetric tip that divides the tissues by dilating through the layers rather than cutting them. One model has a balloon that can be inflated with 10 mL of saline to secure it in place. (ADAPt, Taut, Inc., Geneva, IL) (Figure 14).

## LIGHT SOURCE

An adequate light source is absolutely essential for performing laparoscopic surgery, as it is important to have good illumination in order to obtain image clarity and true colors. A 250 W halogen or xenon light source provides excellent light intensity. The temperature of 6000°K obtained from xenon provides true white light that enhances visualization to permit recognition of pathological changes (Figure 15). A fluid light cable that connects the light source with the



laparoscope may provide optimal light transmission. The fiberoptic light cord should be handled with care, since the fibers within the housing may be broken if the cord is kinked or dropped. If there is a decreased light transmission, one end of the light cord can be held up to a room light and by looking at the other end it is possible to assess whether a significant number of fibers are broken. Due to the concentrated light intensity at the end of the light cable, a significant amount of heat is produced. Therefore,

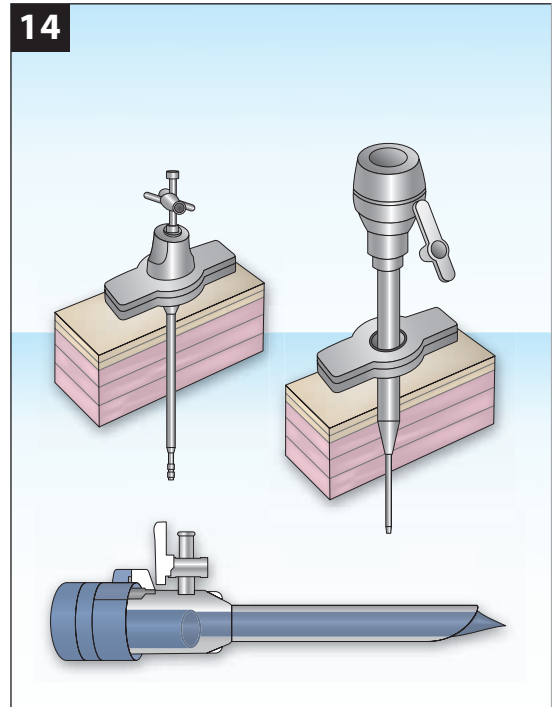
the end of the light cable should not be placed on drapes nor allowed contact with the skin of the patient in order to prevent possible burns.

## OPTICS (LAPAROSCOPES)

It is important to obtain as panoramic a view as possible, allowing the operator to coordinate proper placement of the instruments. Often the surgeons do not realize the magnification afforded by laparoscopy. Indeed, the magnification is one of the many advantages of this technique. The lenses in the scope enable magnification up to 6 times depending upon the distance between the end of the scope and the object. At 3 cm from the tip to the object, the magnification is 4x and at 4 cm it is 6x.

There are several categories of laparoscopes depending on: function, size and angle of view.

**Function:** Scopes may be either diagnostic only or they may be operative. Although most laparoscopic procedures may begin with a 10 mm 0° diagnostic scope, many surgeons prefer operating laparoscopes to be used during the entire case. Most operative scopes have a channel that will allow at least the passage of a 5 mm diameter, 44 cm long instrument. Some scopes have a channel that will allow the passage of 8 mm diameter instruments that can be used in sterilization procedures. These are large diameter scopes that require a 12 mm trocar sheath. The larger diameter scopes may also be utilized for either connecting to a



CO<sub>2</sub> laser or permitting the passage of a fiber for a YAG laser.

**Size:** The optimal diagnostic scope is a 10 mm diameter instrument. However, as fiber optics have improved through the years, the ability to decrease the size of

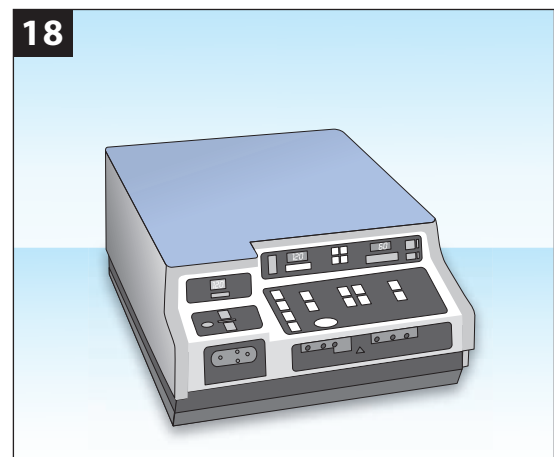
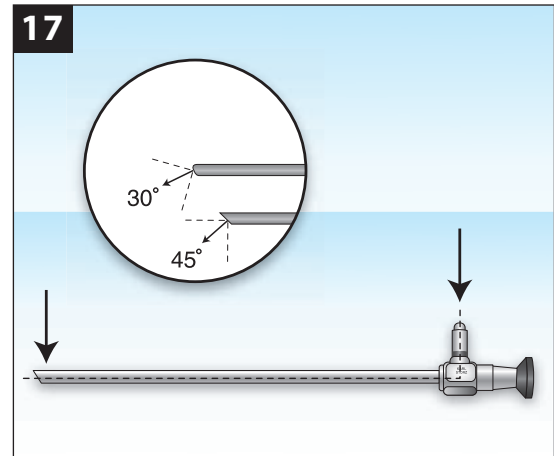
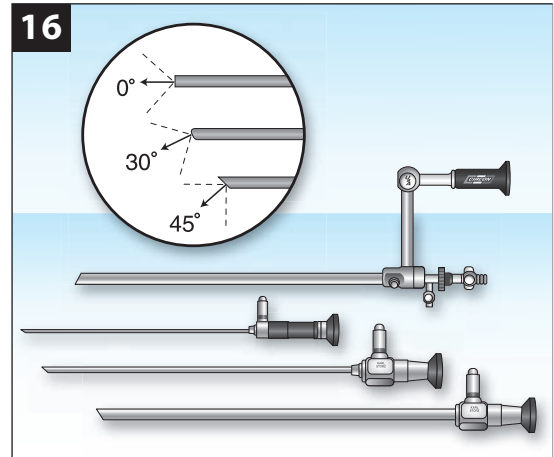


scopes while enhancing the objective view has increased. Frequently a 5 mm scope is utilized for diagnostics as well as directing the use of 5 mm instruments (Figure 16).

**Angle of view:** When using a 10 mm scope as the viewing instrument during operative procedures, it is optimal to have  $0^\circ$  vision (i.e. looking straight ahead). If a scope is used just for diagnostics, it may be advantageous to have an increased angle of vision to observe a more panoramic view of the pelvis. Operative laparoscopes may have a  $6^\circ$  viewing angle. Other scopes may have viewing angles up to  $50^\circ$ . It is important to mention that on every scope there is the engraved number by the eyepiece that specifies the angle of view. If the scope has an angled view, the direction of vision is always pointing away from the light source attachment (Figure 17).

## ELECTROSURGICAL GENERATORS

Electrosurgical generators are designed to produce a high frequency electric energy in either a monopolar or bipolar format (See Chapter 6). Generators have the ability to deliver the energy in either a coagulation (modulated/interrupted) or cutting (non modulated/continuous) waveform. Many generators have some style of ammeter to permit either visually, or by sound, the monitoring of the current flow. This is important because it informs the surgeon when complete desiccation of the tissue, either when coagulating a blood vessel or when sealing a



Fallopian tube during sterilization, has occurred (See Chapters 6 and 8). Some instruments have built-in circuitry to detect insulation failure or capacitive coupling. The generator may be connected to various instruments including scissors, graspers, needles and bipolar forceps (Figure 18).

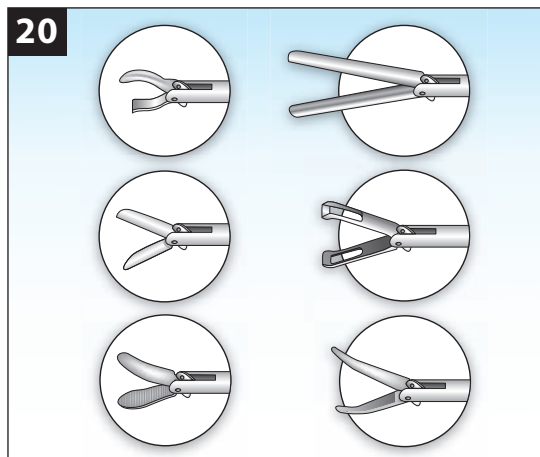
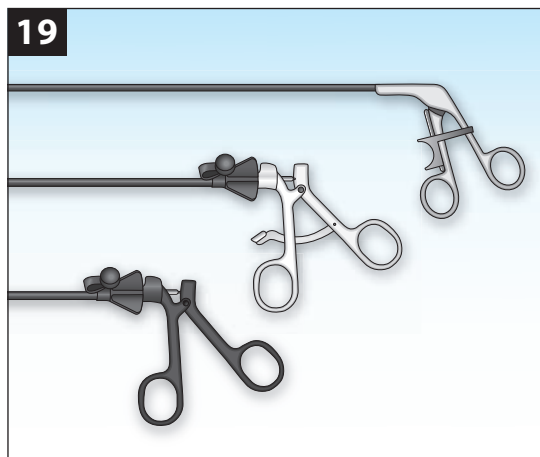
## OPERATIVE INSTRUMENTS

The instruments used during operative laparoscopy may be divided into the following groups.

1. Graspers – traumatic or atraumatic;
2. Cutting instruments;
3. Coagulating instruments (bleeding control) (Staplers, bipolar graspers, harmonic energy instruments, vessel sealing instruments, ligation and suturing equipment);
4. Morcellating and retrieval instruments;
5. Irrigation suction instruments;
6. Lasers;
7. Specialty instruments (sterilization and mini-instruments).

A complete book would be needed to describe all of the various instruments produced by a myriad number of companies. Therefore, only examples of instruments will be described.

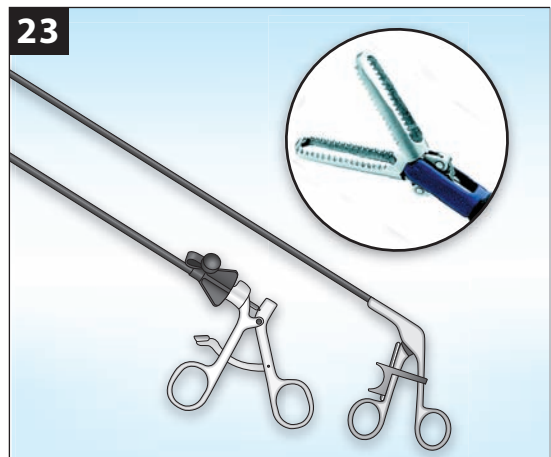
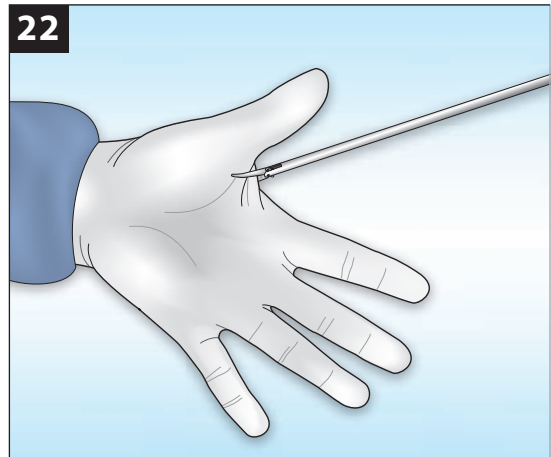
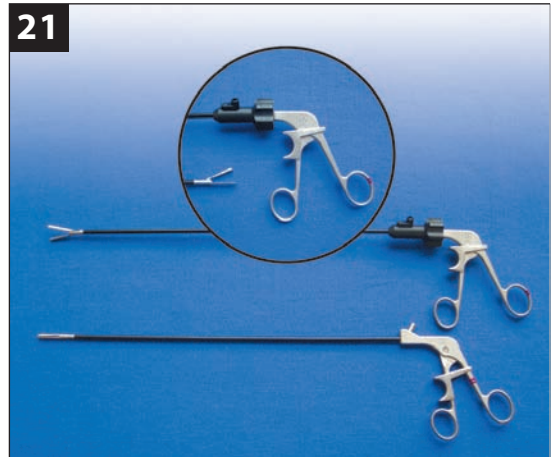
1. All graspers, whether atraumatic or traumatic may be found in a variety of diameters and lengths. They usually range from 3 mm to 11 mm, however, the most commonly used graspers are 5 mm in diameter and 33 cm long. Longer instruments (44 cm) are designed to pass down the channel of operating scopes. Handles are generally of two basic types – those that



will lock (box lock type) and handles that are not locked (Figure 19). The non-locking handles are best used on dissecting type instruments. The tips vary in design depending upon their use. Some have very rounded tips that are extremely dull and the inside of the jaws are also blunt with rounded ridges. This style of instrument is best used for mobilization of bowel and the Fallopian tubes (Figure 20) and may be referred to as atraumatic. The authors prefer the atraumatic grasper with locking handle and long jaws by Aesculap

(Tuttlingen, Germany) (Figure 21) or Snap-In Snap-Out® II or Optima III Laparoscopic hand instruments, (Gyrus ACMI, Maple Grove, MN). The best way to determine whether an instrument is atraumatic is to grasp the web space between the thumb and forefinger. If absolutely pain free it may be considered atraumatic (Figure 22). The more pronounced and sharp the ridges in the jaw, the more traumatic the instrument. This type of instrument should only be used on tissue that will be removed or on tissue not expected to bleed (Figure 23). It does afford a stronger hold on tissue than the atraumatic type.

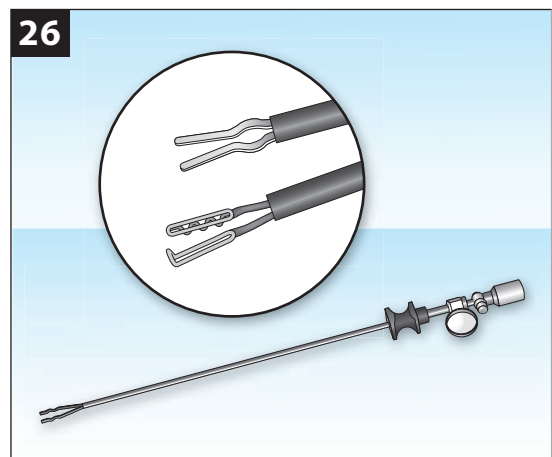

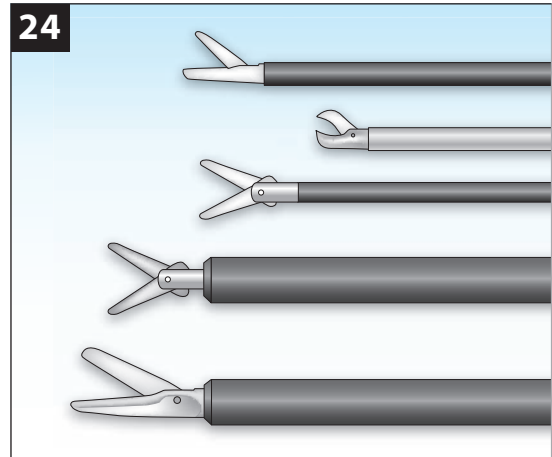
2. Cutting instruments are usually scissors; however, lasers, harmonic energy, and electrical energy may also be used to incise tissue. Scissors may be found in a multitude of forms: straight or curved or hooked and may be reusable or disposable. Some are designed with semi-disposable tips that may be replaced after a number of uses or if they become dull (Figure 24). No matter which scissor is used, the most important aspect is having a sharp instrument. Monopolar electrical energy may be used with the scissor for simultaneous coagulation and tissue cutting. Harmonic energy may be used either in the form of a cutting instrument alone, or in the form of a combination grasper/cutting instrument that not only cuts the tissue, but also coagulates. The harmonic ACE™ (Ethicon Endosurgery, Inc. Cincinnati, OH) is an ultrasonically activated laparoscopic device that provides mechanical energy to cut and coagulate tissue (Figure 25).



The control of bleeding is the most crucial element in all surgery. For hemostasis, the most commonly used instrument in laparoscopy is the bipolar forceps. Dr. Richard Kleppinger invented this type of forceps and most surgeons refer to this type of instrument as Kleppingers, even though they may not be in the classic form. The use of bipolar, high frequency electrical energy is a safe, inexpensive and reliable type of laparoscopic control of bleeding (Figure 26).

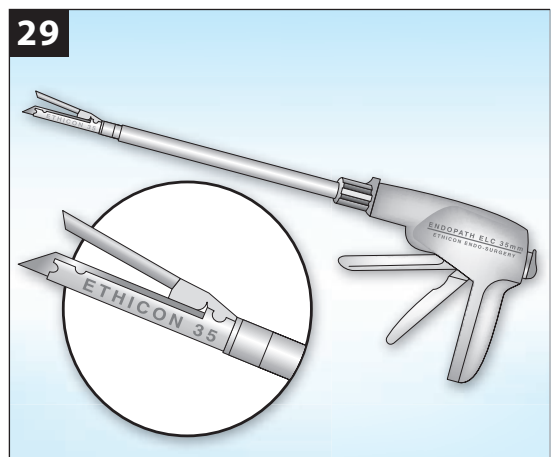
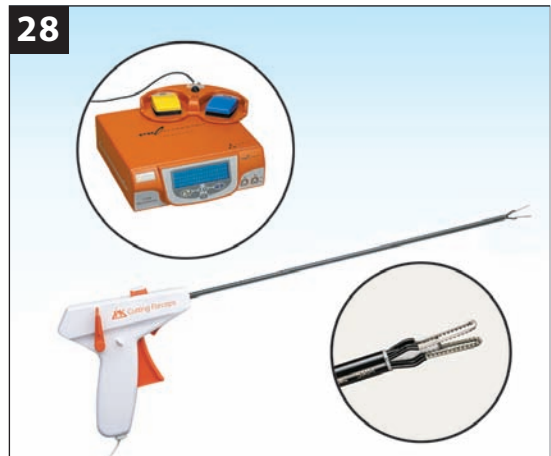
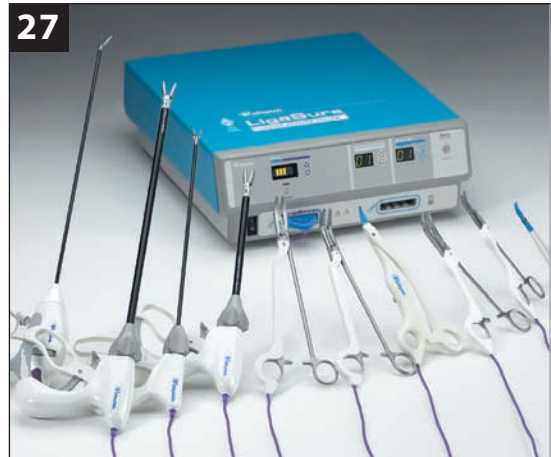Technical improvements in the delivery of radio frequency (RF) energy have resulted in the development of new instruments that not only control bleeding, but also have the ability to cut. These instruments use low voltage and high amperage. The Ligasure™ (Valleylab, Boulder, CO) is an electrothermal bipolar vessel sealer that applies high current and low voltage, and pressure from the jaws of the instrument to seal vessels up to 7 mm in diameter. This differs from the energy in standard monopolar and bipolar cautery instruments that use high voltage and low current (Figure 27). Gyrus ACMI's PK™ Technology offers ultra low voltage combined with very high impact sustainable power to permit predictable next generation RF energy to cut, vaporize, coagulate, and seal over a wide range of tissue conditions while minimizing thermal spread and virtually eliminating sticking. This technology can be delivered with the Cutting Forceps, Plasma Trisector™, and nine other laparoscopic and open devices that complete the PK™ Technology Family of Products (Figure 28).

The use of linear stapler/cutter instruments became popular in the early 90s.



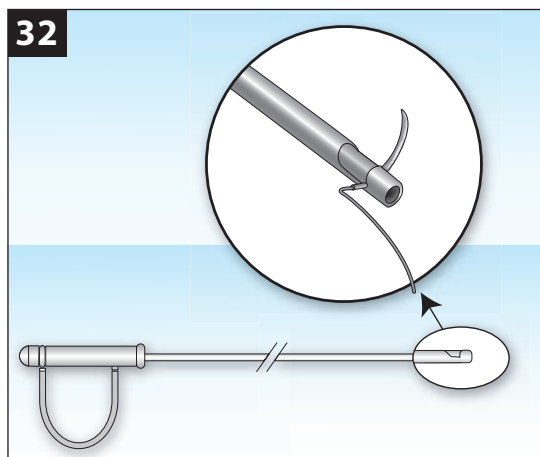
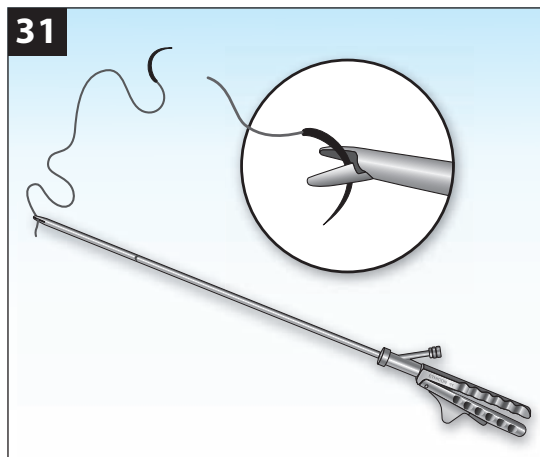
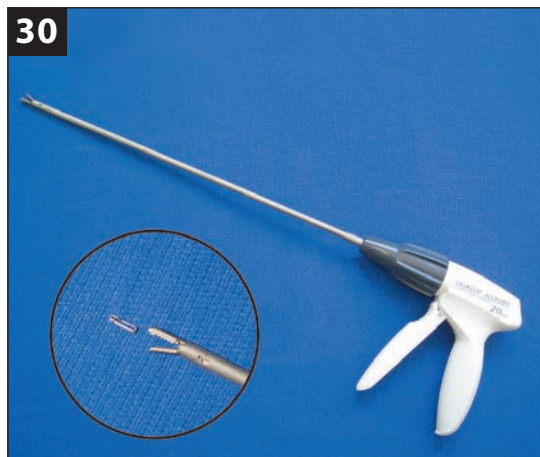
They may now be found in a variety of styles and are extremely useful for rapid cutting of tissue while simultaneously firing a double row of titanium staples for the control of bleeding. The stapler fits through a 12 mm trocar sleeve. The staplers are disposable and use disposable cartridges that have either 48 or 54 titanium staples depending upon which company manufactured the stapler. The staple line is approximately 37 mm with a cut line of 33 mm. (Ethicon Endosurgery) (Figure 29) Another stapler is the Endo GIA Universal Multifire (Tyco Healthcare Inc., Mansfield, MA) which is also a single use stapler that rotates 360° and can be reloaded and fired multiple times. For bleeding control, another useful instrument is the Endoscopic Rotating Multiple Clip Applier Ligaclip™ Allport (Ethicon, Endosurgery Inc. Cincinnati, OH) that is loaded with 20 medium/large titanium ligating clips (Figure 30).

The traditional surgical use of suturing and ligation requires some special materials and equipment. Simple ligation is possible through the use of loop ligation as introduced by Dr. Kurt Semm. This requires an Endoloop™ (Ethicon Endosurgery Inc. Cincinnati, OH) that is a preformed, looped slipknot available in a variety of suture materials and suture sizes (Chapter 7). Endoscopic suturing can be accomplished using a variety of needles and suture materials. The techniques will not be addressed in this chapter, however, some of the instruments that may be required are needle drivers and knot pushers. There are many different types and sizes of needle drivers.



Basically, differences are either in the type of handle or tips. A large number of laparoscopic surgeons prefer the bayonet type of handles (Figure 31); however, the classic Cook needle driver Talon™ (Cook OB/GYN Spencer, IN) remains a favorite of many. The Cook instrument will self-right a curved needle, but has a spring-loaded handle (Figure 32). It is also available in versions that will hold the needle at a 45° angle.

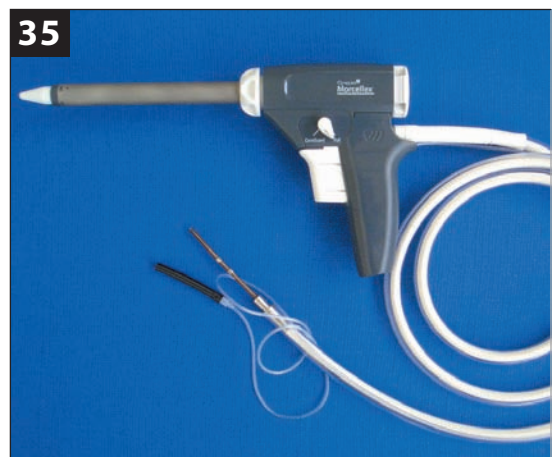
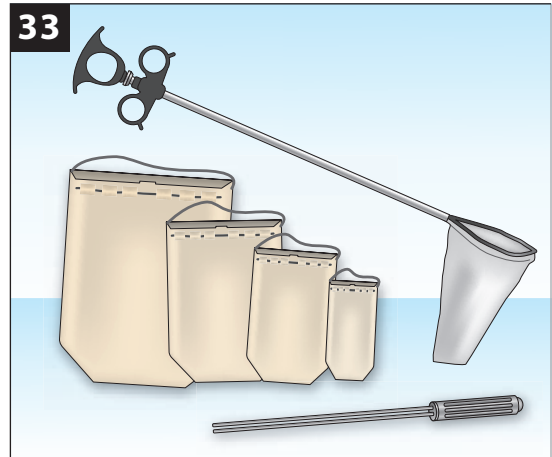
4. The “Holy Grail” of laparoscopy is the most effective method for removing tissue from the body. Presently the two methods of tissue removal are either through morcellation or by use of a sack or some combination of both. The ideal method has to be safe, efficient, and prevent spillage within the abdomen. A retrieval system plays a vital role in laparoscopic surgery. To supply this system it may be necessary to use some type of extraction sack. The specimen bag must be used in the removal of ovarian tissue that has a possibility of neoplasia in order to obviate the dissemination of possible malignant cells and prevent spillage during removal of a benign teratoma. It is necessary that a removal bag be very strong so that it may resist breakage in the face of a large force in pulling it through a small opening. The sack also should be easily deployed within the abdomen and be capable of holding a mass larger than 7 cm such as a Cook sac. Newer bags are equipped with a self-opening and closing mechanism that facilitates easy removal of tissue (Figure 33). The Cook LapSac™ (Cook Urological, Spencer, IN) is a very strong



bag made of nylon with a polyurethane coating; however, it is more difficult to place specimens inside of it.

There are several motorized morcellators that answer many of the problems of morcellation. Rotocut™ Morcellator (Karl Storz Endoscopy Tuttlingen, Germany) (Figure 34) does not require the trocar sheath and comes in 12 mm and 15 mm diameter. The Gynecare Morcellator Morcellex™ (Gynecare, Johnson & Johnson Corp. Somerville, NJ) (Figure 35) also comes in 15 mm diameter, uses disposable handle and blades, and also does not require a trocar sheath.

5. Irrigation and aspiration are necessary for operative laparoscopy because without a clear surgical field the surgeon is blind. Irrigation is used to clear away debris, blood, blood clots, and char that may be produced by electrosurgery or laser treatment. The ideal irrigator must produce enough hydraulic pressure to disrupt clots and assist in aqua dissection. The hand-controlled valve should easily operate both the suction and irrigation. It is important that it be usable with a large enough channel so that large clots may be removed rapidly without clogging the instrument. If the probe tip is to be used for suctioning near bowel, small holes near the tip are useful to avoid pulling bowel into the probe. There are several different types of instruments with varied pumps to deliver the fluid for irrigation such as Endomat™ (Karl Storz Endoscopy, Tuttlingen, Germany and Wave XP™, Gyrus ACMI, Maple Grove, MN) (Figure 36). The disposable suction/irrigator made by Stryker Endoscopy is gaining in popu-



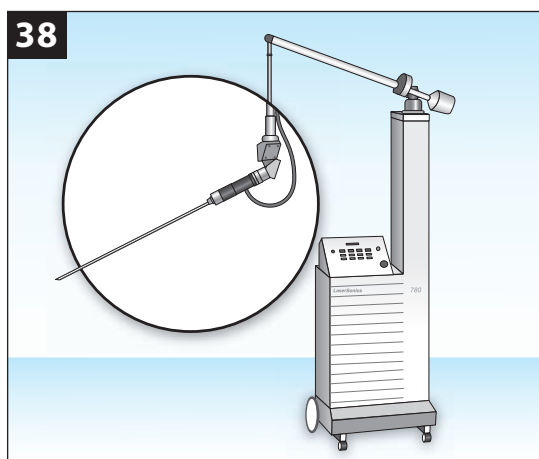
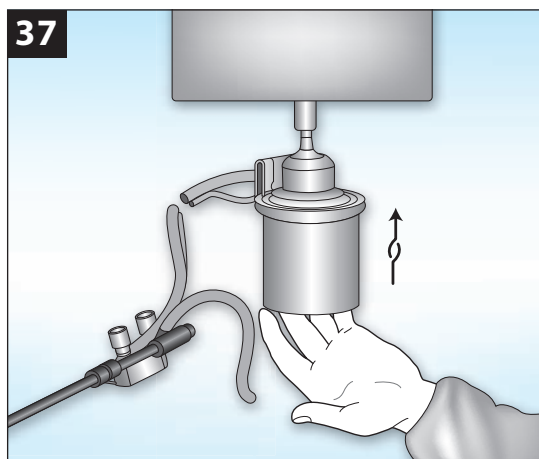
larity. It uses a battery operated disposable pump that is attached to the irrigation fluid bag, and provides excellent fluid pressure (Figure 37).

6. The major types of lasers that are currently used for gynecologic surgery are the CO<sub>2</sub>, argon, KTP-532 and the Nd-YAG (neodymium-yttrium, aluminum, garnet). Each of these has various indications that are not within the purview of this chapter. The basic instruments that supply these different energy sources are fairly large, expensive, and require specific training in their use (Figure 38).

7. As the interest in laparoscopy performed under local anesthesia for pain mapping has expanded, the demand for small instruments has subsequently increased. Pediatric laparoscopy has also necessitated a need for smaller instruments. Small trocar sheaths for 3 mm instruments may be used, but there are even smaller instruments such as the mini-retractor set and grasping instruments (Figure 39).

Instruments that are unique to sterilization may be used either through secondary trocars or through the 8 mm channel of an operating laparoscope. The three most commonly used instruments are the Hulka Clip Applicator™ (Richard Wolf Medical Instruments, Vernon Hills, IL), the Filshie Clip Applicator™ (Avalon Medical Corp., Williston, VT) or the Falope-Ring® Band Applicator (Gyrus ACMI, Maple Grove, MN). Their use will be described in Chapter 8.

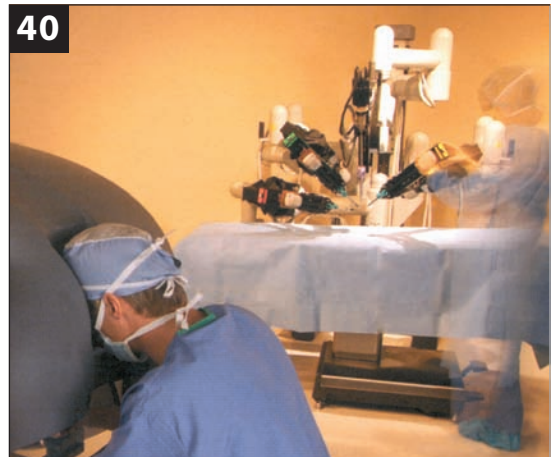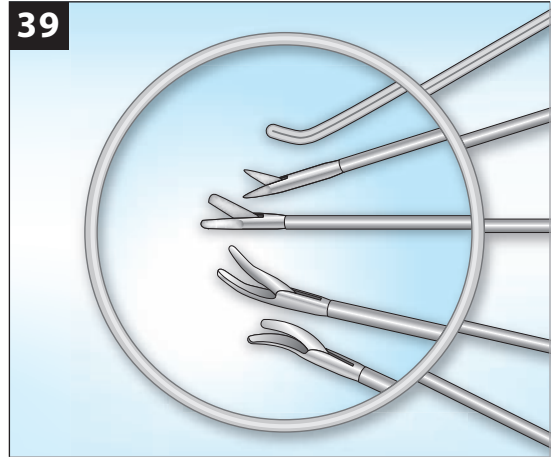
It is impossible to describe every instrument available for use in laparoscopy. Literally new instruments are being





invented every day, but it is important for the surgeon to be aware of the basic instruments that are currently available and be familiar not only with their function, but how to assemble and troubleshoot their use.

8. Although not part of a basic equipment list, robotics are the look of the future. Presently the use of robotics is limited in general gynecology, although there is increasing interest especially in gynecologic oncology. (See Chapter 33) The most used device is the DaVinci™ Surgical System (Intuitive Surgery, Mountain View, CA). This equipment consists of three parts: a surgeon's console, a video electronics tower, and the robotics tower that supports three robotic arms. The surgeon sits at the computer console viewing a virtual operative field through a 3-dimensional imaging system. His/her hands are inserted into a "master" that translates the motions of his hands into motions of the robotic arms, which hold two surgical instruments and a video telescope. The hand-like surgical instruments move with 7° of freedom and 2° of axial rotation. The surgeon's feet activate several pedals that control various aspects of the robot's movements. (Figure 40).



---

SUGGESTED READING:

Operative Laparoscopy: The Masters' Techniques in Gynecologic Surgery.  
Richard Soderstrom, ed. 2nd Edition.  
Publisher: Lippincott-Raven, 1998

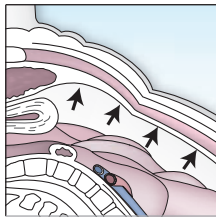
Textbook of Laparoscopy. Hulka JF, Reich H, eds. 2nd Edition.  
Philadelphia: W.B. Saunders, 1994

Mencaglia L, Wattiez A. Manual of Gynecological Laparoscopic Surgery.  
Endo-Press Tuttlingen, Germany, 2000

---



# ANESTHESIA IN LAPAROSCOPY



*Laura Clark, M.D.*

**M**any surgical procedures dictate the management of anesthesia. The procedure of laparoscopy creates its own subset of factors unique to the procedure itself. The impact of laparoscopy on the human body went relatively unnoticed in its infancy because the majority of cases initially were laparoscopic tubal sterilizations performed in a relatively short time on young, healthy individuals.

Barring complications, these individuals could adjust quite well to the changes that occur during laparoscopy. Only when the technique expanded, both in use and type of operations, was the full impact apparent. Presently, laparoscopic operations are frequently longer and the population may have other disease processes, and may even be elderly. This subset of patients has not been able to compensate as well as young, healthy patients and the true impact of these physiologic changes is being delineated. This expansion has been a useful and productive development but as shown later in this chapter, the choice of laparoscopy versus an open procedure is made by the physiologic impact of the laparoscopy on the individual patient during the operative procedure and not only on the physical factor of surgery without a major incision.

### LAPAROSCOPY CAN BE BENEFICIAL:

- LESS PAIN
- EARLY MOBILIZATION
- SHORT TO NO HOSPITALIZATION

### VERY SICK PATIENTS MAY NOT BE CANDIDATES

- CANNOT COMPENSATE FOR CHANGES THAT OCCUR DURING LAPAROSCOPY.

Anesthesia must accomplish amnesia, analgesia, and maintenance physiologic processes to maintain homeostasis during the surgery. Laparoscopic procedures may produce physiologic changes secondary to the procedures required to accomplish visualization of the anatomy in order to complete the surgery without opening the abdomen.

The creation and maintenance of a pneumoperitoneum in the Trendelenburg position are unique requirements of gynecologic laparoscopic surgery and produce responses that have specific impact on the physiology of the patient. How the patient responds depends on the initial health of the individual and what compensatory mechanisms they can maintain. The impact on the patient can be minor to severe. Complications can occur inherent to the milieu that must be created to successfully operate.

The major task of the anesthesiologist and surgeon is to recognize that anesthetic issues related to laparoscopic surgery exist and must be recognized. Awareness of these issues allows good outcomes, even in high-risk patients, comparable to those of low risk patients. The anesthesiologist and surgeon working in concert with good communication will avoid or promptly recognize potential complications that can occur.

## PHYSIOLOGIC CHANGES

The patient responses resulting during laparoscopy can be divided into mechanical and physiologic. Mechanical changes are a result of the physical pressure of superinflating the abdominal cavity and the challenges to the system from being placed in steep Trendelenburg position. Physiologic changes are a result of the absorption of CO<sub>2</sub> and the neurohormonal response to the procedure.

The respiratory and cardiovascular are the primary systems involved. However, hepatic, gastrointestinal, renal, and cerebral changes have been described. These changes can range in severity from unnoticed to severe depending on the

### CHANGES

1. MECHANICAL
2. PHYSIOLOGICAL

CARDIOVASCULAR AND RESPIRATORY SYSTEMS ARE THE MOST INVOLVED.

initial condition of the patient. A detailed preoperative assessment is imperative in the compromised patient when laparoscopic surgery is an option. For this reason, some severely ill patients are not candidates for laparoscopy even though the operation is possible by this method.

## MECHANICAL EFFECTS

### CARDIOVASCULAR

#### Pneumoperitoneum

Just as one might expect, there is a mechanical pressure effect on the large vessels from the pneumoperitoneum. Aortic compression will increase systemic vascular resistance coupled with inferior vena cava and intraabdominal vessel compression causing an initial brief increase in preload. This is short lived, but results in a decrease in preload and, thus, in a decrease in cardiac output. The greater the intraabdominal pressure, the more pronounced these effects become on the patient. The compression of intraabdominal vessels is minimally decreased with insufflation pressures between 7-12 mmHg if the patient is adequately hydrated. There is a direct correlation between intraabdominal pressure and perfusion. Any incremental increase in pressure must be justified as cardiac output and impact to perfusion of internal organs may suffer. Pressure near 20 mmHg should be avoided for any length of time due to a significant decrease in perfusion at this level. However, elevated pressures for a short

### IVC AND AORTIC COMPRESSION

#### INCREASED SVR

#### INCREASED PRELOAD

#### FOLLOWED BY

- DECREASED PRELOAD
- DECREASED CO<sub>2</sub>
- INCREASED OR NO CHANGE HR

period of time during placement of the initial port are usually well tolerated. Effects at any pressure will be pronounced in the patient with hypovolemia. It is important to maintain adequate intravenous fluids during the operation to augment perfusion pressure and venous return during pneumoperitoneum.

If deterioration is seen, it is prudent to communicate with the anesthesiologist and decrease the insufflation. Improvement is often achieved with a small decrease in pressure without affecting operating conditions. The act of inflating the abdomen and the ensuing distension may stimulate the vagus nerve resulting in marked bradycardia requiring vagolytic drugs.

### PATIENT POSITION

Most gynecologic operations are accomplished in the Trendelenburg position. Elevation of the lower body and the head down position will cause an initial increase in venous return by an increase

in the preload as the lower limbs are elevated. This has minimal detrimental impact on the healthy patient.

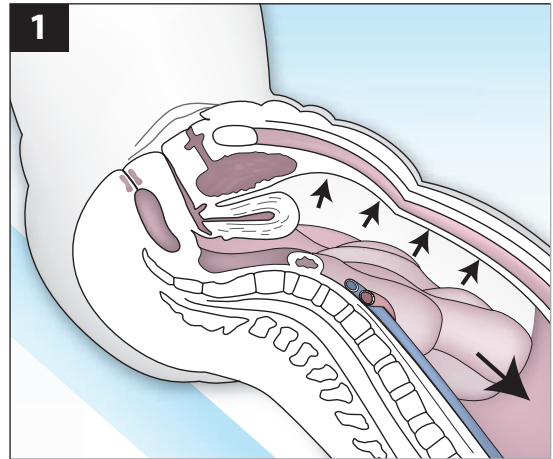
For the compromised patient, this can present as an overload to the heart and precipitate or worsen existing congestive heart failure. Interpretation of pressures from a Swan-Ganz or central venous catheter should be interpreted with caution and may not be reliable in this position.

A SMALL DECREASE IN INTRAABDOMINAL PRESSURE MAY BE ALL THAT IS NEEDED TO IMPROVE HEMODYNAMICS.

TRY TO AVOID UNNECESSARY TRENDLENBURG.

## PULMONARY

The effects of laparoscopy in the supine position are limited to a decrease in compliance and a possible increase in peak airway pressure. These are usually not a problem except in the obese patient. The effects of Trendelenburg on the respiratory system can be severe in all patients, but the possibility of serious compromise is magnified in the obese or those with asthma or other pulmonary disease. These effects may be so critical that the patient cannot be adequately ventilated in this position.



The compression of the viscera in the Trendelenburg position can cause the diaphragm to move cephalad (Figure 1). This may increase the work of ventilation resulting in increased airway pressure, decreased compliance, decreased vital capacity, and decreased functional residual capacity. Even in healthy patients, these can be changed by as much as 50%.

The endotracheal tube may become endobronchial with the Trendelenburg position. The endotracheal tube does not actually move, but the movement of the abdominal contents forward may cause the tube to favor one bronchus or actually enter the bronchus creating a one-lung ventilation scenario. This also causes an

### PULMONARY EFFECTS INCLUDE:

- ↓ COMPLIANCE
- ↑ AIRWAY PRESSURE
- ↓ FRC
- ↓ VC

increase in the peak airway pressure and a picture similar to Trendelenburg itself. One should not assume the position is responsible, but should listen to both lungs once the position is assumed and at any time during the operation that a drop in oxygen saturation occurs. Once two-lung ventilation is assured, and barring other physiologic effects, a decrease in intraabdominal pressure and a decrease in severity of Trendelenburg may result in improvement.

**BE ALERT FOR ENDOBRONCHIAL INHALATION.**

## PHYSIOLOGIC CHANGES

### PULMONARY

Carbon dioxide is absorbed into the bloodstream in a variable manner. Hypercapnea may increase moderately or profoundly and is thought to be due primarily to the absorption of CO<sub>2</sub> rather than decreased mechanical ventilation. The increase may occur early and become fairly steady state in most patients with an increase in minute ventilation of 30%. If compensatory mechanisms are not available to the patient because of other organ system disease, a significant acidosis can develop.

This trend can be observed to some degree from end-tidal CO<sub>2</sub> monitoring, but is not reliable. There can be a signif-

icant difference in the end-tidal and arterial value. Arterial trends may be monitored with frequent arterial samples from an arterial line in very long cases or in medically compromised patients. The ability to eliminate CO<sub>2</sub> varies widely and may persist for several hours. It is not uncommon to see elevated hemidiaphragm in a postoperative X-ray. The absorption is greater if the insufflation has occurred in the subcutaneous or extraperitoneal tissue, thus a larger increase in CO<sub>2</sub> in the arterial system should be expected.

**NEED TO INCREASE MINUTE VENTILATION BY 30% OR MORE.**

ARTERIAL LINE MAY BE NECESSARY TO MONITOR pH IN PATIENTS WHO WOULD NOT NEED ONE IN AN OPEN PROCEDURE.

↓ pH COULD BE SEVERE.

The anesthesiologist will increase the minute ventilation to help compensate for this change, but such increases may not be successful in ill patients. The patient could be placed in a severely acidotic state. Since this is temporary, bicarbonate use would outlast the operation and usually is not considered an option. This possibility must be considered, as the condition of some patients may not tolerate this situation even on a temporary basis. Respiratory status should also be considered. One study suggests that a



forced expiratory volume of less than 70% or a diffusion defect less than 80% would identify patients at risk.

IF FEV IS < 70% OR DIFFUSION CAPACITY IS < 80%, THE PATIENT MAY NOT BE A CANDIDATE FOR LAPAROSCOPY.

## CARDIOVASCULAR

Physiologic effects on the cardiovascular system are primarily related to the establishment of a pneumoperitoneum and the intravascular absorption of carbon dioxide. Cardiovascular effects may or may not be apparent initially on monitoring systems and vary according to the patient's inherent condition. Initial changes depend on pre-existing conditions and on the ability of the patient to compensate.

Absorption of carbon dioxide occurs immediately and can affect the pH and lead to significant changes in the arterial blood gas after a variable amount of time depending on the condition of the patient. After 60-120 minutes, the storage mechanism for carbon dioxide can be impacted. The body can store up to 120 L of CO<sub>2</sub>. Baseline adult CO<sub>2</sub> production is then augmented by absorption of carbon dioxide from the abdomen. This can lead to a pH of 7.1 or lower in longer cases or compromised patients.

Hypercapnea, Pa CO<sub>2</sub> of 45-50 mmHg is "normal" during this operation and may result in sympathetic stimulation.

## CARDIOVASCULAR

↑ SVR  
 ↑ SHUNT  
 ↓ OR ↑ MAP  
 ↑ OR NO CHANGE HR  
 ↓ CO<sub>2</sub>

The initial effect is an increase in blood pressure, heart rate, and cardiac output. One study comparing nitrogen to CO<sub>2</sub> insufflation found a decrease in stroke volume and tachycardia that did not occur with nitrogen. These direct effects on the cardiovascular system are felt to be directly due to acid-base pH changes due to absorption of carbon dioxide.

While under anesthesia, the normal mechanism of increasing minute ventilation is accomplished by the anesthesiologist through the manipulation of ventilator settings. Changing minute ventilation can only accommodate minor absorption of carbon dioxide. The body's compensatory mechanisms of maintaining acid-base are primary. A Pa CO<sub>2</sub> of 60 may be unavoidable and can cause severe acidosis, arrhythmias, and severe myocardial depression. Although time dependent, this can occur at variable times in the compromised patient. Pre-existing conditions must be considered when selecting candidates for laparoscopy. Certainly, this class of patients has a significant propensity to develop cardiac compromise requiring diligent monitoring by the anesthesiologist and a low tolerance by

SWAN-GANZ IS NOT RELIABLE IN  
TRENDELENBURG.

MAY NEED TEE TO MONITOR COM-  
PROMISED PATIENT.

the surgeon to convert to an open procedure. Frequent blood gases should be obtained to monitor the patient's status because end tidal CO<sub>2</sub> often does not correlate with arterial levels.

Acid-base changes resolve over time after release of the carbon dioxide at the end of the operation. Every effort should be made to minimize residual carbon dioxide in the abdomen because hemodynamic effects will persist in the recovery room until normal acid base balance returns.

## OTHER SYSTEMS

Arrhythmias are very common, occur early, and therefore are not thought to be due to the presence of increased CO<sub>2</sub>. Other than arrhythmias secondary to intubation, bradycardia most often occurs during insufflation due to distension of the peritoneum, vagal stimulation, or traction on viscera. They can manifest in patients without a history of cardiac disease. Although all types of arrhythmias have been reported and can occur, life-threatening arrhythmias are rare. While ectopy is common, asystole is very rare and most often associated with severe complications such as gas embolism, and severe hypoventilation, hypertension, and acidosis.

## OTHER SYSTEMS

↓ GFR  
↑ GASTRIC pH  
↓ SPLANCHNIC FLOW

### \* PREOP VISIT:

#### GOAL - TO OPTIMIZE THE MEDICAL CONDITION:

- HISTORY AND PHYSICAL
- LAB TEST
- MODIFY TREATMENT REGIMENS
- IDENTIFY CARDIOVASCULAR DISEASE
- OPTIMIZE CONGESTIVE HEART FAILURE
- PULMONARY FUNCTION TESTS  
IF INDICATED

\* CONSIDER HOLDING ACE-INHIBITORS  
THE DAY OF SURGERY - CONTINUE OTHER  
MEDICATIONS.

Although usually transient, arrhythmias should be treated if the underlying cause is known. Most often an anticholinergic drug such as robinal or atropine, and slowing or stopping insufflation, will restore sinus rhythm.

## PREOPERATIVE ASSESSMENT

The preoperative assessment of the patient is imperative for the successful outcome of any surgical procedure. In laparoscopy this is two-fold. Obviously, any patient will have a better outcome if

## ANESTHETIC CHOICES

1. MONITORED ANESTHESIA
2. REGIONAL
3. GENERAL

their medical condition is optimized. The surgeon and the anesthesiologist should assess the patient's condition as soon as the operation is planned, so that adjustments may be made to improve her condition and optimize her medical status prior to surgery. This is more important in the aging and elderly patient but should not be overlooked in the younger patient as well. Asthma or uncontrolled hypertension may have ramifications that can be magnified by laparoscopy and should, therefore, be well controlled. Many more elderly patients are now being placed on ACE inhibitors to optimize their cardiac status. These drugs should be stopped the day before surgery to minimize hypertension at the time of anesthesia induction. All other cardiac medication, other than diuretics, which can be administered at the discretion of the anesthesiologist during the procedure, should be maintained. All these issues can be addressed with a timely preoperative visit to the anesthesiologist.

The preoperative visit is vital to the success of a tubal sterilization in which the patient and her physicians have elected to accomplish with monitored anesthesia, a sedated and conscious patient without general anesthesia. This

is not a widely accepted method and the surgeon and the anesthesiologist need to communicate with each other concerning the acceptability of each patient for this method. Several conditions must be met for the procedure to be successful.

## MONITORED ANESTHESIA CARE (MAC)

Although not widely accepted as a common clinical practice, short procedures such as tubal sterilizations can be performed with a sedated but arousable patient with proper precautions.

Some anesthesiologists will not perform monitored anesthesia care for this procedure citing concern for the airway, patient comfort, and the ability to ensure adequate respiration in the Trendelenburg position. This also holds true for a regional technique, although spinal, epidural, and monitored anesthesia care has been used in this procedure. Many general surgeons also have reservations in performing this procedure without general anesthesia.

The surgeon must be efficient and adept at handling tissue gently, and adequately anesthetize the tissue with local anesthesia. The anesthesiologist must be able to sedate the patient adequately without losing the patient's protective reflexes. An informed, motivated patient is the best choice for this technique.

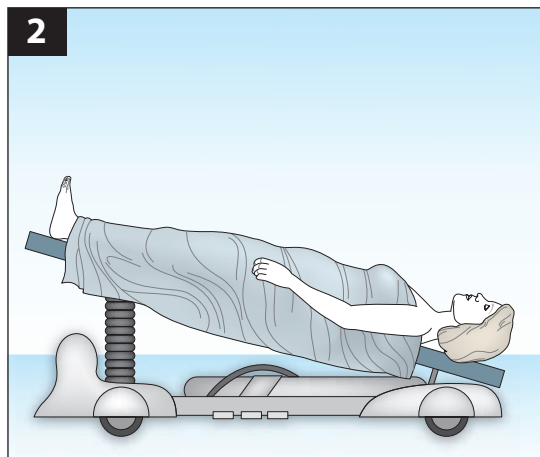
We have performed large numbers of these procedures in this manner with highly successful outcomes and pleased and satisfied patients. To be successful, this method requires more work and

**SURGEON MUST BE REASONABLY EFFICIENT WITH SHORT DURATION OF OPERATIVE TIMES FOR MAC TO BE SUCCESSFUL.**

preplanning on the part of the surgeons and anesthesiologists. The main factor that would exclude the patient as a candidate for this procedure is morbid obesity because of the technical difficulties involved in each aspect of the operation. In the preoperative clinic visit, each patient is shown a video detailing all aspects of the procedure, which uses such phrases, as “when the gas enters your abdomen you will feel as if you are pregnant” and “when your head is lowered it feels like you are standing on your head”.

Trendelenburg positioning may be duplicated on the stretcher prior to surgery to make sure the patient is comfortable with that position (Figure 2). Some surgeons require more Trendelenburg angle than others, which may exclude this method for certain patients for whom the excessive tilt is uncomfortable. The ability to accept this position is usually the most common limiting factor for the patient.

The video of the procedure is extremely important because the patient becomes a participant in the procedure and her understanding of every aspect is vital to the successful outcome. The patient is instructed that she will receive sedation by the anesthesiologist as she

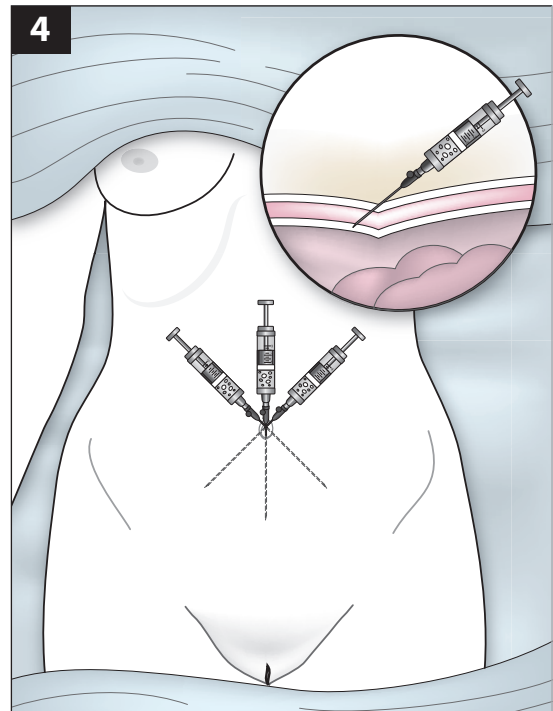
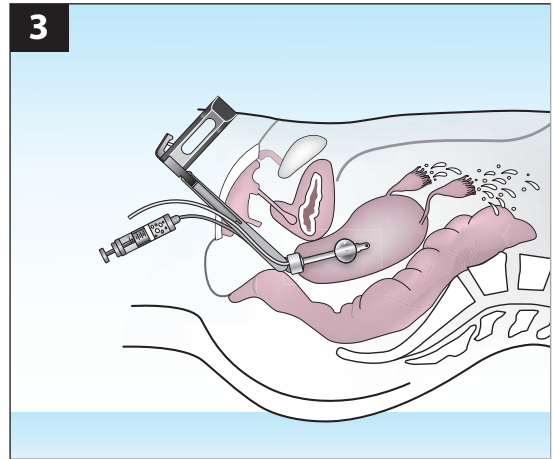


**\* A VIDEO OF PROCEDURE IS VERY IMPORTANT TO INFORM THE PATIENT OF WHAT TO EXPECT.**

wishes, but it should be emphasized that there are aspects she may be aware of but which should not be painful. The pressure of the gas in her abdomen and insertion of the trocar are the main stimulating events. If the sensation is disturbing, a small release in pressure usually makes the patient more comfortable without compromising the visualization of the surgical field. During insertion of the Veress needle or trocar, the surgeon can time the insertion by observing the movement of the abdomen with respiration. No attempt is made to coerce the patient or give her unrealistic expectations, but if she is told of the likelihood of these sensations ahead of time, the patient can make an informed decision during surgery.

An important adjunct to the clinic visit is the clinic nurse. She helps to explain the procedure in her own words and past experiences are shared. Her adeptness at quickly establishing a rapport with the patient is vital as an additional source of information. She will also accompany the physician to the operating room, which greatly enhances continuity of care and an atmosphere of patient trust.

Given a motivated, knowledgeable patient, a safe and successful operation will depend on the skills of the surgeon and anesthesiologist. Enough volume and proper deposition of local anesthetic must be utilized. A paracervical block facilitates the tenaculum placement on the cervix. A uterine manipulator that can be used to perform transuterine hydro-tubation is placed into the cervix (Figure 3). The skin of the abdomen is infiltrated with 1% lidocaine, usually with a small gauge needle initially. A 22-gauge spinal needle may follow as its length is needed in a four-quadrant pattern to anesthetize the skin and subcutaneous tissue (Figure 4). It takes at least 15-20 cc of lidocaine to be adequate. The 22-gauge spinal needle is then inserted into the fascia and approximately 10 cc of local anesthetic is deposited directly into the fascia. This should permit insertion of the Veress needle and trocar. At this stage, 20 cc of 0.5% xylocaine is infused through the uterine manipulator. After ensuring entry into the abdomen, lidocaine is dripped into each tube under direct visualization. This usually takes 10 cc per tube.



The anesthesiologist will provide sedation according to the patient's needs. Occasionally, some patients will watch the procedure on the monitors, although this is uncommon. Preoperative anxiolytics titrated with midazolam is usually

adequate. Speech may begin to slur or a slight disinhibition may be observed. Occasionally, 50 µg of fentanyl is needed to augment the sedation. While the monitors are being attached, a propofol drip is started at 25 µg/kg/min. This allows a blood level to be achieved gradually over time so that a bolus is not necessary prior to the beginning of surgery. It is important to maintain a level of sedation where patients are arousable but sedated. This is usually accomplished with a combination of midazolam, fentanyl and propofol. Usually a propofol drip is the primary sedating agent with fentanyl given only as necessary. One method is a combination of 50 mg (1 cc) of ketamine to 50 cc (500 mg) of propofol for the maintenance infusion. If this method is chosen, very little fentanyl is necessary. The amount of ketamine is so small that dysphoria is not encountered. The ketamine, however, provides some augmentation of

analgesia and sedation with no respiratory depression. In addition to the usual monitors for general anesthesia, end tidal CO<sub>2</sub> monitors as well as a BIS monitor are useful. This information will help monitor sedation levels and respiratory pattern without disturbing a sedated patient. It must be stressed that verbal communication should always be possible to assure the presence of adequate airway reflexes. The BIS levels for this type of anesthesia are somewhat patient variable, but are usually in the 75-85 ranges.

The anesthesiologist must be prepared at any time to intubate the patient and proceed with general anesthesia. This could be for surgical or anesthetic reasons such as complications or discomfort. The continuing communication between the surgeon and the anesthesiologist will allow the optimum conditions to be achieved for all parties.

- EKG, 3-5 LEAD DEPENDING ON THE PATIENT'S CONDITION
- BLOOD PRESSURE
- OXYGEN SATURATION
- END-TIDAL CO<sub>2</sub>
- INSPIRATORY AND END-TIDAL ANESTHETIC AGENT CONCENTRATIONS
- BIS MONITOR
- ESOPHAGEAL STETHOSCOPE
- MUSCLE TWITCH MONITOR

## GENERAL ANESTHESIA

General anesthesia is by far the most common method of anesthesia for laparoscopy. In an adequately prepared patient, laparoscopy has greatly accelerated the recovery process. All of the routine monitors should be employed for this procedure.

In elderly patients, or during a prolonged procedure, an arterial line pressure monitor may sometimes be helpful to determine acid-base status. Other invasive monitors are used as the patient condition warrants.

**SUSPECT SUBCUTANEOUS INFILTRATIONS WITH LARGE INCREASES IN END-TIDAL CO<sub>2</sub>.**

General anesthesia for laparoscopy should always be accompanied by endotracheal intubation to ensure protection of the airway secondary to increased intraabdominal pressure and the Trendelenburg position.

After the airway has been secured and the endotracheal tube position is confirmed, an orogastric tube should be inserted for decompression of the stomach prior to instrumentation of the abdomen. This minimizes the risk of puncturing the stomach in addition to emptying it to help minimize nausea and vomiting during recovery.

General anesthesia can be accomplished by the intravenous or inhalation method. The use of N<sub>2</sub>O varies by anesthesiologist. Its effects on nausea and possible increased bowel distension are controversial. It has been reported that if the procedure lasts longer than 30 minutes, there is enough N<sub>2</sub>O to support combustion.

If the patient gives a positive history of nausea, elimination of N<sub>2</sub>O, as well as the use of antiemetics, may be of some benefit. The use of 80% oxygen may also reduce nausea and vomiting and decrease the incidence of wound infections. Routine use of antiemetics is not indicated. A muscle relaxant that does

not require reversal may also improve the chances of eliminating nausea during recovery. The use of propofol for induction and as the primary anesthetic, or as an adjunct to decrease the amount of inhalation agent, will also help to prevent nausea and vomiting and provide a quick recovery. However, in high-risk patients, treatment with an antiemetic, dexamethasone 4-8 mg, and Reglan or droperidol may be beneficial.

Different antiemetics used postoperatively in the recovery period may also be considered if nausea becomes a problem during that time.

## COMPLICATIONS

### PULMONARY EMBOLISM

Pulmonary embolism, although rare, is possibly due to the venous stasis that may occur from the obstruction of flow secondary to the pneumoperitoneum. Even minimal insufflation values of 12 mmHg can result in venous stasis that is not affected by external compression devices. Pulmonary embolism should always be considered in the differential diagnosis of cardiac compromise.

### PNEUMOTHORAX, PNEUMOMEDIASTINUM, AND PNEUMOPERICARDIUM

Intraperitoneal gas may find its way through openings in the diaphragm and esophageal hiatus that are congenital or surgically created inadvertently. Any

GAS FOLLOWS OPENINGS IN THE DIAPHRAGM AND ESOPHAGEAL HIATUS OR PNEUMOTHORAX.

AN INCREASE IN AIRWAY PRESSURE WITH DECREASE IN CV STATUS.

RESOLVES WITH RELEASE OF INTRAABDOMINAL GAS.

LIMIT PRESSURE TO LOWEST POSSIBLE LEVELS.

interruption in the falciform ligament may also allow access for movement of gas and unwanted accumulation in the mediastinum. Opening of pleural peritoneal ducts, as in ascites, may also lead to the accumulation of gas in the mediastinum or to pneumothorax. Pneumothorax is the most common of the three and can also occur from positive pressure ventilation. Pleural tears may also occur iatrogenically. End-tidal  $\text{CO}_2$  will increase unless the pneumothorax is from a spontaneous cause. Tension pneumothorax is a possibility if the pneumothorax goes unrecognized. Whatever their origin, this must be recognized as quickly as possible. Risk factors include end tidal  $\text{CO}_2$  greater than 50 mmHg and duration of operation greater than 200 minutes.

Recognition of increasing airway pressure is the earliest sign. Blood pressure may not decrease until some time has passed. End-tidal  $\text{CO}_2$  and Pa  $\text{CO}_2$  will increase much sooner than blood pressure changes. Oxygenation itself may or

may not be affected. Auscultation will reveal decreased breath sounds. The surgeon may be asked to look at the diaphragm for uncoordinated motion on one side. Tension pneumothorax should always be considered as a possibility. Other common causes such as migration of the endotracheal tube into one bronchus may be possible. Treatment consists of identifying the cause and supporting the patient by increasing the pressure in the aveoli to decrease the tendency for compression. Utilizing positive end expiratory pressure, increasing the minute ventilation, and oxygen concentration will usually result in an improvement. If the patient tolerates this and improves, chest tube placement is not required and spontaneous resolution usually occurs within 60 minutes of release of abdominal gas.

If  $\text{N}_2\text{O}$  is used, it should be stopped and ventilator settings should be adjusted. Communication with the surgeon to reduce intraabdominal pressure as much as possible, and careful observation of the patient should correct the situation without thoracentesis. Limiting the intraabdominal pressure to the lowest possible levels will decrease the incidence. The most helpful monitor in this situation is transesophageal echocardiography.

## PNEUMOMEDIASTINUM

Accumulation in these areas is rare in gynecologic procedures and occurs most often with retroperitoneal laparoscopy.



These usually resolve spontaneously within 3-4 days. Pneumopericardium can be life threatening if large, but should not be an isolated event.

Limiting the intraabdominal pressure to the lowest possible levels will decrease the incidence. The most helpful diagnostic tool is transesophageal echocardiography.

### SUBCUTANEOUS EMPHYSEMA

Subcutaneous emphysema occurs as CO<sub>2</sub> dissects through peritoneal defects into the subcutaneous tissue. Subclinically it has been shown on computed tomography that was detectable on physical examination. Any increase in end-tidal CO<sub>2</sub> that does not respond to increased minute ventilation should lead to suspicion of subcutaneous emphysema. A correlation exists with more than six ports and prolonged operative time. The patient should be physically observed and examined and preferably not totally covered with drapes. If crepitus and swelling of the tissue is seen, the case should be converted to open or aborted. The patient should be monitored after the procedure because absorption of carbon dioxide may cause hypoventilation due to a decreased respiratory drive and may even require mechanical ventilation. Depending on the level of arterial CO<sub>2</sub>, the patient will often need mechanical ventilation until the CO<sub>2</sub> levels return to normal. This usually resolves within 24 hours or less depending on the severity.

### GAS EMBOLISM

Gas embolism may occur from direct insufflation into a vessel or organ from direct needle or trocar placement. There appears to be an increased incidence during hysteroscopy more than laparoscopy. The volume of gas necessary to produce symptoms is 25 mL/kg of CO<sub>2</sub> as opposed to 5 mL/kg of air. It usually occurs at the beginning of surgery so insufflation techniques that assure the surgeon of proper placement of the Veress needle are important. The Veress needle allows no more than approximately 2-3 L/min to be infused due to the diameter of the needle. If proper technique is used, then it is not necessary to limit the flow to 1 L/min. However, the patient is always watched carefully during initial insufflation. Signs of embolism include tachycardia, arrhythmias, hypotension, millwheel murmur,

#### PROPHYLACTIC TREATMENT NOT INDICATED

POSITIVE HISTORY SHOULD REALIZE PROPHYLACTIC RX

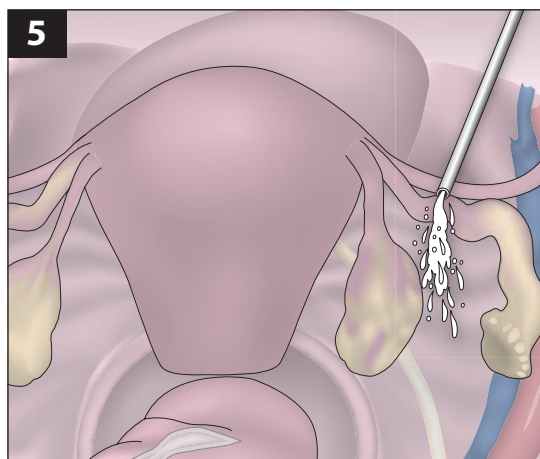
MULTI-MODAL

- METODOPRAMIDE
- ANTI-EMETIC OF CHOICE
- PROMPT TX. IF OCCURS
- SMALL AMOUNTS OF STEROIDS AND BENADRYL MAY HELP
- ALLOW ENOUGH TIME TO EXPEL AS MUCH GAS AS POSSIBLE

and EKG signs of right heart strain. End-tidal CO<sub>2</sub> may be decreased due to the decrease in cardiac output. Aspiration of gas, foamy blood from a central venous line or air bubbles demonstrated on TEE will provide definitive diagnosis. To help reverse the symptoms, deflate the abdomen with the patient placed in the head down and left lateral position trying to keep as much CO<sub>2</sub> as possible in the right atrium, administer 100% oxygen, and aspirate as much gas as possible. Although gas embolism may be fatal, rapid diagnosis and treatment is highly successful as long as blood pressure is supported.

## POSTOPERATIVE RECOVERY

Postoperative nausea and vomiting can be significant problems. A positive history should be treated with preventive measures. Metoclopramide will help to empty the stomach preoperatively. Careful suctioning of the orogastric tube prior to emergence will relieve the stomach distension that may have occurred intraoperatively. For patients with a positive history, an antiemetic and 4 mg dexamethasone prior to emergence is indicated as well as a propofol-based anesthetic. Prompt treatment in the recovery room with antiemetics and a steroid will usually prevent a continuing problem. A multimodal treatment of pain will prevent the total dependence on opioids and thus lessen the propensity for nausea and vomiting. Allowing enough time for as much gas as possible to escape the abdomen is an important



INFILTRATION OF SKIN AND MESOSALPINX  
WILL HELP WITH POSTOP PAIN

PAIN MEDICINE SHOULD  
INCLUDE RETOROLZE

COX-2

and often neglected step in providing patient comfort.

A lidocaine-ropivacaine drip on the Fallopian tubes will greatly decrease the pain of tubal ligation (Figure 5). Pre-emptive analgesia by local infiltration of the skin prior to instrumentation is a useful adjunct if done with a long-acting anesthetic in combination with lidocaine. Many maneuvers have attempted to decrease shoulder pain. Instillation of a long-acting anesthetic may help this condition in some patients. Some studies show that if the insufflation gas is heated and hydrated, the incidence of shoulder pain decreases.

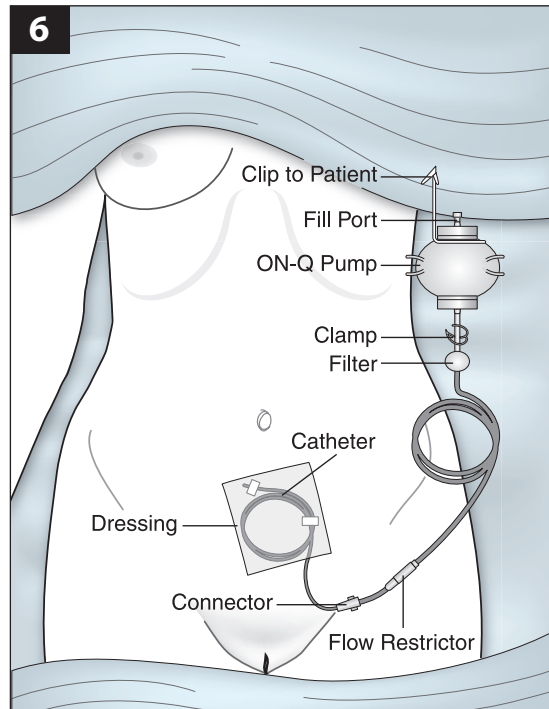
Ketorolac and Cox-2 inhibitors are helpful adjuncts for the treatment of pain and will decrease the amount of opioids needed. One study has demonstrated that injection of the surgical ports with a long acting local anesthetic such as bupivacaine, along with Toradol, will decrease the amount of postoperative pain. Transdermal scopolamine and benadryl may also be of benefit. At the time of skin closure, 60-80 mg of Toradol may avoid postoperative cramping.

## SUMMARY

Laparoscopy has obvious benefits to the patient and will continue to develop as better instruments, greater experience, and more knowledge about the effects on the body are further elucidated. As this occurs, our ability to apply this technique with greater expertise will improve patient morbidity and provide anesthetic challenges to supply a physiologic milieu in the presence of a myriad of physiologic variations caused by this procedure.

## IMPROVING PATIENT OUTCOMES THROUGH NON-NARCOTIC PAIN RELIEF WITH ON-Q® PAINBUSTER® FOLLOWING LAVH

ON-Q® PainBuster® provides targeted post-surgical pain relief for patients following laparoscopic assisted vaginal hysterectomy and allows patients to go home more quickly following the procedure. This pain relief system employs a small, disposable balloon pump that delivers non-narcotic numbing medication directly



to the surgical site through a specially designed, proprietary Soaker Catheter™ inserted during surgery. The medication is automatically delivered for up to five days after surgery.

The ON-Q Soaker Catheter is introduced intra abdominally and visualized through the laparoscope. The catheter is placed approximately 2 cm above and lateral to the pubis. The Soaker Catheter is guided by instrument and placed into the cul-de-sac for postoperative infusion (Figure 6). A bolus is then given through the catheter with 5 cc of 0.5% Sensorcaine, secured with steri strips and tegaderm. The ON-Q PainBuster is then connected and infuses for approximately three days.

ON-Q PainBuster may be worn inside or outside clothing and is completely

---

portable and patient-friendly. The catheter is easily removed by the healthcare provider or the patient after the infusion is complete. Because patients using ON-Q PainBuster typically require less narcotics, they may recover without many of the side effects associated with narcotics, including PONV, respiratory depression, grogginess, constipation and present the potential for addiction.

The recently introduced ON-Q SilverSoaker® catheter contains an antimicrobial agent which may destroy or inhibit the growth of microorganisms on both the inner and outer surfaces of the catheter, providing an added layer of protection for the patient.

## SUGGESTED READING:

Goll V, Akca O, Greif R, et al. Ondansetron is no more effective than supplemental intraoperative oxygen for prevention of postoperative nausea and vomiting. *Anes Analg* 2001; 92:112–7

Greif R, Laciny S, Rapf B, Hickie RS, Sessler DI. Supplemental oxygen reduces the incidence of postoperative nausea and vomiting. *Anesthesiology* 1999;91(5): 1246–1252

Howie MB, Kim MH. Gynecologic surgery. In: *Ambulatory Anesthesia and Surgery*. White PF, ed. Philadelphia: W.B. Saunders 1997, pp 282–284

Jon's JL. Anesthesia for Laparoscopic Surgery. In: *Anesthesia (5th Ed)* Miller RD, ed, Philadelphia: Churchill Livingstone, 2000, pp. 2003–2023

Mortero R, Clark L, Tolan MM, et al. The effects of small-dose ketamine on propofol sedation: respiration, postoperative mood, perception, cognition, and pain. *Anesth Analg* 2001; 92:1–5

Weingram J. Laparoscopic Surgery. In: *Yao & Artusio's Anesthesiology: Problem-Oriented Patient Management*. Yao F-S, ed. with 40 contributors. Philadelphia: Lippincott-Raven, 4th ed. 1998, pp 732–759

Bardoczky GI, Engleman E, Levarlet M, et al. Ventilatory effects of pneumoperitoneum monitored with continuous spirometry. *Anesthesia* 1993;8:309

Wittgen CM, Ngunhein KS, Andrus CH, et al. Preoperative pulmonary evaluation for laparoscopic cholecystectomy. *Arch Surg* 1993;128:880

Ho HS, Saunders CJ, Gunther RI, et al. Effectors of hemodynamics during laparoscopy: CO<sub>2</sub> absorption or intra-abdominal pressure? *J Surg Res* 1995;59:497

Backlund M, Kellolumpu I, Scheimint, et al. Effect of temperature of insufflated CO<sub>2</sub> during and after prolonged laparoscopic surgery. *Surg Endosc* 1998;12:126

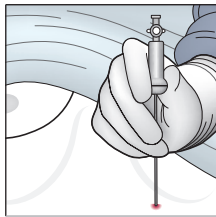
Clinical studies available at [www.iflo.com](http://www.iflo.com)

Stringer N, et al; AON-Q system for managing trocar site pain after operative laparoscopy. *JAAGL* 2000;7(4):552–555

Zimberg S, Guillermo D, Seiler J, Neimark M; AON-Q pain relief system in elective abdominal hysterectomy surgery, a pilot clinical outcomes study evaluating length of stay, postoperative pain, narcotic analgesia use and impact on costs and adverse effects. *Am J of Obstet and Gynecol* 2002;99(4)

Gupta A, et al; Postoperative pain after abdominal hysterectomy: a double-blind comparison between placebo and local anesthetic infused intraperitoneally. *Anesth Analg* 2004;99:1173–9

# CREATION OF PNEUMOPERITONEUM AND TROCAR INSERTION TECHNIQUES



*Resad Pasic M.D., Ph. D.*

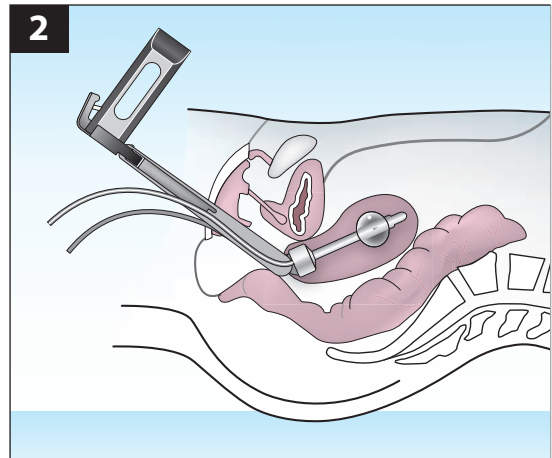
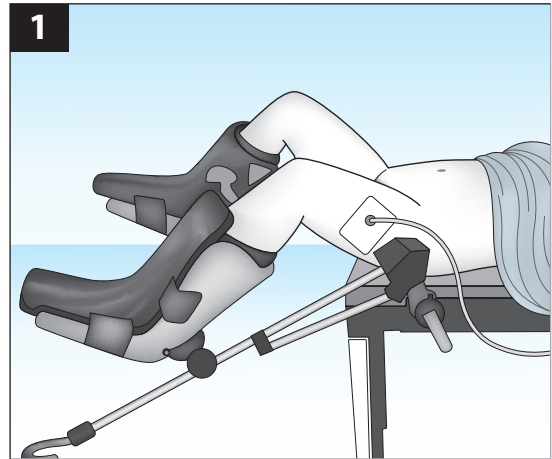
**P**roper patient positioning is essential for performing laparoscopic procedures.

The patient is placed in a dorsolithotomy position with the buttocks extended over the end of the table. The thighs should be flexed ( $120^\circ$ ) to allow good instrument manipulation (Figure 1). Attention should be given to proper positioning of the patient's legs to avoid peroneal nerve injury during lengthy procedures. Shoulder braces may be used to make the steep Trendelenburg position possible during surgery. If shoulder braces are used they should be placed over the acromion to avoid possible nerve injury. It is advisable that both arms should be tucked along the patient's body to provide more space for the surgeons and prevent brachial plexus injury. This is essential, especially if the TV monitor is positioned between the patient's legs, as it permits the surgeon more room to move backwards and to keep a comfortable position during surgery. If electrosurgery is to be used during the procedure, a return plate for unipolar instruments must be properly placed over the patient's thigh, and full surface contact of the plate must be assured. Straight bladder catheterization is performed for short laparoscopic procedures or a

Foley catheter is placed in the bladder if prolonged surgery is anticipated. The bladder has to be emptied to minimize any potential injury during ancillary trocar placement.

After placement of a cervical tenaculum, a uterine manipulator is inserted into the cervix and uterine cavity to properly manipulate the uterus during the procedure (Figure 2). Manipulators with a capability for tubal lavage may be used, as well as to permit the instillation of dilute indigo carmine dye for chromopertubation. If the patient does not have a uterus, or is pregnant, a sponge stick is introduced into the vagina and the cul-de-sac is pushed upward. A rectal probe can also be introduced for manipulation and better visualization of the rectum and identification of the rectovaginal septum during extensive laparoscopic resections.

Povidone iodine is applied to the abdominal area and vagina extending from the nipple line to the inner thighs. The patient is draped with leggings and a laparoscopy sheet. If extensive surgery is likely to be performed, and bowel manipulation or injury anticipated, as in the case of extensive adhesions or endometriosis, it is advisable to administer a mechanical bowel preparation prior to surgery. The use of a nasogastric or orogastric tube prior to the establishment of the pneumoperitoneum is suggested if the left upper quadrant insufflation technique is used to minimize the risk of gastric injury. Prophylactic antibiotics are not routinely used but can be administered if an increased risk of infection appears possible.



- LITHOTOMY POSITION WITH EXTENDED BUTTOCKS
- SHOULDER BRACES
- FOLEY CATHETER IN THE BLADDER
- UTERINE MANIPULATOR
- NASOGASTRIC TUBE
- RETURN ELECTRODE

## CREATION OF PNEUMOPERITONEUM

Creation of a pneumoperitoneum and the insertion of a Veress needle and primary trocar are the most critical steps when performing laparoscopy. Common sites of Veress needle and trocar insertion are shown in Figure 3.

Extra-peritoneal insufflation is one of the most common complications of laparoscopy regardless of body weight and is responsible for technical failures that frequently lead to the abandonment of the procedure.

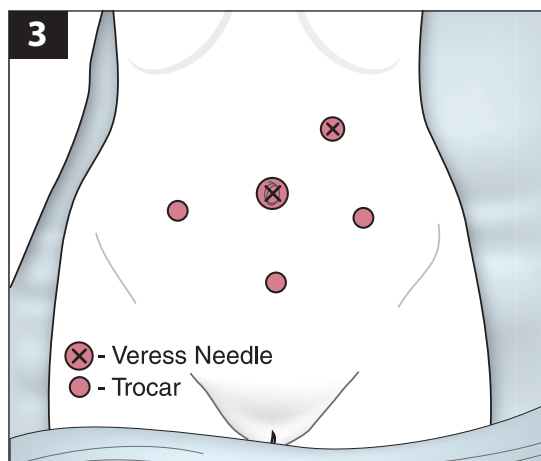
There are four subgroups of patients who can present problems during the development of the pneumoperitoneum during laparoscopy:

1. Obese patients
2. Very thin patients
3. Patients with scars from previous abdominal surgeries
4. Patients with failed insufflation

The abundant abdominal wall and intraabdominal fat of obesity decreases tactile sensation and poses difficulty for the standard transumbilical Veress needle insertion and establishment of a pneumoperitoneum. Higher insufflation pressures may be encountered in these patients.

Extra caution is required with very thin patients, since the abdominal wall is lying very close to the retroperitoneal vascular structures.

Presence of abdominal scars increases the possibility of omental or bowel adhesions to the abdominal wall, which may



### VERESS NEEDLE TECHNIQUES

- TRANSUMBILICAL PLACEMENT
- LEFT UPPER QUADRANT PLACEMENT
- PALMER'S POINT
- 9TH INTERCOSTAL SPACE
- TRANSUTERINE PLACEMENT

### OPEN LAPAROSCOPY

- BLIND DIRECT TROCAR PLACEMENT
- DIRECT VISION TROCARS

interfere with the successful development of the pneumoperitoneum, and may lead to bowel injury. Bowel and other intraabdominal structures have great motility and are resistant to needle puncture unless they are fixed to the abdominal wall by some pathologic process.



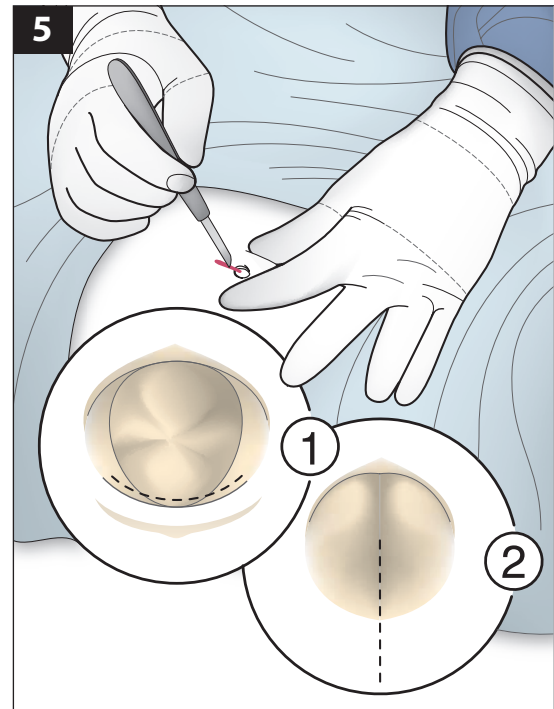
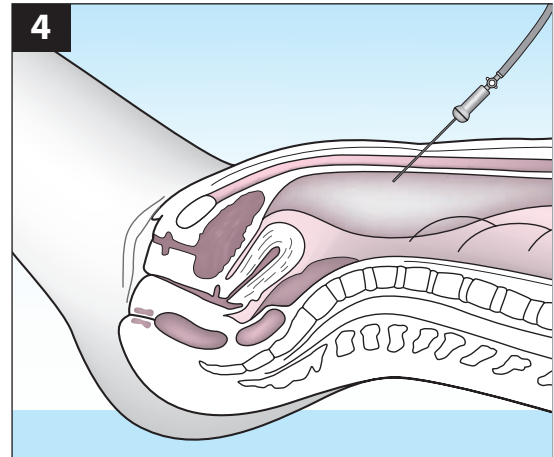
In patients with failed insufflation or preperitoneal insufflation it becomes difficult to enter the peritoneal cavity since the peritoneum is peeled off and an artificial space is created by trapped CO<sub>2</sub> gas that prevents re-entry of the Veress needle into the peritoneal cavity (Figure 4). Therefore, in these cases an alternative insufflation site should be chosen.

### TRANSUMBILICAL INSUFFLATION

The umbilical area is the most common site for Veress needle placement. Carbon dioxide or nitrous oxide (N<sub>2</sub>O) are most often used for insufflation, since room air is not very soluble in blood and may cause embolism if it enters a blood vessel. CO<sub>2</sub> is preferred for most laparoscopic surgery and N<sub>2</sub>O is often used for laparoscopy under local anesthesia.

A skin incision of about 1.5 cm may be made using a number 11-scalpel blade at the umbilical area (Figure 5). The Veress needle should be inspected and checked before insertion. The valve on the Veress needle should be placed in open position during insertion to allow the air to enter the abdominal cavity as the tip of the needle advances. This will prevent possible creation of negative pressure caused by lifting of the abdominal wall that may hold the bowel close to it. When the valve is open it will also immediately alert the surgeon of a major blood vessel injury.

The operating table with the patient should be placed in the flat position (Figure 6). The needle is usually inserted

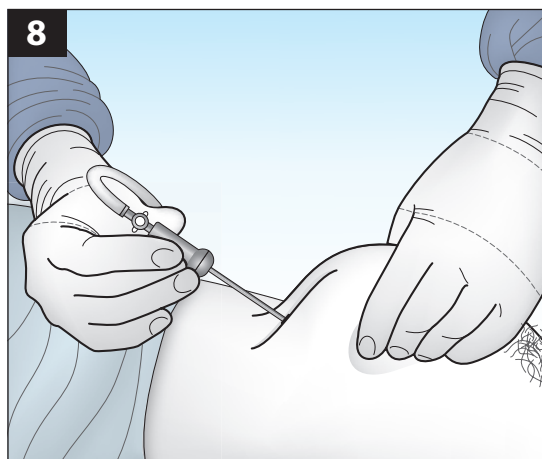
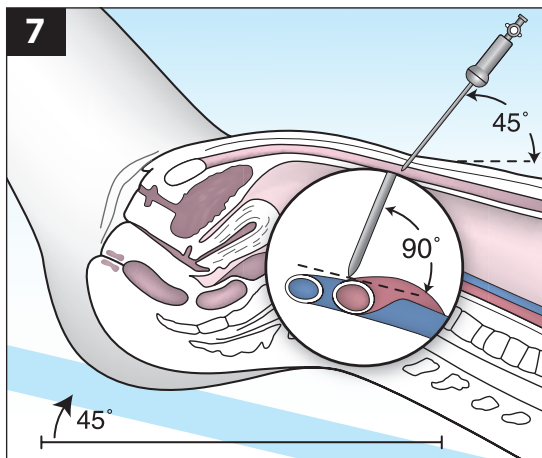
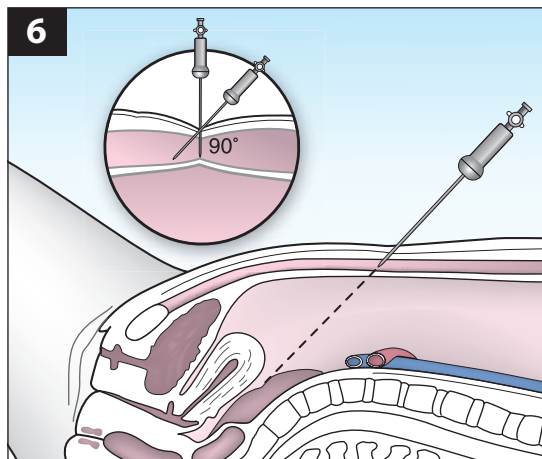


CAREFUL SELECTION OF THE INSUFFLATION TECHNIQUE AND THE INSUFFLATION SITE SHOULD BE CHOSEN FOR EACH PATIENT.

at a  $45^\circ$  angle at the midline and directed toward the uterine fundus. Placing the patient in Trendelenburg position prior to the insertion of the Veress needle and primary trocar changes the position of the major retroperitoneal vessels, and places them in the path of the needle and the trocar which, in turn, places the patient at greater risk of major vascular injury. The  $45^\circ$  angle of Trendelenburg is added to the  $45^\circ$  angle of needle placement making the position of the needle vertical to the retroperitoneal blood vessels (Figure 7).

Lifting the abdominal wall prior to needle insertion is favored by many surgeons (Figure 8), but some insert the Veress needle directly into the abdomen using gentle traction without abdominal wall elevation. Some surgeons use towel clips to grab and lift the abdominal wall at the time of Veress needle insertion. Depending upon the abdominal wall thickness, the angle of insertion may vary from  $45^\circ$  to  $90^\circ$ . In obese patients, the angle of insertion should be close to  $90^\circ$ . If proper intraperitoneal placement of the needle is not obtained, one more attempt should be considered before choosing an alternative site. There are a number of tests that may ensure proper needle placement and avoid possible complications during the insufflation procedure.

1. Hanging drop test: attaching an open syringe filled with saline to the Veress needle and observing the drop of saline while negative intraabdominal pressure is created by lifting the anterior abdominal wall (Figure 9).

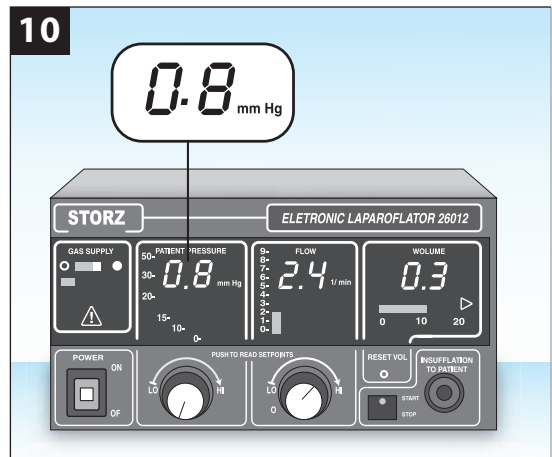
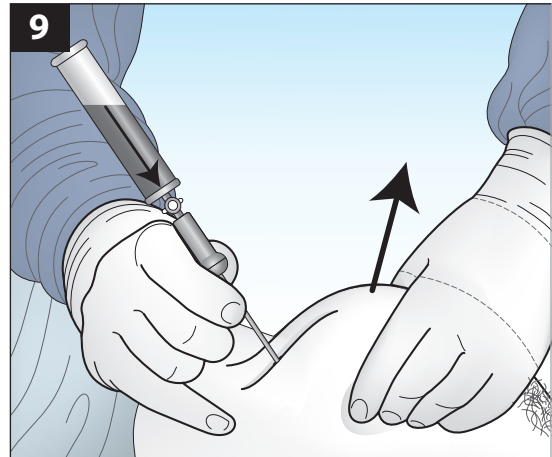


2. Intraabdominal insufflation pressure (Figure 10).

3. Aspiration and sounding test, using an aspiration needle on the syringe (Figure 11).

Although these tests might be of some value in determining proper needle placement, many operators rely primarily on the intraabdominal insufflation pressure and flow volume to ensure proper intraperitoneal needle placement.

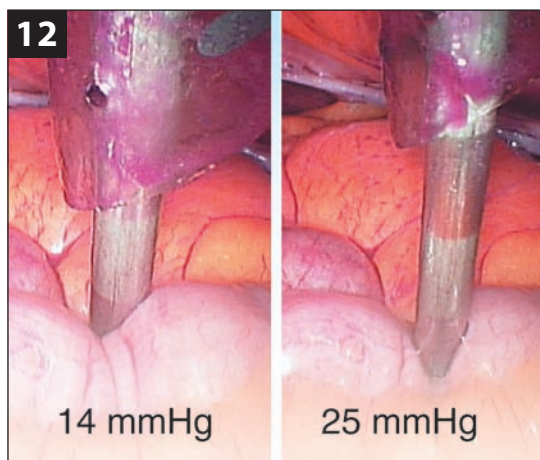
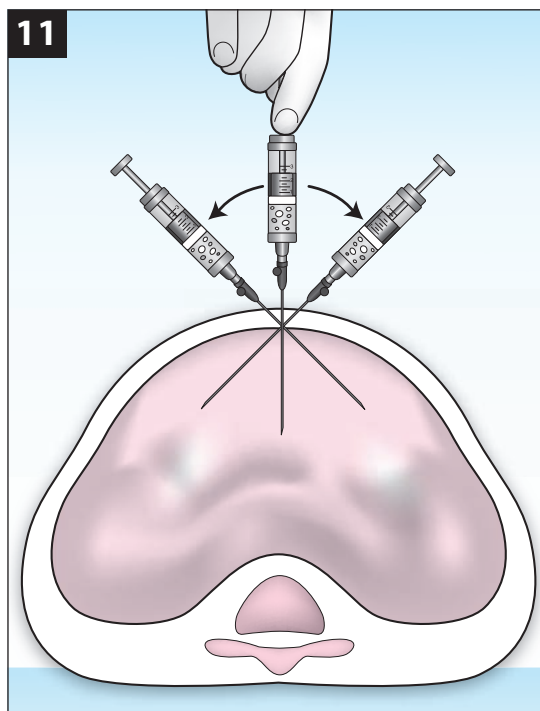
Initial intraabdominal insufflation pressure should not exceed 10 mmHg, and it is the most reliable parameter for monitoring insufflation and proper needle placement. If the initial insufflation pressure exceeds 10 mmHg, the Veress needle is most likely in the preperitoneal space or has entered an intraabdominal viscus or omentum and it should be repositioned or withdrawn. If the surgeon is uncertain that the needle is not placed intraperitoneally, the Veress needle should be withdrawn and re-inserted before too much preperitoneal emphysema has developed. During insufflation other clinical signs such as disappearance of liver dullness and symmetric distension of the lower abdomen can be observed. During the process of insufflation, the slow rise in the intraabdominal pressure compared with the insufflated volume of gas should be monitored. If the intraabdominal pressure rises quickly over 14 mmHg, before 1.5-2 L of gas are insufflated, the suspicion of preperitoneal or viscus insufflation may be assumed. If the needle is properly placed, the peritoneal cavity is insufflated with 3-6 L of



CO<sub>2</sub>, depending upon the patient's size. After insufflating about 1.5-2 L of CO<sub>2</sub>, intraabdominal pressures will begin to rise. Insufflation should be continued until the pressures reach at least 20-25 mmHg. Since the abdominal cavity is a closed space and its volume varies from patient to patient, insufflation pressure is a better indicator of adequate peritoneal insufflation and distension than the volume of gas used. When the insufflation pressure reaches 20-25 mmHg, distension

of the abdominal cavity should be adequate for safe insertion of the trocar, and the needle should be withdrawn. Figure 12 represents the distance from the trocar tip as it pierces the abdominal wall to the retroperitoneal structures at 15 mmHg and at 25 mmHg. Notice that the distance from the tip to the retroperitoneal struc-

- CHECK THE VERESS NEEDLE BEFORE INSERTION.
- CHECK THE STARTING PRESSURE IF MECHANICAL INSUFFLATORS ARE USED.
- PLACE THE PATIENT IN FLAT POSITION.
- MAKE THE SKIN INCISION OF ABOUT 1.5 CM.
- INSERT THE NEEDLE IN MIDLINE POSITION AT A 45° ANGLE WHILE PULLING ON THE ABDOMINAL SKIN TO FORM A COUNTERTRACTION.
- IF THE INSUFFLATION PRESSURE IS ABOVE 10 mmHg WITHDRAW THE NEEDLE AND REPEAT THE SAME PROCEDURE AT THE PROXIMAL END OF THE UMBILICAL INCISION.
- IF HIGH PRESSURE IS OBTAINED AGAIN, WITHDRAW THE NEEDLE AND CONSIDER AN ALTERNATIVE PUNCTURE SITE.
- IF DEALING WITH A MORBIDLY OBESE PATIENT OR PATIENTS WITH SCARS FROM PREVIOUS ABDOMINAL SURGERIES, AN ALTERNATE PRIMARY INSUFFLATION SITE MAY BE CONSIDERED.



tures is much greater if the abdomen is insufflated to 25 mmHg (Figure 12). After the trocar is inserted, the pressure on the insufflator should be set at approximately 14-15 mmHg.

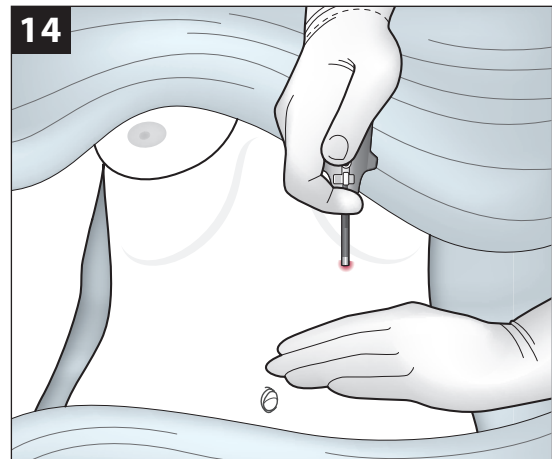
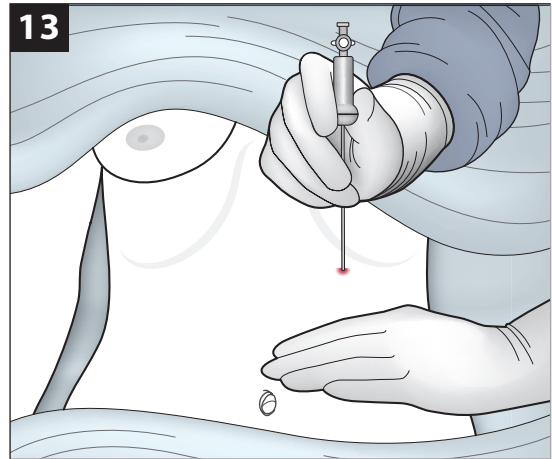
## ALTERNATIVE SITES AND TECHNIQUES

An alternative site for needle placement can be selected if the umbilical area is deemed unsuitable for insertion.

### SUBCOSTAL INSUFFLATION TECHNIQUE

Insertion of the Veress needle through the subcostal space in the left midclavicular line is a safe alternative to transumbilical insufflation. A small stab skin incision is made in the left midclavicular line just beneath the rib cage. A Veress needle is placed at a 90° angle and pushed into the abdominal cavity. No abdominal wall elevation is performed. Three distinct pops of the needle can be felt as the needle advances toward the peritoneal cavity. The abdominal wall is usually thin in this area, no more than 3–4 cm (Figure 13).

The left upper quadrant is easily accessible and is usually free of intraabdominal adhesions. This area is very safe for needle and trocar insertion because the rib cage provides adequate tension and prevents the downward displacement of the abdominal wall. This technique works well for patients with a failed transumbilical insufflation. It should be used as a primary route in obese patients, or patients who have had previous abdominal surgeries and have abdominal scars with suspected adhesions in the umbilical area, regardless if the scar is from a midline, Pfannenstiel, or any other incision.



Subcutaneous emphysema is rarely encountered when insufflating in this space. The spleen is unlikely to be injured when using the midclavicular subcostal space, although, very rarely the left lobe of the liver may be punctured with the Veress needle. To avoid liver injury, the Veress needle should be directed caudad, at an angle slightly less than 90°.

In a patient with suspected abdominal adhesions, upon successful insuf-

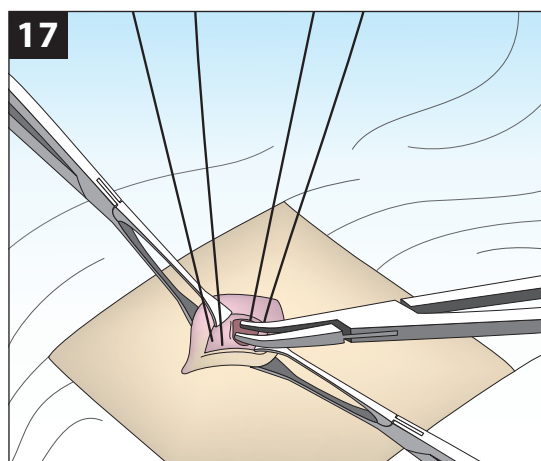
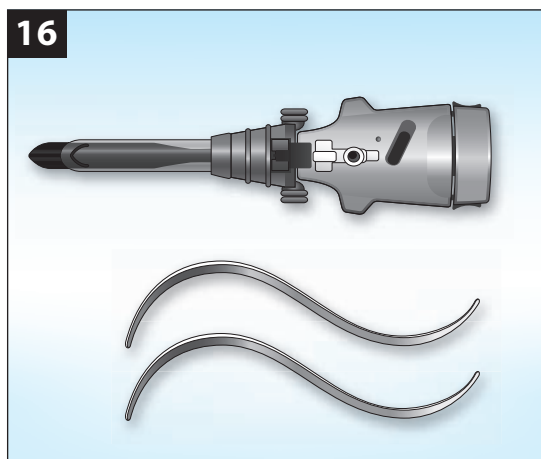
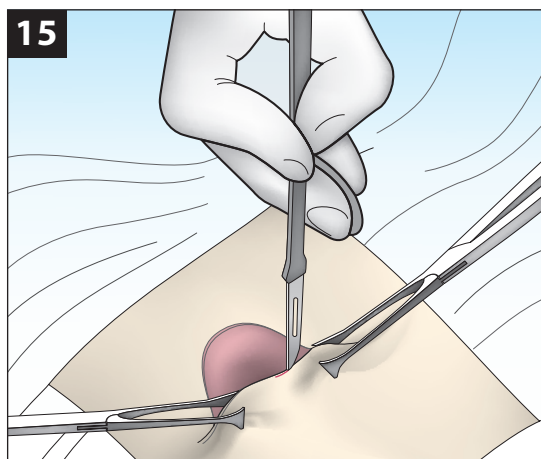
## SUBCOSTAL APPROACH

- MAKE A SMALL STAB INCISION IN THE MIDCLAVICULAR LINE, JUST BELOW THE COSTAL MARGIN, ON THE PATIENT'S LEFT SIDE.
- INSERT THE VERESS NEEDLE AT A 90° ANGLE.
- THREE POPS OF THE NEEDLE ARE USUALLY FELT.
- IF INITIAL PRESSURES ARE TOO HIGH, PULL THE NEEDLE BACKWARD. IT MAY BE STUCK IN THE OMENTUM.

flation, the Veress needle is withdrawn and a 5 mm trocar is inserted through the same space (Figure 14). Through this trocar sleeve, a 5 mm scope is introduced, and the umbilical area is inspected for the absence of adhesions. If the umbilical area is free of adhesions, a 10 mm trocar is inserted into the peritoneal cavity under direct vision.

## OPEN TECHNIQUE

Open laparoscopy (Hasson technique) is a popular technique among many gynecologists and general surgeons. It is indispensable in some patients, particularly those suspected of having adhesions from previous surgeries and abdominal scars. The open technique utilizes a small 2-3 cm umbilical skin incision (Figure 15). The open laparoscopy trocar set contains a 10 mm cannula, blunt trocar, and a conical obturator that plugs off the

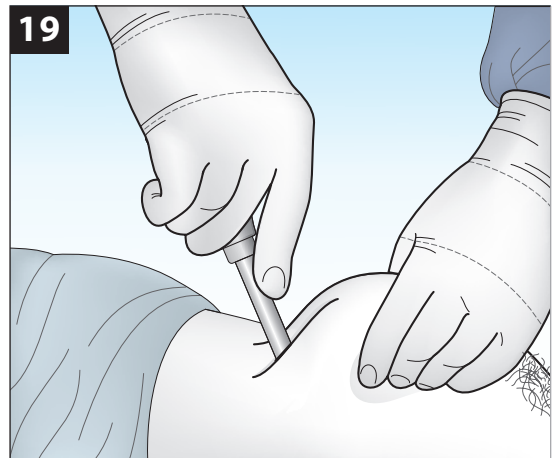
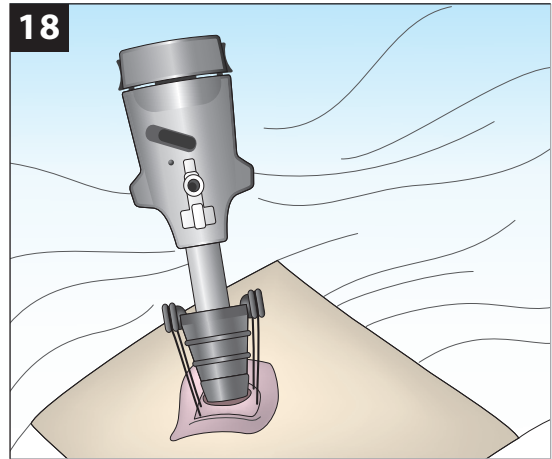


abdominal skin incision (Figure 16). The dissection is performed into the abdomen with Kelly clamps and special 'S' shaped retractors. After the abdominal fascia is visualized and incised, two 0-Vicryl™ sutures are placed into the fascia to support and hold the blunt trocar that is inserted into the abdominal cavity after the incision is carried through the peritoneum. Gas is insufflated directly through the cannula and a blunt trocar is replaced with the laparoscope (Figures 17, 18).

This technique may be safer than blind, Veress needle and trocar incision as noted by the lower rate of vascular injuries; however, its routine application may not prevent bowel injuries. Open laparoscopy is very difficult to perform in a morbidly obese patient, because one must penetrate 8-10 cm of adipose tissue before reaching the fascia and peritoneal cavity through a small skin incision. This technique, therefore, can be impractical and time consuming. Some authors suggest that open techniques are suited for use in obese patients, especially to prevent vascular injuries. However, as noted this technique does not seem very reliable in preventing bowel injuries.

### DIRECT TROCAR INSERTION

Direct trocar insertion is reserved mostly for thin patients with a flaccid anterior abdominal wall. In this technique, a small incision is made in the umbilical area, the abdominal wall is lifted with one hand, and a trocar is pushed with the dominant hand into the peri-



toneal space of the abdominal cavity. Insufflation tubing is attached to the trocar and the laparoscope is inserted (Figure 19).


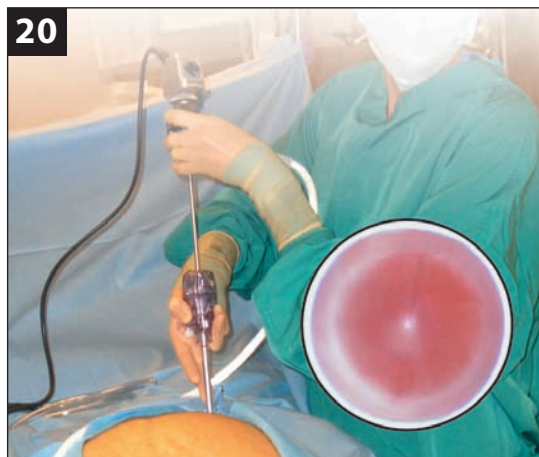
This technique is fast and reliable in carefully chosen patients. Surgeons who routinely use the direct insertion technique consider it to be safer than using the Veress needle. Direct trocar insertion works well for multiparous, thin patients with a flaccid anterior abdominal wall; however, we find it impractical and haz-

### DIRECT TROCAR INSERTION:

- MAKE A 1.5 CM UMBILICAL INCISION.
- LIFT THE ANTERIOR ABDOMINAL WALL WITH LEFT HAND.
- INSERT THE TROCAR WITH THE RIGHT HAND AIMING TOWARD THE UTERUS.
- CONNECT THE TUBING AND BEGIN THE INSUFFLATION.

ardous in obese patients. In obese patients, it is difficult to grasp and elevate the abdominal wall sufficiently for safe placement of the trocar.

Direct trocar insertion may also present a problem for female surgeons because it requires significant strength and force to lift the abdominal wall and push the trocar into the peritoneal cavity. The availability of new direct vision trocars may enhance the safety of this procedure. The technique is very popular with general surgeons and more gynecologic surgeons are also adapting this technique. The disposable optical trocars are used to gain the peritoneal access either directly or after Veress needle insufflation. The 5 or 10 mm laparoscope is placed into the trocar sheath and the trocar is pushed with twisting motion into the abdominal cavity (Figure 20). The layers of the abdominal wall are visualized as the trocar is advanced through the abdominal wall. The proce-



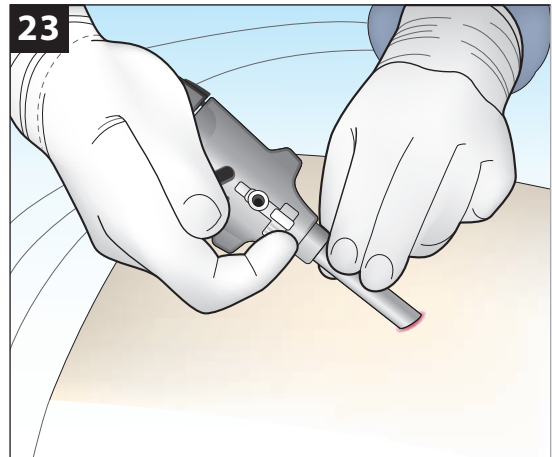
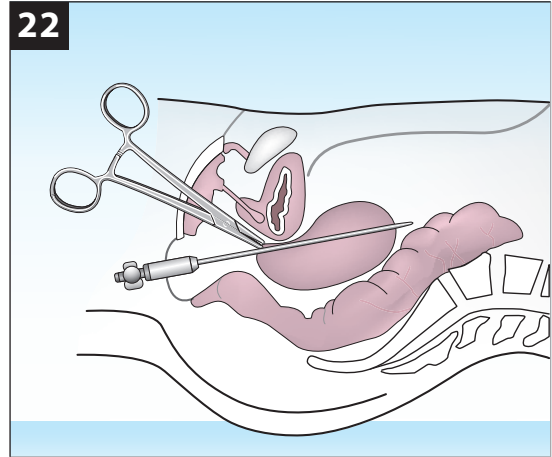
cedure is quite safe and reliable. The non-disposable trocar made by Storz is also available for use with this technique. The trocar is simply screwed into the abdominal wall without any pushing. The abdominal wall is being lifted and pulled up with the turning motion of the trocar until the tip of the trocar enters the abdominal cavity. The whole process is followed under direct vision using the laparoscope that is inserted into the trocar (Figure 21).



## TRANSUTERINE INSUFFLATION

This method enables easy and safe access to the peritoneal cavity, bypassing transabdominal entry of the Veress needle in obese patients. Transuterine insufflation is a useful modality in patients with a large abdominal panniculus, because the peritoneal cavity can be easily entered with the Veress needle via the transcervical route and through the uterine fundus (Figure 22).

This technique is very simple and safe, but it should not be considered in patients with large uterine fibroids and



### TRANSUTERINE APPROACH:

- INSERT VAGINAL SPECULUM
- GRASP ANTERIOR CERVICAL LIP WITH THE TENACULUM AND PULL IT FORWARD.
- SOUND UTERINE CAVITY USING UTERINE SOUND.
- GRASP THE LONG VERESS NEEDLE WITH SPONGE FORCEPS AND INTRODUCE THE NEEDLE THROUGH THE CERVIX INTO THE UTERINE CAVITY. APPLY THE PRESSURE TO PERFORATE THE FUNDUS.
- CONNECT THE TUBING, AND TURN THE INSUFFLATION ON. THE HIGHER PRESSURE IN THE RANGE OF 15-20 MMHG IS EXPECTED.
- INSERT THE TROCAR AND REMOVE THE VERESS NEEDLE UNDER DIRECT LAPAROSCOPIC VISION.

patients who are candidates for chromotubation, since the hole in the uterine wall created by the Veress needle may facilitate the escape of the dye.

With the patient in a moderate Trendelenburg position, a speculum is placed in the vagina. The anterior cervical lip is grasped with an atraumatic grasper and the uterus is pulled forward to straighten its axis. The uterine cavity is sounded to obtain information on the size and direction of the cavity. A long

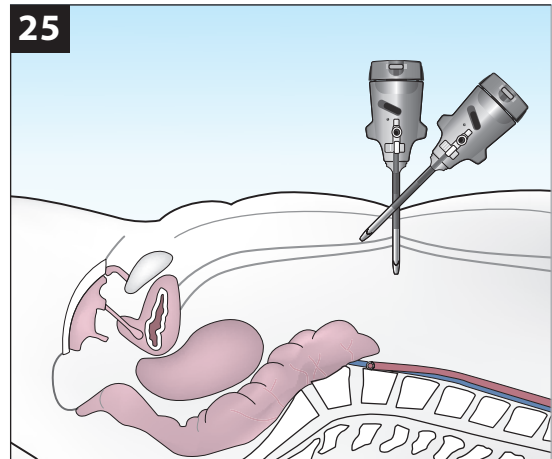
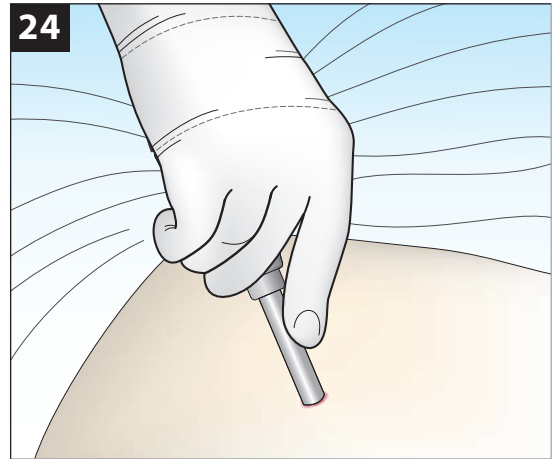
Veress needle is passed through the cervix into the uterine cavity until slight resistance is felt when the needle reaches the fundus. The needle is then pushed through the uterine fundus until it reaches the peritoneal cavity, detected by a pop of the needle as it advances through the uterus. The peritoneal cavity is then insufflated with CO<sub>2</sub>. Somewhat higher initial insufflation pressures, up to 20 mmHg, can be encountered initially with this method. As the abdominal cavity is being insufflated, the pressures begin to drop.

This technique should be considered in obese patients and patients with failed transabdominal insufflation where an artificial preperitoneal space is created.

## TROCAR PLACEMENT

Extensive insufflation of the peritoneal cavity to 25 mmHg will create enough elevation and resistance against the peritoneum for safe insertion of the trocar.

The trocar and sheath are held between the middle and index finger with the hub of the trocar against the palm of the hand. With wrist motion, the trocar is usually advanced with the dominant hand at a 45° angle in midline position toward the hollow of the sacrum. The other hand rests on the abdomen holding the trocar sheath between the index finger and the thumb to act as a safeguard to prevent excessive penetration of the trocar through the abdominal wall (Figure 23). The trocar sheath is slightly wider than the trocar tip and it

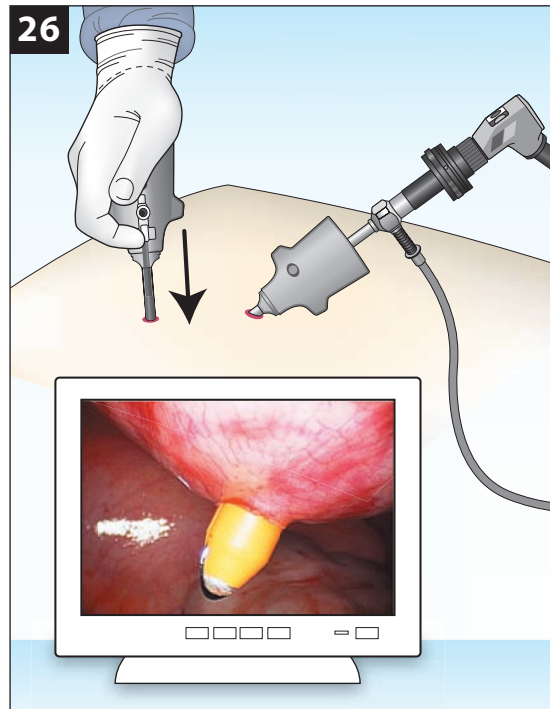


may get caught in the fascia. As the force is applied to the trocar, its tip may be pushed too far into the abdomen, as the trocar sheath passes the resistance of the fascia. Therefore, some type of safeguard mechanism should be applied on the trocar to avoid its excessive penetration. Another way to control the excessive penetration of the trocar is to hold the index finger extended along the shaft of the trocar (Figure 24). Depending upon the abdominal wall thickness the angle of

insertion may vary from  $45^{\circ}$  to  $90^{\circ}$ . In obese patients, the angle of insertion is close to  $90^{\circ}$  (Figure 25).

There is no need to lift the abdominal wall during the trocar insertion if the abdominal cavity is properly insufflated.

- EXTENSIVE INSUFFLATION OF THE PERITONEAL CAVITY. THE MORE THE BETTER.
- ANGLE OF INSERTION USUALLY  $45^{\circ}$ - $60^{\circ}$ .
- SAFEGUARD MECHANISM DURING TROCAR PLACEMENT.
- BEFORE PLACING ANCILLARY TROCARS, INSPECT THE INSIDE ABDOMINAL WALL FOR THE PRESENCE OF ADHESIONS.
- GENTLY TAP THE AREA WITH THE INDEX FINGER, WHERE THE PUNCTURE IS PLANNED, AND LOOK FOR THE INDENTATION OF THE ABDOMINAL WALL THROUGH THE LAPAROSCOPE.
- LOOK FOR BLOOD VESSELS BY TURNING THE ROOM LIGHTS OFF AND ILLUMINATE THE AREA ON THE ABDOMINAL WALL WITH THE LAPAROSCOPE FROM INSIDE.
- MAKE A SMALL 5 MM SKIN INCISION IN THE AREA CLEAR OF BLOOD VESSELS.
- INTRODUCE THE TROCAR SLEEVE UNDER LAPAROSCOPIC VISION, AIMING TOWARD THE POSTERIOR CUL-DE-SAC.
- REPEAT THE SAME PROCEDURE FOR EACH ANCILLARY PORT.



If the abdominal cavity has been insufflated to the pressure of 25 mmHg, the cushion of gas in the abdominal cavity is sufficient to hold the abdominal wall elevated for safe insertion of the trocar. Once the trocar is safely inserted into the abdominal cavity, the obturator is removed and the trocar sheath is held in place. Hiss of escaping gas can be heard by depressing the flap valve. This is the most comforting sound as it assures the surgeon that the trocar is in the right place.

Ancillary trocars should be inserted under direct endoscopic control (Figure 26). The suprapubic midline site is the most common, and two additional lower quadrant sites above the pubic hairline lateral to the deep epigastric vessels are recommended for performing operative

laparoscopic procedures. The authors prefer to place the ancillary 5 mm ports higher, approximately at the level of the umbilicus, about 8-10 cm lateral to the umbilicus. Placing the ancillary ports high will give you more manipulation capabilities especially when working on a large fibroid uterus. The abdominal wall may be transilluminated by the laparoscope at the site of the lateral secondary trocar placement in order to display and avoid deep epigastric blood vessels. This technique is useful, but cannot be relied upon to locate the deep vessels, especially in obese patients. Finger-tapping the skin from above can identify the area of trocar placement, and a small skin incision should be made before the trocar sleeve is inserted. The trocars should be placed perpendicular to the abdominal wall making sure that they do not slide along it. This is especially important in very obese patients where trocars often slide out of the peritoneum if they have not been placed properly at the 90° angle. If the insufflation is not adequate and the trocar tip is approaching close to the bowel, the pressure on the trocar should be intermittently released and the trocar twisted until it reaches the peritoneal cavity. If one of the ancillary trocars is already placed, a grasper can be inserted through it and the abdominal wall elevated from below to assist in placing the additional ancillary trocar. The upper margin of the bladder should be identified, and a Foley catheter should help avoid accidental bladder perforation. Note the patient's position and anatomi-

cal landmarks when inserting the trocars. Midline ancillary trocars should be directed toward the posterior cul-de-sac. Both hands should be used for trocar insertion. If only one hand is used because the second hand is holding the camera and, therefore, cannot be used as a safe stop for the trocar, the index finger should be extended along the trocar shaft to be used as a safeguard against deep penetration of the trocar. Most laparoscopic surgeries can be performed using 5 mm trocar sleeves, but if a stapler or a laparoscopic morcellator are to be used, a 12 mm trocar is inserted usually in the midline position.

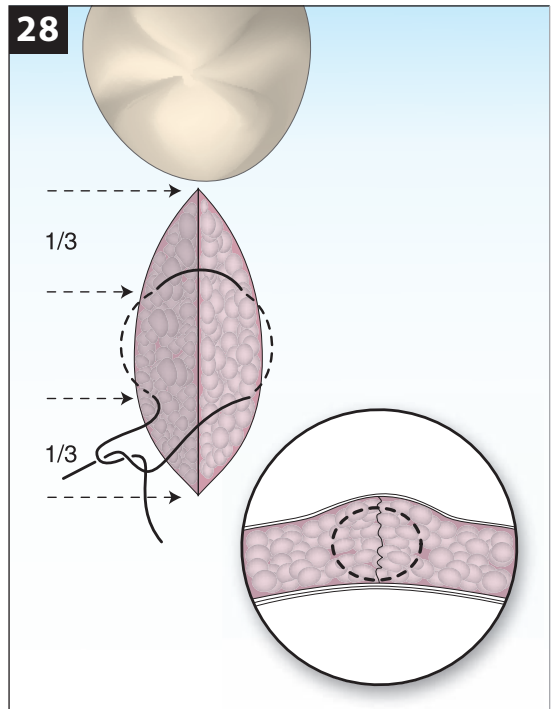
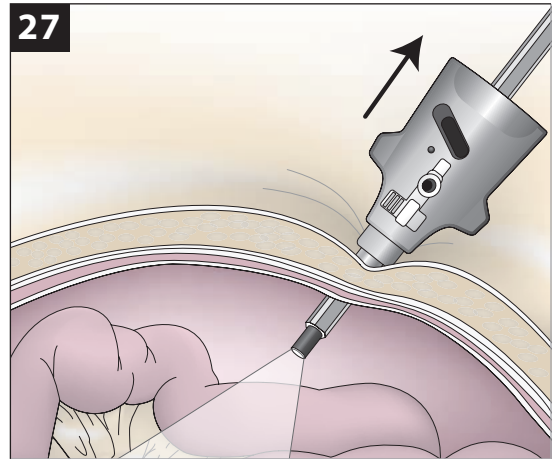
## **TERMINATION OF THE LAPAROSCOPIC PROCEDURE**

At the end of the laparoscopic procedure, all ancillary trocars should be withdrawn under direct laparoscopic vision to ensure hemostasis. The patient is placed in a flat position and the laparoscope removed. Prior to the removal of the trocar, the abdominal cavity should be inspected for absence of bleeding or retroperitoneal hematoma (Figure 27).

**ALWAYS INSPECT THE ABDOMINAL CAVITY FOR ABSENCE OF BLEEDING, HEMATOMA, OR BOWEL INJURY BEFORE WITHDRAWING THE LAPAROSCOPE.**

- CHECK FOR HEMOSTASIS BEFORE TERMINATING THE LAPAROSCOPIC PROCEDURE.
- WITHDRAW THE ANCILLARY TROCARS UNDER DIRECT LAPAROSCOPIC VISION TO CHECK FOR HEMOSTASIS.
- IF MORE ATTEMPTS WERE MADE BEFORE ESTABLISHING ADEQUATE PNEUMOPERITONEUM, OR IF UMBILICAL ADHESIONS ARE OBSERVED, WITHDRAW THE TROCAR SLOWLY BEFORE RELEASING THE PNEUMOPERITONEUM TO CHECK FOR POSSIBLE BOWEL INJURIES. IF NO ABNORMALITIES ARE OBSERVED REINSERT THE TROCAR SLEEVE, AND RELEASE THE PNEUMOPERITONEUM.
- CLOSE ALL FASCIAL INCISIONS OF 1 CM AND GREATER USING THE ABSORBABLE SUTURE.
- FOR 5 MM INCISIONS, ONLY SKIN CLOSURE IS PERFORMED.

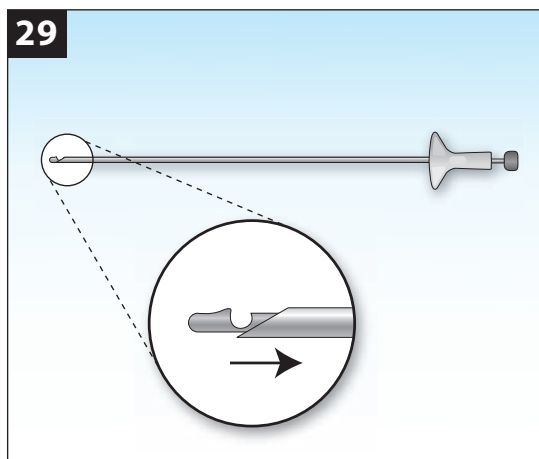
Abdominal gas should be relieved by gentle pressure on the lower abdomen with the trumpet valve open to allow gas escape. The trocar sheath is removed with the valve open to prevent room air from entering the abdominal cavity. If any difficulties were encountered during needle or trocar placement or if omental or bowel adhesions were seen during the laparoscopic procedure, the umbilical trocar should be withdrawn under laparoscopic guidance to make sure that no bowel adhesions were present in the umbilical area that might have been



injured during trocar placement. Each fascial incision greater than 5 mm should be closed to prevent hernia formation. For incision closure, a 3-0 absorbable suture is used to approximate deep fascia and skin (Figure 28). Several devices are available

on the market for closure of the fascia and peritoneum under direct vision such as the Endoclose (Tyco Healthcare, Norwalk, CN) (Figure 29). Usually after laparoscopic procedures, a certain amount of gas or irrigation fluid stays trapped in the peritoneal cavity. This gas may irritate the peritoneum and patients may feel discomfort and minor pain referred to the shoulder area up to 2 weeks after the procedure.

After laparoscopic surgery, proper written documentation should be recorded. The advantage of the laparoscopic procedure is that each surgery can be videotaped or color prints can be made using a video printer. This visual documentation may be used for future reference.



## SUGGESTED READING:

Mumford SD, Bhiwandiwalla PP, Chi IC. Laparoscopic and minilaparotomy female sterilization compared in 15,167 cases. *Lancet* 1980;ii(8203):1066-70

Hasson HM. Open laparoscopy: a report of 150 cases. *J Reprod Med* 1974;12:234-8

Morgan HR. Laparoscopy: introduction of pneumoperitoneum via transfundal puncture. *Obstet Gynecol* 1979;54:260-1

Wolfe WM, Pasic R. Transuterine insertion of Veress needle in laparoscopy. *Obstet Gynecol* 1990;75:456-7

Palmer R. Safety in laparoscopy. *J Reprod Med* 1974;13(1):1-5

Childers JM, Brzechffa PR, Surwit EA. Laparoscopy using the left upper quadrant as the primary trocar site. *Gynecol Oncol* 1993;50:221-5

Reich H, Levie M, McGlynn F, Sekel L. Establishment of pneumoperitoneum through the left ninth intercostal space. *Gynaecological Endoscopy* 1995;4:141-3

Dingfelder JR. Direct laparoscope trocar insertion without prior pneumoperitoneum. *J Reprod Med* 1978;21:45-7

Mlyncek M, Truska A, Garay J. Laparoscopy without use of the Veress needle: results in a series of 1600 procedures. *Mayo Clin Proc* 1994;69:1146-8

Vakili C, Knight R. A technique for needle insufflation in obese patients. *Surg Laparosc Endosc* 1993;3:489-91

Ballem RV, Rudomanski J. Techniques of pneumoperitoneum. *Surg Laparosc Endosc* 1993;3:42-3

Penfield AJ. How to prevent complications of open laparoscopy. *J Reprod Med* 1985;30:660-3

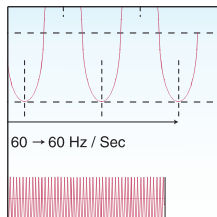
A consensus document concerning laparoscopic entry techniques. Middlesbrough, March 19-20 1999 *Gynecol Endoscopy* 1999;8: 403-6

Byron JW, Fujiyoshi CA, Miyazawa K. Evaluation of the direct trocar insertion technique at laparoscopy. *Obstet Gynecol* 1989;74:423-5

Poindexter AN, Ritter M, Fahim A, Humprey H. Trocar introduction performed during laparoscopy of the obese patient. *Surg Gynecol Obstet* 1987;165:57-9

Hurd WW, Bude RO, Delancey JO, Pearl ML. The relationship of the umbilicus to the aortic bifurcation; implications for laparoscopic technique. *Obstet Gynecol* 1992;80:48-51

# ENERGY SYSTEMS IN LAPAROSCOPY



**Andrew Brill, M.D.**

**E**lectricity is produced when valence electrons are freed from atoms of conductive materials. When these electrons are set in motion in the same direction an electric current ( $I$ ) is produced that is measured in amperes. Opposite charges on the ends of the conductor cause the electrons to flow in one direction toward the positive terminal. The difference in potential between the positive and negative poles provides the electromotive force (voltage) to drive the current through the conductor (Figure 1).

Current that flows in one direction through a circuit is called direct current (DC). When alternating current (AC) flows through a circuit, the movement of electrons reverses direction at regular intervals, which is expressed as cycles per second (Hertz). Since the effects of current on the load are all that is important, the periodic reversal of current flow does not undo its work.

The amount of current that flows through a circuit is determined by the electromotive force (voltage) across the circuit and the resistance that circuit provides to the current. Resistance ( $R$ ) is the difficulty that a material presents to the flow of electrons and is measured in Ohms.



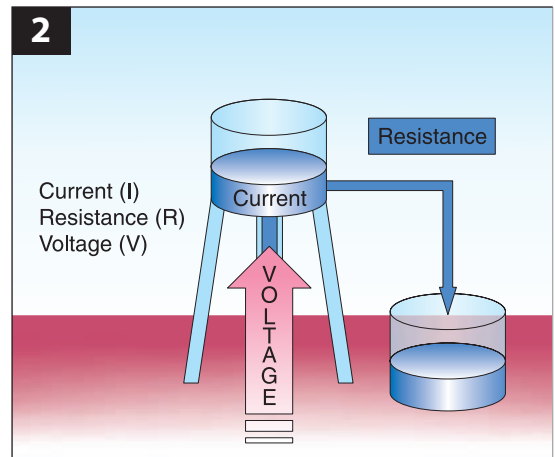
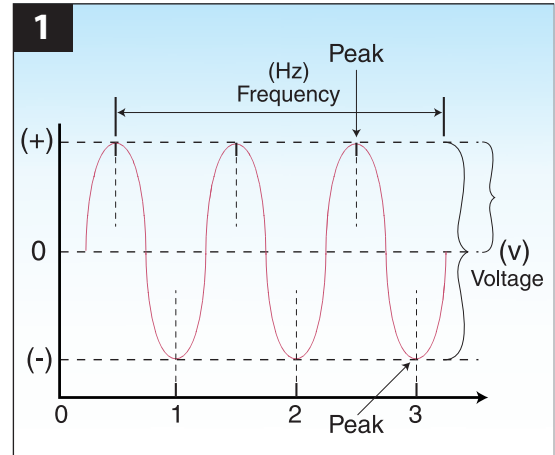
Resistance of biologic tissues varies depending upon the water content. It is very high in desiccated tissue, moderate in lipid-rich adipose tissue, and very low in vascular tissue. Resistance for alternating current is expressed as impedance due to the induction of additional resistive phenomena (inductance) that include the effects of imploding electrostatic fields and the oppositional electromotive force of out-of-phase magnetic fields.

Current is directly proportional to the voltage and inversely proportional to the resistance, as expressed by Ohm's law:

$$I = V / R$$

Therefore, greater resistance requires greater voltage and, with a fixed resistance, greater voltage creates greater current. When the switch of an electrical circuit is left open (i.e., when the resistance is infinite) as when keying an electro-surgical electrode without tissue contact, it is logical that the energy source will work at maximum voltage. This means that an electro-surgical generator produces the highest voltage across the electrode when it is activated remotely from the tissue surface without current flow. In order to better understand the basic principles of the electrical current, the analogy of the electric current to the water flow is presented in Figure 2.

Power is the rate of doing work and is expressed in watts (W). It represents the total quantity of electrons moved and the pressure gradient against which the movement occurred, as expressed by the equation.



$$W = I \times V$$

Inserting Ohm's Law:

$$W = I^2 \times R \text{ and } W = V^2 / R$$

Therefore, power to tissue increases as a function of both the square of the voltage and the square of the current.

The ratio of voltage to current is primarily responsible for the electro-surgical effects on tissue.

Other important factors are time (duration of current application) and power density. The power density repre-

↓ GREATER VOLTAGE



↓ GREATER FORCE



↓ GREATER RISK

sents the amount of energy applied per unit of surface and time, and can be represented in the following way.

Power output / Time

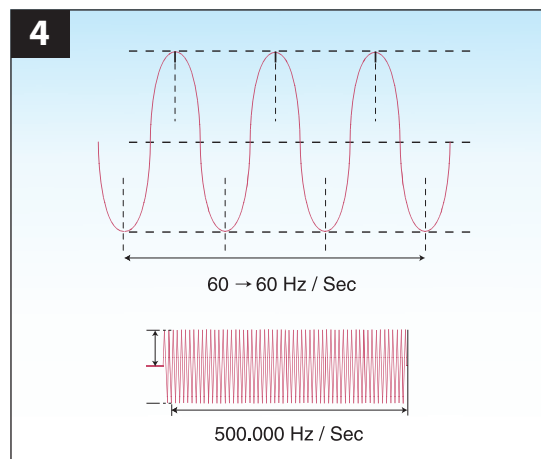
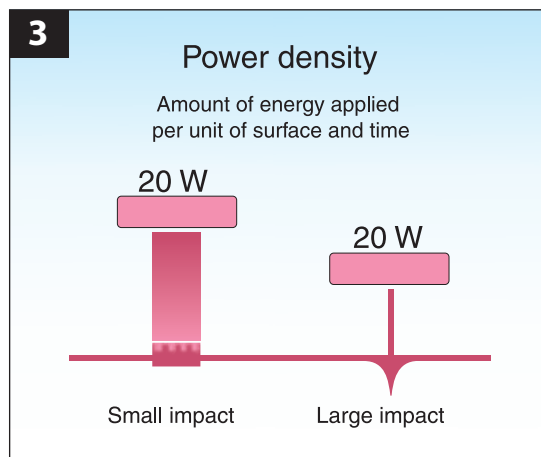
Power density =  $\frac{\text{Power output / Time}}{\text{Surface}}$

This equation shows that if time is kept constant, power density depends upon the wattage and surface of the active electrode. Change in power density can be achieved by changing the power output, or by changing the contact area. Indeed, to maximize power density we use higher energy output and a small contact electrode (Figure 3).

## PRINCIPLES OF ELECTROSURGERY

### CURRENT

Using current that reverses its direction periodically, electrosurgery is exclusively performed with high frequency alternating current. The frequency with which current changes direction is measured in cycles per second or Hertz (Hz). Since electrosurgery only relies on the effects of current on the load (tissue), this periodic reversal does not undue the tissue effects. Normal household current has a frequency of 60 Hz (cycles per sec-



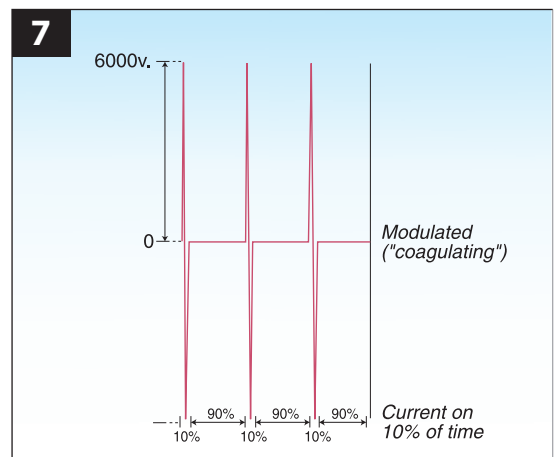
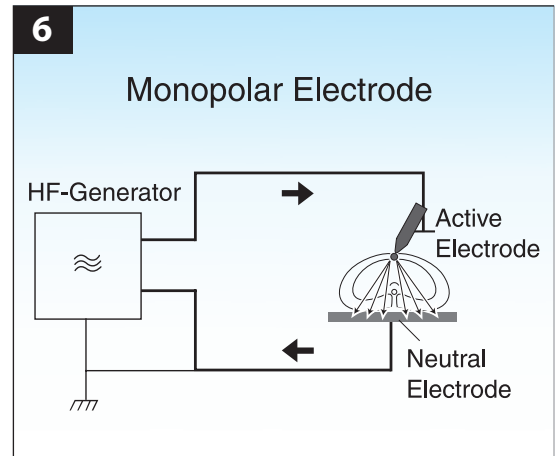
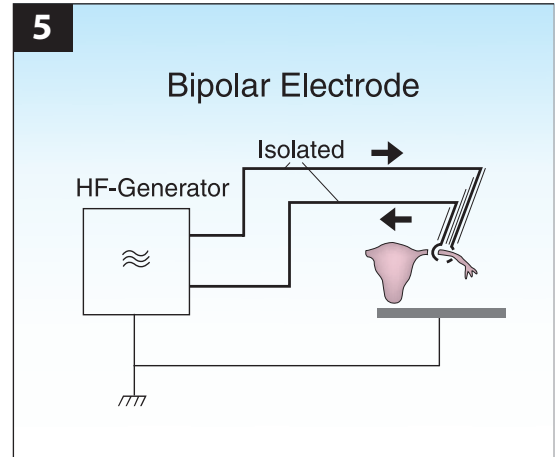
ond). Low frequency alternating current causes tetanic neuromuscular activity by rapidly reversing depolarization of neuromuscular tissue (faradic effects). These effects do not occur at frequencies greater than 100,000 cycles per second (Hz), where the net positional change of cellular ions is minimal. Justifiably then, electrosurgery is typically performed using alternating currents ranging between 500,000 Hz and 3 million Hz (Figure 4).

## BIPOLAR AND MONOPOLAR MODES

Bipolar electrosurgery utilizes two terminals of equal size that are extremely close by virtue of being situated across from one another at the end of an electrosurgical instrument. Rather than the patient being part of the electrical circuit, the current is only conducted by the tissue restricted between the distal electrodes (Figure 5). In monopolar electrosurgery, current is passed through the body by applying two differently shaped electrodes at distant locations of the body. Since the surgical electrode is much smaller than the return electrode, tissue effects are moderated by substantially different current densities (Figure 6).

## WAVEFORMS

Although most contemporary electrosurgical generators have front panel controls that are labeled 'cut', 'blend', and 'coag', these terms are not necessarily related to actual tissue effects. The variety of choices simply reflect different degrees of waveform modulation (damping) that can be incrementally produced by the generator's solid state circuitry. Modulation is the periodic interruption of current flow (Figure 7). The 'cut' mode of the generator produces an unmodulated (undamped) pure sine wave with a relatively low peak voltage. The 'coag' mode produces the most modulated waveform that correspondingly has the highest peak voltage. Therefore, for equal power



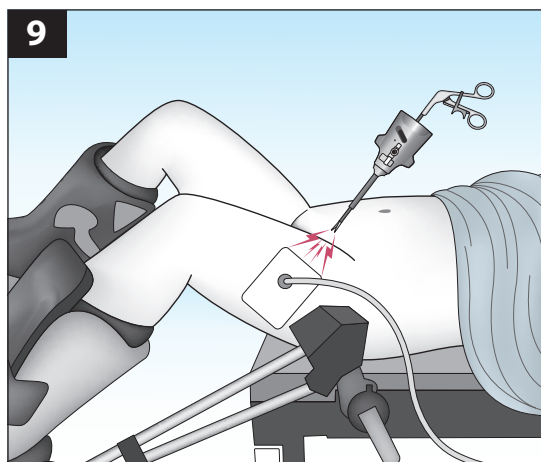
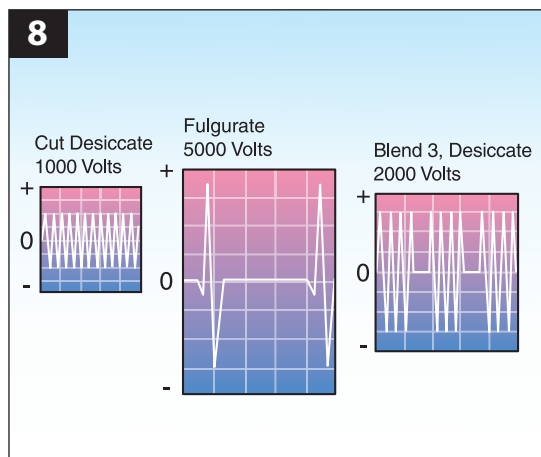
settings, increasing waveform modulation (i.e., switching from 'cut' to 'blend' to 'coag') causes the peak voltage to proportionally increase, i.e., energy must be conserved (Figure 8).

## GROUNDING

A fundamental understanding of grounding is necessary to practice monopolar electrosurgery with safety. A ground is any form of conductive connection between an electrical circuit and earth. Since the earth has an infinite capacity to absorb electrical charges, any electrically charged object connected to earth will equalize its potential difference with the earth.

### THE DISPERSIVE ELECTRODE PAD

Although the dispersive electrode pad provides a pathway of low impedance for returning current to the generator, its misapplication can result in catastrophic thermal insult that is usually undetected at the time of injury. The rules for proper usage seek to minimize impedance while providing the greatest surface area for current return. Impedance is primarily minimized by choosing a site with adequate water content for conduction. Areas of skin with hyperkeratosis or hair and those that overlie dense fat deposits (e.g., buttocks) should be avoided, while hair-free or shaved skin over larger muscles is preferred (e.g., upper thigh). Impedance is further reduced by choosing a site as close as possible to the active electrode (Figure 9). The surface



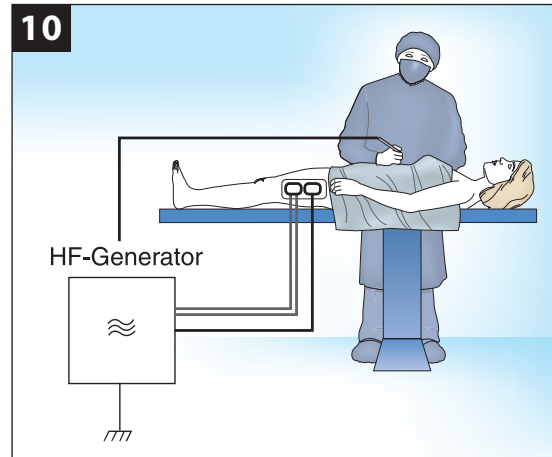
area of the return electrode must be large enough to permit the returning current to be widely dispersed. Tissue heating is intimately related to current density; current density is inversely related to the square of the surface area, and the rise in tissue temperature is directly proportional to the square of the current. Therefore, small decrements in the surface area between the dispersive pad and the skin can dramatically result in injurious thermal effects to the underlying tissues. A large surface area is guaranteed by a uni-

form and unalterable application. Areas with bony prominences are prone to movement on patient repositioning (such as the back and buttocks) and should be avoided. Since the edge of the dispersive electrode pad closest to the active electrode tends to concentrate the current, the longer edge of the pad should be placed toward the operative site.

### ELECTRODE MONITORING SYSTEMS

Contemporary electrosurgical generators are equipped with an automatic alarm and shutdown mechanism that activates when the connection between the generator and the return electrode is not intact. However, this does not monitor the adequacy of contact between the surface of the grounding pad and the patient. Since the impedance to the flow of current via the dispersive electrode is quite small until most of the pad has peeled away, any drop in electrosurgical effectiveness should alarm the surgeon to check the application of the dispersive electrode.

Valleylab (Boulder, CO) originally introduced a return electrode monitoring system (REM) that monitors the dispersive pad's connection to the generator and the degree of contact with the patient. The dispersive pad is split into two functional halves; a small current is generated to flow through the first half, through the contiguous skin and tissue, and then via the other half to return to the generator, which electronically monitors the local impedance. If the impedance is exceeded by separation from the



skin, then the circuit is opened and an alarm is sounded (Figure 10). This innovation in dispersive pad technology completely eliminates the risk of thermal damage from an unpeeled electrode.

### TISSUE EFFECTS OF ELECTROSURGERY

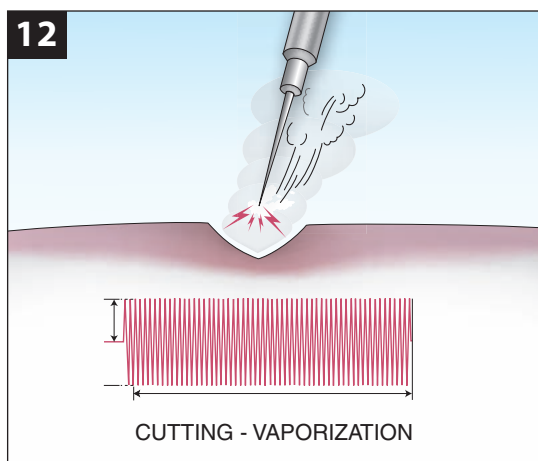
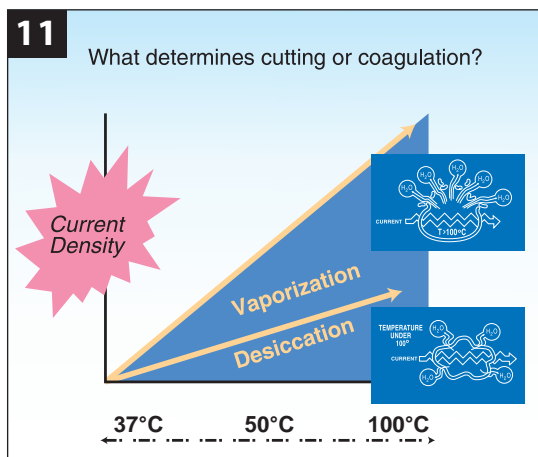
Owing to the impedance, electrical energy when applied to the tissue is transferred to thermal energy, and the tissue effect of this thermal energy directly depends on the temperature inside of the tissue and the time required to reach that temperature (Figure 11). Electrosurgical energy produces three distinct effects on tissue: cutting, fulguration, and desiccation.

By varying the rate and extent of the thermodynamic effects of electric current in biological tissue, high frequency electrosurgery is used to cut and/or coagulate. Although the efficiency of hemostasis is related to the depth of coagulation, it is of paramount importance that no

more tissue suffers thermal damage than is absolutely needed. The art of electro-surgery is balancing between the need for absolute hemostasis and the least amount of deep coagulative necrosis.

## CUTTING (ELECTROSECTION)

The cutting of tissue occurs when there is sufficient voltage (at least 200 V) between the electrode and the tissue to produce an electric arc, which concentrates the current to specific points along the tissue surface. The open circuit creates an electric field that ionizes the intervening air. An avalanche of colliding and accelerating charged ions forms a plasma cloud that gives off light and sound as the ions pass to lower energy states to produce an electric arc (Figure 12). The extremely high current density delivered by the arc rapidly superheats the cellular water to temperatures greater than 6000°C. Explosive cellular vaporization ensues secondary to the production of highly disruptive pressure (steam occupies 6 times the volume of liquid water!) and acoustic forces. Arcing is then enhanced by an envelope of steam vapor that becomes instantly ionized. The use of the unmodulated 'cut' waveform helps sustain this envelope by producing an uninterrupted current that continuously maintains the same pathways for arc formation. However, since the 'cut', 'blend' and 'coag' outputs all provide peak voltages greater than 200 V, any generator setting can be utilized to perform electrosection. In any case, tissue contact eliminates the steam envelope and abolishes the cutting arc.



In general, the depth of coagulation along the cut edges increases with increasing voltage and length or intensity of the electric arcs. Therefore, an unmodulated 'cut' waveform produces a cut with the least amount of coagulative necrosis, whereas waveforms with greater modulation and higher peak voltages (i.e., higher 'blend' and the 'coag' settings) result in substantially larger zones of coagulation (Figure 13).

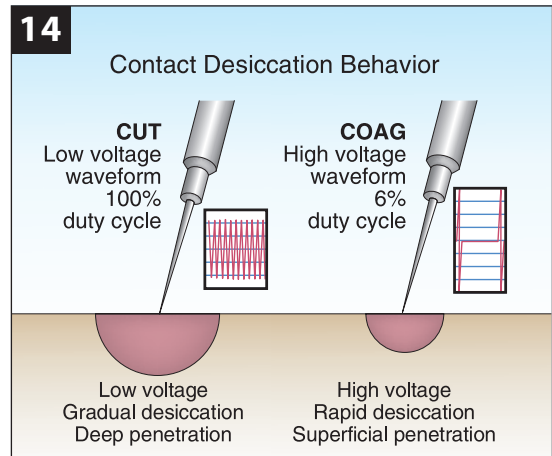
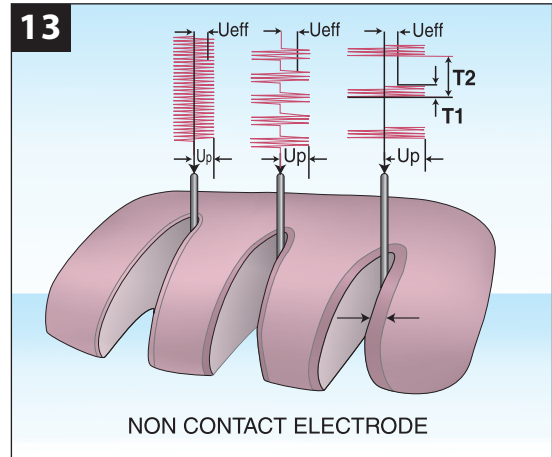
When using conventional electro-surgical generators, the smallest volume of

coagulation during electrosection is assured by employing the thinnest possible electrodes (i.e., edge rather than surface), using the unmodulated ‘cut’ waveform with low peak voltage, and cutting as rapidly as possible using a single pass of the electrode. Deeper coagulation occurs when opposite parameters are applied. A higher ‘blend’ (i.e., blend 2 or 3) or the ‘coag’ waveform may be selectively employed during the electrosection of highly vascular tissues (e.g., leiomyoma) to provide a significant measure of hemostasis along the cut margins.

A new breed of electrosurgical generators incorporate automatic control circuits to ensure that the intensity of the electric arcs and the output voltage are kept constant (constant voltage generator). This makes the depth of coagulation relatively independent of the cutting rate and depth, as well as the magnitude of the output current. Thus, the distance of coagulation remains constant regardless of the magnitude of the output current. With this type of equipment, the operator can move the electrode as quickly or slowly as desired and at any angle without significantly affecting the depth of coagulation.

**DESICCATION AND COAGULATION**

Contact of tissue with the surface of an active electrode leads to conduction of current with a low current density (Figure 14). Resistive heating is produced by the high frequency agitation of intracellular ionic polarities. As the tissue is slowly heated to temperatures above



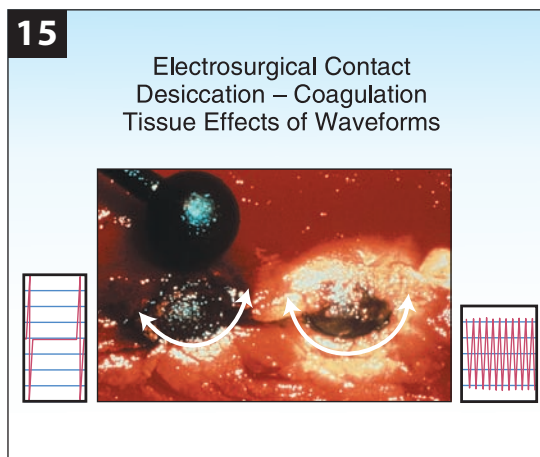
50°C and maintained, irreversible cellular damage is initiated by deconfiguration of regulatory proteins followed by the denaturation of cellular proteins (white coagulation). Further heating to 100°C leads to complete evaporation of cellular water (desiccation), hemostasis secondary to the contraction of blood vessels and the surrounding tissues, and conversion of collagens to glucose that has an adhesive effect between the tissue and electrode. Temperatures above 200°C cause carbonization and charring. The

prudent application of monopolar electrosurgery to tissue is continuously moderated by monitoring for the terminal evanescence of steam formation and tissue whitening; tissue charring and smoke are indicative of overzealous coagulation.

Until the tissue reaches a temperature of 100°C and is completely desiccated, the rise in tissue temperature is directly proportional to the tissue resistance (degree of desiccation), time of current flow, and the square of the current density. Therefore, temperature change is more rapid at superficial depths, and evolves more gradually with larger surface electrodes.

As the tissue is progressively desiccated, current flow is moderated by a zone of electrically insulated steam vapor that forms between the electrode and tissue. The flow of current will eventually cease based on the output voltage. At lower voltages using the unmodulated 'cut' waveform, the coagulative process continues until the tissue is entirely dried out (soft coagulation). Continued application of current after completion of the evaporative phase leads to tissue adherence. Therefore, soft coagulation should ideally be terminated at the time of vapor formation.

At higher voltages when using modulated waveforms (especially with smaller electrodes and higher current densities), the vapor layer and desiccated tissue are punctured by electric arcs (forced coagulation) causing further coagulation until the coagulum is so thick it cannot be penetrated. Tissue becomes carbonized, sticky, and precariously unstable. This



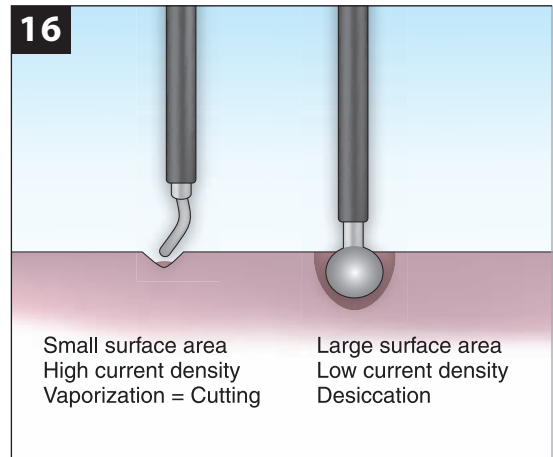
results in deeper coagulation at the expense of greater force, intense arcing, and increased temperature generation (Figure 15).

During soft coagulation, the lower voltage of the 'cut' waveform heats the tissue more slowly so heat can flow into deeper tissue layers. Hence, it can be said that soft coagulation is more effective coagulation. Since the reduction of abnormal uterine bleeding after endometrial ablation is related to the degree of destruction of the basalis layer and superficial myometrium, it can be formally argued that the unmodulated 'cut' waveform should be used during hysteroscopic electrocoagulation of the endometrium.

In consideration of all the physical parameters that govern the behavior and effects of high frequency alternating electric current in biological tissue, laparoscopic monopolar electrosurgery should ideally be performed using the unmodulated 'cut' waveform for cutting and deep coagulation of tissue. Any electrode con-



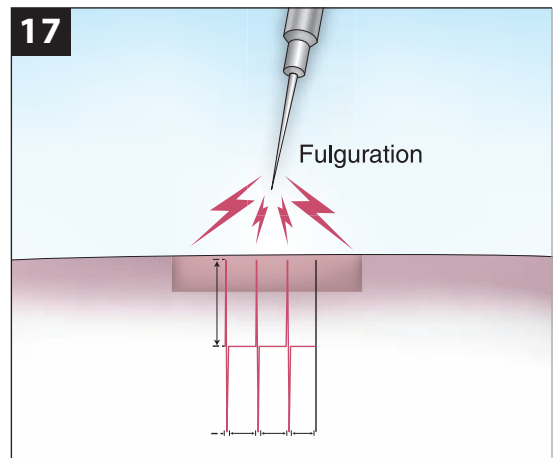
figured with both a flat surface and an edge (e.g., spatula electrode, electro-surgical scissors) can be used as an all-purpose electro-surgical tool with this waveform. The concentration of current at the edge or tip of the electrode provides arcing and hemostatic cutting of tissue. Blunt dissection, tissue traction, coaptation of small blood vessels, and contact coagulation can all be effectively accomplished using the flat surface (Figure 16).



## FULGURATION

Electric arcs generated by modulated waveforms with higher peak voltages (fulguration) can superficially coagulate a broad surface of tissue with open vessels as large as 2 mm (Figure 17). Current modulation allows the steam envelope to dissipate between the interruption of sparks, causing the electric arcs to strike the tissue surface in a widely dispersed and random fashion, thereby preventing tissue cutting. Although the higher voltage sparks are larger and create broad areas of charring (to  $> 500^{\circ}\text{C}$ ) and tissue destruction, current flow is limited to the superficial tissue layers due to rapid desiccation and the build-up of tissue resistance. Fulguration is relatively useless in the presence of a wet surgical field due to the diffusion of current by saline rich blood.

Teleologically then, the only selective indication for using the highly modulated 'coag' waveform during monopolar electro-surgery, is for the superficial coagulation of tissue along a large surface area. Exemplary needs for fulguration during



laparoscopic surgery include the myometrial bed after myomectomy, the base of the ovarian cortex after cystectomy, and for oozing veins enwrapping Cooper's ligament during colposuspension. Since thermal effects are kept quite superficial by the rapid surface desiccation, fulgurative current is the best choice to superficially electrocoagulate areas of endometriosis over vital structures such as the bladder and ureter.

The Argon Beam Coagulator (ABC) is a true fulgurating electro-surgical device

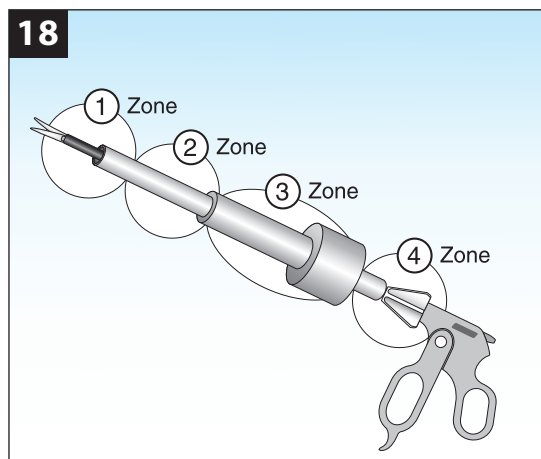
that utilizes the flow of argon gas through an electrode device to form a comparatively longer bridge of electric arcs to the tissue. This gas is easier to ionize than air allowing the electric arcs to create a more uniform surface coagulation effect. The high flow of gas (4 L/min) displaces oxygen and nitrogen as well as pooled blood, which focuses the effective surface area, and reduces the formation of smoke, carbonization, and tissue build-up on the tip of the electrode.

## PROBLEMS OF MONOPOLAR ELECTROSURGERY DURING LAPAROSCOPIC SURGERY

Contrary to the open surgical environment during laparotomy, the bulk of most instruments and nearly all surrounding intraabdominal structures are not visualized during any laparoscopic procedure. Furthermore, nearly all of the potential conductors during laparoscopic electrosurgery are also out of the surgeon's field of view. Intended and unintended couriers of direct or induced currents include the abdominal wall, metallic trocar sheaths and instruments, the operating laparoscope, contiguous visceral tissues, and the active electrode (which is the only part of the circuit under view!) (Figure 18). It comes as no surprise that most accidental electrosurgical burns during laparoscopic surgery are undetected at the time of injury.

### INSULATION FAILURE

Insulation failure occurs secondary to breaks or holes in the insulation caused



by physical abrasion during use (such as during passage through an incompletely engaged trumpet cannula) or during normal reprocessing procedures. Completely intact insulation (especially on disposable instrumentation) can be breached by very high voltage (e.g., during open circuit activation or using a modulated 'coag' waveform). Any break or breach in insulation may provide an alternate pathway for the flow of current. If the defective portion of insulation contacts tissue during electrode activation, an electric arc will bridge directly from the electrode through the defect to this tissue (Figures 19 and 20). Thermal damage will occur if the current density is high enough to significantly heat the tissue. Since these defects are usually out of the field of view, this type of injury usually occurs undetected at the time of insult.

Insulation failure can be minimized by periodically inspecting the insulation covering of all laparoscopic electrodes (especially at the shoulder) for small

cracks and defects. Disposable monopolar electrodes should not be reused. The risk of high voltage can be eliminated by using the unmodulated 'cut' waveform, and avoiding open circuit activation.

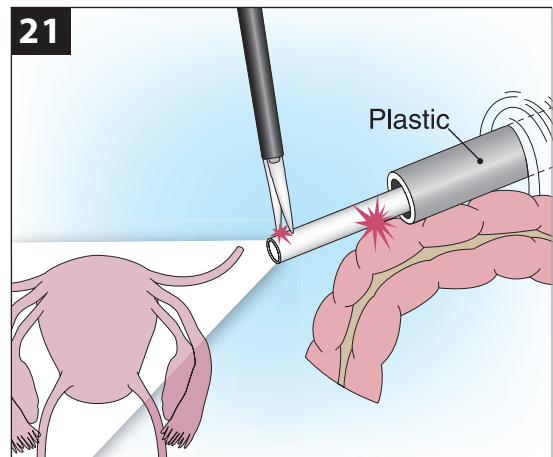
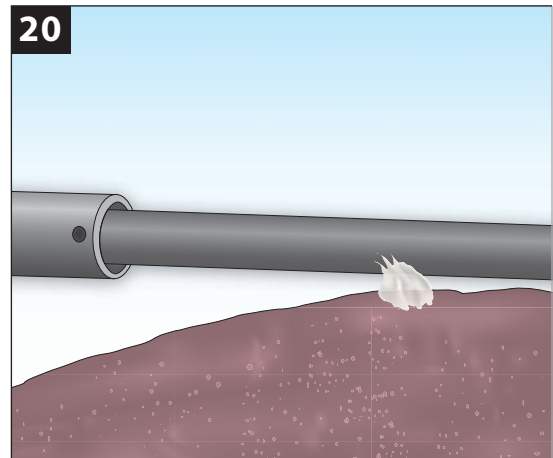
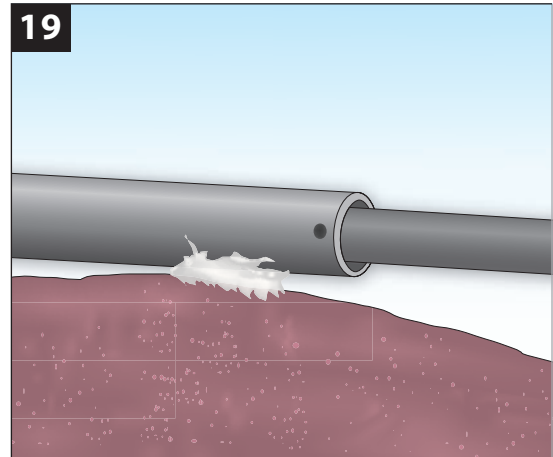
### DIRECT COUPLING

Direct coupling of current occurs when an activated electrode makes unintended contact with another metal object in the area of the surgical field. Accidental electrode contact with a suction-irrigator probe, the operating laparoscope, or a metal cannula creates an alternate pathway that is normally conducted up through a metal trocar to the abdominal wall and back to the dispersive electrode. However, if any of these devices are isolated from direct contact with the abdominal wall by an insulator (e.g., plastic cannula or self-retaining device) the current may take an alternate pathway through a point of contact with adjacent tissue (Figure 21). Again, if the current density is high, thermal damage may occur.

Direct coupling can be avoided by never activating the generator when the electrode is touching or in near proximity to another metal object in the surgical field.

### CAPACITIVE COUPLING

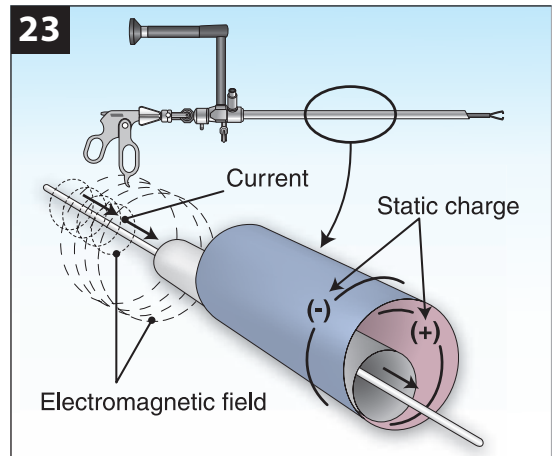
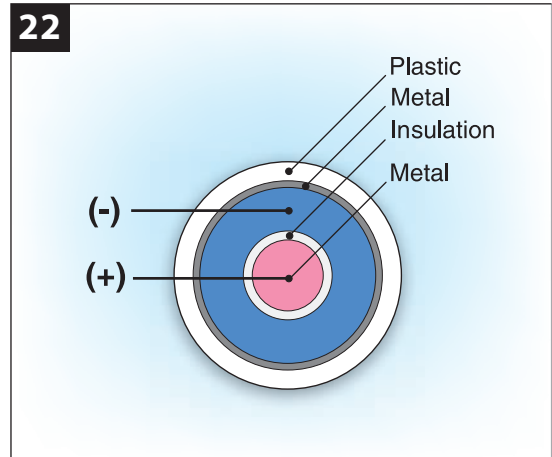
Capacitance is the property of an electrical circuit to store energy. Any device that creates capacitance is called a capacitor. A capacitor exists whenever two conductors that have different potentials are separated by an insulator. A differ-



ence of potential or voltage will exist between two conductors that have differing numbers of free electrons (an overall negative charge on the conductor with excess, and a positive charge on the electron-deficient conductor). Although separation by an insulator prevents the flow of electrons between these conductors, the potential difference nevertheless creates an attraction or electrostatic force between them. This force results in an electric field and creates a reservoir of stored energy. When an alternating current flows through a circuit, the applied voltage and flow of current periodically changes direction. This means that a capacitor with alternating current is continuously 'charged' in alternating directions. With each reversal of current flow, the energy of the stored electric field is discharged. Although no actual current flows through the capacitor, the charged current from capacitance completes the circuit and in essence conducts the alternating current. Since the amount of capacitance is directly proportional to the voltage, capacitance is greatest during open circuit activation and with highly modulated current such as the 'coag' waveform.

Capacitive coupling is the induction of stray current to a surrounding conductor through the intact insulation of an active electrode. In fact, all of the necessary ingredients for the localized genesis of capacitance are provided by an activated monopolar electrode that is passed through a conductive sheath.

Two conductors of differing potentials, the active electrode and the metal

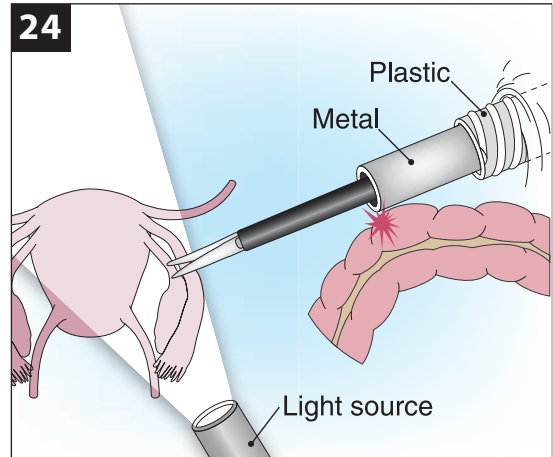


sheath (e.g., trocar sheath, working channel of an operating laparoscope, irrigator-aspirator probe) are separated by the insulation of the electrode (Figures 22 and 23). On activation, up to 80% of the generator current is induced on the metal sheath by capacitance. Normally this stray current is safely returned to the dispersive electrode by conduction through the large area of contact between the metal trocar sheath and the abdominal wall. The magnitude of capacitance is greater with higher voltage, smaller can-

nulas, and longer electrodes. Furthermore, the induced current will persist until the electrode is deactivated or it is conducted via an alternate pathway.

If the metal trocar sheath is attached to the abdominal wall by a nonconductive plastic device [e.g., hybrid trocar (metal/plastic) or plastic self-retaining screw device] the induced current becomes electrically isolated from the abdominal wall. Contact between the cannula and a visceral structure provides an alternate pathway for the stray current to discharge (Figure 24). Significant thermal damage will occur if the current density is sufficiently concentrated by a small area of contact. A similar phenomenon of capacitive coupling and isolation of current may occur during activation of an electrode placed through the working port of an operating laparoscope that is isolated from the abdominal wall by an all plastic cannula. In either case, the thermal injury is usually out of the surgeon's field of view.

Capacitance is minimized by using an unmodulated 'cut' waveform and avoiding open circuit activation (i.e., minimizing voltage). An all-metal system will suffice for the safe conduction of capacitively coupled current back to the dispersive electrode. Hybrid cannula systems (mixtures of plastic and metal) should not be used to house monopolar electro-surgical devices.



## BIPOLAR ELECTROSURGERY

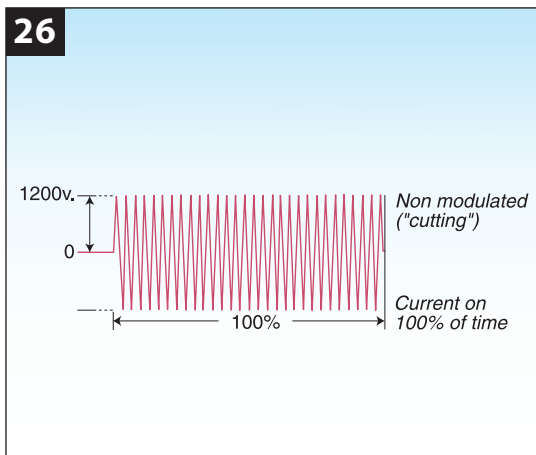
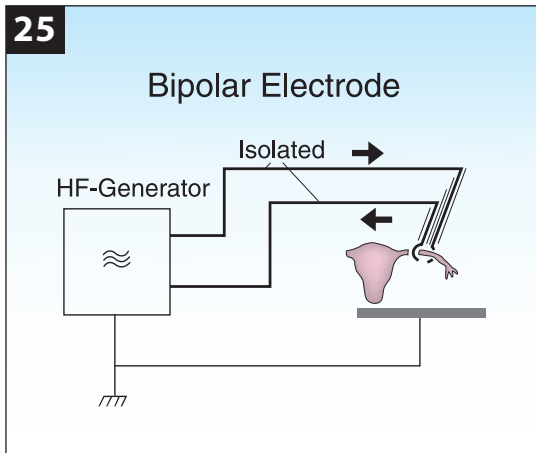
During monopolar electrosurgery, a high density of electrons leave the active electrode and are ultimately dispersed over the broad surface of a return electrode pad. The current returns to the generator after the electrons pass through the patient via a myriad of variably conductive pathways.

Bipolar technology consolidates an active electrode and a return electrode into an electrosurgical instrument with two small poles (e.g., tines of forceps or blades of scissors) (Figure 25). Rather than coursing through the patient, the flow of alternating current is symmetrically distributed through the tissue between the poles, reversing direction every 1/2 cycle. This eliminates the risk of capacitive coupling and alternate current pathways. Power requirements are significantly less than with monopolar surgery due to the current concentration between the poles. Therefore, an unmodulated 'cut' waveform with low peak-to-

### BIPOLAR ELECTROSURGERY STRATEGIES TO LIMIT THERMAL INJURY

- TERMINATE CURRENT AT END OF VAPOR PHASE
- APPLY CURRENT IN PULSATILE FASHION
- LIBERALLY USE RELAXING INCISIONS
- AVOID USE OF AN IN-LINE AMMETER
- USE TOUCH TECHNIQUE WHENEVER POSSIBLE

peak voltage is the generator output during bipolar electro-surgery (Figure 26). These factors typically limit the thermal effects to desiccation and coagulation of tissue. Laparoscopic scissors and shears depicted as bipolar cutting devices are usually mechanical cutting devices that simultaneously desiccate at the edge of the cutting electrodes. Using advanced solid state technology, true bipolar electro-surgical cutting can be accomplished using two more recently introduced bipolar cutting electrodes paired to a dedicated low-voltage electro-surgical generator. The 5 mm PKS Cutting Forceps (Gyrus-ACMI, Maple Grove, MN) consists of a retractable active needle electrode paired with a return electrode collar near the distal tip. Tissue cutting is generated when both electrodes are placed in contact with tissue and then drawn across the tissue surface during activation. More recently, Gyrus-ACMI

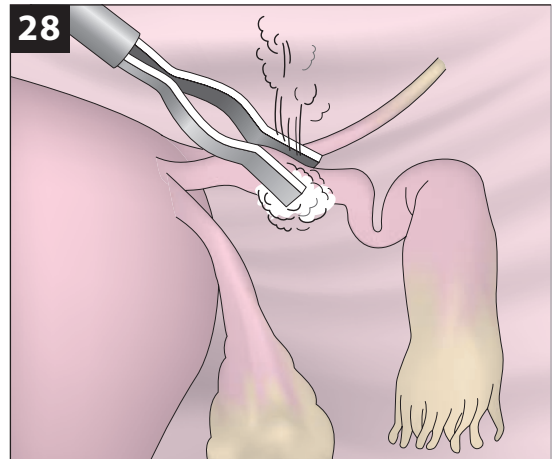



introduced a PlasmaSpatula™ 5 mm cutting-coagulation spatula electrode consisting of multiple conductive surfaces covering the distal electrode which can be manipulated and keyed to either cut or coagulate tissue (Figure 27). Since the PK electro-surgical generator produces a low voltage output, the high impedance posed by very desiccated or fatty tissues may preclude vaporization by either of these novel bipolar electrodes.

Bipolar electrocautery is used for laparoscopic tubal sterilization by sequentially grasping and desiccating the midportion of the Fallopian tube and adjacent mesosalpinx with the Kleppinger forceps. Failure of this method usually results from incomplete destruction of the tubal lumen with persistent viability of the endosalpinx. Complete desiccation is best ensured by including the vascular portion of the tube in the forceps, coagulating at least 3 cm of contiguous areas along the ampullary portion of the tube, using relatively low power (25 W) and an inline ammeter to ensure that the tissue is completely desiccated (Figure 28).

The localization of current between the poles of the instrument during bipolar electrocautery offers several distinct advantages. Thermal damage is generally limited to a discrete volume of tissue. The PKS cutting forceps can be used to coapt and thermally weld blood vessels. The concentrated current and small distance between the poles makes it possible to desiccate tissue that is immersed in fluid. The apparent disadvantages of this modality arise when open blood vessels are retracted or tissue pedicles are very thick.

Although the flow of current and primary thermal effects are restricted to the tissue between the poles, this does not remove the risk of thermal effects to tissue that is distant from the operative site. In fact, the net thermal effects are also governed by the physical parameters described during monopolar electrocautery. The application of bipolar cur-



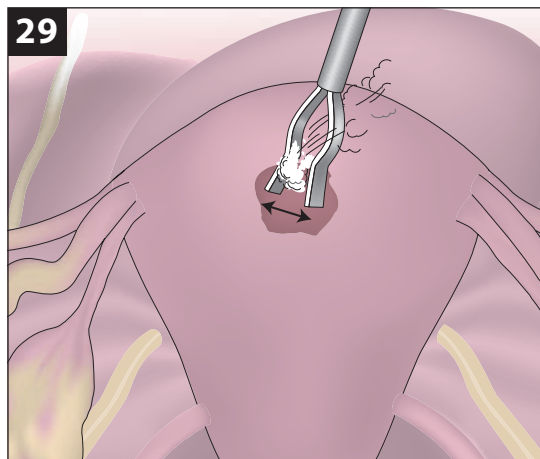
rent leads to the gradual desiccation of the intervening tissue. The rate of tissue coagulation at any given power is moderated by the applied surface area of the poles, the thickness of the pedicle, the formation of a vapor layer between the poles and tissue, and the evanescent degree of tissue hydration. Impedance is maximal when the vapor phase is abolished as the tissue is completely desiccated. If the current is further applied and maintained more than several seconds, a secondary thermal bloom occurs to sur-

rounding tissues from a correspondingly rapid rise in tissue temperature. Thus, tissues at some distance from the operative site may undergo subtle but irreversible thermal damage (e.g., the pelvic ureter during overzealous bipolar desiccation of the uterine artery).

During laparoscopic surgery, other than tubal sterilization, the spread of thermal damage during bipolar desiccation should be minimized by terminating the flow of current at the end of the vapor phase, cooling the surrounding tissues with irrigating solution, applying current in a pulsatile rather than continuous fashion, avoiding the use of an inline ammeter to determine the endpoint of desiccation, and securing vascular pedicles by using a stepwise process that alternates between partial desiccation and incremental cutting. The smallest depth of coagulative necrosis will occur when the sides or tips of a slightly open forceps are used to lightly ‘paint’ the tissue surface for directed hemostasis (Figure 29).

### TAKING THE JUDGEMENT OUT OF BIPOLAR ELECTRODESICCATION

Rather than using the judgement of the surgeon to assess the thermal endpoint during bipolar desiccation, newer bipolar devices can now think for you. The latest advance in bipolar electro-surgery is the introduction of three novel ligating-cutting devices that minimize electromagnetic force by delivering electrical energy as high current and low voltage output. Once tonal feedback



from a dedicated generator confirms complete desiccation of the tissue bundle, the pedicle is cut by advancing a centrally set mechanical blade. By directly responding to incremental increases in tissue resistance during coaptive desiccation, total energy delivery with these devices is dramatically less than conventional bipolar systems (300 V versus 1200 V!). Comparatively then, carbonization, tissue sticking, smoke, incomplete desiccation, and lateral thermal damage are all significantly reduced with these new devices. All produce sufficient energy and vascular coaptation to reliably seal both ovarian and uterine arteries.

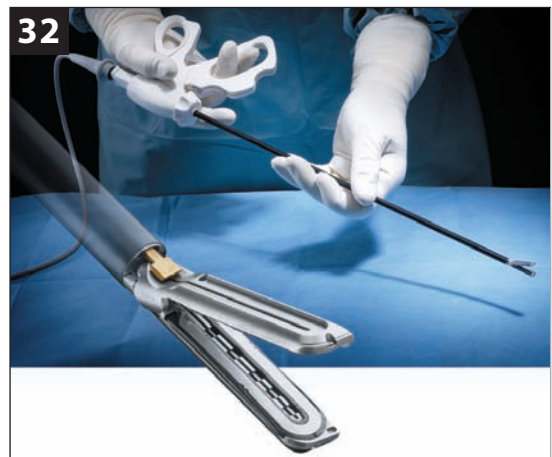
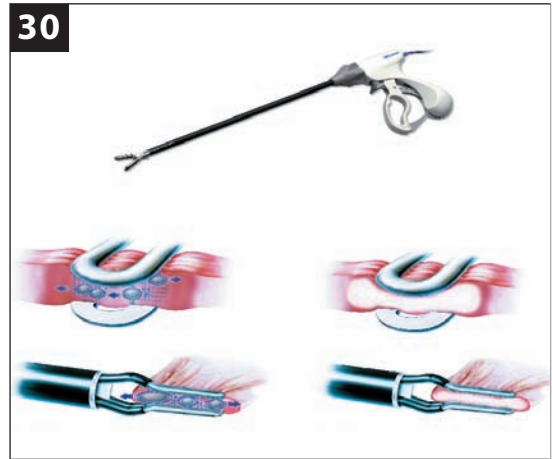
Relying on the breakthrough that vessel wall fusion can be achieved using electrical energy to denature collagen and elastin in vessel walls to reform into a permanent seal, the 5 mm and 10 mm LigaSure™ Laparoscopic Vessel Sealing Device (Valleylab, Boulder, CO) applies a high coaptive pressure to the coapted tissue bundle during the generation of tissue temperatures under 100°C; hydrogen



cross-links are first ruptured and then denatured resulting in a vascular seal that has high tensile strength (Figure 30).

The second device, the 5 mm and 10 mm PK Cutting Forceps (Gyrus-ACMI, Maple Grove, MN) utilizes advanced solid state generator software to deliver pulsed energy with continuous feedback control. The cycle stops once it senses that tissue response is complete; the cool down phase ensures collagen and elastin matrix reforms without tissue fragmentation. Electrical energy delivery in this fashion results in more uniform tissue heating and in less average and total energy delivery when compared to conventional bipolar systems (Figure 31).

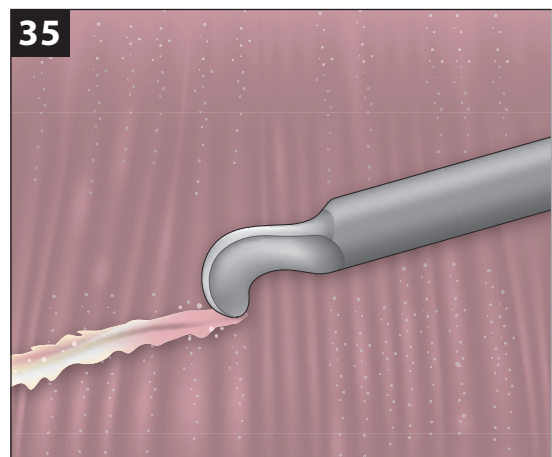

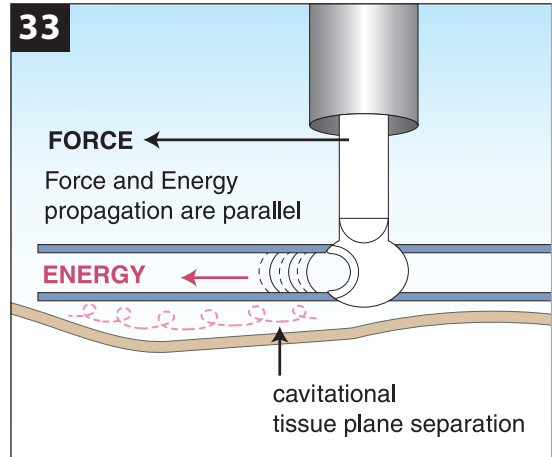
A third device, the 5 mm EnSeal™ Laparoscopic Vessel Fusion System (SurgRx, Inc., Palo Alto, CA) is an innovative bipolar instrument that for all practical purposes displaces the command of the electrosurgical generator into the distal jaw materials of the instrument. This “smart electrode” contains a set of plastic jaws embedded with nanometer-sized spheres of nickel that conduct a locally regulated current. Tissue temperatures never exceed 120°C due to the progressive generation of resistance in the plastic jaws. With this device, desiccation is facilitated by simultaneously advancing a mechanical blade that both cuts and squeezes the tissue bundle to eliminate tissue water. Reducing tissue water during heating at the coaptive interface further addresses lateral thermal spread by reducing the production of percussive steam during tissue desiccation and vaporization (Figure 32).



## HARMONIC SCALPEL

The harmonic scalpel is an ultrasonically activated laparoscopic device that provides mechanical energy to cut and coagulate tissue. A piezoelectric crystal housed in the handpiece vibrates the tip of a titanium blade at 55,500 times/second over a variable excursion of 50-100  $\mu\text{m}$ . Energy is transmitted through tissue primarily in a linear fashion, parallel to lines of force (Figure 33). Hydrogen bonds that maintain the configuration of tissue proteins are ruptured, gradually leading to a denatured protein coagulum up to 2 mm without significant desiccation or charring. Mechanical vibration and cavitation fragmentation of tissue parenchyma produce tissue cutting. Steam bubbles that form as the vaporization threshold is reduced by local changes in atmospheric pressure concurrently separate tissue planes in front of the tip.

Available 5 mm blades include a hook and curved electrodes for cutting and coagulating (Figures 34 and 35). The LCS-B5 is a 5 mm harmonic scalpel shear with a straight cylindrical active blade. Its shape is continuous circumferentially. The ACE™ (Ethicon, Endosurgery, Inc., Cincinnati, OH) is a 5 mm harmonic scalpel shear with a curved active blade. The curved blade has an increased amplitude compared to the straight blade, giving it an increased longitudinal motion, leading to increased cutting speed. The new ACE™ harmonic scalpel provides better hemostasis and cutting.



A 10 mm laparoscopic coagulating shears (LCS) provides coaptive coagulation and cutting by securing tissue between a grooved plastic pad and a 15 mm multipurpose rotational blade with sharp, blunt, and flat surfaces. By employing various combinations of blade configurations, blade excursion, and tissue tension, specific tissue effects are created with this device. Operationally, cutting should be considered the obverse of coagulation. Cutting velocity is proportional to blade excursion, tissue traction, and blade sharpness, and inversely related to density and elasticity of tissue. Coagulation is inversely related to tissue tension, blade sharpness, blade excursion, and cutting speed. Thus, the fastest cutting occurs when tissue is placed on tension and firmly squeezed, lifted, or rotated with the sharp side of the blade set at maximum excursion. Effective coagulation is best accomplished by

#### **AVOIDING A PREMATURE INCISION HARMONIC SCALPEL**

- UTILIZE LOWEST EXCURSION (1 OR 2)
- APPLY LARGEST SURFACE AREA
- AVOID ROTATION
- AVOID LIFTING
- AVOID SQUEEZING
- AVOID PRESSURE
- OBSERVE EVOLUTION OF TISSUE CHANGES

relaxing tissue tension, minimizing blade excursion, and using a blunt edge or flattened surface. Although a zone of coagulation of less than 1 mm is typically created by coaptive incision with the LCS, it remains proportional to blade excursion, application time, and applied pressure.

## SUGGESTED READING:

Ewing J. A Treatise on Tumors. 2nd ed. Philadelphia: WB Saunders, 1922:17

D'Arsonval MA. Action physiologique des courants alternatifs. Soc Biol 1891;43:283-286

Luciano A, Soderstrom R, Martin D. Essential principles of electrosurgery in operative laparoscopy. J Am Assoc Gynecol Laparosc 1994;1:189-195

Friedman J. The technical aspects of electrosurgery. Oral Surg 1973;36:177-187

Tucker RD, Benda JA, Sievert CE, et al. The effect of bipolar electrosurgical coagulation waveform on a rat uterine model of fallopian tube sterilization. J Gynecol Surg 1992;8:235-241

Erbe Elektromedizin. Operating Instructions Manual. Erbotom ACC 450. Tubingen, Germany, 1990

Honig WM. The mechanism of cutting in electrosurgery. IEEE Trans Biomed Eng BME 1975;22:58-55

Sigel B, Dunn MR. The mechanism of bleed vessel closure by high frequency electrocoagulation. Surg Gynecol Obstet 1965;121:823-831

Nduka C, Super P, Monson J, et al. Cause and prevention of electrosurgical injuries in laparoscopy. J Am Coll Surg 1994;179:161

Wattiez A, Khandwala S, Bruhat MA. Electrosurgery. In: Operative Endoscopy. Oxford, Blackwell Science, 1995:81-92

Kelly HA, Ward GE. Electrosurgery. Philadelphia, WB Saunders, 1932

Vaincaillie TG. Electrosurgery at laparoscopy: Guidelines to avoid complication. Gynaecol Endosc 1994;3:143-150

Phipps JH. Thermometry studies with bipolar diathermy during hysterectomy. Gynaecol Laparosc 1994;3:5-7

Ryder RM, Hulka JF. Bladder and bowel injury after electrodesiccation with Kleppinger bipolar forceps: A clinicopathologic study. J Reprod Med 1993;3:595-598

Nezhat C, Crowgey Sr, Garrison CP. Surgical treatment of endometriosis via laser laparoscopy. Fertil Steril 1986;45:778-783

Reich J, MacGregor T III, Vancaillie T. CO<sub>2</sub> laser used through the operating channel of laser laparoscopes: In vitro study of power and power density losses. Obstet Gynecol 1991;77:40-47

Corson SL, Unger M, Kwa D, et al. Laparoscopic laser treatment of endometriosis with the Nd: YAG sapphire probe. *Am J Obstet Gynecol* 1989;160:718-723

Semm K. Endocoagulation: A new field of endoscopic surgery. *J Reprod Med* 1976;16:195-203

McCarus SD. Physiologic mechanism of the ultrasonically activated scalpel. *J Am Assoc Gynecol Laparosc* 1996;3:601-608

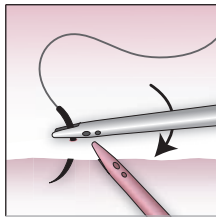
Hambley R, Hebda PA, Abell E. Wound healing of skin incisions produced by ultrasonically vibrating knife, scalpel, electrosurgery, and carbon dioxide laser. *J Dermatol Surg Oncol* 1988;14:1213-1217

Amaral JF, Chrostek C. Depth of thermal injury: Ultrasonically activated scalpel vs electrosurgery. *Surg Endosc* 1995;9:226

Luciano M, Whitman G, Maier DB, et al. A comparison of thermal injury, healing patterns, and postoperative adhesion formation following CO<sub>2</sub> laser and electromicrosurgery. *Fertil Steril* 1987;48:1025-1029

Tulandi T, Chan KL, Arseneau J. Histopathological and adhesion formation after incision using ultrasonic vibrating scalpel and regular scalpel in the rat. *Fertil Steril* 1994;61:548-560

# ALL YOU NEED TO KNOW ABOUT LAPAROSCOPIC SUTURING



*Resad Pasic, M.D., Ph.D.*

**W**hy do laparoscopic surgeons avoid suturing?

The perception is that it is cumbersome to learn and perform.

Surgeons are unfamiliar with:

- principles of needle introduction
- principles of needle positioning and suturing
- knot tying techniques

As laparoscopic hysterectomies, myomectomies, bladder suspensions, pelvic wall reconstructions and other advanced endoscopic procedures are becoming the accepted method of treatment, there is an increasing need for laparoscopic suturing techniques. Laparoscopic ligation and suturing is used for approximation of tissue planes and effectively provides hemostasis. Laparoscopic suturing requires significant hand-eye coordination, since laparoscopic procedures are performed while monitoring a bi-dimensional TV screen with up to six times magnification; this eliminates depth perception and the direct tactile feeling of the tissue. Suturing represents the third level of laparoscopic skills.

The important steps in endoscopic suturing are:


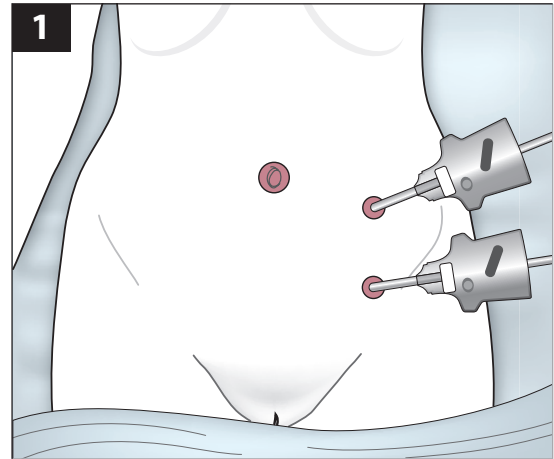
- Introduction of the needle and suture into the abdominal cavity
- Placement of the suture ligature
- Knot tying, either extracorporeal or intracorporeal

The following equipment is required for laparoscopic suturing:

- laparoscopic needle holders
- laparoscopic graspers
- knot pusher
- laparoscopic scissors
- ligatures and sutures

Two-handed manipulation is required to perform laparoscopic suturing and knot tying. This necessitates an assistant to hold the camera and laparoscope and to stabilize the laparoscopic ports. A 0° laparoscope should be used to permit a direct view. Proper placement of ancillary trocars is imperative for optimal suturing and knot tying. The tips of the instruments must be in front of the laparoscope, and should enter the field of view tangentially rather than in coaxial orientation, to prevent obscuring of the operative field. For laparoscopic surgery, the same principles of suture choice and suturing materials are applied as for conventional surgery.

We advocate ipsilateral port placement for laparoscopic suturing. For surgeons who are right handed, two ports above the pubic hairline, lateral to the deep epigastric vessels, on the patient's left side



are recommended for placement of a laparoscopic needle holder and grasper (Figure 1). We recommend using another needle holder with articulating jaws, instead of the grasper, as this will provide better needle handling during suturing, as well as the ability to place a stitch with both hands.

Laparoscopic surgeries can be performed using 5 mm trocar sleeves, but a 10/11 disposable trocar for the introduction of the needle can also be used.

## INSTRUMENTS

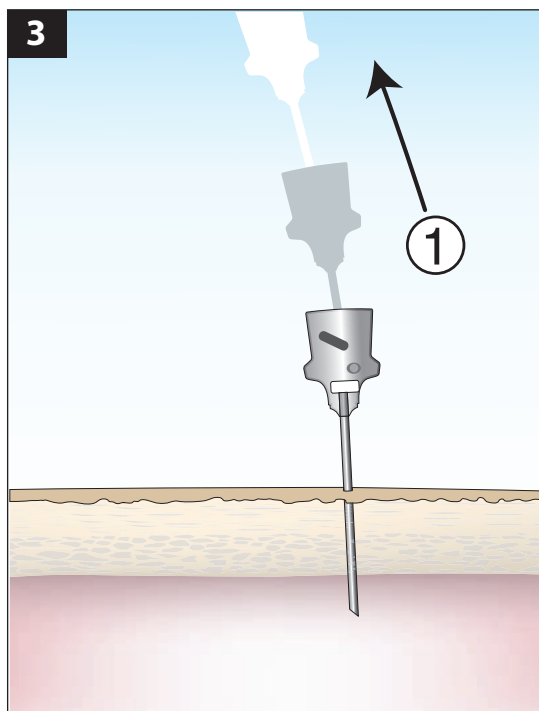
Needle holders have two designs: those with standard articulating jaws and self-righting ones with fixed locking jaw mechanisms such as the Cook needle holder (Cook OB/GYN, Spencer, IN) (Figure 2). However, this type of needle holder cannot be used for instrument tying.

Graspers can be used for tissue stabilization, needle holding or internal knot tying. Graspers with flat narrow tips are optimal, although we prefer to use two needle holders.

Dr. Courtenay Clarke first introduced the laparoscopic knot pusher in 1972. Clarke's horseshoe knot pusher (Marlow Surgical Technologies Inc., Willoughby, OH) is probably the most widely used.

For extracorporeal knot tying, a long ligature thread of at least 70 cm should be used. If an intracorporeal technique is utilized, the preferable ligature length is 10–12 cm.

Curved needles are increasingly utilized for hemostatic ligature placement, closure of tissue defects and suspension of organs. A majority of surgeons use CT-1, CT-2, or HS needles since they can be introduced into the peritoneal cavity through the disposable 10/11 trocar sleeves by grasping the suture near the needle hub with a 5-mm grasper and introducing it into the peritoneal cavity. Pop-off sutures should not be used in laparoscopic suturing. Techniques have also been described for intraperitoneal introduction of any size needle for laparoscopic suturing without the use of large trocars.



## INTRODUCTION OF A SUTURE INTO THE PERITONEAL CAVITY

Dr. Harry Reich's technique allows the placement of any size curved needle into the abdominal cavity by using a 5 mm lower quadrant incision. This technique is illustrated in Figures 3–6.

The ancillary trocar is withdrawn from the abdominal wall. The trocar hole is plugged with the assistant's finger to prevent escape of gas from the peritoneal cavity (Figure 3).

The trocar is held in the surgeon's hand outside the abdominal cavity and the needle holder or grasper is inserted through the trocar sleeve; the suture tail is grasped and pulled back through the trocar. The grasper is then reintroduced



through the trocar along the suture and the suture is grasped about 3-4 cm above the needle hub (Figures 4 and 5).

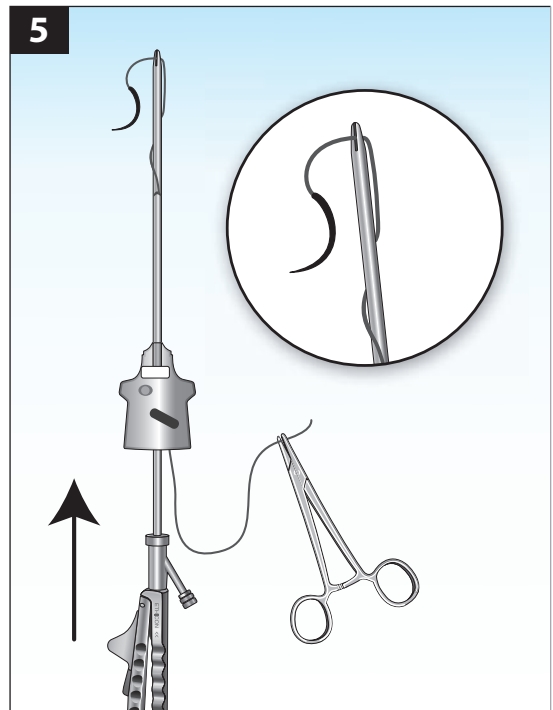
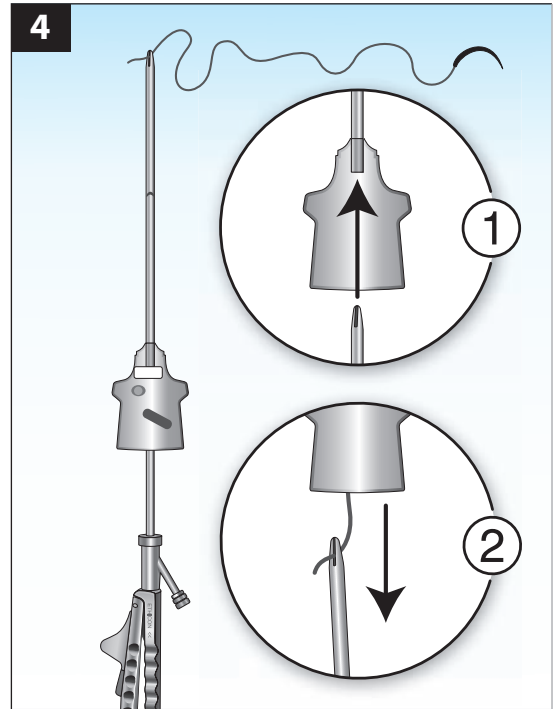
The needle holder is then introduced into the peritoneal cavity through the same incision pulling the needle with it. When the needle is pulled into the abdominal cavity, the trocar sleeve is then pushed over the grasper using it as a guide to seal the incision in the abdominal wall (Figure 6).

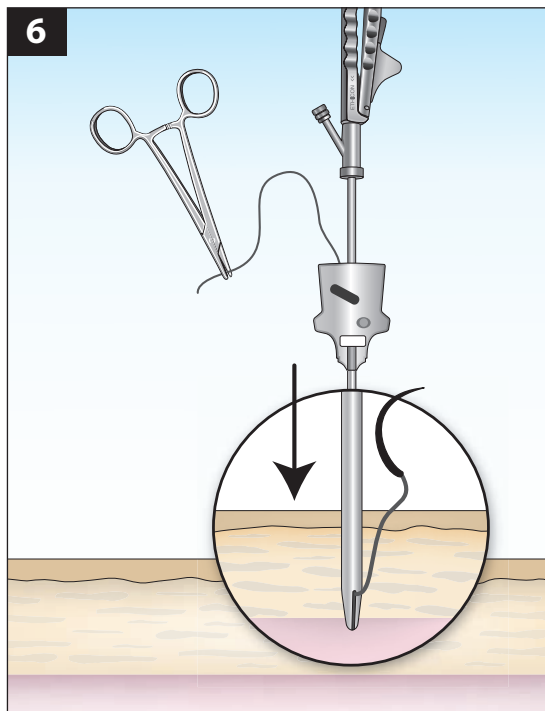
After introducing the needle into the abdominal cavity a small clamp is placed at the suture tail to prevent the tail of the suture from being pulled into the trocar.

## HOW TO PLACE LIGATURES

In order to grasp the needle properly with the needle holder, the suture is held with the surgeon's left hand 1-2 cm above the needle hub and the needle is positioned so that the needle forms a smiley face with the tip facing toward the patient's left side. The laparoscopic needle holder that is held in the surgeon's right hand is pushed forward to grasp the needle at a 90° angle 1/3 the distance from the needle hub. The laparoscopic camera should be zoomed on the needle while the needle holder is grasping it and kept in the middle of the screen at all times (Figure 7).

If the needle cannot be placed in a position to face toward the left side, it should be lowered down until it touches the bowel or pelvic structures, and then slowly turned and manipulated toward the patient's left.

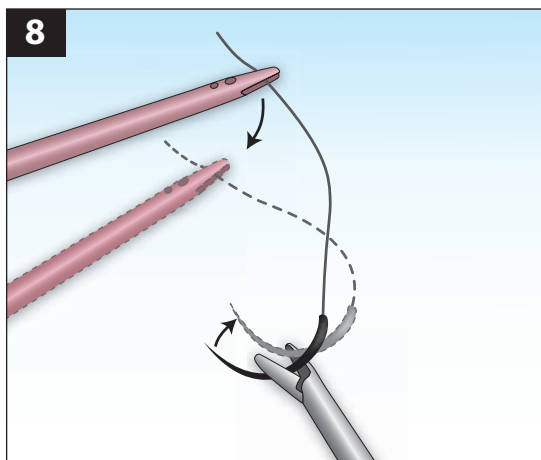
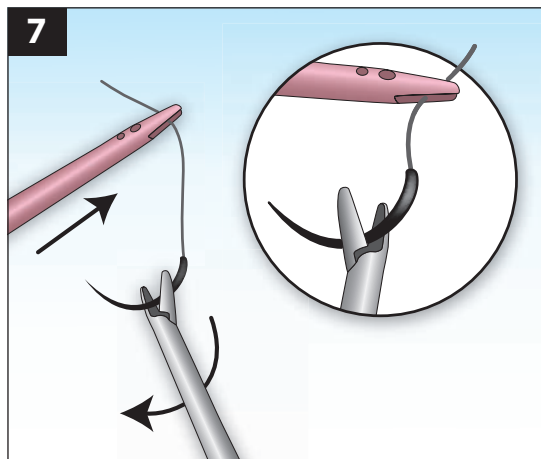




When the needle is grasped with the needle holder, its position can be corrected by loosening the grip on the needle and pulling the suture with the needle holder held in the left hand. The tip of the needle can be rotated toward the left or the right until the desired angle is obtained (Figure 8). The alternative technique is to grasp the needle tip with the grasper and correct its position while slightly loosening the needle holder's grasp on the needle.

The grasper is used to hold the tissue being sutured, or it is pushed against the tissue to create a counter-force while the needle is driven from the other side.

Due to the restricted instrument mobility in laparoscopic surgery, passing the needle through a tissue is limited by the trocar placement to a single rotating

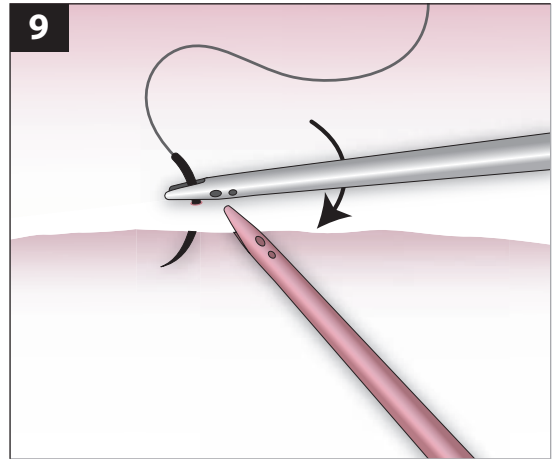


movement around the axis of the needle holder. Because of these limitations, it is crucial that the needle holder is secured with a firm grip onto the needle to avoid needle displacement and rotation in the needle holder's jaws. With practice, a good level of hand-eye coordination can be achieved.

When the needle is correctly grasped, suturing is performed by a gentle initial push followed by rotation of the wrist. When the needle tip is driven through the tissue it can be held by the grasper

and pulled through by continuing the rotation of the needle and releasing the needle holder (Figure 9).

Some laparoscopic surgeons use straight needles for suturing. The straight needles can be easily introduced into the peritoneal cavity through 5 mm cannulas, and they are easily manipulated with laparoscopic instruments (Figure 10). The main disadvantage of straight needles is that it is difficult to suture pedicles.

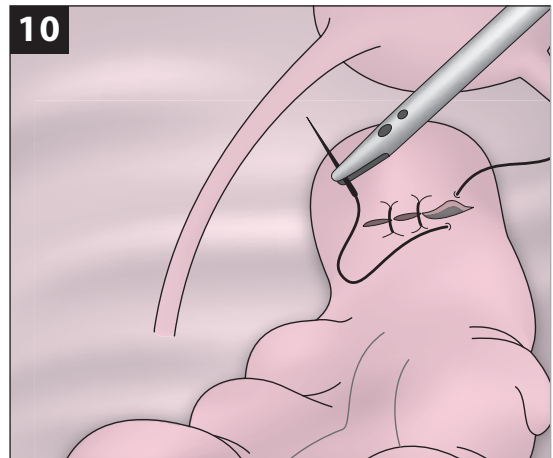


## KNOT TYING

Secure knot formation is essential to laparoscopic suturing procedures. Knot tying can be divided into two general categories; extracorporeal knots formed outside the body and pushed into the peritoneal cavity through the trocar sleeve by a knot pusher, and intracorporeal knots that are tied inside the abdominal cavity using laparoscopic instruments. Both techniques are safe and reliable and can be used in different clinical situations. The endoscopic surgeon should be familiar with both techniques in order to successfully perform advanced laparoscopic surgical procedures.

### EXTRACORPOREAL KNOT TYING

After the suturing is completed, if the needle is introduced through a 5 mm port, the needle has to be cut off and temporarily parked in the anterior abdominal wall until the knot tying is completed. If the needle was introduced through a 10/11 trocar, the needle can be

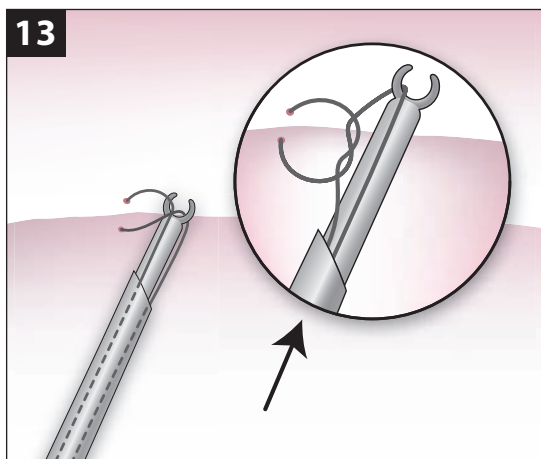
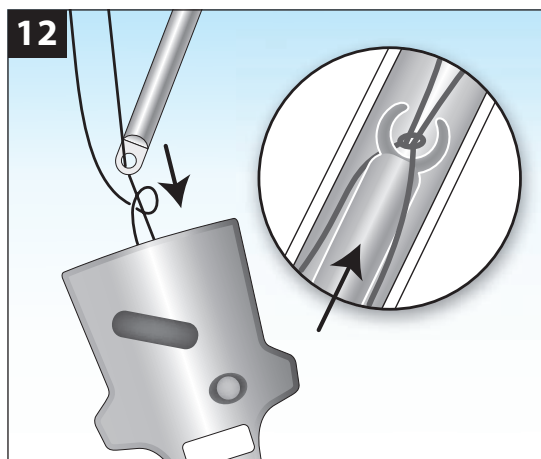
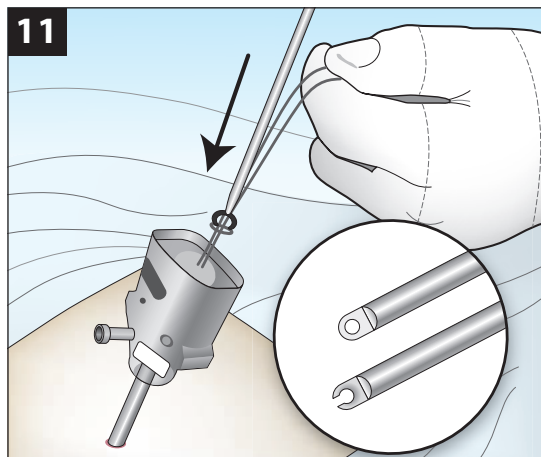


pulled out and cut off after the suturing is completed. If the needle is cut inside the peritoneal cavity, the suture end is grasped with the needle holder and pulled out through the same trocar sleeve where it was originally introduced. While the suture is drawn out of the abdomen, the rest of the ligature should be simultaneously fed into the peritoneal cavity to prevent pulling or sawing on the tissue.

Holding both ends of the suture, a single simple knot is tied and pushed down

with the knot pusher. There are two types of knot pushers available: the closed-end and the open-end knot pusher (Figure 11). Steady pressure should be maintained on the knot pusher and suture ends at all times (Figures 12, 13). Several single knots should be placed on top of each other. If the steady pressure is not maintained on the knot pusher, the open end knot pusher sometimes may become dislodged during knot pushing because polyfilament materials such as silk or catgut do not slide easily. Losing the knot in the trocar sleeve may present a problem since it is impossible to hitch the knot again if the knot pusher becomes dislodged in the trocar sleeve. If the knot pusher is dislodged in the trocar sleeve and the knot is not visible, the suture should be pulled with the grasper inside the peritoneal cavity until the knot can be located. The knot pusher is then placed on the knot under direct vision. If the knot cannot be seen, the whole suture should be pulled inside the abdomen, untangled, and both strings should be taken out through the trocar and a new knot placed.

The closed end pusher is easier to use and many surgeons prefer using it for laparoscopic suturing (Figures 11 and 12). The closed knot pusher does not allow the knot to slip since, after the suture is threaded through the tip of the pusher, it cannot be dislodged and the sutures can be thrown much quicker. One suture end is passed through the hole at the distal end of the knot pusher and a one-hand granny knot is tied with the other end of the suture and pushed

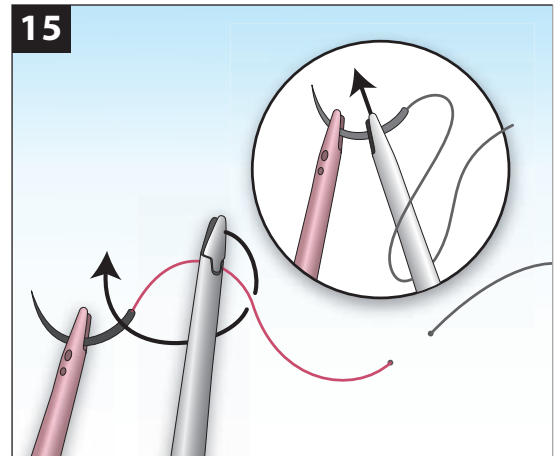
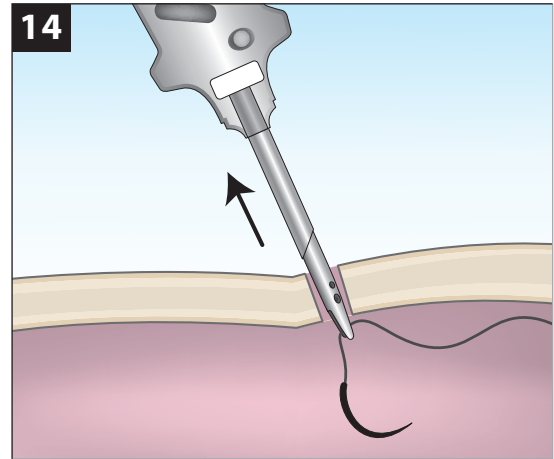


into the abdomen with the knot pusher. After placing three knots, the sutures are switched and the other end of the suture is passed through the hole on the knot pusher, and the next three knots are placed. This maneuver locks the knots in place and prevents sliding.

After knot tying is completed and the suture has been cut, the needle is removed from the peritoneal cavity by grasping the suture about 2 cm away from the needle and extracting it through a 10/11 trocar, or pulling it together with the 5 mm trocar sleeve, from the abdominal cavity. Careful observation of the needle is recommended to complete withdrawal (Figure 14).

## INTRACORPOREAL KNOT TYING

The laparoscopic surgeon may choose to tie knots intraperitoneally. This technique involves instrument tying and requires certain skill. Intracorporeal knots are most often used for tissue fixation that does not require a lot of tension and less often for hemostasis since they cannot be tied with the same strength as extracorporeal knots. They are also used for anchoring a running suture, like those used for peritoneal closure, repair of bladder lacerations, or laparoscopic tubal reanastomosis. The intracorporeal knot tying is a useful adjunct if the suture breaks in the process of extracorporeal tying and the knot can be completed using this technique. For intracorporeal knot tying, a short ligature of about 10-14 cm is used unless a running suture is

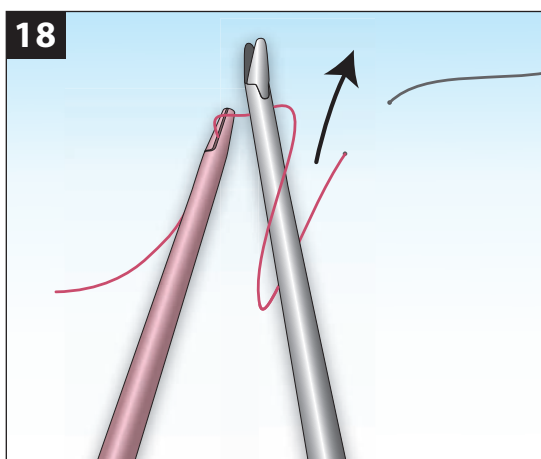
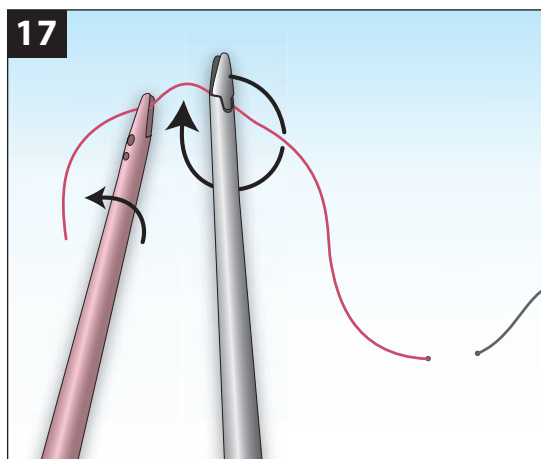
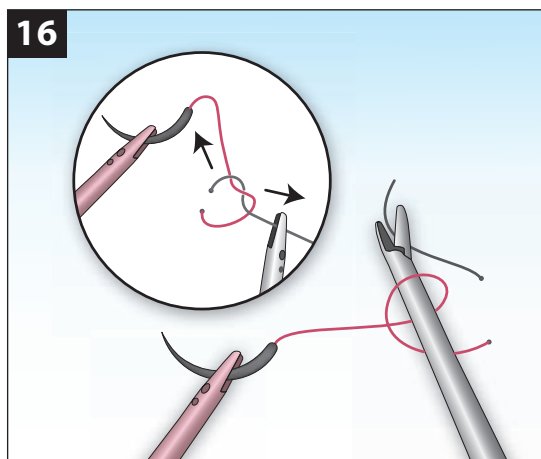


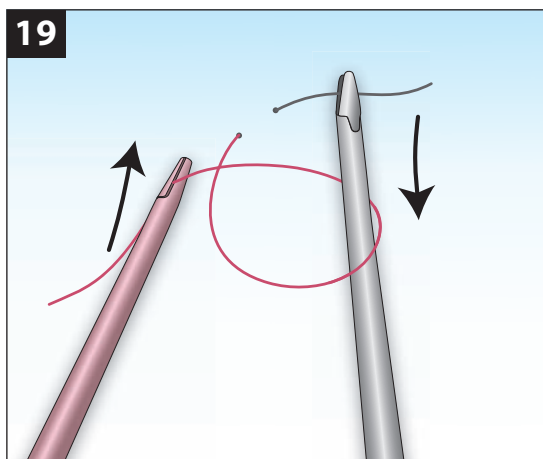
placed, in which case a longer ligature is required. If the suture is too long, it can be very difficult to control the knot formation. The suture is passed into the peritoneal cavity as previously described, and following the suture placement, an instrument tie is performed within the peritoneal cavity. There are several types of intracorporeal knot tying, but only one is necessary. The surgeon must practice and learn the technique well.

## SQUARE KNOT

This knot is tied utilizing the classic microsurgical technique of instrument tying. After the needle is passed through the tissue, the suture is pulled almost all the way, leaving only 1-2 cm of the suture tail at the site of the needle insertion. This knot is much easier to tie if the needle is attached to the suture. If the needle is still attached, it should be grasped with the left hand as shown in Figure 15. The needle holder, held in the right hand, is placed on top of the suture. The tip of the grasper is then moved in the rotating pathway describing a full circle down and back, and again forward through the needle. This motion of the tip wraps the suture around the needle holder held in the right hand and forms the loop required for completion of the knot. The needle holder in the right hand with the suture wrapped around it grasps the short suture tail and pulls it back through the loop completing the knot (Figure 16).

If the needle is not attached, the long tail of the suture is grasped with the needle holder, held in the left hand, and rotated counterclockwise forming a mild upward curve of the suture. The other needle holder is introduced with the right hand and placed forward on top of the suture (Figure 17). It is then moved in the rotating pathway, describing a full circle down and back, and again left and forward. Holding the jaws of the grasper open during this circular movement may help prevent the formed loop from slipping off its tip. This movement of the



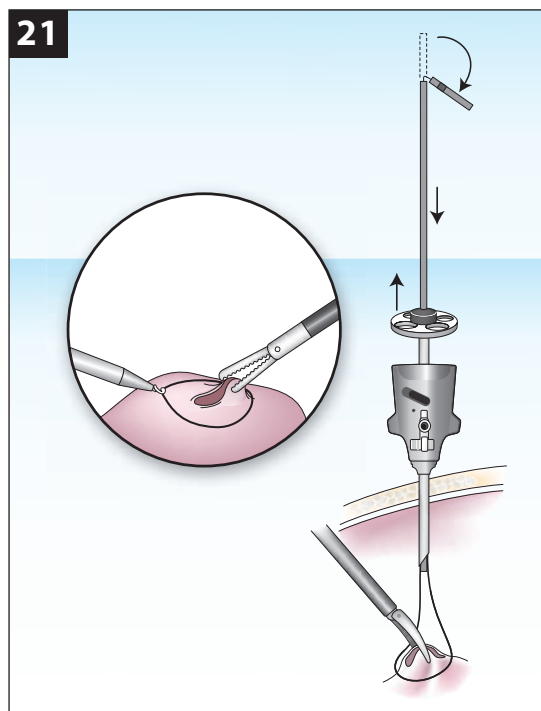
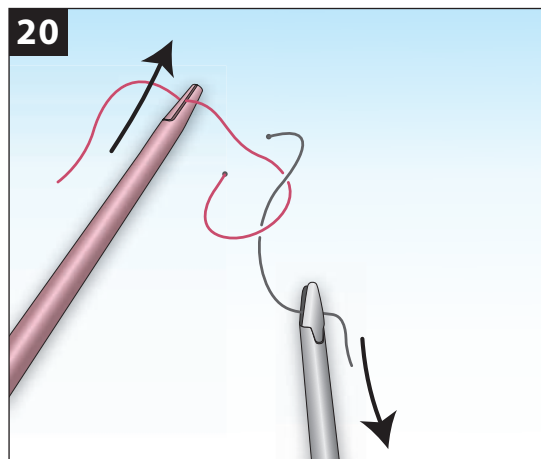


grasper forms the loop that wraps the suture around the grasper (Figures 18 and 19). After the loop is formed around the grasper, a short tail of the suture is grasped and pulled through the loop, while the needle holder provides counter-traction on the opposite end of the suture. With this movement, the first flat knot is created (Figure 20).

The same procedure is repeated in the opposite direction, and a second locking knot is formed. A third optional opposing flat knot can be added in the same manner as the first knot.

## LOOP LIGATURE

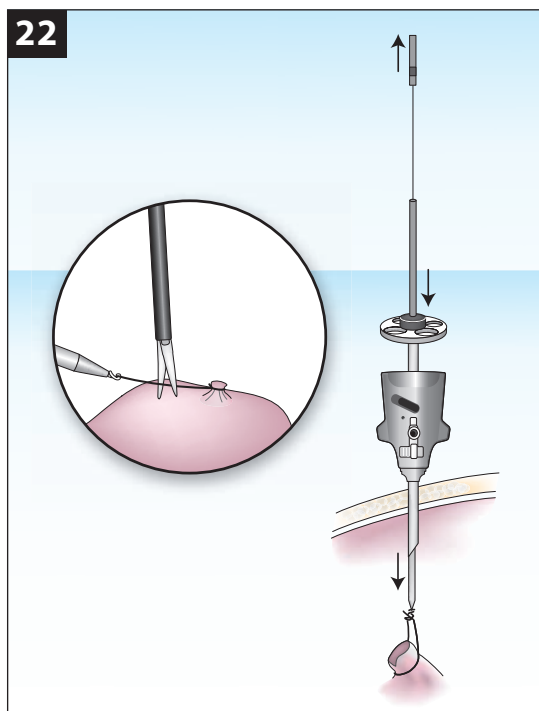
The loop ligature was originally demonstrated by Dr. Kurt Semm and was based on the Roeder Loop. The loop is closed when the distal portion is pulled while pushing the knot into place with the plastic slide. Ligation with the preformed loop has certain limitations, since it is restricted to open ended pedicles and utilizes a slipknot, which may be prone to slipping.



The loop ligature is already pre-packaged and it can be applied through the 5 mm laparoscopic port. The loop ligature is back loaded into a hollow 3 mm tube called an applicator. The tube is then placed through a 5 mm trocar sheath. A loop ligature also can be directly placed

through disposable 5 mm cannulas. The edges of the tissue to be adapted are then grasped through the loop with an appropriate instrument. After the loop is placed around the pedicle, the proximal tip of the loop is broken off by applying pressure with the fingers and the loop is tightened by pulling on the broken end. The tip of the loop applicator is placed on the exact spot where we want the knot to be and the loop is further tightened (Figures 21 and 22). Scissors are introduced through a separate port and the loop ligature is cut.

This is the simplest way to close open pedicles. If a pre-packaged loop ligature is not available, a loop can be improvised by tying a Roeder knot extracorporeally, and using a suture applicator to push the knot into the abdominal cavity.





## SUGGESTED READING:

Reich H, McGlynn F. Laparoscopic repair of bladder injury.  
Obstet Gyn 1990; 76: 909-10

Reich H. Laparoscopic hysterectomy.  
Surg Laparosc Endosc 1992; 2: 85-8

Liu CY, Paek W. Laparoscopic retropubic colposuspension (Burch procedure).  
J Am Assoc Gynecol Laparosc 1993; 1: 31-35

Soper NJ, Hunter JG. Suturing and knot tying in laparoscopy.  
Surg Clin N Am 1992; 72:1139-52

Clarke HC. Laparoscopy-new instruments for suturing and ligation.  
Fertil Steril 1972; 23: 274-77

Semm K. New method of pelviscopy for myomectomy, ovariectomy,  
tubectomy, and appendectomy.  
Endoscopy 1979; 11: 85-93

Reich H, Clarke HC, Sekel L. A simple method for ligating with straight and curved  
needles in operative laparoscopy. Obstet Gynec 1992; 79: 143-7

Semm K. Tissue-puncher and loop-ligation, new ideas for surgical therapeutic pelviscopy  
(laparoscopy) endoscopic intra-abdominal surgery.  
Endoscopy 1978; 10: 119-24

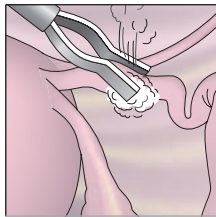
Hay LD, Levine RL, Von Fraunhopper AJ, Masterson JB. Chromic gut pelviscopic loop  
ligature effect of the number of pulls on the tensile strength.  
J Reprod Med 1990; 35: 260-2

Topel H. The video encyclopedia of endoscopic surgery for the gynecologist.  
Shirk GS, ed. Tape 1, Medical Video Productions, 1994

Pasic R, Levine RL. Laparoscopic suturing and ligation techniques.  
J Am Assoc Gynecol Laparosc 1995; 3: 67-79

.....

# LAPAROSCOPIC TUBAL STERILIZATION



*Ronald L. Levine, M.D.*

Laparoscopic sterilization is the most common type of female sterilization surgery performed in the United States. There are essentially three major methods, however, occasionally a surgeon may still use thermal coagulation.

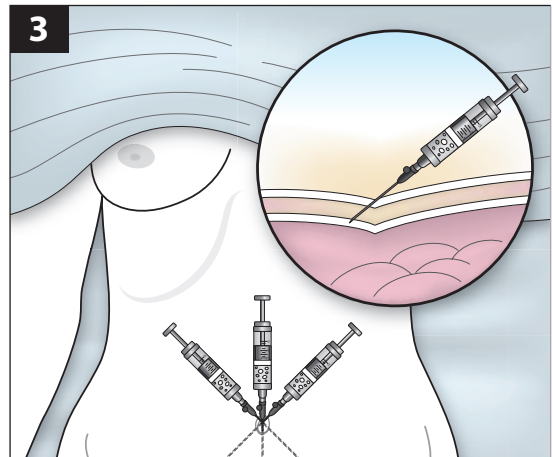
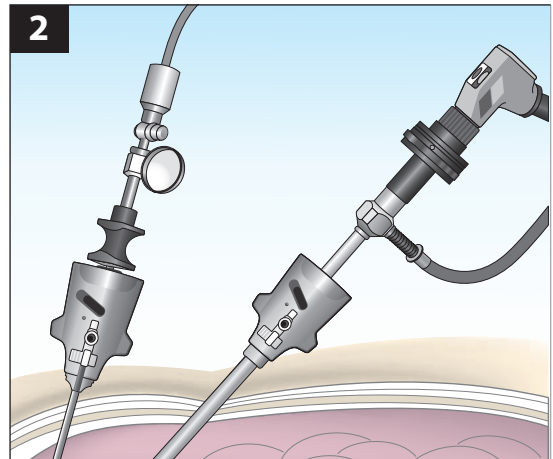
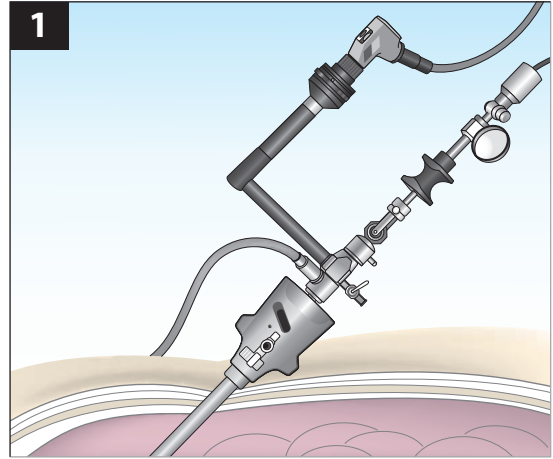
1. Electrosurgical:
  - a. Monopolar
  - b. Bipolar
2. Clips:
  - a. Hulka
  - b. Filshie
3. Bands (Fallope ring)
4. Thermal coagulation

All of the methods that will be described may be performed through either a single puncture technique using an operating laparoscope (Figure 1), or through a double puncture technique, using a 5 mm second puncture trocar that may be placed in the midline suprapubic area.

The double puncture technique uses a 5 mm or 10 mm laparoscope that is inserted through the umbilical port (Figure 2). Our preference in recent years has been to use the single puncture technique unless there is difficulty in mobilizing the Fallopian tube. If the single puncture technique is the method of choice, it is very important that a well functioning uterine manipulator be employed. By moving the manipulator it is possible to stretch the tube laterally. The surgeon can control the operative field by moving the laparoscope in and out, to obtain close up or panoramic view, and by moving the instrument inserted through the operative channel.

One of the most common causes of sterilization failure is the misidentification of either the round ligament or the uteroovarian ligament for the Fallopian tube. Therefore, it is vital to identify all three structures and to trace the tube to the fimbriae if at all possible, prior to performing the sterilization.

Although many of our sterilization procedures are performed under general anesthesia, a large number are accomplished under local. When local is the method, the skin and deeper tissues are blocked using lidocaine (Figure 3). The art, however, is to instill a mixture of 10 cc carbocaine and lidocaine transcervically via the uterine manipulator. The tubes can almost be seen to blanche (Figure 4). Prior to using the desired technique, we then drip another 10 cc of lidocaine along the length of the tube (Figure 5).



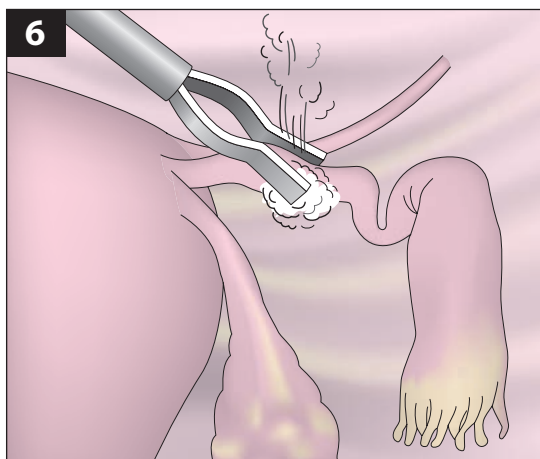
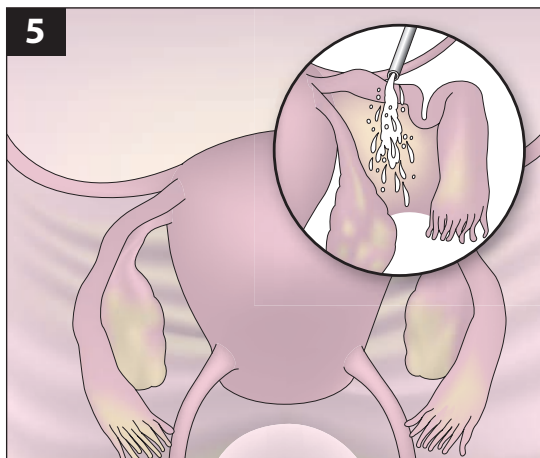
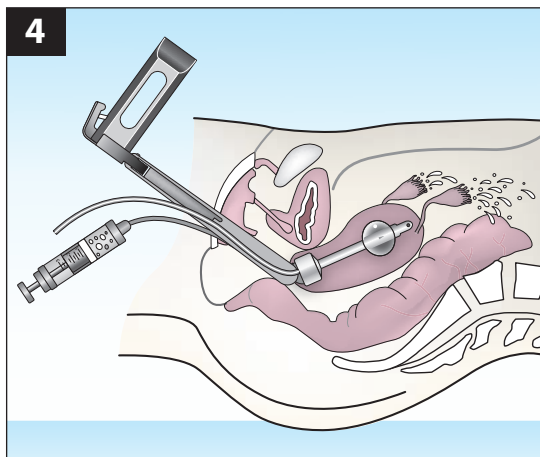
## ELECTROSURGICAL

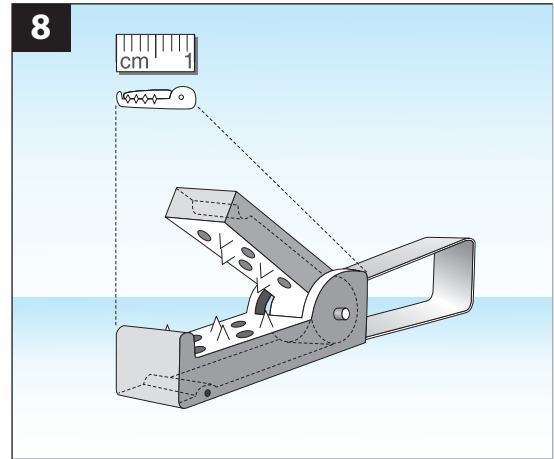
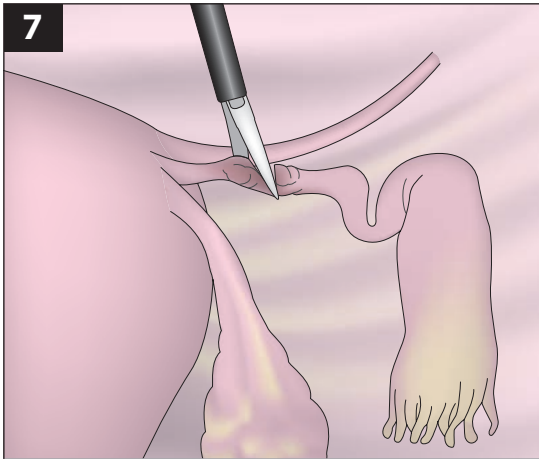
Monopolar electrosurgery is still used by some gynecologists, however, it has lost favor because of its risks of thermal bowel burns. The technique of bipolar coagulation, as originally described by Dr. Richard Kleppinger, is still the most popular form of laparoscopic sterilization and is our suggested form of electrosurgical management.

### BIPOLAR

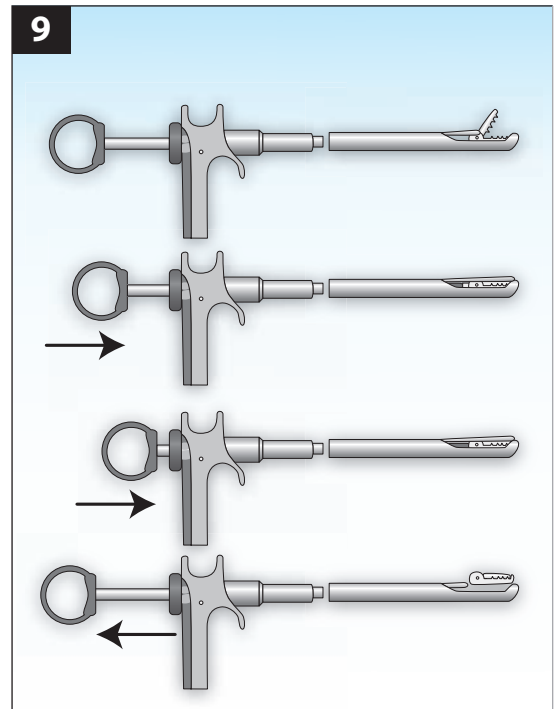
The bipolar Kleppinger type forceps have been described in Chapter 1. The tips of the forceps are where the energy is distributed from one tong to the other. It is therefore important that the tips enclose the tube as much as possible (Figure 6).

Bipolar coagulation provides a more localized area of tubal burn thus requiring at least 3 cm of tube to be coagulated. The tube is grasped in the isthmic portion of the tube at least 2 cm from the cornua (Figure 6). If too close to the uterus there is a risk of creating a uteroperitoneal fistula. The tips of the tongs should be minimally in the mesosalpinx to avoid too much damage to the blood supply of the tube and its anastomotic branches to the ovary. The electrosurgical generator should be set to deliver a power of 25 W in a nonmodulated or cutting mode to desiccate the tissue sufficiently. If too much energy is used, the tube tends to be rapidly coagulated on the periphery, rather than through slow coagulation. This may lead to a ster-





ilization failure. The tube should be coagulated with 2 to 3 contiguous burns to provide an area of about 3 cm of coagulation. The endpoint of coagulation is the cessation of current flow. This will supply a relatively accurate indication of complete coagulation. Most electro-surgical generators have either a visual ammeter or an audio signal of this endpoint. After completing the coagulation, it has been our technique to sever the tube in the middle of the burn area with a laparoscopic scissors (Figure 7). However, there is some controversy regarding this and many surgeons do not cut the tube believing that it leads to a higher failure rate due to possible fistula formation.



### IMPORTANT NUMBERS

2 CM FROM FUNDUS

3 CM OF TUBE

2-3 CONTINUOUS BURNS

25 W POWER

### CLIPS

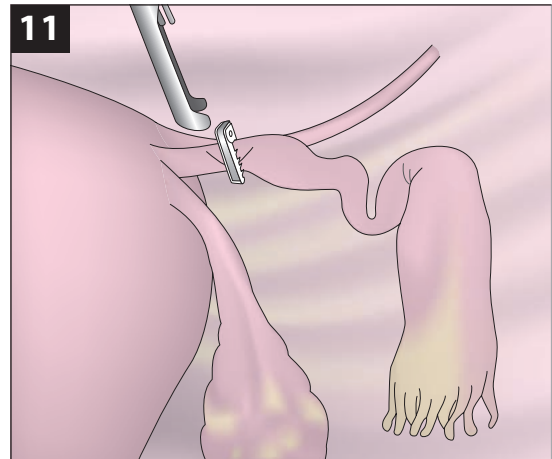
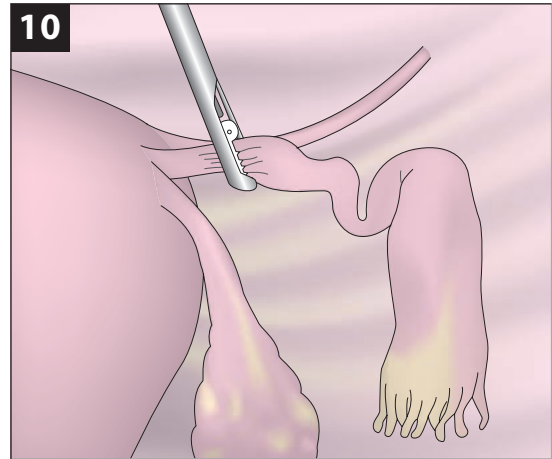
Mechanical occlusion of the tube is most commonly performed using one of two types of clips. The most popular has been the Hulka-Clemens spring-loaded

clip available since 1976. The clip itself is a plastic, hinged device that is closed by advancing a metal spring over the plastic jaws. The inner parts of the jaws have several small teeth that keep the clip in place (Figure 8). The clip requires a special laparoscopic applicator that may be passed through the single puncture operating laparoscope. This instrument is 7 mm and is inserted through the operating channel.

The clip applicator has four positions (Figure 9).

1. Safe open – In this position the clip is held on the end of the applicator and can be opened and closed without locking. This position is used when the applicator and clip are passed through the operating scope channel.
2. Safe closed – The tube is grasped with the clip and closed to this position. The clip may be removed by opening the clip applicator jaws.
3. Full closed – The thumb manipulator of the applicator drives the metal spring over the plastic jaws of the clip and locks it in place.
4. Full open – The ring on the handle is pulled back and the clip is thus removed from the applicator and left in place on the tube.

The applicator jaws are then closed and the instrument is removed. The clip should be applied on the isthmus at least

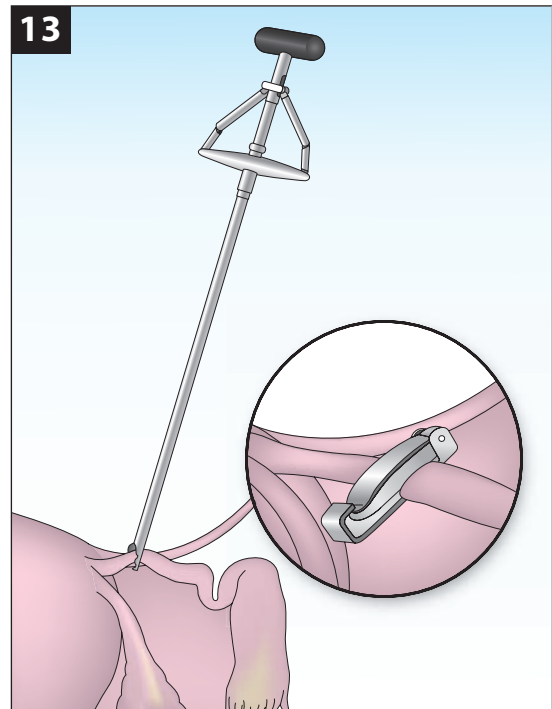
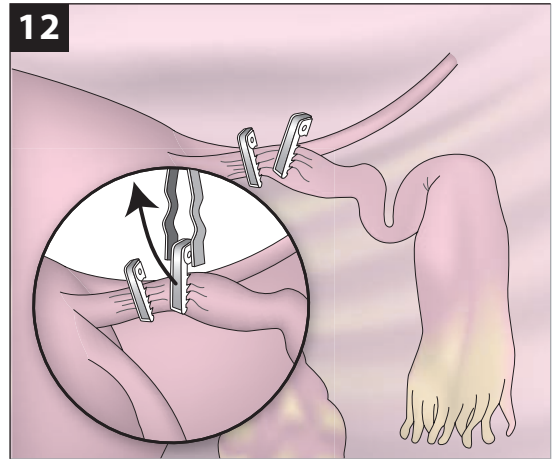


2 cm from the uterus and should be placed completely across the tube. This can be assured by observing that the tube rests completely against the hinge of the clip (Figure 10). With correct application, the mesosalpinx is pulled up to resemble the shape of an envelope flap. This is referred to as the 'Kleppinger envelope sign' (Figure 11). As noted above, because of a misapplication, it is sometimes necessary to apply more than one clip.

Although classically described, if the clip is in a bad position another clip should be placed because it was thought that the clip could not be removed. However, Dr. Walter Wolfe described a technique for removal of a clip that is simple and works well. A Kleppinger force-  
 clip may be passed using the tongs to grasp the sides of the clip (Figure 12). The Kleppinger holds the sides firmly and the clip easily is pulled off and is removed.

A secondary advantage of the clip is the fact that the area of damage to the tube is small. As such, a short segment of tube is destroyed and increases the ability for surgical reversibility.

Another style clip is the Filshie clip (Avalon Medical Corp., Williston, VT). Although first described in 1976 and used in the United Kingdom for many years, it was not approved in the United States until 1996. This clip is made of titanium with a silicone rubber lining that expands to keep the tube compressed as it flattens. This clip also requires a special applicator. It may also be advanced into the abdomen through the operating channel of the single puncture operating laparoscope by half closing the upper jaw. When the finger bar is released the clip opens and is then placed (Figure 13). The Filshie clip is applied in a similar manner to the Hulka clip, on the isthmic portion of the tube. The bar is then squeezed to its limit thus closing the clip and releasing it from the applicator. The clip locks around the tube and cannot be removed. If misapplied another clip may be placed. A small area of the tube is

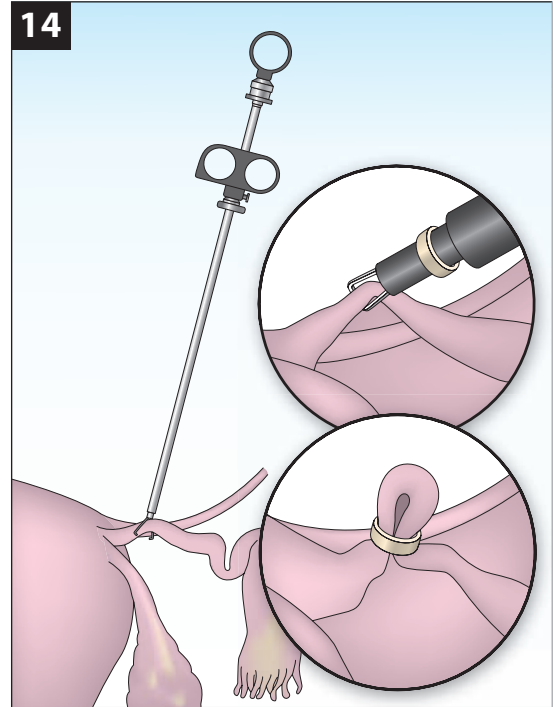


crushed, so that similar to the Hulka clip, this method may yield a high success rate for surgical reversal. The CREST study stated that the Filshie clip has a relatively low failure rate.

## BANDS

Yoon and associates introduced the silastic band in 1974. This small silastic band is applied to the tube by use of a special 8 mm applicator that may be used through the single puncture 12 mm operating laparoscope. The bands are preloaded onto the instrument using a special plastic loading device. The applicator is then passed down the channel and grasping hooks are deployed from the end of the applicator (Figure 14). The tube is grasped in the isthmic area about 3 cm from the cornua of the uterus. The tube is then drawn up into the inner cylinder of the applicator by the grasping hooks and the silastic band is applied by moving the outer cylinder forward. It is important that a sufficient knuckle of tube is brought back into the applicator to assure that two complete lumens have been occluded. After application of the band, the grasping tongs are moved forward out of the inner cylinder to release the occluded tube.

Several problems have been described with the bands. There have been a signif-



icant number of complications secondary to tears in the mesosalpinx. Bleeding from this problem can usually be controlled by bipolar coagulation. Postoperative pain is more frequent than with clips or bipolar coagulation. A large number of these patients require an oral analgesic for several days postoperatively.



## SUGGESTED READING:

ACOG Technical Bulletin. Number 222. April 1996

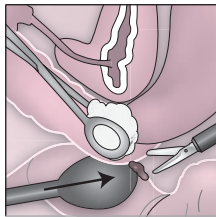
Peterson HB, Xia Z, Hughes JM, et al. The risk of pregnancy after tubal sterilization: Findings from the US Collaborative Review of Sterilization. *Am J Obstet Gynecol* 1996;174:1161-1170

Grimes D. Update on Female Sterilization. *Contraception Report* 1996;7(3):1-2

Christman GM, Vechi H. Female Sterilization. 2000;25:48-58

.....

# ENDOMETRIOSIS



*Dan C. Martin, M.D.*

## INTRODUCTION

**E**ndometriosis is diagnosed in several clinical situations including surgery for pain, infertility, mass, and sterilization. Some presentations, locations, and sizes are readily treated at laparoscopy while others may be better approached at laparotomy. The purpose of this chapter is to describe the recognition and treatment of those lesions which generally are found and treated at laparoscopy.

Controversial concepts will also be addressed. These include biopsy for confirmation, coagulation vs. excision and treatment of asymptomatic endometriosis seen at laparoscopy for sterilization.

## GOALS OF SURGERY

The surgery plans depend on the goals of treatment. Limited surgery may be best for fertility surgery as it may cause fewer adhesions than extensive dissection. Deep dissection and complete removal of endometriosis appears to be a better approach for deep infiltration and

pain. If the purpose is tissue diagnosis, then excisional biopsy with tissue sent to pathology is necessary. When asymptomatic endometriosis is noted at laparoscopy for sterilization, both observation and limited surgery appear reasonable in addition to completing the sterilization procedure.

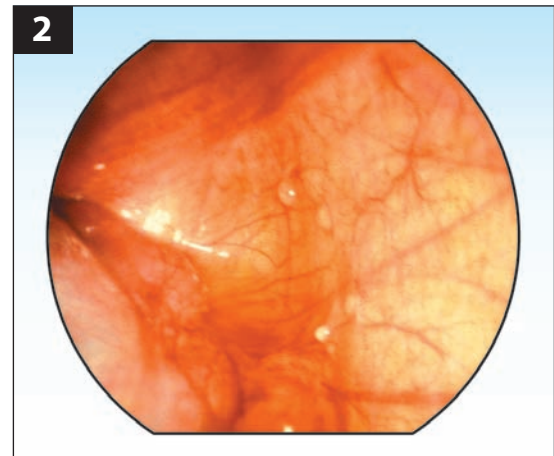
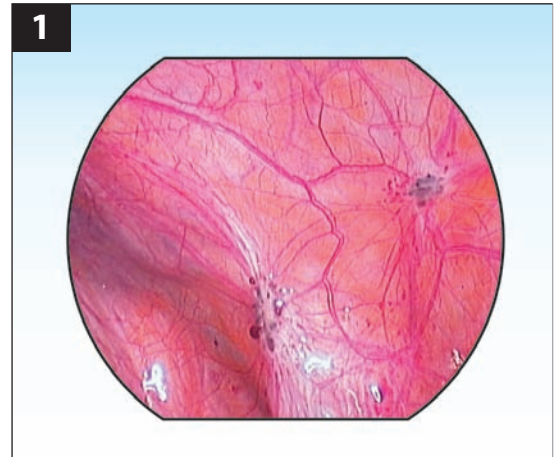
## PURPOSE OF CONFIRMATION

The purposes of histologic confirmation can be clinical, audit, or research. A primary clinical purpose is to rule out cancer or other non-endometriotic pathology. Cancer, foreign body, carbon, ectopic pregnancy, splenosis, hemangiomas, chlamydia, and other diseases can look like endometriosis.

Although confirmation of disease is essential for research studies in most specialties, confirmation by biopsy in medical trials for endometriosis introduces the problem of partial surgical treatment into a medical trial. The problems of confirmation are compounded by a lack of data on medical therapeutic response based on biopsy proven disease and by surgical data that shows similar response in biopsy positive and negative patients.

At an audit level, confirmation can be used for quality assurance. Physicians interested in endometriosis can generally maintain greater than 70% confirmation and recognition. But this degree of confirmation is higher than seen in general clinical care.

At a research level, my 91% confirmation was after 188 endometriosis study



patients. I reached 93% after another 91 patients and 98% in the last 69 of my 495 endometriosis patients studied from 1982 to 1986. Recent studies from the NIH confirm an increasing accuracy over 5 years of research experience. Those studies were under research conditions and do not address clinical relevance. Tissue diagnosis studies are needed to determine the relevance of obtaining biopsies for diagnosis of endometriosis or similar appearing pathology. In the meantime, biopsy to exclude other diagnoses such

as cancer and the therapeutic resection of endometriosis are reasonable while waiting on biopsy confirmation research to progress.

## RECOGNITION

Subtle appearing lesions may be more prevalent than dark lesions. But dark lesions are the easiest to see and to document (Figure 1). The limits of resolution for visualizing these lesions appear to be between 120 $\mu$ m and 400 $\mu$ m. Subtle lesions have many descriptions and appear to precede darker lesions. Colorless, amenorrheic lesions were seen by Fallon in 1950. Karnaky published an age-dependent appearance of endometriosis starting with an initial water blister presentation in 1969 (Figure 2). Red glandular lesions are very active and can appear like native endometrium on histology.

The term ‘typical’ and ‘atypical’ are generally avoided in this chapter for two reasons. First, the most common appearances have been subtle. Second, the use of the term atypical is better reserved for histologic atypicality in premalignant or malignant processes.

A related issue is the higher chance of finding other pathology with a similar appearance to endometriosis when lesions are subtle. This includes any lesion that is not “puckered and pigmented” or “dark and scarred” at first surgery. Furthermore, even dark scarred lesions may be foreign body when seen at second surgeries. Biopsy may be use-

ful in clarifying those problems. When biopsy is used, histologic criteria need to be adequate to avoid diagnosing endometriosis on the basis of soft criteria such as psammoma bodies or granulation tissue. Those findings have been associated with pelvic inflammatory disease, chlamydia and cancer.

Recognition of lesions appears to be related to the surgeon’s experience, attention to the possibility of multiple appearances, and the purposes of surgery. At a research level, confirmation has been as high as 100% in Belgium. However, clinical physicians have confirmation as low as 53% and fail to diagnose as much as 59% of the endometriosis that was sent to the lab and found on histology. The lack of recognition has been a problem for more than 100 years and was first presented in 1898. It wasn’t until the third year of study with more than 188 patients that the recognition level reached 91%. That level of confirmation was accompanied by an additional 15% of endometriosis patients diagnosed by histology when the diagnosis at surgery was not made. Biopsy techniques changed significantly over the 5 years in that study. Physicians may desire to test their own sensitivity and predictivity. The sensitivity is the least expensive measure to produce. This requires that a physician ask for his or her pathology reports that are positive for endometriosis. These can be compared to the operative notes to determine what was seen and what was not. More time consuming is to keep track of every case with a diagnosis of endometriosis by either the surgeon or the pathologist.

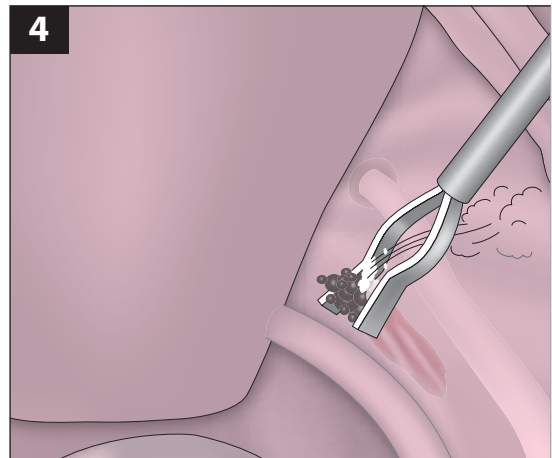
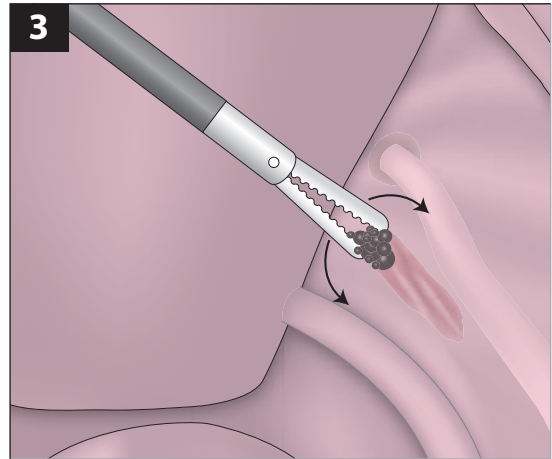
These can be compared with the reports by Scott and Martin.

## TREATMENT

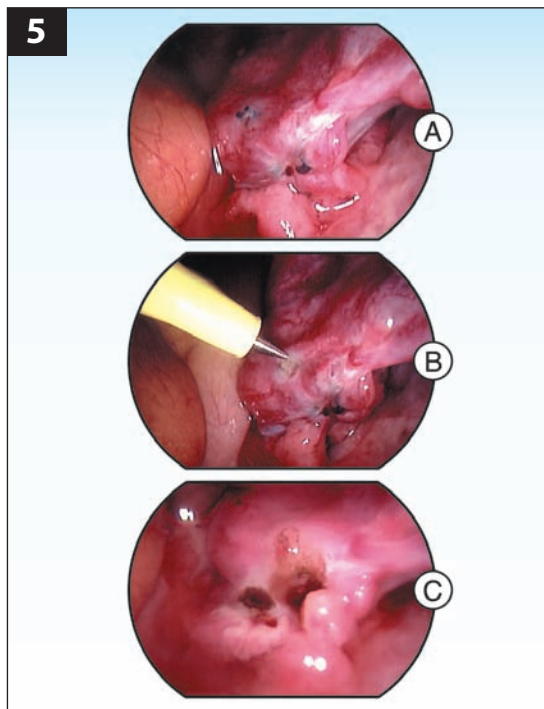
### SUPERFICIAL PERITONEAL LESIONS

Superficial peritoneal lesions can be recognized by grasping them and moving the peritoneum. If these move freely across loose connective tissue, then there is no evidence of deep infiltration (Figure 3). These type lesions can be treated with any energy source when they are small (3 mm to 5 mm). This includes coagulation, excision, and vaporization. Coagulation with bipolar electro-surgery is a technique available to all physicians trained to do bipolar tubal coagulation (Figure 4).

The spread of the white coagulated zone is directly related to the degree of damage and effect of coagulation. Electrosurgical coagulation is generally expected to spread 3 mm to 5 mm but can be as much as 20 mm. Care is needed to avoid prolonged exposure and excess depth of coagulation. Monopolar electro-surgery presents additional risks, as the depth of coagulation has been as great as 50 mm. When vaporization is used, the lesion is vaporized back to healthy fat in most situations. But this may be limited to less in sensitive areas such as the tube, bowel, or ureter. Vaporization can be done with either laser or monopolar electro-surgery. Laser and electro-surgical vaporization have the same tissue effect when corrected for power density.



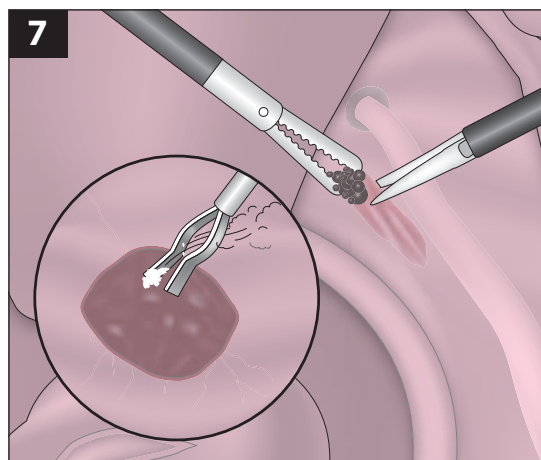
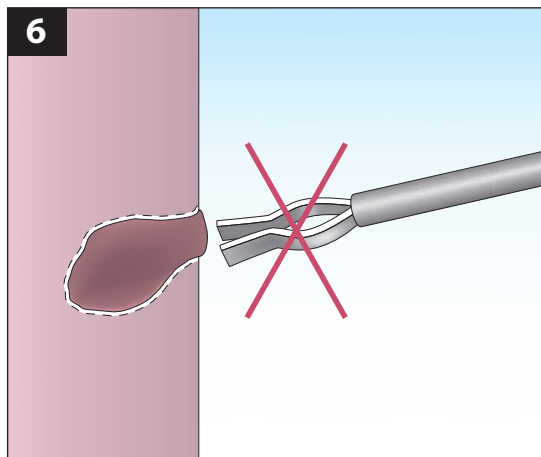
Vaporization is demonstrated in the ampulla of the tube where control of depth is necessary to preserve the tube and tubal function. The monopolar needle is brought into the operative field and high power density monopolar electro-surgery used to vaporize the endometriosis. The dark trapped blood is first released and then superficial vaporization of the back wall is performed on the tube (Figure 5). This is superficial in this situation to avoid deep damage to the tube. When this is in peritoneal surfaces,



vaporization is continued to healthy fat. The appearance at the end of the procedure shows that vaporization has left clean craters (Figure 5). What is not seen on these pictures is the presence of residual endometriosis behind the lower left vaporization crater. That area was too close to the fimbria and was avoided.

## DEEP LESIONS

Deep endometriosis can be difficult to treat when the depth is difficult to determine. Coagulation has limited usefulness with these lesions, as the risk of both inadequate treatment and peripheral damage is present. Attempting to coagulate lesions that are deeper than 5 mm can produce deep burns, which can include damage to organs such as the bowel or ureter (Figure 6). If inadequate

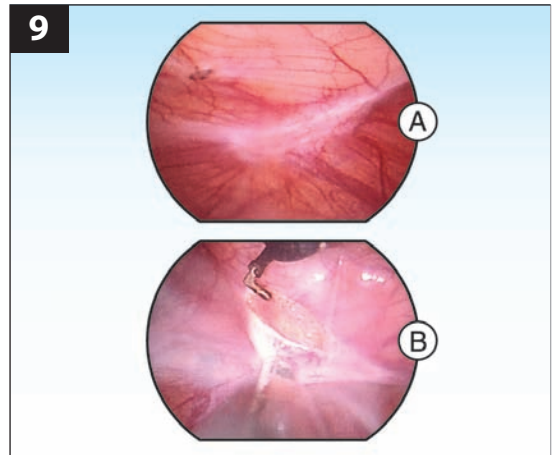
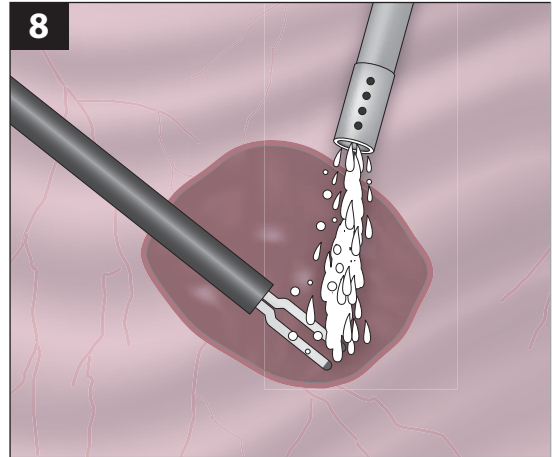


coagulation or vaporization is used, residual endometriosis can be found beneath a foreign body reaction from coagulation or vaporization.

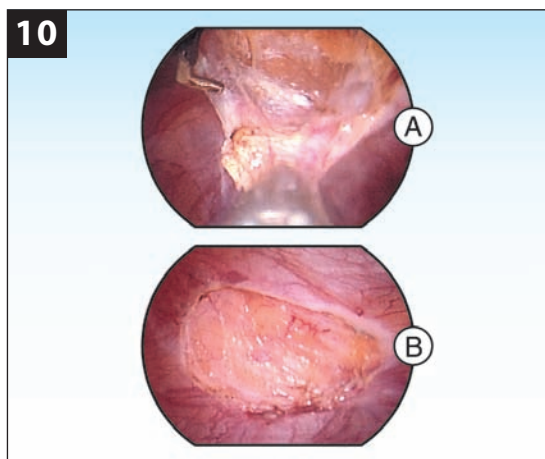
Vaporization has been used to vaporize to the level of healthy fat. Many surgeons find this depth to be very confusing and potentially dangerous. I took almost 3 years learning what vaporizing fat looked like. That concept has been useful for superficial lesions, but not for deep lesions, as the margins were not sufficiently clear due to thermal distortion.

Excision has been a useful technique. Sharp dissection with scissors, incisions with monopolar electro-surgery and incision with lasers have all been useful. Sharp scissors followed by bipolar electro-surgery are available in most operating rooms (Figure 7). Bipolar scissors are useful when the expense of disposable instruments can be justified. Lasers are useful but difficult to learn and expensive to maintain. The bleeding from the incised peritoneum usually stops spontaneously. If the incised area continues to bleed, superficial coagulation with bipolar forceps can be performed by touching the base of the lesion with a bipolar coagulator while keeping the blades slightly apart. Simultaneous irrigation and coagulation of small blood vessels with small, bipolar-irrigator forceps is also effective (Figure 8).

Excision begins by moving the tissue away from other structures. If this is close to the ureter, the lesion is pulled medially or laterally away from the ureter. When close to bowel, it is generally pulled laterally. If moving this away from the ureter or bowel also moves the ureter or bowel, the chance that these are involved increases and preparations need to be made for the possibility of ureteral or bowel surgery. As long as the lesion pulls away easily, scissors or other cutting devices are used to cut to the healthy peritoneum away from the margin of the lesion. The subcutaneous tissue is then dissected and cut when needed and the lesion is lifted up and away from the deeper tissue. The lesion is then removed and sent for pathology.



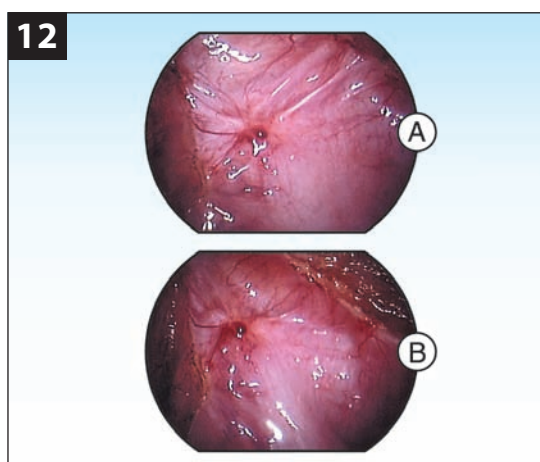
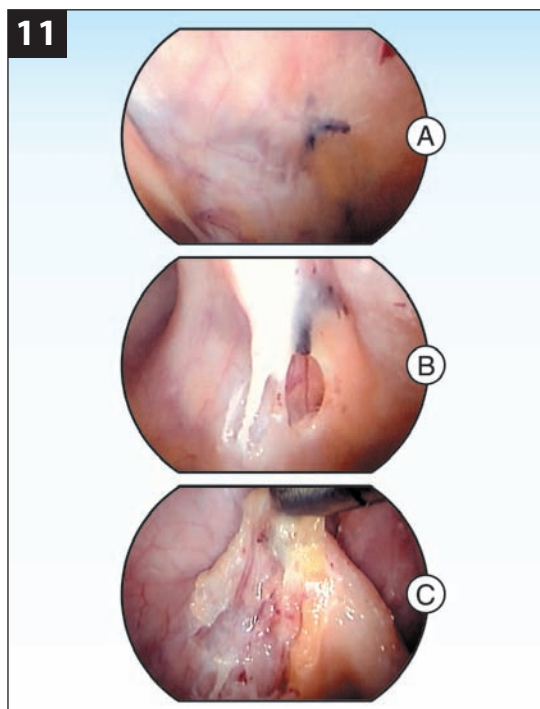
In the first example of incision, a broad white lesion is seen in the peritoneum. The lesion is grasped and pulled away from the sidewall. An initial incision is made into the peritoneum using cutting current with a hook electrode (Figure 9). Needle electrode, electro-surgical scissors, laser, bipolar scissors, and other modalities would be just as useful. Dissection of the loose connective tissue is continued using a combination of the monopolar electrode and blunt dissection. The loose connective tissue is often



easy to see and dissection is maintained in this level for accuracy and safety. At the end of the excision, a crater is seen with healthy loose connective tissue, fat at the base, and minimal coagulation in the perimeter of peritoneum (Figure 10).

A second example of excision is a lesion near the rectosigmoid colon. This lesion was resected using a combination of bipolar scissors and sharp dissection. An initial opening was made into the peritoneum and the lesion lifted upward. The loose connective tissue was dissected until the lesion moved away from the sigmoid. As that occurred, the sigmoid fell to the lower part of the field and the endometriosis was lifted up. Dissection continued in the loose connective tissue and fat between these two areas (Figure 11).

However, as with superficial peritoneal lesions, if the tissue moves beneath these, dissection is avoided. What appears to be a superficial lesion is over the rectosigmoid colon (Figure 12 A). However, when this lesion is lifted up and to the left, the rectosigmoid tents



toward the lesion (Figure 12 B). This suggests muscularis involvement. This lesion was not treated at this time.

Dissection at laparoscopy can be performed when visualization is adequate to differentiate loose connective tissue and fat from the appearance of endometriosis



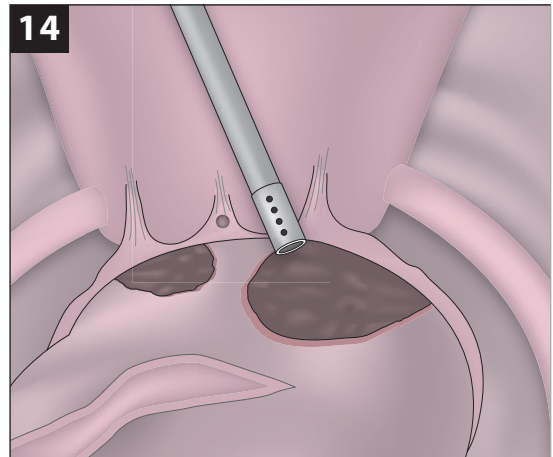
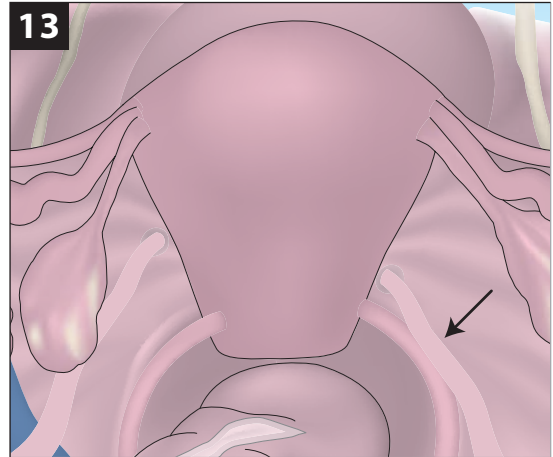
and the associated fibro-muscular metaplasia. On the other hand, manual palpation at laparotomy increases recognition of deep lesions, subperitoneal nodules, epiploic fat nodules, endometriosis in the mesentery appendix, and infiltrating bowel lesions. Almost half of the appendiceal lesions I have found by palpation rather than visualization. I have missed as many as 20 nodules in the bowel at laparoscopy that were found at laparotomy.

### MEDIAL DEVIATION

Of specific note, medial deviation of the ureter has been found in up to 25% of patients with endometriosis (Figure 13). This may be more than 50% of those with broad ligament recesses. Be careful to identify the ureter in the presence of a broad ligament recess. The ureter is usually the medial margin of the recess and may be confused with the uterosacral ligament. After a round structure in this area is identified, follow it into the upper pelvis. The ureter should go over the pelvic brim and the uterosacral ligament deep into the pelvis. If the uterosacral ligament ascends over the pelvic brim, it is not the uterosacral.

### EXCISION VS. COAGULATION

There is an ongoing debate in the literature about the merits of coagulation as opposed to excision. The Cochrane Database concludes that excision is preferred for ovarian endometriomas. But there is no consensus on the treatment of peritoneal lesions. Moreover, there is inadequate data on deep lesions as there



is no practical way to define deep without excision. Although moving the lesion can be a guide to the depth, the only way to confirm that the lesion is superficial or deep is to excise it.

### RETROCERVICAL ENDOMETRIOSIS

Retrocervical endometriosis may be easier to palpate in the office than to find at surgery. Careful mapping and intraop-

erative palpation may help better identify these lesions (Figure 14).

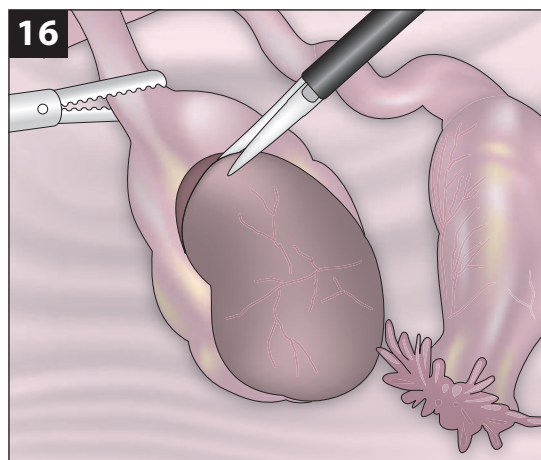
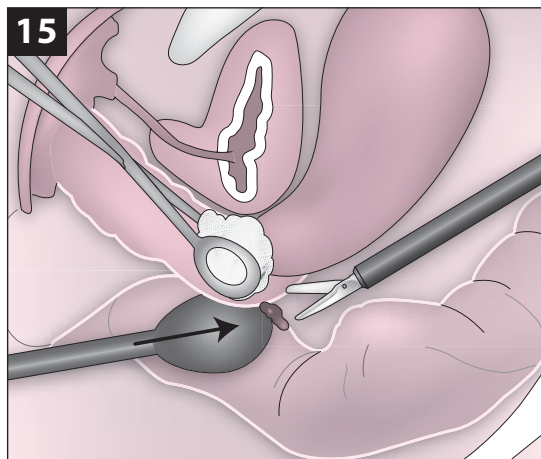
A rectal probe can be placed in the rectum and a sponge stick in the vagina. This combination of instruments helps define the relationships of the lesions, vagina, and rectum. This facilitates dissection and resection in the Pouch of Douglas (POD) (Figure 15). When there is no rectal involvement, the sponge stick in the vagina can be seen between the rectal probe and the lesion. If the lesion extends to the vagina, a combined laparoscopic and vaginal approach may be useful.

When retrocervical endometriosis extends to the bowel, there is either partial or complete obliteration of the POD. With partial POD obliteration, the vaginal probe can still be seen in part of the POD but not through the entire POD. When there is complete POD obliteration, the rectum can be pushed toward the laparoscope but the tip of the vaginal probe is not seen. When there is any degree of POD obliteration with involvement of the bowel, preparations for rectal surgery are needed. In many centers this will be done at laparotomy.

## OVARIAN LESIONS

Ovarian lesions can infiltrate or invaginate into the ovary. Coagulation or vaporization may be useful when these are superficial. With deeper penetration, stripping or drainage of the chocolate cyst followed by coagulation of the inner lining may be more reasonable.

Stripping of the pseudo-capsule of an endometrioma begins by opening it. This



can be done in a linear or rounded fashion. The advantage of a round or oval opening is in identifying the demarcation between healthy ovary and endometrioma (Figure 16). A linear incision directly across the endometrioma may have only abnormal tissue in the incisional area.

Once the demarcation zone between healthy tissue and the endometriotic pseudo-capsule is recognized, slow tension is placed on both edges (Figure 17). If tension is inadequate to produce separ-

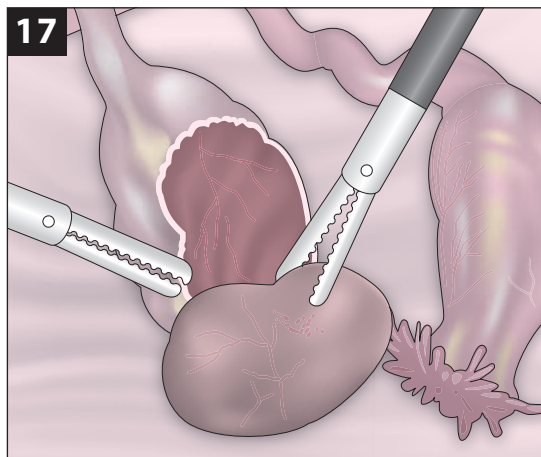
ration, a third instrument can be used to dissect between the first two. This can be a pusher, spreader, or scissors. If dissection is near the hilum, extra care is needed to avoid opening the hilar vessels. If dissection is difficult in the hilar area, the endometrioma is amputated so that the deep portion is left attached to the vessels. This is to avoid excessive bleeding and damage to the ovary. This portion is coagulated.

When diagnosing chocolate cysts, a distinction between a corpus luteum and an endometrioma is clinically important for informing the patient and for long term planning. A corpus luteum generally has a clot and a more uniformly brown base. Endometriosis has free flow of dark, chocolate-like material. The wall is mottled and is generally brown with red areas on a white pseudo-capsule. The wall appearance is seen after washing the inner lining. Ongoing correlation with histology is needed in order to maintain quality control and to confirm recognition.

After stripping or coagulation of the base, sutures are avoided. Healing appears to be better without sutures than with them. Sutures appear to increase the chance of adhesions.

## ENDOMETRIOSIS AND STERILIZATION PROCEDURES

Although endometriosis is frequently described as a progressive disease, it may be progressive, stable, or regressive at any point in time. Over time, the course may change with regressing lesions changing to progressing or progressing lesions



changing to regressing. This has been seen in both humans and animals. Due to the possibility of progression, treatment in asymptomatic patients undergoing sterilization may be reasonable. On the other hand, Moen has shown that asymptomatic patients with endometriosis that was found while undergoing sterilization do not differ significantly from other patients over the next 12 to 15 years.

As a possible concern, some sterilization history and physical forms are shorter than those for more extensive surgery. Careful history for cramps and pain and exam for tenderness as part of a pre-operative evaluation for sterilization may avoid classifying pain patients as asymptomatic.

## COMPLETION OF SURGERY

At the completion of surgery, considerations for flotation and adhesion prevention barriers may be important. Perry has shown that instillation of 1 L to 2 L of fluid at the end of the laparoscopy significantly decreases the frequency of sub-

---

diaphragmatic and shoulder pain when sitting or standing. Flotation is used for this reason in my patients. There is also a chance that flotation may decrease adhesions between surfaces by letting them move easily across each other.

Surgical barriers such as Interceed™ (Johnson & Johnson Medical, Sommerville, NJ) or flotation with 1000 cc of Ringer's lactate may physically represent a barrier between tissue margins. There is potential for decreasing adhesions and Interceed™ has been used for this purpose. This requires complete hemostasis and is not generally used with flotation. I do place a small amount of solution at the end of the procedure in order to displace gas. I try to limit this so that it will not also float the Interceed™.

## CONCLUSIONS

In summary, laparoscopy is excellent for superficial lesions and deep lesions, which can be dissected while avoiding bowel, ureter, ovarian hilar vessels, tubal fimbria, and tubal lumen. Deeper lesions and those involving the serosa or muscularis of the bowel require extended experience and time. Those may be better treated at laparotomy.

## SUGGESTED READING:

ACOG Committee Opinion, Number 310, Endometriosis in Adolescents, April 2005

ACOG Practice Bulletin Number 11, Medical Management of Endometriosis, December 1999

ASRM, Practice Committee of the ASRM. Endometriosis and Fertility. *Fertility & Sterility* 2004; 81: 1441-1446.

Martin DC, Khare VK, Parker L. Clear and opaque vesicles: endometriosis, psammoma bodies, endosalpingiosis or cancer? In Coutinho E, Spinola P, De Moura L, Hanson (eds): *Progress in the Management of Endometriosis: The Pathenon Publishing Group, New York, 1994*, pp 129-132.

Hart R, Hickey M, Maouris, P, et al. Excisional surgery versus ablative surgery for ovarian endometriomata: A Cochran Review. *Human Reproduction* 2005; 20: 3000-3007.

Hoshiai H, Ishikawa M, Sawatari Y, Noda K, Fukaya T. Laparoscopic evaluation of the onset and progression of endometriosis. *Am J Obstet Gynecol* 1993;169:714-719.

Karnaky KJ. Theories and known observations about hormonal treatment of endometriosis-in-situ, and endometriosis at the enzyme level. *Arizona Medicine* 1969; 26:37-41

Kennedy S, Bergqvist A, Chapron C, et al. ESHRE guideline for the diagnosis and treatment of endometriosis. *Human Reproduction* 2005; 20: 2698-2704

Martin DC, Hubert GD, Vander Zwaag R, El-Zeky FA. Laparoscopic appearances of peritoneal endometriosis. *Fertil Steril* 1989; 51:63-67

Martin DC, Ahmic R, El-Zeky FA, Vander Zwaag R, Pickens MT, Cherry K. Increased histologic confirmation of endometriosis. *J Gynecol Surg* 1990; 6:275-279

Moen MH. Endometriosis in women at interval sterilization. *Acta Obstet Gynecol Scand* 1987;66:451-454.

Moen MH, Stokstad T. A long-term follow-up study of women with asymptomatic endometriosis diagnosed incidentally at sterilization. *Fertil Steril* 2002;78:773-776.

Perry CP, Tombrello R. Effect of fluid instillation on post laparoscopy pain. *J Reprod Med* 1993; 38:768-770

Phipps JH. Thermometry studies with bipolar diathermy during hysterectomy. *Gynaecol Endosc* 1994; 3:5-7

Pierce JA. *Electrosurgery*. Chapman & Hall. London. 1986.

Ryder RM, Hulka JF. Bladder and bowel injury after electrodesiccation with Kleppinger bipolar forceps. *J Reprod Med* 1993; 38:595-598

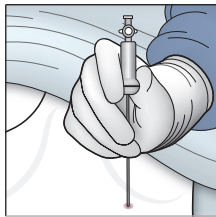
Batt RE, Mitwally MF. Endometriosis from thelarche to midteens: pathogenesis and prognosis, prevention and pedagogy. *J Pediatr Adolesc Gynecol* 2003;16:333-347

<http://www.danmartinmd.com/endometriosis.htm>

[http://www.memfert.com/color\\_atlas.htm](http://www.memfert.com/color_atlas.htm)

<http://www.memfert.com/ColorAtlasLAE1990.pdf>

# LAPAROSCOPIC SURGERY FOR ADHESIONS



*Harry Reich, M.D.*  
*Lisa M. Roberts, M.D.*  
*Enda McVeigh, M.D.*

## INTRODUCTION

**A**dhesions may be defined as abnormal attachments between tissues and organs. They can be either congenital or acquired. Acquired adhesions develop in response to trauma to the peritoneum either as a result of surgery or inflammation. Postoperative adhesions may occur after almost every abdominal surgery and are the leading cause of intestinal obstruction. Adhesions are almost an inevitable consequence of peritoneal surgery. In one study, 93% of patients who had undergone at least one previous open abdominal operation had post surgical adhesions. This is not surprising, given the extreme delicacy of the peritoneum and the fact that apposition of two injured surfaces nearly always results in adhesion formation.

Adhesiolysis should be undertaken to relieve the symptoms of adhesions only in selected cases. For example, good results can be achieved with ovarian adhesiolysis in improving fertility in women. Division of the adhesions around the ovary has been shown to increase pregnancy rates by over 50%. The effectiveness of adhesiolysis in treating chronic pain is

less clear. From recent evidence, it would appear that adhesiolysis is no more effective in relieving pain than diagnostic laparoscopy, which therefore brings into question its efficacy in cases of chronic pain. This is a significant finding as the majority of adhesion-related readmissions are associated with pain. In addition, adhesiolysis itself is associated with a high risk of adhesion reformation. Therefore, clearly it is better to prevent adhesions from forming in the first place rather than treat adhesions once they have occurred.

Although for many patients, most adhesions have little or no detrimental effect, a sizeable proportion of cases lead to serious short and long term consequences. Adhesions are the most common cause of bowel obstruction and most likely result from gynecologic procedures, appendectomies, trauma, and other intestinal operations. Adhesions have also been proposed as a cause of infertility and abdominal and pelvic pain. Although nerve fibers have been confirmed in pelvic adhesions, their presence is not increased in those patients with pelvic pain. In addition, there does not appear to be an association between the severity of adhesions and the complaint of pain. It is generally accepted that adhesions may impair organ motility resulting in visceral pain transmitted by peritoneal innervation. Many patients experience resolution of their symptoms after adhesiolysis. This may be complicated by placebo effect as demonstrated by one study that showed no difference in pain scores between patients who

were randomized to adhesiolysis versus expectant management.

In 1994, adhesiolysis procedures resulted in 303,836 hospitalizations, 846,415 days of inpatient care, and \$1.3 billion in health care expenditures. Of these hospitalizations, 47% were for adhesiolysis of the female reproductive system, the primary site for these procedures. In comparison to similar data from 1988, the cost of adhesiolysis hospitalizations is down. One significant influence on this trend is the increased use of minimally invasive surgical techniques resulting in fewer days of inpatient care.

This chapter reviews the epidemiology and pathophysiology of adhesion formation, the equipment and technique for adhesiolysis, and methods for adhesion prevention.

## EPIDEMIOLOGY OF ADHESIONS

Over the 10 years of this study, over one third (34.7%  $n=10,326$ ) of the 29,790 patients who underwent open surgery were readmitted a mean of 2.1 times for complications directly or possibly related to adhesions. Of the total number of readmissions (21,347), 5.7% were directly related to adhesions. Readmissions occurred within the first year in 22.1%.

## EPIDEMIOLOGY AND PATHOPHYSIOLOGY OF ADHESION FORMATION

The publication of the data from the Surgical and Clinical Adhesions Reduction (SCAR) study in 1999 suggested the epi-

demology of adhesions as an iatrogenic disease to be better understood. Adhesion-related readmissions were identified over a 10-year period and were categorized as being:

1. directly related to adhesions (adhesiolysis and non-operative readmissions for adhesions)
2. possibly related (selected gynecological operations, selected abdominal surgery)
3. selected non-operative readmissions, or readmissions potentially complicated by adhesions (leading to open or laparoscopic procedures).

One of the most important aspects of the SCAR study is the long-term perspective, providing information on the timing of adhesion-related complications. In all groups adhesion-related readmissions increased in a linear fashion with time. After a rapid increase in adhesion-related readmissions over the first 1 or 2 years, the rate of readmission continued to increase steadily. Previous studies have also shown that adhesion-related complications can occur 10 years after the initial surgical procedure. Laparoscopic surgery was not widely used in 1986. SCAR 2 (Surgical and Clinical Adhesion Research Study 2) was a follow up study that assessed the burden of adhesion-related readmissions during a period ten years later than that used in the original SCAR study and compared the overall extent of adhesion-related readmissions following laparoscopic gynecological surgery with open gynecological surgery. Gynecological laparoscopy as well as

open surgery was shown to carry significant risks of adhesion-related readmissions.

These epidemiological data show that adhesion formation results in a significant number of readmissions following both laparoscopic and open surgery and that the risk of adhesion-related complications extends for many years after the initial procedure. There is, therefore, a need for clinically and cost effective strategies to help reduce the development of adhesions.

The Scottish National Health Service Morbidity Record (SMR1) studied a cohort of patients who underwent open abdominal or pelvic surgery in 1986. Adhesion formation is initiated following localized injury to the mesothelial layer of the peritoneum. Bleeding and leakage of plasma proteins lead to fibrin deposits at the injury site, which is augmented by post-traumatic inflammation. Within hours at the site of injury, inflammatory cytokines, predominately interleukins and tumor necrosis factor, attract and activate macrophages to release vascular permeability factor. Simultaneous release of histamine and kinins increases the level of vascular permeability leading to inflammatory exudation with fibrin deposition on the peritoneal surface. By day two, the wound surface is covered by macrophages, islands of primitive mesenchymal cells and mesothelial cells. The enlarging fibrin mesh may attach to an adjoining surface, a process that is counteracted by locally synthesized fibrolytic factors. Depending on the local



peritoneal conditions, the fibrin mesh can either be degraded, resulting in scarless repair, or transformed into an adhesion consisting of connective tissue. If the fibrin is degraded within a few days, the defect heals without scarring. If it is allowed to enlarge for a sufficient period of time, it will reach other tissue surfaces and form a bridge between them, transforming the initially reversible fibrous adhesion into a fibrous, collagen-containing structure. The adhesion continues to mature as collagen fibrils organize into bands covered by mesothelium that contain blood vessels and connective tissue fiber.

## LAPAROSCOPIC PERITONEAL CAVITY ADHESIOLYSIS

The technique emphasized in this chapter for adhesiolysis with the least possibility for reformation is simply described as ‘cold scissors dissection with bipolar backup’. We believe that it is better to avoid the time honored technique of “grasp, coagulate, then cut”. Substitute the concept of “cutting where bleeding is least likely”. Magnification and close inspection through the laparoscope makes this possible. Think like an adhesion and then go backwards. Remember that tissue ischemia caused by thermal energy is the enemy!

Adhesiolysis by laparoscopy and laparotomy can be very time-consuming and technically difficult and is best performed by an experienced surgeon. However, despite lengthy laparoscopic procedures, most patients are discharged

on the day of the procedure, avoid large abdominal incisions, experience minimal complications, and return to full activity within one week of surgery.

In this section, general adhesiolysis, enterolysis, pelvic adhesiolysis, ovariolysis, salpingo-ovariolysis, and salpingostomy are described. The laparoscopic treatment of acute adhesions has not been included. However, the best treatment for sexually transmitted disease adhesive sequelae may be prevention through early laparoscopic diagnosis and treatment of acute pelvic infection, including abscesses. Acute adhesiolysis will often prevent chronic adhesion formation.

## EQUIPMENT

A review of standard equipment such as light sources and video systems is beyond the scope of this chapter. Equipment useful for advanced procedures and energy sources is included.

## LAPAROSCOPES

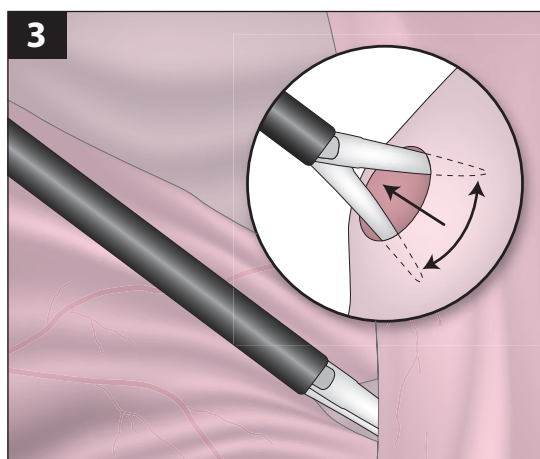
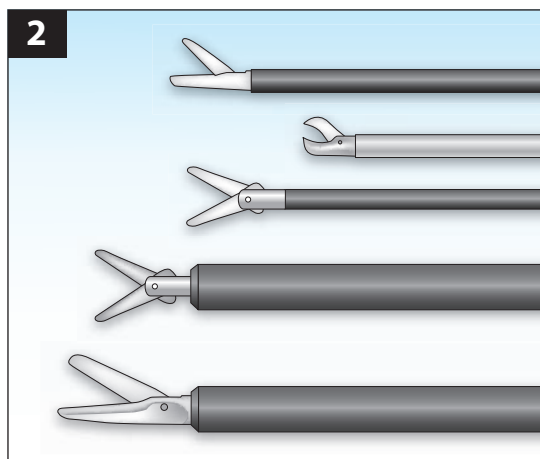
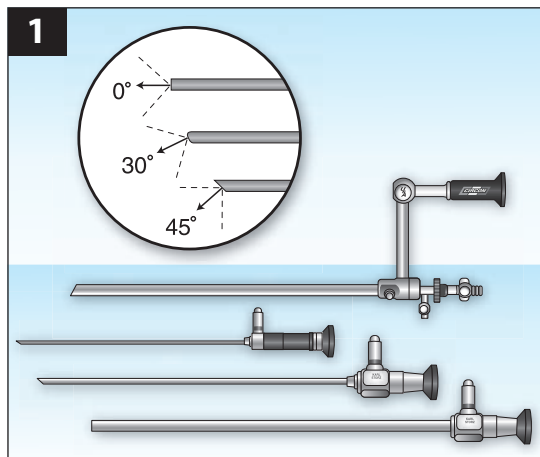
Four laparoscopes are recommended for adhesiolysis: a 5 mm and a 10 mm 0° straight viewing laparoscope; a 10 mm operative laparoscope with 5 mm operating channel; and an oblique-angle laparoscope (30°-45°) for upper abdominal and pelvic procedures (Figure 1).

## SCISSORS

Scissors are the preferred instrument to cut adhesions, especially avascular and/or congenital adhesions (Figure 2). Using the magnification afforded by the laparoscope, most anterior abdominal

wall, pelvic, and bowel adhesions can be carefully inspected and divided with minimal bleeding, rarely requiring electrosurgical energy. Loose fibrous or areolar tissue is separated by inserting a closed scissors and withdrawing it in the open position. (Figure 3) Tissue is pushed with the partially open blunt scissors tip to develop natural planes. Reusable 5 mm blunt-tipped saw tooth scissors and curved scissors cut well without cautery. Blunt or rounded-tip 5 mm scissors with one stable blade and one moveable blade are used to divide thin and thick bowel adhesions sharply. Sharp dissection is the primary technique used for adhesiolysis to diminish the potential for adhesion formation; electrical energy, harmonic scalpel and laser are usually reserved for hemostatic dissection of adhesions where anatomic planes are not evident or vascular adherences are anticipated. Thermal energy sources must be avoided as much as possible to reduce adhesion recurrence. Blunt-tipped, saw-tooth scissors, with or without a curve, cut well (Richard Wolf Medical Instruments, Vernon Hills, IL and Karl Storz Endoscopy, Culver City, CA). Hook scissors are for cutting suture and are not very useful for adhesiolysis.

Surgeons should select scissors that feel comfortable. The scissors should not be too long or encumbered by an electrical cord to facilitate direction changes. Rapid instrument exchanges between scissors and microbipolar forceps through the same portal are used to control bleeding, instead of applying electrical energy via scissors.



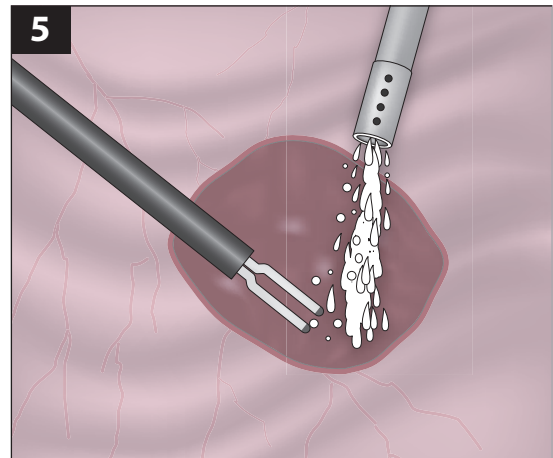
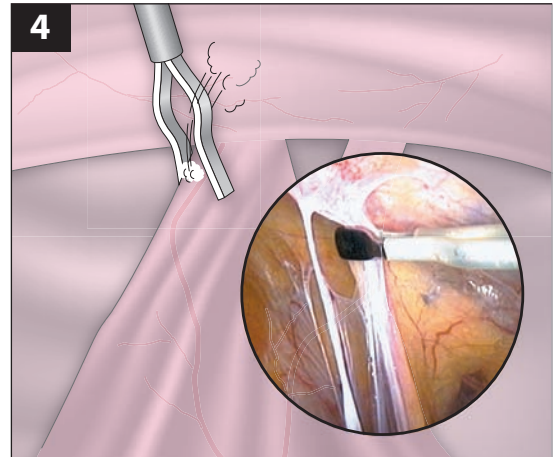
## ELECTROSURGERY

Monopolar cutting current can be used safely, as the voltage is too low to arc to organs even 1 mm away. Cutting current is used both to cut and/or coagulate (desiccate) depending on the portion of the electrode in contact with the tissue. The tip cuts, while the wider body tamponades and coagulates.

Monopolar coagulation current uses voltages over 10 times that of cutting current and can arc 1-2 mm. Thus, the use of coagulation current should be minimized during adhesion surgery.

Electrosurgical injury to the bowel can occur beyond the surgeon's field of view during laparoscopic procedures from electrode insulation defects or capacitive coupling. (See Chapters 6 and 34) Bipolar desiccation using cutting current between two closely opposed electrodes is safe and efficient for large vessel hemostasis. Large blood vessels are compressed and bipolar cutting current passed until complete desiccation is achieved, i.e., the current depletes the tissue fluid and electrolytes and fuses the vessel wall (Figure 4). Coagulating current is not used as it may rapidly desiccate the outer layers of the tissue, producing superficial resistance thereby preventing deeper penetration.

Small vessel hemostasis necessary for adhesiolysis is best achieved by using micro bipolar forceps after precisely identifying the vessel with electrolyte solution irrigation. Micro bipolar forceps with an irrigation channel work best for precise tissue desiccation with minimal thermal spread (Figure 5).

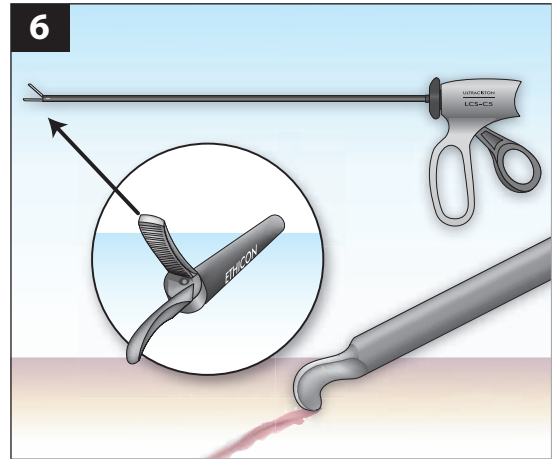


## HARMONIC SCALPEL

The use of the Harmonic Scalpel (Ethicon Endosurgery, Cincinnati, Ohio) for laparoscopic adhesiolysis has gained popularity. Many factors can be attributed to its progressive acceptance. The mechanical energy used to coagulate vessels with a potentially smaller (2 mm) lateral thermal energy spread make it more attractive than conventional electrosurgical instruments to some surgeons who believe that its use may reduce postoper-

ative bowel injuries caused by thermal injury. This is not to say, however, that injury cannot occur. As with standard electrosurgical instruments, the harmonic scalpel, specifically the jaws, can become hot and cause tissue injury if not used in a prudent manner. Although the harmonic scalpel has the ability to grasp, cut, and cauterize simultaneously, making it a useful instrument for a judicious operator (requiring fewer instrument changes in and out of port sites), the inability to cut without applying energy assures the need for a sharp pair of conventional scissors in laparoscopic adhesiolysis.

For adhesiolysis, it bears repeating that the harmonic scalpel is not a scissor. This instrument works by coagulating tissue in between the blades and allowing it to be 'pressed apart' after full coagulation of the tissue between the active blade and the compressing surface. Tissue is first grasped between the blades of the harmonic scalpel, steadily compressed, and the blade is activated allowing the tissue to separate once it is fully coagulated. Any tissue between the blades of the harmonic scalpel will be heated and then be allowed to fall apart. This includes all blood vessels up to 3 mm in diameter incorporated in the tissue between the blades. As stated before, the harmonic scalpel can be used to grasp tissue in a general manner when the blades are not active. However, prior to grasping any tissue, the operator must allow the active blade to cool sufficiently so it will not burn any tissue with which it may come in contact. The Harmonic scalpel comes in 5- and 10-mm size instrumentation



with active jaws as well as adaptable adjuncts to the instrument such as a spatula type dissector, 'ball' type dissector and hook dissector (Figure 6). All of these type instruments can be used in the same location as you would normally use a monopolar electrode; bear in mind once again that the lateral energy spread is only 2 mm with the harmonic scalpel.

## RECTAL AND VAGINAL PROBES

A sponge on a ring forceps is inserted into the vagina or the posterior vaginal fornix, and an 81-French probe is placed in the rectum to define the rectum and posterior vagina for lysis of pelvic adhesions and/or excision of endometriosis when there is a significant degree of cul-de-sac obliteration. Whenever the rectal location is in doubt, it is identified by insertion of the rectal probe (Figure 7).

## CO<sub>2</sub> LASER

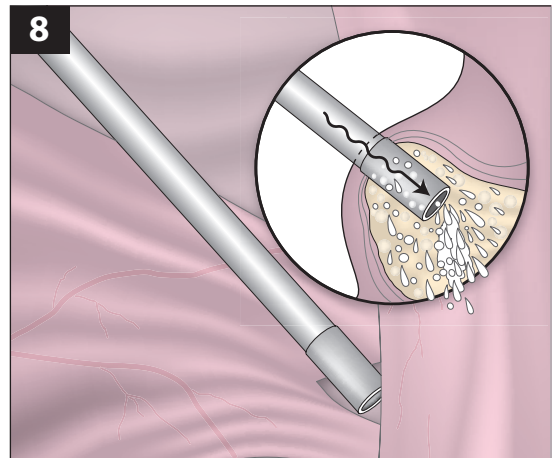
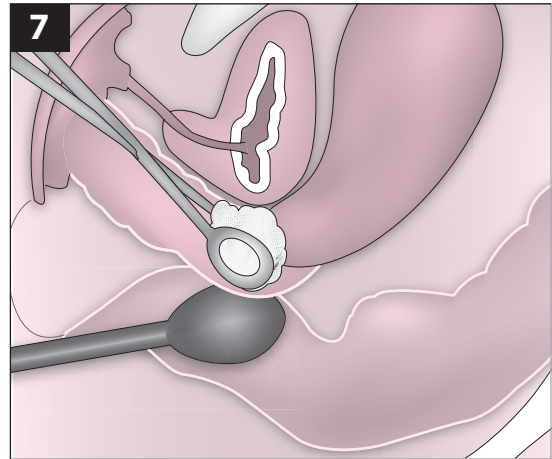
The CO<sub>2</sub> laser, with its 0.1 mm depth of penetration and inability to traverse through fluid, allows the surgeon some

security when lysing adhesions especially in the pelvis. The Coherent 5000L laser (Palo Alto, CA), by using a 11.1  $\mu\text{m}$  wavelength beam, maintains a 1.5 mm spot size at all power settings allowing for more precision than most standard 10.6  $\mu\text{m}$  wavelength CO<sub>2</sub> lasers.

### AQUA DISSECTION

This technique was a major advance early in the learning curve but is used less frequently as expertise in adhesiolysis is acquired. Aqua dissection is the use of hydraulic energy from pressurized fluid to aid in the performance of surgical procedures. The force vector is multidirectional within the volume of expansion of the incompressible fluid; the force applied with a blunt probe is unidirectional. Instillation of fluid under pressure displaces tissue, creating cleavage planes in the least resistant spaces (Figure 8). Aqua dissection into closed spaces behind peritoneum or adhesions produces edematous, distended tissue on tension with loss of elasticity, making further division easy and safe using blunt dissection, scissors dissection, laser, or electro-surgery.

Suction-irrigators with the ability to dissect using pressurized fluid should have a single channel to maximize suctioning and irrigating capacity. This permits the surgeon to perform atraumatic suction-traction-retraction, irrigate directly, and develop surgical planes (aqua dissection). The distal tip should not have side holes as they impede these actions, spray the surgical field without purpose,



and cause unnecessary tissue trauma when omentum, epiploic appendices, and adhesions become caught. The shaft should have a dull finish to prevent CO<sub>2</sub> laser beam reflection, allowing it to be used as a backstop.

### PLUME ELIMINATION

Smoke evacuation during electro-surgery or CO<sub>2</sub> laser laparoscopy is expedited using the suction irrigation cannula.

## CLASSIFICATIONS

Peritoneal adhesiolysis is classified into enterolysis including omentolysis and female reproductive reconstruction (salpingo-ovariolysis and cul-de-sac dissection with excision of deep fibrotic endometriosis). Bowel adhesions are divided into upper abdominal, lower abdominal, pelvic, and combinations. Adhesions surrounding the umbilicus are upper abdominal as they require an upper abdominal laparoscopic view for division. The extent, thickness, and vascularity of adhesions vary widely. Intricate adhesive patterns exist with fusion to parietal peritoneum or various meshes.

Extensive small bowel adhesions are not a frequent finding at laparoscopy for pelvic pain or infertility. In these cases, the Fallopian tube is usually adhered to the ovary, the ovary is adhered to the pelvic sidewall, and the rectosigmoid may cover both. Rarely, the omentum and small bowel are involved. Adhesions may be the result of an episode of pelvic inflammatory disease or endometriosis, but most commonly are caused by previous surgery. Adhesions cause pain by entrapment of the organs they surround. The surgical management of extensive pelvic adhesions is one of the most difficult problems facing surgeons today.

## SURGICAL PLAN FOR EXTENSIVE ENTEROLYSIS

A well-defined strategy is important for small bowel enterolysis. Time fre-

quently dictates that all adhesions cannot be lysed. From the history, the surgeon should conceptualize the adhesions most likely to be causing the pain, i.e., upper or lower abdomen, left or right, and clear these areas of adhesions. Almost always, the anterior abdominal wall adhesions must be released to adequately visualize the peritoneal cavity.

## PREOPERATIVE PREPARATION

Patients are informed preoperatively of the high risk for bowel injury during laparoscopic procedures when extensive cul-de-sac involvement with endometriosis or adhesions is suspected. They are encouraged to hydrate and eat lightly for 24 hours before admission. A mechanical bowel preparation is administered orally the afternoon before surgery to induce brisk, self-limiting diarrhea to cleanse the bowel. The patient is usually admitted on the day of surgery. Lower abdominal, pubic, and perineal hair is not shaved. A Foley catheter is inserted and is removed in the recovery room when the patient is aware of its presence, to prevent bladder distension. Antibiotics (usually cefoxitin) are administered in all cases.

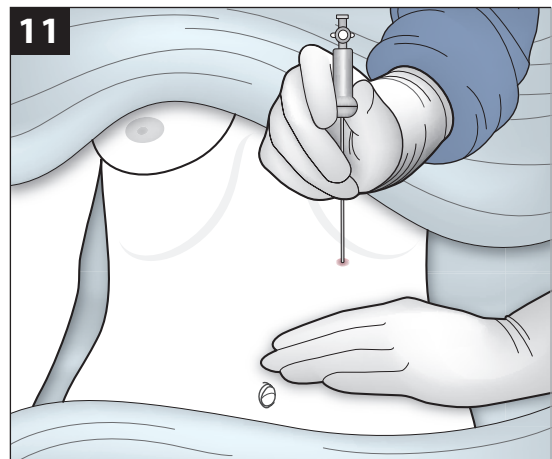
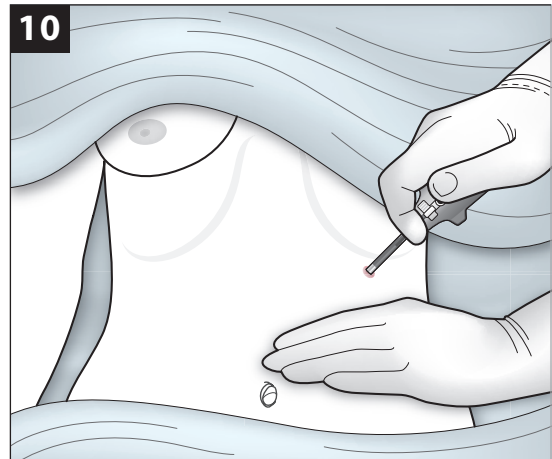
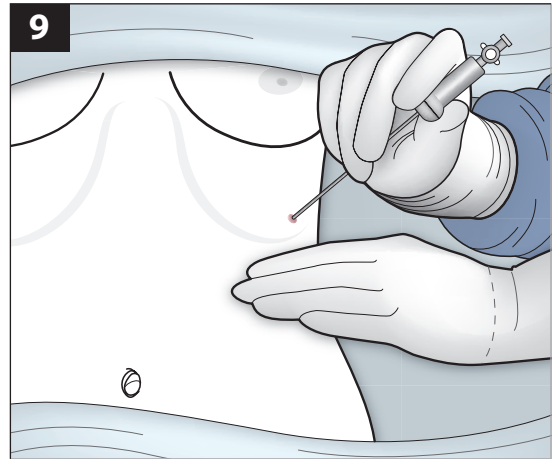
## INCISIONS

Special alternate entry sites and techniques are used when there is a high suspicion for periumbilical adhesions in patients who have undergone multiple laparotomies, have lower abdominal incisions traversing the umbilicus, or who have extensive adhesions either clinically or from a previous operative record.

Open laparoscopy at the umbilicus carries the same risk for bowel laceration if the bowel is fused to the umbilical undersurface. Be aware of a past history of open laparoscopy as more force is often necessary to get the trocar through the umbilical fascia.

One alternate site is in the left ninth intercostal space near the anterior axillary line (Figure 9). Adhesions are rare in this area where the peritoneum is tethered to the undersurface of the ribs, making peritoneal tenting away from the needle unusual. A 5 mm skin incision is made over the lowest intercostal space (the 9th) near the anterior axillary line. The Veress needle is grasped near its tip, like a dart, between thumb and forefinger, while the other index finger spreads this intercostal space. The needle tip is inserted at a right angle to the skin (a 45° angle to the horizontal) between the ninth and tenth ribs. A single pop is felt on penetration of the peritoneum. Pneumoperitoneum to a pressure of 30 mmHg is obtained. A 5 mm trocar is then inserted through this same incision that has migrated downward to below the left costal margin because of abdominal wall distension from the pneumoperitoneum (Figure 10).

Another alternate entry site is Palmer's point located 1 cm inferior to the subcostal arch in the left medioclavicular line (Figure 11). If adhesions are suspected, a 5 mm trocar with a telescope should be inserted in this same space. (See Chapter 5) When unexpected extensive adhesions are encountered initially surrounding the umbilical puncture, the surgeon should



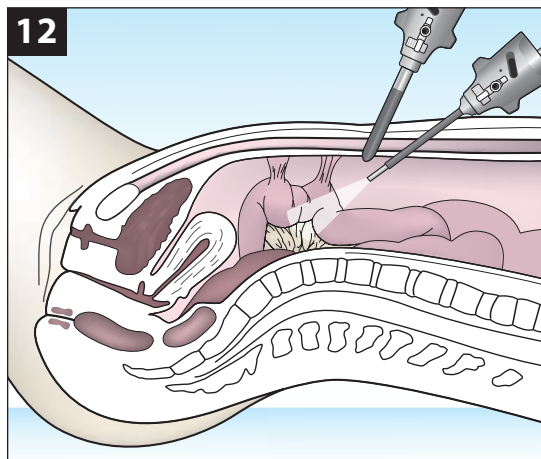
immediately seek a higher site. Thereafter, the adhesions can be freed down to and just beneath the umbilicus, and the surrounding bowel inspected for perforations. An umbilical portal can then be established safely for further work.

Other laparoscopic puncture sites are placed as needed, usually lateral to the rectus abdominis muscles and always under direct laparoscopic vision. If an umbilical insertion is possible and extensive adhesions are present close to, but below the umbilicus, the operating laparoscope with scissors in the operating channel is the first instrument used. If a left upper quadrant 5 mm incision is necessary, there is usually room for another puncture site nearby to insert scissors for initial adhesiolysis.

## ABDOMINAL ADHESIOLYSIS

Anterior abdominal wall adhesions involve the parietal peritoneum stuck to the omentum, transverse colon, and small bowel with varying degrees of fibrosis and vascularity. Adhesions may be filmy and avascular, filmy and vascular, or dense, fibrous and vascular. All of these adhesions to the anterior abdominal wall are released. If adhesions extend from above the level of the laparoscope in the umbilicus, another trocar is inserted above the level of the highest adhesion and the laparoscope is inserted there (Figure 12). Adhesions are easier to divide when working above them, instead of within them.

Adhesiolysis is performed using scissors alone if possible. Electrosurgery,



CO<sub>2</sub> laser, and the harmonic scalpel can also be used. In most cases, the initial adhesiolysis is performed with scissors. CO<sub>2</sub> laser through the laparoscope on adhesions close to the trocar insertion often results in reflection with loss of precision. Electrosurgery (cutting current) is used only when the surgeon is confident that small bowel is not involved in the adhesion.

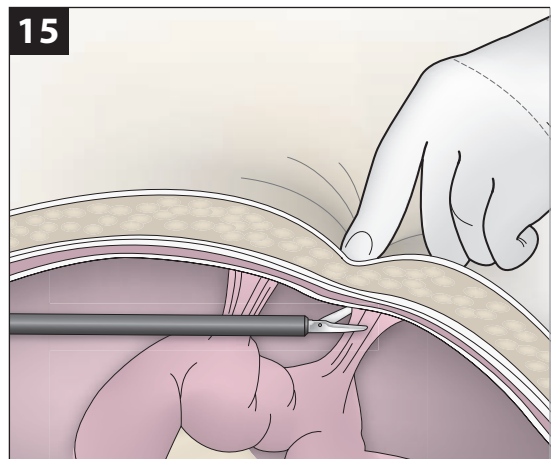
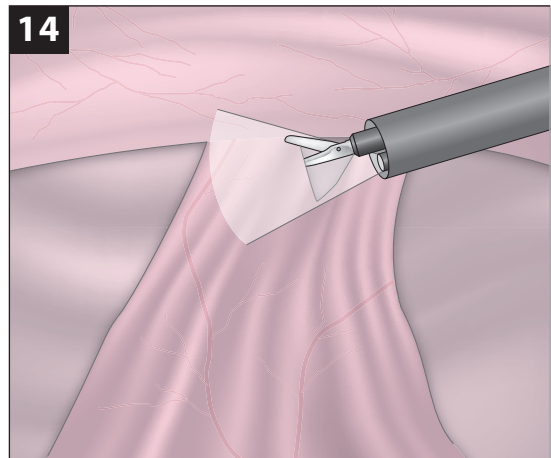
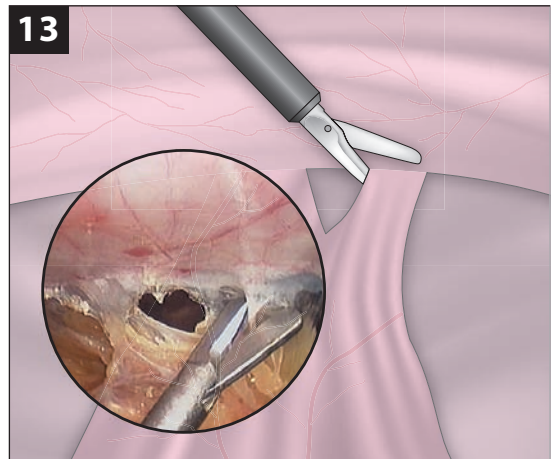
If the patient has an abdominal scar and history of laparotomy, we favor the initial left upper quadrant entry and 5 mm laparoscope placement. Adhesions are rarely encountered at this site. After careful inspection of the abdominal cavity, the site that is free from adhesions is selected for the placement of the secondary trocar. The scissors or the grasper are introduced through the secondary site to free up the adhesions around the umbilical area in order to place the 10 mm trocar with the laparoscope (Figure 13).

Frequently, adhesions can be bluntly divided through the operating channel of the operating laparoscope by grasping



the adhesion in the partially closed scissors, and gently pushing the tissue (Figure 14). If the plane of adhesions cannot be reached with the tip of the scissors, the abdominal wall can be pressed from above with the surgeon or assistant's fingers to make it accessible to the scissors (Figure 15).

After initial adhesiolysis, visualization is improved allowing better access and exposure for further adhesiolysis. Secondary trocar sites can now be placed safely. After their insertion, the remainder of the adhesions can now be lysed using scissors with micro bipolar backup for rare arteriolar bleeders. Small venous bleeders are left alone as they will become hemostatic. On occasion, in operations in which symptomatic bowel adhesions are not the main problem, an electro-surgical spoon or knife is used to divide the remaining omental adhesions if bowel is not involved. If bowel is involved, dissection proceeds with scissors, without electro-surgery, through the second puncture site, aided by traction on the bowel from an opposite placed puncture site (Figure 16). Rarely, the CO<sub>2</sub> laser may be used through the operating laparoscope. When using the CO<sub>2</sub> laser for adhesiolysis, aqua dissection is performed to distend the adhesive surface with fluid before vaporizing the individual adhesive layers. The suction irrigator can also be used for suction traction, instead of a laparoscopic Babcock, and as a backstop to prevent thermal damage to other structures. The suction irrigator is also used to clean the laparoscopic optic, which is

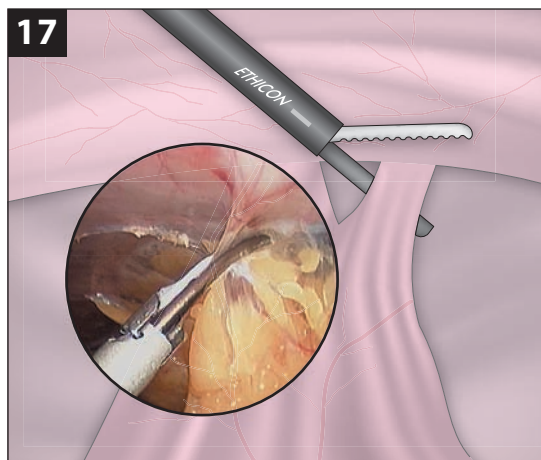
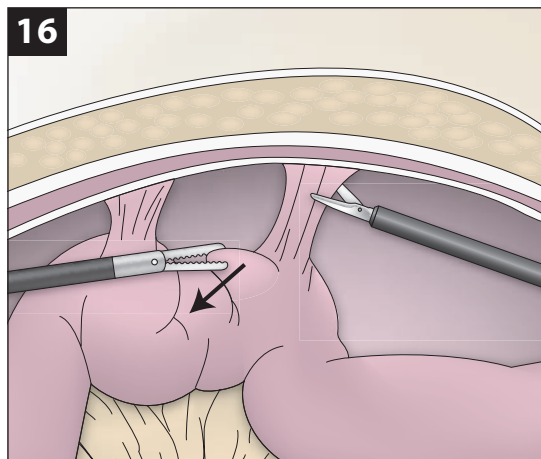


then wiped on the bowel serosa before continuing. Denuded areas of bowel muscularis are repaired transversely using a 3-0 or 4-0 delayed absorbable seromuscular stitch. Denuded peritoneum is left alone. Minimal oozing should be observed and not desiccated unless this bleeding hinders the next adhesiolysis step or persists towards the end of the operation. With perseverance, all anterior abdominal wall parietal peritoneum adhesions can be released.

The harmonic scalpel may be useful for adhesiolysis (Figure 17). But the operator must remember that a harmonic scalpel does not replace the scissor, especially when dealing with bowel into an adhesion plane. Ischemia from thermal energy may result in adhesions during the healing process, regardless of the depth of tissue destruction.

### PELVIC ADHESIOLYSIS

The next step is to free all bowel loops in the pelvis. Small bowel attached to the vesicouterine peritoneal fold, uterus or vaginal cuff, and the rectum is liberated. There are three key points when performing intestinal adhesiolysis within the pelvis: scissors dissection without electro-surgery, countertraction, and blunt dissection. The bowel is gently held with an atraumatic grasper and lifted away from the structure to which it is adhered, exposing the plane of dissection. When adhesive interfaces are obvious, scissors are used. The blunt-tipped scissors are used to sharply dissect the adhesions in small, successive cuts taking



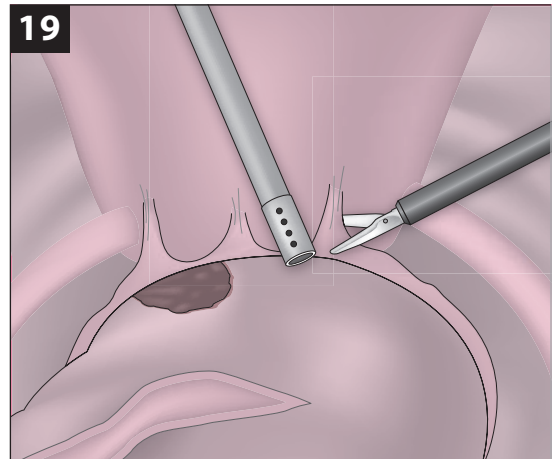
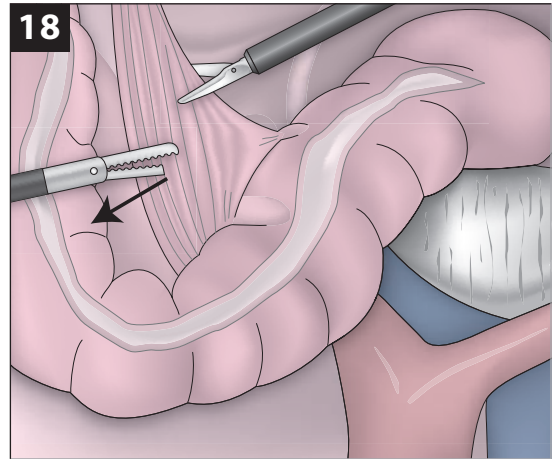
care not to damage the bowel serosa. Countertraction will further expose the plane of dissection and ultimately free the attachment. Electrosurgery and laser are generally not used for adhesiolysis involving the bowel due to the risk of thermal damage and recurrent adhesion formation. However, when adhesive aggregates blend into each other, initial incision is made very superficially with laser, and aqua dissection distends the layers of the adhesions, facilitating identification of the involved structures.

Division of adhesions continues with laser at 10W to 20W in pulsed mode. The aqua dissector and injected fluid from it are used as a backstop behind adhesive bands that are divided with the CO<sub>2</sub> laser.

The rectosigmoid may adhere to the left pelvic sidewall obscuring visualization of the left adnexa. Dissection starts well out of the pelvis in the left iliac fossa. Scissors are used to develop the space between the sigmoid colon and the psoas muscle to the iliac vessels, and the rectosigmoid reflected toward the midline. Thereafter, with the rectosigmoid placed on traction, rectosigmoid and rectal adhesions to the left pelvic sidewall are divided starting cephalad and continuing caudad (Figure 18).

Cul-de-sac adhesions can cause partial or complete cul-de-sac obliteration from fibrosis between the anterior rectum, posterior vagina, cervix, and the uterosacral ligaments. The technique used is to free the anterior rectum to the loose areolar tissue of the rectovaginal septum before excising and/or vaporizing visible and palpable deep fibrotic endometriosis. (Figure 19).

Attention is first directed to complete dissection of the anterior rectum throughout its area of involvement until the loose areolar tissue of the rectovaginal space is reached. Using the rectal probe as a guide, the rectal serosa is opened at its junction with the cul-de-sac lesion. Careful dissection ensues using aqua dissection, suction-traction, laser, and scissors until the rectum is completely freed and identifiable below the lesion.

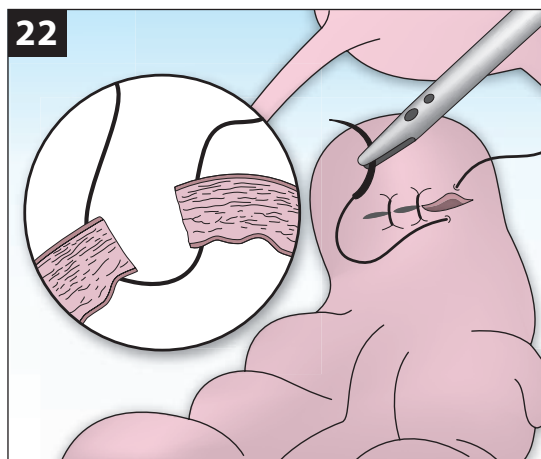
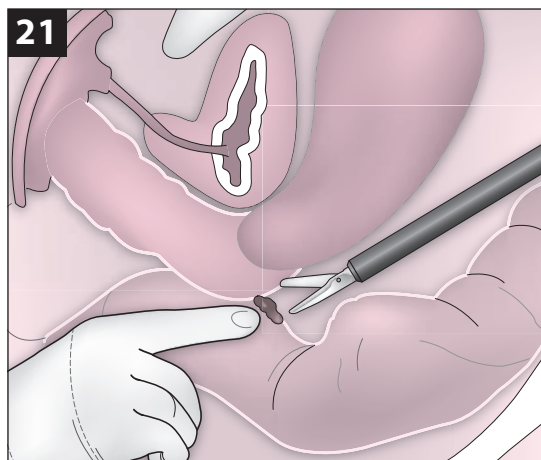
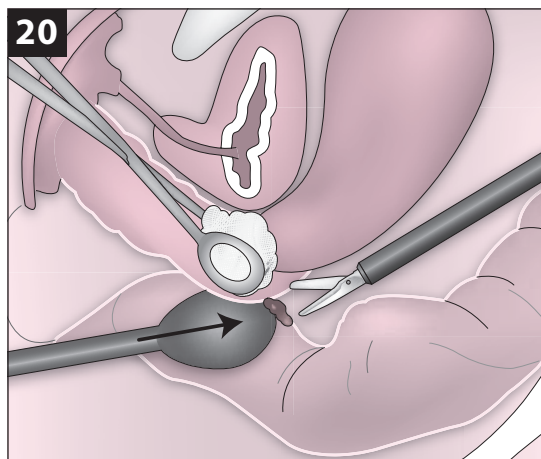


Excision of the fibrotic endometriosis is done only after rectal dissection is completed. Deep fibrotic, often nodular, endometriotic lesions are excised from the uterosacral ligaments, the upper posterior vagina, (the location of which is confirmed by the Valtchev retractor or a sponge in the posterior fornix), and the posterior cervix (Figure 20). The dissection on the outside of the vaginal wall proceeds using laser or scissors until soft pliable upper posterior vaginal wall is uncovered. It is frequently difficult to dis-

tinguish fibrotic endometriosis from cervix at the cervicovaginal junction and above. Frequent palpation using rectovaginal examinations helps identify occult lesions. When the lesion infiltrates through the vaginal wall, an 'en bloc' laparoscopic resection from cul-de-sac to posterior vaginal wall is done, and the vagina is repaired laparoscopically with the pneumoperitoneum maintained by inserting a 30cc Foley balloon in the vagina. Another option is to mobilize the vaginal lesion vaginally, close the vagina over the mobilized portion, and complete the en bloc excision of the lesion laparoscopically. Sometimes the fibrotic cul-de-sac lesion encompassing both uterosacral ligament insertions and the intervening posterior cervix-vagina and anterior rectal lesion can be excised as one en bloc specimen.

Endometriotic nodules infiltrating the anterior rectal muscularis are excised, usually with the surgeon's or the assistant's finger in the rectum just beneath the lesion (Figure 21). In some cases, the anterior rectum is reperitonealized by plicating the uterosacral ligaments and lateral rectal peritoneum across the midline. Deep rectal muscularis defects are always closed with suture. Full thickness rectal lesion excisions are suture repaired laparoscopically (Figure 22).

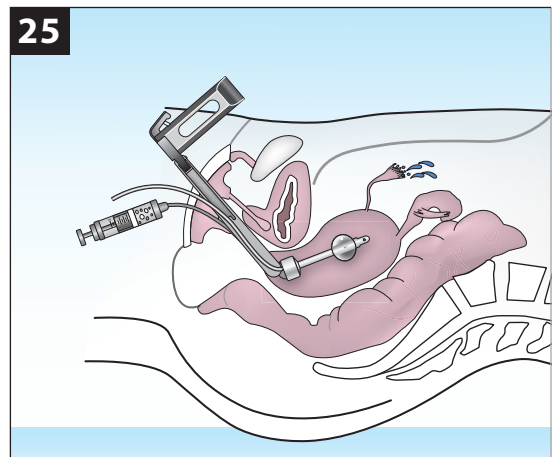
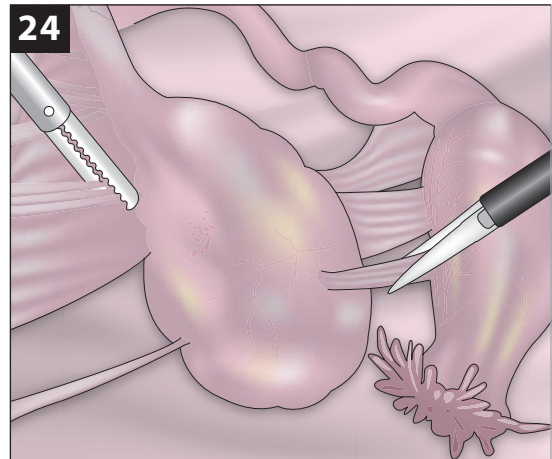
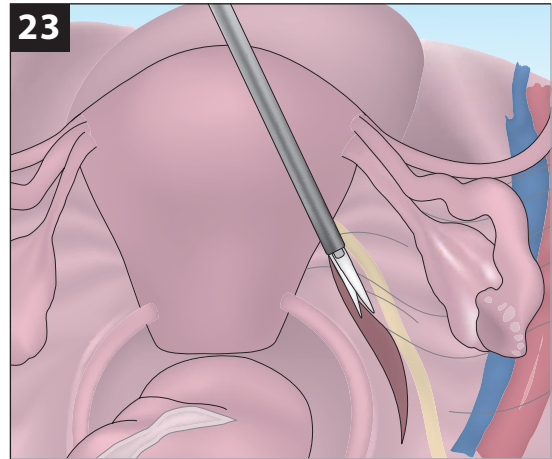
When a ureter is close to the lesion, its course in the deep pelvis is traced by opening its overlying peritoneum with scissors or laser (Figure 23). On the left, this often requires scissors reflection of the rectosigmoid, as previously described, starting at the pelvic brim. Bipolar forceps



are used to control arterial and venous bleeding.

### ADNEXAL ADHESIOLYSIS (SALPINGO-OVARIOLYSIS)

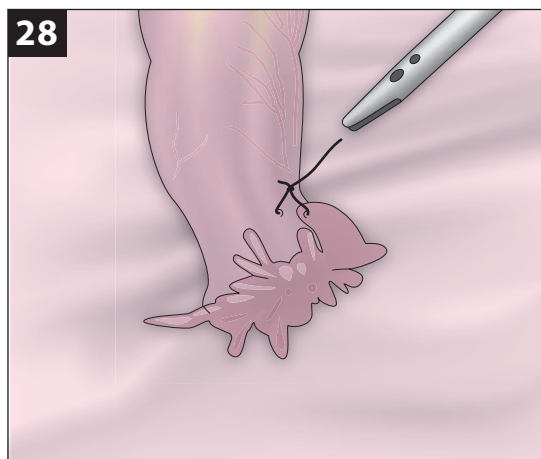
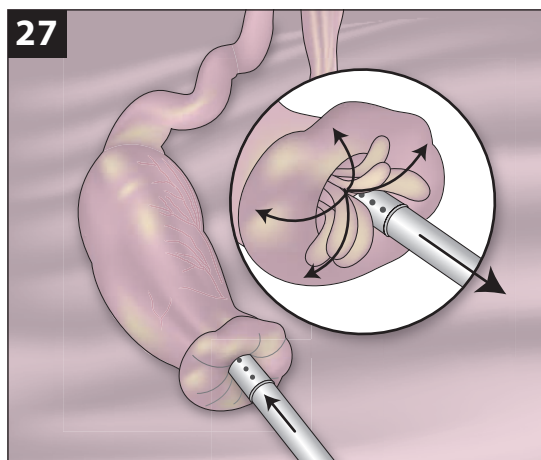
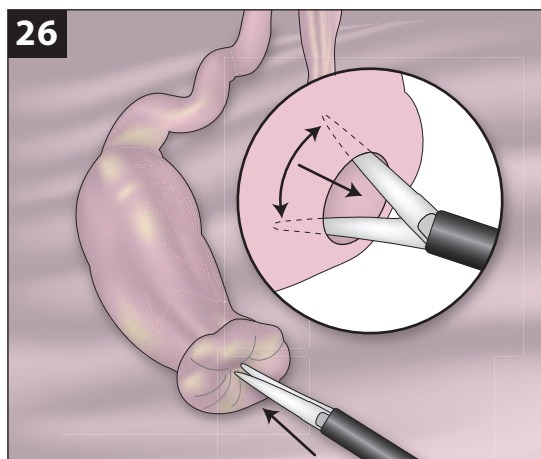
Ovarian adhesions to the pelvic sidewall can be filmy or fused. Initially, adhesions between the ovary and Fallopian tubes and other peritoneal surfaces are identified. It is imperative that the surgeon knows the surrounding anatomy prior to cutting any tissue to avoid damage to vital structures. The plane of dissection is identified and followed to avoid damage to other structures. The uteroovarian ligament may be held with an atraumatic grasper to facilitate countertraction and expose the line of cleavage. During ovariolysis, it is important to preserve as much peritoneum as possible while freeing the ovary. Dissection starts either high in the pelvis just beneath the infundibulopelvic ligament or deep on the pelvic sidewall beneath the ureter in the pararectal space. In each case, scissors are used both bluntly and sharply to mobilize the ovary from the sidewall (Figure 24). Alternatively, aqua dissection may be used to facilitate identification of adhesion layers and to provide a safe backstop for the CO<sub>2</sub> laser. Once an adhesion layer is identified, the aqua dissector can also be placed behind this ridge and used as a backstop during CO<sub>2</sub> laser adhesiolysis. Adhesiolysis is performed sharply and bluntly in a methodical manner working caudad until the cul-de-sac is reached.



If fimbrioplasty is to be performed, then hydro distension is achieved by transcervical injection of dilute indigo carmine through a uterine manipulator (Figure 25). This distends the distal portion of the tube, which is stabilized, and the adhesive bands are freed using scissors, laser or micropoint electrosurgery. If necessary, the fimbriated end can be progressively dilated using 3 mm alligator-type forceps. The closed forceps are placed through the aperture, opened, and removed (Figure 26). This is repeated one or more times. If the opening does not remain everted on its own, the intussusception salpingostomy method of McComb is used to avoid thermal damage to the ciliated tubal epithelium from CO<sub>2</sub> laser or electrosurgery. The tip of the aqua dissector is inserted approximately 2 cm into the newly opened tube, suction applied, and the tube fimbrial edges pulled around the instrument to turn the tube end inside-out. The borders of the incision act as a restrictive collar to maintain the mucosa in this newly everted configuration (Figure 27). In some cases, the ostial margin is sutured to the ampullary serosa with 6-0 suture (Figure 28).

#### UNDERWATER SURGERY AT THE END OF EACH PROCEDURE

At the close of each operation, an underwater examination is used to document complete intraperitoneal hemostasis in stages; this detects bleeding from vessels and viscera tamponaded during the procedure by the increased intraperi-



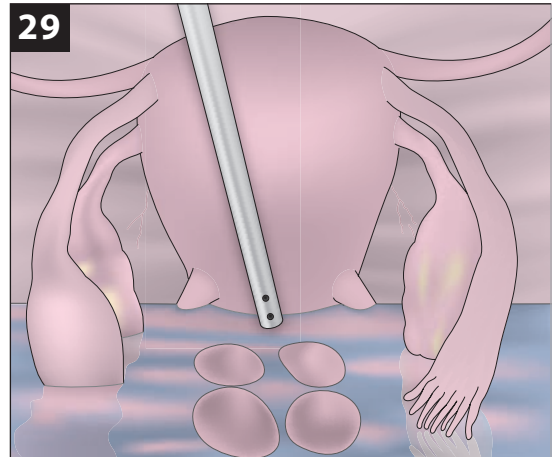
toneal pressure of the CO<sub>2</sub> pneumoperitoneum. The integrity of the rectum and rectosigmoid is often checked at this time by instillation of dilute indigo carmine solution or air transanally through a 30 cc Foley catheter or by performing a proctoscopy.

The peritoneal cavity is vigorously irrigated and suctioned until the effluent is clear of blood products, usually after 5-10 L. Underwater inspection of the pelvis is performed to detect any further bleeding which is controlled using microbipolar-irrigating forceps to coagulate through the electrolyte solution. First, hemostasis is established with the patient in Trendelenburg position, then per underwater examination with the patient supine and in reverse Trendelenburg, and, finally, with all instruments removed, including the uterine manipulator.

A final copious lavage with Ringer's lactate solution is undertaken and all clots directly aspirated; at least 2 L of lactated Ringer's solution are left in the peritoneal cavity to displace CO<sub>2</sub> (Figure 29). No other anti-adhesive agents are employed. No drains, antibiotic solutions, or heparin are used.

### HAND-ASSISTED LAPAROSCOPY

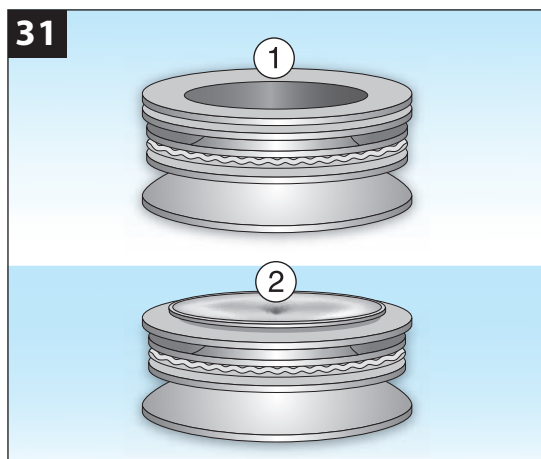
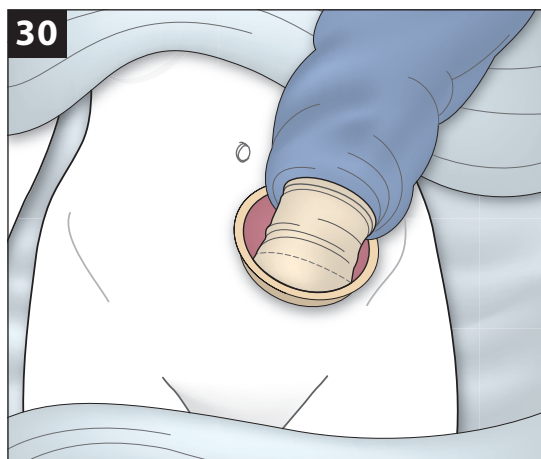
Hand assisted laparoscopy or 'handoscopy' has become popular over the last several years, mainly in the field of solid organ surgery and bowel surgery. The main advantage of handoscopy is that it allows the surgeon to regain the tactile feel of surrounding tissues previ-



ously lost to 'laser' laparoscopists and permits a more purposeful manipulation of larger organs. Often, it is the use of handoscopy for tissue palpation that enables a successful laparoscopic adhesiolysis. At times, during laparoscopic procedures, visualization can be poor due to dense adhesions and the inability to determine tissue planes. With the placement of the operator's hand inside the peritoneal cavity, the surgeon is usually able to palpate surrounding organs and allow for a better tissue dissection plane that otherwise may not have been possible through direct visualization only. Not only can the use of a hand port facilitate an otherwise tedious procedure, it effects a safer operation for the patient with less chance of bowel injury. If bowel resection should become necessary, the use of the hand port allows for exteriorization of the segment that requires resection once again making the procedure easier and less time consuming. A handoscopy incision is usually only 6-8 cm and is either placed in the left, right lower portion, or center of the abdomen with

insertion of the operator's non-dominant hand. The entire peritoneal cavity can be examined through any of these incisions with the operator's hand and it can be used for organ extraction as well (Figure 30). Several different types of handoscopy ports are available and all provide equal access to the peritoneal cavity (Figure 31).

When placing a handoscopy port for adhesiolysis, the operator must first choose a location on the abdominal wall that will allow optimal access to the point where adhesions are greatest. After the hand port location is chosen, a marking pen should be used to outline the area of the abdominal wall where the hand port is to be placed. The area for the incision should be anesthetized with a local anesthetic agent for postoperative pain control and an incision should then be made into the skin. The size of the incision should be the same size as the operator's glove size. After this is completed, a muscle splitting technique should be used to enter the peritoneal cavity just as the operator would in performing an open appendectomy if the incision is placed laterally. Once the peritoneal cavity is entered, the hand port can then be placed. All of the hand port devices require that any adhesions on the peritoneal side of the incision be lysed prior to inserting the handoscopy device. Additionally, these devices should not be placed over any bony prominences, i.e., iliac crest or encompassing any bowel in the peritoneal ring surface as to injure any bowel in the abdomen. If the handoscopy port is placed in the upper

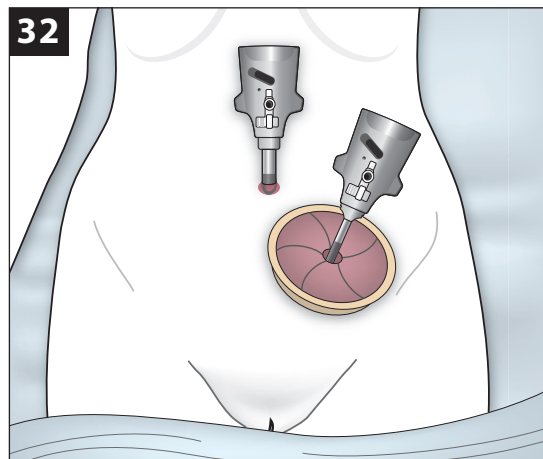


abdomen, the falciform ligament may require division prior to inserting the ring. Once the handoscopy device is in place, the lysis of adhesions can proceed in an orderly fashion by identifying the tissue planes by feel with the operator's fingers and additionally being able to provide appropriate traction and counter-traction to allow for a safe adhesiolysis. Incidental enterotomies can be sutured with conventional suture and then tied using one hand knot-tying technique with the intraabdominal hand. Should



any bowel resections be required the hand port can be used as a mini laparotomy site for extraction of any specimens and for exteriorizing any bowel that may require resection and or repair. Additionally all handoscopy devices that are placed through the abdominal wall act as a wound protector and may minimize postoperative wound infections as well as protect from any potential tumor seeding if the operation is for malignancy. The opening of the Ethicon Lap-Disc™ is like a camera shutter that can be reduced to seal the pneumoperitoneum around any size trocar (Figure 32).

Once the procedure is completed, the hand port device is removed, anterior and posterior rectus sheath muscle fascia are closed with either 0 or 2-0 absorbable suture, and the skin is then closed in a subcuticular manner. Additionally, a variety of ‘pain buster’ catheters are now available for insertion into the supra fascia layer of the wound which allow for excellent postoperative analgesia. These help to minimize postoperative narcotic requirements thereby facilitating an earlier return of bowel function and more expedient discharge from the hospital. It has been the author’s personal experience that patients undergoing a handoscopy type of operation parallel their recovery in the same manner as a conventional laparoscopic case with a delay of only one day in recovery. If a bowel resection should be required, the patient usually only requires to be NPO overnight and clear liquids may be started on the first postoperative day. The patient is maintained on clear liquids



until passing flatus and moving bowels. Most patients are discharged home on the second postoperative day if a bowel resection has been required.

## OPEN ADHESIOLYSIS

In certain situations an open adhesiolysis is best for the patient. It is usually performed after an attempted laparoscopic approach has been abandoned. A Pfannenstiel incision is rarely adequate. A midline incision is usually required if the entire peritoneal cavity is encased in dense fibrotic adhesions. Open adhesiolysis is reserved for the worst possible cases where laparoscopic adhesiolysis has failed, where there have been several incidental enterotomies made, or adhesiolysis cannot be performed secondary to encasement of the bowel. Open adhesiolysis should be considered in patients unable to tolerate CO<sub>2</sub> insufflation.

Open adhesiolysis is performed in the same way as a laparoscopic adhesiolysis. All adhesions are taken down from the abdominal wall usually with the

Metzenbaum scissors. All loops of bowel are extracted out of the pelvis. Finally, all interloop adhesions are lysed from the ligament of Treitz to ileo-cecal valve. Incidental enterotomies are repaired at the time of discovery to avoid intraperitoneal contamination and development of infection. Hemostasis must be meticulous during the entire dissection as in a laparoscopic procedure. An abundant amount of warm irrigation fluid is used as well. It is extremely important to keep the tissues moist to prevent desiccation from atmospheric air as this can stimulate adhesion reformation.

## ADHESION PREVENTION

### APPROACHES TO ADHESION PREVENTION

There are essentially two major adhesion prevention strategies: good surgical technique and the application of anti-adhesion adjuvants.

#### GOOD SURGICAL TECHNIQUE

Good surgical technique is particularly important for adhesion prevention. All the techniques employed in microsurgery should be used including:

1. gentle tissue handling (minimal use of forceps, retractors and clamps on tissue not intended for removal)
2. meticulous hemostasis to minimize blood in the peritoneal cavity
3. irrigation to minimize serosal drying
4. avoid intraperitoneal infection (copious irrigation to dilute peritoneal bacteria count and blood products)
5. minimize foreign bodies
6. use fine non-reactive sutures
7. minimal cauterization to limit peritoneal ischemia.

### ANTI-ADHESION ADJUVANT SOLUTIONS/DRUGS

Several adjuvant solutions/drugs have been used to prevent adhesions including non-steroidal anti inflammatory drugs (NSAIDs), corticosteroids and fibrinolytics. NSAIDs (e.g. ibuprofen, tolmetin, oxyphenbutazone) have been widely studied and can be applied systemically as well as intraperitoneally. The clinical efficacy of NSAIDs, however, is questionable. Corticosteroids show poor efficacy and are associated with immunosuppression and delayed wound healing, e.g. infection, incisional hernia and wound dehiscence. Furthermore, corticosteroids do not remain in the peritoneal cavity for the duration of adhesion formation (4-5 days post surgery). Fibrinolytics are also used but there is a risk of impaired wound healing and/or bleeding by preventing or reversing fibrin deposition. Intraperitoneal or systemic plasminogen activator (tPA), streptokinase and elastase have all undergone extensive clinical evaluation with conflicting results. In some cases, fibrinolytics have been associated with hemorrhagic complications. The lack of efficacy may be attributed to rapid peritoneal absorption and clearance.

A recent Cochrane Database Systematic Review Update confirmed previous conclusions whether pharmacological and liquid agents used as adjuvants during pelvic

surgery in infertility patients lead to a reduction in the incidence or severity of postoperative adhesion (re-) formation, and/or an improvement in subsequent pregnancy rates. The results of this review are as follows: intraperitoneal administration of dextran did not decrease postoperative adhesion formation at second look laparoscopy; there is no evidence that intraabdominal crystalloid instillation, calcium channel blocking agents, non-steroidal antiinflammatory drugs and proteolytics decrease postoperative adhesion formation.

## ANTI-ADHESION AGENTS - SOLUTIONS/BARRIERS

Four main attributes are associated with an ideal anti-adhesion agent. A potential agent should be safe, efficacious (at the operation site and throughout the cavity), easy to use in all types of abdominal surgery (open and laparoscopic), and economical.

Currently, adhesion reducing agents fall within two main categories 1) physical barriers, e.g. Gore-tex®, Hyskon®, Interceed™, Preclude®, Seprafilm®, Spraygel and 2) solutions, e.g. crystalloid solutions, e.g. Adept, dextran 30 and 70, hyaluronic acid gel, Ringer's lactate/saline +/- Heparin, dextran 30 and 70, and Sepracoat and hyaluronic acid gel (Figure 33). Generally, the physical barriers tend to be site specific, whereas solutions have the advantage of being able to penetrate throughout the cavity.

Another recent update to a Cochrane Database Review investigated the effects

these agents have on postoperative adhesion formation. The 15 randomized controlled trials comprised laparoscopic and laparotomy surgical techniques. Results of the investigation were as follows: oxidized regenerated cellulose Interceed™ (Johnson & Johnson Medical, Somerville, NJ) reduces the incidence of adhesion formation and re-formation at laparoscopy and laparotomy in the pelvis; polytetrafluoroethylene Gore-Tex® (W.L. Gore & Associates, Flagstaff, AZ) appears to be superior to Interceed® in preventing adhesion formation in the pelvis but is limited by the need for suturing and later removal; Seprafilm™ (Genzyme, Cambridge, MA) does not appear to be effective in preventing adhesion formation.

Many of these agents (Figure 33), however, do not meet the 4 requirements for the ideal anti-adhesion agent. There are toxicity concerns with dextran, Intergel and Interceed. Gore-tex, Preclude and Seprafilm are not easy to handle. In addition, many of the physical barrier approaches have limited efficacy, with some effect at the operative site but not throughout the cavity. Clinical outcomes and cost are also issues. Hyskon and Preclude are generally unavailable and Intergel and Sepracoat have been withdrawn from use. Adept and hyaluronic acid gel are both currently under investigation and have demonstrated promising results.

It has been demonstrated that adhesions may form in an area away from an incision. This is thought to be the result of a generalized inflammatory response.

Thus, an adhesion barrier alone may not be enough to prohibit adhesion formation or reformation.

## CONCLUSION

Adhesion formation after gynecologic surgery is common. When compared to laparotomy, laparoscopy has been shown to result in less de novo adhesion formation, but adhesion reformation continues to be a problem for both surgical approaches. Sequelae of intraabdominal adhesion formation can be fatal, result in infertility and may be a source of chronic pelvic pain. Minimally invasive surgical management of adhesion formation

affords the patient all of the known benefits of laparoscopic surgery including less postoperative analgesics, shorter hospital stays, and more rapid convalescence and return to normal activities. Unfortunately, recurrence after adhesiolysis for intestinal obstruction is not uncommon (8% to 32%). Thus, for some patients, adhesiolysis may become a repeat surgical procedure. No longer can the surgeon ignore the benefits of minimally invasive surgery for adhesiolysis. While these techniques and procedures are not without risk, patients should not be denied their inherent advantages. Astute clinicians must work together to discern the most appropriate uses for this therapy.

### SITE SPECIFIC

<b>Preclude®</b>	REMOVE AT SUBSEQUENT SURGERY – WITHDRAWN IN US.
<b>Interceed™</b>	LAPAROSCOPIC DIFFICULTIES & INEFFECTIVE WITH BLOOD.
<b>Seprafilm®</b>	LAPAROSCOPIC USE IMPOSSIBLE - ANASTOMOSIS WARNING.
<b>Hyalobarrier®</b>	LIMITED DATA – HYSTEROSCOPY NICHE USE.
<b>SprayGel®</b>	EXPENSIVE - LIMITED DATA.
<b>SurgiWrap®</b>	SUTURING REQUIRED - NO PUBLISHED CLINICAL DATA.
<b>Oxiplex®</b>	NEW GEL AGENT – LIMITED EXPERIENCE.
<b>Broad Coverage</b>	
<b>Crystalloid solns</b>	EFFICACY LIMITED & PERITONEAL IRRITATION ISSUES.
<b>Hyskon®</b>	NOT APPROVED - SERIOUS SAFETY ISSUES.
<b>Intergel™</b>	WITHDRAWN - LATE ONSET POST PROCEDURAL PAIN.
<b>Adept®</b>	SAFE, EASY TO USE, INEXPENSIVE. EFFICACY DATA RECENTLY PRESENTED AT ISGE AND TO FDA – PUBLICATION AWAITED. FDA ADVISORS RECOMMENDED APPROVAL – WILL BE FIRST AND ONLY AGENT LICENSED IN US FOR LAPAROSCOPIC SURGERY.

## SUGGESTED READING:

Ellis H. The clinical significance of adhesions: Focus on intestinal obstruction. *Eur J Surg* 1997; Suppl 577:5-9

Bryant T. Clinical lectures on intestinal obstruction. *Med Tim Gaz* 1872;1:363-5

Welch JP. Adhesions. In: Welch JP, ed. *Bowel obstruction*. Philadelphia: WB Saunders, 1990:154-65

Kligman I, Drachenberg C, Papdimitriou J, et al. Immunohistochemical demonstration of nerve fibers in pelvic adhesions. *Obstet Gynecol* 1993;82:566-568

Kresch AJ, Seifer DB, Sachs LB, et al. Laparoscopy in 100 women with chronic pelvic pain. *Obstet Gynecol* 1984; 64:672-674

Steege JF, Stout AL. Resolution of chronic pelvic pain after laparoscopic lysis of adhesions. *Am J Obstet Gynecol* 1991;165:278-81

Chan CL, Wood C. Pelvic adhesiolysis: The assessment of symptom relief by 100 patients. *Aust NZ Obstet Gynaecol* 1985;25:295-298

Daniell JF. Laparoscopic enterolysis for chronic abdominal pain. *J Gynecol Surg* 1990;5:61-66

Sutton C, MacDonald R. Laser laparoscopic adhesiolysis. *J Gynecol Surg* 1990;6:155-159

Peters A, Trimbos-Kemper G, Admiraal C, et al. A randomized clinical trial on the benefit of adhesiolysis in patients with intraperitoneal adhesions and pelvic pain. *Br J Obstet Gynaecol* 1992;99:59-62

Fox Ray N, Denton WG, Thamer M, Henderson SC, Perry S. Abdominal adhesiolysis: Inpatient care and expenditures in the United States in 1994. *J Am Coll Surg* 1998;186(1):1-9

DiZerega GS. Contemporary adhesion prevention. *Fertil Steril* 1994;61(2):219-235

Reich H. Laparoscopic treatment of extensive pelvic adhesions including hydrosalpinx. *J Reprod Med* 1987;32:736

Odell R. Principles of Electrosurgery. In Sivak M, ed. *Gastroenterologic Endoscopy*. New York: W.B. Saunders Company, 1987:128

Reich H, Vancaillie T, Soderstrom R. Electrical Techniques. *Operative Laparoscopy*. In Martin DC, Holtz GL, Levinson CJ, Soderstrom RM, eds. *Manual of Endoscopy*. Santa Fe Springs: American Association of Gynecologic Laparoscopists, 1990:105

Reich H, McGlynn F. Laparoscopic oophorectomy and salpingo-oophorectomy in the treatment of benign tuboovarian disease. *J Reprod Med* 1986;31:609

Reich H. Laparoscopic oophorectomy and salpingo-oophorectomy in the treatment of benign tubo-ovarian disease. *Int J Fertil* 1987;32:233

Reich H, McGlynn F. Laparoscopic treatment of tubo-ovarian and pelvic abscess. *J Reprod Med* 1987;32:747

Henry-Suchet J, Soler A, Lofferdo V. Laparoscopic treatment of tubo-ovarian abscesses. *J Reprod Med* 1984;29:579

Reich H. Endoscopic management of tuboovarian abscess and pelvic inflammatory disease. In Sanfilippo JS and Levine RL, eds. *Operative Gynecologic Endoscopy*. New York: Springer-Verlag, 1989:118

Reich H. Laparoscopic bowel injury. *Surg Laparosc Endosc* 1992;2:74

Reich H, Levie M, McGlynn F, Sekel L. Establishment of pneumoperitoneum through the left ninth intercostal space. *Gynaecological Endoscopy*; 4, 141-143, 1995.

Palmer R. Safety in laparoscopy. *J Reprod Med* 1974;13:1-5

Fu-Hsing Chang, Hung-Hsueh Chou, Chyi-Long Lee, et al. Extraumbilical insertion of the operative laparoscope in patients with extensive intraabdominal adhesions. *J Amer Assoc Gynecol Laparosc* 1995;2(3):335-337

Pasic R, Wolfe WM. Transuterine insertion of Veress needle. *N Z Med J* 1994;107(987):411

Reich H, McGlynn F, Salvat J. Laparoscopic treatment of cul-de-sac obliteration secondary to retrocervical deep fibrotic endometriosis. *J Reprod Med* 1991;36:516

Peacock LM, Rock JA. Distal Tubal Reconstructive Surgery. In Sanfilippo J ed. *Operative Gynecologic Endoscopy*. New York: Springer, 1996:182-191

McComb PF, Paleologou A. The intussusception salpingostomy technique for the therapy of distal oviductal occlusion at laparoscopy. *Obstet Gynecol* 1991;78:443

Bailliere's Clinical Obstetrics and Gynaecology. London: WB Saunders, 1989:6551

Singhal V, Li T, Cooke I. An analysis of the factors influencing the outcome of 232 consecutive tubal microsurgery cases. *Br J Obstet Gynaecol* 1991;98:628-36

Winston R, Margara R. Microsurgical salpingostomy is not an obsolete procedure. *Br J Obstet Gynaecol* 1991; 98:637-42

Watson A, Vandekerckhove P, Lilford R. Liquid and fluid agents for preventing adhesions after surgery for subfertility. *Cochrane Database of Systematic Reviews*. Issue 3, 2005

Farquhar C, Vandekerckhove P, Watson A, Vail A, Wiseman D. Barrier agents for preventing adhesions after surgery for subfertility. *Cochrane Database of Systematic Reviews*. Issue 3, 2005

Diamond MP, Linsky CB, Cunningham TC, et al. Synergistic effects of Interceed (TC7) and heparin in reducing adhesion formation in the rabbit uterine horn model. *Fertil Steril* 1991;55:389-94

Burns JW, Skinner K, Yu LP, et al. An injectable biodegradable gel for the prevention of postsurgical adhesions: Evaluation in two animal models. In *Proceedings of the 50th Annual Meeting of the American Fertility Society*, San Antonio, Texas, November 5-10, 1994.

Johns DB, Keyport GM, Hoehler F, diZerega GS. Reduction of post surgical adhesions with Intergel® adhesion prevention solution: a multicenter study of safety and efficacy after conservative gynecologic surgery. *Fertil Steril* 2001; 76: 595-604

Operative Laparoscopy Study Group. Postoperative adhesion development after operative laparoscopy: evaluation at early second look procedures. *Fertil Steril* 1991;55:700-4

Ellis H, Moran BJ, Thompson JN, et al. Adhesion-related hospital readmissions after abdominal and pelvic surgery: a retrospective cohort study. *Lancet* 1999;353:1476-1480

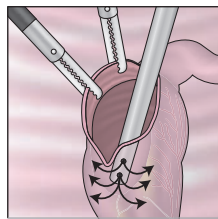
Lower AM, Hawthorn RJS, Ellis H, et al. The impact of adhesions on hospital readmissions over ten years after 8849 open gynaecological operations: an assessment from the Surgical and Clinical Adhesions Research Study. *Br J Obstet Gynaecol*, 2000;107:855-862

Lower AM, Hawthorn RJ, Clark D, Boyd JH, Finlayson AR, Knight AD, Crowe AM. Surgical and Clinical Research (SCAR) Group. Adhesion-related readmissions following gynaecological laparoscopy or laparotomy in Scotland: an epidemiological study of 24 046 patients. *Human Reprod* 2004;19(8):1877-85

Liakakos T, Thomakos N, Fine PM, et al. Peritoneal adhesions: etiology, pathophysiology, and clinical significance. *Dia Surg* 2001;18:260-273.

Swank DJ, Swank-Bordewijk SCG, Hop WCJ, et al. Laparoscopic adhesiolysis in patients with chronic abdominal pain: a blinded randomised controlled multi-centre trial. *Lancet* 2003;361:1247-1251.

# ECTOPIC PREGNANCY



***Danielle E. Luciano, M.D.***

***Gerard Roy, M.D.***

***Anthony Luciano, M.D.***

## INTRODUCTION

**P**regnancy outside the confines of the uterine cavity has been described for hundreds of years. In the 1800s, the mortality associated with ectopic pregnancy was >60%. Today it accounts for 9% of pregnancy related mortality and less than 1% of overall mortality in women. Figure 1 depicts this data from 1970-2000. During this period, we see a greater than 90% reduction in mortality despite more than a 5-fold increase in the overall incidence.

Although ectopic pregnancy has been recognized for over 400 years, it continues to be an ever-increasing affliction affecting greater than 2% of all pregnancies. The rising incidence of ectopic pregnancies in the past 25 years has been attributed to a number of different risk factors listed in Table 1. Theoretically, anything that impedes migration of the conceptus to the uterine cavity may predispose a woman to develop an ectopic gestation. These may be intrinsic anatomic defects in the tubal epithelium, hormonal factors that interfere with normal transport of the conceptus, or pathologic conditions that affect normal tubal functioning.



TABLE 1

**MAJOR CONTRIBUTING FACTORS AND ASSOCIATED RELATIVE RISK FOR ECTOPIC PREGNANCY\***

RISK FACTOR	RELATIVE RISK
CURRENT USE OF IUD	11.9
USE OF CLOMIPHENE CITRATE	10.0
PRIOR TUBAL SURGERY	5.6
PELVIC INFLAMMATORY DISEASE	4.0
INFERTILITY	2.9
INDUCED ABORTION	2.5
ADHESIONS	2.4
ABDOMINAL SURGERY	2.3
T-SHAPED UTERUS	2.0
MYOMATA	1.7
PROGESTIN ONLY OCPs	1.6

\*ADAPTED FROM MARCHBANKS PA ET AL: RISK FACTORS FOR ECTOPIC PREGNANCY: A POPULATION BASED STUDY. JAMA 1988; 259:1823-7.

Besides the symptoms commonly associated with early pregnancy, women with ectopic pregnancy commonly experience pelvic pain and bleeding. The pain is often one sided and the bleeding is often variable and may be the only sign of a complication. It should be noted, however, up to 20% of women with first trimester bleeding will go on to have a healthy pregnancy. Table 2 lists some of the more common signs and symptoms of an ectopic pregnancy to assist the practitioner in differentiating ectopic pregnancy from other gynecologic and non-gynecologic conditions. The differential diagnosis for cases of suspected ectopic pregnancies are listed in Table 3.

Until 1970, more than 80% of ectopic pregnancies were diagnosed after rup-

TABLE 2

**SIGNS AND SYMPTOMS SUGGESTIVE OF ECTOPIC PREGNANCY**

- NAUSEA, BREAST FULLNESS, FATIGUE, AMENORRHEA
- LOWER ABDOMINAL PAIN, HEAVY CRAMPING, SHOULDER PAIN
- UTERINE BLEEDING/SPOTTING
- PELVIC TENDERNESS, ENLARGED, SOFT UTERUS
- ADNEXAL MASS, TENDERNESS
- POSITIVE PREGNANCY TEST
- SERUM LEVELS OF hCG <6000 mIU/mL AT 6 WEEKS
- LESS THAN 66% INCREASE IN hCG TITERS IN 48 HOURS.
- SERUM PROGESTERONE <25 NG/mL
- ASPIRATION OF NON-CLOTTING BLOOD ON CULDOCENTESIS
- ABSENCE OF GESTATIONAL SAC IN THE UTERUS BY U/S WHEN THE hCG TITER EXCEEDS 2500 mIU/mL
- GESTATIONAL SAC OUTSIDE THE UTERUS BY U/S

ture, resulting in significant morbidity and mortality. With excellent resolution obtained from pelvic ultrasound, highly sensitive radio-immunoassays for human chorionic gonadotropin (hCG) and increased vigilance by clinicians, greater than 80% of ectopic pregnancies are now diagnosed intact which allows for more conservative management.

Awareness of the possibility of an ectopic pregnancy is most critical for early detection. Measurement of hCG with a doubling time of 2-3 days should occur if it is a normal gestation. A note of caution is that approximately 10% of nor-

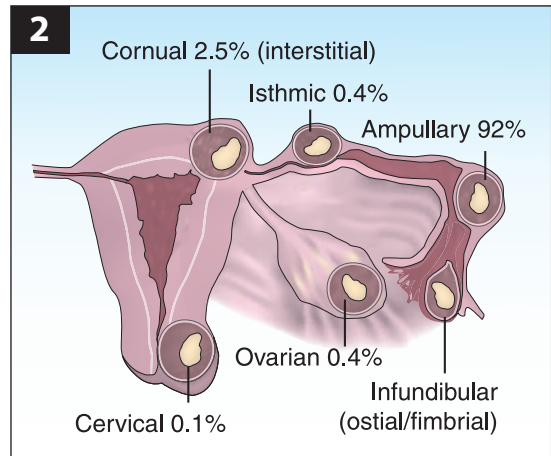
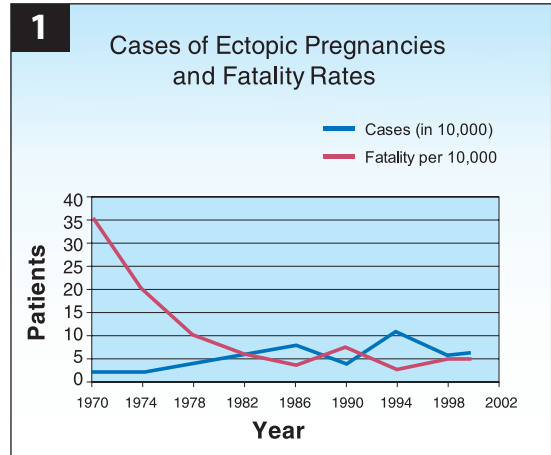
TABLE 3

### DIFFERENTIAL DIAGNOSIS IN CASES OF SUSPECTED ECTOPIC PREGNANCY

- SPONTANEOUS ABORTION
- RUPTURED OVARIAN CYST
- CORPUS LUTEUM HEMORRAGICUM
- ADNEXAL TORSION
- PELVIC INFLAMMATORY DISEASE
- ENDOMETRIOSIS
- UROLITHIASIS
- URINARY TRACT INFECTION
- APPENDICITIS
- OTHER LOWER GASTROINTESTINAL TRACT DISEASE

mal pregnancies do not follow this doubling time, and very early in gestation up to 60% of ectopic pregnancies will follow this doubling time. When hCG levels are >1000 mIU/mL, transvaginal ultrasound is reliable in diagnosing the location of the gestation approximately 98% of the time. If using an abdominal ultrasound, then the hCG needs to be above 6000 mIU/mL to make an accurate diagnosis. Progesterone can also be used to help differentiate a viable from non-viable gestation. A progesterone level of greater than 25 ng/mL is indicative of a healthy gestation about 97.4% of the time and a level of 5 ng/mL indicates an abnormal pregnancy with almost 100% sensitivity. Values between 5 and 25 ng/mL are unfortunately more common and these values are more ambiguous.

The incidence of ectopic pregnancy based on location has been relatively



unchanged for many years. Figure 2 shows the location of various ectopic pregnancies and their incidence in each location. The ampullary portion of the fallopian tube is the site of the majority of ectopic pregnancies. This may result from three characteristics of this area: 1) from the ampullary to the isthmic region the tube begins to narrow, 2) this is where fertilization begins, or 3) this may be the most distal point of the majority of ascending infections that will still allow fertilization. Infectious damage to the

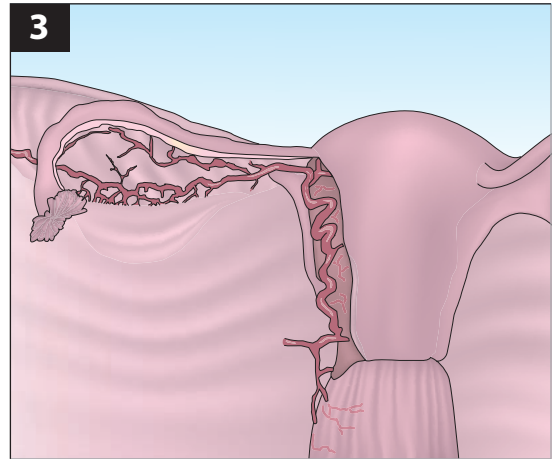
fimbria typically causes phymosis and infertility. The ampullary portion of the tube, fortunately, lends itself extraordinarily well to minimally invasive surgical correction.

## ANATOMY OF THE FALLOPIAN TUBE

The oviduct or tube is approximately 10-12 cm long. The tube itself can be functionally and anatomically divided into four parts. The intramural or interstitial portion of the tube is approximately 1 cm long and traverses through the myometrium and opens in the endometrial cavity. This is the opening through which the sperm travel to the oviduct and the embryo enters the cavity. It is also a highly vascular area and makes conservative surgical management more difficult.

The isthmus of the tube is approximately 4-6 cm in length. It is composed of a double layer of muscle and inner lumen. The outer muscle layer runs longitudinal to the axis of the tube and is thicker than the inner muscle layer, which is oriented in a circular fashion. The lumen of the isthmus is approximately 1-2 mm until it gets to the ampulla where it enlarges.

The ampulla is the longest segment of the tube and makes up approximately 2/3rds of the total length. Beneath the mucosa of the ampullary portion of the tube, there is a series of large blood vessels – mostly veins originating from the uterine/ovarian supply to the tube. These become engorged at the time of ovula-



tion to bring the fimbriae closer to the ovary. They can also be problematic during surgical treatment for an ectopic pregnancy. These vessels travel in a thick longitudinal muscle layer. The lumen of the tube is wider here and the mucosa has more rugae, which are covered with ciliated and secretory cells. These cells may be damaged with infection, previous ectopic or surgery predisposing patients to a greater risk of tubal pregnancy.

The final portion of the tube is the infundibulum; it is funnel shaped and its most distal end is called the fimbriae. There are greater concentrations of ciliary cells here that facilitate transport of the ovum into the ampulla.

The blood supply to the tube arises from a cascade of vessels originating from an arcuate formed by a branch of the ovarian artery and a tubal branch of the uterine artery (Figure 3). This arcuate is located in the mesosalpinx, between the fallopian tube and ovary. Vessels then perforate the medial side of the tube and travel in the intimal layer.

## TREATMENT OPTIONS

Treatment options for ectopic pregnancy have broadened substantially in the past 10-15 years. Prior to this, laparotomy with salpingectomy was the standard of care. Due to better resolution ultrasound and earlier diagnosis, improved microsurgical laparoscopic techniques and chemotherapeutics, a more conservative approach has been taken in order to preserve tubal function. Laparoscopic treatment of this condition is growing in popularity and is currently considered the standard of care. Even hemodynamic instability is not an absolute contraindication to laparoscopy. The availability of optimal anesthesia, advanced cardiovascular monitoring, ability to convert quickly to laparotomy, and superior magnification given by laparoscopy make it a viable option and possibly the best choice. Laparoscopy also has lower morbidity, shorter hospital stays and decreased costs as well as decreased need for postoperative analgesia, and some studies have also shown that laparoscopy achieves superior pregnancy rates to laparotomy.

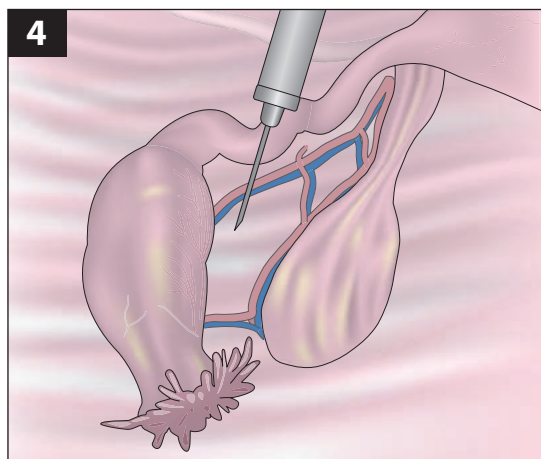
Since the 1970s, a conservative approach to unruptured ectopic pregnancy has been advocated by many of the leading authorities in our field. There are several different types of conservative surgery that can be performed. These include linear salpingostomy, partial salpingectomy with anastomosis, and 'milking' the pregnancy from the distal ampulla.

## SURGICAL MANAGEMENT BASED ON LOCATION

The location, size, and extent of the tubal pregnancy are observed laparoscopically. The management of each ectopic pregnancy is based upon these factors. Whatever the surgical approach chosen, adequate hemostasis with minimal trauma is optimal and should be obtained with as little cauterization as possible. All surgical approaches start by identification and mobilization of the involved fallopian tube and inspection of the uninvolved side.

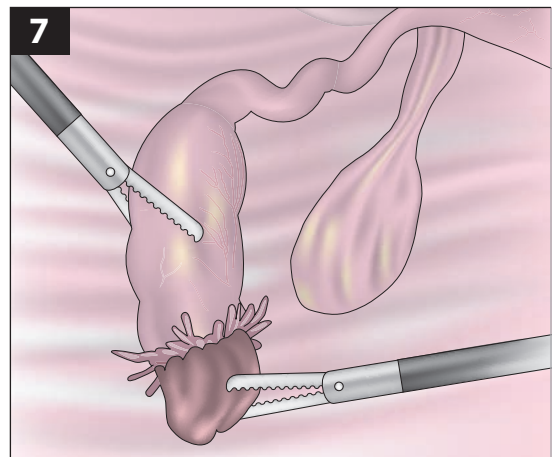
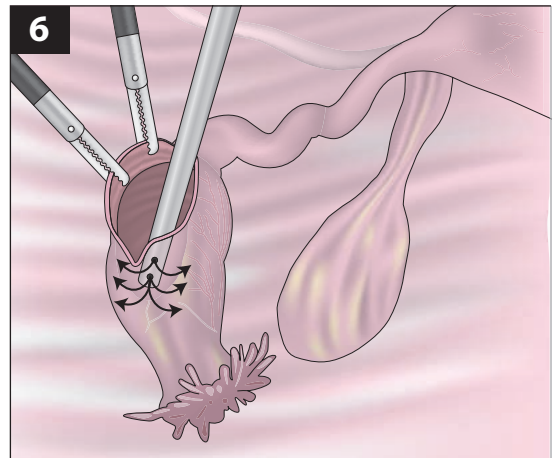
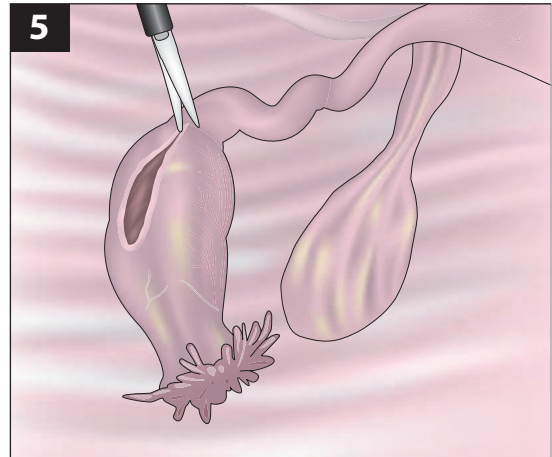
### AMPULLARY ECTOPIC

Once diagnosed, if the pregnancy is in the mid-ampullary segment as in the majority of cases, a 5-7 mL dilute solution of vasopressin (20 U/100mL of NS) is used. This is injected with a laparoscopic needle into the mesosalpinx just below the pregnancy and over the anti-mesenteric surface of the segment containing the gestation (Figure 4). It is extremely



important to make sure that the vasopressin is not injected directly into a blood vessel as it can cause arterial hypertension, bradycardia and death. Using a laser, microelectrode, scissors, or harmonic scalpel a linear incision is made over the pregnancy approximately 1-2 cm in length (Figure 5). As one makes this incision the contents of the pregnancy usually begin to extrude. This can be completed by hydro dissection or using gentle traction with laparoscopic forceps (Figure 6). In some cases, more forceful irrigation in the salpingostomy incision may be required to dislodge the pregnancy from its implantation site. Occasionally, coagulation is used to secure hemostasis and is best accomplished with bipolar micro-forceps. Oozing from the tubal bed is common and usually ceases spontaneously. Copious irrigation is used to dislodge trophoblastic tissue and remove blood from the peritoneal cavity. The tubal opening is left to heal by secondary intention, unless the defect is wide and the edges do not come together spontaneously. For such cases, the edges may be approximated with a single 4-0 absorbable suture.

If the pregnancy is located in the distal ampullary segment of the tube, then, occasionally, the tubal segment can be grasped and the pregnancy 'milked' out the fimbriae of the tube (Figure 7). This can also be done for partially extruded tubal pregnancies and infundibular pregnancies.



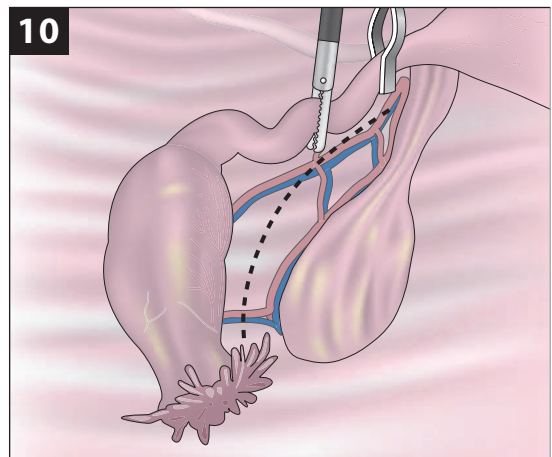
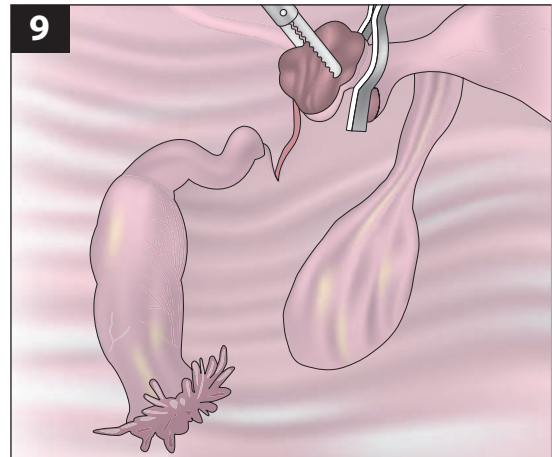
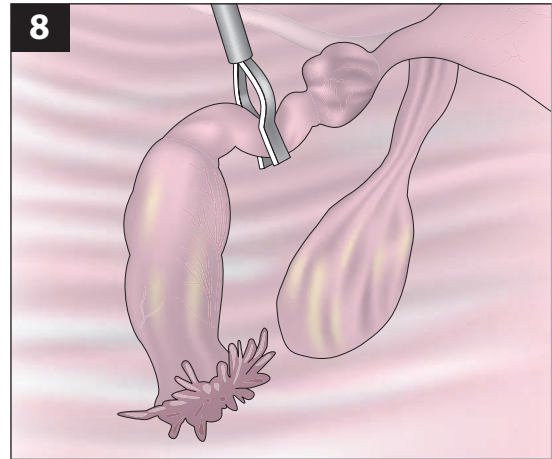
## ISTHMIC ECTOPIC

When the ectopic pregnancy implants in the isthmic portion of the tube, linear salpingostomy is not as successful because typically these pregnancies grow through the lumen of the tube and erode the muscularis.

Isthmic ectopic pregnancies have a higher rate of persistence and tubal patency is seldom preserved. With isthmic tubal pregnancy, segmental tubal resection is preferred. This can be accomplished by various means (i.e. bipolar, laser, sutures, or stapling devices). Bloodless resection is optimal and may be accomplished by using bipolar forceps, grasping both proximal and distal to the gestation and coagulating from the anti-mesenteric surface to the mesosalpinx. This is then cut and the mesosalpinx cauterized and cut in a similar fashion (Figures 8-9). The tube may be reanastomosed at a later date if desired.

## SALPINGECTOMY

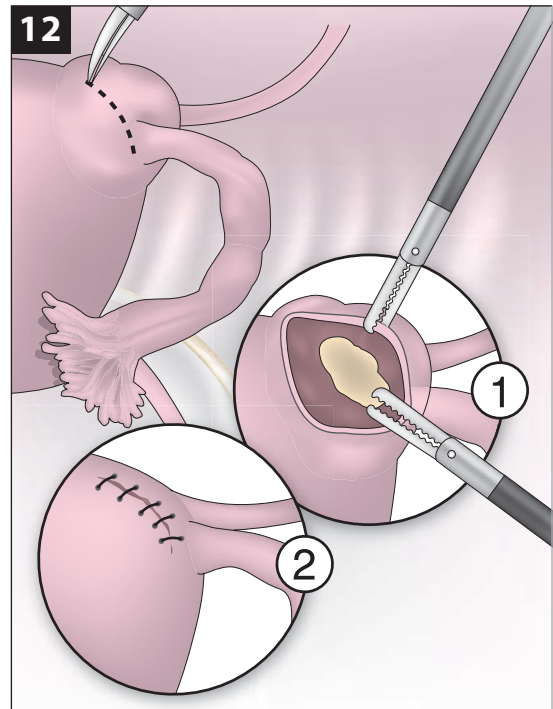
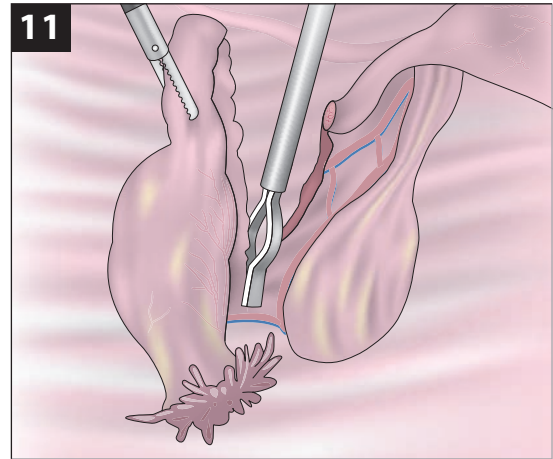
This technique is chosen in the presence of uncontrolled bleeding, tubal destruction, recurrent ectopic in that tube, patient desire, or severe adhesion or hydrosalpinx. The tube is removed from its anatomical attachments. This can be accomplished by numerous methods including laser, stapling devices, harmonic energy, endoloops, or progressive bipolar coagulation. Progressive coagulation and cutting the mesosalpinx begins at the proximal isthmus of the tube and progresses to the fimbriated end (Figures 10-11). The products of conception can



be removed through a 10 mm trocar sleeve with or without the use of a plastic bag (Endo-pouch®, Ethicon, Inc., Cincinnati, OH or Cook Sac).

### INTERSTITIAL/CORNUAL ECTOPIC

Fortunately, these types of ectopic pregnancies are rare with a prevalence of 1 in 5000 live births. Late diagnosis of this type of ectopic pregnancy, and the vascular nature of the cornua account for a mortality rate of 2%-2.5%. Some 2% to 4% of all ectopic gestations are interstitial/cornual. The traditional management of this type of ectopic gestation is laparotomy with salpingectomy and/or cornual resection. This surgery occasionally culminates in hysterectomy. It is important, however, to make a distinction between the interstitial ectopic and a true cornual ectopic pregnancy. The interstitial portion of the fallopian tube is approximately 1 cm long, has a narrow lumen and follows a tortuous course through a thick layer of myometrium. The cornual pregnancy, however, implants in this section of tube but opens to the uterine cavity, allowing hysteroscopy to be a potential method of surgical correction. The interstitial pregnancy implants deeper in this segment of the fallopian tube and is not accessible from the uterine cavity, thus, it is not amenable to hysteroscopic resection. If the diagnosis is made early and the patient is stable, more conservative approaches should be considered. These options include methotrexate locally or systemically, potassium chloride injections locally and prostaglandin adminis-



tration. Once the diagnosis is confirmed and medical management is not possible, surgical treatment options are explored and consist of immediate laparotomy or a combined laparoscopic, and hysteroscopic approach.

Early detection may afford one the option of a combined treatment using laparoscopy/hysteroscopy and methotrexate. If the gestation is truly cornual and accessible by hysteroscopy, it is resected using electrosurgery and removed. If the overlying myometrium is thin, a laparoscopic resection may be possible (Figure 12).

For larger gestations that are accessible through the uterus, it may be safer and faster to do a gentle curettage under laparoscopic guidance. Remember that the cornua are extremely vascular and profuse bleeding can occur rapidly. Therefore, it is always prudent to have these patients typed and crossed for several units of packed red blood cells as well as consented for laparotomy.

## OVARIAN PREGNANCY

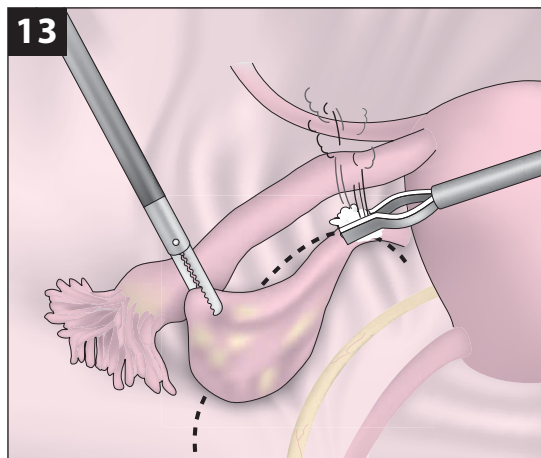
Pregnancy located in the ovary itself is a rare occurrence. The incidence is 1 in 6970 live births and 0.7 per 100 ectopic gestations. Table 4 delineates Speigelberg's criteria for the diagnosis of ovarian pregnancy established in 1878 and still in use today. Management of ovarian pregnancy can be either medical or surgical. Typically, they are diagnosed in the first trimester and can be definitively treated by oophorectomy.

The ovarian ligament is grasped with bipolar forceps, cauterized and cut (Figure 13). The mesoovarium is then taken down in a progressive fashion. This can also be performed using an endoloop or with the harmonic scalpel.

TABLE 4

### SPIEGELBERG'S CRITERIA FOR OVARIAN ECTOPIC PREGNANCY

1. FALLOPIAN TUBE ON THE AFFECTED SIDE MUST BE INTACT
2. FETAL SAC MUST OCCUPY THE POSITION OF THE OVARY
3. OVARY MUST BE CONNECTED TO THE UTERUS BY THE OVARIAN LIGAMENT
4. DEFINITE OVARIAN TISSUE MUST BE FOUND IN THE SAC WALL



## CERVICAL PREGNANCY

This type of ectopic pregnancy is also very rare and in the past was treated by hysterectomy. Rubin first described criteria for diagnosis of a cervical pregnancy in 1911 as: cervical glands must be present opposite the placental attachment, 2) the attachment of the placenta to the cervix must be intimate, 3) the placenta must be below the peritoneal reflection of the anterior and posterior surfaces of the uterus, 4) fetal elements must not be



within the uterine cavity. Conservative management now is by medical therapy with methotrexate when possible to avoid blood loss and hysterectomy. This has been proven safe, effective and preserves the patient's fertility options for the future. Multiple case reports and a case series from Albert Einstein College of Medicine in New York have shown successful treatment of cervical pregnancies with selective uterine artery embolization along with methotrexate. This may also be an effective conservative therapeutic option for this complex condition especially when associated with significant vaginal bleeding.

### ABDOMINAL PREGNANCY

This type of ectopic can either be primary or secondary based on the initial implantation site. Occasionally, a tubal pregnancy will rupture and implant abdominally and continue to evolve. This can also occur with tubal abortions. The management for abdominal ectopic is strictly by laparotomy as these pregnancies are usually not diagnosed until third trimester. Implantation of the placenta can occur on any organ in the abdominal cavity. The delivery is by laparotomy and there is controversy on removal of the placenta at that time or at a later date. It may be more prudent to leave the placenta in situ after delivery and use the interventional radiologist to embolize the placental bed prior to removal in an attempt to conserve blood loss in this potentially catastrophic situation.

### MANAGEMENT OF RUPTURED ECTOPIC PREGNANCY

Presently, laparoscopy is considered the gold standard in treating patients with an unruptured ectopic pregnancy. Sometimes patients may present with ruptured ectopic pregnancy and surgical abdomen full of blood and blood clots. Those patients may frequently be approached laparoscopically and there may be no need for laparotomy in patients with a ruptured ectopic pregnancy. There are several factors you need to keep in mind when performing laparoscopy in these patients.

Establishment of the pneumoperitoneum and placement of the trocar may be just as quick as performing laparotomy. When placing the Veress needle in the abdomen filled with blood, you may encounter higher initial insufflation pressures, since the tip of the needle may be immersed in blood. Only a sponge stick should be placed in the vagina for uterine manipulation, to avoid disruption of a possible intrauterine pregnancy.

After the placement of the umbilical trocar and insertion of the laparoscope, the patient should be placed in steep Trendelenburg position and a suprapubic port should be inserted and grasper introduced for quick localization of the ruptured tube, and to tamponade the bleeding site. After the bleeding area has been compressed, attention should be turned toward the removal of blood and blood clots. A cell saver is a great way to replace the patient's blood loss with her own blood and it may be utilized when-

ever a large blood loss is encountered.

Blood clots should be removed with the help of the 5 mm laparoscopic suction device. The 10 mm suction does not offer any advantages since it is reduced to 5 mm in the instrument's handle. The best way to remove blood clots is to apply constant suction on the suction device, and to aspirate the clots and break them by pulling the suction tip into the 5 mm trocar. This maneuver breaks the clots and helps to evacuate them through the suction aspirator (Figure 14). Try to avoid excessive irrigation since the fluid in the abdomen lifts the bowel, which in turn decreases your area of vision. After the blood has been removed from the abdominal cavity, proper assessment of the ectopic pregnancy can be made and an adequate treatment plan developed.

## MEDICAL MANAGEMENT

The use of methotrexate has enabled treatment of ectopic pregnancy to be even more conservative than laparoscopy. It can be used in all types of ectopic gestation either intramuscularly or directly into the gestation. Not all patients are candidates for medical management. Table 5 shows some of the criteria used to delineate the appropriate patients. If the criteria are met, then 50 mg/m<sup>2</sup> (body surface area) is given in a single IM dose. Quantitative hCG is checked on day 4 and 7. Weekly titers are then obtained until the titer is negative. A drop in titers of 15% should be seen from the day 4 value to the day 7 value. Less than 10% of patients

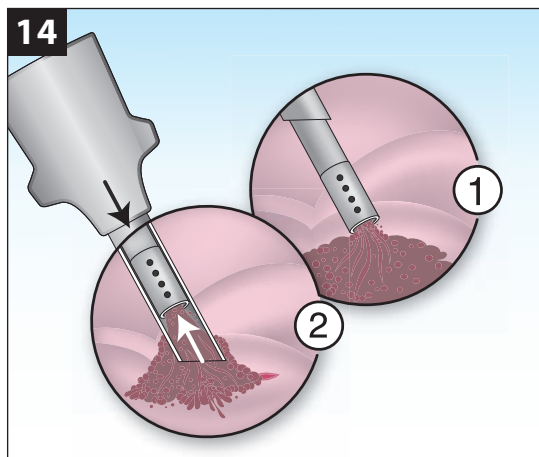


TABLE 5

### INDICATIONS FOR THE USE OF METHOTREXATE IN ECTOPIC PREGNANCY

- PATIENT IS RELIABLE, COMPLIANT, HEALTHY AND HEMODYNAMICALLY STABLE
- ULTRASOUND NOTES DEFINITE ECTOPIC GESTATION
- PREGNANCY SAC IS LESS THAN 4 CM
- hCG TITERS <10,000 IU/mL
- PROGESTERONE LEVELS <10 NG/mL
- ABSENT FETAL CARDIAC ACTIVITY
- NORMAL LIVER FUNCTION TEST, CBC
- GIVE RHOGAM IF RH NEGATIVE

need a second injection of methotrexate. This method is 80%-90% effective but runs the risk of emergent surgical correction for rupture. Therefore, the patient must be reliable, compliant, and aware of this risk. A study by Dudley, et al looked at characteristics of ectopic pregnancies that ruptured while being treated with methotrexate. An hCG that increased by >66%

every 48 hours or persistent increase in hCG after treatment were found to be independent predictors of tubal rupture and should perhaps lower one's threshold for surgical intervention.

Reproductive potential after an ectopic pregnancy has been studied comparing medical and endoscopic surgical treatment. Cumulative IUP rates following both laparoscopy and conservative therapy range from 36%-58%, with a cumulative ectopic recurrence rate of approximately 25% for both treatment groups. Reproductive outcome seems to depend more on the patient's medical/surgical history than on the treatment modality used.

## CONCLUSION

Ectopic pregnancy remains an increasing health problem. Its incidence continues to rise, paralleling the progressive increase in the incidence of its etiologic factors, especially sexually transmitted diseases and advanced reproductive technologies. With improved ultrasonography and minimally invasive techniques, the surgical management of this worrisome condition can be accomplished with minimal trauma. Minimally invasive surgery and medical management have similar success to laparotomy with less morbidity and improved patient care and fertility.

SUGGESTED READING:

Nezhat C, Seigler, Nezhat F, et al. Operative Gynecologic Laparoscopy: Principles and Techniques, 2nd ed. McGraw-Hill Co. New York, 2000:211-31

Speroff, Glass, Kase. Clinical Gynecologic Endocrinology and Infertility, 6th ed. Lippincott Williams & Wilkins, 1999:1149-67

Luciano DE, Jain A, Roy G, Solima E, Luciano AA Ectopic pregnancy. J AAGL 2004; 11(1):109-21.

Marchbanks PA, JF Aneger, CB, Coulman, et al. Risk factors for ectopic pregnancy: A population based study. JAMA 1988;259:1823-1827

Westrom L, Bengtsson LP, Mardh PA. Incidence, trends, and risks of ectopic pregnancy in a population of women. Br Med J (Clin Res Ed.) 1981; 282(6257):15-8.

Shepherd RW, Patton PE, Novy MJ, Burry KA. Serial data-hCG measurements in the early detection of ectopic pregnancy. Obstet Gynecol 1990; 75:417-20

Stovall TG, Ling FW, Carson SA, et al. Serum progesterone and uterine curettage in differential diagnosis of ectopic pregnancy. Fertil Steril 1992;57(2):456-7.

Kadar NG, De Vore G, Romero R. Discriminatory hCG zone: its use in the sonographic evaluation for ectopic pregnancy. Obstet Gynecol 1981; 58(2): 156-61

Decherney AH, Kase N. The conservative surgical management of unruptured ectopic pregnancy. Obstet Gynecol 1979; 54: 451-3

Tuomivaara L, Kauppila A. Radical or conservative surgery for ectopic pregnancy? A follow up study of fertility of 323 patients. Fertil Steril 1988; 50: 580-583

Vermish M, Silva PD, Rosen GF, et al. Management of unruptured ectopic gestation by linear salpingostomy: A prospective randomized clinical trial of laparoscopy versus laparotomy. Obstet Gynecol 1989; 73: 400-3

Bruhat MA, Mahnes H, Mage G, et al. Treatment of ectopic pregnancy by means of laparoscopy. Fertil Steril 1980; 33: 411-14

Brumstead JC, Kessler C, Gibson C, et al. A comparison of laparoscopy and laparotomy for the treatment of ectopic pregnancy. Obstet Gynecol 1988; 71: 889-92

Stenman UH, Tenhunen A, Ylikorkala O. Conservative treatment of ectopic pregnancy. Ann New York Academy Sciences 1991; 626: 516-23

Trio D, Strobelt N, Picciolo C, et al. Prognostic factors for successful expectant management of ectopic pregnancy. Fertil Steril 1995; 63(3): 469-72

Stovall TG, Ling FW, Gray LA. Single-dose methotrexate for treatment of ectopic pregnancy. *Obstet Gynecol* 1991;77(5): 754-7

Lipscomb GH, McCord ML, Stovall TG, et al. Predictors of success of methotrexate treatment on women with tubal ectopic pregnancies. *N Engl J Med* 1999; 341: 1974-8

Graczykowski JW, Mishell DR. Methotrexate prophylaxis for persistent ectopic pregnancy after conservative treatment by salpingostomy. *Obstet Gynecol* 1997; 89: 118-22

Bremer T, Cela V, Luciano A. Surgical management of interstitial pregnancy. *J AAGL* 2000;7(3):387-89

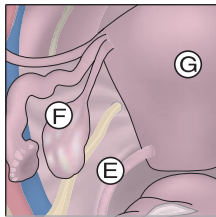
Dudley PS, Heard MJ, Sangi-Haghpeykar H, et al. Characterizing ectopic pregnancies that rupture despite treatment with methotrexate. *Fertil Steril* 2004; 82(5): 1374-78.

Gervaise A, Masson L, de Tayrac R, et al. Reproductive outcome after methotrexate treatment of tubal pregnancies. *Fertil Steril* 2004; 82(2): 304-8.

Trambert JJ, Einstein MH, Banks E, Frost A, Goldberg GL. Uterine artery embolization in the management of vaginal bleeding from cervical pregnancy. *J Repro Med* 2005; 50(11): 844-50.

.....

# ENDOSCOPIC SURGERY FOR CHRONIC PELVIC PAIN



**David L. Olive, M.D.**

**C**hronic pelvic pain should not be considered a primary surgical disease, but in some cases laparoscopic intervention may prove to be of value. Three procedures detailed here have some application to this problem; each can be helpful in specific instances where patients have been thoroughly evaluated and a number of diagnoses excluded. Thus, it is imprudent to think of these procedures as generalized approaches to the problem of chronic pelvic pain. Rather, these surgeries represent highly specialized techniques to combat specific pathologies.

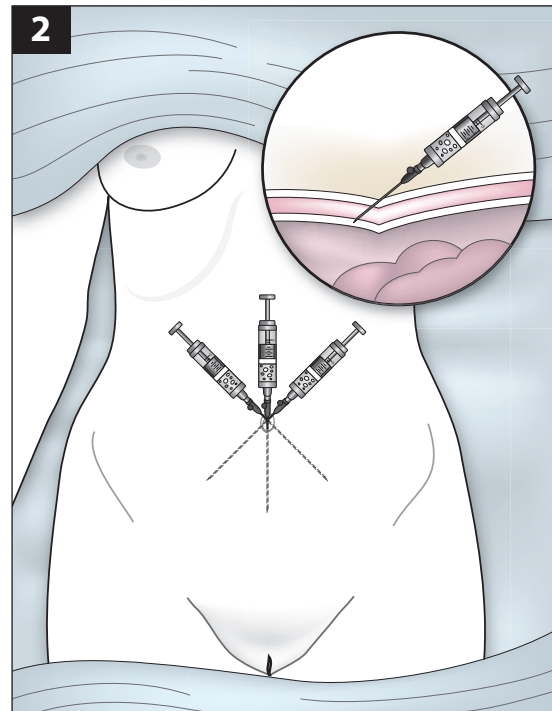
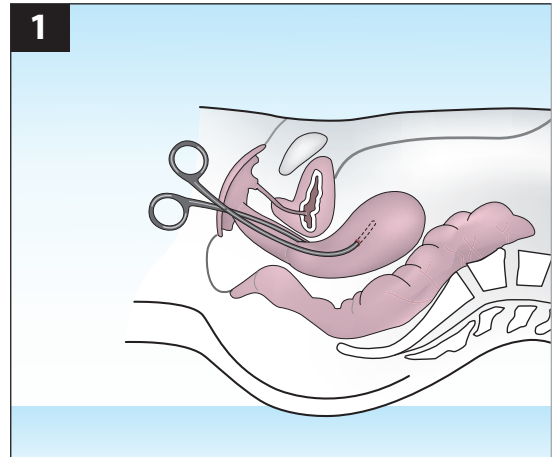
A second aspect these three procedures share is a lack of proven efficacy. While all seem theoretically sound, only the laparoscopic uterosacral nerve ablation has undergone testing via randomized clinical trial, and even here the numbers are small and follow-up is brief. Before these procedures are adopted as routine, more rigorous testing and evaluation are clearly needed.

Chronic pelvic pain (CPP) is the bane of existence for many gynecologists: it is difficult to diagnose, and treatments are often of questionable efficacy. Medical therapy is generally the initial therapy; only when this has failed do gynecologists resort to surgical intervention. Even in this

situation, directly viewing the pelvis can be problematic: in a review by Howard, 61% of patients with chronic pain had pathology at laparoscopy versus 28% in the control group. However, less than half these women experienced pain relief with surgical intervention. This raises several important issues regarding the role of endoscopic surgery for pelvic pain:

1. Can surgery help identify factors critical to the etiology of pelvic pain?
2. Can surgical targets be identified that will modify the pain experienced by those with CPP?
3. Does surgical intervention provide an advantage over medical therapy in the treatment of CPP?

Several chapters in this textbook consider procedures directed at pathology believed to contribute to pelvic pain (see Chapter 9 on Endometriosis, Chapter 10 on Adhesiolysis, and Chapter 14 on Presacral Neurectomy). This chapter will review additional procedures used to combat pelvic pain. The first, laparoscopy under local anesthesia/conscious sedation, is used to map the pain and attempt to determine the potential for surgical and medical intervention. The second, laparoscopic uterosacral nerve ablation/resection, is an attempt to alter the transmission pathway of pain from the central pelvis. Finally, uterine suspension is a procedure used to alter anatomic relationships in an attempt to reduce a specific type of pain: dyspareunia. These procedures will be reviewed in detail in terms of their indications, methodology, and rates of success.



### MICROLAPAROSCOPY UNDER LOCAL ANESTHESIA AND CONSCIOUS SEDATION

When patients present to the physician's office with CPP, the physician generally develops a differential diagnosis and

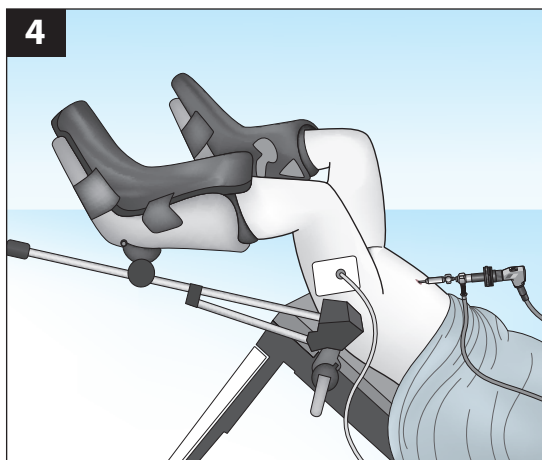
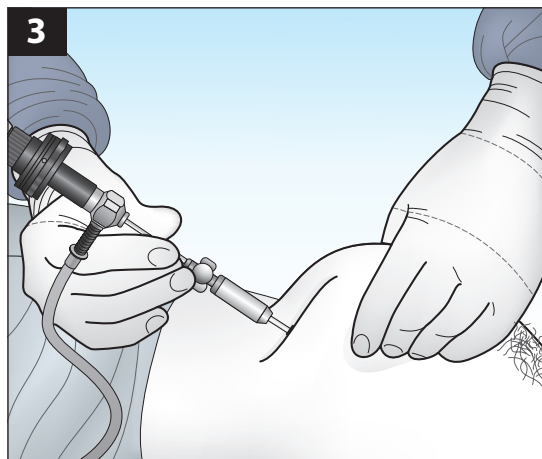
investigates those etiologies thought to be of reasonable likelihood. Often that involves pathology that could be easily viewed at laparoscopy: examples include endometriosis and pelvic adhesions. However, an assumption is often made that pathology seen is causative of, or directly related to, the pelvic pain. In addition, patients with no visible pathology are often assumed to be disease free despite continual pain. When the patient is under general anesthesia, no feedback can be obtained that will add information beyond visual inspection of the pelvis.

Pain mapping during laparoscopy under local anesthesia/conscious sedation allows evaluation of the internal anatomy as a causative factor for chronic pain. The technique is as follows:

A uterine manipulator is placed within the cervical canal, with only local anesthesia (or none). Intrauterine balloons or heavy instruments with traction should be avoided, as they produce significant pain in a large number of patients (Figure 1).

The patient, having been administered mild intravenous sedation (medazolam 1 mg, fentanyl 0.025 mg), is now given local anesthetic in the umbilicus (1% lidocaine and 0.25% bupivacaine in a 1:1 mixture). The local anesthesia is injected first superficially, then deep into the subcutaneous tissue and fascia (Figure 2).

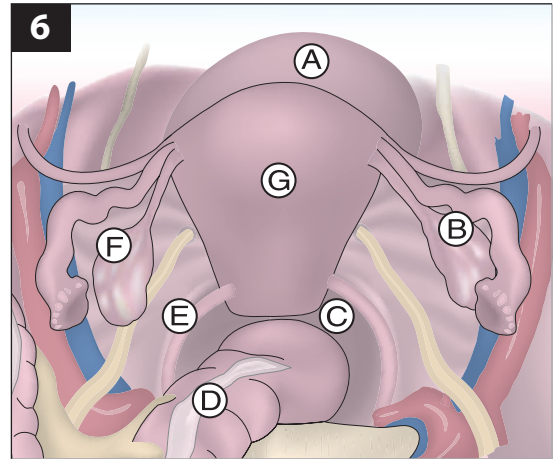
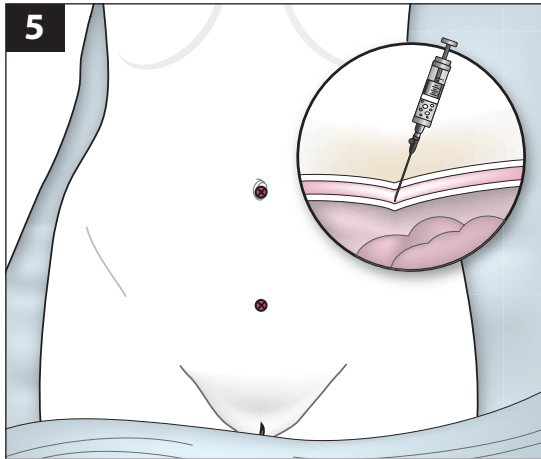
After waiting approximately one minute, a small (2 mm) incision is made in the umbilicus. The lower abdomen is grasped and raised, and a Veress needle with microlaparoscopic sheath is inserted directly into the peritoneal cavity. No insufflation is performed initially; instead,



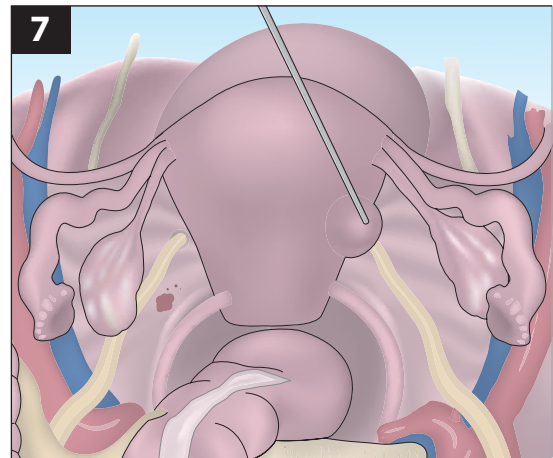
the laparoscope is inserted to determine if placement is correct. If so, insufflation is carried out slowly under direct visualization (Figure 3). Once the pelvis can be seen, the patient is placed in steep Trendelenburg position and the insufflation turned off (Figure 4).

A second puncture site is chosen in the midline just above the pubic symphysis. Local anesthesia, incision, and Veress needle/trocar placement are performed as with the umbilical incision, but this time under direct visualization (Figure 5).

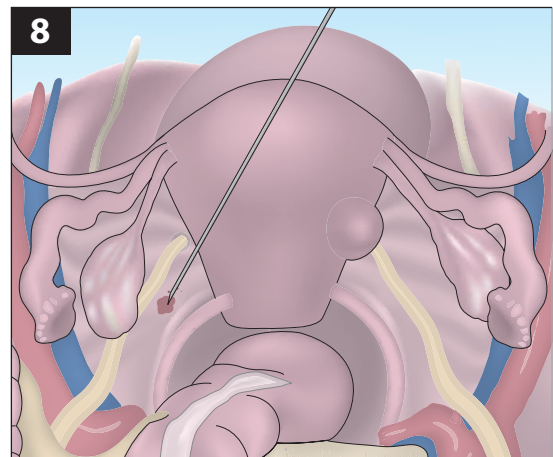




Complete, systematic inspection of the pelvis is now performed. Using a blunt probe in the second trocar site, pressure is applied to each area of normal anatomy and pathology. This can be done most consistently by developing a routine. Our technique is to begin in anterior cul-de-sac and move in a clockwise fashion, thus: (A) the anterior cul-de-sac, (B) right adnexa, (C) posterior cul-de-sac, (D) rectum, (E) uterosacral ligaments, (F) left adnexa, and (G) uterus are all observed and prodded. The patient is asked to rate each area, when probed, on a scale of 0–10, as well as to state whether or not the pain is identical to that responsible for her symptoms (Figure 6).



If areas of pathology are noted, these too are examined for eliciting pain, utilizing the same technique as above (Figure 7). If a distinct area of pain is noted, local anesthesia can be applied directly to the area and pain relief is assessed (Figure 8).



If a uterosacral nerve ablation is contemplated in the future, injection of the uterosacral ligaments under direct visualization is performed in an attempt to predict

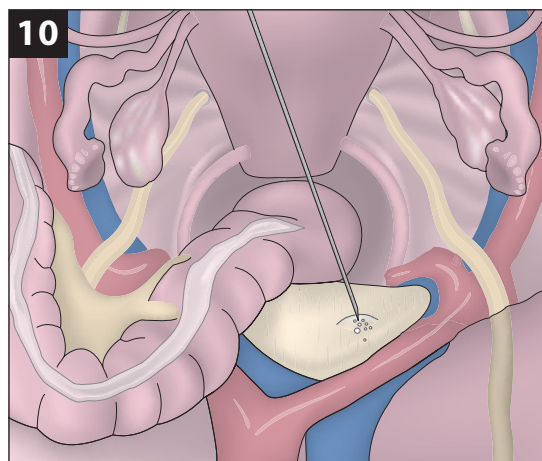
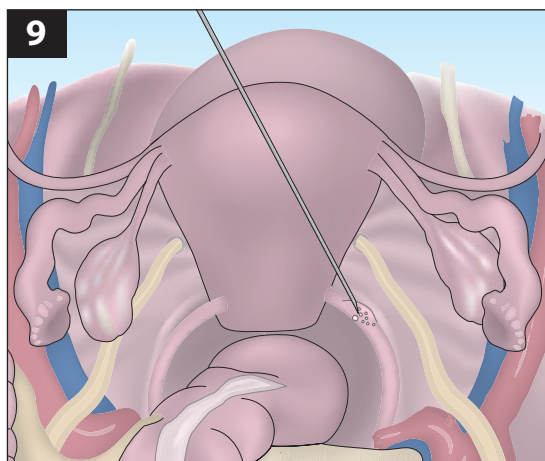


TABLE I

## RESULTS OF OFFICE MICROLAPAROSCOPY UNDER LOCAL ANESTHESIA

	ALL	CPP	INF	P VALUE
AGE (YEARS)	35.33	36.45	34.56	NS
GRAVIDITY	0.96	1.55	0.56	<0.05
OPERATIVE TIME (MINS)	20.85	23.91	18.75	NS
RECOVERY TIME (MINS)	51.65	51.64	51.67	NS
FENTANYL (MG)	81.48	90.91	75.00	0.05
VERSED (MG)	3.20	4.00	2.66	<0.05
PAIN SCALE SCORE	5.87	7.00	5.04	<0.05
30 MIN POSTOP PAIN SCORE	1.48	3.17	0.53	<0.005
TIME TO NORMAL ACTIVITY (DAYS)	1.88	1.73	2.01	NS
TIME TO RETURN TO WORK (DAYS)	1.70	2.23	1.29	<0.05
TIME TO RESUME INTERCOURSE (DAYS)	4.61	5.42	4.21	NS
POSTOPMED USAGE (TABLETS IBUPROFEN)	4.88	9.45	1.53	<0.005

efficacy (Figure 9). Similarly, if a presacral neurectomy is considered, injection of anesthetic into this area can help determine its likely value (Figure 10).

When the procedure is complete, all instruments are removed. Sutures are not

needed to close incisions; small bandages are all that is required.

Results of pain mapping with microlaparoscopy under conscious sedation reveal it to be an extremely well tolerated procedure (Table 1). However, patients with pelvic

pain do respond more poorly than those undergoing the procedure for other indications.

Three overall patterns of response have been observed. In some patients, pain is either not elicited or is uniformly present at a low level. A second group of patients exhibit focally painful areas with a rating significantly greater than background. This finding of focal pain is often independent of identifiable pathology. While these patients may be regarded as surgical candidates, it must be realized that long-term follow-up studies have not been performed to test this hypothesis. A final subset of patients exhibits what we have called generalized visceral hypersensitivity (GVH): these women have pain in virtually all areas probed. It is our hypothesis that these patients will do poorly at surgery; however, this too is untested.

Recent studies suggest that visceral pain is observed in about half of all women undergoing this procedure for pelvic pain. Of even more interest is the frequent misperception of pain location by the patient: 18% perceive pain on the opposite side of the area being palpated, while 31% perceive discomfort at a location outside the pelvis.

Several investigations have attempted to determine the comparative cost effectiveness of microlaparoscopy under conscious sedation. The procedure has repeatedly been shown to be highly cost effective, with less patient discomfort, fast return to daily activities, and shorter hospital stay.

## LAPAROSCOPIC UTEROSACRAL NERVE ABLATION (LUNA)

The central portion of the pelvis receives the bulk of its nerve supply from sympathetic nerve branches and parasympathetic fibers that pass through the uterosacral ligament. One approach to reducing central pelvic pain has been to surgically interrupt these fibers. Two approaches have been utilized: (1) presacral neurectomy (see Chapter 19) and (2) uterosacral nerve ablation. Both can be performed via the endoscope; the latter is described here.

The surgeon must begin by closely examining the pelvic anatomy of the posterior cul-de-sac. If adhesion formation is present, this must be lysed and structures identified prior to any tissue destruction for pain relief. In particular, the ureters must be clearly identified and distinguished from the uterosacral ligaments; these can be closely approximated or even confused with one another in the presence of substantial pathology.

Once the uterosacral ligaments have been clearly isolated from surrounding structures, they are grasped. The ligament is mobilized medially by longitudinally incising the peritoneum lateral to the structure and medial to the ureter (Figure 11).

The uterosacral ligament is then incised at the cervico-utero-ligament junction. The uterosacral ligament is similarly incised approximately 4 cm distally (Figure 12). Anatomic investigations have

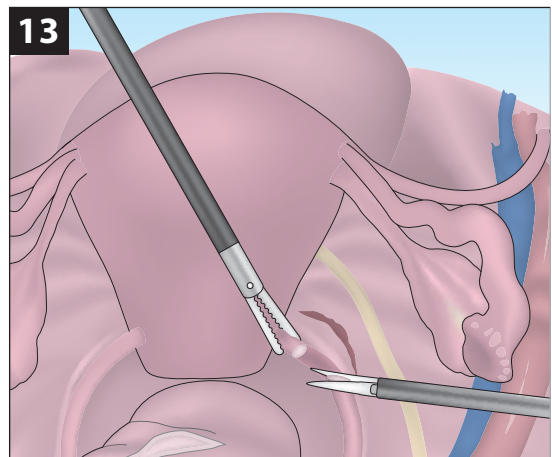
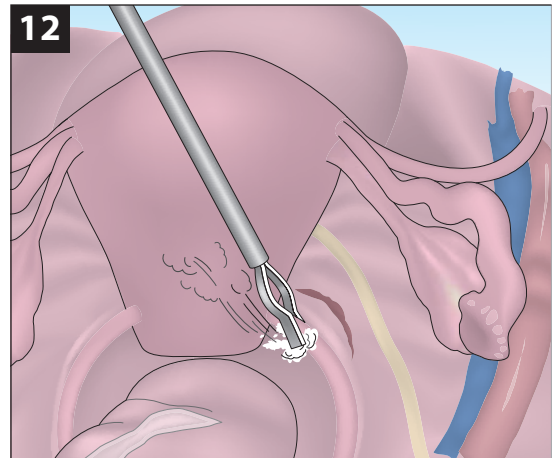
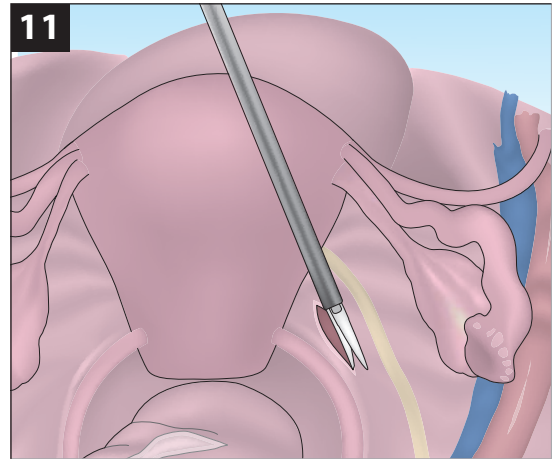
shown that the greatest concentration of nerve fibers (primarily sympathetic and parasympathetic) are found 16.5-33 mm from the cervico-utero-ligament junction, at a depth of 3-15 mm from the surface.

The ligament is now dissected free of all underlying tissue, and the peritoneum medial to the structure is incised, resulting in complete excision of this portion of the uterosacral ligament (Figure 13). The entire procedure is carried out bilaterally.

Results of uterosacral nerve ablations show the procedure to be highly efficacious initially in the treatment of dysmenorrhea. However, the amount of pain relief appears to decline substantially over time, and the procedure has produced results inferior to those of presacral neurectomy at 12 months.

One explanation for this may be the wide variation in technique used by surgeons worldwide; the use of cauterization versus excision, as well as varying locations and depths of interruption have led to drastically different impressions of efficacy.

Significant complications have been reported for the LUNA. Ablating or resecting the uterosacral ligaments may result in a loss of pelvic support and ultimately prolapse. Significant bladder voiding dysfunction has also occurred. Finally, ureteral damage due to incorrect identification and isolation of structures is reported.



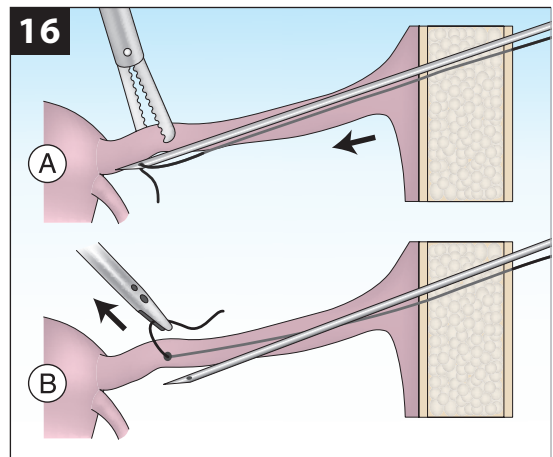
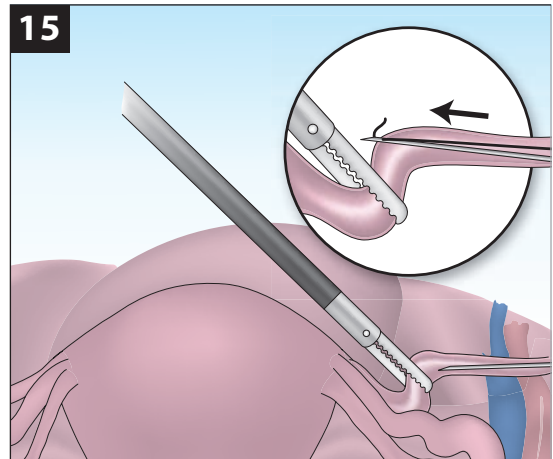
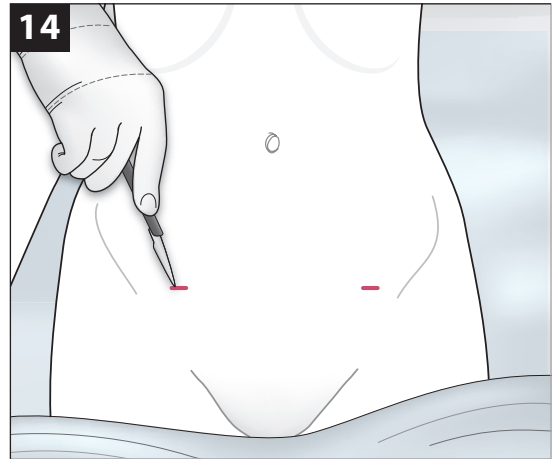
## UTERINE SUSPENSION

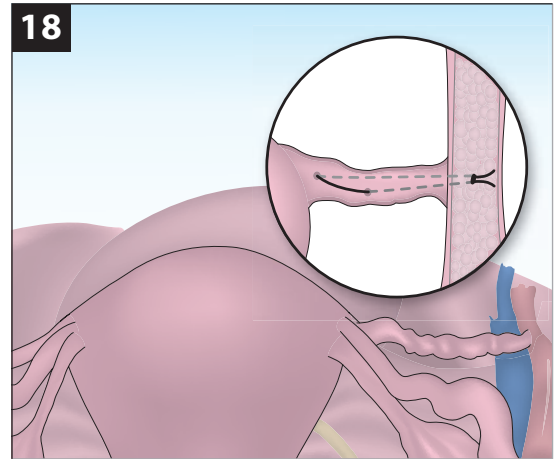
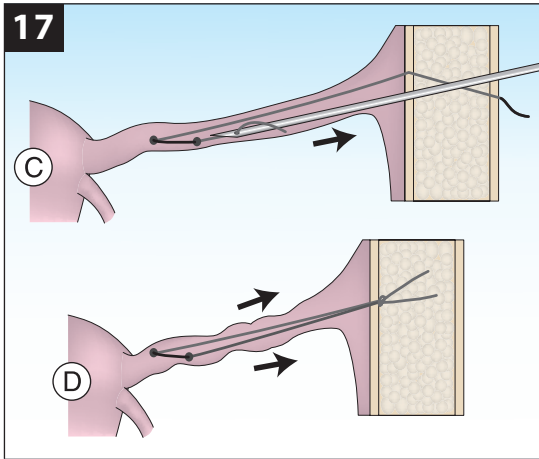
Displacement of the uterus posteriorly was regarded for some time as a pathologic entity, but recent evidence suggests that few disorders are truly linked to such displacement. Contact dyspareunia has been noted in selected women with retropositioned uteri; correction of the uterus to a more anterior position has been used as an attempt to remedy the symptom. Additionally, it is often desirable following extensive surgery of the posterior cul-de-sac to prevent uterine retropositioning in the postoperative period, thereby minimizing adhesion formation in this compartment.

The uterine suspension is best performed laparoscopically with specialized instruments designed to grasp the round ligament and pass suture via small abdominal incisions. A permanent suture is also advised for long-term stability of the repair.

Initially, a small 2 mm incision is made in the skin just above the insertion of the round ligament into the abdominal wall (Figure 14). Using a grasping instrument, the round ligament is grasped and placed in tension to provide a straight course. A suture passer is inserted through the abdominal wall and within the round ligament to within 1-2 cm of the uterus (Figure 15).

The passer then exits the round ligament, the suture is released, and the grasper is used to grasp the suture end (Figure 16). The passer is removed, then reinserted and pushed through a second exit point. The free suture end is then grasped by the passer (Figure 16 B).





The free end is withdrawn with the passer, and the suture is tied above the abdominal wall fascia, shortening and strengthening the round ligament (Figures 17 and 18). The procedure is then repeated on the opposite side.

Uncontrolled trials have repeatedly shown this procedure to be of value in relief of dyspareunia and other pain symptoms believed related to uterine location. Recent evidence suggests that

the initial relief may in fact be fairly durable: in one study of 5-20 years of follow-up, pain relief lasted for approximately one-half the treated women. Recently, a randomized clinical trial has further suggested the value of this procedure, with 87.5% of women with symptomatic uterine retroflexion demonstrating a diminution of pain, a result significantly better than that seen with diagnostic laparoscopy alone.

SUGGESTED READING:

Howard FM. The role of laparoscopy in chronic pelvic pain: promise and pitfalls. *Obstet Gynecol Surg* 1993;48:357-387

Palter SF, Olive DL. Office laparoscopy under local anesthesia for chronic pelvic pain. *J Am Assoc Gynecol Laparosc* 1996;3:359-364

Palter SF. Office-based surgery and its role in the management of pelvic pain. In Blackwell RE, Olive DL, eds. *Chronic pelvic pain: evaluation and management*. New York, Springer-Verlag, 1998:167-182

Lichten EM, Bombard J. Surgical treatment of primary dysmenorrhea with laparoscopic uterine nerve ablation. *J Reprod Med* 1987;32:37-41

Chen FB, Chang SD, Chu KK, et al. Comparison of laparoscopic presacral neurectomy and laparoscopic uterine nerve ablation for primary dysmenorrhea. *J Reprod Med* 1996;41:463-466

Davis GD. Uterine prolapse after laparoscopic uterosacral transection in nulliparous airborne trainees: a report of three cases. *J Reprod Med* 1996;41:279-282

Fitzpatrick CC, Flood H, Punch M, et al. Bladder dysfunction after repeat laparoscopic uterine nerve ablation (LUNA). *Int Urogynecol J* 1995;6:31-33

Sharp HT. Surgical management of pelvic pain. In Blackwell RE, Olive DL, eds. *Chronic pelvic pain: evaluation and management*. New York, Springer-Verlag, 1998, pp 153-166

Carter JE. Carter-Thomason uterine suspension and positioning by ligament investment, fixation, and truncation. *J Reprod Med* 1999;44:417-422

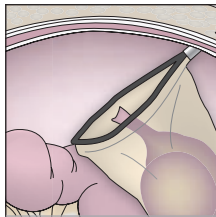
Ivey J. Laparoscopic uterine suspension as an adjunctive procedure at the time of laser laparoscopy for the treatment of endometriosis. *J Reprod Med* 1992;37:759-765

Fujii M, Sagae S, Sato T, Tsugane M, Murakami G, Kudo R. Investigation of the localization of nerves in the uterosacral ligament:determination of the optimal site for uterosacral nerve ablation. *Gynecol Obstet Invest* 2002;54 Suppl 1:11-16

Demco LA. Pain referral patterns in the pelvis. *J AAGL* 2000; 7:181-183

Ostrzenski A. Laparoscopic retroperitoneal hysteropexy: A randomized trial. *J Reprod Med* 1998;43:361-366

# LAPAROSCOPIC MANAGEMENT OF THE ADNEXAL MASS



***C. William Helm, M.D., MB, BChir  
Resad Pasic, M.D., Ph.D.***

**T**he management of an adnexal mass remains one of the most interesting and rewarding areas for the gynecologist and combines the need for appropriate work-up and sound judgment to ensure the optimum outcome for the patient.

The laparoscope is a tool in the surgical armamentarium that should be utilized in the appropriate fashion and not every patient with an adnexal mass can be managed laparoscopically.

## WHAT CONSTITUTES AN ADNEXAL MASS?

Although the adnexa strictly includes only the ovary, fallopian tube, and broad ligament, blood vessels and fascia contained in it, there are many causes of a mass laterally placed in the pelvis which need to be included in the differential diagnosis.

For the purposes of this chapter only gynecologic conditions will be considered.

The questions in relation to an adnexal mass which need addressing are: what is the cause of the mass? Does it need surgical treatment and if so, what kind of surgery?



TABLE 1

**NON-GYNECOLOGIC CAUSES OF ADNEXAL MASS****BOWEL**

FECES  
 DIVERTICULAR DISEASE  
 ILEITIS  
 APPENDICITIS  
 MUCINOUS TUMOR OF APPENDIX  
 SMALL BOWEL STROMAL SARCOMA  
 COLON CANCER

**MISCELLANEOUS**

DISTENDED BLADDER  
 PELVIC KIDNEY  
 RETROPERITONEAL NEOPLASM  
 RETROPERITONEAL HEMATOMA

**MESOTHELIAL TUMORS**

PERITONEAL CYST  
 INTERNAL ILIAC ARTERY ANEURYSM

TABLE 2

**GYNECOLOGIC PROBLEMS CAUSING ADNEXAL MASSES****OVARY**

FUNCTIONAL CYSTS  
 NEOPLASM  
 BENIGN  
 MALIGNANT  
 METASTATIC

**PARA-OVARIAN CYST****FALLOPIAN TUBE**

TUBO-OVARIAN ABSCESS  
 PYOSALPINX  
 HYDROSALPINX  
 ECTOPIC PREGNANCY

**PERITONEAL CYST**

APPENDICEAL TUMOR  
 PELVIC ABSCESS

**DIAGNOSIS OF AN ADNEXAL MASS**

Most often the diagnosis of gynecologic causes of an adnexal mass are made with a combination of history, examination and special investigations.

Since every woman of child bearing age is pregnant until proven otherwise, knowing the level of  $\beta$ -hCG is essential in excluding the possibility of an ectopic pregnancy.

Following the exclusion of pregnancy, the most useful investigation for an adnexal mass is transvaginal ultrasound. When an ovarian cyst/mass is present, features associated with benignity include small size with simple character having a thin wall, without septations, papillations, excrescences or solid ele-

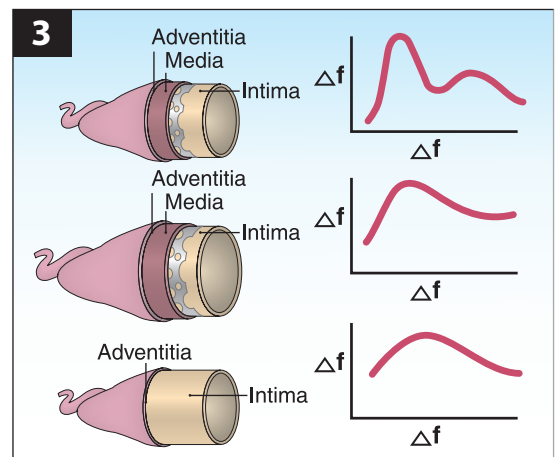
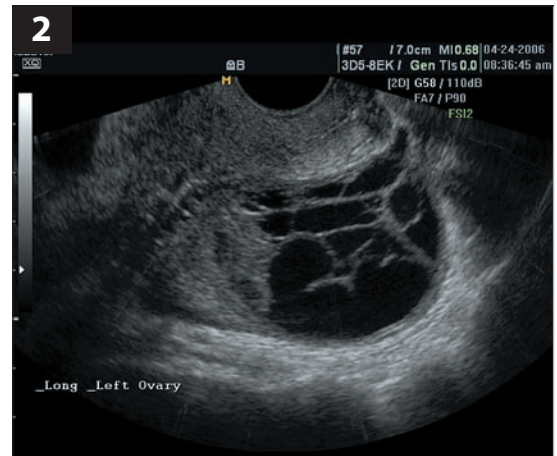
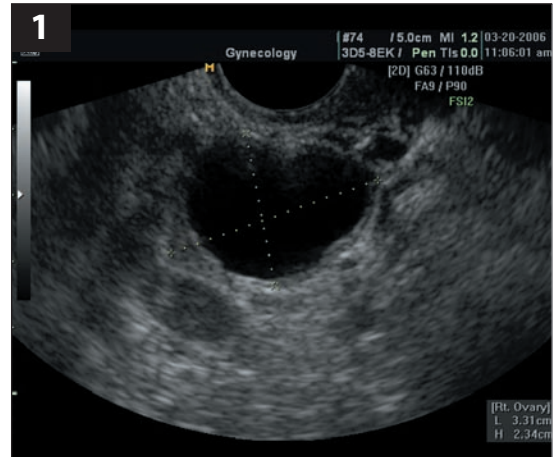
ments (Figure 1). Ultrasonic features of malignancy include increased volume, papillations, internal septa, excrescences and thickening of the wall or septa (Figure 2). Scoring systems have been developed to facilitate the interpretation of ultrasound features. At one time there was concern about the presence of simple ovarian cysts in post-menopausal women but it is now known that these are extremely common and not only is the risk of malignancy low in unilocular ovarian cystic tumors <10 cm in diameter in women 50 years of age and older, but the majority of these cysts will resolve spontaneously.

Ancillary tests have been developed to help better differentiate benign from malignant ovarian cysts. Color-flow Doppler demonstrating blood flow within and around the cyst has never

achieved a pivotal role in the workup of adnexal masses despite initial enthusiasm. The waveform shape obtained by Doppler imaging provides a rough indication of the type of blood flow within a blood vessel. Tumor vessels typically have continuous high diastolic flow with low pulsatility due to the lack of a muscular layer in the vessel wall and this is associated with a low resistance index. Normal arterioles have a muscular layer that helps regulate parenchymal perfusion. This is associated with lack of continuous diastolic flow, high pulsatility, a resistance index higher than 0.7 and presence of a diastolic notch (Figure 3). Unfortunately, some benign lesions including hemorrhagic luteal cysts, dermoid cysts and inflammatory masses such as tubo-ovarian abscesses may demonstrate low impedance or high diastolic flow similar to cancers.

More accurate methods of ultrasonography have, and are, being developed including 3D ultrasound along with the use of intravenous contrast agents.

Many adnexal masses are picked up incidentally on CT scanning but this modality is not usually as helpful in work-up of a known adnexal mass. MRI may be better, particularly in determining whether a solid mass such as a pedunculated fibroid is arising from the uterus and for adnexal masses in obese patients where ultrasound does not give a good picture. Tumor markers play a role in the workup of an adnexal mass.  $\beta$ -hCG will rule out pregnancy if negative. It is also raised in choriocarcinoma and mixed germ cell tumors.



CA125 plays a major role in the management of ovarian cancer but it is not so useful in the diagnosis of adnexal masses. First, it is only raised in about 50% of all stage 1 carcinomas of the ovary and secondly it is non-specific and raised in many benign and other malignant lesions. Many of the benign causes of elevated CA125 resolve after the menopause and thus the level of CA125 has improved accuracy in post-menopausal patients.

Other tumor markers that may need to be tested, particularly prior to surgery in young females under the age of 30 with a mainly solid adnexal mass are, alpha-fetoprotein raised in endodermal sinus (yolk sac) tumors, LDH (raised in dysgerminoma),  $\beta$ -hCG (raised in choriocarcinoma) and alpha subunit of inhibin (raised in granulosa cell tumors).

## **SURGERY**

Once the decision is made that laparoscopic surgery will be performed the question as to who should perform the operation comes in to play. As with any surgical procedure the operation should be performed by a surgeon with the skill, experience and understanding of the disease that is being treated.

One of the main concerns for a patient undergoing surgery for an adnexal mass is whether or not it may be a cancer. If the mass could represent an early ovarian cancer, then the further surgery should be performed expeditiously in conjunction with a gynecologic cancer specialist. The American College of

Obstetricians and Gynecologists has issued guidelines on which patients should be referred to a gynecologic cancer specialist prior to surgery. These represent guidelines only and may be considered by some as not stringent enough.

## **PRE-OPERATIVE PREPARATION**

Patients should be counseled about the possible findings at the time of surgery and the procedures that might be necessary. All patients undergoing laparoscopy should be warned that conversion to a laparotomy may be necessary. Those with known or suspected, severe adhesions and those in whom cancer might be detected should have preoperative bowel preparation.

## **SURGICAL APPROACH**

All patients undergoing surgery for an adnexal mass should have anti-venous thromboembolism measures taken including the wearing of anti-thrombotic stockings and/or sequential compression devices. The surgery should normally be performed under general anesthetic. The whole of the abdominal skin should be prepared in case a laparotomy is needed and all patients should have a vaginal prep.

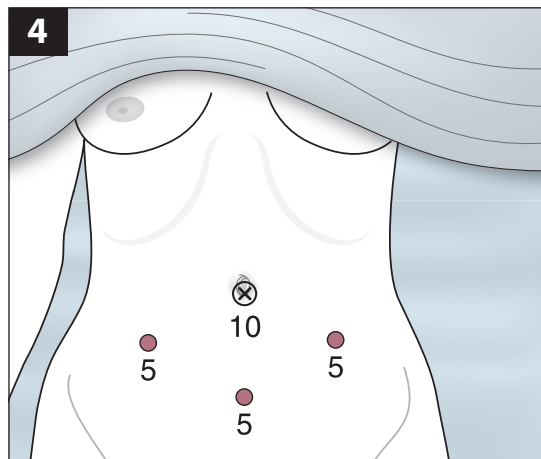
A Foley catheter should be placed to reduce the chance of bladder injury and to improve the operative view. If the patient has a uterus and is not pregnant, then a uterine manipulator can be placed to allow manipulation of the uterus in order to facilitate the adnexal dissection.

If the uterus is absent, a sponge-on-a-stick in the vagina may be very helpful.

A left upper quadrant approach for passing the Veress needle is useful if the patient has had previous surgery involving a midline incision but make sure the patient has had the stomach emptied with a nasogastric or orogastric tube.

An open entry technique either at the umbilicus or above the level of the midline scar is also useful but it is important to take great care not to enter adherent bowel. Whichever route is used, a camera is placed through the initial port and once enough CO<sub>2</sub> has been insufflated, an assessment is made of the abdominopelvic cavity. A 10-mm, 0° diagnostic laparoscope is utilized at the umbilicus because it affords an excellent field of vision, and three 5-12 mm ancillary ports are utilized as needed (Figure 4). Particularly, if the patient is obese we find it useful to secure the ancillary ports to the skin with a '0' suture running from the skin to the gas valve on the port, to reduce the chance that it will be pulled out. The scope is rotated around to inspect the peritoneum, liver, gall-bladder, omentum, appendix and at least the surface of the stomach, as well as small and large bowel. Gross disease may be visible with the camera port alone but if not then a second port is placed and a grasper is passed to facilitate this inspection.

In the pelvis it is necessary to assess all pelvic structures including the peritoneum, uterosacral ligaments, round ligaments, tubes, ovaries, and ureters. Carefully check for peritoneal nodules



that would need to be biopsied. Adhesions may greatly impede visibility but these can often be cleared with patient dissection.

If a gynecologic cancer is found, either by the initial findings or on frozen section, management should be continued with the involvement of a gynecologic cancer specialist so that the patient's outcome is optimized. In this situation, the laparoscopist's role is to make the diagnosis in the least morbid fashion.

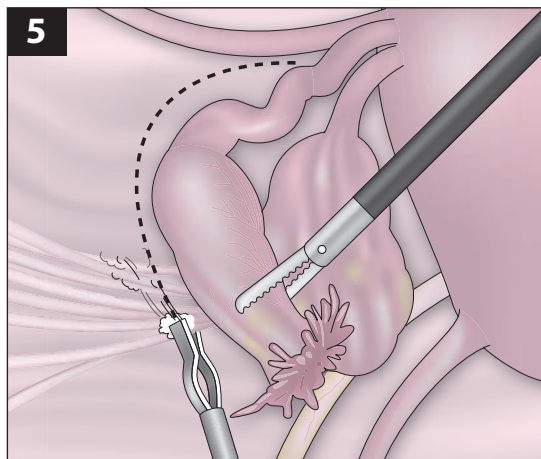
If preoperative preparation has been made and provided that the cancer is macroscopically confined within the ovary, a full laparoscopic staging operation can be performed including hysterectomy, bilateral salpingo-oophorectomy, peritoneal washings, peritoneal biopsies, subcolic omentectomy and bilateral para-aortic and pelvic node dissection.

Remember that on a percentage basis solid/complex ovarian masses in adolescents are more likely to be malignant than in adults.

Beware the patient with an adnexal mass who has previously undergone hysterectomy. Removal of adnexal structures may be difficult under these circumstances due to adhesions.

### ADNEXAL MASS RESECTION

Once preliminary inspection has been made, peritoneal washings taken, and a determination made that the mass is safely resectable, our approach to an adnexal mass involving the ovary or fallopian tube is to gain entry to the retroperitoneum by dividing the ipsilateral round ligament or the peritoneum just lateral to infundibulopelvic ligament (Figure 5). The fallopian tube or peritoneum covering the infundibulopelvic ligament is grasped gently and pulled away from the sidewall as the opening in the lateral peritoneum is extended cranially. The infundibulopelvic ligament is separated from the side-wall with the help of gentle traction on the fallopian tube and blunt dissection. If there is concern for the ureter and it was not identified prior to incising the lateral peritoneum, it should be identified at this time. There are several instruments available to occlude the ovarian vessels including the bipolar forceps, Harmonic Scalpel® (Ethicon Endosurgery, Cincinnati, OH), Endocutter™ (Ethicon Endosurgery, Cincinnati, OH), Ligasure™ (Valley Lab Boulder CO) Gyrus cutting forceps (Gyrus/Acmi Maple Grove, MN) or the Roeder Endoloop™ (Ethicon Endosurgery, Cincinnati, OH). Whichever is used it is important to avoid heat damage to the ovarian or mass capsule which may lead to rupture.



Once the infundibulopelvic pedicle has been ligated, the ovary can be pulled up and away exposing attachments to the sidewall. Do not grasp the ovarian cyst wall itself. These can be freed close in to the ovary together with the peritoneum lying between the ovary and the ureter, and finally the adnexal mass including the tube and ovary, may be detached from the uterus using the above instruments or an 'O' PDS Endoloop, (Ethicon Endosurgery, Cincinnati, OH).

Throughout the resection, an ovarian or other mass should not be directly grasped and manipulation should be kept to a minimum to avoid rupture and the resultant dissemination of malignant cells, a situation which should be avoided since this has been shown to adversely affect prognosis for the patient. If a dermoid cyst ruptures, the pelvis should be irrigated copiously with saline.

When an adherent mass is resected, oozing and bleeding can occur. Hemostasis can be attained by the placement of a 4x4 gauze through the

umbilical 10-12 mm port. When placed adjacent to the bleeding areas, the sucker can be applied to allow more efficient aspiration of blood and saline lavage. Surgicel™ (Ethicon Endosurgery, Cincinnati, OH) can also be placed at the end of surgery to discourage further oozing.

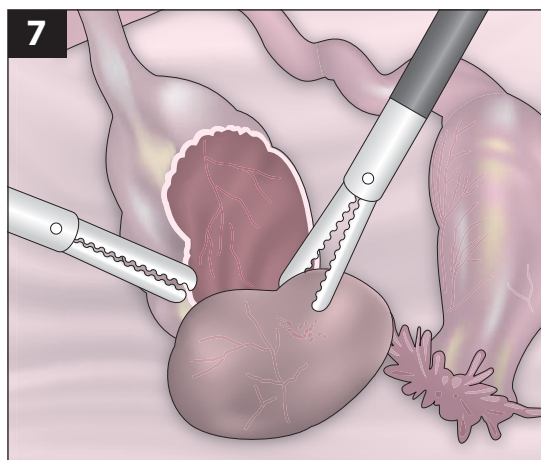
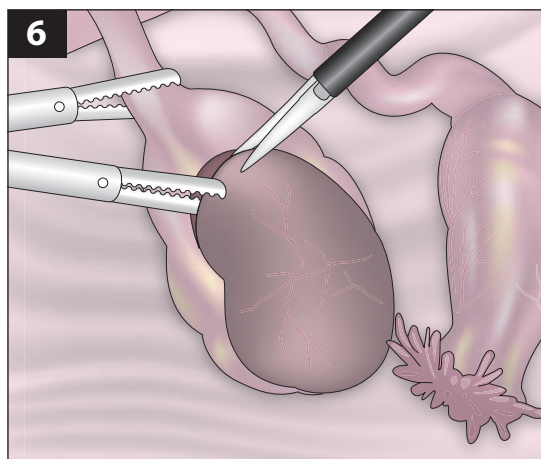
Not uncommonly, an adnexal mass may be adherent to the large or small bowel. Bowel serosa should not be forcefully held with graspers. The bowel edges should be carefully defined and the laparoscopic scissors should be used to cut the adhesions. Do not use instruments that cause heat close to the bowel and always cut parallel to the bowel surface so that the chance of damaging the bowel wall is diminished. Once the bowel is freed, inspect it carefully for serosal damage.

All potentially malignant tissue should be removed using a specimen removal bag.

## CYSTECTOMY

Aspiration of a simple ovarian cyst at laparoscopy in an attempt to treat is usually unsuccessful and there is a potential of disseminating an occult carcinoma. As far as diagnostic aspiration is concerned, cytologic analysis of aspirated cyst fluid has a high false negative rate and is not usually recommended.

Cystectomy may be indicated for benign cysts of many kinds including dermoid cysts, endometriomas and complicated functional cysts but is never indicated for potentially malignant cysts.

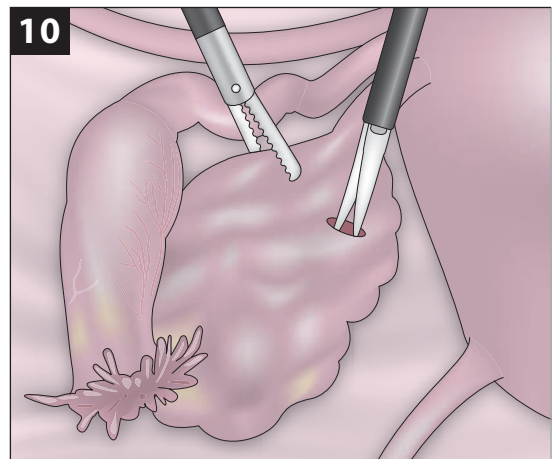
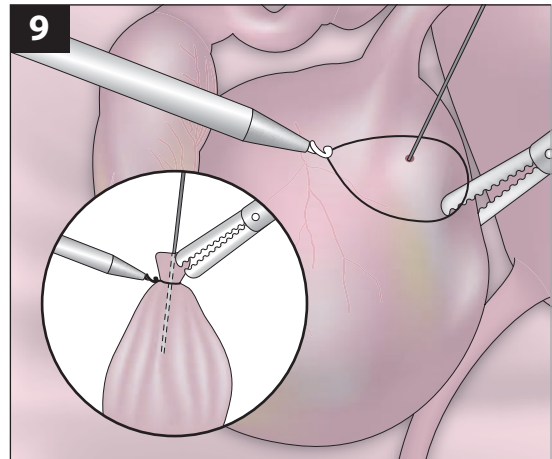
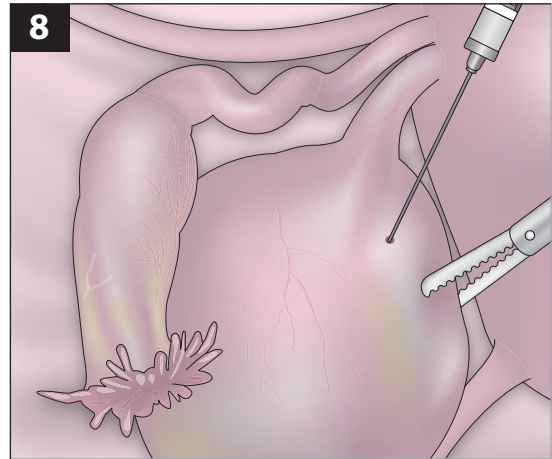


While the ovary is supported by a grasper placed underneath it, an incision is made on the border of normal ovarian tissue and the cyst. This allows the cyst wall to be identified and dissected off the normal ovarian tissue (Figures 6 and 7). The surgeon should try to remove the entire cyst intact without rupture. If an ultrasonically simple cyst appears benign at laparoscopy and is too large to dissect intact, the wall may be punctured with a needle attached to suction tubing, minimizing

spillage of the cystic fluid (Figure 8). In order to minimize the spill of the cyst fluid into the abdominal cavity, an Endoloop may be placed on the area where the cyst puncture is going to be performed. The aspiration needle is inserted through the endoloop. After most of the fluid has been aspirated, the ovary is grasped with a grasper and loop is constricted around the puncture site while the needle is removed (Figure 9). If the cyst fluid appears serous, a small incision in the cyst wall is made with laparoscopic scissors (Figure 10). The interior wall of the cystic cavity is then inspected through the laparoscope. Any suspicious areas discovered during surgery should be biopsied and sent for frozen section. If benign, resection of the entire cyst wall should be performed (Figure 11).

The cyst wall is identified and peeled off the ovary with the help of a traumatic grasper by holding the capsule and rotating it around the grasper. Another grasper is used to provide countertraction by grasping the ovarian capsule (Figure 12). Bleeding from the ovary is usually self-limited or it can be controlled with a spot coagulator or bipolar forceps. The resected tissue and the ovarian capsule are removed through a laparoscopic port by rotating the grasper and pulling it through the port. If the tissue is too big or potentially cancerous it should be placed into a removal bag that is introduced through a 10 mm port (Figure 13). The tissue extraction techniques from the peritoneal cavity are presented in Chapter 19.

The technique of salpingectomy is presented in Chapter 11.

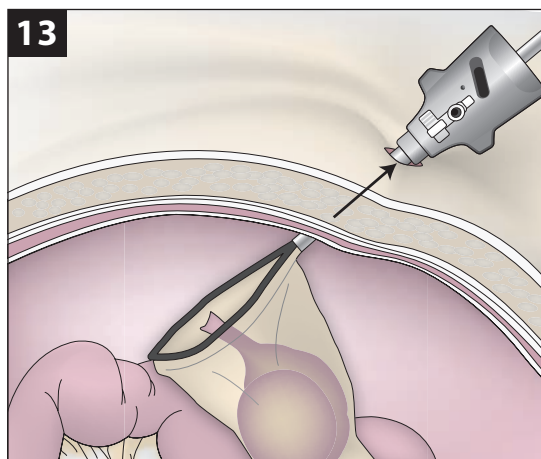
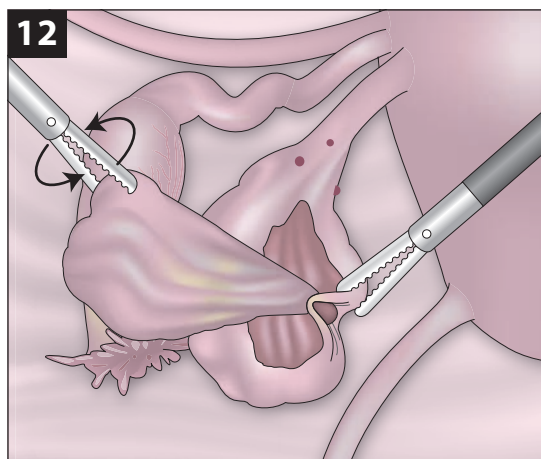
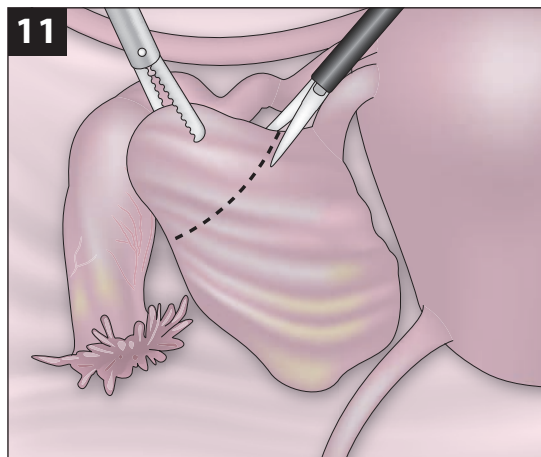


## SURGERY IN PREGNANCY

Laparoscopic removal of an adnexal mass in pregnancy is sometimes necessary and several factors should be considered. Depending on the gestational age, preoperative consultation should be made with an obstetric specialist. Patients in the second trimester should be placed in the dorsal supine position with left lateral tilt and anti-thromboembolic stockings and sequential compression devices should be applied. The placement of the laparoscope and the operating trocars should be modified depending on the uterine size. An open technique or left upper quadrant technique should be used for initial placement. When the CO<sub>2</sub> is insufflated, keep the intraperitoneal pressure to 12 mmHg or less to ensure adequate venous return to the heart. This will maximize maternal cardiac output and minimize fetal acidosis. However, brief elevations at the beginning of the procedure can be well tolerated. During the operative procedure, it is a good idea to keep uterine manipulation to a minimum.

## ADHESION PREVENTION

Following removal of adnexal structures, consideration should be given to reducing the chance of pelvic adhesions developing. Initially, careful attention is given to hemostasis and irrigation with saline is performed. Interceed™ or any adhesive prevention technique of surgeon's preference may be placed through the 10 mm port.





## SUGGESTED READING:

Sassone AM, Timor-Tritsch IE, Artner A, Westhoff C, Warren WB. Transvaginal sonographic characterization of ovarian disease: evaluation of a new scoring system to predict ovarian malignancy. *Obstet Gynecol* 1991;78:70-76

Wolf SI, Gosink BB, Feldesman MR, Lin MC, Stuenkel CA, Braly PS, Pretorius DH. Prevalence of simple adnexal cysts in postmenopausal women. *Radiology* 1991;180: 65-71

Miralles C, Orea M, Espana P, Provencio M, Sanchez A, et al. Cancer Antigen 125 associated with multiple benign and malignant pathologies. *Ann Surg Oncol* 2003;10:150-154

Chan L, Lin WM, Uerpaiojkit B, Hartman D, Reece EA, Helm W. Evaluation of adnexal masses using the new 3D ultrasound technology: A preliminary report. *J Ultrasound Med* 1997 16: p. 349-354

Kohzuki M, Kanzaki T, Murata Y. Contrast-enhanced power Doppler sonography of malignant ovarian tumors using harmonic flash-echo imaging: preliminary experience. *J Clin Ultrasound* 2005;33(5): 237-42

Jacobs I, Bast RC, Jr. The CA 125 tumour-associated antigen: a review of the literature. *Human Reproduction* 1989;4(1): 1-12

Daoud E, Bodor G. CA-125 concentrations in malignant and nonmalignant disease. *Clin Chem* 1991;37: 1968-1974

Malkasian GD, Jr, Knapp RC, Lavin PT, Zurawski VR Jr, Podratz KC, et al. Preoperative evaluation of serum CA125 levels in premenopausal and postmenopausal patients with pelvic masses: discrimination of benign from malignant disease. *Amer J Obstet Gynecol* 1988;159:341-346

Maiman M, Seltzer V, Boyce J. Laparoscopic excision of ovarian neoplasms subsequently found to be malignant. *Obstet Gynecol* 1991;77: 563-567

ACOG Committee Opinion. The Role of the Generalist Obstetrician-Gynecologist in the Early Detection of Ovarian Cancer. *Obstet Gynecol* 2002;100: 1413-1416

Childers JM, Brzechffa PR, Surwit EA. Laparoscopy using the left upper quadrant as the primary trocar site. *Gynecol Oncol* 1993;50:221-225

Reich HF, McGlynn F, Wilkie W. Laparoscopic management of stage I ovarian cancer. A Case Report. *J Repro Med* 1990;35:601-605

Childers JM, Hatch KD, Tran AN, Surwit EA. Laparoscopic para-aortic lymphadenectomy in gynecologic malignancies. *Obstet Gynecol* 1993;82:741-747

Kohler C, Tozzi R, Klemm P, Schneider A. Laparoscopic paraaortic left-sided transperitoneal infrarenal lymphadenectomy in patients with gynecologic malignancies: technique and results. *Gynecol Oncol* 2003;91:139-148

Querleu D, LeBlanc E. Laparoscopic infrarenal paraaortic lymph node dissection for restaging of carcinoma of the ovary of Fallopian tube. *Cancer* 1994; 73:1467-1471

Childers JM, Lange J, Surwit EA. Laparoscopic surgical staging in ovarian cancer. *Gynecol Oncol* 1995;59: 25-33

Reedy M. et al. Laparoscopy during pregnancy, a safe alternative to laparoscopy? *Contemporary Obstetrics and Gynecology*, 1998. April 15th

Vergote I, De Brabanter J, Fyles A, Bertelsen K, Einhorn N, et al. Prognostic importance of degree of differentiation and cyst rupture in stage I invasive epithelial ovarian carcinoma. *Lancet* 2001;357: 176-182

Sunoo CS. Laparoscopic removal of a large adnexal mass. *Obstet Gynecol* 2004;103(5 Pt 2):1087-9

Duncan PG, Pope WDB, Cohen MM. Fetal risk of anesthesia and surgery during pregnancy. *Anesthesiology* 1986;64:790-794

Carter JF, et al. Hemodynamic effects of pneumoperitoneum during gynecologic laparoscopic surgery. *J Gynecol Surg* 1997;13:169-173

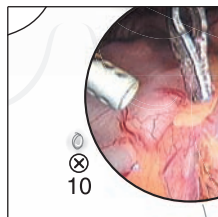
Eichenberg BJ, Vanderlinden J, Miguel C, et al. Laparoscopic cholecystectomy in the third trimester of pregnancy. *Amer Surg* 1996;62: 874-877

Carter JF, Soper DE. Operative laparoscopy in pregnancy. *J Soc Laparoendoscopic Surgeons* 2004;8(1): 57-60

Kamprath S, Possover M, Schneider A. Description of a laparoscopic technique for treating patients with ovarian remnant syndrome. *Fertil Steril* 1997; 68:663-667



# LAPAROSCOPIC PRESACRAL NEURECTOMY



***Ceana Nezhat, M.D.***

***Deidre Fisher, M.D.***

## INTRODUCTION

In 1899, Jaboulay first described presacral neurectomy as the severance of sacral sympathetic afferent fibers using a posterior extraperitoneal approach. In the same year, Ruggi described resections of the utero-ovarian plexus. Leriche advocated periarterial sympathectomy of the internal iliac arteries. Perhaps the most fervent advocate of presacral neurectomy was Cotte, who in 1937 reported excellent results (98% success rate) after transection of the superior hypogastric plexus in 1500 patients. He emphasized that the only nerve tissue that should be resected is that within the interiliac triangle, and that resection of all nerve elements in the triangle is essential. Recent advances in endoscopic surgery have allowed surgeons to perform the technique via laparoscopy.

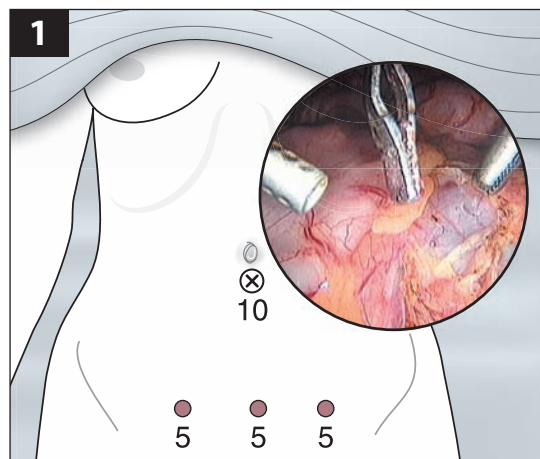
Twenty to twenty-five per cent of patients with central dysmenorrhea fail to respond to medical management and presacral neurectomy continues to be a useful alternative for these women. Presacral neurectomy is indicated in women who have disabling midline dysmenorrhea and pelvic pain who have not responded to medication. It has been proven

effective in the treatment of pelvic pain in women with endometriosis. Approximately 50-75% of patients will achieve pain relief. The procedure has also been as successful as laparotomy, with an apparently lower rate of postoperative morbidity. However, careful patient selection is a prerequisite to presacral neurectomy. The procedure should be done on women with deep, central pelvic pain that has been unresponsive to medical management. In 1992, Nezhat and Nezhat described a simplified method of presacral neurectomy in one of the earliest reports on the laparoscopic approach. The authors performed laparoscopic presacral neurectomy in 52 patients with dysmenorrhea unresponsive to medical treatment. The severity of endometriosis varied among the patients. Forty-eight of the 52 patients (92.3%) reported relief of dysmenorrhea, including 27 (51.2%) who reported complete pain relief. Carter reported on presacral neurectomy in 20 patients with follow-up of up to 18 months. The pain level in these women decreased from an average of 9.4 to 2 (on a 10-point scale with 10 indicating the worst pain and 0 indicating no pain). Nezhat et al evaluated long-term outcomes of laparoscopic presacral neurectomy in 176 women who underwent presacral neurectomy and treatment of endometriosis. More than 50% alleviation of pain was reported in 69.8% of the women with stage 1 endometriosis (using the revised classification of the American Fertility Society); 77.3% of those with stage II; 71.4% with stage III; and 84.6% with stage IV endometriosis. The authors

concluded that long-term outcome of laparoscopic presacral neurectomy is satisfactory in most patients, and that the stage of endometriosis is not related directly to the degree of pain improvement achieved. Zullo et al demonstrated the effectiveness of presacral neurectomy for women with severe dysmenorrhea due to endometriosis who had been treated with conservative laparoscopic surgical intervention. The authors published their two-year success of laparoscopic presacral neurectomy, reporting significant reduction in the frequency and severity of dyspareunia, chronic pelvic pain, and dysmenorrhea.

## INSTRUMENTATION

An operating laser laparoscope is inserted through a 10 mm trocar placed through an umbilical incision. Two or three suprapubic 5 mm cannulas are inserted at about 5 cm mid-suprapubic and 7 cm left and right side for introduc-



tion of bipolar electrode, scissors, or harmonic shears, suction irrigator, and grasping forceps, respectively (Figure 1).

## TECHNIQUE

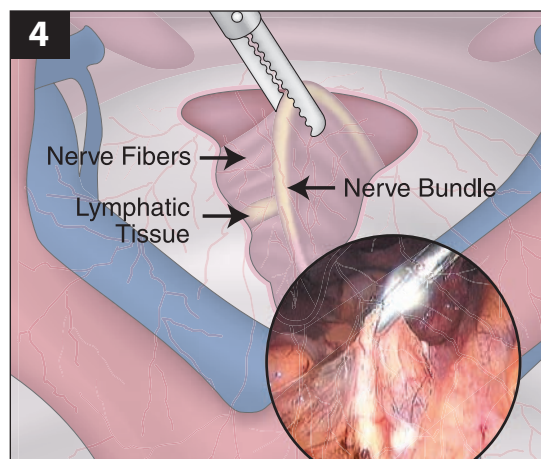
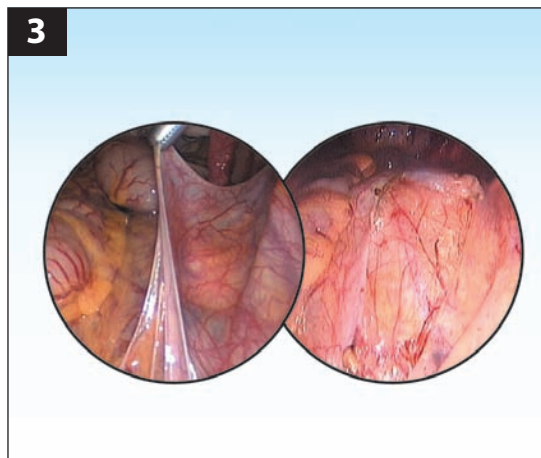
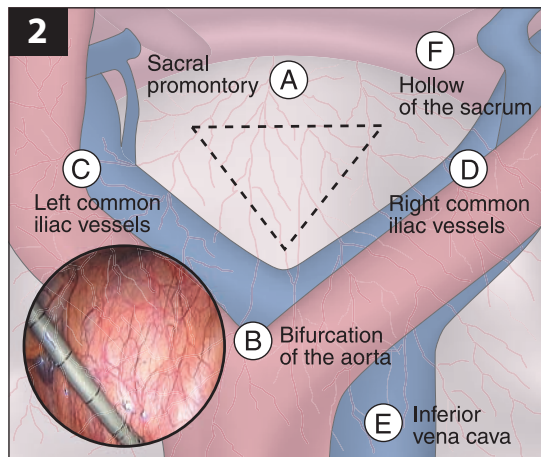
The patient is placed in the steep Trendelenburg position and tilted slightly to the left. Identification of the aortic bifurcation, the common iliac arteries and veins, the ureters, and the sacral promontory, defined as the Triangle of Côte, is completed (Figure 2).

The peritoneum overlying the promontory is elevated with grasping forceps (Figure 3), and a small opening is made with the CO<sub>2</sub> laser or scissors (or any other cutting modality).

The suction irrigator is inserted through this opening and the peritoneum is elevated by hydrodissection. The peritoneum is incised horizontally and vertically and the opening is extended cephalad to the aortic bifurcation (Figure 4).

Bleeding from the peritoneal vessels is controlled with the bipolar electrocoagulator. Retroperitoneal lymphatic and fatty tissue is removed before the hypogastric plexus is reached. Hemostasis is obtained with bipolar electrocoagulation. The pre-sacral tissue can now be identified.

The nerve plexus is grasped with an atraumatic forceps, and using blunt and sharp dissection, the nerve fibers are skeletonized, desiccated, and excised. All the nerves that lie within the boundaries of the interiliac triangle are removed, including any fibers entering the area



from under the common iliac arteries and over the left common iliac vein (Figure 5).

The retroperitoneal space is irrigated, and bleeding points are coagulated (Figure 6).

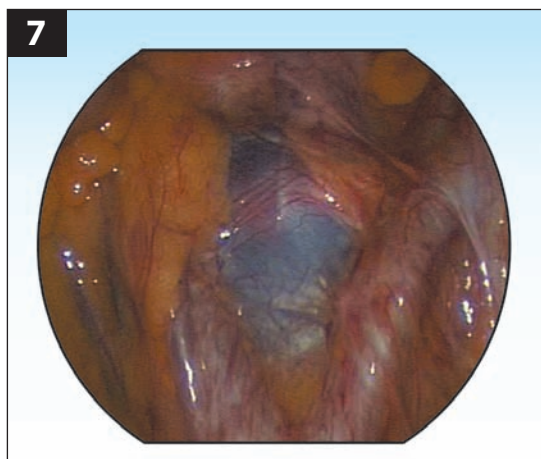
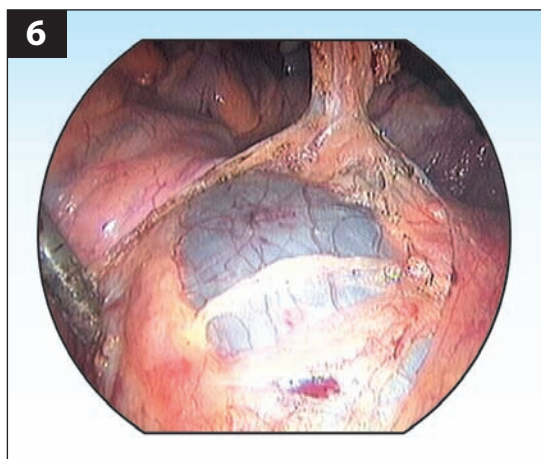
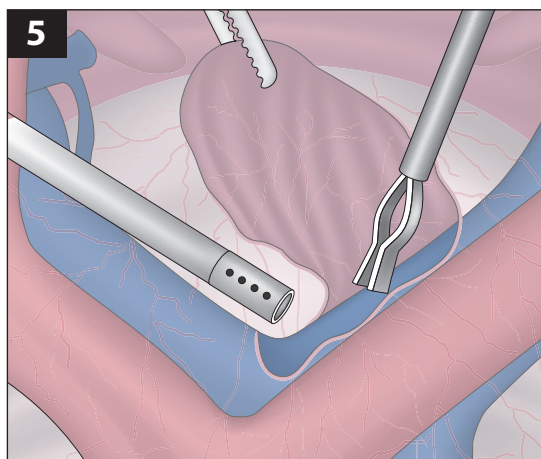
Sutures are not required to approximate the posterior peritoneum. Interceed (Johnson & Johnson Medical, Sommerville, NJ) can be applied over the incised area. The area heals completely on follow-up, and it is covered by the peritoneum (Figure 7). Excised tissue is sent for histologic confirmation.

## COMPLICATIONS

Complications of presacral neurectomy that have been reported are:

- Bleeding from midsacral to presacral vessels
- Ureteral injury
- Poor bladder emptying
- Urinary urgency
- Persistent constipation
- Painless labor
- Intermittent ileal obstruction due to adhesions
- Vaginal dryness
- Chylous ascites

The most common and urgent intraoperative complication of presacral neurectomy is bleeding. Given that the middle sacral vessels are located in the midline between the presacral nerve and the periosteum of the sacral promontory, dissection of the vessels is usually not necessary because these vessels are



located deep or inferior to the nerves. If bleeding does occur, hemostasis can be obtained by ligation, coagulation, or vascular clips. Sometimes, control of bleeding is difficult due to retraction of vessels. In these circumstances, the use of orthopedic thumbtacks directly into the vertebral body, bone wax or suturing through the periosteum and remnant presacral tissue may be necessary. If presacral vessels are damaged, the site of damage should be observed to determine whether laparoscopic attempts at repair may result in further damage, especially to the nearby major vessels. Interventional radiology may be of help in controlling the bleeding from retracted blood vessels. Because the anatomy of the great vessels can be variable, the bifurcation of the vena cava can lie more caudad than usual, placing it or the left common iliac vein at increased risk. The left common iliac vein may be inconspicuous due to a "drainage effect" from steep Trendelenburg positioning and CO<sub>2</sub> gas tamponade. It is, therefore, especially vital to actively identify the anatomy. In the hands of a surgeon skilled in laparoscopic suturing, repair of a small defect may be feasible. Otherwise, immediate conversion to at least a mini-laparotomy may be prudent.

Genitourinary complications such as ureteral injury, urinary urgency, and poor bladder emptying have been noted. Usually urgency symptoms and difficulties with bladder emptying spontaneously resolve or improve over time.

However, some cases may require catheterization or medication. Once recognized, ureteral injury should be repaired either surgically and/or by ureteral catheterization.

Chronic constipation and vaginal dryness during sexual arousal have also been reported. Vaginal dryness usually resolves within six months and lubrication is usually effective, while constipation can be successfully treated using various medical therapies and diet manipulation.

Chylous ascites, a rare complication caused by intraoperative injury to the retroperitoneal lymphatic plexus, can be treated conservatively with temporary placement of a drainage tube and restriction of fat intake. If unsuccessful, this complication is managed intraoperatively with laparoscopic bipolar cauterization, suture closure of the peritoneum, and/or Gelfoam® compression (Pharmacia & UpJohn, Inc., Peapack, NJ). Adhesions leading to either pelvic pain or intestinal obstruction have also been reported and, rarely, may require subsequent surgical intervention.

In 1992, our initial study of 85 patients revealed no major intraoperative or immediate postoperative complications. However, of the 52 women followed after 1 year, 7 women reported minor complications: constipation (3), urinary urgency (1), vaginal dryness (1), and "painless labor" (2).



## SUGGESTED READING:

Jaboulay M. Le traitement e la navralgie pelvienne par a paralysie du sympathetique sacre. *Lyon Med* 1899;90:102

Ruggi G. Della sympathectamia al collo ed ale adome. *Policinico* 1899;1:193

Leriche R. Resultant eloigne cinq ans at deni d'une sympathectomie de deux ateres hypogastriques pour dysmenorrhée douloureuse. *Lyon Ch* 1927;24:360

Cotte MG. Sur le traitement des dysmenorrhées rebelles par la sympathectomie hypogastrique periatérielle ou la section du neuf presacre. *Lyon Med* 1925;135:153

Polan ML, DeCherney A. Presacral neurectomy for pelvic pain in infertility. *Fertil Steril* 1980;34:557

Fliegner JR, Umstac MP. Presacral neurectomy: A reappraisal. *Aust N Z J Obstet Gynaecol* 1991;31:76-80

Nezhat CH, Seidman D, Nezhat F, Nezhat C. Long-term outcome of laparoscopic presacral neurectomy for the treatment of central pelvic pain attributed to endometriosis. *Obstet Gynecol* 1998;91(5 pt 1):701-704

Metzger DA, Montanino-Olivia M, Davis GD, Redwine DB. Efficacy of presacral neurectomy for the relief of midline pelvic pain. *J Am Assoc Gynecol Laparos* 1991;1(4 pt 2):S22

Nezhat C, Siegler AM, Nezhat F, Nezhat CH, Seidman D, Luciano AA. *Operative Gynecologic Laparoscopy: Principles and Techniques*. 2nd ed. New York: McGraw Hill, 2000

Perez JJ. Laparoscopic presacral neurectomy. *J Reprod Med* 1990;35:625-30

Feste JR, Wilson EE. Presacral neurectomy. In: Adamson G, Martin DC, eds. *Endoscopic Management Of Gynecologic Disease*. Philadelphia: Lippincott-Raven Publishers, 1996:227

Nezhat C, Berger G, Nezhat F, Buttram V, Nezhat CH. *Endometriosis: Advanced Management And Surgical Techniques*. New York: Springer-Verlag, 1995

Chen FP, Soong YK. The efficacy and complications of laparoscopic presacral neurectomy in pelvic pain. *Obstet Gynecol* 1998;91:701-704.

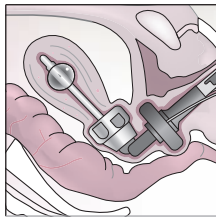
Nezhat C, Nezhat F. A simplified method of laparoscopic presacral neurectomy for the treatment of central pelvic pain due to endometriosis. *Br J Obstet Gynecol* 1992;99:659.

Carter JE. Laparoscopic presacral neurectomy utilizing contact-tip Nd:YAG laser. *Keio J Med* 1996;45:332-335.

Zullo F, Palomba S, Zupi E, et al. Effectiveness of presacral neurectomy in women with severe dysmenorrhea caused by endometriosis who were treated with laparoscopic conservative surgery: A 1-year prospective randomized double-blind study. *Am J Obstet Gynecol* 2003, 189:5-10

Zullo F, Palomba S, Zupi E, et al. Long-term effectiveness of presacral neurectomy for the treatment of severe dysmenorrhea due to endometriosis. *J Am Assoc Gynecol Laparosc* 2004;11:23-28

# LAPAROSCOPIC HYSTERECTOMY



*Robert S. Furr, M.D.*

*C. Y. Liu, M.D.*

## INTRODUCTION

**T**he advent of advanced laparoscopy has facilitated its use for removal of the uterus. The extent to which laparoscopy is used varies depending on the underlying pathology, uterine mobility, vaginal accessibility and the laparoscopic skills of the gynecologic surgeon. When a hysterectomy is indicated, the transvaginal approach should first be considered. If a vaginal hysterectomy is not feasible, a laparoscopic evaluation of the pelvis may be considered before a large abdominal incision is made. In the majority of cases, a laparoscopically assisted vaginal, laparoscopic supracervical, or total laparoscopic hysterectomy can be performed. The advantages of these minimally invasive techniques over the abdominal approach are now well documented in the literature.

Traditionally, the laparoscopic approach has been more commonly reserved to facilitate a vaginal hysterectomy. However, for the advanced laparoscopic surgeon, the uterus can be completely detached from its surrounding structures laparoscopically. In this chapter we will illustrate the various steps of hysterectomy using laparoscopy. We recommend the

novice laparoscopic surgeon master the initial, more basic, steps of performing a hysterectomy laparoscopically prior to proceeding with the more advanced steps. As more residency training programs incorporate advanced laparoscopic training and studies continue to confirm the safety, comparative costs, and overall benefits of the laparoscopic approach, patients will benefit from this advancement in surgical technique. We must remember, however, that conversion to an abdominal hysterectomy should never be considered a complication; rather it is a prudent surgical decision when the surgeon becomes uncomfortable with the laparoscopic approach.

## DEFINITIONS

To help delineate the extent to which laparoscopy is used for removal of the uterus, the following descriptive system is proposed. This system incorporates, and is a modification of, a classification system previously published by one of the authors.

**Diagnostic laparoscopy with vaginal hysterectomy:** The laparoscopic approach is used for diagnostic purposes only. Pelvic adhesions, uterine or ovarian pathology are excluded to assure the vaginal approach is safe. Laparoscopic visualization of the pelvis prior to a planned vaginal hysterectomy is justified in women with pelvic pain, history of endometriosis, previous abdominal or pelvic surgery and in women with questionable uterine or ovarian pathology.

**Operative laparoscopy with vaginal hysterectomy:** The laparoscopic approach is used to lyse adhesions to facilitate a planned vaginal hysterectomy. Laparoscopic oophorectomy, excision or ablation of endometriosis, in conjunction with a vaginal hysterectomy, would also be included in this term. No vascular or ligamentous supporting attachments to the uterus are occluded.

**Laparoscopic Assisted Vaginal Hysterectomy (LAVH):** Part, or the majority, of the vascular and ligamentous attachments to the uterus above the uterine artery are occluded laparoscopically. The uterine arteries are subsequently occluded vaginally. It is the control of the uterine arteries vaginally that distinguishes this procedure from a laparoscopic hysterectomy in which the uterine arteries are occluded laparoscopically.

**Laparoscopic Supracervical Hysterectomy (LSH or CASH):** The laparoscopic approach is used to completely detach the fundus from the cervix. The cervix, cardinal ligaments, and uterosacral ligaments are left intact.

**Total Laparoscopic Hysterectomy (TLH):** The laparoscopic approach is used to completely detach the uterus and cervix from their surrounding structures including the uterine arteries, cardinal ligaments, uterosacral ligaments and vagina. The vaginal cuff is closed laparoscopically or vaginally.

**Laparoscopic radical hysterectomy:** This procedure is used to treat stage I or IIA cervical cancer and involves removal of the uterus, the supporting ligaments

and the upper vagina, together with removal of the pelvic lymph nodes and sometimes the para-aortic lymph nodes.

## **INDICATIONS**

The indications for the laparoscopic approach are the same as for any other approach to hysterectomy and include: symptomatic uterine fibroids, abnormal uterine bleeding refractory to medical management, endometrial hyperplasia, malignancy, persistent pelvic pain, and pelvic organ prolapse. In addition, the laparoscopic approach allows the surgeon not only to better visualize the pelvic anatomy, but also to perform procedures that cannot be adequately accomplished via the vaginal approach. For example, extensive adhesiolysis, safe and secure ligation of the infundibulopelvic ligaments to facilitate oophorectomy, management of large leiomyomata to facilitate vaginal extraction of the uterus, and treatment (via surgical excision) of deep infiltrating fibrotic endometriosis can all be performed laparoscopically.

## **PREOPERATIVE EVALUATION**

All patients must receive a thorough preoperative evaluation including complete history and physical and pelvic examination. If indicated by history or physical exam, a pelvic ultrasound, hysterosonogram or CT scan and endometrial biopsy, or hysteroscopy and D&C should be performed prior to hysterectomy.

Finally, all patients must be given an opportunity to have all questions regarding their preoperative evaluation, the surgery itself and postoperative course answered to their satisfaction.

## **CONTRAINDICATIONS**

There are relatively few contraindications to the laparoscopic approach to hysterectomy and they are the same as for any operative laparoscopy. Certain medical conditions such as cardiac history, pulmonary disease, severe anemia, diabetes, and bleeding diathesis must be carefully evaluated prior to any surgical procedure. Age and weight should rarely be a deterrent to laparoscopic surgery.

To perform a total laparoscopic hysterectomy, the surgeon must be familiar with various fascial planes and avascular spaces in the pelvis and be proficient in performing various complicated operative laparoscopy procedures including retroperitoneal dissection, ureteral and bladder dissections and laparoscopic suture techniques. We feel that the inability of the surgeon to safely and proficiently perform all of these laparoscopic maneuvers is a contraindication to attempting a total laparoscopic hysterectomy.

## **SURGICAL TECHNIQUE OF TOTAL LAPAROSCOPIC HYSTERECTOMY**

Because one of the consistently reported drawbacks of laparoscopic surgery is the additional costs associated

with disposable instruments, we have limited the use of such devices in our practice. However, routine laparoscopic equipment that is essential for performing a successful laparoscopic hysterectomy includes:

- 1) Standard laparoscopic tower containing a high-flow CO<sub>2</sub> insufflator, camera and a light source.
- 2) An operating table with leg stirrups and capability of placing the patient in steep Trendelenburg position is essential.
- 3) Some kind of bleeding control instrument such as, bipolar and unipolar electricity generator, harmonic scalpel, (Gyrus ACMI PKS cutting forceps) or Ligasure vessel sealing instrument. The authors prefer Kleppinger bipolar forceps (Richard Wolf, Rosemont, IL) which is an excellent device for large and small vessel hemostasis. We have found it superior to disposable stapling devices because of lower cost and reduced risk of hematoma formation.
- 4) A sturdy uterine mobilizer, capable of extreme anteversion and movement of the uterus in an arc of 45° to the right and left is important. There are several good uterine mobilizers available (see chapter 3). However, we use instruments readily available in any gynecologic procedure tray to mobilize the uterus. A single-tooth tenaculum is secured to the anterior lip of the cervix and a uterine sound is gently advanced to the fundus. A second tenaculum is used to grasp the poste-

rior lip of the cervix. Sterile rubber bands are then used to secure the tenaculum to the uterine sound.

- 5) Reusable scissors or combination cutting and coagulation shears such as the Endoshear (Ethicon) are essential. We prefer the disposable device in this case because reusable scissors are often not sharpened adequately for the extensive cutting involved in laparoscopic hysterectomy. There are many other disposable devices available at increased cost that perform coagulation and cutting tasks with reasonable results.
- 6) Two good laparoscopic graspers with long jaws for grasping and manipulating the uterus, adnexal structures and bowel.
- 7) Suction irrigator is essential to clear out the smoke if unipolar or bipolar energy is used and to remove the blood and blood clots.
- 8) Ancillary instruments such as laparoscopic needle holders and laparoscopic myoma screw to manipulate the large uterus.

## TROCAR PLACEMENT

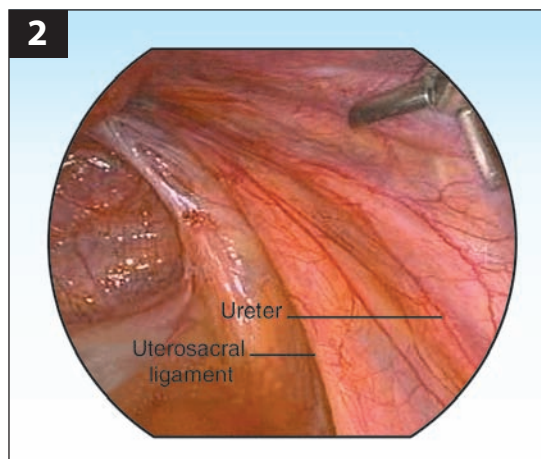
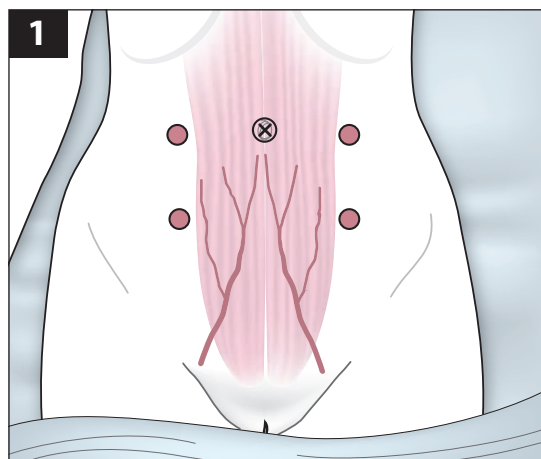
Trocar placement varies depending on the preference of the surgeon. We routinely place a Veress needle in the left upper quadrant in the mid-clavicular line one fingerbreadth below the costal margin. We then insufflate to 20 mmHg prior to placement of any trocars. A 10-12 mm trocar is then placed through a vertical intraumbilical incision for insertion of a (10 mm Gyrus ACMI laparoscope). Four

additional 5 mm trocars are then placed into the peritoneal cavity. The lower pair are placed lateral to the inferior epigastric vessels approximately two fingerbreadths above the pubis. The upper pair are placed lateral to the abdominal rectus muscles at a level slightly inferior to the umbilicus (Figure 1). If a patient has had prior abdominal surgery, we will often place the 5 mm trocar first and then inspect the periumbilical area with a 5 mm laparoscope to evaluate adhesion of underlying omentum and bowel to the anterior abdominal wall. Whatever method is used for trocar insertion, it is crucial to use “backstop” measures to prevent rapid, uncontrolled thrusting of the trocar through the layers of the abdominal wall and into underlying structures and adhesions. Ancillary trocar placement is usually an individual preference, and there are many surgeons who use three ancillary trocars on the lower abdomen.

## IDENTIFICATION AND DISSECTION OF THE URETERS

The ureters should be identified prior to securing any supporting structures to the uterus. Knowledge of pelvic anatomy and the course of the ureter are crucial. In most cases the ureters are visible through the peritoneum (Figure 2). As long as the ureters are clearly identified through the peritoneum, it is reasonable not to dissect them when performing procedures such as a laparoscopic assisted vaginal hysterectomy or supracervical hysterectomy.

However, when performing more advanced steps of the hysterectomy



laparoscopically, we recommend dissecting the ureters to the level of the ureteric canal prior to controlling the uterine arteries laparoscopically.

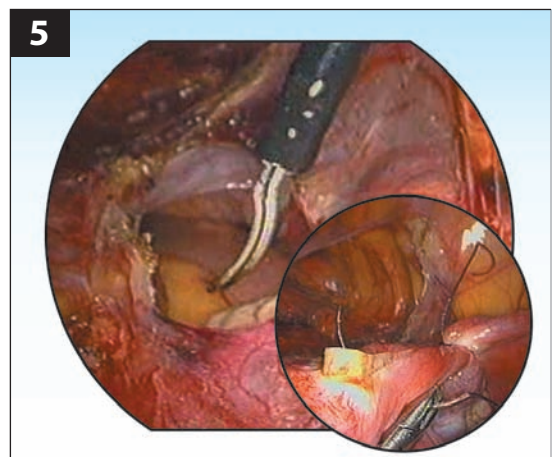
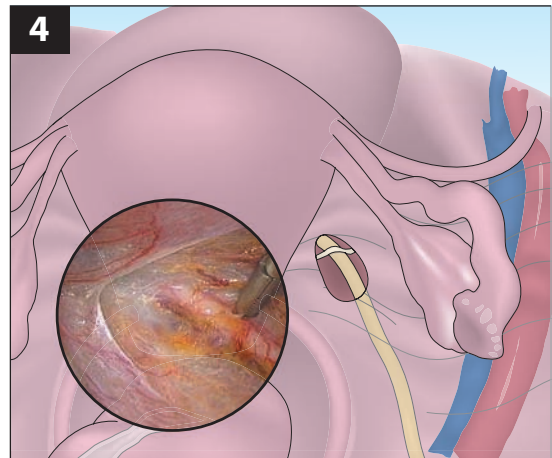
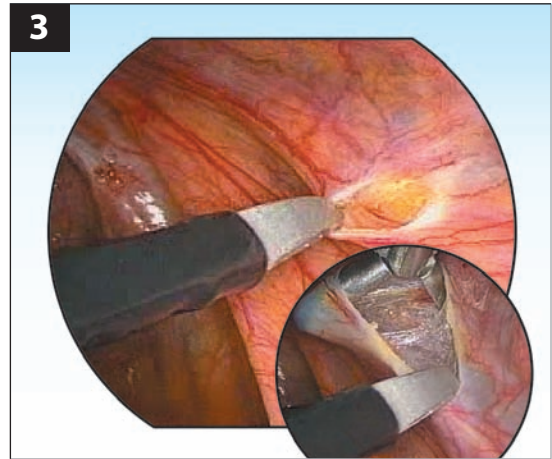
To identify and dissect the ureters, incise the peritoneum just above the ureter approximately at the level of the pelvic brim. In Figure 3, laparoscopic scissors are used to incise the peritoneum just above the right ureter. Alternatively, a CO<sub>2</sub> laser can be used. Graspers are used to separate the peritoneum from the

ureter. With the peritoneum separated from the ureter, incise the peritoneum along the course of the ureter towards the cardinal ligament. Figure 4 shows the course of the right ureter in relation to the right uterosacral ligament. With meticulous dissection, the ureter can be seen passing beneath the uterine artery at the level of the ureteric canal.

### SECURING THE INFUNDIBULOPELVIC AND UTERINE-OVARIAN LIGAMENTS

For women desiring removal of the ovaries, the suspensory ligament of the ovary (infundibulopelvic ligament) is double suture ligated bilaterally. Some surgeons utilize various energy instruments to perform this task. For women who want to preserve their ovaries, the uterine-ovarian ligaments and Fallopian tubes are suture ligated medial to the ovary. In either situation, the course of the ureter should always be confirmed to be clear from the area of ligation prior to placing suture or desiccating the infundibulopelvic ligament.

The process begins by opening a peritoneal window in an avascular plane and passing the suture through the broad ligament (Figure 5). Figure 6 shows ligation and division of the right uterine-ovarian ligament with 1-0 Vicryl suture on a CT-1 needle. The uterus is pushed to the left to place the right uterine-ovarian ligament on tension. To avoid back bleeding, two separate sutures are placed around the uterine-ovarian ligament, which is divided between the sutures. Alternatively, the ligaments can be desiccated with PKS

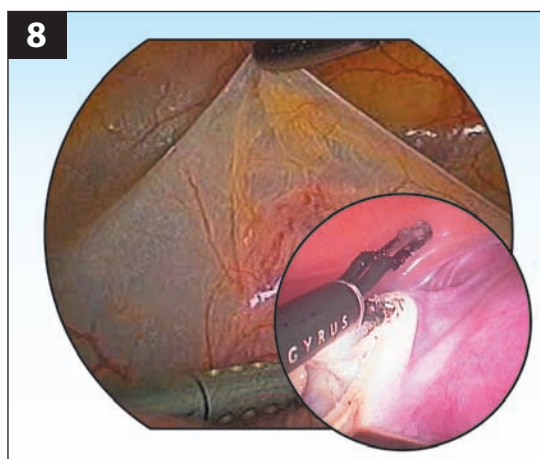
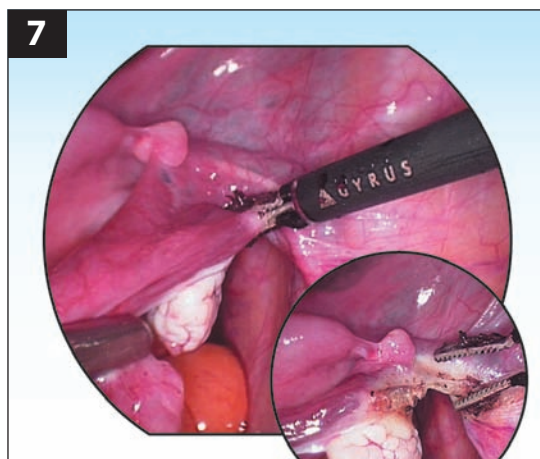
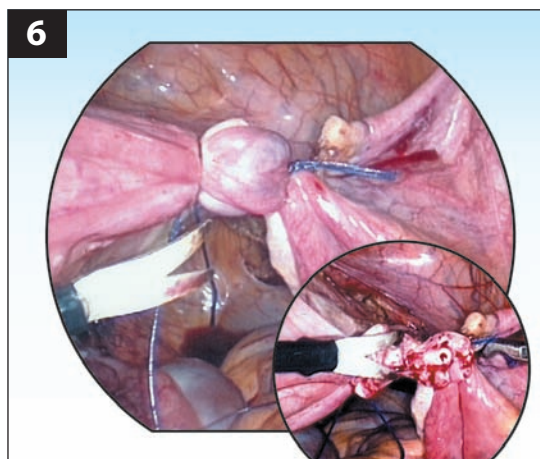


cutting forceps and divided with laparoscopic scissors. Figure 7 demonstrates coagulation and ligation of the infundibulopelvic ligament. The remainder of the broad ligament adjacent to the uterus may then be taken down to the cardinal ligament using these devices.

### CREATION OF THE BLADDER FLAP

First identify the vesico-uterine peritoneal fold. To facilitate identification of the vesico-uterine fold, have an assistant retrovert the uterus and push it cephalad. The upper junction of the vesico-uterine peritoneal fold is distinguished as a white line. Identification of the white line is important because, cephalad to the white line, the peritoneum is attached tightly to the uterus. Below this demarcation the peritoneum is loosely attached to the cervix and can be easily dissected away. Dissection in the wrong tissue plane will lead to unnecessary bleeding. The dome of the bladder is approximately 2.0 cm to 2.5 cm below the white line. If the demarcation of the bladder is obscured, instillation of 200 cc of fluid (with or without dye) is helpful in delineation of the limits of the bladder wall.

Using a grasper, place the vesicouterine fold on traction. Make a transverse incision just below the white line and dissect the bladder away from the lower uterine segment and cervix (Figure 8). In the right tissue plane, the dissection should be relatively bloodless. The middle band of loose connective tissue is the vesico-cervical ligament. This ligament does not contain blood vessels and can





be easily divided. PKS cutting forceps or laparoscopic scissors with electroenergy can be used to coagulate any small incidental bleeders during dissection. The lateral bands of connection on both sides of the cervix are bladder pillars. The bladder pillars contain blood vessels and should be desiccated prior to ligation. Dissection of the bladder laterally helps pull the ureters away from the cervix. To achieve this, incise the bladder peritoneum to the level of the round ligament. Continue dissection in the avascular plane and push the bladder caudad over the cervix to its junction with the anterior fornix of the vagina (Figure 9).

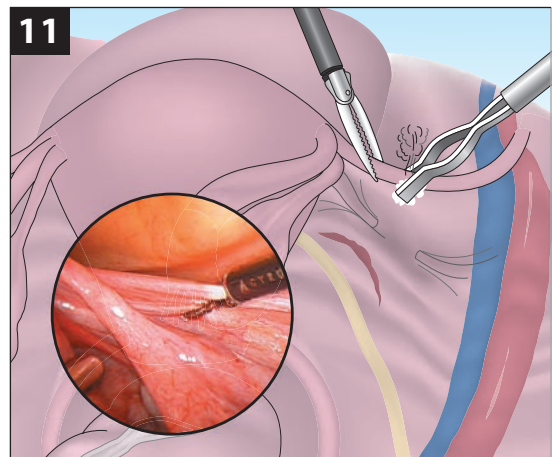
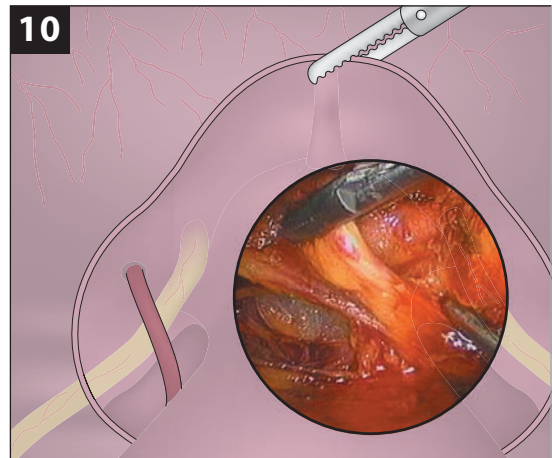
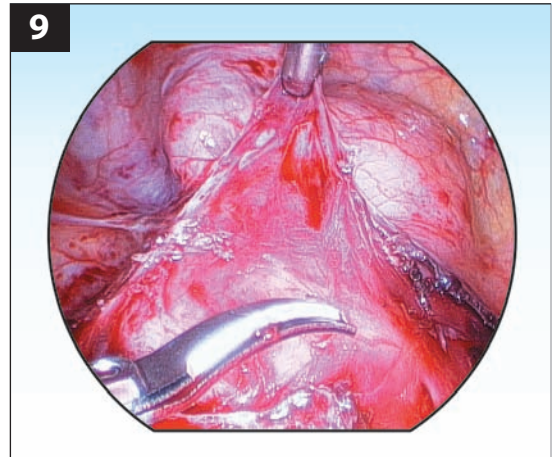
With meticulous dissection, the ureters can be seen as they approach the trigone of the bladder. In Figure 10, the bladder has been dissected laterally, the uterine vessels skeletonized and the left ureter can be seen as it traverses under the uterine vessels (“water under the bridge”).

### SECURING THE ROUND LIGAMENTS

The round ligaments can easily be desiccated with PKS cutting forceps and divided with laparoscopic scissors (Figure 11). The uterus is deviated to the left by an assistant and a grasper is used to place the round ligament on traction. The round ligament is coagulated and cut in the middle of the ligament with the coagulating instrument introduced from the ipsilateral side.

### SECURING THE UTERINE ARTERIES

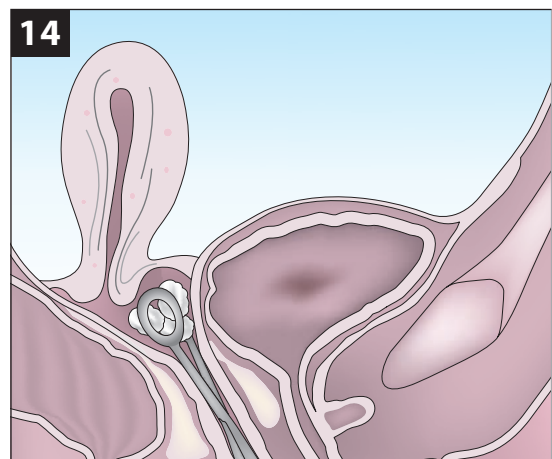
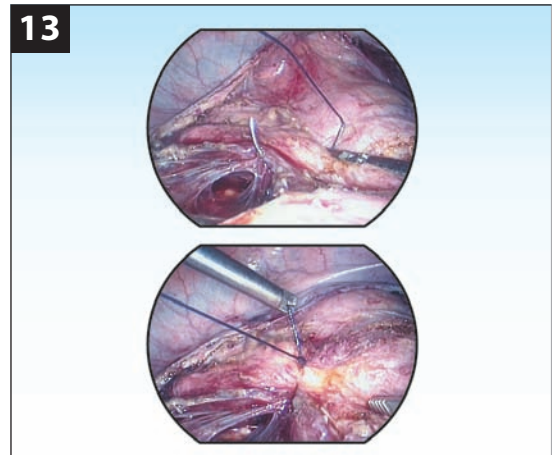
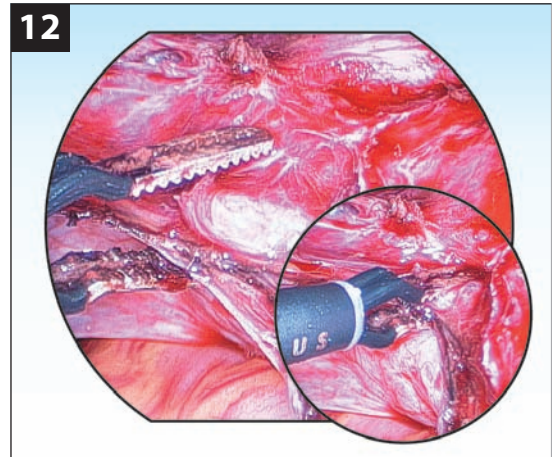
The broad ligaments on both sides are opened downward and towards the



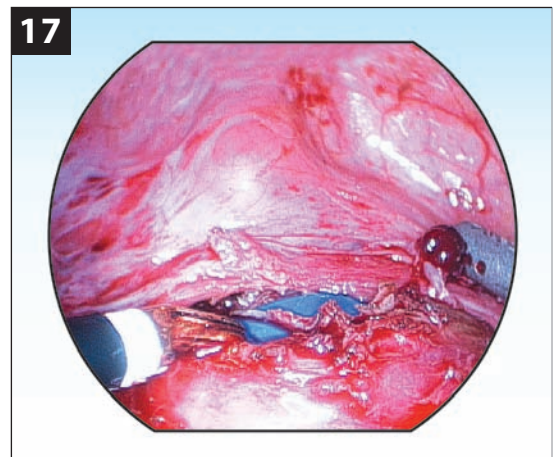
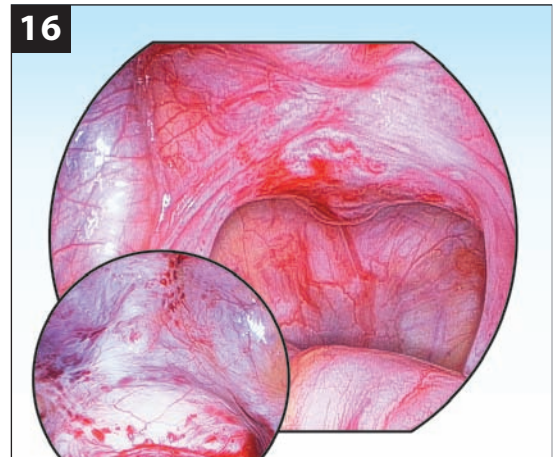
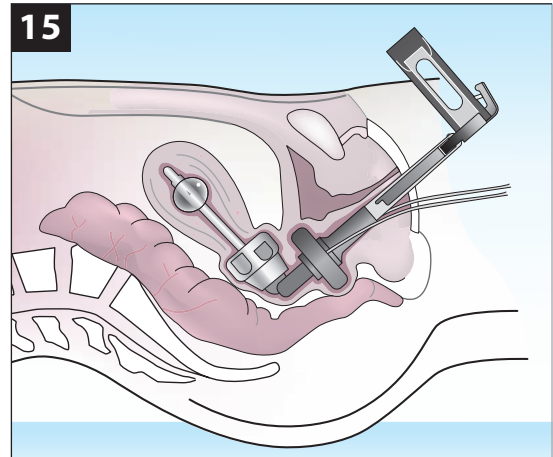
cervix, skeletonizing the uterine vessels. Once the uterine vessels are skeletonized they can be ligated or desiccated laterally, if necessary, to help control bleeding and identify the ureter when dealing with a large or cumbersome uterus. With meticulous dissection, the uterine vessels can be identified at the level of the ureteric canal as it crosses above the ureter. Knowledge of the course of the ureter is essential at this point to avoid injury. Figure 12 shows desiccation and division of the left uterine artery using PKS cutting forceps. Alternatively, the uterine vessels can be ligated at this level with a 1-0 Vicryl suture on a CT-B (blunt) needle. Again, it is not typically necessary to perform lateral ligation of the uterine vessels. In most cases, the uterine vessels can be secured medially as they enter the uterine body. Figure 13 shows ligation of the left uterine vessels with 1-0 Vicryl suture on a CT-B needle. The suture is placed immediately adjacent to the cervix and incorporates part of the cardinal ligaments. The suction irrigator is used to push the body of the uterus to the opposite side. The knot is tied extracorporeally and pushed into place with a knot pusher.

### CULPOTOMY

Once the cardinal ligament and its vessels have been secured the colpotomy may be performed. The authors prefer using a wet 4 x 4 sponge on a ring forceps that is placed into the anterior vaginal fornix. From below, the assistant uses the ring forceps to tent the anterior fornix. An incision is then made between



the bladder and cervix (colpotomy), exposing the white fibers of the 4 x 4 sponge (Figure 14). There are a number of devices available commercially that can be applied vaginally around the cervix to better distinguish between the bladder and vagina (See Chapter 3). These instruments are also equipped with vaginal occluders to prevent failure of the pneumoperitoneum. Figure 15 shows a RUMI (Cooper Surgical, Trumbull, CT) uterine manipulator with the Koh Colpotomizer cup placed around the cervix. The rim of the device is easily visualized and palpated from above. Rotation of the device allows visualization of the posterior fornix and uterosacral ligaments (Figure 16). Upon entering the vagina, the circumferential colpotomy is performed. We routinely use laparoscopic scissors or CO<sub>2</sub> laser, but anterior colpotomy can be performed using the harmonic scalpel or plasma Spatula (Figure 17). At this point, gas leaks rapidly from the peritoneal cavity. If a circumferential colpotomy can be easily and safely performed, it is reasonable to proceed. However, we have found it helpful to remove the uterine manipulator at this stage and place a sponge inside the vagina to maintain a pneumoperitoneum. We place a sponge inside a surgical glove and tie the open end of the glove. The glove with the enclosed sponge is then placed inside the vagina to seal it. Another inexpensive and practical device is a blue infant suction bulb that can be found at the delivery units. The tip of the bulb is cut off and a sponge stick is inserted into the

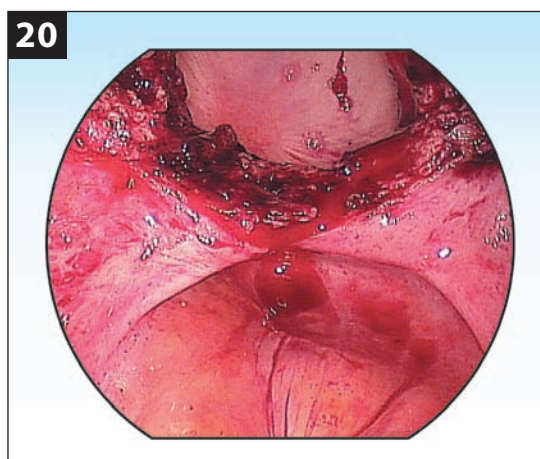
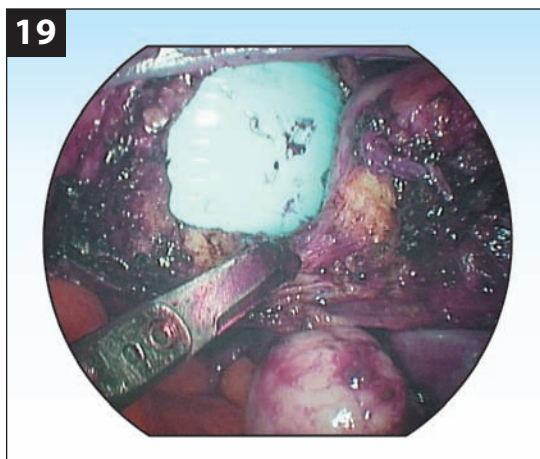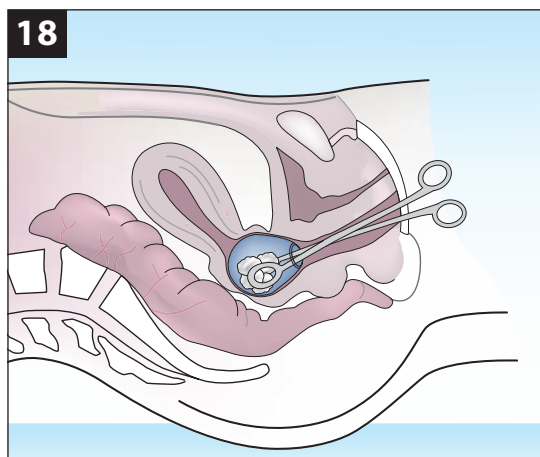


blue bulb through the created hole; the bulb is then placed into the vagina and manipulated with the sponge stick (Figure 18). The bulb serves two purposes: it holds the pneumoperitoneum and serves as a colpotomizer since it clearly delineates vaginal margins and is easily visible from above. Once the vagina is entered, the anterior lip of the cervix is grasped with a single-tooth tenaculum or a myoma screw is placed to manipulate the uterus. With the cervix on traction, a circumferential colpotomy is performed with laparoscopic scissors by completely detaching the cervix from the vagina and cardinal ligaments (Figure 19). Occasional cuff bleeders can be controlled with PKS cutting forceps.

When using the Colpotomizer cups during TLH we often detach the vagina above the insertion of uterosacral ligaments to the paracervical ring preserving the entire uterosacral ligaments and thereby preventing future vaginal prolapse (Figure 20). The sponge inside the vagina is removed and the uterus is removed vaginally. If needed, the uterus can be morcellated vaginally or laparoscopically to permit removal through the culdotomy incision.

#### CLOSURE OF THE VAGINAL CUFF

After removal of the uterus, the surgical glove with the enclosed sponge or a blue bulb is replaced inside the vagina to maintain a pneumoperitoneum. In order to facilitate apical suspension of the vagina, the vaginal cuff angles are sutured to their ipsilateral uterosacral ligaments at



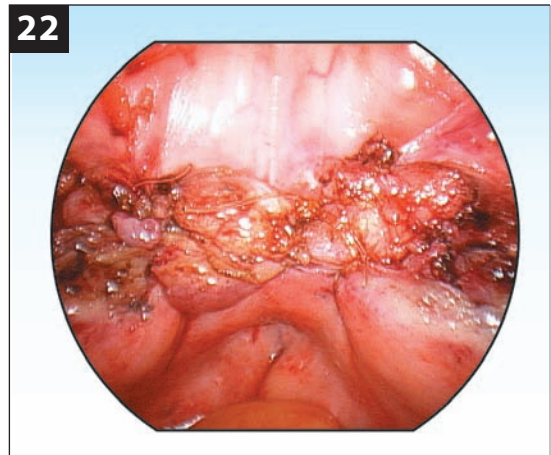
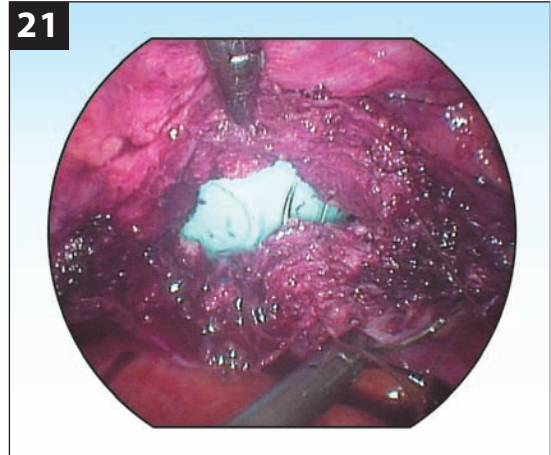
the level of the ischial spine. A hand may be placed vaginally to confirm the location. A Gore-Tex or 2-0 Monocril suture is placed in a figure-of-eight fashion underneath the uterosacral ligament, incorporating the cardinal ligament at the corner and the lateral portion of the anterior vaginal fornix. The sutures can be tied with an extracorporeal knot pusher. Figure 21 shows suture placement. Care must be taken to incorporate the full vaginal thickness and not to incorporate the ureters. The vaginal cuff is closed laparoscopically using 2-0 Monocril figure-of-eight suture (Figure 22).

### UNDERWATER EXAMINATION

To ensure hemostasis, the pelvis is partially filled with Ringer's lactate solution which negates the pneumoperitoneal pressure and therefore permits visualization of small bleeders. The vaginal cuff is viewed by submerging the laparoscope underwater to observe for bleeding. The trickle of blood observed this way would often be missed otherwise. This "red smoke" sign is helpful in identifying bleeding that would otherwise be missed. Alternatively, the gas may be released slowly while closely observing the cuff as the pneumoperitoneum is released.

### CYSTOSCOPY

We routinely perform cystoscopy to ensure ureteral patency. We ask the anesthesiologist to inject 5 mL of indigo carmine dye intravenously followed by 10 mg of furosemide (Lasix). Bilateral



ureteral patency is confirmed by ejection of indigo carmine dye from the ureteral orifices. A cystoscope is connected to the endoscopic camera for better visualization and the entire surface area should also be inspected for signs of injury, endometriosis, foreign body, or neoplasia.

### POSTOPERATIVE CARE

Patients are initially placed on a clear liquid diet when fully awake. The diet is advanced to 'regular' as tolerated. The

majority of our patients go home within 24 hours of surgery. Patients are not discharged until they can ambulate well without assistance, void and tolerate a regular diet. Although it is feasible they could go home the same day, we recommend overnight hospitalization for observation and pain management. Although the procedure is performed laparoscopically, through small skin incisions, it still should be considered a major operation.

Patients who have undergone laparoscopic surgery should usually feel better each day during the postoperative period. In the event a patient does not pro-

gressively improve after surgery, operative complications should be considered. In addition to the standard blood tests and X-rays, a CT scan of the abdomen and pelvis may be indicated. To evaluate for ureteral injury, IV contrast should be given. To evaluate for intestinal injury, oral and rectal contrast should be given. Do not hesitate to perform a second-look laparoscopy when there is doubt regarding the possibility of an operative complication. It is far better to err on the side of caution than to allow an operative complication to further go unrecognized and delay treatment.

## SUGGESTED READING:

Garry R, Reich H, Liu CY. Laparoscopic hysterectomy-definitions and indications. *Gynecol Endoscopy* 1994; 3: 1-3

Sills ES, Saini J, Steiner CA, McGee M, Gretz HF. Abdominal hysterectomy practice patterns in the United States. *Int J Gynaecol Obstet* 1998;63(4):277-83

Kim DH, Bae DH, Hur M, Kim SH. Comparison of classic intrafascial supracervical hysterectomy with total laparoscopic and laparoscopic-assisted vaginal hysterectomy. *J Am Assoc Gynecol Laparo* 1998;5(3):253-260

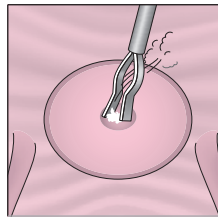
Harkki-Siren P, Sjoberg J, Tiitinen A. Urinary tract injuries after hysterectomy. *Obstet Gynecol* 1998;92(1):113-8

Mettler L, Semm K. Subtotal versus total laparoscopic hysterectomy. *Acta Obstet Gynecol Scand Suppl* 1997;164:88-93

Parker WH. Total laparoscopic hysterectomy. *Obstet Gynecol Clin North Am* 2000;27(2):431-40

Chou DC, Rosen DM, Cario GM, Carlton MA, Lam AM, Chapman M, Johns C. Home within 24 hours of laparoscopic hysterectomy. *Aust N Z J Obstet Gynaecol* 1999;39(2):234-8

# LAPAROSCOPIC SUPRACERVICAL HYSTERECTOMY



***Thomas L. Lyons, M.D.***

***Assia Stepanian, M.D.***

***Wendy K. Winer, R.N.***

**A**s stated by Finley in 1943, hysterectomy in general must be used to: 1. save life, 2. correct deformity, or 3. eliminate suffering. Historically, most hysterectomies were performed in a subtotal or supracervical manner and morbidity and mortality (M&M) were significant. The reasons for this high rate of M&M were poor anesthesia techniques, absence of antibiotic therapy, and lack of modern blood banking procedures. During the first half of the 20<sup>th</sup> century gradual progress was made in the technical aspects of the procedure. By the mid 1940's, when anesthesia was improving and antibiotics became available, mortality rates decreased rapidly.

In addition, another influence was present at that time. The existing mortality rate from cervical carcinoma was high, making this disease the third most common killer of women in the US. Between 1940 and 1955 the rate of total versus subtotal hysterectomy was reversed. Whereas the subtotal rate was 85%-95% in the early 1940's, by 1955 the subtotal rate was less than 5%. The stated reason for this shift was to lower the death rate from cervical cancer. This stated goal was not accomplished until PAP smears became routine in the US in 1958. However, the wholesale



extirpation of cervixes continued for the next 40 years with over one million total hysterectomies performed in 1975.

After a careful examination of the procedure and the needs of the patients, in 1990 we began a series of trials of Laparoscopic Supracervical Hysterectomy (LSH) with the directive of lowering morbidity. The possibility of maintaining the procedure as totally laparoscopic offered a potential simplification to the average operator. After completing a series of these procedures and comparing them to a group of demographically similar patients undergoing LAVH we found that LSH had a significantly lower morbidity. Over the next ten years we performed approximately 750 procedures with continued low morbidity while treating uteri up to 2400 grams, stage IV endometriosis, severe PID, ovarian cancer, leiomyosarcoma, and total pelvic floor prolapse. These patients continued to recover remarkably with lower than normal morbidity despite the increased complexity of the procedures. The learning curve played a role in these statistics but the clinical results were sufficient to warrant the continuation of the LSH procedure.

## INDICATIONS

The LSH can be the procedure of choice for most patients in whom hysterectomy is indicated. There are some specific contraindications, which will be emphasized. Therefore, the list of indications is as follows:

- Dysfunctional uterine bleeding
- Symptomatic uterine leiomyomata
- Pelvic pain
- Endometriosis
- Pelvic floor prolapse
- Ovarian cancer
- Pelvic inflammatory disease

The absolute contraindications for the procedure are:

- Endometrial cancer
- Invasive cervical cancer
- Pelvic floor relaxation in a patient with a retroverted uterus and a short anterior wall (<7 cm)
- Any patient who cannot be expected to continue cytologic surveillance.

The real risk of cervical disease is no greater than with an intact uterus but the patient should be counseled regarding continued PAP smears. The discussion should include an explanation of not only the potential benefits of maintenance of the cervix, but also the possible liabilities of the cervix in situ.

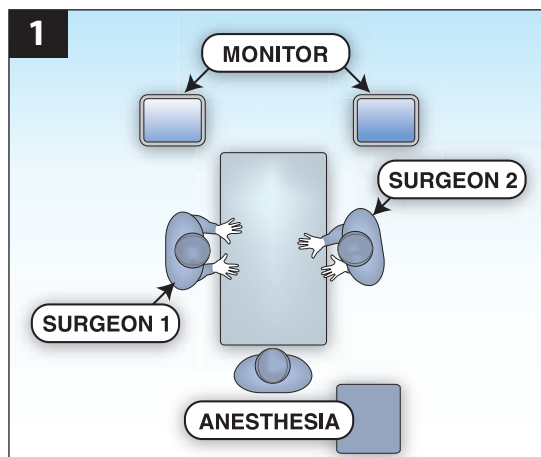
## TECHNIQUE

LSH is performed by this author as described in Telinde, with the exception that laparoscopic incisions are substituted for the midline or Pfannenstiel incision. First, the patient is consented for LSH and laparotomy. A discussion with the patient includes the need for continued cytologic surveillance, which is documented in the chart. Bowel preparation with

Golytely™ or magnesium citrate is advised and preoperative antibiotics are prescribed (usually one gram of cephalosporin intravenously one hour prior to surgery). Bowel prep and antibiotic use may vary but should correspond to the prep that is desired by the gynecologist's consulting general surgeon. Simplification of the procedure and emphasis on preoperative preparation must be stressed.

The room setup is critical to the efficiency of the procedure. The patient is placed in the modified dorsal lithotomy position in boot stirrups. Allen™ stirrups or a similar device are recommended as positioning is critical for the safety and success of the procedure. The surgeon should monitor this positioning until he/she is comfortable that the OR team is totally competent in this activity. Ultimately, it is the surgeon's responsibility medico-legally and, therefore, it is imperative to assure that this is done properly. A team approach to this type of surgery is imperative. In order to become efficient, each member of the team should be well schooled in his/her role in the procedure and the importance of that role. This area has been addressed by Winer in other texts and cannot be overemphasized.

The devices used to complete the procedure are much the prerogative of the surgeon. Vascular pedicles must be isolated and occluded. Laparoscopically this may be accomplished using suture, staples, clips, Harmonic Scalpel®, bipolar electro-surgery, monopolar electro-surgery,



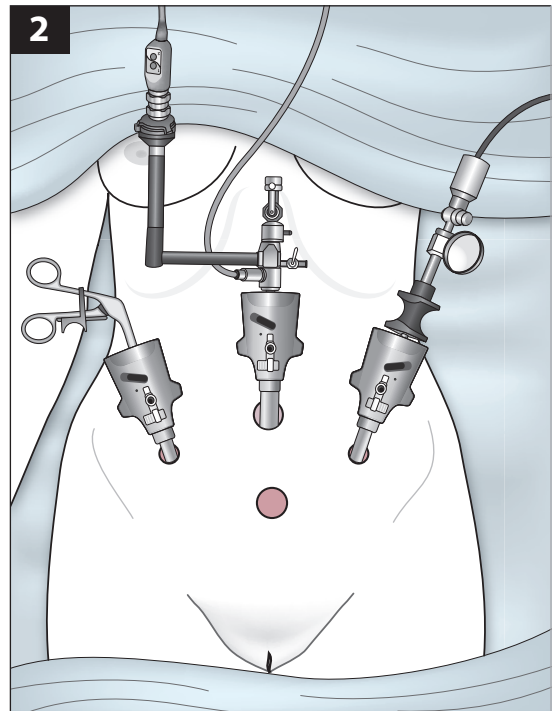
or some form of laser energy. All of these energy forms have strengths and weaknesses but it is wise for the operator to have working knowledge of all of these modalities and use those that best suit the particular style of that operator. We will describe the use of bipolar energy for larger vessel occlusion and the use of the contact Nd:YAG laser as a cutting device. We also favor the Harmonic Scalpel® as a cutter/coagulator and also have used monopolar electro-surgery as a primary cutting device. We also use suture in selected cases as a large vessel occlusive device.

The procedure begins with careful positioning of the patient. The monitors are placed at or toward the foot of the table so that the operator uses the monitors thus eliminating the need to work in a “mirror image” (Figure 1). Any time the operator works at an angle of 90° or greater (into or toward the laparoscope) a “mirror image” is created reversing the directions needed within the operative field.

After the sterile prep is complete, the uterine manipulator is placed. The use of

an effective manipulator is critical. We have used both the Valchev™ and the Pelosi™ manipulators with success but we favor the Pelosi™. The manipulator is critical as a retractor and definitely aids in efficient completion of this task. Whatever the uterine size, the manipulator is key. There are advantages to the use of either the Valchev™ or the Pelosi™, which enable both anteversion and retroflexion as well as rotation and lateral displacement all using only one hand. Furthermore, the fact that the device is fixed to the cervix is of critical importance in the physics of the stated task.

The next step involves placement of trocars. The trocar scheme used by the present authors is based upon experience from several thousand cases but should not be considered as fixed in stone. Several key points should, however, be noted. First, the subumbilical trocar is placed using the open or Hasson technique and is 10/12 mm. The open technique is used because of the frequent treatment of women with very large uteri and/or multiple prior abdominal procedures. Other primary trocar techniques certainly can be considered but the operator should select a technique that he/she is familiar with and suits the clinical situation. Next, the distribution of the lateral trocars is well lateral on the abdominal wall. This lateral placement, as well as the need to place the trocars above the pathology, particularly in the large uterus, is again helpful to facilitate adequate retraction and access to the vascular pedicles. When possible, 5 mm trocars are used particularly in the lateral sites. The lower midline trocar is

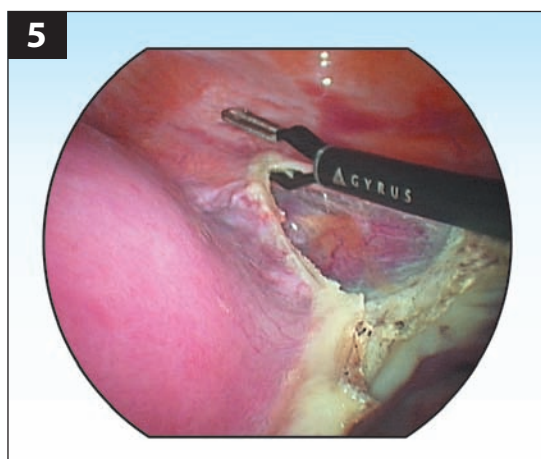
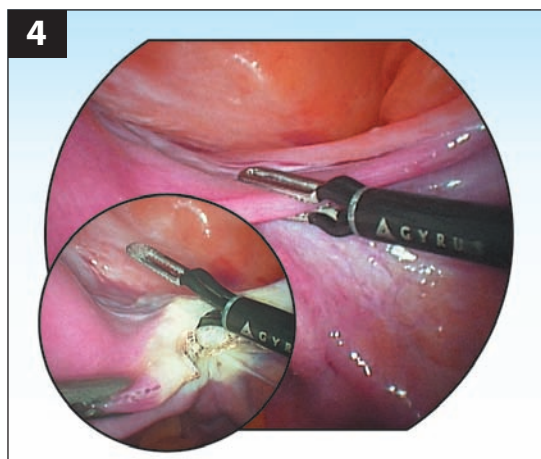
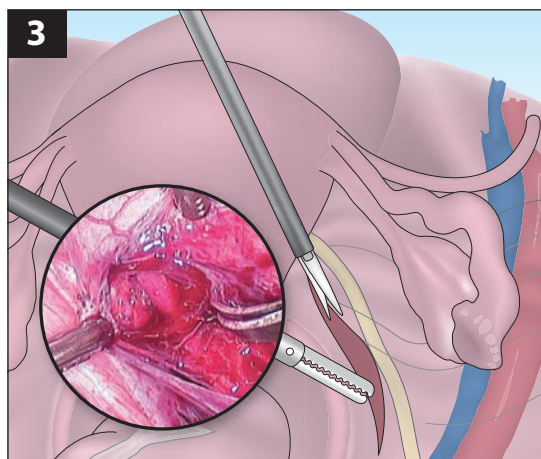


10/11 mm and is used later for suturing and for morcellation of the specimen. In the very large uterus, the primary subumbilical trocar becomes the lower midline trocar and two 5 mm trocars are placed laterally on each side to accomplish the procedure. We currently use disposable trocars from Ethicon EndoSurgery™ but reusable devices may be used. The trocars should be threaded or gripped to the skin/fascia as otherwise unwanted pull out can occur which makes the procedure more difficult as well as lengthier. All secondary trocars should be placed under direct visualization with the laparoscope. A 10-mm operating laparoscope is placed through the upper midline port and the contact Nd:YAG laser scalpel (Surgical Laser Technologies, Philadelphia, PA) is passed through the operating channel of

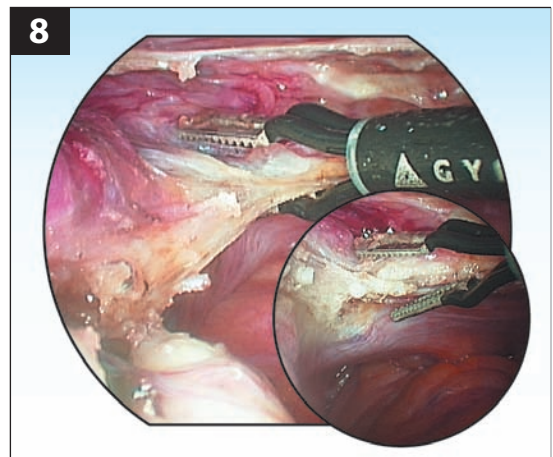
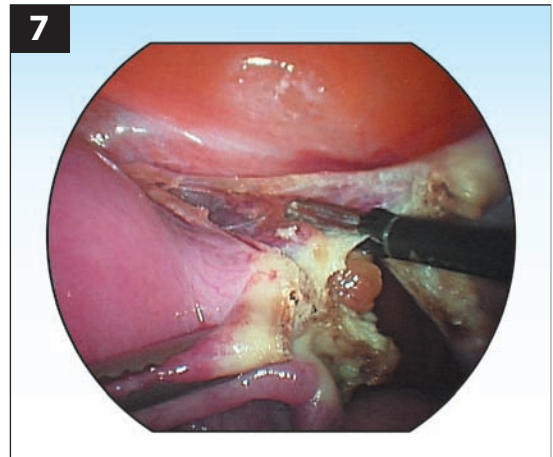
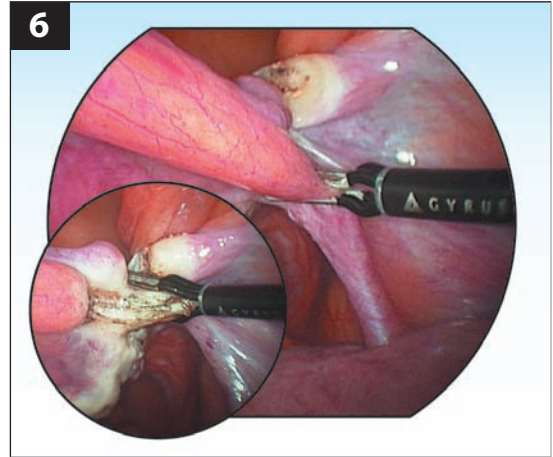
the laparoscope. A 45° 10 mm scope is also kept on hand particularly for the large uterus, as this can be very helpful if the fibroid obscures a straight on view of the operative field. The cutting forceps GyruS ACMI dissector/grasper (Maple Grove, MN) is used first through the left lower lateral port. An atraumatic grasper is used through the right lateral port and the suction irrigation device is placed in the mid-line lower portal (Figure 2).

The procedure then proceeds by exploration, adhesiolysis, and restoration of anatomy. If possible, at this point in the procedure we perform ureterolysis. In this procedure an incision is made medial to the ureter beginning in the midpelvic area and this incision is extended down to the level of the uterosacral ligaments (Figure 3). This serves two purposes. First, the ureter is identified and marked so that it is easily found later. Therefore, if bleeding occurs that must be controlled, the potential for injury to the ureter is decreased. Also, this allows for aggressive support of the vault using a high McCall's culdoplasty at termination of the procedure without ureteral kinking or compromise.

Next, the round ligament is cauterized and divided (Figure 4) and the anterior uterovesical fold is scored with the unipolar scissors, harmonic scalpel, cutting forceps or laser scalpel, and the bladder flap is developed (Figure 5). If the adnexa are to be removed, the tube and ovary are grasped with the grasper from the contralateral side and pulled medially in order to expose the infundibulopelvic ligament. Using the cutting forceps coagulation from the ipsilateral



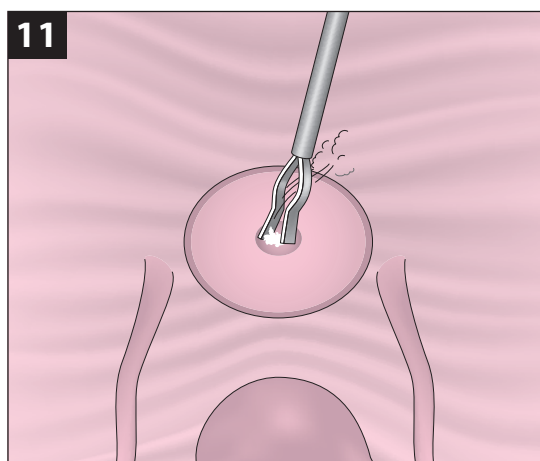
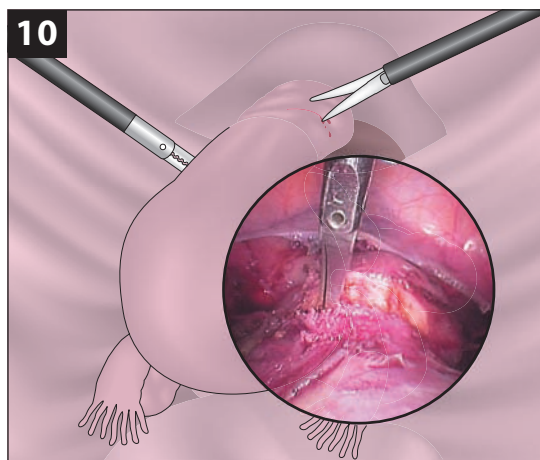
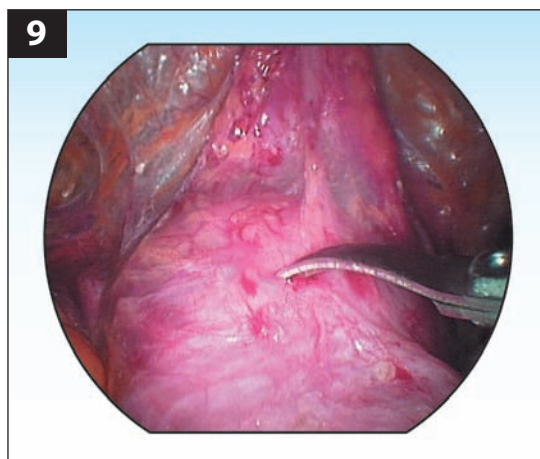
side, the infundibulopelvic ligament is desiccated and divided close to the ovary (Figure 6). The incision is directed toward the one on the round ligament until the two incisions are connected. The stump of the round ligament is grasped with the contralateral grasper and pulled upward and medially. Simultaneously, the uterus is pushed upward with the uterine manipulator. The posterior leaf of the broad ligament is also scored down the specimen side and the vasculature is skeletonized (Figure 7). The ureter is constantly in view due to the ureterolysis incision. Once the uterine vessels are skeletonized, these vascular pedicles can be removed with the cutting forceps placed in the ipsilateral port while good countertraction is applied from the contralateral port and the uterine manipulator. The bipolar is placed at a right angle/perpendicular to the lateral uterus which allows for better occlusion of the spiral uterine vascular pedicle and the heat energy from the cutting forceps is displaced into the specimen rather than away from the uterus and toward the ureter (Figure 8). The manipulator is pushed inward toward the patient's contralateral shoulder thus increasing the distance from the lateral uterine wall and the ureter, which has been released by the ureterolysis incision further creating a safe margin for this desiccation process. Once these vascular pedicles are occluded, the uterus will become cyanotic indicating that the uterus is devascularized. Using the grasper on the bladder peritoneum along with cold scissors, the



bladder is pushed downward to expose the lower uterine segment and the cervix (Figure 9).

From this point the procedure is very straight forward with amputation of the cervix coring well down into the endocervical canal. This amputation should begin at the level of the internal os or at the level of entry into the uterus of the uterine vessels and an aggressive attempt to core downward into the cervix should be used while pushing upward with the manipulator (Figure 10). The operator should pay close attention during this process when applying energy, to stay away from the adjacent bowel and contralateral pelvic sidewall since these structures come in close proximity with the cervix and could be potentially injured. Endocervical mucous is almost always visualized during this amputation assuring that the operator is low enough and that no lower uterine segment is being left behind. Ablation of the remaining endocervical canal using a bipolar forceps is accomplished (Figure 11). The cervical stump is then closed using a #0 Vicryl™ suture on a CT2 needle. The vault is then supported with ipsilateral McCall's sutures of #0 Ethibond™ suture.

The amputation of the uterine corpus can be performed with blunt dissection with scissors, or using monopolar cutting current. Amputation can also be performed with harmonic scalpel. Dr. Jacques Dequesne has introduced a monopolar loop electrode that can be placed around the cervix and tightened to facilitate fast and safe amputation of



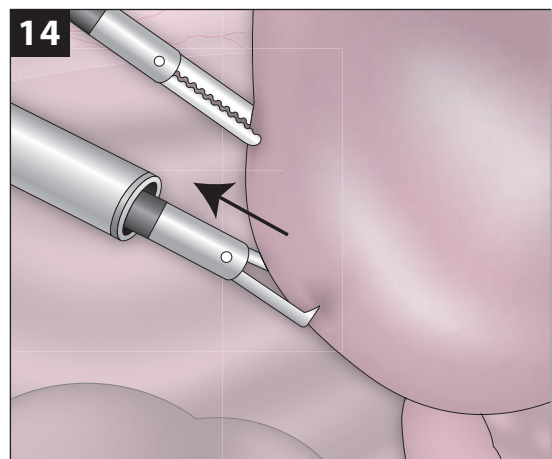
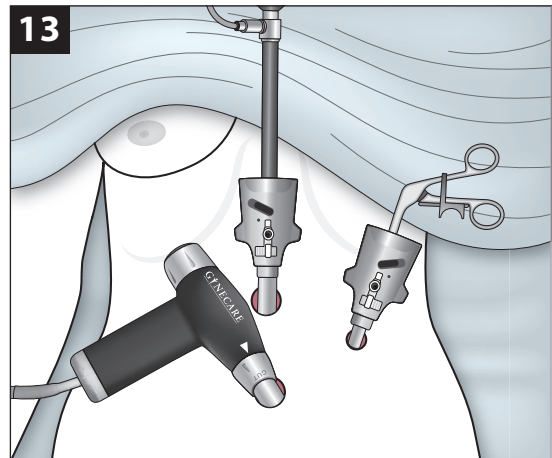
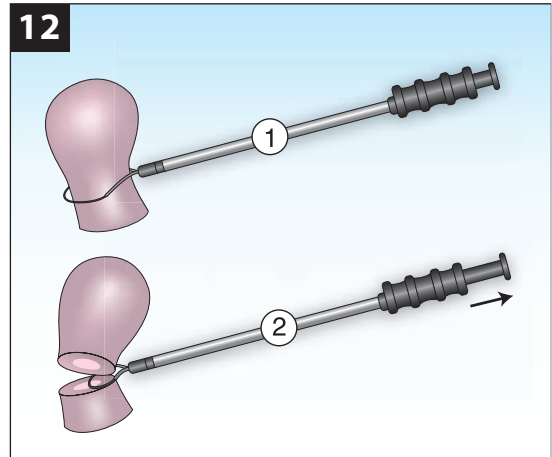
the uterine corpus with unipolar current (Figure 12). The Lap loop System™ (Medsys Gembloux Belgium) is not available in the United States.

The final portion of the procedure is specimen removal. We now use the mechanical morcellator from Gynecare®. This device, which is called the DIVA,™ has been very useful and requires a 10 mm single-toothed tenaculum to work at maximum efficiency. The device will fit through the lower trocar site and requires minimal practice to obtain proficiency (Figure 13). Other morcellators (Storz, WISAP) are also available (See Chapter 3 and 19).

Several safety steps should be considered when using the morcellator. The blade of the morcellator should be held parallel to the anterior abdominal wall and it should be viewed at all times while the tissue is morcellated. The uterine corpus is grasped with the grasper and pulled back into the morcellator keeping the tip of the blade visible at all times (Figure 14). The morcellator shaft should not be pushed into the abdominal cavity while the morcellation is in process (Figure 15). For additional information on tissue retrieval see chapter 19.

After the entire specimen is removed, the abdomen is thoroughly irrigated, the fluid is removed, and the lower 10/11 mm site is closed using the Carter-Thomason fascial closure device. The larger sites receive a subcuticular closure and the 5 mm sites are steri-stripped. All sites are injected with 0.25% Marcaine with epinephrine and dressings are applied.

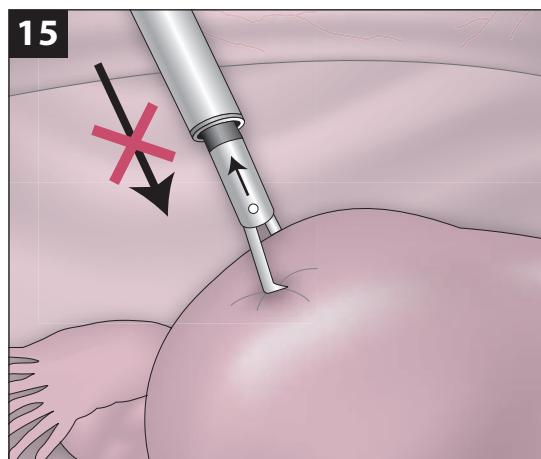
Postoperative care allows the patient to be discharged from the surgical facility within 24 hours. The Foley catheter is



removed in the recovery room and ambulation is encouraged. The patient is allowed to perform all activities with which she is comfortable. Individuals are able to return to normal activity within a few days and are able to return to work within 1-2 weeks.

## CLINICAL EXPERIENCE

Various authors have reported retrospective series of the LSH procedures. The largest series was described by Donnez with over 500 procedures. In this as well as a 500-case series reported by Daniell, the morbidity was extremely low, again justifying the continuance of the procedure. The present author's series is now at >750 procedures with continuing low morbidity and clinical outcomes based on patient satisfaction surveys and morbidity statistics. Data are illustrated in Table 1.



There is more information on a form of supracervical hysterectomy called the CISH procedure. This procedure was first reported by Semm in 1991. Although technically this is also a supracervical hysterectomy, it differs sufficiently from LSH to separate the data. Data from this literature are seen in Table 2.

TABLE 1

DONNEZ (1997)	500 PATIENTS	60-810 GM. 30-135 MINUTES	0.6% COMPLICATIONS
DANIELL (1999)	500 PATIENTS	? SIZE 90 MINUTES (MEAN)	<1% COMPLICATIONS
LYONS (1995)	294 PATIENTS	65-2180 GM 55-224 MINUTES	<1% COMPLICATIONS

TABLE 2

SEMM (16) (1996)	90 PATIENTS	? WGT. 90 MINUTES (MEAN)	0 % COMPLICATIONS
METTLER (17) (1995)	200 PATIENTS	50-250 GM. 120-240 MINUTES (MEAN)	"MINIMAL COMPLICATIONS"
LEVINE (18) (1996)	100 PATIENTS	27-950 GM. 105-240 MINUTES	3% COMPLICATIONS
VIETZ (19) (1996)	60 PATIENTS	? WGT. 90 MINUTES (MEAN)	0% "MAJOR COMPLICATIONS"



## DISCUSSION

We proposed laparoscopic supracervical hysterectomy in 1990 as a possible alternative to LAVH with further decreased morbidity and possible extended applications. Simon et al. evaluated the economic morbidity of the LSH procedure as compared with total abdominal hysterectomy in a community hospital setting. This study concluded that LSH was a cost-effective alternative in those patients with indications for hysterectomy.

The most positive attribute of LSH is decreased overall morbidity, application to virtually any size uterus, probable improved overall pelvic floor support secondary to the intact pericervical ring, and intact neurovascular supply. In addition, the subtotal approach in virtually all cases adequately addresses the pathology associated with the admitting diagnosis.

Many women today are concerned with destructive surgeries to the repro-

ductive anatomy and the associated psychosocial effects of these procedures. LSH is a legitimate alternative for these individuals offering a less invasive and less destructive procedure, which can still eliminate the symptom complex, which brings them to the surgical theater. Kilku addressed these concerns in a series of articles in the mid-1980's. Hasson also discussed this issue in an excellent review of subtotal hysterectomy in 1995.

The final factor is choice. Women today are intelligent and well informed consumers who are willing to obtain sufficient opinions until satisfied with their physician's recommendations. They are informed of the issues and the medical options available and will demand these alternatives. Those surgeons who are willing to discuss these options and apply them to appropriate patients may find greater success and a less litigious atmosphere than those who attempt to patronize their clientele.

SUGGESTED READING:

Reich H, DeCaprio J, McGlynn F. Laparoscopic Hysterectomy.  
J Gynecol Surgery 1989;5: 213-216

Lyons TL. Laparoscopic supracervical hysterectomy-A comparison of morbidity and mortality results with laparoscopically assisted vaginal hysterectomy.  
J Reprod Med 1993;38: 763-767

Lyons TL. Subtotal hysterectomy. In: Diamond, MP, Daniell JF, Jones HA (eds) Hysterectomy. Cambridge, MA Blackwell Science, 1995, 84-98

Lyons TL. Laparoscopic supracervical hysterectomy. In: Wood C, Maher PJ (eds) Balliere's Clinical Obstetrics and Gynecology. London, UK, Balliere & Tindall, 1997,167-181

Winer WK. Operating room personnel. In: Sanfilippo JS, Levine RL (eds) Operative Gynecologic Endoscopy 2nd Edition. New York, NY, Springer-Verlag, 1996, 412-422

Liu CY. Laparoscopic hysterectomy. Report of 215 cases. Gynecol Endosc 1992;1:73-77

Donnez J, Nisolle M, Smets M, Polet R, Bassil S. Laparoscopic supracervical (subtotal) hysterectomy: a first series of 500 cases. Gynecol Endoscopy 1997;6:73-76

Anderson TL, Lindsay, JH, Daniell JF: Performing laparoscopic supracervical hysterectomy. OBG Management 1999;1:15-32.

Semm K. Hysterectomy via laparotomy or pelviscopy. A new CASH method without culpotomy. Geburtshilfe Frauenheilkd 1991;51: 996-1003

Simon NV, Laveran, RL, Cavanaugh S, Gerlach DH, Jackson JR. Laparoscopic supracervical hysterectomy vs. abdominal hysterectomy in a community hospital. A cost comparison. J Reprod Med 1999;44:4, 339-345

Kilkku P. Supravaginal amputation versus hysterectomy with reference to bladder symptoms and incontinence. Acta Obstet Gynecol Scand 1985;64: 375-379

Kilkku P, Hirvonen T, Gronoos M. Supracervical uterine amputation vs. abdominal hysterectomy: The effects in urinary symptoms with special reference to pollakisuria, nocturia, and dysuria. Maturitas 1981;3:197

Kilkku P, Gronoos M, Hirvonen T, et al. Supravaginal uterine amputation vs.hysterectomy: Effects on libido and orgasm. Acta Obstet Gynecol Scand 1983;62:141-146

Hasson HM. Cervical removal at hysterectomy for benign disease.  
J Reprod Med 1993;38:10, 781-790

Semm K. Endoscopic subtotal hysterectomy without culpotomy, classic intrafascial SEMM hysterectomy. A new method of hysterectomy by pelviscopy, laparotomy, per vagina or functionally by total uterine mucosal ablation. *Int Surgery* 1996;81(4), 362-370

Mettler L, Semm K, Lehmann-Willenbrock L, Shah A, Shah P, Sharma R. Comparative evaluation of classic intrafascial supracervical hysterectomy (CISH) with transuterine mucosal resection as performed by pelviscopy and laparotomy: our first 200 cases. *Surg Endosc* 1995; 9(4):418-23

Levine DJ, Botney K. The classic intrafascial SEMM hysterectomy as an alternative to abdominal hysterectomy. *J Am Assoc Gynecol Laparosc* 1996;3(4):545-548

Vietz PF, Ahn TS. A new approach to hysterectomy without culpotomy: pelviscopic intrafascial hysterectomy. *Am J Obstet Gynecol* 1994;170(2):609-613

Becker ER, Spalding J, DuChane J, Horowitz IR. Inpatient surgical treatment patterns for patients with uterine fibroids in the United States, 1998-2002. *J Natl Med Assoc* 2005; Oct:97(10):1336-42

Washington JL. Laparoscopic supracervical hysterectomy compared with abdominal, vaginal and laparoscopic vaginal hysterectomy in a primary care hospital setting. *J SLS* 2005 Jul-Sep;9(3):292-7

Hoffman CP, Kennedy J, Borschel L, Burchette R, Kidd A. Laparoscopic hysterectomy: The Kaiser Permanente San Diego experience. *J Minimally Invasive Gynecol* 2005;12(1):16-24

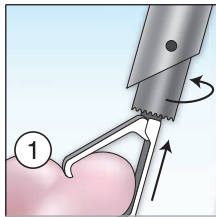
Sarmini OR, Lefholz K, Froeschke H. A comparison of laparoscopic supracervical hysterectomy and total abdominal hysterectomy outcomes. *J Minimally Invasive Gynecol* 2005;12:121-124

Lyons TL, Adolph AJ, Winer WK. Laparoscopic supracervical hysterectomy for the large uterus. *J Am Assoc Gynecol Laparosc* 2004;11(2):170-174

El-Mowafi D, Facharzt WM, Lall C, Wenger J. Laparoscopic supracervical hysterectomy versus laparoscopic-assisted vaginal hysterectomy. *J Am Assoc Gynecol Laparosc* 2004;11(2):175-180

Thompson JD, Warsaw J. Hysterectomy. In: Rock JA, Thompson JD (eds): *Telinde's Operative Gynecology* 8th Edition. New York, NY, Lippencott-Raven Publishers, 1996, 771- 854.

# LAPAROSCOPIC MYOMECTOMY AND LAPAROSCOPICALLY ASSISTED MYOMECTOMY



**Ceana Nezhat, M.D.**  
**Deidre Fisher, M.D.**

**M**yomas are the most common uterine neoplasm, affecting 20-25% of women of reproductive age. Myomas develop from the benign transformation and proliferation of smooth muscle cells, and can occur in any area with smooth muscle cells of Müllerian origin. Uterine myomas can cause abnormal uterine bleeding, abdominal pressure, urinary frequency, and constipation. The severity of these symptoms is dependent on the number of tumors, their size, and location (Figure 1). Although not primarily the cause of infertility, myomas have been linked to fetal wastage and premature delivery. Indications for treatment are listed below. The number, size, and location of the tumors influence the technique used.

Preoperative evaluation should include assessment of anemia. The use of gonadotropin-releasing hormone (GnRH) is indicated for anemic patients as it may restore a normal hematocrit, decrease the size of the myoma, and reduce the need for transfusion. An intravenous pyelogram may be indicated to check for ureteral obstruction when there is a large broad ligament myoma. Pelvic ultrasound is another preoperative tool to monitor the growth rate of asymptomatic myomas and to check for submucous tumors.

### INDICATIONS FOR MYOMECTOMY

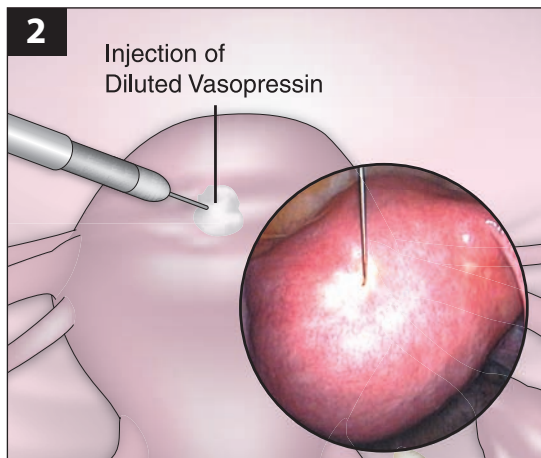
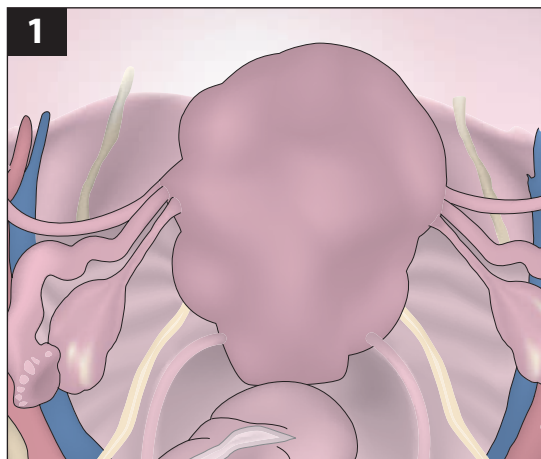
- MENOMETRORRHAGIA AND ANEMIA
- PELVIC PAIN AND PRESSURE
- ENLARGING LEIOMYOMA AND POSSIBILITY OF NEOPLASIA
- ASSOCIATED FETAL WASTAGE OR INFERTILITY
- GESTATIONAL SIZE MORE THAN 12 WEEKS AND INABILITY TO EVALUATE THE ADNEXA
- OBSTRUCTED URETER

Patients should always be counseled regarding the risk of intraoperative and postoperative bleeding, and autologous blood donation may be suggested. In addition, patients should be aware of the possible necessity for laparotomy and, although low, the potential chance of hysterectomy.

### LAPAROSCOPIC MYOMECTOMY - TECHNIQUE

The necessary instruments include a CO<sub>2</sub> laser, unipolar electrode or harmonic scalpel, a bipolar Kleppinger forceps, clawed grasping forceps, myoma screw, and suturing instruments.

Dilute Pitressin (vasopressin 1 cc; 20 units in 60-100 cc NaCl) is injected into the base of the stalk at the junction of the uterine fundus (Figure 2). Pedunculated leiomyomas are removed by coagulating and cutting the stalk, and bleeding areas controlled with bipolar forceps. For intramural myomas, dilute vasopressin is injected in multiple sites between the myometrium and the fibroid capsule.

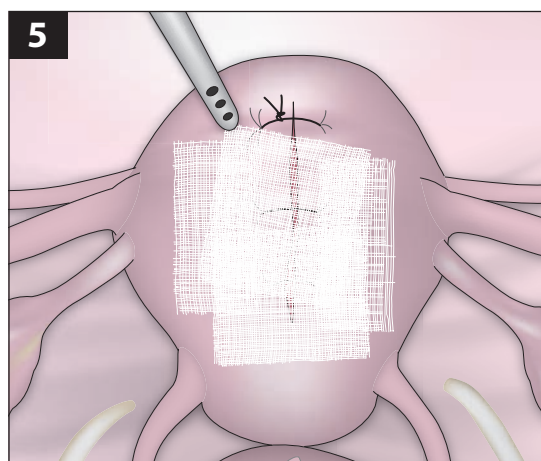
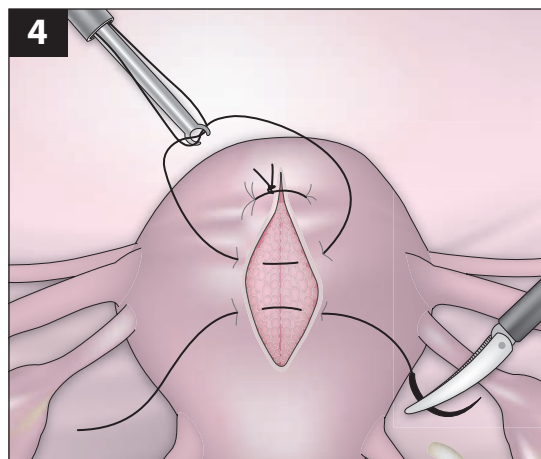
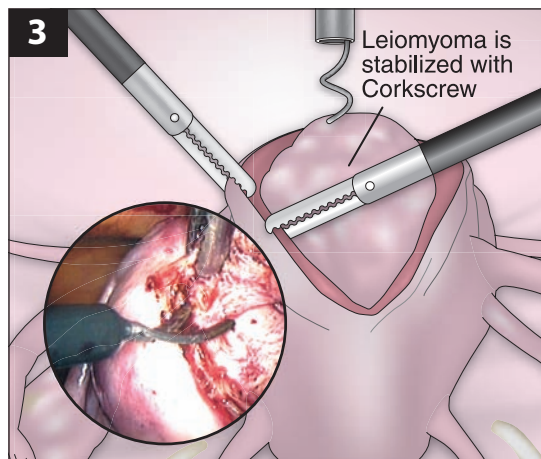


An incision is made on the serosa overlying the leiomyoma using the CO<sub>2</sub> laser, a monopolar electrode, a fiber laser, or harmonic scalpel. The incision is extended until it reaches the capsule, and the myometrium retracts as the incision is made, exposing the tumor. The suction-irrigator is used as a blunt probe to shell the leiomyoma from its capsule while two grasping, toothed forceps hold the edges of the myometrium. A myoma screw is inserted into the tumor to apply traction while the suction-irrigator is used

as a blunt dissector (Figure 3). Vessels are electrocoagulated before being cut, and the uterine defect is irrigated after the myoma has been completely removed. If the defect is deep or large, the myometrium and serosa are approximated by using a 1-0 polydioxanone and 4-0 polyglactin suture in several layers. The repair mainly involves myometrium and the serosal and subserosal layers and may be accomplished in one layer, but we prefer two layers, if possible. The sutures should be applied in 1 cm increments using extracorporeal or intracorporeal knot tying (Figure 4). Once the repair is complete, the uterine surface is irrigated with warmed lactated Ringer's solution and Interceed™ (Johnson & Johnson Medical, Somerville, NJ) is applied over the suture line.

Spraying 10,000 IU of thrombin over the Interceed™ contributes to hemostasis (Figure 5). Suturing is limited because of the high incidence of post-operative adhesions. The defect will heal better and with less deformity when the edges are approximated. Even under ideal circumstances, laparoscopic microsurgical closure of the myometrial defect is difficult.

Ligamentous and broad ligament myomas require careful observation of the course of the ureters and large blood vessels. Depending on the location of the myoma, an incision is made on the anterior or posterior leaf of the broad ligament. The myoma is removed with the same techniques described for subserosal and intramural tumors. The location of the ureters is noted throughout the pro-



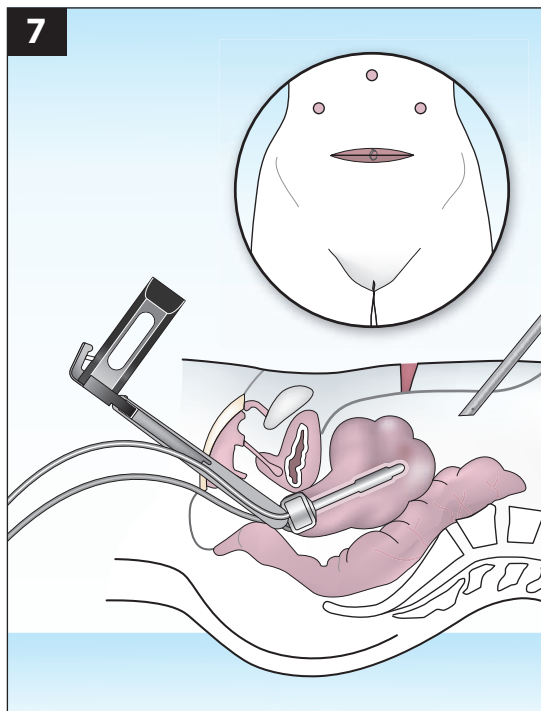
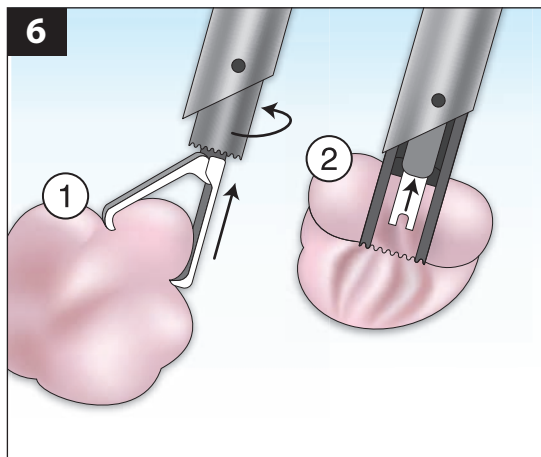
cedure. Hemostasis is obtained with sutures, clips, or bipolar forceps. None of the lasers can adequately coagulate bleeding myometrial vessels, however, a bipolar forceps or argon beam coagulator is excellent for this purpose. The broad ligament and peritoneum are not closed, but allowed to heal spontaneously. Drains are almost never used.

Removal of myomas from the abdominal cavity is a time-consuming procedure, and no methods or instruments are ideal for this purpose. A claw-toothed forceps is inserted through a 10 mm sleeve for myomas <5 cm. A long Kocher clamp is inserted through one suprapubic incision, which often has to be extended. The midline incision is preferred to avoid injury to the inferior epigastric vessels. This is a quick technique.

Larger myomas can be removed through a posterior colpotomy, however, this method may increase operative time, infectious morbidity, and add risk of bowel and ureteral injury. Colpotomy is not safe in women with concurrent posterior cul-de-sac abnormalities. Improvements in electronic morcellators have made this task easier (Figure 6).

## LAPAROSCOPICALLY ASSISTED MYOMECTOMY

Laparoscopically assisted myomectomy (LAM) is a safe alternative to LM, and is less difficult and less time consuming. The criteria for LAM are: myoma greater than 8 cm, multiple myomas requiring extensive morcellation, and a deep, large, intramural or transmural myoma requir-



ing uterine repair in multiple layers. Using a combination of laparoscopy and a 2-4 cm abdominal incision may enable more gynecologists to apply this technique (Figure 7). Uterine suturing in 2 or 3 layers reduces the chances of uterine dehiscence, fistulas, and adhesions.

The three major objectives of LAM are:

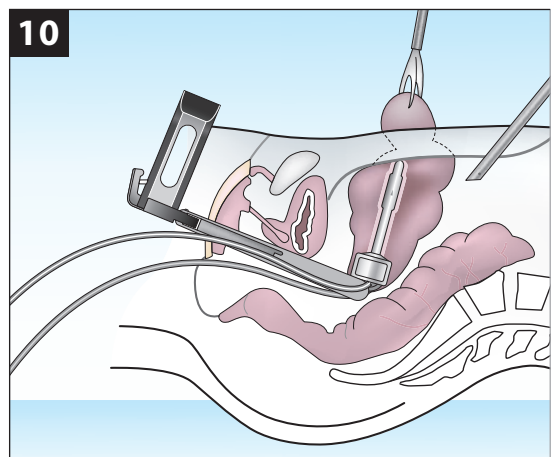
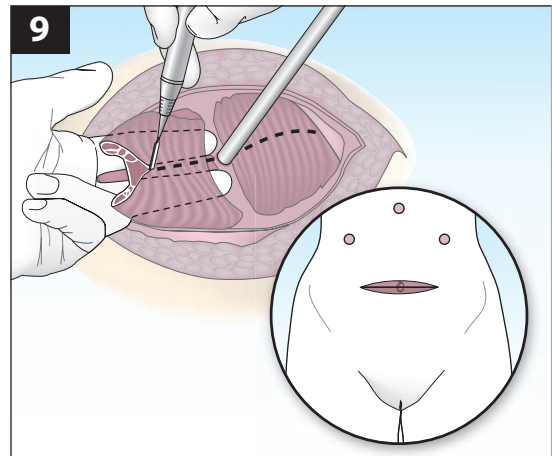
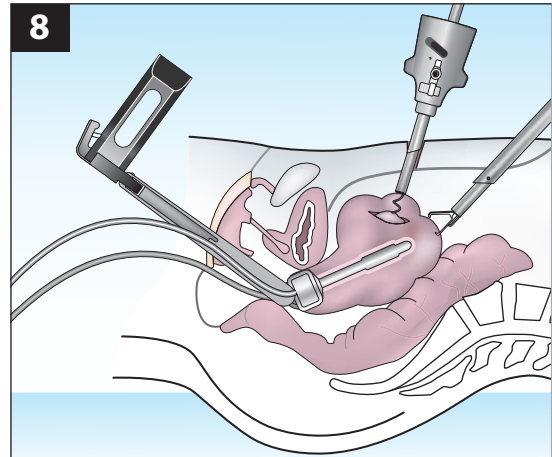
1. Reduction of blood loss,
2. Maintenance of myometrial integrity, and
3. Decrease the chances of post-operative adhesions.

LAM reduces the duration of the operation and the need for extensive laparoscopic experience when performed with morcellation and conventional suturing.

### LAM TECHNIQUE

When multiple myomas are encountered, the most prominent myoma is injected at the base with 10-15 mL of diluted vasopressin. A vertical incision is made over the uterine serosa on to the surface of the tumor. The incision is extended until the capsule of the leiomyoma is reached (Figure 8). A corkscrew manipulator is inserted into the leiomyoma and used to move the uterus toward the midline suprapubic puncture and the puncture is enlarged to a 4 cm transverse skin incision. Once the incision of the fascia is made transversely, the rectus muscle is divided using a monopolar electrode. The inferior epigastric vessels, if found, are coagulated. This provides excellent access to the abdominal cavity (Figure 9).

The peritoneum is entered transversely or vertically and the leiomyoma is observed. Using the corkscrew manipulator, the leiomyoma is brought to the mini-laparotomy incision. The corkscrew manipulator is replaced by two Lahey Tenacula (Figure 10). The tumor is

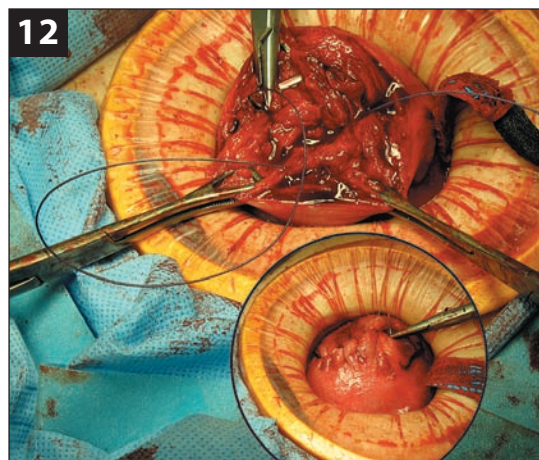
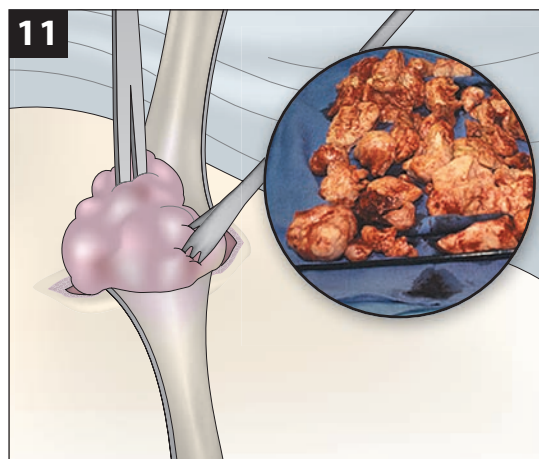




shelled and morcellated (Figure 11). After complete removal, the uterine wall defect shows through the incision. If uterine size allows, the uterus is exteriorized to complete the repair. As many leiomyomas as possible should be removed through one uterine incision. When other leiomyomas are present and cannot be removed through the initial uterine incision, the abdominal opening is approximated with 2 or 3 Allis clamps or an inflated sterile glove. The remaining leiomyomas are removed in the same manner under laparoscopic control. The uterus is then exteriorized through the 4-cm abdominal incision and the myometrium is closed in layers with 2-0 and 0 polydioxanone sutures (Figure 12). The uterus is palpated to ensure that no small intramural leiomyomas remain and it is returned to the peritoneal cavity. The fascia is closed with number 0 polyglactin suture and the skin is closed in a subcuticular manner. The laparoscope is used to evaluate hemostasis and the pelvis is observed to detect and treat any pathology that may have previously been obscured by myomas. Copious irrigation is used, blood clots are removed, and Interceed™ is applied over the uterus to help prevent adhesions.

Injections of dilute vasopressin into the myoma help reduce blood loss intraoperatively. In addition, vertical uterine incisions bleed less than transverse, and pneumoperitoneum seems to decrease intraoperative bleeding.

Most patients are observed in an outpatient unit and discharged the morning after the operation, and some can even



leave on the day of the procedure. Women who desire future -fertility and who require myomectomy for an intramural tumor may benefit from LAM to ensure proper closure of the myometrial incision. Cesarean delivery is safer in patients who had deep intramural myoma removed or who have had multiple myomectomies as well as penetration to the cavity.

## MYOLYSIS

Laparoscopic coagulation of myomas, or laparoscopic myolysis can be used as an alternative to laparoscopic myomectomy for the treatment of intramural or subserosal leiomyomas. Myolysis, which is achieved with use of either monopolar or bipolar energy, is designed to destroy the blood supply and stroma of symptomatic myomas to achieve a decrease in their

size. However, because the procedure carries a higher risk of uterine rupture it is reserved for treatment in women not desiring future fertility. Preoperatively, GnRH-agonists can be used up to 3 months with a 30-50% decreased myoma volume. Myolysis, however, carries a greater risk of adhesion formation. Newer techniques, such as cryomyolysis and laser-induced thermotherapy, are also being studied.

## SUGGESTED READING:

Buttram VC, Reiter RC. Uterine leiomyomata: etiology, symptomatology, and management. *Fertil Steril* 1981;36:433

Vollenhoven BJ, Lawrence AS, Healy DL. Uterine fibroids: a clinical review. *Br J Obstet Gynaecol* 1990;97:393

Freidman AJ, Rein NS, Harrison-Atlas D, et al. A randomized, placebo-controlled, double blind study evaluating leuprolide acetate depot treatment before myomectomy. *Fertil Steril* 1989;52:728

Nezhat C, Nezhat F, Silfen SL, Schaffer N, Evans D. Laparoscopic myomectomy. *Int J Fertil* 1991;36(5):275-280

Nezhat C, Nezhat F, Bess O, Nezhat CH, Mashiach R. Laparoscopically assisted myomectomy: a report of a new technique in 57 cases. *Int J Fertil Menopausal Stud* 1994;39(1)39-44

Melis GB, Ajossa S, Piras B, et al. A randomized trial to evaluate the prevention of de novo adhesion formation after laparoscopic myomectomy using oxidized regenerated cellulose (Interceed™) barrier. *J Am Assoc Gynecol Laparosc* 1995;2:S31

Nezhat C, Siegler AM, Nezhat F, Nezhat CH, Seidman D, Luciano AA. *Operative Gyneco-logic Laparoscopy: Principles and Techniques*. 2nd ed. New York: McGraw Hill, 2000

Hald K, Langbrekke A, Klow NE, Noreng HJ, Berge AB, Istre O. Laparoscopic occlusion of uterine vessels for the treatment of symptomatic fibroids: initial experience and comparison to uterine artery embolization. *Am J Obstet Gynecol* 2004;190:37-43

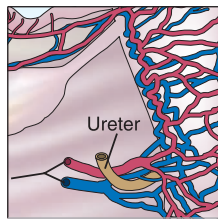
Goldberg J, Pereira L, Berghella V, Diamond J, Darai E, Seiner P, Seracchioli R. Pregnancy outcomes after treatment for fibromyomata: uterine artery embolization versus laparoscopic myomectomy. *Am J Obstet Gynecol* 2004;191:18-21

Pron G, Mocrski E, Bennet J et al. Pregnancy after uterine artery embolization for leiomyomata: the Ontario multicenter trial. *Obstet Gynecol* 2005;105:67-76

Wallach EE, Vlahos NF. Uterine myomas: an overview of development, clinical features, and management. *Obstet Gynecol*. 2004;104:393-406

.....

# LAPAROSCOPIC OCCLUSION OF UTERINE ARTERIES



*Kirsten Hald, M.D.*

*Olav Istre, M.D., Ph.D.*

## INTRODUCTION

**S**ince Ravina published the first report of arterial embolization (UFE) for treatment of uterine fibroids in 1995, several observational studies have subsequently reported effective relief in symptoms of excessive menstrual bleeding or pressure in about 84%-90% of the patients. This treatment has gained increasing popularity among women with such complaints who wish to retain their uteri. Bilateral laparoscopic occlusion of uterine arteries represents another modality of avoiding hysterectomy in these women. In 2000, Liu first published the description of this technique by the use of bipolar coagulation of uterine arteries and anastomotic sites of ovarian arteries. Treatment of women with fibroids and menorrhagia symptoms using bilateral ligation of the uterine artery is not new. In 1890 Rydygier published the first paper presenting the effect of this technique. In 1964, an article by Bateman in the *American Journal of Obstetrics and Gynecology* also reported successful treatment of fibroids and menorrhagia by bilateral ligation. Recently, several authors have reported effective treatment of laparoscopic bilateral occlu-

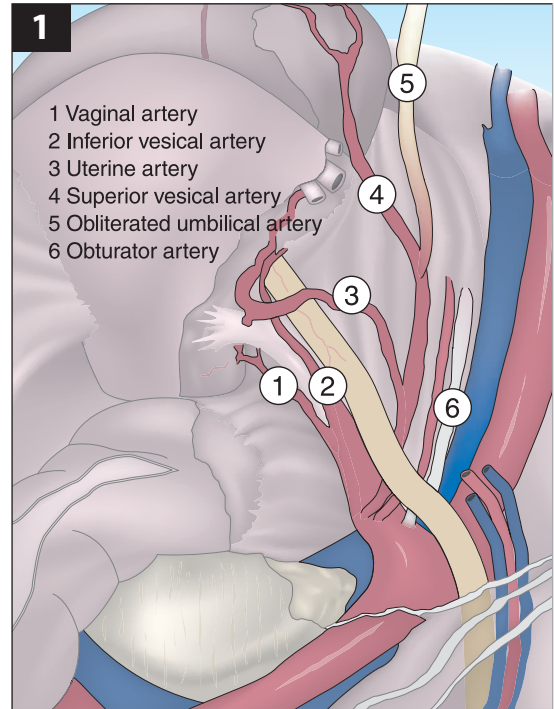
sion of uterine vessels on short-term follow up. However, one must keep in mind that there are a limited number of studied procedures, and no knowledge of long-term efficacy.

## INDICATION

Laparoscopic occlusion of uterine arteries can be an option for women with symptomatic uterine fibroids who wish to retain their uterus. However, the method is still considered investigational. Therefore this technique is recommended in clinical trials only, and for women who are not candidates for other modalities of conservative treatment.

## MECHANISM OF FIBROID DEATH

Why do the fibroids die, while the uterus survives? Fibroids seem to be more vulnerable to uterine ischemia than a healthy myometrium, a mechanism that is not fully understood. Perfusion studies by MRI and computed tomography performed after fibroid embolization indicate that blood initially clots in the vessels of both myometrium and fibroids. After a period of time, the blood clots disappear inside the vessels of healthy myometrium, but not inside the fibroid vessels. The myometrium survives until the bloodflow is re-established, unlike the ischemic fibroids, which die due to their insufficient blood supply. It is hypothesized that the fibroid tissue is less able to lyse clots that form inside the vessels after ischemia and less able to recruit collateral flow. Normal myometrium have



higher activity of fibrinolytic enzymes compared to fibroids, a fact which supports this theory. The combination of a greater microvascular density and vessels with a larger mean surface in the myometrium may contribute to this. The fibrinolytic enzymes are concentrated in the endothelium of the vessels. Future genetic and molecular investigations might reveal further insight to these mechanisms.

## VASCULAR ANATOMY

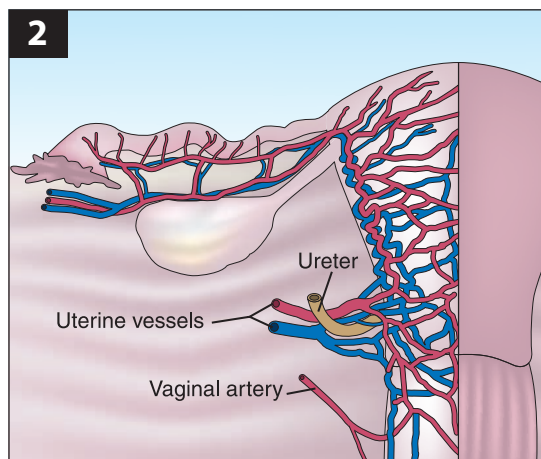
A detailed knowledge of the pelvic vascular anatomy is essential to perform this procedure safely (Figure 1). Because of the variability of the three-dimensional distribution of the internal iliac artery

branches in the deep pelvis, the classic anatomic and radiological topography of the uterine artery might be difficult to understand for the surgeon. Angiographic and surgical experience reveals numerous anatomical variations of the location of this artery. Occasionally there are two instead of one artery, or it may even be missing at one side.

Most commonly the uterine artery arises from the unobliterated segment of the umbilical artery, distal to the origin of the internal pudendal artery, as the first or second branch. Less common the uterine artery arises from the internal pudendal artery. It is crucial to be aware of the other parietal branches of the internal iliac artery in this area. The superior vesical artery often originates from the umbilical artery distal to the uterine artery, but may also have other locations. Similarly, the medial rectal artery and the obturator artery arise variably from the internal iliac artery in the same area.

When the uterine artery has left the internal iliac artery, it runs medial and invariably crosses above the ureter before it reaches the lateral uterine wall and divides into the ascending and descending branches.

The uterus has a rich blood supply, mainly from the uterine artery (Figure 2). The uterine and ovarian arteries communicate through ipsilateral branches. Controversy exists about the direction of flow in these anastomoses. In addition to the primary blood supply of the uterus, there exists a vast network of collateral arterial communication from the vagina, the aorta, external iliac, femoral artery



branch, and other lesser-known arterial collaterals. Intramural intrinsic uterine arteries consist of ascending and descending, arcuate, radial, and peripheral arteries resulting in free flow through the uterus. Fibroids receive their primary blood supply from the end arterioles of the uterine artery. Bilateral occlusion of the uterine artery prevents a collateral flow to the fibroid from the contralateral artery.

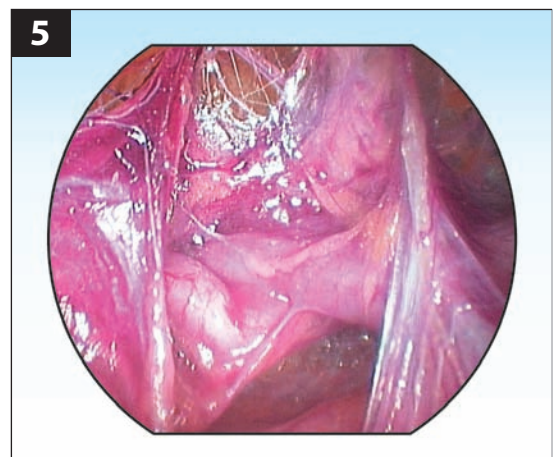
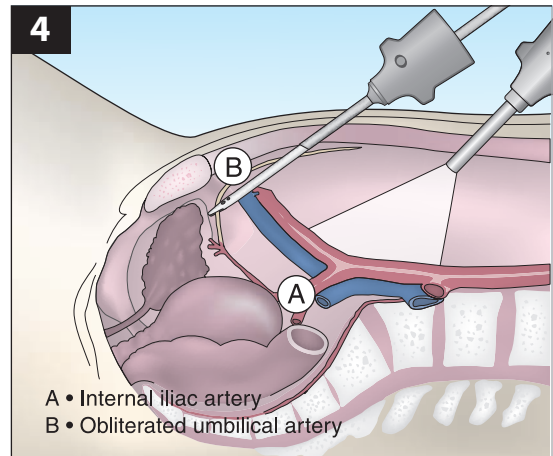
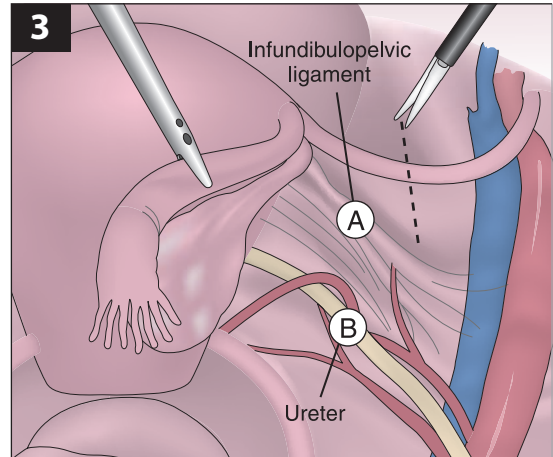
## SURGICAL TECHNIQUE

The patient is placed in the supine position without flexion of the hips. No cervical tenaculae is necessary. Under general anesthesia with tracheal intubation, a 10 mm trocar is inserted in the midline in the umbilical area and two 5.5-mm trocars are inserted ipsilateral to the epigastric artery. The peritoneum between the round ligament and the infundibulopelvic ligament on the patient's right side is incised parallel to the external iliac artery using a scissor

(Figure 3). The retroperitoneal space is entered by blunt dissection. Atraumatic forceps are used to reach the lateral origin of the uterine artery. In order to secure the view, it is considered helpful to coagulate all bleeding that might occur from capillary vessels during this part of the surgery. The identification of the uterine artery might be easy or challenging, due to the extreme variations of the arterial anatomy in this area. Because of the uterine size or the location of fibroids, there is often very little space to work in and the surgeon's view is restricted. Under such circumstances, it is helpful to locate the obliterated umbilical artery on the anterior abdominal wall. It can be firmly grasped with a forceps and lifted to show its posterior part. Then the umbilical artery is dissected from the posterior location caudally towards its unobliterated part, that continues into the internal iliac vessel (Figure 4). In this area, the origin of the uterine artery will appear. It is advisable to dissect the uterine artery towards the uterus to confirm that the artery is crossing over the ureter and enters the uterine wall (Figure 5). The uterine artery can be occluded with bipolar coagulation, with endoclips or with suture ligation (Figure 6). It is not recommended to occlude the uteroovarian collateral arteries in pre-menopausal women.

## INTRAOPERATIVE COMPLICATIONS

It is important to avoid injury of other organs in the area, especially nerves, ves-

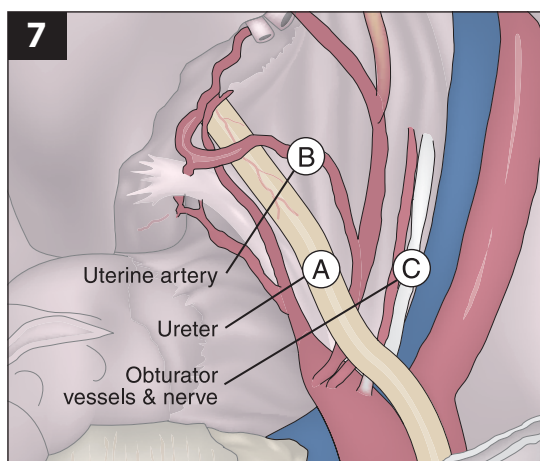
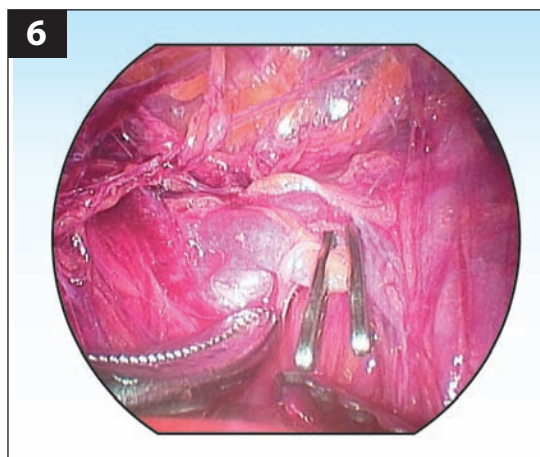


sels and the ureter. When the uterine artery is easy to locate, the risk of such injury will be low. In cases requiring more extensive dissection to locate the artery, there will obviously be a greater risk. It is crucial to be aware of the obturator nerve, positioned posterior to the obliterated umbilical artery. (Figure 7)

In our experience, bleeding from branches of the internal iliac artery or vein is best managed by vascular clip, but coagulation of the vessel is also an option. Laceration of larger veins (e.g., the external or internal iliac vein) is unlikely. If bleeding from one of these vessels occurs, compression of the vein against the pelvic wall may be successful in small injuries. If hemorrhage persists, the use of coagulation or clips is not advised as it may worsen the laceration. The use of vascular sutures is then recommended, often best handled by laparotomy with a vascular surgeon in attendance.

## POSTOPERATIVE COURSE

Reactions related to the post-procedure ischemic and necrotic process can be expected, but to a lesser extent as for embolization of uterine fibroids. The postoperative pain requires less narcotic analgesics, compared to embolization. However, women scheduled for this procedure should be informed about the possibility of pain recurrence one to two weeks after the operation. Occasionally some patients require opioids and re-hospitalization for this reason, which necessitates an exclusion of a postopera-



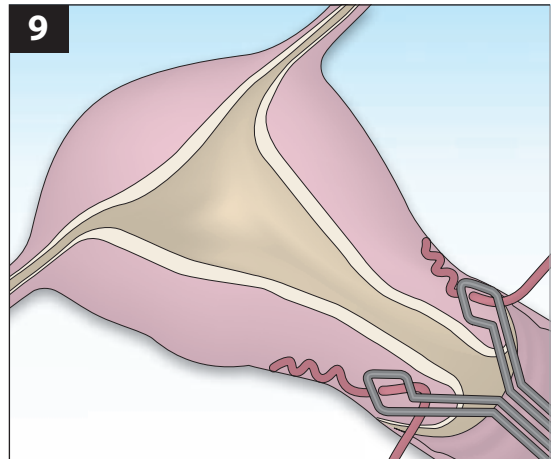
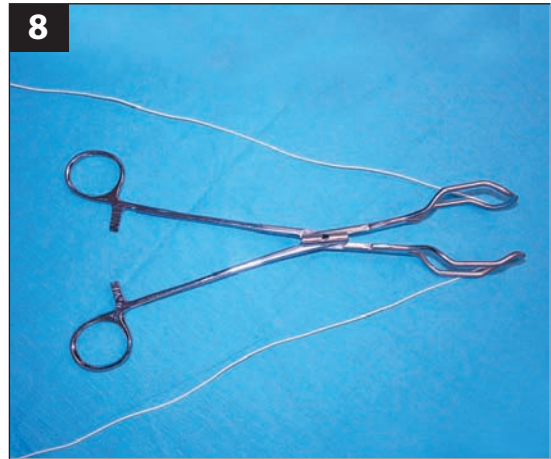
tive infection or hematoma. As for fibroid embolization, vaginal expulsion of necrotic fibroids may occur which might demand dilatation and curettage or transcervical resection of necrotic fibroids or tissue.

## TEMPORARY ARTERY OCCLUSION

Perfusion studies indicate that fibroids deteriorate early during the ischemic process after uterine fibroid embolization



and laparoscopic occlusion. This fact has led to the treatment principle of temporary uterine ischemia. Recently, a device utilizing compression only to interfere with the blood circulation has been developed for treatment of fibroids and does not require an incision, Flowstat™ (Vascular Control Systems, Inc., San Juan Capistrano, CA) (Figure 8). This system for uterine artery occlusion consists of a guiding cervical tenaculum, a transvaginal vascular clamp with integrated Doppler ultrasound crystals, and a small, battery powered transceiver that generates audible Doppler sound. The clamp slides along the guiding tenaculum to the level of the lateral vaginal fornices at the 9:00 and the 3:00 o'clock cervical positions. When the crystals located in the clamp arms contact vaginal mucosa, they return audible signals from the right and left uterine arteries. When the clamp advances further along the guiding tenaculum, the clamp displaces the uterine arteries superior to their points of insertion into the uterus. When closed, the clamp occludes the uterine arteries bilaterally by squeezing them against the lateral borders of the uterus and the clamp remains in place for six hours (Figure 9). Bilateral occlusion of the uterine arteries for six hours was sufficient to treat multiple fibroids in several patients. Application during and after laparoscopic myomectomy might prevent perioperative and postoperative bleeding. Adjuvant therapy of residual fibromas is an additional option for the temporary artery occlusion device. The procedure is still experimental. To prove its long-term value, further results of this therapeutic approach are needed.



## CONCLUSIONS

Fibroids present with a variety of symptoms including infertility, bleeding disturbances, pressure and pain. Fibroids might be solitary or multiple and occur at different ages, which requires individualization with regards to treatment. Infertility patients with a solitary fibroid should in some cases have it removed, whereas multiple fibroids might require medical or circulation therapy if this is the only option for saving the uterus. The

location of the fibroid is an important issue in bleeding disturbances. In case of submucosal or type 0, hysteroscopic resection is the method of choice. For larger intramural, subserosal and even multiple fibroids, uterine artery therapy with embolization or laparoscopy may produce good results for bleeding and

pressure symptoms. Both radiological and laparoscopic occlusion techniques are options for treatment. However, both techniques require a high level of skill and probably should be confined to a special center with appropriate expertise. Counseling of patients is of greatest importance.

## SUGGESTED READING:

Burbank F, Hutchins FL. Uterine artery occlusion by embolization or surgery for the treatment of fibroids: a unifying hypothesis-transient uterine ischemia. *J Amer Assoc Gynecol Laparosc* 2000;7:1-49

Gomez-Jorge J, Keyoung A, Levy EB, Spies JB. Uterine artery anatomy relevant to uterine leiomyomata embolization. *Cardiovasc Intervent Radiol* 2003;26:522-27

Hald K, Langebrekke A, Klow NE, Noreng HJ, Berge AB, Istre O. Laparoscopic occlusion of uterine vessels for the treatment of symptomatic fibroids: Initial experience and comparison to uterine artery embolization. *Am J Obstet Gynecol* 2004;190:37-43

Holub Z, Lukac J, Kliment L, Urbanek S. Short-term results from laparoscopic dissection of uterine vessels in women with symptomatic fibroids. *Eur J Obstet Gynecol Reprod Biol* 2003;110:94-98

Holub Z, Lukac J, Kliment L, Urbanek S. Variability of the origin of the uterine artery: Laparoscopic surgical observation. *J Obstet Gynaecol Res* 2005;31:158-63

Istre O, Hald K, Qvigstad E. Multiple myomas treated with a temporary, noninvasive, Doppler-directed, transvaginal uterine artery clamp. *J Am Assoc Gynecol Laparosc* 2004;11:273-76

Lichtinger M, Hallson L, Calvo P, Adeboyejo G. Laparoscopic uterine artery occlusion for symptomatic leiomyomas. *J Am Assoc Gynecol Laparosc* 2002;9:191-98

Lichtinger M, Burbank F, Hallson L, Herbert S, Uyeno J, Jones M. The time course of myometrial ischemia and reperfusion after laparoscopic uterine artery occlusion - theoretical implications. *J Am Assoc Gynecol Laparosc* 2003;10:554-63

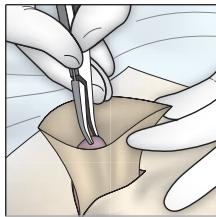
Lichtinger M, Herbert S, Memmolo A. Temporary, transvaginal occlusion of the uterine arteries: a feasibility and safety study. *J Minim Invasive Gynecol* 2005;12:40-42

Liu WM, Ng HT, Wu YC, Yen YK, Yuan CC. Laparoscopic bipolar coagulation of uterine vessels: a new method for treating symptomatic fibroids. *Fertil Steril* 2001;75:417-22

Park KH, Kim JY, Shin JS, Kwon JY, Koo JS, Jeong KA, et al. Treatment outcomes of uterine artery embolization and laparoscopic uterine artery ligation for uterine myoma. *Yonsei Med J* 2003;44:694-702

.....

# TISSUE RETRIEVAL IN ENDOSCOPIC SURGERY



*Eric Heinberg, M.D.*  
*Resad Pasic, M.D.*

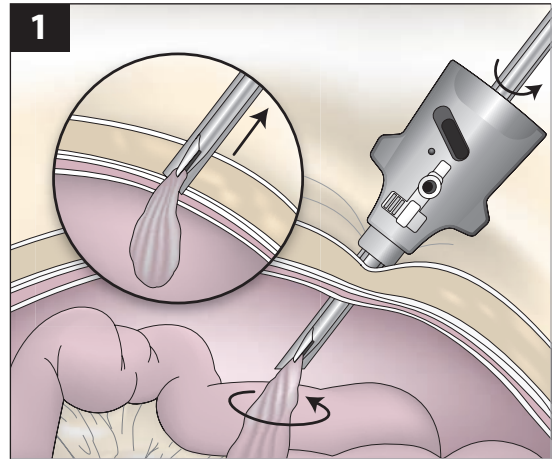
**G**aining access to the body's deep structures while avoiding large skin incisions is the essence of advanced laparo-endoscopic surgery. Minimally invasive techniques have expanded to encompass all areas of surgery and their advancement has reached levels unimaginable even a decade ago. Yet, the advantage of a skillfully performed laparoscopic procedure is greatly diminished if the procedure culminates in a large incision created for the removal of an extirpated organ or tissue. This challenge has led one prominent pioneer of laparoscopy to refer to the creation of effective, minimally invasive techniques for laparoscopic tissue retrieval as the "Holy Grail" of the discipline. Such techniques must be safe for the patient and both time and cost efficient if they are to enhance the inherent benefits of advanced laparoscopic surgery.

## CLASSICAL TECHNIQUES

Prior to the advent of specialized instrumentation, laparoscopic tissue retrieval was accomplished using simple techniques derived from open surgery. Benign specimens up to 8 mm in diameter, such as oviducts,

may be recovered directly through lateral 5 mm incisions. The surgeon draws the tissue into the port sleeve using gentle rotation and opens the flapper valve as the specimen is withdrawn. For specimens too broad to fit entirely into the sleeve, the tissue is grasped at its narrowest aspect and drawn partially into the port. The sleeve, grasping instrument, and specimen are then all drawn out of the abdomen together in one smooth motion (Figure 1). A blunt probe or other instrument may then be placed into the abdomen via the exit tract and the sleeve pushed back in place over it.

For slightly larger specimens such as postmenopausal ovaries without malignant features, decompressed adnexal cysts, or the appendix, the 10-12 mm umbilical sleeve is often adequate for tissue removal. Grasping forceps may be placed through an operative laparoscope and the specimen extracted under direct vision by drawing the scope along with the grasped specimen up through the sleeve. This method is well suited to the appendix, as it minimizes the likelihood of wound contamination. Alternatively, the instrument with the specimen may simply be removed together with the sleeve in a manner similar to that described above using a 5 mm sleeve, but this technique is not recommended for removal of the appendix, contaminated, or malignant tissue. If the surgeon is not using an operative (10 mm) laparoscope, a 5 mm laparoscope may be introduced through one of the lateral ports and the tissue recovered with a grasping forceps under direct vision using either

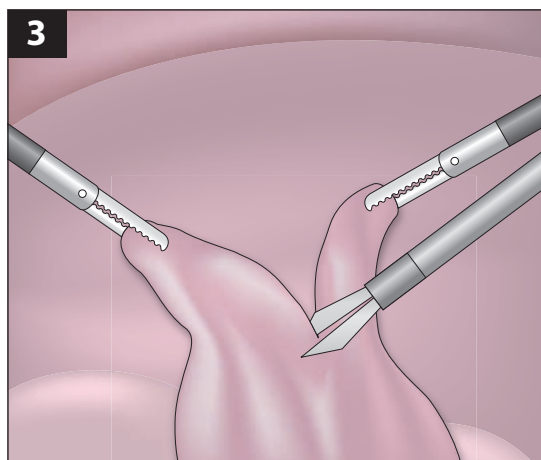
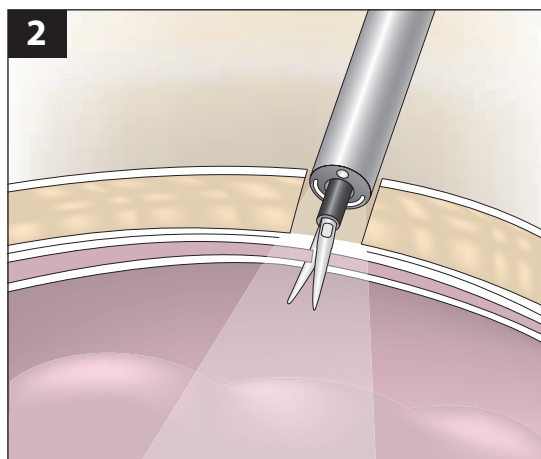


of the above techniques. It is important to grasp and hold onto the specimen while changing to a 5 mm laparoscope in order to avoid losing it within the upper abdomen.

The removal of larger specimens such as benign, pre-menopausal ovaries, small myomas or the gallbladder often requires enlargement of the umbilical incision. This can be accomplished using classical open technique but may be technically difficult and require an exaggerated skin incision in order to approach the rectus fascia in obese patients. Reich described a technique that greatly facilitates extension of the fascial incision in these cases by using laparoscopic scissors passed through an operative laparoscope (Figure 2). The peritoneum and fascia are clearly visualized under laparoscopic magnification and opened with laparoscopic scissors. The specimen is then removed through this incision using a grasper as described above, and the fascia reapproximated in the traditional fashion using permanent or delayed absorbable

suture. Extension of the fascial incision may be avoided by use of a 10 mm laparoscopic scissor placed through a 10 mm sleeve. Laparoscopic graspers are used to stabilize the specimen while manually morcellating it into pieces small enough to be recovered via the 10 mm port sleeve (Figure 3). This is done under direct vision with a 5, mm laparoscope placed through the other 5 mm port and works well for smaller myomas. Alternatively, the surgeon can perform manual morcellation by removing one of the lateral 5 mm ports and inserting through the exit tract, under direct laparoscopic vision, a scalpel fitted with a #10 blade. The specimen is then securely held safely distant from the vital structures of the pelvic sidewall, and cut into small pieces for retrieval. In experienced hands, this technique works well for such specimens as small myomas, but it is time consuming and not without significant risk of penetrating injury to the bowel or major vessels. For these reasons, most laparoscopic surgeons do not prefer it.

Mini-laparotomy for tissue retrieval may be avoided by use of a laparoscopic culdotomy. This incision in the posterior vaginal fornix is well suited to the recovery of large ovaries, cysts and myomas from the peritoneal cavity. The anatomic relationship of the rectum to the posterior vagina must be defined prior to performing laparoscopic culdotomy. This is facilitated by placement of some type of manipulator into the uterus in order to elevate it anteriorly. A probe placed into the rectum provides addition-

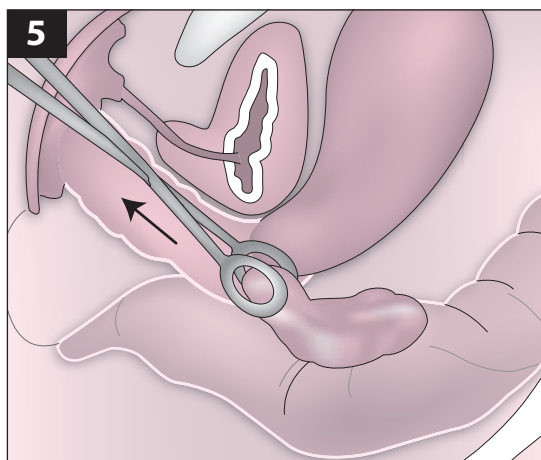
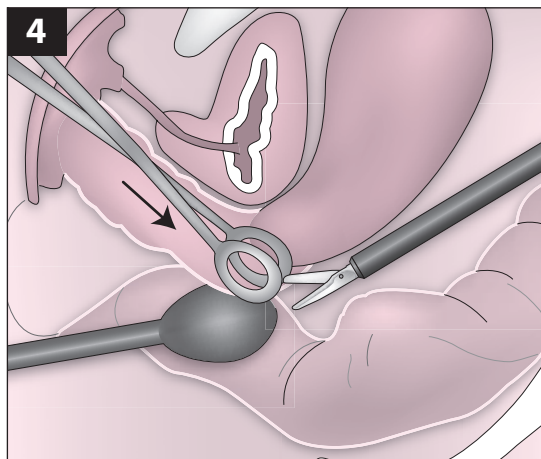


al assistance when difficulty is encountered opening a scarred posterior cul-de-sac. Once normal anatomy is established, the upper vagina is delineated with a moist sponge on a ring forceps or the bulb end of a rubber infant nasal suction (the suction tip cut off) with a ring forceps inside. Either of these implements will highlight the proper incision site slightly above and between the uterosacral ligaments, while maintaining pneumoperitoneum once the incision is made. A transverse culdotomy incision is

then made laparoscopically using either a monopolar electrode tip set at 80 W to 100 W of pure cutting current, with laser energy at a comparable power setting, or with harmonic energy set for cutting (Figure 4). Laparoscopic grasping or traditional ring forceps may then be carefully passed through this incision into the pelvis and the specimen withdrawn vaginally (Figure 5). The culdotomy incision is then vaginally or laparoscopically sutured closed. When using this technique, trauma to vital structures is avoided by direct laparoscopic vision and the maintenance of sufficient pneumoperitoneum with a moist vaginal sponge or the cut infant suction bulb described above. If the surgeon prefers, a 5 mm instrument can be used to deliver the specimen from above into the vagina where it may be grasped with the fingers and removed. In cases of tissue suspicious for malignancy, a specialized laparoscopic tissue retrieval bag (see below) may, likewise, be passed into the vagina for specimen removal.

### **SPECIALIZED SYSTEMS FOR LAPAROSCOPIC TISSUE RETRIEVAL**

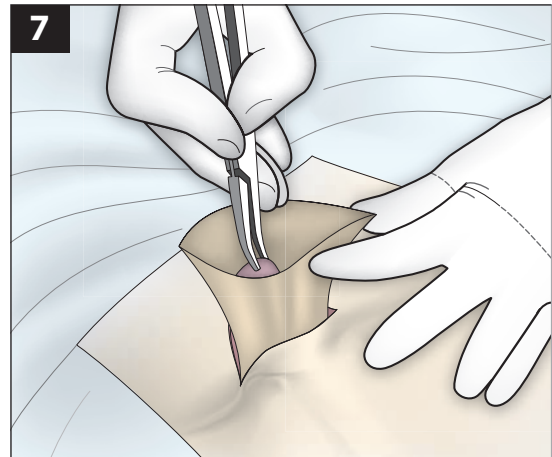
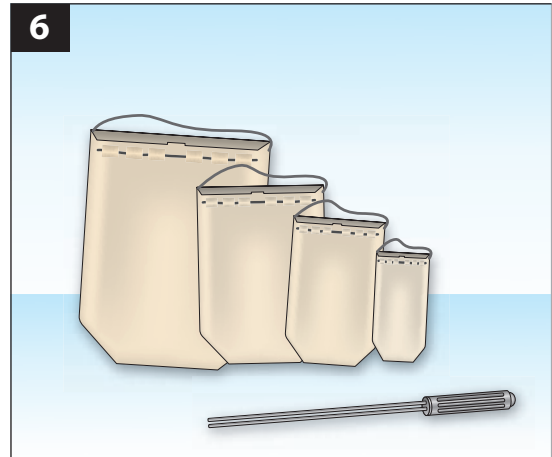
Laparoscopic cholecystectomy was the impetus behind the creation of instruments for the laparoscopic removal of tissue. Whether with a sterile condom or glove, “bagging” the gallbladder allowed the surgeon to use more traction, with less fear of rupture and spillage, to recover an enlarged specimen via a small incision. Today, the laparoscopic surgeon



may choose from numerous products designed expressly for laparoscopic tissue retrieval.

Modern retrieval systems are of varying degrees of sophistication ranging from small plastic bags to large, self-opening pouches contained within an introducer sheath. These devices must be easy to see and maneuver within the abdomen, strong, and, most importantly, impermeable to infectious or malignant tissue.

Among the simplest devices currently available for tissue removal is the Lapsac®, (Cook Women's Health, Spencer, IN, USA). Originally conceived for laparoscopic nephrectomy, this simple bag is made of nylon-reinforced polyamide with a polyurethane inner coating and comes in 50 mL, 200 mL, 750 mL and 1500 mL sizes (Figure 6). The sac is rolled and introduced through a 10-12 mm port by pushing it with a laparoscopic grasper placed through a 10-to 5 mm reducer. A specialized reusable Lapsac® Introducer may be used as well. This product is impermeable and among the strongest made, but the larger sizes can be unwieldy to manipulate intra-abdominally. Tabs at the top edges of the sac facilitate triangular opening and a polypropylene drawstring secures the specimen inside. Again, if changing to a 5 mm laparoscope for tissue retrieval, the specimen should be grasped and held so as not to lose it prior to removing the 10 mm laparoscope. Once the specimen is inside the sac, the drawstring is pulled with a grasper and brought out through the 10-12 mm port. The port is withdrawn from the abdomen and the bag edges drawn up through the skin, bringing the specimen as near to the incision as possible. The specimen can then be recovered using firm, gentle, traction. Large cystic masses can be decompressed within the bag using a suction device prior to retrieval. Larger solid masses can be carefully morcellated manually using either crushing forceps or scalpel (Figure 7). Enlargement of the umbilical incision may be required in



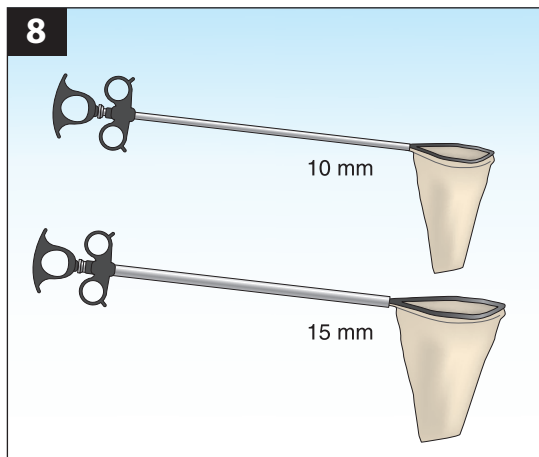
order to safely recover the specimen. Direct laparoscopic observation using a laterally placed 5 mm laparoscope facilitates difficult retrievals and helps minimize the risk of bag rupture.

The Pleatman Sac® Tissue Removal System (Gyrus ACMI, Scarborough, MA, USA) consists of a small plastic pouch at the end of a 10 mm shaft. The sac is deployed with the aid of a reusable metal obturator passed through the device's 5 mm "operative channel." The obturator is



then removed and a 5 mm grasper or other instrument passed through this channel and used to place the tissue into the pouch. The pouch is drawn up into and against the introducer and the specimen withdrawn. Although attractive in its simplicity, this system is limited by its small size and relative weakness compared to other systems. Also, it is not closeable and may be prone to spillage of tissue.

In order to overcome the inherent unwieldiness of manipulating a free-floating bag within the abdomen, two manufacturers have created integrated retrieval systems in which the bags are self-opening and, thus, more stable for easy tissue deposition. Endo Catch Gold™ (Autosuture, Inc., Norwalk, CT, USA) consists of a disposable pouch of impermeable polyurethane 15 cm deep whose mouth is 6 cm in diameter. The 10 mm instrument is introduced into the abdomen and the plunger advanced to deploy the pouch. Once the specimen is inside, the pouch is cinched closed by pulling on the green ring, and the pouch pulled slightly to free it completely from the introducer cannula. The introducer and port are then withdrawn and the string used to draw the bag edges up through the skin where the specimen can be recovered. For larger specimens, the Endo Catch II is 23 cm deep with a 12.5 cm opening and must be introduced via a 15 mm port. The Endopouch™ Retriever (Ethicon Endo-Surgery, Cincinnati, OH, USA) is a similar self-opening system that employs an impermeable 224 mL polyurethane pouch. Like the Endo Catch



products, it uses a plunger-type introducer via a 10-12 mm port (Figure 8). Both of these systems use bags of good tensile strength and provide added convenience in that they can be deployed for specimen recovery using one hand.

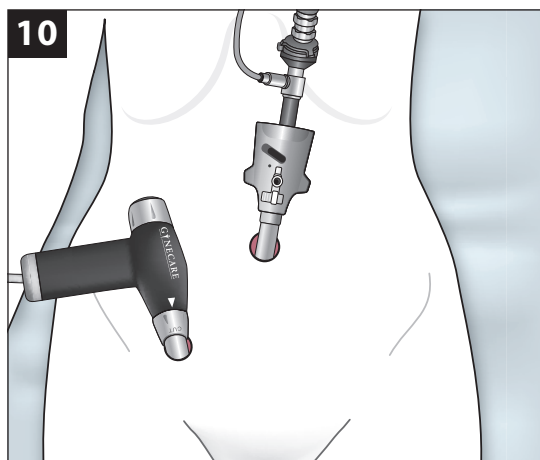
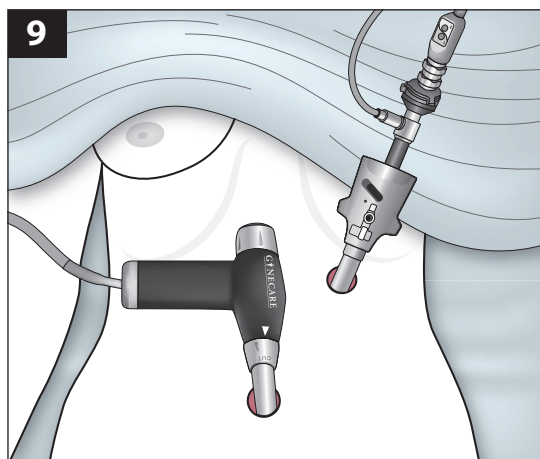
Derived from technology used to make hot air balloons, Espiner E-Sacs, (Espiner Medical Products, Clevedon, U.K.) are made using impervious polyurethane lined Nylon 66 fabric. Nylon 66 is notable for its lightness and strength. It handles well and is quite easily seen within the abdomen. The Standard E-Sac comes in sizes from 60 mL to 850 mL. It is a simple sac designed for deployment through a 10 mm sleeve for smaller (60 mL, 225 mL) sacs, and 12 mm sleeves for larger sacs (300 mL, 850 mL). Tabs on the mouth and bottom facilitate handling and opening. Like the Cook product above, it is introduced into the abdomen using a 5 mm instrument and the specimen recovered similarly. The Super E-Sac is similar to the Standard E-Sac but is larger (600 mL to 3000 mL)

and incorporates a nitinol wire into the mouth of the sac. This wire serves both to hold open the mouth of the sac and to draw it closed for tissue capture. For improved handling, the Master E-Sac (225 mL to 2000 mL) uses an introducer rod to deploy and control the sac and to close it securely around the specimen.

There are limited data comparing the handling characteristics, strength, and permeability of the systems described above. Surgeons should use clinical judgment and preference to select the product that will permit him or her to safely and most effectively recover specimens laparoscopically.

## TECHNIQUES FOR TISSUE MORCELLATION

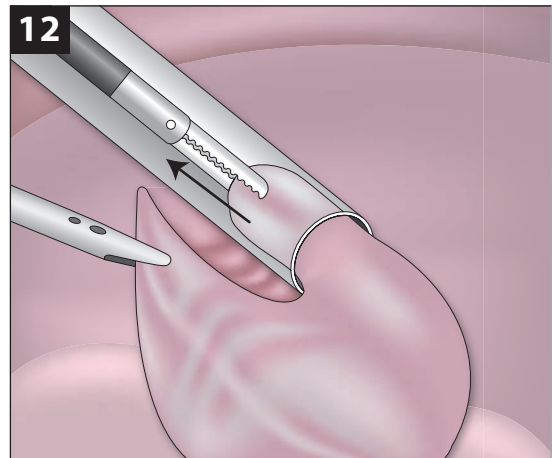
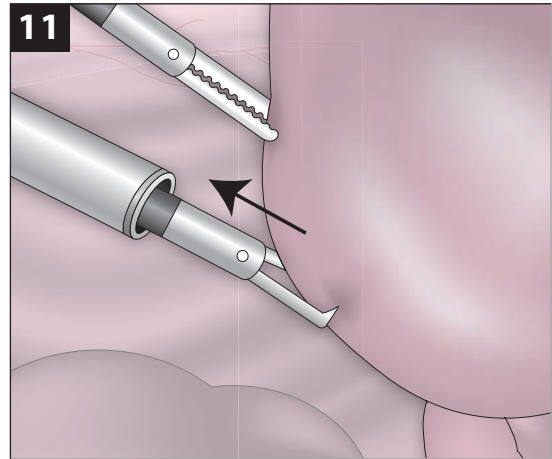
The expansion of minimally invasive surgery to include the extirpation of increasingly large organs has created the need to render masses of solid tissue into smaller pieces for endoscopic retrieval. Because morcellation involves the risk of potentially serious injury to vital structures of the abdomen and pelvis, safety is of the utmost importance. Several instruments exist to facilitate mechanical tissue morcellation. Regardless of the instrument selected for this purpose, the same fundamental techniques must be rigorously applied in order to avoid injury to the patient. First and most importantly, the morcellator must be visualized AT ALL TIMES. This is accomplished using a 5 mm laparoscope placed either through a lateral or left upper quadrant (Palmer's point) port while the morcellator is introduced through the umbilical area (Figure 9). The morcellator



can also be introduced through the low lateral abdominal port while the 10 mm laparoscope with the camera is kept in the umbilical port (Figure 10). Morcellation should be performed within the pelvis and with the patient in the steep Trendelenburg position in order to provide the activated blade with the greatest possible clearance from surrounding structures. Finally, safe technique includes using tenaculum forceps to draw the tissue into the morcellator while holding the activated

instrument motionless and distant from the bowel and pelvic sidewalls (Figure 11). The activated morcellator should NEVER be driven towards the tissue, as this creates the greatest risk of accidental injury. Ideally, the surgeon should always see the top portion of the circular blade while morcellating in order to avoid coring the specimen. When the blade begins to dive into the tissue, the surgeon should adjust the angle of the blade and redirect its upper edge to the tissue surface. If this cannot be done, the surgeon should orient the morcellator so as to sever the tissue and begin a new pass in the correct orientation. Strips of tissue which break off before fully recovered can be re-grasped at their cut end and drawn back into the morcellator. An assistant can greatly facilitate proper technique by stabilizing and guiding the specimen into the morcellator. In this way, the surgeon “skins” the specimen by removing strips of tissue from the outside edges (Figure 12) rather than creating a “swiss cheese” effect that is unsafe and makes the specimen difficult to handle. Meticulous adherence to these principles is essential to safe morcellation and enables the surgeon to recover large volumes of tissue quickly and efficiently.

Following morcellation, the surgeon should attempt to recover any and all tissue fragments. This assures that the entire specimen is sent for histologic study and helps to minimize the chance of “paracytic” growth within the abdomen of tissues such as myomas. In the case of less dense organs such as the spleen, or kidney, manual or power morcellation of the specimen within a large, impervious retrieval bag is essential to preventing ectopic tissue



implantation. Because of the risk of dissemination, tissue suspicious for malignancy should never be morcellated, but removed intact using an impermeable retrieval sac.

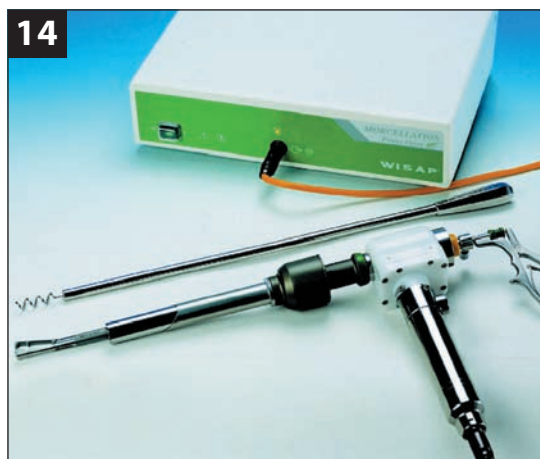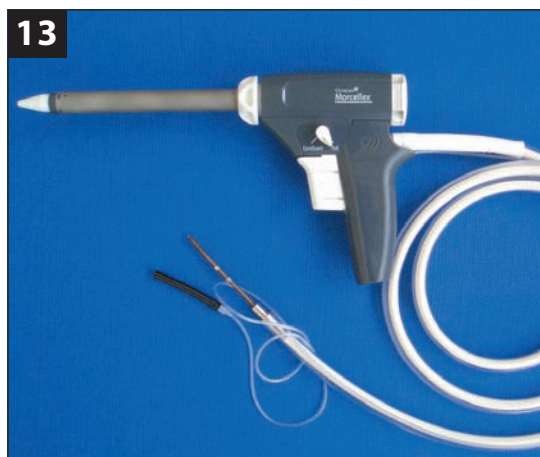
## SYSTEMS FOR TISSUE MORCELLATION

Three manufacturers currently make devices for power morcellation. All of these instruments incorporate a propri-

etary intrinsic or extrinsic motor drive unit that is used to power a rapidly rotating cylindrical blade. They differ in design characteristics and power, but function in the same manner by cutting cylindrical strips of tissue. The Gynecare X-tract™ (Ethicon Endo-Surgery, Cincinnati, OH, USA) laparoscopic morcellator is a 15 mm instrument that requires no port sleeve and employs a blunt plastic obturator for insertion into the abdomen (Figure 13). A blade guard covers the blade for abdominal entry and while the instrument is not in use. The operator may activate the unit in a simple on/off (all or none) fashion by means of a foot pedal and may select to operate the blade in a clockwise or counterclockwise direction by means of a toggle switch on the external motor drive. A pneumoseal mechanism within the instrument maintains pneumoperitoneum while preventing the backslash of tissue and blood while morcellating. The entire instrument, including the blade and power drive cable, is disposable.

The S\*E\*M\*M\* (Serrated Edge Macro Morcellator) laparoscopic tissue morcellators from Wisap (Munich, Germany) are available as manual (Manual-Drive™), externally driven (Power-Drive™) or battery powered, internally driven units (Moto-Drive™). All units have their own metal operative sleeves and obturators and each accepts 10 mm, 15 mm, 20 mm, and 24 mm serrated blades (Figure 14). All instruments may be sterilized and are fully reusable.

The Rotocut™ G1 (Karl Storz GmbH & Co. KG, Tuttlingen, Germany) represents the newest generation of morcellators



(Figure 15). This instrument is notable for its power and versatility due to an internal hollow shaft motor unit that interchangeably accepts both 12 mm and 15 mm blades. It requires no port sleeve and is introduced into the abdomen using a blunt metal obturator. The instrument incorporates a metal sleeve whose tip is obliquely shaped and designed to facilitate proper specimen “skinning” technique while protecting surrounding structures. The system is activated by means of a foot pedal and is unique in that an external microcontroller unit (Unidrive™ Gyn) allows the operator to vary the blade speed (not unlike the “gas pedal” of an automobile) for the efficient morcellation of tissues of different densities. The unit and its parts are fully autoclavable and its blades reusable.

For all of these units, blade sharpness is essential to efficient tissue cutting and directly related to the time needed to

morcellate a large specimen. Therefore, it is important to ensure that the jaws of the tenaculum forceps are completely closed on the tissue when drawing it into the morcellator so that the activated blade is not damaged by contact with metal instrument.

## SUMMARY

Mastery of the different methods and systems for laparoscopic tissue retrieval is essential to the safe and successful practice of advanced laparo-endoscopic surgery. The surgeon should take the time to become familiar with the different products available for this purpose and employ those that consistently perform well in a variety of operative circumstances. Patient safety and respect for oncologic principles are of paramount importance when laparoscopically retrieving any tissue specimen.

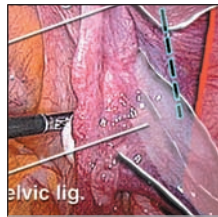
---

SUGGESTED READING:

Miller CE. Methods of tissue extraction in advanced laparoscopy.  
Current Opinion Obstet Gynecol 2001;13(4):399-405



# RETROPERITONEAL DISSECTION OF THE PELVIC SIDEWALL FOR BENIGN DISEASE



*Grace M. Janik, M.D.*

**M**any gynecologists use a procedure-based approach to benign gynecologic surgery with limited use of pelvic anatomy. While many operations can be performed safely by this method, surgical skills often plateau before the surgeon has the ability to confidently manage complex pathology with minimal complications. An anatomic surgical approach puts emphasis on using fixed anatomic landmarks in the pelvis to safely dissect and identify vital structures from areolar connective tissue and pathology. The vital structures of the pelvis are primarily located in the retroperitoneal space of the pelvic sidewall. Once they are located, the remainder of the operation becomes relatively straightforward and safe, enabling successful completion of complex surgical procedures such as peritoneal resection of cul de sac endometriosis, adhesiolysis of severe adnexal adhesions or remnant ovary, sacrocolpopexy, and laparoscopic hysterectomy of large uterus.

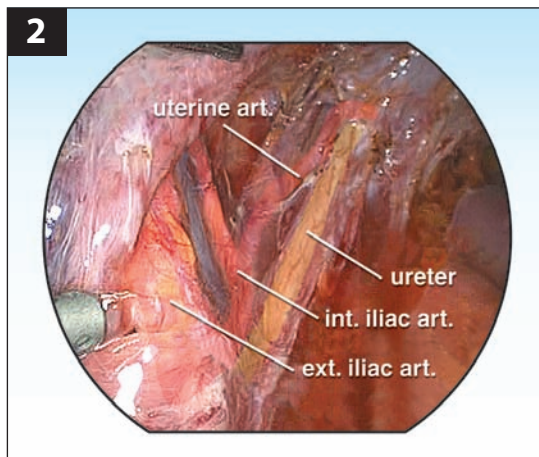
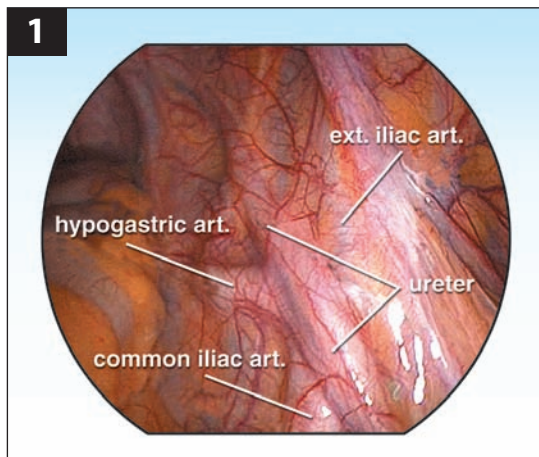
## LAPAROSCOPIC SURGICAL ANATOMY

Anatomy is a constant, but its appearance varies based on how it is visualized and approached. Laparoscopy offers some distinct advantages



in identifying anatomy during retroperitoneal dissection of the pelvic sidewall and cul de sac, areas which are particularly difficult to visualize while performing a laparotomy. During laparoscopy, the continuous illumination and magnification enables detailed identification and microdissection of tissue planes and vital structures. Visualization is further enhanced by the pneumoperitoneum which reduces bleeding during dissection and improves avascular dissection. The disadvantages of laparoscopy are the fixed visual angles and the conversion of a three dimensional pelvis to a two dimensional image. While these limitations may prolong the learning curve of laparoscopy, they do not negate its significant advantages in retroperitoneal dissection.

Surgical anatomy emphasizes the clinically relevant aspects of anatomy that are essential for safe, efficient surgery. Knowledge of the anatomy of the pelvic brim and the three levels of the pelvic sidewall are required for retroperitoneal dissection (Chapter 2). Special emphasis should be placed on the ureter as it is the most frequently injured structure in gynecological surgery. A firm understanding of the ureter's path through the pelvis to the bladder is critical, especially its relationship to the pelvic vasculature. The ureter enters the pelvic cavity at the pelvic brim by crossing anterior to the bifurcation of the common iliac artery and just below the ovarian vessels of the infundibulopelvic ligament. The right ureter usually crosses over the external iliac whereas the left ureter tends to run more medial and crosses over the common iliac. The anat-



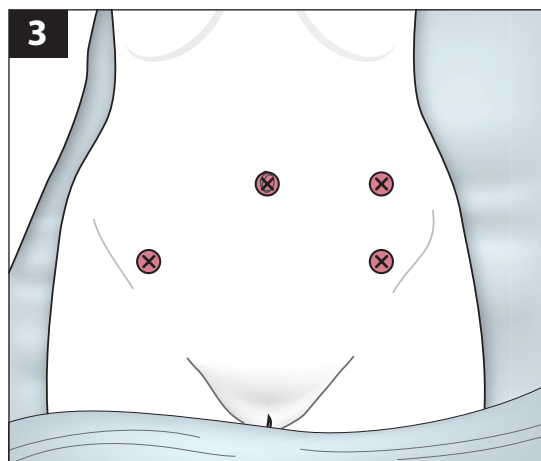
my at the pelvic brim pushes the ureter anteriorly with minimal connective tissue between the ureter and peritoneum making this the most consistent location for identification of the ureter, particularly with severe pelvic disease or obesity (Figure 1). The ureter then courses in the medial leaf of the broad ligament towards the bladder, entering the cardinal ligament approximately 2 cm medial to the ischial spine and 2 cm lateral to uterosacral ligament. The hypogastric artery and upper uterine artery run parallel, lateral and

deep to the ureter until the uterine artery crosses over the ureter at the base of the broad ligament (Figure 2). The ureter will then enter the ureteric tunnel in the vesicocervical ligament bending abruptly anteriorly and medially for the final 1-2 cm of the ureter called the “knee.”

While the anatomic relationship between the ureter and the pelvic vessels is the corner stone of pelvic sidewall dissection, it is important to remember that there is a significant rate of urinary and vascular anomalies in the retroperitoneum: 1.6% and 13.6%, respectively. Dissection of avascular tissue planes should proceed bluntly with careful exposure of structures encountered to avoid injury of vascular and renal anomalies.

## SURGICAL TECHNIQUE

There are two main approaches for retroperitoneal resection of the pelvic sidewall: the medial approach and the lateral approach. The lateral approach is most commonly used in gynecologic oncology for lymph node dissection (Chapter 32). It can also be useful in benign surgery when the primary objective is isolating the uterine artery for laparoscopic uterine artery occlusion or hysterectomy. The medial approach is most useful for the majority of benign gynecologic pathology as the peritoneum of the ovarian fossa is commonly involved in the disease process (i.e. adnexal adhesions, endometriosis). The medial approach is also advantageous because below the pelvic brim, the main blood flow to the ureter is lateral. Both approaches require a responsive uterine



manipulator to be able to achieve extreme anteversion. We prefer a RUMI manipulator by Cooper Surgical, (Trumbull, CT). Lateral port placement of the secondary trocars is optimal to achieve a useful angle to the pelvis and maximize the stability of the surgeon who uses two lateral ports on one side. The lower ports are placed 1-2 cm superior and lateral to the anterior superior iliac spine. The upper port is placed at the same level lateral at the periumbilical level (Figure 3).

## THE MEDIAL APPROACH

### 1. RESTORE NORMAL ANATOMIC RELATIONSHIPS

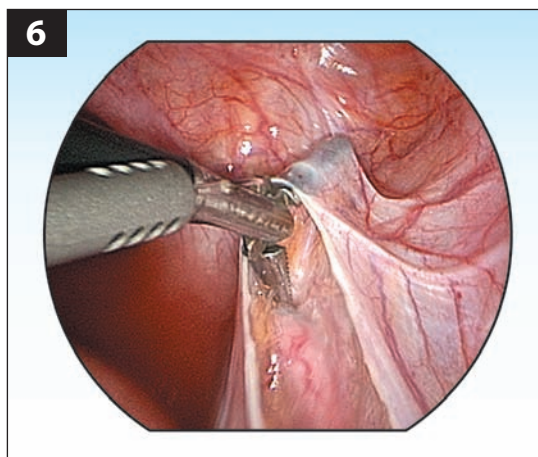
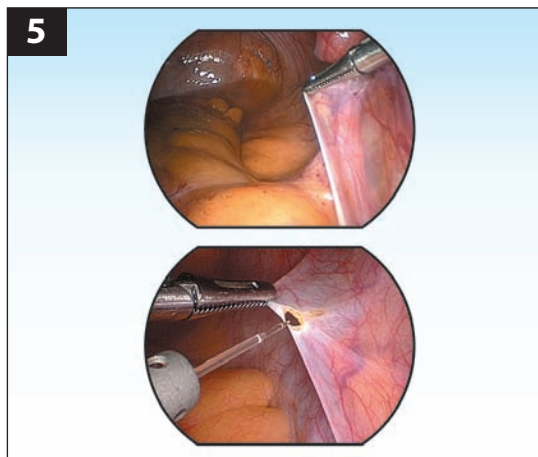
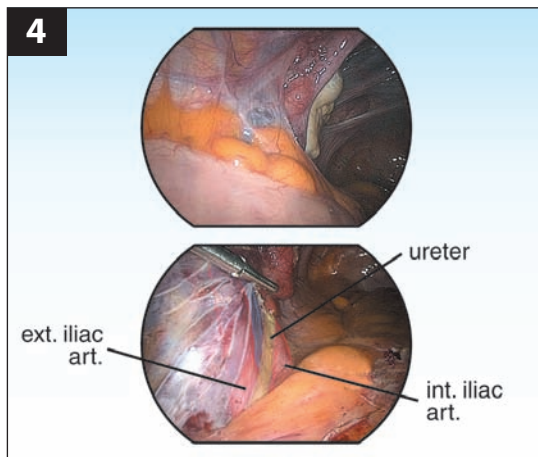
The approach to a grossly distorted pelvis begins with the restoration of normal anatomic relationships of organs adherent to the pelvis such as omentum and bowel. This is accomplished by blunt and sharp dissections depending on the density of the adhesions. Adhesiolysis of dense adhesions to the cul-de-sac and sidewall should not be addressed at this time.

## 2. IDENTIFICATION OF THE URETER

The ureter must be identified before surgery in the ovarian fossa or cul de sac is initiated. Identification of the ureter along the pelvic sidewall can be attempted but if unsuccessful, attention should be directed to the pelvic brim where consistent identification is possible as the ureter crosses over the bifurcation of the common iliac artery (Figure 1). Identification can be confirmed by grasping the suspected location of the ureter with an atraumatic grasper to stimulate peristalsis. The left ureter may require mobilization of the sigmoid mesentery from the abdominal sidewall to gain access to the pelvic brim (Figure 4).

## 3. URETEROLYSIS

Once the ureter is identified, it can be traced caudally until the pathology begins or the ureter is no longer visible. Just before this point, the peritoneum directly over the ureter is grasped and excised (Figure 5). CO<sub>2</sub> gas will quickly enter the retroperitoneal space aiding in further dissection. The frequent peristalsis of the ureter within the loose retroperitoneal connective tissue creates a pseudosheath around the ureter. Ureterolysis can be continued down to the level of the uterine artery by placing a grasper along the medial aspect of the ureter in the pseudosheath and dividing the overlying peritoneum (Figure 6). As the ureter approaches the uterine artery, the ureter will start to travel more posteriorly in relationship to the peritoneum. The depth of the pathology determines how close the



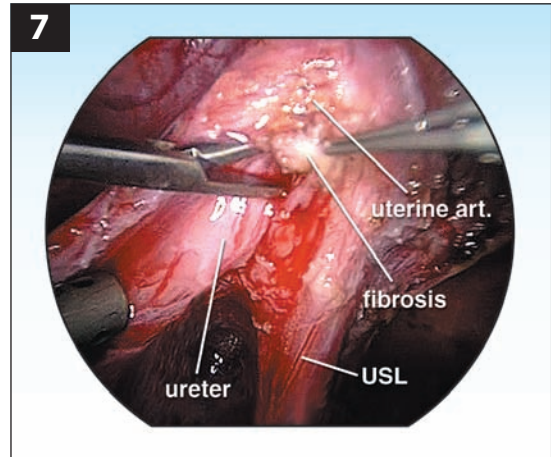
dissection needs to be to the ureter. It is possible to dissect through the deepest layers of pseudosheath using a micro-grasper to perform ureterolysis directly along the adventitia liberating even deep fibrotic endometriosis that is responsible for hydroureter (Figure 7).

#### 4. PATHOLOGY DIRECTED DISSECTION

After the ureters have been isolated, many operations can proceed without any further retroperitoneal dissection such as hysterectomy, lysis of adnexal adhesions, oophorectomy, and peritoneal resection of endometriosis provided that the pathology does not extend past the first layer of the pelvis. In some cases it may become necessary to extend the dissection to isolate the internal iliac artery and uterine artery. Following peritoneal resection in the ovarian fossa, the areolar spaces around the vessels can be easily dissected using blunt dissection isolating the vessels from the pathology (Figure 2). Inadvertent injury to the vessels is rare, but if it occurs, it is important to grasp the vessel with an atraumatic grasper to control the bleeding, then confirm the location of the previously dissected ureter before coagulating or ligating the vessel.

#### 5. EXTENDING THE PELVIC SIDEWALL DISSECTION TO UTEROSACRAL LIGAMENTS AND RECTOVAGINAL SPACE

If there is disease invading the uterosacral ligaments or cul-de-sac, the rectovaginal space can be opened after ureterolysis. The lateral pararectal space



is between the ureter and the uterosacral ligament. It is avascular with no vital structures; resection in this area can proceed confidently. Mild bleeding may be encountered at the posterior lateral aspect of the uterosacral ligament which is easily managed with bipolar cautery. The medial pararectal space is the area between the uterosacral ligament and rectum. Care must be taken when operating in this area because of the mesenteric vessels present in the perirectal fat. Dissection in this area can be aided by a rectal probe or a ring forceps in the rectum. The rectovaginal space is the large cavernous potential space between the rectum and posterior vagina. The ability to open this space is essential for pelvic reconstructive surgery and management of cul de sac endometriosis. The best place to enter the rectovaginal space is in the perirectal fat just medial to the attachment of the uterosacral ligament. If the ligament has not been transected, the peritoneum is incised. A blunt grasper is placed in the perirectal fat just medial to the uterosacral ligament, using blunt dis-

section parallel to the vagina opening the rectovaginal space (Figure 8). The space is expanded further by extending the lateral perirectal entry spaces medially using blunt dissection and dividing the medial peritoneum (Figure 9). Once the space is open, further surgery can proceed such as pelvic reconstruction or resection of endometriosis from the rectum or vagina (Figure 10).

## LATERAL APPROACH

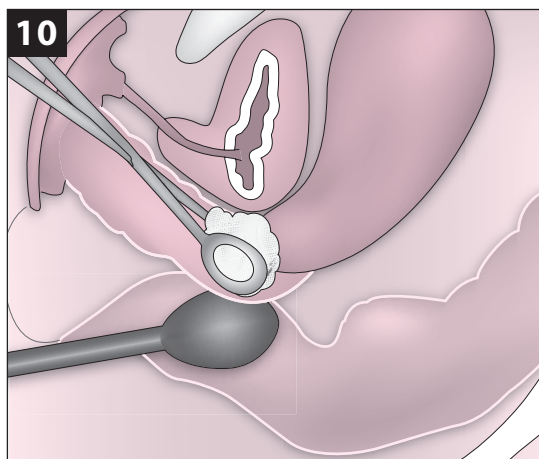
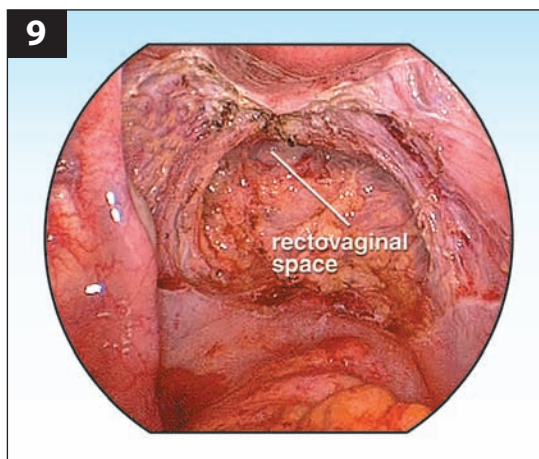
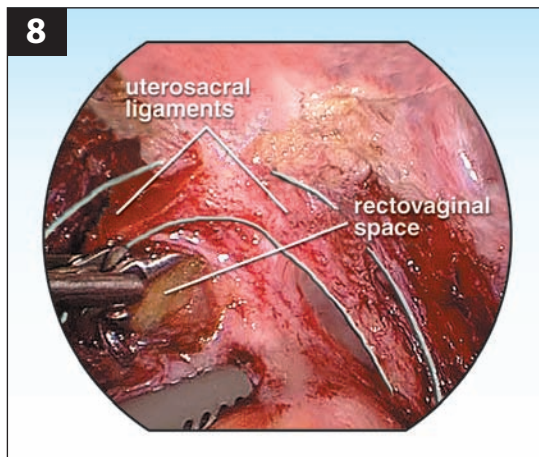
The lateral approach for pelvic sidewall dissection is described in detail for pelvic lymphadenectomy (Chapter 32). Summary of the key steps in the lateral approach for benign disease are as follows.

### 1. PERITONEAL INCISION AT THE PELVIC SIDEWALL TRIANGLE

The uterus is placed on contralateral traction exposing the triangle of the lateral broad ligament, created by the round ligament, the external iliac, and the infundibulopelvic ligament. An incision is made from the base of the triangle (the round ligament) to the apex (the junction of the external iliac and infundibulopelvic ligament) (Figure 11). It is important that the incision be extended sufficiently cephalad to enable adequate medial mobilization of the infundibulopelvic ligament and ureter.

### 2. DISSECTION OF PARAVESICAL SPACE AND IDENTIFICATION OF THE URETER

Using blunt dissection, the avascular paravesical space is dissected. The



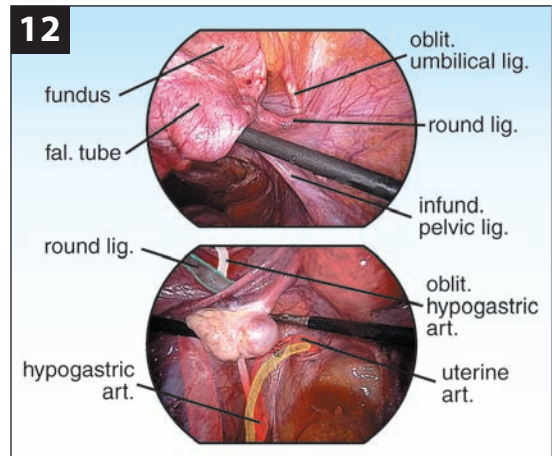
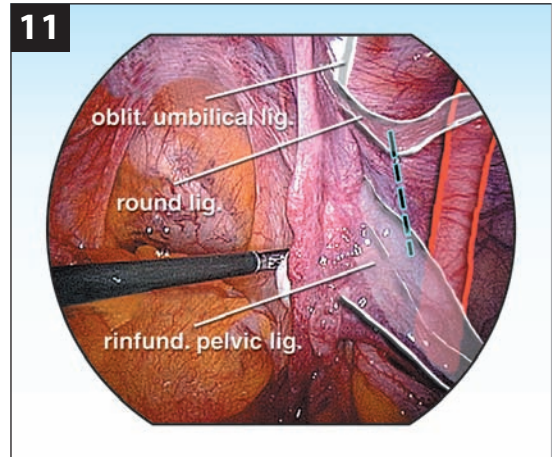
infundibulopelvic ligament and ureter are retracted medially. The attachment of the ureter to the medial leaf of the broad ligament is left intact and the ureter is identified laterally. The identification may need to begin at the apex where the ureter crosses the common iliac artery. Care must be taken to minimize dissection lateral to the obliterated hypogastric artery as the external iliac vein is medial to the external iliac artery.

### 3. IDENTIFICATION OF THE UTERINE ARTERY

Locating the uterine artery can be accomplished by identification of the obliterated hypogastric artery on the anterior abdominal wall (Figure 12 ) and tracing it retrograde to the uterine artery. The uterine artery can be ligated before it crosses the ureter. Pulling on the obliterated umbilical ligament can aid in identification.

### ENDOMETRIOSIS

In no other gynecologic disease is adherence to a surgical anatomic approach more vital than in severe endometriosis. The cul-de-sac and ovary are the most frequently involved areas of endometriosis. Deep fibrotic endometriosis can cause dense adhesions, grossly distorting pelvic anatomy. The peritoneum can be severely thickened and fibrotic making visualization and palpation of vital structures problematic. Fortunately, even in the most severe cases, dissection down to normal connective tissue planes and liberation of vital structures from fibrotic endometriosis

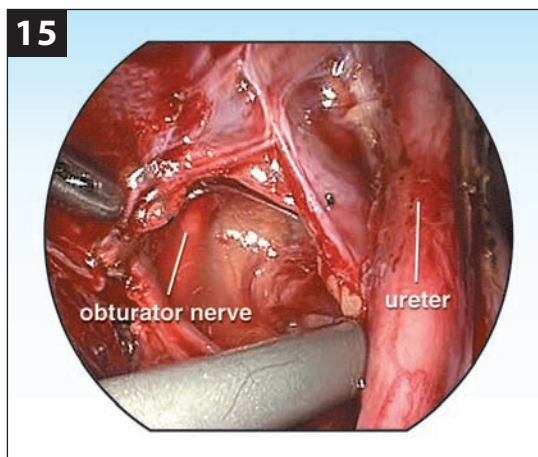
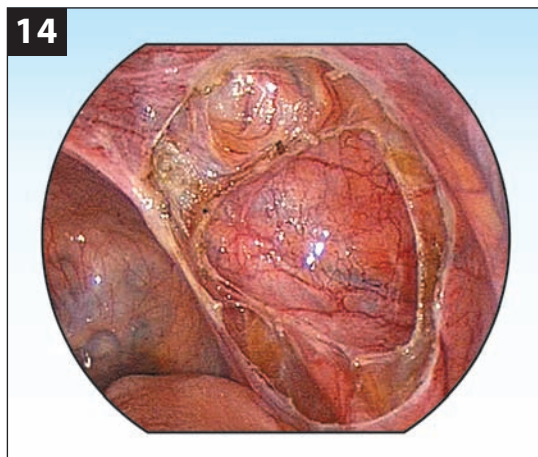
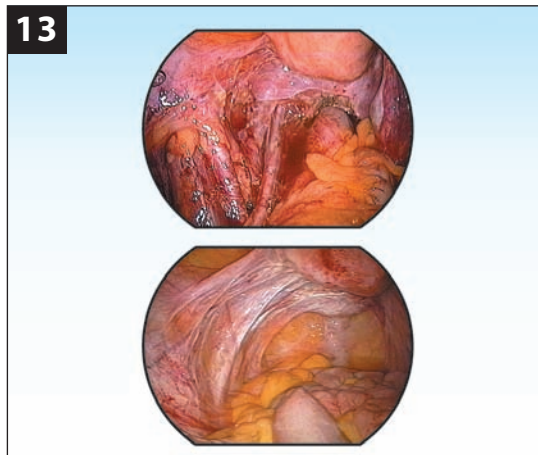


is possible by following the steps for the medial approach to retroperitoneal dissection.

Peritoneal resection of endometriosis is a surgical approach for treatment of endometriosis where all peritoneum with endometriosis is completely resected down to disease free connective tissue. New peritoneum, free of endometriosis, will generate in 2-3 days with minimal de novo adhesion formation (Figure 13). Even though peritoneal resection of endometriosis can be surgically challeng-

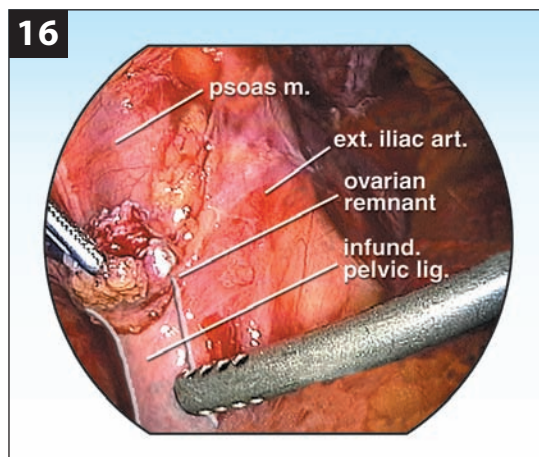
ing, results for both pain control and fertility are encouraging. Long term pain studies show over 80% of patients are pain free or pain controlled. Fertility rates as high as 68% have been reported for severe endometriosis. Even in cases of extensive cul de sac endometriosis requiring bowel resection, a 48% pregnancy rate can be achieved.

The surgical steps in peritoneal resection of endometriosis begin with a careful inspection of the pelvis to identify all areas of peritoneal endometriosis before the peritoneum is distorted by surgical echymosis. Close magnification and irrigation help identify more subtle lesions. Peritoneal windows are usually indicative of endometriosis especially at the base of the pocket which can extend deep into the pelvic sidewall. After all areas of endometriosis have been mapped out, the steps for the medial approach to retroperitoneal resection of the sidewall are initiated. Once the vital structures are isolated, en bloc resection is performed by circumscribing the peritoneum around the lesions, leaving a disease free-margin (Figure 14). The circumscribed peritoneum is then dissected from the underlying connective tissue. This technique is the same for both superficial and deep lesions. Endometriosis may invade so deeply that dissection may need to be extended to the third layer of the pelvis isolating the obturator nerve and vasculature (Figure 15). In extreme circumstances, deep infiltrating endometriosis can be invasive to the bowel, bladder, vagina, or ureter requiring resection and repair of these organs.



## RETROPERITONEAL OVARY

Pelvic sidewall dissection is central to both the prevention and treatment of retroperitoneal ovaries. The retroperitoneal ovary has two subcategories: residual ovarian syndrome and ovarian remnant syndrome. In residual ovarian syndrome, the ovary becomes encapsulated by adhesions secondary to previous surgery or pathologic process such as endometriosis or pelvic inflammatory disease. Ovarian remnant syndrome is ovarian tissue persistent after oophorectomy. The main etiology is incomplete removal of the ovary, usually at the infundibulopelvic ligament or residual cortex adherent to the pelvic sidewall. Other proposed mechanisms are seeding during oophorectomy with fragment reattachment, or accessory ovaries. Predisposing factors to ovarian remnant syndrome are ovarian enlargement, periovarian adhesions, multiple previous surgeries, and most importantly a history of endometriosis present in over 50% of cases. Adequate retroperitoneal dissection of the sidewall during these cases may reduce the incidence of ovarian remnant syndrome. Treatment of ovarian remnant can be difficult due to adhesions and distorted anatomy. Retroperitoneal dissection with identification of landmarks and vital structures enables location and removal of residual ovarian tissue (Figure 16). The recurrence of ovarian remnant has been reported as 8-20% but many of these cases were by laparotomy. The largest laparoscopic series by Nezhat, reported an 8% recurrence rate. Complication rates in the



literature range from 3-33% with 5.8% reported in Nezhat's laparoscopic series.

## COMPLICATIONS

The prime objective of retroperitoneal dissection of the pelvic sidewall is to reduce complications during difficult surgery with complex pathology. Even with a thorough understanding or surgical anatomy and meticulous dissection technique, the surgeon must be prepared to encounter surgical complications. It is important to control bleeding with pressure and evaluate the surrounding anatomy before coagulating the vessel. Pre-planning consultations with urology, general, and vascular surgeons can be helpful in formulating a detailed management plan for repair of injuries even before they occur. Many complications can be safely managed laparoscopically if suturing skills are solid and the same standards as open surgery are maintained.



## SUGGESTED READING:

Benedetti-Panici, P, Maneschi F, Scambia G, et al. Anatomic abnormalities of the retroperitoneum encountered during aortic and pelvic lymphadenectomy. *Am J Obstet Gynecol* 1994;170(1 pt 1):111-6

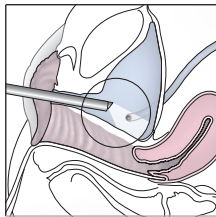
Jain N. State of the art atlas of endoscopic surgery in infertility and gynecology; In: *Laparoscopic Retroperitoneal Anatomy*. Nezhat F, Tzitzimikas S, Yadov J (eds.). Jaypee Brothers Medical Publishers Ltd. 2004

Kadar N. *Atlas of Laparoscopic Anatomy*. Blackwell Science Ltd. Oxford, England 1995

Koh CH, Janik GM. The surgical management of deep rectovaginal endometriosis. *Curr Opin Obstet Gynecol*. 2002;14(4):357-64

Nezhat C, Kearney S, Malik S, Nezhat C, Nezhat F. Laparoscopic management of ovarian remnant. *Fertil Steril*. 2005;83(4):973-8

# LOWER URINARY TRACT ENDOSCOPY



*Sam H. Hessami, M.D.*

*David Shin, M.D.*

## INTRODUCTION

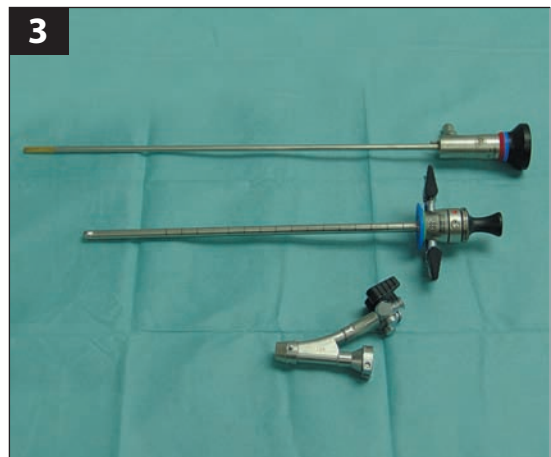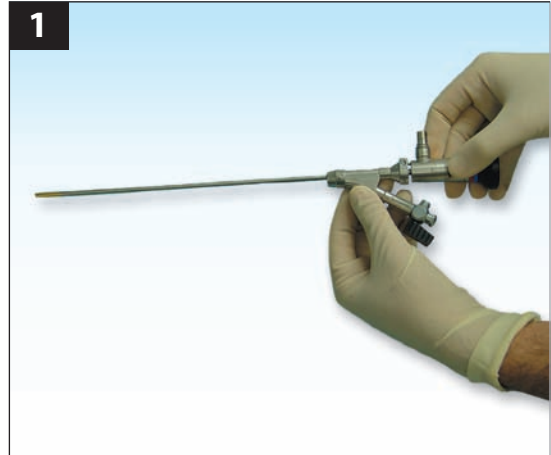**G**ynecologists have not been traditionally trained in performing endoscopy of the lower urinary tract. Cystourethroscopy, when compared to hysteroscopy and laparoscopy, is one of the simpler procedures to teach and to learn. Medically speaking, given the close proximity of the genital organs to the urinary tracts, it is necessary for gynecologists to ensure the intactness of the urinary system after complicated pelvic procedures. Although the benefits of the routine use of cystoscopy after certain gynecologic procedures such as vaginal hysterectomy has been debated, there is no question that with advances in pelvic reconstructive surgery and the use of synthetic and non-synthetic grafts, it is incumbent on every surgeon to ensure intactness of the urinary tract. Failure to identify iatrogenic injuries intraoperatively will have life changing and catastrophic sequelae for the patient. More complex vaginal procedures, such as those for advanced pelvic organ prolapse, where the ureters are at greatest risk for injury, also dictate routine cystoscopic evaluation at the end of the procedure.

The surgeon must be familiar with the different equipment and choose the best for the application since there are multitudes of endoscopes and lenses currently available on the market. In this chapter we will focus on diagnostic cystoscopy only.

## EQUIPMENT

### ROD-LENS ENDOSCOPES

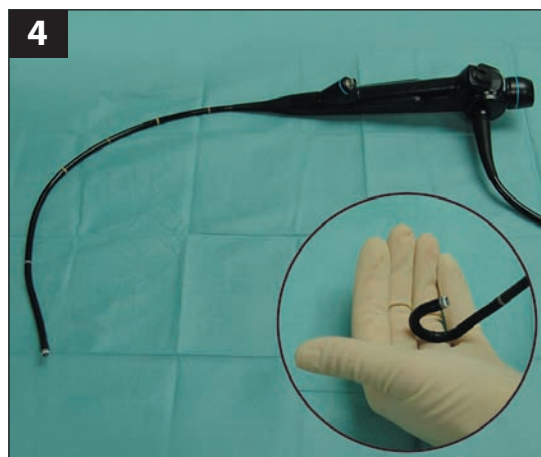There are two types of endoscopes available on the market: rod-lens versus fiberoptic. Rod-lens endoscopes, familiar to all laparoscopists, are also known as rigid scopes. They are stiff, rod-shaped instruments with a cylindrical lens where the angles of deflection range from  $0^\circ$  to  $120^\circ$  ( $0^\circ$ ,  $30^\circ$ ,  $70^\circ$ ,  $90^\circ$ ,  $120^\circ$ ), depending on the specific use. The rigid cystoscope must be attached to a bridge and then passed through a sheath before it can be inserted (Figure 1). The bridge will allow for attachment of the telescope to the sheath as well as the passage of instruments through its working channels, in case of operative cystoscopy. The sheath is used for atraumatic passage of the telescope into the urethra and then bladder (Figure 2). The rigid endoscopes measure 4 mm in diameter and the cystoscopic sheath ranges in diameters from 17Fr to 25Fr (Figure 3). In general, a 17Fr sheath is all that is required for diagnostic cystoscopy. Keep in mind that an adult female urethra measures 4 mm in diameter, and thus a 17Fr-sheath is easily tolerated by patients even in an office setting with minimal use of a topical anesthetic gel (1Fr. = 3 mm). Larger caliber sheaths



are needed to allow for passage of instruments in cases of operative cystoscopy. It is important to understand the differences and benefits of different objective lenses. The 0°-lens is used for urethroscopy. Even though a 30°-lens also can be used for this purpose, it is not the lens of choice. A 30°-lens is most suited for abdominal telescopy, allowing for the visualization of both ureteral orifices. It is also used for transurethral inspection of the bladder and ureteral orifices. For diagnostic purposes, a 70°-lens is preferred, as it allows for inspection of the ureteral orifices as well as bladder side walls and dome with minimal need for rotation and movement of the endoscope, thus resulting in conservation of movement and better tolerance by patients in an outpatient setting with topical use of anesthesia. Rigid scopes are sturdy, resulting in excellent longevity. They are the easiest to operate, and more readily available when compared to flexible scopes. Their obvious limitation is their stiffness and lack of flexibility, which results in their inability to inspect the anterior bladder neck.

## FLEXIBLE ENDOSCOPES

The flexible cystoscopes contain fiberoptic bundles, which with the advancement in technology, can now offer excellent images, but are still fragile. Their flexibility allows for a more comprehensive inspection of the bladder. A specific mechanical property of these devices, secondary deflection, allows for it to be retroflexed so that the



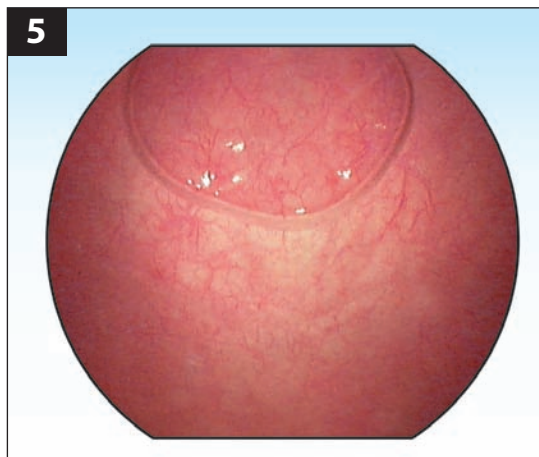
bladder neck and the trigone can be easily inspected (Figure 4). The smallest size flexible cystoscope comes in 16Fr easily tolerated by patients and smaller than the 17Fr rigid cystoscope sheath, the smallest diameter adult sheath. Flexible cystoscopes do not require a bridge or a sheath. Technically speaking, flexible cystoscopes are harder to master and also require careful handling due to their fragile nature.

## CYSTOSCOPIC TECHNIQUE

The endoscopic inspection of the lower urinary tract must be systematic, beginning with the urethra. Prior to the procedure, the patient is prepped with an antiseptic solution. The bladder is drained, as concentrated urine will interfere with the clarity of the image. About 5 cc to 10 cc of xylocaine jelly (Urojet 2%) are then injected transurethrally, while the cystoscope is being assembled. Sterile water or normal saline can both be used as irrigation for a diagnostic cys-

toscopy. If electrocautery is planned, solutions containing electrolytes must be avoided. When using a rigid scope, first attach the bridge to the scope. Then pass the cystoscope, with the bridge attached, through the sheath. The light stump and the deflection on the sheath should both be pointing upward to 12 o'clock. In order to conserve movements, the light handle should be used to manipulate the cystoscope as opposed to the actual rotation of the cystoscope. The water tubing is then connected next to the bridge. The water tubing does not need to be primed. This is to allow for the passage of air into the bladder, and for identification of the bladder dome by visualization of the air bubble (Figure 5). This will also confirm the integrity of the bladder as the bubble will escape from a perforated bladder. The laparoscopic camera should be held in upward position with the nondominant hand and the cystoscope can be directed by holding and rotating the light cable in the dominant hand. The bladder should be filled with 200 cc of medium to allow for adequate distention of the bladder walls. Keep in mind that over inflating the bladder will make it difficult to see the ureteral orifices, while under inflation will leave mucosal folds intact, resulting in inadequate inspection.

Upon insertion of a well lubricated cystoscope, the urethra is inspected first. This should be done while the distending medium is flowing, thus allowing for the urethra to remain open. Upon entry into the bladder, and after adequate volume is instilled, a systematic inspection is performed.



After inserting the cystoscope, the light cord assists in orienting the lens as the operator inspects the trigone, the ureteric orifices, and the bladder walls. The cystoscope lens is always directed opposite from the light cord insertion.

First the bladder floor is inspected. This is where the interureteric ridge, just inside the bladder neck and along the trigone, is identified. A few centimeters lateral to the center of this ridge, the ureteral orifices are located. The ureteric orifices are located below the urethra and cannot be visualized with the  $0^{\circ}$  scope. Therefore, the operator should use a  $70^{\circ}$  scope to visualize the orifices. In order to visualize the patient's right orifice, the camera should be raised and moved toward the patient's left leg pointing the tip of the cystoscope down toward the patient's right orifice. The camera should always be kept in the upright position! The light cord should be rotated  $45^{\circ}$  clockwise pointing the  $70^{\circ}$  lens toward the patient's right side until the orifice is found (Figure 6). In order to visualize the

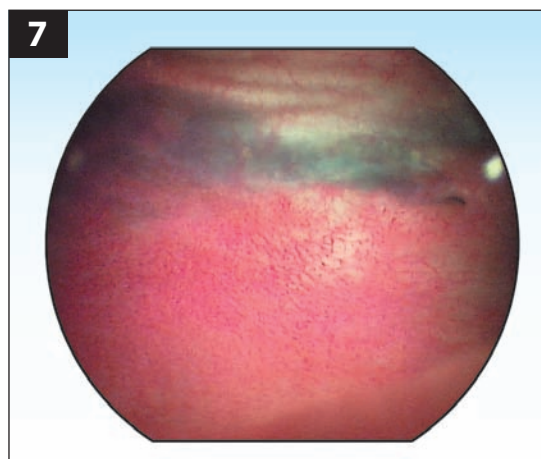
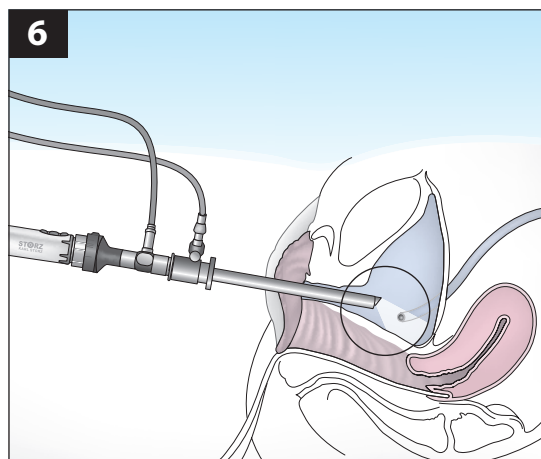
left orifice, the camera should be held in the upright position and moved toward the patient's right leg changing the axes of the scope, and pointing the tip of the cystoscope toward the left orifice. The light cord should be rotated counter-clockwise until the left orifice is visualized. Laterally, on either side of the ureteral orifices, short ridges can be also identified, representing the most distal segment of ureters running intramurally through the bladder wall. The imaginary lines connecting the urethral opening to the two ureteral orifices, and the interureteral ridge form the three borders of the triangle of the trigone (Figure 7). The trigone is the most dependent and, therefore, the least forgiving part of the bladder in case of injuries. Injuries to this region are at high risk to fistulize despite adequate repair.

Indigo carmine may be administered intravenously approximately 2 to 3 minutes prior to performing a cystoscopy. Indigo carmine allows for the clear visualization of both ureteric orifices as it causes the urine to turn blue.

After visualization of both ureteral ostia, the lateral walls and the bladder dome are inspected next. The camera is kept steady in the upright position and the light cable is rotated downward pointing the tip of the cystoscope toward the bladder dome and the rest of the bladder is inspected.

The anterior bladder wall is inspected last. This can be accomplished with a 90° or 120° telescope only.

Alternatively a flexible cystoscope can be used. Flexible cystoscopes are han-



dled slightly differently. The tip of the scope is deflected up and down to inspect the entire bladder cavity. In general, as with rigid scopes, the trigone and the ureteral orifices are inspected first, followed by bladder walls, and then the dome of the bladder. The collection of air bubbles here serves as a consistent landmark, and also ensures intactness of the bladder. The secondary deflection property of flexible cystoscopes will allow it to retroflex and thus be capable of inspecting the bladder neck and the ante-

rior wall, something that is not easily accomplished with rigid scopes. Flexible cystoscopes also have a working channel allowing for passage of instruments for tissue sampling and coagulation.

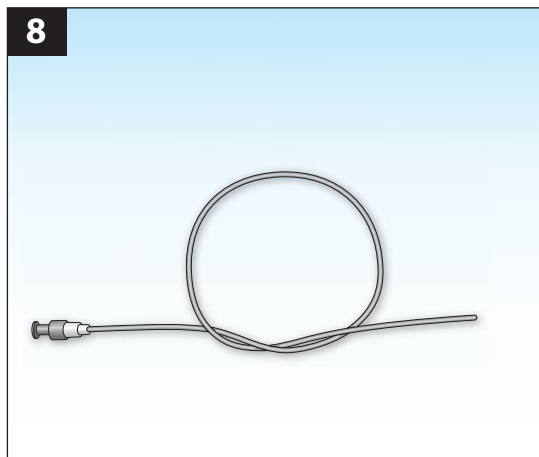
## URETERAL STENT

### INDICATION

Ureteral stents are commonly placed to relieve obstruction within the urinary tract whether it is extrinsic compression on the ureter due to malignancy or internal blockage within the ureter due to stones. Ureteral stents are also placed if suspected injury to the ureter has occurred during pelvic surgery. Intraoperative urology consultation is usually advised for these situations. However, if an urologist is not immediately available, then the surgeon needs to perform diagnostic tests to determine if an injury to the ureter has occurred and whether or not a temporary stent can be placed to divert urine into the bladder.

### TECHNIQUE

A 22Fr- or 23Fr-rigid cystoscope is inserted through the urethra and advanced into the bladder to allow better visualization of the bladder and to provide a larger working channel to pass instruments. As previously noted, a 30°-lens is used to visualize the trigone and ureteral orifices. Attention is then turned towards the ureteral orifice where the suspected injury may have occurred. An 8Fr cone-tipped catheter (Figure 8) is introduced

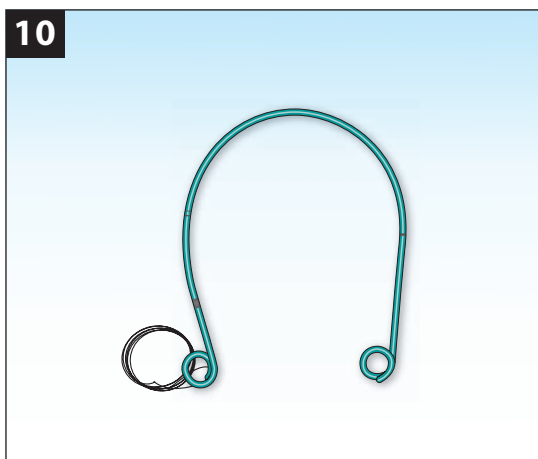


through a working channel on the cystoscope and advanced within the cystoscope sheath until the cone tip is visualized. The cone tip is then advanced gently up to and into the ureteral orifice causing temporary occlusion. Using a 10 cc syringe connected to the 8Fr cone-tipped catheter, a 50:50 mixture of Renografin contrast and normal saline is injected into the catheter to perform the retrograde pyelogram. Under direct radiographic visualization, the dye should be seen to freely flow up the ureter and into the kidney without extravasation or blockage.

If extravasation of contrast is seen anywhere along the ureter, then one has to suspect that patency of the ureter has been compromised. At this point, a ureteral stent should be placed to promote healing and prevent further damage to the ureter. Therefore, the 8Fr cone-tipped catheter is removed. A 0.035 in (2.7Fr) straight-tipped, stainless steel, polytetrafluoroethylene-coated guide wire (Cook Standard PTFE coated # 635413) (Figure 9) is introduced through

a working channel on the cystoscope and advanced within the cystoscope sheath until it is visualized. Once the tip of the guide wire is seen, it is placed into the opening of the ureteral orifice and passed up the ureter into the kidney. The surgeon should encounter minimal resistance as the guide wire is advanced up the ureter. Placement of the wire is then confirmed by radiography. This confirmation is very important to ensure that the guide wire is within the urinary tract and did not migrate into the retroperitoneum.

After confirmation of placement, the surgeon has to choose the appropriate ureteral stent. The most common stent placed has both a proximal and distal coil (double J or pigtail), which decreases the probability of migration out of the kidney or bladder (Figure 10). The length of the stent (the distance between the two pigtails) varies between 8 cm and 32 cm. The length choice by the surgeon will be dependent upon the patient's height. For example, the typical stent placed is a ureteral catheter with a 6Fr diameter and 24 cm length (6 x 24 double J stent) because it adequately drains urine in a person ranging in height from 5'5" to 5'10". Because of its versatility, the 6 x 24 double J stent (Microvasive Polaris™; Bardex® Double Pigtail Soft Stent) is a popular choice for temporary internal stent placement. For persons less than 5'5" in height, a shorter 6 x 22 double J stent is a more appropriate choice. For persons more than 5'10" in height, a longer 6 x 26 double J stent is necessary to provide adequate urinary drainage.



Once the proper choice of ureteral stent is made, it is placed over the guide wire and a second “pusher” catheter (included with the stent kit) is used to advance the stent up the ureter under direct visualization. Typically, 5 bars or 1 fat bar is an indication that the end of the stent is approaching. When the distal end of the stent is visualized in the bladder, the surgeon must also confirm by radiography that the proximal coil of the stent is within the pelvis of the kidney. Once the stent has been confirmed to be



in the proper position, the guide wire is removed. Then, the cystoscope is carefully retreated out of the bladder and urethra while leaving the stent in place for a minimum of 6 weeks.

If during the injection of contrast media, the dye flow abruptly stops in the lower or mid-ureter within the pelvis, then one has to strongly suspect obstruction of the ureter by hemostatic clips or suture. An attempt to place a ureteral stent as described can be performed but should not be aggressively pursued if the guide wire does not easily advance up the ureter. At this point, open surgical exploration to repair any ureteral occlusion or injury should be performed. If the patient is clinically unstable, another option is to place a percutaneous

nephrostomy tube to drain the urine directly away from the kidney.

## CONCLUSION

Diagnostic cystoscopy is a relatively simple procedure. It should be mastered by all gynecologists who perform difficult pelvic cases or pelvic reconstructive cases as the lower urogenital system is at increased risk for injury. The procedure must be done in a systematic and organized manner, inspecting directly the bladder and urethra and indirectly the ureters by observing efflux of urine from ureteral orifices. This additional five-minute procedure can save a patient and her surgeon a lifetime of heartache and sorrow.

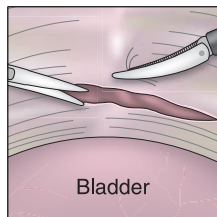
---

SUGGESTED READING:

Rosenberg BH, Averch TD. Ancillary instrumentation for ureteroscopy.  
Urol Clin North Am 2004 Feb;31(1):49-59



# LAPAROSCOPIC PARAVAGINAL REPAIR AND BURCH URETHROPEXY



***Robert D. Moore, D.O.***

***John R. Miklos, M.D.***

**S**ince the introduction of the retropubic urethral suspension in 1910, over 100 different surgical techniques for the treatment of genuine stress urinary incontinence (GSUI) have been described. Many have been modifications of original procedures in an attempt to improve clinical outcome, shorten operative time, and reduce surgical morbidity. Despite the number of surgical procedures developed each year, the Burch colposuspension and pubovaginal sling operations have remained the mainstay of surgical correction for GSUI because of their high long-term cure rates. However, these procedures do not address the concurrent anterior vaginal wall prolapse often associated with GSUI secondary to urethral hypermobility. We present a laparoscopic approach to anterior vaginal wall reconstruction using the paravaginal repair and Burch colposuspension for treatment of cystocele and stress urinary incontinence, respectively, resulting from lateral vaginal wall support defects.

Emphasizing the principles of minimally invasive surgery, the laparoscopic approach has been successfully adopted for many procedures that previously relied on an abdominal or transvaginal route. First described in 1991, the laparoscopic retropubic colposuspension has rap-

idly gained popularity because of its many reported advantages, including improved visualization, shorter hospital stay, faster recovery, and decreased blood loss.

Laparoscopy should be considered only as a mode of abdominal access and not a change in the operative technique. Ideally the indications for a laparoscopic approach to retropubic colposuspension should be the same as an open (laparotomy) approach. This would include patients with GSUI and urethral hypermobility. The authors believe the laparoscopic Burch colposuspension can be substituted for an open Burch colposuspension in the majority of cases. Factors that might influence this decision include any history of previous pelvic or anti-incontinence surgery, the patient's age and weight, the need for concomitant surgery, contraindications to general anesthesia, and the surgeon's experience. The surgeon's decision to proceed with a laparoscopic approach should be based on an objective clinical assessment of the patient as well as the surgeon's own surgical skills. Loss of the lateral vaginal attachment to the pelvic sidewall is called a paravaginal defect and usually results in a cystourethrocele and urethral hypermobility. If the patient demonstrates a cystocele secondary to a paravaginal defect diagnosed either pre- or intraoperatively, a paravaginal defect repair should be performed before the colposuspension. This approach combines the paravaginal repair with Burch colposuspension for treatment of anterior vaginal prolapse secondary to paravaginal

defects and stress urine incontinence secondary to urethral hypermobility. The paravaginal defect repair also places the anterior vaginal wall in its correct anatomic position, i.e. at the level of the arcus tendineus fascia pelvi prior to the Burch sutures being placed. This helps minimize the chance of overcorrection of the bladder neck with the Burch sutures because the paravaginal repair limits how much the Burch sutures can be tightened and only allows the bladder neck to be elevated approximately 1-2 cm above the level of the base of the bladder. This adjustment and limitation helps reduce the risk of postoperative voiding dysfunction.

We recommend that all patients have a modified bowel preparation consisting of a full liquid diet 48 hours before scheduled surgery and a clear liquid diet and one bottle of magnesium citrate 24 hours before surgery. This regimen appears to improve visualization of the operative field by bowel decompression and reduces that chance of contamination in case of accidental bowel injury. A single dose of prophylactic intravenous antibiotics is administered 30 minutes before surgery. Antiembolic compression stockings are routinely used. The patient is intubated, given general anesthesia, and placed in a dorsal lithotomy position with both arms tucked to her side. A 16F 3-way Foley catheter with a 5 mL balloon tip is inserted into the bladder and attached to continuous drainage.

Since Vancaillie and Schuessler published the first laparoscopic colposuspension case series in 1991, many other

investigators have reported their experience. Review of the literature reveals a lack of uniformity in surgical technique and surgical materials used for colposuspension. This lack of standardization is also noted with the conventional open (laparotomy) technique. Because of this lack of standardization and the steep learning curve associated with laparoscopic suturing, surgeons have attempted to develop faster and easier ways of performing a laparoscopic Burch colposuspension. These modifications have included the use of stapling devices, bone anchors, synthetic mesh, and fibrin glue. However, we believe the laparoscopic approach should be identical with the open technique to allow comparative studies as well as to ensure the patient is receiving an identical procedure utilizing either approach. When conventional surgical technique is described and utilized, cure rates have been shown to be identical via a laparoscopic or open approach. Advantages of the laparoscopic approach are improved visualization, decreased blood loss, decreased bladder/ureteral injuries and magnification of other pelvic floor defects that need to be repaired. Other advantages include less postoperative pain, shorter hospital stays, and shorter recovery time with faster return to a better quality of life.

The space of Retzius is one of the most difficult areas to suture laparoscopically secondary to limited space and the angles required to place and retrieve sutures. We utilize one port to do all of our laparoscopic suturing and the surgeon is the only one passing and retriev-

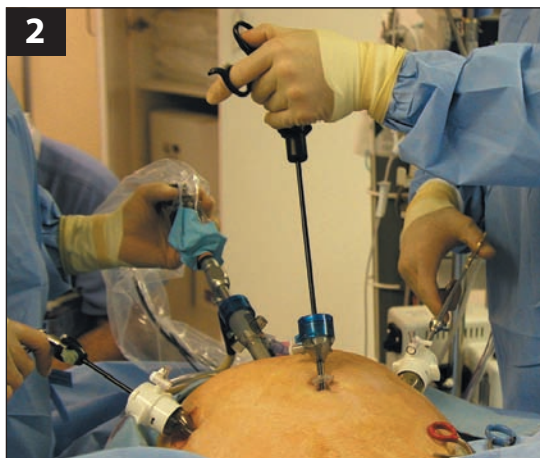
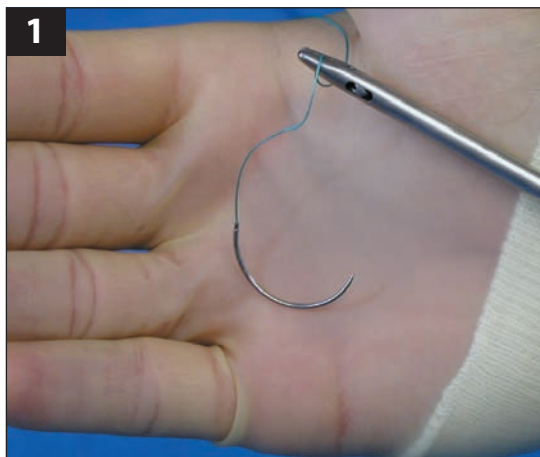
ing needles. Some authors recommend either using their assistant to load or retrieve needles or the surgeon changes sides of the table to suture on the patients contra-lateral side. We feel this is not necessary, nor is it efficient. Utilizing proper angles and needle placement, as well as utilizing the vaginal hand to elevate and manipulate the anterior vaginal wall, the surgeon can complete all suturing from one side of the table and utilize the assistant to hold the camera and retract only. We feel this helps improve efficiency, safety, and optimizes the economy of motion of the procedure. There is no need for the surgeon or the assistant to change sides of the table.

## EQUIPMENT AND SUTURES

Many different types of sutures and instruments have been described for use in laparoscopic paravaginal repair and Burch colposuspension. We feel that permanent sutures should be utilized in pelvic floor repairs and therefore use permanent sutures in laparoscopic Burch/PVR. Our suture of choice for pelvic reconstructive surgery is 2-0 Ethibond (Ethicon) on a SH needle (Figure 1), which is a braided permanent suture. To be able to tie extracorporeal knots when suturing in the space of Retzius, it is necessary to have a minimal suture length of 48 inches, therefore, some sutures may need to be special ordered to obtain this minimal length. Since there is a limitation of space retro-pubically, we have found the ideal size of needle should be no larger than an SH

needle. CT-1 needles have been utilized, however, we find these needles too large to manipulate in the space of Retzius and feel there is more chance of injury to vascular and visceral structures. We use Gore-Tex permanent sutures on a CT-1 taper cut needle for the Burch portion of the procedure secondary to taking two passes through the pubocervical fascia. A double-pass allows us to get an adequate purchase of vaginal tissue and the nature of the Gore-Tex suture allows the suture to slide very easily through the tissue, even with a double-bite. Braided sutures such as Ethibond or Vicryl do not slide through the tissue like this and each throw through the tissue has to be taken separately which increases operative time. In paravaginal repair, only one pass is taken through the vagina and sidewall and therefore Gore-Tex (which is more expensive than Ethibond) is not necessary.

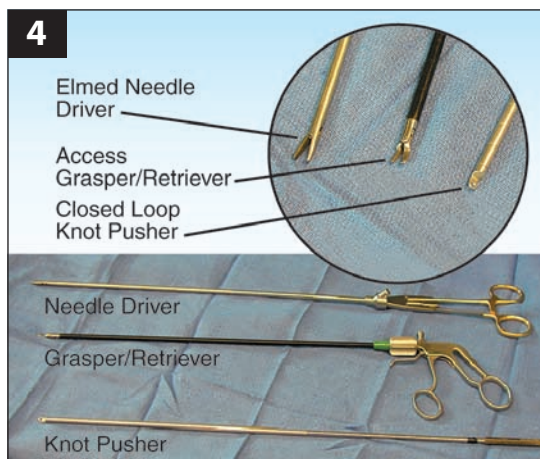
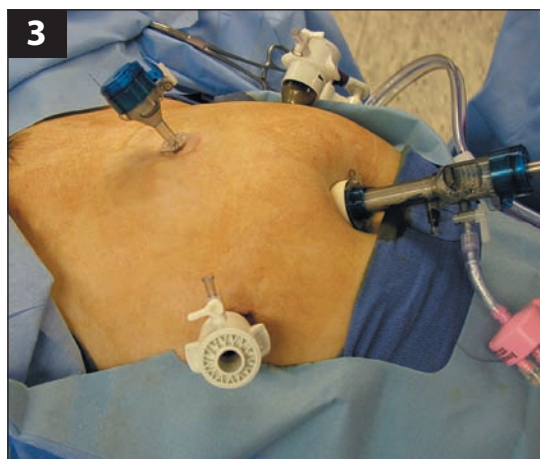
As stated above, the surgeon completes all suturing, retrieving of needles and knot tying from one port on the patient's left side (if right handed). The assistant stands on the patient's right side and holds the camera with their left hand and uses their right hand to assist in the surgical field (Figure 2). The suturing port needs to be a minimal of 10 mm to be able to accommodate passing the needle through the port. Secondary to multiple sutures being placed throughout a laparoscopic reconstructive procedure, it is not efficient to utilize other methods of needle placement into the abdominal cavity that may take several steps to try to use a smaller (i.e. 5 mm) port. We currently use the Adept (Taut) 5/10 mm port



in the left lower quadrant that has a diaphragm designed to not leak gas when suturing and also allows up to a CT-1 needle to be passed easily in and out of the abdominal cavity. A 10 mm balloon trocar is used in the umbilicus, as we complete the open approach in all patients for safe access into the abdomen. Two 5 mm ports are used as well. One is placed suprapubically that the surgeon utilizes with his left hand for a grasper to retrieve needles and the

other is placed in the right lower quadrant that the assistant uses for retraction, suction/irrigation, etc. The suprapubic port is placed high, approximately 4 fingerbreadths above the pubic bone to be able to have access to the retropubic region (Figure 3). All sutures are thrown from the left to the right in the patient.

We utilize an Elmed needle driver for all of our laparoscopic suturing. It is designed exactly like a traditional needle driver and also allows the needle to be placed with different angles and locked in these positions, which is important for suturing in the space of Retzius. Self righting needle drivers may be easier to use for beginners, however, they do not allow the needle to be at any other angle but 90°, nor can the needle be leaned in or out, again limiting your suturing abilities. The surgeon also utilizes an Access needle driver through the suprapubic port, however, it is used as a retriever/grasper and not a driver. We have found this to be an excellent needle retriever as it can be used as a grasper and has the advantage of slightly curved delicate jaws that can be rotated and does not lock down, therefore, it can also stabilize the needle in position in the tissue when necessary (Figure 4). We hold the Access “backwards” with our left hand, as this allows us almost 360° of motion with simple rotation of the left wrist. Sutures are tied extracorporeally with a closed loop Saye/Reddick knot-pusher. Extracorporeal knot tying is much faster and more efficient than intracorporeal knot tying, again decreasing overall operating time.

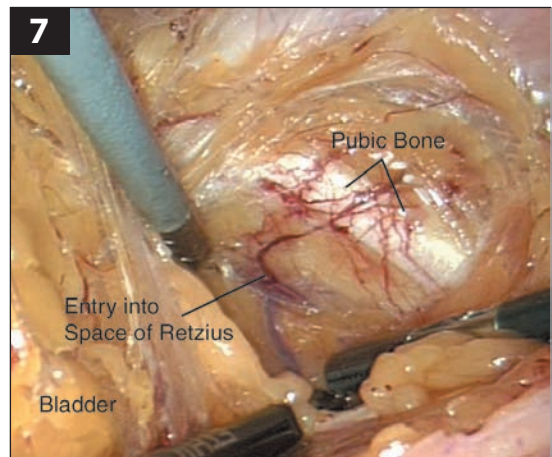
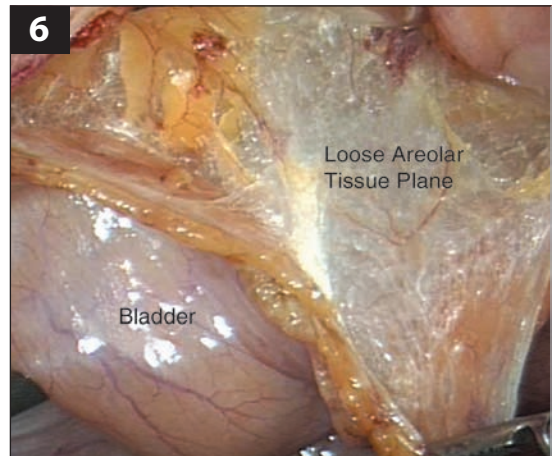
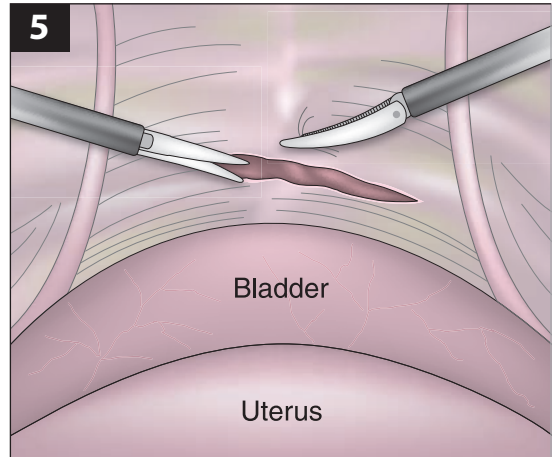


A transperitoneal approach is utilized to complete the procedure, this allows access to the remainder of the pelvis and to complete other reconstructive procedures as necessary. The bladder is retrograde filled with 200cc-300cc of sterile water solution through a 3-way foley catheter. This allows clear visualization of the superior border of the bladder edge, which in some cases is above the level of the superior pubic symphysis. A harmonic scalpel is utilized to gain entry into the



retroperitoneal space. An incision is made in the peritoneum approximately 3 cm superior to the dome of the bladder between the obliterated umbilical ligaments which can be clearly visualized in most patients (Figure 5). Staying medial (inside) to the ligaments protects the surgeon from injuring the inferior epigastric vessels which run lateral to the ligaments. Identification of loose areolar tissue (white cob-web type tissue) confirms a proper plane of dissection (Figure 6). After the space of Retzius has been entered and the pubic ramus visualized (Figure 7), the bladder is drained in order to prevent injury. Separating the loose areolar and fatty layers using blunt dissection develops the retropubic space. Blunt dissection is continued until the retropubic anatomy is visualized.

After blunt dissection is completed on the patient's right side, a laparoscopic kitter (peanut) is used to gently clean off the pubocervical fascia. The pubic symphysis and bladder neck are identified in the midline and the obturator neurovascular bundle, Cooper's ligament, and the arcus tendineus are visualized along the pelvic sidewall. Clearly visualized is the lateral margin of the detached pubocervical fascia and the broken edge of the white line, creating a paravaginal defect on this side (Figure 8). The dissection is continued on the patient's left side and anatomy identified. The anterior vaginal wall and its point of lateral attachment from its origin at the pubic symphysis to its insertion at the ischial spine are identified (Figure 9).

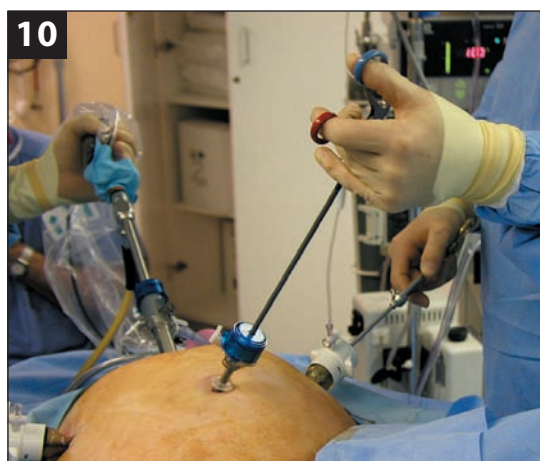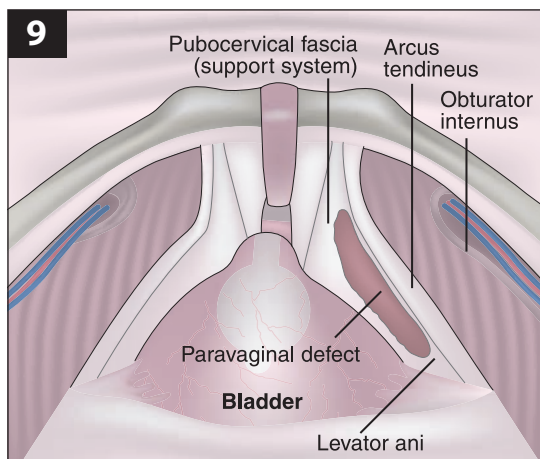
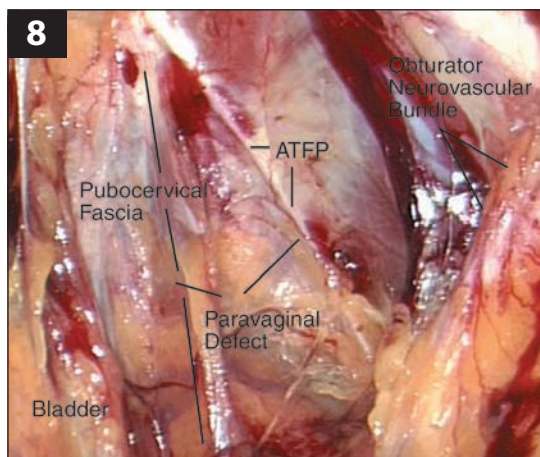


## LAPAROSCOPIC PARAVAGINAL REPAIR

A 2-0 braided non-absorbable suture (Ethibond) on a SH needle is utilized for the paravaginal defect repair. The suture is grasped with the Elmed needle driver approximately 3 cm from the needle and is fed through the 5/10 mm Taut suturing port in the left paramedian region into the abdomen. The surgeon utilizes the Access needle driver in his left hand through the supra-pubic port as a grasper/retriever during the suturing process (Figure 10). The assistant holds the camera and a grasper for retraction or suction and does not assist in any needle passage, retrieving, etc. The surgeon is self-sufficient and does all aspects of suturing from the left side with no assistance.

Once in the abdomen, the surgeon regrasps the suture with the instrument in the suprapubic port with his left hand and allows the needle to dangle freely in the abdomen. The jaws of the grasper can then be rotated to place the needle in the proper position to be loaded in the needle driver in his right hand. The needle can also be gently laid on the side-wall to help in loading into a correct position as well.

For the paravaginal defect repair on the right side, the assistant lays an instrument across the bladder, opening the retropubic space for suturing. The surgeon places his left hand in the vagina and elevates the anterior vaginal wall up to place the first suture into the pubocervical fascia at the apex of the defect near

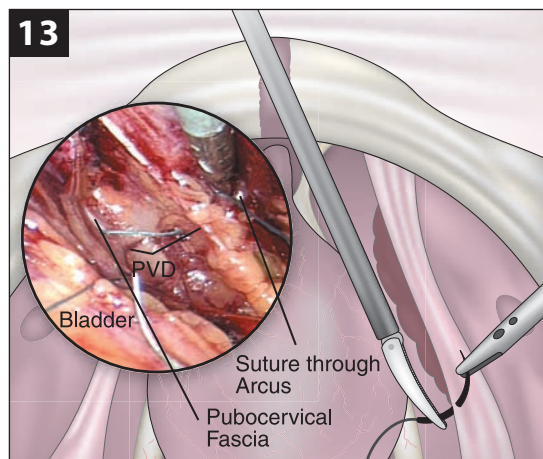
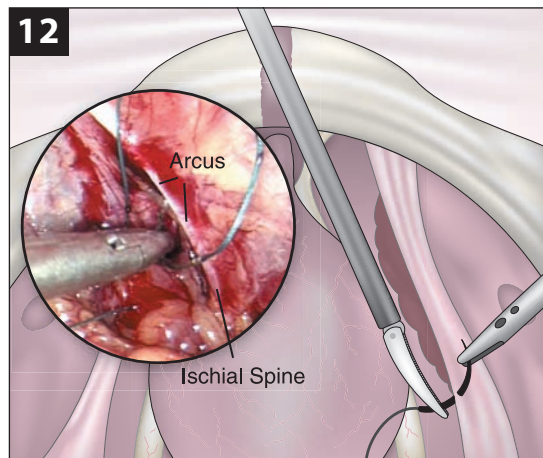
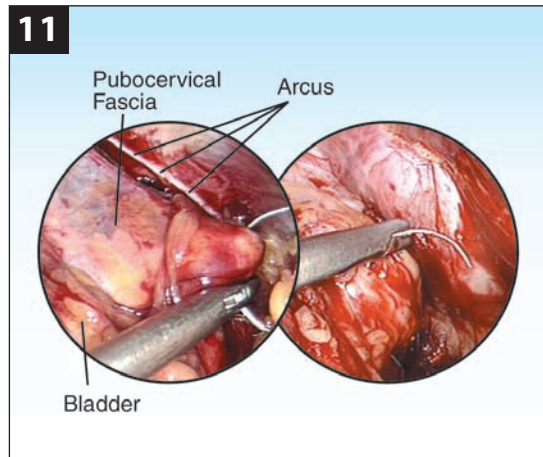


the top of the vagina on the right side. The assistant retracts the bladder away from the pubocervical fascia and the surgeon then places the needle through the fascia (Figure 11). Maintaining the elevation of the vagina with his left index finger, the needle is then retrieved with the driver in his right hand (Figure 11). Separate passes are always utilized for the vagina and the sidewall to ensure proper placement and adequate tissue bites.

Once the needle is reset, the surgeon then passes the needle through the ipsilateral obturator internus muscle and fascia around the arcus tendineus fascia at its origin 1-2 cm distal to the ischial spine (Figure 12). The assistant uses a grasper or retractor to keep the space open and extreme care must be used to identify and know the position of the obturator neurovascular bundle at all times. When placing sutures through the sidewall (on either side) the surgeon uses both hands, his right hand to drive the needle and his left hand with the Access grasper to retract if necessary and then retrieve the needle from the sidewall (Figure 13).

The suture is then tied by the surgeon extracorporeally using the closed-loop knot pusher and 3-4 more sutures are placed with the same technique on this side for repair of the right sided defect (Figure 14).

The repair on the left begins with placement of the first suture at the apex of the defect around the white line approximately 1-2 cm from the ischial spine (Figure 15). We always suture left to right and therefore on the left side, we



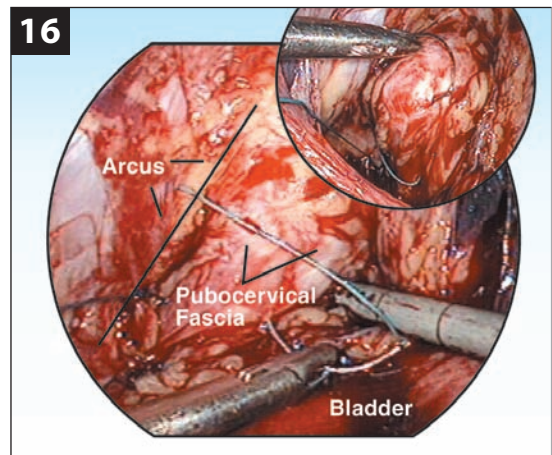
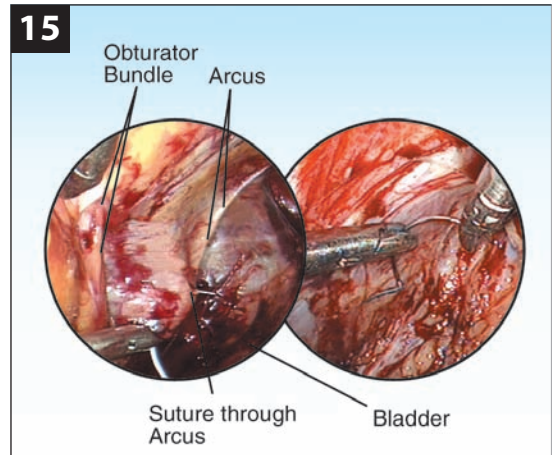
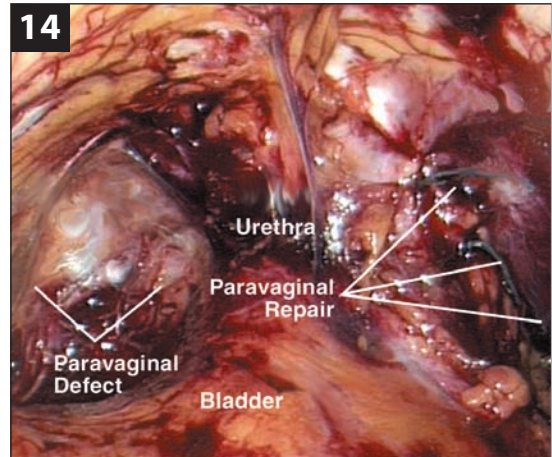
go through the sidewall first and then through the vagina. Again, when placing the suture around the arcus, the surgeon utilizes both hands laparoscopically; the needle driver with his right hand, and the grasper/retriever with his left hand to initially retract, and then retrieve the needle from the sidewall (Figure 15). The needle is reset and then the vagina is again elevated up by the surgeon with his non-dominant hand, the bladder retracted off the pubocervical fascia by the assistant, and the suture placed through the vagina and retrieved with the needle driver in the surgeon's right hand. Maintaining elevation of the vagina with the left hand, the surgeon has easier access to retrieving the needle (Figure 16).

All sutures are cut by the surgeon with hook scissors. When tying the knot, the scrub technician places the hook scissors gently in the suprapubic port, allowing the surgeon to cut the suture as soon as he is done tying the knot down. Hook scissors are much safer and can actually be used to "hook" the suture when it is in a difficult position to cut, again maintaining a higher safety level.

The schematic drawing of the bilateral paravaginal defect repair is shown in Figure 17.

## LAPAROSCOPIC BURCH COLPOSUSPENSION

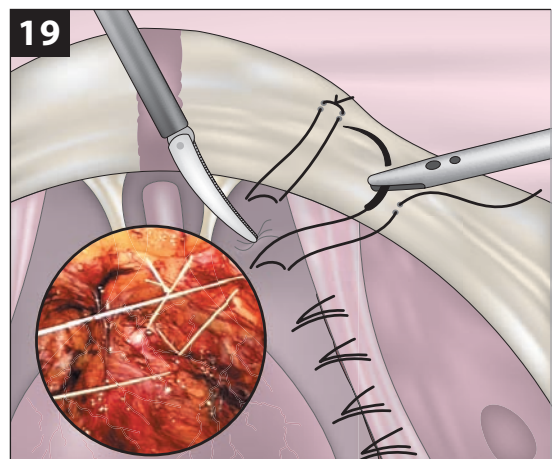
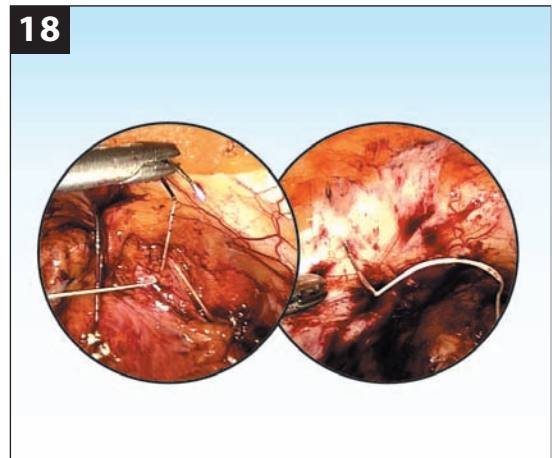
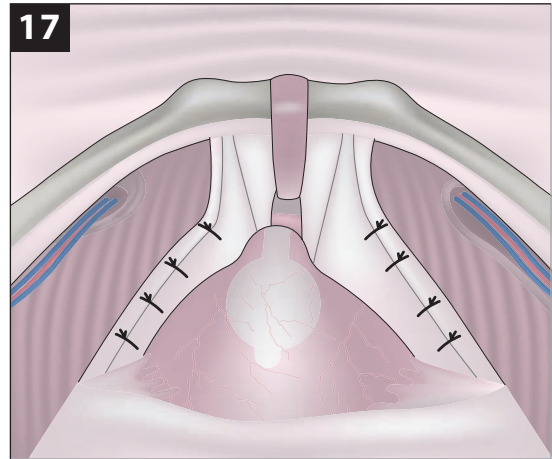
The laparoscopic colposuspension is performed using nonabsorbable No. 0 sutures; we routinely use polytrifluoroethylene. The surgeon's nondominant hand is placed in the vagina and a finger



is used to elevate the vagina. The endopelvic fascia on both sides of the bladder neck and midurethra is exposed using an endoscopic Kittner. The first suture is placed 2 cm lateral to the urethra at the level of the midurethra (Figure 18). A figure of eight bite, incorporating the entire thickness of the anterior vaginal wall excluding the epithelium is taken and the suture is then passed through the ipsilateral Cooper's ligament. With an assistant's fingers in the vagina to elevate the anterior vaginal wall toward Cooper's ligament, the suture is tied down with a series of extracorporeal knots using an endoscopic knot pusher.

An additional suture is then placed in a similar fashion at the level of the urethrovesical junction, approximately 2 cm lateral to the bladder edge on the same side (Figure 19). The procedure is repeated on the opposite side. Excessive tension on the vaginal wall should be avoided when tying down the sutures. We routinely leave a suture bridge of approximately 2-3 cm. The outcome of paravaginal repair and Burch colpopexy is shown in Figure 20.

Upon completion of the paravaginal repair and Burch urethropexy, the intraabdominal pressure is reduced to 10-12 mmHg, and the retropubic space is inspected for hemostasis. Cystoscopy is performed to rule out urinary tract injury. The patient is given 5 mL of indigo carmine and 10 mL furosemide intravenously, and a 70° cystoscope is used to visualize the bladder lumen, assess for unintentional stitch penetration and confirm bilateral ureteral patency. After cys-

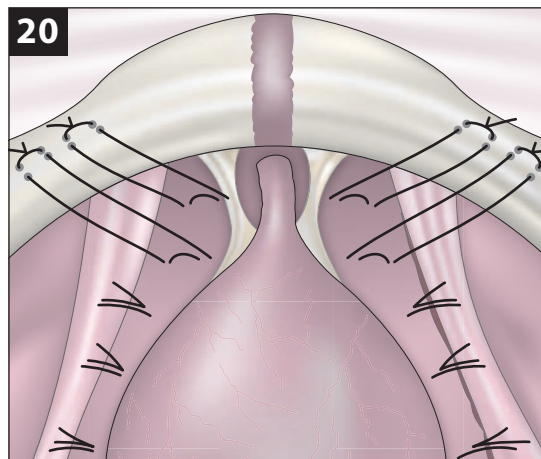


toscopy, attention is returned to laparoscopy. We recommend routine closure of the anterior peritoneal defect in a pursestring fashion using a 0-chromic suture on a CT-1 needle. All ancillary trocar sheaths are removed under direct vision to ensure hemostasis and exclude iatrogenic bowel herniation. Excess gas is expelled and fascial defects of 10 mm or more are closed using delayed absorbable suture. Postoperative bladder drainage and voiding trials are accomplished using either: a transurethral catheter, suprapubic tube, or intermittent self catheterization.

## POTENTIAL COMPLICATIONS AND INJURIES

### LOWER URINARY TRACT INJURIES

The most common reported complication of Burch and paravaginal repair is injury to the bladder and/or the ureters. Lower urinary tract injuries have been reported to be as high as 4% in open procedures. We have shown a much lower rate of injury with a laparoscopic approach, however, others have reported injury rates as high as 6% and, therefore, one must be prepared to handle these complications. Clearly, injury to the lower urinary tract is higher when there has been previous surgery in the space of Retzius such as previous Burch/MMK or retropubic sling procedure as the space will have extensive scar tissue in it and, therefore, risk of injury to the bladder or vasculature is much higher. We recommend only advanced experienced laparo-



scopic surgeons attempt dissection and repair in these patients. Again patient selection and surgeon experience are key determinants in minimizing risk of injury in advanced laparoscopic surgery.

Cystotomy is the most common bladder injury encountered and typically occurs during dissection into the space of Retzius. We recommend using a 3-way foley catheter to retrograde fill the bladder with 250 cc of fluid prior to beginning the dissection into the Space. Once the bladder is filled, the superior edge of the dome of the bladder is identified and the incision made between the obliterated umbilical ligaments approximately 3 cm above this. After making the initial incision through the peritoneum, blunt dissection is used to find the loose areolar tissue (cob-web like appearance) and then the dissection continued down to the pubic bone. Once the pubic bone is identified, the risk of bladder injury is minimal and, therefore, the bladder is emptied to have better visualization of the space. Blunt dissection is continued

and then a laparoscopic Kittner is used to gently clean the fatty tissue off the pubocervical fascia. A finger is placed in the vagina, to elevate the vagina up and the Kittner (peanut) is then used to ensure the bladder is gently dissected medially off the lateral pubocervical fascia where sutures will be placed for the repair. As long as the “white” pubocervical fascia can be visualized, the risk of suture placement in the bladder is minimal.

If cystotomy occurs, it typically is during dissection and is at the dome of the bladder, far away from the ureters and typically is a very simple repair. Cystoscopy should be completed to ensure the ureters are not involved or close enough to the injury that the repair would compromise them. The cystotomy should be repaired laparoscopically with interrupted sutures of 3-0 vicryl in two layers. Cystoscopy should be completed after repair to ensure water tight closure and ureteral patency. If the repair is close to one of the ureters, a ureteral stent should be placed during repair to ensure patency and to protect the ureter. Postop drainage for 7 days with foley catheter is recommended following repair.

Postoperative cystoscopy is recommended for all patients undergoing Burch and/or paravaginal repair to ensure ureteral patency and that there is no injury to the bladder, or sutures in the bladder. An ampule (5cc) of indigo carmine is given to the patient intravenously to ensure ureteral patency. If there is ureteral compromise, the sutures on that side must be removed. The most common suture that could cause ureteral

obstruction is the highest paravaginal suture that is placed near the ischial spine and this is the first suture that should be released. If ureteral patency is still compromised, the next suture that should be removed is the Burch suture at the bladder neck. If the ureter is still not patent, then all sutures on that side should be removed and a number 5 or 6 ureteral stent passed to assure patency. The stent should be left in place and the sutures replaced. As long as there is no evidence of ureteral injury (i.e. blue dye spilling into the space of Retzius), the stent can be removed immediately following the procedure. If a suture is seen penetrating the bladder on cystoscopy, it needs removed and replaced. There is no need for prolonged catheterization following removal of a suture from the bladder.

## VASCULAR INJURIES

The most common and devastating vasculature injury that can occur in the space of Retzius would be to the obturator neurovascular bundle. This should be one of the first structures visualized when entering the space and the surgeon must be aware of its location at all times throughout the procedure. Typically, injury to this structure occurs with the shaft of the needle (i.e. the back of it) when trying to manipulate the needle in the Space. If injury occurs to the obturator bundle, brisk bleeding will be encountered. Suction irrigation must be utilized immediately to try to obtain visualization and ultimately hemostasis. We recommend utilizing 10 mm hemoclips to

obtain hemostasis laparoscopically, however, the surgeon should be prepared to open immediately if hemostasis cannot be obtained. Blind placement of clips or the use of electrocautery is not recommended as this can compromise and/or damage the obturator nerve. Once hemostasis is obtained, the obturator nerve needs to be isolated to ensure that no clips have been placed across it. Another option is the use of Flow Seal, which is thrombin gel-type agent that can be placed in the area of bleeding and can seal off the vessels, even with arterial bleeding. We recommend having this agent available for immediate use in the operating room at all times. If the vessels retract into the obturator canal, obtaining hemostasis can be very difficult and it

may be necessary to approach this through the groin and obtain vascular surgery consult.

## CONCLUSION

Although there have been no studies regarding the long-term results of the laparoscopic paravaginal plus colposuspension procedure, one would assume that there is a higher cure rate for the paravaginal plus Burch colposuspension (8 to 12 sutures) compared with the Burch colposuspension only (4 sutures) for the treatment of stress urinary incontinence, because more sutures result in a greater distribution of force to the pelvic floor during episodes of increased abdominal pressure.



## SUGGESTED READING:

Goebell R. Zur operativen beseilligung der angeharenen incontinence vesicae. *Incontinentia Vesicae Gynakol Urol* 1910;2:187-191

Vancaille TG, Schussler W. Laparoscopic bladderneck suspension. *J Laparoendosc Surg* 1991;1:169-173

Miklos JR, Kohli N. "Paravaginal Plus" Burch procedure: a laparoscopic approach. *J Pelvic Surg* 1998;4:297-302

Kohli N, Miklos JR. Laparoscopic Burch colposuspension: a modern approach. *Contemp Obstet Gynecol* 1997;42:36-55

Miklos JR, Kohli N. Laparoscopic paravaginal repair plus Burch colposuspension. *Urology* 2000;56:(suppl 6A) 64-69

Henley C. The Henley staple-suture technique for laparoscopic Burch colposuspension. *J Am Assoc Gynecol Laparoscopists* 1995;2:441-444

Ou CS, Presthus J, Beadle E. Laparoscopic bladder neck suspension using hernia mesh and surgical staples. *J Laparoendosc Surg* 1993;3:563-566

Kiilholma P, Haarala M, Polvi H, Makinen J, Chancellor MB. Sutureless colposuspension with fibrin sealant. *Tech Urol* 1995;1:81-83

Liu CY. Laparoscopic treatment of genuine urinary stress incontinence. *Clin Obstet Gynecol* 1994;8:789-798

Ross JW. Laparoscopic Burch repair compared to laparotomy Burch for cure of urinary stress incontinence. *Int Urogynecol* 1995;6:323-328

Ross JW. Two techniques of laparoscopic Burch repair for stress incontinence: a prospective randomized study. *J Am Assoc Gynecol Laparoscopists* 1996;3:351-357

Lam AM, Jenkins GJ, Hyslop RS. Laparoscopic Burch colposuspension for stress incontinence: preliminary results. *Med J Aust* 1995;162:18-22

Su TH, Wang KG, Hsu CY, Wei H, Hong BK. Prospective comparison of laparoscopic and traditional colposuspensions in the treatment of genuine stress incontinence. *Acta Obstet Gynecol* 1997;76:576-582

Ross JW. Multichannel urodynamic evaluation of laparoscopic Burch colposuspension for genuine stress incontinence. *Obstet Gynecol* 1998;91:55-59

Miklos JR, Moore RD, Kohli N. Laparoscopic pelvic floor repair. *Obstet Gynecol Clin N Am* 2004;31: 551-565

Miklos JR, Moore RD, Kohli N. Laparoscopic management of urinary incontinence, ureteric and bladder injuries. *Curr Opinion Obstet Gynecol* 2001;13:411-417

Speights S, Moore RD, Miklos JR. Frequency of lower urinary tract injury at laparoscopic burch and paravaginal repair. Review of 171 cases. *J Am Assoc Gynecol Laparosc* 2000;7: 515-518

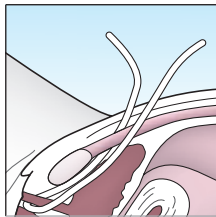
Harris RL, Cundiff GW, Theofrastous JP, et al. The value of intraoperative cystoscopy in urogynecologic and reconstructive pelvic surgery. *Am J Obstet Gynecol* 1997;177: 1367-1369

Stevenson KR, Cholhan HJ, Hartmann DM, et al. Lower urinary tract injury during Burch procedure. *Am J Obstet Gynecol* 1999;181: 35-38

Paraiso MF, Walters MD, Karram MM, et al. Laparoscopic Burch Colposuspension versus Tension-Free Vaginal Tape: A Randomized Trial. *Obstet Gynecol Surv* 2005;60(3):166-7



# TENSION FREE VAGINAL TAPE AND TOT SLING FOR STRESS URINARY INCONTINENCE



***Robert D. Moore, D.O.***

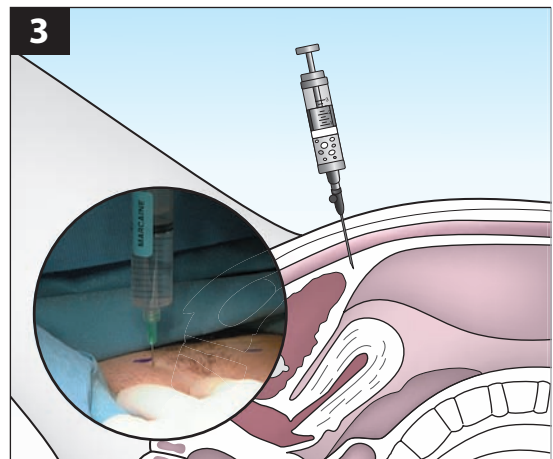
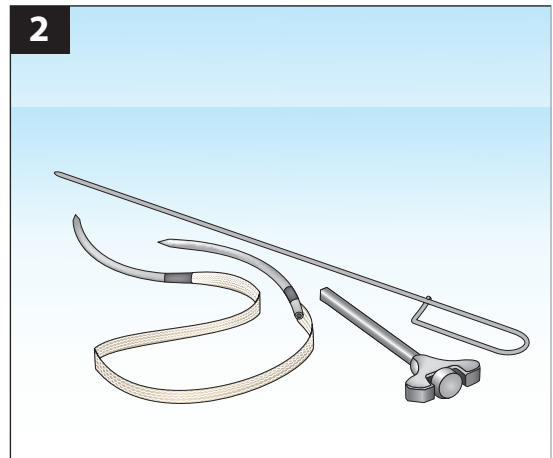
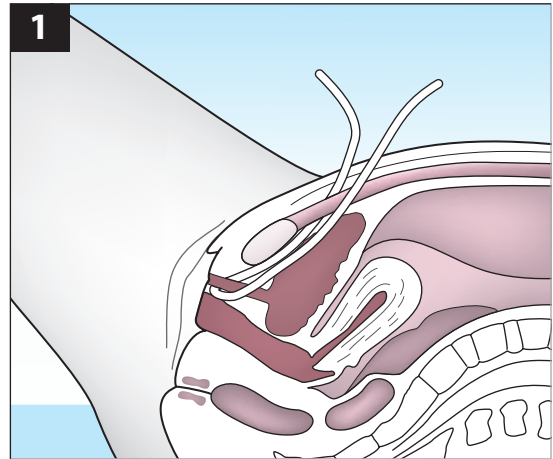
***John R. Miklos, M.D.***

**P**ubovaginal sling procedures have long been utilized for effective treatment of stress urinary incontinence. Traditional sling procedures require relatively large vaginal and suprapubic incision(s) or bone fixation devices and have been reported to have high incidence of postoperative voiding dysfunction. The traditional sling procedures also have never been standardized. Recently, minimally invasive mid-urethral mesh slings have been introduced in Australia, Europe and the United States. The Tension-Free Vaginal Tape sling was the first sub-urethral sling in this new category of minimally invasive mid-urethral slings to be introduced for the surgical correction of female genuine stress urinary incontinence (GSUI). First described by Ulmsten and Petros in 1995, the TVT procedure (Tension-Free Vaginal Tape, Gynecare, Somerville, NJ) has been used extensively in Europe and in the United States since clinical trials established its safety and effectiveness as an ambulatory surgical procedure for treatment of GSUI in women (Figure 1). TVT is provided in a kit that contains a 1.1 cm x 40 cm polypropylene mesh (Prolene, Ethicon, Inc., Somerville, NJ) covered by a plastic sheath and connected to two 5 mm stainless steel needles (Figure 2). The plastic sheath allows easy passage/placement of the tape, and is thought to reduce risk of

infection by covering the mesh during passage. The mesh is designed to stay fixed in place once the smooth protective cover is removed. The handles for the application of the stainless steel needle and the rigid catheter guide are required for the TVT placement and are not provided in the kit.

The procedure is routinely performed via the vaginal route with a 1.5 cm vaginal incision; two small suprapubic stab incisions (<5 mm) require no fixation. It can be completed in 20-25 minutes and is the first sling that is adjusted intraoperatively in a tension-free manner with a cough stress test. This objective adjustment is thought to contribute to its success rate and reduce postoperative voiding dysfunction.

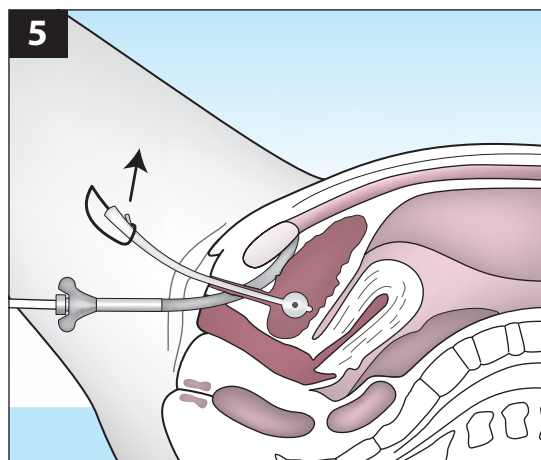
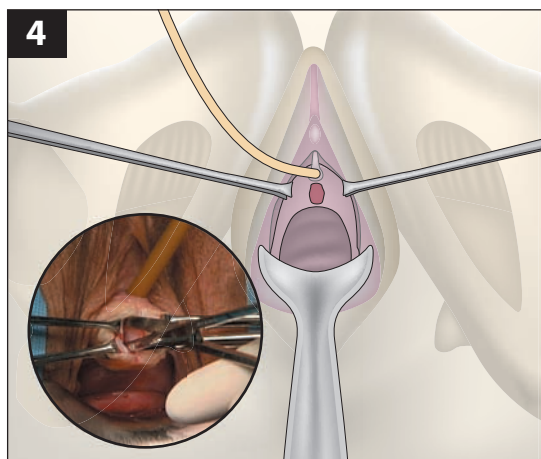
Suprapubic incisions are marked approximately 2 cm off the midline (clitoral hood marks the midline). Two small abdominal skin incisions (0.5 cm) are made on each side of the midline just above the pubic symphysis. No dissection is necessary. Local anesthesia is injected bilaterally via a long spinal needle in the skin and abdominal wall just above the pubic symphysis, downward posterior to the pubic bone through the space of Retzius (Figure 3). An 18-Fr Foley catheter is used to drain the bladder throughout the procedure. Local anesthetic agent is then injected into the vaginal mucosa and submucosal tissues in the midline and bilaterally at the level of the mid-urethra toward the bladder neck and in the direction of the retropubic space. A one-centimeter mucosal incision is made in the mid-urethra and the



edges of the vaginal incision are grasped with Adair clamps and minimal dissection is used to free the vaginal wall from the suburethral tissues to develop a small tunnel paraurethrally bilaterally (Figure 4). The pubocervical fascia is NOT broken through. Dissection is completed sharply with Metzenbaum scissors — the surgeon should not utilize fingers for blunt dissection.

The local anesthesia is again injected bilaterally with a spinal needle along the tract the TVT needle will take, i.e. through the pubocervical fascia and then up into the retropubic space right behind pubic bone.

A re-usable TVT handle is inserted on the needle preparing for passage. The speculum is removed from the vagina. The bladder is drained, a catheter guide is placed, and the urethra is deviated to the side of needle passage. The needle tip is placed through the vaginal incision into the paraurethral space and directed towards the ipsilateral shoulder. Two hands are used to pass the needle, one on the needle itself and the other on the handle. A finger should be placed vaginally (not in the incision) and the inferior ramus should be palpated; the needle should then be advanced directly under the inferior ramus and through the endopelvic fascia (Figure 5). Once the needle tip has broken through the fascia, the needle is adjusted slightly to the midline and the handle of the needle is then directed downward and the needle is advanced through the retropubic space upward, being careful to try to



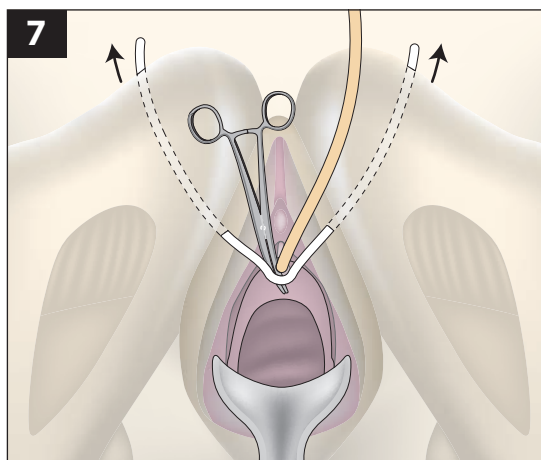
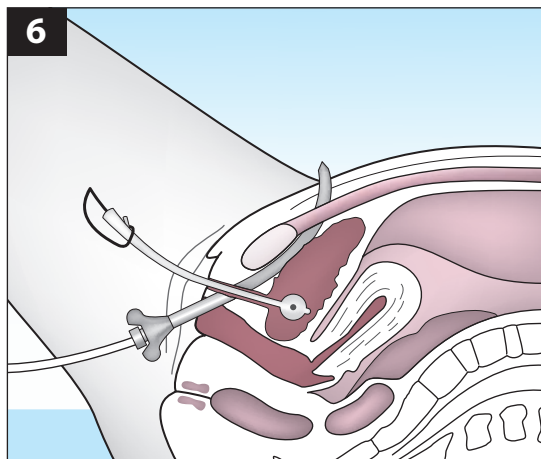
hug the pubic bone as the needle passes through the space. The force advancing the needle actually comes from the palm or thumb of the vaginal hand and the vaginal finger guiding it. The second hand on the handle directs or “steers” the needle, but does not advance it. The needle is directed toward the patient’s opposite shoulder and passed behind the pubic bone. The dominant hand then grasps the base of the needle and the handle and the other hand is placed on the abdomen to

advance the needle tip through the abdominal fascia and stab incision (Figure 6).

Cystoscopy is completed with the needle in place to rule out any perforation of the bladder. The bladder should be completely distended. Most perforations occur at the lateral border of the dome of the bladder. The bladder is drained and the needle passed on the contralateral side in an identical fashion followed by cystoscopy. Once bladder injury is ruled out, both needles are pulled upward from above. The tape is left very loose under the urethra (both needles have been pulled through and are on the abdomen still attached to the tape), the bladder is filled with 250 cc of fluid and the patient is asked to cough. The tape is then tightened sequentially (always with an instrument between the tape and the sub-urethral tissues) until only a small “welling up” of fluid is seen with cough.

Once final adjustment is reached, the tape is held in place sub-urethrally with an instrument such as a curved mayo scissors and the outer sheath is removed from above and excess mesh cut off (Figure 7). The suprapubic incisions are closed with steri-strips and the vaginal incision with absorbable suture.

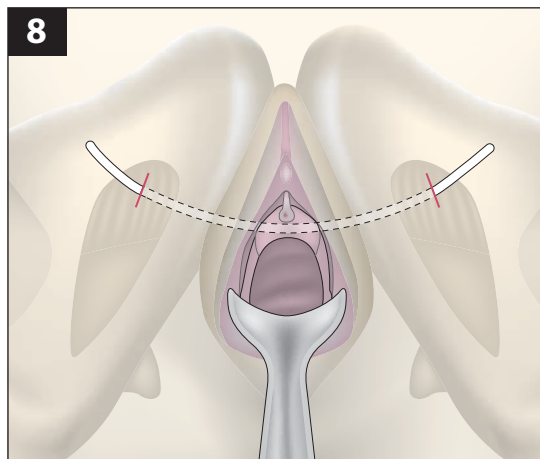
Recent studies have shown that the TVT procedure is associated with high success rates comparable to the traditional sub-urethral sling procedure, yet may lower the incidence of intraoperative and postoperative complications. The procedure is completed under local or regional anesthesia either as an outpatient or



with a hospital stay of less than 24 hours. Long-term data and clinical experience have proven exceptional efficacy and safety. Success rates continue to be excellent (85% cured, 96% significantly improved) at 5 years and impressive success rates have also been shown with recurrent SUI (91%), intrinsic sphincter deficiency (86%), and mixed incontinence (89%). Over one million procedures have been completed worldwide, virtually revolutionizing the treatment of SUI in women.

More recently, similar procedures have been developed that utilize some of the same basic concepts of mesh tape placed suburethrally in a minimally invasive approach. The SPARC (American Medical Systems, Minnetonka, Minnesota) is a mid-urethral sling procedure that utilizes a prolene mesh tape as well, however, it is completed via an abdominal approach. Needles are first passed from above abdominally through small suprapubic incisions, to a small vaginal incision and the tape is then pulled up from below. A prolene suture is woven through the mesh so that the sling can be adjusted, if necessary, after the outer sheath is removed. The procedure was developed for surgeons who were more comfortable passing needles from above to below, such as Stamey or Raz needles.

A new approach that has been investigated and utilized in Europe and is recently gaining popularity in the United States, is the transobturator approach (TOT) to place the mesh tape suburethrally. Several companies have released transobturator approaches for placement of a tension-free suburethral sling and the differences between these slings seem to be insignificant. Different companies use different types of mesh for the tape and the weave of the mesh may vary. Some use an outer plastic sheath and differ by whether the needle is passed from the groin to the vagina (outside-in) or from the vagina out to the groin (inside-out). There are several products on the market such as: Uretex® by C.A. Bard, Inc (Covington, GA), Ethicon Urology and Womens Health



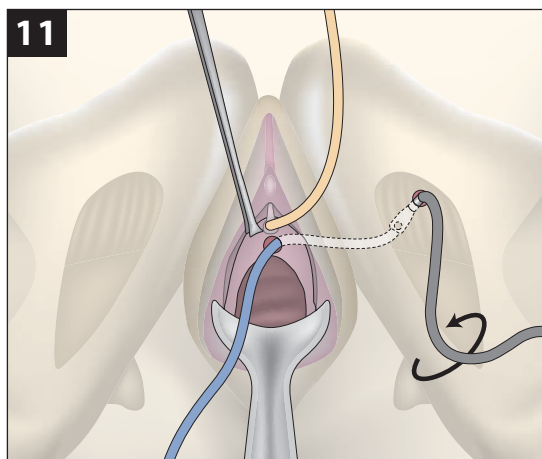
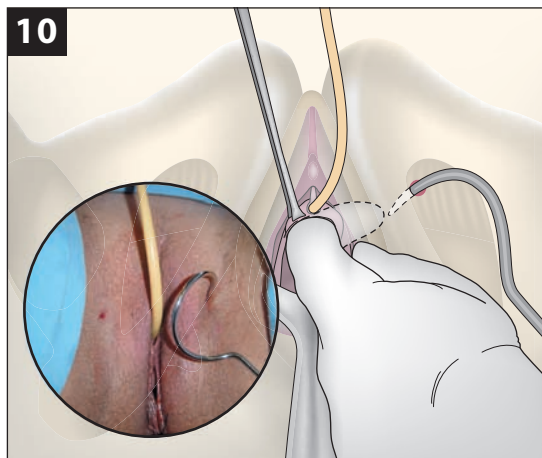
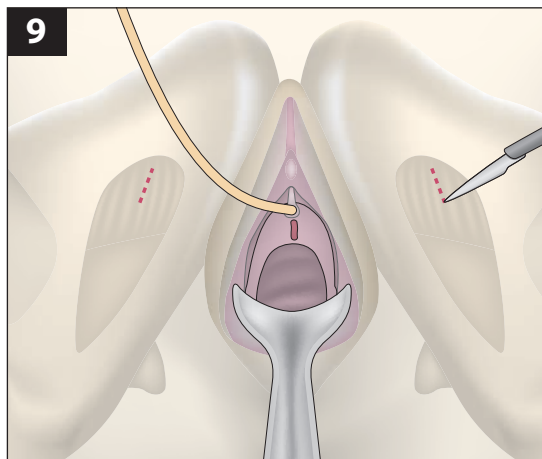
TOT (Cincinnati, OH). The MONARCR subfascial hammock sling (AMS) utilizes the same mesh as the SPARC procedure. The TOT procedure utilizes the same vaginal incision, however, the needle and sling are passed laterally through a small incision in the groin then through the obturator membrane and muscle instead of the retropubic space and rectus muscle (Figure 8). This seems to offer a much safer needle passage than the retropubic needle passage by avoiding the dangers of potential major vessel injury, bleeding in the retropubic space, bladder and bowel injury.

A stab incision is made in the genitofemoral fold at the level of the clitoris bilaterally (Figure 9). A finger is placed in the vagina to palpate the obturator fascia (obturator internus) from inside the vagina. The outside finger palpates the tract the needle will take through the obturator foramen, just lateral to ischiopubic ramus. The index fingers can actually palpate each other. The needle tip is then placed in the stab incision (Figure 10).



With the index finger remaining in the vaginal incision, the needle is rotated and guided through the space and brought into the paraurethral space with the vaginal finger. The needle path is around the medial edge of the descending ischiopubic ramus just below the insertion of the adductor longus tendon, then through the obturator externus muscle, obturator membrane, and obturator internus. Pressure is exerted by the thumb of the vaginal hand on the curve of needle as it breaks through the obturator fascia and the needle is guided by the index finger of the vaginal hand throughout the path the needle takes (Figure 10). Mesh tape covered by the outer plastic sheath is connected to the needle and the tape is then pulled back through the space by opposite rotation of the needle and handle (Figure 11). The needle is then placed on the contralateral side and the tape is pulled through on that side. Final position of the tape is determined by a cough stress test as shown in Figure 12. Stab incisions are closed with steri-strips.

Additional benefits to TOT seem to be less voiding dysfunction and urinary obstruction compared to traditional slings and even retropubic tape slings. This is thought to result secondary to the fact that when the sling is placed through the transobturator space, the angle of the sling is less acute and actually replicates the position of the pubo-urethral ligament very closely. This apparently leads to a very anatomic positioning of the tape with less voiding dysfunction. Some authors believe it may be safer to use an approach from the outside to the inside

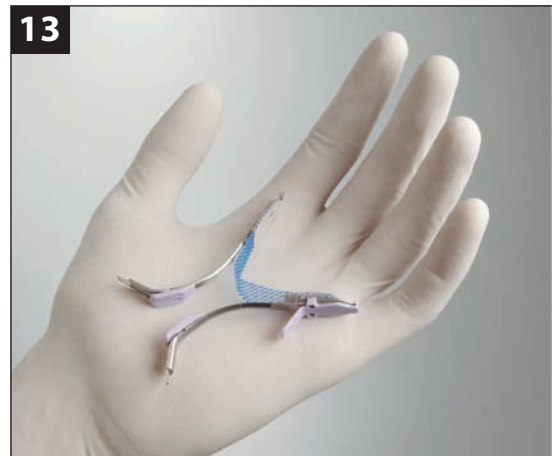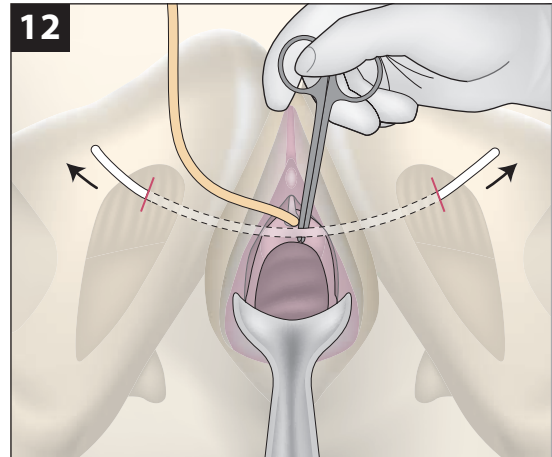


as the needle tip apparently is directed away from the obturator vessels and nerves. The needle tip is under direct finger guidance with the vaginal finger into the vaginal incision protecting the urethra and bladder.

Early data shows promising results and cure rates in the range of retropubic tension-free tape slings and therefore the procedure is gaining popularity in Europe and the US.

### THE GYNECARE TVT SECUR™ SYSTEM

The GYNECARE TVT SECUR™ System is a device used in a minimally invasive procedure to treat female stress urinary incontinence (SUI) (Figure 13). The mesh tape is introduced to the patient using a novel “attach and release” mechanism that allows for stable and controlled placement, resulting in no skin exits. Absorbable fixation tips made of VICRYL® (polyglactin 910) knitted mesh and PDS® (polydioxanone) suture yarn provide mechanical fixation until complete tissue ingrowth occurs. The reduced length of the mesh is designed to allow the surgeon to avoid proximity to the bowel and major vessels or nerves. In addition, the device does not require the use of needles or anatomical guides.



## SUGGESTED READING:

Ulmsten U, Petros P. Intravaginal slingplasty (IVS): an ambulatory surgical procedure for treatment of female urinary incontinence. *Scand J Urol Nephrol*. 1995;29:75-82

Kohli N, Lucente V, McKinney T, Miklos JR, Garely A, Karram MM. Tension-free Vaginal Tape (TVT) for the treatment of stress urinary incontinence: The initial North American experience. *Int Urogynecol J* 1999;(10 suppl):S1-S914

Kohli N, Miklos JR, Lucente V. Tension-free vaginal tape: a minimally invasive technique for treating female SUI. *Cont OB/Gyn* 1999 May:25-35

Nilsson CG, Kuuva N, Falconer C, Rezapour M, Ulmsten U. Long-term results of the tension-free vaginal tape procedure for surgical treatment of female stress urinary incontinence. *Int Urogynecol J* 2001;(suppl 2):S5-8

Rezapour M, Ulmsten U. Tension-free vaginal tape (TVT) in women with recurrent stress urinary incontinence-a long term follow-up. *Int Urogynecol J* 2001;(suppl 2):S9-11

Rardin CR, Kohli N, Miklos JR, Moore RD, Rosenblatt PL. Tension-free vaginal tape: outcomes among women with primary versus recurrent stress urinary incontinence. *Obstet Gynecol* 2002 Nov;100:893-97

Rezapour M, Falconer C, Ulmsten U. Tension-free vaginal tape (TVT) in stress incontinent women with intrinsic sphincter deficiency (ISD)-a long term follow-up. *Int Urogynecol J* 2001;(suppl 2):S12-14

Rezapour M, Ulmsten U. Tension-Free vaginal tape (TVT) in women with recurrent stress urinary incontinence--a long-term follow up. *Int Urogynecol J Pelvic Floor Dysfunct*. 2001;12 Suppl 2:S9-11

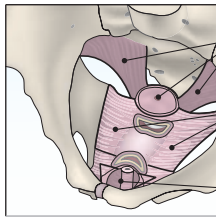
Dargent D, Bretones S, George P, Mellier G. Insertion of sub-urethral sling through the obturator membrane for treatment of female urinary incontinence. *Gynecol Obstet Fertil* 2002 Jul-Aug V;30(7-8):576-82

Fischer A, Find T, Zachman S, et al. Comparison of retropubic and outside-in transoburator sling systems for the cure of female genuine stress urinary incontinence. *Eur Urol* 2005 Nov;48(5):799-804

Mellier G, Benayed B, Bretones S, et al. Suburethral tape via the obturator route: is the TOT a simplification of the TVT? *Int Urogynecol J Pelvic Floor Dysfunct* 2004 Jul-Aug;15(4):227-32

Moore RD, Mellier G, Jacquetin, et al. Intraoperative safety and effectiveness of the transobturator hammock 3 using combined results from two prospective studies with 272 patients from nine countries. *ACOG Annual Mtg, San Fran, CA, May 2005*

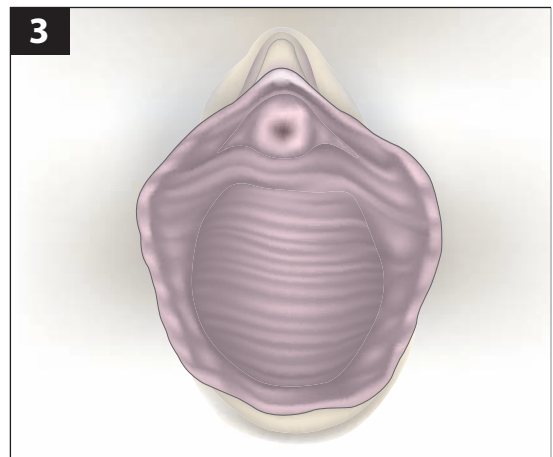
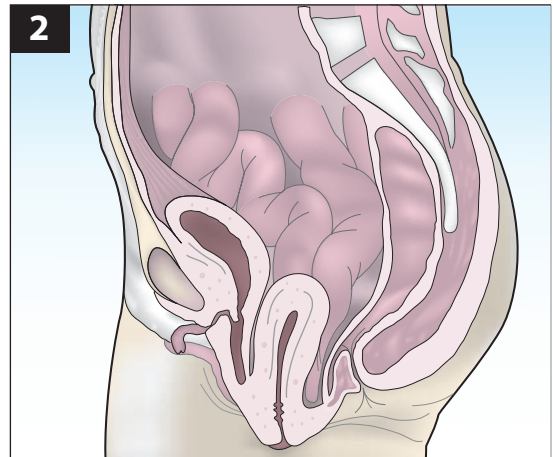
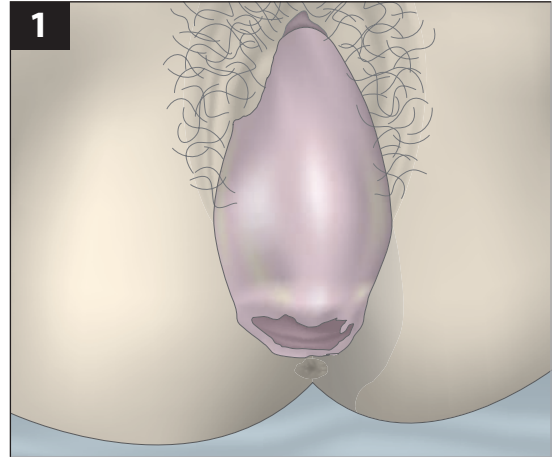
# PELVIC FLOOR SURGERY

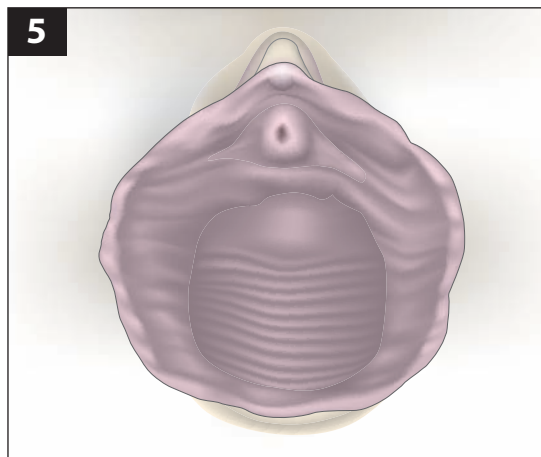
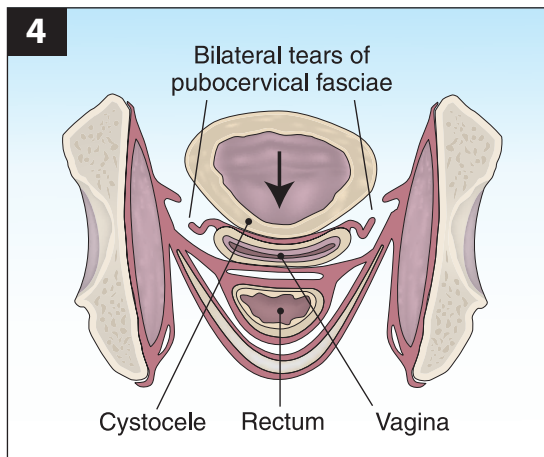


***Timothy B. McKinney, M.D.***

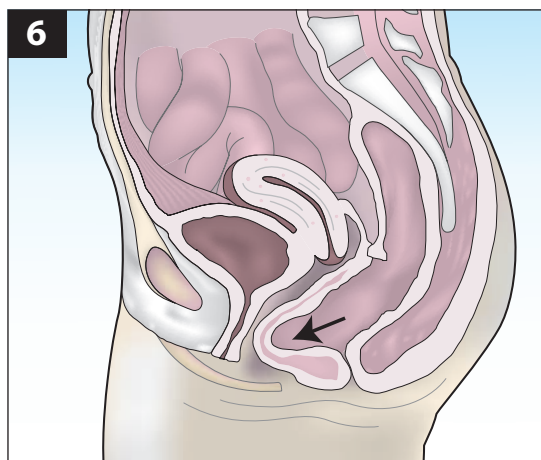
**T**hroughout hundreds of years of the earliest writings on operative gynecology, the problems of pelvic support have always been referred to as pelvic relaxation. Over the past 25 years, we have witnessed a major shift in our understanding of the concepts of pelvic floor support. Defects in these supports leads to a relationship which, if re-established, will generate the normal anatomical support of the internal pelvic viscera. Terms such as generalized stretching and attenuation have been employed commonly in almost all descriptions. The consensus has been that to repair all support tissue, it was necessary to correct the generalized stretching by way of plicating, resecting or shortening these attenuated tissues. The true causes of genital urinary prolapse are failures of the fibromuscular support system to confine the visceral organs within the pelvic cavity. When this fibromuscular support system of endopelvic fascia is damaged, visceral organ prolapse/herniation results. The anatomical proximity of all female genital organs to the lower urinary tract and alimentary tract predispose pelvic organ prolapse and can easily affect bladder, urethra and rectal function. This prolapse leads to voiding and defecating difficulties as well as sexual dysfunction in females (Figures 1 and 2).

Prior to 25 years ago the concepts of pelvic relaxation were rarely questioned. Cullen Richardson, in his manuscript “A New Look at Pelvic Relaxation” published in 1976 in the *American Journal of Obstetrics and Gynecology*, fostered a new understanding of pelvic floor defects. He stated that, “in all patients with cystoceles, there were isolated breaks in the pubocervical fascia”. He proposed that breaks in the endopelvic fascial hammock of the pubocervical fascia, in one or more of four areas, would yield an anterior compartment hernia (cystocele/anterior enterocele) (Figures 3 and 4). It was further suggested and observed that isolated breaks in other areas of endopelvic fascia accounted for all other support defects. These findings of isolated breaks in the endopelvic fascia are the key to pelvic floor support and need to be addressed during any kind of reparative pelvic surgery. Isolated breaks in the rectovaginal septum cause rectoceles as well as (Figures 5 and 6) breaks between the rectovaginal septum and pubocervical fascia, giving rise to enteroceles (Figure 7). It has been demonstrated that isolated breaks in the uterosacral ligament component of this network cause vaginal vault prolapse. This work was first performed extensively on cadaveric models, then moved to patients and, finally, was demonstrated on MRI studies. Today, it is generally accepted that essentially all support defects represent a break or breaks in the endopelvic fascial network. These breaks, as well as neuromuscular damage, combine to cause all pelvic support problems in the female patient. When these breaks in support



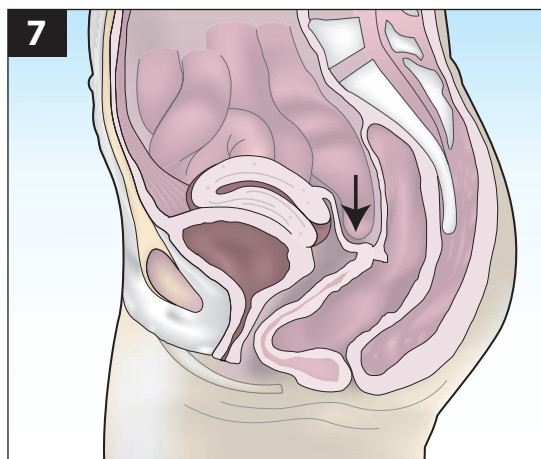


have occurred and the normal anatomical relationships are disrupted, physiologic dysfunctions such as urinary and fecal incontinence and prolapse in the pelvic organs can ensue. The critical relationships of the pelvis rely heavily on the integrity of the structural elements, namely bones, ligaments, muscles and endopelvic fascia. It is imperative that in performing any reparative pelvic surgery that anatomical concepts are well understood before embarking on surgical correction of the problem.



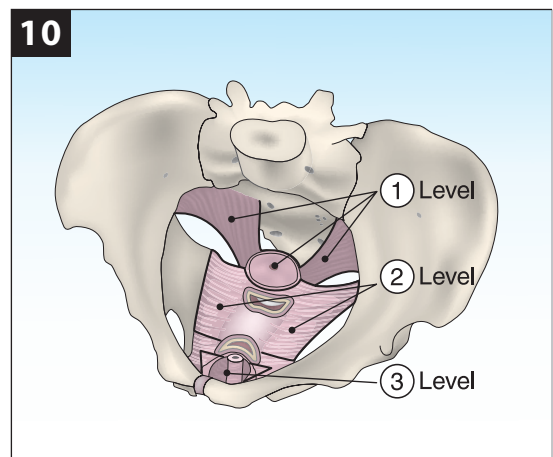
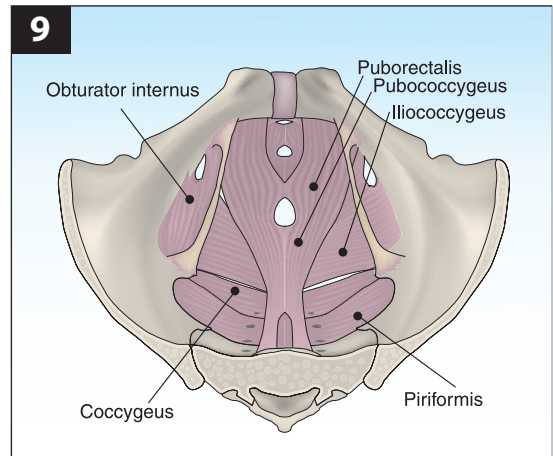
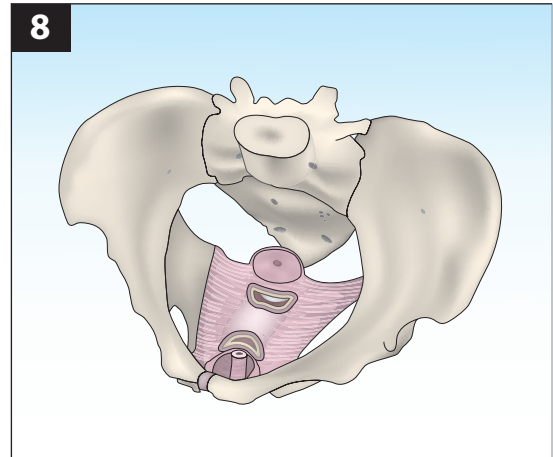
## ANATOMY OF PELVIC SUPPORT

Various bulges we encounter in the vagina, cystoceles, urethroceles, uterine prolapse, enteroceles and rectoceles all represent some failure of the pelvic floor to support one or more of the visceral structures resting upon or contained within it. The pelvic floor acts as a unit and should be thought of that way. It is divided into three layers of support from the inside out: the endopelvic fascial net-



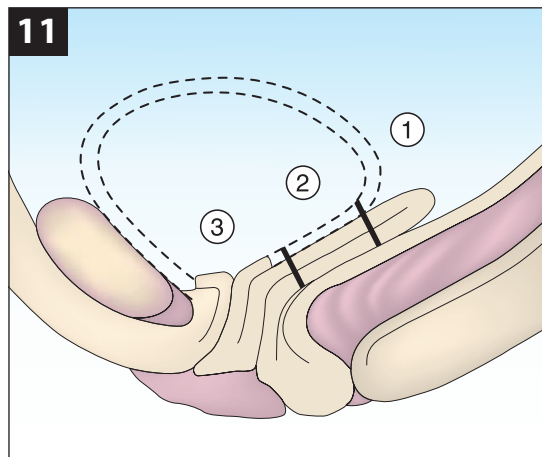
work (Figure 8), the striated muscles of the pelvic diaphragm and, lastly, the urogenital diaphragm and bony pelvis (Figure 9). Although the bony superstructure surrounding the pelvis is in itself a great support for pelvic organs, it is truly the muscular and fascial structures that lie at the bottom that act as the strongest support layers. This combination of the connective tissue endopelvic fascia and the striated muscle pelvic diaphragm are responsible for the bulk of normal support. The mechanism of failure is always from the inside out in organ prolapse. Therefore, in all major prolapses there are isolated breaks in the innermost layer or endopelvic fascia.

Surgically we need to use these endopelvic fascial structures, the uterosacral ligament complex, pubocervical fascia and rectovaginal fascia in all of our repair procedures. The clinical identification of these defects allows for the appropriate repair. When contemplating the various supportive structures, it is helpful to consider the vagina as a flattened fibromuscular tube lined with vaginal epithelium. The top of the tube is supported by the pubocervical fascia. The bottom is the rectovaginal fascia or septum. The top of the tube, as well as the uterus, are supported above the pelvic diaphragm by structures identified as the cardinal/uterosacral ligament complex. The uterosacral ligaments represent the level one (I) support of endopelvic fascia as described by John DeLancey. The mid-portion of the endopelvic fascia support or level (II), attaches the vagina to the levator ani muscles from the ischial spines



to the urogenital diaphragm. The anterior vaginal wall, pubocervical fascia, as well as the posterior vaginal wall, attach laterally at the same spot, the arcus tendineus ligament, and form a restraining layer that prevents the bladder and rectum from protruding into the vagina (Figure 10).

On the distal end of the tube, DeLancey level (III), there is a fusion with the urogenital diaphragm and perineal body (Figure 11). In the normally functioning pelvis, the levator ani muscles are always contracted keeping the pelvic floor closed and allowing for minimal exposure of pressure on the endopelvic fascia. The endopelvic fascia network simply suspends the organs in their proper position above the levator ani muscles. This interaction between the pelvic floor muscles and fascia is critical to the proper pelvic floor support and function. If the pelvic floor muscles are damaged or relaxed for prolonged periods of time, increases in intraabdominal pressure and gravity can damage the underlying endopelvic fascia or expose weaknesses in the fascia. It is these defects in the endopelvic fascia in conjunction with poorly functioning levator ani muscles that result in genital organ prolapse. In this chapter, we will describe surgical corrections that are geared at reconstruction of these endopelvic fascial defects. How we treat the levator ani problem greatly affects the long-term outcomes of our surgeries. Therefore, all patients that undergo pelvic floor reconstruction should be placed on some form of pelvic floor rehabilitation postoperatively much like the orthopedic surgeon



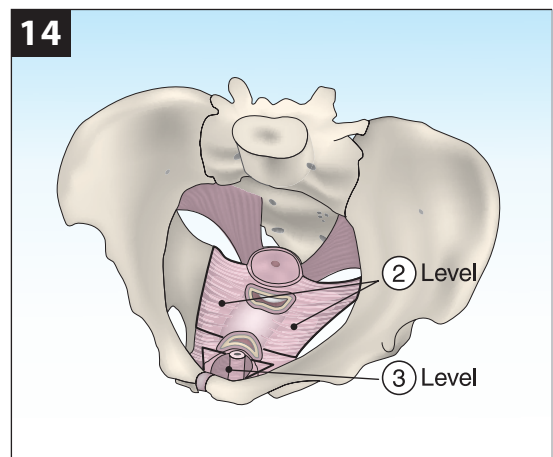
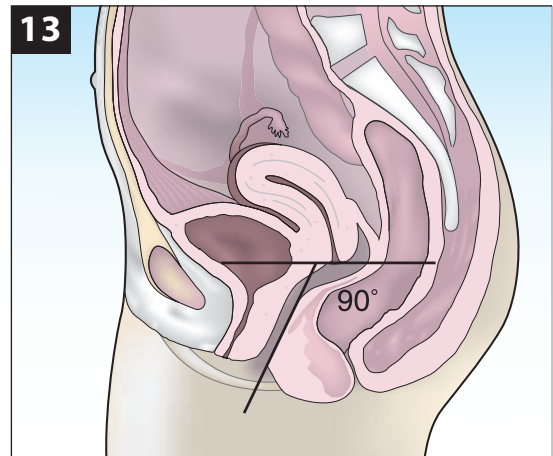
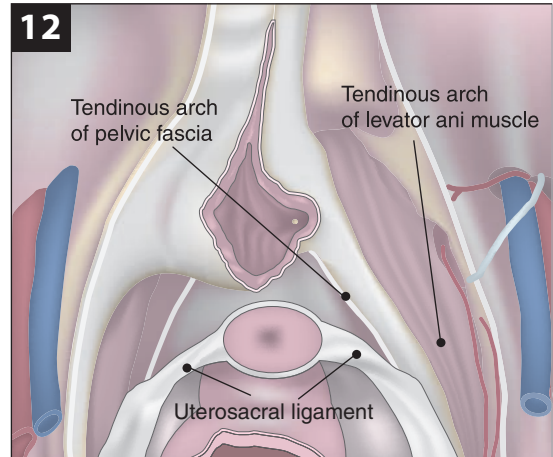
would require after a knee replacement. We use biofeedback and good estrogenization to achieve this goal.

## ENDOPELVIC FASCIA

Since the endopelvic fascia is the single most important element responsible for the maintenance of the normal anatomical relationship, it will be these layers that we emphasize most at this juncture. The endopelvic fascia is a skeletal matrix made up of a meshwork of collagen, elastin and smooth muscle (Figure 12). The endopelvic fascia serves two important purposes: first, to support the pelvic viscera in a proper orientation. In a standing female, the bladder, upper 2/3rds of the vagina and rectum lie in the horizontal axis thus, the endopelvic fascia serves as support (Figure 13). This mechanism is critical in preventing prolapse of organs through the urogenital levator hiatus. The mechanism by which this works to maintain organ position is that during times of intraabdominal pressure, a perpendicular force is exerted



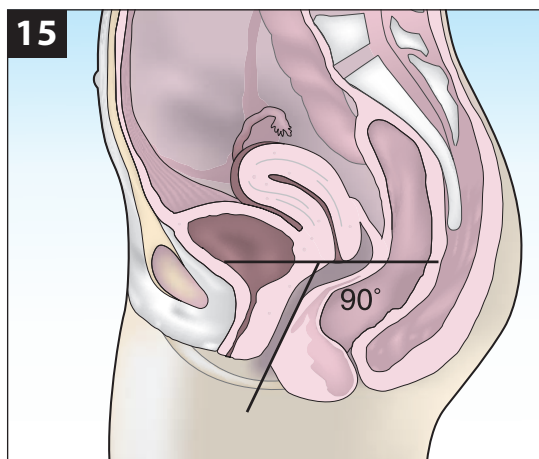
against the vagina and pelvic viscera. Simultaneously, the contracting levator ani plate elevates the pelvic floor pinning organs and entrapping them in a flapper valve mechanism preventing organ prolapse. It is this mechanism that we aim to re-establish during our surgical reconstruction. The second purpose of the endopelvic fascia is to envelope and support blood vessels, visceral nerves and lymphatics as they course through the pelvis. The first support axis, DeLancey's level I, represents the upper vertical axis, and is delineated by the cardinal-uterosacral ligament complex holding the pelvic viscera horizontally over the levator plate. The uterosacral ligament does not contain any of the major blood supply or ureters. This structure represents a complex of endopelvic fascia beginning on the sacrum at the lateral aspect of S2, 3 and 4 and extends to fuse with the vagina and the levator ani muscles below. Clinically, they cannot be seen or palpated unless tension is applied to their distal margins. Therein lies the problem with their identification and utilization in repair of significant uterine and vaginal vault prolapse where the attachment has been ruptured. Cullen Richardson, et al demonstrated that the pelvic connective tissue is more likely to be damaged by rupture than by stretching. Richardson and Say presented a paper in 1996 at the Society of Gynecological Surgeons on the laparoscopic use of the uterosacral ligaments in the repair of uterine and vaginal vault prolapse in 46 consecutive patients. The uterosacral ligaments were identified in these patients with no evidence of uterosacral ligament attenuati-



ated. We utilize the uterosacral ligaments in all our surgical repairs whether it is laparoscopic, vaginal or abdominal for our level one support. The uterosacral ligaments provide bilateral attachment of the upper end of the vagina and uterus to prevent prolapse downward through the urogenital hiatus. The advantage to using these ligaments is that it allows free mobility of the attached vagina laterally and superiorly, which is so essential in proper sexual function. These ligaments suspend the vagina to the level of the ischial spine.

The second support axis or DeLancey's level II is a horizontal axis from the ischial spine to the posterior aspect of the pubic bone. The paravaginal or lateral supports of the bladder, upper 2/3rds of the vagina, and rectum are derived from this axis. They are supported by the pubocervical fascia anteriorly, and the rectovaginal septum posteriorly which are attached laterally to the arcus tendineus ligament or white line (Figure 14). These levels can be approached quite readily laparoscopically both repairing the paravaginal defects anteriorly, as well as the rectovaginal septum posteriorly.

The third support axis, DeLancey's level III, is responsible for the almost vertical orientation of the urethra, lower third of the vagina, and anal canal. It travels perpendicularly to the urogenital triangles. The lower 1/3rd of the vagina passes through the levator hiatus, forming an almost 90° angle due to the puborectalis muscle posteriorly, and the pubocervical fascia hammock anteriorly. This allows for an almost 90° angle for the urethra to

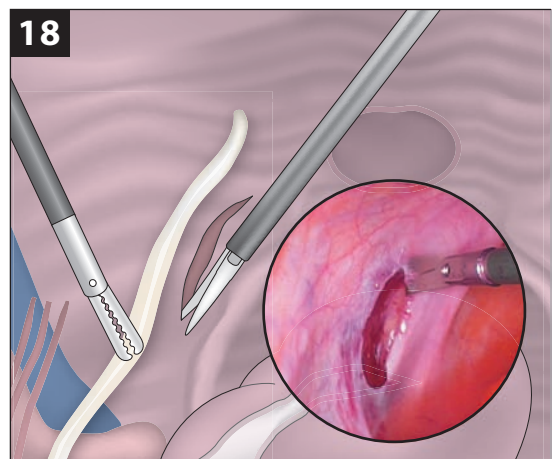
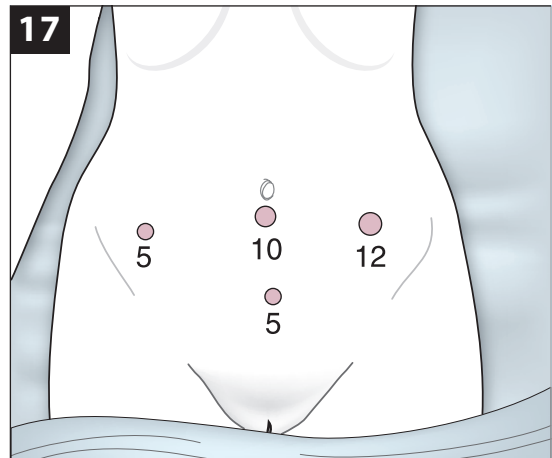
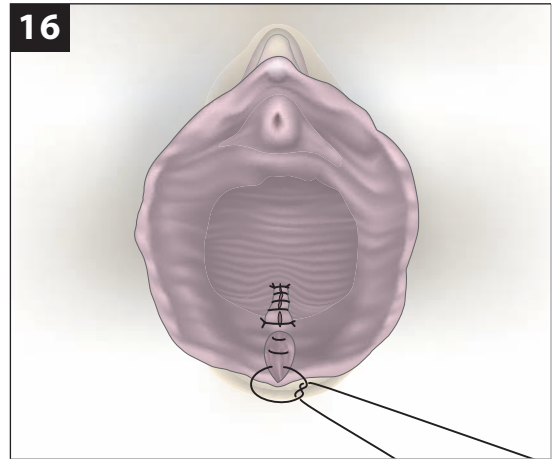


descend through and contributes greatly to the continence mechanism (Figure 15). Posterior level III defects are best handled vaginally and are extremely difficult to accomplish laparoscopically, although not impossible.

## LAPAROSCOPIC UTEROSACRAL LIGAMENT SUSPENSION

The patient is placed in the low semi-lithotomy position allowing laparoscopic instruments to be rotated 360° around the abdomen. Kendal boots and Allen stirrups are used exclusively for patient's safety. Examination under anesthesia identifies all site-specific defects that need to be addressed. A low transverse defect, when noted on the perineal body of the rectovaginal septal area, would be repaired first (Figure 16). The dissection of the rectovaginal septum free from the vaginal epithelium to the vaginal apex, allows for decreased work performed on the laparoscopic side to identify the rectovaginal septum. In the case of poor rectovaginal

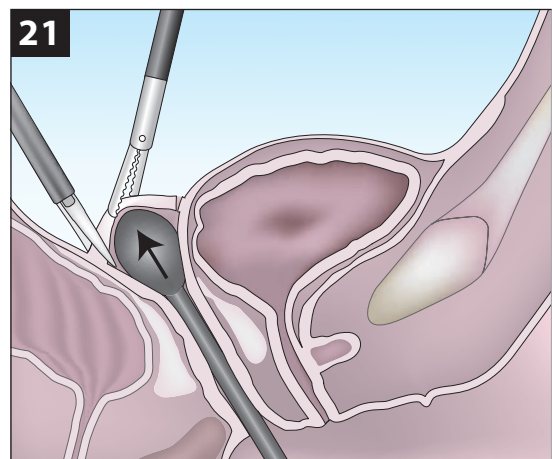
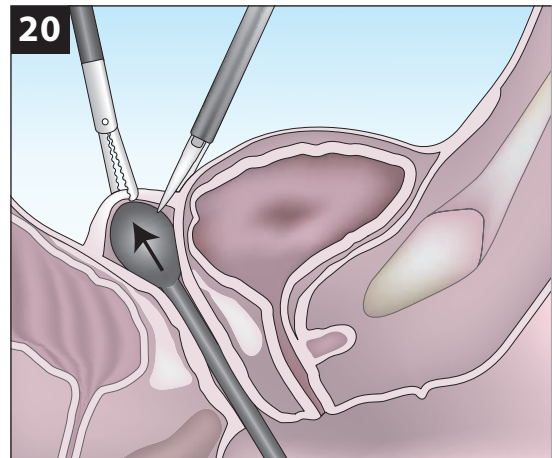
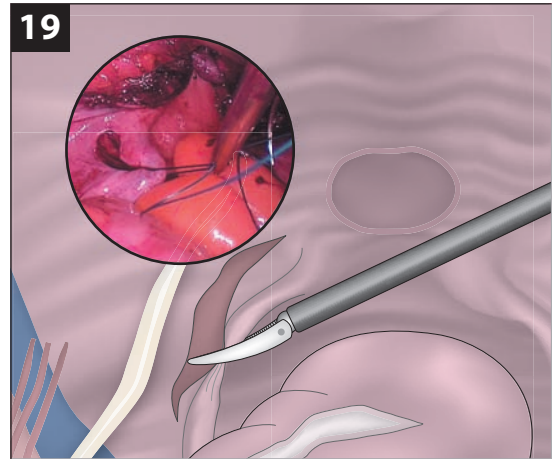
septal fascia, polypropylene mesh or cadaveric fascia can be substituted and attached to the perineal body and the levator muscles laterally and the vaginal mucosa closed. (See chapter 26) When performing the laparoscopic posterior dissection we can then attach the high defect to the uterosacral ligament to complete the posterior repair. A three-way Foley catheter is placed into the bladder for drainage. We begin by making a vertical incision within the umbilicus and introducing a 10-12 mm optiview type of trocar which allows us to identify and count the layers entering into the abdominal cavity under direct visualization similar to open laparoscopy. Prior to making each incision, they are injected with 1% lidocaine with epinephrine. The abdomen is insufflated to a level of 15 mmHg of pressure with a humidified heated CO<sub>2</sub> insufflator. A series of three suprapubic ports are placed, one just in a suprapubic hair-line area (5 mm), the other two just lateral to transversalis fascia and about the level of McBurney's point (1-12 mm and 1-5 mm) (Figure 17). The patient is then placed in a steep Trendelenburg position. A thorough bowel prep is used on all patients, thus, debulking the bowel for better visualization and preparing for possible bowel injury. Importantly, nitrous oxide should not be used because it dilates/inflates the bowel. In a vaginal vault suspension, the first step should be to identify the ureters bilaterally, as in any surgical case. The vaginal vault is exposed and approximated by using either a vaginal blunt manipulator or an EEA rectal sizer. Identification of the uterosacral ligaments is accomplished by locating the



ureter and making a releasing incision with the laparoscopic scissors or the harmonic scalpel just underneath the ureter and extending down the line of the ureter into the deep pelvis (Figure 18).

Palpation of the anatomy vaginally reveals where the ischial spine is found in relation to the ureter and will help locate the uterosacral ligaments. A semi-traumatic grasper can be utilized to grab the uterosacral ligament structures including the peritoneal wall as well as all the tissue dissected free from the ureter downward towards the ischial spine area. The uterosacral ligament is then elevated towards the anterior abdominal wall and, with another instrument, you can actually palpate and pluck the tensed uterosacral ligaments (Figure 19). If this tissue stretches, you have not identified the ligament appropriately, and should continue to grasp the tissue until finding the true ligament. In my experience of performing well over 300 cases of vault suspension, the uterosacral ligaments were found in every patient, except one who had a radical hysterectomy. Next, the bladder should be mobilized off the vagina. A three-way Foley catheter is then filled with 60-200 cc of saline expanding the bladder and noting the location of the vesical peritoneal fold. The bladder is mobilized all the way down to the pillars on either side exposing the pubo-cervical fascia at this level (Figure 20).

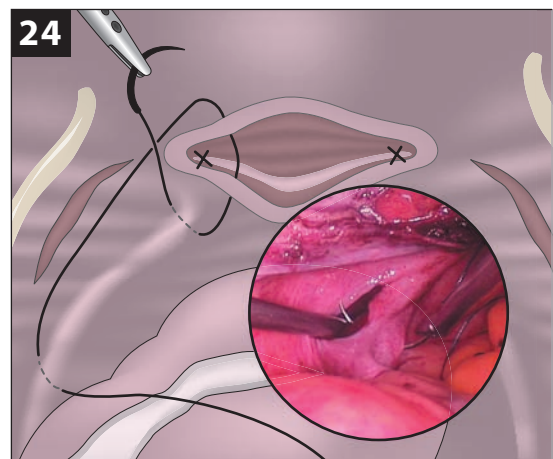
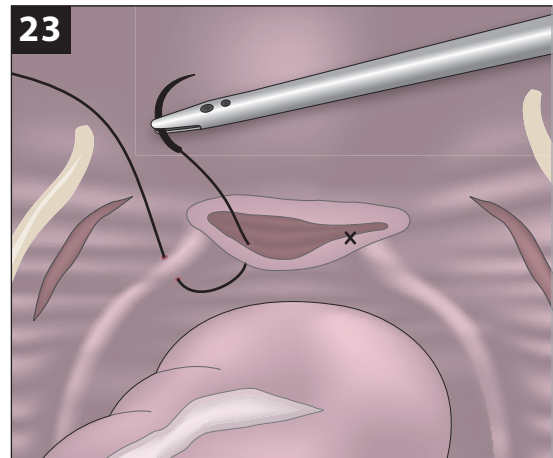
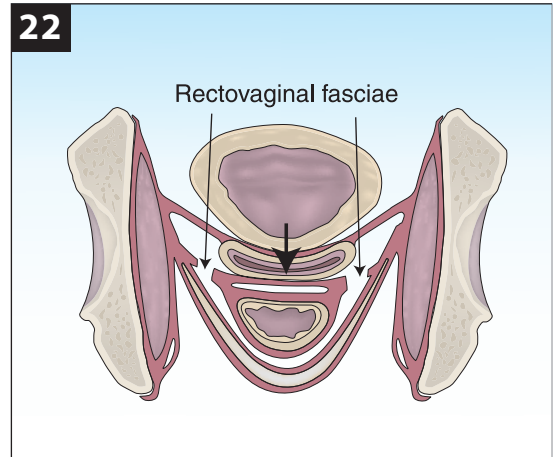
Attention is then directed posterior to the vagina where the peritoneum is entered and dissection is conducted to identify the rectovaginal septum (Figure 21). This layer should be avascular and, therefore, should separate fairly easily. The



dissection is carried out laterally until you reach the levator muscles. Once again, it is often helpful to perform a vaginal or rectal exam at this time to identify the ischial spine as well as any particular site-specific defects that may exist. Once the dissection is completed and identification of a site-specific defect is identified, grab the actual rectovaginal septum and reapproximate it back to its normal support area. While holding it in the correct position, again perform a rectovaginal exam and identify whether this corrects the defect. With this accomplished, we repair the rectovaginal septal defects. We place interrupted stitches from the arcus tendineus ligament to the rectovaginal septum building the rectovaginal septum back to the ischial spine (Figure 22).

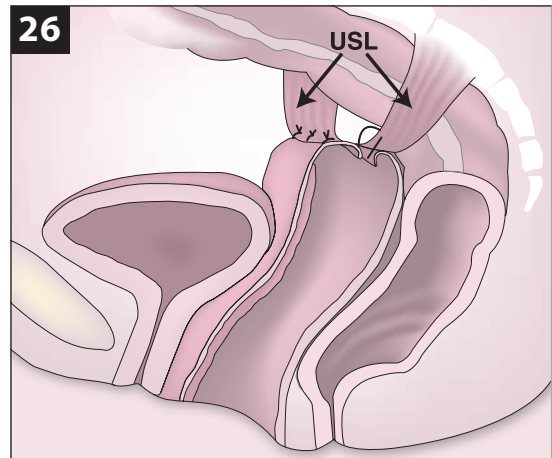
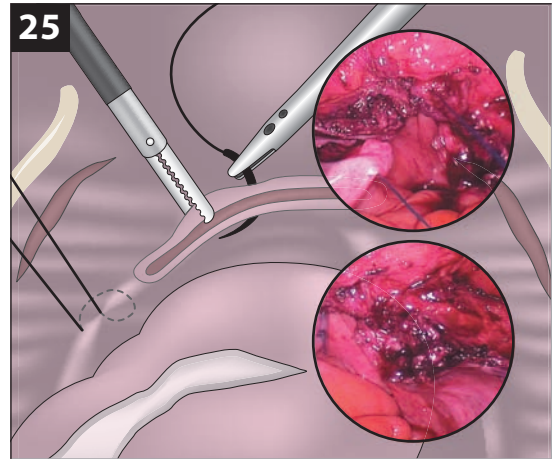
This needs to be performed bilaterally and can be tested again with a rectal exam. Once the rectovaginal septum is intact, a 2-0 Ethibond is placed through the uterosacral ligament on the left side and then placed into the rectovaginal septum and then back to the uterosacral ligament and tied down securely (Figure 23).

We perform this again on the left side forming an individual attachment of the rectovaginal septum into the uterosacral ligament at the level of the ischial spine and the top of the uterosacral ligament. A stitch is then placed through the uterosacral ligament very low at its origin at the sacrum, then back up anteriorly to the pubocervical fascia and then back posteriorly to the rectovaginal septum and then back to the uterosacral ligament (Figure 24).



Before tying down the stitch, a second stitch is placed on the right side through the uterosacral ligament, pubocervical fascia, rectovaginal septum, and back to the uterosacral ligament. These sutures are passed out through the opposite port on the right side once all throws have been made. This reduces the risk of entanglement while throwing the knots. At this time, a third stitch is placed through the pubocervical fascia and rectovaginal septum in the midline. The sutures are then tied down securely thus closing any of the enterocele defects (Figure 25). It is rare that any vaginal epithelium needs removing during the course of this technique and we find that most of the vaginal epithelium will remold itself into the exoskeleton of the vagina within 6 weeks. The sutures are then tied securely closing the enterocele and creating the vault suspension (Figure 26).

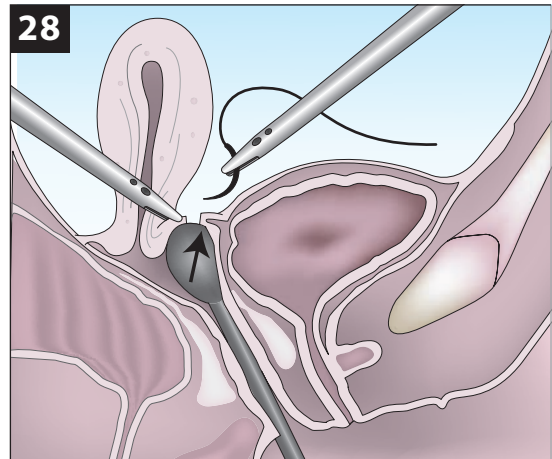
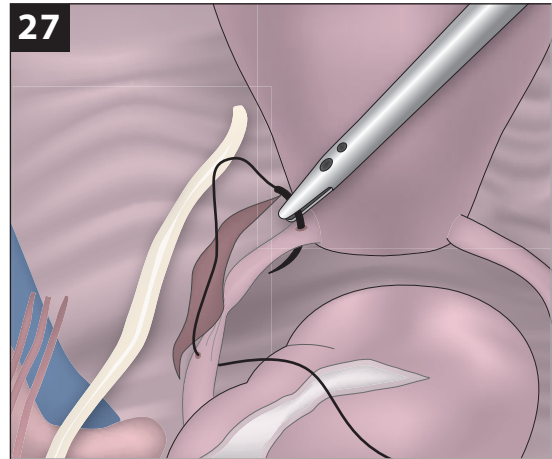
A vaginal probe is then re-inserted to check if it can be pushed through the vaginal apex. If there are any further defects, sequential stitches are placed to gain the proper support. Never in the procedure are the uterosacral ligaments to be plicated across the midline. We feel that plicating the uterosacral ligaments will close down the cul-de-sac and will create an increased risk of problems in the future. These include a risk of the vaginal vault being torn down by the propulsion of bowel contents peristalsing and ramming into the suture anastomosis putting undue excess pressure on the vault. The cul-de-sac is designed to fill with stool and any compromise of this



space will either cause pain, increased constipation, or increased risk of failure from the peristalsis pushing against the repair. Once the vault suspension is complete, sterile irrigation is performed. An underwater examination or decreasing the air pressure to approximately 6 mmHg, should identify any bleeders. Cystoscopy is usually performed at this point to ensure that ureters have not been compromised and that there have been no subsequent stitches placed into

the bladder. At this time, if there are any paravaginal defects, an incision is then made in the peritoneum and the space of Retzius is opened and direct visualization of the ischial spine and the entire arcus tendineus ligament and pubocervical fascia defects are identified and repaired directly utilizing a 2-0 Ethibond with interrupted stitches as described in chapter 23. A retropubic urethropexy, TVT™ or TOT™ (Gynecare-Johnson & Johnson Inc., Somerville, NJ) or other incontinence procedure of choice, can be accomplished as well if needed. The large ports are then closed with a 0 Vicryl placed through the abdominal cavity utilizing a Carter Thompson needle-nosed grasper to pass the suture through the fascia, thus closing the port entry.

If the uterus is intended to remain in situ, this entire procedure is performed with interrupted stitches from the uterosacral ligament into the cervical ring at the level of attachment where uterosacral ligaments originate from the cervix (Figure 27). This would be accomplished bilaterally with sequential interrupted stitches into this high cervical ring area. A bladder flap is then developed and the bladder mobilized off the cervix and the vaginal area down to the level of the bladder pillars. The pubocervical fascia is identified and stitches placed through the pubocervical fascia and then reattached back into the cervical ring at the level of the transverse defect area (Figure 28). These are all tied off and secured. Postoperatively, patients are sent to recovery with a Foley catheter in



place and given analgesia by way of a PCA and then oral analgesia once a diet is tolerated. The patient's Foley catheter is usually removed on postoperative day 1 with a bladder trial. The bladder is filled with a known quantity of fluid, between 200-400 cc until the patient feels urgency to void. The catheter is removed and the patient asked to walk to the bathroom to void. Knowing the volume of urine infused, we can measure the amount voided, and by simple subtrac-

tion, know the post-void residual urine. Once over 50% of the volume is voided, the catheter is left out. The majority of patients are discharged on day 0 or day

1. They are seen at follow-up 2 and 6 weeks postop and are sent home with pain meds, 3 days of a prophylactic antibiotic, and Pyridium.



## SUGGESTED READING:

Shull BL, Bachofen C, Coates KW, Kuehl TJ. A transvaginal approach to repair of apical and other associated sites of pelvic organ prolapse with uterosacral ligaments. *Am J Obstet Gynecol* 2000; 183:1365–74.

Jenkins II VR. Uterosacral ligament fixation for vaginal vault suspension in uterine and vaginal vault prolapse. *Am J Obstet Gynecol* 1997;177:1337–44

Paraiso MFR, Walters MD. Laparoscopic surgery for stress urinary incontinence and pelvic organ prolapse. *Clin Obstet Gynecol* 2005 Sep;48(3):724–36

Paraiso MFR, Walters MD. Laparoscopic pelvic reconstructive surgery. *Clin Obstet Gynecol* 2000 Sep;43(3):594–603.

Miklos JR, Moore RD, Kohli N. Laparoscopic surgery for pelvic support defects. *Curr Opin Obstet Gynecol* 2002;14:387–395

Gadonneix P, Ercoli A, Salet-Lizee D, Cotelle O, Bolner B, Van Den Akker M, Villet R. Laparoscopic sacrocolpopexy with two separate meshes along the anterior and posterior vaginal walls for multicompartiment pelvic organ prolapse. *J Am Assoc Gynecol Laparosc* 2004;11(1):29–35

Benson JT, Lucente V, McClellan E. Vaginal versus abdominal reconstructive surgery for the treatment of pelvic support defects: A prospective randomized study with long-term outcome evaluation. *Am J Obstet Gynecol* 1996;175:1418–22

Paraiso MFR, Falcone T, Walters MD. Laparoscopic surgery for enterocele, vaginal apex prolapse and rectocele. *Int Urogynecol J* 1999;10:223–229

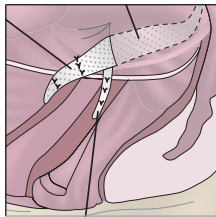
Cundiff GW, Harris RL, Coates K, Low VHS, Bump RC, Addison WA. Abdominal sacral colpoperineopexy: A new approach for correction of posterior compartment defects and perineal descent associated with vaginal vault prolapse. *Am J Obstet Gynecol* 1997;177:1345–55

Sze EHM, Kohli N, Miklos JR, Roat T, Karram MM. A retrospective comparison of abdominal sacrocolpopexy with burch colposuspension versus sacrospinous fixation with transvaginal needle suspension for the management of vaginal vault prolapse and coexisting stress incontinence. *Int Urogynecol J* 1999;10:390–393

Ng CCM, MD, Han WHC. Comparison of effectiveness of vaginal and abdominal routes in treating severe uterovaginal or vault prolapse. *Singapore Med J* 2004;45(10):475–481

Nezhat CH, Nezhat F, Nezhat C. Laparoscopic sacral colpopexy for vaginal vault prolapse. *Obstet Gynecol* 1994;84:885–8

# LAPAROSCOPIC SACRALCOLPOPEXY AND ENTEROCELE REPAIR WITH MESH



*Robert D. Moore, D.D.*

*John R. Miklos, M.D.*

## INTRODUCTION

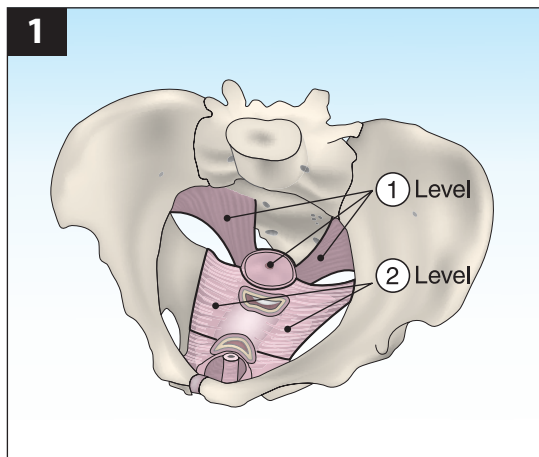
**T**he anatomy, pathophysiology, and treatment of pelvic organ prolapse has significantly evolved over the last decade with increasing understanding of anatomy and development of minimally invasive surgical procedures. Although support for the pelvic viscera, the vagina, and neighboring structures involves a complex interplay between muscles, fascia, nerve supply, and appropriate anatomic orientation, the endopelvic fascia and pelvic floor muscles provide most of the support function in the female pelvis. Laparoscopic reconstructive pelvic surgery requires a thorough knowledge of pelvic floor anatomy and its supportive components before repair of defective anatomy is attempted. This chapter reviews the anatomy and laparoscopic repair of vaginal vault prolapse and enterocele with Y-mesh sacralcolpopexy.

## ANATOMY OF PELVIC SUPPORT

### ENDOPELVIC FASCIA

To understand the pelvic support system of the female pelvic organs, it is useful to subdivide the pelvic support system into 3 axes: 1) the upper vertical axis, 2) the midhorizontal axis, and 3) the lower vertical axis. The endopelvic fascia--a network of connective tissue and smooth muscle--constitutes the physical matrix which envelops the pelvic viscera and maintains the integrity of the axes supporting the bladder, urethra, uterus, vagina, and rectum in their respective anatomic relationships.

DeLancey further describes the 3 levels of support axes as follows: level 1 - superior suspension of the vagina to the cardinal-uterosacral complex; level 2 - lateral attachment of the upper 2/3 of the vagina; and level 3 - distal fusion of the vagina into the urogenital diaphragm and perineal body. Level 1--paracolpium suspends the vaginal apex from the lateral pelvic sidewall via the uterosacral-cardinal complex. Level 2--the anterior vaginal wall is attached laterally to arcus tendineus fascia pelvis and the posterior vaginal wall is attached laterally to the fascia overlying the levator ani muscle. In this support system, the endopelvic fascia system is thought to be continuous, extending from the origin of the cardinal-uterosacral complex to the urogenital diaphragm, providing structural support to the vagina and adjacent organs (Figure 1). In this chapter we will be concentrating on Level 1 or apical support.

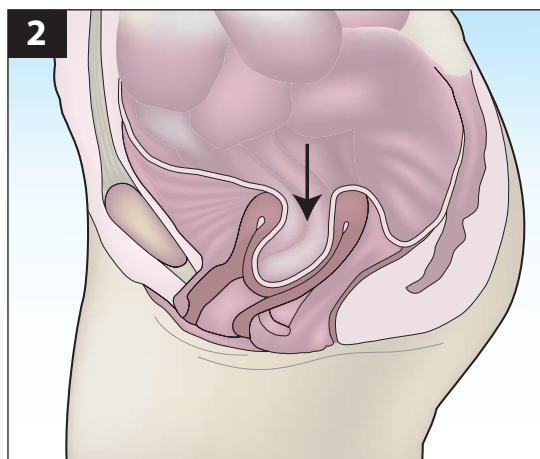


### LEVEL 1 – APICAL SUPPORT

The cardinal-uterosacral complex provides apical support by suspending the uterus and upper one third of the vagina to the bony sacrum. This complex can be described as two separate entities: the cardinal ligament and the uterosacral ligament. The cardinal ligament is a fascial sheath of collagen that envelops the internal iliac vessels and then continues along the uterine artery, merging into the visceral capsule of the cervix, lower uterine segment and upper vagina. The uterosacral ligament is denser and more prominent than the cardinal ligament. Collagen fibers of the uterosacral ligament fuse distally with the visceral fascia over the cervix, lower uterine segment, and upper vagina, forming the paracervical ring; proximally these fibers end at the presacral fascia overlying the second, third, and fourth sacral vertebrae. This complex appears to be the most supportive structure of the uterus and upper 1/3 of the vagina. Disruption of the car-

dinal-uterosacral complex may result in uterine descensus or vaginal vault (apex) prolapse. Likewise, the most common cause of vaginal vault prolapse is previous hysterectomy with failure to adequately reattach the cardinal-uterosacral complex to the pubocervical fascia and rectovaginal fascia at the vaginal cuff, intraoperatively.

An enterocele is defined as a pelvic floor hernia where the parietal peritoneum comes into direct contact with the vaginal epithelium with no intervening fascia. In normal pelvic supportive anatomy, the anterior pubocervical fascia, posterior rectovaginal fascia, cardinal-uterosacral ligaments and paracolpial fibers all converge, or fuse to form the pericervical ring. The integrity and continuity of these supportive tissues can be compromised in patients who have had a complete hysterectomy as previously described. An enterocele is likely to be directly related to a disruption of the fusion of the proximal margins of the pubocervical and rectovaginal fascia (Figure 2). Although vaginal mucosa may cover this defect, it is not supportive, which greatly increases the likelihood that an enterocele will eventually develop within the vaginal cavity. Though it is possible to have an enterocele without concurrent vaginal vault prolapse, the two defects usually occur concomitantly. Although the depth and overall anatomic configuration of the cul-de-sac have been implicated in the development of the enterocele, it has never been proven to be the primary etiology.



## **LEVEL I SUPPORT - LAPAROSCOPIC APPROACH TO ENTEROCELE REPAIR AND VAGINAL VAULT SUSPENSION**

### **SITE-SPECIFIC ENTEROCELE REPAIR & VAGINAL VAULT SUSPENSION**

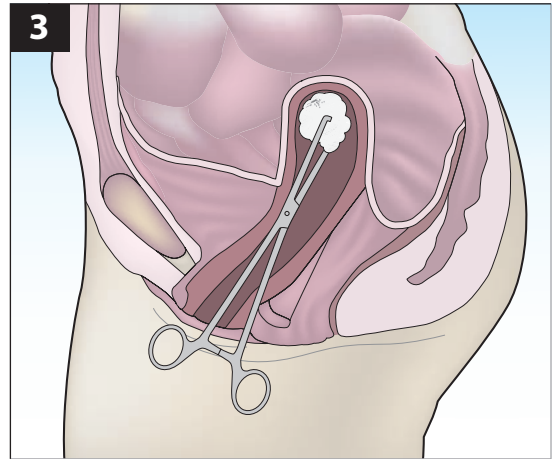
As previously mentioned, level 1 support involves the long paracolpial fibers which suspend the proximal vagina and cervicovaginal junction. The cardinal and uterosacral ligaments previously described merge with these fibers and attach to the pericervical ring. This network of connective tissue fibers and smooth muscle serves to prevent vaginal eversion. A disruption of the integrity of these fibers, as opposed to stretching, results in apical vaginal vault eversion. A disruption of the fascia at the vaginal cuff results in an enterocele formation.

Enterocele repair begins first by anatomically defining the fascia defect present that results in the herniation of

peritoneum and bowel through the apex of the vagina. An enterocele is defined as a pelvic hernia where the parietal peritoneum comes into direct contact with vaginal epithelium with no intervening fascia. The development of an enterocele is likely to be directly related to a disruption of the fusion of the proximal margins of the anterior pubocervical fascia and posterior rectovaginal fascia or failure to surgically reattach these two fascial margins at the time of vaginal cuff closure following hysterectomy. It is possible that the surgeon may not incorporate the apex of the pubocervical and or the rectovaginal fascia at the time of closure of the vaginal cuff. Instead the surgeon may be only incorporating vaginal mucosa and unintentionally neglecting the reattachment of the supportive fascial layers. Poor surgical closure or disruption at the apex of the pubocervical and rectovaginal fascia results in parietal peritoneum in direct contact with vaginal epithelium. Chronic rises of intraabdominal pressure will ultimately exploit this vaginal weakness with stretching of the peritoneum and vaginal mucosa and clinically evident symptomatic enterocele.

### LAPAROSCOPIC ENTEROCELE REPAIR

The technique of laparoscopic enterocele repair begins with identification of the vaginal vault apex, the proximal uterosacral ligaments and the course of the pelvic ureter. The identification of the vaginal vault and the delineation of the rectovaginal and pubocervical fascia are facilitated by the use of a vaginal probe. Using the vaginal probe (Figure 3), trac-



tion is placed cephalad and ventrally, causing the uterosacral ligaments to stretch so they can be identified and traced backward to their most proximal point of origin, lateral to the sacrum. In many cases the uterosacral ligaments are of very poor quality and/or very stretched out. Therefore, we believe that the utilization of mesh to suspend the apex and ultimately assist in enterocele repair shows superior cure rates compared to utilizing ligaments that have already failed. An apical enterocele is often encountered with vault prolapse. The vault is elevated up into the pelvis with an EEA sizer and the excess vaginal epithelium is identified (Figure 4).

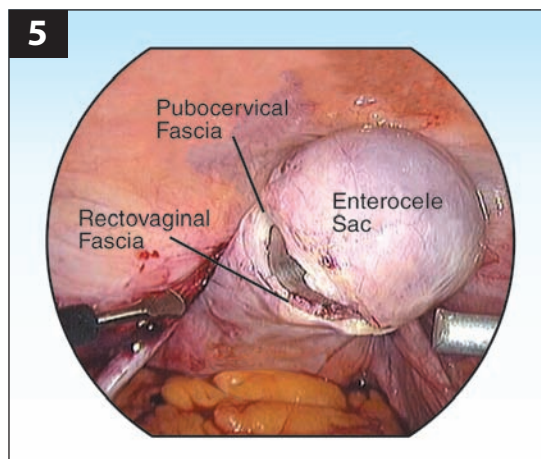
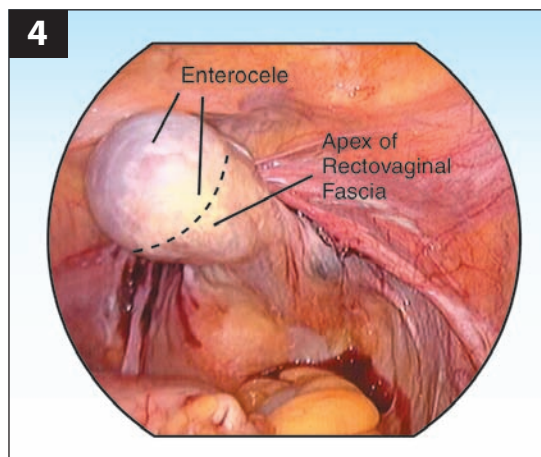
The peritoneum overlying the vaginal apex is incised to expose the pubocervical fascia anteriorly and the rectovaginal fascia posteriorly. If the edge of the bladder is difficult to identify, the bladder is retrograde filled with sterile water to help identify the edge and then the bladder is dissected off of the anterior apical portion of the vagina. Likewise if the recto-

vaginal space is difficult to identify, a rectal probe can be placed to identify the rectum and the peritoneum incised between the rectum and the vagina. The rectovaginal space can then be identified and the rectum dissected off the posterior wall of the vagina, almost all the way down to the perineal body. If the enterocele sac is large, it may be excised and the apical edges of the pubocervical and rectovaginal fascia should be exposed (Figure 5). The excess vaginal epithelium is excised to get down to the level of the pubocervical fascia anteriorly and the rectovaginal septum posteriorly. The cuff is then reapproximated with interrupted sutures. If the enterocele sac is smaller, the pubocervical fascia and rectovaginal septum can be reapproximated at the apex with plication sutures, therefore avoiding excision.

The enterocele repair is further supported by the placement of the Y-mesh over the apex of the vagina, as the anterior leaf goes approximately 1/3 of the way down the anterior vaginal wall and the posterior leaf, approximately 2/3 of the way down the posterior wall (ensuring attachment of the mesh to the pubocervical fascia anteriorly) and the rectovaginal fascia posterior.

#### LAPAROSCOPIC SACRAL COLPOPEXY

Abdominal sacral colpopexy remains one of the most successful operations for the treatment of vaginal vault prolapse with excellent results on long-term follow-up. If the surgeon utilizes laparoscopy as a means of surgical access and performs

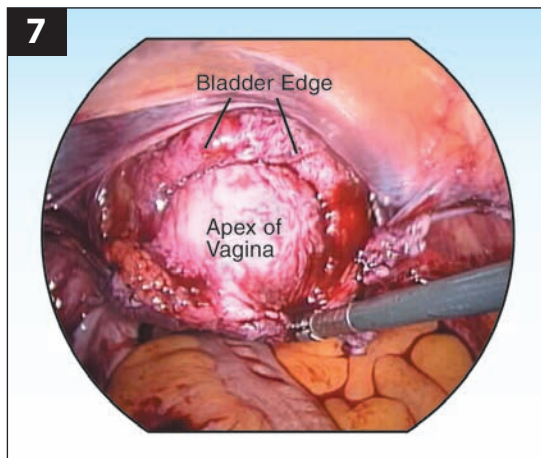
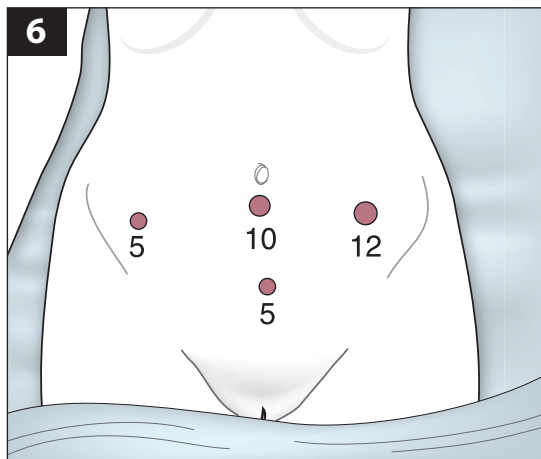


the sacral colpopexy in the same manner as in the open abdominal approach, operative cure rate should theoretically be equivalent.

The room set-up and patient positioning are exactly the same as we described in the Laparoscopic Paravaginal Repair and Burch Urethropexy chapter. The patient is placed in dorsal lithotomy position with adjustable Allen stirrups. A 3-way 16-Fr Foley catheter is placed for gravity drainage. Inflatable sequential

compression devices are placed on the patient's lower extremities for DVT prophylaxis. A 48-hour bowel prep is used for all of our laparoscopic patients. This helps decompress the bowel for better visualization and helps minimize risk of infection if bowel injury occurs. Two days prior to surgery the patient is placed on a full liquid diet (shakes, pudding, etc.), and the day prior to surgery only clear liquids are allowed. The afternoon prior to surgery the patient drinks 8 ounces of magnesium citrate to clean out the bowels. We also do not recommend the use of nitrous oxide for an anesthetic agent during laparoscopy because this can cause bowel distention during the case and increase risk of bowel injury.

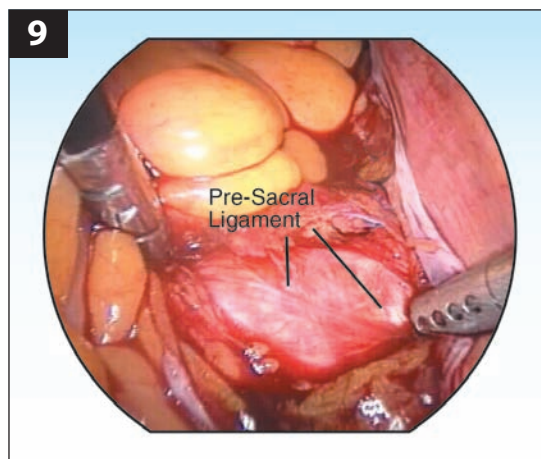
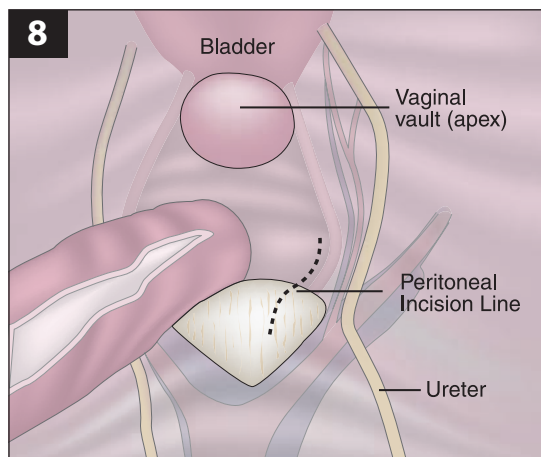
Port placement is based on the surgeon's preference, skill and acquired technique. We place our ports in an identical fashion as was described in the Laparoscopic Paravaginal Repair and Burch Urethropexy chapter. Briefly, we utilize a 10 mm suturing port in the left paramedian region, and two 5 mm ports, one in the suprapubic region and the other in the right paramedian region (Figure 6). The surgeon stands on the patient's left side and completes all needle passing, suturing, needle retrieving and knot tying by himself utilizing the left paramedian and suprapubic port. The assistant stands on the patient's right side and drives the camera and utilizes the right lower port for retraction, suction/irrigation, etc. Once the operative ports have been placed, the vagina is elevated with an EEA sizer and the peritoneum overlying the vaginal apex is dissected posteri-



only exposing the apex of the rectovaginal fascia. This dissection opens the rectovaginal space as described above and the dissection is taken down to within 3 cm of the perineal body (Figure 7). Any bleeding can be controlled with bipolar electrocautery or surgical clips. Next, anterior dissection is performed to delineate the apex of the pubocervical fascia by dissecting the bladder off of the anterior apex of the vagina. If the edge of the bladder is difficult to identify secondary to scar tissue, the bladder can be retro-

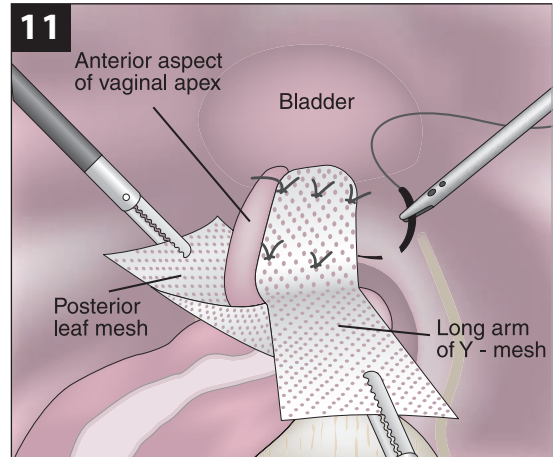
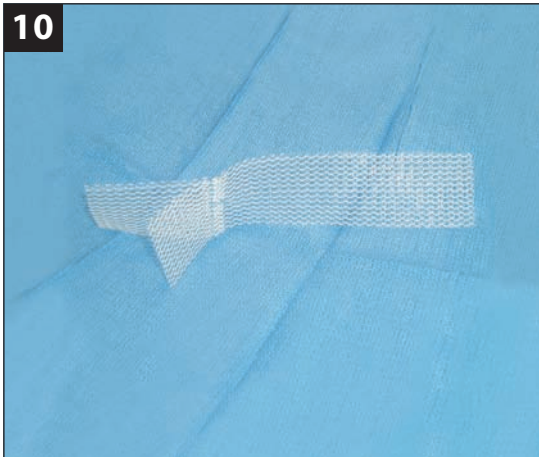
grade filled through the 3-way Foley catheter with sterile water and then the bladder can be carefully dissected off the anterior segment. We take this dissection approximately 1/3 to 1/2 way down the anterior wall. A separation between the rectovaginal and pubocervical fascia confirms an enterocele at the apex. If a small enterocele is present it should be repaired in a site-specific fashion by imbricating the stretched vaginal epithelium between the apical edges of the pubocervical and rectovaginal fascia. Permanent suture can be utilized in a continuous purse-string fashion or in interrupted fashion. A large enterocele should be resected (as shown in Figure 5) and the cuff reapproximated with absorbable sutures so the excessive vaginal epithelium is not utilized as a point of mesh attachment. Theoretically, suturing the mesh to the enterocele sac, instead of the more supportive pubocervical and rectovaginal fascia, may predispose the patient to an increased risk of mesh erosion, suture pullout and/or surgical failure.

Attention is then directed to the sacral promontory and the presacral space. The peritoneum overlying the sacral promontory is incised longitudinally and this peritoneal incision is extended to the cul-de-sac (Figure 8). A laparoscopic dissector is used to expose the anterior ligament of the sacral promontory through blunt dissection (Figure 9). The peritoneum on the sidewall is incised and freed up beneath the ureter so that the mesh can be retroperitonealized at the end of the case. Hemostasis is achieved using either coagulation or surgical clips.

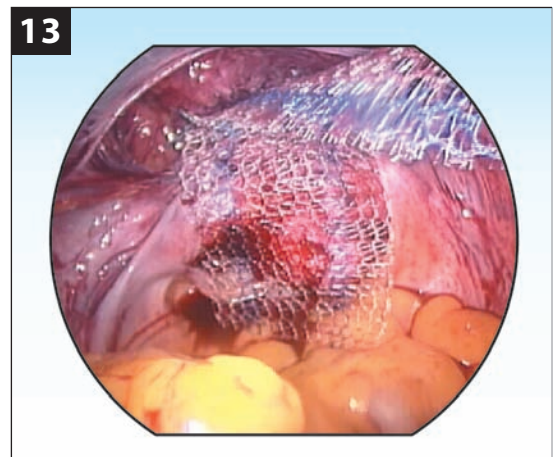
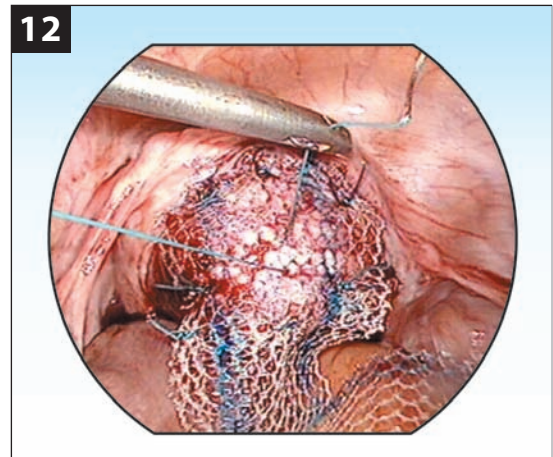


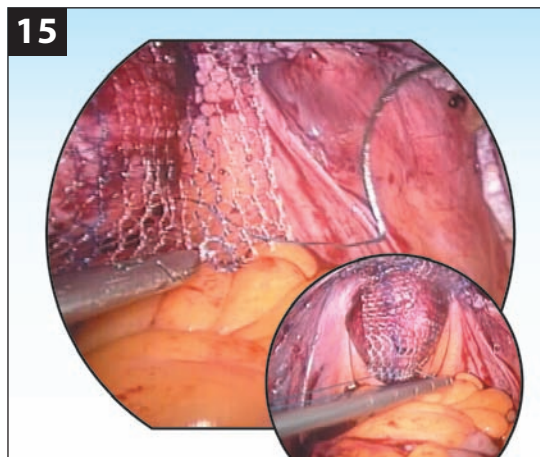
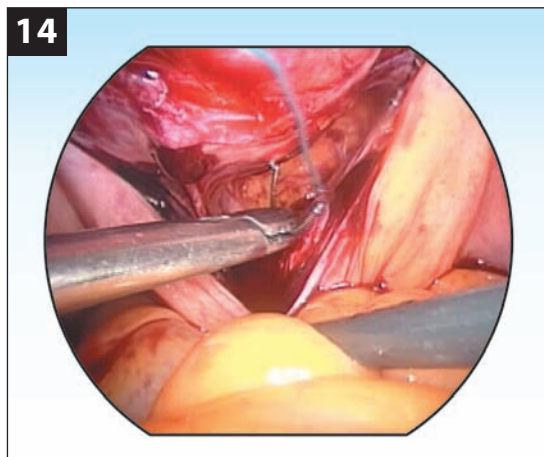
A 12 cm X 4 cm polypropylene mesh graft is fashioned into a Y shape, so there is an anterior and posterior leaf of the mesh. Typically the anterior leaf is about 3-4 cm long and the posterior leaf is longer at 5-6 cm so that it can be brought down deeper into the rectovaginal space (Figure 10). The mesh is then introduced into the abdominal cavity through a 10-or 12 cm port. The posterior leaf is sutured back to the tail of the mesh to keep it out of the way, as we suture the anterior leaf in place first. The vaginal apex is then



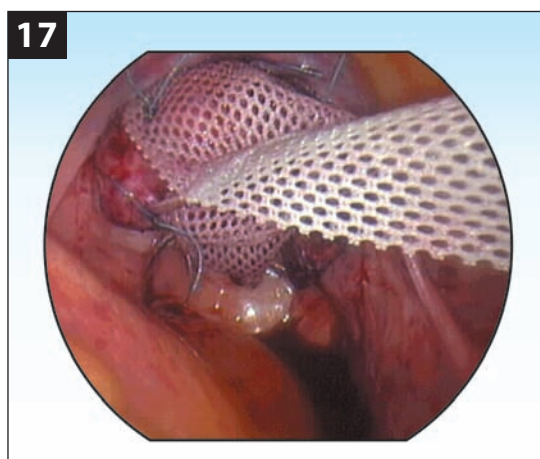
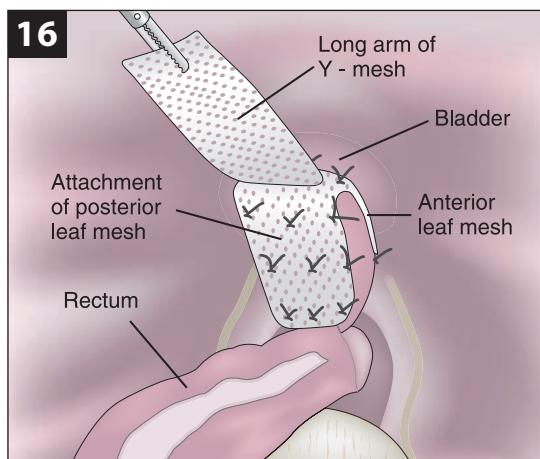


directed anterior and cephalad exposing the pubocervical fascia for application of the surgical graft. The anterior leaf of the mesh is then sutured to the pubocervical fascia with three pairs of no. 2-0 nonabsorbable sutures beginning distally and working towards the rectovaginal fascia apex (Figures 11, 12). We utilize nonabsorbable sutures and tie extracorporeally with a closed loop knot pusher, which is time saving and efficient. All suturing methods and equipment are described in detail in the Laparoscopic Paravaginal Repair and Burch chapter. We utilize the same techniques for suturing with enterocele repair and sacralcolpopexy. The first suture is placed through the mesh and then through the pubocervical fascia, being careful to avoid the bladder edge. Once the anterior leaf is sutured in place, the posterior leaf is then released and sutured in place in a similar fashion (Figure 13). We typically place the most distal suture through the vagina first (being careful to avoid the rectum) and then bring the suture





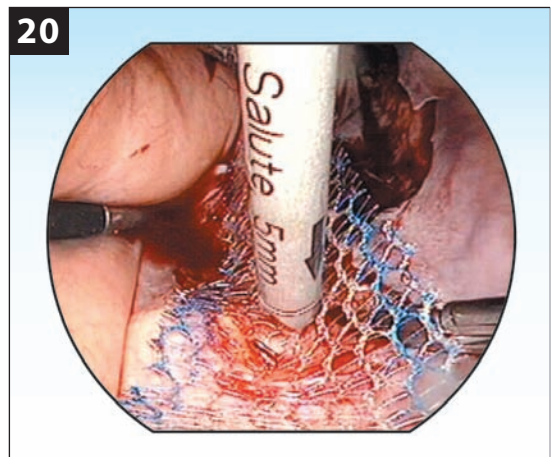
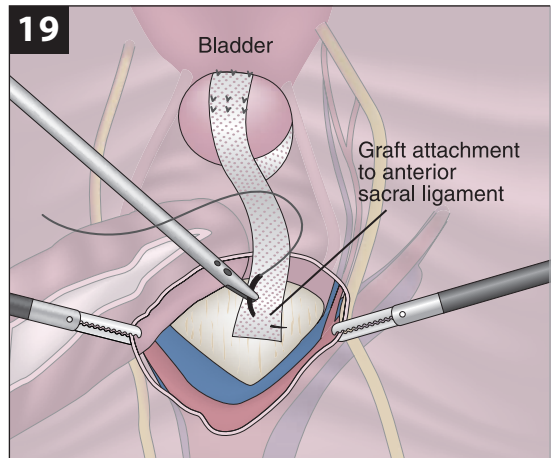
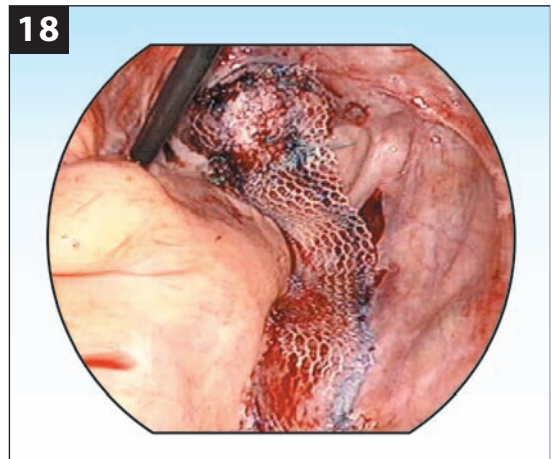
through the mesh and then tie it down into position. The vagina is tented up in the pelvis and the most distal suture (approximately 2/3 down the posterior wall) is placed through the posterior wall (Figure 14), fed through the mesh and then subsequently tied down with an extracorporeal closed-loop knot pusher (Figure 15). Hooked scissors are used throughout the case as they can easily “hook” the suture and slide down to the point it needs to be cut. This helps protect surrounding visceral structures, by pulling the suture away from them prior to cutting the suture. The remaining sutures are taken through the mesh and the vagina, typically in one bite. The posterior leaf is attached with 6-8 sutures as it is longer than the anterior leaf. The final Y-shaped configuration is seen in Figures 16 and 17. This helps repair and prevent further enterocele formation at the cuff in addition to supporting the apex after attachment to the sacrum. The surgeon should attempt to take stitches through the entire thickness of the vagi-



nal wall, excluding the vaginal epithelium. If hysterectomy is completed at the time of the surgery, the cuff is reapproximated in the normal fashion prior to mesh placement and the procedure is then completed in the identical fashion as above. Some have suggested the use of a double-layer closure of the vaginal cuff to help decrease the rate of mesh erosion. However, we do not routinely do this and we have seen no increased rate in cuff erosion. We do feel it is very important, however to keep the sutures that are being placed together to hold the mesh in place away from the vaginal cuff, as suturing the mesh right into the cuff can lead to extrusion in the suture line.

The apex of the vagina is then elevated into its normal anatomic position and the mesh is positioned in the pelvis for its attachment to the pre-sacral ligament. The mesh is positioned so that there is no tension on the vagina (Figure 18).

The surgeon sutures the free end of the Y-shaped mesh to the anterior longitudinal ligament of the sacrum using two pairs of No. 0 nonabsorbable suture (Figure 19). In an attempt to decrease surgical time some surgeons have utilized titanium bone tacks and hernia staplers for the mesh attachment to the anterior longitudinal ligament of the sacrum (Figure 20). After reducing intraabdominal pressure and inspecting the presacral space for hemostasis, the peritoneum is reapproximated with 2-0 polyglactin suture. We utilize a running suture starting at the level of the sacrum, down the sidewall, then up through the bladder



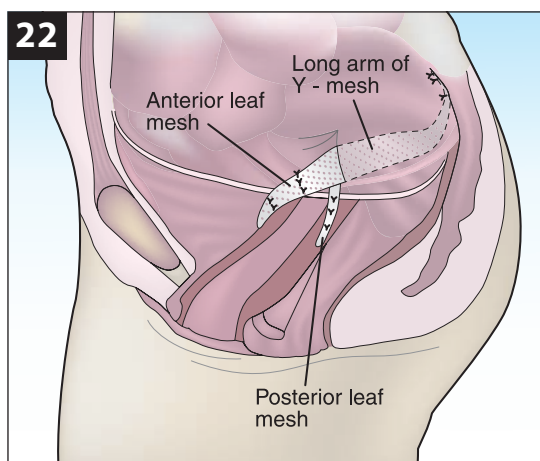
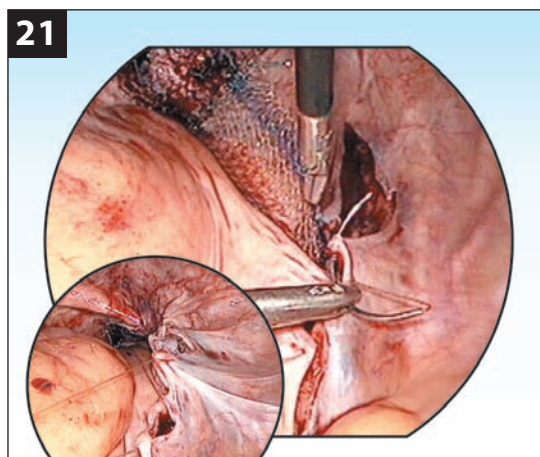
peritoneum, then run it partially back up the sidewall to be able to tie easily near the starting point (Figure 21). Sideview of sacral colpopexy final positioning demonstrates the support of the apex with the graft going down the anterior and posterior walls attached to both pubocervical fascia and rectovaginal septum (Figure 22). We feel the most important aspect of retroperitonealizing the mesh is not necessarily to cover over all the mesh, but is to eliminate the open space between the mesh and the right pelvic sidewall where bowel could potentially become entrapped and obstructed or ischemic.

Once the repair is completed, cystoscopy is performed to ensure ureteral patency and to ensure that there is no suture penetration into the bladder or damage to the bladder from dissection or suture placement.

## POTENTIAL COMPLICATIONS AND INJURIES

### Lower Urinary Tract Injuries

Potential injuries can occur to the ureters and or bladder during the repair. The ureters should be identified at the beginning of the case. Clearly the right ureter is at more risk of injury, secondary to the placement of the mesh on the sacrum on the right side of the colon. The right ureter is identified at the pelvic brim prior to dissection down into the pre-sacral space. As this space is opened and the incision is extended down into the pelvis on the right sidewall, the ureter should be clearly visualized throughout



the dissection and is actually released laterally, away from the operative field with the dissection. The ureters could also potentially be compromised during suture placement of the mesh arms onto the anterior and posterior vagina, specifically the most distal lateral sutures on the anterior wall near the edge of the bladder where the ureters are entering into the bladder (a good dissection will help avoid this danger area) and the lateral sutures of the posterior leaf near the uterosacral ligaments. Cystoscopy is per-

formed at the end of the procedure to ensure ureteral patency. If ureteral obstruction is identified, the suture causing this must be identified and removed and ureteral patency confirmed. If any evidence of compromise or injury is identified to the ureter, a ureteral stent should be left in place for 14-21 days. If a suture is seen penetrating the bladder, it needs to be removed (laparoscopically) and replaced away from the bladder; no further treatment is necessary. If cystotomy occurs during the original dissection of the bladder off of the vagina, this should be repaired laparoscopically with a double-layer closure with delayed absorbable sutures. The procedure can still be completed and mesh placed, however, care should be taken to keep the mesh away from the suture line in the bladder. The bladder should be drained for an extended period of time with this type of an injury (7-10 days) to ensure proper drainage and healing. Overall, the risk of lower urinary tract injury is lower with sacralcolpopexy than with other vault suspensions such as uterosacral ligament suspension.

### BOWEL INJURY

The bowel can be injured with lysis of adhesions or with dissection of the rectum off of the posterior wall of the vagina. A proper 48-hour bowel prep described above is vital to help decrease the risk of bowel injury as this actually deflates the small and large bowel and makes it much easier to get the bowel out of the pelvis and have it stay in the upper abdomen and out of the surgical field.

Additionally, the use of nitrous oxide should be avoided as well as an anesthetic agent as this will cause the bowel to become distended and inflated, increasing the risk of injury. If a small bowel injury occurs, we recommend primary repair laparoscopically. If a proper bowel preparation was conducted, the mesh sacralcolpopexy can be completed, however, antibiotic coverage should be prescribed for one week postoperatively. If the rectum or large bowel is injured during the dissection into the rectovaginal space, primary repair can be accomplished if proper bowel prep was completed, however, we would not recommend mesh be placed following a large bowel injury. Certainly, antibiotic coverage is warranted postoperatively as well.

### VASCULAR INJURIES

As with any advanced pelvic surgical procedure, a thorough knowledge of the pelvic anatomy and vasculature is required prior to attempting laparoscopic sacral colpopexy. The overall risk for bleeding is actually quite low, however if it does occur, it can be a life threatening event. Our average blood loss in over 300 cases over the past 2 years has been less than 75 cc and we have not had to give any blood transfusions for intraoperative bleeding. We feel that the average blood loss for laparoscopic reconstruction is actually much less than with laparotomy secondary to more precise dissection and better visualization. The bleeding encountered with a large abdominal wall incision is likewise eliminated. There is actually

minimal risk of bleeding or major vasculature injury with dissection of the vaginal cuff. This area can be quite vascular, especially down in the rectovaginal space, however, it is typically venous in nature and can be easily controlled with cautery or surgical clips. Certainly, one should always identify and know the location of the ureters prior to any cauterization or clipping. However, dissection into the presacral space has the potential for catastrophic bleeding. We place the patient in deep Trendelenburg position with a left tilt so the bowel can be placed in the upper abdomen and the rectum will fall off to the patient's left side. The right common iliac artery and vein are identified, as is the ureter. The peritoneum is tented up using fine graspers and the peritoneum incised over the sacral promontory. We then carefully dissect down into the presacral space until we reach the pre-sacral ligament and carefully clean this area off with a laparoscopic Kittner until we see the white of the ligament. The middle sacral artery is identified and we ensure that we find a vessel-free area to suture or attach the mesh. One must be careful as, on occasion, the left common iliac vein can traverse this area as well. If bleeding is encountered during the dissection or down in the sacral hollow, it can be life-threatening and rapid conversion to laparotomy needs to be considered. Bipolar electrocautery, surgical clips or hemostatic sutures may be utilized laparoscopically to try to control the bleeding, but again the position of the ureter needs to be identified to ensure it

is away from the surgical field. FloSeal (Cooper Surgical, USA), a thrombin gel agent, may be utilized laparoscopically and has been shown to control both arterial and venous bleeding. We have utilized this material in several incidences with excellent clinical results and have not had to convert any patient to laparotomy to date. If bleeding cannot be controlled, conversion to laparotomy is required and packing/pressure should be placed immediately to control bleeding and restore volume. The patient may require administration of blood products if necessary. Thumb tacks with bone wax have been utilized in the sacral hollow to control bleeding vessels that have retracted into the sacrum and again hemostatic agents such as thrombin gel may be utilized to help obtain hemostasis. If all of the above fails, interventional radiology may be considered for occlusion of the retracted blood vessels.

#### LEVEL 1 SUPPORT PROCEDURES - CLINICAL RESULTS

Richardson first described this anatomic defect for enterocele in 1995 in his landmark paper "The anatomic defects in rectocele and enterocele." Since that time, others have described laparoscopic surgical techniques which employ Richardson's anatomic theories in the treatment of enterocele and vaginal apex prolapse. Recently Carter et al reported on 8 patients who underwent the Richardson-Saye laparoscopic vaginal vault suspension and enterocele repair technique with excellent results.

There are no other reports in the literature that evaluate clinical results of the laparoscopic uterosacral ligaments suspensions and/or traditional types of enterocele repairs such as the Halban and Moskowitz procedures. However, some have described their surgical technique and/or complications. Lyons and Winer reviewed the technique and complications in 276 patients who had either a Moskowitz or Halban procedure. The worst complications encountered in this series were port site infections. Koninckx et al emphasized using the CO<sub>2</sub> laser for vaporization of the enterocele sac, followed by uterosacral ligament shortening and suspension of the posterior vaginal wall. A modified Moschowitz procedure with approximation of the posterior vaginal fascia to the anterior wall of the rectum laparoscopically has also been described. Despite the paucity of data regarding long-term cure rates, the uterosacral ligament suspension and site-specific enterocele repair remain a mainstay in many surgeon's armamentarium.

In 1994 Nezhat et al were the first to report a series of 15 patients who underwent laparoscopic sacral colpopexy. They reported an apical vault cure rate of 100% on follow-up ranging from 3 to 40 months. In 1995, Lyons reported 4 laparoscopic sacrospinous fixation and 10 laparoscopic sacral colpopexies. Ross subsequently reported on 19 patients who underwent laparoscopic sacral colpopexy, Burch colposuspension and modified culdeplasty in 1997. The author reported 7 complications including: 3 cystotomies, 2 urinary tract infections, 1

seroma, and 1 inferior epigastric laceration. Despite 2 patients being lost to follow-up, he reported a cure rate of (13/13) 100% for vaginal apex prolapse at 1 year.

Cosson et al reported on their experience of feasibility and short-term complications in 77 patients who had undergone laparoscopic sacral colpopexies. Laparoscopy was actually performed on 83 patients with symptomatic prolapse of the uterus. Six cases required conversion to laparotomy because of technical difficulties. All of the remaining 77 patients underwent laparoscopic sacrocolpopexy. Subtotal hysterectomy was performed in 60 cases. Three patients required reoperations for hematoma or hemorrhage. Mean operative follow-up was 343 days. Three other patients required reoperation, 1 for a third-degree cystocele and 2 for recurrent stress incontinence. The surgeons concluded that sacralcolpopexy is feasible and the operative time, and post-operative complications are related to the surgeon's experience but remain comparable to those noted in laparotomy.

Use of synthetic mesh for the treatment of vaginal vault prolapse has been performed since 1991 at The University of Auvergne, Clermont-Ferrand. More than 250 cases have been performed there laparoscopically with an apical vault cure rate of approximately 92%. Complications are rare with the most common being mesh extrusion (2%) and only in patients who underwent concomitant hysterectomy. Patients who had uterine suspensions or who have not had a concomitant hysterectomy have

not experienced this complication. (Wattiez A, personal communication - International Society of Gynecologic Endoscopy - Berlin 2002). Rozet et al reported on 363 cases of laparoscopic sacralcolpopexy with polyester mesh with mean follow-up of 14.6 months. Cure rate was reported at 96% and complications were minimal including 3 mesh erosions, 1 bowel incarceration, 1 spondylitis, and 2 mesh infections. We have performed more than 300 laparoscopic Y-mesh sacralcolpopexies with macroporous soft polypropylene mesh in the past 2 years and have had excellent clinical results with a very low rate of complications. Our cure rate is greater than 94% and we have had only 2 mesh erosions (0.6%) to date and both patients underwent concomitant hysterectomy.

## CONCLUSION

Laparoscopy should only be considered a mode of surgical access, which should not significantly change the technique of operative reconstructive surgery. Laparoscopy benefits the surgeon by improving visualization, decreasing blood loss and magnifying the pelvic floor defects which need to be repaired.

Other advantages including less postoperative pain, shorter hospital stays, shorter recovery time and earlier return to a better quality of life have also been described in the literature. Disadvantages often cited in the literature include increased operative time and associated increased costs. The authors' personal experience is that operative time is similar and in many times reduced, especially for patients with a high body mass index. However, complex operative laparoscopy is associated with a steep and lengthy learning curve after which operative time is significantly reduced based on the surgeon's experience and laparoscopy skills as well as the quality of the operative team.

A thorough knowledge of pelvic floor anatomy is essential before undertaking any type of reconstructive pelvic surgery, and advanced knowledge of laparoscopic surgery and suturing are essential to perform the surgical procedures discussed in this review. Despite the paucity in the literature, laparoscopic pelvic reconstructive surgery will continue to be driven by patient demands as well as surgeon preference. With increasing experience, greater data should support its continued use and favorable long-term outcomes.



## SUGGESTED READING:

DeLancey JO. Anatomic aspects of vaginal eversion after hysterectomy. *Am J Obstet Gynecol* 1992;166:1717-24

Richardson AC. The rectovaginal septum revisited: its relationship to rectocele and its importance in rectocele repair. *Clin Obstet Gynecol* 1993;36:976-983

Richardson AC. The anatomic defects in rectocele and enterocele. *J Pelvic Surg* 1995;1:214-221

Kauppila O, Punnonen R, Teisala K. Operative technique for the repair of posthysterectomy vaginal prolapse. *An Chir Gynaecol* 1986;75:242-244

Symmonds RE, Williams TJ, Lee RA, Webb MJ. Post-hysterectomy enterocele and vaginal vault prolapse. *Am J Obstet Gynecol* 1981;140:852-859

Cruikshank SH, Kovac SR. Anterior vaginal wall culdoplasty at vaginal hysterectomy to prevent posthysterectomy anterior vaginal wall prolapse. *Am J Obstet Gynecol* 1996;174:1863-1869

Ross JW. Apical vault repair, the cornerstone of pelvic floor reconstruction. *Int Urogynecol J* 1997;8:146-152

Ross JW. Techniques of laparoscopic repair of total vault eversion after hysterectomy. *J Am Assoc Gynecol Laparosc* 1997;4:173-183

Miklos JR, Kohli N, Lucente V, Saye WB. Site specific fascial defects in the diagnosis and surgical management of enterocele. *Am J Obstet Gynecol*. 1998;179:1418-1423

Carter JE, Winter M, Mendelsohn S, Saye WB, Richardson AC. Vaginal vault suspension and enterocele repair by Richardson-Saye laparoscopic technique: description of training technique and results. *J Soc Laparoend Surg* 2001;5:29-36

Lyons TL. Minimally invasive treatment of urinary stress incontinence and laparoscopically direct repair of pelvic floor defects. *Clin Obstet Gynecol* 1995;38:380-391

Koninckx PR, Poppe W, Depress J. Carbon dioxide laser for laparoscopic enterocele repair. *J Am Assoc Gynecol Laparosc* 1995;2:181-185

Nezhat CH, Nezhat F, Nezhat C. Laparoscopic sacral colpopexy for vaginal vault prolapse. *Obstet Gynecol* 1994;4:381-383

Lyons TL, Winer WK. Vaginal vault suspension. *Endosc Surg* 1995;3:88-92

.....

---

Cosson M, Rajabally R, Bogaert E, Querleu D, Crepin G. Laparoscopic sacrocolpopexy, hysterectomy and burch colposuspension: feasibility and short-term complications of 77 procedures. *J Soc Lap Surg* 2002;6(2):115-119

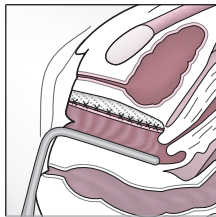
Wattiez A, Canis M, Mage G, Pouly JL, Bruhat MA. Promontofixation for the treatment of prolapse. *Urol Clin N Amer* 2001;28:151-157

Rozet F, Mandron E, Arroyo C, et al. Laparoscopic sacral colpopexy approach for genitourinary prolapse: experience with 363 cases. *Eur Urol* 2005 Feb;47(2):230-6

---



# USE OF MESH IN VAGINAL PELVIC RECONSTRUCTIVE SURGERY



*Sam H. Hessami, M.D.*

## INTRODUCTION

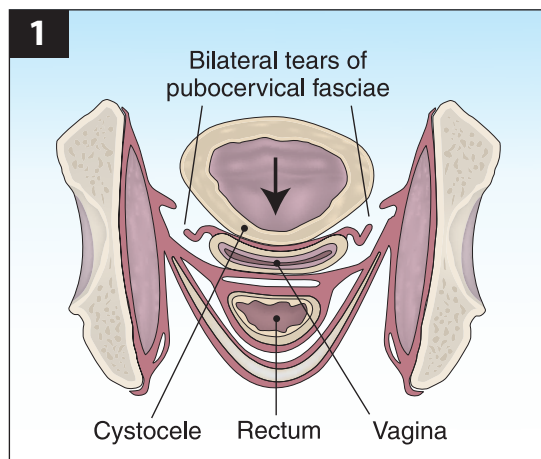
**W**omen have an 11% lifetime risk of undergoing surgery for pelvic organ prolapse. Of concern is the high rate of recurrence involving the same site after reconstructive surgery. The highest recurrence rate is associated with anterior compartment repairs, estimated at 30%, followed by apical repairs estimated at 18% (sacrospinous ligament fixation). Posterior defect repairs are less likely to reoccur. This probably has to do with the mechanics involved and the way rises in intra-abdominal pressure are transmitted to the posterior compartment as opposed to anterior or apical compartments. It is now widely accepted that prolapse occurs as a result of tears in the support structure of pelvic organs. Distal tears in the uterosacral ligaments result in uterine prolapse, while tears in the pubocervical fascia and rectovaginal fascia result in cystoceles and rectoceles, respectively. In case of apical prolapse, vaginal repair techniques include high uterosacral suspension, sacrospinous ligament fixation and iliococcygeus hitch (Inmon's procedure). Anterior compartment defects are believed to be mostly caused by either unilateral or bilateral

paravaginal tears in the pubocervical fascia (Figure 1). Proximal transverse defects are seen in post-hysterectomy patients, where the pubocervical fascia was never re-approximated to the rectovaginal fascia, thus creating an opening through which bladder herniation can occur. The traditional anterior colporrhaphy addresses only central defects, probably the reason why they are associated with high recurrence rates. Newer approaches such as site specific repair try to identify actual tears in the endopelvic fascia, followed by their repair. The problem associated with this approach is our inability to identify actual endopelvic fascia. The use of biomaterial, either synthetic or natural, will bypass this problem, by replacing or reinforcing the endopelvic fascia in the area involved: pubocervical fascia in the case of anterior compartment defects and rectovaginal fascia in the case of posterior defects. Use of biomaterial will make the need to identify either the sites of tears or the actual endopelvic fascia unnecessary. When using the graft materials, we need to ask ourselves three questions:

- Will the graft improve the durability of the repair?
- Will the graft improve the functionality of the repair?
- Does the graft increase the rate of complications?

## BIOMATERIAL USED IN VAGINAL SURGERY

In an attempt to reduce the risk of recurrence of anterior and posterior repairs, a variety of biomaterial is being



used. These materials have been used both in the traditional repairs as well as defect-specific repairs. Biomaterials are divided into natural or synthetic.

### NATURAL BIOMATERIALS INCLUDE:

autografts - tissue harvested from patient

xenografts - tissue from animal sources, either bovine or porcine

allografts - tissue harvested from cadavers

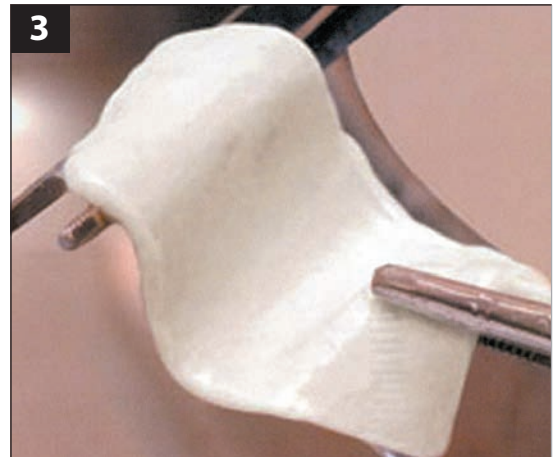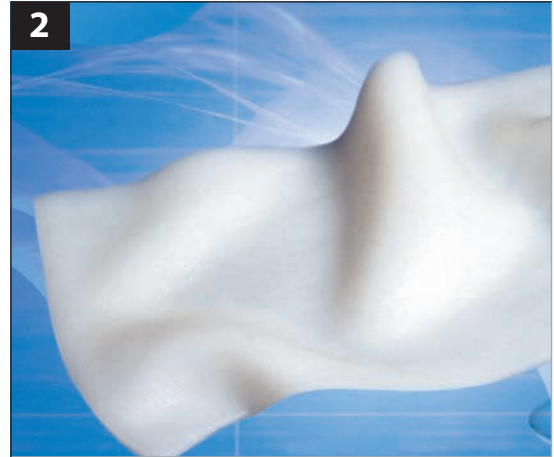Synthetic biomaterial could be absorbable or permanent.

The properties of the ideal mesh have been studied and include non-immunogenic, inertness, ability to resist shrinkage, ability to prevent physical modification by the host, and affordability. None of the current biomaterial on the market meets all of the above criteria for an ideal graft.

## NATURAL MATERIAL

All natural material, whether autogenic, allogenic or xenogenic will be broken down. The duration of this process is variable, ranging from three months to one year, depending on the limited data available. The theory behind the use of natural material rests on the ability of tissue to regenerate; that is the grafted material is used as a scaffold onto which the patient's own tissue will start the process of regeneration. However, if one considers pelvic organ prolapse a systemic connective tissue disorder, as opposed to an isolated or localized condition, then one can realize that the regenerated tissue will still be of poor quality. Since not every woman with risk factors develop pelvic organ prolapse, one can conclude that this condition occurs in a subset of women who are genetically predisposed, hence a systemic condition as opposed to a localized or isolated event. Natural material overall seems to be safer, not in terms of overall complication rates, but rather through treatment of the complications. Tissue tends to encapsulate natural material, and thus their removal is relatively simple, in case of infection or other complications. Conservative management of extrusion of natural material with estrogen is also more successful when compared to synthetics.

Xenografts make up the bulk of natural material currently used. Bard and Boston Scientific corporations all make quality xenografts. The most popular products made by Bard Inc (Cranston, RI)



are acellular porcine dermis Pelvicol™ and acellular collagen matrix, Pelvisoft™, while Boston Scientific (Natick, MA) makes soft tissue repair matrix Xenform™ which represents non-crosslinked, bovine dermal matrix that promotes revascularization and regeneration (Figure 2).


Popular allografts on the market are made by Boston Scientific dermal graft Repliform® that represents human tissue matrix (Figure 3) and Mentor Corporation

Tutoplast®. AlloDerm® is derived from cadaveric human dermis, while Tutoplast® is cadaveric Fascia Lata.

### SYNTHETIC MATERIAL

Synthetic materials have been available since the early 1940's. However, their use has been limited to sterile abdominal cases as opposed to clean-contaminated vaginal procedures. It was not until the late 1990's that synthetic mesh was first used in pubovaginal sling procedures, followed by their use in vaginal pelvic reconstruction. Their popularity is a direct result of our increased knowledge about properties of an ideal synthetic material. These properties include the type and amount of material used, composition of the material and intrafiber pore sizes. Currently, pore size is thought to be a key factor in determining both the inflammatory response and collagen infiltration. The minimum desired pore size is 50 micron. This allows for passage of macrophages and polymorphonuclear leukocytes to fight off bacterial infection, as well as forming fibrous connections to the surrounding environment by ingrowths of fibrocollagenous tissue. On the basis of pore size, the synthetic meshes can be classified into four types. Type I meshes are macroporous, containing pores larger than 75 microns. Therefore an ideal synthetic mesh is a polypropylene, monofilament type I mesh. Most, but not all, synthetic mesh currently available meet these criteria.

The most popular synthetic mesh currently on the market is Gynemesh, a



polypropylene, knitted, monofilament mesh made by Ethicon Women's Health and Urology (formerly Gynecare). Bard's Pelvitex™, a monofilament polypropylene mesh coated with collagen, was recently introduced on the market. Polyform™ synthetic mesh by Boston Scientific Corp (Natick, MA) is made from uncoated monofilament macroporous polypropylene (Figure 4).

### TECHNIQUE FOR ANTERIOR MESH INTERPOSITION

The first step in anterior vaginal wall dissection and mobilization of the bladder involves hydrodissection. This step is especially useful in primary repairs, where the vesicovaginal space has not been obliterated by fibrosis due to previous surgery. About 30 cc of 0.25% Marcaine or 1% Lidocaine is mixed with 60 cc of normal saline for this purpose. Vasoconstrictive agents should be avoided as they contribute to necrosis of the flap edges and may result in mesh extru-

## SYNTHETIC MESH CLASSIFICATION TABLE

### TYPE I MESHES:

MACROPOROUS, CONTAINING PORES LARGER THAN 75 MICRONS.

GYNEMESH, PELVITEX, POLYFORM

### TYPE II MESHES:

TOTALLY MICROPOROUS. THE PORE SIZE IS SMALLER THAN 10 MICRON. (GORE-TEX)

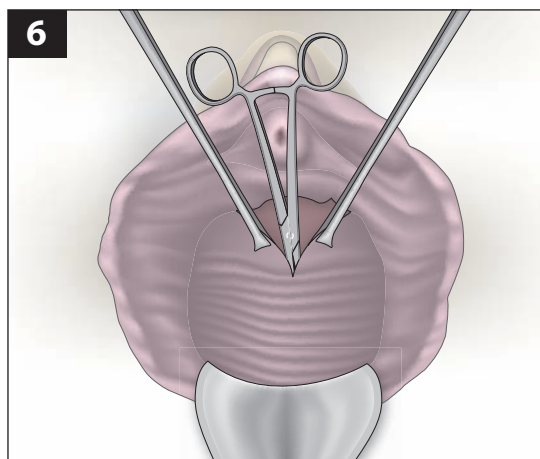
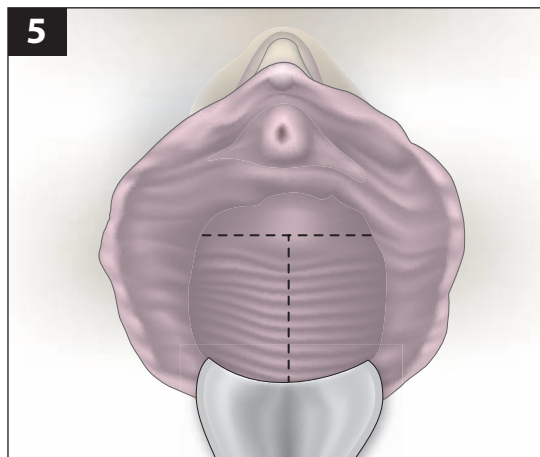
### TYPE III MESHES:

MACROPOROUS PATCH, WITH MULTIFILAMENTS OR A MICROPOROUS COMPONENT, TEFLON, MERSALINE.

### TYPE IV MESHES:

BIOMATERIALS WITH SUBMICRONIC PORES, SILASTIC, PRECLUDE, CELLGARD, PERICARDIAL MEMBRANE.

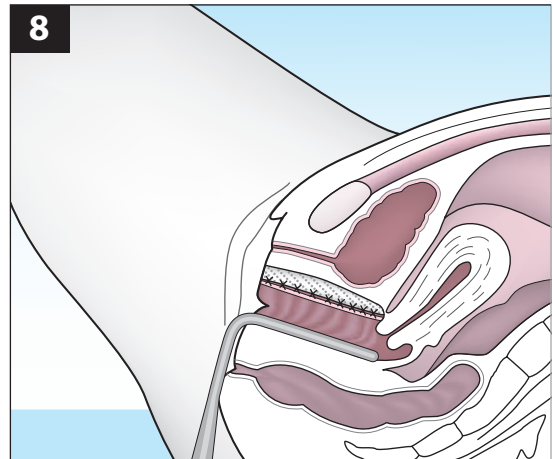
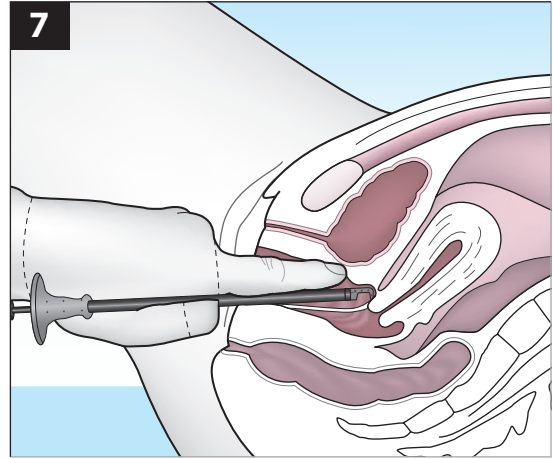
sion. The cocktail is injected using a 10 cc syringe through a 21-gauge needle. Upon injection, blanching of the anterior vaginal wall should occur. Hydrodissection serves two purposes. First, it helps with dissection of the vesicovaginal space which is a potential space. Second, it creates a safety buffer zone, where iatrogenic injury to the bladder and the urethra is minimized. After hydrodissection is complete, an anterior vaginal incision is made, either via a midline incision, along the length of the anterior vaginal bulge or a transverse incision (Figure 5). A transverse incision offers two advantages over a traditional midline incision. First, it tends to be shorter in length thus offering the theoretical advantage of minimizing infection



rate, as it is known that incidence of wound infection is proportional to the length of incision. Second, in cases where a concomitant sling procedure is needed, the midurethral area is avoided. Its only disadvantage is that bladder mobilization tends to be more difficult via this incision as opposed to a traditional midline incision as it offers less room. Long Alice clamps are used over the path of the incision for traction (Figure 6). Once the incision is made,



either horizontal or vertical, the Alice clamps are repositioned along the flaps, and again used for traction and counter-traction. The bladder is then mobilized sharply using Metzenbaum scissors laterally to the level of inferior pubic rami. Care is taken to avoid the anterior midline, where the urethra courses. The dissection is continued until both inferior pubic rami and ischial spines are identified bilaterally. At least four anchoring sutures are placed during this type of procedure. Two are placed proximally at the level of ischial spines, through the point of origin of the arcus tendineus and the fascia of iliococcygeus muscle. The distal sutures are placed through the periostium of the symphysis or through the fascia of the obturator internus muscle, approximating the course of the arcus as it extends from the ischial spine to the back of the symphysis pubis. For proximal suture placement, a suture retrieval device such as a Capio (Boston Scientific) is preferable (Figure 7), but regular Heany needle holders can be used as well. During suture placement at this level, the needle should be passed upward, trying to avoid the pudendal neurovascular bundles as they course behind the ischial spine, running through the Alcock's canal. If the sutures are placed too low, gluteal pain due to nerve entrapment is often seen. Placement of sutures too high will put the ureters at risk. Therefore it is important to remember that the proximal sutures must be placed at the level of ischial spines, through the fascia of the obturator internus and levator ani muscles which is the

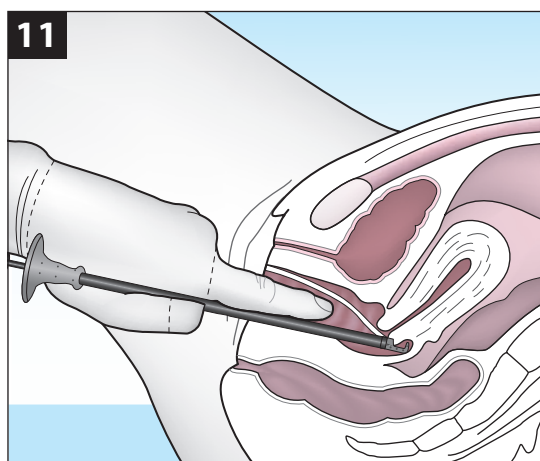
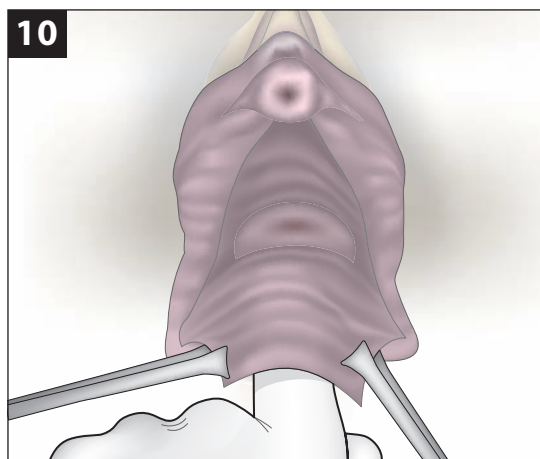
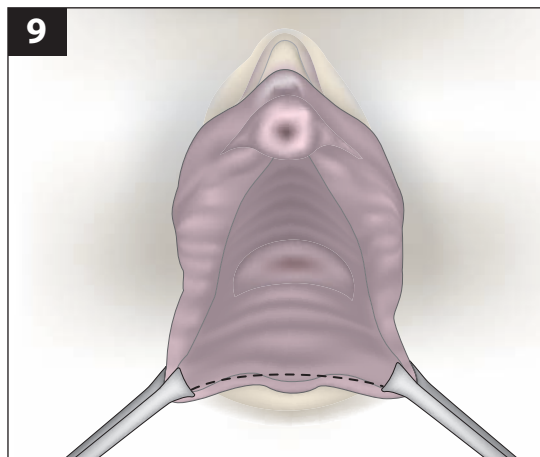


point of origin of the arcus tendineus as well. Permanent sutures, such as 2-0 Prolene or 2-0 Ethibond are used in case of synthetic non-absorbable mesh. Delayed absorbable sutures, such as 2-0 PDS are used if synthetic absorbable or biodegradable mesh is used. The sutures are then passed through the four corners of the mesh, which is usually cut in a trapezoidal fashion, measuring no more than 5 X 3 cm in size. The mesh is then parachuted in at the last moment and the

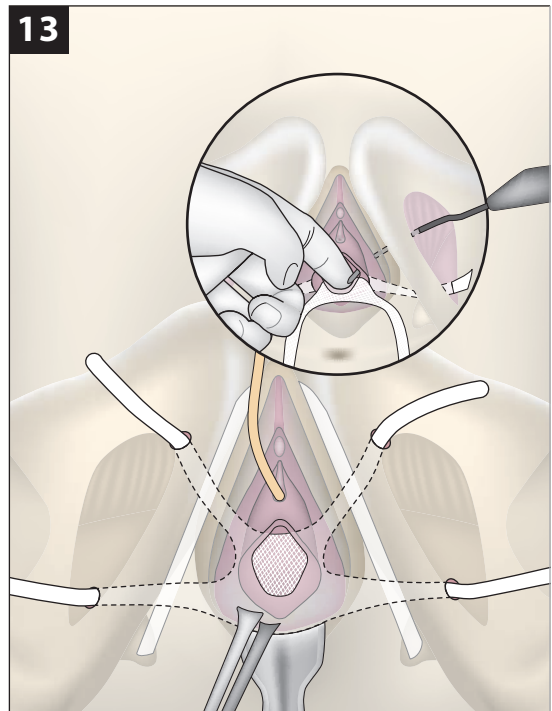
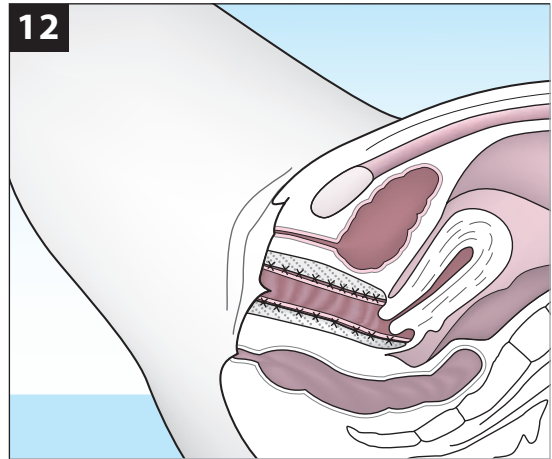
sutures are tied, beginning with the proximal sutures (Figure 8). The vaginal epithelium is then trimmed minimally and then closed in a continuous interlocking fashion using absorbable 0 or 2-0 vicryl. A cystoscopy should be done to ensure intactness of the bladder and patency of the ureters.

## TECHNIQUE FOR POSTERIOR MESH INTERPOSITION

The posterior compartment repair also starts with hydrodissection of the rectovaginal space, in the exact same method described above. This is followed by a transverse incision over the perineal body measuring about 3 cm. Two long Alice clamps are then placed over the posterior bulge and a vertical incision is made, perpendicular to the transverse perineal incision (Figure 9). Metzenbaum scissors are used to sharply mobilize the rectum from the posterior vaginal wall (Figure 10). The dissection is continued to the level of ischial spines bilaterally. Again, a total of at least four anchoring sutures are used. The proximal sutures are placed at the level of ischial spine, through the iliococcygeal muscles at the point of origin of the arcus tendineus (Figure 11). This is the same position where the proximal sutures for anterior compartment defects are placed. This should be no surprise, since the arcus tendineus fascia pelvis and arcus tendineus rectovaginalis both originate from the level of ischial spine. Midway through their course, they split into a Y. The arcus tendinous fascia pelvis, sup-



porting the pubocervical fascia courses towards the back of the symphysis, while the arcus tendineus rectovaginalis, supporting the rectovaginal fascia, courses toward and meshes in with the perineal body. Therefore, the distal sutures in the posterior compartment defect are placed through and on either side of the perineal body. In doing so, one must also incorporate the rectovaginal fascia, the distal corners of the mesh as well as the ipsilateral distal edges of the bulbocavernosus and ischiocavernosus muscles, found just before the inferior border of the descending pubic ramus. It must be emphasized that these two distal corners should not be embrocated together in order to prevent formation of an introital ridge which is not only anatomically incorrect, but also has been associated with dyspareunia. The sutures are then passed through the four corners of the mesh and the mesh is then parachuted in. The mesh measures about 5 X 3 cm in size. The sutures are tied, beginning with the most proximal sutures (Figure 12). The vaginal epithelium is then trimmed minimally, and then closed with absorbable suture in a running interlocking fashion. A rectal exam at the end of the case ensures intactness of the rectum.



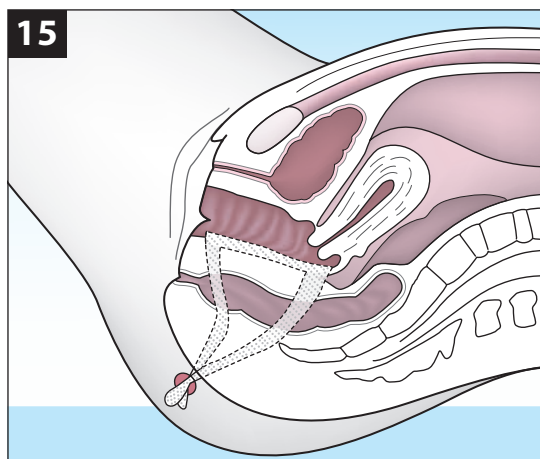
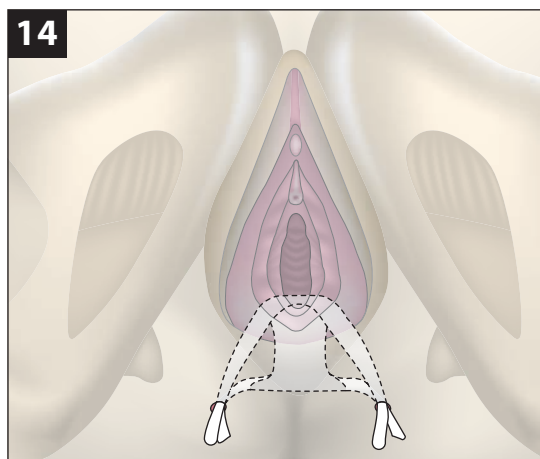
### VAGINAL MESH PLACEMENT VIA OTHER APPROACHES

Mesh placement, whether synthetic or organic, have been tried via other non conventional vaginal routes. The infracoccygeal/gluteal approach was first used in the late 1990's for post-hysterectomy vagi-

nal vault suspension (IVS Tunneller, US Surgical). More recently, a trans-obturator approach for anterior and posterior mesh placement was introduced (Perigee™ and Apogee™ by AMS, Prolift™ by Johnson and Johnson, Avaulta™ by Bard). All those procedures utilize simple introduc-

er needle systems similar to the TOT procedure and prefabricated mesh that can be trimmed to facilitate the patient's anatomy. The anterior approach uses the relatively safe obturator area immediately adjacent to the inferior pubic rami for retrieval and passage of the arms of the mesh (Figure 13). The mesh in these instances is not sutured to any fixed point, but rather is held in position in a tension-free manner, similar to the tension-free sling devices. The Velcro effect of the polypropylene mesh will prevent mesh migration. The ingrowths of collagen by infiltrating fibroblasts will keep the mesh fixed permanently in place.

For posterior mesh placement, the infragluteal approach is used. In this technique two para-rectal incisions are made, through which the specialized introducer is placed aiming the needle tip toward the ischial spines and through the posterior vaginal wall incision. The vaginal finger is used to help guide and exteriorize the needle tip. Proximal mesh arm is attached to the needle and the needle is retracted back to draw the mesh through the pararectal skin incision. The procedure is performed on the contralateral side and the traction is applied to the proximal arms of the graft to bring it to the desired position, to place the proximal end of the central graft at the vaginal apex. The introducer is again placed through the same pararectal incision and the needle tip is directed toward the vaginal introitus. The vaginal finger is again used to guide the needle tip to stay lateral to the anal sphincter and rectum and to exteriorize the tip through the vaginal incision.



The distal mesh is attached to the needle and withdrawn through the pararectal skin incision. The procedure is repeated on the contralateral side and the traction is applied to position the mesh in place. Digital rectal exam should be performed to confirm the integrity of the rectum after the mesh is positioned. Figures 14 and 15 show the posterior mesh in place. In both the anterior and posterior techniques, the proximal point of entry of the introducers is the iliococcygeal muscle, adjacent to the ischial spine. Distally, the point of

introducer entry is at the level of the urethral meatus, but lateral to the inferior pubic rami, while for the posterior approach, the point of entry is at the level of the vaginal introitus, through the puborectalis and pubococcygeus muscles.

## **COMPLICATIONS ASSOCIATED WITH MESH USE**

The introduction of mesh to vaginal surgery is relatively new. Data is scarce in regards to both efficacy as well as complications associated with mesh use. To date few prospective randomized studies have looked at the benefit of mesh in vaginal surgery. Until more data is available, mesh, especially synthetic mesh, should be used in selected patients who will clearly benefit from mesh interposition: those undergoing primary repair of a large defect (stage 3 or 4), or patients undergoing secondary repair. Most common complications associated with mesh are mesh extrusion, followed by persistent granulation tissue, and mesh erosion. Exposure of mesh into the vagina is described as mesh extrusion, while its exposure into the bladder, urethra or rectum is described as erosion. Extrusion and persistent granulation tissue can be managed conservatively at first, with in-office resection of the exposed mesh or suture, followed by

daily application of estrogen cream preparation for two weeks. Most often results of conservative therapy are less than satisfactory, with patients complaining of persistent vaginal bleeding, especially after intercourse. This will necessitate operative intervention, with resection of exposed mesh, followed by creation of epithelial flaps to cover over the defect. Flaps are made after hydro dissection, using a size 15 knife. If the extrusion is anterior and proximal, care must be taken to avoid injury to the ureters during the creation of the vaginal epithelial flaps. Ureteral stenting will help in palpating the ureters and thus avoid injury to them. A cystoscopy must be performed after resection and flap formation again to ensure bladder intactness and ureteral patency. Mesh erosion is treated surgically with resection and primary repair of the organ in case of bladder or urethra. Rectal erosion must also be treated surgically and most often a primary repair of rectal injury will suffice. However, larger and more extended erosions may require diversion with colostomy, followed by re-anastomoses a few months later. Since the complications associated with mesh can be serious, appropriate patient selection is as crucial as mesh selection. Therefore surgeries should be tailored around patients and not the other way around.

## SUGGESTED READING:

Farrel SA, Dempsey T, Geldenhuys L. Histological examination of fascia used in coporrhaphy. *Obstet Gynecol* 2001; 98:794-8

Brun JL, Bordenave L, Lefebvre F, et al. Physical and biological characteristics of the main biomaterials used in pelvic surgery. *Biomed Mater Eng* 1992; 2:203-225

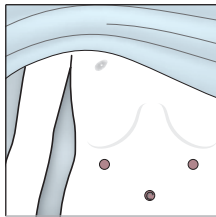
Amid PK, Shulman AG, Lichtenstein IL. Selected synthetic mesh for the repair of groin hernia. *Postgrad Gen Surg* 1992; 4:150-155

Sand PK, Sumana K, Lobel RW, et al. Prospective randomized trial of polyglactin 910 mesh to prevent recurrence of cystocele and rectocele. *Am J Obstet Gynecol* 2001; 184:1357-64

Weber AM, Watters MD, Piedmonte MR, et al. Anterior colporrhaphy: a randomized trial of three surgical techniques. *Am J Obstet Gynecol* 2001; 185(6): 1299-304



# PEDIATRIC LAPAROSCOPY



*Claire Templeman, M.D.*

*S. Paige Hertweck, M.D.*

## INTRODUCTION

In adults, laparoscopy is an established alternative to open surgery. However, until recently concerns regarding proven benefit and adequate equipment have limited its use in pediatric patients. The advent of microendoscopic equipment has made pediatric endoscopy more practical but there are some important technical differences between it and adult laparoscopy and they will be the focus of this chapter.

## INDICATIONS

There is now considerable experience with laparoscopy for appendectomy, cholecystectomy, splenectomy exploration of non palpable testis, hernia repair, and trauma in children. Some relevant indications for gynecologists who treat young children and adolescents are listed in Table 1. Specific techniques for the management of ovarian masses and uterovaginal anomalies are detailed in chapters 13 and 28.



**TABLE 1: GYNECOLOGICAL INDICATIONS FOR LAPAROSCOPY IN THE PEDIATRIC AND ADOLESCENT POPULATION.**

AGE GROUP	INDICATION
NEONATAL	COMPLEX, ENLARGING OR SYMPTOMATIC OVARIAN MASS ABDOMINAL MASS OF UNCERTAIN ORIGIN
PREPUBERTAL	PERSISTENT OVARIAN CYST OR MASS PARATUBAL CYST, OVARIAN TORSION, OOPHOROPEXY
ADOLESCENT	PERSISTENT OVARIAN CYST OR MASS OVARIAN TORSION, PARATUBAL CYST, SUSPECTED ENDOMETRIOSIS UTEROVAGINAL ANOMALIES, OOPHOROPEXY PELVIC INFLAMMATORY DISEASE

When contemplating laparoscopy in a pediatric patient, an experienced anesthetic team is essential. Insufflation of the abdomen with carbon dioxide gas (CO<sub>2</sub>) increases intraabdominal and intrathoracic pressure with the potential for ventilation and perfusion abnormalities. Correct insufflation pressure is critical in infants because they rely on diaphragmatic excursion for adequate ventilation. Over insufflation may result in restricted diaphragmatic movement.

It has been demonstrated in animal models that intraabdominal pressures maintained between 0-10 mmHg do not deleteriously affect ventilation or gas exchange. An insufflation pressure of 8 mmHg with a flow rate of 0.5 L/min is appropriate for neonates or infants with pressures of 10-12 mmHg appropriate for older children. Carbon dioxide insufflation may also result in hypercapnia and metabolic acidosis if the end tidal CO<sub>2</sub>, and oxygen saturation are not monitored closely. A minute ventilatory rate that

maintains the end tidal CO<sub>2</sub> in the range of 30-45 mmHg is required and in neonatal patients undergoing laparoscopy this has been found to be 30-40% more than that required at laparotomy. The use of humidified gas (37°C) is advisable since it has also been shown to decrease the risk of hypothermia that may occur in pediatric patients undergoing laparoscopy. Intravenous fluids such as lactated ringer solution should be administered to maintain urine output at 1 mL/kg/hour. Recent work suggests that the creation of a pneumoperitoneum in pediatric patients may adversely affect urine output during surgery. Anuria has been noted in infants less than one year of age and oliguria in about one third of patients over one year of age. These phenomena appear to be completely reversible but highlight the inaccuracies of using urine output in the calculation of fluid administration requirements during laparoscopic surgery in infants.

## PATIENT POSITIONING

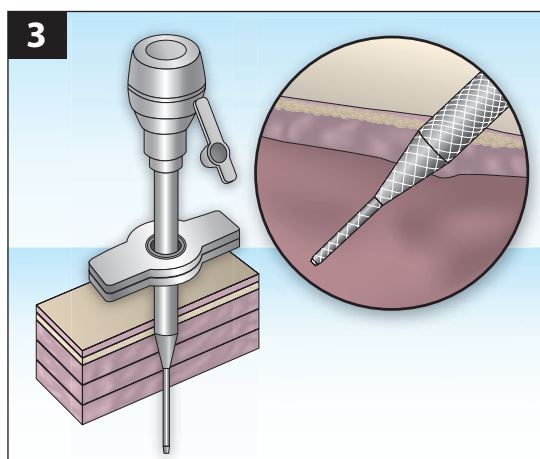
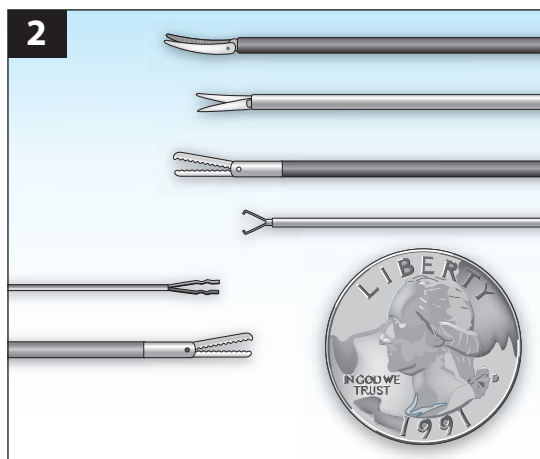
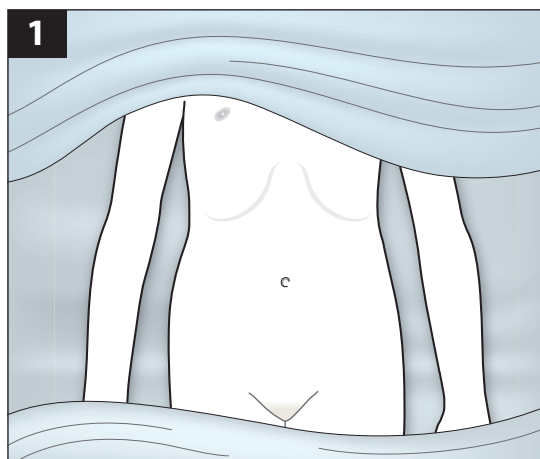
In pediatric patients, the supine position is used almost exclusively since there is no need to instrument the uterus (Figure 1). If access to the vagina is required, proper use of padded stirrups that align the ipsilateral heel with the contralateral hip and shoulder are important. Stirrups that place the hips in hyperflexion are occasionally used in children because they give maximum access to the perineum, however, they place the patient at risk for femoral nerve damage particularly if the case is lengthy.

Irrespective of age, tucking the child's arms by their side also allows the surgeon maximum flexibility while operating.

## INSTRUMENTATION

There is now a range of instrumentation available that provides adequate optics for work in neonatal and pediatric patients including 3-5 mm trocars for 2.7-4.5 mm instruments (Figure 2). It has been shown that the use of these smaller caliber instruments in pediatric patients is associated with greater postoperative comfort. Traditional 10 mm laparoscopes can be used in adolescents if required.

Trocars are available as reusable metal, disposable plastic and newer radially expanding models (Figure 3). The choice of trocar is important since leakage from around these sites and compensatory rapid CO<sub>2</sub> insufflation into the abdomen may contribute to hypothermia, especially in neonates. A recent report suggests that the radially expand-



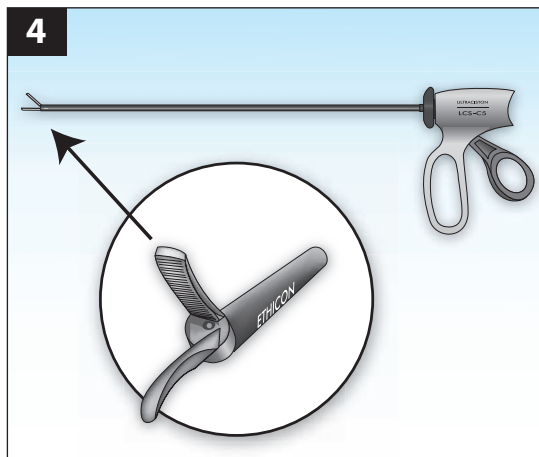
ing trocars may be the most effective in very young patients because they have a lower incidence of slippage from the abdominal wall.

Laparoscopes ranging from 2.7 to 10 mm in diameter with angles from 0° to 45° allow the surgeon a wide choice of views depending upon the size of the patient. The newest cameras offer an autorotation feature maintaining an upright image irrespective of the angle of the camera. All these features are helpful when large masses or adhesions obscure the view within the abdomens of small infants.

In addition to conventional energy sources such as monopolar and bipolar cautery, the ultrasonically activated, harmonic scalpel can be a useful tool in pediatric laparoscopy (Figure 4). It uses mechanical energy, generated by a vibrating crystal in the hand piece, to cut and coagulate without the transmission of energy to structures out of immediate view. This instrument has been used to coagulate gonadal and bowel vessels in very small infants including neonates. The reported benefit of this dual action instrument in pediatric patients is a decrease in operating time resulting in a shorter time under anesthesia.

## PORT PLACEMENT AND ENTRANCE INTO THE ABDOMEN

Surgical complications in pediatric laparoscopy are often related to the introduction of the Veress needle or the first trocar. In a large review of 5400 laparoscopic surgeries performed in patients



ranging in age from from 0-20 years, the significant predictors of complications were operator experience and the method used to create a pneumoperitoneum. Specifically, the Veress needle was associated with a 2.6% major complication rate (viscus or major blood vessel injury) compared with 1.2% for the open technique. This difference continued even in experienced operators (>100 laparoscopic cases). This finding has led to the suggestion that the open technique is the method of choice for the creation of the pneumoperitoneum in pediatric patients, however, the Veress needle is used by many practitioners.

In neonates, the umbilical vessels may still be patent at the time of surgery, therefore, correct identification and ligation of these is essential before proceeding with abdominal entry (Figure 5). This can be done following skin incision at the umbilical site with the use of small claw retractors to retain the skin and fine hemostat clamps to dissect the superficial tissue away until the umbilical vessels are

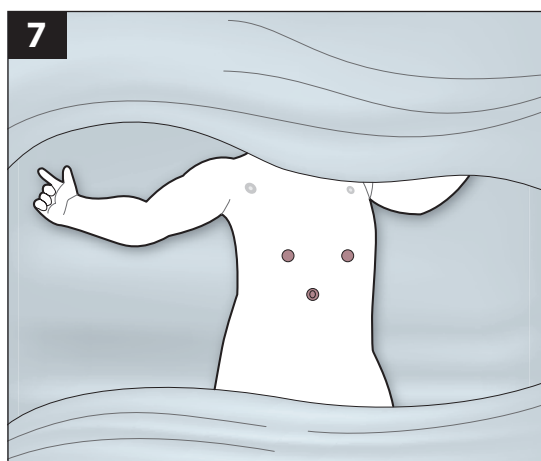
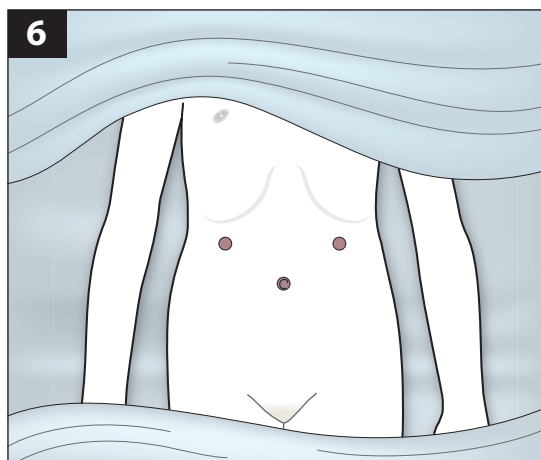
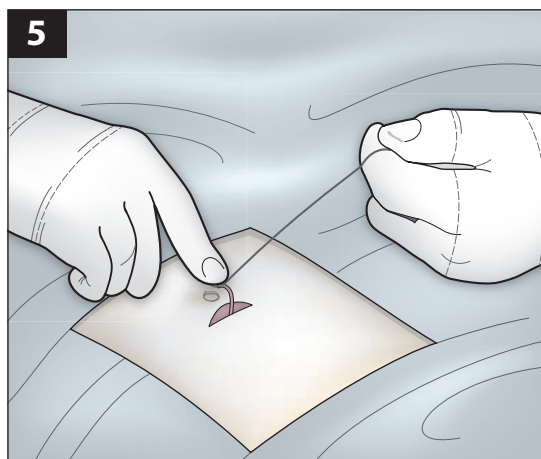
identified, clamped, and suture ligated. Due to the intraabdominal location of the bladder, there is a reduced margin of safety in children in comparison with adolescents or adults. Preoperative emptying is therefore very important in avoiding secondary trocar injury especially if suprapubic trocars are used.

Port placement on the abdomen will depend upon the operation contemplated and surgeon preference. However, in prepubertal patients with large ovarian masses, the placement of secondary trocars that are high, typically 2 fingers above the umbilicus, and lateral to the inferior epigastric artery may assist with access to the pathology (Figure 6). The primary trocar in a neonate is placed through the umbilicus and the ancillary ports are placed superior and lateral to this in the midclavicular line (Figure 7).

The fascia of all ports  $\geq 5$  mm in diameter should be closed in pediatric patients since there is a reported 2.7% incidence of port site hernia through open incisions. More recently there have been reports of omental herniation through a 2 mm port site. Closure can be achieved with claw retractors at the site of incision, identification of the fascia with Kocher's clamps and closure with an 0 vicryl suture on a UR5 needle.

## OVARIAN MASSES

A young girl with a persistent or complex appearing ovarian mass is a typical indication for surgery in the pediatric population and the likely ovarian pathology is dependent upon patient age. The



techniques for removing ovarian masses including cystectomy, oophorectomy and the use of an endobag is the same in children as adults and is described in the chapter on ovarian surgery. In neonates, ovarian cysts are functional as the result of maternal gonadotrophin stimulation during the antenatal period. The indications for surgery therefore are complex, enlarging or symptomatic masses where torsion is suspected or the diagnosis is in doubt. Since the incidence of ovarian malignancy in this age group approaches zero, laparoscopy is appropriate for operators experienced with neonatal surgery. In the prepubertal age group, approximately 11% of noninflammatory ovarian masses requiring surgery are malignant, therefore, careful investigation on an individual basis is essential. If pre-

operative assessment suggests malignancy, laparotomy and staging is indicated unless the surgeon is proficient with laparoscopic oncologic surgery.

Ovarian torsion occurring in the pediatric population is often associated with either a normal ovary or benign ovarian pathology. Laparoscopic management utilizing detorsion with or without cystectomy is becoming more common. Long-term follow up of these children reveals folliculogenesis and resumption of normal size over time.

In conclusion, laparoscopy, when performed by experienced practitioners is a safe and practical approach to the surgical management of a variety of gynecological problems in children.

## SUGGESTED READING:

Rubin SZ, Davis GM, Sehgal Y, Kaminski MJ. Does laparoscopy adversely affect gas exchange and pulmonary mechanics in the newborn? An experimental study. *J Laparoendo Surg* 1996;6(Suppl 1):S69-73

Fujimoto T, Segawa O, Lane GJ, et al. Laparoscopic surgery in newborn infants. *Surg Endosc* 1999;13:773-7

Fujimoto T, Segawa O, Kobayashi H, Lane G, Miyano T. Endosurgery in children: Prospects and problems-An analysis of 88 cases. *Ped Endosurg Innov Tech* 1997;1(3):189-95

Gomez Dammeier BH, Karanik E, Gluer S, Jesch NK, Kubler J, Latta K, Sumpelmann R, Ure BM. Anuria during pneumoperitoneum in infants and children: a prospective study. *J Pediatr Surg* 2005;40(9):1454-8

Matsuda T, Ogura K, Uchida J, et al. Smaller ports result in a shorter convalescence after laparoscopic varicocelectomy. *J Urol* 1995;153:1175-7

Eposito C, Ascione G, Garipoli V, et al. Complications of pediatric laparoscopic surgery. *Surg Endo* 1997;11(6):655-7

Peters CA. Complications in pediatric urological laparoscopy: results of a survey. *J Urol* 1996;155(3):1070-3

Ure BM, Bax NM, van der Zee DC. Laparoscopy in infants and children: A prospective study on feasibility and the impact of routine surgery. *J Ped Surg* 2000;35(8):1170-3

Backman T, Arnbjornsson E, Kullendorff CM. Omentum herniation at a 2-mm trocar site. *J Laparoendosc Adv Surg Tech A* 2005 Feb;15(1):87-8

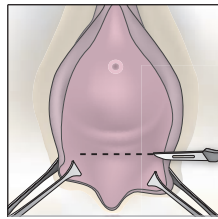
Templeman CL, Reynolds AJ, Hertweck SP, Nagaraj H. The laparoscopic management of neonatal ovarian cysts. *J Am Assoc Gyn Laparosc* 2000;7:401-404

Templeman CL, Fallat M, Blinchevsky A, Hertweck SP. Noninflammatory ovarian masses in girls and young women. *Obstet Gynecol* 2000; 96:229-223

Celik A, Ergun O, Aldemir H, Ozcan C, Ozok G, Erdener A, Balyk E. Long-term results of conservative management of adnexal torsion in children. *J Pediatr Surg* 2005 Apr;40(4):704-8



# ENDOSCOPIC DIAGNOSIS AND CORRECTION OF MALFORMATIONS OF FEMALE GENITALIA



*Leila V. Adamyan, M.D.*

*Katerine L. Yarotskaya, M.D.*

**C**ongenital malformations of female genitalia comprise about 4% of all congenital anomalies. These malformations are associated with extragenital anomalies in about 74% of cases manifesting as skin marks and skeletal defects, as well as breast, heart, renal and digestive system anomalies. Diagnosis of malformations of the uterus, and/or vagina present significant difficulties that may confuse the character of the disease and cause incorrect, and sometimes, unwarranted or aggressive radical surgery in 24-34% of patients. The high rate of diagnostic mistakes may be due to absence of a universal classification of genital malformations. Suggested classifications do not reflect all clinical-anatomic features of malformations, which are essential for an optimal treatment strategy that will be beneficial for the patient's health, reproductive and sexual function, and general quality of life.

Presently, invasive diagnostic tools (ultrasonography, hysterosalpin-gography, magnetic resonance imaging and spiral computer tomogra-phy) together with endoscopic techniques may permit the determination of the real character of a malformation of the uterus and/or vagina, and reveal concomitant extragenital anomalies of the urinary and digestive



systems. The correct diagnosis will allow the rational management of anomalies. Based on the results of clinical examination and treatment of 855 patients, using modern imaging techniques, hysteroscopy and laparoscopy, L.V. Adamyan and co-authors (1998) introduced a classification of genital malformations and outlined a paradigm of examination, surgical treatment and rehabilitation of patients with malformations. We suggest the original methods of reconstructive plastic surgery using an endoscopic approach, which we consider the methods of choice for this complicated pathology.

## CLASSIFICATION OF MALFORMATIONS OF UTERUS AND/OR VAGINA

### Class I: Vaginal aplasia

1. Complete aplasia of vagina and uterus
  - a) one uterine myometrial rudiment (located laterally or in the center of the small pelvis)
  - b) two myometrial rudiments
  - c) absence of uterine rudiments
 

In this malformation:

    - Uterine tubes are not connected with uterine rudiments
    - Uterine rudiments have no functional endometrium and no endometrial cavity
    - Adnexa are located high on the lateral pelvic walls
2. Complete aplasia of vagina and functional rudimentary uterus
  - a) one or two functional uterine rudiments
  - b) functional rudimentary uterus with aplasia of the cervix

- c) functional rudimentary uterus with aplasia of the cervical canal
  - Uterine tubes are connected with rudimentary uterus
  - The layers of uterine wall are differentiated
  - In all variants hemato- or pyometra, chronic endo- and perimetritis, hemato- or pyosalpinx may be observed
3. Functional uterus and partial aplasia of vagina
  - a) aplasia of upper 1/3; a1) aplasia of upper 2/3
  - b) aplasia of middle 1/3 ;b1) aplasia of middle part of vagina comprising 2/3 of its length
  - c) aplasia of lower 1/3;c1) aplasia of lower 2/3 of vaginal length
    - In a) and a1) hemato- and/or -pyometra, hemato- and/or pyosalpinx
    - In b) and b1) hemato- and/or pyocolpos
    - In c) and c1) hemato- and/or pyocolpos

### Class II: Unicornuate uterus

1. Unicornuate uterus with rudimentary horn communicating with the cavity of the main horn
2. Unicornuate uterus with noncommunicating rudimentary horn
  - In both variants endometrium of the rudimentary horn may be functional or nonfunctional
3. Rudimentary horn without cavity
4. Absence of rudimentary horn

### Class III: Uterus and vagina duplex

1. Uterus and vagina duplex without obstruction to menstrual outflow
2. Uterus and vagina duplex without partial aplasia of one vagina
  - a) aplasia of upper 1/3; a1) aplasia of upper 2/3

- b) aplasia of middle 1/3; b1) aplasia of middle part of vagina comprising 2/3 of its length
- c) aplasia of lower 1/3; c1) aplasia of lower 2/3 of vaginal length
- In a) and a1) hemato- and/or pyometra, hemato- and/or pyosalpinx
  - In b) and b1) hemato- and/or pyocolpos
  - In c) and c1) hemato- and/or pyocolpos, fistula in the vagina with partial aplasia
3. Uterus and vagina duplex with nonfunctional single uterus

#### **Class IV: Bicornuate uterus**

1. Arcuate form
2. Incompletely bicornuate form
3. Complete bicornuate form

#### **Class V: Intrauterine septum**

1. Complete intrauterine septum (reaching internal cervical os)
2. Incomplete intrauterine septum
  - The septum may be thin or wide-based, one hemicavity may be longer than other

#### **Class VI: Malformations of uterine tubes and ovaries**

1. Unilateral aplasia of adnexa
2. Aplasia of one or both uterine tubes
3. Accessory uterine tubes
4. Aplasia of ovaries
5. Hypoplasia of ovaries
6. Accessory ovaries
  - These malformations may be isolated or associated with other uterine and/or vaginal malformations

#### **Class VII: Rare forms of genital malformations**

1. Genitourinary malformations: extrophy of the urinary bladder

2. Genitorectal malformations: recto-introital fistula associated with aplasia of uterus and vagina; recto-introital fistula associated with unicornuate uterus and functional rudimentary uterus
  - These malformations may be isolated or associated with other uterine and/or vaginal malformations

### **CLASS I: APLASIA OF VAGINA**

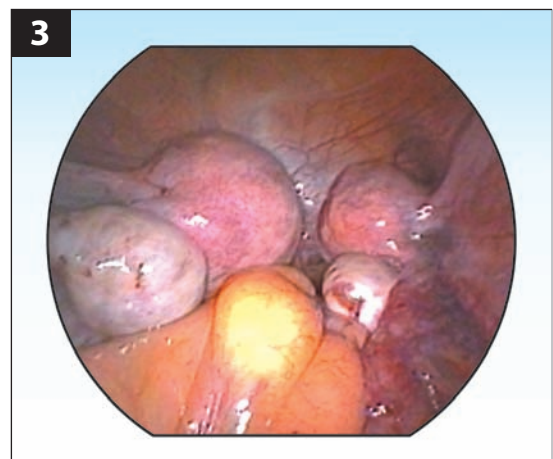
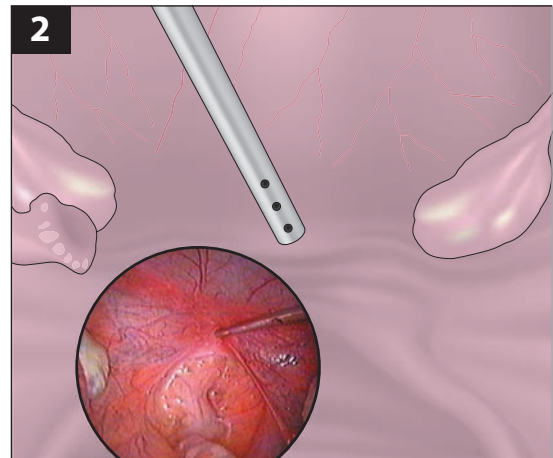
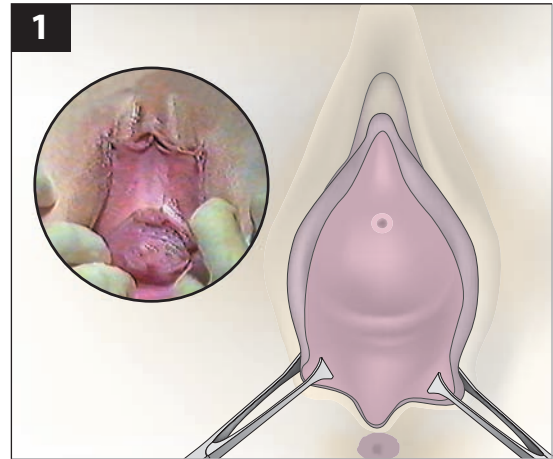
#### **1.1. COMPLETE APLASIA OF VAGINA AND UTERUS**

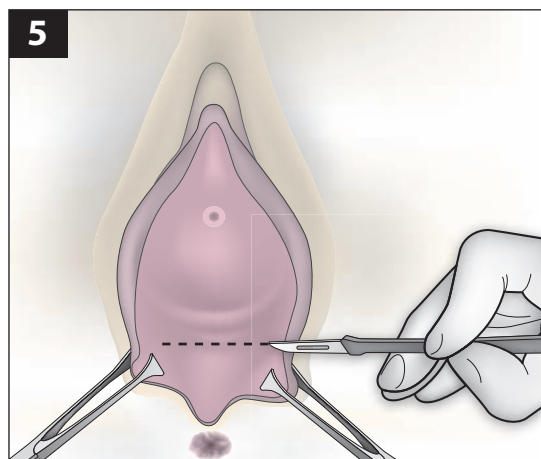
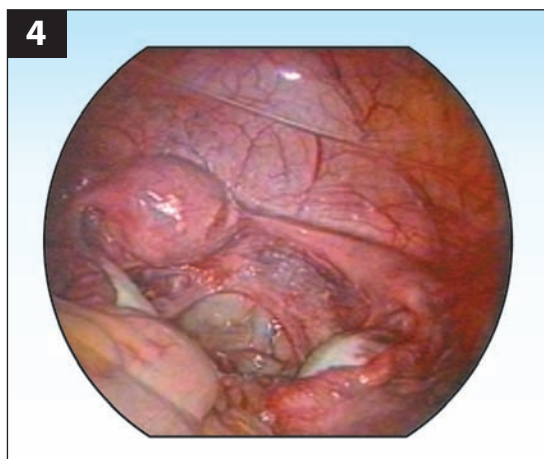
Aplasia of the vagina and uterus (Mayer-Rokitansky-Kuster-Hauser syndrome) is a malformation characterized by congenital absence of the uterus (usually presented by two muscular rudiments, but other variants can also be encountered: asymmetric muscular mounds, complete absence of rudiments, etc.), and vagina, normally functioning ovaries, female phenotype and karyotype (46,XX), and is often accompanied by other congenital anomalies (skeletal, urinary, digestive) (Figures 1-4). Figure 2 presents a laparoscopic view of aplasia of uterus and vagina: absence of uterine rudiments. Laparoscopic view of aplasia of uterus and vagina with symmetric uterine rudiments is shown on Figure 3, and a laparoscopic view of aplasia of uterus and vagina with asymmetric uterine rudiments is presented on Figure 4.

The main clinical features of uterine and vaginal aplasia are the absence of menstruation and inability to have vaginal sexual intercourse. The uterine rudiments may be affected by adenomyosis, causing pelvic pain.

The diagnosis is based on the patient's complaints, physical examination, ultrasonographic data and other methods of visualization (MRI, SCT), which are necessary to determine if associated malformations (especially of the urinary system which occur in almost 40% of cases) are present.

Surgical correction, although not absolutely necessary, is required if normal sexual activity is anticipated. Gynecologists have long discussed the ethics involved in creating an artificial vagina. Most surgeons are in agreement that safe and reliable methods are needed to achieve the goal of a functional vagina. Different methods of colpoelonylation appear to be minimally invasive, but require considerable time and are not always effective. Another approach to correct this malformation is based on techniques to create a canal between the urinary bladder and rectum. In this case, subsequent tamponade and dilatation with various prosthetic appliances is required. Another possibility is creating a lining with skin flaps or segments of rectum, sigmoid, small intestine, or pelvic peritoneum. One-stage colpoptoiesis from pelvic peritoneum has proved to be the most simple and at the same time the most safe and effective. This method supplies a better quality of neovagina with rapid epithelization and sufficient capacity and depth. In 1993 L.V. Adamyan introduced a method of colpoptoiesis incorporating pelvic peritoneum using laparoscopy in all the main steps of the operation, confirming diagnosis, identification and opening of the peritoneum,



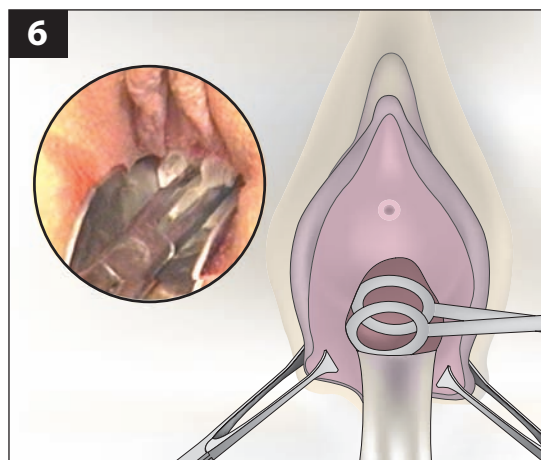


and creation of a vaginal vault, which we consider to be a method of choice for correction of this anomaly.

#### SURGICAL TECHNIQUE

Surgery is performed by a combined laparoscopic-perineal approach. The patient is placed in the lithotomy position with legs wide apart. Under general (endotracheal) anesthesia, diagnostic laparoscopy is carried out to specify the character of malformation and to evaluate the mobility of the peritoneum. The number and location of muscular rudiments, and their status are noted. Enlarged uterine rudiments, causing pelvic pain and possibly affected by adenomyosis, should be removed laparoscopically with subsequent restoration of peritoneum.

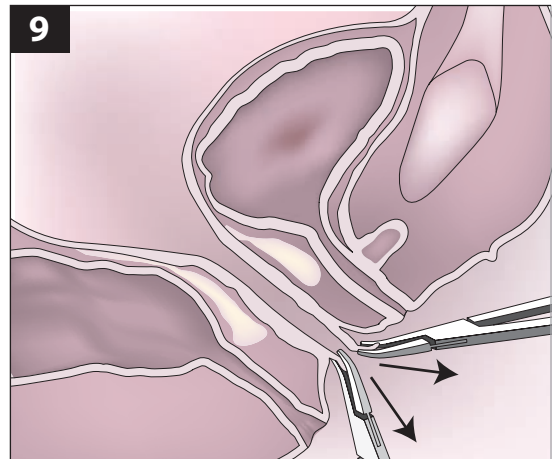
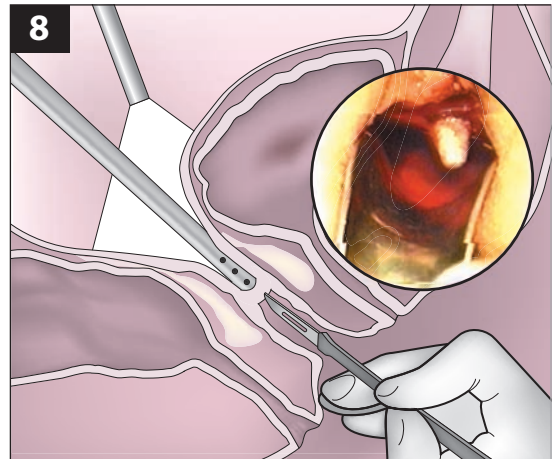
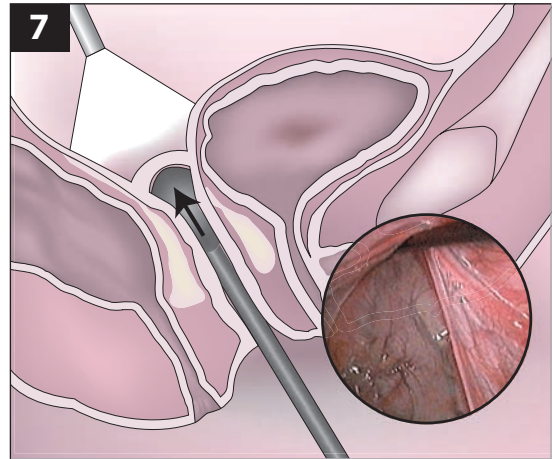
After laparoscopy, the perineal step is initiated: the skin is incised 3-3.5 cm transversally between the rectum and urinary bladder at the level of the lower border of the labia minora (Figure 5). By sharp and/or blunt dissection in a strictly

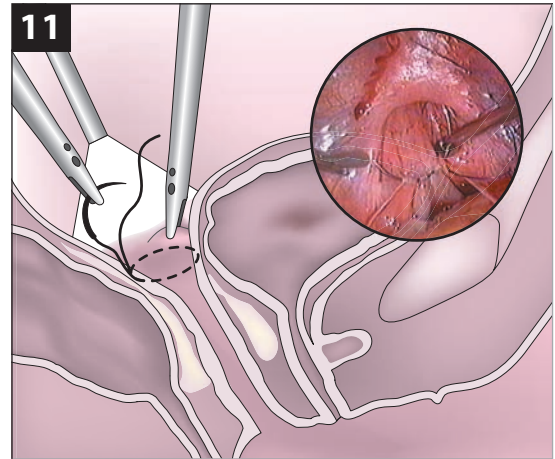
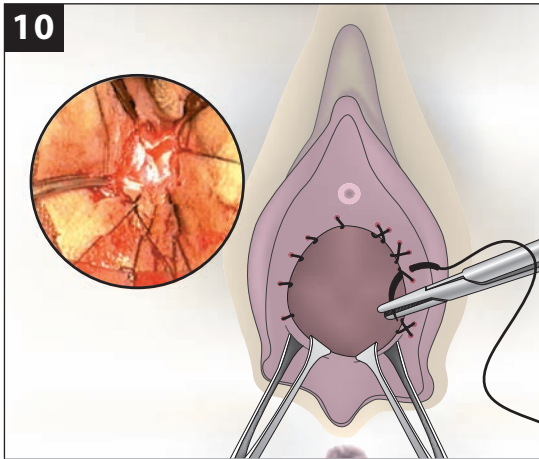


horizontal direction along the urinary bladder, the canal is created (Figure 6). This step is the most difficult because of the high risk of possible injury to the bladder and rectum. Most difficulties occur in the case of atypical (low) location of the urethra and when scarring is present at the site of the potential introitus. Scarring may be caused by repeated courses of colpoelongation, attempts at sexual intercourse or perineal surgery, which may lead to formation of a false passage directed toward the rectum. The

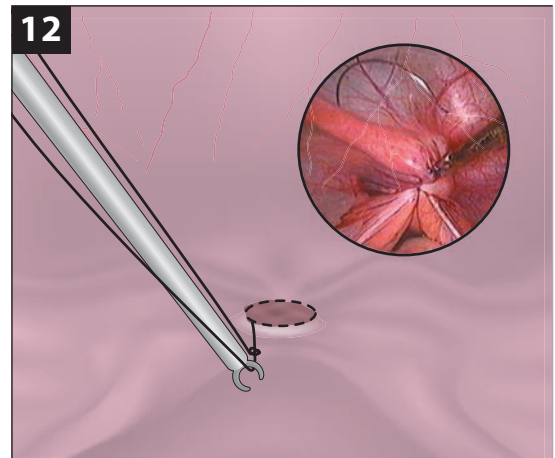
canal is formed up to the pelvic peritoneum. The most crucial step of the operation – identification of peritoneum – is performed using the laparoscope (Figure 7). The most mobile part of the peritoneum is between the bladder and the rectum and is often divided by the transverse fold between two muscular rudiments. It is identified, then marked with an atraumatic laparoscopic instrument (a manipulator or forceps) and is brought down into the created canal. The peritoneal fold is grasped in the canal by the forceps and transected either laparoscopically or from below (Figure 8). The edges of peritoneal incision are brought down and sutured to the edges of the skin incision with separate vicryl stitches, forming the introitus (Figures 9 and 10). In case of previous scarring and excessive bleeding in the canal, fibrin glue made from the patient’s blood may be applied for better attachment of the peritoneum to the canal walls. However, this is not available in the United States. A moist sponge or vaginal probe is then placed at the introitus of the neovagina, to re-establish the pneumoperitoneum.

Formation of the neovaginal vault – the final step of the operation – is performed by laparoscopic placement of one purse-string or two semipurse-string sutures on a curved needle, incorporating the bladder peritoneum, muscular uterine rudiments, and peritoneum lining the pelvic sidewall and sigmoid colon (Figure 11). The suture is tied with an extracorporeal knot. In case there is too much tension in the tissues the vault can be formed by separate sutures, connect-





ing the transverse peritoneal fold with muscular rudiments and peritoneum of the back-side pelvic walls (Figure 12). When muscular rudiments are absent (for example, in patients with testicular feminization) and there is a shortage of peritoneum, the neovaginal vault can be formed using biologically compatible polymeric material, (e.g. copolymer of glycolid and lactid (vicryl mesh) or polyglycolic acid (dexon mesh). The mesh is sutured endoscopically to the anterior, posterior and lateral aspects of the pelvic end of the neovaginal tunnel to provide the barrier between the pelvic cavity and the neovagina.



Laparoscopically assisted colpopoiesis takes approximately 25-45 min, and the operation itself is almost bloodless. Antibiotics are introduced intraoperatively for prophylaxis. Subsequent antibacterial therapy for 24-36 hours is considered only if there is a high risk of infectious complications. A Foley catheter is placed into the bladder immediately after the operation to facilitate urination which

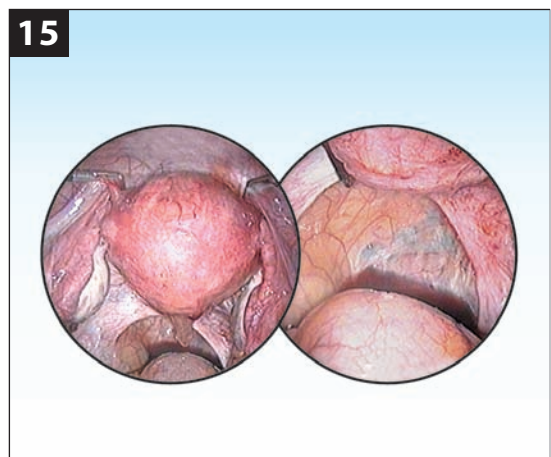
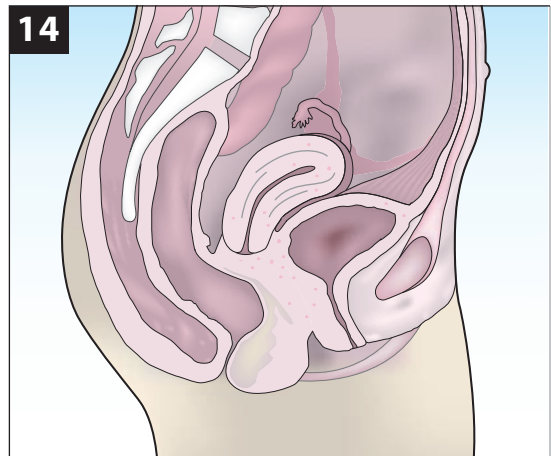
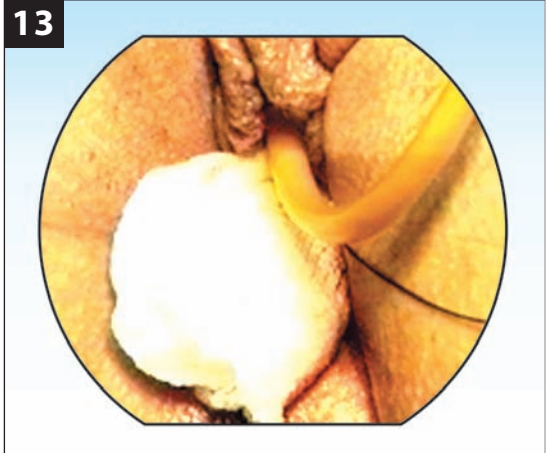
may be difficult in the early postoperative period due to a displacement of the urethral orifice by tension of the anterior neovaginal wall. A gauze sponge moistened with an antiseptic solution and Vaseline is introduced into the neovagina for 1-2 days (Figure 13). The patients are allowed to sit and stand 5-6 hours after surgery. Gynecologic examination is performed on the 5-7th postoperative day to assess the reaction and patency of the tissues of the neovagina. The neovagina usually permits insertion of two fingers

and its length varies from 11-12.5 cm. The patient is asked to wear a sterile glove and to insert her index finger lubricated with KY Jelly into the neovagina. This manipulation is necessary to acquaint the patient with her new anatomy, and for maintenance of the neovaginal caliber until she starts regular sexual activity, which is allowed 2-4 weeks after this procedure. Most patients do not feel any discomfort during coitus and appear to be satisfied with their sexual activity which significantly contributes to their psychological well-being.

The main features of the neovagina (the ability to perform a vaginal examination and to permit intercourse) are assessed 3-4 months after the operation. On examination the border between the introitus and neovagina itself is absent; the vagina is about 11-12 cm long with sufficient caliber. The walls are moderately folded, producing some mucus. Morphologic and electron-microscopic examination of the neovaginal wall reveals that 3 months after colpoptosis the neovaginal epithelium is similar to the stratified squamous epithelium of a normal vagina, most likely due to metaplasia.

## 1.2. APLASIA OF VAGINA IN CASE OF FUNCTIONAL UTERUS

Aplasia of the vagina can be complete or partial and associated with a functional normal or functional rudimentary uterus (Figures 14, 15). The main clinical features in this malformation are absence of menstruation, cyclic or permanent



pelvic pain from menarche, and inability to have vaginal sexual intercourse.

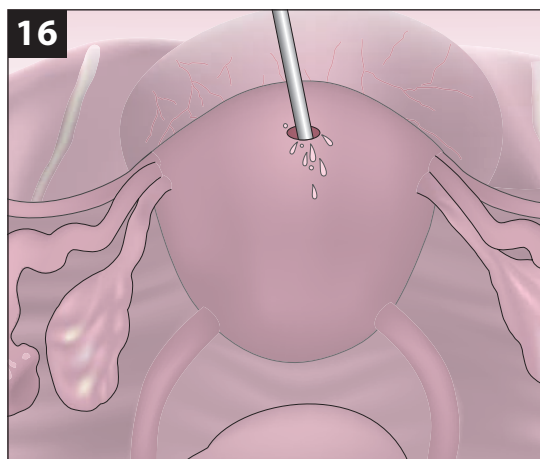
Diagnosis is based on the patient's complaints, physical examination, ultrasonographic data and other methods of visualization (MRI, SCT). Diagnostic difficulties may lead to unjustified surgery (in 24-65% of cases). In most of the patients hemato- and/or pyometra, chronic endometritis and perimetritis, hemato- and pyosalpinx and in patients with partial vaginal aplasia hemato- and/or pyocolpos, are found.

Surgical correction is necessary and should be undertaken as soon as the diagnosis is established. One should remember that this malformation usually manifests itself in adolescence and may result in a distortion of the reproductive organs' anatomy. Definitive surgery is essential for the further reproductive health of these patients.

## METHODS OF SURGICAL CORRECTION

The patients with partial vaginal aplasia and a normal functional uterus, accompanied by hematocolpos, need conventional vaginoplasty. Laparoscopy in this malformation is absolutely necessary to evaluate the status of the internal genitalia (the character of the malformation, damage caused by menstrual reflux) and for correction of pathology (pelvic irrigation, drainage of the hematosalpinx, adhesiolysis, endometriosis elimination, etc.).

In patients with complete aplasia of the vagina and a functional uterus, the first crucial aspect to be determined in



order to choose the correct surgical modality, is absence or presence of a cervical canal. For this purpose, we have introduced a method of retrograde hysteroscopy (by laparoscopic approach) by perforating the uterine fundus (Figure 16). The correction, which may be attempted to preserve a functional rudimentary uterus in patients with cervical and vaginal aplasia, is the creation of a tunnel between the uterus and neovagina, which can be performed as follows:

## OPERATIVE TECHNIQUE

- Transverse incision of perineal skin between the urethra and lower border of labia minora;
- Creation of a canal between the urinary bladder and rectum;
- Simultaneous laparoscopy, pelvic revision, final diagnosis;
- Laparoscopic grasping and opening of peritoneum of rectouterine pouch;
- Bringing down the peritoneal incision edges and suturing to the introital skin;



- Laparoscopic hysterotomy and retrograde hysteroscopy for identification of a site for further tunnel creation between the uterine cavity and neovagina;
- Canalization of the uterine wall towards the created tunnel;
- Fixation of the uterus at the tunnel, introduction of the dilator into the neocanal.

If such correction appears impossible or ineffective, resulting in atresia of the previously created tunnel, the method of choice is total laparoscopic hysterectomy and laparoscopically assisted colpoptosis from pelvic peritoneum. Total laparoscopic extirpation of a functional uterus in case of cervical and vaginal aplasia is performed according to our technique of laparoscopic hysterectomy applied for other uterine pathology, and includes the following steps:

- Coagulation and transection of round ligaments with simultaneous dissection of the plica vesical-utero fold, downward bladder dissection and anterior dissection of uterine vessels;
- Fenestration of posterior leaves of broad ligaments and dissection to the uterosacral ligaments with their partial transection and simultaneous exposition of the uterine vessels;
- Ligation of ovarian ligaments and proximal uterine tubes;
- Suturing of ascendent uterine vessels;
- Transection of ovarian ligaments and uterine tubes (if technically advisable);
- Transection of uterine vessels and circular dissection of posterior aspect

of the uterus from the pelvic fascia with transection of rudiments of cardinal and uterosacral ligaments. The specificity of this step of the operation is substantiated by abnormal development of the uterus (absence of cervix and normal cardinal and uterosacral ligaments).

Another peculiarity of this operation is the inability to use a uterine manipulator. Therefore, this requires the manipulation of the uterus with laparoscopic graspers introduced through secondary abdominal punctures. The uterus is removed from the abdominal cavity by electro-mechanical morcellation. Colpoptosis is performed according to the technique described above, with particular care of the peritoneum, which can be damaged by hysterectomy, adhesiolysis, and removal of endometriosis and when forming the neovaginal vault. Average operating time is 1.5 hours with minimal blood loss. Average hospital stay is 4.5 days.

## **CLASS II: UNICORNUATE UTERUS**

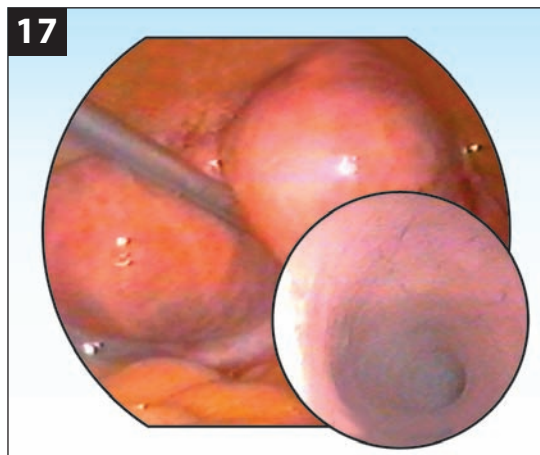
Unicornuate uterus is an anomaly caused by formation of only one paramesonephric duct, whereas, the other has remained undeveloped. From an embryologic view, a unicornuate uterus is half of a normal uterus. The variants of the horn, or unicornuate uterus with a supplementary rudimentary horn may be encountered. Sometimes the rudimentary horn is embedded in the wall of the main horn.

Unicornuate uterus without a supplementary horn usually does not cause any gynecologic or obstetric problems. On the contrary, the patients with a supplementary non-communicating (or obstructed) rudimentary horn with functioning endometrium complain of painful menses from menarche or of perimenstrual pain due to the formation of hematometra. One of the potential dangers in this malformation is the possibility of an ectopic pregnancy in the rudimentary horn, as well as a high rate (over 50%) of endometriosis. Thus, the removal of a rudimentary horn is substantiated by a range of indications.

Preliminary diagnosis is based on the patient's complaints, physical examination (pelvic mass), and information provided by imaging techniques – ultrasonography, MRI, SCT. Definite diagnosis, however, is possible only during laparoscopy and hysteroscopy (Figure 17), which allows the differentiation of four variants of this malformation: 1) unicornuate uterus with supplementary rudimentary horn communicating with principal horn; 2) unicornuate uterus with supplementary non-communicating horn (sometimes embedded in the wall of the main uterine horn); 3) unicornuate uterus with supplementary horn without endometrial cavity; 4) unicornuate uterus without supplementary rudimentary horn.

## SURGICAL CORRECTION

Laparoscopic removal of the rudimentary horn is performed according to the hysterectomy technique.



- The horn is grasped, and round ligament, proximal tube, and ovarian ligament are coagulated and transected;
- Broad ligaments and utero vesical-fold are dissected up to the level of junction between the principal and rudimentary horn, exposing uterine vessels supplying rudimentary horn;
- Securing of the vessels by extracorporeal suturing or bipolar coagulation (as the diameter of vessels is rather small);
- Transection of the rudimentary horn by monopolar cutter or ultrasonic scalpel;
- Endosutures are placed at the uterine wound;
- Rudimentary horn is removed from the abdominal cavity by electric morcellation or through a colpotomy.

Our technique of resection of the rudimentary horn when incorporated in the uterine wall, allows preservation of the uterine wall due to minimal resection of myometrium:

1. The wall is opened over the rudimentary horn cavity;

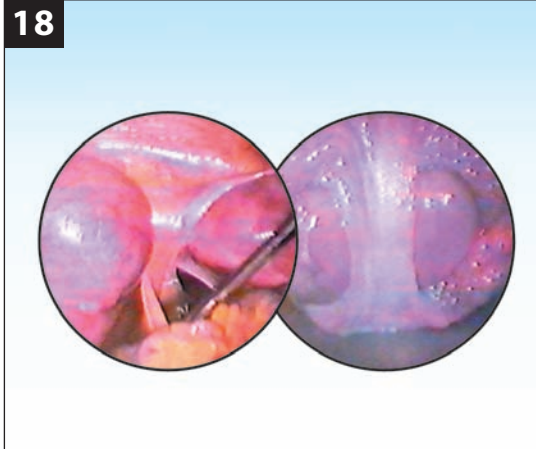
2. The cavity lining is ablated by CO<sub>2</sub> laser;
3. The uterine wall is restored by suturing.

These techniques are usually free from complications. The patients may stand up and walk 2-3 hours after surgery, and are discharged on the 2nd or 3rd postoperative day. Pregnancy is allowed 2-3 months after operation, and a vaginal delivery may be performed.

### CLASS III: UTERUS DUPLEX

Uterus duplex is characterized by presence of two uteri and one or two vaginas (Figure 18). The following variants of this malformation are differentiated: uterus duplex without obstruction to menstrual outflow; uterus and vagina duplex with partial vaginal aplasia; uterus and vagina duplex where one uterus is non-functional.

Clinical manifestation depends upon the malformation variant. The first variant (uterus duplex without obstruction to menstrual outflow) in most cases does not cause any problems and is often an occasional discovery, but, if not previously diagnosed, there may be difficulty in choosing the mode of delivery in a pregnant patient. Uterus and vagina duplex with partial aplasia of one hemivagina is accompanied by pelvic pain, caused by hematocolpos. Sometimes the diagnosis presents difficulties when one uterus is normally menstruating. Patients in whom one uterus is non-functional may appear infertile if intercourse involves the vagina of the non-functional uterus.



Patient's complaints, physical examination, ultrasonographic data and other methods of visualization (MRI, SCT) contribute to the preliminary diagnosis but only simultaneous hysteroscopy and laparoscopy provide the final differentiation between uterus duplex and other symmetric malformations (complete intrauterine septum and bicornuate uterus).

### SURGICAL CORRECTION

Uterus duplex without obstruction to menstrual outflow itself does not necessitate surgical correction. In patients with uterine and vagina duplex with complete or partial aplasia of one of the hemivaginas, laparoscopy is used for final diagnosis, correction of associated gynecologic disease and control after resection of the wall of the obstructed hemivagina which must provide a wide communication between the latter and the functional vagina. Laparoscopy with simultaneous correction of gynecologic disease during vaginoplasty in patients aged 12-15 years provides normal reproductive function.

## CLASS IV: BICORNUATE UTERUS

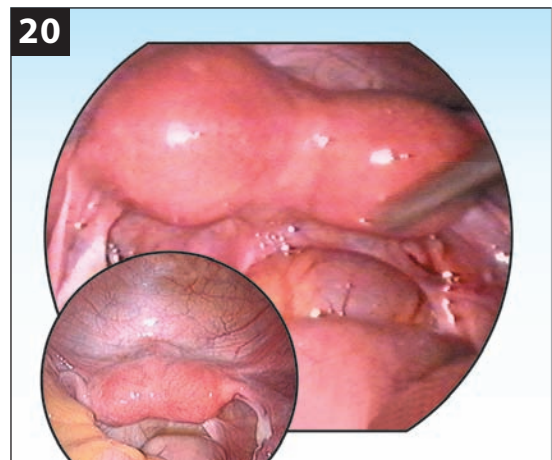
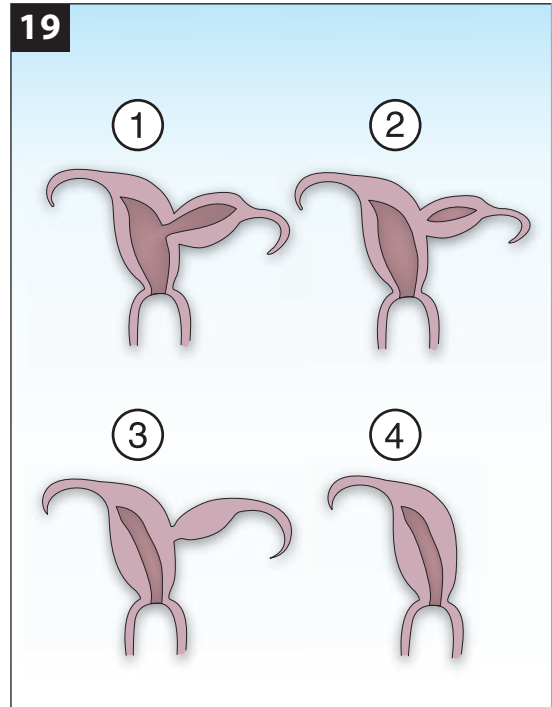
Bicornuate uterus is a malformation where the upper part of the uterine body is divided into two horns. In some patients the bicornuate uterus is found during routine examinations or treatment for other gynecologic diseases. In some patients this malformation may be a cause of miscarriage, isthmic-cervical insufficiency, and abnormal labor. Various anomalies are presented on Figure 19.

None of the available diagnostic tools (ultrasonography, CT, MRI, HSG, hysteroscopy or laparoscopy alone) is adequate to provide 100% accuracy in differentiation between bicornuate and septate uterus. The hysteroscopic picture may look like that of an intrauterine septum. Laparoscopic examination performed together with hysteroscopy is crucial because the definitive diagnosis is possible only after visual evaluation of the external shape of corpus uteri (Figure 20).

### SURGICAL CORRECTION

The only indication for surgical correction of this malformation is miscarriage. We use our own methods of combined laparoscopic-hysteroscopic metroplasty based on the principles of the conventional Strassman technique, comprising creation of a united cavity that includes:

1. Dissection of the uterine fundus in the frontal plane with opening of both hemicavities;

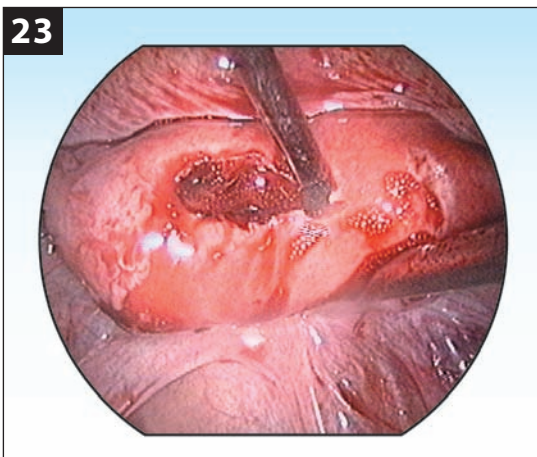
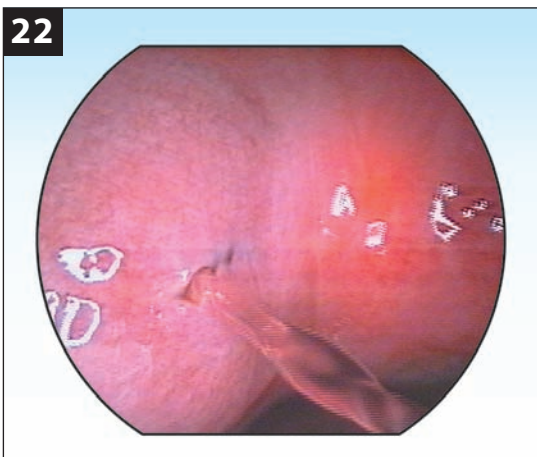
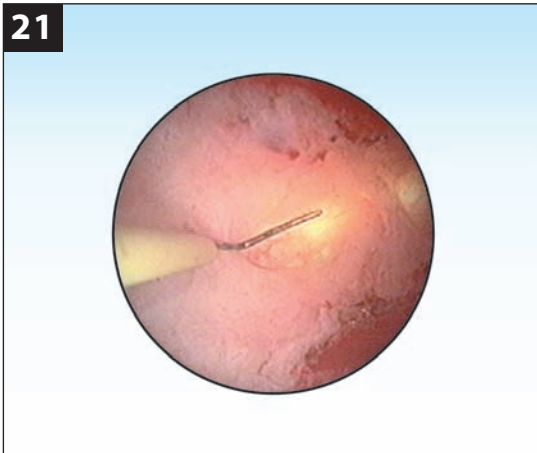


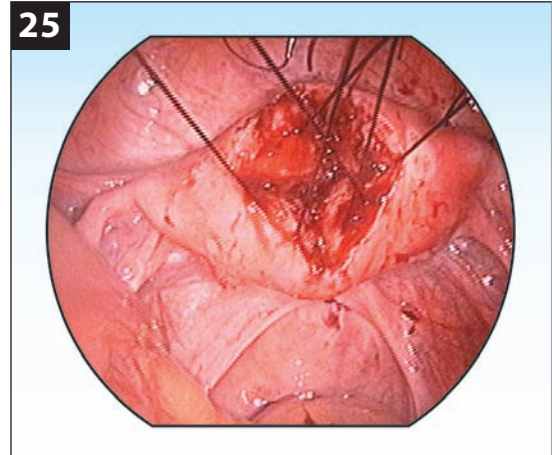
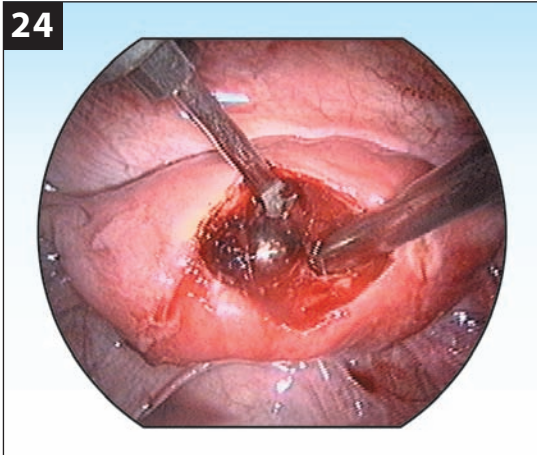
2. Suturing of the uterine wound in the sagittal plane.

In case of incomplete bicornuate uterus, and if simultaneous distension of both hemicavities is possible, the operation is started by hysteroscopy. Five per

cent mannitol or 5% glucose solution may be used as the distension media. The mucosal-muscular layer of the uterine wall is dissected by the hook electrode of the resectoscope up to the serosa in the frontal plane, avoiding the tubal ostia. The depth of dissection is visually controlled hysteroscopically and laparoscopically by transillumination of the uterine wall (Figure 21). The hysteroscopic step is terminated by planned perforation of the uterus, which is necessary to determine the direction of the incision of the serosa. Further steps are performed laparoscopically (Figure 22).

Laparoscopy is performed through four punctures of the anterior abdominal wall. The uterine serosa is transected in the frontal plane by a monopolar electrode or ultrasonic scalpel (Figure 23). Hemostasis is achieved by bipolar coagulation (Figure 24). Two layers (mucosal-muscular and muscular-serosal) of absorbable sutures are placed at the uterine wound in the sagittal direction (Figures 25 and 26). The ends of the first layer of sutures are withdrawn from the abdominal cavity through a central puncture outside the trocar sleeve, and are left untied until the last suture is placed. The ligatures are then consecutively introduced into the trocar sleeve and tied extracorporeally. To avoid excessive tension and tissue sawing during knot tying, both halves of the uterus are brought to the midline with the manipulators. The serosal-muscular suture may be placed continuously. Second-look laparoscopy and hysteroscopy performed 3 months after endoscopic metroplasty show no



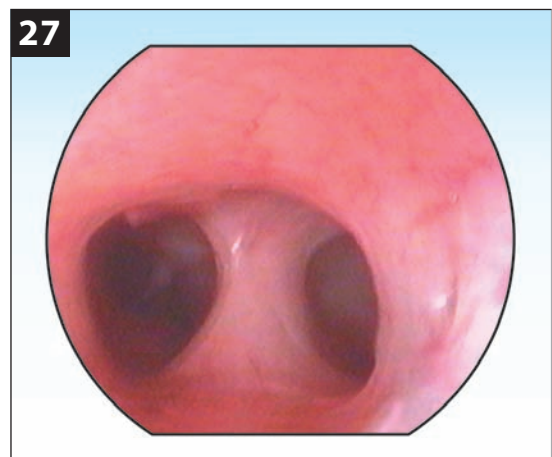
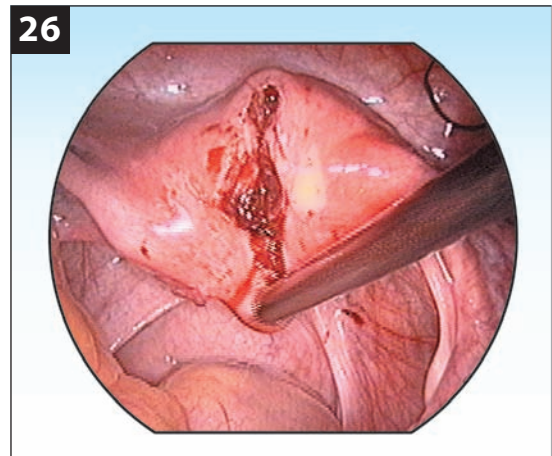


evidence of adhesions either in the pelvis, or in the uterine cavity. Satisfactory results of endoscopic metroplasty lead us to believe that minimally invasive approaches are more effective than conventional laparotomy techniques.

### **CLASS V: INTRAUTERINE SEPTUM**

Intrauterine septum is a symmetric malformation in which the uterine cavity is divided into two hemicavities by a longitudinal septum of varying length. The patients with intrauterine septum often suffer from reproductive failures (miscarriages or infertility). Final diagnosis is possible only under simultaneous hysteroscopy and laparoscopy. Laparoscopy shows united corpus uteri. Hysteroscopy is necessary to evaluate the volume of the uterine cavity, and the length and thickness of the septum (Figure 27). Two variants of malformation exist:

1. Complete septum;



## 2. Partial septum

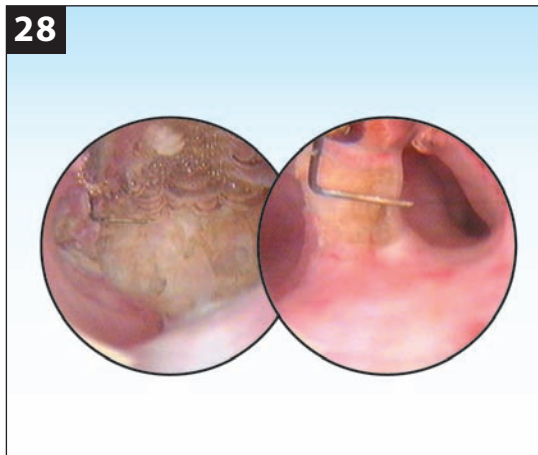
(not reaching internal ostium).

This intervention is incomparably less invasive than laparotomic metroplasty using the Jones or Tompkins techniques. Our method provides excellent anatomic effectiveness and is almost free from complications and disadvantages such as formation of pelvic adhesions and the necessity of subsequent Cesarean section.

Hysteroscopic resection is performed in the early follicular phase of the menstrual cycle (preferably immediately after menstruation) or after medical preparation of the endometrium (for reduction of its thickness, operative blood loss, and for better visualization) with 2 months of GnRH agonists, according to the following technique (Figure 28):

- Cervical canal is dilated up to 10.5–11.5 Hegar;
- Resectoscope is inserted into uterine cavity; intrauterine septum is consecutively transected in its middle part from the summit to the base with the small movements of the hook electrode, and by monopolar pure cutting current of 100–130 W, until the uterine cavity assumes a normal triangular shape;
- Bleeding is controlled by coagulating current of 40–60 W.

For distension, 5% glucose solution or other non-electrolytes are used. The fluid (2–6 L, depending on the septum length and thickness) is delivered at a rate of 150–400 mL/min, average pressure in the cavity is maintained at 60–80 mmHg. If the procedure duration exceeds 20 min, 20 mg of Lasix can be given intravenous-



ly for prevention of complications associated with possible fluid overload. Laparoscopic control after hysteroscopic resection of the intrauterine septum is advisable, considering the risk of perforation of the uterus, and for simultaneous evaluation and correction of associated pelvic disease.

The operation rarely lasts longer than 15 minutes. The patient is allowed to stand up 2 hours after surgery, and to leave the hospital on the same day. Contraception is recommended for 2–3 months. Reproductive function is restored in about 64% of patients who have undergone hysteroscopic resection, and they usually deliver vaginally, provided there are no obstetric indications for operative delivery.

To conclude, laparoscopy and hysteroscopy not only provide the definitive diagnosis of the full spectrum of malformations of the genitalia, but are the most rational and minimally invasive operative approaches to the majority of surgically correctable anomalies.

## SUGGESTED READING:

Buttram VC, Jr. Mullerian anomalies and their management.  
*Fertil Steril* 1983;40:159

Adamyán LV. Additional international perspectives: colpoptosis in vaginal and uterine aplasias In: *Gynecologic and Obstetric Surgery* (ed) David Nichols, Mosby, 1993:1167-1182

Adamyán LV. Laparoscopic management of vaginal aplasia with or without functional noncommunicating uterus. In: *Principles of Laparoscopic Surgery: Basic and Advanced Techniques*. (ed) Maurice E. Arregui, et al., Springer-Verlag, New York 1995:652-671

Adamyán LV. Laparoscopy in surgical treatment of vaginal aplasia: laparoscopy assisted colpoptosis and perineal hysterectomy with colpoptosis. *Int J Fertil* 41(1);1996:40-45

Adamyán LV. Therapeutic and endoscopic perspectives: colpoptosis in vaginal and uterine aplasias. In: *Gynecologic and obstetric surgery* (ed) David Nichols, Mosby. St. Louis 1999:187-195

Monks P. Uterus didelphys associated with unilateral cervical atresia and renal agenesis. *Aust NZJ Obstet Gynaecol* 1979;19:245-6

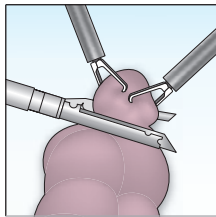
Jones HJ, Wheelless C. Salvage of the reproductive potential of women with anomalous development of the Mullerian ducts: 1868-1968-2068.  
*A J Obstet Gynecol* 1969; 104:348-64

Frank RT. The formation of artificial vagina without operation.  
*Am J Obstet Gynecol* 1938;35:1053-5





# LAPAROSCOPIC BOWEL SURGERY



*Jeff W. Allen, M.D.*

*Benjamin D. Tanner, M.D.*

**A**fter mastering basic laparoscopic techniques such as tissue handling, intracorporeal suturing, and optical facility with 0° and 30° telescopes, operations that are more difficult can be performed using a minimal access approach. This includes many operations on the small and large bowel. This chapter will review some advanced laparoscopic procedures such as colon resection and also some of the problems encountered during operations such as closure of iatrogenic enterotomy.

## COLON RESECTION

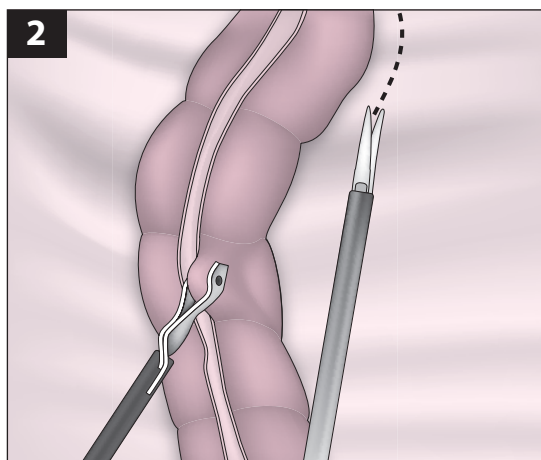
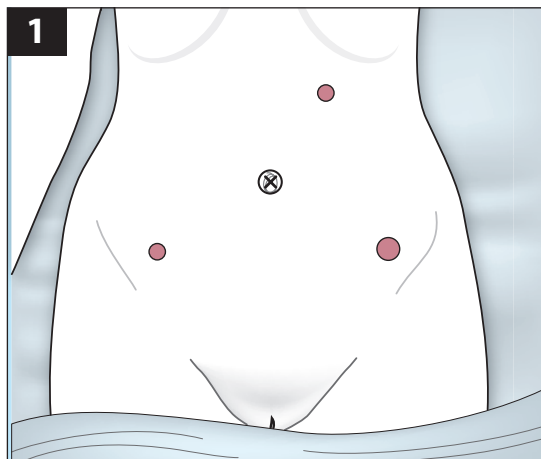
The laparoscopic approach to colon resection for benign disease is now preferred over the open operation in many circumstances. With malignant disease, concerns over issues of port site recurrences, inadequate oncologic resections, and intraperitoneal tumor spread with pneumoperitoneum have made laparoscopic colectomy controversial. A 2004 prospective, randomized study by Nelson, et al. showed no differences in the overall or surgical wound rates of recurrence between laparoscopic and open colectomy for malignancy. The caveat in this study was

that all surgeons who participated had performed at least 20 laparoscopic colon resections for benign disease prior to enrolling in the study and the results were for only 3 years of follow-up. Benign diseases treated by laparoscopic partial colectomy include diverticular disease, some polyps, arterial venous malformations, endometriosis, benign strictures, and certain cases of colitis. Patients benefit from the laparoscopic approach to colon resection because there is a decrease in postoperative pain and wound infections. Most studies show earlier return of bowel function, decreased hospital stay, along with improvements in pulmonary function and cosmesis.

## SIGMOID COLECTOMY

With sigmoid colon resections, the patient is positioned in stirrups. Care is taken to adequately pad the legs in the stirrups to prevent neuropraxia. The patient is placed in the Trendelenburg position, and the operating table is rolled so that the patient's left side is elevated. Some surgeons advocate a full lateral position with the use of beanbag support. Pneumoperitoneum is obtained with 5 mm working trocars placed in the left upper quadrant, left lower quadrant, and right lower quadrant (Figure 1). Since the extended incision of the left lower quadrant port is often the site for specimen extraction, this port can be 10 mm in size. A 10 mm camera port is placed below the umbilicus. A 30° laparoscope enables maximum viewing.

After port placement, the sigmoid colon is grasped using atraumatic bowel

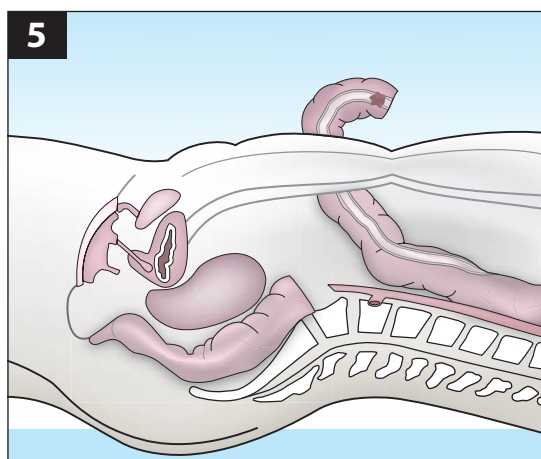
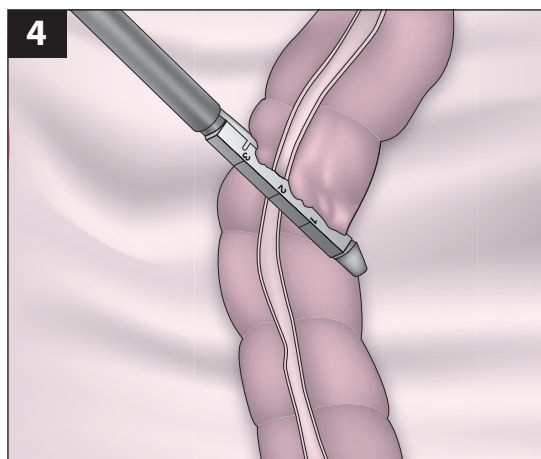
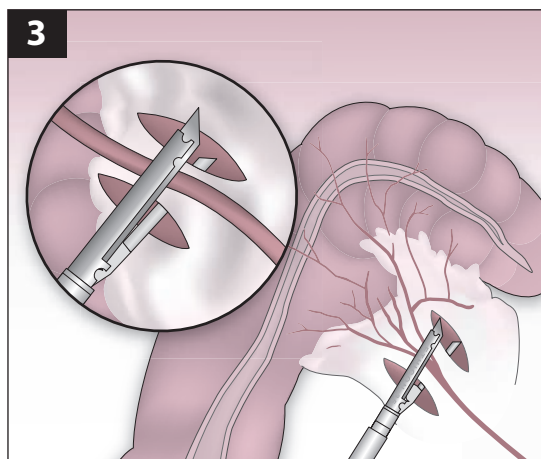


graspers or a Babcock and retracted medially. The white line of Toldt is incised using scissors equipped with electrocautery through the port in the left lower quadrant (Figure 2). Retroperitoneal structures including the ureter and left common iliac artery are identified. This dissection is continued cephalad to the splenic flexure. In some instances, the splenic flexure must be fully mobilized to ensure an adequate length of colon for a tension-free anastomosis.

After the colon is completely mobilized and the ureter identified, the major terminal portion of the inferior mesenteric artery is identified and ligated close to its origin. The vessel is most easily located by visualizing the arterial pulsations in the mesentery while the colon is retracted toward the anterior abdominal wall. Ligation of this vessel includes creating a mesenteric window on either side of the artery and transecting it either with a linear laparoscopic stapler or large clips (Figure 3). In most patients, this vessel is too large for safe division with the harmonic scalpel.

Next, the remainder of the sigmoid colon mesentery is divided using the harmonic scalpel. It is important not to divide too far into the mesentery of the descending colon because this can decrease the length of viable bowel available for anastomosis. After the mesentery has been divided, a linear laparoscopic stapler is fired across the distal sigmoid colon at the rectosigmoid junction below the area of pathology (Figure 4). It is important to identify the ureter prior to transecting the bowel.

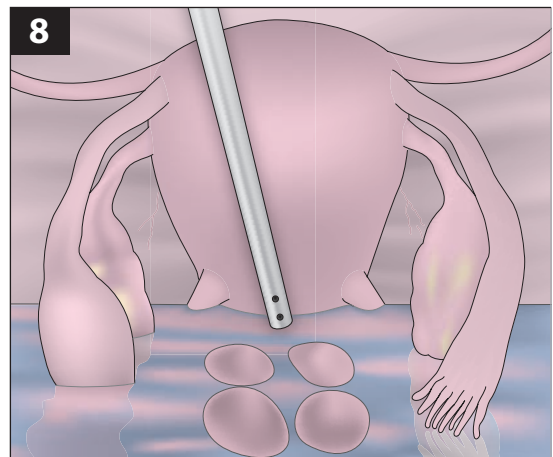
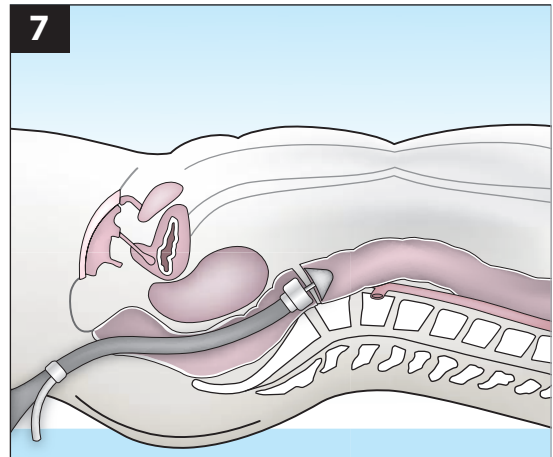
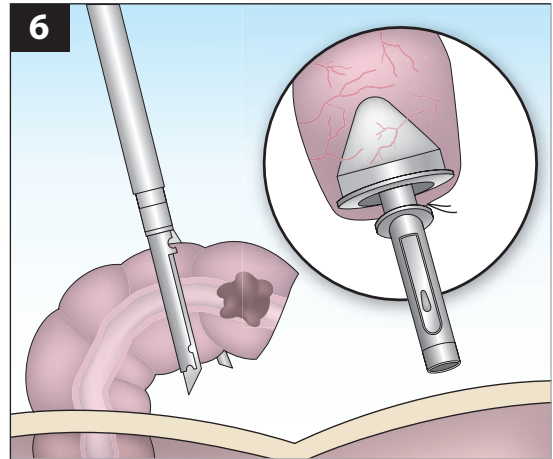
The incision of either the left lower quadrant or the infraumbilical port site is extended, and the specimen with attached proximal colon is delivered (Figure 5). The proximal end is transected with a firing of the laparoscopic stapler and opened. The anvil of an end-to-end (EEA) 25 mm stapler is placed in this colotomy and secured with a purse-string suture of 2-0 polypropylene (Figure 6). The 25 mm EEA is the size most suitable for this anastomosis, but other sizes can



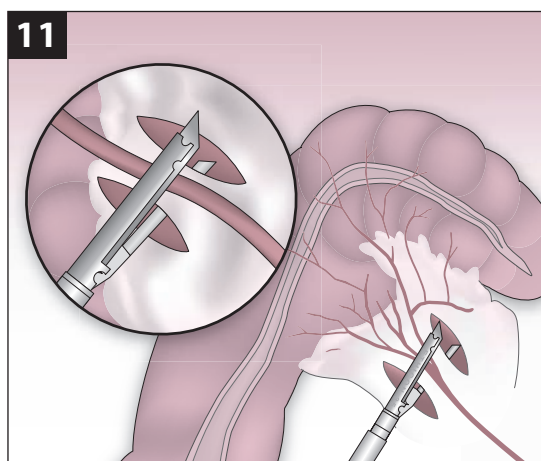
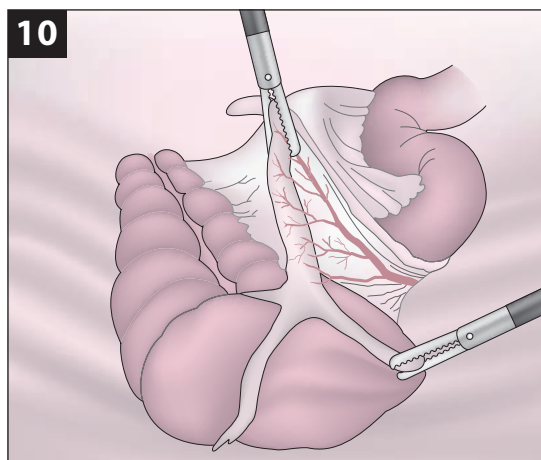
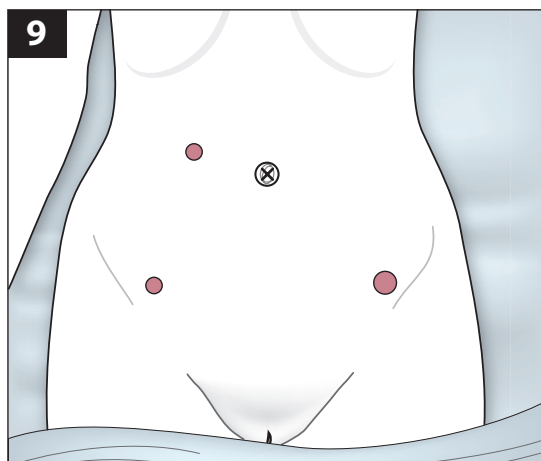
be used depending on the circumference of the descending colon. The descending colon with anvil in place is then returned to the abdomen and the incision closed. It is important to make this closure airtight to re-establish a pneumoperitoneum. The EEA stapler is introduced per rectum, and the spike deployed through the rectal stump. The proximal colon with anvil in place is stretched into the pelvis to the spike (Figure 7). If the anastomosis appears to be under tension, it is best to further mobilize the splenic flexure before performing the intracorporeal anastomosis to prevent a leak. The EEA stapler spike is then interfaced with its anvil, closed, and fired. The entire stapling apparatus is removed. It is important to test this anastomosis by clamping the colon proximal to the staple line with a non-crushing grasper, filling the pelvis with sterile saline or water, and insufflating with air (Figure 8). A rigid sigmoidoscope can also be used to visualize the staple line and check for leakage. If a leak is noted, 2-0 silk sutures should be used to close the area by taking full thickness bites using an intracorporeal suturing technique. The pneumoperitoneum is decompressed and the skin incisions are closed. We routinely close the fascia on all port sites larger than 5 mm to prevent herniation.

## RIGHT HEMICOLECTOMY

The patient is placed supine on the operating room table. No stirrups are used and the arms are tucked at the patient's side. Rotating into the left later-



al position provides maximal exposure. Open pneumoperitoneum is obtained via a 10 mm infraumbilical trocar. Working ports of 5 mm are placed in the right lower, the right upper, and left lower quadrants (Figure 9). The table is rolled toward the patient's left side to increase visualization by allowing the small intestine to fall away from the right colon. The terminal ileum, appendix, and cecum are located, and the white line of Toldt is identified and incised as previously described. This mobilization continues so that the cecum is free from its retroperitoneal attachments (Figure 10). Often, the dissection is continued around the hepatic flexure, and the harmonic scalpel is used to prevent bleeding. At this point, the ureter must be identified and protected along its entire path. Medial and inferior traction on the right and transverse colon is applied and the duodenum is visualized and bluntly dissected away from the transverse mesocolon. Once the duodenum is completely freed, the pathologic process is identified and a 5 cm distal margin obtained. The transverse colon is transected using a linear 45 mm laparoscopic stapler. The mesentery is divided using the harmonic scalpel and the laparoscopic stapler is used to divide the right colic artery (Figure 11). Alternatively, large clips may be used and the vessel divided with endoscopic shears. The specimen is delivered through a port site that has been extended. In our experience, either the infraumbilical or right lower quadrant incision may be used for this purpose. Note, the ileum is still attached to the right colon

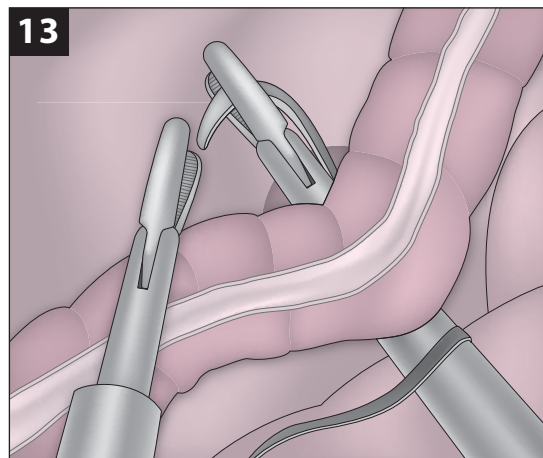
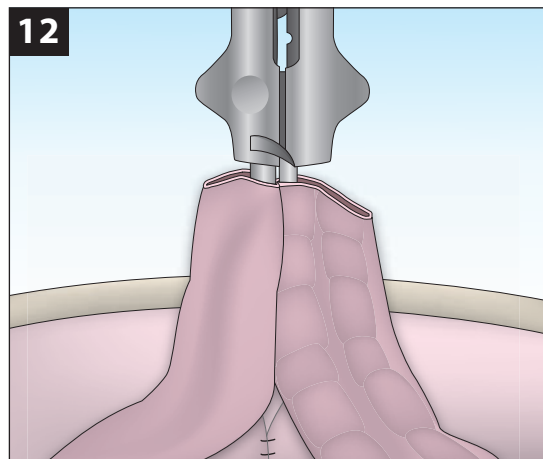


and delivered out of the abdomen due to its lack of attachments. The ileum is transected with a 45 mm linear stapler 5-10 cm proximal to the ileocecal valve. A hand-sewn end-to-end or side-to-side stapled anastomosis is performed extracorporeally (Figure 12). The mesenteric defect is closed with silk sutures and the ileocolic segment is returned to the abdomen and the incisions closed.

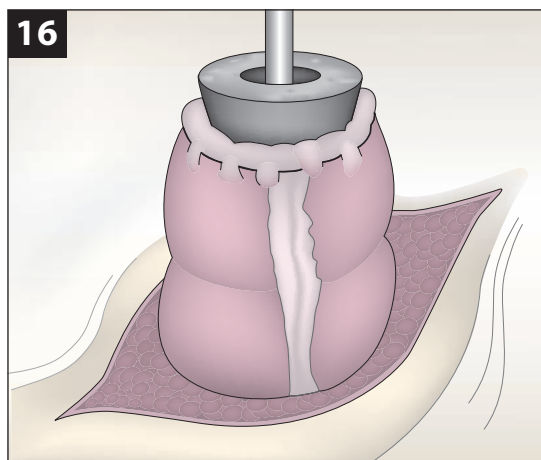
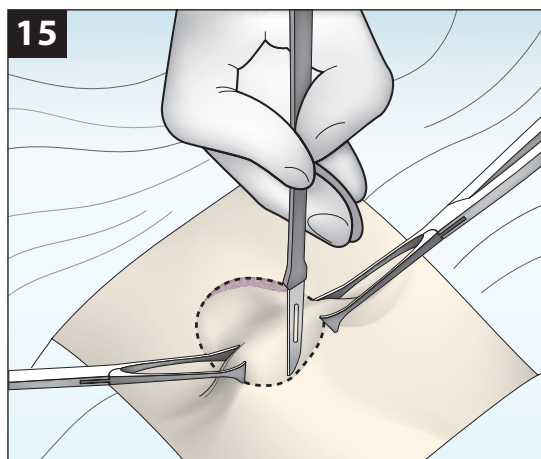
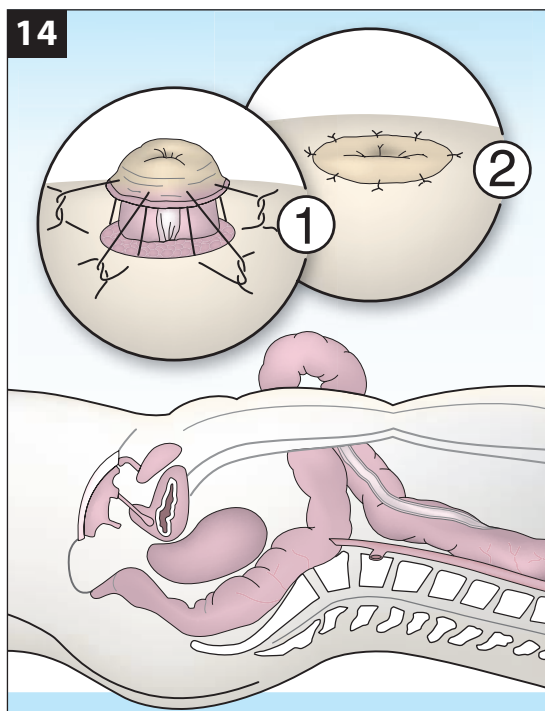
Alternatively, this may be performed entirely intracorporeally with a side-to-side stapled anastomosis and closure of the common stoma with running 2-0 silk sutures tied intracorporeally. The specimen may then be delivered through an extended incision.

## COLOSTOMY CREATION

Sigmoid or transverse colostomy is easily created using the minimally invasive technique. First, obtain pneumoperitoneum via an infraumbilical skin incision and place working ports in the right upper and left lower quadrant. The large bowel is identified and a sling is placed around it for easy manipulation (Figure 13). This is helpful because the colostomy site can be located based on how easily the colon reaches to the skin site, as opposed to vice versa. After the colostomy site is identified, any needed mobilization along the line of Toldt is undertaken as previously described. Once the loop will reach freely, an incision is made, and the colon is pulled through and matured in the usual fashion. A colostomy bar may replace the sling through the same aperture.



An end colostomy, with or without colon resection, entails identifying the site for the colostomy and dividing the colon and mesentery for proper length. The colon proximal to the colostomy is stretched to the site for the colostomy, a skin incision made, and the colon delivered. The colostomy is matured in a standard fashion (Figure 14).



## COLOSTOMY CLOSURE

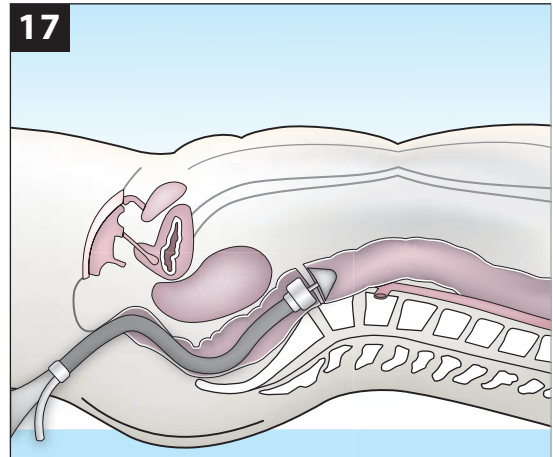
The takedown of a colostomy is often a more morbid procedure than colostomy creation because of the large adhesiolysis that often is necessary and the occasional difficulty in identifying the distal colon for anastomosis.

With the laparoscopic approach, the patient is placed in the supine position in stirrups. Care is taken to pad the legs to prevent neuropraxia. Port placement is based on previous incisions and the assumption that generally there will be fewer adhesions under unscarred skin. During the dissection, the peristomal area is cleared, and the colon that is proximal to the colostomy is mobilized. This often involves mobilizing the splenic flexure in the case of a descending colostomy.

Next, the colonic stump is identified. At this point, the pneumoperitoneum is decompressed and a peristomal incision is made with dissection of the colon off the fat and skin (Figure 15). The colostomy is then equipped with the anvil of a 25 mm EEA stapler secured with a purse-string suture of 2-0 polypropylene and replaced into the abdomen (Figure 16). The colostomy incision is closed in an airtight fashion. The skin may be closed over drains or left open based on the preference of the surgeon. Next, the



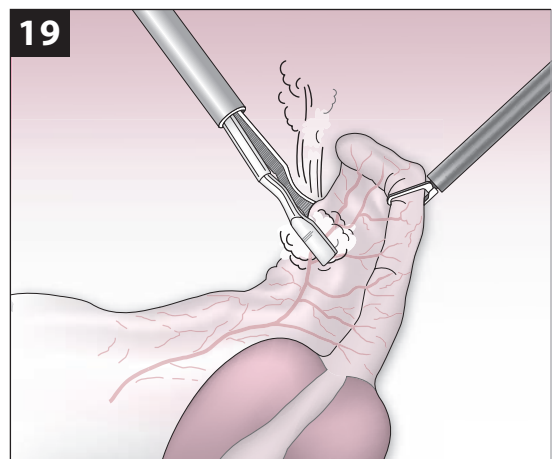
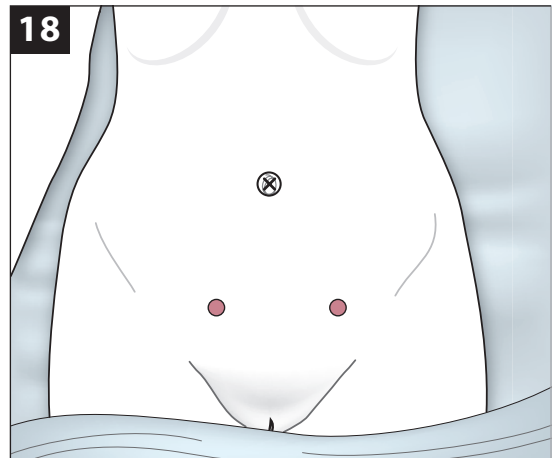
pneumoperitoneum is re-established and the colon with anvil is directed into the pelvis. The EEA stapler is passed per rectum following the curve of the sacrum. Once the EEA stapler is observed in the rectal stump, the sharp spike is deployed and the anvil and spike are interfaced. The stapler is fired after the appropriate pressure is obtained by closing the stapler (Figure 17). The anastomosis is checked as previously described.



## APPENDECTOMY

The laparoscopic approach to appendectomy remains a controversial subject with regard to indications and cost. We believe it is most beneficial for patients when the diagnosis is uncertain. This is often the case in obese patients, those with history of inflammatory bowel disease, and especially in pre-menopausal women when the possibility of adnexal pathology mimicking appendicitis is present. A 1997 prospective study by Laine et al evaluated 161 pre-menopausal women with a diagnosis of acute appendicitis who underwent diagnostic laparoscopy. An appendectomy was performed in 55% and 23% thought to have appendicitis actually had a gynecologic diagnosis. The authors showed that the negative appendectomy rate could be lowered with diagnostic laparoscopy in this population.

For maximum cosmesis, an infraumbilical incision is made for the camera port and two lower 5 mm incisions in the hair-line are placed (Figure 18). The technique involves creation of a pneumoperitoneum,



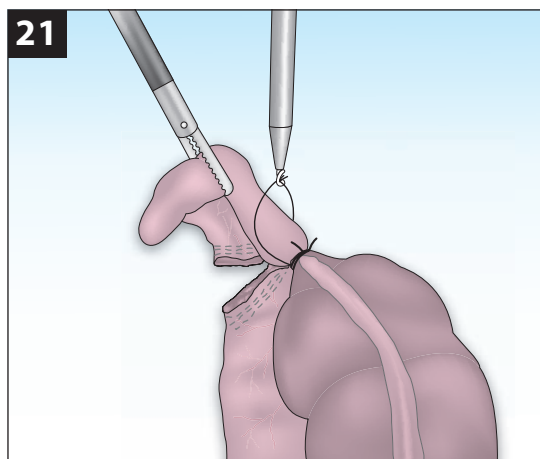
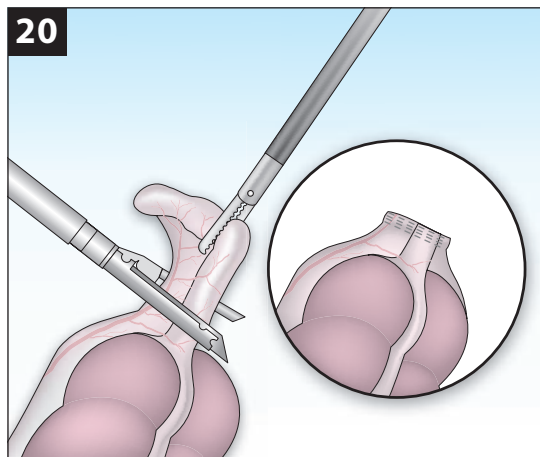
establishing a diagnosis requiring appendectomy, and isolating the appendix from its surrounding structures. Occasionally, the appendix is adherent to the retroperitoneal structures through filmy adhesions, and these must be incised.

After freeing the appendix, the mesoappendix is divided with clips and scissors, or alternatively bipolar electrocautery (Figure 19), the harmonic scalpel, or a linear stapler (Figure 20). Once the appendix is free from its mesoappendix, it is divided with the linear stapler. This step may also be safely and cost-efficiently performed using a series of looped ligatures (Figure 21). The appendix is delivered through the largest port. To minimize contamination, a specimen retrieval bag is used. Alternatively, the thumb of a large powderless glove may be used. The operative field is inspected for bleeding and the appendiceal stump is checked for security. The entire abdomen should undergo peritoneal lavage and aspiration to decrease the chance for abscess formation.

## MECKEL'S RESECTION

An asymptomatic Meckel's diverticulum is best treated without an operation. However, in cases when a symptomatic Meckel's is discovered or when an operation is performed for abdominal pain with no clear cause, a resection is indicated. The surgery for Meckel's diverticulum is either a simple diverticulectomy or a small bowel resection with enteroenterostomy.

A diverticulectomy is performed most commonly in the laparoscopic realm with



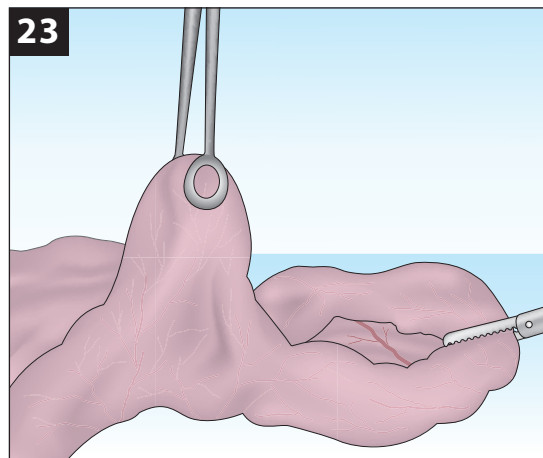
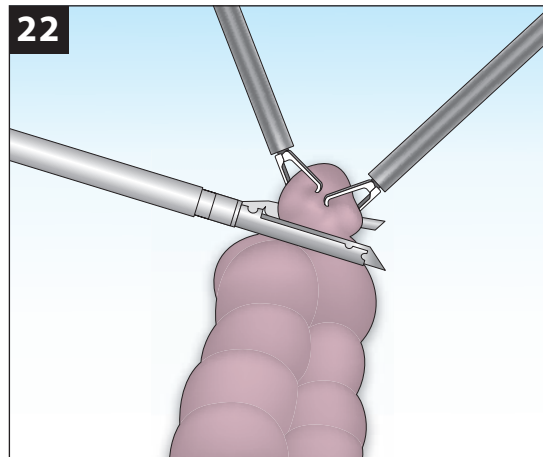
a laparoscopic linear stapler fired at the base of the diverticulum (Figure 22). This is performed after proper alignment and identification of the Meckel's. It is important not to excessively impinge on the lumen of the small bowel and equally important not to leave heterotopic mucosa behind.

In cases when the Meckel's is causing gastrointestinal hemorrhage, the diverticulum is large (>5 cm), or when an associated omphalomesenteric band is pres-

ent, a small bowel resection is indicated. This can be accomplished with the use of just two ports, a 10 mm infraumbilical port for the camera and a 5 mm port to grasp and elevate the small bowel. The diverticulum is grasped and removed from the abdomen through an extension of the 10 mm site. The resection and subsequent anastomosis are performed and then returned intraabdominally (Figure 23). This may also be performed intracorporeally, by firing a linear stapler across the bowel proximal and distal to the Meckel's and then fashioning a side-to-side stapled anastomosis. It is imperative to have generous margins, because in a case of hemorrhage, the small bowel mucosa is likely to be the source of the bleeding due to the proximal heterotrophic gastric acid-producing diverticulum. After firing a stapler proximal and distal to the Meckel's, the mesentery is transected either with an ultrasonic sheer or with an additional load of the linear stapler. A side-to-side anastomosis is then fashioned using the stapler. The common stoma is closed with a running intracorporeally tied suture as previously described. The specimen is then delivered through the largest port in a protective bag.

## INCIDENTAL ENTEROTOMY

In the past, the expected management of a recognized enterotomy at the time of laparoscopy was unquestionable. This would include conversion to a laparotomy, consultation with a general surgeon, and repair of the enterotomy. When the enterotomy involves heavily contaminat-



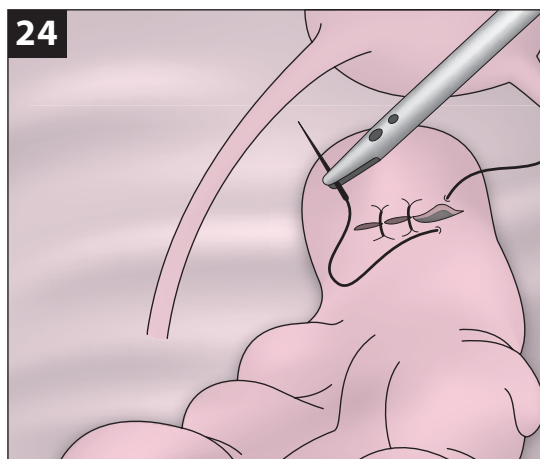
ed fecal material, the possibility of a diverting colostomy is entertained. Just as less conservative approaches to the management of penetrating colon injuries are becoming more readily accepted, so too are the approaches to management of laparoscopic enterotomies.

As the skills of laparoscopic surgeons increase, the ability to manage a complication such as an enterotomy has improved. A surgeon with intracorporeal suturing skills may safely repair iatrogenic enterotomies in prepped bowel.

Contraindications to this management would include: heavy spillage, hypotension, inadequate exposure, or the belief that additional unrecognized enterotomies exist. Nezhat et al. performed a review of 26 laparoscopic closures of enterotomies, with no appreciable morbidity or mortality associated with the technique.

In cases of left colon injuries, the management is even more controversial because high luminal levels of bacteria portend a high rate of wound infection, sepsis, and possible leakage. A review of the recommendations for colon injuries caused by penetrating trauma may be insightful. There is sufficient evidence in the trauma literature to support primary repair for non-destructive colon wounds when the patient has no peritonitis, significant underlying disease, or evidence of shock. These same basic recommendations can be applied to laparoscopic surgery.

A colotomy may be oversewn; we recommend that this be done in two layers



of nonabsorbable suture (Figure 24). It is helpful to check the colotomy for leakage in left colon injuries by insufflating air and methylene blue or povidone-iodine (Betadine) transrectally. It is probably best to leave a drain in as well. Whenever there is a question about the appropriate management, the exposure, or the ability of the surgeon to repair the injury, consultation with a general surgeon and/or conversion to an open procedure are indicated.

## SUGGESTED READING:

Muckleroy SK, Ratzler ER, Fenoglio ME. Laparoscopic colon surgery for benign disease: A comparison to open surgery. *JLS* 1999;3:33-37

Jager RM. Laparoscopic right hemicolectomy in left lateral decubitus position. *Surg Laparosc Endosc* 1994;4:348-352

Berne JD, Velmahos BG, Chan LS, Asensio JA, Demetriades D. The high morbidity of colostomy closure after trauma: further support for the primary repair of colon injuries. *Surgery* 1998;123:157-164

George SM, Fabian TC, Voeller GR, Kudsk KA, Mangiante EC, Britt LG. Primary repair of colon wounds: A prospective trial in nonselected patients. *Ann Surg* 1989;209:728-734

Sasaki LS, Allaben RD, Golwala R, Mittal VK. Primary repair of colon injuries: A prospective randomized study. *J Trauma* 1995;39:895-901

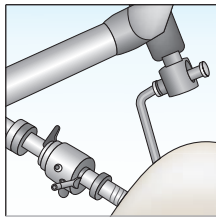
Gonzalez RP, Merlotti GJ, Holevar MR. Colostomy in penetrating colon injury. Is it necessary? *J Trauma* 1996;41:271-275

Nezhat C, Nezhat F, Ambroze W, Pennington E. Laparoscopic repair of small bowel and colon. *Surg Endosc* 1993;7:88-89

Laine S, Rantala A, Gullichsen R, et al. Laparoscopic appendectomy. Is it worthwhile? A prospective, randomized study in young women. *Surg Endosc* 1997;11:95-97

The Clinical Outcomes of Surgical Therapy (COST) Study Group. A comparison of laparoscopically assisted and open colectomy for colon cancer. *N Engl J Med* 2004; 350: 2050-9

# GASLESS LAPAROSCOPY



***Daniel Kruschinski, M.D.***

***Bernd Bojahr, M.D.***

***Miroslav Kopjar, M.D.***

## INTRODUCTION

**G**asless laparoscopy is a system that does not require a pneumoperitoneum. Instead, it uses an abdominal wall lifting system. One such system is the AbdoLift® (Karl Storz Endoscopy, Tuttlingen, Germany). With a special design of the retractors, the AbdoLift® mechanical elevation of the abdominal wall provides the surgeon with the necessary space comparable with that of pneumoperitoneum laparoscopy. As no gas is needed, flexible and valveless trocars can be used. This technique avoids several typical intraoperative problems of pneumoperitoneum laparoscopy such as gas leakage, rinsing and suction as well as removal of tumors and organs out of the abdominal cavity.

By utilizing conventional instruments and standard surgical techniques and avoiding disposables, gasless laparoscopy is a cost-effective procedure with benefits for the patients, surgeons, hospitals, and the health system. Gasless laparoscopy is a simple, effective, and economical introduction to operative laparoscopy and extends the indications of minimally invasive surgery. It combines minimally invasive surgery and

modern magnification with endoscopic imaging systems, opening the possibility of using standard techniques and conventional instruments, which have been developed and modified for a very long time. They allow the surgeon, in contrast to laparoscopic instruments, to use tactile sense and palpation, as they are very short and have only one link. Performing surgery with short instruments means that the hand is close to the area of operation and the fulcrum is short so that accuracy is relatively higher than that of laparoscopic instruments where the surgeon's hand is very far from the area of the operation.

Via flexible trocars, conventional and/or laparoscopic instruments can be used. It is also possible to introduce several instruments simultaneously through the same trocar. The insertion and the change of instruments, as well as suturing and tying, can be performed easier through the flexible valveless trocars. Gasless laparoscopy has the advantage of performing laparo-vaginal procedures more extensively than with gas laparoscopy.

Complications during the blind Veress needle or trocar insertion such as vascular lesions or intestinal injury are virtually excluded by this technique. Problems and complications of the iatrogenic insufflation of CO<sub>2</sub> (pneumothorax, pneumomediastinum, pneumopericardium, air embolism, massive subcutaneous emphysema) are completely excluded. Physiologically, gasless laparoscopy is less invasive than pneumoperitoneum insufflation and allows the use of laparoscopic surgery in high-risk patients, e.g.

MAIN INDICATIONS FOR  
GASLESS LAPAROSCOPY ACCORDING  
TO TECHNICAL OPERATIVE ABILITIES  
AND ADVANTAGES:

- ENUCLEATION OF MYOMAS (SUFFICIENT CONVENTIONAL SUTURING OF THE MYOMETRIUM)
- OTHER ORGAN PRESERVING SURGERY AS ENUCLEATION OF OVARIAN TUMORS (AVOIDANCE OF RUPTURE AND CELL SPILLAGE)
- ORGAN RECONSTRUCTIVE SURGERY SUCH AS TUBAL SURGERY
- TOTAL LAPAROSCOPIC HYSTERECTOMY
- SUPRACERVICAL HYSTERECTOMY
- LAPAROSCOPIC ASSISTED VAGINAL HYSTERECTOMY
- COMBINED LAPARO-VAGINAL SURGERY AS THE EXCISION OF RECTOVAGINAL ENDOMETRIOSIS
- OPERATIVE AND DIAGNOSTIC PROCEDURES IN RISK PATIENTS AND IN PREGNANT WOMEN UNDER GENERAL, REGIONAL, OR LOCAL ANESTHESIA
- OPERATIVE AND DIAGNOSTIC PROCEDURES FOR CANCERS OR SUSPICIOUS TUMORS (OVARIAN TUMORS, PELVIC/PARAAORTIC LYMPHADENECTOMY)

those with heart insufficiency or lung obstruction as well as in pregnancy. The ability to utilize operative laparoscopy under regional anesthesia as the combination of minimally invasive surgery and minimally invasive anesthesia (MIS MIA) will become a new challenge.

In case of oncologic surgery gasless laparoscopy might have some advantages over pneumoperitoneum laparoscopy as experimental studies indicate that utilizing CO<sub>2</sub> could possibly lead to a more aggressive spreading of tumor cells and progressive tumor cell implantation in the abdominal cavity.

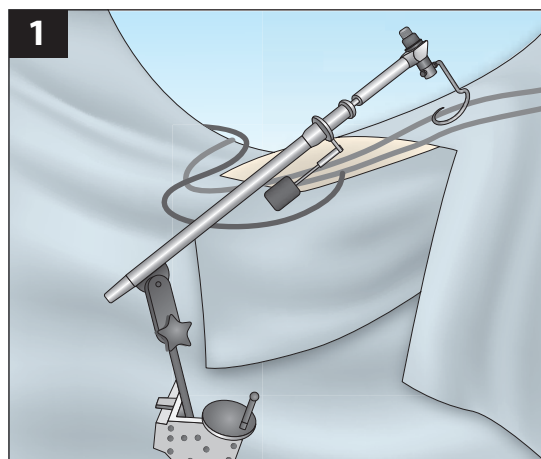
Lift-laparoscopy offers the concept of laparoscopy as a minimally invasive surgery, and is simpler, cost-effective, and extends the range of application.

## **PATIENT POSITIONING, PREPARATION AND ANESTHESIA**

It is advisable and also mandatory that both arms should be tucked along the body and shoulder braces must be used to allow a steep Trendelenburg position (up to 30°). If a diagnostic procedure along with an operative surgery is going to be performed, it is recommended that the bowel should be prepared as for laparotomy.

### **ANESTHESIA**

If general anesthesia is chosen, it should be performed without the use of N<sub>2</sub>O, as nitrogen oxide distends into the bowel after 90-120 minutes with the consequence that the distended bowel is placed in the pouch of Douglas and might disturb parts of the operation. A bladder catheter can be inserted into the rectum during the procedure to evacuate air from the bowel if necessary. In cases of spinal, epidural, or combined



spinal/epidural anesthesia the patient should have both hands free due to the psychological stress of being unable to move any part of the body. For the patient's convenience, a CD-player or a DVD-player is very helpful. To prevent intraoperative pain or nausea, especially in anxious patients, sedative drugs can be administered.

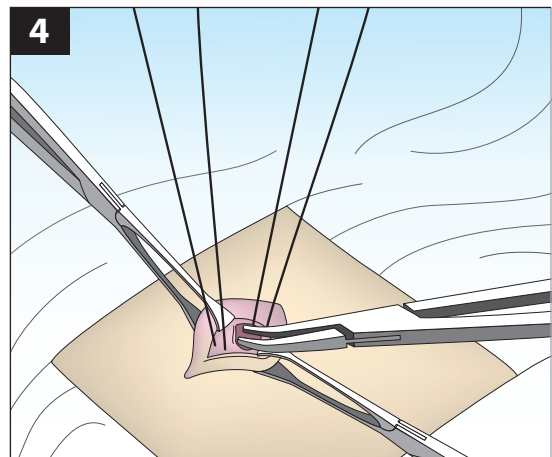
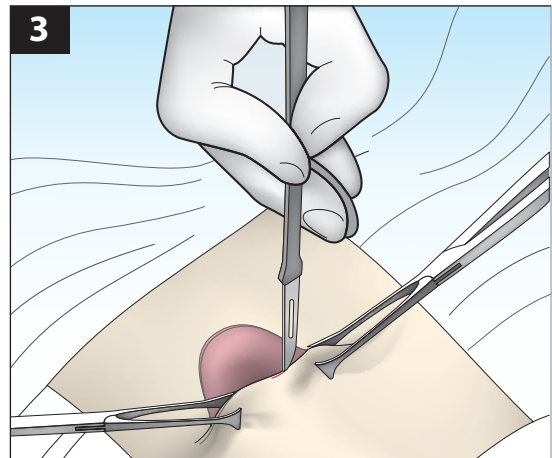
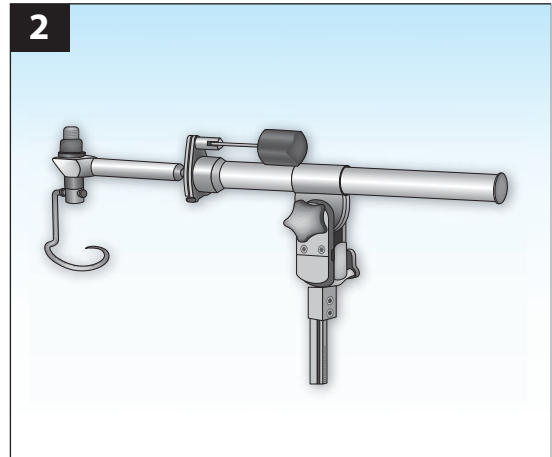
## **CREATION OF THE ABDOMINAL WALL ELEVATION**

The patient is placed in the lithotomy position and covered with a sterile drape. The fixing stand has to be attached to the right rail of the operating table by the fixation device, usually at the height of the patient's shoulder (Figure 1). The vertical arm of the AbdoLift® is attached on top of the fixing stand, the spring balance and the retractor can be inserted and the system can be adjusted to the anatomical position of the patient by using all joints to correct the position of the components (Figure 2).



## APPROACHING THE ABDOMINAL CAVITY

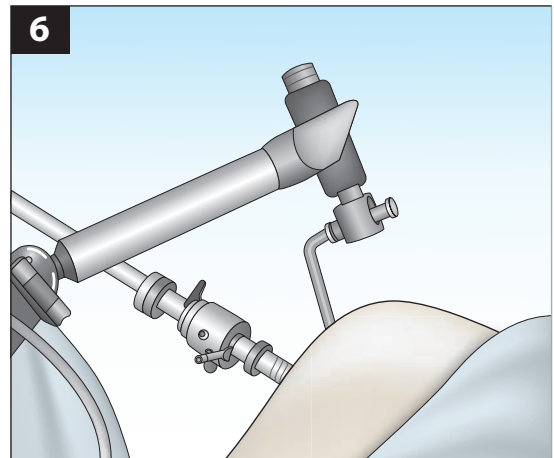
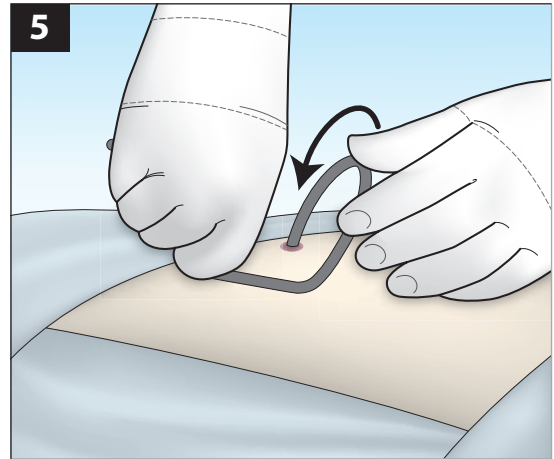
The technique is similar to the Hasson open procedure, however, the skin incision in the lower umbilical fold is only 12-15 mm (Figure 3). With the help of special S-shaped hooks one can reach the fascia layer by layer, displacing the subcutaneous and fatty tissue by blunt dissection (Figure 4). After reaching the fascia, a small incision (2-3 mm) is made with a number 11 scalpel followed by insertion of blunt scissors and opening of the fascia up to 15 mm. By using the S-hooks, the rectus muscle is pushed aside and the peritoneum can be visualized. The light of the endoscope is used for transillumination of the abdominal cavity to visualize adhesions if present. At an adhesion-free area, the incision of the superficial layer of the peritoneum can be performed either by a number 11 scalpel or scissors and then widened by spreading the scissor arms. After reaching the abdominal cavity, the left and the right S-hook are inserted into the abdomen under vision and the abdominal wall is elevated. Introducing the endoscope, the entire periumbilical area can be visualized to detect adhesions that would prevent insertion of the retractor. Sometimes, a digital palpation of the anterior abdominal wall is useful in detecting any adhesions. Under elevation of the abdominal wall with the S-hooks by the assistant, the retractor is then inserted under vision rotating into the abdominal cavity (Figure 5). Behind the retractor, a trocar for the endoscope is



introduced. Following this step, the endoscope is inserted for inspection. The purpose of this inspection is mainly to examine whether the omentum or the bowel have become pinched between the retractor and the abdominal wall. If so, it is necessary to remove the retractor and to start the procedure for reposition of the retractor.

Gasless laparoscopy is more difficult than pneumoperitoneum laparoscopy when severe adhesions are present around the periumbilical area. If adhesions in the lower abdominal quadrant are found, the retractor can be inserted first in the direction of the upper abdominal cavity or in a direction where no adhesions are present. After inspecting the abdominal cavity with the endoscope, an area free of adhesions must be found to introduce a trocar and perform an adhesiolysis. Sometimes a low-pressure (8–10 mmHg) pneumoperitoneum is necessary to perform adhesiolysis, prior to insertion of the abdominal wall retractor.

Checking the appropriate position of the retractor, the abdominal wall can be elevated by the height adjusting wheel (Figure 6) to the level of the mark 'Max' on the spring balance, which gives the level of approximately 1.5 kg. This mark can be higher or lower according to the weight of the abdominal wall and the size of the patient. After the abdominal wall is elevated, the upper abdominal quadrant can be visualized with the endoscope in the same manner as in pneumoperitoneum laparoscopy. In some corpulent patients, it might be necessary to change the position of the



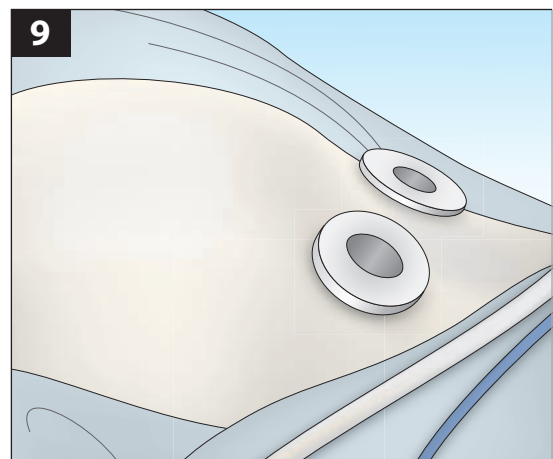
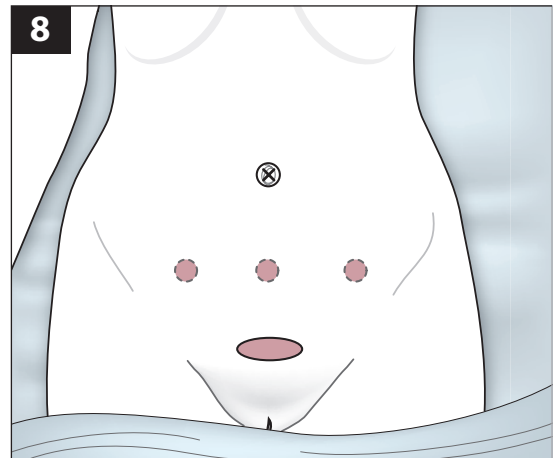
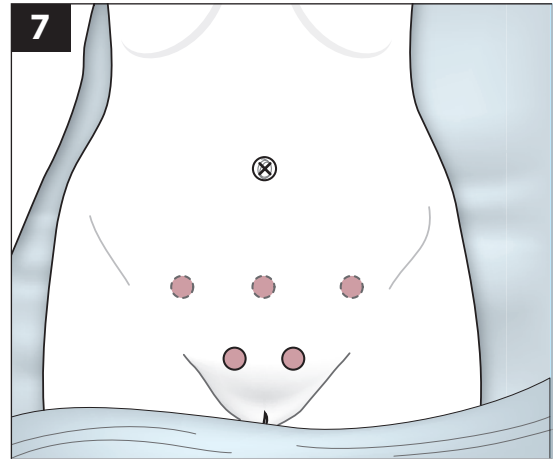
retractor to the upper abdomen for visualization of the organs from the upper abdominal quadrant. When changing the retractor and the optic back to the pelvis the patient has to be placed in steep Trendelenburg position (up to 30°) which allows the bowel to slide to the upper abdominal quadrant that serves as a 'reservoir' for the intestine. Routinely, two ancillary ports can be introduced in the suprapubic region. In contrast to gas laparoscopy, these ports might be placed very close to each other (both trocars are

medial from the epigastric vessels!) and about 1 cm under the pubic hairline, since using conventional instruments that are curved, makes it possible to reach all pelvic organs and structures (Figure 7). After a few weeks the pubic hair covers the incisions and the cosmetic results obtained by this technique are better than in pneumoperitoneum laparoscopy, where the incisions have to be placed above the hairline (as marked in Figures 8 and 9) in order to reach the area behind the uterus with the long and straight laparoscopic instruments.

Recent applications show that it is possible to perform surgery even with one incision where two instruments can be introduced at the same time (Figure 8). This incision can be widened as required and a laparoscopic assisted mini-laparotomy can be performed, allowing extension possibilities and principles from open surgery, like palpation and grasping of tissue or applying a ligature knot with two fingers.

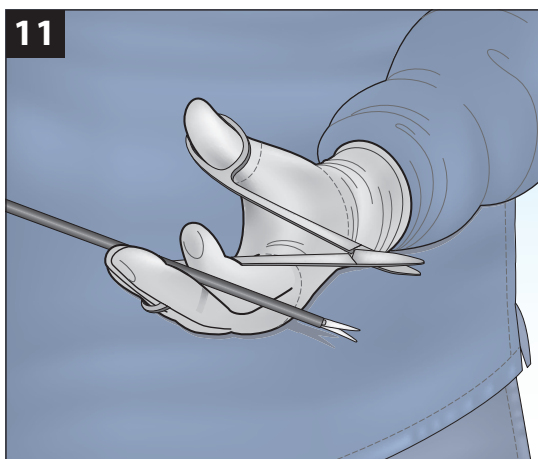
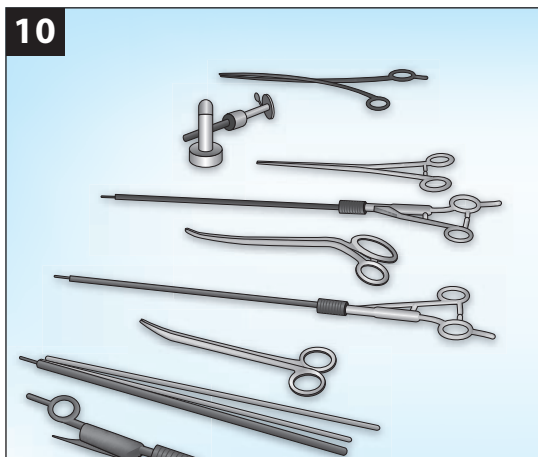
To introduce the ports, one can use the same technique as in gas laparoscopy. Through a skin incision of 10 mm, a round sharp obturator with a rubber sheath that has a thread on the external site, can be introduced with a little force and turned clockwise through the abdominal wall. The abdominal wall may be transilluminated by the endoscope to avoid injury to epigastric vessels. The obturator is removed after insertion, leaving the trocar sheath in place (Figure 9).

If the bowel is still in the posterior cul-de-sac, it can be displaced to the upper abdomen with the help of two sponges.



#### CREATION OF THE ABDOMINAL WALL ELEVATION:

1. MAKE A 12-15 MM SKIN INCISION IN THE LOWER UMBILICAL FOLD
2. ATTACH AND FIX THE ABDOLIFT TO THE OPERATING TABLE
3. DISSECT FAT, SUBCUTANEOUS TISSUE, FASCIA AND MUSCLE UNTIL REACHING THE PERITONEUM
4. DETECT ADHESIONS BY TRANSILLUMINATION
5. MAKE A 2-3 MM INCISION IN THE PERITONEAL LAYER AND SPREAD IT WITH BLUNT SCISSORS
6. INSERT THE RETRACTOR AND THE SCOPE AND CHECK FOR VESSEL OR BOWEL INJURIES
7. PLACE THE PATIENT IN STEEP TRENDLENBURG POSITION AFTER AN OVERVIEW
8. INTRODUCE TWO ANCILLARY PORTS IN THE SUPRAPUBIC REGION
9. BEGIN PROCEDURE



Then examination of the pelvic organs can take place exactly in the same manner as in pneumoperitoneum laparoscopy and the operative procedure can begin.

### TECHNICAL ABILITIES AND ADVANTAGES OF GASLESS LAPAROSCOPY

The new concept of gasless laparoscopy allows identical exposure and vision as in pneumoperitoneum laparoscopy, but the operative procedure is technically less diffi-

cult to perform. By means of Lift-laparoscopy it is not only possible to manage all operative procedures performed under gas laparoscopy, but additionally to extend the range of application to more complex procedures and advanced surgery.


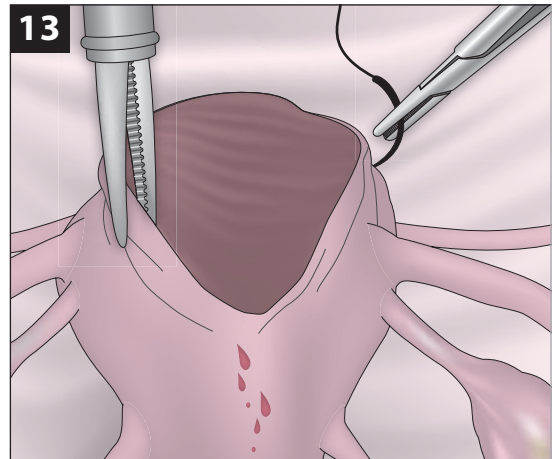
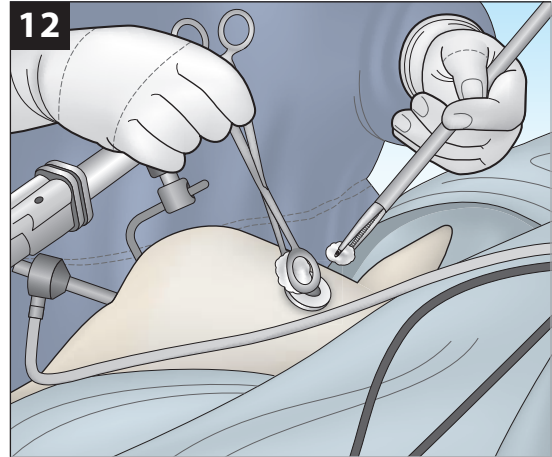
Conventional instruments are used. The grasping parts or the cutting edge of a conventional instrument is ergonomic with the ability to grasp or to cut tissue very precisely (Figures 10 and 11). With

sponges for blunt dissection the procedures become easy and rapid (Figure 12). Where necessary, one can introduce a finger for palpation or dissection. It is also very easy to control bleeding by suction with a conventional plastic tube, irrigation, or sponges and to grasp the vessel with a clamp to apply a ligature or to coagulate it with the bipolar forceps.

Suturing can be performed very easily and fast using conventional suture material with curved needles as in open surgery (Figure 13). Tying the thread extracorporeally and pushing the knot with a knot pusher makes suturing as easy as in open surgery.

As no gas leakage occurs, Lift-laparoscopy allows extraction and removal of tissue from the abdominal cavity in a less problematic manner than in gas laparoscopy. Small myoma or morcellated pieces can be extracted directly through the flexible trocar. Ovarian tumors and other tissue samples should be extracted via an endobag. Conventional instruments allow open endobags for use inside the abdominal cavity and inserting the tissue sample is easy.

Despite all advantages of open surgery, Lift-laparoscopy still remains laparoscopy and it is logical to use special instruments which allow multifunctionality and multimodality. For example, one of these instruments is the bipolar diathermic scissors, PowerStar™, (Ethicon, Cincinnati, OH) (Figure 14). These are like Metzenbaum scissors (originally developed for open surgery) covered with special ceramics so that the energy is applied only on the tip of the scissors and between the scissor blades.

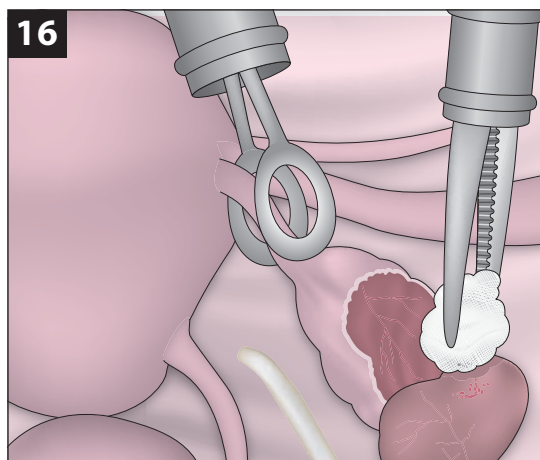
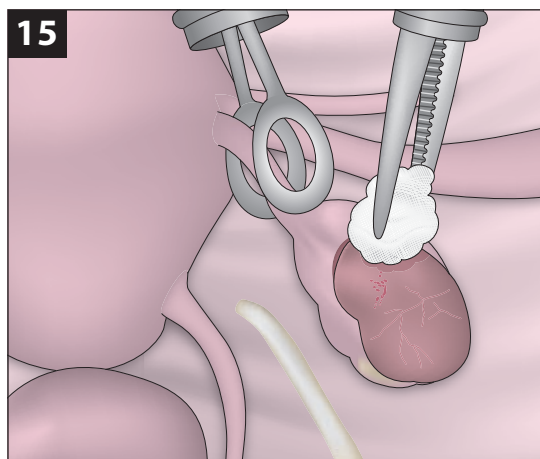


## ADNEXAL TUMORS

In case of enucleation of an ovarian cyst, it should be removed from the ovary without rupture and spillage of the cystic contents, especially in case of suspicious findings. Conventional surgical methods, which are very easy to apply using gasless laparoscopy, avoid spillage. In Figures 15 and 16, the procedure of a blunt dissection of an endometrioma by traction with a sponge and countertraction with a forceps is shown. With the help of conventional instruments and surgical techniques it is possible to avoid spillage in most ovarian tumors. For example, in our series of 102 gasless laparoscopic operated dermoids, we had a microrupture only in two cases (2%). In these cases, it was easy to continue surgery as one was able to grasp the rupture site with a long forceps longitudinally and continue the procedure of enucleation or apply a ligature over the ruptured cyst capsule. Applying the technique of blunt dissection spares as much ovarian tissue as possible. In Lift-laparoscopy the removal of tissue specimens is less problematic as there is no interaction with gas leakage and the endobag can be grasped with conventional curved instruments, allowing the bag to be held open around the instruments. The closure of the ovarian capsule is performed with ordinary suture material and a curved needle as used in laparotomy.

## ENUCLEATION OF FIBROIDS

Fibroids, which are located intramurally are sometimes difficult to enucleate. After an incision is made through the



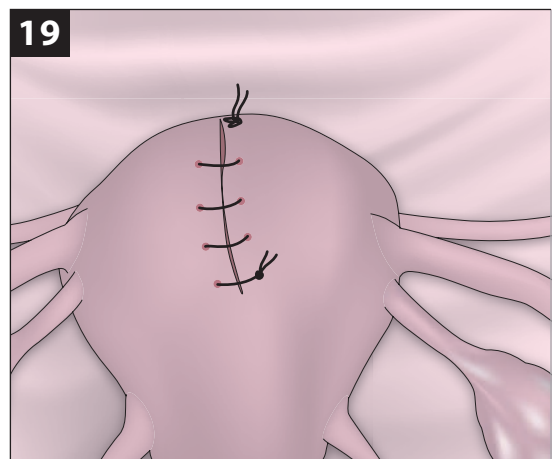
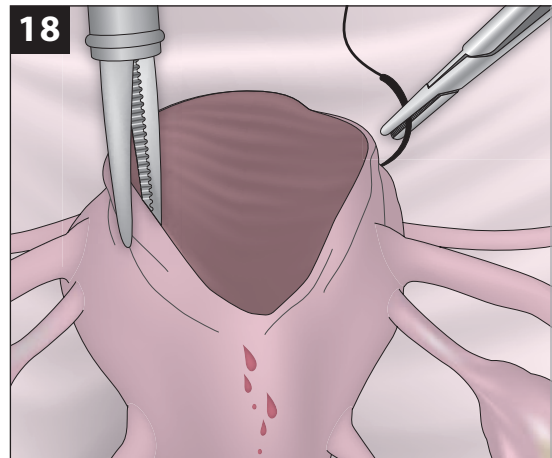
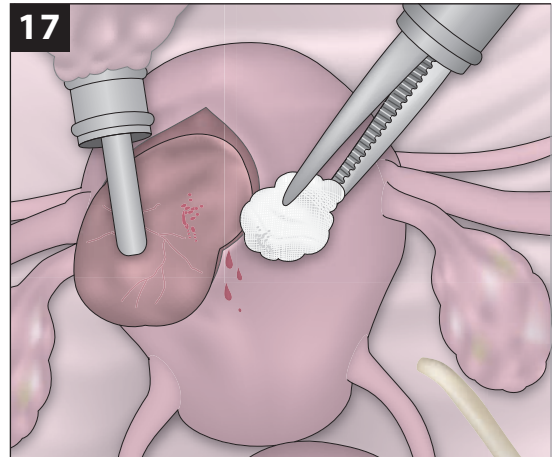
myometrium with the bipolar scissors, the enucleation of the myoma can begin by grasping the myoma with forceps (Figure 17). The enucleation procedure must be performed using bipolar forceps or bipolar scissors. In case of bleeding, conventional plastic suction tubes from open surgery can be used to evacuate blood clots, and rinse out water and smoke. After removing the fibroid, the myometrium must be sutured. In case of intramural fibroids, an adequate closure of the myometrium is necessary.

In contrast to gas laparoscopy, conventional needle drivers can be used (Figure 18) to manipulate suture material with a curved needle for an adequate closure of the myometrial tissue. We perform closure of all layers with as few stitches as necessary (Figure 19) to achieve an adequate and functional closure of the myometrial wound. With this technique, we avoid wound healing problems due to infections and necrosis that may occur with numerous stitches. With this technique, we have performed more than 200 myomectomies in infertile patients with 77% pregnancy rate. There have been no uterine ruptures during pregnancy or during delivery.

Lift-laparoscopy extends organ preserving operations for fibroid removal of any size according to the skill of the surgeon. Even myomatous uteri with a size of about 1.5 kg can be managed. For morcellation of such huge fibroids, an electrical morcellator should be used, however, small myomas can be morcellated without difficulties with a scalpel or scissors.

## HYSTERECTOMY

The most difficult problem for hysterectomy is how to divide vessels, especially the uterine artery. Gasless laparoscopy allows plenty of variations for this procedure. Without these problems, one can apply a ligature around the uterine vessel (Figure 20). With a knot pusher the vessels are ligated and after applying a ligature contralaterally, the uterine vessels can be cut.

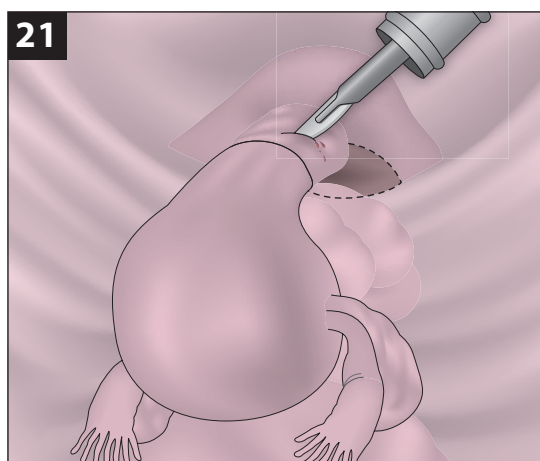
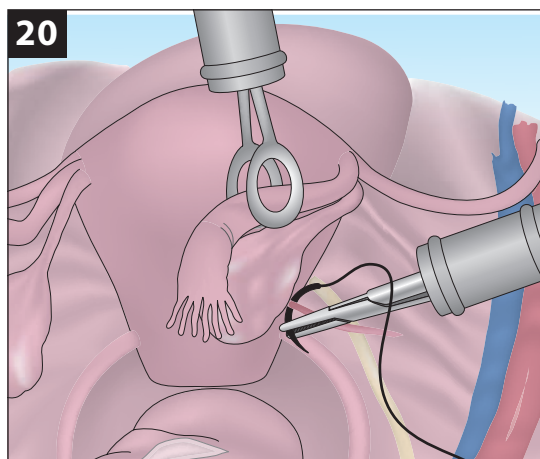


The coagulation with the bipolar forceps or other energy sources is, of course, also possible in gasless laparoscopy. An additional positive effect is that the open abdomen prevents smoke from accumulating and avoids the fogging of the laparoscope.

Using the bipolar scissors, coagulation and cutting can be securely performed in one step without carbonization and with less of a coagulation edge to avoid injury to other structures like the ureter. With one-step coagulation and cutting, the laparoscopic procedure becomes very fast as there is no change of instruments during the vessel ligations. To open the vaginal cuff, one can use the scalpel (Figure 21) or the bipolar scissors.

## PELVIC AND PARAAORTIC LYMPHADENECTOMY

Even though a magnified vision extends the ability of laparoscopic surgery for cancer, in general, abdominal cancer operations are not performed laparoscopically. However, laparoscopy may even obtain a better surgical result and reduce morbidity, the duration of hospitalization, and recovery time associated with conventional surgery. The feasibility of diagnostic or therapeutic laparoscopic pelvic and/or paraaortic lymphadenectomy is described in a growing number of publications (see Chapter 24). Importantly, increasing numbers of reports concerning laparoscopic approaches for cancer patients have discussed the possible role of CO<sub>2</sub> in spreading cancer cells, tumor dissemi-



nation, implantation, and trocar site metastasis. Clinical reports and the results of experimental animal studies suggest that CO<sub>2</sub> pneumoperitoneum should be avoided for malignant or suspicious tumors. Further studies are needed to compare conventional abdominal methods with the approach of gasless laparoscopy.

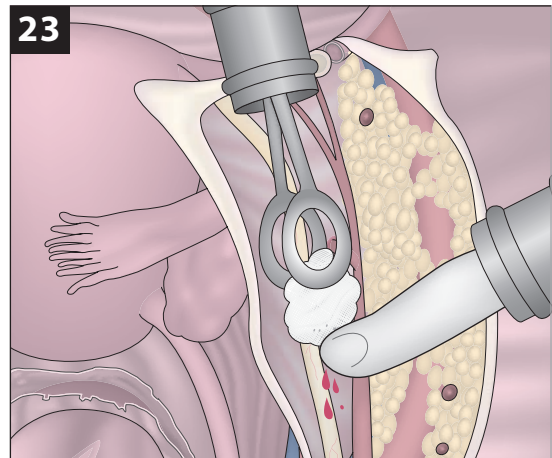
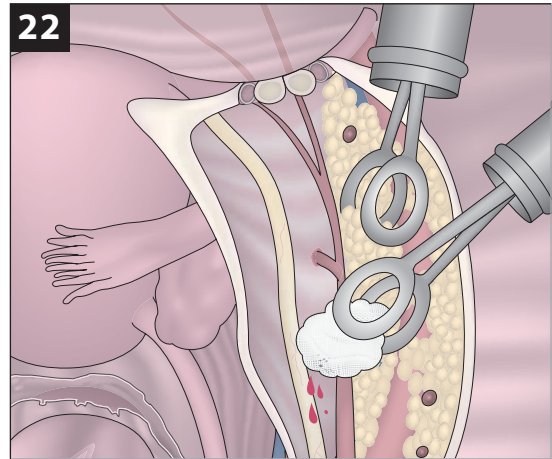
The results of our pilot study show that gasless laparoscopy allows similar surgical results to those obtained by the



conventional abdominal route. During the operative procedure, Lift-laparoscopy can be used for a number of surgical maneuvers as in open surgery. Using cotton swabs, for example, fatty tissue lateral to the iliac vessels can be dissected and extracted using conventional grasping forceps (Figure 22). Thus the external iliac artery and vein can be easily identified. After incising and opening the perivascular sheath along the external iliac artery, the lymph nodes and the fatty tissue can be removed from this area while sparing the genitofemoral nerve.

The outstanding technical possibilities using gasless laparoscopy may contribute to increased safety compared with CO<sub>2</sub> laparoscopy. Through the valveless trocars, conventional instruments can be introduced and changing instruments is rapid and without gas loss. In case of severe bleeding, a hemostat or a conventional clamp can be placed during constant irrigation and/or suction without affecting visibility. Suturing or placement of clips is easier due to the lack of valves in the trocar sleeves. The introduction of curved needles is less problematic via the 10 mm flexible trocars than through the metal trocars used with pneumoperitoneum laparoscopy. Using conventional needle drivers and clamps, suturing is as easy as in open surgery.

Isolated lymph nodes or lymph node groups can be separated by simply pulling them bluntly using a fenestrated clamp and dissecting the lymph nodes out of fatty and surrounding tissue (Figure 22). Coagulation is used only in case of hemorrhage. To remove the lymphatic tis-



sue, one can simply extract the specimen through the flexible trocars without contamination of the trocar incision.

Moreover, the lack of pneumoperitoneum has a positive effect on the iliac vessels as they are filled with blood and do not collapse as in pneumoperitoneum laparoscopy. This improves the process of isolating vessels and dissecting lymph nodes. Using a finger, one can also palpate tissue, vessels, lymph nodes, or suspicious findings (Figure 23).

---

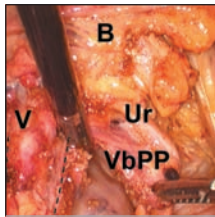
## **TERMINATION OF THE GASLESS-LAPAROSCOPIC PROCEDURE**

When the procedure is completed, the entire abdominal cavity is checked for hemostasis. Then, the ancillary trocars should be withdrawn under vision. To prevent hernia formation, the fascia of the umbilical and the ancillary ports should be closed. Closure of ancillary ports should be performed under endoscopic vision. Afterwards, the retractor can be removed out of the abdominal cavity turning it

counter-clockwise. The abdominal cavity can then be elevated by one hand while the other hand is holding the endoscope. The trocar sheath is removed from the incision while the scope remains in the abdomen. Withdrawing the endoscope slowly out of the abdominal cavity ensures that no bowel or omentum is pinched in the incision. The fascia is sutured, and, after approximating subcutaneous tissue, the skin is adapted by sutures. The AbdoLift® is then removed piece by piece from the operating table and prepared for cleaning and sterilization.



# LAPAROSCOPIC RADICAL HYSTERECTOMY: TRADITIONAL AND NERVE-SPARING TECHNIQUE



*Javier F Magrina, M.D.*  
*Rosanne Kho, M.D.*  
*Wojciech Pawlina, M.D.*

**T**he magnified view provided by the laparoscope to the deep pelvic structures, and direct access with the tip of the laparoscope and the laparoscopic instruments to the deep pelvic structures provide an excellent opportunity for the performance of radical hysterectomy, particularly when performing the nerve-sparing technique. The seven degrees of articulation of robotic instruments, available with the daVinci® robotic interface system (Intuitive Inc, Sunnyvale, CA), offers accurate and minimally traumatic tissue dissection, unsurpassed by the human hand or conventional rigid laparoscopic instrumentation. The surgical technique described below is alike whether the operative approach is robotic or conventional laparoscopy, however, the instrumentation and trocar site placement are different in robotics. All steps of the operation are performed laparoscopically.

## INDICATIONS

Laparoscopic radical hysterectomy is primarily used for patients with cervical cancer Stage IB1 lesions > 2 cm and endometrial cancer Stage IIB. In patients with cervical cancer lesions < 2 cm, the modified radical

hysterectomy technique has been shown to provide similar results as the radical technique but with decreased morbidity, in particular bladder dysfunction.

## TECHNIQUES

The traditional and nerve-sparing techniques of laparoscopic radical hysterectomy will be described here. The degree of radicality in both techniques is similar but in the latter the sympathetic (hypogastric nerve and pelvic plexus) and parasympathetic (pelvic splanchnic nerves and pelvic plexus) innervation is preserved. Whenever possible, the nerve-sparing technique is preferable since bladder function and vaginal lubrication are better preserved without compromising recurrence or survival. This technique is more commonly used in Japan, where it originated (Tokyo method), and in some European centers in Italy, Belgium, and Germany. It is uncommonly used in United States.

The surgical steps are demonstrated in a fresh cadaver to have time for photo documentation and to offer a comparison between the nerve-sparing technique (performed on the right side) and the traditional technique (left side). Moreover, additional resection of the remaining right parametrium was performed to demonstrate a more extensive degree of radicality, exposing sacral nerve roots. The rectum was mobilized from the presacral space to better demonstrate the right pelvic splanchnic nerves.

The additional surgical steps of the nerve-sparing technique are indicated

separately in the description below. Where there is no such indication, the surgical steps are similar for both techniques.

The techniques of pelvic and aortic lymphadenectomies are not described here since they are not particular for patients with cervical cancer. Pelvic lymphadenectomy can be performed prior to the radical hysterectomy or after its completion. It is routinely performed in all patients undergoing radical hysterectomy. Aortic lymphadenectomy is indicated in the presence of positive pelvic nodes, enlarged aortic nodes, or cervical lesions > 5 cm irrespective of pelvic node status.

## PATIENT PREPARATION

A preoperative medical examination is routinely performed one or two days before the surgery day to identify any subclinical conditions that may represent a risk or the need for a change in anesthesia. The day before surgery, the patient remains on clear liquids after lunch and until midnight. A Fleets enema is self-administered by the patient at home before checking into the hospital two hours before the planned time for the operation.

Cefotetan 1 gm IV is given one hour before surgery in the preoperative area and repeated three hours into the operation.

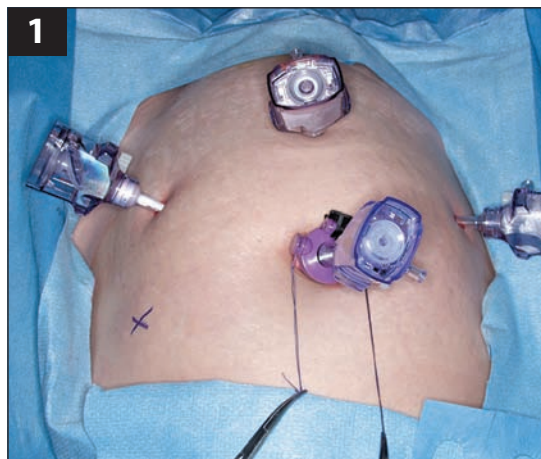
## PATIENT POSITIONING

The patient is placed in the semi-lithotomy position using Allen stirrups. Arms are tucked in bilaterally. Arms and legs are padded to protect injury. To prevent

sliding during the much needed Trendelenburg position during the procedure, an egg crate mattress is fastened with wide tape to the OR table and the patient's bare back lays directly on it. This also avoids the risk of cervical plexus injury associated with the use of inappropriately placed shoulder straps. A Foley catheter is inserted into the bladder. The patient is then prepped and draped as customary.

### TROCAR PLACEMENT

The open technique of entry is used routinely with the Hassan trocar. The incision is made at the deepest part of the umbilicus, where one finds the shortest distance between skin and abdominal wall fascia. Three additional trocars are placed in the pelvic area (Figure 1). If an aortic lymphadenectomy is indicated, a fifth trocar is placed 7-10 cm cranial to the left lower quadrant trocar site. It is used to insert the instrument to retract the sigmoid mesentery and the left ureter laterally. The operating surgeon uses dissecting monopolar scissors (Electroshield scissors, Encision  $3/4$ " Curved Scissors, Boulder, CO) with the right hand (at a setting of 55 W) and a grasper (Davis & Geck grabber, Aesculap Prestige 5 mm 35 cm grasper, Center Valley, PA) with the left hand. The assistant utilizes a grasper (Davis & Geck grabber, Aesculap Prestige 5 mm 35 cm grasper, Center Valley, PA) with the right hand. The laparoscope is voice-controlled by the surgeon with the assistance of a robotic arm, Aesop (Intuitive Inc, Sunnyvale, CA). The abdomen and pelvis are inspected for



metastatic disease and other pathology. Pelvic washings are obtained using saline solution.

### OPENING THE LATERAL PELVIC SPACES IDENTIFICATION OF MAIN BLOOD VESSELS AND URETER

An incision is made with the coagulating scissors over the peritoneum lateral and parallel to the infundibulopelvic ligament, starting at a level cranial to the pelvic brim and continuing in a caudal direction over or medial to the external iliac vessels towards the outer third of the round ligament. The round ligament is transected with monopolar scissors medial to the external iliac vessels and the incision continued over the anterior leaf of the broad ligament in the direction of the vesicouterine fold (Figure 2).

The bifurcation of the common iliac is identified at the pelvic brim. The dissection is continued immediately over the hypogastric (internal iliac) artery in a caudal direction until the anterior bifur-

cation is found by simply separating the loose connective tissue with a grasper. The superior vesical artery (a branch of the umbilical artery) is followed to the upper lateral aspect of the bladder. The ureter is identified attached to the pelvic peritoneum (Figure 3).

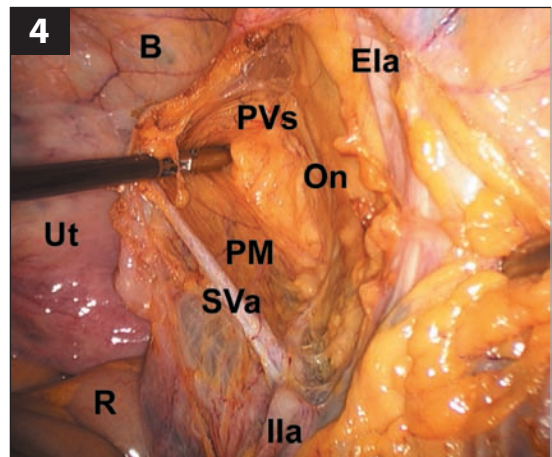
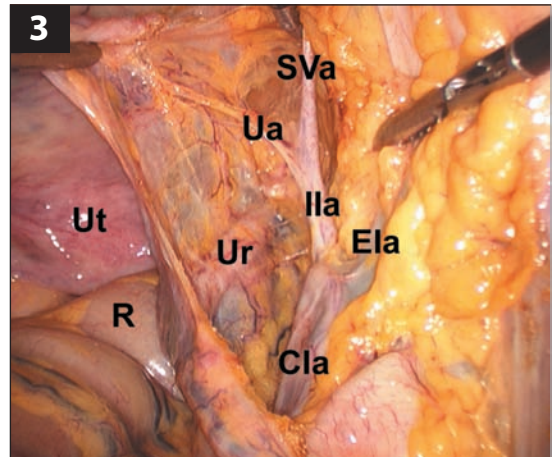
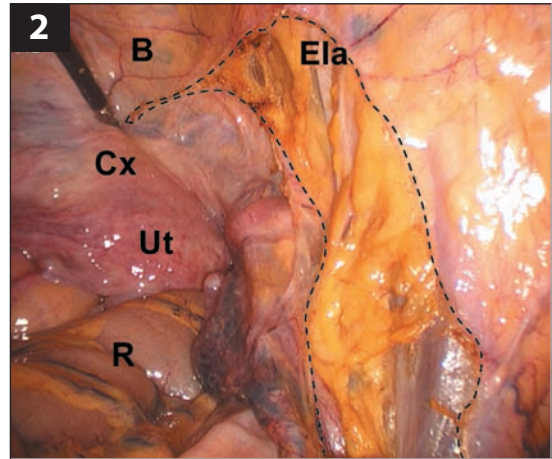
### DEVELOPMENT OF PARAVESICAL SPACE

Anterolateral to the superior vesical artery and medial to the external iliac vein is the safe entry to the paravesical space. The space is created by dissecting in a dorsal and caudal direction the loose connective tissue, by traction and countertraction medially and laterally, respectively, in successive steps, until the pelvic floor (levator ani muscle) is reached. The external iliac vessels and obturator nodes constitute the lateral wall, the parametrial web the posterior aspect, the bladder the medial wall, and the pubic bone the anterior boundary (Figure 4).

### DEVELOPMENT OF PARARECTAL SPACE

The ureter is found attached to the lateral pelvic peritoneum and is traced until crossing the uterine artery. The dissecting instrument must stay immediately above the ureter, this will minimize the risk of injury and potential bleeding.

Immediately posteromedial to the superior vesical artery, medial to the hypogastric artery and lateral to the ureter is the safe entry to the pararectal space. Separating the loose connective tissue in a caudal and dorsal direction by medial and lateral traction and countertraction, respectively, in successive steps,



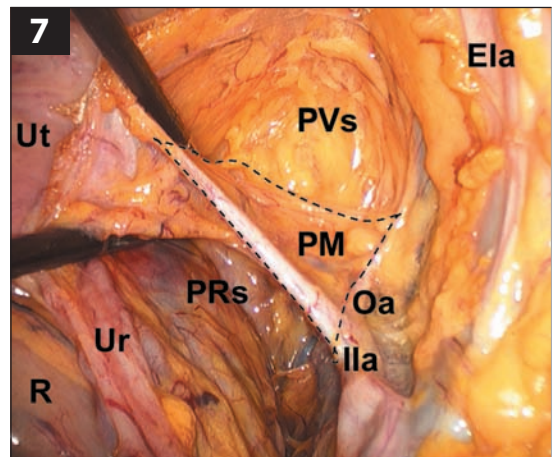
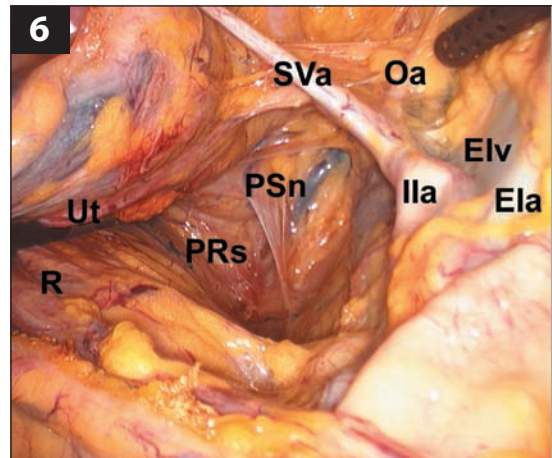
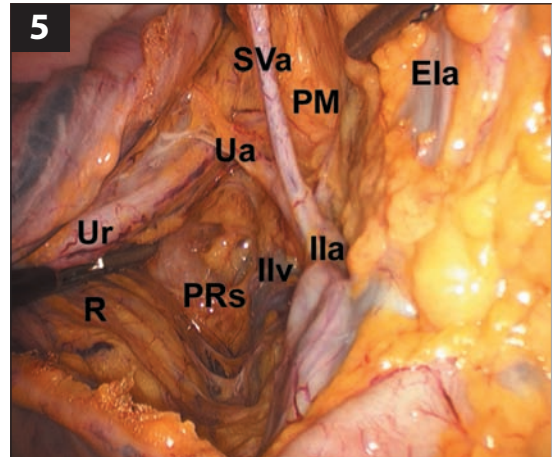
the space is developed. The hypogastric artery and vein lay on the lateral wall, the rectum medially, the sacrum posteriorly and the parametrium anteriorly (Figure 5). If the dissection is carried out in a straight dorsal direction where the sacrum is found and the full depth of the pararectal space is not reached, subsequent resection of the parametrium would be compromised.

#### NERVE-SPARING TECHNIQUE: IDENTIFICATION OF THE PELVIC SPLANCHNIC NERVES

In the dorsal and lowermost aspect of the pararectal space, the pelvic splanchnic nerves (parasympathetic fibers) are identified. They originate from S2, S3 and S4 roots of the sacral plexus and can be seen coursing towards the medial and lower aspect of the parametrium (Figure 6). There they join the hypogastric nerve (sympathetic) and form the pelvic (inferior hypogastric) plexus, which conveys sympathetic and parasympathetic innervation. The ventral branches of the pelvic plexus provide innervation to the uterus (uterine branches) and its caudal branches supply bladder (vesical branches) and vaginal (vaginal branches) innervation.

#### IDENTIFICATION OF PARAMETRIUM

With traction on the medial wall of the paravesical and pararectal spaces, the parametrium is identified, separating both spaces. It is the dorsal continuation of the cardinal ligament, inserting into the upper third of the vagina and lower cervix and reaching in a posterolateral direction the pelvic wall (Figure 7). It inserts in the





pelvic wall in a triangular fashion, its apex resting at the level of the anterior division of the hypogastric artery and the base, on the lateral pelvic wall, at the level of the iliac spine. The parametrium is inspected and palpated between two graspers for any enlarged lymph nodes or tumor involvement.

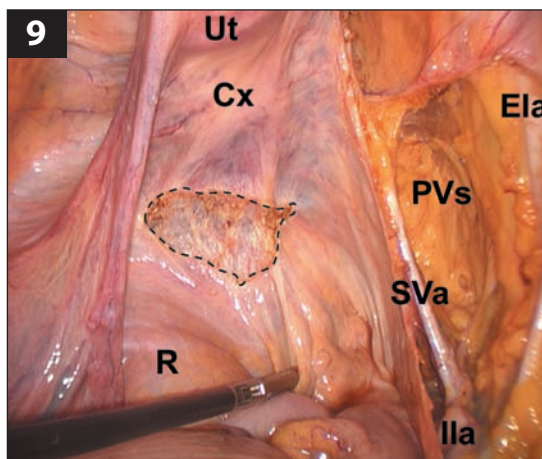
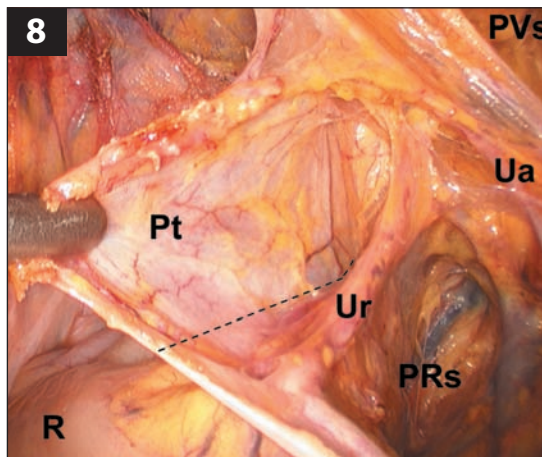
### MOBILIZATION OF THE URETER FROM THE MEDIAL ASPECT OF THE LATERAL PELVIC PERITONEUM

The ureter is separated from the lateral pelvic peritoneum by coagulating with the scissors its peritoneal attachments about 5 mm ventral and parallel to its course and developing a dissecting plane between the ureter and the lateral pelvic peritoneum. This dissection is carried caudally until the uterine artery is identified (Figure 8). The proper dissecting plane is easily developed, and the ureter remains with an intact adventitia, preserving its blood supply. A ureter that appears “naked” (markedly white), without adventitia, has been dissected in the wrong plane and carries the risk of ischemia with subsequent development of stricture or fistula.

The lateral pelvic peritoneum is cut at the level of future division of the uterosacral ligaments and the division carried until it reaches the upper border of the uterosacral ligament (Figure 8).

### DEVELOPMENT OF THE RECTOVAGINAL SPACE AND IDENTIFICATION OF THE UTEROSACRAL LIGAMENTS

By downward traction on the peritoneum at the most caudal portion of the



posterior cul-de-sac, and upward traction on the uterus, a transverse incision is made with the coagulating scissors across the most dependent portion of the cul-de-sac and anterior to the rectum. The transected edges of the peritoneum will separate due to the traction on the tissues (Figure 9). The loose connective tissue of the rectovaginal space is separated by traction and counter-traction in a ventral and dorsal direction, respectively. To assist in the dissection, the scrub nurse places the vaginal probe in the posterior

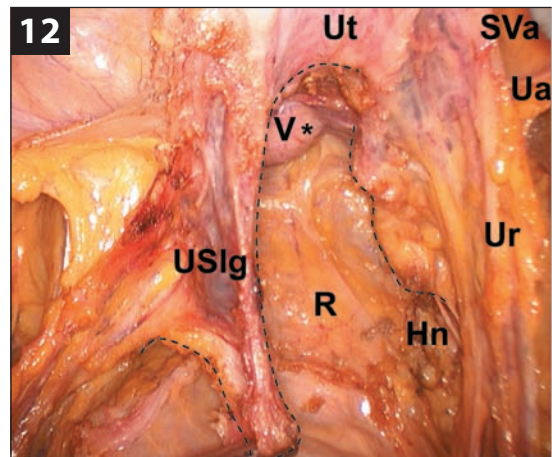
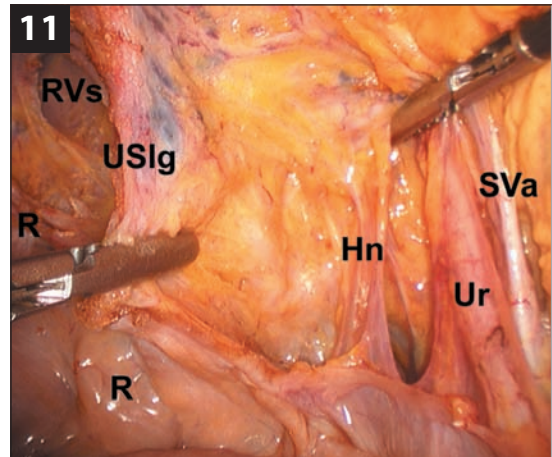
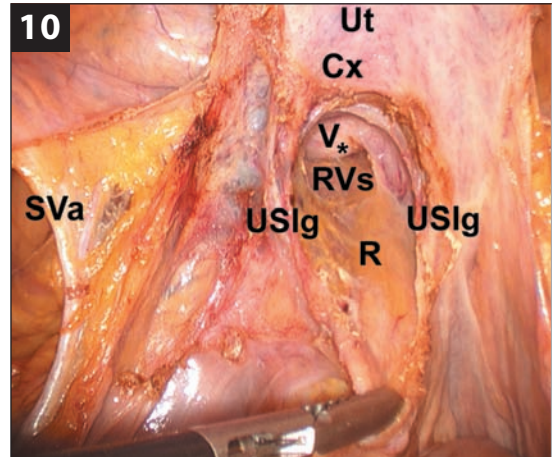
vaginal fornix. In the rare case where the anterior rectal wall can not be clearly identified, a rectal probe (Apple Medical Rectal Probe, Marlborough, MA), inserted in the rectum and advanced to that level, will facilitate its identification. The rectum is displaced dorsally at its lateral borders where it is in contact with the uterosacral ligaments. The uterosacral ligaments become apparent, and are separated from the lateral wall of the rectum until their insertion into the upper posterior vagina (Figure 10).

#### A. TRADITIONAL TECHNIQUE

The uterosacral ligaments are divided using a bipolar vessel sealing instrument (EnSeal™; SurgRx, Palo Alto, CA), at the appropriate level away from the cervix. The degree of resection depends on the size and location of the tumor, but usually is at the level of the anterior rectal wall.

#### B. NERVE-SPARING TECHNIQUE: SEPARATION OF THE HYPOGASTRIC NERVE FROM THE UTEROSACRAL LIGAMENTS

The rectovaginal space is developed and the uterosacral ligaments are identified as indicated above. The hypogastric nerves are identified on the soft lateral aspect of the uterosacral ligament. A grasper is used to create a space between the hypogastric nerve and the lateral aspect of the uterosacral ligament by blunt dissection. The hypogastric nerve is then isolated and preserved (Figure 11). The uterosacral ligaments are selectively divided (without including the hypogas-



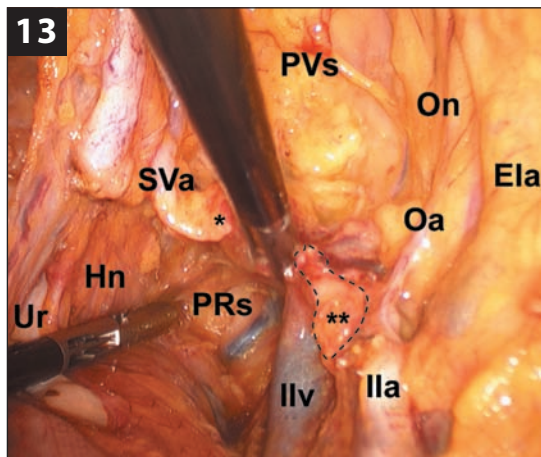
tric nerves) at the level of the anterior rectal wall with the EnSeal™ (SurgRx, Inc, Palo Alto, CA) and until their attachment to the posterior vaginal wall, sparing the hypogastric nerves (Figure 12).

### DIVISION OF THE PARAMETRIUM

A. Traditional technique. The parametrium (also known as parametrial web or lateral parametrium) is made apparent by placing traction on the paravesical and pararectal spaces (Figure 7). Using the EnSeal, the superior vesical and uterine arteries are selectively divided at their origin from the internal iliac artery. The division of the parametrium continues dorsally with successive applications of the EnSeal, dividing the veins from their origin at the internal iliac vein (Figure 13). The transection continues at that level of lateral division until the pelvic floor is reached. The paravesical and pararectal spaces become united.

### B. NERVE-SPARING TECHNIQUE: PRESERVATION OF THE PELVIC PLEXUS

The hypogastric nerve (previously isolated from the lateral aspect of the uterosacral ligament) is followed towards the medial and dorsal aspect of the parametrium, where it is joined by the pelvic splanchnic nerves. The vascular portion of the parametrium, not containing innervation, is located in its ventral aspect, which in addition to the vessels also contains fat, lymph nodes, lymphatics and loose connective tissue. The nervous part or nerve-containing portion of the parametrium is located at its dorsal aspect



where dense connective tissue is present. By preserving this lower dense part, the pelvic plexus, constituted by the fusion of the pelvic splanchnic nerves to the hypogastric nerves, is spared.

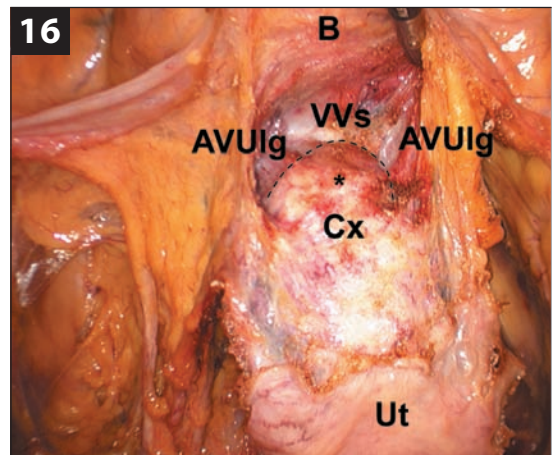
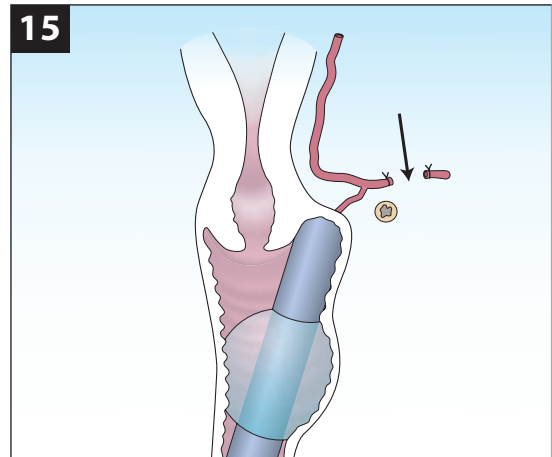
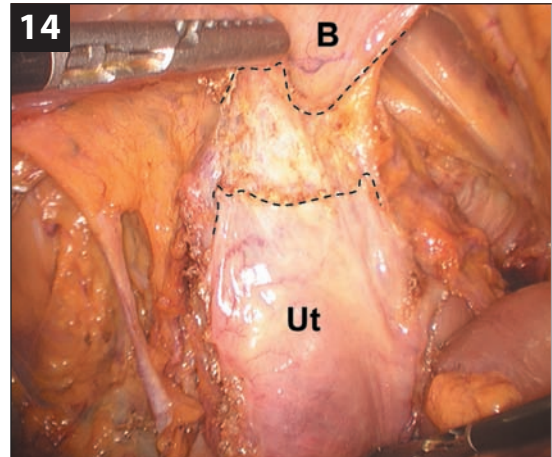
The superior vesical and uterine arteries are divided selectively as described above. The vascular portion of the parametrium is divided with the EnSeal as described in the nerve-cutting technique. The division stops at the level of the deep uterine vein, transecting it at its origin from the internal iliac vein (Figure 13). Alternatively, the middle hemorrhoidal (rectal) artery can also be used to determine the lower level of transection of the vascular part of the parametrium. Below that level, thicker dense connective tissue is identified and the beginning of the nerve-containing section of the parametrium. The division of the parametrium is then continued in a medial and dorsal direction, dividing the uterine fibers of the pelvic plexus but preserving the pelvic plexus (containing pelvic splanchnic nerves and the hypogastric nerve). Once

the parametrium is divided, the paravesical and pararectal space become a single space (for a comparison of the right and left divided parametria see below).

#### DEVELOPMENT OF THE VESICOVAGINAL SPACE AND IDENTIFICATION OF THE VESICOUTERINE LIGAMENTS

With ventral traction on the bladder by the surgeon and dorsal and cranial traction on the uterus by the assistant, the coagulating scissors are used to transect the peritoneum transversally at the level of the vesicouterine fold. The edges of the transected peritoneum will separate due to the traction on the tissues (Figure 14). With the scissors closed, and with the assistance of the left grasper, the loose connective tissue between bladder and vagina is dissected by traction and counter-traction in a ventral and dorsal direction, respectively. Short touches of the coagulating scissors are applied when necessary. To assist in the dissection, a vaginal probe (Mayo Clinic) with an inflatable ring (Koh inflatable ring, Cooper Surgical Colpopneumo occluder, Trumbull, CT) (Figure 15) is introduced into the vagina by the scrub nurse and advanced towards the anterior vaginal wall (Figure 16). This facilitates the identification of the anterior vaginal wall and its separation from the bladder wall.

The dissection is carried at least until the full upper third of the vagina is exposed (Figure 16). It is important to always remain in the midline of the vesicovaginal space until the lower limit of the dissection is reached, since there are



no blood vessels in that area. The vesicouterine ligaments containing blood vessels are the lateral limits of the vesicovaginal space.

If the vesicovaginal space does not dissect easily or bleeds, the surgeon is in the wrong dissecting plane (most likely into the detrusor muscle) or there is malignant involvement of the anterior vaginal wall. If the latter is suspected to be the case, a frozen section of the anterior vaginal wall will provide the answer. To assist in the former, filling the bladder with 200 mL of normal saline fluid, will serve to identify the lower aspect of the bladder and to return to the correct plane of dissection.

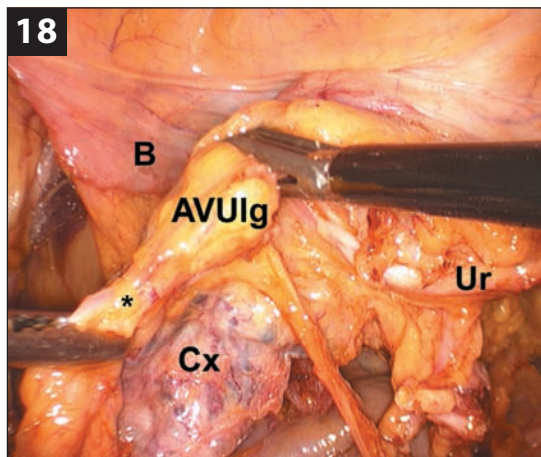
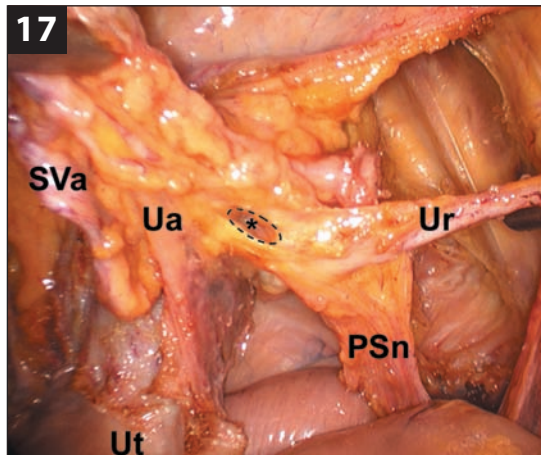
### DIVISION OF THE SUPERIOR VESICAL ARTERY

The superior vesical artery is sectioned with the EnSeal at the upper lateral border of the bladder and the transected end mobilized medially (Figure 17).

### PARAMETRIAL URETERAL DISSECTION

#### DIVISION OF THE ANTERIOR VESICOUTERINE LIGAMENT

With medial traction on the transected uterine and superior vesical arteries and lateral traction of the ureter by the surgeon, the point of entry of the ureter into the parametrial tunnel is identified. With the use of the scissors or fine grasper, the entrance to the tunnel is widened by staying immediately above the ureter and



below the uterine artery, where an avascular plane exists (Figure 17). The transected uterine artery and superior vesical arteries remain mobilized medial to the ureter, since they are removed with the uterus (they can be cut and removed separately if they interfere with exposure).

The parametrial ureteral dissection is carried out caudally as to be able to insert the EnSeal instrument into the tunnel just above the ureter. The first portion of the anterior vesicouterine ligament is coagulated and transected with the

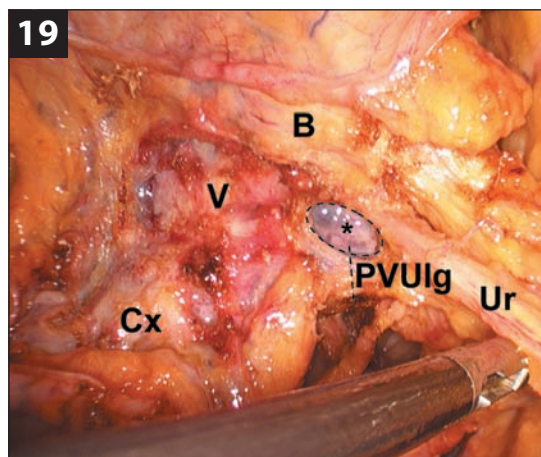
EnSeal (Figure 18). The technique of widening the tunnel above the ureter with scissors or a fine grasper and reinserting the EnSeal and transecting the anterior vesicouterine ligament is repeated (usually two more times) until the junction of the entrance of the ureter into the bladder is encountered. Once the entire anterior vesicouterine ligament has been divided the parametrial portion of the ureter is clearly exposed (Figure 18).

### DIVISION OF THE POSTERIOR VESICOUTERINE LIGAMENT

With the use of coagulating scissors, the exposed parametrial ureter is gently mobilized laterally, uncovering the posterior portion of the vesicouterine ligament, located between the ureter, vagina, and anterior aspect of the parametrium. At the junction of the ureter into the bladder and the lateral edge of the vagina, there is an avascular space which identifies the entry point for division of the posterior vesicouterine ligament (Figures 19, 20, 21).

#### A. TRADITIONAL TECHNIQUE

The avascular space is developed laterally until it reaches the paravesical space. Retracting the bladder ventrally with the left grasper, and the assistant the ureter in a lateral direction, the EnSeal is used, two or three times, to transect the posterior portion of the vesicouterine ligament. The ureter becomes free from the vesicouterine ligament and parametrium.



#### B. NERVE-SPARING TECHNIQUE: PRESERVATION OF VESICAL BRANCHES OF PELVIC PLEXUS

The dorsal and lateral portion of the posterior vesicouterine ligament contains the vesical branches of the pelvic plexus which provide innervation to the bladder and vagina. There they can be identified and separated by blunt dissection from the vascular portion of that ligament. By selectively dividing the vascular part of the ligament, the vesical and vaginal branches can be spared. The pelvic plexus continues caudally along the lateral aspect of the vaginal wall.

With lateral and ventral traction of the ureter by the assistant, and ventral retraction of the bladder with the left grasper, the surgeon introduces the posterior blade of the EnSeal in a cranial direction into the identified avascular space (Figure 19). The posterior vesicouterine ligament is transected in its medial aspect with one or two applications of the EnSeal in a similar fashion preserving the vesical branch-

es of the pelvic plexus, located in the dorsal and lateral aspect of this ligament. This results in complete mobilization of the ureter from the vesicouterine ligament and parametrium with preservation of the vesical branches of the pelvic plexus (Figure 20). Additionally, the blood supply to the lowermost and distal portion of the ureter is preserved, reducing the risk of ischemia and the potential for subsequent stricture or fistula formation.

## DIVISION OF PARAVAGINAL TISSUE

### A. TRADITIONAL TECHNIQUE

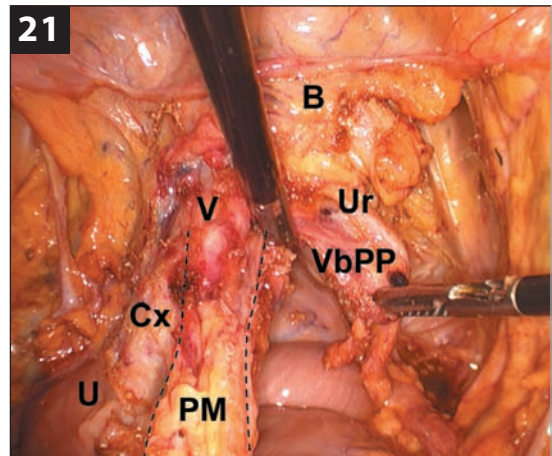
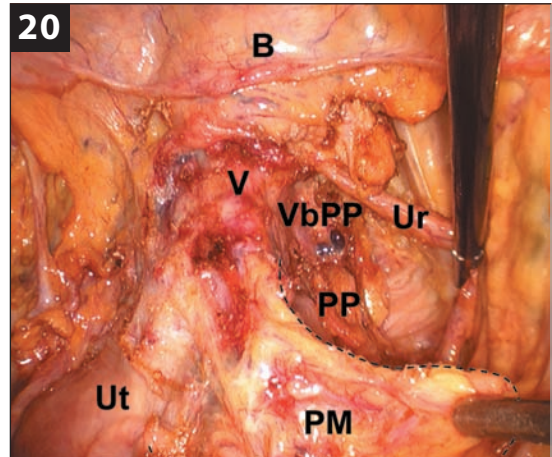
With the transected parametrium retracted ventrally and the ureter laterally, the paravaginal tissue is exposed. The EnSeal is applied once or twice to divide the paravaginal tissue, at a level below the lower portion of the parametrium, until the lateral vaginal wall is reached.

### B. NERVE-SPARING TECHNIQUE

With the transected parametrium retracted ventrally and the ureter laterally, the paravaginal tissue is exposed. The vesical branches of the pelvic plexus run along the lateral edge of the vagina where they are identified and gently separated laterally. The paravaginal tissue is divided with the EnSeal below the lower portion of the parametrium, usually with one or two applications, until the lateral aspect of the vagina is reached (Figure 21).

## TRANSECTION AND CLOSURE OF THE VAGINA

With both paravaginal tissues divided, the extent of parametrial resection can be



noted and the level of transection of the vagina determined (Figure 22). The level of transection is determined by the proximity of the tumor to the periphery of the cervix and the tumor size. To assist in identifying the level of transection, the vaginal probe is advanced by the scrub nurse towards the anterior vaginal fornix, delineating the lower aspect of the cervix (Figure 16). The surgeon determines the length of vagina to be removed measuring from the lower aspect of the cervix. Prior to transecting the vagina, the ring is

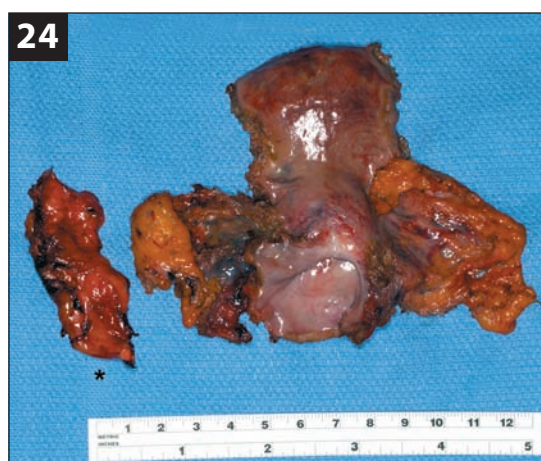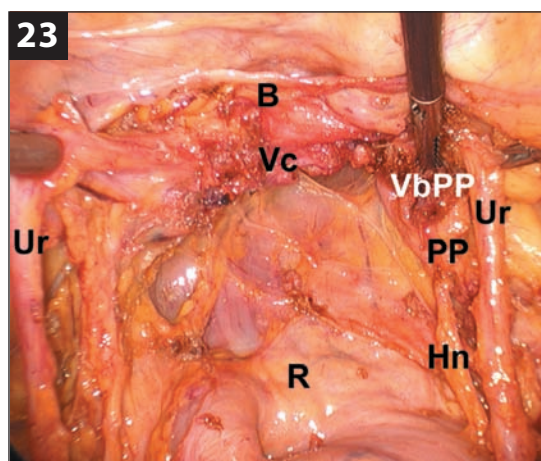
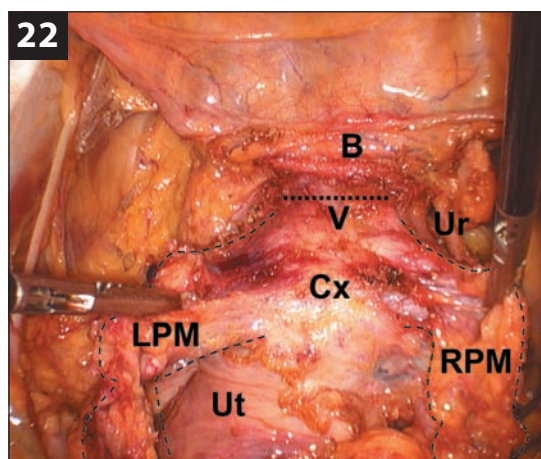
inflated with 60 mL of water, preserving the pneumoperitoneum once the vagina is entered (Figure 15). The coagulating scissors are used to transect the vagina circumferentially, starting at the 12 o'clock position. Excessive coagulation of the transected vaginal edge is to be avoided since this may result in extensive thermal damage, subsequent necrosis, formation of granulation tissue and possible evisceration.

The vaginal cuff is closed with a precut (26 cm) 0 continuous absorbable suture with a CT 2 needle (Ethicon, Sommerville, NJ), starting at the right angle, incorporating the paravaginal tissue below the cut vaginal edge, and continuing to the opposite site. The Cook needle holder is used with this needle size (Cook endoscopic needle driver standard 5 mm, Spencer, IN). A Lapraty (Ethicon, Sommerville, NJ) is used at each end of the suture, eliminating the need for intracorporeal knot tying. At the completion of the operation no difference is appreciated in the degree of resection between both sides of the pelvis despite the fact that the pelvic plexus is preserved on the right side (Figure 23). The surgical specimen is shown in Figure 24.

The pelvis is inspected for hemostasis while irrigating with water, since blood does not mix well with water. This allows for the detection of small bleeding vessels. No drains are used.

#### TROCAR SITE CLOSURE

The fascia at the site of the 10 mm trocar incisions is closed with a single suture of 0 absorbable material using the Inlet





closure device (Inlet Medical Carter-Thompson CloseSure System, Eden Prairie, MN). The skin is closed with a subcuticular continuous suture of 4-0 absorbable material. The fascia at the umbilical incision is closed with a running suture of 0 absorbable material with a urological needle (0 Vicryl UR 6, Ethicon, Sommerville, NJ).

## POSTOPERATIVE COURSE

Clear liquids are started immediately upon awakening if patient is not nauseated. Regular diet is started next morning for breakfast. If patient is tolerating liquids, the IV is removed and capped. Patient is allowed to ambulate freely. The patient is discharged when pain is under control and is tolerating oral feedings,

usually on the second or third postoperative day. Patient is discharged with Foley catheter in place. Oral Nitrofurantoin 100 mg daily is given for cystitis prophylaxis while the Foley catheter is in.

The Foley catheter is removed on the fifth postoperative day and the patient is allowed to void within a period of 4 hours. If the residual urine volume is <100 mL, the patient is taught self-catheterization every four hours during the day for the ensuing 10 days until the residual urine volume is <100 mL consistently. If the residual urine volume is >100 mL, the catheter is reinserted and a new voiding trial is allowed in 72 hours. If the patient is unable to void, the catheter is reinserted immediately and a repeat voiding trial is allowed in 7 days.

AVULG - ANTERIOR VESICOUTERINE LIGAMENT  
 B - BLADDER  
 CIA - COMMON ILIAC ARTERY  
 CX - CERVIX  
 ELA - EXTERNAL ILIAC ARTERY  
 ELV - EXTERNAL ILIAC VEIN  
 HN - HYPOGASTRIC NERVE  
 IIA - INTERNAL ILIAC ARTERY  
 IIV - INTERNAL ILIAC VEIN  
 LPM - LEFT PARAMETRIUM  
 OA - OBTURATOR ARTERY  
 OIM - OBTURATOR INTERNUS MUSCLE  
 ON - OBTURATOR VEIN  
 PM - PARAMETRIUM  
 PP - PELVIC PLEXUS  
 PRS - PARARECTAL SPACE

PSN - PELVIC SPLANCHNIC NERVES  
 PSS - PRESACRAL SPACE  
 PT - PERITONEUM  
 PVS - PARAVESICAL SPACE  
 PVULG - POSTERIOR VESICOUTERINE LIGAMENT  
 R - RECTUM  
 RPM - RIGHT PARAMETRIUM  
 RVs - RECTOVAGINAL SPACE  
 SVA - SUPERIOR VESICAL ARTERY  
 UA - UTERINE ARTERY  
 UR - URETER  
 USLG - UTEROSACRAL LIGAMENT  
 UT - UTERUS  
 V - VAGINA  
 VVs - VESICOVAGINAL SPACE  
 VbPP - VESICAL BRANCHES OF PELVIC PLEXUS

## SUGGESTED READING:

Magrina JF, Goodrich MA, Lidner TK, Weaver AL, Cornella JL, Podratz KC. Modified radical hysterectomy in the treatment of early squamous cervical cancer. *Gynecol Oncol* 1999;72:183-186

Landoni F, Maneo A, Cormio G, Perego P, Milani R, Caruso O, Mangioni C. Class II versus Class III Radical hysterectomy in stage IB-IIA Cervical Cancer: a prospective randomized study. *Gynecol Oncol* 2001;80:3-12

Yang Y-C, Chang C-L. Modified radical hysterectomy for early Ib cervical cancer. *Gynecol Oncol* 1999;74:241-244

Michalas S, Rodolakis A, Voulgaris Z, Vlachos G, Giannakoulis N, Diakomonalis E. Management of early-stage cervical cancer by modified (Type II) radical hysterectomy. *Gynecol Oncol* 2002;85:415-422

Sakakamoto S, Takizawa K. An improved radical hysterectomy with fewer urological complications and with no loss of therapeutic results for invasive cervical cancer. *Ballieres Clin Obstet Gynecol* 1988;2:953-962

Sakuragi N, Todo Y, Kudo M, Yamamoto R, Sato T. A systematic nerve-sparing radical hysterectomy technique in invasive cervical cancer for preserving postsurgical bladder function. *Int J Gynecol Cancer* 2005;15:389-397

Raspagliesi F, Ditto A, Fontanelli R, Solima E, Hanozet F, Zanaboni F, Kusamura S. Nerve-sparing radical hysterectomy: a surgical technique for preserving the autonomic hypogastric nerve. *Gynecol Oncol* 2004;93:307-314

Ercoli A, Delmas V, Gadonneix P, Fanfani F, Villet R, Paparella P, Mancuso S, Scambia. Classical and nerve-sparing radical hysterectomy: an evaluation of the risk of injury to the autonomous pelvic nerves. *Surg Radiol Anat* 2003;25:200-206

Trimbos JB, Mass CP, DeRuiter MC, Peters AAW, Kenter GG. A nerve-sparing radical hysterectomy; Guidelines and feasibility in Western patients. *Int J Gynecol Cancer* 2001;11:180-186

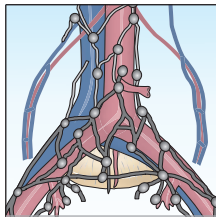
Havenga K, Maas CP, DeRuiter MC, Welvaart K, Trimbos JB. Avoiding long-term disturbance to bladder and sexual dysfunction in pelvic surgery, particularly with rectal cancer. *Seminars in Surg Onc* 2000;18:235-243

Hockel M, Konerding MA, Heubel CP. Liposuction-assisted nerve-sparing extended radical hysterectomy: oncologic rationale, surgical anatomy, and feasibility study. *Am J Obstet Gynecol* 1988;178:971-976

Hockel M, Horn L-C, Hentschel B, Hockel S, Naumann G. Total mesometrial resection: High resolution nerve-sparing radical hysterectomy based on developmentally defined surgical anatomy. *Int J Gynecol Cancer* 2003;13:791-803



# LAPAROSCOPIC LYMPHADENECTOMY IN GYNECOLOGIC ONCOLOGY



***Farr Nezhat, M.D.***  
***Tanja Pejovic, M.D.***

**I**n patients with gynecologic cancer, prognosis correlates with the extent of the disease according to the established FIGO classification systems. Surgical staging is superior because it provides histologic verification of tumor extent. Lymph node status is the most important prognostic factor in gynecologic cancer and surgical removal of pelvic and/or para-aortic lymph nodes for histologic assessment is a part of staging of gynecologic malignancies. Additionally, removal of bulky lymph nodes may have therapeutic benefit.

Lymphadenectomy has generally been performed via laparotomy, leading to large incisions and significant intra- and perioperative morbidity. Dargent and Salvat were the first to describe laparoscopic lymphadenectomy for the management of gynecologic malignancies in 1989. In 1991, Querleu et al. reported transperitoneal pelvic lymphadenectomy in 39 patients with cervical cancer. First laparoscopic para-aortic lymphadenectomy was reported by Nezhat et al. in 1991-1993 in a series of patients with cervical cancer undergoing laparoscopic radical hysterectomy and pelvic and para-aortic lymphadenectomy. Since that time a number of other reports have described the safety and accuracy of

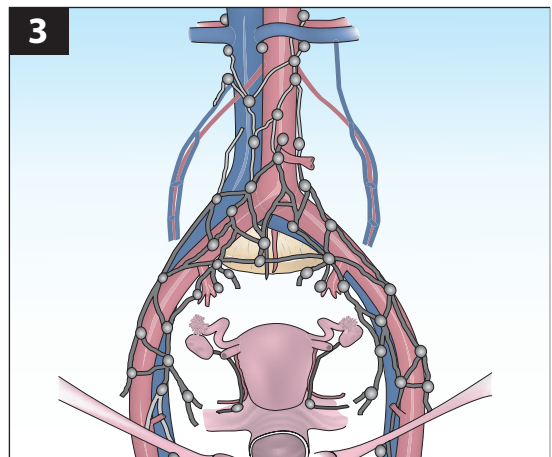
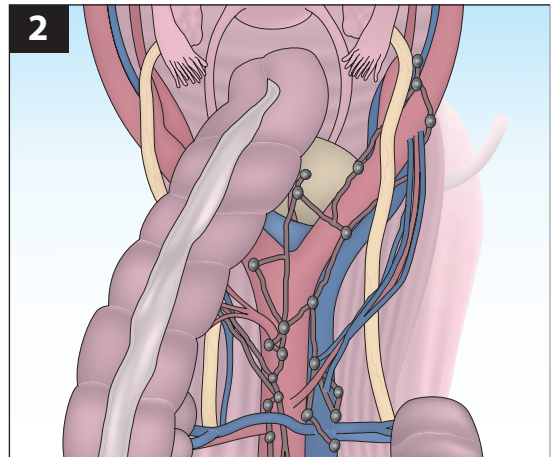
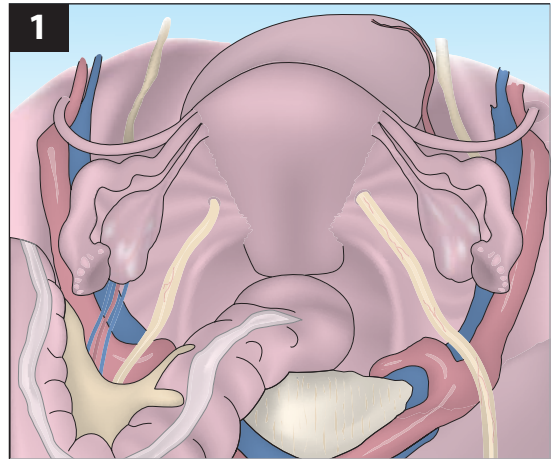
laparoscopic lymphadenectomy for cervical, endometrial, and ovarian cancer. Numerous reports describe better magnification, fewer complications, and superior visualization of the anatomy provided by the video laparoscope in comparison with conventional techniques (Figures 1-3).

PLACING THE PATIENT IN STEEP TRENDLENBURG POSITION DISPLACES THE BOWEL CEPHALAD AND EXPOSES THE AREA OF THE PERITONEUM WHERE THE INCISION IS MADE FOR LYMPH NODE RETRIEVAL.

## PELVIC LYMPHADENECTOMY

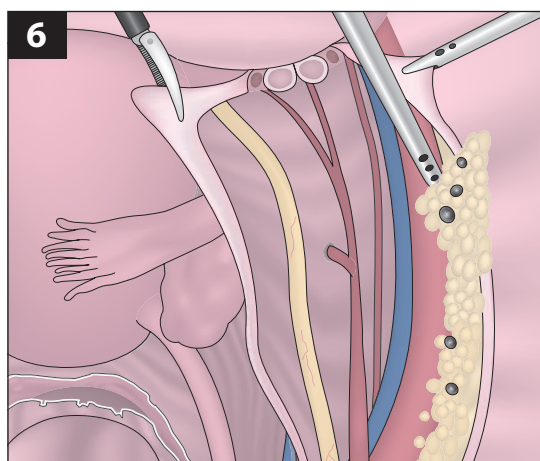
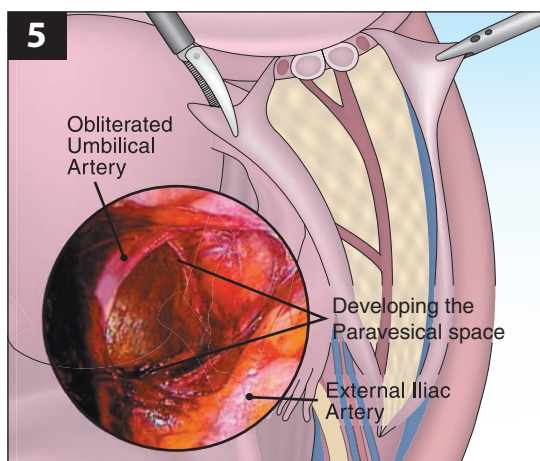
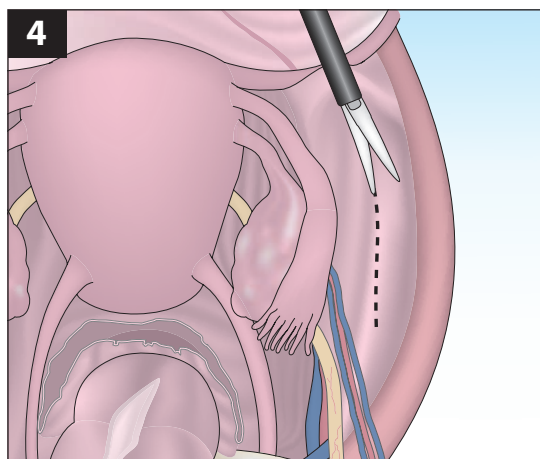
Pelvic and para-aortic lymphadenectomy is accomplished before or after hysterectomy and bilateral oophorectomy. The initial approach to pelvic lymphadenectomy is to expose the anterior and posterior leaves of the broad ligament by incising the round ligament and cutting the broad ligament in a cephalad fashion lateral and parallel to the infundibulopelvic ligament (Figure 4).

An incision is made in the broad ligament lateral or parallel to the infundibulopelvic ligament to develop the paravesical space. Using the suction-irrigation probe, grasper and scissors, paravesical space is created. It is bordered medially by the obliterated hypogastric artery, bladder and vagina and laterally by the pelvic sidewall. Creating the avascular paravesical space helps identify the



obturator nerve and vessels, and pelvic vessels. The obliterated hypogastric artery and external iliac vein are landmarks to get to the paravesical space (Figure 5). The spaces lateral to this vessel and medial to the external iliac vein and obturator internus muscle are created with blunt and sharp dissection. Electrocoagulation should not be necessary as this space is generally avascular. Once this space is created, the bony lateral sidewall, the levator plate laterally, and the obturator nerve and vessels anteriorly should be visible. The pelvic lymph nodes can now be safely removed. Starting laterally over the psoas muscle and proceeding medially provide a safe approach that avoids the genitofemoral nerve. The external iliac nodes along the external iliac artery and vein are excised caudally from common iliac vessels to the level of the deep circumflex iliac vein seen crossing over the distal portion of the external iliac artery (Figure 6).

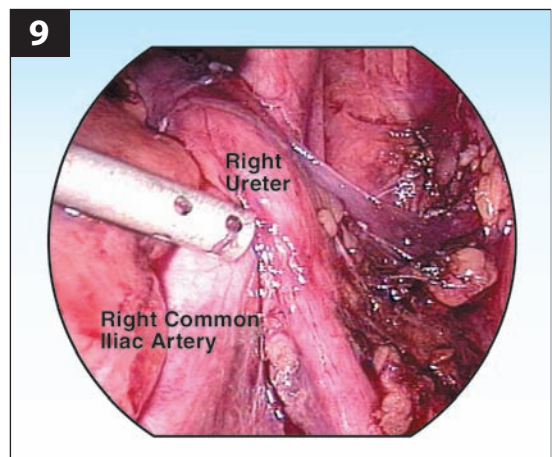
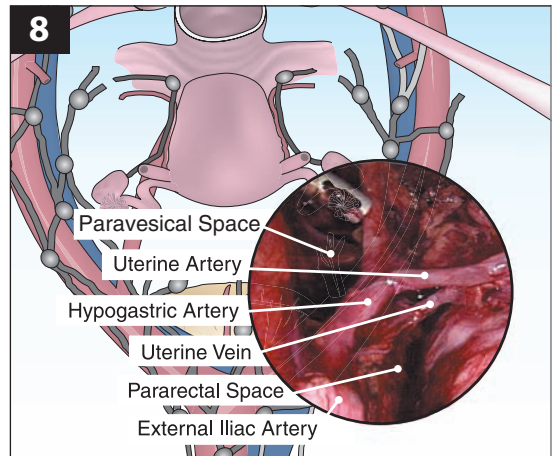
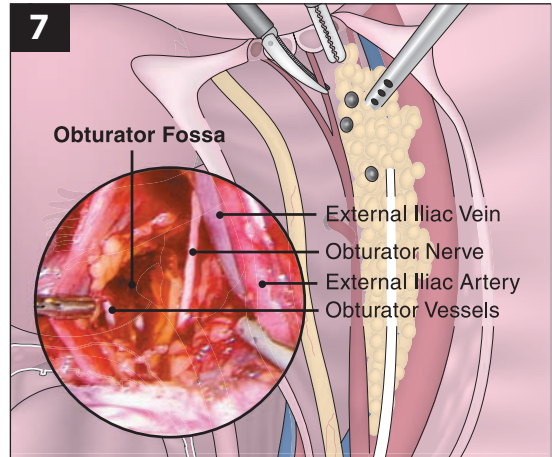
The obturator nerve is identified by blunt dissection below and between the obliterated umbilical artery and the external iliac vein. Of note is that although the obturator vessels are usually posterior to the nerve, sometimes an aberrant obturator vein may enter the midpoint of the external iliac vein and is anterior to the



THE NODES ALONG THE EXTERNAL ILLIAC ARTERY AND VEIN ARE REMOVED TO THE LEVEL OF THE DEEP CIRCUMFLEX VEIN.

nerve (Figure 7). The nodal tissue anterior and lateral to the nerve and medial and inferior to the external iliac vein is removed by blunt and sharp dissection. Venous anastomosis between the obturator and the external iliac veins are saved from injury. The obturator fossa lymph nodes are excised caudally to the pelvic sidewall where the obturator nerve exits the pelvis through the obturator canal and cephalad up to the bifurcation of the common iliac artery. Before the removal of each nodal bundle, each pedicle is ligated by electrocoagulation, endoscopic hemoclips, or Harmonic sheers to prevent lymph cyst formation. The lymph node packets are removed in a bag through the largest trocar to avoid any contact between potentially malignant lymph node tissue and the abdominal wall. Using sharp and blunt dissection, the nodes between the external iliac vessels and the obliterated hypogastric artery are removed. Hemoclips can be used as needed. The nodes along the hypogastric vessels are excised up to the bifurcation of the common iliac vessels as shown on the patient's left side (Figure 8). Caution is necessary to avoid injury to the obturator nerve and hypogastric vein.

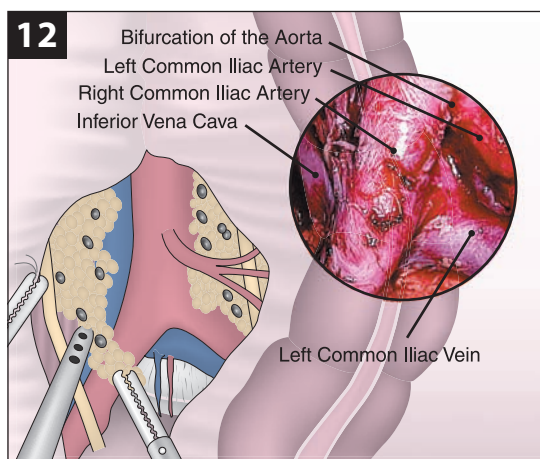
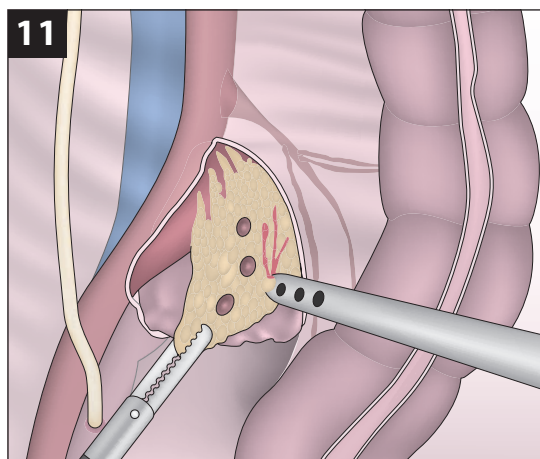
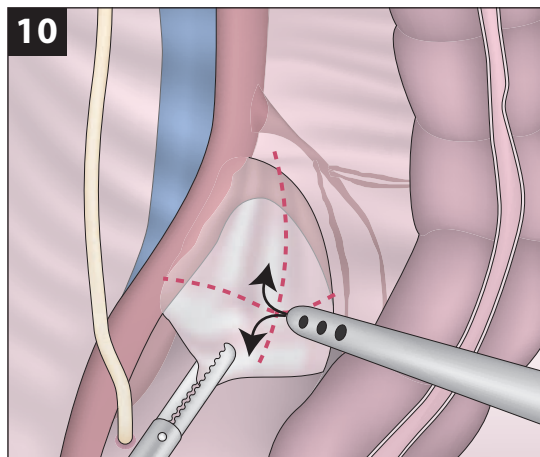
To excise the lymph nodes around the common iliac artery, a plane is created between the posterior peritoneum and the adventitia overlying the common iliac artery. Another option is to extend the dissection over the common iliac vessels when removing the proximal portion of the external iliac nodes. Before the nodes are detached, the orientation of the ureter and ovarian vessels crossing the



common iliac artery is identified (Figure 9). When one is performing a left pelvic lymph node dissection, it may be necessary to take down rectosigmoid colon from the left pelvic sidewall to allow visualization of the pelvic vessels.

## PARA-AORTIC LYMPHADENECTOMY

There are several ways to begin the dissection: incising the peritoneum overlying the aorta, opening the peritoneum over sacral promontory, and extending the incision overlying the common iliac artery toward the aorta. The peritoneum over the sacral promontory or lower aorta is incised. The underlying retroperitoneum is developed by blunt and sharp dissection (Figure 10). Next, the retroperitoneal space is created by using sharp and blunt dissection, to develop the space lateral to the aorta. Before cutting, it is essential to identify the ureter, separate it from underlying tissue, and retract it laterally. The nodal tissue overlying the aorta, right common iliac artery, and sacral promontory is removed laterally toward the psoas muscle. Fatty and nodal tissue overlying the sacral promontory are removed. This tissue may contain hypogastric nerves. The left common iliac vein must be observed before starting this dissection. This maneuver allows the nodal tissue anterior to the vena cava to be detached (Figure 11). The dissection is continued cephalad to the level of the inferior mesenteric artery, removing all lymphatic tissue anterior to and between the aorta and inferior vena cava (Figure 12). Again,



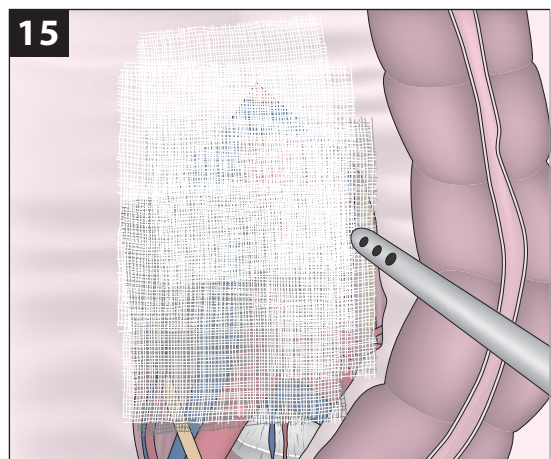
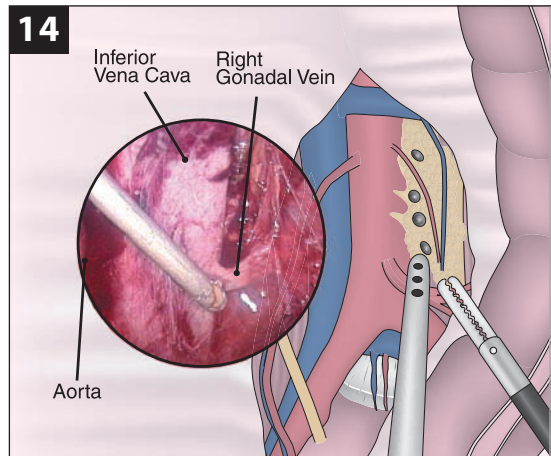
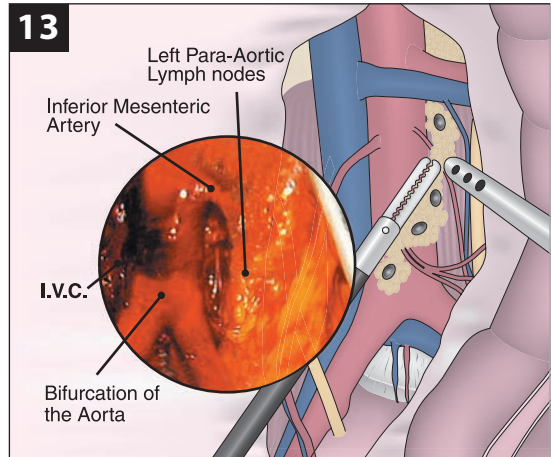


THE NODAL TISSUE ALONG VENA CAVA IS REMOVED ABOVE THE LEVEL OF THE INFERIOR MESENTERIC ARTERY. THE RIGHT URETER MUST BE SEEN AND CONSTANTLY RETRACTED LATERALLY.

it is essential to identify the ureter along the inferior border of the dissection and the transverse duodenum along the superior margin of the dissection. Perforating vessels from vena cava are electrocoagulated or ligated with hemoclips.

The removal of the left para-aortic nodes may be more difficult because of the location of the sigmoid colon. Attention is necessary to avoid injury to the inferior mesenteric artery, ovarian vessels, and the ureter. The left common iliac vein lies at the bifurcation of the aorta. The dissection proceeds from the aorta laterally toward the psoas muscle, excising the lymph nodes from above the inferior mesenteric artery to below the left common iliac artery (Figure 13). This allows the surgeon to dissect laterally in a plane that is beneath the inferior mesenteric artery and the mesentery of the sigmoid colon. It is important not to

THE LYMPH NODES ALONG THE LEFT SIDE OF THE AORTA ARE REMOVED FROM ABOVE THE INFERIOR MESENTERIC ARTERY TO BELOW THE LEFT COMMON ILIAC ARTERY.



IN PATIENTS WITH OVARIAN CANCER, THE PARA-AORTIC NODES ARE EXCISED TO THE LEVEL OF THE LEFT RENAL VEIN AND RIGHT OVARIAN VEIN.

dissect laterally until the adventitia of the aorta is incised to prevent entering the wrong plane.

When para-aortic lymphadenectomy above the mesenteric artery is being performed, the peritoneal incision is extended to the level of the left renal vein and right ovarian vein (Figure 14). The ovarian vessels and the mesenteric artery are ligated, if necessary, to have better exposure and to prevent bleeding. After the lymphadenectomy is completed, evaluation of the area under decreased pneumoperitoneal pressure is done to ensure hemostasis.

As with pelvic lymphadenectomy, the peritoneum is not closed and the drains are not placed. Intercedes or Surgiwrap can be applied to decrease postoperative adhesions (Figure 15).

Our experience and the published data in the literature suggest that the mean number of pelvic and para-aortic lymph nodes retrieved laparoscopically is similar to that of lymph nodes retrieved by laparotomy. One report addressed the fact that 25% of the pelvic lymph nodes were still present at laparotomy after laparoscopic lymphadenectomy; however, no patient with negative nodes at laparoscopy

had positive nodes at laparotomy. Along with this the objective that must be remembered is to remove the significant nodes, not the high number of nodes. The rarity of pelvic sidewall recurrences in node-negative patients managed without a complete lymphadenectomy indicates that laparoscopy may enable us to remove the significant nodes even when the total number of nodes removed is low. If the requirement of clearly identifying the dorsal part of the obturator nerve and lumbosacral nerve is fulfilled, the risk of missing a positive pelvic lymph node is very low.

Despite the degree of caution used, complications do occur during laparoscopic lymphadenectomy. In a series by Passover et al. (1998) ten major vessel injuries were identified among 150 procedures. These included four vena cava, two right renal vein, two external iliac vein, one internal iliac artery, and one internal iliac vein injuries. A conversion to laparotomy was necessary in four cases. The mean hospital stay for patients undergoing laparoscopic lymphadenectomy was 3.2 days. In other studies, the length of hospital stay, and recovery time were significantly shorter for patients managed laparoscopically.

In summary, in properly selected patients, operated by an experienced gynecological oncologist, the laparoscopic pelvic and para-aortic lymphadenectomy provides adequate lymph nodes with acceptable complications rate giving the patients the benefits of laparoscopy.

## SUGGESTED READING:

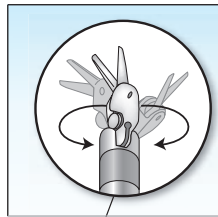
Nezhat CR, Burrell MO, Nezhat FR, Benigno BB, Welander CE. Laparoscopic radical hysterectomy with paraaortic and pelvic node dissection. *Am J Obstet Gynecol* 1992;166:864-865

Melendez TD, Childers JM. Laparoscopic lymphadenectomy. *Curr Opin Obstet Gynecol* 1995;7:307-310

Possover M, Krause N, Plaul K, Kuhne-Heid R, Schneider A. Laparoscopic para-aortic and pelvic lymphadenectomy: experience with 150 patients and review of the literature. *Gynecol Oncol* 1998;1:19-28

Dargent DF. Laparoscopic techniques for gynecologic cancer: description and indications. *Hematol Oncol Clin North Am* 1999;13:1-19

# ROBOTICS: THE CLINICAL NUTS AND BOLTS TO APPLICATIONS IN MINIMALLY INVASIVE GYNECOLOGIC SURGERY



*Arnold P. Advincula, M.D.*

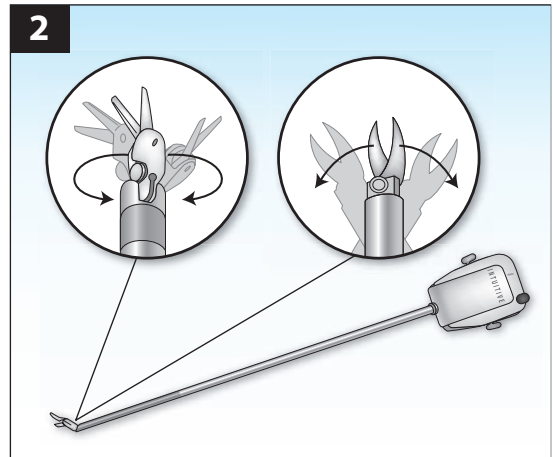
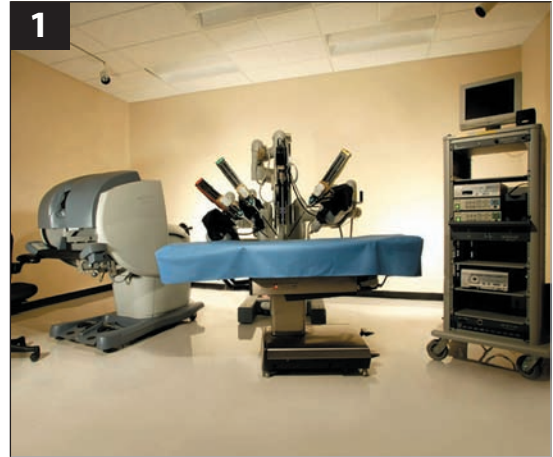## INTRODUCTION

**T**he role of robotics in minimally invasive gynecologic surgery can best be summed up with one word - evolution. The application of endoscopic techniques to the practice of gynecologic surgery has come a long way from Boesch's early descriptions of the first gynecologic use of laparoscopy for tubal sterilization in the 1930's. Improvements in endoscopic instrumentation have provided modern day gynecologists with high intensity xenon and halogen light sources, multi-chip cameras, and advanced electrosurgical technology. On the other hand, there remain many limitations. Current conventional laparoscopic instrumentation still has a limited degree of motion within the body that must be balanced by overcoming the inherent fulcrum effect that results in counter-intuitive hand movements. Additionally, the view of the operative field is two-dimensional. Altogether, these limitations continue to result in significant learning curves for advanced endoscopic cases. In an attempt to overcome these obstacles, robotics may represent the next frontier in the evolution of gynecologic endoscopy.

Historically, there have been many examples of the application of robotics to gynecologic surgery. The first involved the use of a voice-controlled robotic arm known as AESOP® (Computer Motion Inc.®, Goleta, CA) which held the laparoscope. Early pioneers were able to demonstrate improved surgical efficiency by returning two operating hands to the surgeons. Soon thereafter the Zeus® surgical system (Computer Motion Inc.®, Goleta, CA) came into clinical use and incorporated not only a robotic laparoscope holder but also two additional robotic operating arms. Although not perfect, surgeons were able to gain improved vision and instrumentation. Preliminary experience with tubal reanastomosis seemed promising. Today only one FDA approved robotic platform exists and that is the daVinci surgical system (Intuitive Surgical®, Sunnyvale, CA). This chapter will focus specifically on this system and its current applications in gynecologic surgery.

## DAVINCI® SURGICAL SYSTEM

The daVinci® surgical system is comprised of three components (Figure 1). The first component is the surgeon console where the surgeon controls the robotic system remotely. A stereoscopic viewer as well as hand and foot controls are housed in this unit. The second component of the daVinci® surgical system is the InSite® vision system which provides three dimensional (3-D) imaging through a 12 mm endoscope. The third component of the daVinci® surgical system is



the patient-side cart with either three or four telerobotic arms and Endowrist® instruments. One of the arms holds the laparoscope while the other two to three arms hold the various laparoscopic surgical instruments such as a bipolar Maryland forceps and round-tip scissors. Although the Endowrist® instruments lack any type of haptic (tactile) feedback, they are unique in that they possess seven degrees of freedom which replicate the full range of motion of the surgeon's hand. These seven degrees of freedom

are 1) in and out movement, 2) axial rotation, 3) opening and closing of instrument, 4) lateral movement at the articulation, 5) vertical movement at the articulation, 6) right movement at each articulation, and 7) left movement at each articulation. As a result of this flexibility, the fulcrum effect seen with conventional laparoscopy is eliminated (Figure 2). Overall, the design and make-up of the daVinci® surgical system have resulted in a paradigm shift for the surgeon who now operates remotely without haptic feedback but gains 3-D visualization with improved instrumentation.

## CREDENTIALING & PRIVILEGING

Prior to the actual clinical application of robotic technology in the surgical arena, there are a few key concepts to keep in mind. The first of these is the fact that surgeons must obtain appropriate credentialing and privileging in their respective institutions. A successful formula involves system certification through an Intuitive Surgical sponsored program as required by the FDA, case observation, and proctored cases, the number of which is determined by each individual institution. In addition, minimizing the interval between training and the performance of the first case as well as incorporating a team approach all help to ensure a successful start to a robotics program.

A “crawl, walk, then run” mentality should be incorporated with early case selection. In other words, start with simple cases that are known inside and out,

backwards and forwards both open and endoscopically. Remember that the incorporation of robotics into a surgical practice is not only a paradigm shift for the surgeons but also the entire operating room team. Build on early successes to fuel confidence. Finally, never underestimate the importance of the bedside assistant. The role of the bedside assistant is extremely critical since the console surgeon is situated remotely from the patient. Active uterine manipulation, the passage of suture, suction/irrigation, and traction/counter-traction are all facilitated by the bedside assistant.

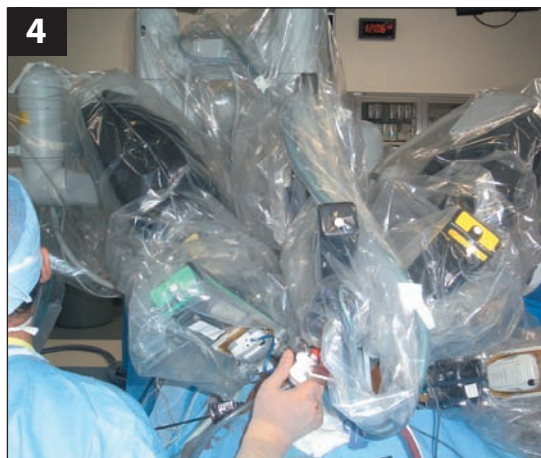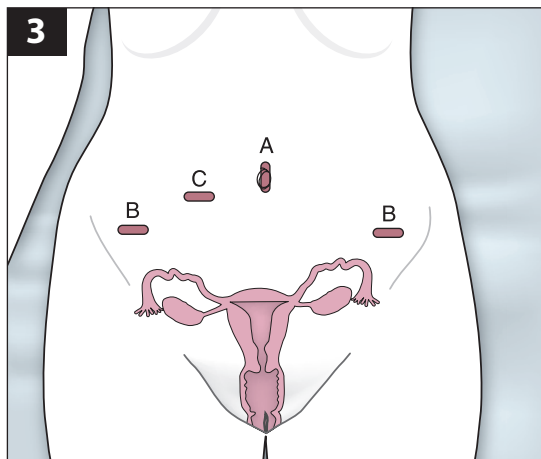
## SET-UP

The operating room layout is very important. Floor dimensions must be large enough to accommodate the footprint of the daVinci® surgical system without compromising patient care or the flow of operating room personnel throughout the room. In order to properly determine the layout of a room, the system cable connections and their lengths must be considered along with the physical dimensions of the surgical system components. Additionally, the following generators are currently approved for use with the daVinci® surgical system: ValleyLab Force 2, Force FX, and ERBE Model ICC 350.

Patient positioning is also very important. The patient is placed in low dorsal lithotomy with arms padded and tucked at her sides after general endotracheal anesthesia is administered. Anti-skid measures should be employed so as to

prevent patient movement during steep Trendelenburg. The bladder is typically drained with a Foley catheter and a uterine manipulator is placed.

Four or five trocars are typically utilized after pneumoperitoneum is obtained. A 12 mm trocar is placed either at or above the umbilicus depending on the size of the uterus. This trocar accommodates the endoscope that provides 3-D vision. Occasionally, a left upper quadrant entry with a 3 mm or 5 mm laparoscope is performed in order to help guide operative trocar placement in patients with a markedly enlarged uterus or who are at increased risk for pelvic adhesions such as those who have undergone prior abdominal surgery. Figure 3 represents trocar placement for a three-armed robotic system. Two 8 mm trocars, which mount directly to the surgical cart's two operating arms, are placed in the left and right lower quadrants, respectively. This location is typically medial to the anterior superior iliac spine, 3 cm on a diagonal line to the umbilicus. In cases where leiomyomata or pathology are above the pelvic brim, lateral trocar placement is moved cephalad in order to allow adequate working distance between the superior-most border of the enlarged uterus or mass and the port site. A fourth trocar which serves as an accessory port is placed between the camera port and either the right or left lower quadrant port depending on the location of the bedside assistant. This is typically 10-15 mm in order to facilitate introduction of suture, a tissue morcellator, and suction/irrigation instruments.

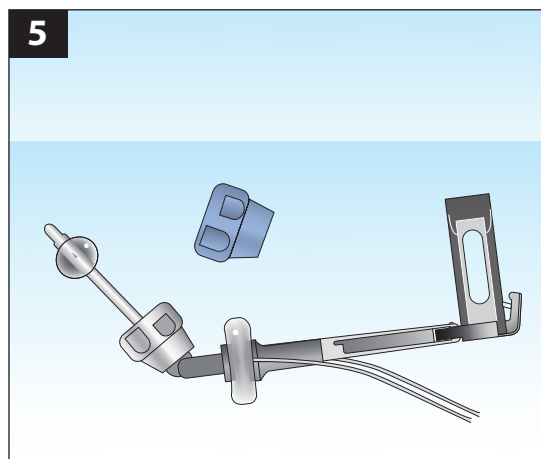


Once all four trocars are in place, the patient is placed in steep Trendelenburg and the surgical cart with three robotic arms is brought between the patient's legs and docked, meaning that each trocar is attached to the assigned robotic arm with the exception of the accessory port which is managed by the bedside assistant. The camera arm is attached to the umbilical or supraumbilical trocar. The right and left operating arms are attached directly to the right and left lower quadrant trocars, respectively (Figure 4).

The use of robotics in gynecology has continued to increase over the past five years, particularly as of April 2005 when the daVinci® surgical system gained FDA clearance for its use in gynecologic laparoscopic procedures. This was a major regulatory milestone that extended beyond the original FDA clearance for general laparoscopic use in July 2000. In numerous studies across various disciplines, the daVinci® surgical system has been shown to be a safe and effective alternative to conventional laparoscopic surgery, particularly when dealing with complex pathology. In the area of gynecology, there are reports of robot-assisted laparoscopy for procedures such as tubal reanastomosis, ovarian transposition, hysterectomy, and the repair of vaginal vault prolapse where improved dexterity and precision coupled with advanced imaging is a huge advantage to the surgeon. A great example of both a complex and suture-based gynecologic procedure that may benefit from robotic assistance is myomectomy.

## ROBOTIC (DAVINCI) MYOMECTOMY

Although today many cases of intramural and subserous fibroids are managed with laparoscopic myomectomy as a result of improvements in technology, the ability to enucleate leiomyomata and repair the uterus with a multi-layer sutured closure is crucial and technically challenging when done laparoscopically. Despite having a skilled surgeon, the surgical limitations that exist with conven-



tional laparoscopy are thought to affect conversion rates to laparotomy and may play a role in cases of uterine rupture. In the end, myomectomy still represents a procedure performed predominantly by laparotomy. As a result, robotic platforms such as the daVinci® surgical system may serve as an enabling technology that translates into more myomectomies being done in a minimally invasive fashion. Advincula et al. described a practical approach to robotic myomectomy.

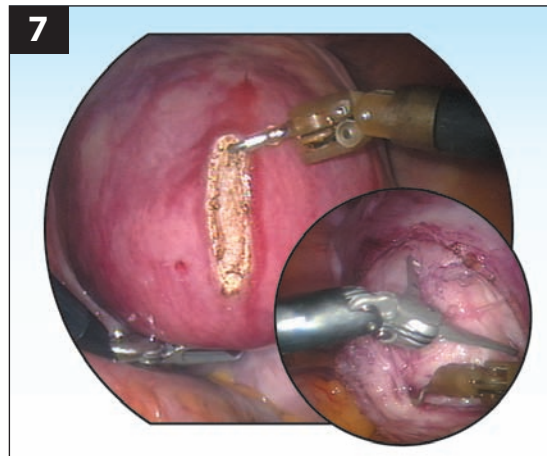
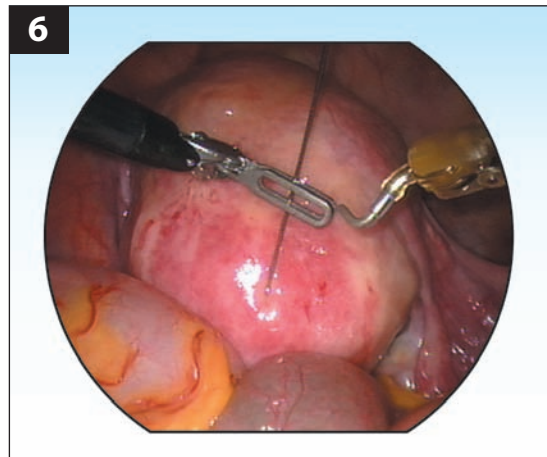
## TECHNICAL PEARLS

All patients are placed in low dorsal lithotomy position with arms padded and tucked at their sides after general endotracheal anesthesia is administered. The stomach is evacuated with a nasogastric tube. The bladder is drained with a Foley catheter and a uterine manipulator (surgeon preference) is placed (Figure 5). The following description of the surgical approach is based on a three-armed robotic system. Four trocars are typically utilized after pneumoperitoneum is



obtained. A 12 mm trocar is placed either at or above the umbilicus depending on the size of the pathology. Occasionally a left upper quadrant entry with a 3 mm or 5 mm laparoscope is performed in order to help guide operative trocar placement. Two 8 mm trocars, which mount directly to the surgical cart's two operating arms, are placed in the left and right lower quadrants, respectively. Again, more cephalad placement is required with larger pathology. A fourth trocar which serves as an accessory port is placed between the camera port and either the right or left lower quadrant port depending on the location of the bedside assistant. This is typically 10-15 mm in order to facilitate introduction of suture, a tissue morcellator, and suction/irrigation instruments.

Once all four trocars are in place, the patient is placed in steep Trendelenburg and docking of the patient-side cart takes place. A survey of the operative field is performed, after which a dilute concentration of vasopressin, a vasoconstrictive agent, is infiltrated via a 7 inch, 22 gauge spinal needle transabdominally into the myometrium surrounding the fibroid as an adjunct for hemostasis (Figure 6). Heavy grasping instruments such as a Cadiere® (fenestrated forceps), Tenaculum® or CobraGrasper® and a permanent cautery hook or spatula, all Endowrist® instruments, are attached to the right and left operating arms and used to incise the serosa as well as enucleate the leiomyomata (Figure 7). Counter-traction is provided by the bedside assistant through the accessory port with a myoma grasper or cork screw.

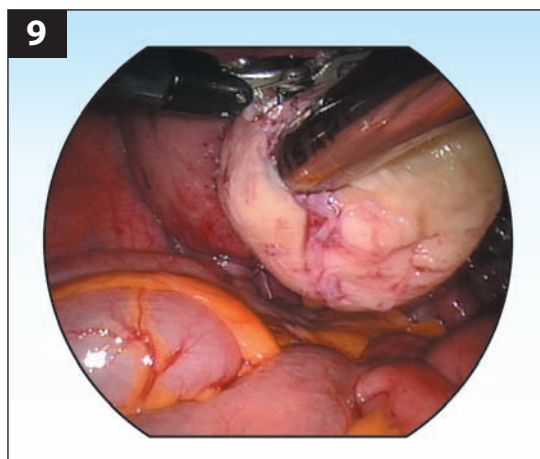
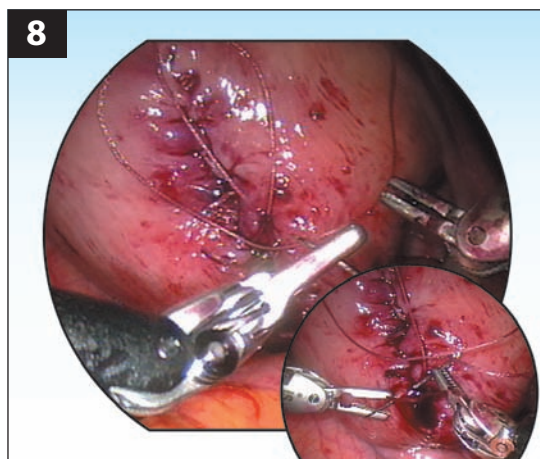


Adequate hemostasis is obtained with the combination of the vasopressin administered at the onset of the case, pneumoperitoneum, and judicious use of electro-surgical current. Once the myoma(s) are successfully enucleated, attention is directed towards closure of the myomec-tomy resection bed(s). Endowrist® instruments are changed over to a Debaquey forcep and needle driver or two needle drivers. A three-layer closure modeled after traditional open surgical technique is utilized. Interrupted sutures of 0-Vicryl™ on

CT-2 needles cut to 6 inches in addition to a 3-0-Vicryl™ on a SH needle cut to 11 inches (serosal running baseball closure) are used to complete this portion of the procedure in an intracorporeal fashion (Figure 8). Once the uterine defect(s) are repaired, a tissue morcellator is used to extract the specimen(s) (Figure 9). A low pressure check is performed to ensure hemostasis. Once hemostasis is confirmed, the robot-assist device is undocked. An adhesion barrier can be placed over the uterine incision(s) as an adhesion prophylaxis measure prior to the conclusion of the case. Trocar sites are closed accordingly.

## **ROBOTIC (DAVINCI) HYSTERECTOMY FOR BENIGN & MALIGNANT DISEASE**

Approximately 600,000 hysterectomies are performed annually in the United States with the majority due to benign conditions. In the late 1980s and early 1990s, trends toward laparoscopic-assisted vaginal hysterectomy and total laparoscopic hysterectomy began to occur as improvements in conventional laparoscopy developed. This trend has also affected the way that gynecologic cancers are treated and allowed laparoscopic approaches for many gynecologic surgical procedures for cancer. Despite the increasing acceptance of laparoscopy for the treatment of both benign and malignant disease, hysterectomy via laparotomy remains the most common route. Two reasons often cited are the



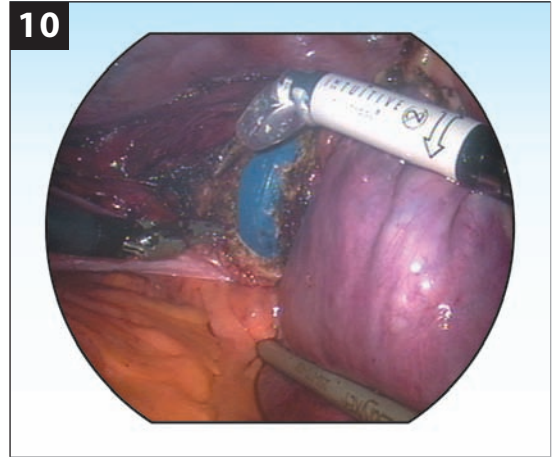
technical limitations of conventional laparoscopic instruments and the condition of the surgical field. Additionally, the surgeon's skill level and the lengthy learning curve to attain laparoscopic competence for advanced procedures have been known to affect the ability to complete a hysterectomy by minimally invasive means. Robotics may help overcome many of these limitations and bridge the gap between novice and expert surgeons which in the end may allow for more hysterectomies to be completed in a

minimally invasive fashion. Several studies currently exist that document the feasibility of this approach.

### TECHNICAL PEARLS

The description of the following technique is based on a three-armed daVinci® surgical system and can be applied to both benign and malignant disease. All patients are positioned in the same fashion as that described with a robotic myomectomy after general anesthesia is administered. The bladder and stomach are decompressed accordingly. For patients with an intact uterus, a uterine manipulator is placed in conjunction with a Koh® colpotomy ring and vaginal pneumo-occluder balloon (all Cooper Surgical®, Trumbull, CT) (Figure 5). For patients with an absent uterus, a sponge stick is placed in the vagina for delineation of the vaginal cuff. Four ports are typically utilized and placed in a fashion similar to that described with a robotic myomectomy after pneumoperitoneum is obtained. A larger uterus or the need for para-aortic lymphadenectomy may require a more cephalad or supra-umbilical placement of the trocars.

The patient is then placed in steep Trendelenburg and the patient-side cart is brought between the patient's legs and docked. Pelvic washings are obtained prior to the onset of any operative intervention for known or suspected malignancy. Typical Endowrist® instruments utilized during a robotic hysterectomy are bipolar Maryland® forceps, DeBakey forceps, needle driver, and monopolar Hot



Shears®. Either 0-Vicryl™ on CT-2 needles or free ties of 0-Vicryl™, cut 4-6 inches can be utilized during the case.

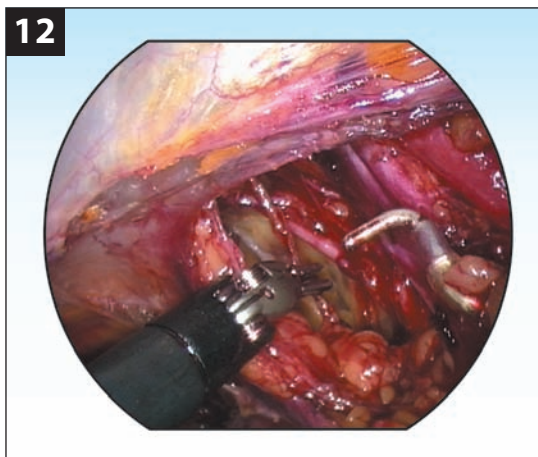
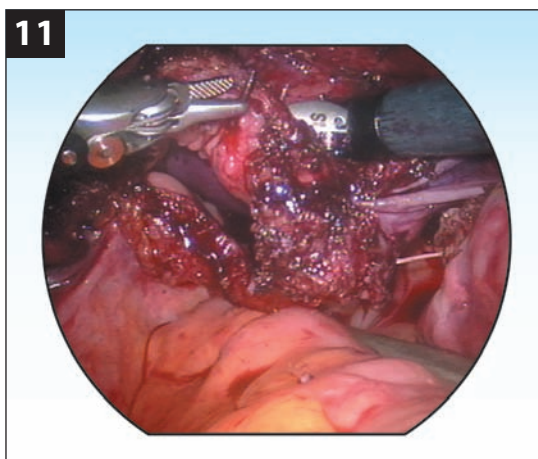
The approach to hysterectomy is carried out in a fashion analogous to open surgical technique and consistent with either a type IVE or LSH III laparoscopic hysterectomy based on the American Association of Gynecologic Laparoscopists' classification system. All vascular pedicles including the infundibulopelvic ligament and the uterine artery pedicles are skeletonized and subsequently either suture ligated or coagulated with radiofrequency current prior to transection. In cases where a total laparoscopic hysterectomy is intended, the monopolar Hot Shears® are utilized to create the anterior/posterior culdotomy and divide the cardinal and uterosacral ligament complex bilaterally with the aide of the Koh colpotomy ring while upward uterine traction is provided by the bedside assistant, thereby improving visualization of the colpotomizer and displacing the ureters laterally (Figure 10). Pneumoperitoneum is maintained by infla-

tion of the vaginal pneumo-occluder balloon. Once the uterus and cervix are completely detached, the specimen with or without adnexae is delivered into the vagina. The uterine fundus or vaginal pneumo-occluder balloon can then be used to maintain pneumoperitoneum during the closure of the vaginal cuff. This is accomplished with either interrupted or running suture in an intracorporeal fashion (Figure 11). Once the vaginal cuff is closed, a low pressure check is performed to ensure hemostasis and the robot-assist device is undocked.

In cases where laparoscopic subtotal hysterectomy is intended, the monopolar Hot Shears® are used to amputate the uterine corpus below the internal os. The cervical stump can be closed or left open depending on the surgeon preference. A tissue morcellator is used to extract the uterine corpus through the accessory port.

During cases where an oncologic staging is required, the retroperitoneum is opened. Once the pelvic vessels and ureters are identified, lymph nodes are isolated and removed. During this process, care is taken to identify the obturator nerve, which is stripped free of its attachment to the lymphatic tissues (Figure 12). Common iliac and para-aortic nodes up to the level of the inferior mesenteric artery can be obtained by extending the peritoneal incision above the pelvic brim.

Attaining high para-aortic nodes above the inferior mesenteric artery is difficult without either re-docking the patient-side cart in an over the patient's head and shoulders orientation or plac-



ing trocars at the onset of the case in a more cephalad or supra-umbilical location. Alternatively, the robot can be undocked in exchange for a conventional laparoscopic approach.

#### OTHER ROBOTIC APPLICATIONS IN MINIMALLY INVASIVE GYNECOLOGIC SURGERY

Although the majority of the literature surrounding robotics in gynecology is in the area of hysterectomy, there are also

reports of its use with tubal reanastomosis, sacrocolpopexy, and ovarian transposition. A theme common to these newer applications is the strong emphasis on suture-based procedures.

Overall, the application of robotics to gynecologic minimally invasive surgery may serve three purposes. The first is the ability to allow surgeons to adhere very closely to the principles of open surgical technique. Secondly, it may allow for conversion of cases traditionally done by

laparotomy to laparoscopy. Third, robotics can be looked upon as enabling technology that may shorten learning curves for advanced laparoscopic procedures.

If one looks into the future, robotics may also serve a fourth purpose and that is to allow gynecologic surgeons to perform procedures never thought feasible by standard laparotomy techniques. The concept certainly challenges conventional thinking but makes for an exciting future in gynecologic minimally invasive surgery.

## SUGGESTED READING:

Mettler L, Ibrahim M, Jonat W. One year of experience working with the aid of a robotic assistant (the voice-controlled optic holder AESOP) in gynecologic endoscopic surgery. *Hum Reprod* 1998;13:2748-50

Falcone T, Goldberg JM, Margossian H, Stevens L. Robotically assisted laparoscopic microsurgical anastomosis: a human pilot study. *Fertil Steril* 2000; 73:1040-1042

Degueldre M, Vandromme J, Huong PT, Cadiere GB. Robotically-assisted laparoscopic microsurgical tubal reanastomosis: a feasibility study. *Fertil Steril* 2000; 74: 1020-1023

Molpus KL, Wedergren JS, Carlson MA. Robotically-assisted endoscopic ovarian transposition. *JLS* 2003;7:59-62

Diaz-Arrastia C, Jurnalov C, Gomez G, Townsend C. Laparoscopic hysterectomy using a computer-enhanced surgical robot. *Surg Endosc* 2002; 16: 1271-1273

Marchal F, Rauch P, Vandromme J, et al. Telerobotic-assisted laparoscopic hysterectomy for benign and oncologic pathologies: initial clinical experience with 30 patients. *Surg Endosc* 2005; 19:826-831

Beste TM, Nelson KH, Daucher JA. Total laparoscopic hysterectomy utilizing a robotic surgical system. *JLS* 2005; 9:13-15

Advincula AP, Reynolds RK. The use of robot-assisted laparoscopic hysterectomy in the patient with a scarred or obliterated anterior cul de sac. *JLS* 2005; 9:287-291

Fiorentino RP, Zepeda M, Goldstein BH, John CR, Rettenmaier MA. Pilot study assessing robotic laparoscopic hysterectomy and patient outcomes. *JMIG* 2006; 13:60-63

Dimarco DS, Chow GK, Gettman MT, Elliott DS. Robotic-assisted laparoscopic sacrocolpexy for treatment of vaginal vault prolapse. *Urology* 2004; 63:373-376

Advincula AP, Song A, Burke W, Reynolds RK. Preliminary experience with robot-assisted laparoscopic myomectomy. *J Am Assoc Gynecol Laparosc* 2004;11(4):511-518

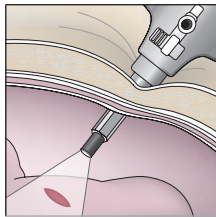
Reynolds RK, Burke WM, Advincula AP. Preliminary experience with robot-assisted laparoscopic staging of gynecologic malignancies. *JLS* 2005; 9:149-158

Olive DL, Parker WH, Cooper JM, Levine RL. The AAGL classification system for laparoscopic hysterectomy. *J Am Assoc Gynecol Laparosc* 2000; 7: 9-15

Sarle R, Tewari A, Shrivastava A, Peabody J, Menon M. Surgical robotics and laparoscopic training drills. *J Endouro* 2004; 18: 63-67



# COMPLICATIONS OF LAPAROSCOPY



**Barbara Levy, M.D.**  
**Michael Traynor, M.D.**

**C**omplications are inherent with any surgical endeavor, whether the procedure is performed by laparotomy or laparoscopy. Often patients pursue laparoscopic surgery in the misguided view that it is not really surgery and that it carries a lower risk of adverse events than ‘open’ surgery. It should be emphasized that minimally invasive surgery does not mean minimal risk.

Complications of laparoscopic surgery are inevitable. The literature addressing laparoscopic complications is extensive but can be highly variable, depending upon (amongst other things) the complication(s) being addressed, the surgical specialty involved, the type of study examining the issue, and the specific procedure(s) under review.

Keeping with the theme of this book, the purpose of this chapter is not to dwell on any particular type of complication or specific issue. Instead, the following pages will attempt to give a brief overview of laparoscopic complications and “how to” prevent them.

In addition, we will offer some insight into those circumstances in which complications are more likely to occur and how to recognize as well as manage them should they occur.



## PREVENTION OF COMPLICATIONS

The most paramount consideration for a laparoscopic surgeon with regard to complications is how to prevent them from occurring. Specific issues will be subsequently addressed, but it is also important to take a step back and look at prevention in terms of preoperative, intraoperative, and postoperative considerations.

While some complications are unavoidable and may stem from circumstances that are beyond the surgeon's control, most complications can be avoided if the physician has in place a structured routine that actively checks and double checks particular issues and concerns that may contribute to or develop into complications.

## PREOPERATIVE PREVENTION OF COMPLICATIONS

### HISTORY AND PHYSICAL

Important issues should be addressed before heading to the OR. Key items to consider are any prior abdominal or pelvic surgeries, the patient's body habitus, prior medical conditions that may affect pelvic anatomy such as PID, peritonitis, or endometriosis. Pelvic pathologica, large or immobile uterus, fibroids, and adnexal masses must also be carefully considered before the day of surgery. Prior operative reports may offer critical insight and information that could affect multiple aspects of the proposed procedure.

## LAPAROSCOPIC COMPLICATIONS

POSITIONAL  
EQUIPMENT  
INSUFFLATION  
TROCAR PLACEMENT  
ELECTRICAL ENERGY  
VASCULAR INJURY  
BOWEL INJURY  
GENITOURINARY  
WOUND HERNIA

## COUNSELING AND CONSENT

A decision whether or not to proceed to the OR is the first way to avoid unnecessary complications, and this decision must be made in conjunction with the understanding and consent of the patient. The procedure in detail, the risks, benefits, and alternatives, including doing nothing, must be reviewed. An unnecessary or questionably indicated surgery potentially exposes the patient to avoidable risks. If the surgery is indicated, what is the best operative approach, i.e. laparotomy vs laparoscopy. A patient's initial understanding and expectations of a laparoscopic approach may be unrealistic and their tolerance for complications quite low. This must be addressed before proceeding to the OR.

## SURGICAL INSTRUMENTATION AND OPERATING ROOM PREPARATION

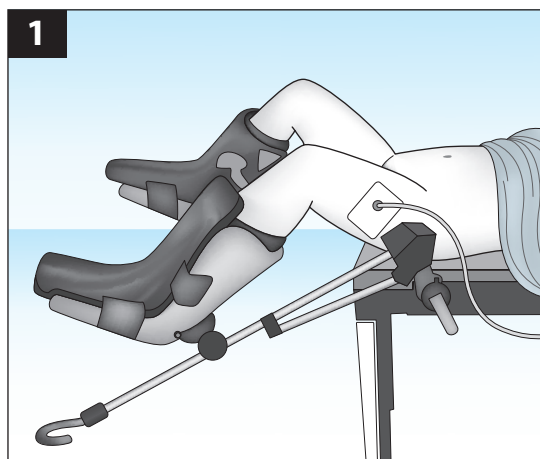
The availability of specific instrumentation may vary from hospital to hospital,

### INCIDENCE OF LAPAROSCOPIC COMPLICATIONS

VASCULAR	1.2%
URINARY TRACT	2.7%
BLADDER	1.5%
URETER	1.2%
BOWEL	0.4%

equipment may be disposable or reusable, and a variety of electrosurgical devices may be employed. Particular caution should be exercised with the use of monopolar cautery as it carries the highest risk of complications. The surgeon must be familiar and knowledgeable with all of the equipment being used and should be ready to employ a back up or alternative device if necessary. With that said, patient safety should never be compromised if equipment is not available.

The OR room should be fluid and efficient so as to avoid delays which may prolong the patient's anesthesia time. Monitors and cameras should be checked prior to the start of the surgery. If there is the possibility that additional equipment or instrumentation may be necessary, be sure to have it in the room available. While the surgeon is ultimately in charge of the surgery, a team approach with an understanding of the procedure and communication between the various members (circulator, scrub tech, anesthesia) will not only help avoid unnecessary complications, but will also facilitate prompt and efficient action should something occur.



**ALWAYS CHECK PATIENT POSITIONING AND THE INSTRUMENTS BEFORE EACH PROCEDURE.**

### PATIENT POSITIONING

While not unique to laparoscopic surgery, nerve injuries are more common after long, difficult procedures. Nerve injuries represent one-third of all anesthesia-associated medico-legal claims in the US. Patient positioning is key to preventing many of these problems (Figure 1). Once anesthesia has been administered, the patient should be properly positioned by the surgeon. The goal is to provide best exposure and access while minimizing risk to patients. The presence of any neuropathic symptoms in the pre-operative (and early postoperative periods) should be documented. The judicious use of padding (cloth/towels, foam sponges, gel pads) may help to minimize

## POSITIONAL COMPLICATIONS

BRACHIAL PLEXUS ARM  
EXTENSION  $>90^\circ$

PERONEAL NERVE LATERAL PRESSURE

FEMORAL & SCIATIC NERVE  
COMPRESSION

SHOULDER BRACE

RETURN ELECTRODE POSITIONING

FOLEY CATHETER

risk of injury. Steep Trendelenburg position and hyperextension of the arm may cause brachial plexus traction and damage. The peroneal nerve on the outer side of the knee may be at risk when there is pressure between the knee and some fixed object. Femoral neuropathy may occur, particularly in very thin patients, when this large, relatively avascular nerve is stretched around the sciatic notch. This may happen when the hips and knees are flexed. Padding the sacrum and keeping the hips as flat as possible will help to avoid this problem.

## ABDOMINAL ENTRY

### ENTRY/TROCAR INSERTION

It is estimated that more than one-half of all complications related to laparoscopy are associated with the entry technique. As a result, successful entry essentially eliminates half the risk of all laparoscopic complications! The surgeon should have a pri-

mary technique (closed/Veress vs. open/Hasson), but should be familiar and comfortable with both types. While there have been reports of decreased incidence of vascular complications with the open/Hasson technique, other studies show that surgeon familiarity and proficiency is the most important factor with regard to safe entry. In addition, alternative entry sites such as left upper quadrant may be considered in cases involving morbid obesity, a large uterus, challenging umbilical entry, or prior abdominal or pelvic surgeries that may cause adhesions around the umbilical area. Proper trocar/port placement should be performed with the intent to optimize laparoscopic instrumentation. A detailed knowledge of both superficial and deep abdominal wall vessels is essential in safe trocar placement.

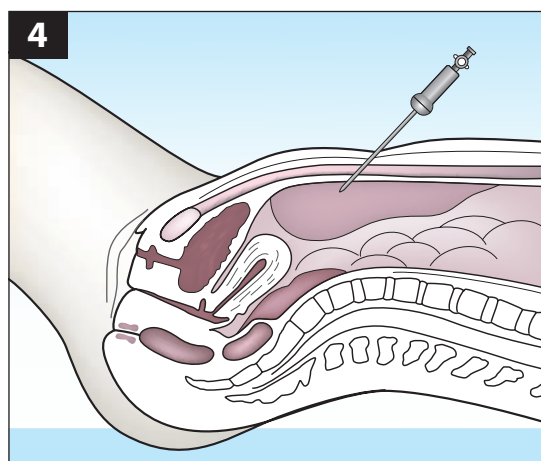
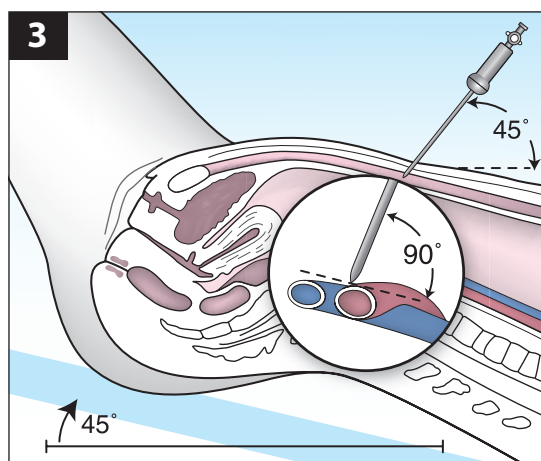
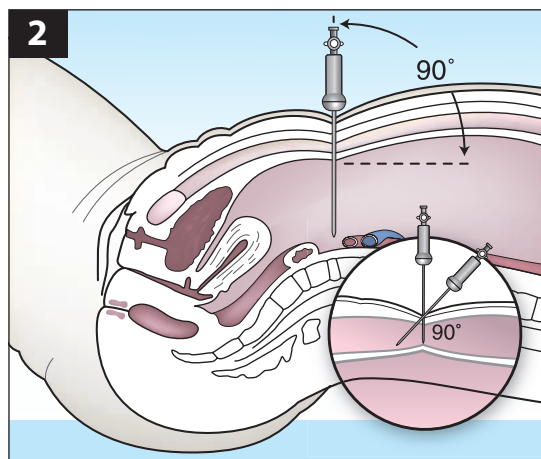
There are many techniques for entering the abdomen none of which are uniformly safe. Both the anatomy of the patient and the surgeon must be considered when determining the appropriate method of access for any procedure. Thin, nulliparous patients may require a different technique than the morbidly obese. Patients with previous abdominal surgery, either laparoscopic or open, present additional challenges. No one technique, angle or instrument is appropriate for all surgeons or all procedures. The experience, training and the judgment of the surgeon must combine to choose the instruments in any given circumstance.

There are, however, certain principles that may help us avoid injuries most of the time. A knowledge of the three dimensional anatomy of the abdomen

and pelvis will prompt us to ‘map out’ the hazardous regions for each patient prior to making the first incision. While in obese patients the aortic bifurcation may be as deep as 6 cm or more below the umbilicus, it may be as close as 1.5 cm in a thin woman. Trocar insertion at  $90^\circ$  may be quite reasonable for the obese patient, but extreme caution would be required in using that technique in the thin patient (Figure 2).

In general, there are a few tricks that provide some measure of safety in gaining access to the abdomen:

- 1) Avoid the Trendelenburg position. This rotates the sacral promontory closer to the umbilicus (Figure 3). Keep the patient flat and centered on the operating table.
- 2) Use standard length instruments. If the anatomy is considered and the appropriate access site and angle are chosen, there should be no need to use long needles or trocars.
- 3) In patients with difficult access, either very thin or obese patients, or those who have had prior abdominal surgery, consider alternate sites for needle and trocar insertion. An alternate site should be chosen in patients with failed insufflation attempt since preperitoneal insufflation pushes the peritoneum away making it difficult to enter the peritoneal cavity in the same place (Figure 4). The left upper quadrant location is usually adhesion-free and easy to access.
- 4) Use a spinal needle with a syringe filled with saline or local anesthetic to

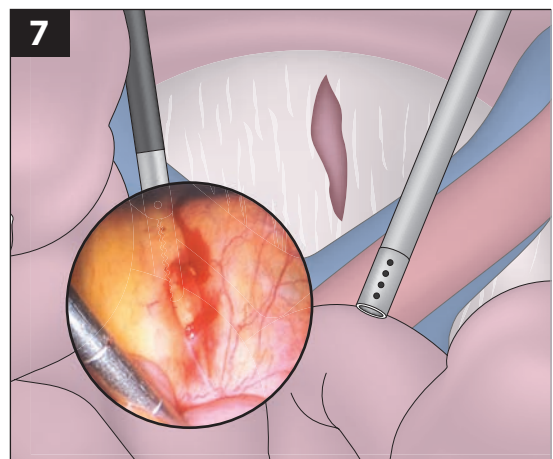
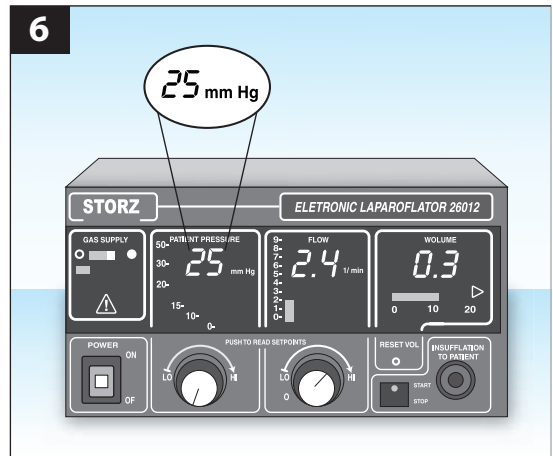
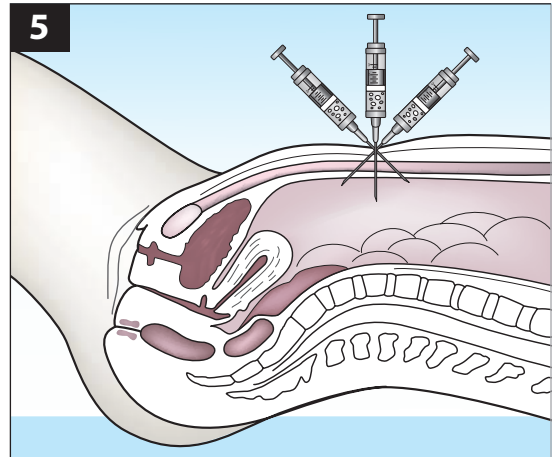


explore the region underlying your intended insertion site. Inject and then aspirate, looking for either bowel contents or blood (Figure 5). A sufficient volume must be injected to permit aspiration of thick material such as fecal matter.

- 5) Insufflate the abdomen to a relatively high pressure (e.g., 25 mmHg) for a short period of time to permit maximal counter pressure while inserting the trocar (Figure 6).
- 6) Determine the estimated depth of the peritoneal cavity and note it on the trocar or needle, then use slow steady pressure on the instrument to insert it just to the predetermined depth. In general, it is not so much the angle of insertion that creates retroperitoneal injuries as it is the depth of insertion of the instruments. It is advisable to hold the trocar shaft with the non-dominant hand or to hold the index finger along the trocar shaft to prevent excessive insertion of the trocar, and retroperitoneal injuries shown on Figure 7. If resistance is felt during the trocar insertion, as if the trocar is hitting against a hard surface after the laparoscopic camera is introduced, the patient should be placed in a steep Trendelenburg and the bowel moved away in order to inspect the retroperitoneal space underneath the primary trocar.

- 7) Avoid multiple passes with the needle or the trocar.

WC Fields said, “If at first you don’t succeed, try again, then quit. There’s no use being a damn fool about it.” This is reasonable advice for the

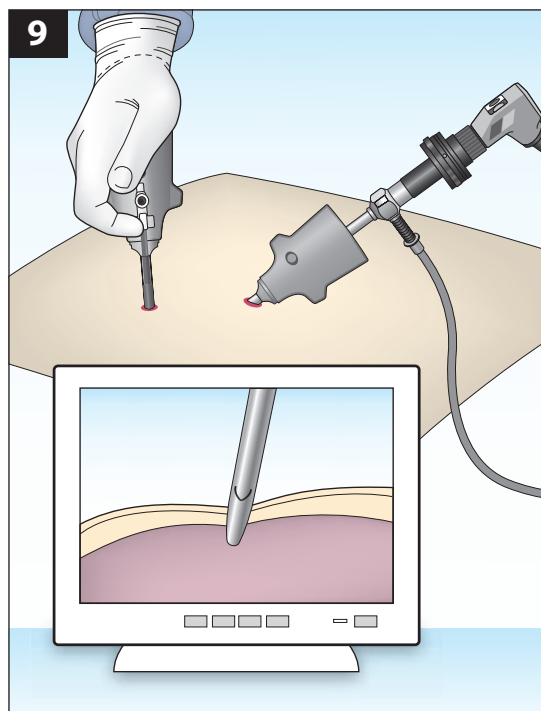
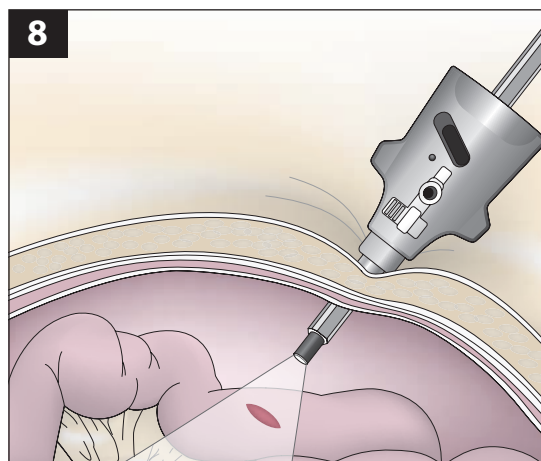


laparoscopic surgeon. If abdominal access is difficult at one location, consider alternate sites or methods rather than risking injury with repeated attempts at insertion in a tough place.

8) Inspect the region underneath the insertion site immediately upon placement of the laparoscope. Look for blood, debris or bowel contents (Figure 8). Bleeding may be an ominous sign and mandates careful inspection of the retroperitoneum for hematoma formation. Similarly, damage to bowel is most easily identified early in the procedure before the patient has been placed into steep Trendelenburg position and the bowel contents swept out of the visual field. This step will not avoid a complication, but it may permit early recognition and treatment.

9) Place all secondary ports under direct vision (Figure 9). Consider placement carefully in order to avoid the inferior epigastric vessels as well as the pelvic sidewall and the bladder. I like to use a 22-gauge needle with local anesthetic to explore the areas of secondary trocar placement as well. That way I can be sure the region of entry is in my visual field and I can determine the angle and depth of trocar insertion. For patients with prior pelvic surgery, the bladder may have been advanced as the peritoneum was closed. Sometimes filling the bladder may help to identify its borders before midline insertion of a trocar.

10) Finally, at the conclusion of the procedure, remove the laparoscope



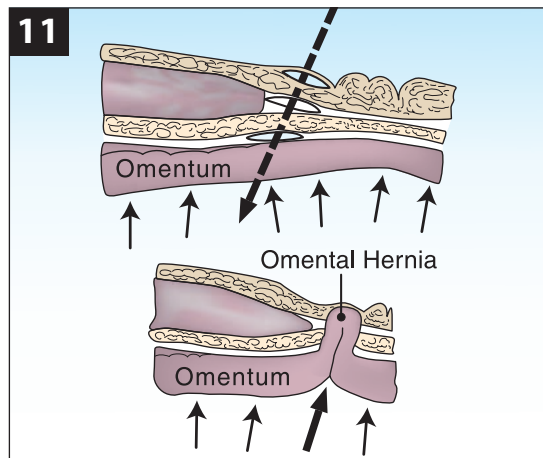
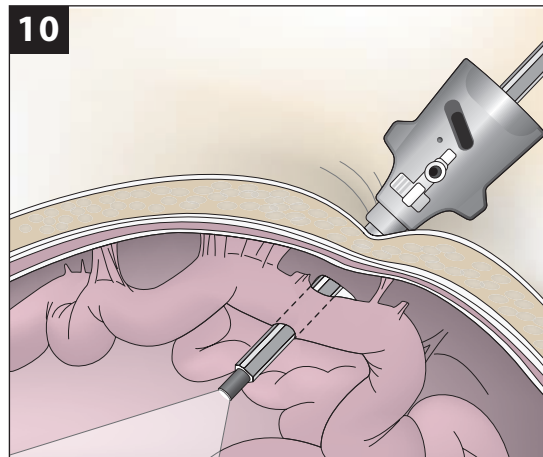
under direct vision, looking at each layer of the abdominal wall as the trocar sleeve is removed. With a through injury to a loop of bowel, this maneuver may be the only way to recognize the perforation (Figure 10).

**THINGS TO KEEP IN MIND**

- ATTENTION TO ANATOMY AND PATIENT'S SIZE
- AVOID TRENDLENBURG POSITION DURING INSERTION
- USE STANDARD SIZE INSTRUMENTS
- INSUFFLATE TO HIGH PRESSURES FOR TROCAR INSERTION
- AVOID MULTIPLE PASSES
- CONSIDER ALTERNATIVE SITES
- INSPECT THE SITE UNDERNEATH THE INSERTION SITE
- PLACE ANCILLARY TROCARS UNDER DIRECT VISION
- REMOVE THE LAPAROSCOPE UNDER DIRECT VISION

There are a few late complications related to abdominal entry that should be discussed. Hematoma formation in the abdominal wall is not particularly uncommon. In complicated cases however, these hematomas may become infected. Necrotizing fasciitis has resulted in destruction of the abdominal wall and fascia requiring months of treatment and multiple reconstruction procedures. Pressure dressings may help to avoid hematomas as it is often difficult to isolate and control oozing from small, deep trocar sites.

Complex laparoscopic procedures often require multiple 10-12 mm ports for instrumentation. Several factors may predispose patients to hernia formation in these areas (Figure 11). Although there are many instruments available to help us



close these port sites, none will be uniformly successful in avoiding hernias. Just as with open surgery, the most meticulous closure may still break down. Infection, hematoma formation, poor nutrition, and abdominal distension will all predispose the patient to wound breakdown. In addition, several technical issues may predispose to hernias. The anchoring threads on many trocars may cause pressure necrosis of the fascia during long operative procedures. This compromised tissue may break down early

allowing sutures to pull through. Pyramidal or knife-blade trocars, if inserted with a twisting motion, may shred the fascial fibers making it difficult for sutures to hold. Finally, multiple passes through the abdominal wall in any one site may compromise the strength and viability of tissue in that location, once again compromising suture placement and security.

One last complication of abdominal entry sites must be mentioned. Tumor seeding at laparoscopic port sites has been reported in our literature as well as the general surgery literature. Operating laparoscopically for malignancy requires significant skill and meticulous technique. Even so, it appears that port site metastases are significantly more common than metastases in large abdominal incisions. There are several theories to explain this, however, the important message here is that they do seem to occur with some frequency. Therefore it is prudent to counsel these patients preoperatively regarding the possibility and observe them diligently postoperatively to identify metastases early when they do occur.

## **INTRAOPERATIVE COMPLICATIONS**

### **ADHESIOLYSIS AND RESTORATION OF ANATOMY**

The two dimensional view, the limited visual field, and the lack of tactile sensation during laparoscopic surgery may be associated with several complications. Adhesiolysis and ureterolysis (if necessary

and if physician skill allows) with meticulous restoration of anatomy should be undertaken before ever starting the intended procedure. Endometriosis, PID, and prior surgeries may all contribute to adhesions and distortion of normal pelvic anatomy, placing nearby pelvic organs, blood vessels, or ureters at risk for injury. Bowel injury may occur during adhesiolysis. The left ovary is frequently densely adherent to the sigmoid colon and the pelvic sidewall. Traction on the structures, intense dissection in a field with vision often limited by oozing and anatomic distortion and the use of various energy sources (laser, electro-surgery, ultrasound) may all cause injury to the bowel.

Once normal anatomy has been restored, key anatomic landmarks should be identified and recognized including anterior and posterior cul-du-sac, ureters, and major blood vessels.

## **COMPLICATIONS OF ELECTRICAL ENERGY**

You have to be very familiar with the energy forms that you are using during laparoscopic surgery. The surgeon must have an understanding of monopolar and bipolar electro-surgery, ultrasonic energy and laser energy in order to choose an appropriate technique and use it safely. If electro-surgical techniques are used be aware of the possibility of direct or indirect (capacitive) coupling, in order to avoid complications (Figures 12 and 13).

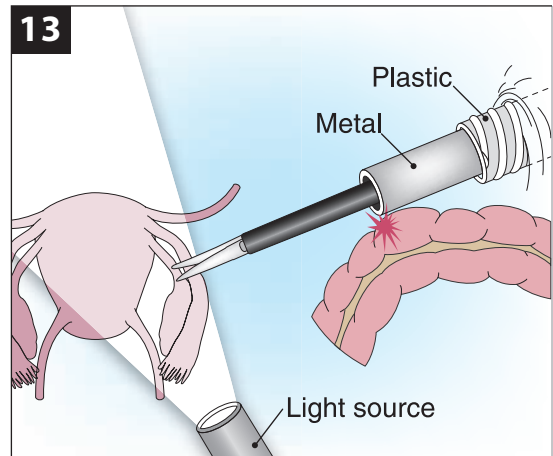
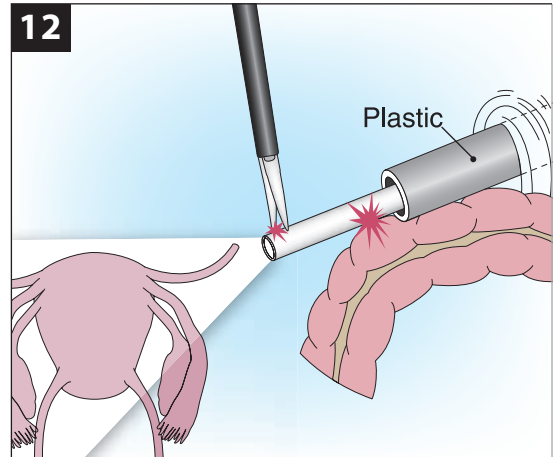
When using any kind of energy during laparoscopy keep in mind two simple



- KEEP THE TIPS OF YOUR INSTRUMENTS IN THE CENTER OF THE SCREEN, WHILE APPLYING ENERGY!
- NEVER USE TWO DIFFERENT ENERGY SOURCES IN THE ABDOMEN AT THE SAME TIME.

rules: always keep the tips of your instruments in the center of the screen, while applying energy! Never use two different energy sources in the abdomen at the same time. It is very easy to get confused and to press a different pedal creating the potential disaster (Figure 14).

Bowel perforations by scissors or tearing/shearing forces, if not recognized at the time of the surgical procedure, are likely to result in early and severe abdominal pain in the postoperative period. Many of these patients report extraordinary pain in the recovery room. Any patient with enough discomfort to require admission for pain management should be monitored with the suspicion for bowel perforation. Delayed perforation may occur in patients where adhesiolysis was accompanied by the use of energy techniques for hemostasis. Devascularization and coagulative necrosis may result in perforation several days after the procedure. Any patient who has a failure to thrive after laparoscopic surgery should be observed carefully. The surgeon must consider bowel perforation, incarcerated hernia and bladder or ureteral injuries in



### BOWEL INJURY

- NOT FROM VERESS NEEDLE
- INJURY MAY NOT BE APPARENT FOR 4-5 DAYS
- ANY SYMPTOMS OF PERITONITIS (SHARP ABDOMINAL PAIN, VOMITING) MUST BE CONSIDERED AS BOWEL INJURY UNLESS PROVEN OTHERWISE!!!
- USE BOWEL PREP

these patients. It is helpful to generate a differential diagnosis during the period of observation. Choose laboratory and diagnostic studies to rule in or out each possibility, but remember that there is no substitute for good clinical judgment. Ileus, pelvic inflammatory disease and pneumonia are extraordinarily rare after laparoscopic surgery. If a patient returns with pain, fever and abdominal distention she has an intraperitoneal injury until proven otherwise. Delay in surgical intervention may be catastrophic.

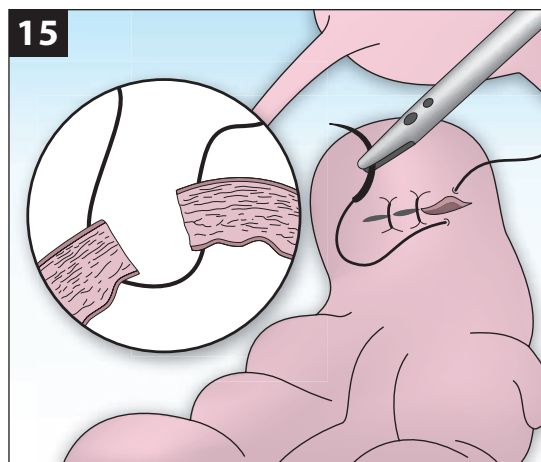
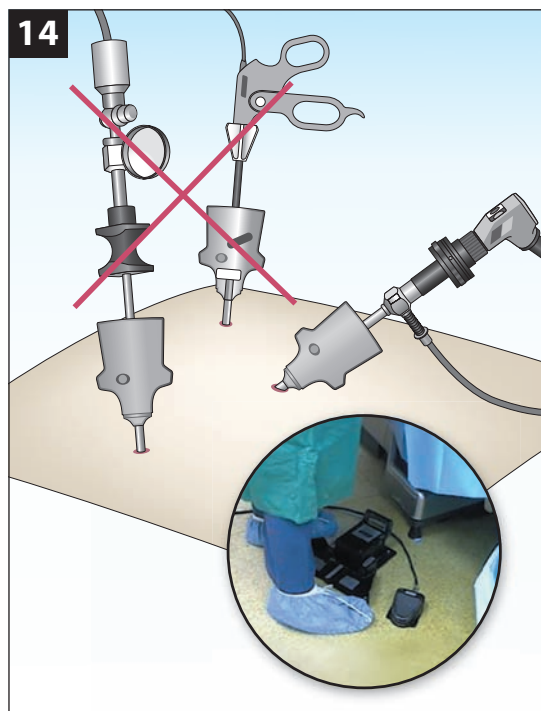
If bowel injury is recognized during laparoscopic surgery, it can be fixed laparoscopically (Figure 15), or injured bowel may be pulled out through an expanded 10 mm incision and fixed. Sutured bowel may be carefully pushed back inside, avoiding laparotomy incision.

## VASCULAR INJURY

Vascular injuries may occur in three different areas:

1. Pelvic sidewall
2. Intraperitoneal parenchymal bleeding
3. Retroperitoneal injury

Pelvic sidewall injury may occur during adhesiolysis, adnexal surgery, hysterectomy myomectomy, and lymphadenectomy. Careful anatomic dissection prior to initiating the surgical procedure may help to avoid some of these injuries, however, at times the anatomic distortion is such that the injury may occur during the effort at dissection. The lack of tactile sensation and the limited operative field are particularly challeng-



ing for the surgeon under these circumstances. The external iliac artery and vein are at risk during adhesiolysis as well as adnexal surgery for ovarian cystectomies or ectopic pregnancy (Figure 16). Extreme caution is required when using

## VASCULAR INJURY

### ABDOMINAL WALL BLEEDING

- INFERIOR EPIGASTRIC ARTERY

### INTRAPERITONEAL VESSEL INJURY

- MESENTERY
- OVARIAN ARTERY
- UTERINE ARTERY

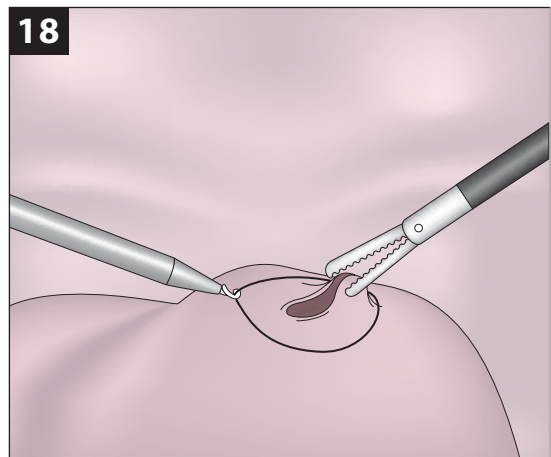
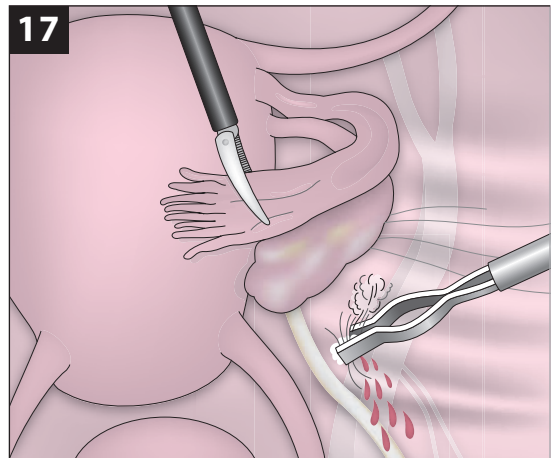
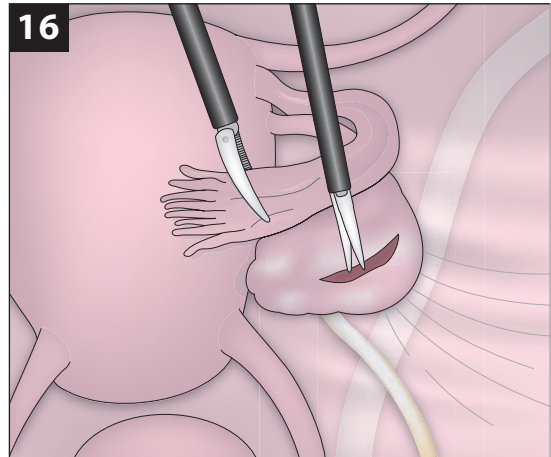
### RETROPERITONEAL MAJOR VESSEL INJURY

- ILIAC ARTERY
- VENA CAVA
- AORTA

energy sources in the pelvis, as the proximity of the pelvic sidewall vessels render them quite vulnerable to injury.

Whenever possible, the adnexa should be freed from the sidewall and surgical intervention carried out in the anterior cul-de-sac. If excessive bleeding is encountered, the external iliac artery must be dissected and inspected. Parenchymal bleeding can usually be treated laparoscopically. It is important not to panic. The first step is to grasp the bleeder with the atraumatic grasper to stop active bleeding. After irrigation with fluids and aspiration of blood, bleeding vessels are identified and hemostasis is established either with the help of laparoscopic suturing, endoloop, bipolar current, or simple mechanical pressure (Figures 17 and 18).

Remember that the pneumoperitoneum may collapse the veins. Injury to these structures may not become evident until the postoperative period. Before closure, release of the pneumoperitoneum



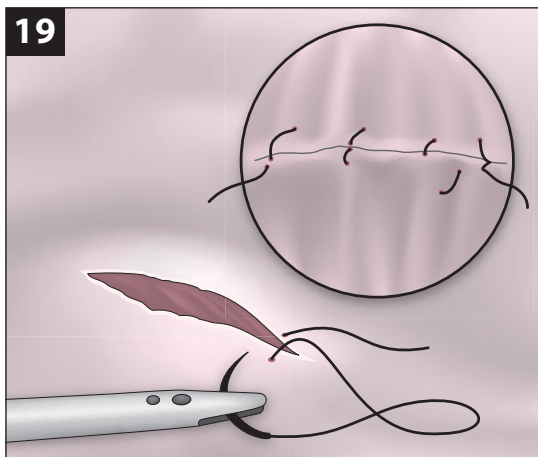
## RETROPERITONEAL INJURY

- DIRECT COMPRESSION ON AORTA
- IV FLUIDS
- EARLY RECOGNITION IS THE KEY TO SURVIVAL
- DO NOT OPEN THE PERITONEUM OVER A HEMATOMA!
- CALL A VASCULAR OR TRAUMA SURGEON

and inspection of the pelvis under low pressure conditions, or under fluid, should help to identify these problems intraoperatively.

Retroperitoneal injuries are the most problematic complications of laparoscopic surgery. They usually occur as a result of Veress needle placement or primary trocar placement. Surgeons must be particularly careful with those procedures, and make sure that the operating table is in a flat position before Veress needle and trocar insertion. Always check visually with the laparoscope the area underneath the trocar for the absence of a retroperitoneal hematoma or bowel injury.

If retroperitoneal vessel injury is diagnosed, immediate laparotomy should be performed, and a vascular surgeon consulted. Manual pressure on the aorta underneath the renal arteries should be applied while the vascular surgeon is summoned. Additional IV access should be established to replace blood and fluids.



## 19 GENITOURINARY COMPLICATIONS

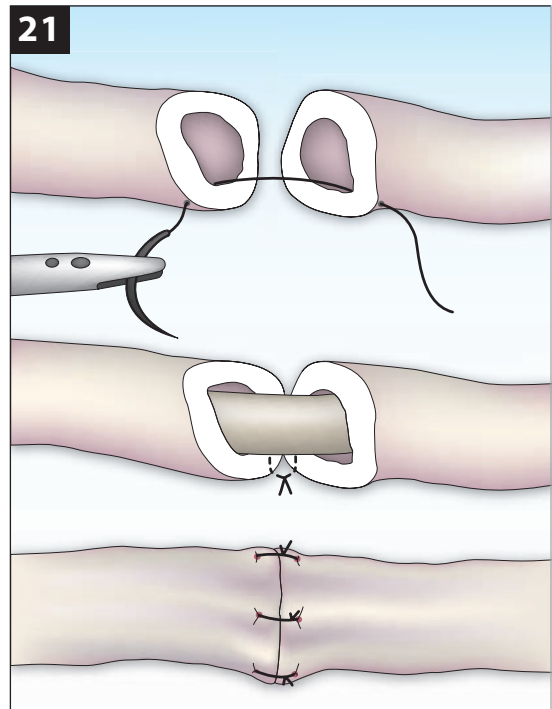
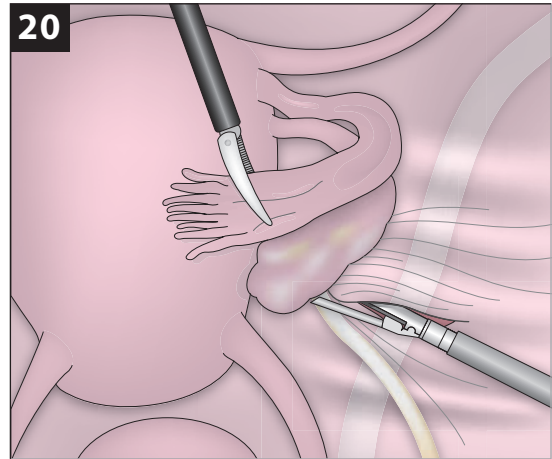
Bladder injury usually occurs as a result of the secondary trocar placement. The bladder is a very forgiving organ, and it can be fixed laparoscopically in two layers using absorbable sutures if an injury is detected during surgery (Figure 19).

The ureters may be injured up to ten times as frequently during laparoscopic surgery as they are during traditional abdominal procedures. At laparotomy, we employ several techniques to protect the ureter. Traction on the uterus creates additional space between the ureter and the uterine artery during hysterectomy. This usually permits safe control and division of the vessels as well as the cardinal and uterosacral ligaments without the need for complete ureteral dissection. At laparoscopy, it may be more difficult to deviate an enlarged, fibroid uterus enough to protect the ureter. In addition, we use some techniques for hemostasis much more often at laparoscopy. It is

uncommon to use stapling devices, electro-surgery or lasers extensively during open surgery. These devices have all been associated with ureteral injury (Figure 20). The size of the stapling devices makes it difficult to see around them at times and any energy system, when used in proximity to the ureter, may cause thermal damage to the ureter itself or to its blood supply. This may result in delayed necrosis.

Once again, early recognition of ureteral injury requires vigilance and a high index of suspicion. The symptoms are often vague initially. Fever and pyelonephritis are rare after laparoscopic surgery. A patient presenting with flank pain and fever or abdominal distension should be evaluated for an injury to the urinary tract. Early diagnosis via ultrasound or X-ray studies may enable the injury to be treated with stent placement rather than requiring re-exploration.

When in doubt that potential ureteral injury may have occurred during laparoscopic surgery, give the patient indigo



#### BLADDER INDIGO CARMINE

- IF <ICM CONSIDER FOLEY CATHETER FOR 7-10 DAYS
  - IF >ICM LAPAROSCOPIC 2 LAYER CLOSURE + FOLEY AND CYSTOSCOPE
- URETER TRACE FROM PELVIC BRIM
- SMALL NON-ELECTRICAL INJURY PRIMARY REPAIR OVER STENT.
  - SOME INJURIES MAY HEAL WITH STENT PLACEMENT ALONE.

carmine dye intravenously and perform cystoscopy to check ureteral function. It is much easier to perform cystoscopy and visualize ureteral orifices if using a video camera. You can also use a 5 mm diagnostic hysteroscope attached to the laparoscopic camera to perform cys-

toscopy. If ureteral injury is recognized during laparoscopic surgery, end-to-end anastomosis can be performed laparoscopically using 4.0 sutures at each quadrant over the ureteral stent. If a small ureteral injury or laceration is observed, a ureteral stent should be passed and left in place without need for suturing (Figure 21). See Chapter 20.

## CHECKING FOR UNRECOGNIZED INJURIES

While an unintended injury is an unfortunate occurrence, an unrecognized injury carries more serious as well as long-term risks. As a result, surgeons should take care to exercise measures to ensure that some unrecognized injury has not occurred. For example, if there is any question regarding the location of the bladder edges (possibly distorted due to prior cesarean section) backfilling the bladder through a foley catheter would help to identify the margins. Lowering the abdominal pressures to 8 mmHg may reveal bleeding from a peritoneal edge or vessel that had been tamponaded by the pneumoperitoneum. If extensive dissection occurred along the pelvic sidewall or electrocauterization was used in close proximity to the course of the ureter, cystoscopy with direct visualization of ureteral patency would help to ensure that no ureteral damage had occurred. Directly visualizing ancillary trocar removal would reduce the possibility of unrecognized abdominal wall vessel injury. Dissection of endometriosis or adhesions from the posterior cul-du-sac may expose the

## BASIC LAPAROSCOPIC CONTRAINDICATIONS

### ABSOLUTE

- CONDITIONS WHICH MITIGATE AGAINST PRODUCTION OF PNEUMOPERITONEUM
- CARDIOVASCULAR
- PULMONARY

### RELATIVE

- TRAINING AND EXPERIENCE OF SURGEON
- AVAILABILITY OF NECESSARY INSTRUMENTATION
- DIFFUSE PERITONITIS
- SHOCK OR IMPENDING SHOCK
- OBESITY

bowel to risk of injury. Filling the pelvis with irrigation while simultaneously placing air in the rectum with a proctoscope would reveal air bubbles if there was an unrecognized injury to the bowel.

## POSTOPERATIVE PREVENTION OF COMPLICATIONS

Since unrecognized injury may have occurred outside of the monitor's field of view, vigilant attention to unexpected postoperative signs or symptoms and early recognition of complications is an absolute necessity for the gynecologic laparoscopist. The surgeon should be aware of the usual timeline of occurrence for some of the most common complications.

Vascular or vessel injuries are usually most immediate and should be recognized with PACU to the first 24 hours postoperatively. These are usually the most immediate and life-threatening injuries sustained in laparoscopy.

Abnormal or unstable vital signs in the recovery room or significant drops in hemoglobin should cause a high level of suspicion. These are the most common complications and/or causes of death related to trocar injuries reported to the FDA.

Ureteral injury usually occurs within the first 48-72 hours postoperatively, but may present later. Fever, flank pain, peritonitis, and abdominal distention should be recognized as concerning signs. These injuries may also present with leukocytosis and hematuria. If these injuries were not recognized intraoperatively, an IVP is essential for diagnosis.

Bowel complications are (regrettably) an inevitable aspect of laparoscopic surgery. Their presentation may occur days to weeks after the initial surgery. In contrast to vascular injury which usually presents immediately, bowel injury frequently goes unnoticed, leading to delayed and insidious complications. The patient may pres-

ent with obvious symptoms such as fever, abdominal tenderness, and an elevated white count, but may also present with minimal complaints of malaise or nausea. Postoperative recovery from laparoscopic surgery should see progressive improvement; worsening and/or persistent pain demands immediate and thorough examination to exclude bowel trauma.

## CONCLUSION

While minimally invasive surgery has been a tremendous advance in the art and science of pelvic and abdominal surgery, it is not without its risks and complications. The only way to avoid these problems altogether is to avoid walking into the operating room. With careful attention to detail and a critical approach to patients who are at increased risk, either by virtue of their anatomy or their history, complications may be anticipated in most instances and steps may be taken to minimize them. Thoughtful, reasoned and disciplined postoperative management of patients who are not recovering as expected will identify those with complications early.

## SUGGESTED READING:

Hurd WW, Bude RO, DeLancey JO, Pearl ML. The relationship of the umbilicus to the aortic bifurcation: Implications for laparoscopic technique.

Obstet Gynecol 1992;80:48-51

Boike GM, Miller CE, Spirtos NM, et al. Incisional bowel herniations after operative laparoscopy: a series of nineteen cases and review of the literature.

Am J Obstet Gynecol 1995;172:1726-1733

Soderstrom RM. Bowel injury litigation after laparoscopy.

Am Assoc Gynecol Laparosc 1993;1:74

Harkki-Siren P, Sjoberg J, Makinen J, et al. Finnish National Register of laparoscopic hysterectomies: A review and complications of 1165 operations.

Am J Obstet Gynecol 1997;176:118-22

Peterson HB, DeStefano F, Rubin GL, et al. Deaths attributable to tubal sterilization in the United States, 1977 to 1981. Am J Obstet Gynecol 1983;146:131

Chapron CM, Pierre F, Lacroix S, et al. Major vascular injuries during gynecologic laparoscopy. J Am Coll Surg 1997;185:461

Hasson HM, Parker WH. Prevention and management of urinary tract injury in laparoscopic surgery. J Am Assoc Gynecol Laparosc 1998;5:99

Chapron C, Quarleu D, Bruhat MA, et al. Surgical complications of diagnostic and operative gynecological laparoscopy: A series of 29,966 cases. Hum Reprod 1998;113:867

Kives SL, Levy BS, Levine RL. American Association of Gynecologic Laparoscopists. Laparoscopic-assisted vaginal hysterectomy: American Association of Gynecologic Laparoscopists' 2000 membership survey. J Am Assoc Gynecol Laparosc 2003;10:135

Chan JK, Morrow J, Manetta A. Prevention of ureteral injuries in gynecologic surgery. Am J Obstet Gynecol 2003;188:1273

Isaacson K. Complications of Gynecologic Endoscopic Surgery. Philadelphia. Saunders Elsevier 2006





# INDEX

Page numbers in *italics* refer to illustrations or tables

- AbdoLift® system 377, 379  
*see also* gasless laparoscopy
- abdominal access  
 complications of 430–5, 431–4  
 instruments 24–6, 25  
*see also* trocars
- abdominal pregnancy 164  
*see also* ectopic pregnancy
- abdominal wall 8–9
- Access needle driver 275
- ACE™ laparoscopic device 30, 31, 93
- acid-base changes 43–5
- adhesiolysis 129–30, 435  
 abdominal 139–41, 139–41  
 adnexal 144–5, 144, 145  
 aqua dissection 136, 136, 141–2, 144–5  
 classifications 137  
 CO<sub>2</sub> laser 135–6, 139, 140, 142, 144–5  
 electrosurgery 134, 134  
 enterolysis 137  
 surgical plan for 137–9, 138  
 hand-assisted laparoscopy 146–8, 147, 148  
 harmonic scalpel 134–5, 135, 141, 141  
 laparoscopes 132, 133  
 open 148–9  
 pelvic 141–4, 142–4  
 plume elimination 136  
 probes 135, 136  
 scissors 132–3, 133  
 underwater surgery at end of procedure 145–6, 146
- adhesions 129–32, 137  
 bowel 137  
 epidemiology 130–2  
 prevention 149–51, 187  
 anti-adhesion adjuvant solutions/drugs 149–50  
 anti-adhesion agents 150–1, 151  
 good surgical technique 149  
*see also* adhesiolysis
- adnexal mass 179–87  
 causes 180  
 diagnosis 180–2, 181  
 pediatric 343–4  
 surgical treatment 182–7  
 adhesion prevention 187  
 cystectomy 185–6, 185–7  
 gasless laparoscopy 385, 386  
 in pregnancy 187  
 preoperative preparation 182  
 resection 184–5, 184  
 surgical approach 182–4, 183
- AESOP® robotic arm 416
- AlloDerm® 330
- allografts 328, 329–30, 330
- anesthesia 39–55  
 gasless laparoscopy 379  
 general anesthesia 49–50  
 mechanical effects of laparoscopy 41–3  
 monitored anesthesia care 46–9, 48  
 physiologic changes during laparoscopy 40–1, 43–5  
 preoperative assessment 45–6
- appendectomy 372–3, 372, 373
- appendicitis 372
- aqua dissection 136, 136, 141–2, 144–5
- Argon Beam Coagulator (ABC) 84–5
- arrhythmias 45
- arterial embolization 231
- aspiration and sounding test 62, 63
- autografts 328
- bicornuate uterus 349, 359–61, 359  
 diagnosis 359  
 surgical correction 359–61, 360, 361
- biomaterial 328–30  
 natural 328–30, 329  
 synthetic 330, 330  
 classification 331  
*see also* mesh
- bipolar electrosurgery 78, 78, 88–92, 89–92  
 tubal sterilization 111–12, 111, 112  
*see also* electrosurgery
- bipolar forceps 31, 31
- bladder 10, 10  
 injury during surgery 281–2, 320, 439, 439  
 inspection 264–6, 264, 265

- bladder flap creation 203–4, 203, 204  
bleeding control 31–3, 235  
  parenchymal bleeding 438  
  presacral neurectomy 194–5  
  sacral colpopexy 321  
  *see also* vascular injury during surgery  
bowel injury during surgery 320, 436–7, 442  
  surgical correction 437, 437  
bowel surgery 365–75  
  appendectomy 372–3, 372, 373  
  colon resection 365–6  
    right hemicolectomy 368–70, 369, 370  
    sigmoid colectomy 366–8, 366–8  
  colostomy closure 371–2, 371, 372  
  colostomy creation 370, 370, 371  
  incidental enterotomy 374–5, 375  
  Meckel's resection 373–4, 374  
broad ligament  
  base 12–14  
  incision 408  
bupivacaine 54  
Burch colposuspension 272  
  technique 279–81, 280, 281  
  *see also* paravaginal repair and Burch colposuspension
- CA125 182  
capacitance 86–7  
capacitative coupling 87–8, 87, 88  
carbon dioxide absorption 43–4  
  *see also* insufflation  
cardiac disease 2  
cardinal ligament 310  
cardiovascular effects 44–5  
  patient position 41–2  
  pneumoperitoneum 41  
cervical cancer 391–2, 407  
cervical pregnancy 163–4  
  *see also* ectopic pregnancy  
children *see* pediatric laparoscopy  
chocolate cysts 126  
cholecystectomy 242  
chronic pelvic pain (CPP) *see* pain  
chylous ascites 195  
clips 112–14, 112–14  
CO<sub>2</sub> laser adhesiolysis 135–6, 139, 140, 142, 144–5  
coagulation 81–4, 82, 83, 94  
  endometriosis treatment 120, 120, 121, 121  
  vs. excision 124  
  instruments 31–3  
colon resection 365–6  
  right hemicolectomy 368–70, 369, 370  
  sigmoid colectomy 366–8, 366–7  
colostomy closure 371–2, 371, 372  
colostomy creation 370, 370, 371  
colpoelongation 350  
colpopexy, sacral 313–19, 314–19  
colpopoiesis 350–4, 351–4  
colposuspension *see* Burch colposuspension  
colpotomy 205–7, 206, 207, 226  
complications 50–3, 427–42, 428  
  abdominal entry 430–5, 431–4  
  bowel injury 320, 436–7, 442  
    surgical correction 437, 437  
  electrical energy complications 435–7, 436, 437  
  gas embolism 52–3  
  genitourinary complications 439–41  
    bladder injury 281–2, 320, 439, 439  
    ureteral injury 281, 282, 319–20, 439–41, 440, 442  
  incidence 429  
  mesh use 336  
  pediatric laparoscopy 342  
  pneumomediastinum 50–2  
  pneumopericardium 50–1  
  pneumothorax 50–1  
  positional complications 430  
  prevention of 428–30  
    counselling and consent 428  
    history and physical 428  
    instrumentation and operating room preparation 428–9  
    patient positioning 429–30, 429  
    postoperative prevention 441–2  
  pulmonary embolism 50  
  subcutaneous emphysema 52  
  unrecognized injuries 441  
  vascular injuries 282–3, 320–1, 413, 437–9, 438, 442  
  *see also* specific procedures  
congenital malformations *see* malformations  
consent 3, 428  
contraindications 2, 441  
Cook Lapsac™ 33–4, 243, 243  
corticosteroids 149  
counselling 428  
Cox-2 inhibitors 54  
cul-de-sac adhesions 142, 142  
culdotomy 241–2  
cutting 81–2, 81, 82, 94  
  instruments 30, 31  
cystectomy 185–6, 185–7  
cystocele 296, 297, 327  
cystoscopes  
  flexible 263, 263, 265–6  
  rod-lens 262–3, 262  
cystoscopy 208–9, 261, 440–1  
  technique 263–6, 264, 265

- cystotomy 281–2
- cystourethroscopy 261
- DaVinci™ Surgical System 36, 36, 391, 416–19, 416
- credentialing and privileging 417
  - hysterectomy 421–3, 422, 423
  - myomectomy 419–21, 419–21
  - set-up 417–19, 418
- desiccation 82–4, 83, 84
- minimization of tissue damage 91
- diagnostic laparoscopy with vaginal hysterectomy 198
- see also* laparoscopic hysterectomy
- dispersive electrode pad 79–80, 79
- documentation 22, 73
- dysmenorrhea 191
- ectopic pregnancy 155–8
- diagnosis 156–7
  - differential diagnosis 157
  - location of 157–8, 157
  - medical management 165–6
  - mortality rates 155, 157
  - risk factors 156
  - signs and symptoms 156, 156
  - surgical management 159–65
    - abdominal pregnancy 164
    - ampullary ectopic 159–60, 159, 160
    - cervical pregnancy 163–4
    - interstitial/cornual ectopic 162–3, 162
    - isthmic ectopic 161, 161
    - ovarian pregnancy 163, 163
    - ruptured ectopic pregnancy 164–5, 165
    - salpingectomy 161–2, 161, 162
  - treatment options 159
- electric current 75–6, 76, 77
- capacitive coupling 86–8, 87, 88
  - direct coupling 86, 86
- electrosurgery
- adhesiolysis 134, 134
  - bipolar mode 78, 78, 88–92, 89–92
    - tubal sterilization 111–12, 111, 112
  - complications of electrical energy 435–7, 436, 437
  - current 77
  - generators 28–9, 28
  - grounding 79–80
    - dispersive electrode pad 79–80, 79
    - electrode monitoring systems 80, 80
  - monopolar mode 78, 78
    - problems of 85–6
  - tissue effects of 80–5, 81
    - coagulation 81–4, 82, 83, 94
    - cutting (electrosection) 81–2, 81, 82, 94
    - desiccation 82–4, 83, 84
    - fulguration 84–5, 84
    - waveform modulation 78, 78, 79
- Elmed needle driver 275
- emphysema 52
- Endo Catch Gold™ 244
- Endo GIA Universal Multifire 32
- EndoEye™ video laparoscope 21, 22
- Endoloop™ 32
- Endomat™ irrigator 34
- endometrial cancer 391
- endometrioma 125–6, 125
- endometriosis 117–27, 118, 257–8
- confirmation of 118–19
  - goals of surgery 117–18
  - medial deviation of ureter 124, 124
  - ovarian lesions 125–6, 125, 126
  - recognition of 119–20
  - retrocervical 124–5, 124, 125
  - sterilization procedures and 126
  - treatment 120–4
    - completion of surgery 126–7
    - deep lesions 121–4, 121–3, 257–8, 258
    - presacral neurectomy 192
    - superficial peritoneal lesions 120–1, 120, 121
- Endopath™ bladeless trocar 25, 26
- endopelvic fascia 296–301, 298, 300–1, 310, 310
- breaks in 296, 298
  - function 299–300
- Endopouch™ Retriever 244, 244
- endoscopes
- flexible 263, 263, 265–6
  - rod-lens 262–3, 262
- Endoscopic Rotating Multiple Clip Applier Ligaclip™ 32, 33
- EndoSite Digital Camera™ 22, 22
- ENDOTIP™ device 26, 26
- EnSeal™ Laparoscopic Vessel Fusion System 92, 92, 398–402, 400, 401
- enterocele 295, 296, 311, 311, 312
- repair 311–13, 312, 313
  - clinical results 321–3
- enterolysis 137
- surgical plan for 137–9, 138
  - see also* adhesiolysis
- enterotomy 374–5, 375
- epigastric artery
- inferior 8–9, 8
  - superficial 8, 8
- erosion, mesh 336
- Espiner E-Sacs 244–5
- Ethicon LapDisc™ 148, 148

- excision, endometriosis treatment 122–4, 122, 123  
vs. coagulation 124
- expandable sheaths 26, 27
- extrusion, mesh 336
- Fallopian tubes 158  
malformations 349
- Falope-Ring® Band Applicator 35
- fascial white line 15
- fentanyl 49
- fibrinolytics 149
- fibroids 231, 232  
gasless laparoscopy 385–6, 386  
*see also* laparoscopic occlusion of uterine arteries; myomas
- Filshie Clip™ 114, 114  
applicator 35
- FloSeal 321
- Flowstat™ 236, 236
- fulguration 84–5, 85
- gas embolism 52–3
- gasless laparoscopy 377–89  
abdominal cavity approach 380–3, 380–2  
abdominal wall elevation 379, 379, 380, 383  
adnexal tumors 385  
advantages of 383–4, 383, 384  
anesthesia 379  
fibroid enucleation 385–6, 386  
hysterectomy 386–7, 387  
indications 378  
patient positioning 379  
pelvic and para-aortic lymphadenectomy 387–8, 388  
termination of procedure 389
- general anesthesia 49–50  
*see also* anesthesia
- generalized visceral hypersensitivity (GVH) 174
- genital malformations *see* malformations
- genital organ prolapse *see* pelvic organ prolapse
- genitourinary complications 439–41  
bladder injury 281–2, 320, 439, 439  
ureteral injury 281, 282, 319–20, 439–41, 440, 442  
surgical management 440, 441
- genuine stress urinary incontinence (GSUI) 271, 272  
sling procedures 287–93, 288–93  
*see also* paravaginal repair and Burch colposuspension
- Gore-Tex® 150, 274
- graspers 29–30, 29, 30, 99
- grounding 79–80  
dispersive electrode pad 79–80, 79  
electrode monitoring systems 80, 80
- Gynecare  
Morcellator Morcellex™ 34  
TVT SECUR™ System 293, 293  
X-tract™ 247, 247
- Gynemesh 330
- hand-assisted laparoscopy 146–8, 147, 148
- hanging drop test 61, 62
- harmonic energy instruments 30, 31, 93–4, 93  
adhesiolysis 134–5, 135, 141, 141  
for pediatric laparoscopy 342, 342
- Hasson cannula 25, 25
- Hasson technique 65–6, 65, 66
- hematoma 434
- hemorrhage *see* bleeding control; vascular injury  
during surgery
- HERMES™ system 20
- hernia formation 434–5, 434
- Hulka-Clemens clip™ 112–14, 114  
applicator 35, 113
- hypercapnea 43, 44  
pediatric patients 340
- hypogastric nerve 397, 397, 398
- hysterectomy *see* laparoscopic hysterectomy
- iliac artery  
common 11, 410–11, 410  
external 437, 438  
internal 10, 10, 14, 15, 232–3
- iliac vein  
common 8, 8, 11, 411, 411, 412  
external 409–10, 410, 437
- incontinence *see* stress incontinence
- indigo carmine 265
- informed consent 3, 428
- infundibulopelvic ligament 12, 12  
desiccation 202–3, 202, 203, 216, 216
- Inlet closure device 403–4
- instruments 29–36  
abdominal access 24–6, 25  
gasless laparoscopy 378  
insufflation 23–4, 23, 24  
laparoscopic hysterectomy 200  
lower urinary tract endoscopy 262–3, 262, 263  
paravaginal repair and Burch colposuspension 273–6, 274–6  
pediatric laparoscopy 341–2, 341, 342  
preparation of 428–9  
presacral neurectomy 192–3, 193  
suturing 98, 99
- insufflation  
direct trocar insertion 66–7, 66, 67  
failed 59–60  
instruments 23–4, 23, 24

- pediatric patients 340
- subcostal 64–5, 64
- transumbilical 60–3, 60, 61
- transuterine 68–9, 68
- Insufflow® device 24
- insulation failure 85–6, 86
- Interceed™ 127, 150
- intestinal obstruction 2
- intra-abdominal insufflation pressure 62, 62, 63
- intrauterine septum 349, 361–2, 361
  - diagnosis 361
  - surgical correction 362, 362
  - variants 361–2
- irrigation 34–5, 35
  
- ketamine 49
- ketorolac 54
- Kleppinger envelope sign 113, 113
- knot pushers 99
- knot tying 102
  - extracorporeal 102–4, 103, 104
  - intracorporeal 104
  - square knot 105–6, 105, 106
  
- laparoscopes 27–8, 28
  - for pediatric laparoscopy 342
- laparoscopic assisted vaginal hysterectomy (LAVH) 198
  - postoperative pain relief 54–5
  - see also* laparoscopic hysterectomy
- laparoscopic coagulating shears (LCS) 93, 94
- laparoscopic hysterectomy 197–209
  - contraindications 199
  - definitions 198–9
  - gasless laparoscopy 386–7, 387
  - indications 199
  - postoperative care 208–9
  - preoperative evaluation 199
  - radical hysterectomy 198–9, 391–404
    - indications 391–2
    - nerve-sparing technique 395, 397–404, 397–403
    - operative procedure 393–404, 394–403
    - patient positioning 392–3
    - patient preparation 392
    - postoperative course 404
    - trocar placement 393, 393
  - robotic hysterectomy 421–3, 422, 423
  - see also* laparoscopic supracerical hysterectomy (LSH); total laparoscopic hysterectomy (TLH)
- laparoscopic myomectomy 224–5, 224–6
- laparoscopic occlusion of uterine arteries 231–7
  - complications 234–5
  - indication 232
  - mechanism of fibroid death 323
  - postoperative course 235
  - surgical technique 233–4, 234, 235
  - see also* fibroids; myomas
- laparoscopic paravaginal repair *see* paravaginal repair and Burch colposuspension
- laparoscopic radical hysterectomy 198–9
  - see also* laparoscopic hysterectomy
- laparoscopic supracerical hysterectomy (LSH) 198, 211–20
  - clinical experience 219, 219
  - CISH procedure 219
  - indications 212
  - technique 212–19, 213–19
  - see also* laparoscopic hysterectomy
- laparoscopic uterosacral nerve ablation (LUNA) 174–5, 175
- laparoscopically assisted myomectomy (LAM) 226–8, 226
  - criteria for 226
  - objectives 227
  - technique 227–8, 227, 228
- Lapsac™ 33–4, 243, 243
- lasers 35, 35
  - CO<sub>2</sub> laser adhesiolysis 135–6, 139, 140, 142, 144–5
- leiomyomas *see* myomas
- levator ani muscles 15, 15, 299
- lidocaine 48, 53, 53
- Lift-laparoscopy *see* gasless laparoscopy
- Ligasure™ 31, 32, 91–2, 92
- ligation 32–3
  - ligature placement 100–2, 101, 102
  - loop ligature 32, 106–7, 106, 107
- light source 26–7, 27
- loop ligature 32, 106–7, 106, 107
- lower urinary tract endoscopy 261–8
  - cystoscopic technique 263–6, 264, 265
  - equipment 262–3, 262, 263
  - injury during surgery 281–2, 319–20
  - ureteral stent 266–8, 266, 267
- lymphadenectomy 387–8, 388, 407–8, 408
  - complications 413
  - para-aortic 387–8, 388, 411–13, 411, 412
  - pelvic 387–8, 388, 408–11, 409, 410
  
- McBurney's point 9, 9
- malformations 347–62
  - bicornuate uterus 359–61, 359–61
  - classification 348–9
  - diagnosis 347–8
  - intrauterine septum 361–2, 361, 362
  - unicornuate uterus 356–8, 357

- malformations (*cont.*)  
 uterus duplex 358, 358  
 vaginal aplasia 349–56, 350–5
- manipulators 23, 23, 58, 58  
 laparoscopic supracervical hysterectomy 213–14
- Mayer-Rokitansky-Kuster-Hauser syndrome 349
- mechanical effects of laparoscopy 41–3  
 patient position 41–2  
 pneumoperitoneum 41  
 pulmonary effects 42–3, 42
- Meckel's diverticulum 373
- Meckel's resection 373–4, 374
- mesh 328–30  
 anterior mesh interposition 330–3, 331, 332  
 complications 336  
 natural biomaterials 328–30, 329  
 posterior mesh interposition 333–4, 333, 334  
 synthetic biomaterials 330, 330  
 classification 331  
 vaginal placement via non-conventional routes 334–6, 334, 335
- methotrexate, ectopic pregnancy management 165–6
- metoclopramide 53
- metroplasty 359–61, 360, 361
- midazolam 49–50
- modulation 78–9, 79
- monitored anesthesia care 46–9, 48
- monopolar electrosurgery 78, 78  
 problems of 85–8  
 capacitive coupling 86–8, 87, 88  
 direct coupling 86, 86  
 insulation failure 85–6, 86  
*see also* electrosurgery
- morcellation 33–4, 34, 245–8  
 laparoscopic supracervical hysterectomy 218, 218, 219  
 systems 246–8, 247  
 techniques 245–6, 245, 246  
*see also* tissue retrieval
- muscle white line 15
- myolysis 229
- myomas 223, 224  
 preoperative evaluation 223  
*see also* fibroids; laparoscopic occlusion of uterine arteries; myomectomy
- myomectomy  
 indications 224, 224  
 laparoscopic 224–5, 224–6  
 laparoscopically assisted (LAM) 226–8, 226  
 criteria for 226  
 objectives 227  
 technique 227–8, 227, 228
- robotic 419–21, 419–21  
*see also* fibroids; myomas
- N<sub>2</sub>O 50, 51, 379
- nausea, postoperative 53  
 prevention 50
- necrotizing fasciitis 434
- needle holders 98, 99
- neonates *see* pediatric laparoscopy
- non-steroidal anti inflammatory drugs (NSAIDs) 149
- Nylon 66 244
- obesity 2
- obturator nerve 11, 235, 235, 283
- obturator neurovascular bundle 409–10, 410  
 injury 282–3
- obturator space 14, 14
- omentolysis 137  
*see also* adhesiolysis
- ON-Q® PainBuster® 54–5
- open laparoscopy 65–6, 65, 66
- operating room  
 preparation of 428–9  
 setup 19–21, 20, 21  
 robotic surgery 417–19, 418
- operative instruments *see* instruments
- operative laparoscopy with vaginal hysterectomy 198  
*see also* laparoscopic hysterectomy
- OR1™ system 20
- ovarian cyst 180–1, 181  
 cystectomy 185–6, 185–7  
*see also* adnexal mass
- ovarian remnant syndrome 259
- ovary  
 adhesions 144  
 adnexal adhesiolysis 144–5, 144, 145  
 cyst *see* ovarian cyst  
 endometriosis lesions 125–6, 125, 126  
 malformations 349  
 malignancy 180, 181  
 tumor markers 181–2  
 ovarian pregnancy 163, 163  
 retroperitoneal 259, 259  
 torsion 344  
*see also* adnexal mass
- pain  
 chronic pelvic (CPP) 169–70  
 laparoscopic uterosacral nerve ablation (LUNA) 174–5, 175  
 microlaparoscopic pain mapping 170–4, 170–3  
 uterine suspension 176–7, 176, 177  
 postoperative 53–5

- presacral neurectomy 191–2
- para-aortic lymphadenectomy 387–8, 388, 411–13, 411, 412
- parametrium 395–6, 395, 398  
division of 398–9, 398
- parametrial ureteral dissection 400–2, 400–2
- pararectal space 13–14, 14, 394–5, 395
- paravaginal repair and Burch colposuspension 271–83, 276  
Burch colposuspension technique 279–81, 280, 281  
complications 281–3  
lower urinary tract injuries 281–2  
vascular injuries 282–3  
equipment and sutures 273–6, 274, 275  
paravaginal repair technique 277–9, 277–80  
paravaginal tissue division 402, 402
- paravesical space 14, 394, 394, 408–9, 409  
dissection 256–7
- parencymal bleeding 438  
*see also* vascular injury during surgery
- patient evaluation 1  
contraindications 2  
preoperative assessment 45–6, 428
- patient positioning 57, 58, 429  
gasless laparoscopy 379  
mechanical effects of 41–2  
pediatric patients 341, 341  
prevention of complications 429–30  
robotic surgery 417–18  
Trendelenburg position 41–2, 47  
*see also specific procedures*
- patient preparation  
day of surgery 4  
preoperative routine 3–4  
*see also specific procedures*
- pediatric laparoscopy 339–44  
complications 342  
indications 339–40, 340  
instrumentation 341–2, 341, 342  
ovarian masses 343–4  
patient positioning 341, 341  
port placement 342–3, 343
- pelvic brim 11–12, 11
- pelvic diaphragm 298
- pelvic lymphadenectomy 387–8, 388, 408–11, 409, 410
- pelvic organ prolapse 295, 296–9, 296, 309, 327–8  
recurrence 327  
vaginal vault 296, 311  
vaginal wall 271, 272  
*see also* paravaginal repair and Burch  
colposuspension; pelvic support; sacral colpopexy
- pelvic plexus 395  
preservation of in radical hysterectomy 398–9, 398, 401–2, 401, 402
- pelvic relaxation 295–6
- pelvic sidewall 12, 13, 251–3, 252  
injury during surgery 437–8, 438  
*see also* retroperitoneal dissection
- pelvic splanchnic nerves 395, 395, 398
- pelvic support 295–7, 309  
anatomy of 297–301, 298–301, 310–11  
laparoscopic uterosacral ligament suspension 301–7, 302–6  
level I support 298, 300–1, 310–11  
level II support 298–9, 298, 300, 301  
level III support 299, 299, 301, 301
- Pelvicol™ 329
- Pelvisoft™ 329
- Pelvitex™ 330
- peritoneal anatomy 9–10
- physiologic changes during laparoscopy 40–1, 43–5  
pulmonary 43–4
- PK™ Technology instruments 31, 32, 89, 92, 92
- PlasmaSpatula™ 89, 90
- Pleatman Sac® Tissue Removal System 243–4
- plume elimination 136
- pneumomediastinum 50–2
- pneumopericardium 50–1
- pneumoperitoneum 41  
creation of 59–63  
pediatric patients 340, 342
- pneumothorax 50–1
- Polyform™ 330, 330
- port placement *see* trocars
- positioning *see* patient positioning
- postoperative recovery 53–4
- Pouch of Douglas (POD) 125, 125
- power 76
- power density 76–7, 77
- pregnancy 2  
adnexal mass surgery 187  
*see also* ectopic pregnancy
- preoperative assessment 45–6  
laparoscopic hysterectomy 199  
myomas 223
- preoperative preparation *see* patient preparation
- presacral nerves 11
- presacral neurectomy 10, 191–5  
complications 194–5  
instrumentation 192–3, 193  
technique 193–4, 193, 194
- presacral space 10–11, 11
- prolapse *see* pelvic organ prolapse
- propofol 49, 50



- pubocervical fascia 298–9  
tears 296, 327, 328, 328
- pubovaginal sling procedures 287–93, 288–93
- pulmonary effects  
mechanical 42–3, 42  
physiologic 43–4
- pulmonary embolism 50
- rectal probe 135, 136
- rectocele 296, 297, 327
- rectosigmoid adhesions 142, 142
- rectovaginal fascia 298  
tears 327
- rectovaginal septum 296
- rectovaginal space 16, 16, 255–6, 256, 396–7, 396
- red smoke sign 208
- Repliform® 329, 329
- residual ovarian syndrome 259
- resistance 75–6, 76
- retrieval instruments 33–4, 34
- retroperitoneal dissection 251–3, 253  
complications 259, 439  
endometriosis 257–8, 258  
retroperitoneal ovaries 259, 259  
surgical technique 253–7, 253  
lateral approach 256–7, 257  
medial approach 253–6, 254–6
- retropubic colposuspension 271–2  
*see also* paravaginal repair and Burch colposuspension
- retropubic space 14–15
- return electrode monitoring (REM) system 80, 80
- right hemicolectomy 368–70, 369, 370
- robotics 36, 391, 415–24  
credentialing and privileging 417  
hysterectomy 420, 421–3, 421  
myomectomy 419–21, 419–21  
set-up 417–19, 418
- rod-lens endoscopes 262–3, 262
- Rotocut™ morcellator 34, 247–8, 247
- round ligament 204, 204, 215–16, 215
- Rumi™ manipulator 23, 23, 206, 206
- S\*E\*M\*M\* (Serrated Edge Macro Morcellator) 247, 247
- sacral colpopexy 313–19, 314–19  
clinical results 321–3  
complications 319–21, 322–3  
bowel injury 320  
lower urinary tract injuries 319–20  
vascular injuries 320–1
- salpingectomy 161–2, 161, 162
- salpingo-ovariolysis 144–5, 144, 145
- scissors 30, 31  
for adhesiolysis 132–3, 133
- scopolamine 54
- sedation 48–9
- sheaths 25–6, 25, 69  
expandable 26, 27  
rod-lens endoscope 262–3, 262  
small 35
- shoulder pain 53, 73
- sigmoid colectomy 366–8, 366–7
- sigmoid colostomy 370
- sling procedures 287–93, 288–93
- space of Retzius 14–15, 273  
suturing in 273–5, 274, 275
- SPARC sling procedure 291
- splanchnic nerves 395, 395, 398
- square knot 105–6, 105, 106
- staplers 31–2, 32
- stents, ureteral 266–8, 266, 267  
indication 266
- Step™ expandable sheath 26, 27
- sterilization 90, 109–15, 110  
bands 115, 115  
bipolar electrocoagulation 111–12, 111, 112  
clips 112–14, 112–14  
endometriosis and 126  
instruments 35
- stress incontinence 271, 272  
sling procedures 287–93, 288–93  
*see also* paravaginal repair and Burch colposuspension
- Stryker SDC HD™ 22, 22
- superior vesical artery division 400, 400
- suturing 32–3, 33, 97–8, 98  
Burch colposuspension 273–5, 279–80, 280  
gasless laparoscopy 384, 384  
instruments 98, 99  
knot tying 102  
extracorporeal 102–4, 103, 104  
intracorporeal 104  
square knot 105–6, 105, 106  
ligature placement 100–2, 101, 102  
loop ligature 106–7, 106, 107  
mesh interposition 332–4, 332–4  
paravaginal repair 273–5, 274, 275, 277–9, 277–80  
sacral colpopexy 315, 316–19, 316–19  
suture introduction into peritoneal cavity 99–100, 99–101  
total laparoscopic hysterectomy 208
- temporal artery occlusion 235–6, 236
- Tension-Free Vaginal Tape (TVT) sling 287–90, 288–90
- termination of procedure 71–3, 72  
gasless laparoscopy 389

- Thermoflator® insufflator 24
- tissue retrieval
- classical techniques 239–42, 240–2
  - instruments 33–4, 34
  - laparoscopic supracervical hysterectomy 218, 218
  - specialized systems 242–5, 243, 244
  - see also* morcellation
- Toradol 54
- TOT sling procedure 291–3, 291–3
- total laparoscopic hysterectomy (TLH) 198
- postoperative care 208–9
  - surgical technique 199–208
    - bladder flap creation 203–4, 203, 204
    - colpotomy 205–7, 206, 207
    - securing ligaments 202–3, 202, 203, 204, 204
    - securing uterine arteries 204–5, 205
    - trocar placement 200–1, 201
    - underwater examination 208
    - ureter dissection 201, 201–2, 202
    - vaginal cuff closure 207–8, 208
  - see also* laparoscopic hysterectomy
- transverse colostomy 370
- Trendelenburg position 41–2, 47, 431, 431
- trocars 25–6, 25
- insertion sites 59, 59
  - open laparoscopy 65–6
  - pediatric laparoscopy 341–2, 341
  - placement 68, 69–71, 69, 70
    - complications 430–5, 431–4
    - direct insertion 66–7, 66, 67
    - laparoscopic radical hysterectomy 393, 393
    - laparoscopic supracervical hysterectomy 214
    - robotic surgery 418, 418
    - total laparoscopic hysterectomy 200–1, 201
  - removal 71–2
  - small 35, 36
- tubal sterilization *see* sterilization
- tumor seeding 435
- Turbo Flow 8000™ Insufflator 24
- Tutoplast® 330
- umbilical folds 9–10, 9
- umbilicus 8
- unicornuate uterus 348
- unicornuate uterus 348, 356–8, 357
- diagnosis 357
  - surgical correction 357–8
  - variants 357
- ureter 11, 13, 13, 252–3, 252
- dissection
    - laparoscopic radical hysterectomy 400–2, 400–2
    - total laparoscopic hysterectomy 201–2, 201, 202
  - identification of 254, 254, 256–7
  - injury during surgery 281, 282, 319–20, 439–41, 440, 442
    - surgical management 440, 441
  - medial deviation in endometriosis 124, 124
  - mobilization in radical hysterectomy 396, 396, 401, 402
  - patency 208, 282, 320
  - stenting 266–8, 266, 267
    - indication 266
- ureterolysis 215, 215, 254–5, 254, 255
- urethra 262
- inspection 264
- urethropexy *see* Burch colposuspension
- urinary incontinence *see* stress incontinence
- urinary tract
- obstruction 266
  - see also* bladder; genitourinary complications; lower urinary tract endoscopy; ureter
- urogenital diaphragm 298
- uterine arteries 233, 233, 252–3, 252
- identification of 257, 257
  - securing in total laparoscopic hysterectomy 204–5, 205
  - see also* laparoscopic occlusion of uterine arteries
- uterine corpus amputation 217–18, 218
- uterine malformations
- aplasia 349–54, 350–4
  - bicornuate uterus 349, 359–61, 359–61
  - classification 348–9
  - intrauterine septum 349, 361–2, 361, 362
  - unicornuate uterus 348, 356–8, 357
    - surgical correction 357–8
  - uterus and vagina duplex 348–9, 358, 358
    - surgical correction 358
- uterine manipulators 23, 23, 58, 58
- laparoscopic supracervical hysterectomy 213–14
- uterine prolapse 327
- uterine tubes *see* Fallopian tubes
- uterine-ovarian ligament 202, 202
- uterosacral ligaments 255, 298, 300–1, 300, 310–11, 397–8, 397
- laparoscopic suspension 301–7, 302–6, 322
  - tears 296, 327
- vagina 298–9, 298, 299
- aplasia 348, 349–56
    - with aplasia of uterus 349–54, 350–4
    - with functional uterus 354–6, 354, 355
  - duplex 348–9, 358, 358
    - surgical correction 358
  - transection in radical hysterectomy 402–3, 403
    - closure 403, 403

- vagina (*cont.*)
  - vault prolapse 296, 311
    - laparoscopic sacral colpopexy 313–23, 314–19
  - wall prolapse 271, 272
  - see also* paravaginal repair and Burch colposuspension; pelvic support
- vaginal hysterectomy *see* laparoscopic hysterectomy
- vaginal probe 135, 136
- vaporization
  - endometriosis treatment 120–1, 121
- vascular anatomy 232–3, 232, 233
- vascular injury during surgery 437–9, 438, 442
  - lymphadenectomy 413
  - paravaginal repair and Burch colposuspension 282–3
  - sacral colpopexy 320–1
  - see also* bleeding control
- vasopressin
  - ectopic pregnancy management 159–60
  - myomectomy and 224, 228
- Veress needle 23–4, 23
  - insertion sites 59, 59
  - subcostal 64–5, 64
  - transumbilical 60–2, 61
  - transuterine 68–9, 68
    - pediatric laparoscopy 342
- vesico-uterine fold 203
- vesicouterine ligaments 400
  - division 400–2
    - anterior vesicouterine ligament 400–1, 400
    - posterior vesicouterine ligament 401–2, 401, 402
- vesicovaginal space 15, 16, 399–400, 399
- video imaging 21–2, 21, 22
- voltage 75–6, 76
- vomiting, postoperative 53
  - prevention 50
- Wave XP™ irrigator 34, 35
- waveform modulation 78–9, 79
- Xenform™ 329, 329
- xenografts 328, 329, 329
- xylocaine 48
- Zeus® surgical system 416

A PRACTICAL MANUAL OF  
**LAPAROSCOPY**  
AND MINIMALLY INVASIVE  
GYNECOLOGY

*Resad P. Pasic, M.D., Ph. D.*  
*Ronald L. Levine, M.D.*



**Resad Paya Pasic, M.D., Ph.D.**

Dr. Pasic is an Associate Professor in the Department of Obstetrics, Gynecology and Women's Health at the University of Louisville School of Medicine, where he serves as the Director of the Division of Gynecologic Endoscopy and Co-Director of the Gynecologic Endoscopy Fellowship. He completed his medical school education and residency training at Sarajevo University School of Medicine in Bosnia & Herzegovina and a Ph.D. from the University of Sarajevo and the University of Louisville.

Dr. Pasic is certified in advanced laparoscopy and hysteroscopy and has become an international educator of gynecologic endoscopy. He has published many scientific papers on his research in minimally invasive surgery, serves on the OBGYN.net editorial board, and is an ad hoc reviewer for several scientific journals. Dr. Pasic has lectured in many courses internationally.

Dr. Pasic has served as a member of the Board of Trustees of the AAGL from 2003-2005. He has served as faculty for a number of AAGL postgraduate courses and is the Course Director of "Advanced Workshops on Gynecologic Laparoscopic Anatomy and Surgery on Unembalmed Female Cadavers" in Louisville KY. His website is: [www.gynlaparoscopy.com](http://www.gynlaparoscopy.com)



**Ronald L. Levine, M.D.**

Dr. Levine is a Professor in the Department of Obstetrics, Gynecology & Women's Health at the University of Louisville School of Medicine. He has been active in pioneering and teaching laparoscopy since 1970. He has led multiple courses in advanced laparoscopic surgery.

Dr. Levine served several terms as a trustee on the Board of the American Association of Gynecologic Laparoscopists and was President in 1998. He has also served on the Board of the Accreditation Council of Gynecologic Endoscopy from 1994 to the present.

He has co-authored three text books on gynecologic endoscopy, has written many book chapters and has published more than 25 articles in various peer reviewed journals and has had multiple lectureships both nationally and internationally. He has performed laparoscopic surgery on three continents including the first LAVH in Zimbabwe, Africa.

**informa**

healthcare

[www.informahealthcare.com](http://www.informahealthcare.com)

ISBN 1-84214-330-1



9 781842 143308