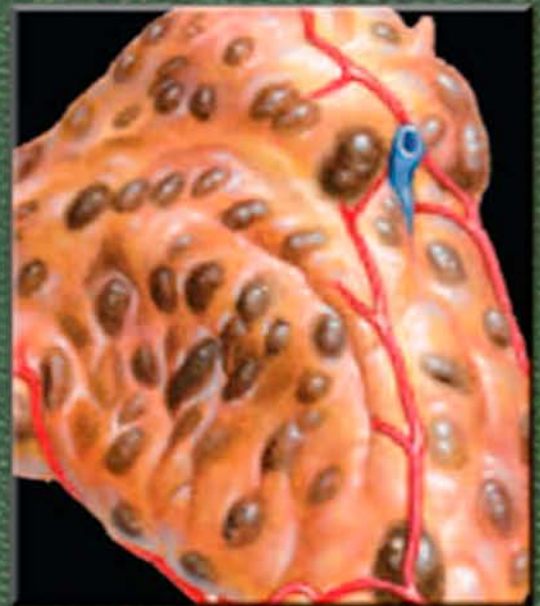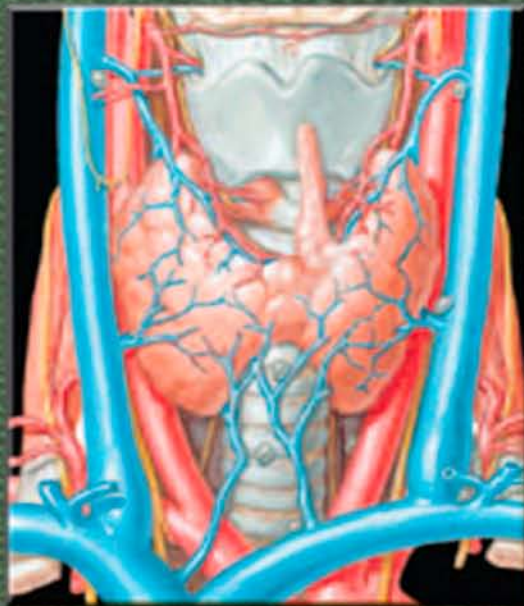


*F. Netter  
M.D.*

# THE NETTER COLLECTION of Medical Illustrations

2nd Edition

VOLUME 2

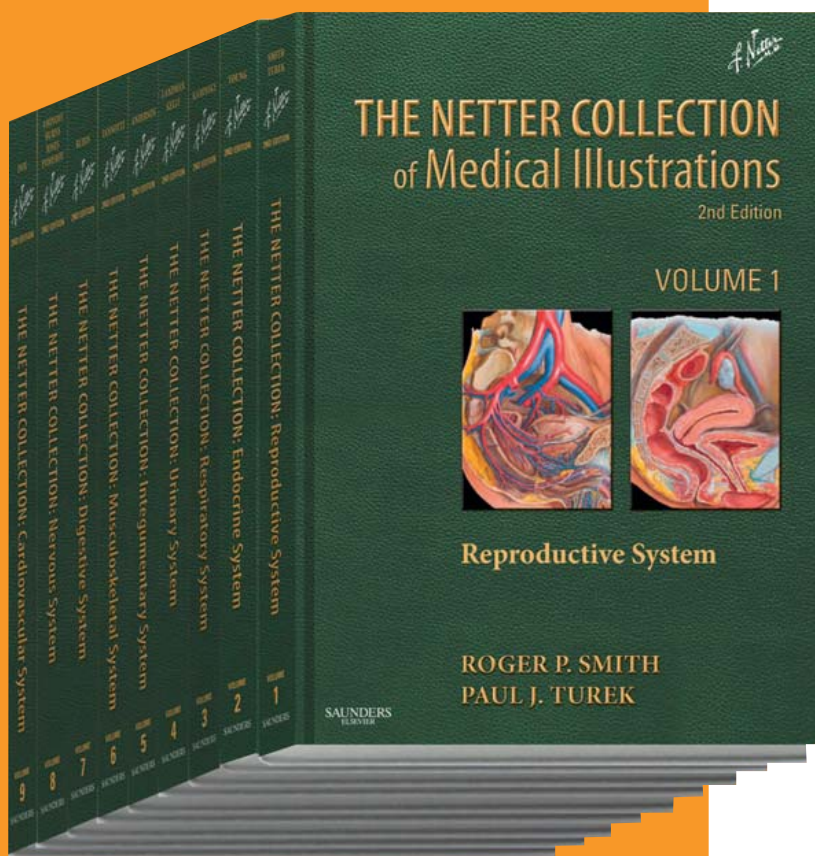


## Endocrine System

WILLIAM F. YOUNG, JR.



# The ultimate Netter Collection is back!



Netter's timeless work, now arranged and informed by modern text and radiologic imaging!


The long-awaited update of **The Netter Collection of Medical Illustrations**, also known as the CIBA “green books,” is now becoming a reality! **Master artist-physician, Carlos Machado, and other top medical illustrators** have teamed-up with medical experts to make the classic Netter “green books” a **reliable and effective current-day reference**.

- **Apply a visual approach—with the classic Netter art, updated illustrations, and modern imaging--** to normal and abnormal body function and the clinical presentation of the patient.
- **Clearly see the connection between basic and clinical sciences** with an integrated overview of each body system.
- **Get a quick understanding of complex topics** through a concise text-atlas format that provides a context bridge between general and specialized medicine.

**ORDER YOURS TODAY!**

Learn more about the series at [www.NetterReference.com/greenbooks](http://www.NetterReference.com/greenbooks)

ELSEVIER



# Netter. It's how you know.



## Atlas of Human Anatomy, 5th Edition Professional Edition

Frank H. Netter, MD

May 2010. 978-1-4377-0970-4.

The **Netter Atlas** is your authoritative guide to the human body—through versatile **print and online resources**. The new 5th Edition features a **stronger clinical focus** than ever before, including an online image bank of some of Netter's classic anatomy and pathology illustrations, diagnostic imaging examples, and videos from Netter's 3-D Interactive Anatomy.

**ORDER TODAY! | [mynetter.com](http://mynetter.com) | 1-800-545-2522**

VOLUME 2



# The Netter Collection OF MEDICAL ILLUSTRATIONS: **Endocrine System**

*Second Edition*

**William F. Young, Jr., MD, MSc**

Professor of Medicine, Mayo Clinic College of Medicine  
Division of Endocrinology, Diabetes, Metabolism, and Nutrition  
Mayo Clinic  
Rochester, Minnesota

***Illustrations by***

*Frank H. Netter, MD, and Carlos A. G. Machado, MD*

**CONTRIBUTING ILLUSTRATORS**

James A. Perkins, MS, MFA

John A. Craig, MD

Kristen Wienandt Marzejon, MS, MFA

ELSEVIER  
SAUNDERS



**ELSEVIER**  
SAUNDERS

1600 John F. Kennedy Blvd.  
Ste 1800  
Philadelphia, PA 19103-2899

**THE NETTER COLLECTION OF MEDICAL ILLUSTRATIONS:  
ENDOCRINE SYSTEM, Volume 2, Second Edition**

**ISBN: 978-1-4160-6388-9**

Copyright © 2011 by Saunders, an imprint of Elsevier Inc.

No part of this publication may be reproduced or transmitted in any form or by any means, electronic or mechanical, including photocopying, recording, or any information storage and retrieval system, without permission in writing from the publisher. Details on how to seek permission, further information about the Publisher's permissions policies and our arrangements with organizations such as the Copyright Clearance Center and the Copyright Licensing Agency, can be found at our website: [www.elsevier.com/permissions](http://www.elsevier.com/permissions).

This book and the individual contributions contained in it are protected under copyright by the Publisher (other than as may be noted herein).

#### Notices

Knowledge and best practice in this field are constantly changing. As new research and experience broaden our understanding, changes in research methods, professional practices, or medical treatment may become necessary.

Practitioners and researchers must always rely on their own experience and knowledge in evaluating and using any information, methods, compounds, or experiments described herein. In using such information or methods they should be mindful of their own safety and the safety of others, including parties for whom they have a professional responsibility.

With respect to any drug or pharmaceutical products identified, readers are advised to check the most current information provided (i) on procedures featured or (ii) by the manufacturer of each product to be administered, to verify the recommended dose or formula, the method and duration of administration, and contraindications. It is the responsibility of practitioners, relying on their own experience and knowledge of their patients, to make diagnoses, to determine dosages and the best treatment for each individual patient, and to take all appropriate safety precautions.

To the fullest extent of the law, neither the Publisher nor the authors, contributors, or editors, assume any liability for any injury and/or damage to persons or property as a matter of products liability, negligence or otherwise, or from any use or operation of any methods, products, instructions, or ideas contained in the material herein.

ISBN: 978-1-4160-6388-9

Acquisitions Editor: Elyse O'Grady  
Developmental Editor: Marybeth Thiel  
Editorial Assistant: Chris Hazle-Cary  
Publishing Services Manager: Patricia Tannian  
Senior Project Manager: John Casey  
Designer: Lou Forgione


Printed in China

Last digit is the print number: 9 8 7 6 5 4 3 2 1

# ABOUT THE SERIES



Dr. Frank Netter at work



The single-volume “blue book” that paved the way for the multivolume *Netter Collection of Medical Illustrations* series, affectionately known as the “green books.”

Dr. Frank H. Netter exemplified the distinct vocations of doctor, artist, and teacher. Even more important, he unified them. Netter’s illustrations always began with meticulous research into the forms of the body, a philosophy that steered his broad and deep medical understanding. He often said, “Clarification is the goal. No matter how beautifully it is painted, a medical illustration has little value if it does not make clear a medical point.” His greatest challenge—and greatest success—was chartering a middle course between artistic clarity and instructional complexity. That success is captured in this series, beginning in 1948, when the first comprehensive collection of Netter’s work, a single volume, was published by CIBA Pharmaceuticals. It met with such success that over the following 40 years the collection was expanded into an eight-volume series—each devoted to a single body system.

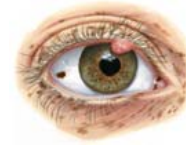In this second edition of the legendary series, we are delighted to offer Netter’s timeless work, now arranged and informed by modern text and radiologic imaging contributed by field-leading doctors and teachers from world-renowned medical institutions and supplemented with new illustrations created by artists working in the Netter tradition. Inside the classic green covers, students and practitioners will find hundreds of original works of art—the human body in pictures—paired with the latest in expert medical knowledge and innovation, and anchored in the sublime style of Frank Netter.

Dr. Carlos Machado was chosen by Novartis to be Dr. Netter’s successor. He continues to be the primary artist contributing to the Netter family of products. Dr. Machado says, “For 16 years, in my updating of the illustrations in the *Netter Atlas of Human Anatomy*, as well as many other Netter publications, I have faced the challenging mission of continuing Dr. Netter’s legacy, of following and understanding his concepts, and of reproducing his style by using his favorite techniques.”

Although the science and teaching of medicine endures changes in terminology, practice, and discovery, some things remain the same. A patient is a patient. A teacher is a teacher. And the pictures of Dr. Netter—he called them pictures, never paintings—remain the same blend of beautiful and instructional resources that have guided physicians’ hands and nurtured their imaginations for over half a century.

The original series could not exist without the dedication of all those who edited, authored, or in other ways contributed, nor, of course, without the excellence of Dr. Netter, who is fondly remembered by all who knew him. For this exciting second edition, we also owe our gratitude to the authors, editors, advisors, and artists whose relentless efforts were instrumental in adapting these timeless works into reliable references for today’s clinicians in training and in practice. From all of us at Elsevier, we thank you.

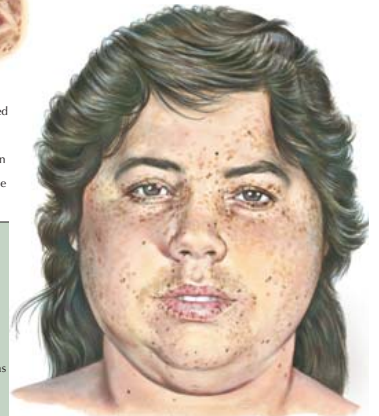
CUSHING’S SYNDROME IN A PATIENT WITH THE CARNEY COMPLEX



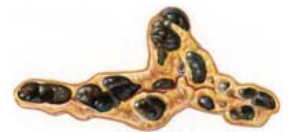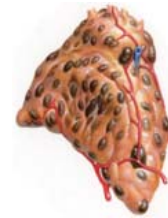Carney complex is characterized by spotty skin pigmentation. Pigmented lentiginos and blue nevi can be seen on the face—including the eyelids, vermilion borders of the lips, the conjunctivae, the sclera—and the labia and scrotum.

Additional features of the Carney complex can include:

- ▶ Myxomas: cardiac atrium, cutaneous (e.g., eyelid), and mammary
- ▶ Testicular large-cell calcifying Sertoli cell tumors
- ▶ Growth-hormone-secreting pituitary adenomas
- ▶ Psammomatous melanotic schwannomas

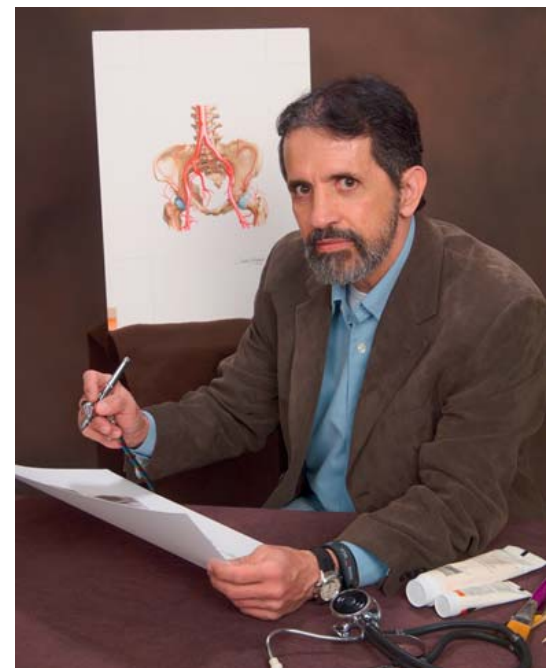


C. Machado



PPNAD adrenal glands are usually of normal size and most are studded with black, brown, or red nodules. Most of the pigmented nodules are less than 4 mm in diameter and interspersed in the adjacent atrophic cortex.

A brand new illustrated plate painted by Carlos Machado, MD, for *The Endocrine System*, Volume 2, ed. 2



Dr. Carlos Machado at work



## ABOUT THE EDITOR



**W**illiam F. Young, Jr, MD, MSc, is Professor of Medicine at Mayo Clinic College of Medicine, Mayo Clinic, Rochester, Minnesota, USA. He holds the Tyson Family Endocrinology Clinical Professorship in Honor of Vahab Fatourech, MD. He received his bachelor degree and his medical degree from Michigan State University and his master of science degree from the University of Minnesota. Dr. Young trained in internal medicine at William Beaumont Hospital in Royal Oak, Michigan, and completed a fellowship in endocrinology and metabolism at Mayo Clinic in Rochester, Minnesota. He has been a member of the staff at Mayo Clinic since 1984. Dr. Young is the recipient of multiple education awards including the Mayo Fellows Association Teacher of the Year Award in Internal Medicine, the Mayo Clinic Endocrinology Teacher of the Year Award, the Mayo School of Continuing Medical Education Outstanding Faculty Member Award, and the H. Jack Baskin, MD, Endocrine Teaching Award from the American Association of Clinical Endocrinologists in recognition of his profound impact in teaching fellows in training. Professional honors include being a recipient of the Distinguished Mayo Clinician Award, the Distinction in Clinical Endocrinology Award from the American College of Endocrinology, and the Distinguished Physician Award from the Endocrine Society. Dr. Young's clinical research focuses on primary aldosteronism and pheochromocytoma. He has published more than 200 articles on endocrine hypertension and adrenal and pituitary disorders. Dr. Young has presented at more than 300 national and international meetings and has been an invited visiting professor at more than 100 medical institutions.

The second edition of the Endocrine System volume of the Netter Collection is designed to provide physicians at all stages of training and practice with a visual guide to the anatomy, physiology, and pathophysiology of the endocrine glands. The first edition was published in 1965. In the intervening 5 decades, there have been remarkable developments in our understanding of endocrine disorders. The text has been entirely rewritten, but most of the anatomic and clinical artwork of Frank H. Netter, MD, has stood the test of time. Since new endocrine disorders and treatment approaches have been recognized over the past 50 years, new artwork has been added in every section, including the following: current surgical approaches to remove pituitary tumors, tests used in the diagnosis of Cushing syndrome, adrenal venous sampling for primary aldosteronism, Cushing syndrome caused by primary pigmented nodular adrenocortical disease, treatment of type 1 and type 2 diabetes mellitus, multiple endocrine neoplasia types 1 and 2, and von Hippel–Lindau syndrome. Carlos Machado, MD, James A. Perkins, MS, MFA, Kristen Wienandt Marzejon, MS, MFA, and John Craig, MD, have contributed outstanding new plates to this edition, as well as adapted and updated existing artwork. The accompanying text serves to illuminate and expand on the concepts demonstrated in the images.

The book is organized in 8 sections, which correspond to the glands and components of the endocrine system: pituitary and hypothalamus, thyroid, adrenal, reproduction, pancreas, bone and calcium, lipids and nutrition, and genetics and endocrine neoplasia. In some cases, the Netter drawings are supplemented with modern diagnostic images (e.g., computed tomography

and magnetic resonance imaging). The original Netter edition and the new illustrations focus on embryology, gross anatomy, histology, physiology, pathology, clinical manifestations of disease, diagnostic modalities, and surgical and therapeutic techniques.

Writing an “update” that spans 5 decades has been a daunting challenge. However, this new edition will serve to preserve and provide context for the original Netter illustrations well into the twenty-first century. This work is not a complete textbook of endocrinology, but rather it is a visual tour of the highlights of this medical discipline. I hope readers find the artwork and accompanying text useful guides as they navigate the world of endocrinology.

I gratefully acknowledge my colleagues and patients at Mayo Clinic who have provided me with the clinical experience, perspective, and insights to address the broad field of endocrinology. The editorial and production staffs at Elsevier have been very supportive at every step from initial general concepts to final publication. I am indebted to the incredible second generation of Netter artists. I also want to thank my daughter, Abbie L. Abboud, MS, CGC, ELS, for her invaluable help in medical editing and providing guidance on clarity of thought and concept. Finally, I dedicate this book to my family—their encouragement and support have been inspirational during the 2 years it took to produce the second edition of the *Endocrine System* volume of the Netter Collection.

**William F. Young, Jr., MD, MSc**  
*Rochester, Minnesota*  
*November 2010*



# ABOUT THE ARTIST FROM THE FIRST EDITION



Many readers of the CIBA COLLECTION have expressed a desire to know more about Dr. Netter. In response to these requests this summary of Dr. Netter's career has been prepared.

Frank Henry Netter, born in 1906 in Brooklyn, New York, received his M.D. degree from New York University in 1931. To help pay his way through medical school and internship at Bellevue, he worked as a commercial artist and as an illustrator of medical books and articles for his professors and other physicians, perfecting his natural talent by studying at the National Academy of Design and attending courses at the Art Students' League.

In 1933 Dr. Netter entered the private practice of surgery in New York City. But it was the depth of the Depression, and the recently married physician continued to accept art assignments to supplement his income. Soon he was spending more and more time at the drawing board and finally, realizing that his career lay in medical illustration, he decided to give up practicing and become a full-time artist.

Soon, Dr. Netter was receiving requests to develop many unusual projects. One of the most arduous of these was building the "transparent woman" for the San Francisco Golden Gate Exposition. This 7-foot-high transparent figure depicted the menstrual process, the development and birth of a baby, and the physical and sexual development of a woman, while a synchronized voice told the story of the female endocrine system. Dr. Netter labored on this project night and day for 7 months. Another interesting assignment involved a series of paintings of incidents in the life of a physician.

Among others, the pictures showed a medical student sitting up the night before the osteology examination, studying away to the point of exhaustion; an emergency ward; an ambulance call; a class reunion; and a night call made by a country doctor.

During World War II, Dr. Netter was an officer in the Army, stationed first at the Army Institute of Pathology, later at the Surgeon General's Office, in charge of graphic training aids for the Medical Department. Numerous manuals were produced under his direction, among them first aid for combat troops, roentgenology for technicians, sanitation in the field, and survival in the tropics.

After the war, Dr. Netter began work on several major projects for CIBA Pharmaceutical Company, culminating in THE CIBA COLLECTION OF MEDICAL ILLUSTRATIONS. To date, five volumes have been published and work is in progress on the sixth, dealing with the urinary tract.

Dr. Netter goes about planning and executing his illustrations in a very exacting way. First comes the study, unquestionably the most important and most difficult part of the entire undertaking. No drawing is ever

started until Dr. Netter has acquired a complete understanding of the subject matter, either through reading or by consultation with leading authorities in the field. Often he visits hospitals to observe clinical cases, pathologic or surgical specimens, or operative procedures. Sometimes an original dissection is necessary.

When all his questions have been answered and the problem is thoroughly understood, Dr. Netter makes a pencil sketch on a tissue or tracing pad. Always, the subject must be visualized from the standpoint of the physician; is it to be viewed from above or below, from the side, the rear, or the front? What area is to be covered, the entire body or just certain segments? What plane provides the clearest understanding? In some pictures two, three, or four planes of dissection may be necessary.

When the sketch is at last satisfactory, Dr. Netter transfers it to a piece of illustration board for the finished drawing. This is done by blocking the back of the picture with a soft pencil, taping the tissue down on the board with Scotch tape, then going over the lines with a hard pencil. Over the years, our physician-artist has used many media to finish his illustrations, but now he works almost exclusively in transparent water colors mixed with white paint.

In spite of the tremendously productive life Dr. Netter has led, he has been able to enjoy his family, first in a handsome country home in East Norwich, Long Island, and, after the five children had grown up, in a penthouse overlooking the East River in Manhattan.

ALFRED W. CUSTER

# INTRODUCTION TO THE FIRST EDITION

In the early days the endocrine glands were looked upon as an isolated group of structures, secreting substances which, in some strange way, influenced the human organism. The thyroid gland was known to be an organ of considerable significance. The clinical syndromes of hyper- and hypothyroidism and the therapeutic effects of thyroid administration and thyroidectomy were recognized. Insulin had become available, and its use in controlling diabetes was being explored. It was known generally that the pituitary gland exerted some influence over the growth and sex life of mankind. Nonetheless, the endocrine glands were still considered as a system apart, secreting mysterious and potent substances. In the light of modern knowledge, however, this is not an isolated system at all but, rather, an essential and controlling mechanism of all the other systems; indeed, together with the nervous system, the integrator of biochemistry and physiology in the living organism.

Thus, although this volume was originally planned as an atlas on the endocrine glands, it was impossible to execute it intelligently without becoming involved in such basic and related subjects as carbohydrate, protein, and fat metabolism; the major vitamins; enzyme chemistry; genetics; and inborn metabolic errors. As a matter of fact, as I now survey the entire subject, it seems to me that the growth of our understanding of the function of the endocrine glands has come about as much or more from the study of the basic physiology of the glandular secretions as from study of the morphological effects of the endocrine system itself. I have also been tremendously impressed and awed by the painstaking,

patient, and unrelenting work of the men and women who have, bit by bit, unraveled and correlated the mysteries of these various fields. It has been my great pleasure, in creating this volume, to have worked with some of these pioneers or with their disciples. No words of appreciation for the help and encouragement I received from all my collaborators can completely convey the satisfaction I obtained from getting to know each of them and becoming their friend.

In finding my way through the uncharted space of the endocrine universe, I sorely needed a guide—one who could plot a course among the biochemical constellations, yet at all times would know his way back to earthly clinical considerations. Such a one I found in Dr. Peter H. Forsham, who took over the editorship of this volume upon the death of Dr. Ernst Oppenheimer, about whom I have written in the preceding pages. I shall always cherish the stimulating hours Dr. Forsham and I spent together in work and, occasionally, in play.

A creative effort such as that which this volume has demanded absorbs a great deal of one's time, effort, and dreams. In short, it tends to detach the artist from his surroundings and personal relationships and to make him difficult to live with! For these reasons I must express special appreciation to my wife, Vera, for patiently bearing with me through these tribulations. She always managed to return me to reality when I became too detached, bring a smile to my face when I was distressed, and help me in so many other ways during this challenging but rather awesome assignment.

FRANK H. NETTER, M.D.



# ADVISORY BOARD

**John Stuart Bevan, FRCP, MBChB, MD**

Lead Endocrinologist and Honorary Professor of Endocrinology  
Aberdeen Royal Infirmary  
Foresterhill, Aberdeen, Scotland, UK

**Frederick R. De Rubertis, MD**

Chief, VA Healthcare System  
University of Pittsburgh  
Pittsburgh, Pennsylvania

**馮琮涵 Associate Professor Fong**

Tsorng-Harn Fong  
National Taiwan University  
Taipei, Taiwan

**Serge Jabbour, MD, FACP, FACE**

Professor of Medicine  
Division of Endocrinology, Diabetes, and Metabolic Diseases  
Jefferson Medical College of Thomas Jefferson University  
Philadelphia, Pennsylvania

**William J. Kovacs, MD**

Professor of Internal Medicine  
Division of Endocrinology and Metabolism  
UT Southwestern Medical Center  
Dallas, Texas

**Howard Lilienfeld, MD, FACP, FACE**

Assistant Professor  
H. Lee Moffitt Cancer Center  
University of South Florida  
Endocrine Tumor Clinic  
Tampa, Florida

**Paolo Mulatero, MD**

Assistant Professor  
Division of Internal Medicine  
University of Torino  
Torino, Italy

**Mitsuhide Naruse, MD, PhD**

Director, Department of Endocrinology  
Kyoto Medical Center  
Fushimi Kyoto (NKD), Japan

**Tommy Olsson, MD, PhD**

Professor, Department of Medicine  
Umea University Hospital  
Umea, Sweden

**Dr. Francisco G. Martínez Sandoval**

Director Programa Internacional  
Titular de Anatomía  
Universidad Autónoma de Guadalajara  
Guadalajara, México

**Janet A. Schlechte, MD**

Professor, Department of Internal Medicine  
University of Iowa College of Medicine  
Iowa City, Iowa

**Peter James Trainer, MD, BSc, FRCP, MBChB**

Professor of Endocrinology  
University of Manchester  
Manchester Academic Health Science Centre  
The Christie NHS Foundation Trust  
Manchester, England, UK

## SECTION 1

### PITUITARY AND HYPOTHALAMUS

- 1-1 Development of the Pituitary Gland, 3
- 1-2 Divisions of the Pituitary Gland and Relationship to the Hypothalamus, 4
- 1-3 Blood Supply of the Pituitary Gland, 5
- 1-4 Anatomy and Relationships of the Pituitary Gland, 6
- 1-5 Relationship of the Pituitary Gland to the Cavernous Sinus, 7
- 1-6 Relationships of the Sella Turcica, 8
- 1-7 Anterior Pituitary Hormones and Feedback Control, 9
- 1-8 Posterior Pituitary Gland, 10
- 1-9 Manifestations of Suprasellar Disease, 11
- 1-10 Craniopharyngioma, 12
- 1-11 Effects of Pituitary Tumors on the Visual Apparatus, 13
- 1-12 Nontumorous Lesions of the Pituitary Gland and Pituitary Stalk, 14
- 1-13 Pituitary Anterior Lobe Deficiency in Childhood and Adolescence in Boys, 15
- 1-14 Pituitary Anterior Lobe Deficiency in Adults, 16
- 1-15 Selective and Partial Hypopituitarism, 17
- 1-16 Severe Anterior Pituitary Deficiency or Panhypopituitarism, 18
- 1-17 Postpartum Pituitary Infarction (Sheehan Syndrome), 19
- 1-18 Pituitary Apoplexy, 20
- 1-19 Pituitary Gigantism, 21
- 1-20 Acromegaly, 22
- 1-21 Prolactin-Secreting Pituitary Tumor, 23
- 1-22 Corticotropin-Secreting Pituitary Tumor, 24
- 1-23 Nelson Syndrome, 25
- 1-24 Clinically Nonfunctioning Pituitary Tumor, 26
- 1-25 Secretion and Action of Oxytocin, 27
- 1-26 Secretion and Action of Vasopressin, 28
- 1-27 Central Diabetes Insipidus, 29
- 1-28 Langerhans Cell Histiocytosis in Children, 30
- 1-29 Langerhans Cell Histiocytosis in Adults, 31
- 1-30 Tumors Metastatic to the Pituitary, 32
- 1-31 Surgical Approaches to the Pituitary, 33

## SECTION 2

### THYROID

- 2-1 Anatomy of the Thyroid and Parathyroid Glands, 36
- 2-2 Anatomy of the Thyroid and Parathyroid Glands (cont'd), 37
- 2-3 Development of the Thyroid and Parathyroid Glands, 38
- 2-4 Development of the Thyroid and Parathyroid Glands (cont'd), 39
- 2-5 Congenital Anomalies of the Thyroid Gland, 40
- 2-6 Effects of Thyrotropin on the Thyroid Gland, 41
- 2-7 Physiology of Thyroid Hormones, 42
- 2-8 Graves Disease, 43
- 2-9 Graves Disease (cont'd), 44
- 2-10 Graves Ophthalmopathy, 45

- 2-11 Thyroid Pathology in Graves Disease, 46
- 2-12 Clinical Manifestations of Toxic Adenoma and Toxic Multinodular Goiter, 47
- 2-13 Pathophysiology of Toxic Adenoma and Toxic Multinodular Goiter, 48
- 2-14 Clinical Manifestations of Hypothyroidism in Adults, 49
- 2-15 Clinical Manifestations of Hypothyroidism in Adults (cont'd), 50
- 2-16 Clinical Manifestations of Hypothyroidism in Adults (cont'd), 51
- 2-17 Congenital Hypothyroidism, 52
- 2-18 Euthyroid Goiter, 53
- 2-19 Gross Pathology of Goiter, 54
- 2-20 Etiology of Nontoxic Goiter, 55
- 2-21 Chronic Lymphocytic Thyroiditis and Fibrous Thyroiditis, 56
- 2-22 Subacute Thyroiditis, 57
- 2-23 Papillary Thyroid Carcinoma, 58
- 2-24 Follicular Thyroid Carcinoma, 59
- 2-25 Medullary Thyroid Carcinoma, 60
- 2-26 Hürthle Cell Thyroid Carcinoma, 61
- 2-27 Anaplastic Thyroid Carcinoma, 62
- 2-28 Tumors Metastatic to the Thyroid, 63

## SECTION 3

### ADRENAL

- 3-1 Development of the Adrenal Glands, 67
- 3-2 Anatomy and Blood Supply of the Adrenal Glands, 68
- 3-3 Anatomy and Blood Supply of the Adrenal Glands (cont'd), 69
- 3-4 Innervation of the Adrenal Glands, 70
- 3-5 Histology of the Adrenal Glands, 71
- 3-6 Biosynthesis and Metabolism of Adrenal Cortical Hormones, 72
- 3-7 Biosynthesis and Metabolism of Adrenal Cortical Hormones (cont'd), 74
- 3-8 The Biologic Actions of Cortisol, 75
- 3-9 Cushing Syndrome—Clinical Findings, 76
- 3-10 Tests Used in the Diagnosis of Cushing Syndrome, 77
- 3-11 Cushing Syndrome: Pathophysiology, 78
- 3-12 Cushing Syndrome Caused by Primary Pigmented Nodular Adrenocortical Disease, 80
- 3-13 Major Blocks in Abnormal Steroidogenesis, 81
- 3-14 Classic Congenital Adrenal Hyperplasia, 82
- 3-15 The Biologic Actions of Adrenal Androgens, 84
- 3-16 Adult Androgenital Syndromes, 85
- 3-17 The Biologic Actions of Aldosterone, 86
- 3-18 Primary Aldosteronism, 87
- 3-19 Adrenal Venous Sampling for Primary Aldosteronism, 88
- 3-20 Renin–Angiotensin–Aldosterone System and Renovascular Hypertension, 89
- 3-21 Acute Adrenal Failure—Adrenal Crisis, 90
- 3-22 Chronic Primary Adrenal Failure—Addison Disease, 91
- 3-23 Laboratory Findings and Treatment of Primary Adrenal Insufficiency, 92
- 3-24 Laboratory Findings and Treatment of Secondary Adrenal Insufficiency, 93
- 3-25 Adrenal Medulla and Catecholamines, 94

- 3-26 Catecholamine Synthesis, Storage, Secretion, Metabolism, and Inactivation, 95
- 3-27 Pheochromocytoma and Paraganglioma, 96
- 3-28 Pheochromocytoma and Paraganglioma (cont'd), 97
- 3-29 Tumors Metastatic to the Adrenal Glands, 98

## SECTION 4

### REPRODUCTION

- 4-1 Differentiation of Gonads, 100
- 4-2 Differentiation of Genital Ducts, 101
- 4-3 Differentiation of External Genitalia, 102
- 4-4 Testosterone and Estrogen Synthesis, 103
- 4-5 Normal Puberty, 104
- 4-6 Normal Puberty (cont'd), 105
- 4-7 Normal Puberty (cont'd), 106
- 4-8 Normal Puberty (cont'd), 107
- 4-9 Precocious Puberty, 108
- 4-10 Precocious Puberty (cont'd), 109
- 4-11 Precocious Puberty (cont'd), 110
- 4-12 Disorders of Sex Development, 111
- 4-13 Disorders of Sex Development (cont'd), 112
- 4-14 Disorders of Sex Development (cont'd), 113
- 4-15 Disorders of Sex Development (cont'd), 114
- 4-16 Errors in Chromosomal Sex, 115
- 4-17 Klinefelter Syndrome, 116
- 4-18 Turner Syndrome (Gonadal Dysgenesis), 117
- 4-19 Turner Syndrome (Gonadal Dysgenesis) (cont'd), 118
- 4-20 Turner Syndrome (Gonadal Dysgenesis) (cont'd), 119
- 4-21 Hirsutism and Virilization, 120
- 4-22 Hirsutism and Virilization (cont'd), 121
- 4-23 Influence of Gonadal Hormones on the Female Reproductive Cycle from Birth to Old Age, 123
- 4-24 Functional and Pathologic Causes of Uterine Bleeding, 124
- 4-25 Gynecomastia, 125
- 4-26 Galactorrhea, 126

## SECTION 5

### PANCREAS

- 5-1 Pancreas Anatomy and Histology, 129
- 5-2 Exocrine Functions of the Pancreas, 130
- 5-3 Normal Histology of Pancreatic Islets, 131
- 5-4 Insulin Secretion, 132
- 5-5 Actions of Insulin, 133
- 5-6 Glycolysis, 134
- 5-7 Tricarboxylic Acid Cycle, 135
- 5-8 Glycogen Metabolism, 136
- 5-9 Consequences of Insulin Deprivation, 137
- 5-10 Diabetic Ketoacidosis, 138
- 5-11 Type 1 Diabetes Mellitus, 139
- 5-12 Type 2 Diabetes Mellitus, 140
- 5-13 Diabetic Retinopathy, 141
- 5-14 Complications of Proliferative Diabetic Retinopathy, 142



- 5-15 Diabetic Nephropathy, 143
- 5-16 Diabetic Neuropathy, 144
- 5-17 Atherosclerosis in Diabetes, 145
- 5-18 Vascular Insufficiency in Diabetes: The Diabetic Foot, 146
- 5-19 Diabetes Mellitus in Pregnancy, 147
- 5-20 Treatment of Type 2 Diabetes Mellitus, 148
- 5-21 Treatment of Type 1 Diabetes Mellitus, 149
- 5-22 Insulinoma, 150
- 5-23 Primary Pancreatic  $\beta$ -Cell Hyperplasia, 151

## SECTION 6

### BONE AND CALCIUM

- 6-1 Histology of the Normal Parathyroid Glands, 154
- 6-2 Physiology of the Parathyroid Glands, 155
- 6-3 Bone Remodeling Unit, 156
- 6-4 Pathophysiology of Primary Hyperparathyroidism, 157
- 6-5 Pathology and Clinical Manifestations of Primary Hyperparathyroidism, 158
- 6-6 Tests for the Differential Diagnosis of the Causes of Hypercalcemia, 159
- 6-7 Renal Osteodystrophy, 160
- 6-8 Renal Osteodystrophy: Bony Manifestations, 161
- 6-9 Histology of the Parathyroid Glands in Hyperparathyroidism, 162
- 6-10 Pathophysiology of Hypoparathyroidism, 163
- 6-11 Clinical Manifestations of Acute Hypocalcemia, 164
- 6-12 Pathophysiology of Pseudohypoparathyroidism, 165
- 6-13 Clinical Manifestations of Pseudohypoparathyroidism Type 1a, 166
- 6-14 Pathogenesis of Osteoporosis, 167
- 6-15 Osteoporosis in Postmenopausal Women, 168
- 6-16 Osteoporosis in Men, 169

- 6-17 Clinical Manifestations of Osteoporotic Vertebral Compression Fractures, 170
- 6-18 Nutritional-Deficiency Rickets and Osteomalacia, 171
- 6-19 Pseudovitamin D-Deficiency Rickets and Osteomalacia, 172
- 6-20 Hypophosphatemic Rickets, 173
- 6-21 Clinical Manifestations of Rickets in Childhood, 174
- 6-22 Clinical Manifestations of Osteomalacia in Adults, 175
- 6-23 Paget Disease of the Bone, 176
- 6-24 Pathogenesis and Treatment of Paget Disease of the Bone, 177
- 6-25 Osteogenesis Imperfecta, 178
- 6-26 Osteogenesis Imperfecta (cont'd), 179
- 6-27 Hypophosphatasia, 180

## SECTION 7

### LIPIDS AND NUTRITION

- 7-1 Cholesterol Synthesis and Metabolism, 183
- 7-2 Gastrointestinal Absorption of Cholesterol and Triglycerides, 184
- 7-3 Regulation of Low-Density Lipoprotein Receptor and Cholesterol Content, 185
- 7-4 High-Density Lipoprotein Metabolism and Reverse Cholesterol Transport, 186
- 7-5 Hypercholesterolemia, 187
- 7-6 Hypercholesterolemic Xanthomatosis, 188
- 7-7 Hypercholesterolemic Xanthomatosis (cont'd), 189
- 7-8 Abetalipoproteinemia and Tangier Disease, 190
- 7-9 Hypertriglyceridemia, 191
- 7-10 Clinical Manifestations of Hypertriglyceridemia, 192
- 7-11 Clinical Manifestations of Hypertriglyceridemia (cont'd), 193
- 7-12 Atherosclerosis, 194
- 7-13 Atherosclerosis (cont'd), 195

- 7-14 Atherosclerosis Risk Factors, 196
- 7-15 Metabolic Syndrome, 197
- 7-16 Mechanisms of Action of Lipid-Lowering Agents, 198
- 7-17 Treatment of Hyperlipidemia, 199
- 7-18 Absorption of Essential Vitamins, 200
- 7-19 Vitamin B<sub>1</sub> Deficiency: Beriberi, 201
- 7-20 Vitamin B<sub>3</sub> Deficiency: Pellagra, 202
- 7-21 Vitamin C Deficiency: Scurvy, 203
- 7-22 Vitamin A Deficiency, 204
- 7-23 Celiac Disease and Malabsorption, 205
- 7-24 Lysosomal Storage Disorders: Sphingolipidoses, 206
- 7-25 Anorexia Nervosa, 208
- 7-26 Obesity, 209
- 7-27 Surgical Treatment Options for Obesity, 210

## SECTION 8

### GENETICS AND ENDOCRINE NEOPLASIA

- 8-1 Multiple Endocrine Neoplasia Type 1, 213
- 8-2 Multiple Endocrine Neoplasia Type 2, 214
- 8-3 Multiple Endocrine Neoplasia Type 2 (cont'd), 215
- 8-4 Von Hippel-Lindau Syndrome, 216
- 8-5 Neurofibromatosis Type 1 (von Recklinghausen Disease), 217
- 8-6 Clinical Manifestations of Autoimmune Polyglandular Syndrome Type 1, 218
- 8-7 Carcinoid Syndrome, 219

### GLOSSARY OF ABBREVIATIONS, 221

### REFERENCES, 223

### INDEX, 233

# PITUITARY AND HYPOTHALAMUS



This page intentionally left blank

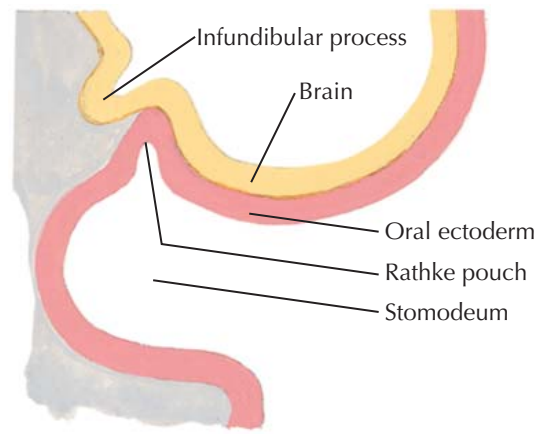
## DEVELOPMENT OF THE PITUITARY GLAND

The pituitary gland, also termed the *hypophysis*, consists of two major components, the adenohypophysis and the neurohypophysis. The adenohypophysis (anterior lobe) is derived from the oral ectoderm, and the neurohypophysis (posterior lobe) is derived from the neural ectoderm of the floor of the forebrain.

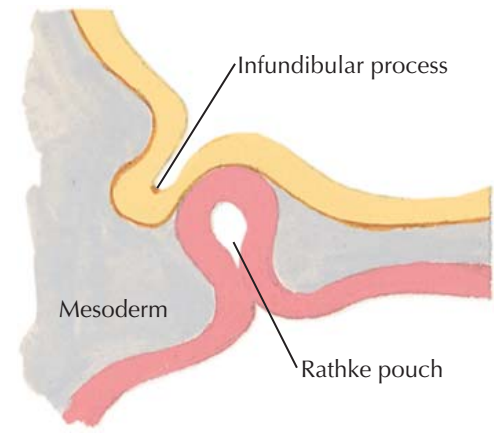
A pouchlike recess—Rathke pouch—in the ectodermal lining of the roof of the stomodeum is formed by the fourth to fifth week of gestation and gives rise to the anterior pituitary gland. Rathke pouch extends upward to contact the undersurface of the forebrain and is then constricted by the surrounding mesoderm to form a closed cavity. The original connection between Rathke pouch and the stomodeum—known as the craniopharyngeal canal—runs from the anterior part of the pituitary fossa to the undersurface of the skull. Although it is usually obliterated, a remnant may persist in adult life as a “pharyngeal pituitary” embedded in the mucosa on the dorsal wall of the pharynx. The pharyngeal pituitary may give rise to ectopic hormone-secreting pituitary adenomas later in life.

Behind Rathke pouch, a hollow neural outgrowth extends toward the mouth from the floor of the third ventricle. This neural process forms a funnel-shaped sac—the infundibular process—that becomes a solid structure, except at the upper end where the cavity persists as the infundibular recess of the third ventricle. As Rathke pouch extends toward the third ventricle, it fuses on each side of the infundibular process and subsequently obliterates its lumen, which sometimes persists as Rathke cleft. The anterior lobe of the pituitary is formed from Rathke pouch, and the infundibular process gives rise to the adjacent posterior lobe (neurohypophysis). The neurohypophysis consists of the axons and nerve endings of neurons whose cell bodies reside in the supraoptic and paraventricular nuclei of the hypothalamus, forming a hypothalamic–neurohypophysial nerve tract that contains approximately 100,000 nerve fibers. Remnants of Rathke pouch may persist at the boundary of the neurohypophysis, resulting in small colloid cysts.

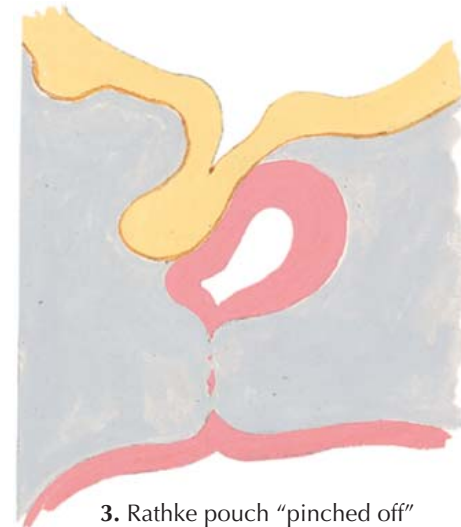The anterior lobe also gives off two processes from its ventral wall that extend along the infundibulum as the pars tuberalis, which fuses to surround the upper end of the pituitary stalk. The cleft is the remains of the original cavity of the stomodeal diverticulum. The dorsal (posterior) wall of the cleft remains thin and fuses with the adjoining posterior lobe to form the pars intermedia. The pars intermedia remains intact in some species, but in humans, its cells become interspersed



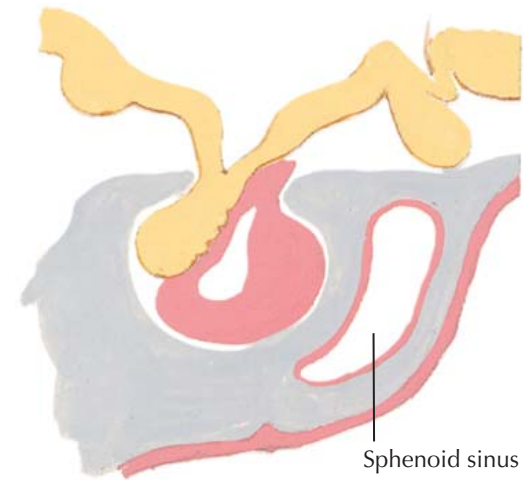
1. Beginning formation of Rathke pouch and infundibular process



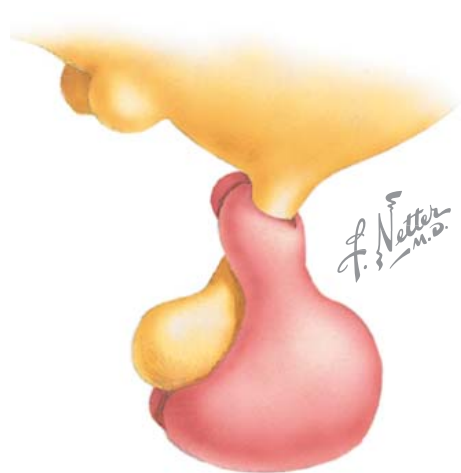
2. Neck of Rathke pouch constricted by growth of mesoderm



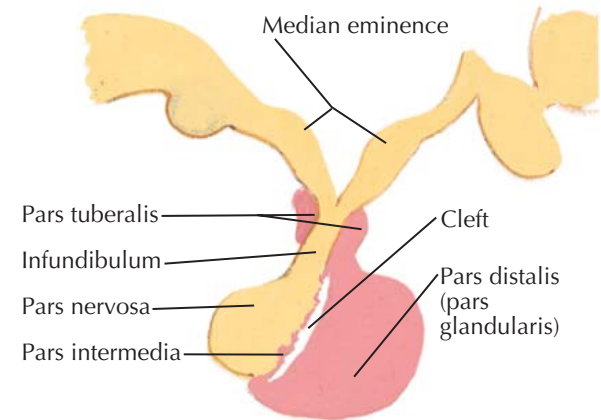
3. Rathke pouch “pinched off”



4. “Pinched off” segment conforms to neural process, forming pars distalis, pars intermedia, and pars tuberalis



5. Pars tuberalis encircles infundibular stalk (lateral surface view)



6. Mature form

with those of the anterior lobe, and it develops the capacity to synthesize and secrete pro-opiomelanocortin (POMC) and corticotropin (adrenocorticotropic hormone [ACTH]). The part of the tuber cinereum that lies immediately above the pars tuberalis is termed the *median eminence*.

Both the adenohypophysis and the neurohypophysis are subdivided into three parts. The adenohypophysis consists of the pars tuberalis, a thin strip of tissue that

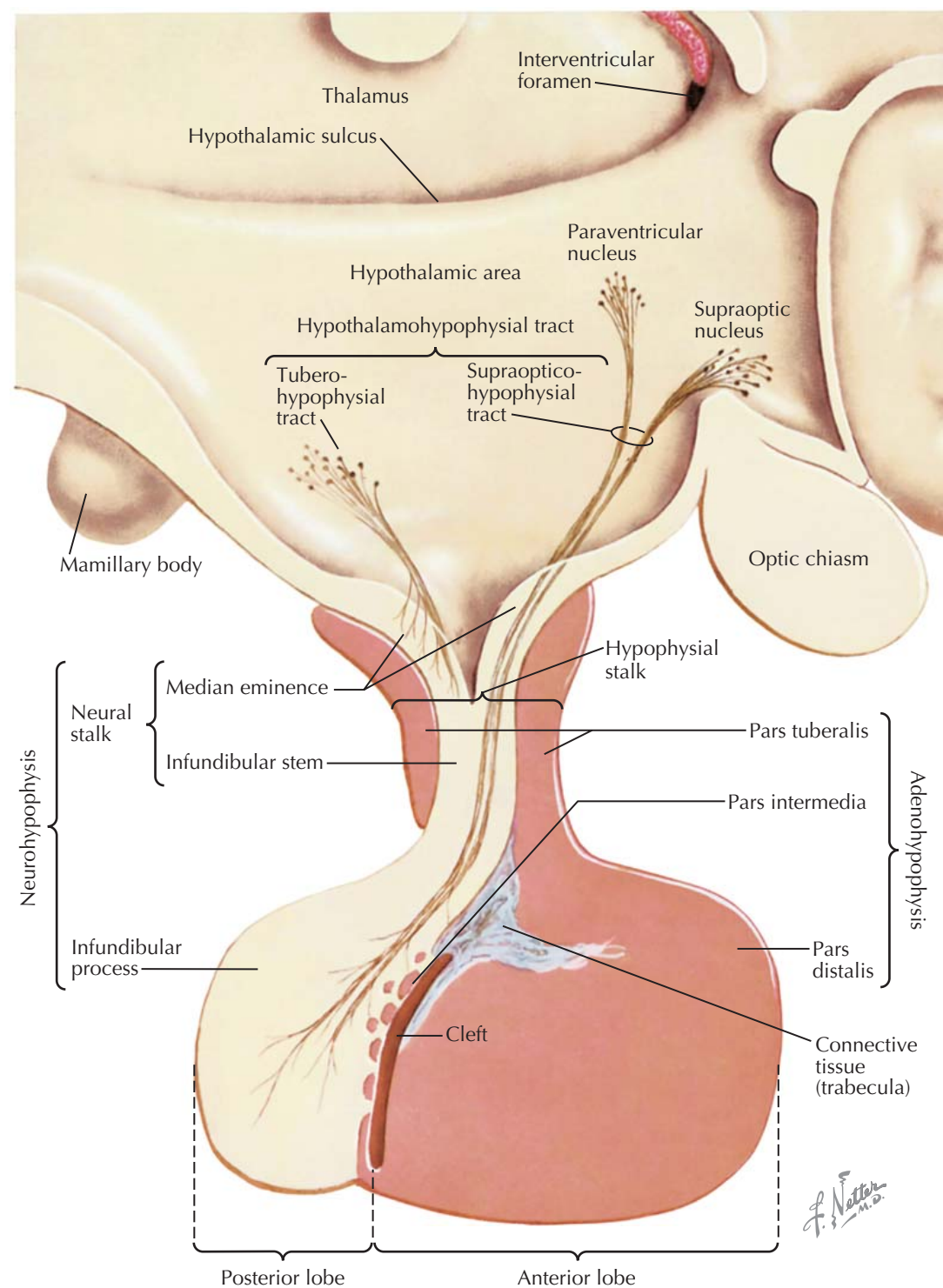
surrounds the median eminence and the upper part of the neural stalk; the pars intermedia, the portion posterior to the cleft and in contact with the neurohypophysis; and the pars distalis (pars glandularis), the major secretory part of the gland. The neurohypophysis is composed of an expanded distal portion termed the *infundibular process*; the infundibular stem (neural stalk); and the expanded upper end of the stalk, the median eminence of the tuber cinereum.



## DIVISIONS OF THE PITUITARY GLAND AND RELATIONSHIP TO THE HYPOTHALAMUS

The pituitary gland (hypophysis) is composed of the neurohypophysis (posterior pituitary lobe) and adenohypophysis (anterior pituitary lobe). The neurohypophysis consists of three parts: the median eminence of the tuber cinereum, infundibular stem, and infundibular process (neural lobe). The adenohypophysis is likewise divided into three parts: the pars tuberalis, pars intermedia, and pars distalis (glandularis). The infundibular stem, together with portions of the adenohypophysis that form a sheath around it, is designated as the hypophysial (pituitary) stalk. The extension of neurohypophysial tissue up the stalk and into the median eminence of the tuber cinereum constitutes approximately 15% of the neurohypophysis. A low stalk section may leave enough of the gland still in contact with its higher connections in the paraventricular and supraoptic nuclei to prevent the onset of diabetes insipidus. Atrophy and disappearance of cell bodies in the supraoptic and paraventricular nuclei follow damage to their axons in the supraopticohypophysial tract. If the tract is cut at the level of the diaphragma sellae, only 70% of these cells are affected; if the tract is severed above the median eminence, about 85% of the cells will atrophy. Thus, approximately 15% of the axons terminate between these levels.

The main nerve supply, both functionally and anatomically, of the neurohypophysis is the hypothalamohypophysial tract in the pituitary stalk. It consists of two main parts: the supraopticohypophysial tract, running in the anterior or ventral wall of the stalk, and the tuberohypophysial tract in the posterior, or dorsal, wall of the stalk. The tuberohypophysial tract originates in the central and posterior parts of the hypothalamus from the paraventricular nucleus and from scattered cells and nuclei in the tuberal region and mamillary bodies. The supraopticohypophysial tract arises from the supraoptic and paraventricular nuclei. On entering the median eminence, it occupies a very superficial position, where it is liable to be affected by basal infections of the brain and granulomatous inflammatory processes. The tuberohypophysial tract in the dorsal region of the median eminence is smaller and consists of finer fibers. In the neural stalk, all the fibers congregate into a dense bundle lying in a central position,



leaving a peripheral zone in contact with the pars tuberalis, which is relatively free of nerve elements. The hypothalamohypophysial tract terminates mainly in the neurohypophysis.

The hypothalamus has ill-defined boundaries. Anteriorly, it is limited by the optic chiasm and optic tracts; passing posteriorly, it is bounded by the posterior perforated substance and the cerebral peduncles. On sagittal section, it can be seen to be separated from the thalamus by the hypothalamic sulcus on the wall of the third ventricle. Anteriorly, it merges with the pre-optic septal region, and posteriorly, it merges with the tegmental area of the midbrain. Its lateral relations are the subthalamus and the internal capsule.

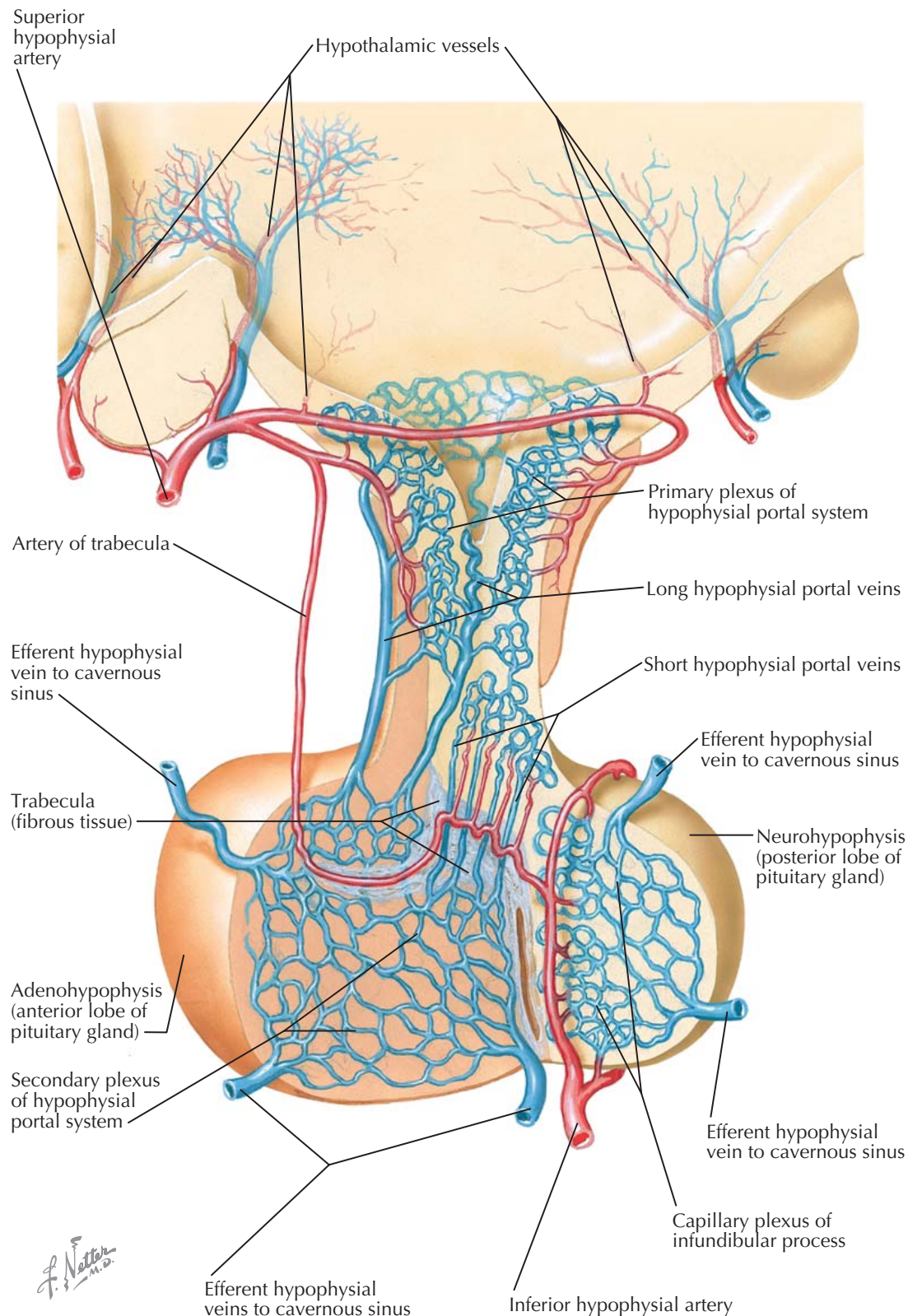
A connective tissue trabecula separates the posterior and anterior lobes of the pituitary; it also extends out into the anterior pituitary lobe for a variable distance as a vascular bed for the large-lumened artery of the trabecula. The embryonic cleft, which marks the site of the Rathke pouch within the gland, may be contained, in part, in this trabecula. It is easier to see in newborns and tends to disappear in later life. Colloid-filled follicles in the adult gland mark the site of the pars intermedia at the junction between the pars distalis and the neurohypophysis. This boundary may be quite irregular because fingerlike projections of adenohypophysial tissue are frequently found in the substance of the neurohypophysis.

### BLOOD SUPPLY OF THE PITUITARY GLAND

The pituitary gland receives its arterial blood supply from two paired systems of vessels: from above come the right and left superior hypophysial arteries, and from below arise the right and left inferior hypophysial arteries. Each superior hypophysial artery divides into two main branches—the anterior and posterior hypophysial arteries passing to the hypophysial stalk. Communicating branches between these anterior and posterior superior hypophysial arteries run on the lateral aspects of the hypophysial stalk; numerous branches arise from this arterial circle. Some pass upward to supply the optic chiasm and the hypothalamus. Other branches, called *infundibular arteries*, pass either superiorly to penetrate the stalk in its upper part or inferiorly to enter the stalk at a lower level. Another important branch of the anterior superior hypophysial artery on each side is the artery of the trabecula, which passes downward to enter the pars distalis. The trabecula is a prominent, compact band of connective tissue and blood vessels lying within the pars distalis on either side of the midline. At its central end the trabecula is contiguous with the mass of connective tissue, which is interposed between the pars distalis and the lower infundibular stem. Peripherally, the components of the trabecula spread out to form a fibrovascular tuft. On approaching the lower infundibular stem, the artery of the trabecula gives off numerous straight parallel vessels to the superior portion of this area and thus constitutes the “superior artery of the lower infundibular stem.” The “inferior artery of the lower infundibular stem” is derived from the inferior hypophysial arterial system. The artery of the trabecula is of large caliber throughout its course; it gives off no branches to the epithelial tissue through which it passes. It is markedly tortuous and is always surrounded by connective tissue.

The inferior hypophysial arteries arise as a single branch from each internal carotid artery in its intracavernous segment. Near the junction of the anterior and posterior lobes of the pituitary, the artery gives off one or more tortuous vessels to the dural covering of the pars distalis and finally divides into two main branches—a medial and a lateral inferior hypophysial artery. The infundibular process is surrounded by an arterial ring formed by the medial and lateral branches of the paired inferior hypophysial arteries. From this arterial ring, branches are given off to the posterior lobe and to the lower infundibular stem. Components of the superior and inferior hypophysial arterial systems anastomose freely.

The epithelial tissue of the pars distalis receives no direct arterial blood. The sinusoids of the anterior lobe receive their blood supply from the hypophysial portal vessels, which arise from the capillary beds within the median eminence and the upper and lower portions of the infundibular stem. Blood is conveyed from this primary capillary network through hypophysial portal veins to the epithelial tissue of the anterior lobe. Here, a secondary plexus of the pituitary portal system is formed, leading to the venous dural sinuses, which surround the pituitary, and to the general circulation. Some of the long hypophysial portal veins run along the surface of the stalk, chiefly on its anterior and lateral aspects. Most of the long hypophysial portal vessels leave the neural tissue to run down within the pars tuberalis, but a few remain deep within the stalk until they reach the pars distalis. The short hypophysial



portal veins are embedded in the tissue surrounding the lower infundibular stem. They supply the sinusoidal bed of the posterior part of the pars distalis, and the long portal veins supply its anterior and lateral regions. Vascular tufts, comprising the primary capillary network in the median eminence and infundibular stem, are intimately related to the great mass of nerve fibers of the hypothalamo-hypophysial tract running in this region. On excitation, these nerve fibers liberate into the portal vessels, releasing hormones (e.g., growth

hormone-releasing hormone, corticotropin-releasing hormone, gonadotropin-releasing hormone, thyrotropin-releasing hormone) and inhibitory factors (e.g., somatostatin, prolactin-inhibitory factor [dopamine]), which are conveyed to the sinusoids of the pars distalis. Extensive occlusion of the hypophysial portal vessels or of the capillary beds of the hypophysial stalk may lead to ischemic necrosis of the anterior pituitary because these hypophysial portal vessels are the only afferent channels to the sinusoids of the pars distalis.

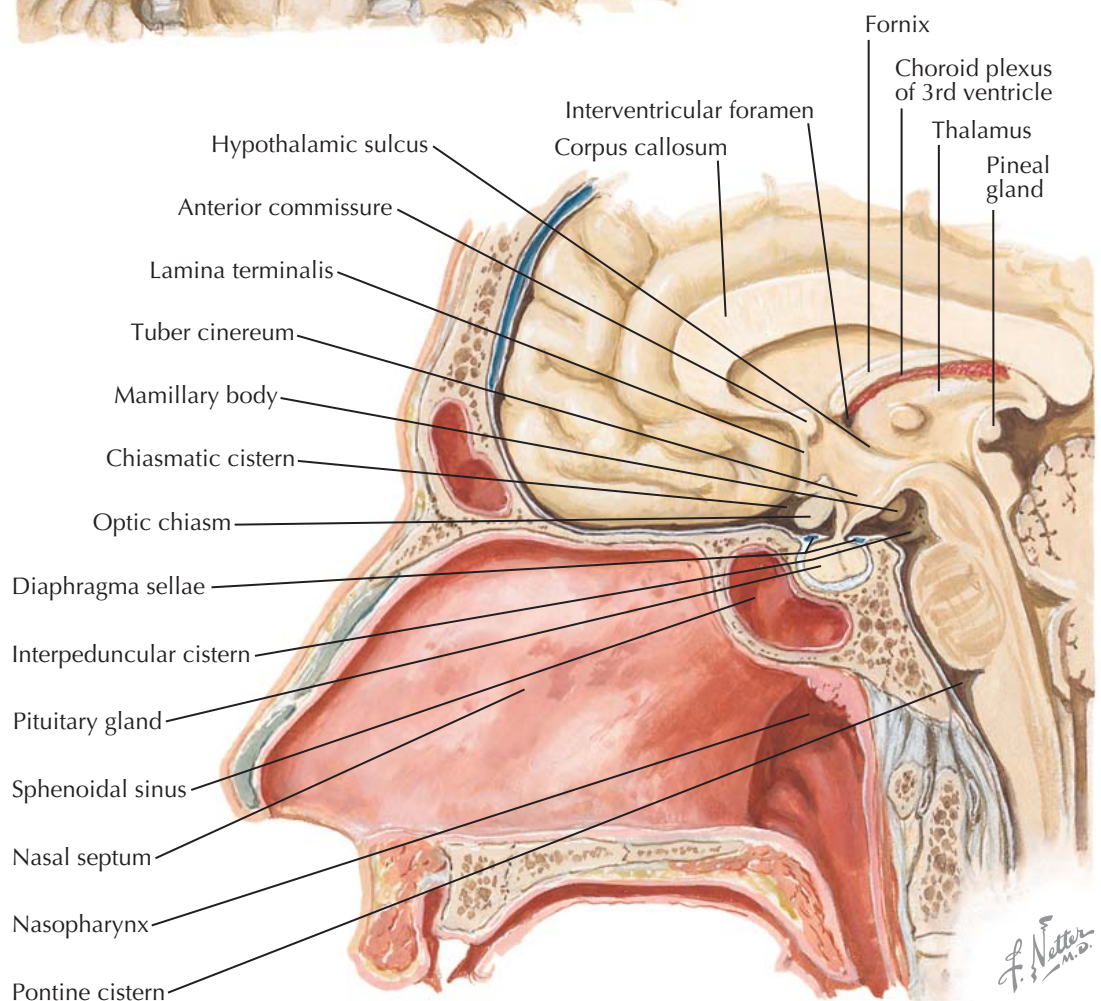
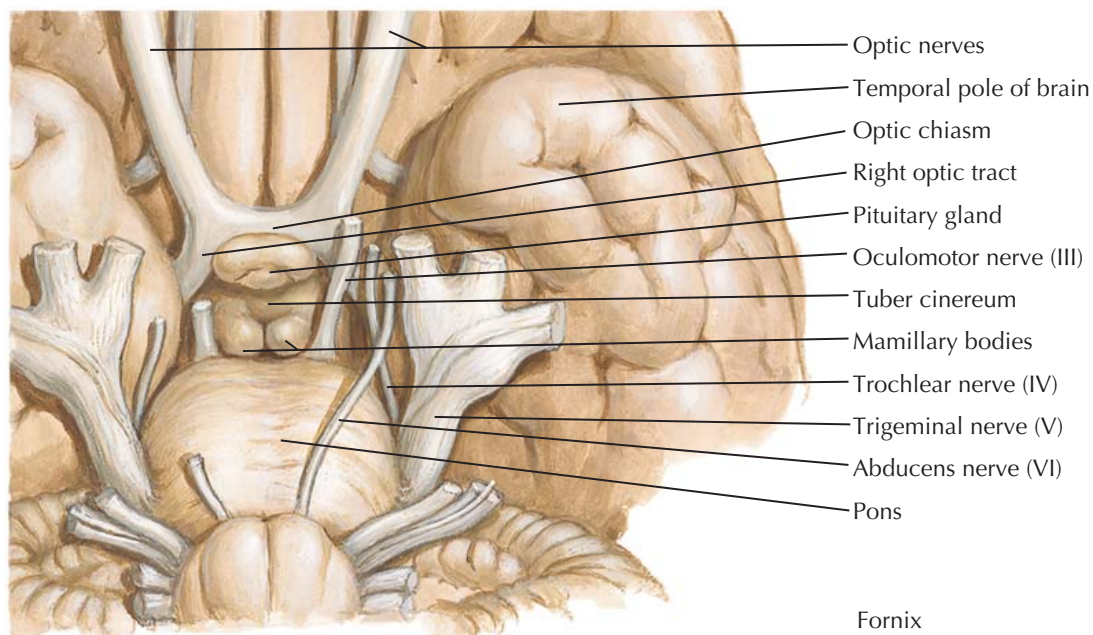


## ANATOMY AND RELATIONSHIPS OF THE PITUITARY GLAND

The pituitary gland is reddish-gray and ovoid, measuring about 12 mm transversely, 8 mm in its anterior-posterior diameter, and 6 mm in its vertical dimension. It weighs approximately 500 mg in men and 600 mg in women. It is contiguous with the end of the infundibulum and is situated in the hypophysial fossa of the sphenoid bone. A circular fold of dura mater, the diaphragma sellae, forms the roof of this fossa. In turn, the floor of the hypophysial fossa forms part of the roof of the sphenoid sinus. The diaphragma sellae is pierced by a small central aperture through which the pituitary stalk passes, and it separates the anterior part of the upper surface of the gland from the optic chiasm. The hypophysis is bound on each side by the cavernous sinuses and the structures that they contain. Inferiorly, it is separated from the floor of the fossa by a large, partially vacuolated venous sinus, which communicates freely with the circular sinus. The meninges blend with the capsule of the gland and cannot be identified as separate layers of the fossa. However, the subarachnoid space often extends a variable distance into the sella, particularly anteriorly, and may be referred to as a "partially empty sella" when seen on magnetic resonance imaging (MRI) (see Plate 1-12). In some cases of subarachnoid hemorrhage, the dorsal third of the gland may be covered with blood that has extended down into this space.

The hypothalamus is an important relation of the pituitary gland, both anatomically and functionally. This designation refers to the structures contained in the anterior part of the floor of the third ventricle and to those comprising the lateral wall of the third ventricle below and in front of the hypothalamic sulcus. The mammillary bodies are two round, white, pea-sized masses located side by side below the gray matter of the floor of the third ventricle in front of the posterior perforated substance. They form the posterior limits of the hypothalamus. At certain sites at the base of the brain, the arachnoid is separated from the pia mater by wide intervals that communicate freely with one another; these are called *subarachnoid cisterns*. As the arachnoid extends across between the two temporal lobes, it is separated from the cerebral peduncles by the interpeduncular cistern. Anteriorly, this space is continued in front of the optic chiasm as the chiasmatic cistern. Space-occupying lesions distort these cisterns.

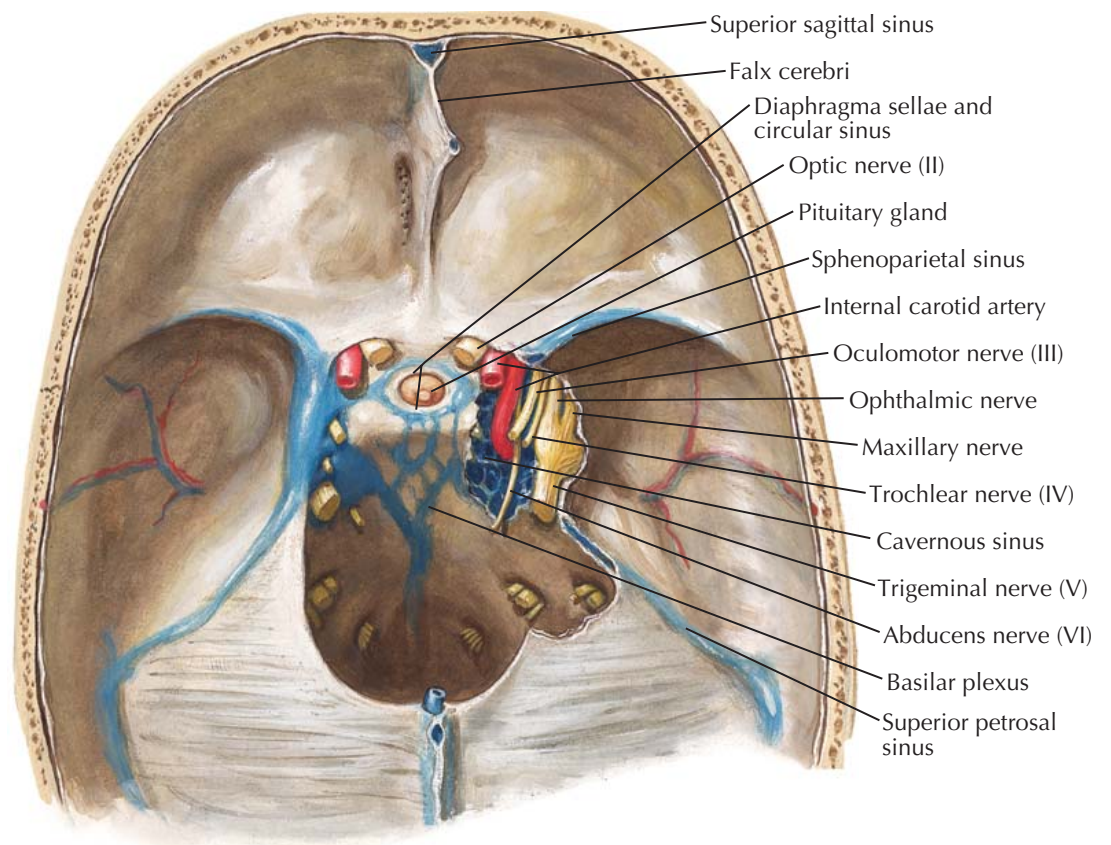
The optic chiasm is an extremely important superior relation of the pituitary gland. It is a flat, somewhat quadrilateral bundle of optic nerve fibers situated at the junction of the anterior wall of the third ventricle with its floor. Its anterolateral angles are contiguous with the



optic nerves, and its posterolateral angles are contiguous with the optic tracts. The lamina terminalis, which represents the cephalic end of the primitive neural tube, forms a thin layer of gray matter stretching from the upper surface of the chiasm to the rostrum of the corpus callosum. Inferiorly, the chiasm rests on the diaphragma sellae just behind the optic groove of the sphenoid bone. A small recess of the third ventricle, called the *optic recess*, passes downward and forward over its upper

surface as far as the lamina terminalis. A more distant relationship is the pineal gland, which is a small, conical, reddish-gray body lying below the splenium of the corpus callosum. Rarely, ectopic pineal tissue occurs in the floor of the third ventricle and gives rise to tumors of that region. Compression of neighboring cranial nerves, other than the optic nerves, may occur if there is extensive cavernous sinus extension from a pituitary neoplasm (see Plate 1-24).

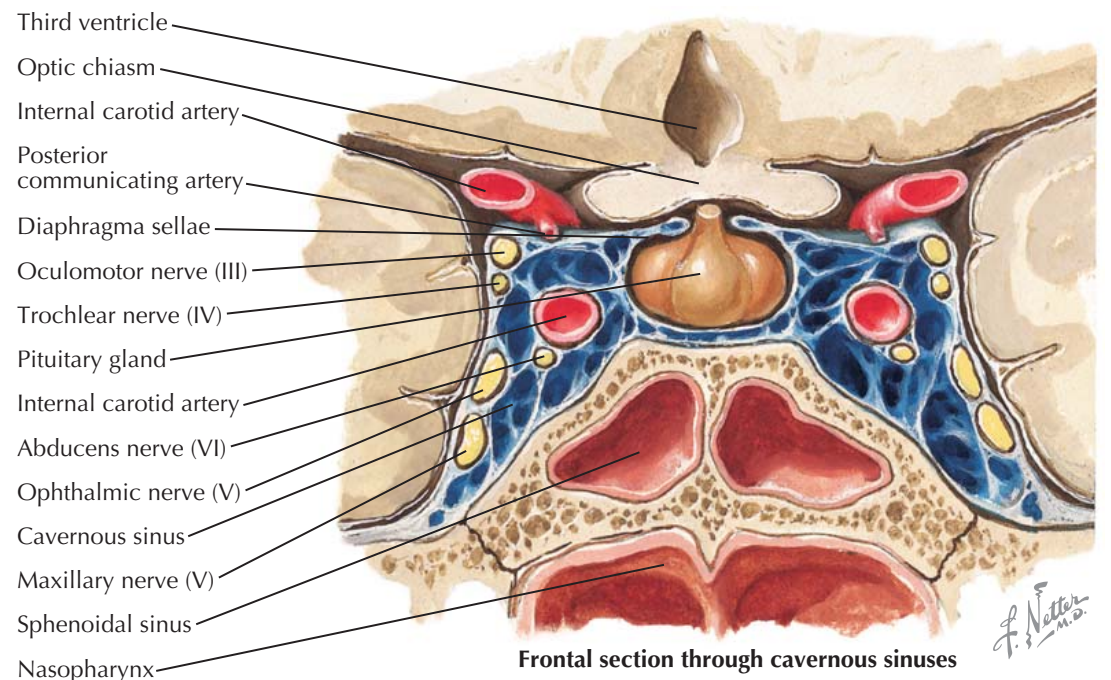




**RELATIONSHIP OF THE PITUITARY GLAND TO THE CAVERNOUS SINUS**

The sinuses of the dura mater are venous channels that drain the blood from the brain. The cavernous sinuses are so named because of their reticulated structure, being traversed by numerous interlacing filaments that radiate out from the internal carotid artery extending anteroposteriorly in the center of the sinuses. They are located astride and on either side of the body of the sphenoid bone and adjacent to the pituitary gland. Each opens behind into the superior and inferior petrosal sinuses (see Plate 3-10). On the medial wall of each cavernous sinus, the internal carotid artery is in close contact with the abducens nerve (VI). On the lateral wall are the oculomotor (III) and trochlear (IV) nerves and the ophthalmic and maxillary divisions of the trigeminal nerve (V). These structures are separated from the blood flowing along the sinus by the endothelial lining membrane. The two cavernous sinuses communicate with each other by means of two intercavernous sinuses. The anterior sinus passes in front of the pituitary gland and the posterior behind it. Together they form a circular sinus around the hypophysis. These channels are found between the two layers of dura mater that comprise the diaphragma sellae and are responsible for copious bleeding when this structure is incised when a transcranial surgical approach to the pituitary gland is used. Sometimes profuse bleeding from an inferior circular sinus is encountered in the transsphenoidal approach to the pituitary gland (see Plate 1-31).

The superior petrosal sinus is a small, narrow channel that connects the cavernous sinus with the transverse sinus. It runs backward and laterally from the posterior end of the cavernous sinus over the trigeminal nerve (V) and lies in the attached margin of the tentorium cerebelli and in the superior petrosal sulcus of the temporal bone. The cavernous sinus also receives the small sphenoparietal sinus, which runs anteriorly along the undersurface of the lesser wing of the sphenoid.



The intercavernous portion of the internal carotid artery runs a complicated course. At first, it ascends toward the posterior clinoid process; then it passes forward alongside the body of the sphenoid bone and again curves upward on the medial side of the anterior clinoid process. It perforates the dura mater that forms the roof of the sinus. This portion of the artery is surrounded by filaments of sympathetic nerves as it passes between the optic and oculomotor nerves. The

hypophysial arteries are branches of the intercavernous segment of the internal carotid artery. The inferior branch supplies the posterior lobe of the pituitary gland, and the superior branch leads into the median eminence to start the hypophysial portal system to the anterior lobe.

The surgical approaches to the pituitary gland are designed to circumvent the major vascular channels and to avoid injury to the optic nerves and to the optic chiasm (see Plate 1-31).



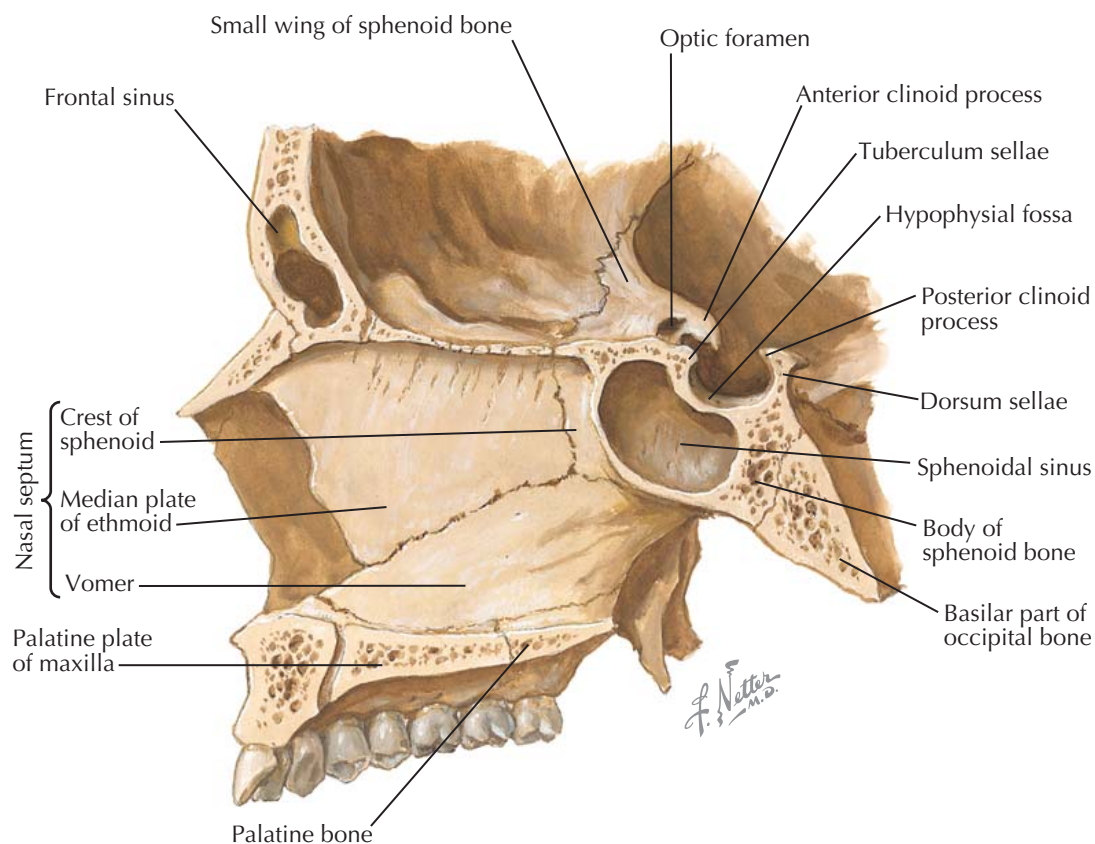
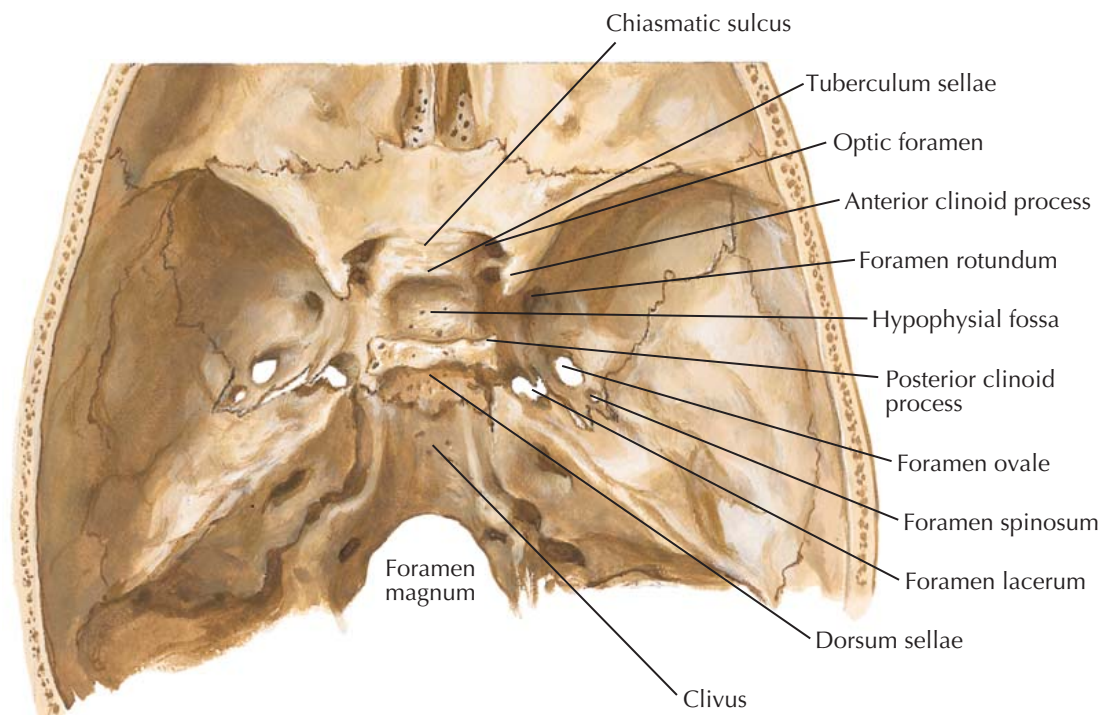
## RELATIONSHIPS OF THE SELLA TURCICA

The sella turcica—where the pituitary gland is located—is the deep depression in the body of the sphenoid bone. In adults, the normal mean anterior-posterior length is less than 14 mm, and the height from the floor to a line between the tuberculum sellae and the tip of the posterior clinoid is less than 12 mm.

To understand its relations, a more general description of the sphenoid bone is needed. Situated at the base of the skull in front of the temporal bones and the basilar part of the occipital bone, the sphenoid bone somewhat resembles a bat with its wings extended. It is divided into a median portion, or body, two great and two small wings extending outward from the sides of the body, and two pterygoid processes projecting below. The cubical body is hollowed out to form two large cavities, the sphenoidal air sinuses, which are separated from each other by a septum that is often oblique. The superior surface of the body articulates anteriorly with the cribriform plate of the ethmoid and laterally with the frontal bones. Most of the frontal articulation is with the small wing of the sphenoid bone. Behind the ethmoidal articulation is a smooth surface, slightly raised in the midline and grooved on either side, for the olfactory lobes of the brain. This surface is bound behind by a ridge, which forms the anterior border of a narrow transverse groove, the chiasmatic sulcus, above and behind which lies the optic chiasm. The groove ends on either side in the optic foramen, through which the optic nerve and ophthalmic artery enter into the orbital cavity.

Behind the chiasmatic sulcus is an elevation, the tuberculum sellae. Immediately posterior there is a deep depression, the sella turcica, the deepest part of which is called the hypophysial fossa. The anterior boundary of the sella turcica is completed by two small prominences, one on each side, called the middle clinoid processes. The posterior boundary of the sella is formed by an elongated plate of bone, the dorsum sellae, which ends at its superior angles as two tubercles, the posterior clinoid processes.

Behind the dorsum sellae is a shallow depression, the clivus, which slopes obliquely backward to continue as a groove on the basilar portion of the occipital bone. The lateral surfaces of the sphenoid body are united with the great wings and the medial pterygoid plates. Above the attachment of each great wing is a broad



groove that contains the internal carotid artery and the cavernous sinus. The superior surface of each great wing forms part of the middle fossa of the skull. The internal carotid artery passes through the foramen lacerum, a large, somewhat triangular aperture bound in the front by the great wing of the sphenoid, behind by the apex of the petrous portion of the temporal bone, and medially by the body of the sphenoid and the basilar portion of the occipital bone. The nasal relations

of the pituitary fossa are the crest of the sphenoid bone and the median, or perpendicular, plate of the ethmoid.

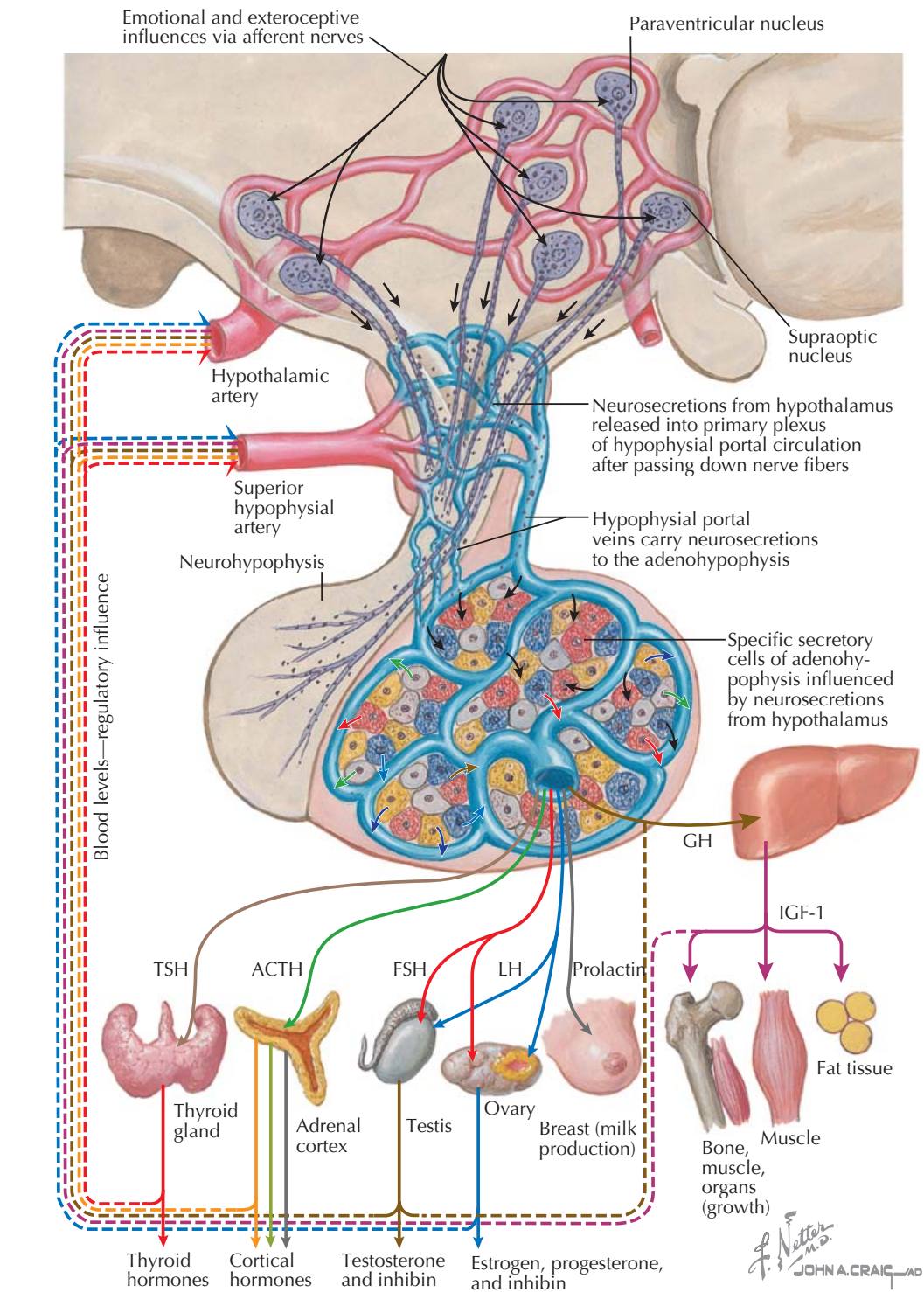
Since the introduction of the operating microscope in 1969 by Jules Hardy, the sublabial transseptal trans-sphenoidal approach to the pituitary has been the standard in the treatment of pituitary adenomas. However, improved endoscopes have led to development of endoscopic transnasal applications in many pituitary surgical centers (see Plate 1-31).

## ANTERIOR PITUITARY HORMONES AND FEEDBACK CONTROL

The quantitative and temporal secretion of the pituitary trophic hormones is tightly regulated and controlled at three levels: (1) Adenohypophysiotropic hormones from the hypothalamus are secreted into the portal system and act on pituitary G-protein-linked cell surface membrane binding sites, resulting in either positive or negative signals mediating pituitary hormone gene transcription and secretion. (2) Circulating hormones from the target glands provide negative feedback regulation of their trophic hormones. (3) Intrapituitary autocrine and paracrine cytokines and growth factors act locally to regulate cell development and function. The hypothalamic-releasing hormones include growth hormone-releasing hormone (GHRH), corticotropin-releasing hormone (CRH), thyrotropin-releasing hormone (TRH), and gonadotropin-releasing hormone (GnRH). The two hypothalamic inhibitory regulatory factors are somatostatin and dopamine, which suppress the secretion of growth hormone (GH) and prolactin, respectively. The six anterior pituitary trophic hormones—corticotropin (adrenocorticotropic hormone [ACTH]), GH, thyrotropin (thyroid-stimulating hormone [TSH]), follicle-stimulating hormone (FSH), luteinizing hormone (LH), and prolactin—are secreted in a pulsatile fashion into the cavernous sinuses and circulate systemically.

Hypothalamic-pituitary-target gland hormonal systems function in a feedback loop, where the target gland blood hormone concentration—or a biochemical surrogate—determines the rate of secretion of the hypothalamic factor and pituitary trophic hormone. The feedback system may be “negative,” in which the target gland hormone inhibits the hypothalamic-pituitary unit, or “positive,” in which the target gland hormone or surrogate increases the hypothalamic-pituitary unit secretion. These two feedback control systems may be closed loop (regulation is restricted to the interacting trophic and target gland hormones) or open loop (the nervous system or other factors influence the feedback loop). All hypothalamic-pituitary-target gland feedback loops are in part open loop—they have some degree of nervous system (emotional and exteroceptive influences) inputs that either alter the setpoint of the feedback control system or can override the closed-loop controls. Feedback inhibition to the hypothalamus and pituitary is also provided by other target gland factors. For example, inhibin, a heterodimeric glycoprotein product of the Sertoli cell of the testes and the ovarian granulosa cell, provides negative feedback on the secretion of FSH from the pituitary. Synthesis and secretion of gonadal inhibin is induced by FSH.

Blood levels of trophic and target gland hormones are also affected by endogenous secretory rhythms. Most hormonal axes have an endogenous secretory rhythm of 24 hours—termed *circadian* or *diurnal rhythms*—and are regulated by retinal inputs and hypothalamic nuclei. The retinohypothalamic tract affects the circadian pulse generators in the hypothalamic suprachiasmatic nuclei. Rhythms that occur more frequently than once a day are termed *ultradian rhythms*, and those that have a period longer than a day are termed *infradian rhythms* (e.g., menstrual cycle). Examples of circadian rhythms of pituitary and target gland hormones include the following: GH and prolactin secretion is highest shortly after the onset of sleep;

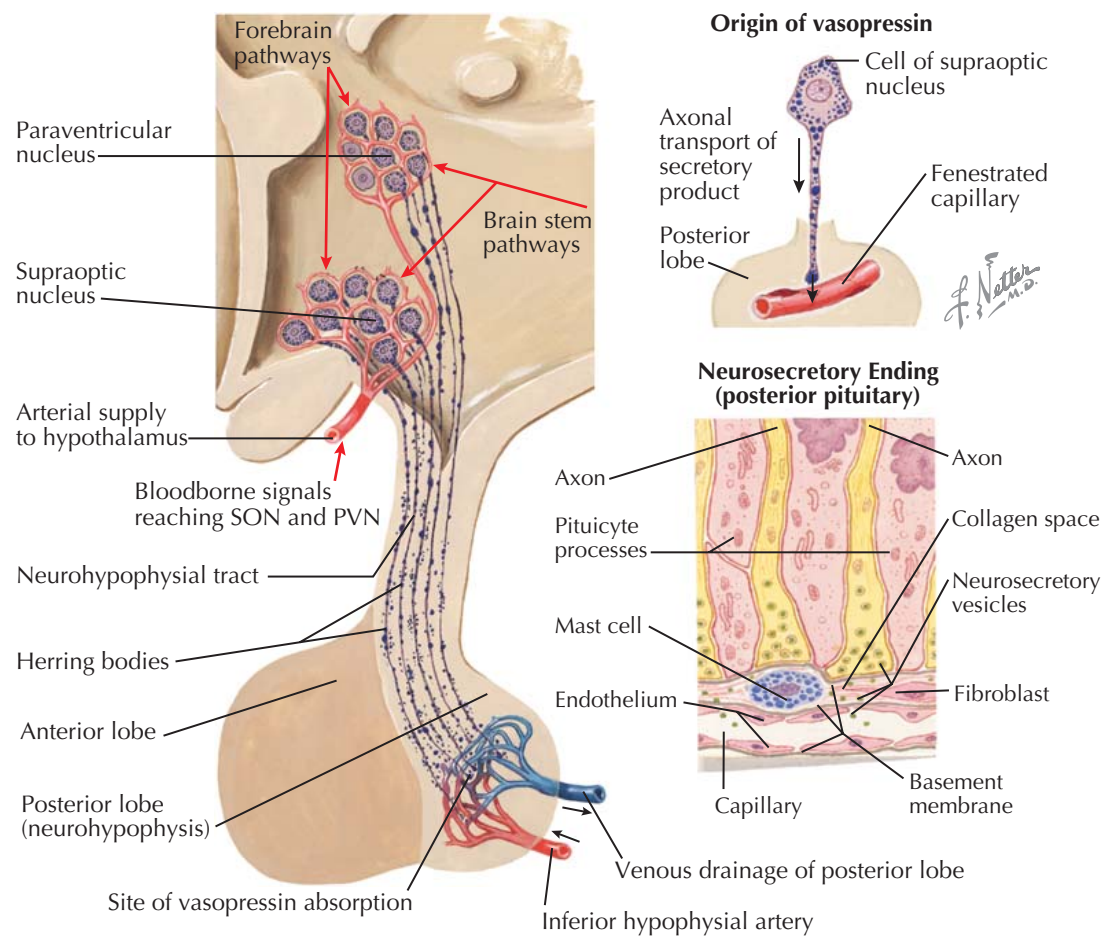


cortisol secretion is lowest at 11 PM and highest between 2 and 6 AM; and testosterone secretion is highest in the morning. In addition, GH, ACTH, and prolactin are also secreted in brief regular pulses, reflecting the pulsatile release of their respective hypothalamic releasing factors.

The circadian and pulsatile secretion of pituitary and target gland hormones must be considered when assessing endocrine function. For example, because of pulsatile secretion, a single blood GH measurement is not a good assessment of either hyperfunction or hypofunction of pituitary somatotropes; the serum concentration of the GH-dependent peptide insulinlike growth factor 1 (IGF-1)—because of its much longer serum

half-life—provides a better assessment of GH secretory status. Circulating hormone concentrations are a function of circadian rhythms and hormone clearance rates; laboratories standardize the reference ranges for hormones based on the time of day. For example, the reference range for cortisol changes depending on whether it is measured in the morning or afternoon. Normal serum testosterone concentrations are standardized based on samples obtained from morning venipuncture. Disrupted circadian rhythms should clue the clinician to possible endocrine dysfunction—thus, the loss of circadian ACTH secretion with high midnight concentrations of cortisol in the blood and saliva is consistent with ACTH-dependent Cushing syndrome.

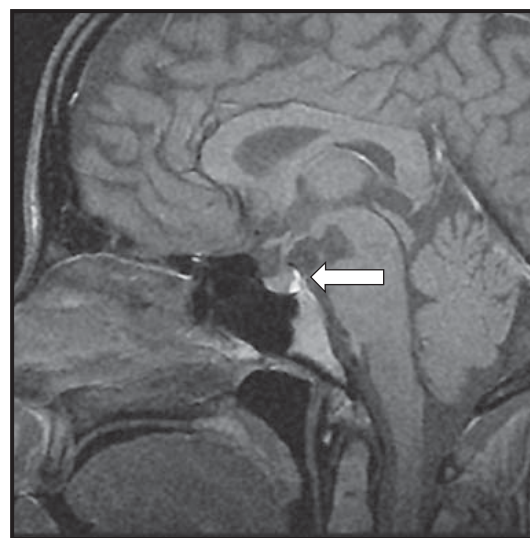




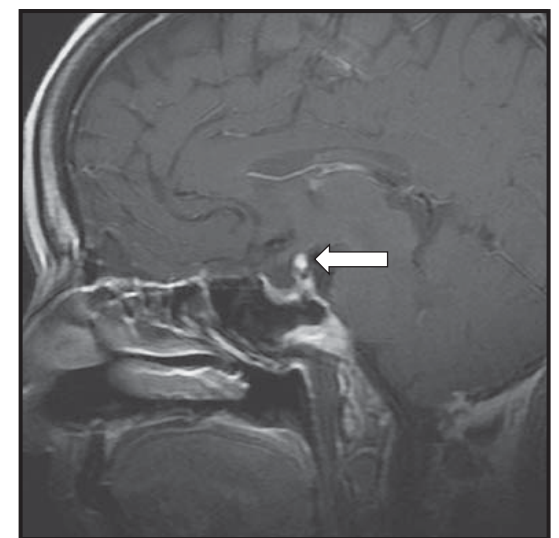
## POSTERIOR PITUITARY GLAND

The posterior pituitary is neural tissue and is formed by the distal axons of the supraoptic nucleus (SON) and the paraventricular nucleus (PVN) of the hypothalamus. The axon terminals store neurosecretory granules that contain vasopressin and oxytocin—both are non-peptides consisting of a six-amino acid ring with a cysteine-to-cysteine bridge and a three-amino acid tail. In embryogenesis, neuroepithelial cells of the lining of the third ventricle migrate laterally to and above the optic chiasm to form the SON and to the walls of the third ventricle to form the PVN. The blood supply for the posterior pituitary is from the inferior hypophysial arteries, and the venous drainage is into the cavernous sinus and internal jugular vein.

The posterior pituitary serves to store and release vasopressin and oxytocin. The posterior pituitary stores enough vasopressin to sustain basal release for approximately 30 days and to sustain maximum release for approximately 5 days. Whereas approximately 90% of the SON neurons produce vasopressin, and all its axons end in the posterior pituitary, the PVN has five subnuclei that synthesize other peptides in addition to vasopressin (e.g., somatostatin, corticotropin-releasing hormone, thyrotropin-releasing hormone, and opioids). The neurons of the PVN subnuclei project to the median eminence, brainstem, and spinal cord. The major stimulatory input for vasopressin and oxytocin secretion is glutamate, and the major inhibitory input is  $\gamma$ -aminobutyric acid (GABA). When a stimulus for secretion of vasopressin or oxytocin acts on the SON or PVN, an action potential is generated that propagates down the long axon to the posterior pituitary. The action potential triggers an influx of calcium that causes the neurosecretory granules to fuse with the cell membrane and release the contents of the neurosecretory



Posterior pituitary bright spot. Sagittal T1-MRI image showing hyperintensity (arrow) in the posterior aspect of the sella turcica.



Ectopic posterior pituitary. Sagittal T1-MRI image showing hyperintensity (arrow) along the posterior aspect of the pituitary infundibulum.

granule into the perivascular space and subsequently into the fenestrated capillary system of the posterior pituitary.

The stored vasopressin in neurosecretory granules in the posterior pituitary produces a bright signal on T1-weighted magnetic resonance imaging (MRI)—the “posterior pituitary bright spot.” The posterior pituitary bright spot is present in most healthy individuals and is absent in individuals with central diabetes

insipidus. In addition, this bright spot may be located elsewhere in individuals with congenital abnormalities such that the posterior pituitary is undescended—it may appear at the base of the hypothalamus or along the pituitary stalk. Although posterior pituitary function is usually intact, this “ectopic posterior pituitary” may be associated with a hypoplastic anterior pituitary gland and with varying degrees of anterior pituitary dysfunction.

### MANIFESTATIONS OF SUPRASSELLAR DISEASE

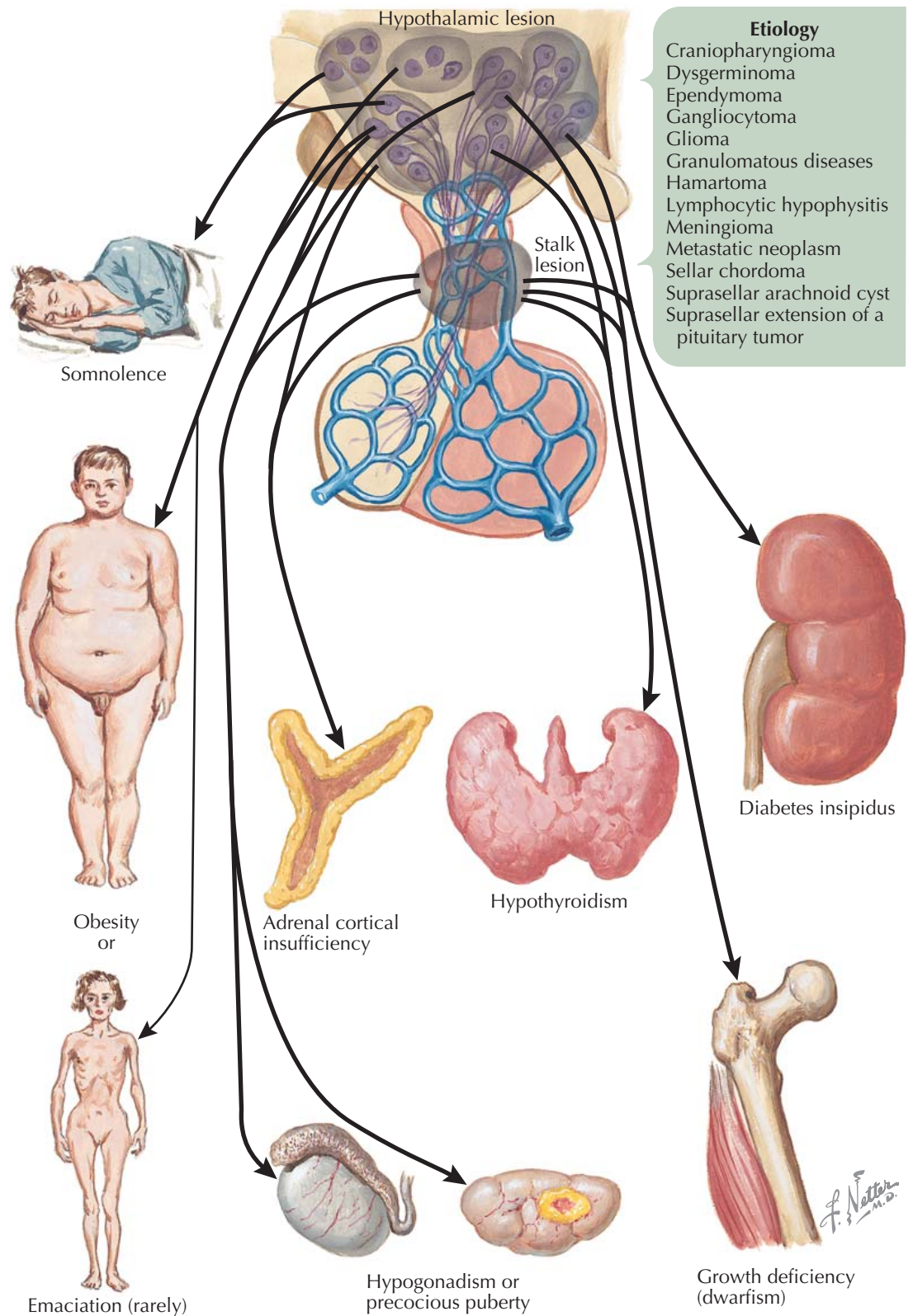
Suprasellar lesions that may lead to hypothalamic dysfunction include craniopharyngioma, dysgerminoma, granulomatous diseases (e.g., sarcoidosis, tuberculosis, Langerhans cell histiocytosis), lymphocytic hypophysitis, metastatic neoplasm, suprasellar extension of a pituitary tumor, glioma (e.g., hypothalamic, third ventricle, optic nerve), sellar chordoma, meningioma, hamartoma, gangliocytoma, suprasellar arachnoid cyst, and ependymoma.

Endocrine and nonendocrine sequelae are related to hypothalamic mass lesions. Because of the proximity to the optic chiasm, hypothalamic lesions are frequently associated with vision loss. An enlarging hypothalamic mass may also cause headaches and recurrent emesis. The hypothalamus is responsible for many homeostatic functions such as appetite control, the sleep-wake cycle, water metabolism, temperature regulation, anterior pituitary function, circadian rhythms, and inputs to the parasympathetic and sympathetic nervous systems. The clinical presentation is more dependent on the location within the hypothalamus than on the pathologic process. Mass lesions may affect only one or all of the four regions of the hypothalamus (from anterior to posterior: preoptic, supraoptic, tuberal, and mammary regions) or one or all of the three zones (from midline to lateral: periventricular, medial, and lateral zones). For example, hypersomnolence is a symptom associated with damage to the posterior hypothalamus (mammary region) where the rostral portion of the ascending reticular activating system is located. Patients with lesions in the anterior (preoptic) hypothalamus may present with hyperactivity and insomnia, alterations in the sleep-wake cycle (e.g., nighttime hyperactivity and daytime sleepiness), or dysthermia (acute hyperthermia or chronic hypothermia).

The appetite center is located in the ventromedial hypothalamus, and the satiety center is localized to the medial hypothalamus. Destructive lesions involving the more centrally located satiety center lead to hyperphagia and obesity, a relatively common presentation for patients with a hypothalamic mass. Destructive lesions of both of the more laterally located feeding centers may lead to hypophagia, weight loss, and cachexia.

Destruction of the vasopressin-producing magnocellular neurons in the supraoptic and paraventricular nuclei in the tuberal region of the hypothalamus results in central diabetes insipidus (DI) (see Plate 1-27). In addition, DI may be caused by lesions (e.g., high pituitary stalk lesions) that interrupt the transport of vasopressin through the magnocellular axons that terminate in the pituitary stalk and posterior pituitary. Polydipsia and hypodipsia are associated with damage to central osmoreceptors located in anterior medial and anterior lateral preoptic regions. The impaired thirst mechanism results in dehydration and hypernatremia.

Anterior pituitary function control emanates primarily from the arcuate nucleus in the tuberal region of the hypothalamus. Thus, lesions that involve the floor of the third ventricle and median eminence frequently result in varying degrees of anterior pituitary dysfunction (e.g., secondary hypothyroidism, secondary adrenal



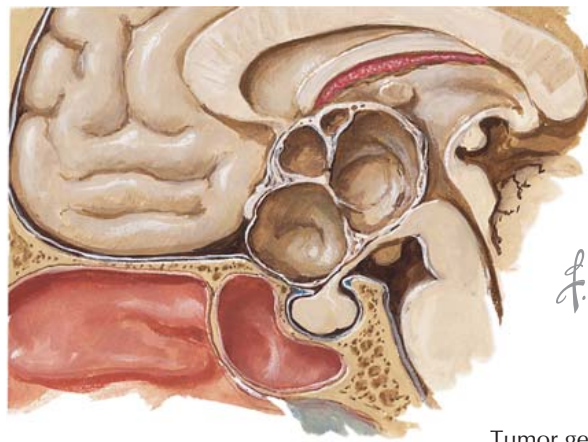
insufficiency, secondary hypogonadism, and growth hormone deficiency).

Hypothalamic hamartomas, gangliocytomas, and germ cell tumors may produce peptides normally secreted by the hypothalamus. Thus, patients may present with endocrine hyperfunction syndromes such as precocious puberty with gonadotropin-releasing hormone expression by hamartomas; acromegaly or Cushing syndrome with growth hormone-releasing

hormone expression or corticotropin-releasing hormone expression, respectively, by hypothalamic gangliocytomas; and precocious puberty with  $\beta$ -human chorionic gonadotropin ( $\beta$ -hCG) expression by suprasellar germ cell tumors.

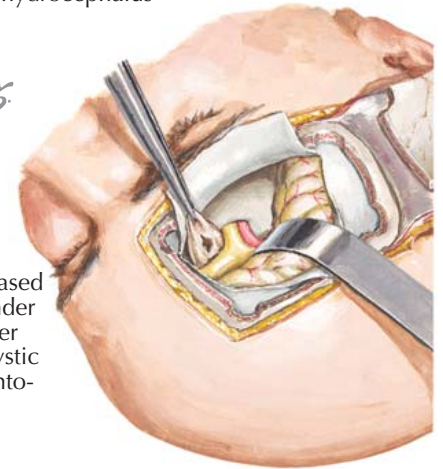
Because of the close microanatomic continuity of the hypothalamic regions and zones, patients with suprasellar disease typically present with not one but many of the dysfunction syndromes discussed.



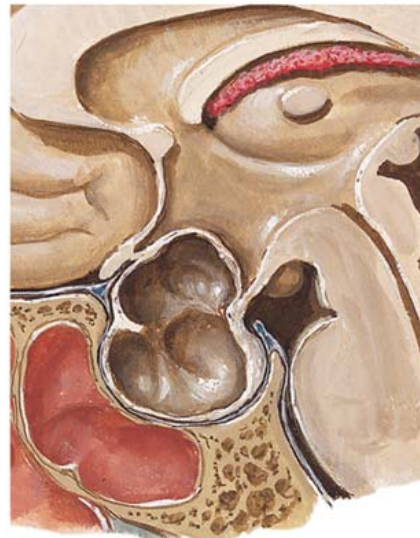


Large cystic suprasellar craniopharyngioma compressing optic chiasm and hypothalamus, filling third ventricle up to interventricular foramen (of Monro), thus causing visual impairment, diabetes insipidus, and hydrocephalus

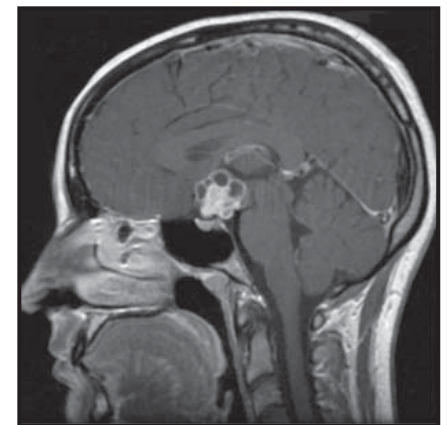
*F. Netter M.D.*



Tumor gently teased forward from under optic chiasm after evacuation of cystic contents via fronto-temporal flap



Intrasellar cystic craniopharyngioma compressing pituitary gland to cause hypopituitarism

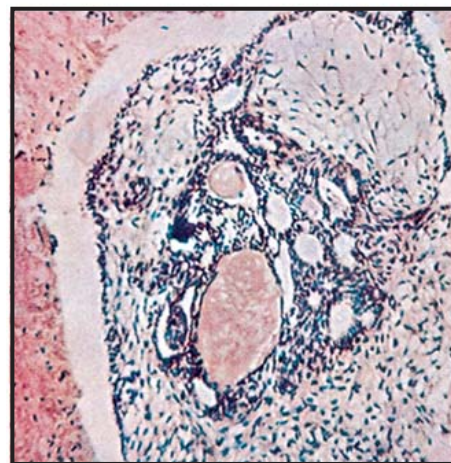


MRI (sagittal view) showing cystic suprasellar craniopharyngioma

## CRANIOPHARYNGIOMA

Craniopharyngioma is the most common tumor found in the region of the pituitary gland in children and adolescents and constitutes about 3% of all intracranial tumors and up to 10% of all childhood brain tumors. Craniopharyngiomas—histologically benign epithelioid tumors arising from embryonic squamous remnants of Rathke pouch—may be large (e.g., >6 cm in diameter) and invade the third ventricle and associated brain structures. This tumorous process is usually located above the sella turcica, depressing the optic chiasm and extending up into the third ventricle. Less frequently, craniopharyngiomas are located within the sella, causing compression of the pituitary gland and frequently eroding the bony confines of the sella turcica. Signs and symptoms—primarily caused by mass effect—typically occur in the adolescent years and rarely after age 40 years. The mass effect symptoms include vision loss by compression of the optic chiasm; diabetes insipidus by invasion or disruption of the hypothalamus or pituitary stalk; hypothalamic dysfunction (e.g., obesity with hyperphagia, hypersomnolence, disturbance in temperature regulation); various degrees of anterior pituitary insufficiency (e.g., growth hormone deficiency with short stature in childhood, hypogonadism, adrenal insufficiency, hypothyroidism); hyperprolactinemia caused by compression of the pituitary stalk or damage to the dopaminergic neurons in the hypothalamus; signs and symptoms of increased intracranial pressure (e.g., headache, projectile emesis, papilledema, optic atrophy); symptoms of hydrocephalus (e.g., mental dullness and confusion) when large tumors obstruct the flow of cerebrospinal fluid; and cranial nerve palsies caused by cavernous sinus invasion.

The findings on radiologic imaging are quite characteristic. Plain skull radiographs and computed tomography (CT) show irregular calcification in the suprasellar region. Magnetic resonance imaging (MRI) typically shows a multilobulated cystic structure that is usually suprasellar in location, but it may also appear to arise

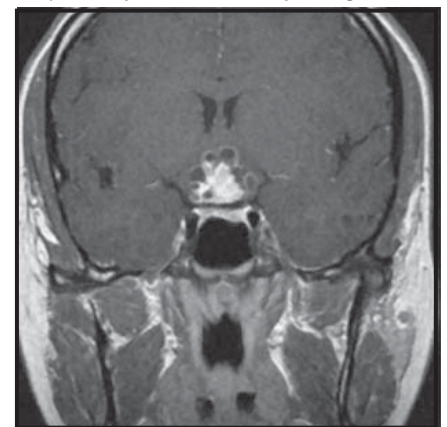


Histologic section: craniopharyngioma (H & E stain, ×125)

from the sella. The cystic regions are usually filled with a turbid, cholesterol-rich, viscous fluid. The walls of the cystic and solid components are composed of whorls and cords of epithelial cells separated by a loose network of stellate cells. If there are intercellular epithelial bridges and keratohyalin, the tumor is classified as an adamantinoma.

Treatment options for patients with craniopharyngiomas include observation, endonasal transsphenoidal

surgery for smaller intrasellar tumors, craniotomy for larger suprasellar tumors, stereotactic radiotherapy, or a combination of these modalities. Most of these treatment approaches result in varying degrees of anterior or posterior pituitary hormone deficits (or both). In addition, recurrent disease after treatment is common (~40%) because of tumor adherence to surrounding structures, and long-term follow-up is indicated.



MRI (coronal view) showing suprasellar craniopharyngioma

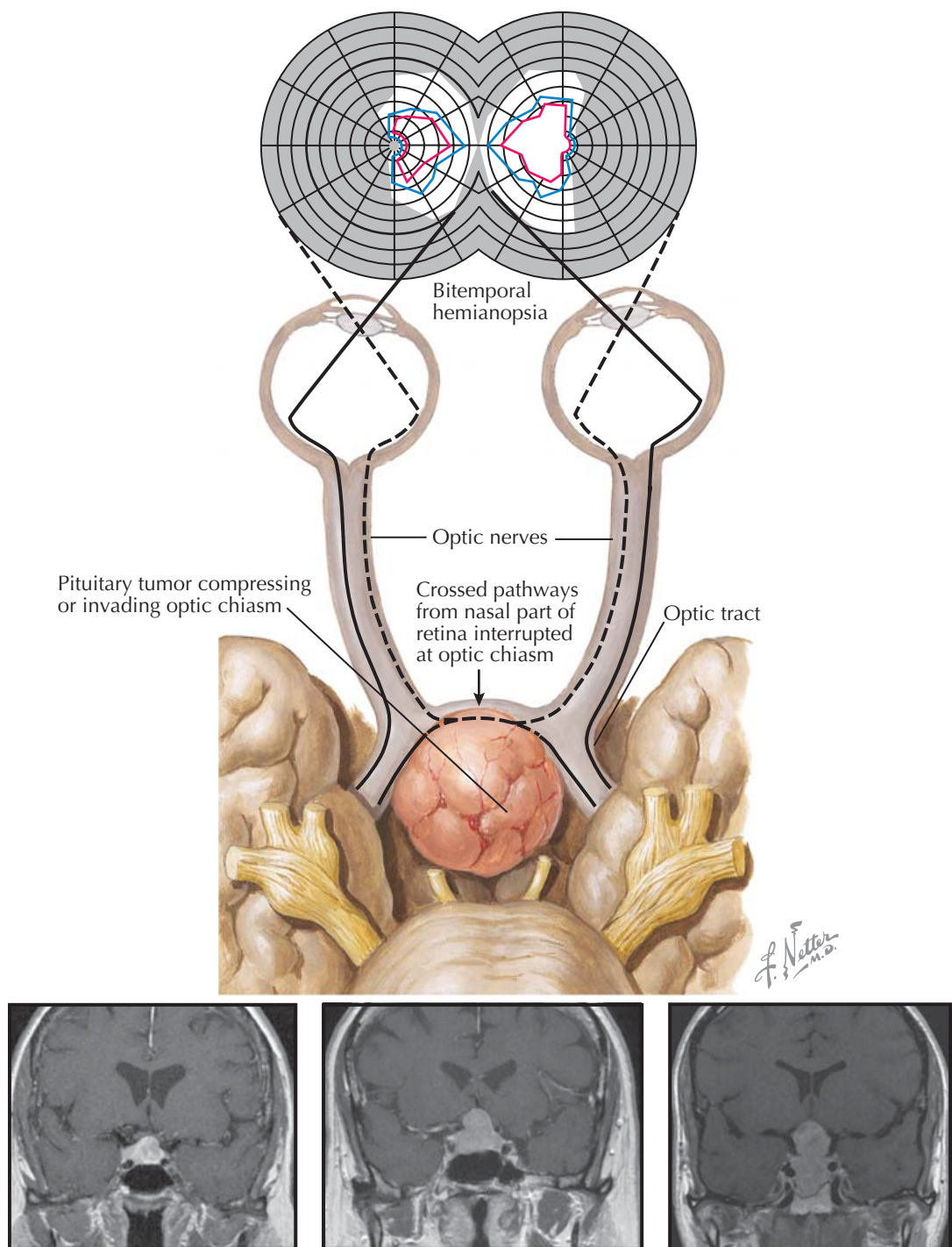


## EFFECTS OF PITUITARY TUMORS ON THE VISUAL APPARATUS

The optic chiasm lies above the diaphragma sellae. The most common sign that a pituitary tumor has extended beyond the confines of the sella turcica is a visual defect caused by the growth pressing on the optic chiasm. The most frequent disturbance is a bitemporal hemianopsia, which is produced by the tumor pressing on the crossing central fibers of the chiasm and sparing the uncrossed lateral fibers. The earliest changes are usually enlargement of the blind spot; loss of color vision, especially for red; and a wedge-shaped area of defective vision in the upper-temporal quadrants, which gradually enlarges to occupy the whole quadrant and subsequently extends to include the lower temporal quadrant as well.

The type of visual defect produced depends on the position of the chiasm in relation to the pituitary gland and the direction of tumor growth. In about 10% of the cases, the chiasm may be found almost entirely anterior or posterior to the diaphragma sellae instead of in its usual position, which is directly above the diaphragma. There are also lateral displacements of the chiasm, which may cause either its right or its left branch to lie above the diaphragma. If the chiasm is abnormally fixed, the adenoma may grow upward for a long time before it seriously disturbs vision. Bilateral central scotomas are caused by damage to the posterior part of the chiasm, and their occurrence suggests that the chiasm is prefixed and that the tumor is large. In other cases of prefixed chiasm, the tumor may extend in such a direction as to compress the optic tract rather than the chiasm, thus producing a homonymous hemianopsia. However, homonymous defects do not always indicate a prefixed chiasm; they may also be produced by lateral extension into the temporal lobe below a normally placed chiasm. Other visual defects that may occur include unilateral central scotoma; dimness of vision (amblyopia) in one eye caused by compression of one optic nerve; and an inferior quadrantal hemianopsia, presumably resulting from a large tumor causing the anterior cerebral arteries to cut into the dorsal surface of a normally placed chiasm.

Primary optic atrophy is present in most cases, but it may be absent when the lesion is behind the chiasm. Although papilledema is rare, it may occur with large tumors that cause increased intracranial pressure. If pressure on the visual pathway is relieved (e.g., with surgery or pharmacotherapy), the visual fields may return to normal. However, vision recovery is caused partly by the degree and duration of the optic tract deformation. Field defects can be detected on gross examination by observing the angle at which an object, such as the examiner's finger, becomes visible when the patient looks straight ahead. Quantitative perimetry is



MRI showing pituitary macroadenoma with suprasellar and right cavernous sinus extension. Optic chiasm is raised slightly, but visual fields are normal.

MRI showing pituitary macroadenoma with suprasellar and bilateral cavernous sinus extension. The optic chiasm is compressed, causing bitemporal superior quadrant vision loss.

MRI showing pituitary macroadenoma with suprasellar, bilateral cavernous, and sphenoid extensions. The optic chiasm is markedly compressed, causing complete bitemporal hemianopsia.

necessary for exact plotting of the size and shape of the field defect.

In some cases of pituitary tumor showing expansive growth sufficient to enlarge the sella, the visual pathway escapes damage because the sellar diaphragm is tough and prevents expansion toward the chiasm. In these cases, the pituitary tumor may extend laterally into the cavernous sinus or inferiorly into the sphenoid sinus. This structure shows considerable variation, from a

dense, closely knit membrane to a small rim with a wide infundibular opening. In most cases, the diaphragm does yield to pressure from below. Usually, the chiasm lies directly on the diaphragm and is separated from it by only a potential cleft. Frequently, particularly where there is a well-developed chiasmatic cistern, the optic chiasm may be as high as 1 cm above the diaphragm, which allows an invading tumor considerable room for expansion before it presses on the visual pathway.

## NONTUMOROUS LESIONS OF THE PITUITARY GLAND AND PITUITARY STALK

The nontumorous lesions of the pituitary gland that can affect function include lymphocytic hypophysitis, granulomatous disorders (e.g., sarcoidosis, tuberculosis, Langerhans cell histiocytosis, Wegener granulomatosis), head trauma with skull base fracture, iron overload states (e.g., hemochromatosis, hemosiderosis), intrasellar carotid artery aneurysm, primary empty sella, pituitary cyst infection (e.g., encephalitis, pituitary abscess), mutations in genes encoding pituitary transcription factors, and developmental midline anomalies.

Lymphocytic hypophysitis is an autoimmune disorder characterized by lymphocytic infiltration and enlargement of the pituitary gland followed by selective destruction of pituitary cells. The most common clinical setting is in late pregnancy or in the postpartum period. Patients typically present with headaches and signs and symptoms of deficiency of one or more pituitary hormones. Frequently, there is a preferential destruction of corticotrophs. However, these patients may have panhypopituitarism (including diabetes insipidus [DI]). Magnetic resonance imaging (MRI) usually shows a homogeneous, contrast-enhancing sellar mass with pituitary stalk involvement. The pituitary hormone deficits are usually permanent, but recovery of both anterior and posterior pituitary function may occur.

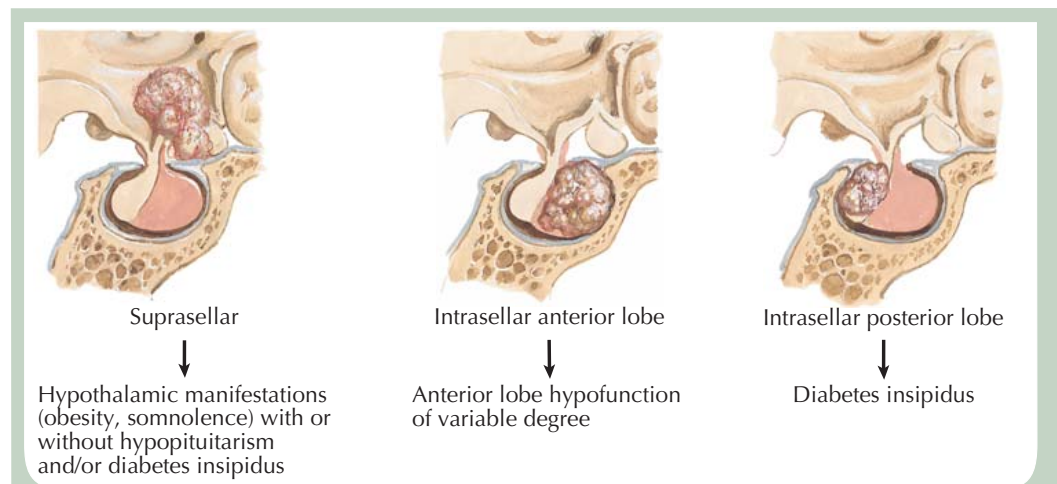
Granulomatous hypophysitis can be caused by sarcoidosis, tuberculosis, Langerhans cell histiocytosis, or Wegener granulomatosis. The granulomatous inflammation may involve the hypothalamus, pituitary stalk, and pituitary gland and cause hypopituitarism, including DI.

Head trauma that results in a skull base fracture may cause hypothalamic hormone deficiencies, resulting in deficient secretion of anterior and posterior pituitary hormones. Head trauma may lead to direct pituitary damage by a sella turcica fracture, pituitary stalk section, trauma-induced vasospasm, or ischemic infarction after blunt trauma.

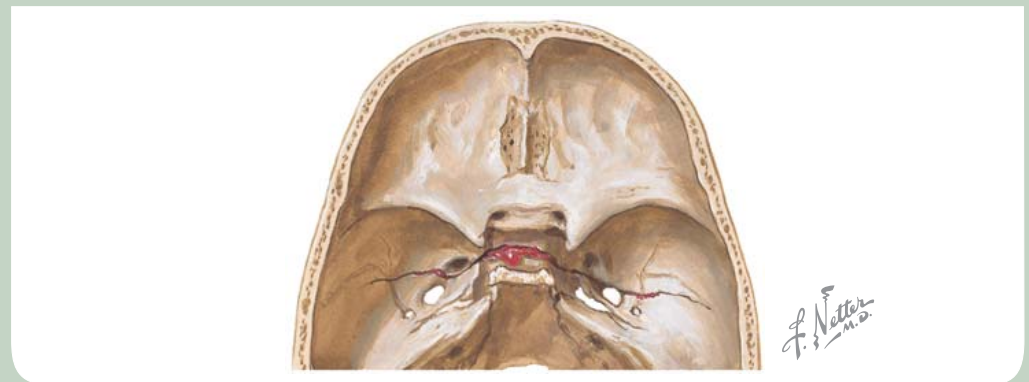
Iron overload states of hemochromatosis and hemosiderosis of thalassemia may involve the pituitary, resulting in iron deposition (siderosis) in pituitary cells. Iron overload most commonly results in selective gonadotropin deficiency.

The term *empty sella* refers to an enlarged sella turcica that is not entirely filled with pituitary tissue. A secondary empty sella occurs when a pituitary adenoma enlarges the sella but is then surgically removed or damaged by radiation or infarction. In a primary empty sella, a defect in the sellar diaphragm allows cerebrospinal fluid to enter and enlarge the sella ( $\leq 50\%$  of patients with a primary empty sella have benign increased intracranial pressure). With a primary empty sella, pituitary function is usually intact. On MRI, demonstrable pituitary tissue is usually compressed against the sellar floor.

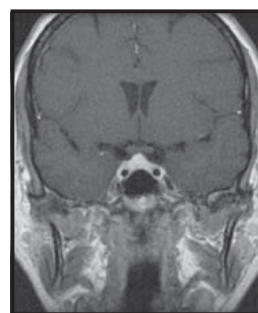
Hypopituitarism is also associated with mutations in genes that encode the transcription factors whose expression is necessary for the differentiation of anterior pituitary cells (e.g., *HESX1*, *LHX3*, *LHX4*, *PROPI*, *POU1F1* [formerly *PIT1*], *TBX19* [also known as *TPIT*]). Mutations in *PROPI* are the most common cause of familial and sporadic congenital hypopituitarism. *PROPI* is necessary for the differentiation of a cell type that is a precursor of somatotroph, lactotroph, thyrotroph, and gonadotroph cells. The protein



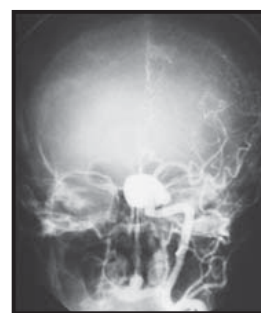
**Lymphocytic hypophysitis and granulomatous disorders**  
Degree and type of hypopituitarism depend on size and location of involvement



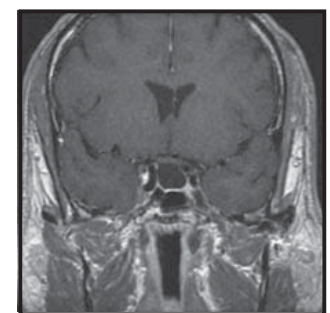
**Trauma** Skull fracture, hemorrhage → Hypopituitarism of variable degree



MRI showing diffusely enhancing lymphocytic hypophysitis filling the sella and extending toward the optic chiasm



Angiogram showing intrasellar carotid artery aneurysm



MRI showing a primary empty sella

Imaging is key in the diagnosis of and in determining the type of nontumorous sellar process

encoded by *POU1F1*, which acts temporally just after the protein encoded by *PROPI*, is necessary for the differentiation of a cell type that is a precursor of somatotroph, lactotroph, and to a lesser degree, thyrotroph cells. *TBX19* is required for specific differentiation of the corticotroph cells. Because the proteins encoded by *HEXS1*, *LHX3*, and *LHX4* act early in pituitary differentiation, mutations in these genes cause combined pituitary hormone deficiency, which refers to deficiencies of growth hormone (GH), prolactin, thyrotrophin (thyroid-stimulating hormone [TSH]),

luteinizing hormone (LH), and follicle-stimulating hormone (FSH) (see Plate 1-13).

Developmental midline anomalies may lead to structural pituitary anomalies (e.g., pituitary aplasia or hypoplasia). Craniofacial developmental anomalies may result in cleft lip and palate, basal encephalocele, hypertelorism, and optic nerve hypoplasia, with varying degrees of pituitary dysplasia and aplasia. Congenital basal encephalocele may cause the pituitary to herniate through the sphenoid sinus roof, resulting in pituitary failure and DI.

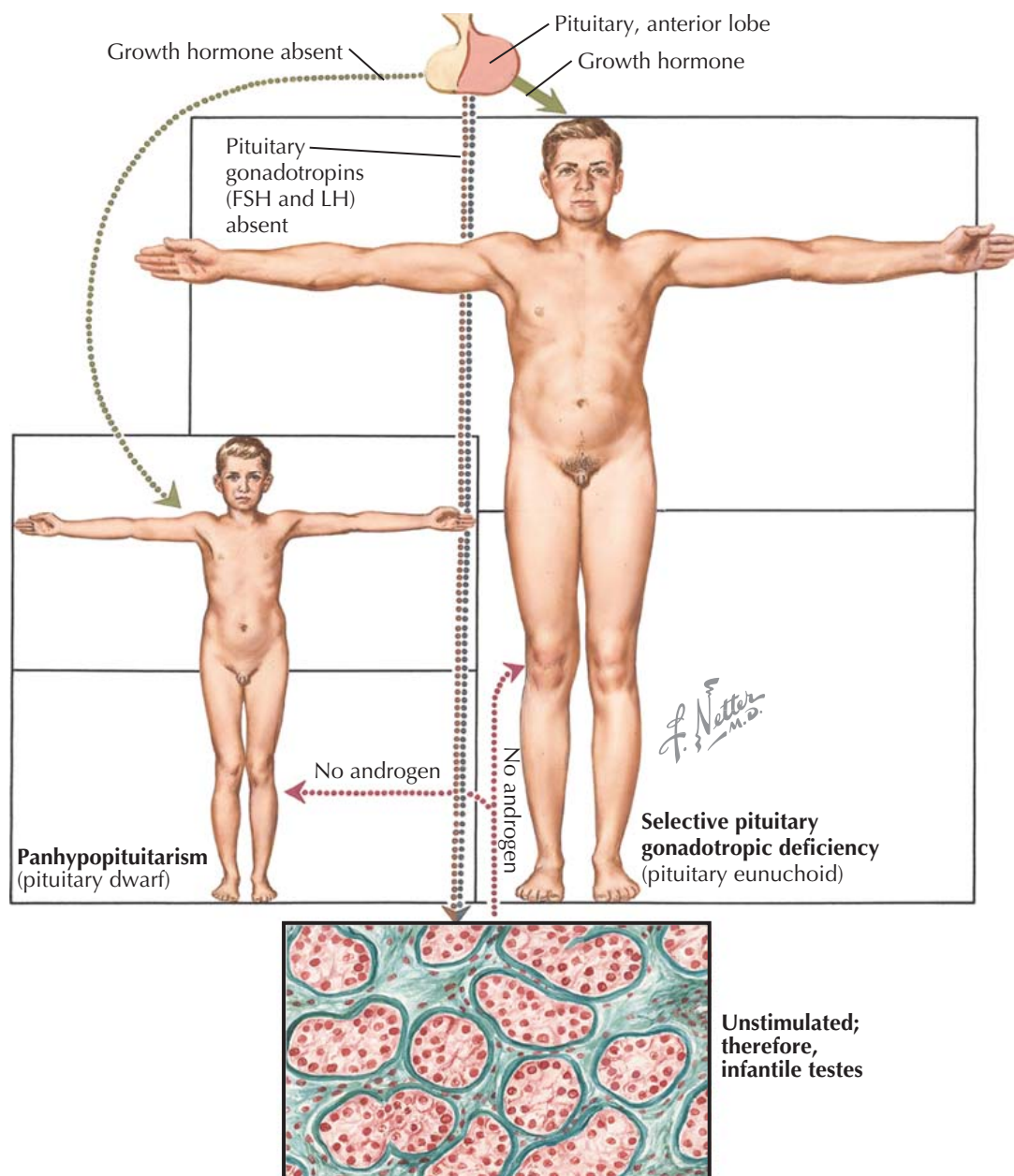


## PITUITARY ANTERIOR LOBE DEFICIENCY IN CHILDHOOD AND ADOLESCENCE IN BOYS

The most common deficient hormones in children and adolescents with anterior pituitary failure are the gonadotropins, luteinizing hormone (LH), and follicle-stimulating hormone (FSH). Gonadotropin deficiency may occur in isolation or in concert with other anterior pituitary hormone deficiencies. In the absence of gonadotropins in boys, puberty is delayed, and secondary sex characteristics do not develop (see Plate 4-7). The penis and prostate gland remain small, and the scrotum fails to develop rugae; the larynx fails to enlarge, and the voice maintains the high pitch of childhood. Some pubic hair appears, but it is usually sparse and fine. Axillary hair either does not appear or is sparse. Beard growth is absent.

Lack of androgens leads to prolonged persistence of open epiphyseal plates and—in the presence of intact growth hormone (GH) and insulinlike growth factor 1—linear growth continues for longer than normal. The linear growth is particularly prominent in the extremities, and the arms and legs become disproportionately long. Eunuchoid proportions develop; lower body length (from the soles of the feet to the pubis) exceeds upper body length (from the pubis to the top of the cranium). In addition, the arm span exceeds the standing height (normally, these dimensions should be equal). Eventually, the epiphyses close in the third decade of life, even in untreated eunuchoid men. Administration of testosterone leads to prompt epiphyseal closure. Excessive linear growth is not seen in adults with anterior pituitary deficiency after epiphyseal closure.

The presentation of secondary hypogonadism in adolescence may be affected by the presence or absence of other anterior pituitary hormone deficiencies. If GH is also deficient in childhood, short stature is evident. Short stature occurs when a child is 2 standard deviations or more below the mean height for children of that gender and chronologic age—typically below the third percentile for height. The three phases of growth are infantile, childhood, and pubertal. Infantile growth is a rapid but decelerating growth pattern during the first 2 years of life with an average growth of 30 cm. A statistically significant and positive correlation exists between the height at age 2 years and final adult height. The childhood growth phase progresses at a relatively constant velocity of 5 to 7 cm per year. The pubertal growth phase refers to the growth spurt of 8 to 14 cm per year that occurs during puberty. The most common causes of short stature are genetic short stature and delayed growth. In addition to GH deficiency, the disorders that are most often associated with short stature



### Pituitary causes:

- ▶ Pituitary adenoma
- ▶ Pituitary cyst
- ▶ Pituitary surgery
- ▶ Infiltrative lesion (e.g., lymphocytic hypophysitis)
- ▶ Infarction (e.g., Sheehan syndrome)
- ▶ Apoplexy
- ▶ Genetic disorder (e.g., *POU1F1* mutation)
- ▶ Primary empty sella syndrome
- ▶ Metastatic disease to the sella

### Hypothalamic causes:

- ▶ Mass lesion (e.g., craniopharyngioma)
- ▶ Radiation (e.g., for brain malignancy)
- ▶ Infiltrative lesion (e.g., sarcoidosis)
- ▶ Trauma with skull base fracture
- ▶ Infection (e.g., viral encephalitis)

are renal disease, cancer (and its treatment), glucocorticoid therapy, pulmonary diseases (e.g., cystic fibrosis), cardiac disorders (e.g., congenital heart disease), gastrointestinal disorders (e.g., celiac disease, inflammatory bowel disease), poorly controlled diabetes mellitus, vitamin D deficiency, hypothyroidism, and Cushing syndrome.

Additional anterior pituitary hormone deficiencies may contribute to the clinical presentation. For

example, corticotropin deficiency may cause signs and symptoms of postural hypotension, tachycardia, fatigue, anorexia, weight loss, hyponatremia, and hypoglycemia. Thyrotropin deficiency may contribute signs and symptoms of fatigue, cold intolerance, constipation, facial puffiness with periorbital edema, dry skin, bradycardia, and delayed relaxation phase of the deep tendon reflexes.



## PITUITARY ANTERIOR LOBE DEFICIENCY IN ADULTS

Anterior pituitary deficiency is decreased secretion of pituitary hormones caused by a disorder of the pituitary or hypothalamus. Compression of a normal pituitary gland by a pituitary adenoma is the most common cause. Other causes of anterior pituitary failure include pituitary cyst, pituitary surgery, pituitary radiation, infiltrative lesion (e.g., lymphocytic hypophysitis, hemochromatosis), infarction (e.g., Sheehan syndrome), apoplexy, genetic disorder (e.g., *POU1F1* mutation), primary empty sella syndrome, and metastatic disease to the sella. Hypothalamic diseases that may cause varying degrees of hypopituitarism include mass lesions (e.g., craniopharyngioma, germinoma, metastatic disease), radiation (e.g., for brain or nasopharyngeal malignancies), infiltrative lesions (e.g., sarcoidosis, Langerhans cell histiocytosis), trauma with skull base fracture, and infection (e.g., viral encephalitis, tuberculous meningitis).

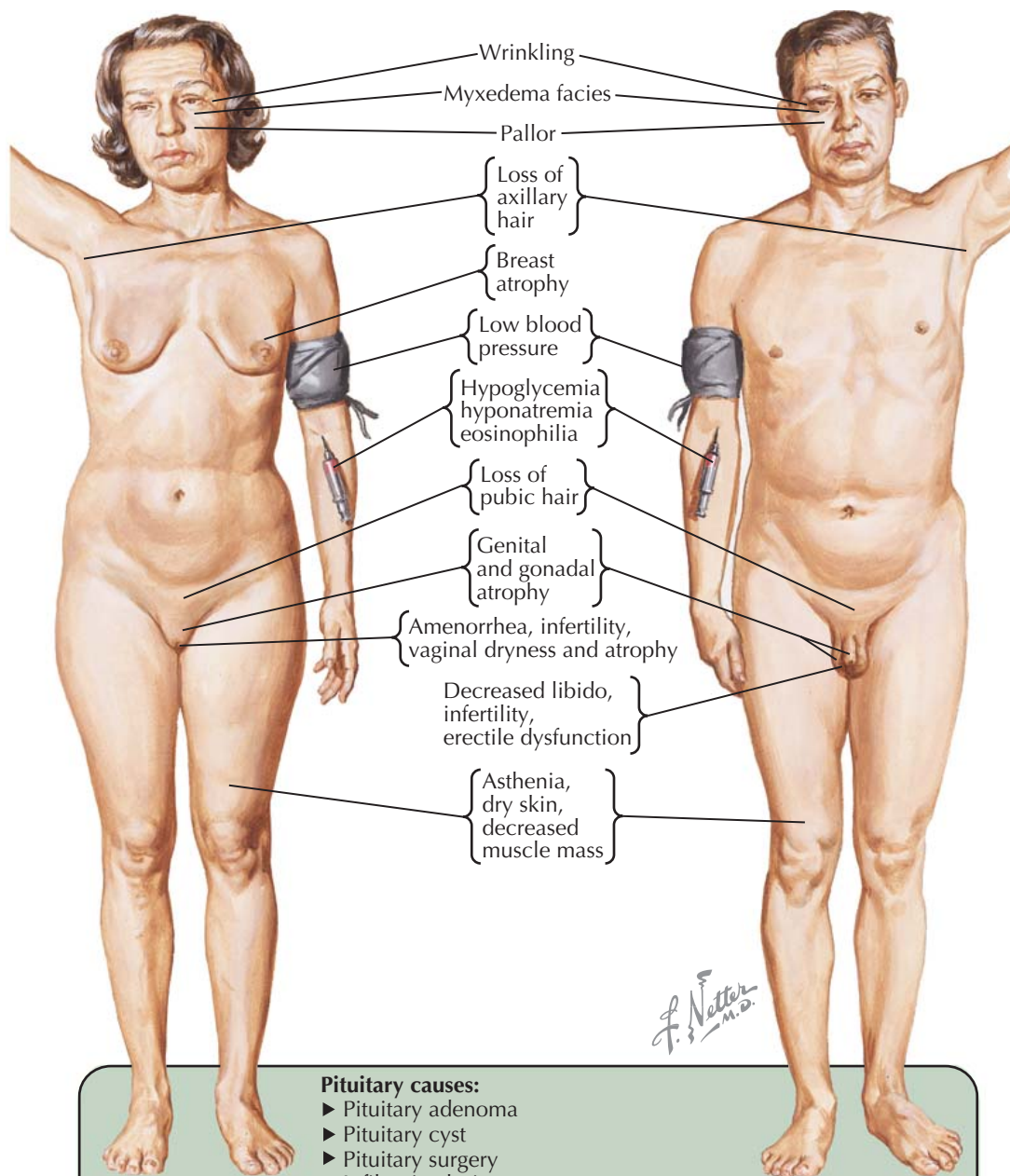
The signs and symptoms related to anterior pituitary insufficiency may occur slowly or suddenly; may be mild or severe; and may affect the secretion of a single, several, or all pituitary hormones. Whereas pituitary apoplexy (see Plate 1-18) is an example of a sudden onset presentation dominated by abrupt loss of corticotropin (adrenocorticotropic hormone [ACTH]) secretion, the impact of slow-growing nonfunctioning pituitary adenomas or radiation therapy on pituitary function develops over years. *Panhypopituitarism* is the term used to describe deficiency of all pituitary hormones. Partial hypopituitarism is more common. In general, the secretion of growth hormone (GH) and gonadotropins is more likely to be affected than ACTH and thyrotropin (thyroid-stimulating hormone [TSH]).

The clinical picture may be dominated by secondary hypogonadism from gonadotropin deficiency. With longstanding gonadal steroid deficiency, individuals develop fine facial wrinkles around the eyes, mouth, and cheeks. Pallor, out of proportion to the moderate anemia usually present, is observed. There is loss of axillary and pubic hair. In women, amenorrhea, infertility, vaginal dryness and atrophy, hot flashes, breast atrophy, osteoporosis, and loss of libido occur. In men, secondary gonadal failure may cause infertility, decreased libido, decreased vitality, decreased testicular size, erectile dysfunction, and osteoporosis.

GH deficiency in adults may be associated with decreased sense of well-being, increased fat mass, decreased muscle mass, increased risk of cardiovascular disease, and decreased bone mineral density.

Prolactin deficiency may result in the inability to lactate postpartum.

Thyroid deficiency produces a subnormal temperature, cold intolerance, a low metabolic rate, fatigue, dry skin, periorbital puffiness (myxedema facies),



### Pituitary causes:

- ▶ Pituitary adenoma
- ▶ Pituitary cyst
- ▶ Pituitary surgery
- ▶ Infiltrative lesion (e.g., lymphocytic hypophysitis)
- ▶ Infarction (e.g., Sheehan syndrome)
- ▶ Apoplexy
- ▶ Genetic disorder (e.g., *POU1F1* mutation)
- ▶ Primary empty sella syndrome
- ▶ Metastatic disease to the sella

### Hypothalamic causes:

- ▶ Mass lesion (e.g., craniopharyngioma)
- ▶ Radiation (e.g., for brain malignancy)
- ▶ Infiltrative lesion (e.g., sarcoidosis)
- ▶ Trauma with skull base fracture
- ▶ Infection (e.g., viral encephalitis)

bradycardia, anemia, delayed relaxation phase of the deep tendon reflexes, and constipation (see Plates 2-14 and 2-15). Also, the combined decrease of thyroid hormone and testosterone may result in loss of the lateral third of the eyebrows.

Adrenal insufficiency is responsible for low blood pressure, asthenia, weight loss, eosinophilia, and crises of nausea and vomiting, which may be associated with spontaneous hypoglycemia. Because the adrenal

secretion of aldosterone is preserved, secondary adrenal failure does not cause salt wasting or hyperkalemia (see Plate 3-24). Also, the hyperpigmentation characteristic of primary adrenal failure (see Plate 3-22) is absent. However, both primary and secondary adrenal failure may cause hyponatremia, a result of inappropriate secretion of antidiuretic hormone (ADH; vasopressin) and a lack of permissive effect of cortisol for the kidneys to excrete free water.

### SELECTIVE AND PARTIAL HYPOPITUITARISM

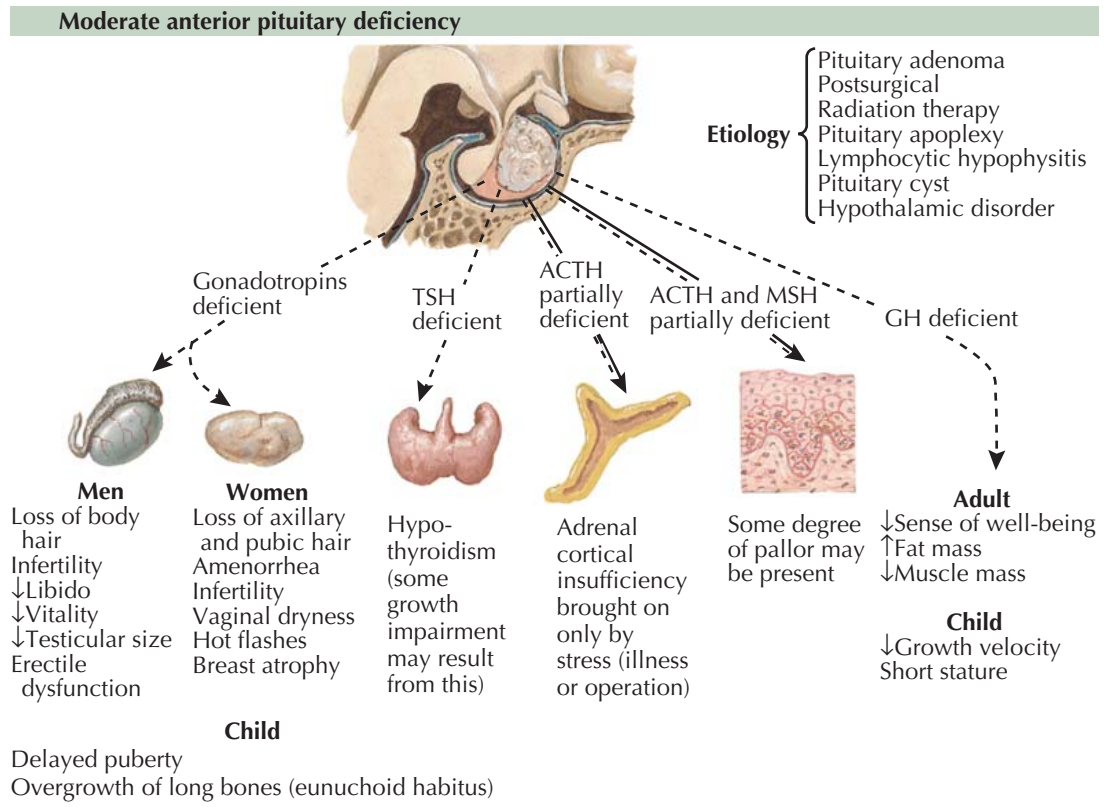
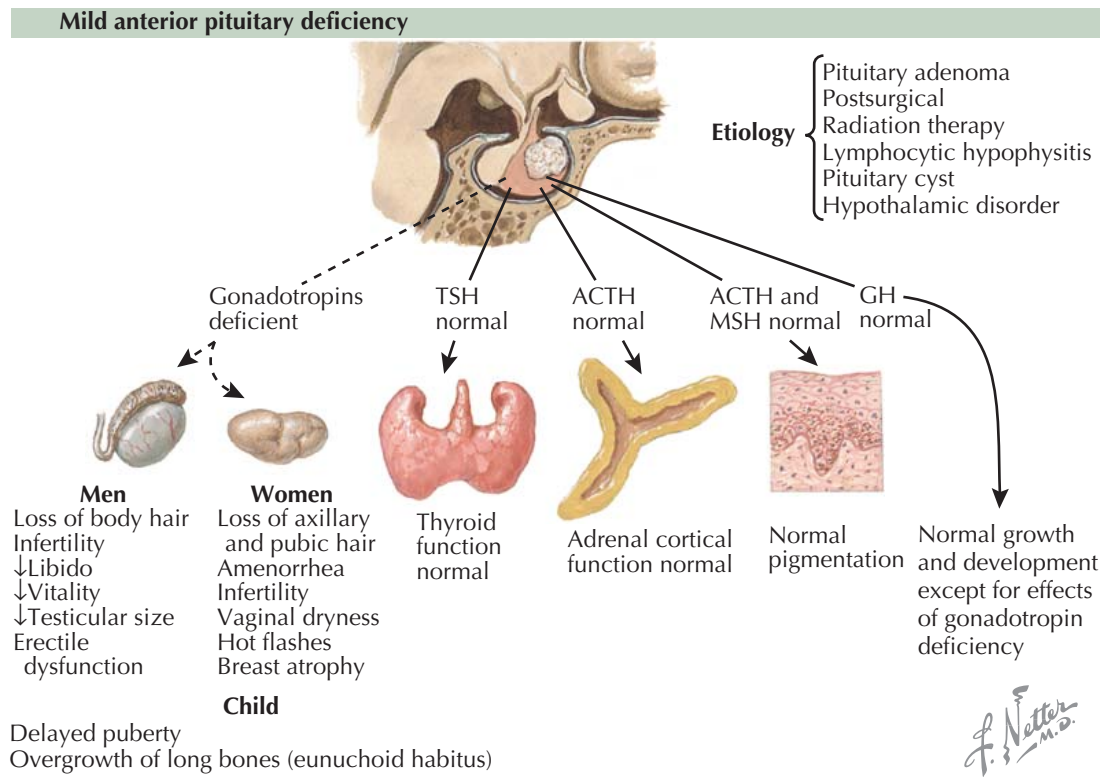
*Selective and partial hypopituitarism* refers to the loss of at least one but not all pituitary hormones. The term *panhypopituitarism* is reserved for the syndrome resulting from the loss of all the hormonal functions of the pituitary, including those of the neurohypophysis (see Plates 1-16 and 1-27). The clinical presentation depends on the rapidity of hormone loss (e.g., sudden with pituitary apoplexy [see Plate 1-18] vs. slow with a slowly growing pituitary tumor) and the number of pituitary hormones affected.

The gonadotropic function of the pituitary is usually the first to fail, probably because the gonadotrophs are more sensitive to adverse conditions than are the other anterior pituitary cell types. In children with mild pituitary destruction, puberty is delayed or does not occur. If growth hormone is present in normal quantities and the other functions of the pituitary are not impaired, then overgrowth of the long bones will occur, and a eunuchoid body habitus will develop (see Plate 1-13). Men and women with acquired secondary hypogonadism typically present with slowly progressive symptoms (see Plate 1-14). Blood concentrations of testosterone in men and estradiol in women are below the reference ranges, and concentrations of the gonadotropins luteinizing hormone (LH) and follicle-stimulating hormone (FSH) are inappropriately normal or low.

Growth hormone (GH) deficiency also tends to occur early in patients with hypopituitarism, and the potential symptoms in adults (e.g., decreased sense of well-being, increased fat mass, decreased muscle mass) may be attributed to other causes, but with GH deficiency in childhood, a slowing of linear growth is typically evident. GH deficiency is evaluated by blood measurement of insulinlike growth factor 1 and GH response to provocation (e.g., insulin-induced hypoglycemia, arginine infusion, or growth hormone-releasing hormone administration).

With more severe insults to the pituitary gland, thyrotroph function and subsequently corticotroph function may be affected. Blood concentrations of thyroxine (total and free) are below the reference range, and thyrotropin (thyroid-stimulating hormone [TSH]) is inappropriately normal or low. The symptoms of primary hypothyroidism (see Plates 2-14 to 2-16) are indistinguishable from those of secondary hypothyroidism. In some instances, hypothyroidism-related symptoms may dominate the clinical picture, and treatment with levothyroxine in patients with concurrent secondary adrenal insufficiency may increase the clearance of the limited cortisol being produced, create an additional metabolic strain on the patient, and precipitate an adrenal crisis.

Secondary adrenal insufficiency differs from primary adrenal insufficiency in two important ways: (1) because of the loss of corticotropin (adrenocorticotrophic hormone [ACTH]) and melanocyte-stimulating hormone (MSH), pallor may be present that is not proportional to the moderate anemia sometimes seen, and (2) adrenal aldosterone secretion remains intact because the main regulators (angiotensin II and blood potassium) are not dependent on normal pituitary function. The blood concentration of cortisol measured at 8 AM is below the reference range, and ACTH is typically undetectable (see Plate 3-24).



Prolactin is frequently the most preserved pituitary hormone in patients with progressive hypopituitarism, and its absence may only be evident by the inability to lactate after delivery.

Selective loss of one pituitary hormone may also occur with lymphocytic hypophysitis—for example, these patients may present with selective ACTH deficiency. If the partial hypopituitarism is attributable to a pituitary or sellar mass, patients may also have

symptoms related to tumor-specific pituitary hormone hypersecretion (e.g., acromegaly, hyperprolactinemia, or Cushing syndrome) or related to mass effect (e.g., vision loss, diplopia, or headache).

Typically, patients with single or multiple pituitary hormone deficiencies respond well to target hormone replacement therapy. If the causative lesion is not progressive, the prognosis for a long and active life is excellent.



## SEVERE ANTERIOR PITUITARY DEFICIENCY OR PANHYPOPITUITARISM

Severe symptoms of anterior pituitary insufficiency appear only when destruction of the adenohypophysis is nearly complete. With progressive destruction (>75%), mild hypogonadism becomes more severe, and general symptoms attributable to thyroid and adrenal cortical hypofunction, such as asthenia, fatigue, loss of appetite, and cold intolerance, appear and progress. Complete anterior pituitary failure may occur after surgery for a pituitary macroadenoma.

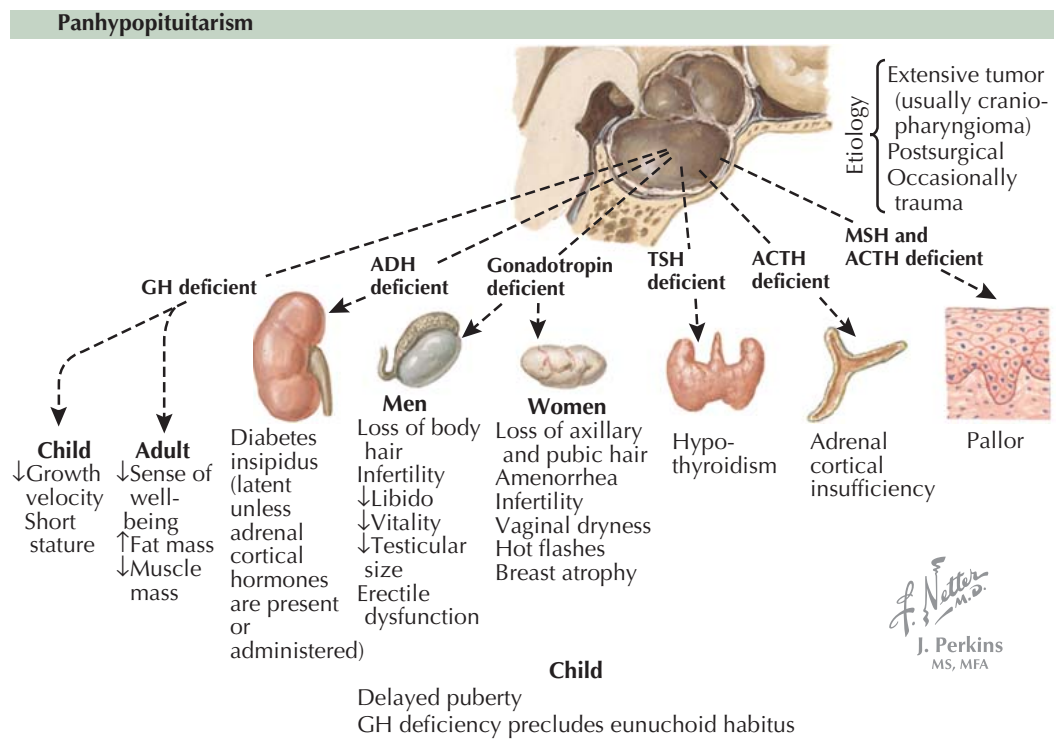
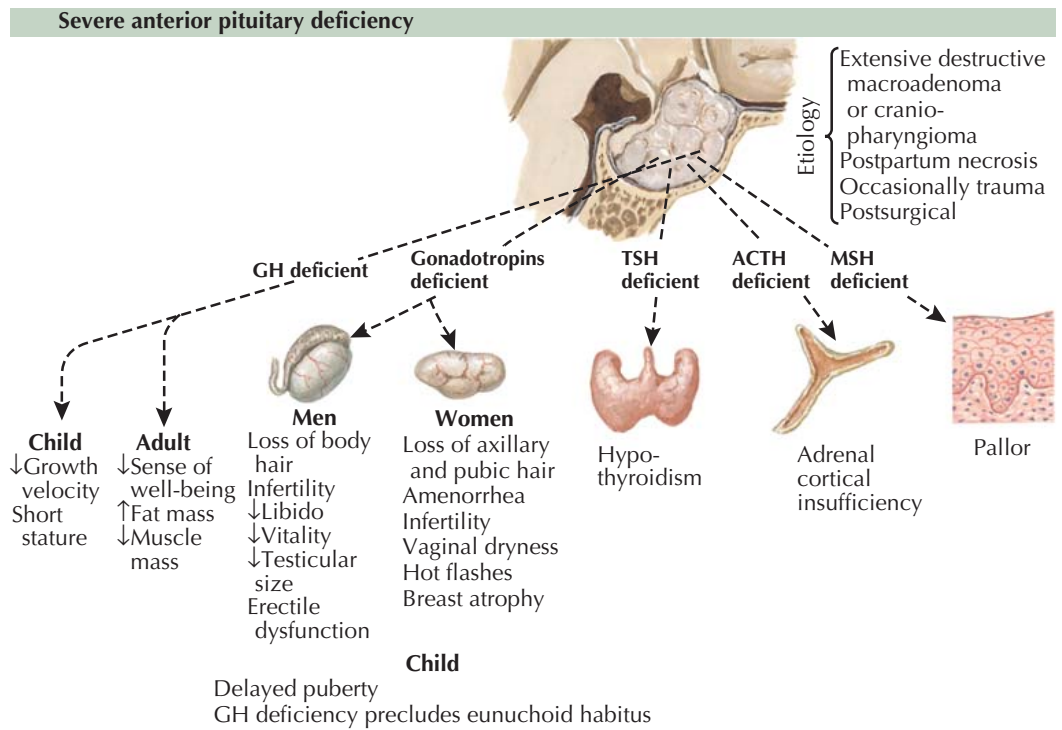
Atrophy of the gonads is a constant finding in this disease. A regression of secondary sexual characteristics also occurs. In women, the ovaries become small and fibrous, and the uterus regresses to infantile proportions with an extremely thin layer of endometrium. The external genitalia shrink, as does the vagina, which develops a smooth, atrophic epithelium. The breasts regress, and the areolae lose pigmentation. In men, the penis is small, the testes are shrunken and devoid of rugae, and the prostate is markedly atrophied. In both sexes, the thyroid gland is small, with follicles lined with low cuboidal epithelium. Shrinkage of the adrenal cortex is most obvious in the zona fasciculata and zona reticularis. The zona glomerulosa, which is the site of aldosterone production, does not depend on corticotropin (adrenocorticotropic hormone [ACTH]) secretion, in contrast to the other two layers. The general architectural pattern of the adrenal cortex is maintained, but the cells are poor in lipid content.

Pallor that is not proportional to the moderate anemia is typically present and is probably attributable to a deficiency of ACTH and melanocyte-stimulating hormone. There is a loss of muscle mass—although multifactorial, the lack of growth hormone (GH) is a main contributor. Children have a tendency to have hypoglycemia, which is associated with deficiency of adrenal glucocorticoids as well as lack of GH together with poor food intake.

The term *panhypopituitarism* should be reserved for cases in which all the functions of the adenohypophysis and neurohypophysis are affected. Patients with slowly progressive destructive lesions of this region may first manifest diabetes insipidus (DI), which disappears when involvement of the adenohypophysis becomes extreme enough to cause secondary adrenal cortical insufficiency. This antagonism between vasopressin and glucocorticoids is further demonstrated by the reappearance of DI when these patients are treated with replacement doses of cortisol.

The treatments for ACTH, thyrotropin (thyroid-stimulating hormone [TSH]), luteinizing hormone (LH), and follicle-stimulating hormone (FSH) deficiencies are the same as the treatments for primary deficiencies of the respective target glands. For example, for ACTH deficiency, hydrocortisone (or other glucocorticoid) is administered to mimic the normal pattern of cortisol secretion with regard to timing and amount, and the patient is instructed on the need for higher doses in times of illness and other stresses. The goal of therapy is resolution of signs and symptoms of adrenal insufficiency and avoidance of excess glucocorticoid effect (e.g., Cushing syndrome).

Patients with TSH deficiency are treated with levothyroxine. The goal of therapy is a mid-normal serum free thyroxine concentration. In patients with panhypopituitarism, levothyroxine should not be administered until glucocorticoid replacement has been initiated.



Treatment of patients with LH and FSH deficiency depends on whether fertility is desired. In men, transdermal testosterone replacement is the treatment of choice for those not interested in fertility. The dosage of testosterone is adjusted for mid-normal blood testosterone concentrations. If fertility is desired, men are treated with gonadotropins. Women can be treated with estrogen-progestin replacement therapy. Women who wish to become fertile can undergo ovulation induction.

Although the role for GH replacement in children with hypopituitarism is clear, GH replacement in adults is optional. Adults with GH deficiency can be treated with GH to optimize body fat, muscle mass, bone

mineral density, and a sense of well-being. The dosage of GH is titrated to reach a mid-normal insulinlike growth factor 1 concentration.

The only symptom related to prolactin deficiency is the inability to breastfeed. Recombinant human prolactin for the treatment of lactation insufficiency is in development.

Patients with diabetes insipidus can be treated with desmopressin—a two-amino acid modification of vasopressin that has potent antidiuretic but no vasopressor activity. The goals of therapy are to reduce nocturia to provide adequate sleep and to control excess urination during the day. Desmopressin can be administered as a nose spray or an oral tablet.



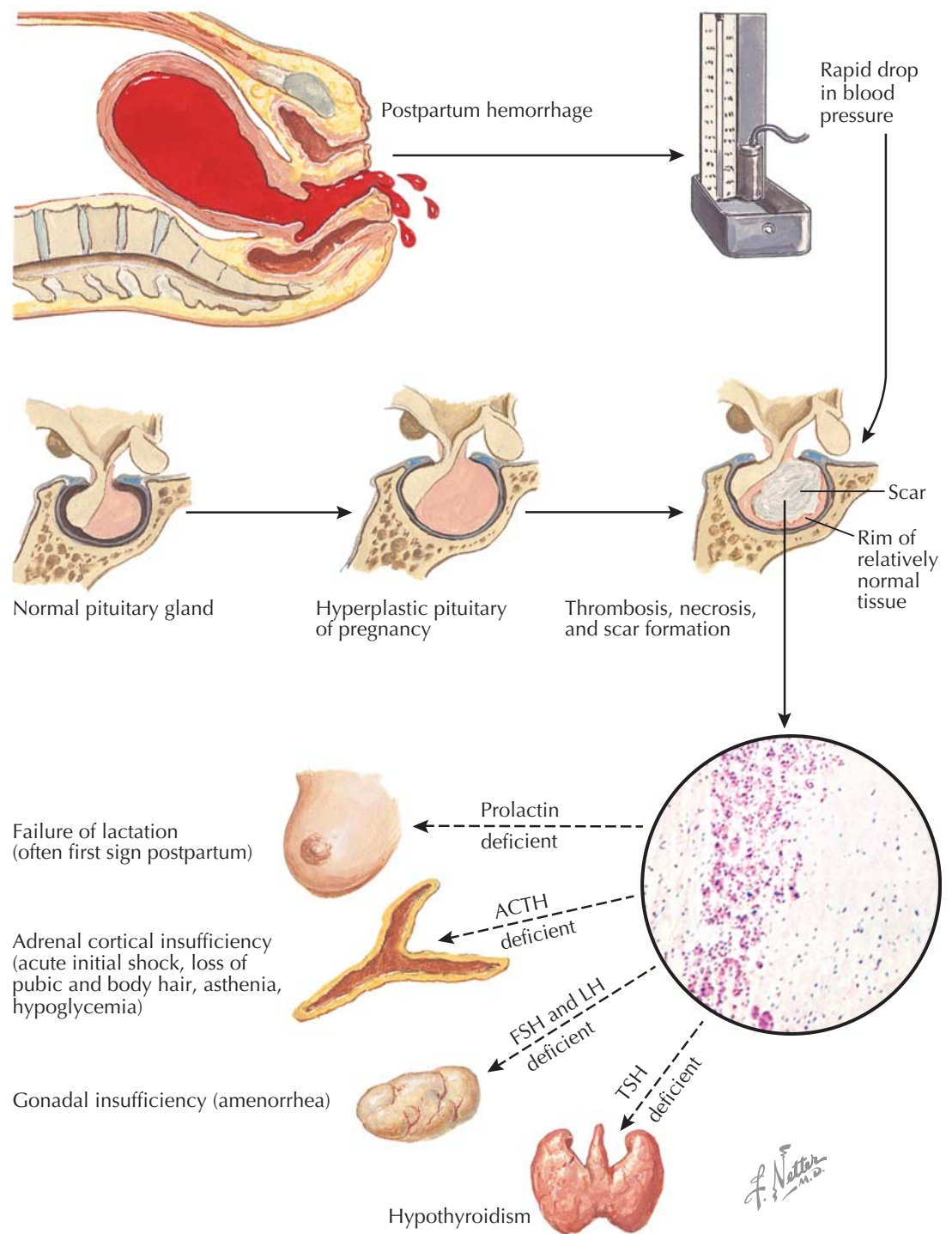
### POSTPARTUM PITUITARY INFARCTION (SHEEHAN SYNDROME)

The pituitary gland enlarges during pregnancy (primarily because of lactotroph hyperplasia) and because of its portal venous blood supply is uniquely vulnerable to changes in arterial blood pressure. In 1937, Sheehan suggested that in the setting of severe postpartum uterine hemorrhage, spasm of the infundibular arteries, which are drained by the hypophysial portal vessels, could result in pituitary infarction. If the lack of blood flow continued for several hours, most of the tissues of the anterior pituitary gland infarcted; when blood finally started to flow, stasis and thrombosis occurred in the stalk and the adenohypophysis. The necrotic areas of the adenohypophysis underwent organization and formed a fibrous scar. Sheehan speculated that variations in the extent and duration of the spasm account for variations in the extent of the necrosis. Today it is recognized that the basic mechanism is infarction secondary to a lack of blood flow to the adenohypophysis. However, it is actually not clear if the infarction is a result of vasospasm, thrombosis, or vascular compression.

In about half of postpartum pituitary infarction cases, the process involves approximately 97% of the anterior lobe, but the pars tuberalis and a small portion of the superior surface of the adenohypophysis are preserved. This remnant retains its structural connections with the hypothalamus and receives portal blood supply from the neural portion of the stalk. Another type of anterior lobe remnant that is sometimes found in these cases is a small area of parenchyma at the lateral pole of the gland without vascular or neural connections with the stalk and hypothalamus. In other instances, a thin layer of parenchyma remains up against the wall of the sella under the capsule. Presumably, these peripheral remnants are nourished by a small capsular blood supply. Normal pituitary function can be maintained by approximately 50% of the gland, but partial and complete anterior pituitary failure results in losses of 75% and 90%, respectively, of the adenohypophysis cells. If more than 30% of the gland is preserved, there is usually sufficient function to forestall the development of acute pituitary failure.

The clinical presentation may range from hypovolemic shock (associated with both the uterine hemorrhage and glucocorticoid deficiency) to gradual onset of partial to complete anterior pituitary insufficiency, only recognized when the patient is unable to breastfeed and has postpartum amenorrhea. These patients may have all of the signs and symptoms of partial or complete hypopituitarism (see Plates 1-15 and 1-16). The acute loss of glucocorticoids can be fatal if not recognized. These patients require lifelong pituitary target gland replacement therapy. Diabetes insipidus in this setting is rare.

Sheehan syndrome should be suspected in women who have a history of postpartum hemorrhage—severe enough to require blood transfusion—and who develop postpartum lethargy, anorexia, weight loss, inability to lactate, amenorrhea, or loss of axillary and pubic hair. The evaluation involves measuring blood concentra-



**Pituitary insufficiency of variable degree usually without diabetes insipidus**

ACTH, corticotropin; FSH, follicle-stimulating hormone; LH, luteinizing hormone; MSH, melanocyte-stimulating hormone; TSH, thyrotropin.

tions of the pituitary-dependent target hormones—8 AM cortisol, free thyroxine, prolactin, estradiol, and insulinlike growth factor 1. Sheehan syndrome is one of the few conditions in which hypoprolactinemia may be found. Magnetic resonance imaging shows evidence of ischemic infarct in the pituitary gland with enlargement followed by gradual shrinkage over several months and eventual pituitary atrophy and the appearance of an empty sella.

Because of the improvements in obstetric care, Sheehan syndrome is no longer the most common cause of postpartum hypopituitarism. Lymphocytic hypophysitis is the most common cause of postpartum pituitary dysfunction (see Plate 1-12).

Very rarely, a normal nonparturient pituitary may become infarcted in association with hemorrhagic shock.

## PITUITARY APOPLEXY

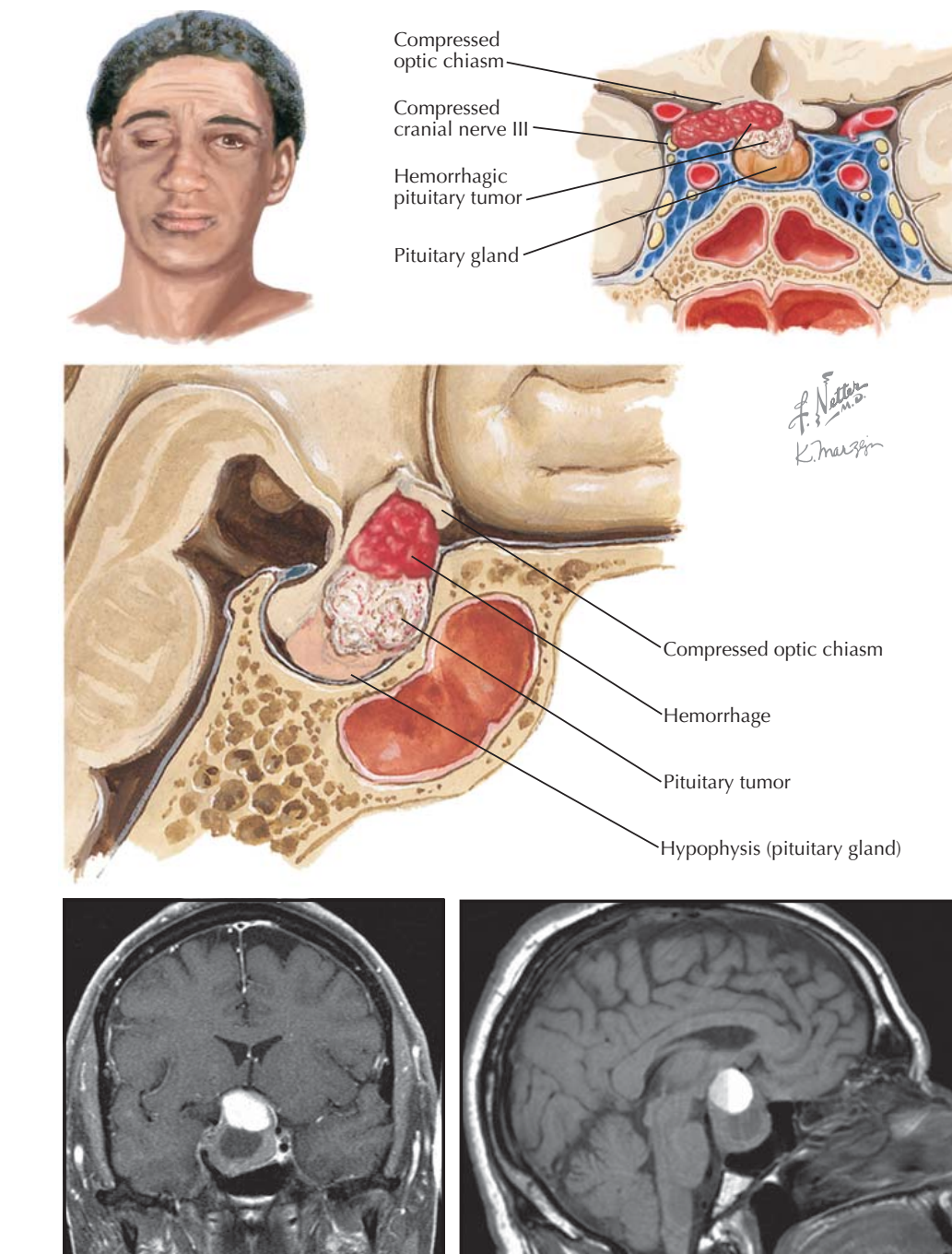
Although pituitary apoplexy, acute hemorrhage of the pituitary gland, is an uncommon event, it is an endocrine emergency, and prompt diagnosis and treatment are critical. The typical presentation is acute onset of severe headache (frequently described as “the worst headache of my life”); vision loss (the hemorrhagic expansion takes the path of least resistance and extends superiorly and compresses the optic chiasm); facial pain; nausea and vomiting; or ocular nerve palsies (e.g., ptosis, diplopia) caused by impingement of the third, fourth, and sixth cranial nerves in the cavernous sinuses. In addition, patients may have signs of meningeal irritation and an altered level of consciousness. Increased intracranial pressure may result in increasing drowsiness and stupor and may mandate surgical intervention and decompression. Hypothalamic involvement may lead to disorders of sympathetic autoregulation, resulting in dysrhythmia and disordered breathing. Erythrocytes and an increased protein concentration are found in the cerebrospinal fluid of many patients with pituitary apoplexy. This may be a potential source of confusion in differentiating pituitary apoplexy from meningitis or subarachnoid hemorrhage.

The most immediate hormonal deficiency is secondary adrenal insufficiency, which may lead to hypotension and adrenal crisis. Pituitary apoplexy occurs most often in the setting of a preexisting pituitary macroadenoma or cyst, and the hemorrhage may be spontaneous or triggered by head trauma, coagulation disorders (e.g., idiopathic thrombocytopenic purpura), or anticoagulant (e.g., heparin, warfarin) administration. Rarely, the pituitary tumor apoplexy may be induced by the administration of a hypothalamic-releasing hormone (e.g., gonadotropin-releasing hormone agonist in a patient with a gonadotropin-secreting adenoma) or by the administration of an agent used to treat the pituitary tumor (e.g., bromocriptine for a prolactin-secreting pituitary tumor). The rapid expansion of the sellar contents results in the immediate mass-effect symptoms. In more than 50% of cases of pituitary apoplexy, the apoplectic event is the initial clinical presentation of a pituitary tumor. The risk of pituitary apoplexy is not related to age or gender.

Pituitary imaging with magnetic resonance imaging (MRI) is diagnostic and typically shows signs of intrapituitary or intra-adenoma hemorrhage, fluid-fluid level, and compression of normal pituitary tissue. Hormonal evaluation typically shows complete anterior pituitary failure (including prolactin). Because of the anatomy of the pituitary circulation and the sparing of the infundibular circulation (inferior hypophysial arteries), the posterior pituitary is infrequently affected by pituitary apoplexy. Thus, diabetes insipidus is rare in patients with pituitary apoplexy.

The clinical course of pituitary apoplexy varies widely in duration and severity. Thus, the appropriate intervention may be difficult to determine. Treatment is aimed at alleviating or relieving local compression that compromises adjacent structures such as the visual individualized pathways.

In addition to anatomic considerations, the endocrine status of the patient must be considered and treated accordingly. The timing of therapy must be individualized on the basis of the symptoms and the severity of the apoplectic event. Neurosurgical intervention is often the most rapid and effective method of



MRI showing pituitary tumor apoplexy. Coronal image (*left*) shows the partially cystic pituitary tumor in the sella with the hemorrhagic component extending above the sella. Sagittal image (*right*) shows fluid-fluid level within the area of recent hemorrhage.

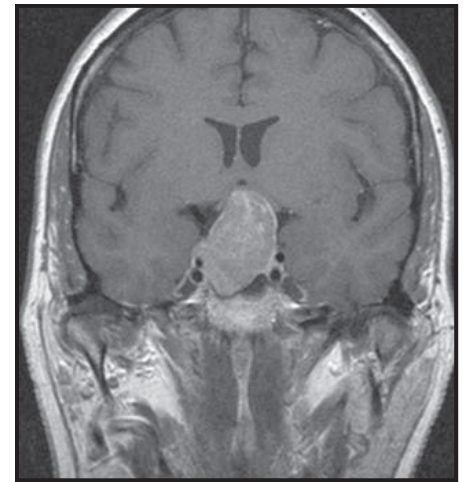
decompressing the sella turcica and the surrounding structures and is indicated in the event of mental status changes and other symptoms attributable to increased intracranial pressure. Surgical decompression is also indicated in the absence of these symptoms when the visual pathways are compromised to prevent prolonged ischemia leading to irreversible nerve dysfunction. Although the timing of the surgical intervention does not seem to affect the recovery of ocular palsies, an operation within 1 week after apoplexy in a conscious patient whose condition is stable improves recovery of visual acuity more than an operation performed with a delay of more than 1 week after the event. Although hemorrhagic areas of the pituitary are absorbed over time, reabsorption alone may not occur fast enough for recovery of visual acuity. Therefore, waiting for

spontaneous resolution of a visual field defect in a patient whose condition is otherwise stable may not be optimal management. In patients with normal visual fields who lack cranial nerve palsies, observation is a reasonable treatment approach. Stress dosages of glucocorticoids should be initiated in all patients with pituitary apoplexy. Pituitary function may not recover, and long-term pituitary target gland hormone replacement therapy may be needed.

It should be noted that necrosis and hemorrhage within a pituitary tumor occur much more frequently than the clinical syndrome of pituitary apoplexy, especially in silent corticotroph adenomas, in which hemorrhage occurs in more than 50% of the tumors. Overall, hemorrhage occurs in 10% to 15% of pituitary adenomas, and it is usually clinically silent.



MRI (coronal view) shows a large GH-secreting pituitary tumor in a 16-year-old adolescent boy with gigantism.



## PITUITARY GIGANTISM

Pituitary gigantism occurs when a growth hormone (GH)-secreting pituitary tumor develops before fusion of the epiphyseal growth plates in a child or adolescent. In contrast, when GH-secreting pituitary tumors develop in an adult (after complete epiphyseal fusion), there is no linear growth, but there are acral changes, and the condition is termed *acromegaly* (see Plate 1-20).

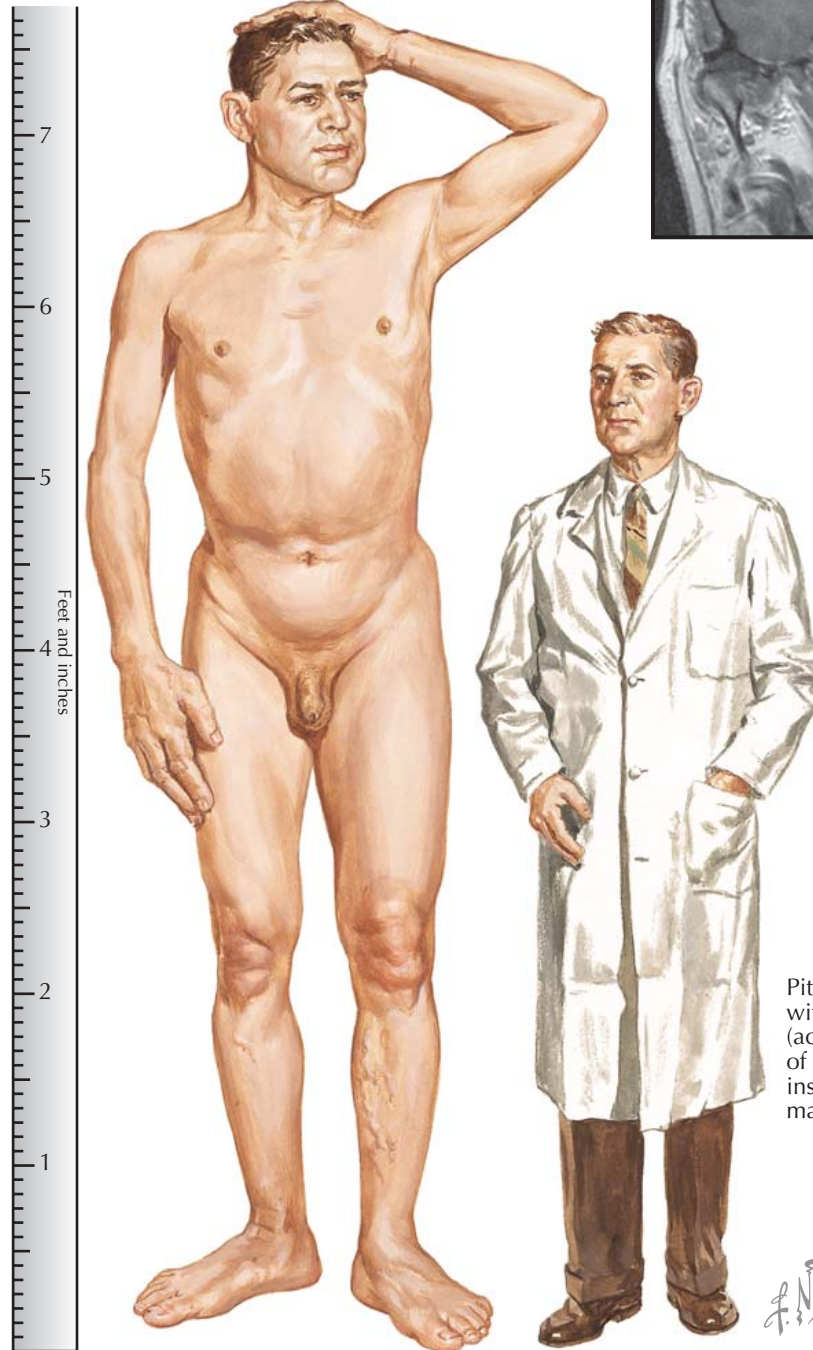
Pituitary gigantism is rare. When it starts in infancy, it may lead to exceptional height. The tallest well-documented person with pituitary gigantism measured 8 ft, 11 in (272 cm). When untreated, pituitary giants are typically taller than 7 ft. The GH-secreting pituitary tumors in individuals with pituitary gigantism are usually sporadic, but they may arise as part of a syndrome such as multiple endocrine neoplasia type 1 (see Plate 8-1), McCune-Albright syndrome (see Plate 4-11), and the Carney complex (see Plate 3-12).

Although usually caused by a pituitary GH-secreting adenoma, pituitary gigantism may also be caused by an ectopic tumor secreting GH-releasing hormone (GHRH) or by hypothalamic dysfunction with hypersecretion of GHRH.

In addition to the accelerated linear growth, patients with pituitary gigantism may slowly develop many of those features seen in adults with acromegaly—for example, soft tissue overgrowth, progressive dental malocclusion (underbite), a low-pitched voice, headaches, malodorous hyperhidrosis, oily skin, proximal muscle weakness, diabetes mellitus, hypertension, obstructive sleep apnea, and cardiac dysfunction. The mass effects of GH-producing pituitary macroadenomas (>10 mm) are similar to those of other pituitary macroadenomas—they include visual field defects, oculomotor pareses, headaches, and pituitary insufficiency.

It is important to note that most children with accelerated linear growth do not have pituitary gigantism. More common causes of tall stature include precocious puberty, genetic tall stature, and hyperthyroidism.

High plasma GH levels are not diagnostic of pituitary gigantism. The diagnosis of pituitary gigantism should be considered in patients after other causes of accelerated linear growth have been excluded. The biochemical diagnosis is based on two criteria: a GH level that is not suppressed to less than 0.4 ng/dL after an oral glucose load (75–100 g) and an increased serum concentration (based on normal range adjusted for age and gender) of insulinlike growth factor 1 (IGF-1). Serum prolactin concentrations should also be measured because the pituitary neoplasm in children frequently arises from the mammosomatotroph, so cohypersecretion of prolactin may occur. The laboratory assessment of pituitary gigantism is supplemented with magnetic



Pituitary giant contrasted with average-size man (acromegaly and signs of secondary pituitary insufficiency may or may not be present)

resonance imaging (MRI) of the pituitary and visual field examination by quantitative perimetry. If imaging of the pituitary fails to detect an adenoma, then plasma GHRH concentration and CT of the chest and abdomen are indicated in search of an ectopic GHRH-producing tumor (e.g., pancreatic or small cell lung neoplasm).

Treatment is indicated for all patients with confirmed pituitary gigantism. The goals of treatment are

to prevent the long-term consequences of GH excess, remove the sellar mass, and preserve normal pituitary tissue and function. Treatment options include surgery, targeted irradiation, and medical therapy. Surgery—transsphenoidal adenectomy by an experienced neurosurgeon—is the treatment of choice and should be supplemented, if necessary, with Gamma knife radiotherapy, pharmacotherapy, or both.



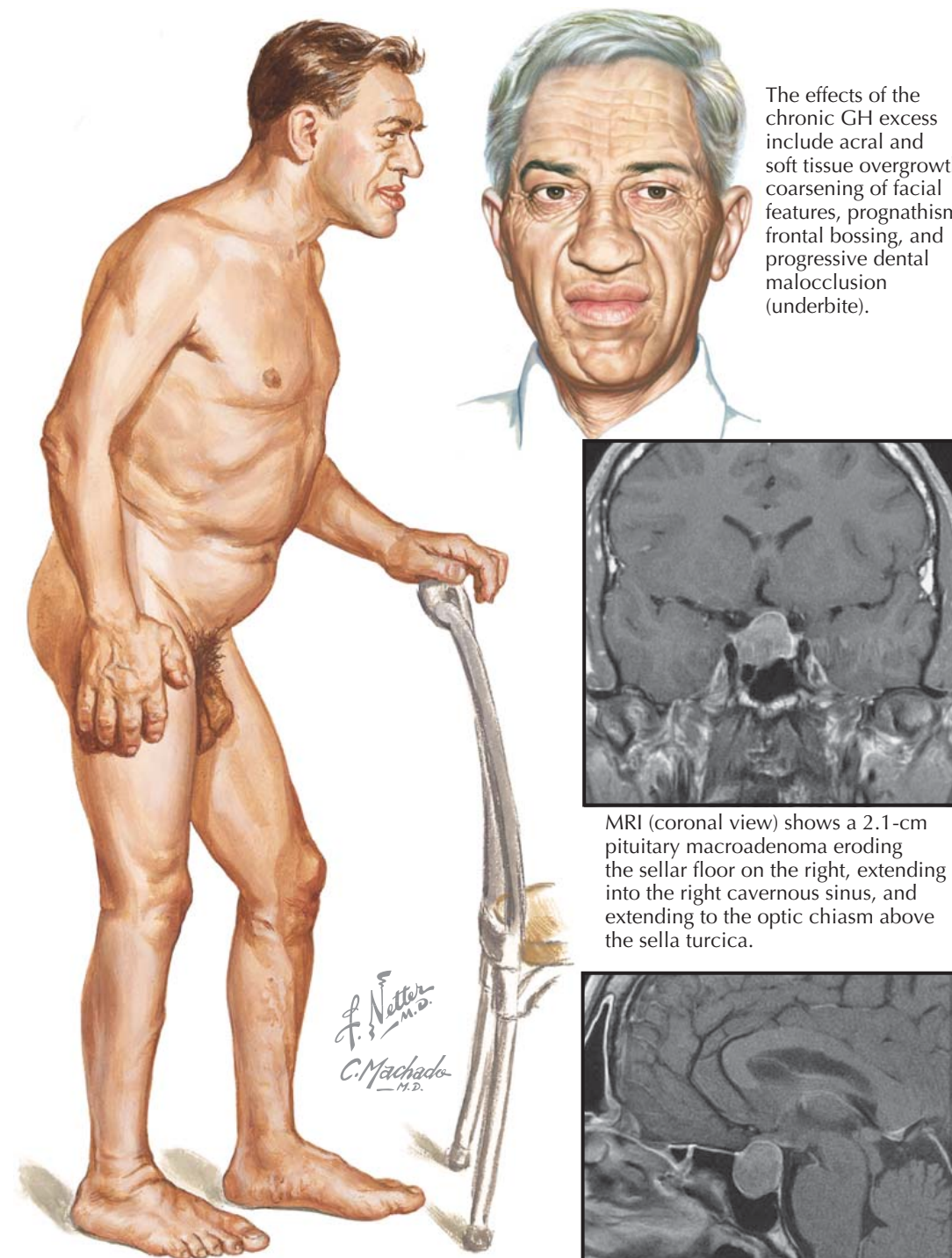
## ACROMEGALY

Chronic growth hormone (GH) excess from a GH-producing pituitary tumor results in the clinical syndrome of acromegaly. Acromegaly was the first pituitary syndrome to be recognized, described by Pierre Marie in 1886. If untreated, this syndrome is associated with increased morbidity and mortality. Although the annual incidence is estimated to be only three per 1 million persons in the general population, a GH-secreting pituitary adenoma is the second most common hormone-secreting pituitary tumor. The effects of the chronic GH excess include acral and soft tissue overgrowth, progressive dental malocclusion (underbite), degenerative arthritis related to chondral and synovial tissue overgrowth within joints, a low-pitched sonorous voice, headaches, malodorous hyperhidrosis, oily skin, perineural hypertrophy leading to nerve entrapment (e.g., carpal tunnel syndrome), proximal muscle weakness, carbohydrate intolerance (the initial presentation may be diabetes mellitus), hypertension, colonic neoplasia, obstructive sleep apnea, and cardiac dysfunction. The mass effects of GH-producing pituitary macroadenomas (>10 mm) are similar to those of other pituitary macroadenomas and include visual field defects, oculomotor pareses, headaches, and pituitary insufficiency.

Patients with acromegaly have a characteristic appearance with coarsening of the facial features, prognathism, frontal bossing, spadelike hands, and wide feet. Often there is a history of progressive increase in shoe, glove, ring, or hat size. These changes may occur slowly and may go unrecognized by the patient, family, and physician. The average delay in diagnosis from the onset of the first symptoms to the eventual diagnosis is 8.5 years. Comparison with earlier photographs of the patient is helpful in confirming the clinical suspicion of acromegaly.

High plasma GH levels are not diagnostic of acromegaly. Basal plasma GH levels are increased in patients with poorly controlled diabetes mellitus, chronic hepatic or renal failure, or conditions characterized by protein-calorie malnutrition such as anorexia nervosa. The diagnosis of acromegaly depends on two criteria: a GH level that is not suppressed to less than 0.4 ng/dL after an oral glucose load (75–100 g) and an increased serum concentration (based on normal range adjusted for age and gender) of insulinlike growth factor 1 (IGF-1, a GH-dependent growth factor responsible for many of the effects of GH and previously known as somatomedin C). Serum IGF-1 levels are rarely falsely elevated. IGF-1 levels do rise in pregnancy two- to threefold above the upper limit of gender- and age-adjusted normal values. The laboratory assessment of acromegaly is supplemented with magnetic resonance imaging of the pituitary and with visual field examination by quantitative perimetry. If imaging of the pituitary fails to detect an adenoma, then plasma GH-releasing hormone (GHRH) concentration and CT of the chest and abdomen are indicated in search of an ectopic GHRH-producing tumor (e.g., pancreatic or small cell lung neoplasm).

Treatment is indicated for all patients with acromegaly. The goals of treatment are to prevent the long-term consequences of GH excess, remove the sellar



The effects of the chronic GH excess include acral and soft tissue overgrowth, coarsening of facial features, prognathism, frontal bossing, and progressive dental malocclusion (underbite).

MRI (coronal view) shows a 2.1-cm pituitary macroadenoma eroding the sellar floor on the right, extending into the right cavernous sinus, and extending to the optic chiasm above the sella turcica.

MRI (midline sagittal view) shows pituitary macroadenoma extending into the sphenoid sinus and suprasellar region.

mass, and preserve normal pituitary tissue and function. Treatment options include surgery, targeted irradiation, and medical therapy. Surgery—transsphenoidal adenectomy by an experienced neurosurgeon—is the treatment of choice and should be supplemented, if necessary, with Gamma knife radiotherapy, pharmacotherapy, or both.

After successful surgical treatment, there is a marked regression of the soft tissue excess, but the bone changes

are permanent. After the soft tissue changes have stabilized, combined oral and plastic surgery may be indicated (e.g., mandibular osteotomies, recession of the supraorbital ridges, rhinoplasties, and reduction of tongue size). Disabling hypertrophic osteoarthropathy of the hip or other large joints may require joint replacement. Because of the increased risk of colorectal adenomas and cancer, patients with acromegaly should be offered regular colonoscopic screening.



## PROLACTIN-SECRETING PITUITARY TUMOR

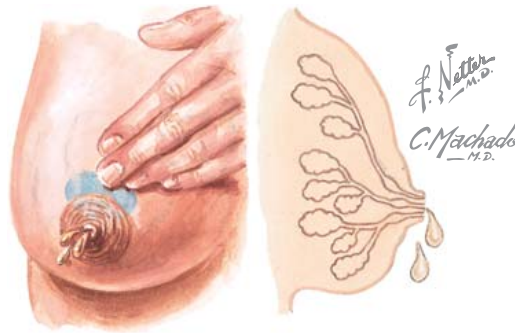
Prolactin-secreting pituitary tumors (prolactinomas) are the most common hormone-secreting pituitary tumor. They are monoclonal lactotroph cell adenomas that appear to result from sporadic mutations. Although most prolactinomas are sporadic, they are the most frequent pituitary tumor in persons with multiple endocrine neoplasia type 1 (see Plate 8-1). In addition, more than 99% of prolactinomas are benign. Approximately 10% of prolactin-secreting pituitary tumors cosecrete growth hormone because of a somatotroph or mammosomatotroph component.

In women, the typical clinical presentation of a prolactin-secreting microadenoma ( $\leq 10$  mm in largest diameter) is secondary amenorrhea with or without galactorrhea. But in men, because of the lack of symptoms related to small prolactinomas, a prolactinoma is not usually diagnosed until the tumor has enlarged enough to cause mass-effect symptoms. This late diagnosis is also the typical clinical scenario in postmenopausal women. Mass-effect symptoms of prolactin-secreting macroadenomas include visual field defects with suprasellar extension, cranial nerve palsies with lateral (cavernous sinus) extension (e.g., diplopia, ptosis), headaches, and varying degrees of hypopituitarism with compression of the normal pituitary tissue.

Hyperprolactinemia results in decreased gonadotropin secretion in men and women. In men, hypogonadotropic hypogonadism causes testicular atrophy, low serum testosterone concentrations, decreased libido, sexual dysfunction, decreased facial hair growth, and decreased muscle mass. Because men lack the estrogen needed to prepare breast glandular tissues, they rarely present with galactorrhea. In premenopausal women, however, hyperprolactinemia may cause bilateral spontaneous or expressible galactorrhea (see Plate 4-26). In addition, prolactin-dependent hypogonadotropic hypogonadism in women results in secondary amenorrhea and estrogen deficiency symptoms. Long-standing hypogonadism in both men and women may lead to osteopenia and osteoporosis.

In general, the blood concentration of prolactin is proportionate to the size of the prolactinoma. For example, a 5-mm prolactinoma is associated with serum prolactin concentrations of 50 to 250 ng/mL (reference range, 4–30 ng/mL), but prolactinomas larger than 2 cm in diameter are associated with serum prolactin concentrations greater than 1000 ng/mL. However, there are exceptional cases of small prolactinomas that have extremely efficient prolactin secretory capacity (e.g., serum prolactin concentration  $>1000$  ng/mL) and cases of the converse—very inefficient prolactin-secreting macroadenomas (e.g., serum prolactin concentrations  $<200$  ng/mL).

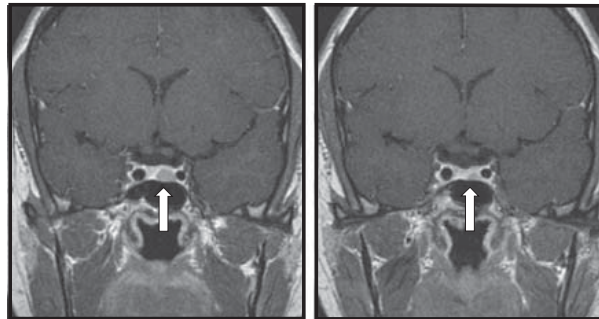
Treatment decisions in patients with prolactin-secreting pituitary tumors are guided by the signs and symptoms related to hyperprolactinemia and mass-effect symptoms related to the sellar mass. For example, a 4-mm prolactin-secreting microadenoma detected incidentally in an asymptomatic postmenopausal woman may be observed without treatment. However, because prolactin-secreting pituitary macroadenomas grow over time, treatment is almost always indicated for macroprolactinomas even if the patient lacks tumor-related symptomatology. When treatment is indicated (e.g., if secondary hypogonadism is present in men or in premenopausal women or if a



▲ In premenopausal women, hyperprolactinemia causes bilateral spontaneous galactorrhea



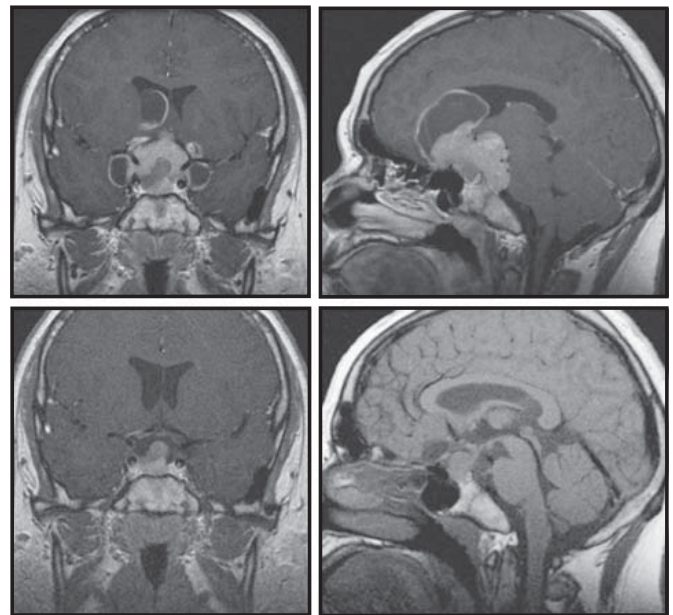
▲ Mass-effect symptoms of prolactin-secreting macroadenomas include visual field defects with suprasellar extension, cranial nerve palsies with lateral (cavernous sinus) extension (e.g., diplopia, ptosis), headaches, and varying degrees of hypopituitarism



◀ Serial head MRI scans (coronal views) from a patient with a 9-mm prolactin-secreting pituitary microadenoma (arrows). At the time of diagnosis (image on left), the serum prolactin concentration was 280 ng/mL. The image on the right was obtained 6 months after normalizing the serum prolactin concentration with a dopamine agonist. The size of the prolactinoma decreased more than 50% (image on right).

► Head MRI (coronal view on left and sagittal view on right) from a patient with a 6.5-cm prolactin-secreting pituitary macroadenoma. There are scattered cystlike areas within the mass, the largest in the right inferior frontal region deforms the frontal horn, resulting in mild midline shift to the left. The mass wraps around the superior and lateral margins of the cavernous sinuses. The patient presented with visual field defects and secondary hypogonadism. Baseline serum prolactin concentration was 6100 ng/mL.

► Head MRI (coronal view on left and sagittal view on right) from the same patient 6 months after normalizing the serum prolactin concentration with a dopamine agonist. Dramatic shrinkage on the MRI is evident. Visual field defects resolved, and pituitary function returned to normal.



macroadenoma is present), an orally administered dopamine agonist (e.g., cabergoline or bromocriptine) is the treatment of choice. Dopamine agonists are very effective in promptly normalizing the serum prolactin concentration and reducing the size of the lactotroph adenoma. After initiating a dopamine agonist, the serum prolactin concentration should be monitored every 2 weeks, and the dosage of bromocriptine or cabergoline should be increased until the prolactin levels decrease into the reference range. Approximately 3 to 6 months after achieving a normal serum prolactin concentration, pituitary-directed magnetic resonance imaging (MRI) should be performed to document tumor shrinkage. The minimal dosage of the dopamine agonist that results in normoprolactinemia should be continued indefinitely. In a small percentage of patients,

prolactin-secreting adenomas may be cured with long-term dopamine agonist therapy. Thus, a periodic (e.g., every 2 years) 2-month holiday off the dopamine agonist is indicated to determine whether hyperprolactinemia recurs. Patients with macroprolactinomas that have sphenoid sinus extension should be cautioned about the potential for cerebrospinal fluid (CSF) rhinorrhea that may occur as the tumor shrinks. CSF rhinorrhea requires an urgent neurosurgical procedure to prevent the development of pneumocephalus and bacterial meningitis. When patients are intolerant of the dopamine agonist (e.g., nausea, lightheadedness, mental fogging, or vivid dreams) or if the tumor is resistant to this form of therapy, transsphenoidal surgery or gamma knife radiation therapy may be considered.



## CORTICOTROPIN-SECRETING PITUITARY TUMOR

Corticotropin (adrenocorticotropic hormone [ACTH])-secreting pituitary adenomas stimulate excess adrenal secretion of cortisol, resulting in the signs and symptoms characteristic of Cushing syndrome (see Plate 3-9). ACTH-secreting pituitary tumors are typically benign microadenomas ( $\leq 10$  mm in largest diameter); occasionally, they are macroadenomas, and very rarely they are carcinomas. Treatment of choice for an ACTH-secreting pituitary adenoma is transsphenoidal selective adenectomy. Surgical success is defined as cure of Cushing syndrome and intact anterior and posterior pituitary function.

The most common operative approach is an endonasal approach (with use of an endoscope), traversing the sphenoid sinus (transsphenoidal) and through the floor of the sella (see Plate 1-31). Corticotroph adenomas are basophilic and stain positively for ACTH on immunohistochemistry. Tissue adjacent to the adenoma usually shows Crooke hyaline change, a result of atrophy of normal corticotrophs. Cure rates are 80% to 90% when a microadenoma can be localized preoperatively with either magnetic resonance imaging (MRI) or inferior petrosal sinus sampling (see Plate 3-10). A lack of cure in patients with microadenomas is attributable to either their small size, so they cannot be seen at surgery, or to an inaccessible location (e.g., cavernous sinus). MRI should be performed with a high-strength magnet (e.g., 3 tesla) and gadolinium enhancement. Only about half of ACTH-secreting pituitary tumors are large enough to be detected by MRI. In addition, approximately 10% of healthy individuals have an apparent microadenoma on MRI; thus, in a patient with Cushing syndrome, an apparent small sellar adenoma on MRI is not specific for a corticotroph adenoma. The lower cure rate ( $\sim 60\%$ ) for macroadenomas is usually because of cavernous sinus involvement that prevents complete resection.

On the day of surgery, these patients should receive an intravenous dose of glucocorticoid (e.g., hydrocortisone, 100 mg). The serum cortisol concentration should be measured the morning after surgery (before additional exogenous glucocorticoid administration) to document a short-term cure, defined as a low serum cortisol concentration (e.g.,  $<1.8$   $\mu\text{g/dL}$ ). If the patient develops symptoms of acute glucocorticoid withdrawal before the serum cortisol laboratory result is available, stress dosages of glucocorticoids should be administered (e.g., hydrocortisone, 100 mg intravenously twice daily). The glucocorticoid dosage is then decreased daily, and patients are typically discharged from the hospital on dosages of exogenous orally administered glucocorticoids twofold above the standard replacement therapy dosage (e.g., prednisone, 10 mg in the morning and 5 mg at 4 PM daily). However, this dosage should be adjusted according to the severity of hypercortisolism preoperatively to prevent severe steroid withdrawal symptoms. Then the dosage of exogenous glucocorticoid is slowly tapered to a standard replacement dosage over 4 to 6 weeks after operation. The hypothalamic corticotropin-releasing hormone neurons and the atrophic anterior pituitary corticotrophs take months to recover from chronic suppression. Most patients tolerate a single dose of a short-acting glucocorticoid (e.g., 15-20 mg of hydrocortisone every morning) starting 8 to 12 weeks after surgical cure. The 8 AM serum cortisol concentration should be measured

every 6 weeks; venipuncture should be performed before taking a morning dose of hydrocortisone. The serum cortisol concentration will slowly increase from undetectable levels to a concentration higher than 10  $\mu\text{g/dL}$ ; when this occurs, the hydrocortisone dosage can be tapered and discontinued over 2 weeks. With this postoperative management protocol, the patient with typical pituitary-dependent Cushing syndrome requires exogenous administration of glucocorticoids for approximately 12 months after curative pituitary surgery. The signs and symptoms related to Cushing syndrome resolve very slowly over the first 6 months after surgery.

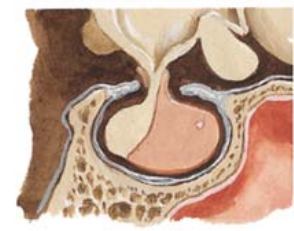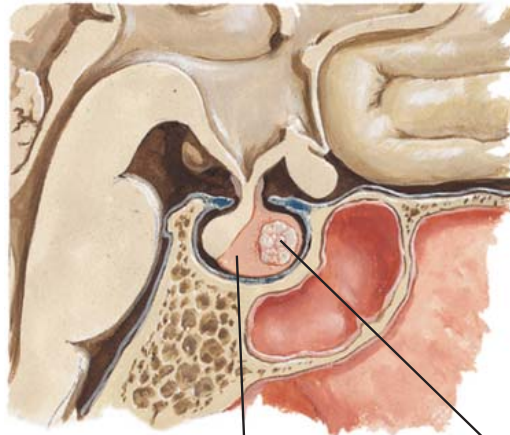
However, even when the postoperative serum cortisol concentration is low, a risk for recurrent disease remains—if a small number of viable adenomatous corticotroph cells are not resected at surgery, they multiply

over time and eventually have the ACTH secretory mass to cause recurrent Cushing syndrome. The average time to clinically evident recurrence is 3 to 4 years. Thus, all patients should be followed up annually and assessed for recurrent disease.

Patients with Cushing syndrome are at increased thromboembolic risk perioperatively, and prophylactic measures to prevent deep venous thrombosis (including starting ambulation the day after surgery) are encouraged.

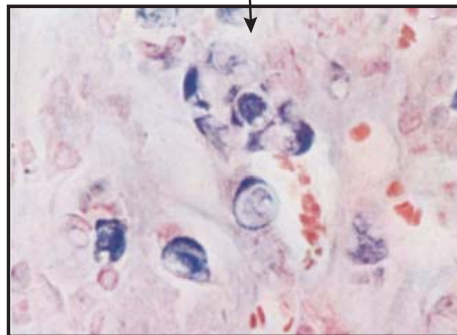
When transsphenoidal surgery fails to cure a patient with pituitary-dependent Cushing syndrome, the two main treatment options are to perform another transsphenoidal surgery or to perform bilateral laparoscopic adrenalectomy. Less frequently used options are radiation therapy to the sella or pharmacotherapy to decrease adrenal cortisol production.

Corticotroph adenoma

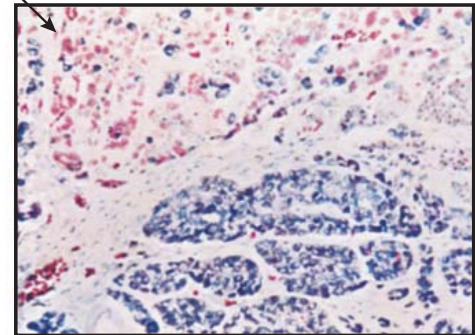


Minute adenoma

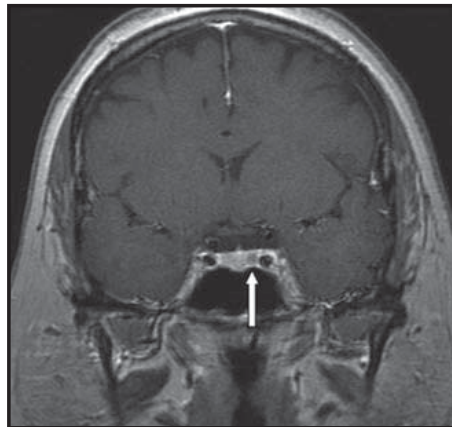
Corticotroph adenoma of moderate size



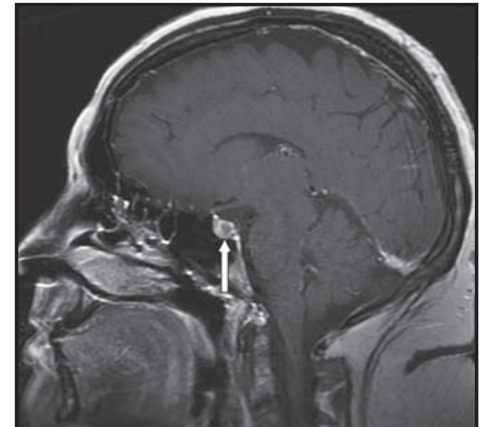
Crooke hyaline change (Mann stain,  $\times 400$ )



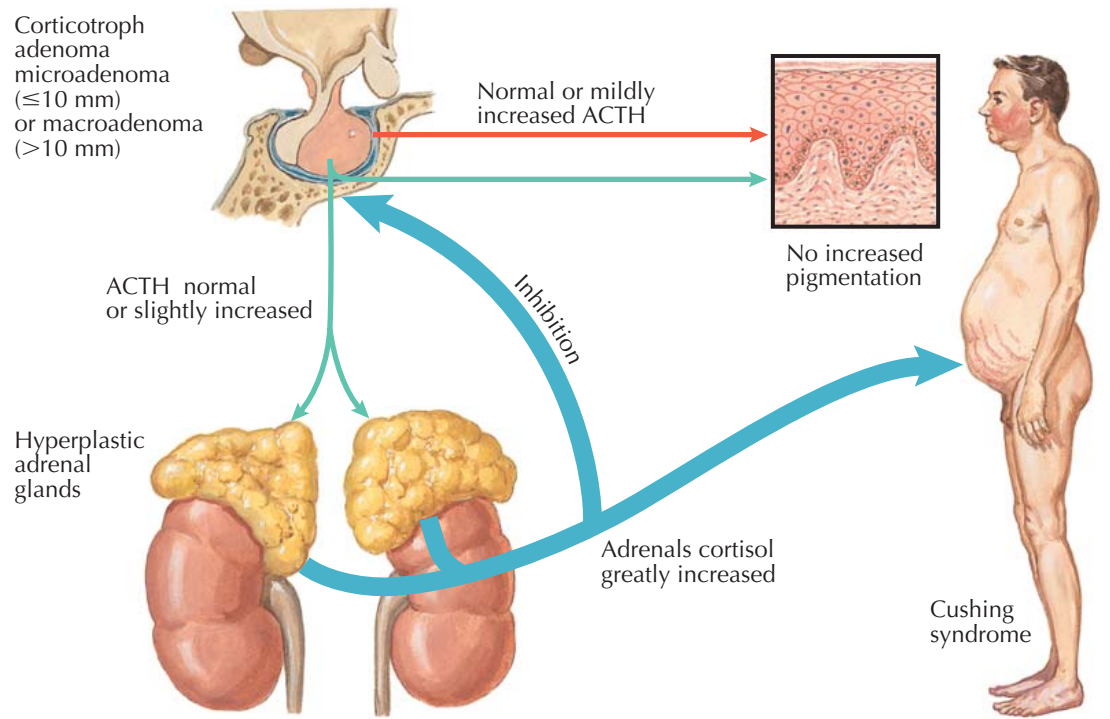
Basophil adenoma (Mann stain,  $\times 125$ )



Head MRI (coronal view) with a 4-mm corticotroph adenoma (arrow) seen as a rounded, hypodense nodule on left side of the sella



Head MRI (sagittal view) with a 4-mm corticotroph adenoma (arrow) located between the anterior and posterior lobes of the pituitary gland

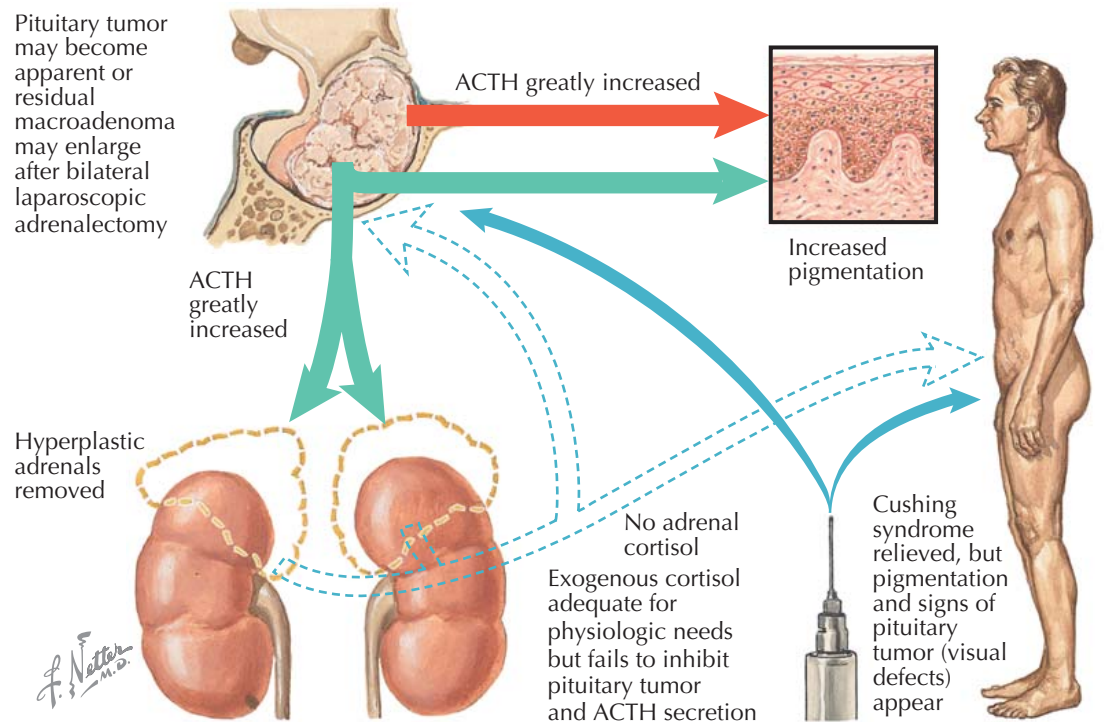


### NELSON SYNDROME

Nelson syndrome is progressive pituitary corticotroph tumor enlargement after bilateral adrenalectomy is performed for the treatment of pituitary-dependent Cushing syndrome. Although the treatment of choice for a corticotroph adenoma is selective adenectomy at the time of transsphenoidal surgery (see Plate 1-22), bilateral laparoscopic adrenalectomy is indicated when pituitary surgery is not successful. When bilateral adrenalectomy cures hypercortisolism, there is less negative feedback on the corticotroph tumor cells with physiologic glucocorticoid replacement, and the adenoma may grow. Nelson syndrome occurs in a minority of patients who follow the treatment sequence of failed transsphenoidal surgery and bilateral adrenalectomy. Most corticotroph microadenomas do not enlarge over time in this setting. However, when pituitary-dependent Cushing syndrome is caused by a corticotroph macroadenoma ( $> 10$  mm in largest diameter), the risk of tumor enlargement after bilateral adrenalectomy is high.

The clinical features of Nelson syndrome are skin hyperpigmentation related to the markedly increased blood levels of pro-opiomelanocortin and corticotropin (adrenocorticotropic hormone [ACTH]) and symptoms related to mass effects of an enlarging pituitary tumor (e.g., visual field defects, oculomotor nerve palsies, hypopituitarism, and headaches). As in Addison disease (see Plate 3-22), generalized hyperpigmentation is caused by ACTH-driven increased melanin production in the epidermal melanocytes. The extensor surfaces (e.g., knees, knuckles, elbows) and other friction areas (e.g., belt line, bra straps) tend to be even more hyperpigmented. Other sites of prominent hyperpigmentation include the inner surface of the lips, buccal mucosa, gums, hard palate, recent surgical scars, areolae, freckles, and palmar creases (the latter may be a normal finding in darker-skinned individuals). The fingernails may show linear bands of darkening arising from the nail beds. Suspected Nelson syndrome can be confirmed by magnetic resonance imaging (MRI) of the sella that demonstrates an enlarging sellar mass. In addition, blood ACTH concentrations are markedly increased in this setting (e.g.,  $> 1000$  pg/mL; reference range, 10–60 pg/mL).

Patients with pituitary-dependent Cushing syndrome who are treated with bilateral adrenalectomy should be



monitored annually with pituitary MRI for approximately 10 years. Tumor-directed radiation therapy should be considered if tumor growth is documented on serial MRI. If feasible, gamma knife radiosurgery is the treatment of choice for Nelson corticotroph tumors. However, unlike most pituitary adenomas, these neoplasms may demonstrate aggressive growth despite radiotherapy. Extensive cavernous sinus involvement may result in multiple cranial nerve palsies. No effective pharmacologic options are available to treat this locally

aggressive neoplasm. Temozolomide is being investigated as a potential treatment option for aggressive pituitary tumors or carcinoma.

Despite the concern about potential development of Nelson syndrome, clinicians should never hesitate to cure Cushing syndrome with bilateral laparoscopic adrenalectomy when transsphenoidal surgery has not been curative. Untreated Cushing syndrome can be fatal, but Nelson syndrome is usually manageable.



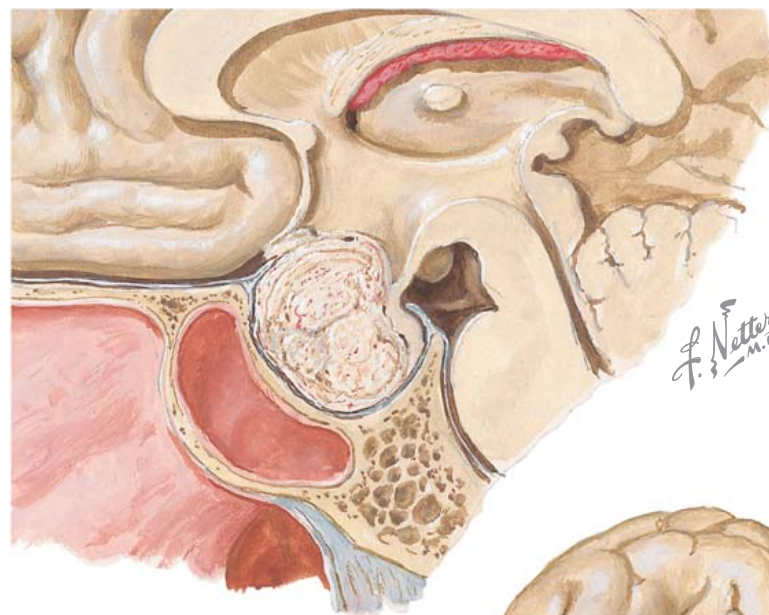## CLINICALLY NONFUNCTIONING PITUITARY TUMOR

Clinically nonfunctioning pituitary tumors are identified either incidentally (e.g., on head magnetic resonance imaging [MRI] to evaluate unrelated symptoms) or because of sellar mass–related symptoms (e.g., visual field defect). On the basis of autopsy studies, pituitary microadenomas ( $\leq 10$  mm in largest dimension) are relatively common, present in approximately 11% of all pituitary glands examined. However, pituitary macroadenomas ( $>10$  mm in largest dimension) are uncommon. Immunohistochemical studies on resected pituitary adenomas can determine the adenohypophyseal cell of origin. The most frequent type of pituitary macroadenoma is the gonadotroph cell adenoma; most do not hypersecrete gonadotropins; thus, affected patients do not present with a hormone excess syndrome. The second most common clinically nonfunctioning pituitary macroadenoma is the null cell adenoma that is not basophilic or acidophilic (chromophobe adenoma); this is a benign neoplasm of adenohypophyseal cells that stains negatively for any anterior pituitary hormone on immunohistochemistry. Rarely, lactotroph, somatotroph, and corticotroph pituitary adenomas may be clinically silent.

The mass-effect symptoms in patients with clinically nonfunctioning pituitary macroadenomas usually prompt evaluation with head MRI. Suprasellar extension of the pituitary adenoma causes compression of the optic chiasm, resulting in the gradual onset of superior bitemporal quadrantanopia that may progress to complete bitemporal hemianopsia (see Plate 1-11). Because the onset is gradual, patients may not recognize vision loss until it becomes marked. Additional mass-effect symptoms from an enlarging sellar mass include diplopia (with cavernous sinus extension and oculomotor nerve compression), varying degrees of pituitary insufficiency (related to compression of the normal pituitary gland by the macroadenoma), and headaches.

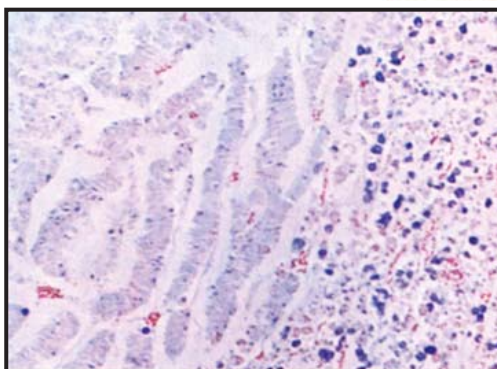
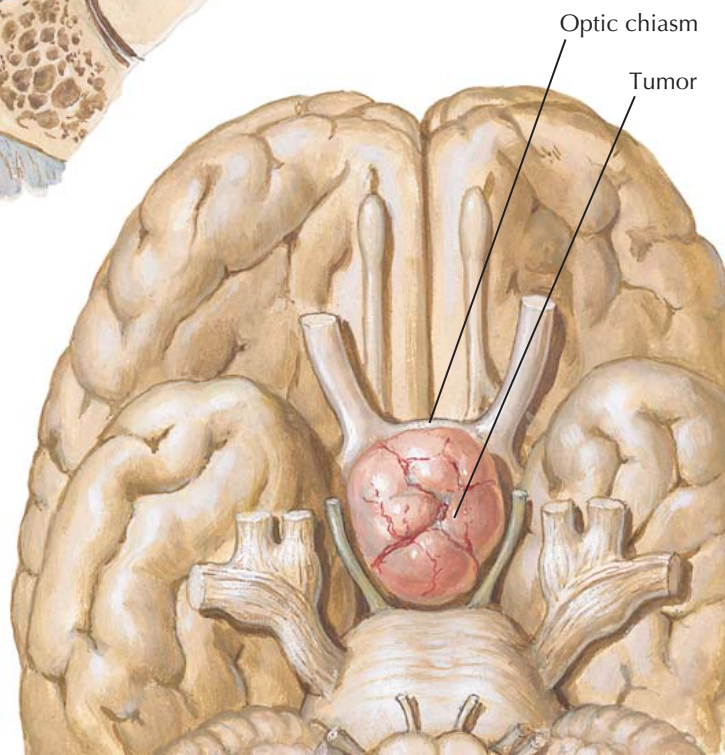
MRI is the imaging of choice to evaluate the sella and surrounding structures. MRI clearly shows the degree of suprasellar and parasellar extension of pituitary macroadenomas. All patients with pituitary macroadenomas should be assessed for tumoral hyperfunction, compression-related hypopituitarism, and visual field defects. Nonfunctioning pituitary macroadenomas are often associated with mild hyperprolactinemia (e.g., serum prolactin concentration between 30 and 200 ng/mL) because of pituitary stalk compression and prevention of hypothalamic dopamine (prolactin inhibitory factor) from reaching all of the anterior pituitary lactotrophs. Pituitary lactotrophs are the only anterior pituitary cells that are under continuous inhibitory control from the hypothalamus. Additional pituitary-related hormones that should be measured in all patients with pituitary macroadenomas include luteinizing hormone, follicle-stimulating hormone,  $\alpha$ -subunit of glycoprotein hormones, target gonadal hormone (estrogen in women and testosterone in men), insulinlike growth factor 1, corticotropin, cortisol, thyrotropin, and free thyroxine. Diabetes insipidus is rare in patients with benign tumors of the adenohypophysis.

The goals of treatment are to correct mass-effect symptoms (e.g., vision loss) and to preserve pituitary

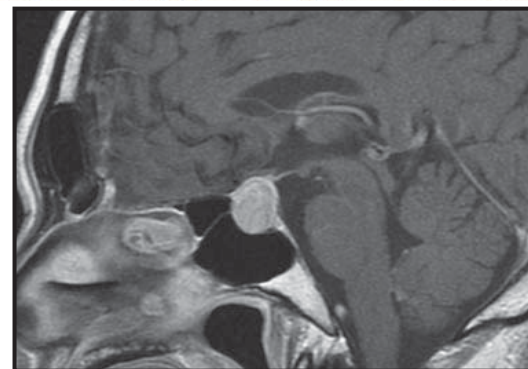


Gonadotroph adenoma enlarging sella

Compression of optic chiasm by clinically nonfunctioning pituitary macroadenoma



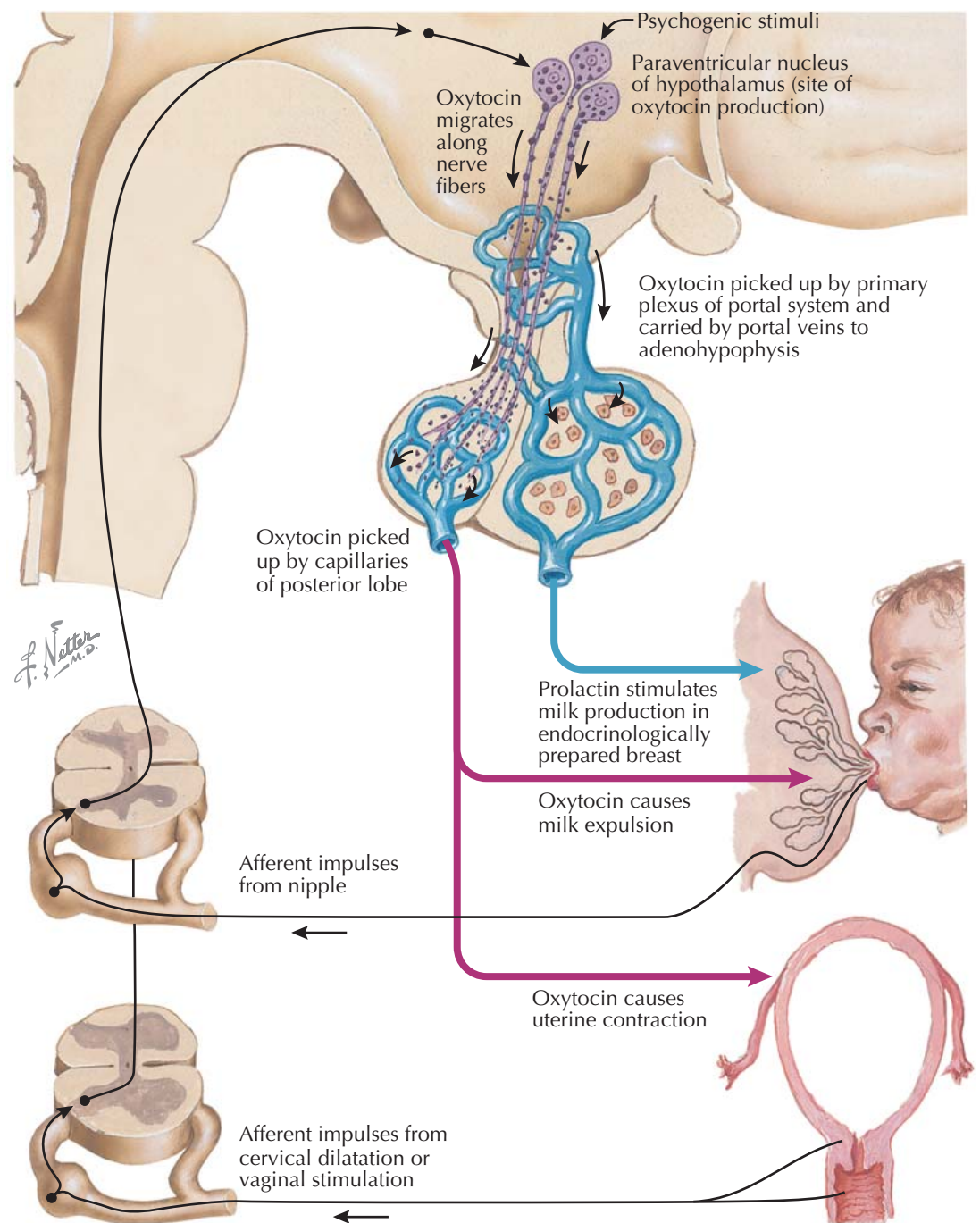
Null cell adenoma (Mann stain,  $\times 100$ )



MRI (sagittal view) showing suprasellar extension of a clinically nonfunctioning pituitary macroadenoma

function. Currently, no effective pharmacologic options are available to treat patients with clinically nonfunctioning pituitary tumors. Observation is a reasonable management approach in elderly patients who have normal visual fields. However, intervention should be considered in all patients with vision loss. Transsphenoidal surgery (see Plate 1-31) can provide prompt resolution of visual field defects and a permanent cure. If present preoperatively, pituitary insufficiency may

recover in some patients after operation. Effectiveness of transsphenoidal surgery is assessed by the findings on postoperative MRI (typically performed 3 months after surgery) and by blood levels of adenoma secretory products that may have been increased before surgery (e.g.,  $\alpha$ -subunit of glycoprotein hormones). Recurrence of the pituitary adenoma after transsphenoidal surgery can be treated with stereotactic Gamma knife radiotherapy.



## SECRETION AND ACTION OF OXYTOCIN

The physiologic roles of oxytocin are smooth muscle activation promoting milk letdown with breastfeeding and uterine myometrial contraction at parturition. The milk-producing compartments of the breast are composed of multiple alveolar clusters of milk-producing (glandular) cells surrounded by specialized myoepithelial cells. Prolactin stimulates milk production in endocrinologically prepared breasts. The alveoli are connected to ductules that lead to large ducts that lead to the nipple. The glandular cells have receptors for oxytocin and cause myoepithelial contraction when activated. In addition, oxytocin acts on ductal myoepithelial cells to enhance milk flow to the nipple. Activation of nipple tactile and mechanoreceptors by suckling sends an afferent signal to the spinal cord and from the spinal cord to the oxytocinergic neurons in the supraoptic and paraventricular nuclei. Oxytocin is then released

from the posterior pituitary in a pulsatile fashion that effects a pumping action on the alveoli, promoting emptying of milk from the alveoli. In the absence of oxytocin, only approximately 30% of stored milk is released during nursing. There is a latent period of approximately 30 seconds between the onset of suckling and commencement of milk flow. Psychogenic stimuli can also trigger milk letdown in lactating mothers. Changes in estrogen and progesterone at the time of parturition help modulate the lactation response both by affecting oxytocin synthesis and secretion and by impacting oxytocin receptors.

Oxytocin is a powerful uterotonic stimulant for contractions, and oxytocin secretion increases with the expulsive phase of parturition. During pregnancy, the uterus is maintained in a quiet state by the actions of progesterone and relaxin. The initiation of labor is accomplished by a relative increase in estrogen

activation and a decrease in progesterone activation. There is a 200-fold increase in the responsiveness of the uterus to oxytocin as parturition approaches.

Synthetic oxytocin administration is a clinically proven method of labor induction. Oxytocin is administered intravenously at an escalating dose until there is normal progression of labor, strong contractions occurring at 2- to 3-minute intervals, or uterine activity reaches 150 to 350 Montevideo units (the peak strength of contractions in mm Hg measured by an internal monitor multiplied by their frequency over 10 minutes). When uterotonic drugs are administered, continuous monitoring of fetal heart rate and uterine activity helps prevent induction of excessive or inadequate uterine activity. Other methods used to induce labor include "membrane stripping," amniotomy, intravaginal administration of prostaglandins E<sub>2</sub> or E<sub>1</sub>, and breast stimulation.

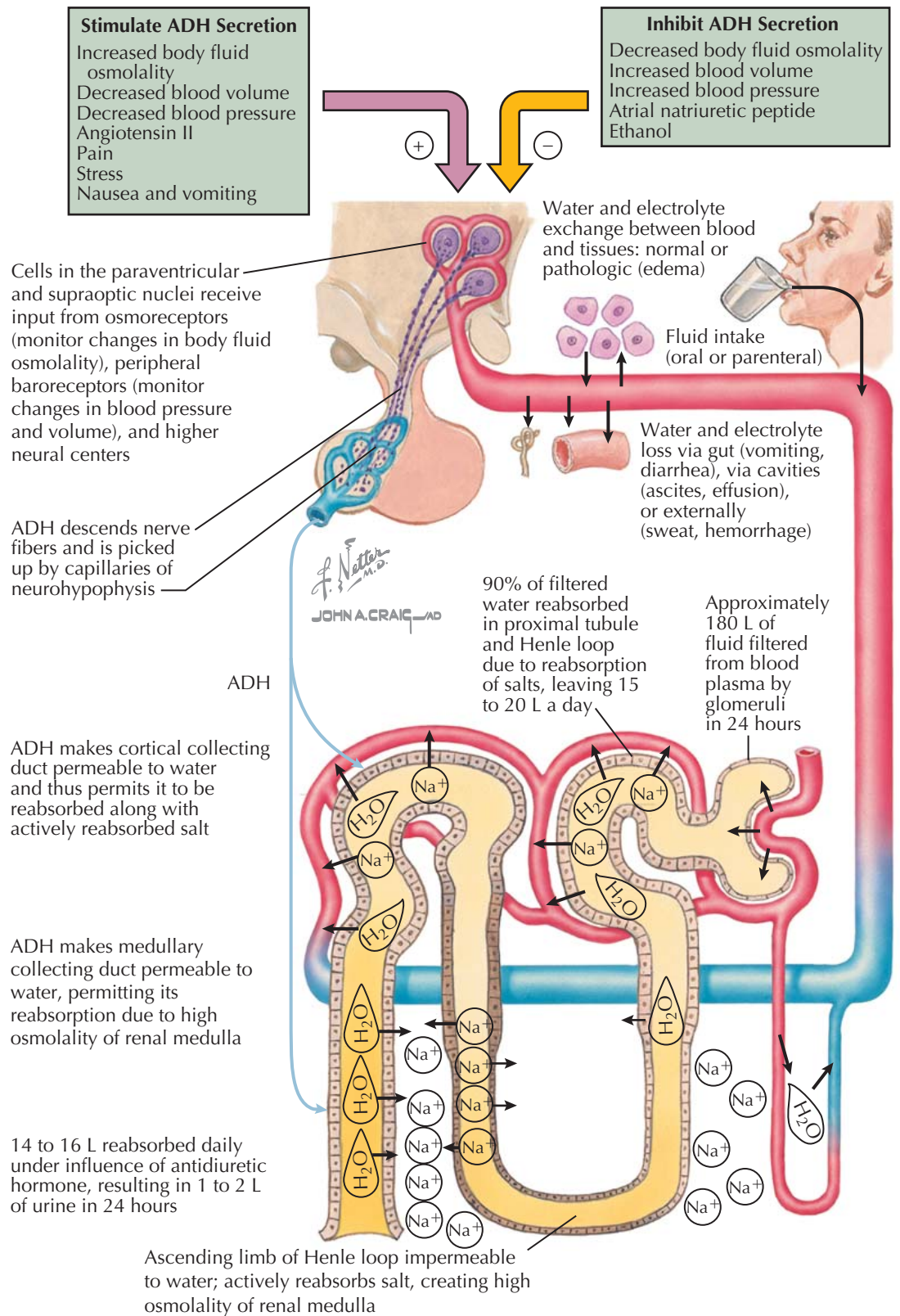


## SECRETION AND ACTION OF VASOPRESSIN

Vasopressin, also known as antidiuretic hormone (ADH), is the key hormone involved in the regulation of water homeostasis and osmolality of body fluids. The secretion and action of vasopressin are regulated by osmotic and pressure/volume factors. Osmoreceptors continuously monitor plasma osmolality. The osmoreceptors are outside the blood-brain barrier, are located in the organum vasculosum of the lamina terminalis (adjacent to the anterior hypothalamus near the anterior wall of the third ventricle), and are perfused by fenestrated capillaries. The normal extracellular fluid osmolality—determined to a major degree by serum sodium concentration—varies from 282 to 287 mOsm/kg in healthy individuals. The keys to maintaining this narrow normal range are (1) the very sensitive osmoreceptor-regulated response of vasopressin secretion to changes in plasma osmolality, (2) the prompt response of urine osmolality to changes in plasma vasopressin, and (3) the short plasma half-life of vasopressin (~15 minutes). Thus, small increases in plasma osmolality result in a prompt increase in urine concentration, and small decreases in osmolality result in prompt water diuresis.

Over 24 hours, glomerular filtration presents 180 L of isoosmotic fluid to the proximal convoluted renal tubules. Ninety percent of the filtered water is reabsorbed in the proximal tubule without the help of vasopressin. This passive transfer of water is determined by the active reabsorption of solutes (e.g., sodium and chloride) taking along water by osmotic forces. Thus, proximal tubular urine remains isoosmotic with plasma. Distal collecting duct reabsorption of water is controlled by vasopressin. The loop of Henle and the collecting duct in the kidney are critical to water conservation. The countercurrent multiplier system in the loop of Henle generates a high osmolality in the renal medulla. The ascending, or distal, limb of Henle loop actively transports sodium without water from the tubular urine to the interstitial fluid of the renal medulla, making it very hypertonic. The water impermeability of this limb of Henle loop renders the urine entering the distal tubule hypotonic with respect to plasma. In the absence of vasopressin, the distal tubule and collecting ducts remain largely impermeable to water, and very dilute urine leaves the kidney. With maximum vasopressin secretion, urine osmolality plateaus at approximately 1000 to 1200 mOsm/kg, limited by the maximal osmolality of the inner renal medulla. When vasopressin is absent, 14 to 16 L of urine is excreted per day.

The site of action of vasopressin is the V2 receptor on the epithelial principal cells of the collecting ducts. Activation of the collecting duct V2 receptor increases water permeability to allow for osmotic equilibration between the urine and the hypertonic medullary interstitium. Thus, water is extracted from the urine into the medullary interstitial blood vessels, causing an increased urine concentration and decreased urine volume. Aquaporins are intracellular organelles, or water channels, that mediate rapid water transport across collecting duct cell membranes. V2-receptor activation by vasopressin increases intracellular cyclic adenosine monophosphate (cAMP) levels by activating adenylate cyclase. cAMP activates protein kinase A, which phosphorylates aquaporin-2 and induces a fusion of aquaporin-2-containing intracytoplasmic vesicles with the apical plasma membranes of the principal cells, thus



Cells in the paraventricular and supraoptic nuclei receive input from osmoreceptors (monitor changes in body fluid osmolality), peripheral baroreceptors (monitor changes in blood pressure and volume), and higher neural centers

ADH descends nerve fibers and is picked up by capillaries of neurohypophysis

ADH makes cortical collecting duct permeable to water and thus permits it to be reabsorbed along with actively reabsorbed salt

ADH makes medullary collecting duct permeable to water, permitting its reabsorption due to high osmolality of renal medulla

14 to 16 L reabsorbed daily under influence of antidiuretic hormone, resulting in 1 to 2 L of urine in 24 hours

Ascending limb of Henle loop impermeable to water; actively reabsorbs salt, creating high osmolality of renal medulla

increasing apical water permeability by markedly increasing the number of water-conducting pores in the apical plasma membrane. The aquaporin-containing vesicles are shuttled into and out of the membrane in response to changes in intracellular cAMP levels, resulting in a minute-to-minute regulation of renal water excretion in response to changes in circulating vasopressin.

Water intake is also a key factor in maintaining water homeostasis. Increases in plasma osmolality of the

extracellular fluid or decreases in intravascular volume stimulate thirst. Thirst is regulated by osmoreceptors in the anterior hypothalamus and baroreceptors in the chest. The sensation of thirst is typically triggered by a 2% increase in plasma osmolality. Because of unregulated fluid ingestion (e.g., coffee, tea, soft drinks, and water from metabolized food), thirst does not represent a major regulatory mechanism and, in a typical healthy person, excess water is excreted daily by the osmoregulated secretion of vasopressin.

## CENTRAL DIABETES INSIPIDUS

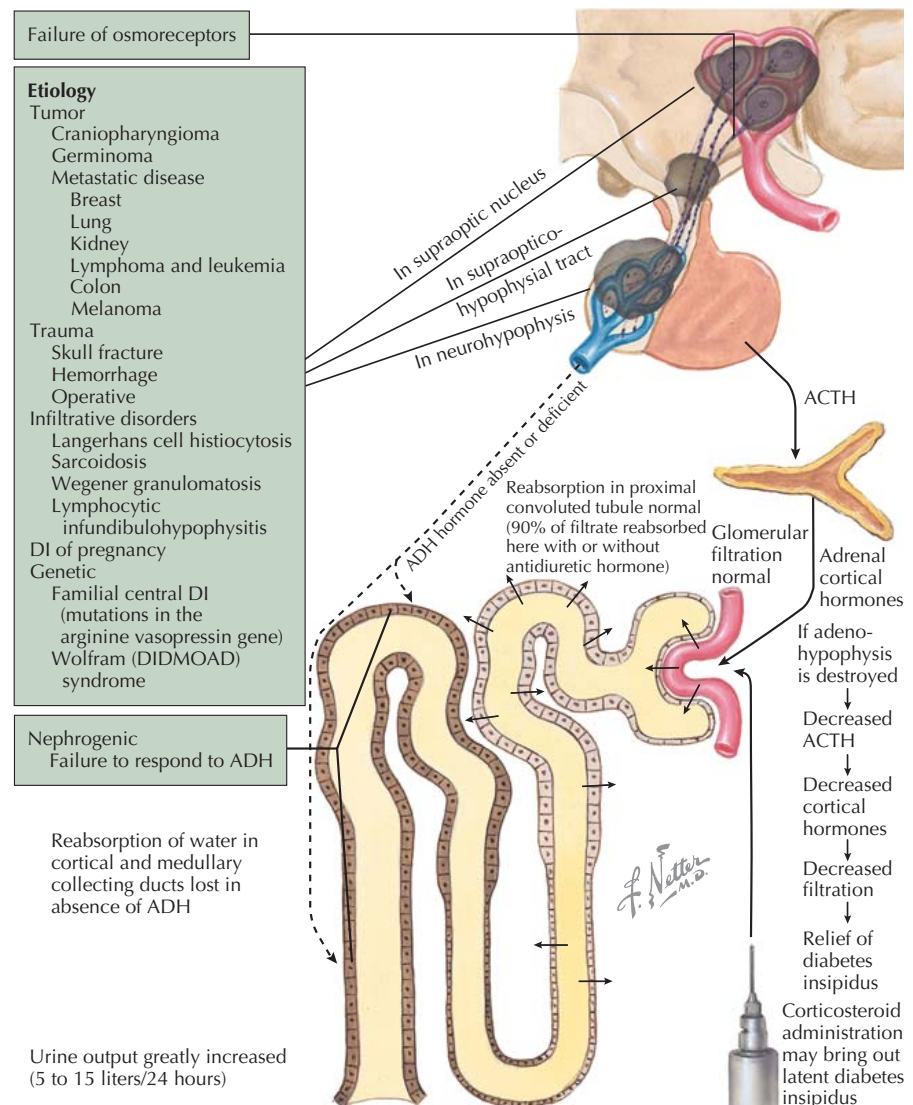
Diabetes insipidus (DI) literally means a large volume of urine (diabetes) that is tasteless (insipid). Central DI is characterized by a decreased release of antidiuretic hormone (ADH; vasopressin), resulting in polydipsia and polyuria. ADH deficiency may be a result of disorders or masses that affect the hypothalamic osmoreceptors, the supraoptic or paraventricular nuclei, or the superior portion of the supraopticohypophysial tract. Approximately 90% of the vasopressinergic neurons must be destroyed to cause symptomatic DI. Because the posterior pituitary gland stores but does not produce ADH, damage by intrasellar pituitary tumors usually does not cause DI. The most common causes of central DI are trauma (e.g., neurosurgery, closed-head trauma), primary or metastatic tumors, and infiltrative disorders. Central DI can be exacerbated by or first become apparent during pregnancy, during which ADH catabolism is increased by placental hyperproduction of the enzyme cysteine aminopeptidase (vasopressinase).

Persons with central DI typically have a sudden onset of polyuria and thirst for cold liquids. They usually wake multiple times through the night because of the need to urinate and drink fluids—often ice cold water from the refrigerator. When seen in the outpatient clinic, these patients usually have a large thermos of ice water by their side. The degree of polyuria is dictated by the degree of ADH deficiency—urine output may range from 3 L/day in mild partial DI to more than 10 to 15 L/day in severe DI. In patients with concurrent anterior pituitary failure, secondary adrenal insufficiency is associated with decreased glomerular filtration (associated with decreased blood pressure, cardiac output, and renal blood flow), leading to decreased urine output. Glucocorticoid deficiency also increases ADH release in patients with partial DI. These effects are reversed when glucocorticoid replacement is administered and DI is “unmasked,” resulting in the rapid onset of polyuria.

Neurosurgery in the sellar region (either by craniotomy or transsphenoidal routes) or blunt head trauma that affects the hypothalamus and posterior pituitary may result in DI. As many as 50% of patients experience transient central DI within 24 hours of pituitary surgery; it resolves over several days. With the minimally invasive endoscopic transnasal transsphenoidal approach to pituitary surgery, the rate of postoperative permanent DI is less than 5%; however, with transcranial operations and with larger tumors that have hypothalamic involvement (e.g., craniopharyngioma), up to 30% of patients develop permanent DI. Damage to the hypothalamus by neurosurgery or trauma often results in a triphasic response: (1) an initial polyuric phase—related to decreased ADH release because of

axon shock and lack of action potential propagation—beginning within 24 hours of surgery and lasting approximately 5 days; (2) an antidiuretic phase (days 6–12), during which stored ADH is slowly released from the degenerating posterior pituitary, and hyponatremia may develop if excess fluids are administered; and (3) a permanent DI after the posterior pituitary ADH stores are depleted. In 10% to 25% of all patients who undergo pituitary surgery, only the second of these three phases is seen, and DI never develops because surgical trauma only damages some of the axons; this results in inappropriate ADH release, but the intact axons continue to function and prevent the onset of DI. However, this transient, inappropriate release of ADH can have serious consequences, with marked hyponatremia that peaks approximately 7 days after surgery and that may be associated with headaches, nausea, emesis, and seizures. This sequence of events can be avoided by advising the patient to “drink for thirst only for the first 2 weeks” after a pituitary operation.

Primary (e.g., craniopharyngioma, germinoma) or metastatic (e.g., breast, lung, kidney, lymphoma, leukemia, colon, or melanoma) disease in the brain can involve the hypothalamic–pituitary region and lead to central DI. Polyuria and polydipsia may be the presenting symptoms of metastatic disease.



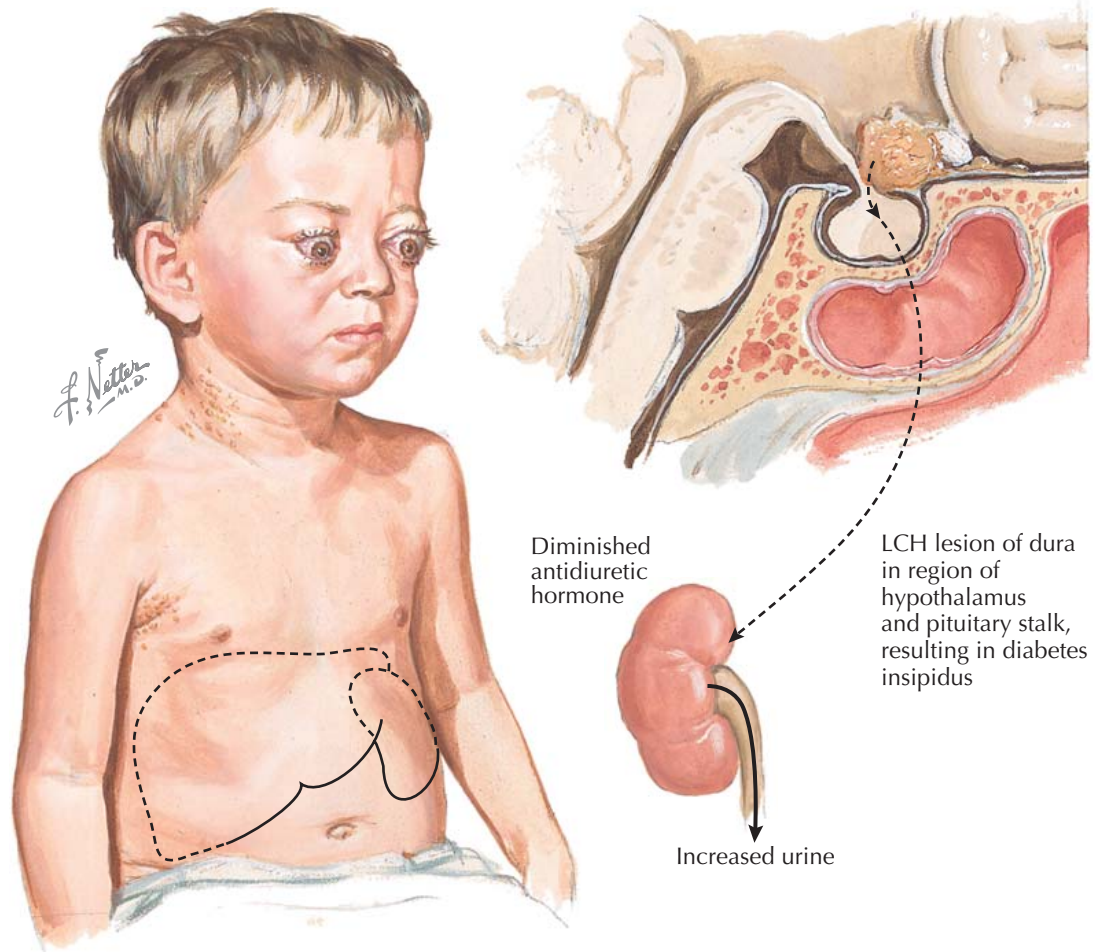


## LANGERHANS CELL HISTIOCYTOSIS IN CHILDREN

Langerhans cell histiocytosis (LCH)—previously known as histiocytosis-X, eosinophilic granuloma, Hand-Schüller-Christian disease, or Letterer-Siwe disease—is a disorder of the Langerhans cell, a bone marrow–derived dendritic cell that has a key role in antigen processing. Normal Langerhans cells—located in the epidermis, lymph nodes, thymic epithelium, and bronchial mucosa—process antigens and then migrate to lymphoid tissues, where they function as effector cells stimulating T-cell responses. Although the cause of the defect in LCH is unknown, it is a result of immunologic dysfunction. In LCH, the Langerhans cell loses its ability to present antigens.

LCH in children is rare, affecting three to five children per million each year. LCH may present as a localized or diffuse disorder. When localized, the presenting findings may include bone, skin, or lymph node involvement. In infants, brown-purplish papules may be evident, which are usually associated with a benign and self-healing course in the first year of life. However, multisystem disease may become evident later in childhood. When skin-limited LCH is suspected, it should be confirmed with computed tomographic (CT) imaging of the chest and abdomen and bone marrow biopsy to verify that there are no other abnormalities. Later in infancy, skin-limited LCH presents as a red papular rash variably involving the neck, axilla, abdomen, back, groin, and scalp.

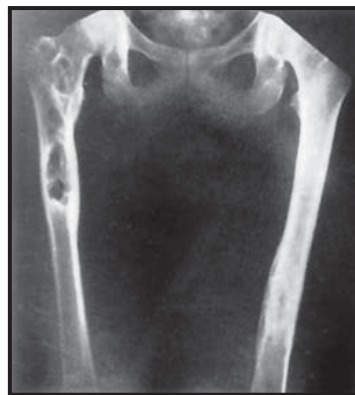The most common site of involvement in childhood LCH is bone, typically presenting as a lytic skull lesion identified in the evaluation of localized pain and erythema. Other bones that may be involved include ribs, cervical vertebral bodies, humerus, and femur. LCH lesions can extend from the bone and cause mass-effect presentations. For example, skull base, maxillofacial bone, and sellar involvement may lead to hearing loss, exophthalmos, cranial nerve palsies, and diabetes insipidus (DI). On skull radiographs, extensive involvement of the skull may be observed with irregularly shaped, lucent lesions—“geographic skull.” DI is the most common endocrine manifestation of LCH, and it may be the initial presenting symptom complex (see Plate 1-27). These patients also have varying degrees



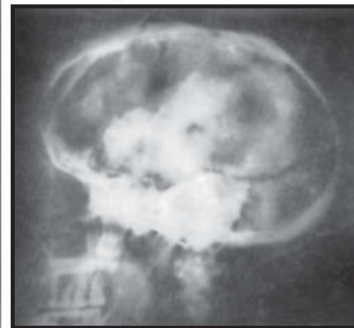Diminished antidiuretic hormone

LCH lesion of dura in region of hypothalamus and pituitary stalk, resulting in diabetes insipidus

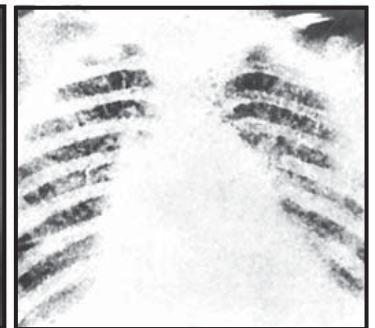Increased urine



Osteolytic lesions of bones



Osteolytic LCH lesions of skull (geographic skull)



Lung involvement

of anterior pituitary insufficiency. In patients with pituitary dysfunction, thickening of the pituitary stalk is usually evident.

LCH may present as isolated lymphadenopathy, usually of the cervical or mediastinal lymph nodes.

Diffuse multisystem disease often involves the liver and spleen. Patients with hepatic involvement may present with signs and symptoms related to clotting factor deficiencies, increased bilirubin, and low serum albumin. Cytopenias may result from the splenomegaly. When the lungs are involved, LCH appears in a cystic and nodular pattern; the first sign of pulmonary involvement may be pneumothorax (see Plate 1-29).

LCH in the lung can cause diffuse fibrosis with symptoms of dyspnea. Bone marrow involvement is common in patients with diffuse disease. Ataxia and cognitive dysfunction sometimes result from LCH lesions involving the cerebellum or basal ganglia.

In the past, LCH was referred to as Hand-Schüller-Christian disease if the triad of skull defects, DI, and exophthalmos were prominent. *Letterer-Siwe disease* was the old term used to describe the presentation of LCH with extensive multiorgan involvement (e.g., skin, lungs, liver, spleen, lymph nodes, bone marrow, lymph nodes). *Eosinophilic granuloma* was the term used to describe localized lesion(s) confined to bone.



## LANGERHANS CELL HISTIOCYTOSIS IN ADULTS

Langerhans cell histiocytosis (LCH)—previously known as histiocytosis-X, eosinophilic granuloma, Hand-Schüller-Christian disease, or Letterer-Siwe disease—is a disorder of the Langerhans cell, a bone marrow-derived dendritic cell that has a key role in antigen processing. Normal Langerhans cells—located in the epidermis, lymph nodes, thymic epithelium, and bronchial mucosa—process antigens and then migrate to lymphoid tissues where they function as effector cells stimulating T-cell responses. Although the cause of the defect in LCH is unknown, it is a result of immunologic dysfunction. In LCH, the Langerhans cell loses its ability to present antigens.

LCH in adults is rare, affecting one to two persons per million each year. The mean age at the time of diagnosis is 32 years. The most common presentation is dermatologic symptomatology (rash) followed by pulmonary symptoms (e.g., cough, dyspnea, tachypnea), pain (e.g., bone pain), diabetes insipidus (DI), systemic symptoms (e.g., fever, weight loss), lymphadenopathy, ataxia, and gingival hypertrophy. Because of the diverse presentation and the rarity of this disorder, LCH may not be accurately diagnosed for many years. In some cases, apparent isolated DI is diagnosed in childhood, and the other sites of involvement and associated symptoms do not develop until later in life. DI, caused by Langerhans cell infiltration of the hypothalamus and pituitary stalk, occurs in approximately 25% of patients with LCH and is irreversible.

The skin rash of LCH is papular and pigmented (red, brown). Papule size ranges from 1 mm to 1 cm. Some of the skin lesions may become ulcerated, especially in intertriginous areas.

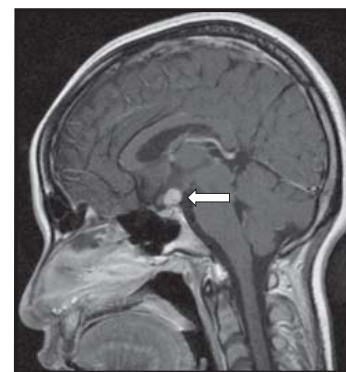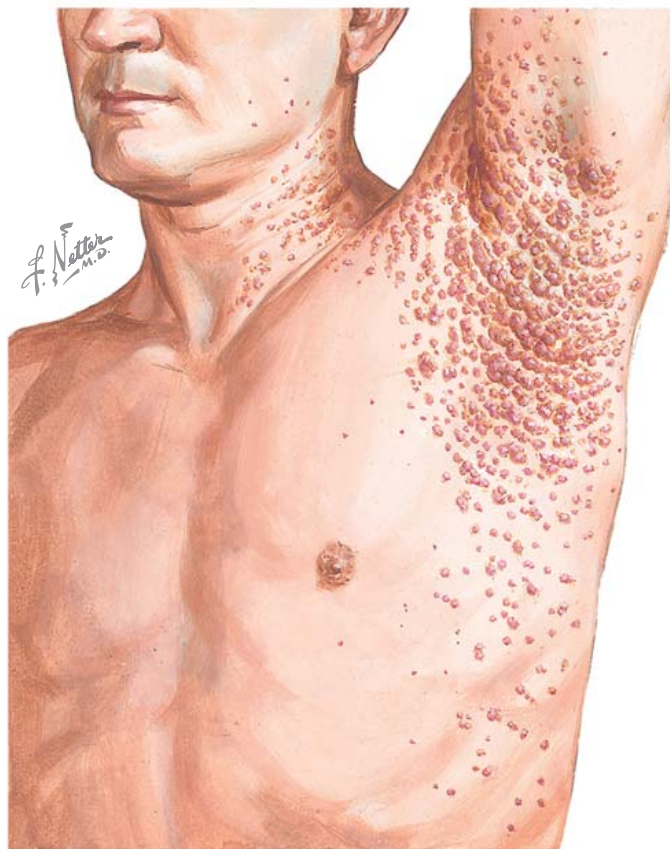
The most common sites of bone involvement in LCH are the mandible, skull, long bones, pelvic bones, scapula, vertebral bodies, and ribs. Thus, the initial presenting symptoms in a patient with LCH may be jaw pain and loose teeth. Dental radiographs may show erosion of the lamina dura and the appearance of “floating teeth.” Solitary or polyostotic eosinophilic granuloma, representing 75% of all cases of LCH, typically occur in children or young adults. These lesions present as areas of tenderness and swelling. Radiographs show round lesions with a beveled edge.

Isolated pulmonary involvement may present with pneumothorax. Pulmonary LCH is exacerbated by cigarette smoking. Chest radiographs show a diffuse infiltrate with a “honeycomb lung” appearance. Computed tomography (CT) shows typical nodules and cysts of LCH.

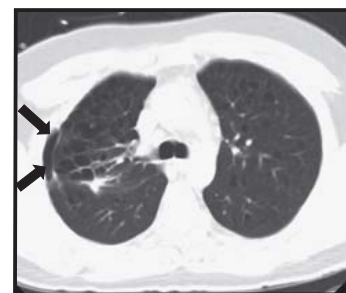The diagnosis of LCH should be confirmed with a biopsy of a lesion. Pathologic examination shows a mixed cellular infiltrate with proliferation of immature clonal Langerhans cells. Other inflammatory cells (e.g., eosinophils, macrophages, granulocytes, and lymphocytes) are frequently seen in the specimen. Multinucleated giant cells may be present. The macrophages and multinucleated giant cells are phagocytic and can accumulate cholesterol and have the appearance of “foam cells.” Immunohistochemical studies are confirmatory with positive staining for S100 protein, vimentin, CD1a, and antilangerin.

A full laboratory and imaging evaluation is indicated to determine the extent of disease in newly diagnosed patients. Typical laboratory tests include a complete blood cell count, liver function tests, coagulation studies, and simultaneous fasting urine and serum

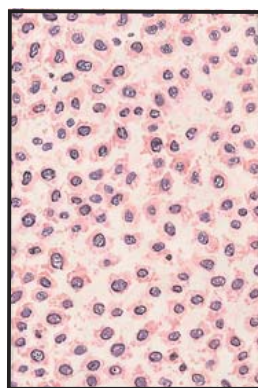
Disseminated LCH lesions in axilla and on neck and trunk



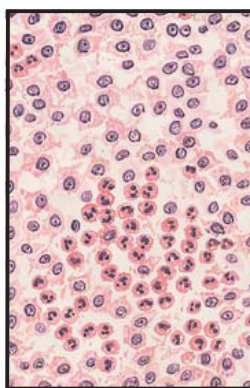
Sagittal head MRI showing a 1-cm enhancing suprasellar lesion (arrow) of LCH. Also note the lack of the posterior pituitary bright spot in this patient with diabetes insipidus.



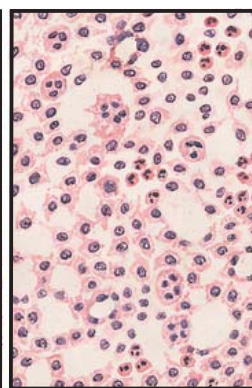
Chest CT showing multiple pulmonary cysts typical of pulmonary LCH. Also note the small pneumothorax on the right lateral chest (arrows).



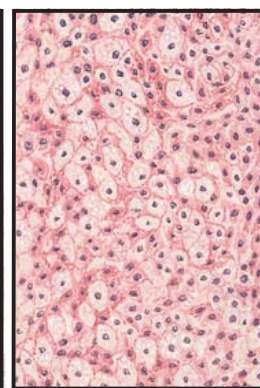
Sheets of Langerhans cell histiocytes with abundant pink cytoplasm and folded nuclei with prominent nuclear grooves



Nests of eosinophils among Langerhans cell



Multinucleated giant cells in granulation tissue



Lipid accumulation within macrophages and giant cells

osmolalities. Imaging should include a skeletal survey, skull radiography, and chest radiography. Signs and symptoms should guide whether additional tests are needed (e.g., dental radiographs, head magnetic resonance imaging [MRI], chest CT, pulmonary function tests, bone marrow biopsy).

The prognosis for patients with LCH can be predicted in part by the age of onset, number of organs involved, and degree of organ dysfunction (e.g., hyperbilirubinemia). For example, whereas an adult with a solitary bone lesion (eosinophilic granuloma) has an excellent prognosis, an infant with marked multiorgan involvement has a worse prognosis. Thus, in general, a

better prognosis is associated with an age of onset older than 2 years and involvement of fewer than four organ systems.

Treatment based on prognosis stratification may include cladribine (2-chlorodeoxyadenosine) or a combination of chemotherapeutic agents (e.g., vinblastine, etoposide, methotrexate, and 6-mercaptopurine), corticosteroids (topical or systemic), and radiotherapy. Solitary bone lesions may be treated with surgical curettage, localized radiation therapy, or both. Anticytokine-based therapies are under investigation. Bone marrow transplantation may be considered for patients whose disease does not respond to standard therapies.

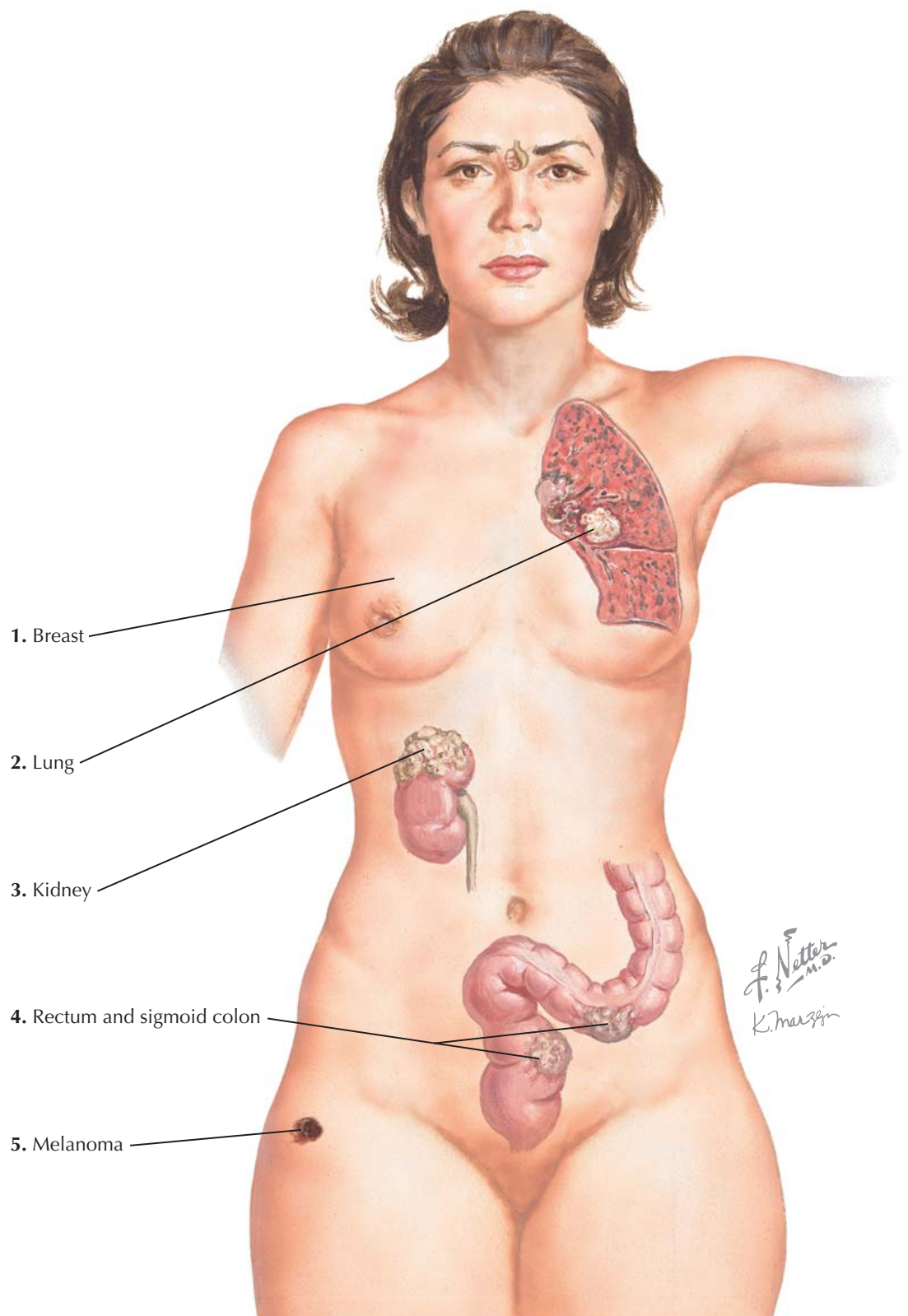


## TUMORS METASTATIC TO THE PITUITARY

Metastasis to the pituitary gland is a rare cause of an intrasellar mass discovered during life. When the pituitary gland of patients with cancer is examined at autopsy, pituitary metastases are found in about 3.5% of patients. Most metastases to the pituitary are clinically silent and may be too small to be detected on computed imaging. When detected during life, the most common clinical presentations are diabetes insipidus (DI), visual impairment (e.g., bitemporal hemianopsia), headaches, cranial nerve deficits (e.g., palsies of cranial nerves III or IV), and varying degrees of hypopituitarism. Mild hyperprolactinemia (i.e., serum prolactin concentrations are usually  $<200$  ng/mL) may be present and associated with an interruption of the pituitary stalk delivery of dopamine to suppress normal lactotroph production of prolactin. The most common locations for the primary malignancy (in order of frequency) are the breast, lung, kidney, colon, skin (melanoma), prostate, thyroid, stomach, pancreas, nasopharynx, lymph nodes, uterus, and liver. Breast and lung cancer account for most metastases to the pituitary. In approximately 80% of cases, the pituitary metastasis is discovered after or concurrent with the primary malignancy—the average interval is 3 years. The longest interval between the diagnosis of primary cancer and the discovery of the pituitary metastasis is found in patients with breast cancer, and the shortest interval is found in those with lung cancer. Most of these patients have metastatic disease to five or more sites in addition to the sellar region. The most common sites of extrapituitary metastases are the lymph nodes, lung, and bone.

The routes by which metastases reach the pituitary include hematogenous spread, spread from a hypothalamo-hypophyseal metastasis through the portal vessels, direct extension from parasellar sites or skull base, or meningeal spread from the suprasellar cistern. Most metastases involve the posterior lobe, presumably because of its direct arterial blood supply from the hypophyseal arteries. Because the anterior lobe does not have a direct arterial supply (see Plate 1-3), metastases that involve the anterior lobe are usually attributable to direct extension from the posterior lobe nidus.

A pituitary metastasis may closely mimic pituitary adenoma. Indeed, the clinical presentation and the neuroimaging and endocrinologic data usually suggest a nonfunctioning pituitary adenoma. Thus, metastatic



1. Breast
2. Lung
3. Kidney
4. Rectum and sigmoid colon
5. Melanoma

disease should always be considered in the differential diagnosis of a pituitary mass. Because DI is a very unusual ( $<1\%$ ) component of the presentation of benign pituitary adenomas, sellar metastasis should be highly suspected when patients present with DI and a rapidly growing pituitary mass. Tissue diagnosis is required to confirm metastatic disease.

Metastatic disease to the pituitary is a poor prognostic sign; the 1-year mortality rate is 70%. Because of

the poor prognosis associated with sellar metastases, the most reasonable therapeutic approaches are palliative radiotherapy, pituitary target hormone replacement therapy when indicated, and primary tumor-directed chemotherapy. Total resection is usually not possible because metastases are usually diffuse, invasive, vascular, and hemorrhagic. Surgical debulking of the sellar metastasis may be beneficial in patients with visual field defects caused by compression of the optic chiasm.

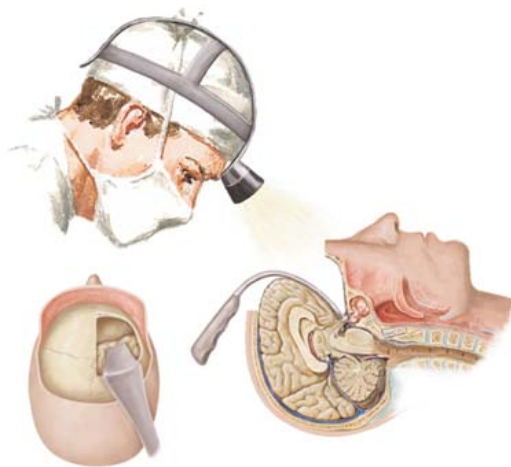
## SURGICAL APPROACHES TO THE PITUITARY

The three primary goals of pituitary surgery are to (1) completely resect the pituitary adenoma so that visual field defects are corrected and the hormone excess syndrome (e.g., acromegaly, Cushing disease) is cured, (2) avoid complications (e.g., cerebrospinal fluid rhinorrhea, neurologic damage), and (3) preserve viable pituitary tissue and avoid hypopituitarism. The ability to meet these three objectives depends on the expertise of the pituitary surgeon and on the size, location, and consistency of the pituitary tumor. For example, whereas the cure rate for pituitary microadenomas ( $\leq 10$  mm in diameter) is 80% to 90%, the cure rate for pituitary macroadenomas ( $> 10$  mm in diameter) is 50% to 60%. When pituitary tumors are larger than 20 mm in diameter, the surgical cure rate decreases to 20%. In addition, the location of the pituitary tumor is an important determinant of the cure rate; invasion of the cavernous sinuses usually prevents complete removal. Some tumors with marked suprasellar extension may adhere to the optic chiasm, the hypothalamus, or both, and attempting complete removal risks vision loss or hypothalamic damage. Most pituitary adenomas are soft in consistency and can be easily curetted. However, when very fibrous, complete resection is difficult.

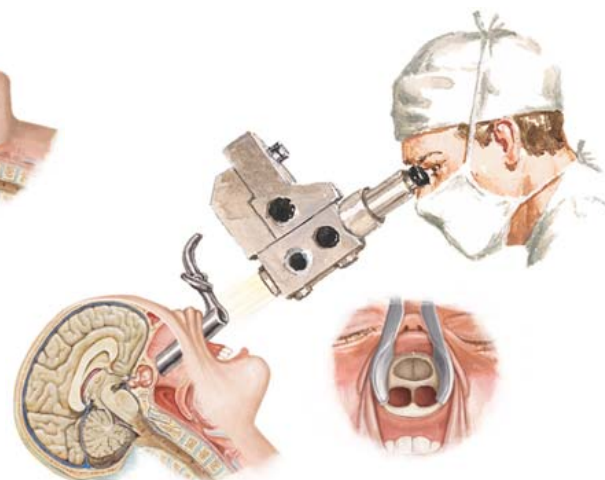
The sublabial transseptal transsphenoidal surgical approach to the pituitary was developed in the early 1900s but was abandoned because of the high mortality rate related to infection. Up until 1969, the most common surgical approach to the sella was transfrontal craniotomy, an approach associated with clinically significant morbidity and mortality. With the development of the operative microscope and the availability of antibiotics, the sublabial transseptal transsphenoidal surgical approach to the pituitary was reintroduced in the 1970s. This approach to the sphenoid sinus involved making a sublabial incision for access to the nasal cavity and then removing the nasal septum. The sphenoid sinus was entered, allowing access to the sella turcica. After resection of the tumor, the nasal septum was replaced, requiring nasal packing postoperatively. Complications included nasal septal perforation and permanent numbness of the front teeth and upper lip. The sublabial transseptal transsphenoidal surgical approach to the sella has been replaced by the direct transnasal approaches.

The direct transnasal transsphenoidal approach—introduced in the 1990s—requires no external incision. This surgical approach can be completed with an operating microscope or with an endoscope. With the microscope-based procedure, a long, narrow speculum is placed directly into the nostril and extended to the sphenoid ostia. The mucosal incision is made at the posterior aspect of the nasal airway passage, and there is no disruption of the nasal septum. On entering the sphenoid sinus, the anterior wall of the sella is seen and opened under microscopic vision. The tumor is removed under direct microscopic view. The transnasal technique may also be completed with an endoscope. The nasal endoscope is advanced through a nostril to the anterior wall of the sphenoid sinus. The sphenoid ostium is enlarged, and the posterior portion of the vomer is removed, allowing access to the sphenoid sinus. After placement of a self-retaining nasal speculum, the sella turcica is entered, and the neurosurgical portion of the procedure is undertaken as with the sublabial transseptal approach. After resection of the

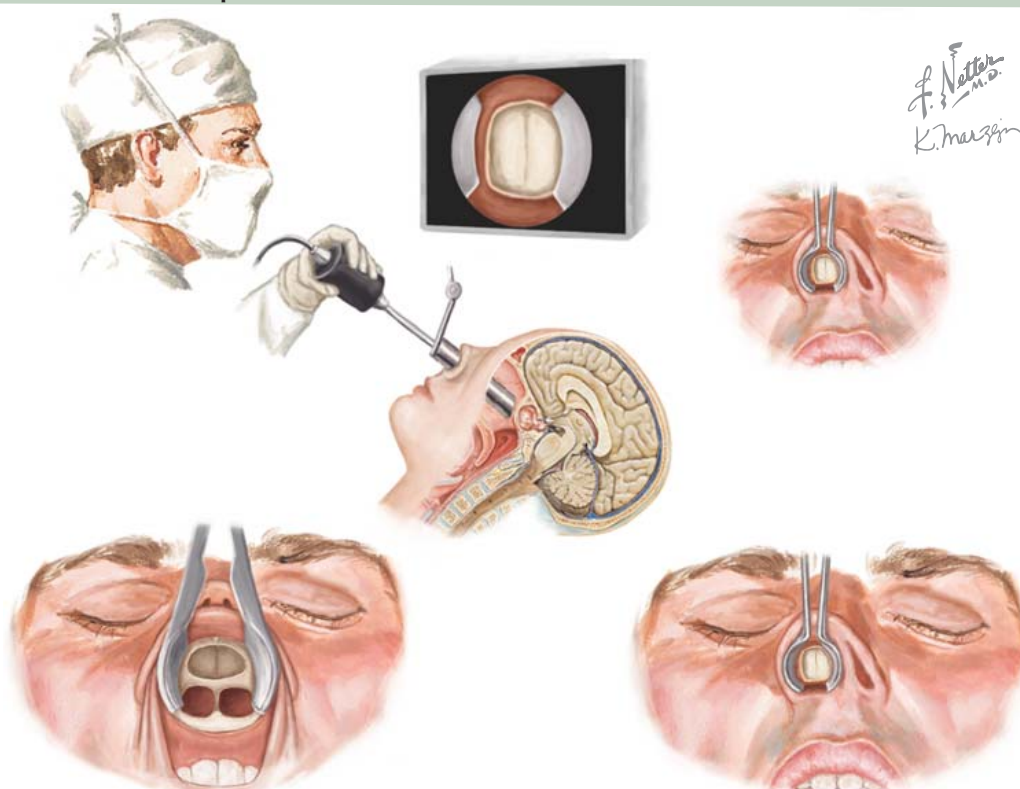
### Craniotomy 1930–1960s



### Transseptal 1969–1990s



### Transnasal 1990s–present



Sublabial transseptal transsphenoidal surgical approach

Endoscopic transnasal transsphenoidal surgical approach

tumor, the nasal speculum is withdrawn, the nasal septum is adjusted to midline if necessary, and a mustache nasal dressing is applied. The operative time, anesthesia time, and hospital length of stay are shorter in patients who undergo the endoscopic transnasal approach to pituitary surgery than in those who undergo the sublabial transseptal procedure. Most patients are in the hospital for 1 night.

Although intraoperative complications are rare, they can be serious, and they include injury to the cavernous

carotid artery; injury to the optic pathways; injury to cranial nerves III, IV, V, and VI; and cerebrospinal fluid (CSF) leakage. Postoperatively, the potential complications include sellar hematoma, CSF rhinorrhea, meningitis, and hypopituitarism.

More than 90% of sellar and parasellar tumors can be removed with the transnasal approach. The transcranial approach is reserved for lesions that extend into the middle fossa or have a large, complex suprasellar component.



This page intentionally left blank

# THYROID



## ANATOMY OF THE THYROID AND PARATHYROID GLANDS

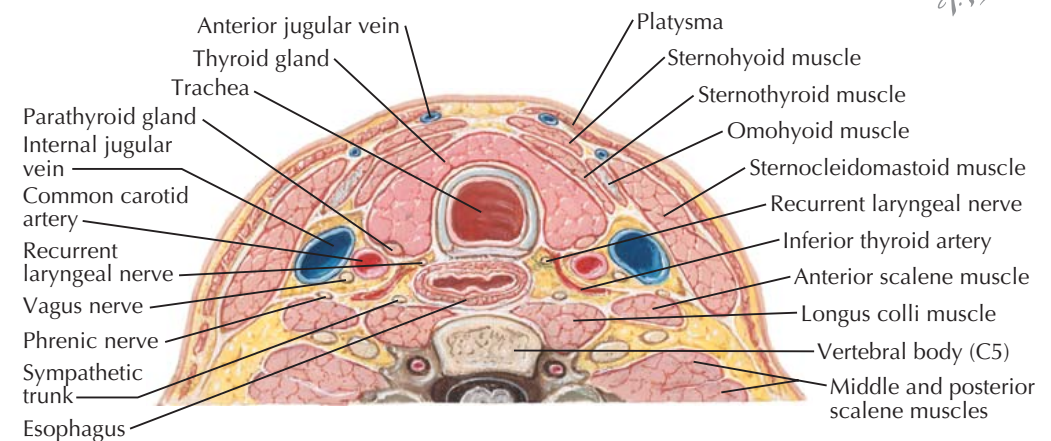
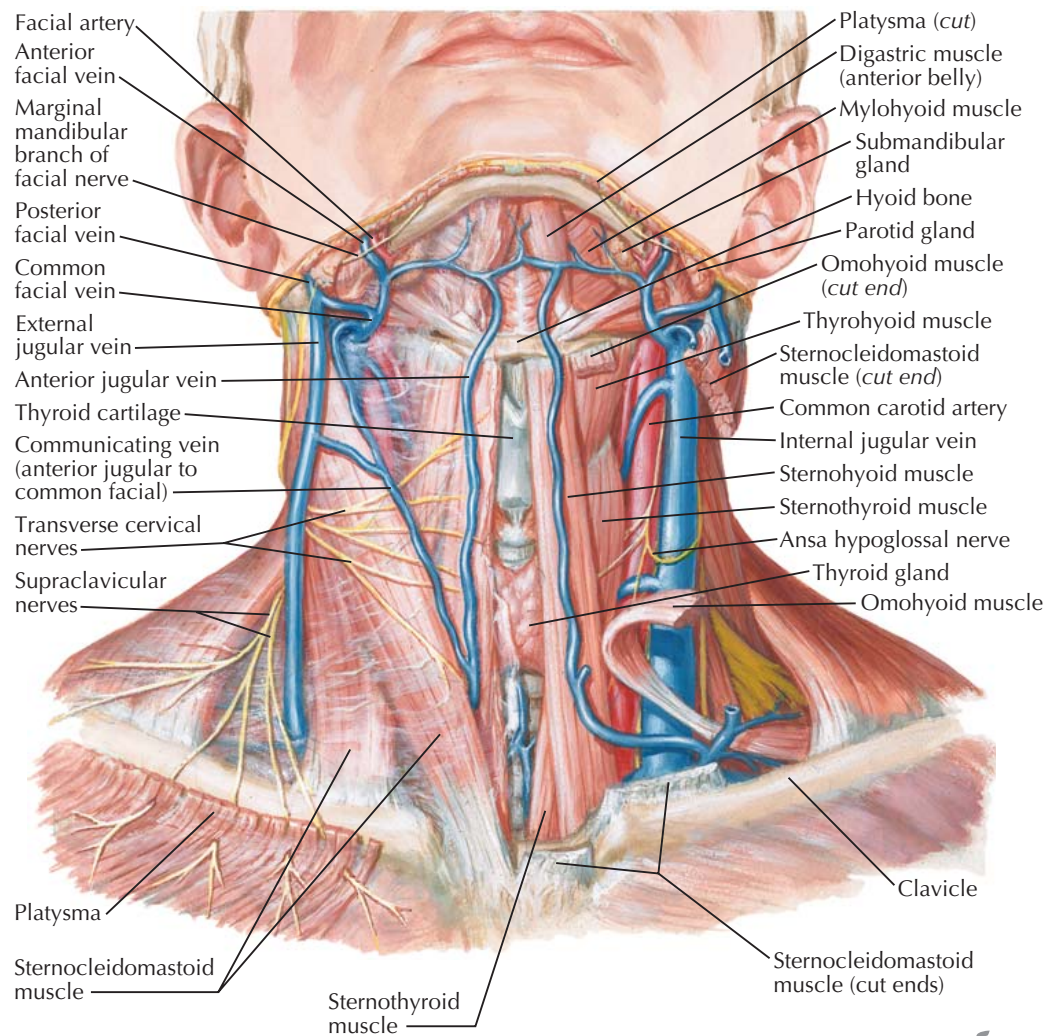
Located between the larynx and the trachea medially and the carotid sheath and the sternomastoid muscles laterally, the thyroid gland weighs 15 to 25 g. The lateral thyroid lobes are 3 to 4 cm long and 1.5 to 2 cm wide; the isthmus is 1.2 to 2 cm long and 2 cm wide and crosses the trachea between the I and II rings. In Plate 2-1 (*upper image*), the skin, subcutaneous fat, and platysma muscle have been excised, exposing, on the right half of the neck, the anterior or first cervical fascia. This fascia envelops the external and anterior jugular veins and the transverse cervical nerves. The subcutaneous fat and platysma muscle contain a rich blood supply, so that wide surgical exposures may be obtained, without sacrificing skin, by raising flaps of skin, subcutaneous fat, and platysma. The veins and nerves thus exposed are left initially in situ to be moved later with the muscles beneath.

On the left side of the neck (Plate 2-1, *upper image*), the first cervical fascia, the external jugular vein, the transverse nerves, and the sternocleidomastoid muscle have been excised. This excision shows the positions of the omohyoid muscle, the ansa hypoglossal nerve, the important limiting insertion of the shorter inner pretracheal muscle, the sternothyroid muscle, and the entire course of the longer thyrohyoid muscle. The same fascial layer has been incised down the midline, exposing the medial borders of the sternohyoid muscle. These muscles, normally meeting together in the midline, have been partially retracted to expose the thyroid and cricoid cartilages, the isthmus of the thyroid, and the upper trachea lying beneath.

The anterior jugular veins supplement the external jugular vein in returning the blood from the pharynx and upper neck. They also receive tributaries throughout their length: first, from the platysma superficial to them; second, from the pretracheal muscles (sternohyoid, sternothyroid, and omohyoid) deep to them; and third, at the level of the larynx, particularly at the notch, from several fine tributaries from the upper larynx near the midline. In exposing the thyroid and parathyroid glands and the trachea, it is important to save as many of these vessels as possible by retracting them, rather than dividing them, to avoid unnecessary edema of the upper neck and larynx. These anterior veins may be greatly dilated when tumors of the thyroid or other organs deep in the neck have pressed on either internal jugular vein.

The sensory transverse cervical nerves may be severed because they will regenerate. However, this is not true for the two lower branches of the facial nerve—transsection of the marginal mandibular branch is followed by drooping of the lower lip on the paralyzed side. The ansa hypoglossal nerve, lying along the anterior medial aspect of the carotid sheath, should be preserved. In exposing the nerve, it is helpful to remember that a small branch of the superior thyroid artery comes down just in front of the nerve, delivering branches to the posterior edge of the muscle as well as supplying the nerve. Division of this nerve renders swallowing more difficult after operation.

The lymphatic vessels in the superficial fascia, anterior to the prethyroid muscles, are not prominent. Lymph nodes are rare; the first one consistently encountered lies immediately in front of the thyroid isthmus in the midline between the pretracheal muscles, deep to the anterior fasciae and superficial to the second or middle cervical fasciae, the false capsule of the



thyroid. This node drains the pharynx or larynx but not the thyroid gland or deeper tissues beneath. It is thus enlarged in patients with acute pharyngitis and laryngitis but not in those with thyroiditis or tracheitis.

Exposure of the thyroid, parathyroid, and thymus glands is achieved by retracting the pretracheal or prethyroid muscles. The widest exposure is obtained if the muscles are cut transversely and the ends retracted up and down. A good view of the upper thyroid pole often requires transection of the inner muscle.

The position of the esophagus, shown slightly to the right of midline (Plate 2-1, *lower image*), is adjacent to the usually larger right lobe of the thyroid.

The Plate 2-2 (*upper image*) depicts the organs of the neck and anterior superior mediastinum with the anterior neck muscles and the bones of the upper thorax removed. When the thyroid, parathyroid, and thymus glands are first exposed, they lie enveloped on their anterior, lateral, and posterior surfaces by an ill-defined loose areolar fascia (also called the false capsule of the thyroid), which permits the glands, larynx, and trachea to rise and fall with swallowing. Indeed, nearly the entire anterior surface of both thyroid lobes can be palpated when the patient is instructed to swallow.



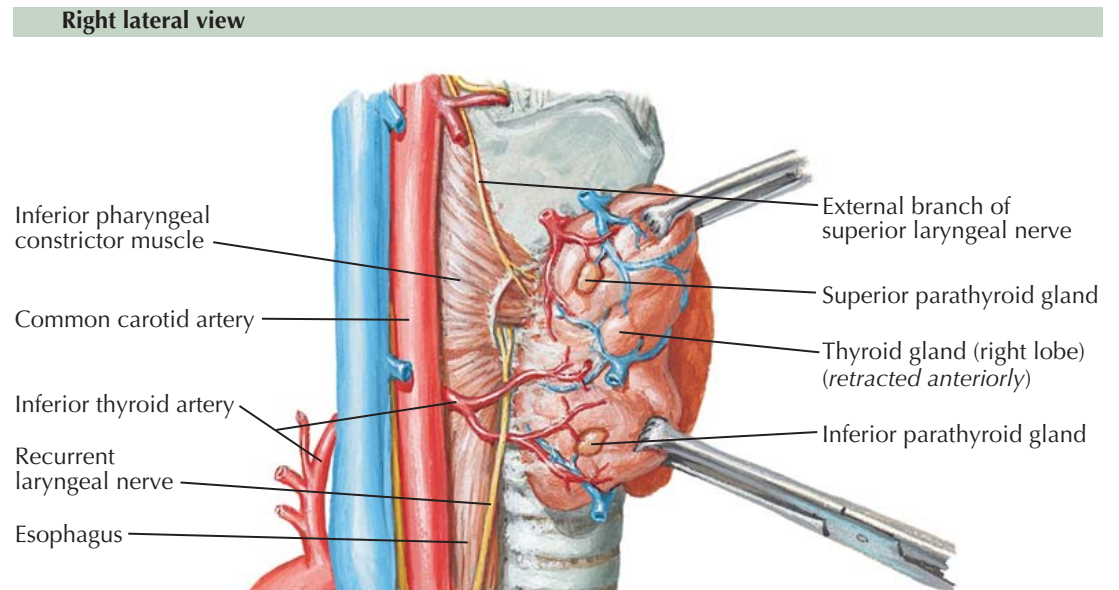
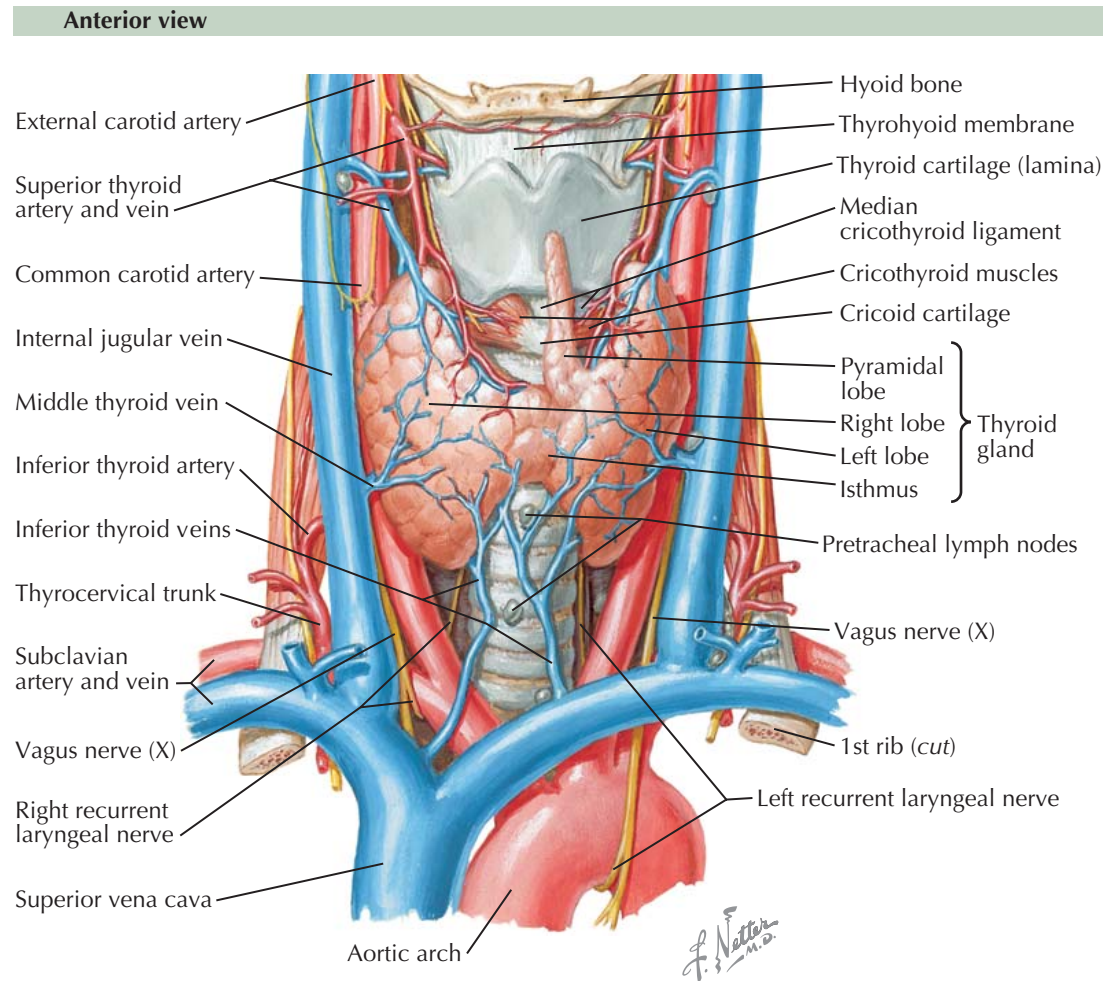
## ANATOMY OF THE THYROID AND PARATHYROID GLANDS (Continued)

The normal thyroid gland is nearly always asymmetric. The right lobe may be even twice as large as the left lobe. The right upper pole extends higher up in the neck, and the lower pole extends lower. In a patient with dextrocardia, the lobe size is reversed.

Four developmental anomalies are to be noted. A pyramidal lobe persists in at least 15% of the population, becoming enlarged if the thyroid is enlarged by a diffuse process. It is occasionally the site or origin of thyroid neoplasia. The second anomaly is the failure of thyroid tissue to be contained within the main thyroid mass posteriorly, which occurs in at least 5% of people. The noncontiguous nature may be palpable on physical examination, giving rise to suspicion of a tumor. The third and fourth anomalies are the failure of the isthmus to fuse in the midline and the absence of a substantial part of the lateral lobe, notably the lower half of the left lobe. These anomalies are rare, occurring in less than 1% of the population. When the isthmus fails to fuse, the medial aspects of the lateral lobes may feel like tumors, but palpating the tracheal rings where the isthmus should be will give the clue. Similarly, absence of the lower half of a lateral lobe may lead to the mistaken impression that the upper half is a thyroid nodule.

The lower image on Plate 2-2 is a lateral view of the organs of the right side of the neck, with the neck muscles, right clavicle, and sternum removed. The position and size of the normal parathyroids are variable. Usually, there are four glands, two upper and two lower. Rarely, there is a fifth, which the surgeon may need to find if it is adenomatous and the source of parathyroid hormone hypersecretion or if it is involved in hyperplasia (e.g., in multiple endocrine neoplasia type 1). The upper glands are more constant and circumscribed in position than the lower glands, often significantly larger, and therefore easier to find. They lie in the plane behind the thyroid, from the upper thyroid pole to the lower branches of the inferior thyroid artery. When enlarged by disease, they may be displaced downward into the posterior mediastinum. The lower glands, arising from a branchial cleft higher than the upper glands and associated, in their embryologic descent, with the thymus, are found over a much wider extent—above or behind the thyroid and down into the anterior mediastinum as far as thymic tissue is found.

The lymphatic vessels and nodes, in the *upper image* on Plate 2-2, follow a consistent pattern. The most readily felt and the first encountered are those in the midline in front. The uppermost, just above the thyroid isthmus, in front of the cricoid cartilage, and medial to a pyramidal lobe, if present, is a constant node group of one to five nodes, which has been termed the *Delphian node*. If involved in thyroid cancer or Hashimoto thyroiditis, it may be felt preoperatively. The pretracheal nodes below the thyroid isthmus are harder to identify because they are embedded in fat and not so constant in position as the Delphian. The other node groups, in order of operative importance, are those on the lateral thyroid surface along the lateral thyroid vein, the nodes along the upper stretch of the recurrent laryngeal nerve behind the thyroid lobe, those at the angle of the jaw, those along the carotid sheath (jugular chain), and the more lateral nodes in the supraclavicular



fossa. The sentinel nodes of Virchow are the lowermost of the jugular chain at the upper end of the thoracic duct. These nodes may be involved with thyroid and parathyroid carcinoma, as well as with metastases from carcinomas localized outside of the neck.

The laryngeal motor nerves are well depicted in both images on Plate 2-2. The superior nerve carries the motor branch to the cricothyroid muscle. This muscle tenses the vocal cord by drawing the front of the thyroid cartilage down on the cricoid. Fuzziness of the voice

follows section of the nerve, particularly if the injury is bilateral.

The different sites of origin of the two inferior or recurrent laryngeal nerves induce a different course for the nerve on either side. The right nerve passes diagonally from lateral to medial on its upward course, but the left is thrown by the aortic arch, at its inception, against the trachea and esophagus and comes straight up in the tracheoesophageal groove. This constant course makes it the easier of the two to find.



## DEVELOPMENT OF THE THYROID AND PARATHYROID GLANDS

### PHARYNX

By the beginning of the second month of embryonic development, the portion of the originally tubular entodermal foregut caudal to the buccopharyngeal (oral) membrane has differentiated into the pharynx. At this time, the pharynx is relatively wide; compressed dors-oventrally; and has on each side a series of four lateral outpocketings, the pharyngeal pouches (see Plate 2-3, A and B). Each pouch is in close relationship to an aortic arch and is situated opposite a branchial cleft (gill furrow) (see Plate 2-3A).

In certain aquatic species, the tissue in the depths of the branchial clefts and at the extremities of the pharyngeal pouches disintegrates to produce communications (the gill slits) between the pharyngeal cavity and the surface of the body. Persistent gill slits can occur in humans; the anomaly may be a slender, epithelially lined tract (branchial or cervical fistula) that extends from the pharyngeal cavity to an opening near the auricle (first pouch) or onto the neck (second and third pouches) (see Plate 2-4). When the anomaly is less extensive, it is either a cervical diverticulum or an epithelially lined cervical cyst. A blind diverticulum may extend either outward from the pharynx, for a variable distance, or inward from the neck. A cyst may be located at one site or another in the depths of the neck, causing no trouble unless it becomes infected or filled with fluid in postnatal life.

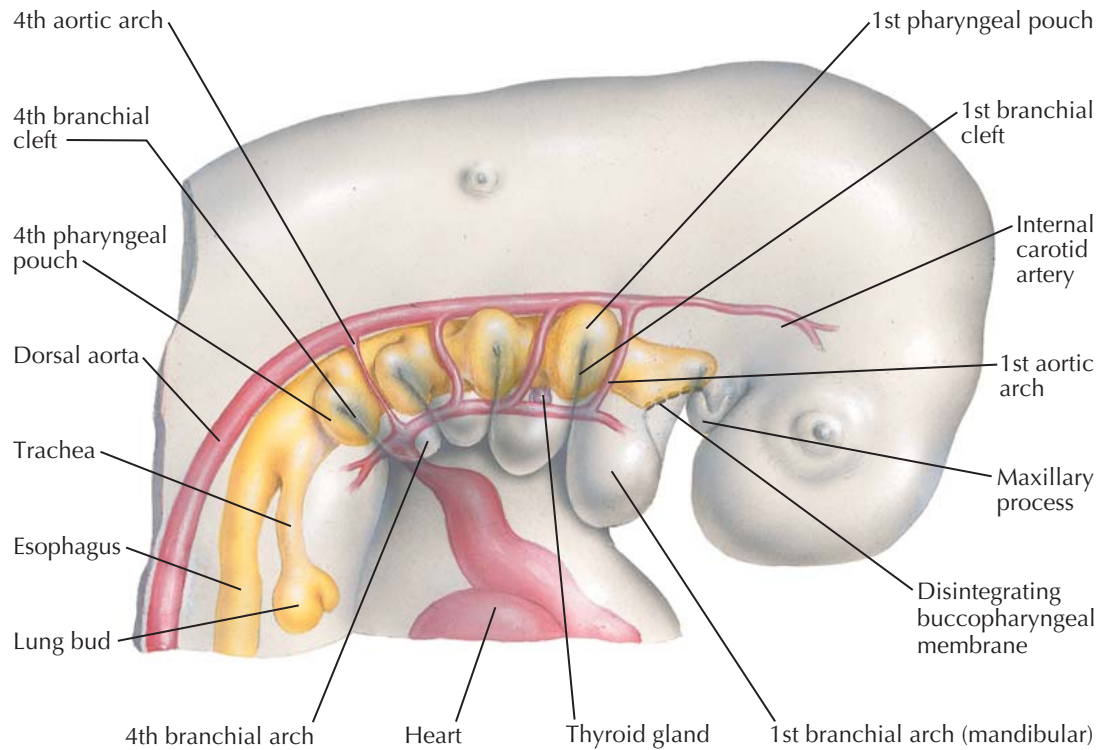
The central lumen of the embryonic pharynx gives rise to the adult pharynx (see Plate 2-4). The first, or most cephalic, pair of pharyngeal pouches gives rise to the auditory (eustachian) tubes, to the tympanic (middle ear) cavities, and to the mucous membrane lining the inner surface of each tympanum. The first branchial clefts, located opposite the first pouches, give rise to the external acoustic (auditory) meatuses and to the outer epithelial lining of each eardrum. The second pouches give rise to the epithelium lining the palatine tonsils. The latter pouches are, for the most part, absorbed into the pharyngeal wall, persisting only as pharyngeal outpocketings by contributing to the formation of the supratonsillar fossae (see Plate 2-4).

### THYROID GLAND

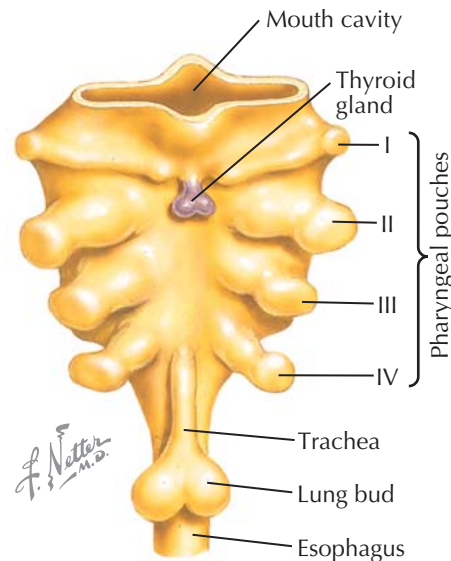
At a level between the first and second pharyngeal pouches, a saclike entodermal diverticulum (the thyroid sac) appears in the midline of the ventral surface of the pharynx. This sac, destined to give rise to the parenchyma of the thyroid gland (see Plate 2-3A), is the first glandular derivative of the pharynx. When it appears, near the end of the fourth gestational week, it almost immediately becomes bilobated, and a narrow, hollow neck connects the two lobes. This neck is known as the thyroglossal duct because its pharyngeal attachment is located where the ventral floor of the pharynx contributes to the formation of the tongue. The duct becomes a solid stalk and begins to atrophy by the sixth gestational week; however, its pharyngeal connection results in a permanent pit, the foramen cecum, at the apex of the V-shaped sulcus terminalis on the dorsum of the tongue (see Plate 2-3C and 2-4).

The thyroid sac is converted into a solid mass of cells by the time the thyroglossal stalk disappears. By the end of the seventh week, the developing thyroid becomes crescentic in shape and is relocated to a position at the

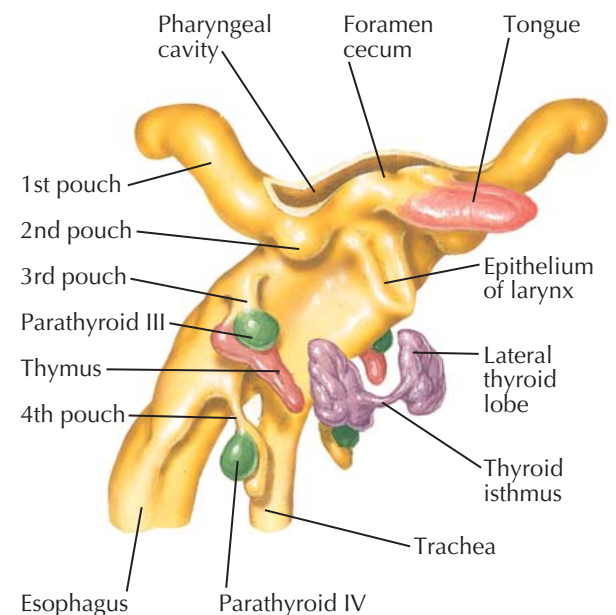
### A. Pharynx and related structures: 4th week



### B. Pharynx (ventral view) 4th week



### C. Pharynx and derivatives (between 6th and 7th weeks)



level of the developing trachea (see Plate 2-3C). This relocation occurs because the thyroid is left behind as the pharynx grows forward. At this time, the thyroid's two (lateral) lobes, one on each side of the trachea, are connected in the midline by a very narrow isthmus of developing thyroid tissue (see Plate 2-3C).

The formation of thyroid follicles begins during the eighth week of development. They acquire colloid by the third month. By the end of the fourth month, new follicles arise only by the budding and subdivision of those already present. The mesenchyma, surrounding

the thyroid primordium, differentiates into the stroma of the gland and its thin proper fiber-elastic capsule.

The thyroglossal duct may persist either as an epithelial tract, which is open from the foramen cecum of the tongue to the level of the larynx, or as a series of blind pockets (thyroglossal duct cysts) (see Plates 2-4 and 2-5).

Persistent portions of the duct or stalk may give rise to accessory thyroids or to a median fistula that opens onto the neck. When a portion of thyroglossal duct persists at the level of the hyoid bone, it passes through the body of the bone (see Plate 2-4).

## DEVELOPMENT OF THE THYROID AND PARATHYROID GLANDS

(Continued)

The variably occurring “pyramidal lobe of the thyroid” results from the retention and growth of the lower end of the stalk. A ligament or a band of muscle, usually located to the left of the midline, may connect the pyramidal lobe either to the thyroid cartilage or to the hyoid bone. The pyramidal lobe undergoes gradual atrophy; therefore, it is found more often in children than in adults.

Other variations of the thyroid gland are found. For example, the isthmus may be voluminous, rudimentary, or absent. The lateral lobes may be of different sizes, or both may be absent, with only the isthmic portion present. The shape of the gland may be more like that of an “H” than that of a “horseshoe.” Rarely, the gland may be located at the base of the tongue (lingual thyroid) or deep to the sternum. Complete absence of the gland or failure of the gland to function is seldom noticed until a few weeks after birth because fetuses are supplied, through the placenta, with sufficient maternal thyroid hormone to permit normal development. If proper hormonal treatment is not instituted after birth, the result is congenital hypothyroidism

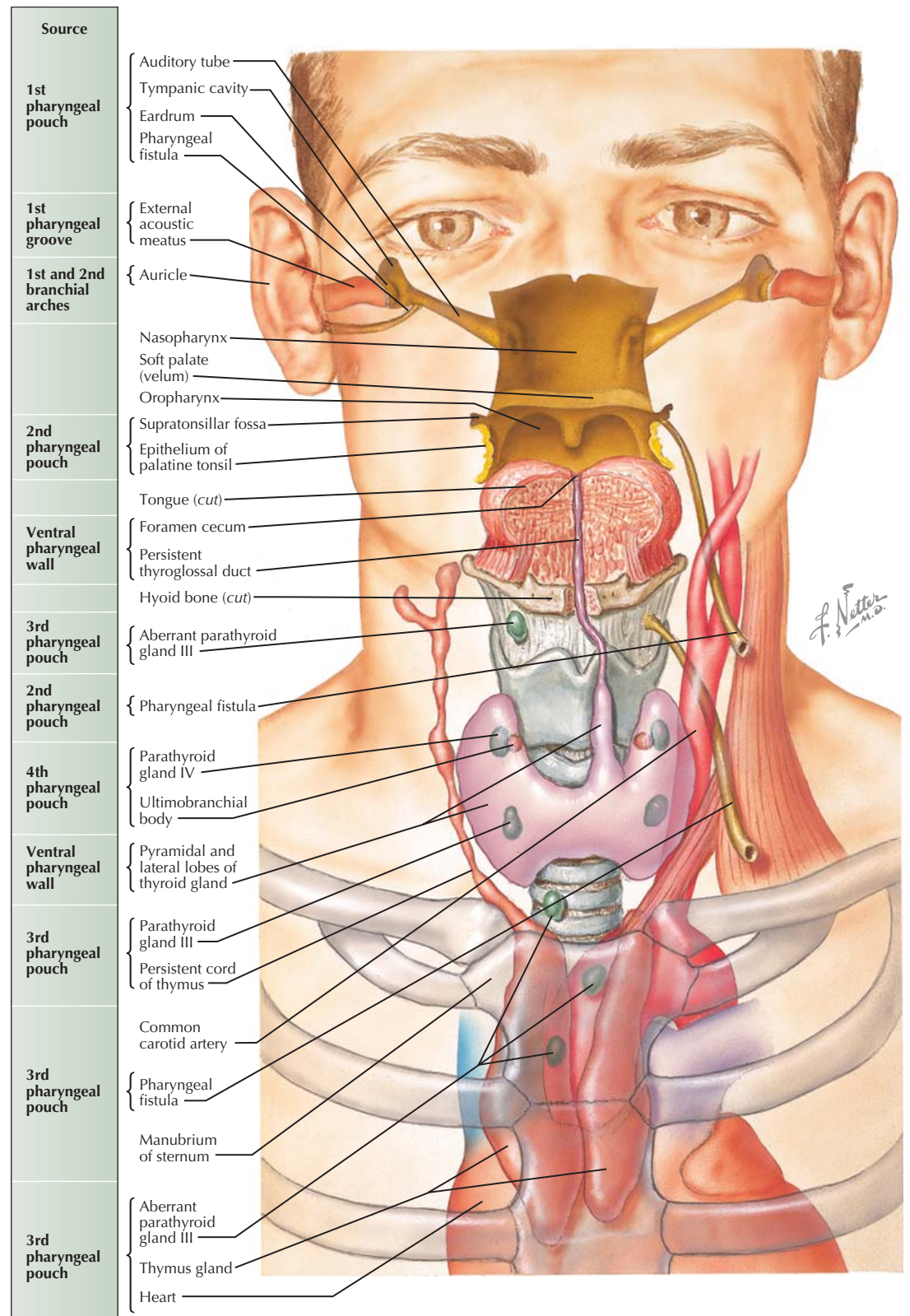
### PARATHYROID AND THYMUS GLANDS

During the fifth and sixth weeks of development, the endodermal epithelium of the dorsal portions of the distal ends of the third and fourth pharyngeal pouches differentiates into the primordia of the parathyroid glands. At the same time, the ventral portions of the distal ends of the third pouches differentiate into the primordia of the thymus gland (see Plate 2-3C). The ventral portions of the distal ends of the fourth pouches may give rise to thymic primordia, which soon disappear without contributing to the adult thymus.

Usually, two pairs of parathyroid glands are formed. By the end of the sixth gestational week, the primordia of the parathyroids and thymus lose their connection with the pouches. At this time, the lumen of the third and fourth pouches becomes obliterated. Parathyroid tissue from the third pouch and thymic primordia migrate, during the seventh week, in a caudomedial direction. During the eighth week, the lower ends of the thymic primordia enlarge and become superficially fused together in the midline. This bilobated lower end continues to descend, to be located in the superior mediastinum of the thorax, posterior to the manubrium. During this descent, the upper ends of the thymic primordia are drawn out into tail-like extensions that usually disappear. Occasionally, they persist as fragments embedded in the thyroid gland or as isolated thymic nests or cords.

Parathyroid tissue from the third pouch migrates with the thymic primordia and usually comes to rest at the caudal level of the thyroid gland to become the inferior parathyroid glands of the adult. Situated within the cervical fascial sheath of the thyroid, the glands are attached to the back of the proper capsule of each lateral thyroid lobe; however, each has its own proper capsule. Occasionally, parathyroid tissue descends with the thymic primordia to a lower level, being located in the thorax, close to the thymus.

The parathyroids from the fourth pouch do not shift their position appreciably; therefore, parathyroids from the third pouch pass them in their caudal migration to



a lower level. Thus, parathyroids from the fourth pouch become the superior parathyroid glands of the adult, located within the fascial sheath of the thyroid, attached to the back of the proper capsule of each lateral thyroid lobe at the level of the lower border of the cricoid cartilage. Variations in the number, size, and location of the parathyroids are common. Both the regularly occurring and accessory glands may be situated at some distance from the thyroid. The parathyroids produce

parathyroid hormone, which maintains the normal calcium and phosphorus balance.

The thymus gland is a conspicuous organ in infants. At about 2 years of age, it attains its largest relative size, continuing to grow until puberty. It undergoes a gradual involution after puberty as the thymic tissue is replaced by fat. Therefore, in adults, the thymus is of approximately the same form and size as during the earlier years, but it now consists chiefly of adipose tissue.



## CONGENITAL ANOMALIES OF THE THYROID GLAND

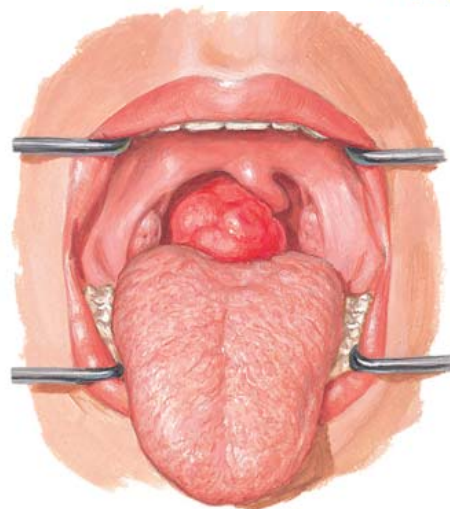
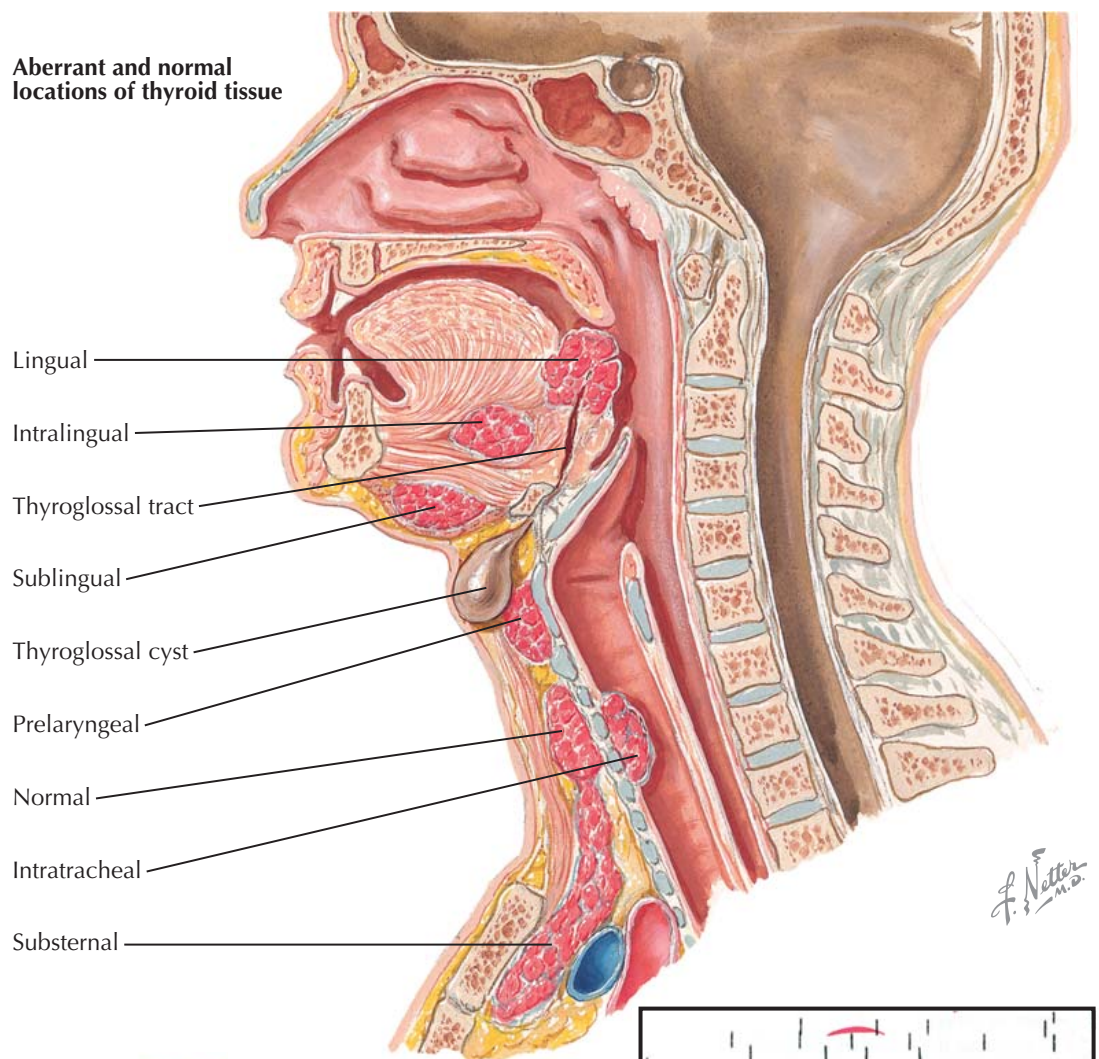
Aberrant, or abnormal, locations of thyroid tissue may be explained on the basis of abnormal embryologic migration of the thyroid and of its close association with lateral thyroid anlagen. These abnormal settings of thyroid tissue can better be understood if one considers the embryology of the thyroid gland, which, in humans, arises about the seventeenth day of gestation and is derived from the alimentary tract. The median part of the thyroid is formed from the ventral evagination of the floor of the pharynx at the level of the first and second pharyngeal pouches. The lateral thyroid anlage, from the area of the fourth pouch, becomes incorporated into the median thyroid anlage to contribute a small proportion of the final thyroid parenchyma. The thyroid anlage becomes elongated and enlarges laterally, with the pharyngeal region contracting to become a narrow stalk—the thyroglossal tract or duct. This subsequently atrophies, leaving at its point of origin on the tongue a depression known as the foramen cecum. Normally, the thyroid continues to grow and simultaneously migrates caudally.

The anatomic sites for the location of anomalously formed thyroid tissue range from the posterior tongue down into the region of the heart, within the mediastinum. Persistence of thyroid tissue on the posterior tongue is a fairly uncommon anomaly known as lingual thyroid. This may be the only source of thyroid tissue in the individual. It can often be demonstrated with radioactive iodine scintigraphy, revealing the localization of radioiodine only within the lingual thyroid without any thyroid tissue being demonstrated in the neck.

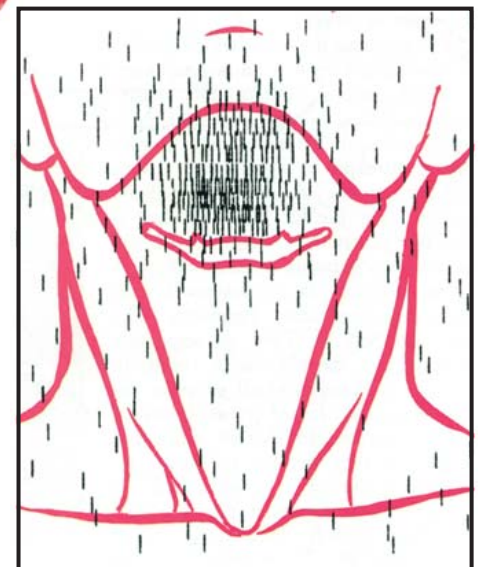
Intralingual and sublingual rests of thyroid tissue have been described, but these are quite uncommon. The thyroglossal tract that persists usually atrophies completely. However, it may fail to atrophy, remaining as a cystic mass in the midline of the neck, somewhere between the base of the tongue and the hyoid bone. A thyroglossal cyst should therefore be considered in any individual presenting with an enlarging cystic mass immediately beneath the chin in the midline. Occasionally, such cysts may be associated with thyroid tissue capable of concentrating radioactive iodine.

Substernal aberrant thyroid, tissue in the mediastinum, is rarely the consequence of abnormal development, representing glandular rests remaining from the

### Aberrant and normal locations of thyroid tissue



Lingual thyroid



Scintigram; lingual thyroid

time of the caudal descent of the thyroid. However, most often, substernal thyroid tissue is the result of downward growth of a nodular goiter. Prelaryngeal thyroid tissue may exist, being attached to a very long pyramidal lobe or to a thyroglossal cyst. Intratracheal thyroid rests have also been reported, although infrequently. The “lateral aberrant thyroid” may represent original branchial tissue that did not fuse with the median thyroid. However, the demonstration of microscopic carcinoma in the thyroids of some patients with

so-called “lateral aberrant thyroid tissue” suggests that, in most instances, these may actually be metastases from a low-grade, well-differentiated thyroid papillary thyroid carcinoma.

The medical significance of aberrant thyroid tissue is quite limited. Occasionally, an inflammatory change or, rarely, enlargement and consequent thyrotoxicity will call for surgical or radiotherapeutic intervention. The exact interpretation of these lesions necessitates an understanding of their embryologic derivation.

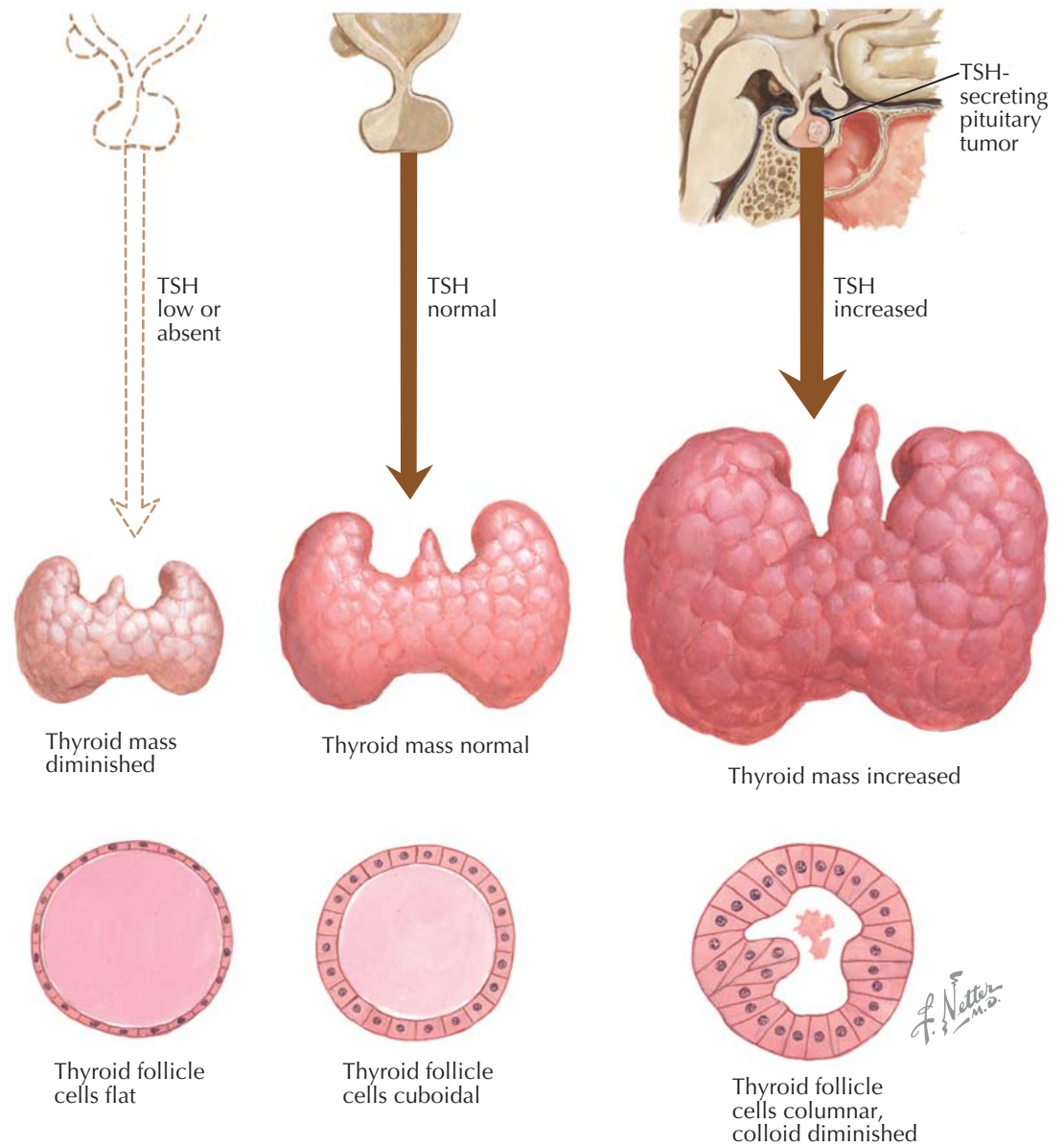
### EFFECTS OF THYROTROPIN ON THE THYROID GLAND

The hypothalamic–pituitary unit has an indispensable role in the regulation of thyroid function. Hypothalamic dysfunction or anterior pituitary failure leads to diminished thyroid mass and decreased production and secretion of thyroid hormones. The pituitary hormone that targets the thyroid gland is the glycoprotein thyrotropin (thyroid-stimulating hormone [TSH]), which is secreted by pituitary thyrotrophs. TSH is the main regulator of the structure and function of the thyroid gland. TSH is composed of an  $\alpha$  subunit and a  $\beta$  subunit. The  $\alpha$  subunit consists of 92 amino acids, and it is identical to the  $\alpha$  subunit of luteinizing hormone, follicle-stimulating hormone, and human chorionic gonadotropin. The  $\beta$  subunit of glycoprotein hormones confers specificity. The  $\beta$  subunit synthesized in thyrotrophs is an 112-amino acid protein. Hypothalamic thyrotropin-releasing hormone (TRH) is a modified tripeptide (pyroglutamyl-histidyl-proline-amide) that increases the transcription of both subunits, and thyroid hormones (thyroxine [ $T_4$ ] and triiodothyronine [ $T_3$ ]) suppress the transcription of both subunits. In healthy persons, the serum TSH concentration is between 0.3 and 5.0 mIU/L. TSH concentrations are increased in primary hypothyroidism, increased in secondary hyperthyroidism (e.g., TSH-secreting pituitary tumor), and decreased in primary hyperthyroidism. Blood TSH concentrations vary in both a pulsatile and a circadian manner—a nocturnal surge precedes the onset of sleep.

Both  $T_4$  and  $T_3$  mediate feedback regulation of TRH and TSH secretion. A linear inverse relationship exists between the serum free  $T_4$  concentration and the log of the TSH. Thus, the serum TSH concentration is a very sensitive indicator of the thyroid state of patients with intact hypothalamic–pituitary function.

A TSH receptor is expressed on thyroid cells. The TSH receptor is a member of the glycoprotein G protein–coupled receptor family. The TSH receptor couples to Gs and induces a signal via the phospholipase C and intracellular calcium pathways that regulate iodide efflux,  $H_2O_2$  production, and thyroglobulin iodination. Signaling by the protein kinase A pathways mediated by cyclic adenosine monophosphate regulates iodine uptake and transcription of thyroglobulin, thyroperoxidase, and the sodium-iodide symporter mRNAs, leading to thyroid hormone production. In addition to TSH, the TSH receptor also binds thyroid-stimulating antibody (increased in the setting of Graves disease) and thyroid-blocking antibodies (increased in the setting of Hashimoto thyroiditis). At high concentrations, the closely related glycoprotein hormones—luteinizing hormone and chorionic gonadotropin—also bind to and activate TSH receptor signaling and can cause physiologic hyperthyroidism of early pregnancy.

With an intact hypothalamic–pituitary–thyroid axis, the thyroid gland mass is normal, thyroid follicle cells



|                        |                           |                         |
|------------------------|---------------------------|-------------------------|
| TSH: low               | TSH: normal               | TSH: high               |
| Free $T_4$ : low       | Free $T_4$ : normal       | Free $T_4$ : high       |
| Total $T_3$ : low      | Total $T_3$ : normal      | Total $T_3$ : high      |
| $^{131}I$ -uptake: low | $^{131}I$ -uptake: normal | $^{131}I$ -uptake: high |

appear cuboidal, TSH concentration is in the reference range, free  $T_4$  and total  $T_3$  concentrations are in the reference range, and radioactive iodine uptake is normal. In the setting of hypothalamic or pituitary dysfunction, secondary hypothyroidism is manifest by decreased thyroid gland mass (which may not be palpable on physical examination), flat-appearing thyroid follicle cells, low TSH concentration (or inappropriately low for the low thyroid hormone levels), free  $T_4$  and total  $T_3$  concentrations below the reference range,

and low radioactive iodine uptake. However, in a patient with a TSH-secreting pituitary tumor, the thyroid gland mass is increased and is usually evident as a firm goiter on physical examination, thyroid follicle cells appear columnar and the colloid is diminished, TSH concentration is inappropriately within or slightly above the reference range, free  $T_4$  and total  $T_3$  concentrations are above the reference range, and radioactive iodine uptake is increased.



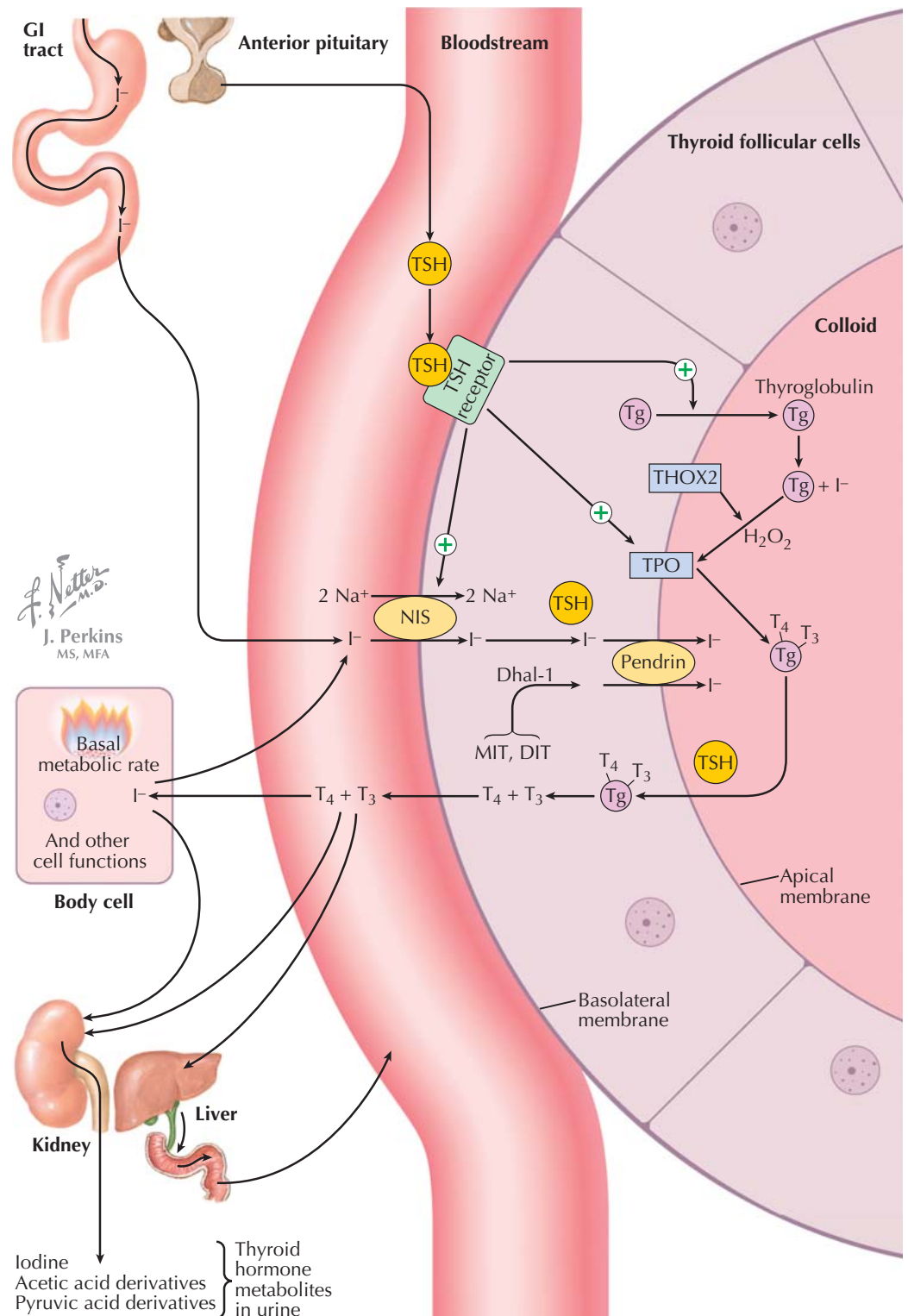
## PHYSIOLOGY OF THYROID HORMONES

The role of the thyroid gland in the total body economy comprises the synthesis, storage, and secretion of thyroid hormones, which are necessary for growth, development, and normal body metabolism. These thyroid functions can be considered almost synonymous with iodine metabolism. Iodination of the tyrosine molecule leads to synthesis of thyroxine (tetraiodothyronine [ $T_4$ ]) and triiodothyronine ( $T_3$ ).

Inorganic iodine ( $I^-$ ) is rapidly absorbed in the gastrointestinal (GI) tract and circulates as iodide, until it is either trapped by the thyroid or salivary glands or excreted by the urinary tract. The thyroid extracts iodine from the plasma, against a 25-fold concentration gradient, by virtue of the sodium-iodide symporter (NIS). The function of NIS requires a sodium gradient across the basolateral membrane—the transport of 2  $Na^+$  ions allows the transport of 1 iodide atom. NIS also transports  $TcO_4^-$ , which is used clinically for thyroid scintigraphy, and potassium perchlorate ( $KClO_4^-$ ), which can block thyroid iodide uptake. NIS gene transcription and protein half-life are enhanced by thyrotropin (thyroid-stimulating hormone [TSH]). Intra-follicular cell iodide is also generated by the action of iodotyrosine dehalogenase 1 isoenzyme (Dhal-1) that deiodinates monoiodotyrosine (MIT) and diiodotyrosine (DIT).

Pendrin is a glycoprotein expressed on the apical border of the thyroid follicular cell, where it facilitates the transfer of iodide into the follicular colloid. After the pendrin-facilitated iodide transfer to the colloid, iodide is oxidized by thyroid peroxidase (TPO) to facilitate the iodination of tyrosine to MIT and DIT. Antithyroid drugs (e.g., propylthiouracil, methimazole, carbimazole) inhibit the function of TPO. TPO requires  $H_2O_2$  that is generated by thyroid oxidase 2 (THOX2), a step that is inhibited by iodide excess. The organic compounds of iodine are stored in the thyroid as part of thyroglobulin (Tg; molecular weight, 660 kDa). TPO also serves to catalyze the coupling of 2 molecules of DIT to form  $T_4$  and 1 molecule of MIT and 1 molecule of DIT to form  $T_3$ .  $T_4$  and  $T_3$  are stored in the colloid as part of the Tg molecule—there are 3 to 4  $T_4$  molecules in each molecule of Tg. TSH stimulates the retrieval of Tg from the colloid by micropinocytosis to form phagolysosomes, where proteases free  $T_4$ ,  $T_3$ , DIT, and MIT within the phagolysosome.  $T_4$  and  $T_3$  are then transported from the phagolysosome across the basolateral cell membrane and into the circulation. This action is inhibited by large amounts of iodine, a finding that can be used therapeutically in the treatment of patients with hyperthyroidism caused by Graves disease. DIT and MIT are deiodinated by Dhal-1, and the iodide is returned to the follicular lumen.

The ratio of  $T_4$  to  $T_3$  in Tg is approximately 15 to one, and when released from the follicular cell, it is approximately 10 to one (the difference reflecting the action of a 5'-deiodination). The deiodination step can be inhibited by propylthiouracil.  $T_4$  is produced only in the thyroid gland. Although  $T_3$  is released from the thyroid, 75% of  $T_3$  in the body is derived from peripheral 5'-deiodination of one of the outer ring iodine atoms in  $T_4$ .  $T_4$  and  $T_3$  can be inactivated by inner ring (5-deiodination) to form reverse  $T_3$  and diiodothyronine ( $T_2$ ), respectively. The presence of these deiodinases in various cell types provides for local regulation of thyroid hormone effect.



$T_4$  and  $T_3$  are poorly water soluble and circulate bound to plasma proteins—thyroxine-binding globulin (TBG),  $T_4$ -binding prealbumin (transthyretin), and albumin. TBG has one iodothyronine binding site per molecule. The affinity of TBG for  $T_3$  is 20-fold less than that for  $T_4$ .

From the thyroxine-binding proteins,  $T_4$  and  $T_3$  enter the body cells, where they exert their metabolic actions, which are, predominantly, calorogenic (raising the basal metabolic rate). Thyroid hormones act by binding to the thyroid hormone receptor, which, in turn, binds to DNA.  $T_3$  has a 15-fold higher binding affinity for the thyroid hormone receptor than does  $T_4$ .

Both  $T_4$  and  $T_3$  are metabolized by kidney and liver tissue to their pyruvic acid and acetic acid derivatives and, eventually, to iodide. These metabolites are concentrated and conjugated in the liver to glucuronic acid, excreted with the bile, hydrolyzed in the small bowel, and reabsorbed.

The thyroid gland is unique with regard to the amount of stored hormone. There is approximately 250  $\mu g$  of  $T_4$  for every gram of thyroid gland—approximately 5 mg of  $T_4$  in a 20-g thyroid. Thus, it is not surprising that thyrotoxicosis is common when the thyroid gland is acutely damaged by inflammation (e.g., subacute thyroiditis).

## GRAVES DISEASE

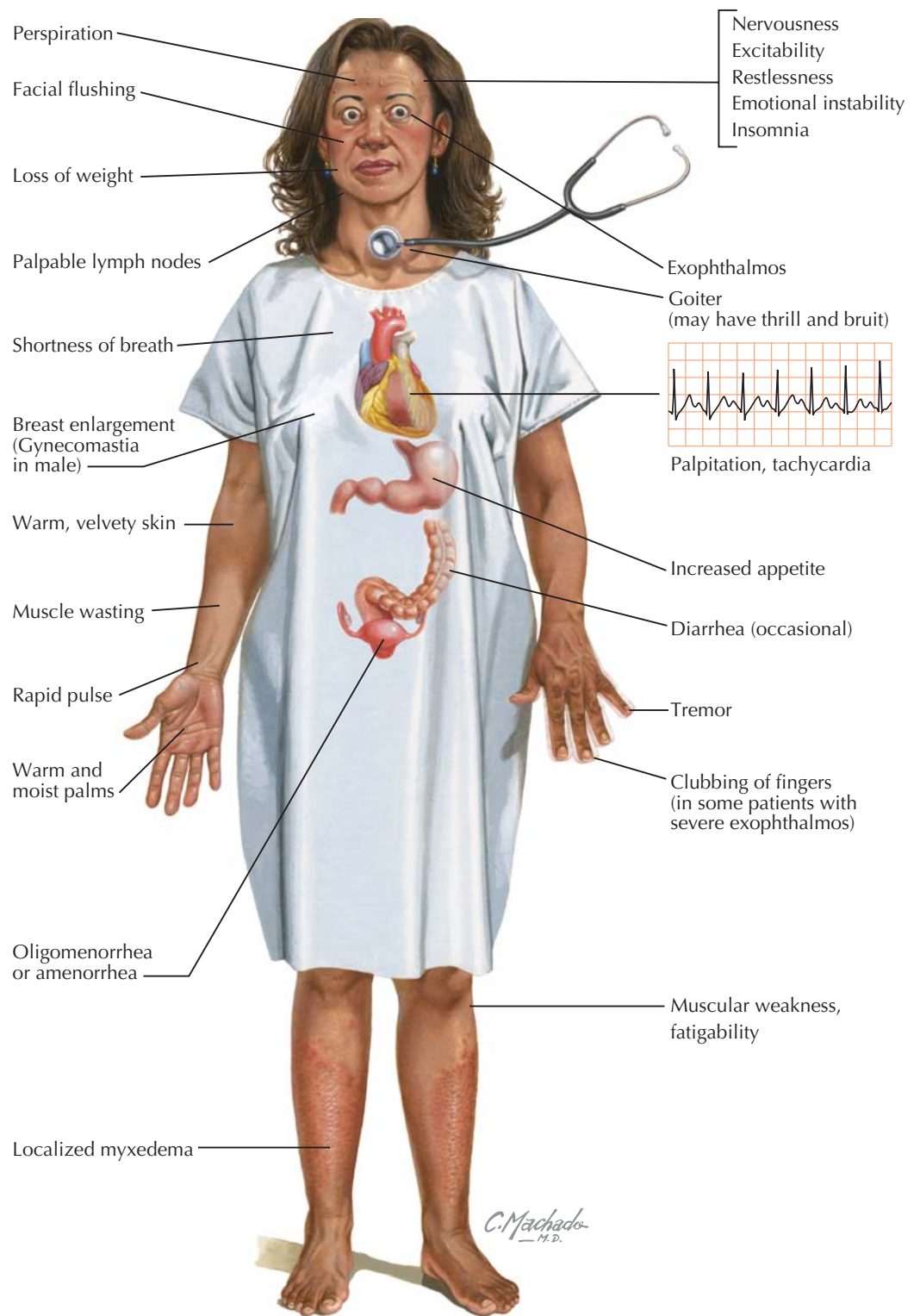
Graves disease is an eponym that describes a thyroid autoimmune syndrome characterized by hyperthyroidism, goiter, ophthalmopathy, and occasionally an infiltrative dermatopathy (pretibial or localized myxedema). Graves disease and hyperthyroidism are not synonymous because some patients with Graves disease have ophthalmopathy but not hyperthyroidism. Also, in addition to Graves disease, hyperthyroidism has several other causes. The hyperthyroidism in Graves disease is caused by autoantibodies to the thyrotropin (thyroid-stimulating hormone [TSH]) receptor that activate the receptor and stimulate the synthesis and secretion of thyroid hormones (thyroxine [ $T_4$ ] and triiodothyronine [ $T_3$ ]) and thyroid gland growth.

Graves disease occurs more commonly in females than in males (8:1) and more frequently during the childbearing years, although it may occur as early as in infancy and in extreme old age. Although this malady's primary signs are an enlarged thyroid gland and prominent eyes, along with cardiovascular symptoms, it actually involves most systems of the body and is thus a systemic disease. The thyroid is diffusely enlarged (goiter) and is anywhere from two to several times its normal size. Some asymmetry may be observed, the right lobe being somewhat larger than the left. The pyramidal lobe is usually enlarged. Rarely in a patient with Graves disease, there is no palpable enlargement of the thyroid gland. The gland has an increased vascularity, as evidenced by a bruit that can be heard with a stethoscope and sometimes by a thrill felt on palpation, which may be demonstrated over the upper poles. Histologically, the gland shows follicular hyperplasia with a marked loss of colloid from the follicles and an increased cell height, with high columnar acinar cells that may demonstrate papillary infolding into the follicles. Late in the disease, there may be multifocal lymphocytic (primarily T cells) infiltration throughout the thyroid gland, and, occasionally, even lymph follicles (primarily B cells) may be seen within the thyroid parenchyma.

The hyperplastic thyroid functions at a markedly accelerated pace, evidenced by an increased uptake and turnover of radioactive iodine and increased levels of  $T_4$  and  $T_3$ , which cause an increased rate of oxygen consumption or increased basal metabolic rate and decreased serum total and high-density lipoprotein cholesterol concentrations. The increased levels of  $T_4$  and  $T_3$  cause a variety of physical and psychologic manifestations. Patients with this malady are usually nervous; agitated; restless; and experience insomnia, personality changes, and emotional lability. Behavioral findings include difficulty concentrating, confusion, and poor immediate recall.

On physical examination, patients with Graves disease present a fine tremor that may not be obvious but is best demonstrated by placing a paper towel on the extended fingers. The increased levels of  $T_4$  and  $T_3$  and the increased levels of oxygen consumption, with concomitant generalized vasodilatation, result in increased cardiac output, presenting with palpitation and sinus tachycardia. The increased stimulus to the heart action may result in atrial fibrillation and heart failure.

The skin of patients with this disease is warm and velvety (because of a decrease in the keratin layer); it may also be flushed and is often associated with marked perspiration caused by increased calorogenesis. Occasionally, vitiligo—another autoimmune manifestation—is



observed. Onycholysis (known as Plummer nails)—loosening of the nails from the nail bed and softening of the nails—occurs in a minority of patients with Graves disease. Infiltrative dermatopathy (pretibial myxedema) is the skin change that sometimes occurs in the lower extremities or on the forearms in patients with severe progressive ophthalmopathy. This is associated with a brawny, nonpitting thickening of the skin. It presents as a rubbery, nonpitting swelling of the cutaneous and subcutaneous tissues, with a violaceous discoloration of the skin on the lower third of the legs. Usually, it is predominant in the outer half of the leg. Nodules (as large

as 1 cm in diameter) over the tibia, extending up as high as the knees, may be associated with classic localized pretibial myxedema. This lesion may also occur on the forearms, and it has been known to involve the feet and even the toes. Characteristically, hair does not grow in such myxedematous sites, but the occasional presence of hair follicles, producing hair at the site, does not exclude the diagnosis. When localized myxedema occurs, it is almost always in patients who have severe and progressive ophthalmopathy. Graves disease is also associated with clubbing of the fingers and of the toes (thyroid acropachy).



**GRAVES DISEASE** (Continued)

Sympathetic overactivity results in a stare and eyelid lag in most patients with hyperthyroidism. Eyelid lag is demonstrated by having the patient follow the examiner's finger through a vertical arc—the sclera can usually be seen above the iris as the patient looks down. Unique to Graves disease is ophthalmopathy (see Plate 2-10).

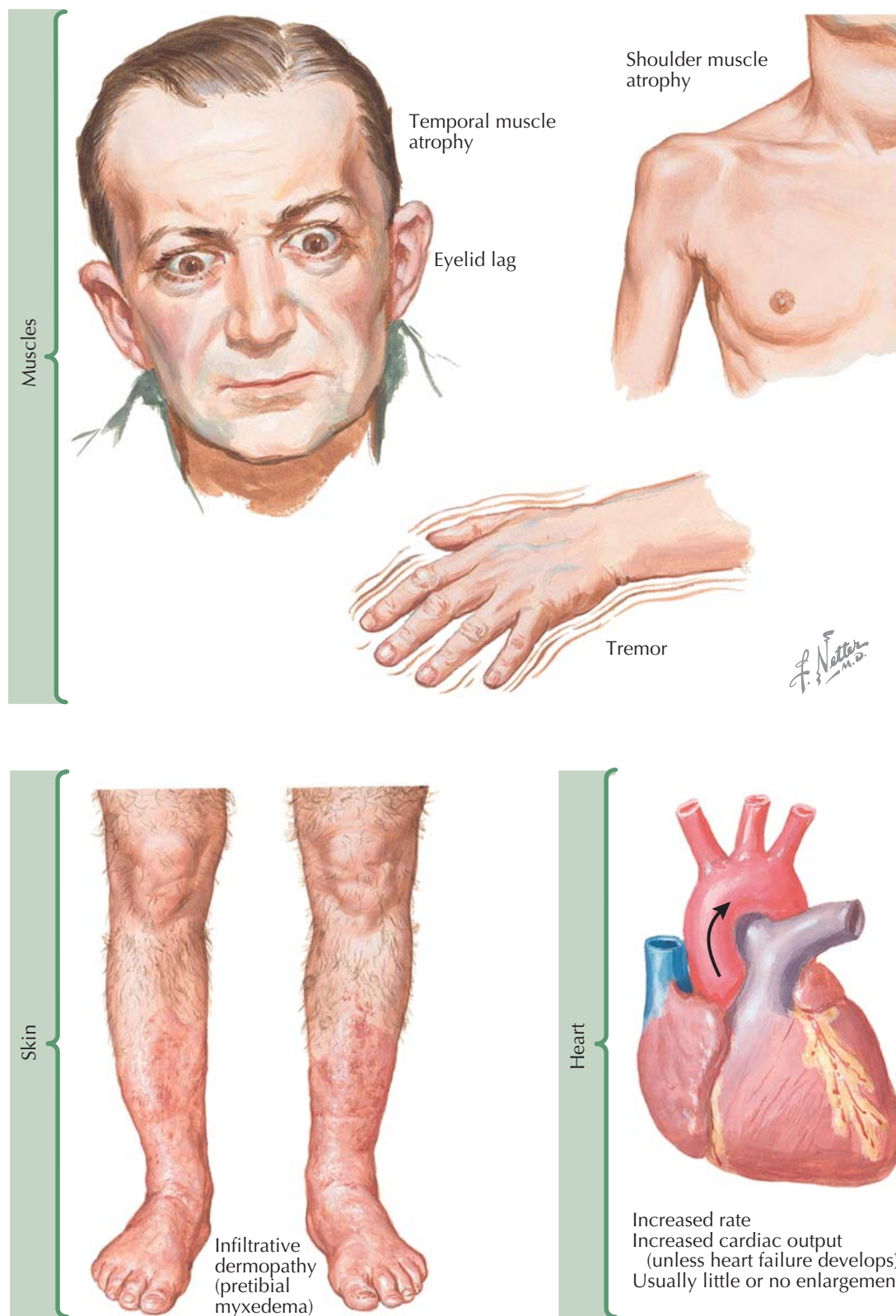
The increased metabolic rate and calorigenesis of these patients leads to a loss of weight despite a good to increased appetite, and to wasting of certain muscles, which is associated with muscular weakness. Hyperthyroidism has mixed effects on glucose metabolism, but affected patients typically have fasting hyperglycemia. Severe hyperthyroidism may be associated with hyperdefecation and malabsorption.

In women, the total serum estradiol concentrations are increased because of increased serum sex hormone-binding globulin concentrations. However, free estradiol concentrations are low, and serum luteinizing hormone concentrations are increased—factors that lead to oligomenorrhea or even amenorrhea, which is corrected by restoring the euthyroid state. The increase in serum sex hormone-binding globulin concentrations is also observed in hyperthyroid men, reflected in high serum total testosterone concentrations, low serum free testosterone concentrations, and mild increases in serum luteinizing hormone concentrations. The aromatization of testosterone to estradiol is increased, frequently resulting in gynecomastia, decreased libido, and sexual dysfunction.

Patients with Graves disease manifest the symptoms and signs of profound muscle changes known as thyroid myopathy. Atrophy of the temporal muscles, the muscles of the shoulder girdle, and the muscles of the lower extremities—notably the quadriceps femoris group—is typical. Muscular weakness is present, and these patients are often unable to climb steps or to lift their own weight from a chair. The muscular weakness may also contribute to dyspnea. Characteristically, these patients have a tremor, and when asked to extend a leg, they manifest a marked trembling and are usually unable to hold the leg in the extended position for more than 1 minute.

Excess  $T_4$  and  $T_3$  stimulate bone resorption, which reduces trabecular bone volume and increases the porosity of cortical bone. The effect on cortical bone density is usually greater than that on trabecular bone density. The high bone turnover state can be confirmed by measurement of increased blood concentrations of osteocalcin and bone-specific alkaline phosphatase. In some patients, the increased bone resorption leads to hypercalcemia. The hypercalcemia inhibits parathyroid hormone secretion and the genesis of 1,25-dihydroxyvitamin D, which leads to impaired calcium absorption and increased urinary calcium excretion. Thus, patients with long-standing hyperthyroidism are at increased risk for bone fracture and osteoporosis.

The earliest descriptions of Graves disease concerned patients who had goiters and some degree of heart failure. Characteristically, patients with hyperthyroidism report a variety of cardiac symptoms and signs. An increased heart rate is usually present. Cardiac output is increased, and those who develop heart failure present the manifestations of high-output failure characterized by a shorter than normal circulation time despite elevated venous pressure. Systolic hypertension is frequently present. Enlargement of the heart is



unusual except in a case of frank heart failure or in a patient with previous heart disease. The heart does not show any characteristic anatomic or microscopic changes that can be attributed to hyperthyroidism. The stimulus to cardiac output has been attributed to the elevated basal metabolic rate and the increased oxygen demands of the body. The usual cardiac effects of the catecholamines are accentuated by thyroid hormones, and all sympathetic activity is exaggerated in

hyperthyroidism. Atrial fibrillation occurs in approximately 15% of patients and is more common in patients older than age 60 years. In most patients, the atrial fibrillation spontaneously converts to normal sinus rhythm when euthyroidism is established. Thus, a peripheral  $\beta$ -adrenergic blocker will control most of the circulatory manifestations, reduce sweating, and diminish eyelid retraction—all independent of any effect on circulating levels of  $T_4$  and  $T_3$ .

## GRAVES OPHTHALMOPATHY

Graves ophthalmopathy is an autoimmune disease of the retro-orbital tissues, and the eye signs, of which proptosis and periorbital edema are the most common, vary in degree from mild to extremely severe and progressive.

Most patients with hyperthyroidism (regardless of the cause) have retraction of the eyelids (caused by contraction of the eyelid levator palpebrae muscles), which leads to widened palpebral fissures and a stare. Although the stare may give the appearance of proptosis, it must be confirmed with an exophthalmometer (see following text). Frequently, an eyelid lag can be demonstrated. This is a failure of the upper eyelid to maintain its position relative to the globe as the gaze is directed downward. There also may be globe lag—the eyelid moves upward more rapidly than does the globe as the patient looks upward. The eyelid retraction and eyelid lag regress after correction of the hyperthyroidism.

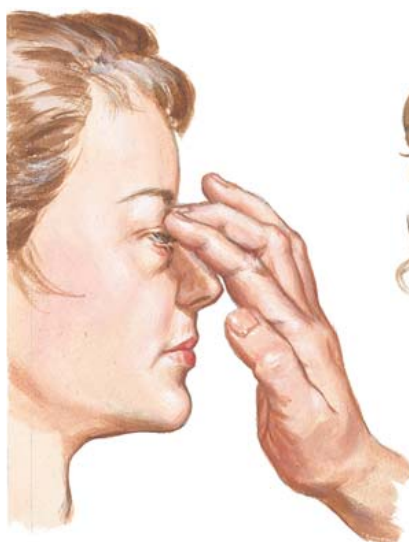Graves ophthalmopathy includes varying degrees of additional findings such as true proptosis, conjunctival injection, conjunctival edema (chemosis), periorbital edema, weakness of convergence, and palsy of one or more extraocular muscles. Patients often report increased lacrimation (aggravated by bright light, wind, or cold air), a sandy feeling in the eyes, and an uncomfortable sense of fullness in the orbits. When the patient is requested to look in one direction or another, a significant weakness of one or more of the extraocular muscles may be noted. The patient may complain of blurred vision, or even of diplopia on looking either upward or to the side.

If the distance, measured with an exophthalmometer, from the canthus to the front of the cornea exceeds 20 mm in white patients and 22 mm in black patients, proptosis is present. The proptosis may be asymmetric, and it may be masked by periorbital edema. Testing the eye and the orbital contents for resiliency is also useful. This is done by applying the fingers to the eyeball over the closed eyelid and attempting to move the eyeball backward. Normally, the eyeball can be pushed back easily and without resistance; in patients with severe ophthalmopathy, however, a significant decrease in resiliency is evident, and in some patients, it is impossible to push the eyeball back at all—a poor prognostic sign of progressive ophthalmopathy. The progression may be so rapid and extensive that the eyelids cannot be closed over the eyes, so that ulcerations of the cornea may result. These ulcerations may become infected and may even lead to loss of the eye. Rarely, the optic nerve may be involved by papilledema, papillitis, or retrobulbar neuritis, causing blindness.

The pathogenesis of Graves ophthalmopathy is related to an increased volume in the retro-orbital space—the extraocular muscles and retro-orbital connective and adipose tissues—because of inflammation and the accumulation of hydrophilic glycosaminoglycans (GAGs) (e.g., hyaluronic acid). As GAGs accumulate in these tissues, a change in osmotic pressure and an increase in fluid content displace the globes forward and compromise the function of the extraocular muscles. The extraocular muscles are swollen and infiltrated with T lymphocytes—the latter also probably play a key role in the pathogenesis of this disorder. T cells appear to be activated by the thyrotropin (thyroid-stimulating hormone [TSH]) receptor antigen. There is a positive correlation between the severity of

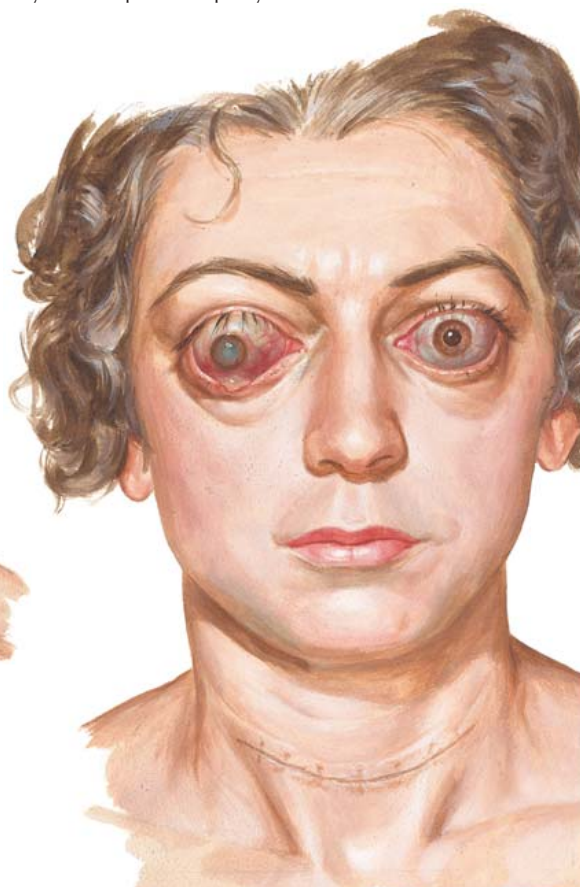


Moderately severe ophthalmopathy



Testing for resiliency

*F. Netter M.D.*



Severe progressive ophthalmopathy

ophthalmopathy and serum TSH receptor antibody concentrations.

In addition to a high titer of TSH receptor antibodies, several other risk factors for the development of ophthalmopathy in patients with Graves disease have been identified. Graves eye disease is more common in women, as is hyperthyroidism. However, when present, men appear to have more severe ophthalmopathy than women. Cigarette smoking has been clearly shown to increase both the risk for and the severity of ophthalmopathy. Cigarette smoke appears to increase GAG production and adipogenesis. Radioiodine therapy for hyperthyroidism appears to trigger or worsen ophthalmopathy more than subtotal thyroidectomy or antithyroid drug therapy. Although treating hyperthyroidism decreases the eyelid retraction, it does not improve

Graves ophthalmopathy. Finally, there is a temporal relationship between the Graves eye disease and the onset of hyperthyroidism. Ophthalmopathy appears before the onset of hyperthyroidism in 20% of patients, concurrently in 40%, when hyperthyroidism is treated in 20%, and in the 6 months after diagnosis in 20%.

Most patients can be successfully treated by raising the head of the bed at night, using saline eye drops frequently through the day, and wearing sunglasses when outside. In patients with more severe symptoms (e.g., chemosis, diplopia), glucocorticoid therapy should be considered. Orbital decompression surgery should be considered if the ophthalmopathy progresses despite glucocorticoid therapy, if vision is threatened, or if there is a cosmetic reason in patients with severe proptosis.



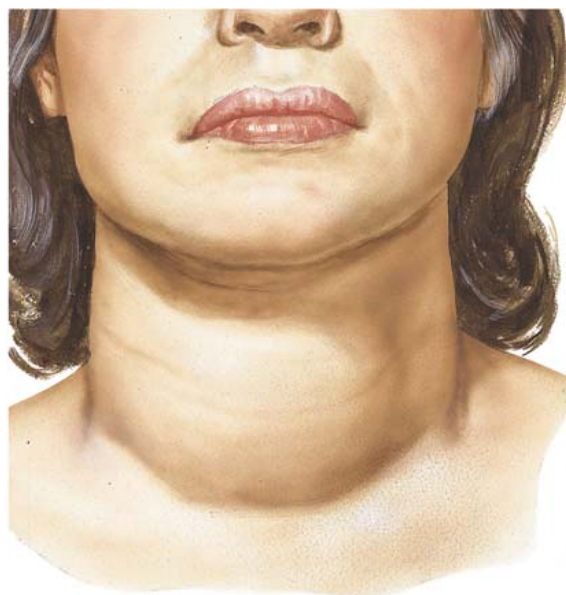
## THYROID PATHOLOGY IN GRAVES DISEASE

In patients with Graves disease, the most dramatic anatomic changes are those found in the thyroid gland, although characteristic changes in organs other than the thyroid also occur. The thyroid, which in healthy adults weighs between 15 and 20 g, is usually two to four times its normal size in patients with Graves disease. In extreme situations, it may be as large as 10 times the normal size. Rarely, patients with Graves disease do not have any significant enlargement of the thyroid gland. Diffuse enlargement and engorgement of the thyroid occur in a more or less symmetric fashion. These features can very well be demonstrated by scintigraphy of the thyroid after the administration of a test dose of radioactive iodine. As shown here, the thyroids of such patients concentrate radioactive iodine very diffusely and evenly. Notwithstanding the diffuseness of the process and the apparent symmetry of the thyroid, some surgeons have called attention to the fact that one lobe may be somewhat larger, although minimally so, than the other. Characteristically, the pyramidal lobe, which extends above the isthmus on one or the other side of the trachea, is enlarged enough to be easily palpable. The enlarged thyroid gland is firm, smooth, and rubbery to palpation. Typically, it is very vascular, as evidenced by an audible bruit (which may be heard usually over the superior poles of either lobe) and, in some instances, by a palpable thrill over the lateral lobes. The untreated thyroid gland, being vascular and friable in this disease, can be a source of serious bleeding during surgery.

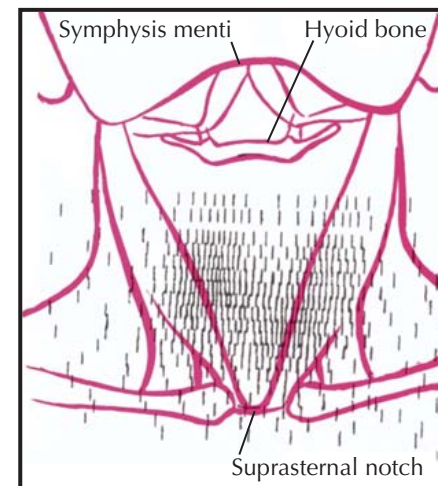
Histologic examination of the untreated thyroid reveals a very characteristic microscopic picture of diffuse hyperplasia. Usually, the colloid is completely lost from within the follicle. Any colloid that remains is pale-staining and demonstrates marginal scalloping and vacuolization. The thyroid cells are hypertrophied and hyperplastic. The acinar cells, which are normally low cuboidal, become high cuboidal or columnar and, by measurement, may be more than twice as high as those in the normal thyroid gland. In some instances, the hyperplasia of the acinar cells is so great that an intra-acinar papillary infolding takes place.

Along with the marked hyperplasia, there is a pronounced increase in avidity for radioactive iodine. Whereas the normal iodine uptake is 3% to 16% at 6 hours and 8% to 25% at 24 hours, in patients with Graves disease, it is nearly always more than 50% and may be as great as 80% or 90%.

In a small number of patients with long-standing Graves disease, hyperplasia is accompanied by significant to extensive lymphocytic infiltration (most are T lymphocytes) of the thyroid parenchyma, occasionally with large lymph follicles being present. The degree of lymphocytic infiltration may be decreased by antithyroid drug therapy. The size of the follicular epithelial



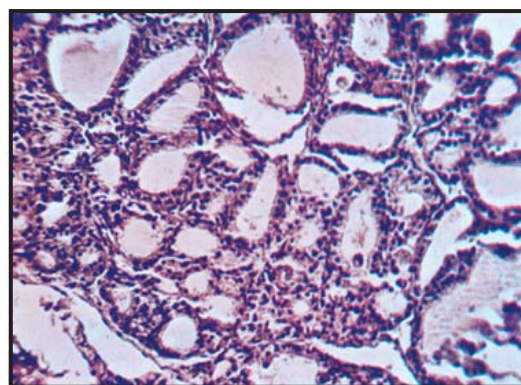
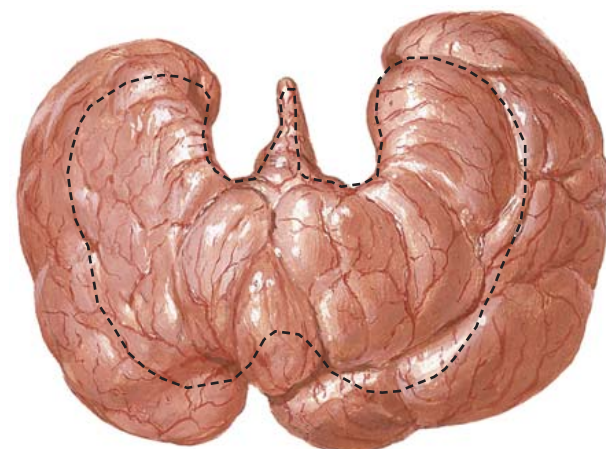
Diffuse goiter of moderate size



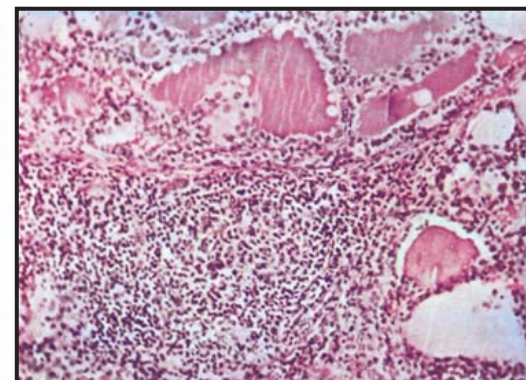
Scintigram

*F. Netter M.D.*

Diffuse enlargement and engorgement of thyroid gland (*broken line indicates normal size of gland*)



Diffuse hyperplasia



Hyperplasia with lymphocytic infiltration

cells correlates with the intensity of the local lymphocytic infiltrate, implicating local thyroid cell stimulation by thyrotropin receptor antibodies.

Other anatomic and functional changes include those in the eyes, skin, skeletal muscles, nervous system, heart, liver, thymus, and lymphoid tissues. The eyes are frequently proptosed; associated with this condition are enlarged, edematous extraocular muscles with increased fluid and fat in the retro-orbital space (see Plate 2-10). These muscles and the skeletal muscles

show edema, round cell infiltration, hyalinization, fragmentation, and destruction. Hyperthyroidism can affect the central and peripheral nervous systems—most of these represent direct or indirect effects of thyrotoxicosis. Other nervous system effects are related to the autoimmune nature of Graves disease (e.g., myasthenia gravis). The heart may be somewhat enlarged, but it does not present any characteristic or classic pathologic changes. Characteristically, the thymus and lymphoid tissues are enlarged, displaying simple hypertrophy.

### CLINICAL MANIFESTATIONS OF TOXIC ADENOMA AND TOXIC MULTINODULAR GOITER

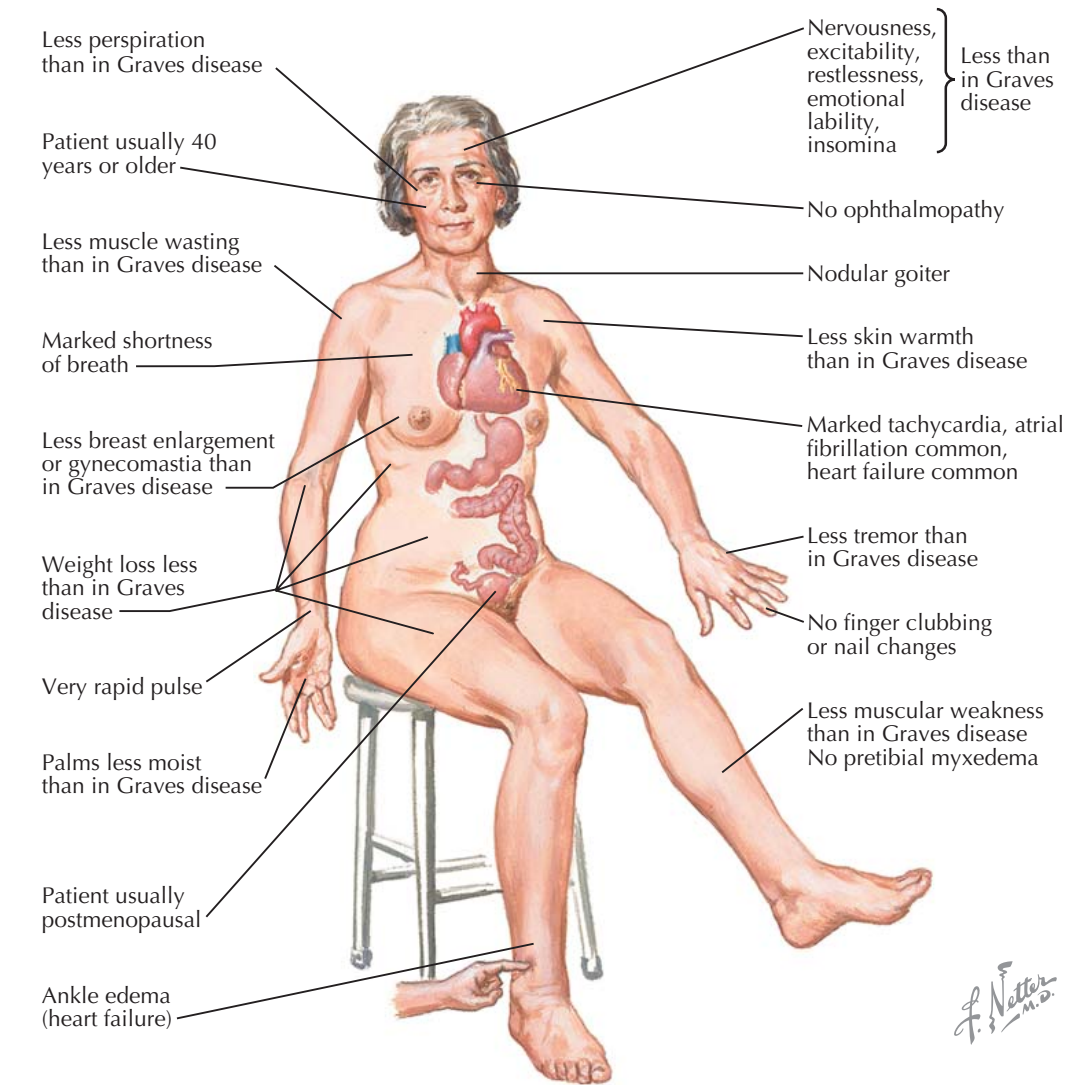
The hyperthyroidism associated with toxic adenomas and toxic multinodular goiters is caused by hyperfunctioning adenoma(s), which are the most common cause of hyperthyroidism after Graves disease. Hyperthyroidism is caused by nodular hyperplasia of thyroid follicular cells that is independent of thyrotropin (thyroid-stimulating hormone [TSH]) regulation. The clinical picture of this type of hyperthyroidism differs in important ways from that observed in patients with Graves disease. Patients with adenomatous goiters with hyperthyroidism are usually older than 40 years. They often give a history of having had either a multinodular thyroid or a single nodule in the thyroid for a long time. As a rule, they have cardiovascular symptoms, and frequently they have been referred to a cardiologist before being sent to an endocrinologist. They describe marked shortness of breath and have tachycardia, frequently with atrial fibrillation. When in heart failure, they may manifest all the signs and symptoms of this disease except that they usually do not have an increased circulation time, as in Graves disease. Characteristically, these patients do not have ophthalmopathy. Rarely, one may observe a minimal eyelid retraction or even a minimal eyelid lag. There is no thyroid acropachy or pretibial myxedema. Patients with this type of hyperthyroidism have less of the muscular weakness so characteristic of Graves disease. The basal metabolic rate is not as markedly elevated as it is in Graves disease, and these patients are not especially nervous or excitable. Typically, they do not show signs of marked weight loss or of muscle wasting, both of which are striking in Graves disease. Because a large percentage of affected female patients are postmenopausal, changes in the menstrual cycle, often seen in Graves disease, are not present.



The pathogenesis of a toxic adenoma and toxic multinodular goiter is frequently associated with activating somatic mutations in the gene encoding the TSH receptor. Toxic multinodular goiter tends to be more common in geographic areas where iodine intake is relatively low, but the incidence of solitary toxic thyroid adenomas does not seem to be affected by iodine intake.

Patients with this malady have a moderate elevation in serum free thyroxine (T<sub>4</sub>) and total triiodothyronine (T<sub>3</sub>) concentrations. The serum total and high-density lipoprotein (HDL) cholesterol concentrations are slightly decreased.

Studies with radioactive iodine are highly useful in examining these patients, especially if the site of radioactive iodine concentration is localized. Although the uptake of radioactive iodine may not be as great as is observed in classic Graves disease, in this malady, the radioactive iodine is usually concentrated primarily in the hyperfunctioning adenoma, with practically none in the remainder of the thyroid gland. However, in patients with toxic multinodular goiter, typically one or more focal areas of increased radioiodine uptake are found; nonfunctioning (or “cold”) nodules are also evident in some of these patients.

Effective treatment of hyperthyroidism is aimed at both symptomatic relief and decreasing the excess production of thyroid hormone. β-Adrenergic blockers control many of the hypermetabolic-type symptoms of hyperthyroidism. The treatment options to normalize



|                            |   |  |  |
|----------------------------|---|--|--|
| <b>Laboratory findings</b> |  | <b>Basal metabolic rate</b><br>Moderately elevated (25%–30%)   | <b>Blood tests:</b><br>Decreased TSH<br>Increased free T <sub>4</sub><br>Increased total T <sub>3</sub><br>Undetectable TSH-receptor antibodies<br>Decreased total and HDL cholesterol<br>Increased sex hormone-binding globulin<br>Increased estradiol (in men and women)<br>Increased osteocalcin and bone-specific alkaline phosphatase |
|                            |  | <b><sup>131</sup>I uptake</b><br>Elevated less than in Graves disease (40%–55%) localized in functioning adenoma |  |

T<sub>4</sub> and T<sub>3</sub> excess include thionamide administration, radioiodine administration, or surgery.

Thionamides (methimazole and propylthiouracil) are frequently used as the initial treatment of choice in patients who are elderly and have underlying cardiovascular disease. However, unlike Graves hyperthyroidism, which may go into long-term remission after the thionamide is discontinued, hyperthyroidism associated with toxic nodules and toxic multinodular goiters recurs when thionamide therapy is discontinued. The goal of thionamide therapy is to achieve a euthyroid state before definitive therapy (e.g., radioiodine or surgery).

Patients who are young and healthy usually do not need thionamide treatment before definitive therapy. A permanent cure can be achieved with radioiodine; it causes extensive tissue damage and destroys the adenoma or autonomous foci within 2 to 4 months after treatment. However, because the radioiodine is taken up primarily by the hyperfunctioning nodules and intervening normal thyroid tissue is quiescent, most patients are euthyroid after radioiodine therapy. Because the cure rate of radioiodine therapy decreases with very large toxic multinodular goiters, surgery is the treatment of choice for this subset of patients.



## PATHOPHYSIOLOGY OF TOXIC ADENOMA AND TOXIC MULTINODULAR GOITER

Hyperthyroidism arising in a hyperfunctioning adenoma(s) of the thyroid is the second most common cause of hyperthyroidism. This syndrome usually occurs in patients who previously had nontoxic nodular goiters. In the most clear-cut and classic setting, the patient, usually a middle-aged woman, presents with cardiovascular symptoms varying from complaints of palpitation and dyspnea to the picture of chronic atrial fibrillation and frank heart failure. The heart failure of hyperthyroidism exhibits a few characteristic features that should direct the physician to an investigation of the thyroid. Such patients have high-output failure with a decreased circulation time despite an elevated venous pressure. Other extrathyroidal pathology in patients with hyperthyroidism arising from hyperfunctioning adenomas of the thyroid is uncommon. Patients do not develop the typical eye signs, thyroid acropachy, or pretibial myxedema of Graves disease. These patients do not have the muscle weakness so characteristic of Graves disease.

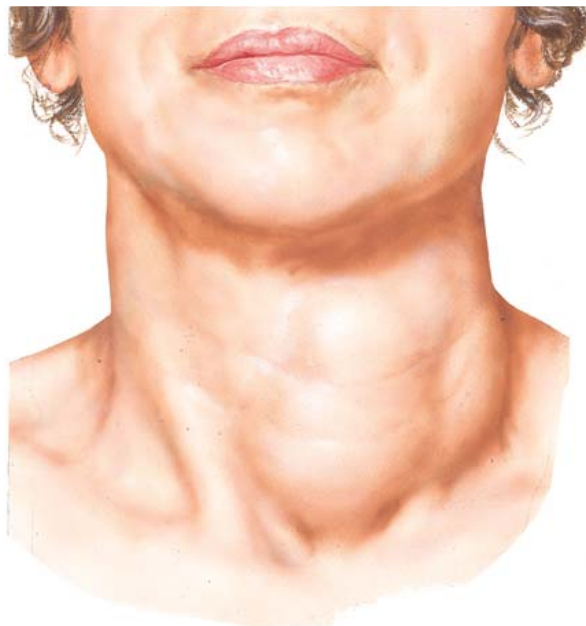
Pathologically, the most classic feature of this disease is that found in the patient with a rare “single” hyperfunctioning adenoma of the thyroid, which may be significantly enlarged while the rest of the thyroid gland remains uninvolved. No palpable nodules are present in the remainder of the gland, which may actually be smaller than normal. In such unique situations, the examiner may be impressed by the small size or the impalpability of the unaffected lobe, as contrasted with the large, single nodule in the opposite lobe. It is extremely uncommon to hear a bruit or to detect a thrill over a hyperfunctioning adenoma of the thyroid. If a test dose of radioactive iodine is administered to the patient and a scintigram is made over the neck at 24 hours, all the radioactive iodine will be found in the nodule, the remainder of the gland having concentrated none.

Grossly, whereas the nodule may be red, the rest of the gland is pale in color.

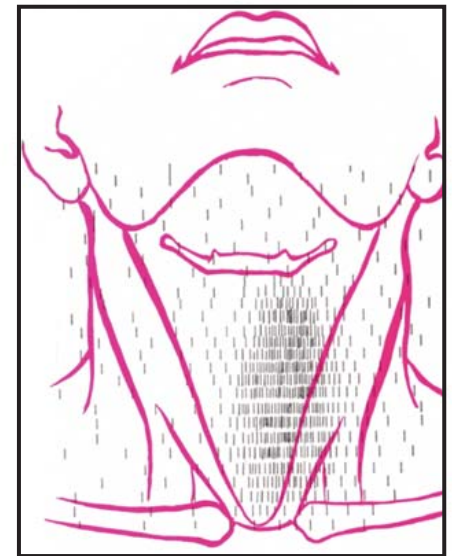
Histologic examination of the hyperfunctioning adenoma demonstrates a uniform hypertrophy and hyperplasia of the acinar cells. Some papillary infolding may be present, although this is much less common than in the diffusely hyperplastic gland of Graves disease. Lymphocytic infiltration is not found in this type of hyperplastic thyroid lesion. The remainder of the gland shows involution. If the acinar cells are measured, the cell height will be uniformly increased, averaging around 12 to 14  $\mu\text{m}$ , whereas the cell height of the uninvolved tissue may be less than that of a normal thyroid, averaging around 5 to 6  $\mu\text{m}$ .

The toxic adenoma is a true follicular adenoma that has one of several somatic point mutations in the gene encoding the thyrotropin (thyroid-stimulating hormone [TSH]) receptor, which lead to constitutive activation of the TSH receptor in the absence of TSH.

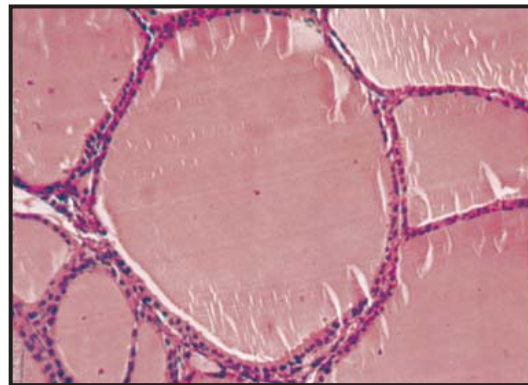
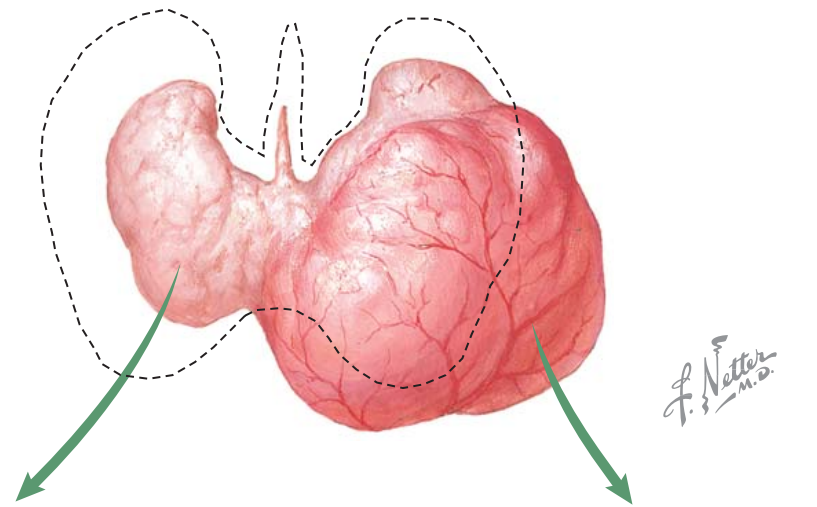
The more common type of hyperfunctioning adenomatous goiter, the “multinodular” type, occurs in patients who had a long-standing multinodular goiter before developing hyperthyroidism, with a number of adenomas within the gland. Some of these nodules may



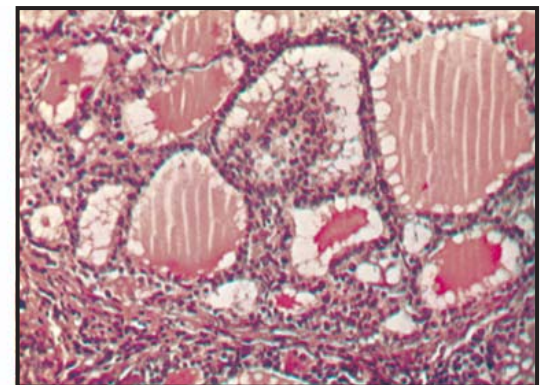
Hyperfunctioning adenoma



Scintigram



Remainder of gland—involution



Adenoma—hyperplasia

be highly undifferentiated adenomas, and, rarely, even a cancerous lesion may be found within one of the nodules. If all multinodular thyroids could be examined, it is quite possible that in many of them, the structure of undifferentiated adenomas would be present; others would show varying degrees of differentiation; and a few would exhibit the structure of a well-differentiated, functional adenoma.

The somatic mutations in the TSH receptor gene found in solitary toxic nodules may also be seen in some

cases of toxic multinodular goiter but may differ from one nodule to another. Radioiodine scans show localization of isotope in more than one of the nodules; iodine uptake in the rest of the gland is usually suppressed. Histopathologic examination shows that the functioning areas resemble adenomas and are distinct from the surrounding tissue. These multinodular thyroid glands contain multiple solitary hyperfunctioning and hypofunctioning adenomas in the midst of suppressed normal thyroid tissue.

## CLINICAL MANIFESTATIONS OF HYPOTHYROIDISM IN ADULTS

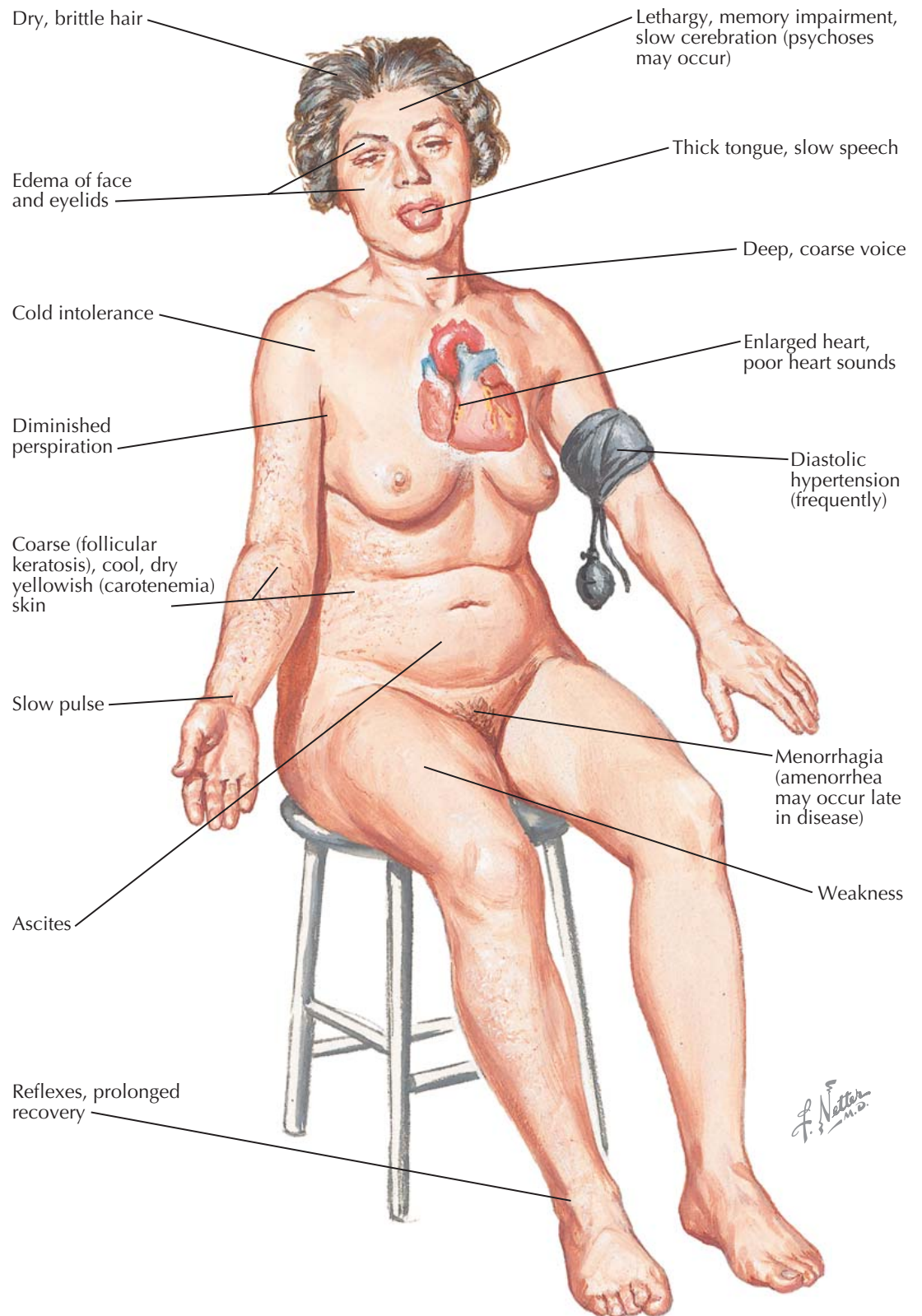
### SYMPTOMS AND SIGNS

Primary hypothyroidism, although not described until 1874, is a common endocrine disorder that occurs about seven or eight times more often in females than in males. The clinical presentation of hypothyroidism depends on the degree of thyroid hormone deficiency and the rapidity of the loss of the thyroid hormones, thyroxine (T<sub>4</sub>) and triiodothyronine (T<sub>3</sub>). Patients with gradual onset of hypothyroidism may not be diagnosed for many years—patients often attribute the signs and symptoms to aging. In addition, the clinical presentation of hypothyroidism may be affected by coexisting morbidities. For example, in patients with hypothyroidism caused by hypothalamic or pituitary disease, the presentation may be dominated by the signs and symptoms of secondary adrenal failure, hypogonadism, or diabetes insipidus.

The basis of the pathophysiology of hypothyroidism can be thought of as the “slowing down” of most metabolic processes. Patients may be lethargic with slow cerebration, slow speech patterns, cold intolerance, constipation, and bradycardia. These patients typically have dry, brittle hair, which, if previously curly, loses its curl. Individuals with profound hypothyroidism may actually manifest many psychotic features, which have been labeled “myxedema madness.” The edema of the face and eyelids (periorbital edema) is associated with the subcutaneous accumulation of glycosaminoglycans. The tongue is thick, and the voice is deep and coarse, with a relative lack of inflection.

The skin is cool and dry because of diminished perspiration and may be coarse. Often, a sandpapery follicular hyperkeratosis occurs over the extensor surfaces of the arms and elbows, frequently on the lateral thoracic wall and over the lateral thighs, and occasionally over the shoulders. The skin of the hands or face frequently acquires a yellowish color, suggesting carotenemia. The fingernails may be brittle and chip easily. Loss of hair of the lateral third of the eyebrows is frequently observed. Vitiligo and alopecia may be present in patients with autoimmune polyglandular failure.

Patients with hypothyroidism generally have a slow pulse and diastolic hypertension; the latter is associated with increased peripheral vascular resistance. Cardiac output is decreased, and patients may note dyspnea on exertion. A typical feature in patients with marked and long-standing primary hypothyroidism is diffuse cardiac enlargement owing to myxedematous fluid in



the myocardium and to pericardial effusions, which may also be associated with pleural effusions and even with ascites. Heart sounds are distant. There is a decreased rate of cholesterol metabolism that leads to hypercholesterolemia.

Respiratory muscle weakness may contribute to dyspnea on exertion. Some of these patients may have hypoxia and hypercapnia. Macroglossia may contribute to obstructive sleep apnea.

Younger female patients may have menorrhagia severe enough to require surgical curettage. Later in the disease, reversible secondary amenorrhea may occur. Hyperprolactinemia and galactorrhea may be seen in women with primary hypothyroidism, in whom increased hypothalamic thyrotropin (thyroid-stimulating hormone [TSH])–releasing hormone secretion can stimulate prolactin release from pituitary lactotrophs.



## CLINICAL MANIFESTATIONS OF HYPOTHYROIDISM IN ADULTS

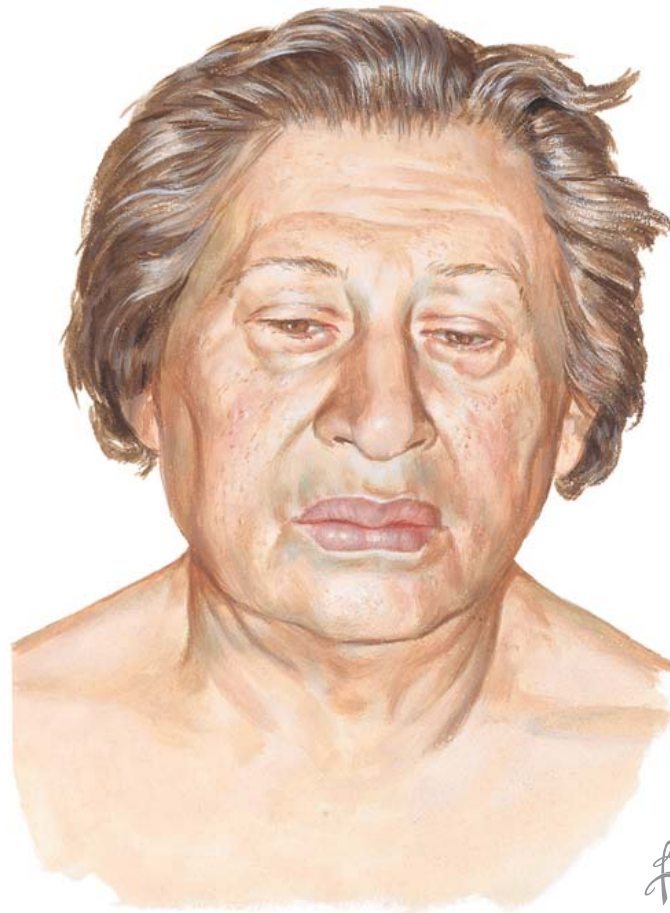
(Continued)

Neurologic findings include a prolonged relaxation phase of the ankle jerk reflex and generalized weakness. Carpal tunnel syndrome is fairly common in these patients. Myxedema coma—a rare complication—should be considered in patients who have hyponatremia, hypercapnia, and hypothermia. Myxedema coma may be triggered in patients with severe hypothyroidism by the administration of opiates or by infection or trauma.

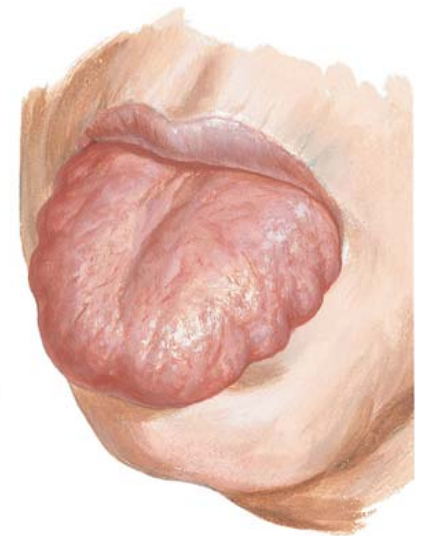Hypochromic anemia, if present, may be of any type—microcytic or normocytic. Occasionally, normochromic macrocytic anemia is found. If the patient has polyglandular failure, pernicious anemia may be present. The menorrhagia seen in hypothyroid premenopausal women may lead to iron-deficiency anemia. Decreased free water clearance may result in hyponatremia.

Primary hypothyroidism (resulting from disease of the thyroid gland itself) must be distinguished from central hypothyroidism (resulting from disease of the pituitary gland or hypothalamus). Some signs and symptoms may provide clues as to the cause of hypothyroidism. The history of patients with the latter disease often includes severe postpartum hemorrhage followed by absence of lactation and failure of the menstrual cycle to return after recovery from the postpartum period. Usually, the picture of myxedema does not develop until some time after the first sign of pituitary insufficiency (e.g., amenorrhea without hot flushes). These individuals usually describe extreme weakness, somnolence, intolerance to the cold, impaired memory, and slow cerebration. On physical examination, they differ from patients with primary hypothyroidism if they lack other pituitary hormones. Thus, patients with central hypothyroidism may also have finer, softer hair; loss of axillary and pubic hair; a small heart (in contrast to the enlarged heart of patients with primary myxedema); some degree of hypotension; and skin that is less dry and not scaly.

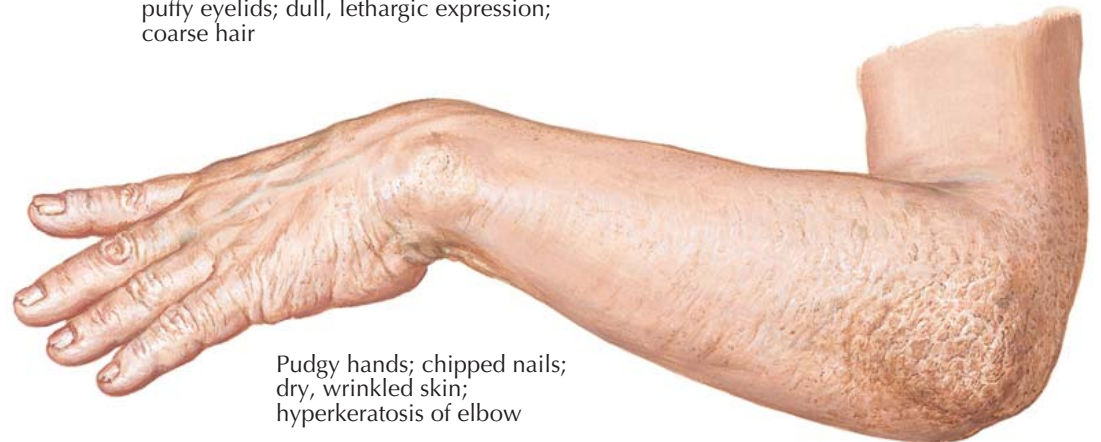Although findings on the history and physical examination provide the clinician with clues regarding primary vs central hypothyroidism, serum TSH and free  $T_4$  concentrations are the key tests. In primary hypothyroidism, the serum TSH concentration is above the reference range, and the blood concentration of free  $T_4$  is usually below the lower limit of the reference range. In central hypothyroidism caused by hypothalamic or pituitary dysfunction, the serum TSH concentration is inappropriately low for the low level of free  $T_4$ . Radioactive iodine uptake is low in both types of hypothyroidism.



Characteristic facies in hypothyroidism: coarse features; thick lips; dry skin; puffy eyelids; dull, lethargic expression; coarse hair



Macroglossia, showing dental impressions



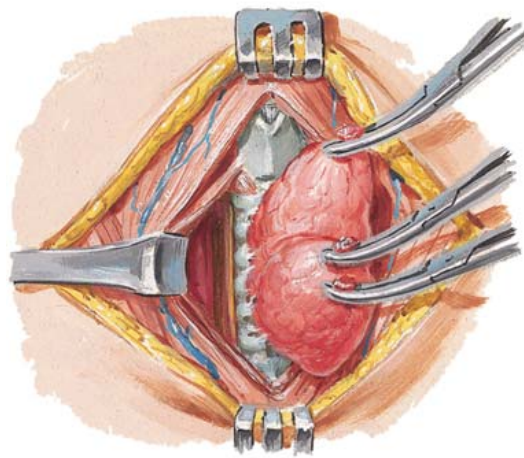
Pudgy hands; chipped nails; dry, wrinkled skin; hyperkeratosis of elbow

### ETIOLOGY

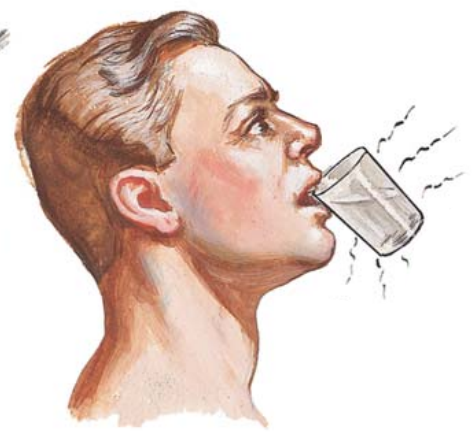Primary hypothyroidism, with deficient secretion of the thyroid hormones  $T_4$  and  $T_3$ , is the most common cause of hypothyroidism. This may result from destruction or removal of the thyroid gland or from thyroid gland atrophy and subsequent replacement by fibrous tissue. Primary hypothyroidism may also develop with goiters, which are incapable of synthesizing thyroid hormone

either because of the administration of some agent that inhibits the organification of iodine or because of some defect in the enzymes necessary for the synthesis of thyroid hormone. It may also result from autoimmune chronic thyroiditis, such as Hashimoto thyroiditis. Central hypothyroidism is caused by a process that inhibits release of TSH-releasing hormone from the hypothalamus or TSH release from the pituitary.

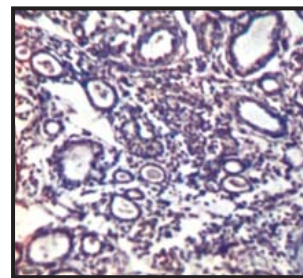
Primary hypothyroidism



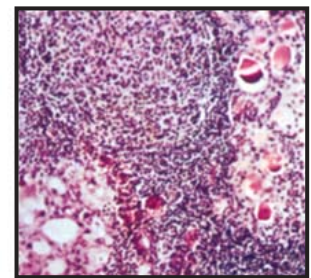
After thyroidectomy



After radioactive iodine to treat Graves disease



After acute thyroiditis



After Hashimoto thyroiditis

## CLINICAL MANIFESTATIONS OF HYPOTHYROIDISM IN ADULTS

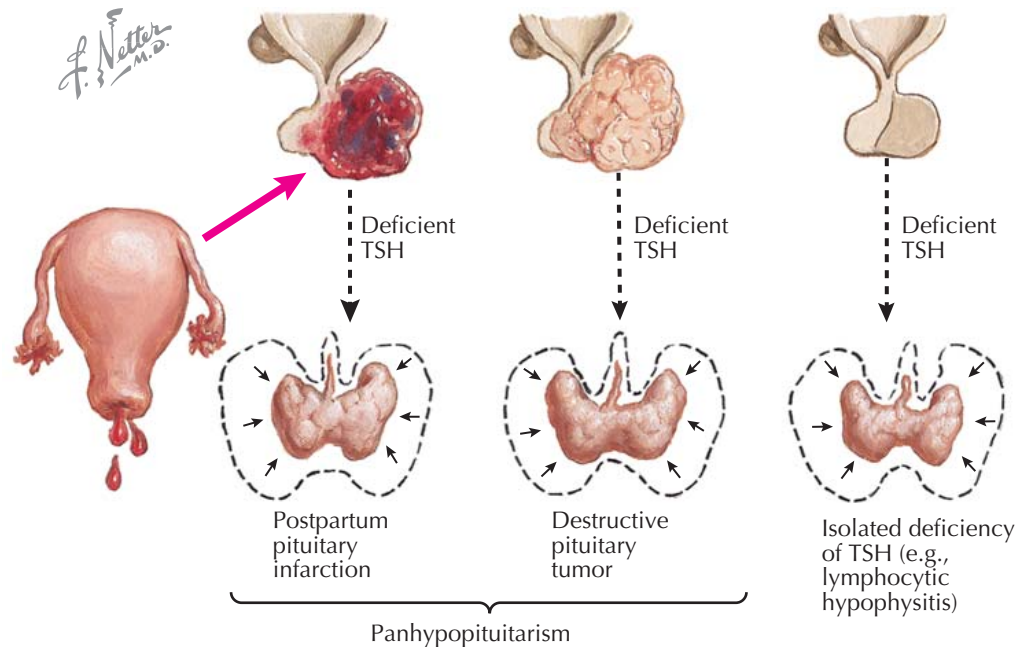
(Continued)

The most common cause of primary hypothyroidism is Hashimoto thyroiditis. The second most common cause is iatrogenic. For example, most patients who have undergone thyroidectomy in the treatment of nontoxic goiter or of Graves disease develop primary hypothyroidism. The most common treatment of Graves disease is radioactive iodine with the goals of total thyroid gland destruction and primary hypothyroidism.

Hashimoto thyroiditis is the most common spontaneous cause of primary hypothyroidism. Transient primary hypothyroidism may develop after subacute and acute thyroiditis (see Plate 2-22). A high serum thyroid peroxidase antibody concentration is consistent with Hashimoto thyroiditis.

Central hypothyroidism is the result of a variety of processes that affect the anterior pituitary gland, resulting in loss of TSH secretion. TSH deficiency may occur in isolation (e.g., with lymphocytic hypophysitis) or, more commonly, as part of complete anterior pituitary failure (see Plate 1-16). Complete anterior pituitary failure may be the result of inflammation, infarction (e.g., postpartum apoplexy), primary neoplasms, metastatic disease, infiltrative disorders (e.g., sarcoidosis, Langerhans cell histiocytosis, hemochromatosis), surgery, head trauma, or radiation therapy (see Plates 1-12 to 1-18). Pituitary-directed head magnetic resonance imaging is indicated in these patients to assist in differentiating among these multiple causes.

Central hypothyroidism (hypothalamic or pituitary origin)



## TREATMENT

Whether primary or secondary in etiology, the treatment of hypothyroidism is daily levothyroxine administered orally. In patients with primary hypothyroidism, the serum TSH concentration is measured to guide the adjustment of the levothyroxine dosage; the goal is a TSH concentration in the middle of the reference range. In patients with central hypothyroidism, blood

TSH measurement is useless, and the levothyroxine dosage is adjusted to a free  $T_4$  concentration in the middle of the reference range. However, before starting levothyroxine therapy in patients with central hypothyroidism, it is essential to assess the hypothalamic-pituitary-adrenal axis. If levothyroxine, which can accelerate cortisol metabolism, is administered to a patient with concomitant untreated adrenal insufficiency, it may precipitate an adrenal crisis.



## CONGENITAL HYPOTHYROIDISM

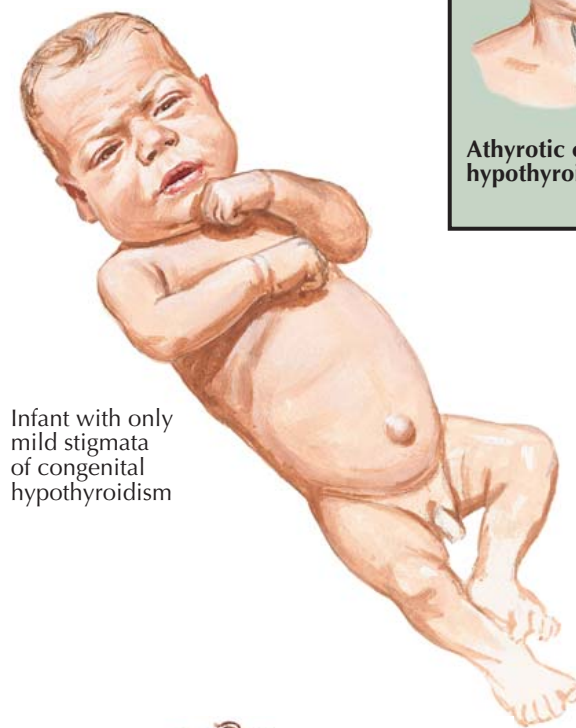
Congenital hypothyroidism is the most common cause of mental retardation that can be prevented and treated. The intelligence quotient later in life is inversely related to the age at the time of diagnosis; thus, identifying congenital hypothyroidism as soon as possible after birth is critical. The most common cause is thyroid dysgenesis, including congenital absence (agenesis) of the thyroid gland itself, thyroid hypoplasia, or thyroid gland ectopy. Less commonly, congenital hypothyroidism is associated with nonfunctioning goiters or with goiters that have inborn errors of thyroid hormone biosynthesis (goitrous hypothyroidism). The synthetic defects are usually inherited in an autosomal recessive pattern and include deficits in impaired thyroid peroxidase activity, abnormal iodide transport, iodotyrosine deiodinase deficiency, and abnormal thyroglobulin molecules. This malady occurs most frequently in endemic goiter regions, but goitrous congenital hypothyroidism has been observed in areas where goiters are quite uncommon.

Central (hypothalamic or pituitary) hypothyroidism is a much less common cause of congenital hypothyroidism (one in 100,000 babies) and can be detected only by measuring the serum thyroxine ( $T_4$ ) concentration. When present, it may occur in the setting of other midline developmental disorders (e.g., cleft lip and palate, septo-optic dysplasia) and be associated with other anterior pituitary gland hormone deficiencies.

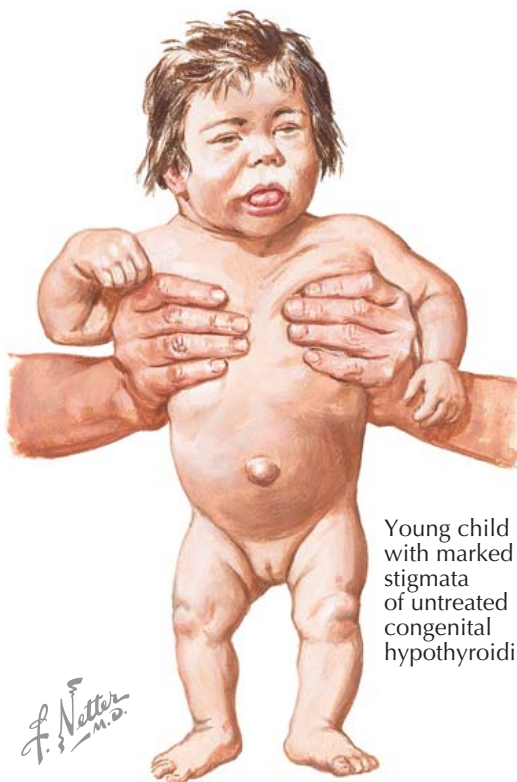The physical stigmata of congenital hypothyroidism may be mild or absent at the time of birth because some maternal  $T_4$  crosses the placenta. Congenital hypothyroidism is sporadic more than 85% of the time and is thus unsuspected. In the mid-1970s, state-wide newborn screening programs in the United States were developed. These programs measure either thyrotropin (thyroid-stimulating hormone [TSH]),  $T_4$ , or both in blood samples collected by heel stick on filter paper cards 24 to 48 hours after delivery. On the basis of these data, the incidence of elevated TSH levels varies from one in 2000 to one in 32,000 babies; the variance depends on geographic location and ethnicity. The frequency of congenital hypothyroidism is approximately twofold higher in baby girls. Rapid institution of thyroid hormone replacement therapy can prevent subsequent irreversible disabilities.

When untreated, congenital hypothyroidism in infants has similar features to those seen in adults with hypothyroidism, but there are some important differences. There is a failure of skeletal growth and maturation and a marked retardation and deficiency in intellect. The development of centers of ossification is markedly delayed, and the epiphyses show a characteristic stippling. Delayed ossification of bone, of epiphysial union, and of dentition is observed. The skull base is usually short; there may be persistence of the cartilaginous junctions between the presphenoid and postsphenoid bones, which normally ossify in the eighth month of fetal life. Furthermore, because of a delay in ossification of the membranous bones, the frontal suture is usually wide, and the anterior fontanels are exceptionally large.

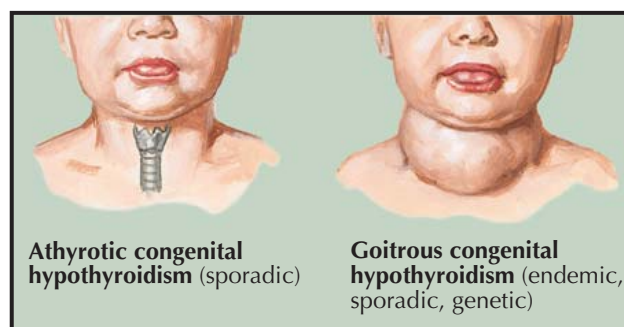
The face of a child with untreated congenital hypothyroidism is round, with a dull expression and yellowish color. The eyelids are puffy, and the palpebral fissures are generally narrowed but horizontal. The



Infant with only mild stigmata of congenital hypothyroidism

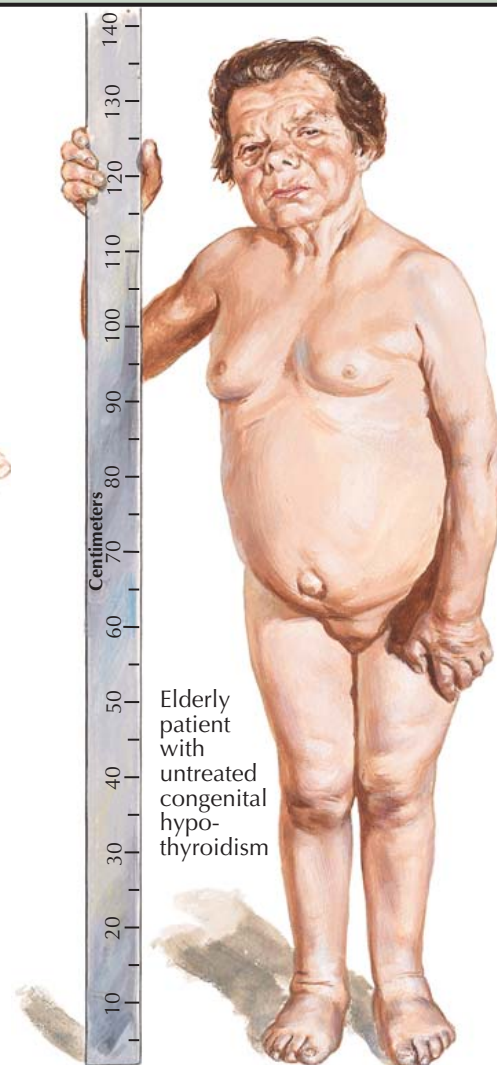


Young child with marked stigmata of untreated congenital hypothyroidism



Athyrotic congenital hypothyroidism (sporadic)

Goitrous congenital hypothyroidism (endemic, sporadic, genetic)



Elderly patient with untreated congenital hypothyroidism

nose is frequently flat and thick; the lips are thick; the mouth remains open, and a large, thick tongue protrudes. The voice is flat and harsh. The neck is usually short and thick. The skin is dry and cool and presents a picture of nonpitting edema. There is usually marked hyperkeratosis in the skin over the anterior abdominal wall. The hair is fine, lifeless, dry, and often quite sparse. Juvenile patients with untreated congenital hypothyroidism may also have a marked growth of fine,

short hair, of a lanugo type, over the shoulders, upper arms, and face.

The physical features of children with congenital hypothyroidism may be confused with the features observed in trisomy 21. Persons with trisomy 21 have finer features, absent coarse skin, slanted eyes, a palmar crease, and excessive extensor flexibility of the fingers arc. On laboratory evaluation, babies with trisomy 21 have normal blood concentrations of TSH and  $T_4$ .

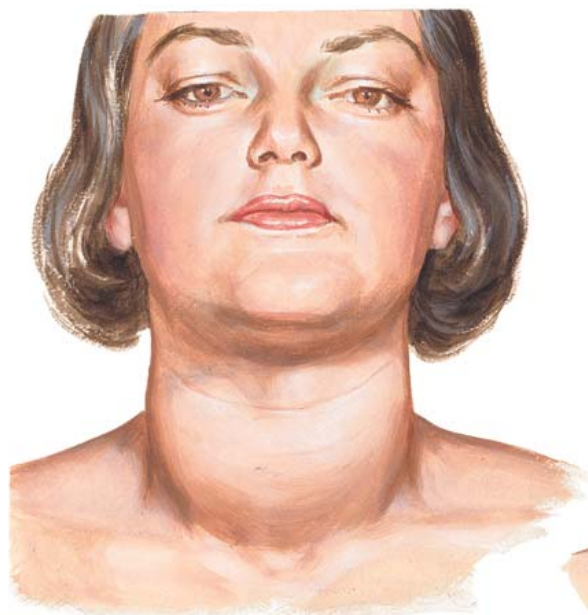


## EUTHYROID GOITER

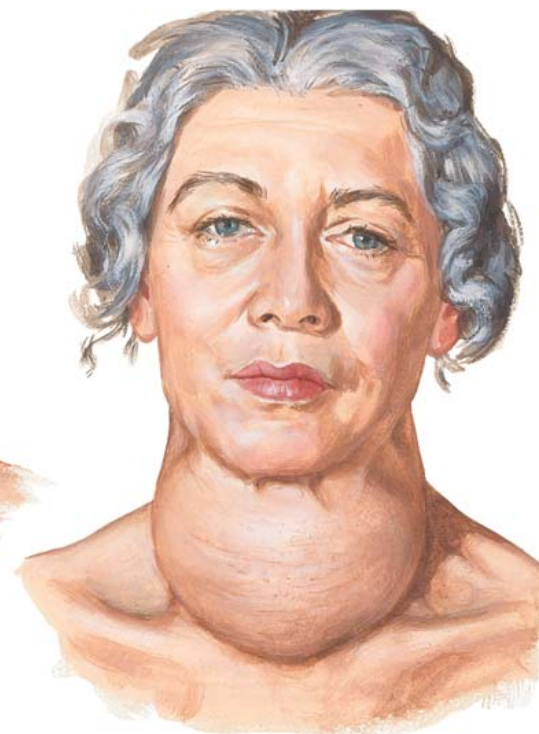Euthyroid (nontoxic) goiters occur throughout the world, although they are more common in areas where the iodine content in the water and soil is low. In iodine-deficient goiters, there is characteristic enlargement of the thyroid with a moderate-sized, nontoxic, diffuse goiter that occurs in both boys and girls at about the time of puberty. Such goiters are diffuse in the early stage; later, they may become nodular, feeling hard in one area or cystic in another. Nodular goiters may be more or less symmetric or quite asymmetric. Such a goiter, if allowed to progress, may descend beneath the sternum and produce the picture of an intrathoracic goiter. With the increase in goiter size, especially if some of it is lodged beneath the sternum, obstructive symptoms may result from distortion of the trachea, esophagus, nerves, or jugular veins. This may occur because the thoracic inlet is a small area ( $\sim 5 \times 10$  cm) that has bony boundaries—first ribs laterally, first thoracic vertebral body posteriorly, and manubrial and sternal bones anteriorly. Typically, these multinodular goiters grow very slowly, and the development of early obstructive symptoms can be quite insidious. Dyspnea on exertion may be the first symptom related to a substernal goiter. With advancing tracheal compression, stridor may become evident. Other thoracic inlet compressive symptoms include dysphagia, vocal cord palsy from recurrent laryngeal nerve compression, and Horner syndrome from compression of the cervical sympathetic chain. On physical examination, the Pemberton maneuver may be used to detect thoracic inlet obstruction. The patient is asked to hold the arms straight up vertically for 1 minute; if the patient develops marked facial plethora, cyanosis, or stridor, the result is considered positive for thoracic inlet obstruction.

Occasionally, a nodular goiter may enlarge in one area very suddenly, producing pain that may be referred to the ear, neck structures, or shoulder. This is frequently explained on the basis of a hemorrhage into a follicle or into an adenoma or a large cyst in the thyroid.

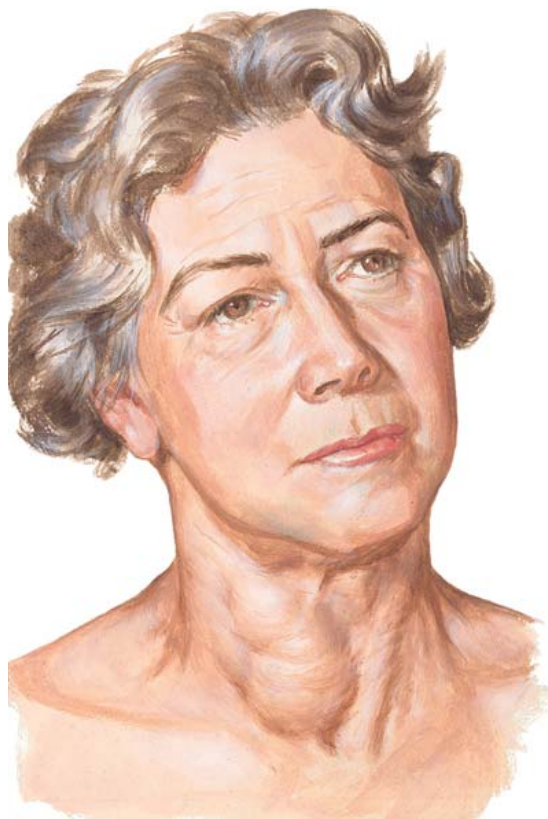In such multinodular goiters, adenomas of various types may be observed, and these may present various kinds of histologic structures. Some may be capable of function and may develop hyperfunction, resulting in a clinical picture of hyperthyroidism in an adenomatous goiter, a so-called “hot nodule” (see Plates 2-12 and 2-13). Cancer is much less common in these multinodular goiters than in thyroids with a single nodule. However, the fact that the goiter is multinodular does not rule out the possibility of cancer’s developing or being found in it.



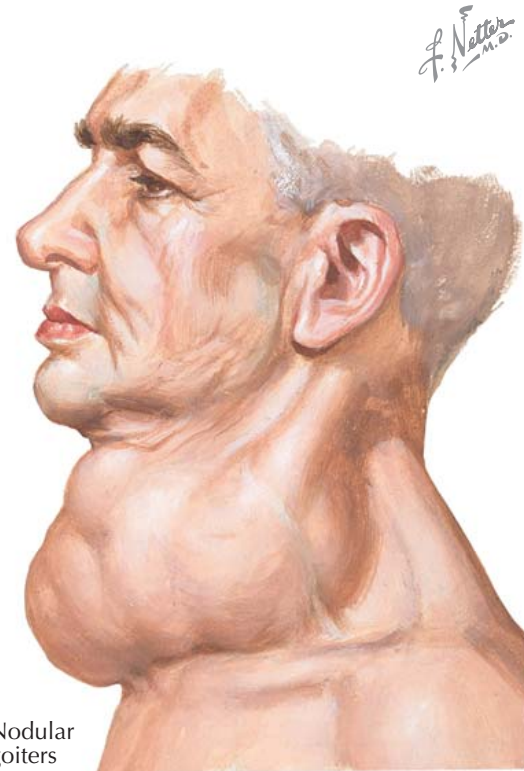
Moderate size nontoxic diffuse goiter



Large diffuse goiter



Nodular goiters



Hyperthyroidism should be excluded by measuring the serum thyrotropin concentration. Thyroid ultrasonography is helpful in assessing the structure of the suprasternal component of a multinodular goiter. If needed, the extent of substernal goiters can be determined with either computed tomography or magnetic resonance imaging. If prominent nodules are present, the underlying pathophysiology can be assessed with ultrasound-guided fine-needle aspiration biopsy.

The indications for surgical removal of such thyroids may fall into several categories: (1) cosmetic reasons that may impel the patient to seek surgical removal of the gland; (2) sudden enlargement of the gland, especially if the site of rapid growth is hard, suggesting a neoplastic change; and (3) most importantly, to correct any obstructive symptoms produced by the impingement of such a large mass on either the trachea or the esophagus.



## GROSS PATHOLOGY OF GOITER

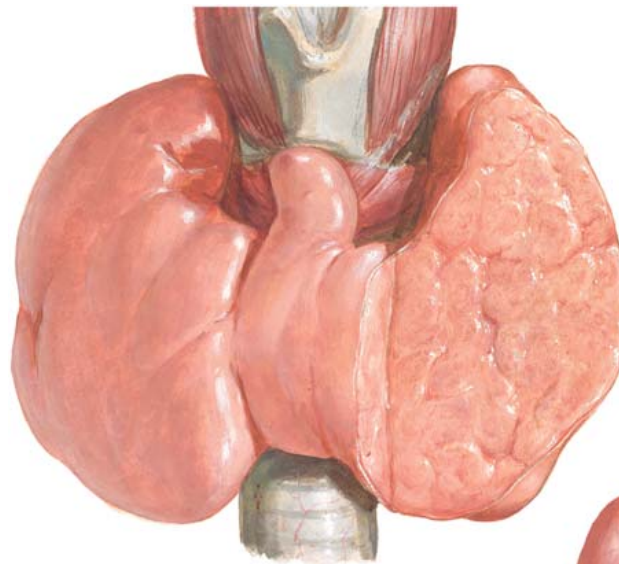
The term “goiter” refers to an enlargement of the thyroid gland. In general, the prevalence of goiter depends on the dietary iodine intake. Thus, goiters may be endemic in geographic areas of iodine deficiency. Early in the development of a nontoxic goiter, the gland is usually diffusely and uniformly enlarged, with an increase in the size of the pyramidal lobe. This is known as a diffuse nontoxic, or colloid, goiter. Nontoxic goiters are eightfold more common in females and frequently become evident in adolescence or pregnancy. Such glands may be two to three times the normal size or even larger. The patient may become aware of the condition because others have commented on the fullness of the neck, because shirt collars may feel too tight, or because it may become difficult to swallow. Large goiters may compress the trachea and result in stridor. Venous engorgement from narrowing of the thoracic inlet may occur. Most simple and multinodular goiters are associated with a euthyroid state.

On physical examination, the gland feels firm but not hard. As the process progresses, with the advancing age of the patient the thyroid may become asymmetric and multinodular, which is evident on gross examination of the gland. Significant variations in the size and structure of the nodules become apparent. In very long-standing nodular goiters, hemorrhages into various sites in the gland, cyst formation, fibrosis, and even calcification are likely to be observed. On chest radiographs, asymmetric goiters typically cause lateral displacement of the trachea; in addition, any retrosternal extension of such a goiter may, if calcified, initially simulate intrapulmonary calcifications.

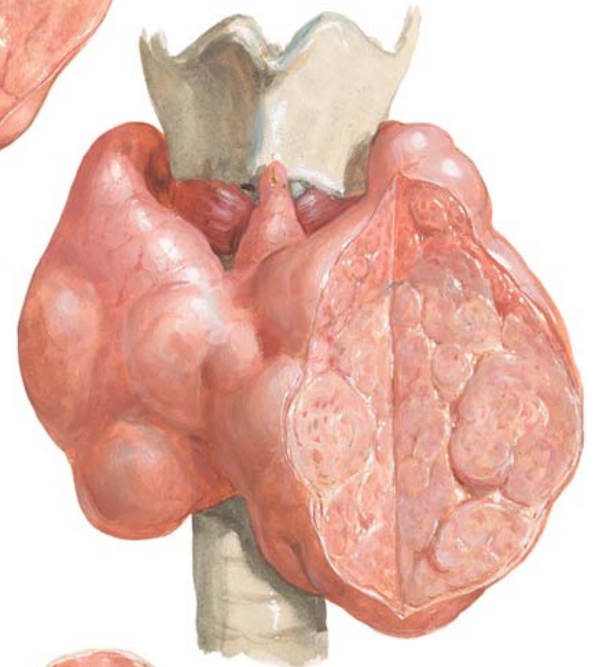
The cut surface of a colloid goiter shows a uniform amber color with a translucent appearance. Colloid goiters may weigh anywhere from 40 to 1000 g or more. The thyroid gland is distorted in shape and nodular, with some nodules partially or completely separated from the gland. The gross pathology appearance on cut section typically shows areas of nodularity, fibrosis, hemorrhage, and calcification. Some nodules may show cystic change, and some may have a thickened fibrous connective tissue capsule and have the general appearance of a follicular neoplasm.

Cytologic examination from fine-needle aspiration biopsy of colloid nodules typically shows colloid and mixed cell populations with relatively few cells in the aspirate. The types of cells usually seen on cytologic examination include follicular cells with uniform nuclei, inflammatory cells, and Hürthle cells. Hypercellular foci within a multinodular goiter may simulate a follicular neoplasm.

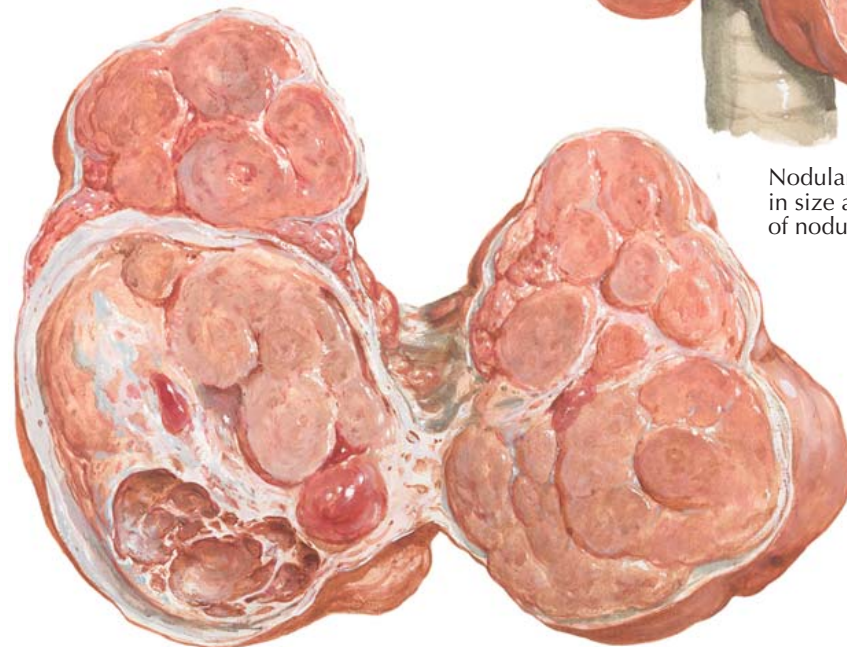Microscopic examination of the colloid nodular goiter may reveal every conceivable type of benign adenoma, including a highly undifferentiated trabecular pattern or



Diffuse colloid goiter



Nodular goiter; variation in size and structure of nodules



Long-standing nodular goiter with hemorrhages, cyst formation, fibrosis, and calcification

*F. Netter M.D.*

the earliest stage of differentiation of tubular structure, the structure of microfollicles, or the picture of a hyperplastic adenoma. The follicles—usually lined by flattened epithelium with involutinal changes—can be of varying size and as large as 2 mm in diameter. Large distended follicles may coalesce to create cystic areas.

Rarely, within these nodules may be seen various types of cancerous growths, such as differentiated

thyroid carcinomas (papillary and follicular). However, the cancerous changes in such thyroids are much less common than they are in those of patients presenting with a single nodule in the thyroid. Thoracic inlet obstructive symptoms represent the most important indication for therapeutic intervention, but the rare occurrence of a small malignancy must always be kept in mind.

## ETIOLOGY OF NONTOXIC GOITER

The development of nontoxic goiter—thyroid enlargement (diffuse or nodular) that is not associated with overt hyperthyroidism or hypothyroidism or caused by neoplasia or inflammation—can usually be attributed to a genetic or environmental factor that leads to deficiency in thyroid hormone secretion, to which the pituitary responds with an increased output of thyrotropin (thyroid-stimulating hormone [TSH]). For example, iodine deficiency may result in decreased thyroid gland production of thyroxine (T<sub>4</sub>) and triiodothyronine (T<sub>3</sub>), resulting in increased TSH secretion that in turn promotes thyroid gland growth. Iodine deficiencies are usually related to geographic areas where the soil and water lack iodine, especially in mountainous and formerly glaciated regions. Approximately 1 billion people live in iodine-deficient regions of the world and are at risk for endemic goiter. Plasma iodide is replenished in part by iodide liberated through deiodination of iodothyronines in peripheral tissues. Ultimately, however, the diet is the most important source. The thyroid requires 75 μg of iodine daily; in North America, the daily dietary intake of iodine ranges between 150 and 300 μg. The use of iodized table salt in North America has markedly reduced the incidence of iodine deficiency goiter. Thus, the impairment of, or interference with, the synthesis of thyroid hormone is the most common cause of goiter in the United States.

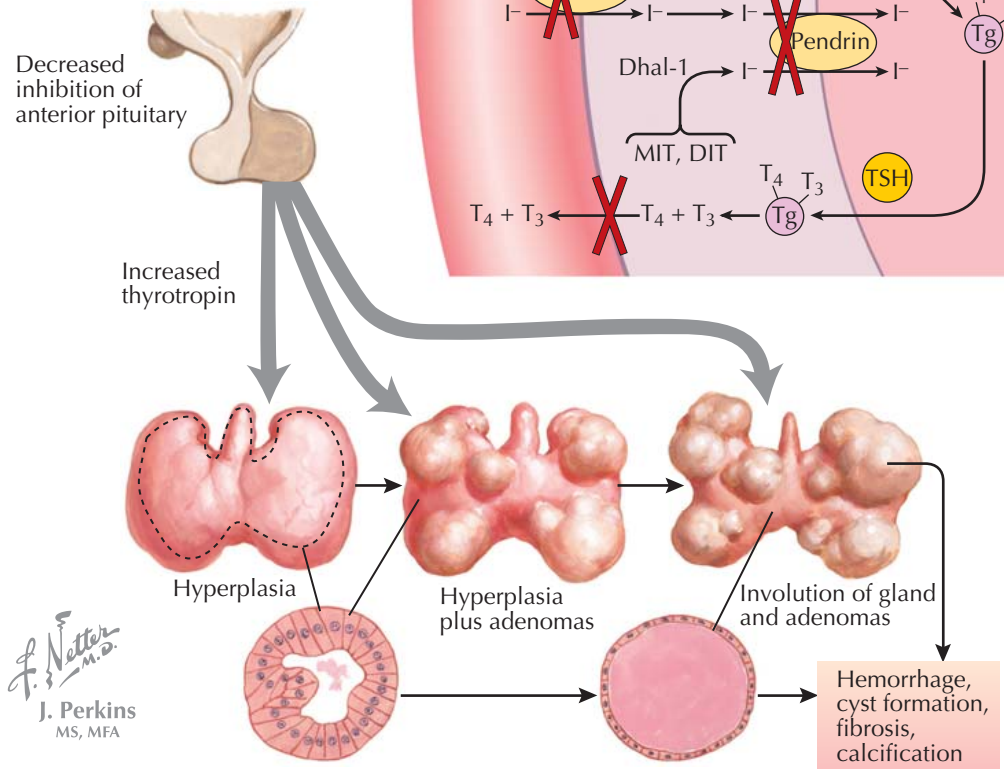
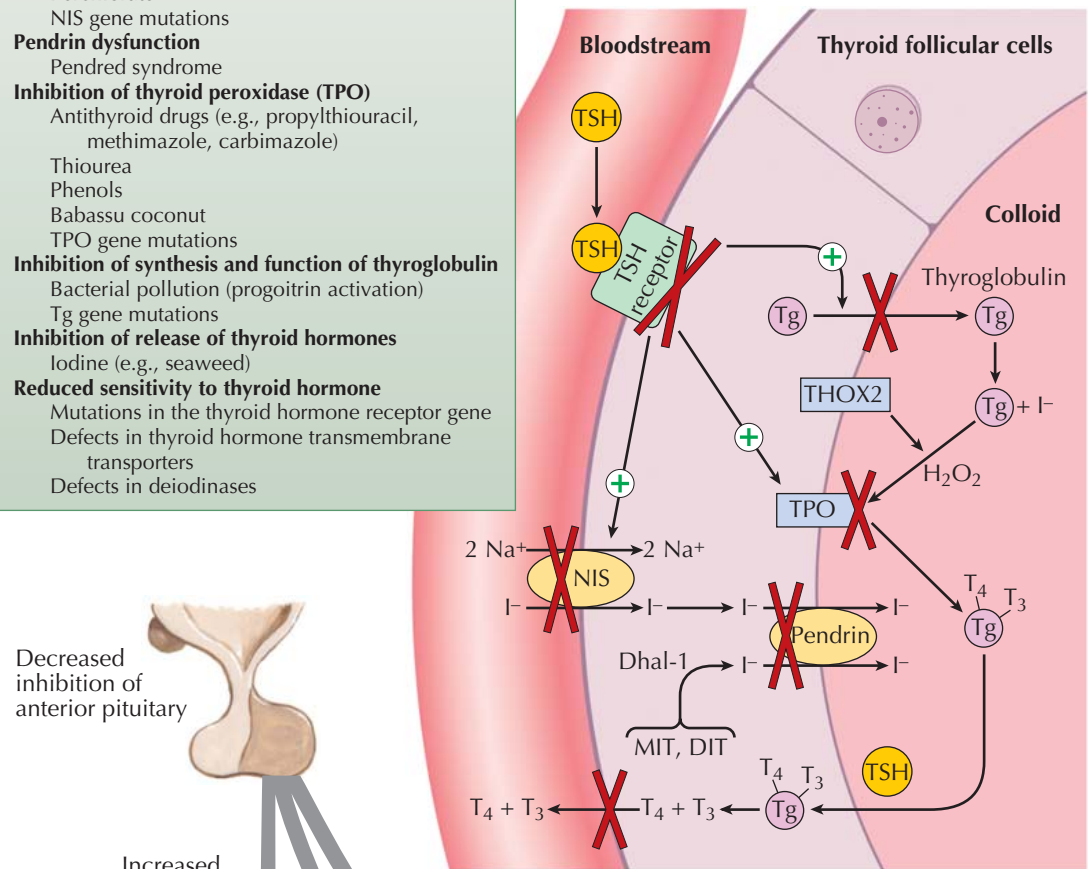
A growing number of clinical entities are recognized in which congenital deficiencies of a step necessary to the intrathyroidal metabolism of iodine or to the synthesis of thyroid hormone explain the congenital hypothyroidism and the development of nontoxic goiters. For example, a number of families that have goiter with congenital hypothyroidism have now been identified in which various mutations in the sodium-iodide symporter (NIS) gene and an iodide transport defect are evident. Mutations in the genes responsible for the synthesis of thyroglobulin (Tg), thyroid peroxidase (TPO), and the TSH receptor may all lead to nontoxic goiters. However, predisposing gene mutations are not found in most patients with nontoxic goiter.

Pendred syndrome is the association of impaired thyroid hormone synthesis and sensorineural hearing loss. Pendrin, the protein critical to iodide transport into the lumen of the thyroid follicular cell, is also required for ion and fluid transport in the cochlear apparatus.

Congenital defects in organification of thyroid hormone lead to goiter. For example, congenital absence of TPO or inadequate production of hydrogen peroxide by thyroid oxidase 2 (THOX2) is goitrogenic.

Patients with reduced sensitivity to thyroid hormone may have mutations in the gene encoding the thyroid

- Etiologic factors of nontoxic goiter**
- Iodine deficiency**
    - Nutritional
  - Thyrotropin (TSH) receptor dysfunction**
    - TSH receptor mutations
  - Block of sodium-iodide symporter (NIS)**
    - Iodine
    - Thiocyanate (e.g., millet, cassava)
    - Perchlorate
    - NIS gene mutations
  - Pendrin dysfunction**
    - Pendred syndrome
  - Inhibition of thyroid peroxidase (TPO)**
    - Antithyroid drugs (e.g., propylthiouracil, methimazole, carbimazole)
    - Thiourea
    - Phenols
    - Babassu coconut
    - TPO gene mutations
  - Inhibition of synthesis and function of thyroglobulin**
    - Bacterial pollution (progoitrin activation)
    - Tg gene mutations
  - Inhibition of release of thyroid hormones**
    - Iodine (e.g., seaweed)
  - Reduced sensitivity to thyroid hormone**
    - Mutations in the thyroid hormone receptor gene
    - Defects in thyroid hormone transmembrane transporters
    - Defects in deiodinases



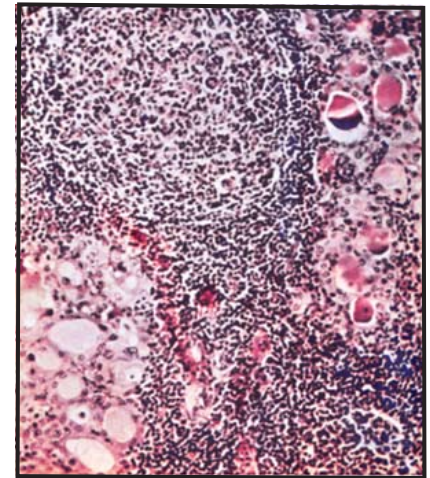
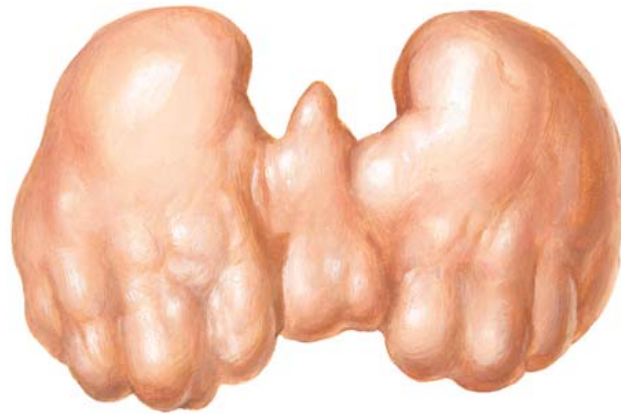*J. Perkins*  
MS, MFA

hormone receptor (thyroid hormone resistance, which is usually caused by mutations in the T<sub>3</sub>-binding domain in the thyroid receptor β gene), or defects in thyroid hormone transmembrane transporters, or deiodinases responsible for intracellular activation of T<sub>4</sub> to T<sub>3</sub>. Patients with thyroid hormone resistance typically present with a nontoxic goiter, are clinically euthyroid, and have serum T<sub>4</sub> to T<sub>3</sub> concentrations above the reference range.

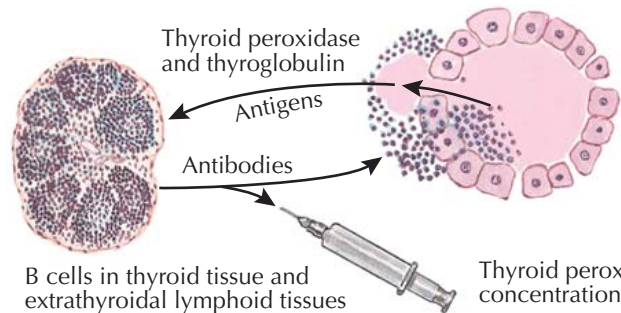
After a prolonged period of thyroid hyperplasia, incompletely encapsulated nodules of various types develop within the hyperplastic thyroid. Finally, after a period of extreme hyperplasia, exhaustion or involution occurs. The epithelium becomes flat; the follicles fill with a viscous colloid; and, eventually, hemorrhagic cysts may occur, some becoming calcified or fibrosed. Rarely, carcinoma may form within such a hyperplastic gland.



**Hashimoto thyroiditis**



**Microscopy of Hashimoto Thyroiditis**  
Mixture of hyperplastic and atrophic follicles with diffuse lymphocytic infiltration



**CHRONIC LYMPHOCYTIC THYROIDITIS AND FIBROUS THYROIDITIS**

**CHRONIC LYMPHOCYTIC (HASHIMOTO) THYROIDITIS**

In iodine-replete regions of the world, Hashimoto thyroiditis is the most common cause of primary hypothyroidism. It is a chronic autoimmune thyroiditis characterized by circulating antibodies to thyroid antigens (thyroid peroxidase and thyroglobulin) and by diffuse lymphocytic infiltration of the thyroid gland. As with other endocrine autoimmune disorders, it is more common in women (8:1 female:male ratio) and has a genetic predisposition. Although thyroid reserve allows for normal thyroid hormone levels for many years, gradual loss of function occurs, and patients eventually progress from subclinical to overt hypothyroidism. Hashimoto thyroiditis becomes clinically evident most commonly between 20 and 40 years of age. On pathology, these thyroid glands demonstrate marked lymphocytic infiltration (both T and B cells), destruction of thyroid follicles, and lymphoid germinal centers.

On physical examination, most affected patients have an asymptomatic, firm, symmetric goiter; the borders are scalloped with pseudopodia, and the surface is bosselated.

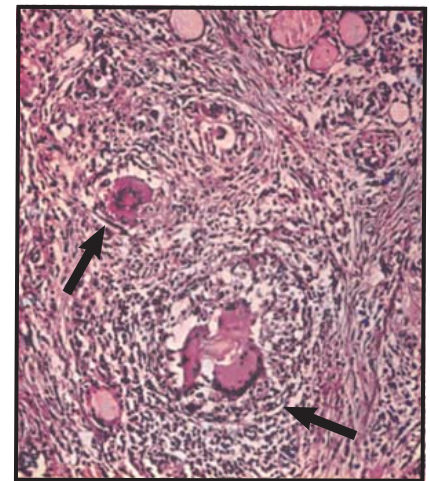
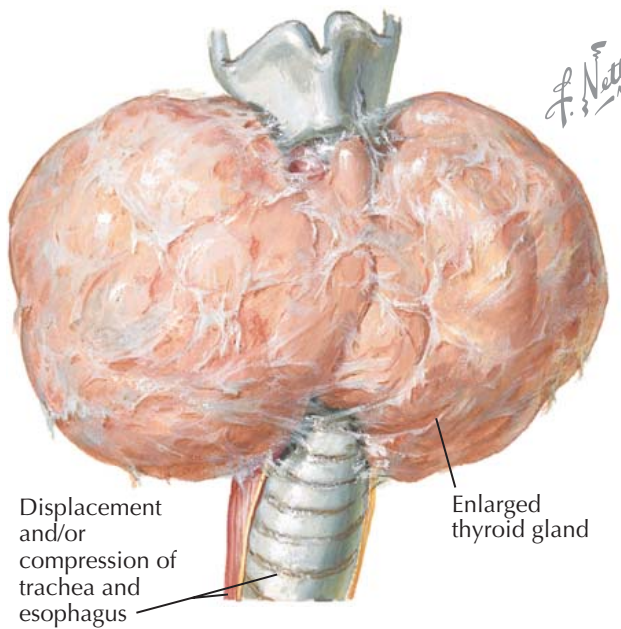
After Hashimoto thyroiditis has been documented with increased serum thyroid peroxidase and thyroglobulin antibodies, and primary hypothyroidism has been documented with an increased serum thyrotropin (thyroid-stimulating hormone [TSH]) concentration, patients with Hashimoto thyroiditis are simply treated with levothyroxine replacement. Thyroid biopsy is usually not needed to confirm the diagnosis of Hashimoto thyroiditis. Surgery is rarely needed except, for example, in patients with symptomatic large goiters.

**FIBROUS (RIEDEL) THYROIDITIS**

Riedel thyroiditis, or fibrous thyroiditis, is rare and occurs predominantly in males. It is a chronic, proliferative, invasive, and fibrosing process involving the thyroid gland. It may extend to displace and/or compress the trachea and esophagus and the overlying fasciae and muscles. Although the cause of Riedel thyroiditis is unknown, it is a primary fibrosing disorder, and some patients may also have retroperitoneal and mediastinal fibrosis.

Microscopically, this disease is characterized by a marked diffuse fibrosis, with macrophage and eosinophilic infiltration of the thyroid gland. A woodlike, hard texture is characteristic. The unaffected portions of the gland reveal varying numbers of persistent acini,

**Riedel thyroiditis**



**Microscopy of Riedel Thyroiditis**  
Macrophage and eosinophilic infiltration with atrophy of follicles (arrows) and marked diffuse fibrosis

which appear to be compressed by the surrounding dense, fibrous stroma.

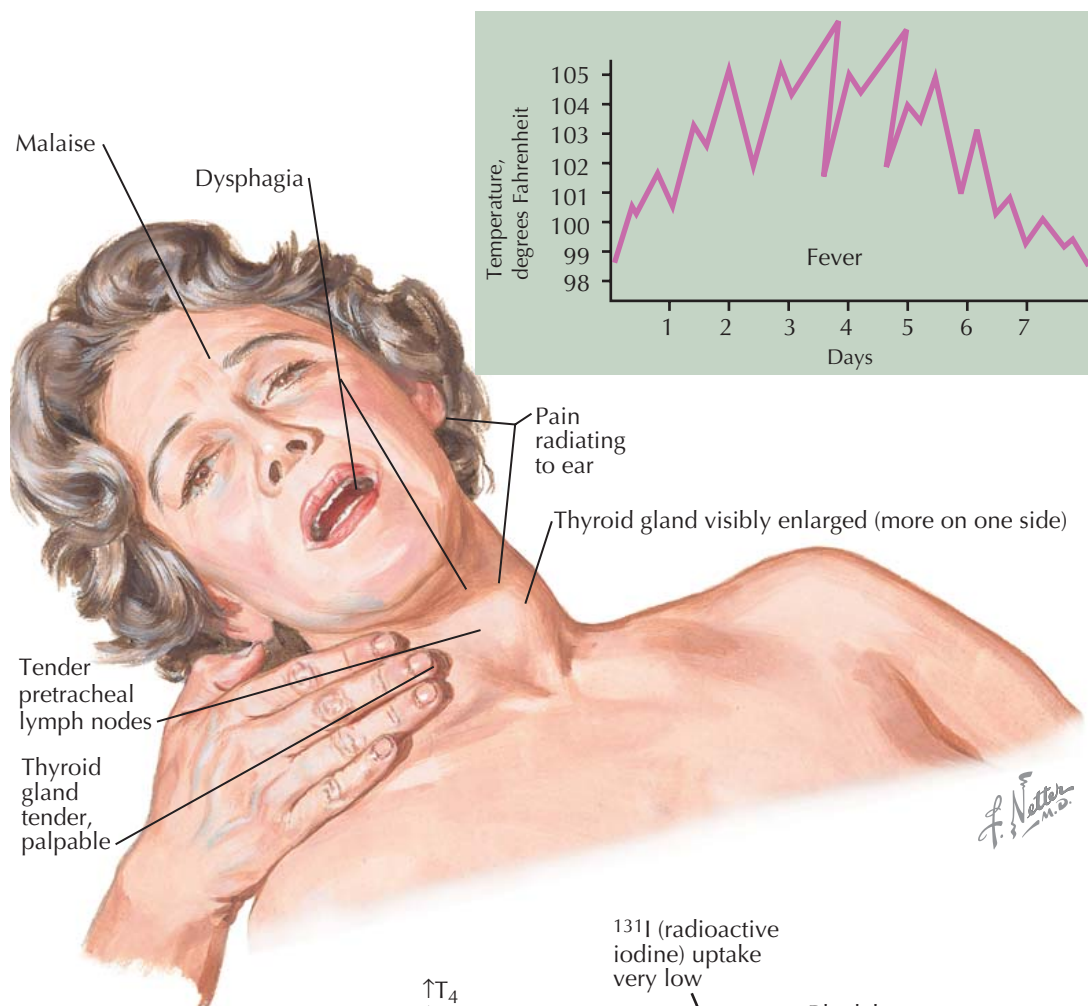
On physical examination, Riedel thyroiditis is characterized by a stony-hard, enlarged thyroid gland, which is firmly adherent to adjacent structures but not to the skin. Often, the gland may be asymmetric, with greater enlargement of one side.

Subjectively, patients with Riedel thyroiditis may describe neck pressure and tightness, dysphagia, and hoarseness. Just as with Hashimoto thyroiditis,

antibodies to thyroid peroxidase and thyroglobulin may be increased. However, frequently these patients are clinically euthyroid, and the serum TSH concentration may be normal. When suspected on physical examination, the diagnosis of Riedel thyroiditis is confirmed by thyroid biopsy.

Treatment with glucocorticoids or tamoxifen may stop the progression or help resolve the advancing fibrotic process. Surgery may be required for advancing symptomatic tracheal compression.





### SUBACUTE THYROIDITIS

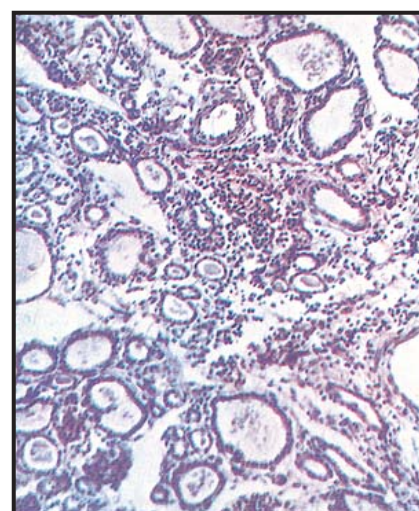
Subacute thyroiditis—also known as subacute granulomatous thyroiditis, acute nonsuppurative thyroiditis, or de Quervain thyroiditis—is characterized by an abrupt onset of hyperthyroid-related symptoms: fever, fatigue, myalgias, and a very tender enlargement of the thyroid gland. It is an uncommon disorder that is five times more frequent in women than in men. The thyroid gland enlargement is usually asymmetric, and it may be 1.5- to 2-fold times its normal size. The thyroid gland pain may be referred to the mandibular joints or to the ears. A marked tenderness in the thyroid, even in lymph nodes near the gland, is evident, and the patient may report dysphagia.

The cause of this disease appears to be related to viral infections; most patients have a recent history of an upper respiratory infection. The insult results in thyroid gland inflammation, follicular damage, and the release of stored thyroxine (T<sub>4</sub>) and triiodothyronine (T<sub>3</sub>), causing symptomatic hyperthyroidism followed by a hypothyroid phase. The hyperthyroidism persists until the thyroid gland stores are exhausted; the typical duration is 2 to 8 weeks. As the thyroid gland inflammation resolves, the thyroid follicles regenerate, and eventually normal thyroid function returns.

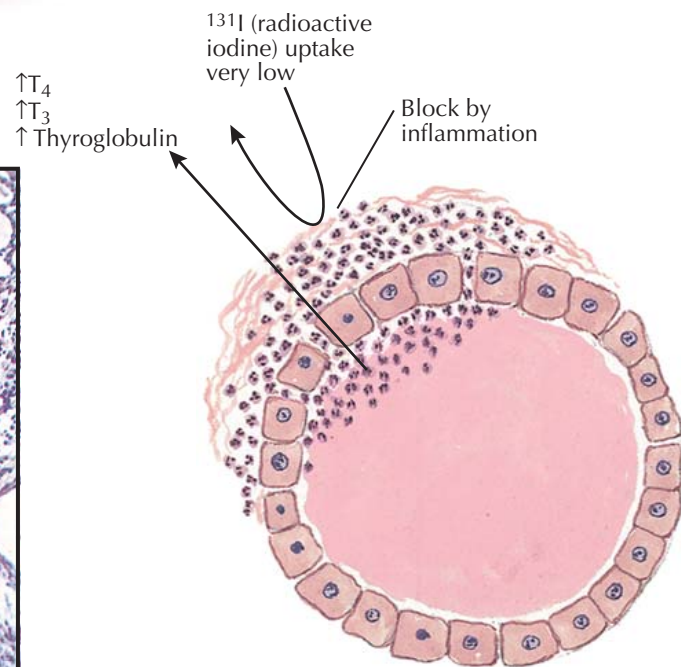
On physical examination, the thyroid gland is symmetrically enlarged and is exquisitely tender to palpation. Some patients refuse to have their neck palpated.

If a thyroid biopsy is performed, an inflammatory reaction is seen with infiltration with lymphocytes and neutrophils. Necrosis of thyroid follicular cells and disruption of thyroid follicles are seen within various parts of the specimen.

Laboratory studies demonstrate increased serum concentrations of free T<sub>4</sub>, total T<sub>3</sub>, and thyroglobulin and low levels of thyrotropin (thyroid-stimulating hormone [TSH]). The erythrocyte sedimentation rate (ESR) is usually greater than 50 mm/h, and leukocytosis may also be present. If a radioactive iodine (<sup>131</sup>I) uptake scan is performed, these inflamed thyroid glands do not concentrate significant amounts of iodine—the 24-hour uptake is usually only 1% to 2%. The



Diffuse infiltration of thyroid stroma



combination of a low <sup>131</sup>I uptake, normal or increased blood T<sub>4</sub> and T<sub>3</sub> concentrations, increased blood thyroglobulin concentration, suppressed TSH, and increased ESR are diagnostic of subacute thyroiditis. Silent and postpartum thyroiditis have similar findings, except that neck pain and an increased ESR are absent.

Treatment should focus on pain control and treatment of hyperthyroid symptomatology. Typically, management includes a 2- to 8-week course of either a

nonsteroidal antiinflammatory drug or glucocorticoids. The hyperthyroid symptoms (e.g., tremor, anxiety, palpitations) can be treated with a β-adrenergic blocker.

After the hyperthyroid phase resolves, the hypothyroid phase may be subclinical, or patients may have hypothyroid symptoms. For symptomatic patients, treatment with levothyroxine may be prescribed for 6 to 8 weeks. Thyroid function eventually returns to normal.



## PAPILLARY THYROID CARCINOMA

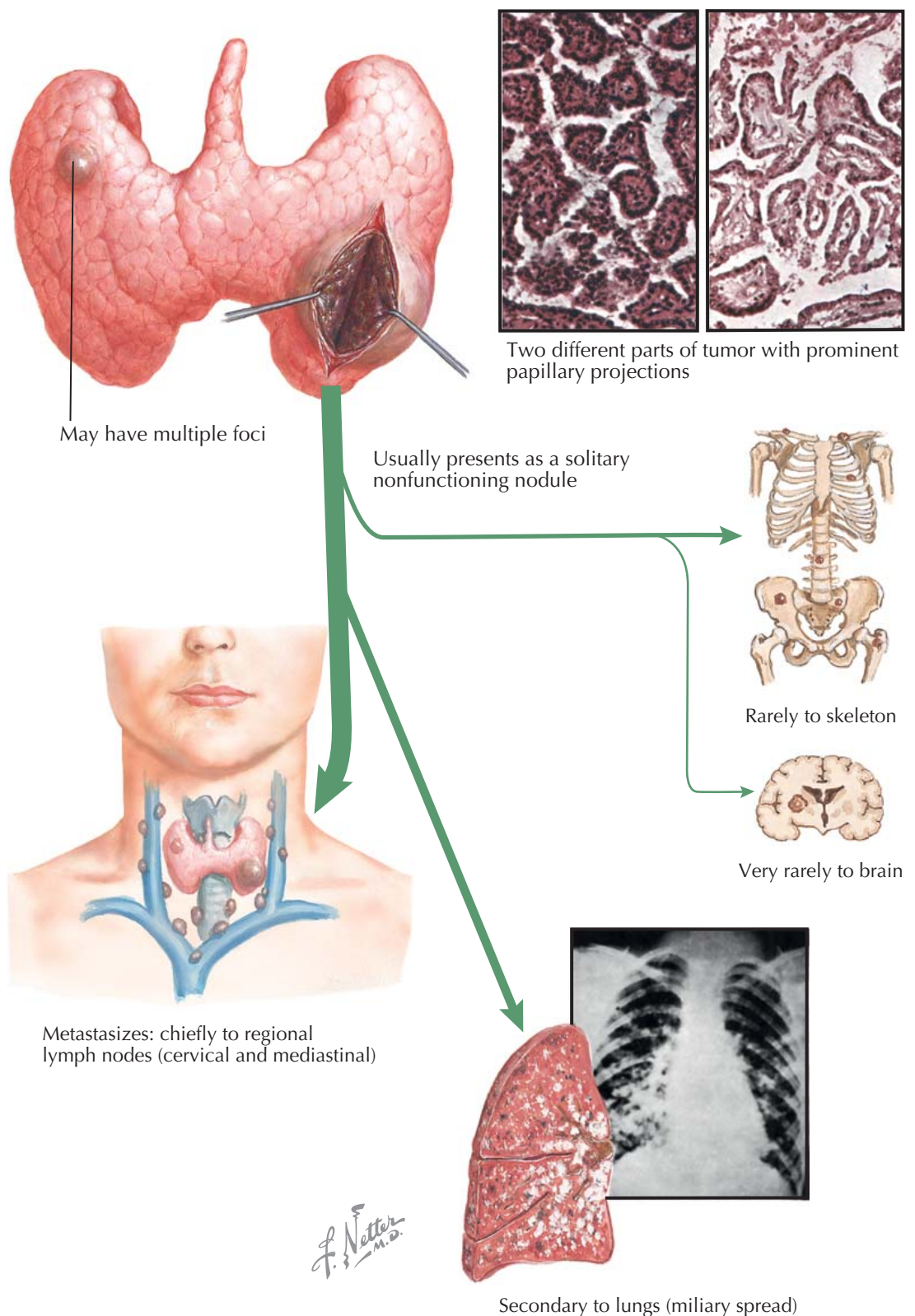
Papillary thyroid carcinoma (PTC) is one of the three thyroid epithelial-derived thyroid cancers (follicular thyroid carcinoma and anaplastic thyroid carcinoma being the other two). PTC is the most common malignant tumor of the thyroid gland, accounting for approximately 75% of cases. PTC incidence is greatest in the fourth and fifth decades of life and is 2.5 times more common in women than in men. PTCs may be very small or may be readily palpable. The most frequent presentation is that of a solitary thyroid nodule. However, with the advent of widespread use of computed tomography (CT) imaging and ultrasonography, such a tumor may also present as an incidentally discovered thyroid nodule.

PTCs frequently have multiple foci within the thyroid gland. It is common to find two or more lesions in the thyroid gland of a patient who presents with a lymph node in the neck, which, on fine-needle aspiration biopsy, proves to be a papillary lesion of thyroid origin. Although some of these sites represent intraglandular metastases, at least half have different clonal origins.

Histologically, PTC is usually unencapsulated and is composed of papillary cords, with a delicately vascularized connective tissue that is lined by one to many layers of cuboidal and columnar cells. Thyroid colloid and follicles are absent from a pure PTC. The nuclei are quite characteristic in their large size and oval shape with hypodense chromatin; they show cytoplasmic "pseudoinclusions" (redundant nuclear membrane). In approximately 50% of PTCs, calcified, scarred remains of tumor papillae (psammoma bodies) are found. Approximately 10% of all PTCs are of the follicular variant type, characterized by the presence of follicles in addition to the characteristic microscopic findings of PTC. Although follicular variant PTC is usually smaller in diameter at the time of diagnosis, the overall prognosis is the same as the prognosis of common PTC. However, the tall-cell variant of PTC (1% of all PTCs) is a more aggressive tumor; they are larger at the time of diagnosis and are more likely to be invasive than the common type of PTC. Other less common PTC variants that are associated with increased aggressive tumor behavior include the clear-cell, insular, columnar, trabecular, oxyphilic, and diffuse sclerosing variants.

PTC metastasizes frequently to the cervical and upper-mediastinal lymph nodes. At the time of initial diagnosis, PTC is found beyond the confines of the neck in only 2% of patients, usually in the lung and less commonly in bone. (Other less common sites of metastatic disease include the brain, liver, kidneys, and adrenal glands.) In the setting of metastatic disease to the lungs, chest radiography or chest CT typically shows miliary nodules fanning out from the hilum. Skeletal metastases occur infrequently. When the bones are involved, the patient is usually older.

PTC is one of the least aggressive and least malignant of the cancers occurring in the human body; most patients with PTC do not die of this tumor. However, it is capable of causing death. The three factors most associated with higher risk for PTC recurrence and cancer-related mortality are the following: patient older than 45 years at the time of diagnosis, larger tumors (>7 cm in diameter), and soft-tissue invasion (e.g., trachea, esophagus). Additional factors that increase the risk of recurrent disease include male gender, multicentric thyroidal PTC, large number of lymph node metastases (>10), and age younger than 7 years.



For PTCs larger than 1 cm in diameter or for PTCs with known lymph node metastases, total thyroidectomy with central compartment lymphadenectomy is the treatment of choice. More extensive surgery is indicated for patients with invasion of other neck tissues (e.g., trachea, esophagus), but less aggressive surgery (e.g., lobectomy and isthmusectomy) may be considered in patients with solitary PTCs smaller than 1 cm in diameter. Radioactive iodine  $^{131}\text{I}$  treatment serves as an adjuvant therapy for PTC, but it is not universally administered and should be considered

individually. External-beam radiotherapy may be considered in patients who have metastatic disease that cannot be resected and that is refractory to  $^{131}\text{I}$  therapy. Systemic chemotherapy may be beneficial in patients with aggressive and symptomatic PTC that is refractory to all other treatment options. Molecular pathway-blocking drugs (e.g., tyrosine kinase inhibitors) are under investigation for patients with refractory disease. All patients should be treated with levothyroxine after surgery to prevent pituitary thyrotropin secretion from stimulating PTC growth.

## FOLLICULAR THYROID CARCINOMA

Follicular thyroid carcinoma (FTC) is one of the three thyroid epithelial-derived thyroid cancers (papillary thyroid carcinoma [PTC] and anaplastic thyroid carcinoma being the other two). After PTC, FTC is the second most common type of thyroid cancer, accounting for 10% of cases. Compared with PTC, FTC occurs more commonly in older persons; the peak incidence is between 40 and 60 years of age and is threefold more common in women than in men. FTC is more common in iodine-deficient regions of the world.

FTC may present as a small nodule or as a large mass within the thyroid. Unlike PTC, FTC usually has a solitary intrathyroidal focus. Cytologic examination of a thyroid fine-needle aspiration biopsy specimen cannot be used to distinguish between FTC and a benign follicular adenoma. FTC can be diagnosed only on the basis of en bloc thyroid tissue removed at surgery and documentation of tumor capsule or vascular invasion.

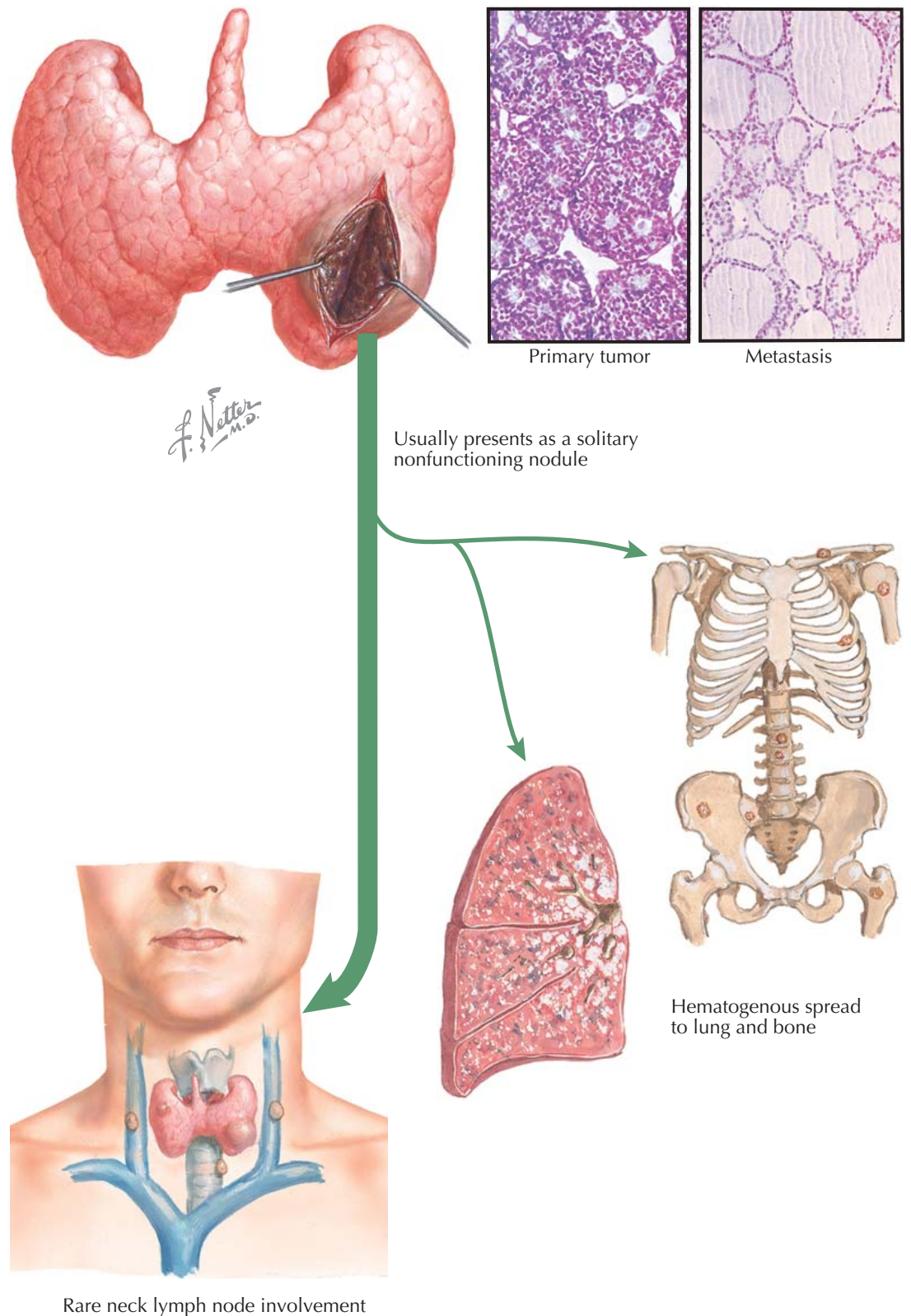
Histologically, FTC shows a fairly well-organized follicular pattern, with small but frequently irregular follicles lined by high cuboidal epithelium. The follicles with a more orderly arrangement commonly contain colloid. Findings consistent with PTC (e.g., psammoma bodies) are absent. Although tumor extension through the capsule or vascular invasion is usually present in patients with FTC, minimally invasive FTC is a subtype that is encapsulated and is associated with a good prognosis. Widely invasive FTC, however, extends into blood vessels and adjacent thyroid tissue and is associated with a poor prognosis.

Most FTCs appear to be monoclonal, and approximately 40% are associated with somatic point mutations in the *RAS* oncogenes, a finding associated with a more aggressive tumor.

FTC frequently metastasizes early via hematogenous dissemination; distant metastases are evident at the time of primary tumor detection in 15% of patients with FTC. The most common sites of metastatic disease are bone and lung (less common sites of involvement include the liver, brain, urinary bladder, and skin). Neck lymph node involvement is much less common in FTC than in PTC. Skeletal metastases, when biopsied, may look like normal thyroid tissue.

FTC tends to have a more aggressive clinical course than PTC. A worse prognosis is associated with larger tumor size, distant metastasis, and vascular invasion. Insular carcinoma is a poorly differentiated form of FTC that is associated with a poor prognosis. Hürthle cell carcinoma is an oncocyctic variant of FTC (see Plate 2-26).

The treatment of patients with FTC is similar to that for those with PTC. Total thyroidectomy with central



compartment lymph node dissection is the treatment of choice. Preoperative neck ultrasonography with lymph node mapping is essential in planning a successful operation. FTC cells are able to retain radioactive iodine 131 ( $^{131}\text{I}$ ) but not as well as normal thyroid follicular cells. Iodine 131 may be administered after surgery to destroy thyroid remnant tissue in the thyroid bed and microscopic metastatic disease. After treatment, levothyroxine replacement therapy is initiated to suppress

pituitary thyrotropin, with the intent to prevent thyrotropin-driven growth of any residual FTC cells. External-beam radiation therapy may be used when primary or metastatic disease cannot be resected. Systemic chemotherapy may be needed in the small subset of patients whose disease is refractory to all other treatment options. In addition, molecular pathway-blocking drugs (e.g., tyrosine kinase inhibitors) may be beneficial in patients with refractory disease.



## MEDULLARY THYROID CARCINOMA

Medullary thyroid carcinoma (MTC) is a neoplasm of the thyroid parafollicular or “C cells.” Approximately 3% of all thyroid malignancies prove to be MTC. The C cells are located in the upper portion of each thyroid lobe and originate from the embryonic neural crest; thus, from the clinical and histologic perspectives, MTC is more of a neuroendocrine tumor than a thyroid neoplasm.

In approximately 80% of patients, MTC is sporadic, but it may be familial either as part of multiple endocrine neoplasia type 2 (MEN 2) syndrome or familial MTC (FMTC). Sporadic MTC typically presents as a solitary thyroid nodule at age 40 to 60 years, with a slight female preponderance. MTC is easily diagnosed by fine-needle aspiration biopsy of a thyroid nodule. At the time of diagnosis, more than half of patients with sporadic MTC have metastatic disease, typically involving regional lymph nodes.

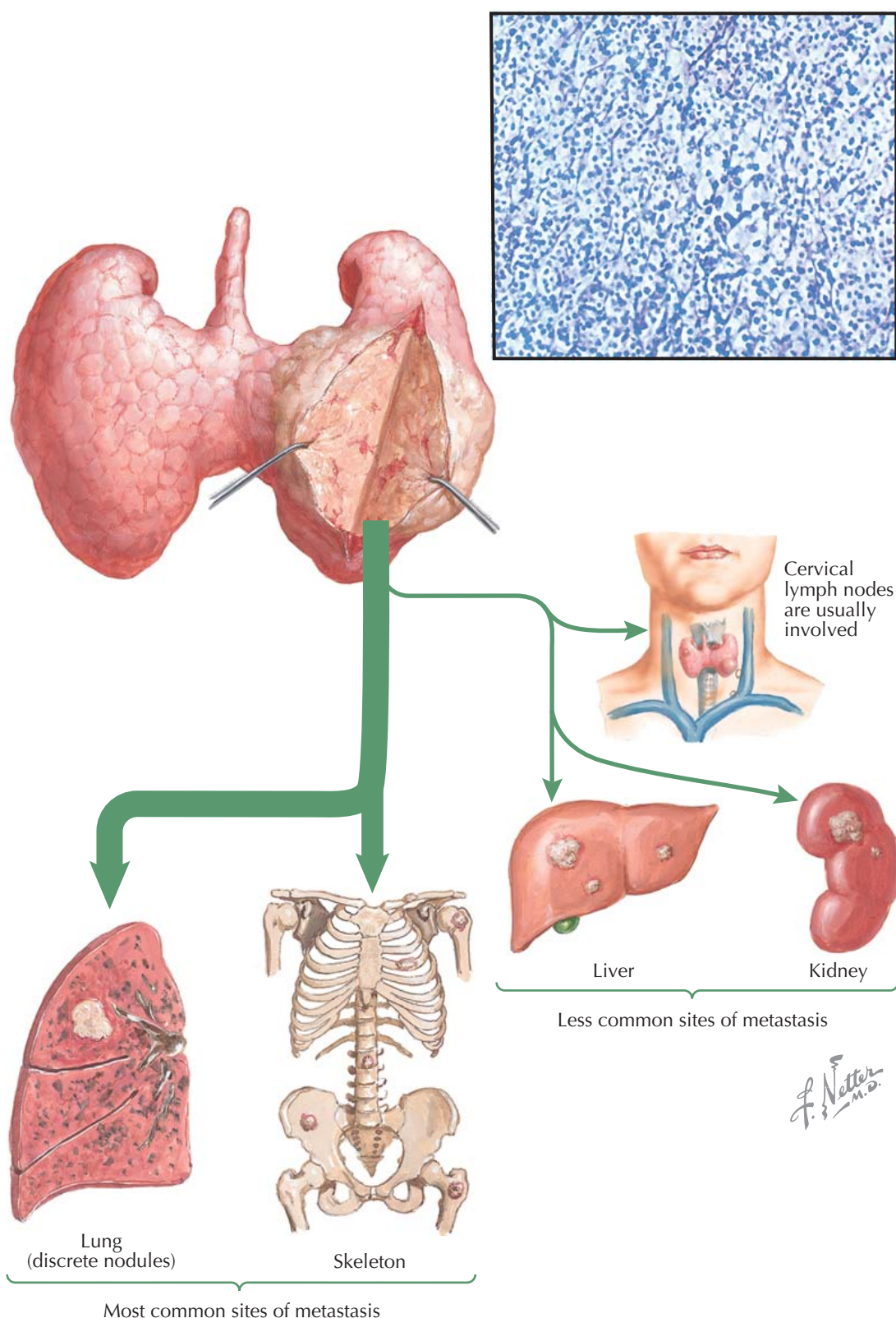
MTC secretes the hormone calcitonin. Markedly elevated levels of calcitonin may be found in patients with MTC and may result in severe diarrhea. Also, because of its neuroendocrine embryology, MTC has the potential to secrete other hormones that may cause additional clinical symptomatology. For example, MTC may hypersecrete corticotropin and cause Cushing syndrome.

On histology, MTC shows a solid trabecular pattern with closely packed cells, with considerable variation in hyperchromatism and the size of the nuclei. The cells usually immunostain for calcitonin, galectin-3, and carcinoembryonic antigen.

Inherited MTC is associated with mutations in the *RET* proto-oncogene and presents as MEN 2A, MEN 2B, or FMTC. The penetrance of MTC in patients with MEN 2 is 100%. Men and women are affected with equal frequency. Patients with MEN 2B have a more aggressive form of MTC, and they should have prophylactic thyroidectomy in the first year of life. Patients with inherited MTC that is not recognized earlier in life typically present between the ages of 20 and 30 years. However, when the risk of familial MTC is known, MTC can be diagnosed before it is palpable or clinically evident. After the specific *RET* proto-oncogene mutation has been identified in the proband, at-risk family members can have genetic testing for the specific mutation to determine their risk for MTC.

Even patients with apparently sporadic MTC should have genetic testing for mutations in the *RET* proto-oncogene because approximately 7% have a mutation. This finding can facilitate genetic testing of at-risk family members to identify individuals with MTC and treat them surgically before metastases develop.

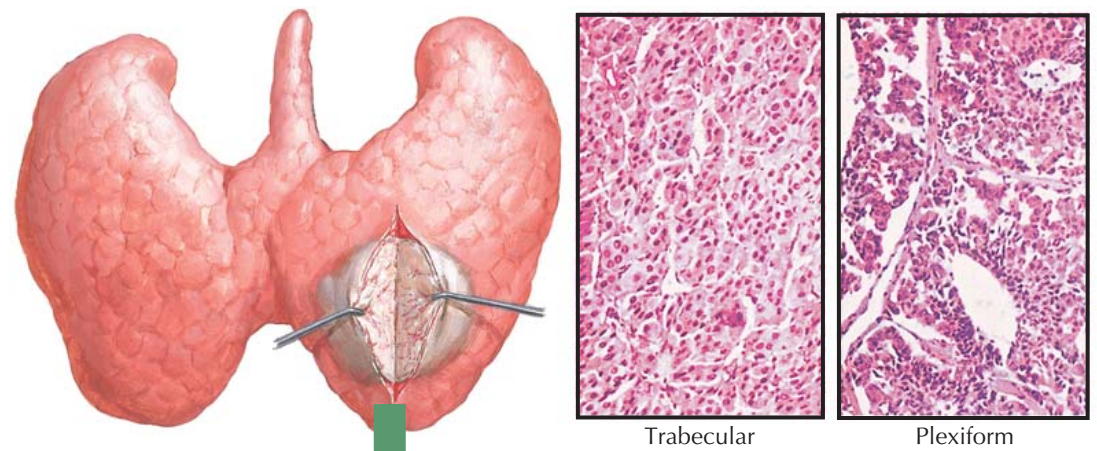
All patients with MTC should have biochemical testing to exclude primary hyperparathyroidism and pheochromocytoma (components of MEN 2). Serum calcitonin concentration should be measured preoperatively in all patients with MTC. The higher the serum calcitonin concentration, the more likely it is that the



patient has metastatic disease and will not be cured with thyroidectomy.

The treatment of choice is total thyroidectomy. Prognosis is determined in part by the age at the time of diagnosis (the older the patient, the poorer the prognosis). For patients with familial disease, the prognosis is determined by the age at which thyroidectomy is performed; cure rates are higher when thyroidectomy

is performed at a younger age. Serum calcitonin concentration should be measured postoperatively to determine if a surgical cure has been achieved. Metastatic disease may involve the neck, mediastinum, lungs, liver, bone, and kidneys. Persistent metastatic disease that cannot be surgically resected may be treated with molecular pathway-blocking drugs (e.g., tyrosine kinase inhibitors).



Trabecular

Plexiform

### HÜRTHLE CELL THYROID CARCINOMA

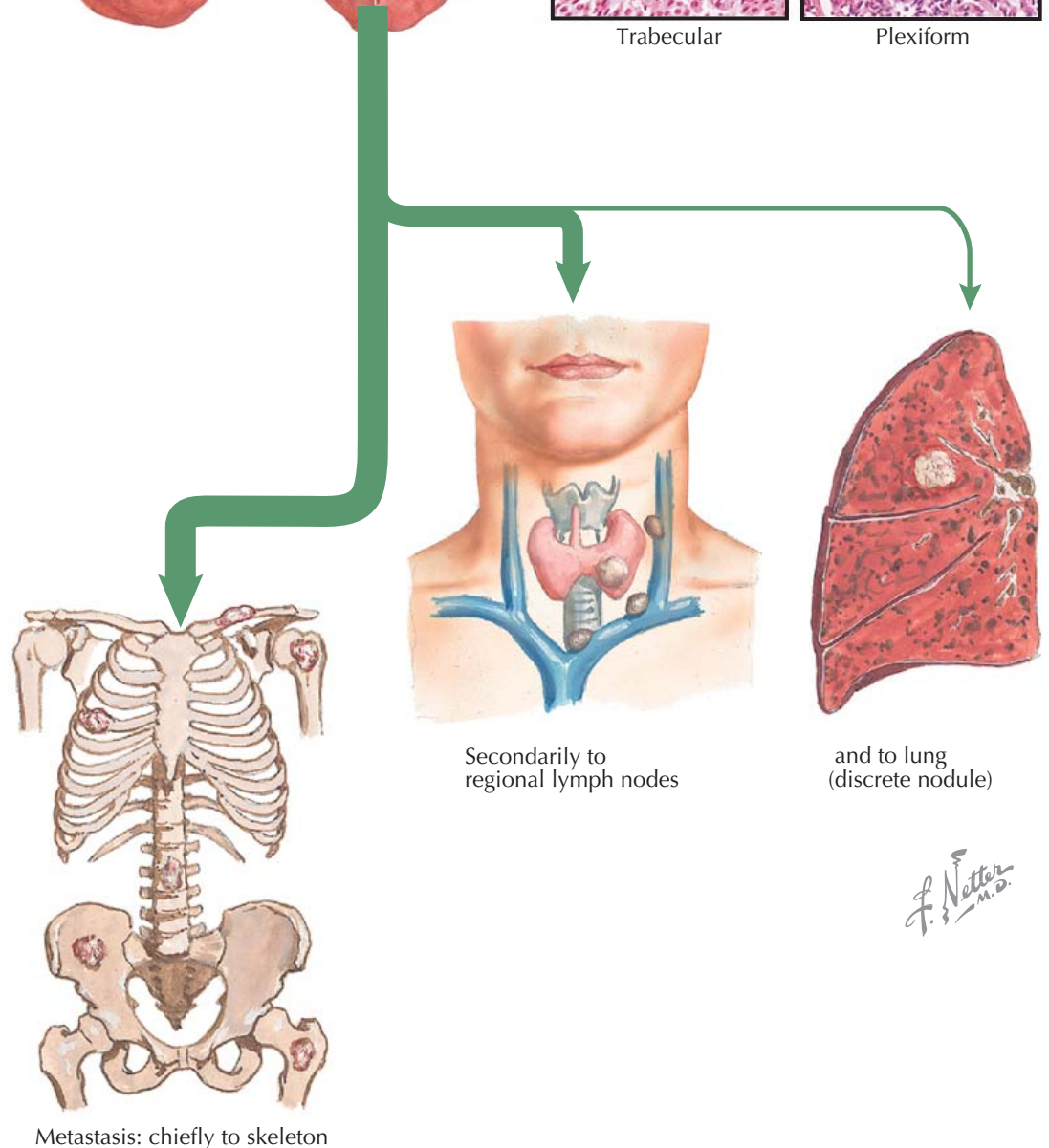
Hürthle cell carcinoma (HCC) is a variant of follicular thyroid carcinoma and represents 3% to 4% of all thyroid malignancies. HCC is also referred to as an “oncocytic variant of follicular thyroid cancer.” HCC is distinctive because of a cell population of oncocytes that form at least 75% of the neoplasm. Eosinophilic oxyphilic cells are distinguished by their abundant cytoplasm, oval nuclei with prominent nucleoli, and closely packed mitochondria. Compared with common-type follicular thyroid carcinoma, HCC is associated with a poorer prognosis, and it has an increased recurrence rate in local lymph nodes. Peak age range at the time of diagnosis is 40 to 70 years (median age, 61 years). HCC is twofold more common in women than in men.

HCC typically presents as a painless single nodule; it may be barely palpable, or it may be large enough to involve an entire lobe of the thyroid.

Gross pathology usually shows a mahogany brown tumor. Histologically, HCC is characterized by the appearance of bright, opaque, eosinophilic, and granular cells that are high cuboidal to low columnar and that may occur in an orderly trabecular arrangement, with each column being separated by a rich, thin-walled capillary blood supply, or they may be stratified in plexiform groups, which are also separated by the capillaries of the rich blood supply. Colloid is scant or absent. The nuclei are hyperchromatic and pleomorphic with prominent eosinophilic nucleoli. Ultrastructurally, HCC cells are filled with mitochondria. The diagnosis of carcinoma rests on the demonstration of capsular invasion, vascular invasion, or metastatic spread.

About 5% of patients with HCC have distant metastases to lung or bone at the time of diagnosis. Regional lymph node metastases are evident in approximately 25% of cases. Fewer than 10% of HCCs take up radioiodine.

The prognosis for patients with HCC can be predicted on the basis of the presence of distant metastases at presentation, increasing patient age, large primary tumor size, gender, and local extrathyroidal invasion. In



Metastasis: chiefly to skeleton

Secondarily to regional lymph nodes

and to lung (discrete nodule)

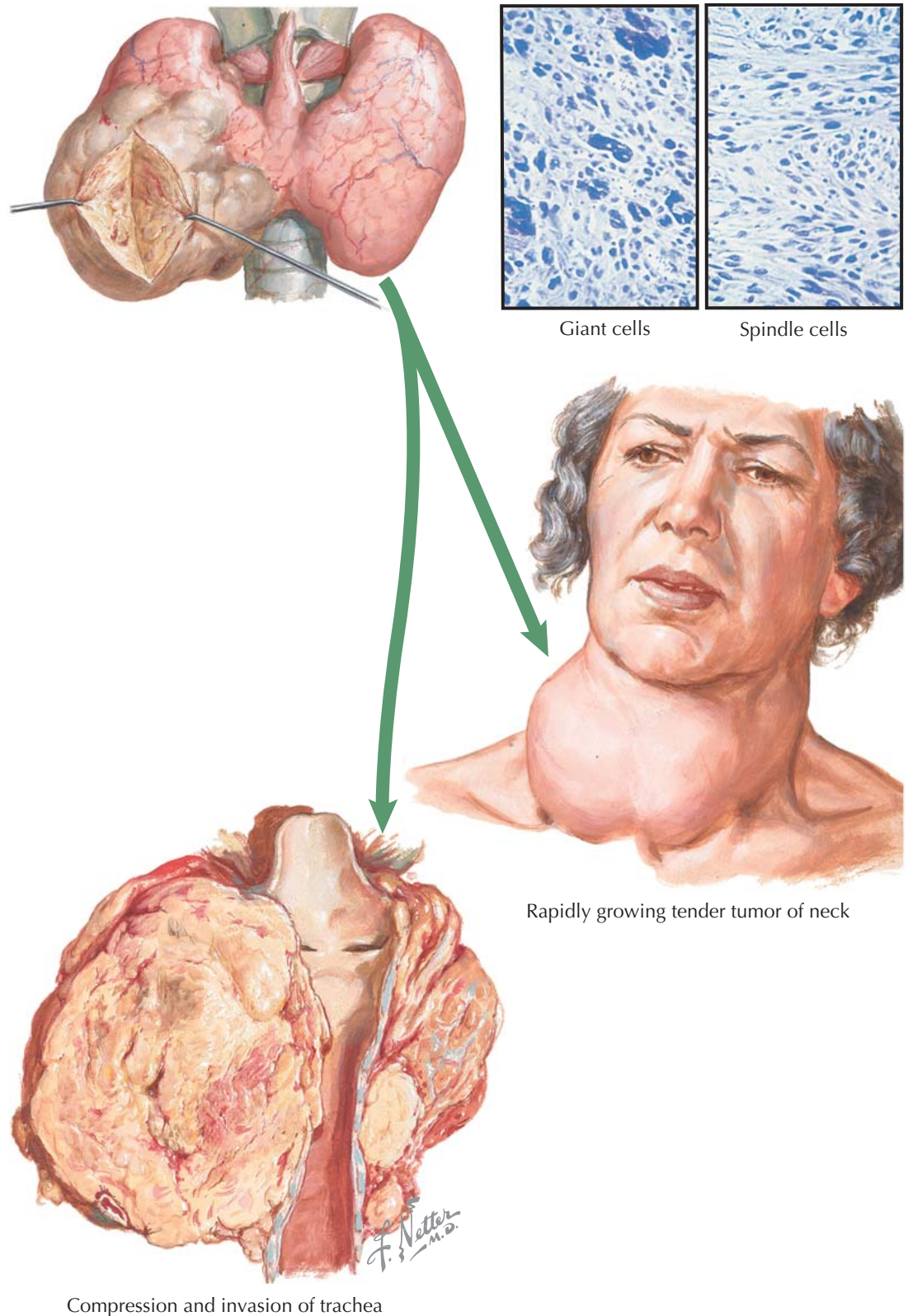
*F. Netter M.D.*

general, HCC is a more aggressive cancer than papillary or follicular thyroid cancers. The recurrence rate after surgery is approximately 35%. The presence of distant metastases is the strongest predictor of poor outcome. In addition, HCC is more aggressive in men than in women.

The treatment of patients with HCC is identical to that of patients with follicular thyroid carcinoma. Total

thyroidectomy with ipsilateral central neck lymph node dissection is the most common treatment approach. Treatment with radioiodine does not appear to improve outcomes in patients with HCC. External-beam radiotherapy may be considered in patients with unresectable HCC. In addition, molecular pathway-blocking drugs (e.g., tyrosine kinase inhibitors) may be beneficial in some patients with refractory disease.





## ANAPLASTIC THYROID CARCINOMA

Anaplastic thyroid carcinoma (ATC) is one of three thyroid epithelial-derived thyroid cancers (papillary thyroid carcinoma [PTC] and follicular thyroid carcinoma [FTC] being the other two). Whereas PTC and FTC are considered differentiated thyroid cancers, ATC is an undifferentiated thyroid cancer. ATC is one of the most malignant and deadly of all carcinomas occurring in humans and accounts for approximately 2% of all thyroid cancers. It usually occurs after age 50 years (mean age, 65 years), and approximately two-thirds of ATCs occur in women.

ATC develops as a rapidly growing, tender tumor of the neck, and it never shows any sign of hormonal function. The patient can often give the exact date of onset (usually a very recent one) and describes rapid growth causing pressure symptoms, dyspnea, dysphagia, hoarseness, cough, and even tenderness or pain in the mass. Systemic symptoms of weight loss, anorexia, fatigue, and fever may also be present. Examination of the nodule reveals a large (frequently larger than 5 cm in diameter), hard mass, which may be fixed. It is usually tender. Heat and even redness in the skin over the nodule may be present. Cervical adenopathy is frequently present. The trachea may be deviated, and the patient may have vocal cord paralysis. In addition, superior vena cava syndrome may be evident in patients whose tumor occupies most of the thoracic inlet.

Approximately 20% of patients with ATC have a history of differentiated thyroid carcinoma (either PTC or FTC), and approximately 50% have a history of goiter. Thus, it appears that ATC arises from differentiated thyroid neoplasms, probably caused by a dedifferentiating step (e.g., loss of a tumor suppressor protein or an acquired activating mutation).

The diagnosis of ATC can be confirmed on fine-needle aspiration biopsy or surgical biopsy. Histologically, this tumor is a solid, highly anaplastic growth, with spindle cells predominating but with many large giant cells occurring throughout the tumor.

This cancer, which is so highly malignant, seldom metastasizes widely. Its rapid growth is local and invasive into the surrounding neck structures (e.g., muscle, lymph nodes, larynx, trachea, esophagus, and great vessels of the neck), usually causing death by direct invasion of the trachea, resulting in compression and asphyxiation. The lungs are the most frequent site of

distant spread. ATC may also metastasize to bone, skin over the chest wall, liver, heart, kidneys, and adrenal glands.

Computed tomography imaging of the neck and chest is helpful in planning therapy and monitoring the response to treatment interventions. Survival is longer for ATCs that are smaller than 6 cm in diameter and that are confined to the thyroid gland.

ATC is almost never curable by surgery; if disease appears localized to the thyroid gland, complete

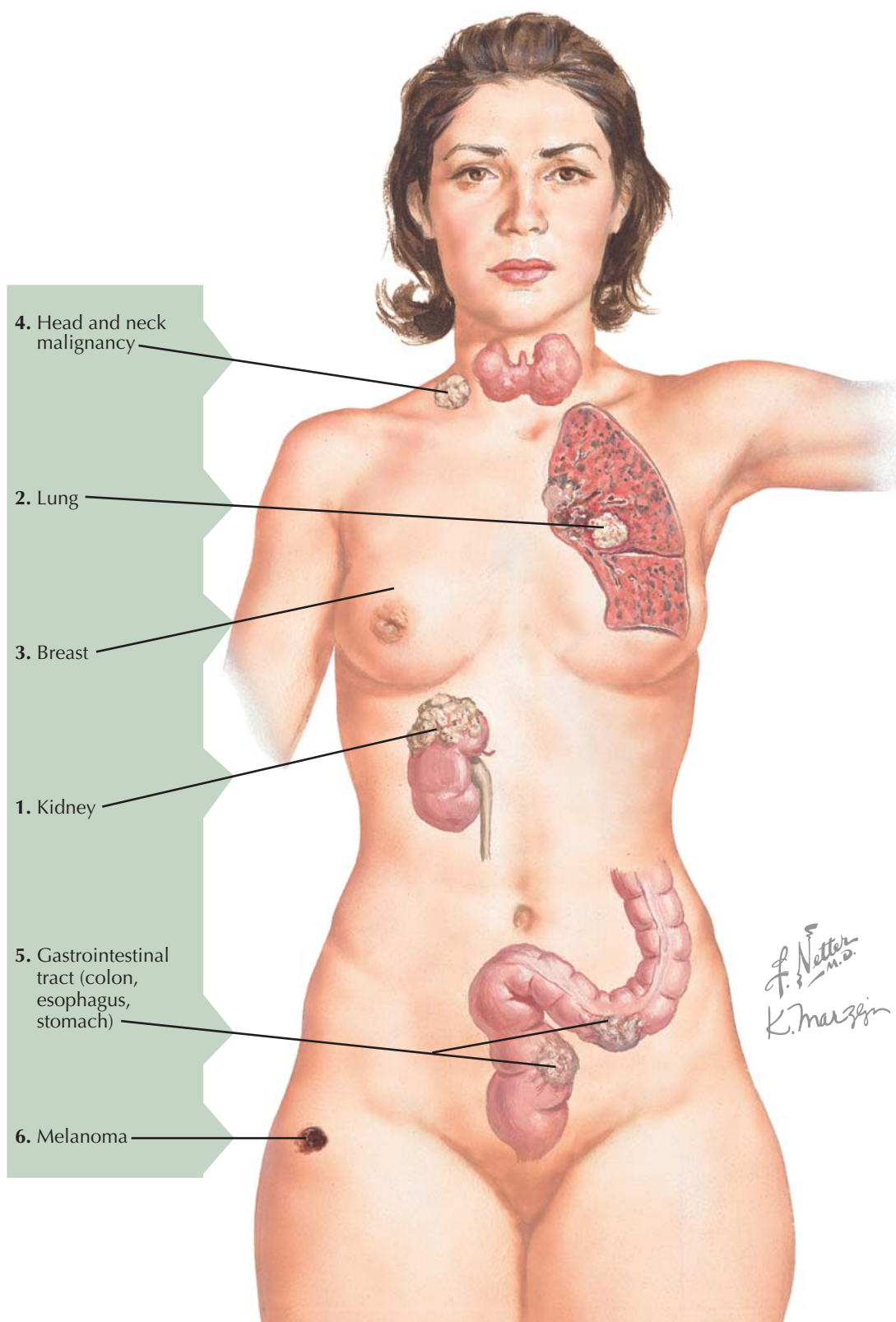
resection should be attempted. However, ATC usually recurs within months after surgical removal even though the lesion appeared at operation to have been completely eradicated. Adjuvant external-beam radiotherapy after surgery may be considered. There is no curative therapy for metastatic ATC. Chemotherapy with agents such as paclitaxel may provide temporary responses. Survival more than 12 months after the diagnosis is extremely uncommon. The disease-specific mortality rate is essentially 100%.

## TUMORS METASTATIC TO THE THYROID

Metastatic disease to the thyroid is common; it likely relates to its rich blood supply of approximately 560 mL/100 g tissue/min (a flow rate per gram of tissue that is second only to the adrenal glands). The prevalence of metastases to the thyroid gland in autopsy series varies from 1.25% in unselected autopsy studies to 24% in those that died with widespread malignant neoplasms. When preoperative fine-needle aspiration (FNA) biopsies are performed, the frequency of clinically important metastases to the thyroid gland is approximately 5%. In a patient with a thyroid nodule and a history of cancer, metastatic disease should be the prime consideration.

Although patients with metastatic disease to the thyroid may present with mass-effect symptoms (e.g., hoarseness, dysphagia, stridor, or neck mass), most have asymptomatic disease, and the thyroid nodule is found on physical examination or it is an incidental finding on radiologic imaging (e.g., positron emission tomography) obtained for tumor staging. The diagnostic procedure of choice in these patients is thyroid FNA biopsy, a highly sensitive and specific procedure.

The most common organ locations for the primary malignancy (in order of frequency) are the kidney (clear cell), lung, breast, head and neck, gastrointestinal tract (colon, esophagus, stomach), and skin (melanoma). Other organ locations and cell types that have been



reported to metastasize to the thyroid include the uterus, ovary, prostate, pancreas, parathyroid, and sarcoma. Most metastases to the thyroid present within 3 years of the primary tumor resection, although intervals as long as 26 years (in a patient with renal cell carcinoma) have been reported.

The metastatic site in the thyroid may be the only apparent location of metastatic involvement. Although there is no consensus on the role for surgery in these patients, most endocrinologists and endocrine surgeons

recommend thyroid lobectomy. If the metastasis is large or if it involves both lobes, a near-total thyroidectomy may be needed. Although it is usually a palliative procedure, aggressive surgical treatment of thyroid metastases in the patients with isolated metastatic renal cell carcinoma have been curative. Radiotherapy may be considered for treatment of metastases that cannot be completely resected. Systemic chemotherapy may be indicated when there are multiple other sites of metastatic disease.

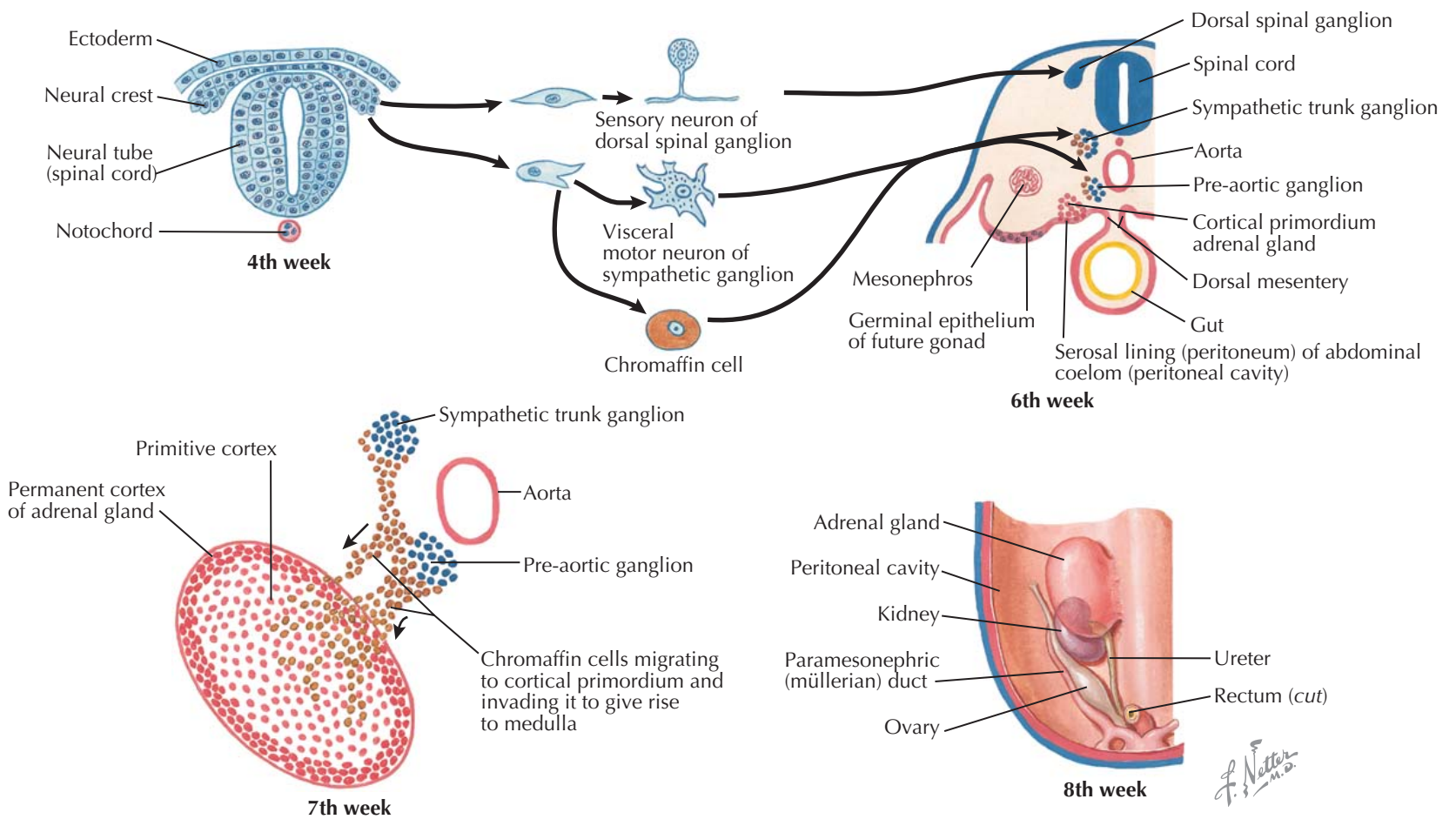


This page intentionally left blank

# ADRENAL



This page intentionally left blank



## DEVELOPMENT OF THE ADRENAL GLANDS

The detailed anatomy of the adrenal glands was first described by Bartholomeo Eustacius in 1563. Each adrenal gland consists of two parts—the cortex and medulla—that are enveloped in a common capsule. The cortex is derived from mesenchymal tissue and the medulla from ectodermal tissue. From the fifth to sixth week of embryogenesis, the cortical portion of each adrenal gland begins as a proliferation of cells, which originate from the coelomic cavity lining adjacent to the urogenital ridge. The cells proliferate rapidly and penetrate the retroperitoneal mesenchyme to form the primitive cortex. The primitive cortex soon becomes enveloped by a thin layer of more compactly arranged cells that become the permanent cortex, the cells being derived from the same source as those of the primitive cortex. By the eighth week, the cortical tissue has an intimate relationship with the cranial pole of the kidney. Toward the end of the eighth week, the cortical mass attains a considerable size, separates from its peritoneal mesothelial cell layer of origin, and becomes invested in the capsule of connective tissue. At this time, the developing adrenal gland is much larger than the developing kidney.

The primitive, or fetal, cortex constitutes the chief bulk of the adrenal glands at birth. By the second week

after birth, the adrenal glands lose one-third of their weight; this is a result of the degeneration of the bulky primitive cortex, which disappears by the end of the first year of life. The outer permanent cortex, which is thin at birth, begins to differentiate as the inner primitive cortex undergoes involution. However, full differentiation of the permanent cortex into the three zones of the adult gland (glomerulosa, fasciculata, and reticularis) is not completed until about the third year after birth. The differentiation of the adrenal cortex is dependent on the temporal expression of transcription factors (e.g., steroidogenic factor 1, zona glomerulosa-specific protein, and inner zone antigen).

Certain ectodermal cells arise from the neural crest and migrate from their source of origin to differentiate into sympathetic neurons of the autonomic nervous system. However, not all of the cells of the primitive autonomic ganglia differentiate into neurons. Some become endocrine cells, designated as chromaffin cells because they stain brown with chromium salts. Cytoplasmic granules turn dark when stained with chromic acid because of the oxidation of epinephrine and norepinephrine to melanin. Certain chromaffin cells migrate from the primitive autonomic ganglia adjacent to the developing cortex to give rise eventually to the medulla of the adrenal glands. When the cortex of the adrenal gland has become a prominent structure (during the seventh week of embryogenesis), masses of these migrating chromaffin cells come into contact with the

cortex and begin to invade it on its medial side. By the middle of fetal life, some of the chromaffin cells have migrated to the central position within the cortex. Some chromaffin cells also migrate to form paraganglia, collections of chromaffin cells on both sides of the aorta. The largest cluster of chromaffin cells outside the adrenal medulla is near the level of the inferior mesenteric artery and is referred to as the *organ of Zuckerkanndl*, which is quite prominent in fetuses and is a major source of catecholamines in the first year of life.

True accessory adrenal glands, consisting of both cortex and medulla, are rarely found in adults. When they are present, they may be within the celiac plexus or embedded in the cortex of the kidney. Adrenal rests, composed of only cortical tissue, occur frequently and are usually located near the adrenal glands. In adults, accessory separate cortical or medullary tissue may be present in the spleen, in the retroperitoneal area below the kidneys, along the aorta, or in the pelvis. Because the adrenal glands are situated close to the gonads during their early development, accessory tissue may also be present in the spermatic cord, attached to the testis in the scrotum, attached to the ovary, or in the broad ligament of the uterus. Although one adrenal gland may be absent occasionally, complete absence of the adrenal glands is extremely rare.



## ANATOMY AND BLOOD SUPPLY OF THE ADRENAL GLANDS

The adrenal glands are two small triangular structures located retroperitoneally at the upper poles of the kidneys. They are found on the posterior parietal wall, on each side of the vertebral column, at the level of the 11th thoracic rib and lateral to the first lumbar vertebra. The typical weight of each adrenal gland is 3.5 to 6.0 g. The surface of the gland is corrugated or nodular to a variable extent. Each gland measures 2 to 3 cm in width, 4 to 6 cm in length, and 0.3 to 0.6 cm in thickness. They are surrounded by areolar tissue, containing much fat and covered by a thin, fibrous capsule attached to the gland by many fibrous bands. The adrenal glands have their own fascial supports so they do not descend with the kidneys when these are displaced. The glands appear golden-yellow, distinct from the paler surrounding fat. The cut section demonstrates a golden cortical layer and a flattened mass of darker (reddish-brown) medullary tissue.

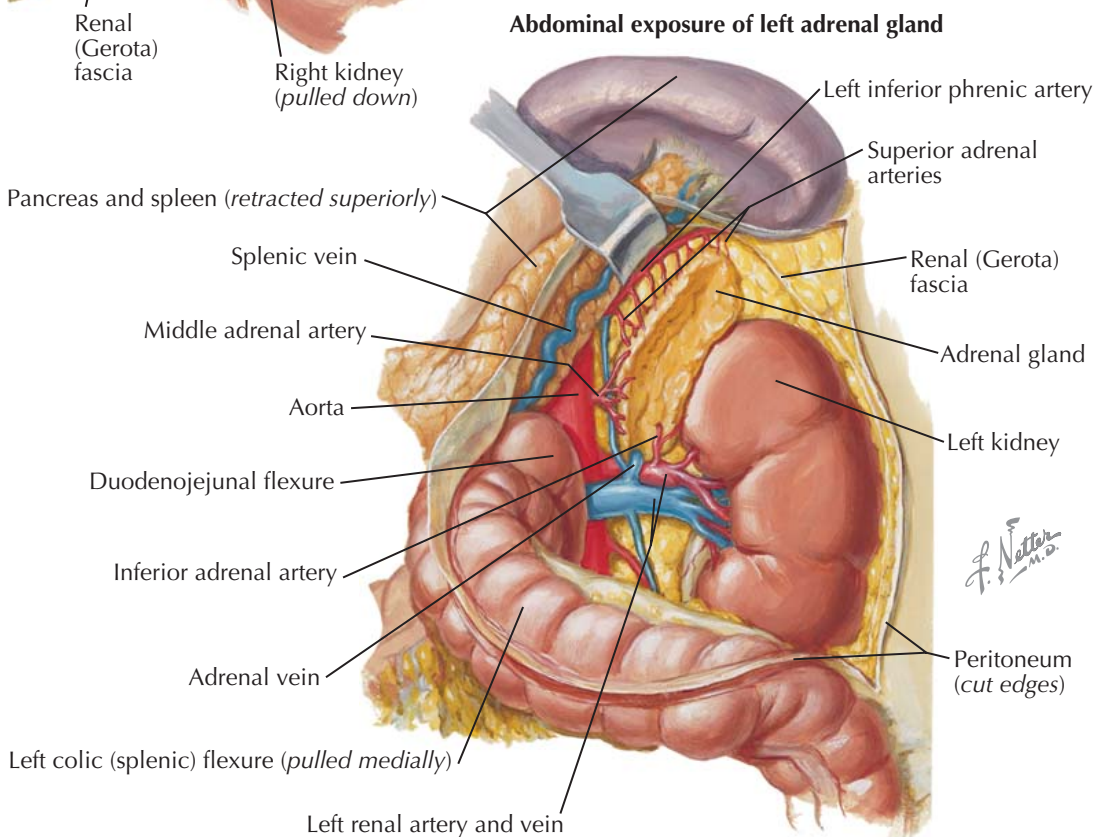
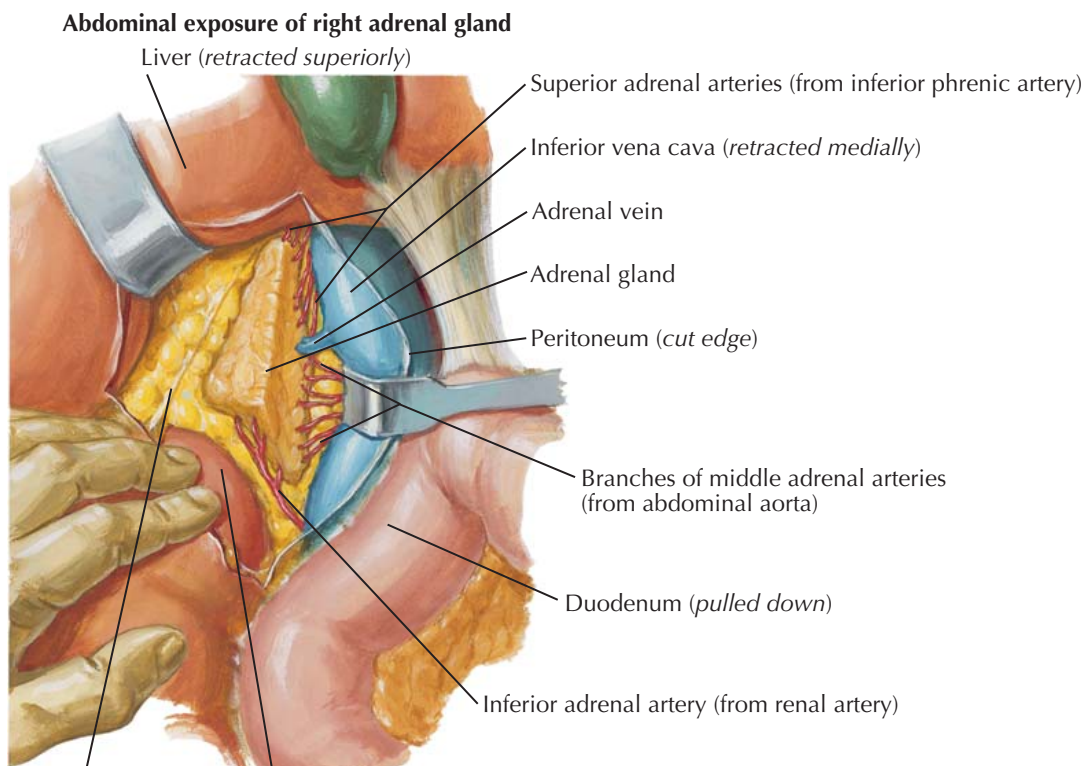
The right adrenal gland is pyramidal or triangular in shape. It occupies a somewhat higher and more lateral position than does the left one. Its posterior surface is in close apposition to the right diaphragmatic crus. The gland is located retroperitoneally in the recess, bounded superiorly by the posteroinferior border of the right lobe of the liver and medially by the right border of the inferior vena cava. The base of the pyramid is in close apposition to the anteromedial aspect of the upper pole of the right kidney.

The left adrenal gland is generally elongated or semi-lunar in shape and is a little larger than the right one. It is more centrally located, its medial border frequently overlapping the lateral border of the abdominal aorta. Its posterior surface is in close relationship to the diaphragm and to the splanchnic nerves. The upper two-thirds of the gland lie behind the posterior peritoneal wall of the lesser sac. The lower third is in close relationship to the posterior surface of the body of the pancreas and to the splenic vessels.

The adrenal glands have a very rich vascular supply, characterized by the following features:

1. Unlike those in other organs, the arteries and veins do not usually run together.
2. The arterial supply is abundant, with as many as 12 small arteries.
3. The venous blood is channeled almost completely through a large, single venous trunk that is easily identified.

Arterial blood reaches the adrenal glands through a variable number of slender, short, twiglike arteries, encompassing the gland in an arterial circle (see Plate 3-5). Three types must be distinguished: short capsular arterioles, intermediate cortical ones, and long branches that go through the cortex to the medulla and its sinusoids. These small arteries are terminal branches of the inferior phrenic artery superiorly forming the superior adrenal artery (located along the superior medial margin of the gland). The middle adrenal artery arises from the aorta; the inferior adrenal artery from the renal artery. This general pattern is occasionally supplemented by additional branches from vessels adjacent to the gland, such as the ovarian artery in females or the internal spermatic artery in males (on the left side).



Venous blood from the right adrenal gland empties into the vena cava through the right adrenal vein. This vein is short, generally measuring only 4 to 5 mm, and is located in an indentation on the anteromedial aspect of the right adrenal gland at the junction of the upper and middle thirds. On the left side, the left adrenal vein is situated inferomedially and empties directly into the left renal vein. The left adrenal vein is often joined by the left inferior phrenic vein before it empties into the left renal vein.

Arterial and venous capillaries within the adrenal gland help to integrate the function of the cortex and medulla. For example, cortisol-enriched blood flows from the cortex to the medulla, where cortisol enhances the activity of phenylethanolamine-N-methyltransferase that converts norepinephrine to epinephrine. Extra-adrenal chromaffin tissues lack these high levels of cortisol and produce norepinephrine almost exclusively.



## ANATOMY AND BLOOD SUPPLY OF THE ADRENAL GLANDS

(Continued)

### SURGICAL APPROACHES TO THE ADRENAL GLANDS

The pathologic process, tumor size, patient size, and previous operations are all factors that help determine the surgical approach to the adrenal glands. No one particular approach can be considered suitable for all cases, and the removal of a diseased gland or an adrenal tumor may, at times, present formidable difficulties.

#### Open Transabdominal Adrenalectomy

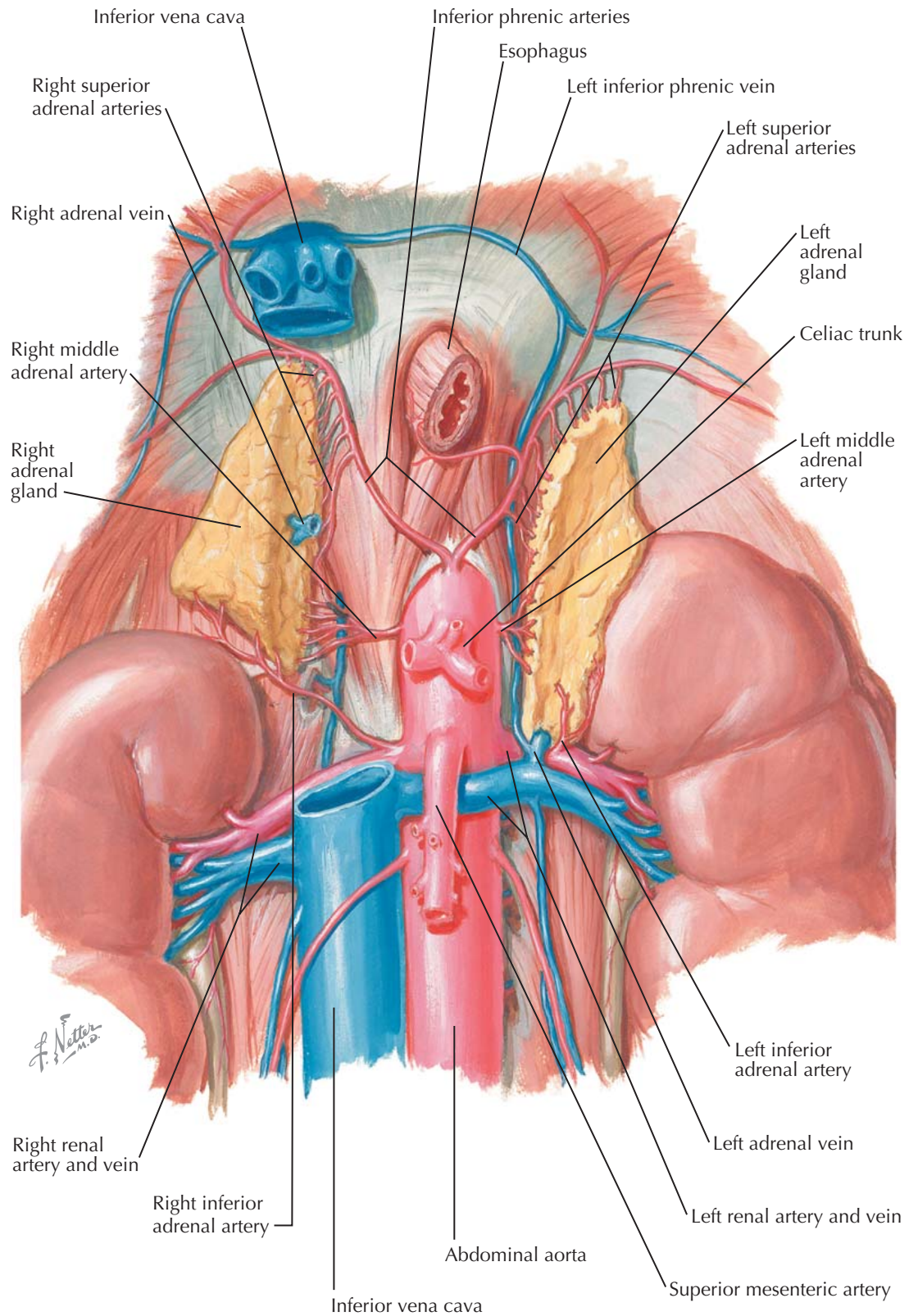
The patient is in the supine position, and the incision is typically in an extended subcostal location. A midline incision may be used if the patient has a narrow costal angle or bilateral adrenal disease is present. The approach to the left adrenal gland is typically through the gastrocolic ligament into the lesser sac. The left adrenal is exposed by lifting the inferior surface of the pancreas upward, Gerota fascia is opened, and the upper pole of the kidney is retracted inferiorly. The approach to the right adrenal gland involves mobilizing the hepatic flexure of the colon inferiorly and retracting the right lobe of the liver upward.

#### Open Posterior Adrenalectomy

Compared with the open anterior approach, the open posterior approach causes less pain, ileus, and other complications. The patient is in the prone position and the incision is either curvilinear extending from the 10th rib (4 cm from the midvertebral line) to the iliac crest (8 cm from the midvertebral line) or a single straight incision over the 12th rib with a small vertical paravertebral upward extension. The 12th rib is resected, the pleura is reflected upward, and Gerota fascia is incised.

#### Laparoscopic Transabdominal Adrenalectomy

Since its description in 1992, laparoscopic adrenalectomy has rapidly become the procedure of choice for unilateral adrenalectomy when the adrenal mass is smaller than 8 cm and there are no frank signs of malignancy (e.g., invasion of contiguous structures). The postoperative recovery time and long-term morbidity associated with laparoscopic adrenalectomy are significantly reduced compared with open adrenalectomy. The patient is placed in the lateral decubitus position with the side to be operated facing upward. Four trocars are placed in a straight line, 1 to 2 cm below the subcostal margin. On the right side, the liver with the gallbladder is retracted upward, and the retroperitoneum is incised. On the left side, the left colonic flexure and the descending colon are mobilized inferiorly and medially to expose the upper pole of the left kidney, and the retroperitoneum is incised.



#### Posterior Retroperitoneoscopic Adrenalectomy

A minimally invasive posterior approach to the adrenal is favored by some endocrine surgeons and is advantageous in patients who have had previous anterior upper abdominal operations. The patient is in the prone position, and three trocars are used. A gas pressure of 20 to 25 mm Hg allows the creation of sufficient space in the retroperitoneum to facilitate the operation.

#### Keys to Successful Adrenal Surgery

The keys to successful adrenal surgery are appropriate patient selection, knowledge of anatomy, delicate tissue handling, meticulous hemostasis, and experience with the approach used. Familiarity with the vascular anomalies of the blood supply of the adrenal glands is indispensable. Finally, the gland should be handled gently because it fractures easily when traumatized, jeopardizing its complete removal.



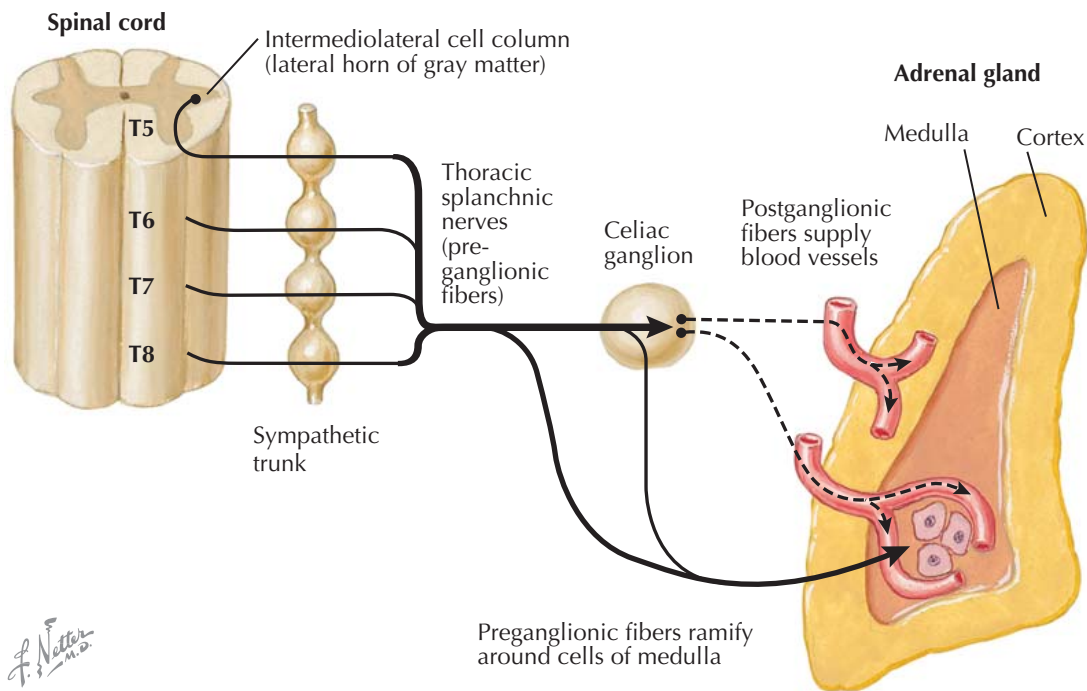
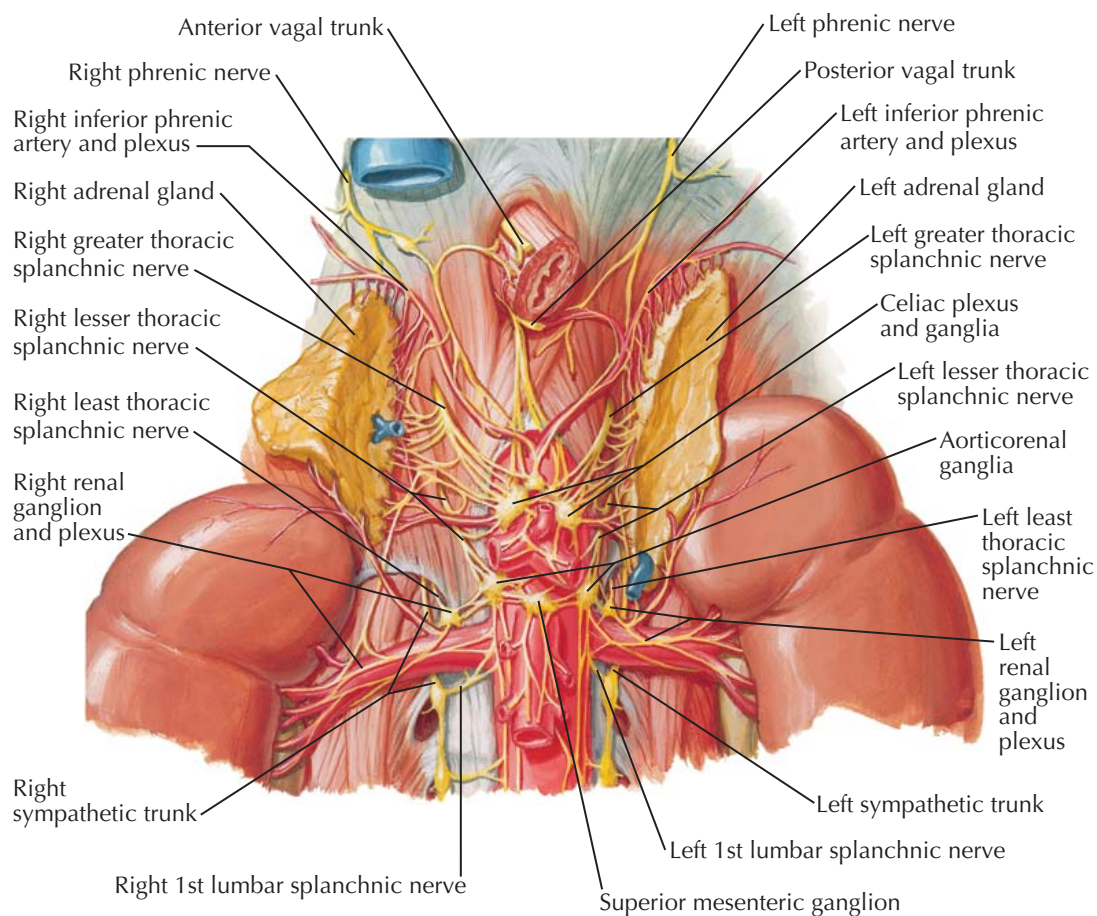
## INNERVATION OF THE ADRENAL GLANDS

Relative to their size, the adrenal glands have a richer innervation than other viscera. The sympathetic pre-ganglionic fibers for these glands are the axons of cells located in the intermediolateral columns of the lowest two or three thoracic and highest one or two lumbar segments of the spinal cord. They emerge in the anterior rootlets of the corresponding spinal nerves; pass in the white rami communicantes to the homolateral sympathetic trunks; and leave them in the greater, lesser, and least thoracic and first lumbar splanchnic nerves, which run to the celiac, aorticorenal, and renal ganglia. Some fibers end in these ganglia, but most pass through them without relaying and enter numerous small nerves that run outward on each side from the celiac plexus to the adrenal glands. These nerves are joined by direct contributions from the terminal parts of the greater and lesser thoracic splanchnic nerves, and they communicate with the homolateral phrenic nerve and renal plexus. Small ganglia exist on the adrenal nerves and within the actual adrenal medulla; a proportion of sympathetic fibers may relay in these ganglia.

Parasympathetic fibers are conveyed to the celiac plexus in the celiac branch of the posterior vagal trunk, and some of these are involved with adrenal innervation and may relay in ganglia in or near the gland.

On each side, the adrenal nerves form an adrenal plexus along the medial border of the adrenal gland. Filaments associated with occasional ganglion cells spread out over the gland to form a delicate subcapsular plexus, from which fascicles or solitary fibers penetrate the cortex to reach the medulla, apparently without supplying cortical cells en route, although they do supply cortical vessels. Most of the branches of the adrenal plexus, however, enter the gland through or near its hilum as compact bundles, some of which accompany the adrenal arteries. These bundles run through the cortex to the medulla, where they ramify profusely and mostly terminate in synaptic-type endings around the medullary chromaffin cells; some fibers invaginate but do not penetrate the plasma membranes of these cells. The preganglionic sympathetic fibers end directly around the medullary cells because these cells are derived from the sympathetic anlage and are the homologues of sympathetic ganglion cells. Other fibers innervate the adrenal vessels, including the central vein.

Catecholamines are released from the adrenal medullary and sympathoneuronal systems—both are key components of the fight-or-flight reaction. The signs and symptoms of the fight-or-flight reaction include cutaneous and systemic vasoconstriction with cold and



clammy skin, anxiety, agitation, piloerection, tachycardia, dilated pupils, hyperventilation, hyperglycemia, decreased gastrointestinal motility, and decreased urinary output. This reaction is triggered by neural signals from several sites in the brain (e.g., the hypothalamus, pons, and medulla), leading to synapses on cell bodies in the intermediolateral cell columns of the thoracolumbar spinal cord. The preganglionic sympathetic nerves leave the spinal cord and synapse in

paravertebral and preaortic ganglia of the sympathetic chain. Preganglionic axons from the lower thoracic and lumbar ganglia innervate the adrenal medulla via the splanchnic nerve and ramify about cells of the medulla. Acetylcholine is the neurotransmitter in the ganglia, and the postganglionic fiber releases norepinephrine. The chromaffin cell of the adrenal medulla is a "postganglionic fiber equivalent," and its chemical transmitters are epinephrine and norepinephrine.



## HISTOLOGY OF THE ADRENAL GLANDS

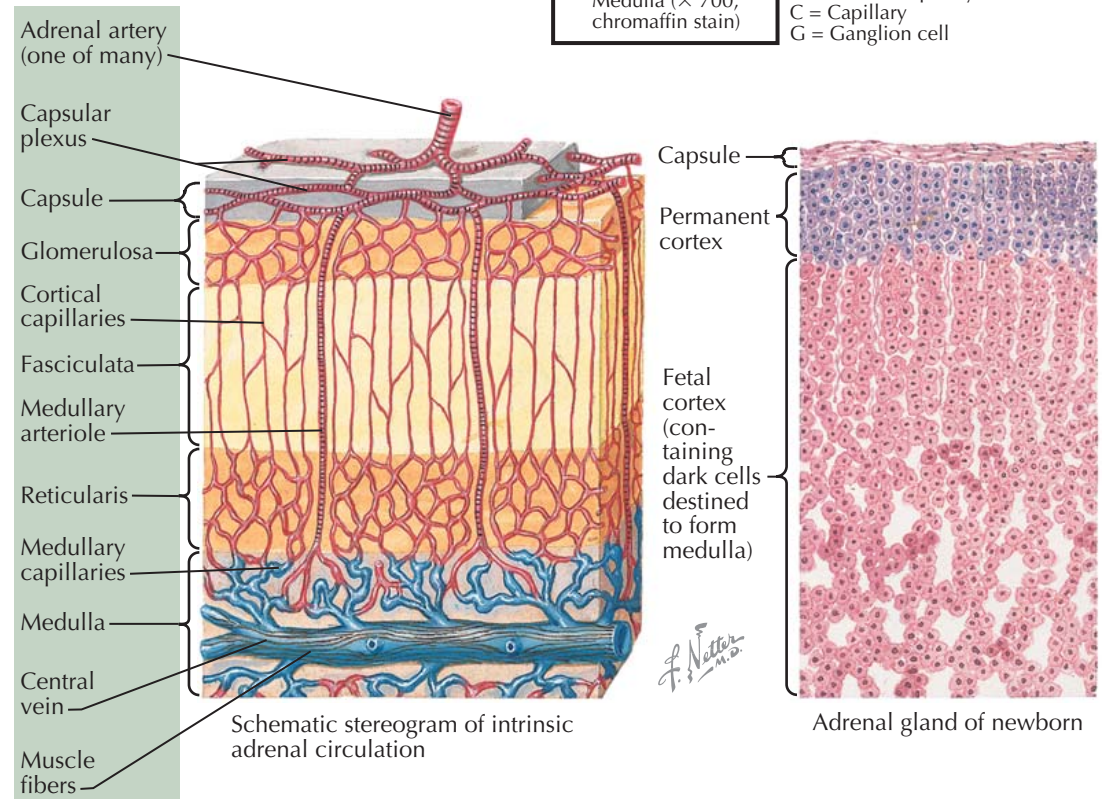
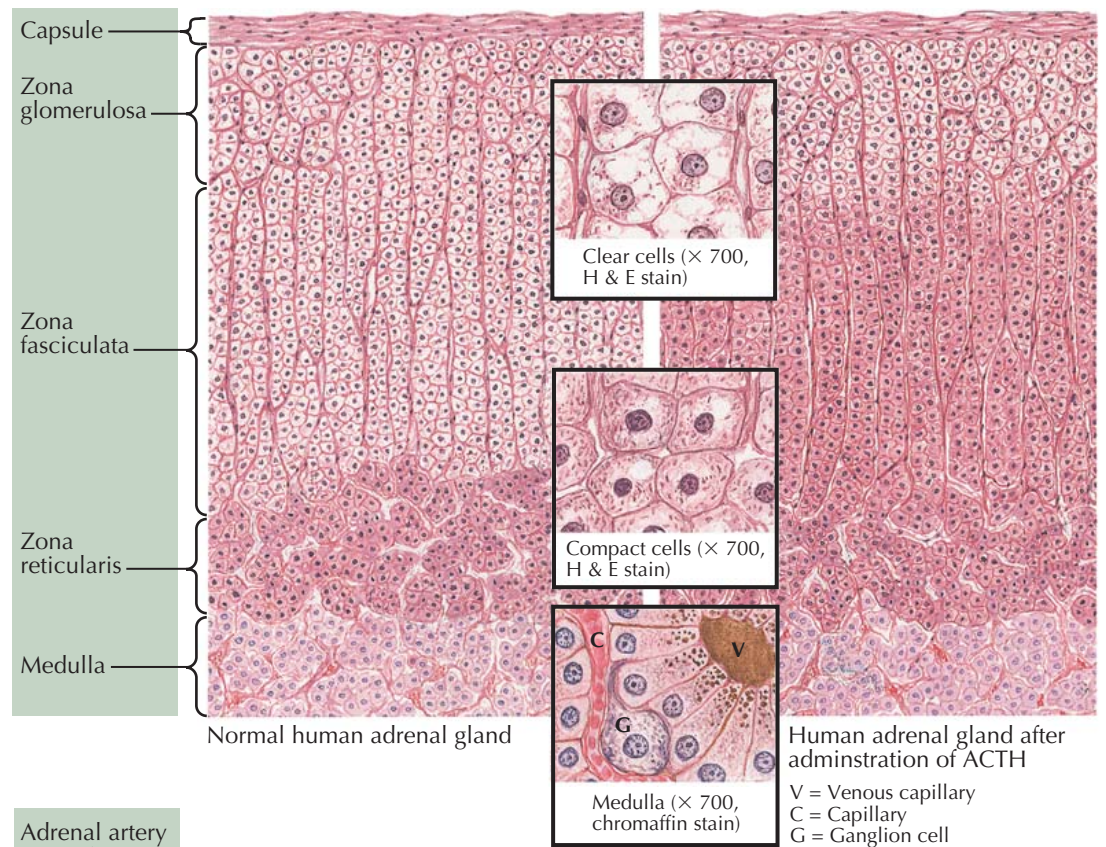
The adrenal glands are composed of two separate and distinct endocrine tissues—the adrenal cortex and the adrenal medulla—and each is entirely different in embryologic origin, structure, and function. In adults, the cortex comprises about 90% of the adrenal gland and completely surrounds the thin layer of centrally located medulla. In histologic sections, the cortex is seen to be composed mainly of radially oriented cords of cells. During embryogenesis, cells destined to form the medulla migrate through the cortex. At birth, in addition to a thin outer layer of permanent cortex, there is a thick band of fetal cortex, which soon involutes.

The cells of the adrenal cortex are typically epithelioid in appearance, with centrally placed nuclei having two or more prominent nucleoli. The cytoplasm features a variable abundance of lipid-containing vacuoles in addition to mitochondria and the Golgi apparatus.

In the adrenal cortex, three concentrically arranged cell layers, or zones, can be identified on the basis of the grouping of cells and the disposition of cell cords. In the thin outermost layer, the zona glomerulosa, the cells occur in arched loops or round balls. The middle layer, the zona fasciculata, is the widest of the three zones and is composed of cells arranged in long straight cords, or fascicles. The innermost layer, the zona reticularis, is contiguous with the medulla, and the cell cords are entwined, forming a reticulum. The two inner zones are entirely dependent on pituitary corticotropin (adrenocorticotrophic hormone [ACTH]) secretion for the maintenance of their structure and function. However, the zona glomerulosa remains structurally and functionally normal in the absence of ACTH. Under normal conditions, the cortical cells at the inner border of the cortex have few lipid vacuoles and are referred to as *compact cells*, in contrast to the lipid-laden light cells that occupy the midportion of the cortex. Under ACTH stimulation, the layer of compact cells increases in width at the expense of the layer of light cells.

The zona glomerulosa is primarily responsible for the secretion of aldosterone, a mineralocorticoid having the prime function of regulating sodium and potassium balance. The function of the zona glomerulosa is essentially independent of that of the remainder of the cortex. The control of aldosterone secretion involves the renal juxtaglomerular apparatus and the renin-angiotensin system. The zona fasciculata and reticularis can best be regarded as a functional unit, having as its primary purpose the secretion of the glucocorticoid cortisol and some adrenal androgens. Cortisol has a prominent role in regulating the catabolism of protein, facilitating gluconeogenesis, and suppressing inflammation.

The adrenal gland receives blood from 30 to 50 small arteries that penetrate the capsule at different points and form the capsular plexus of arterioles. These supply the capillaries that extend radially through the cortex and separate the cords of cells. The adrenal medulla has



both a venous and an arterial blood supply. Capillaries from the cortex extend into the medulla as venous capillaries; a few medullary arterioles extend through the cortex to form arterial capillaries in the medulla. Both categories of vessels join to form veins that drain through the single large central adrenal vein. The venous tributaries enter the latter between thick bands of smooth muscle, longitudinally disposed in its wall.

The adrenal medulla is composed of columnar cells that secrete the catecholamines epinephrine, norepinephrine, and dopamine. Because the catecholamines are readily darkened by the oxidizing agent potassium dichromate, the medulla is often referred to as *chromaffin tissue*. Preganglionic sympathetic fibers enter the medulla and terminate directly on the parenchymal cells or scattered sympathetic ganglion cells.

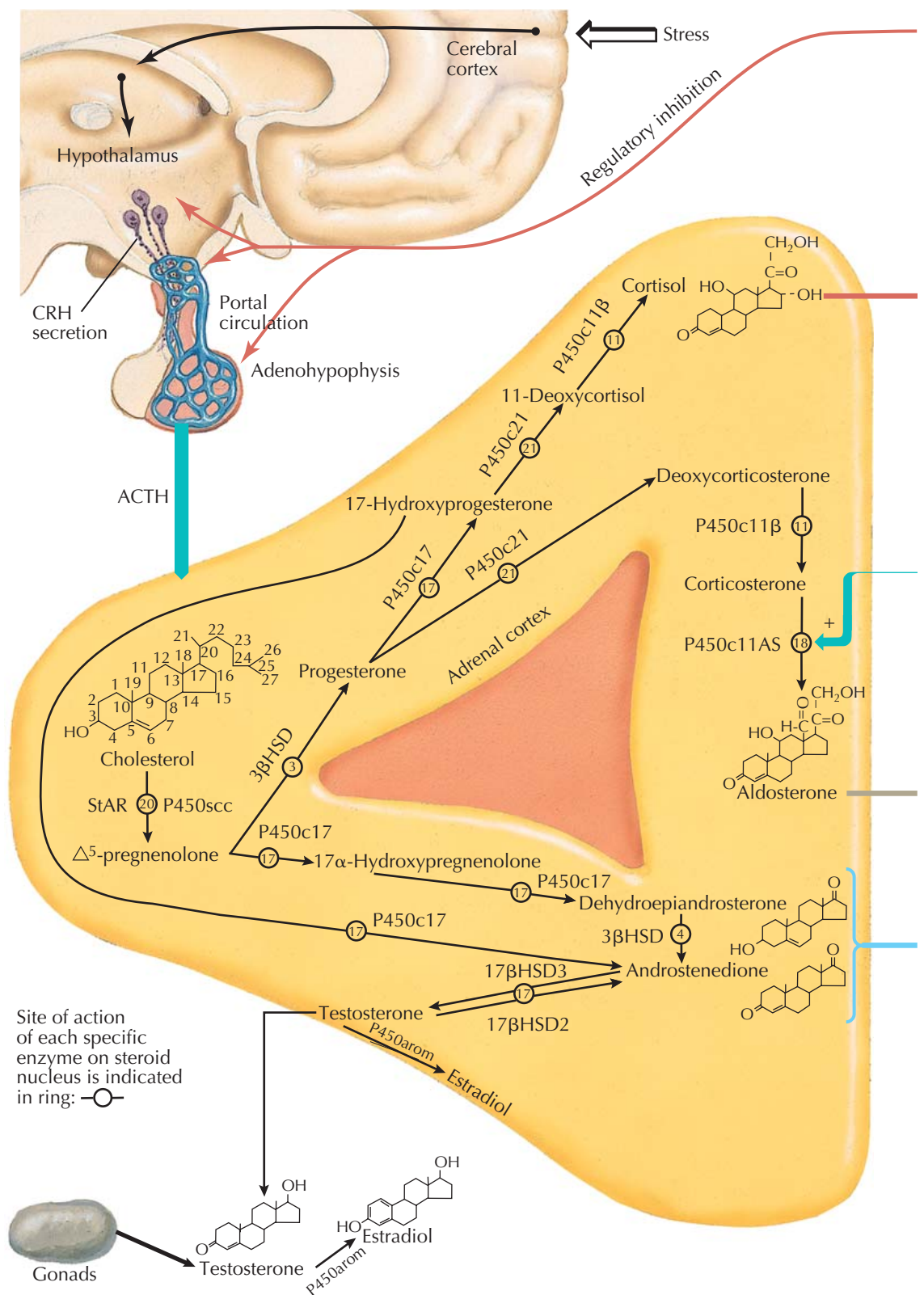


### BIOSYNTHESIS AND METABOLISM OF ADRENAL CORTICAL HORMONES

The steroids produced by the adrenal cortex include glucocorticoids, mineralocorticoids, adrenal androgens (17-ketosteroids), estrogens, and progestogens. Although some steroids are highly potent biologically, others are relatively inactive. Whereas the secretory activity and growth of the zona fasciculata and zona reticularis of the adrenal cortex are regulated by the pituitary secretion of corticotropin (adrenocorticotropic hormone [ACTH]), the secretion of aldosterone from the zona glomerulosa of the adrenal cortex is regulated by angiotensin II, potassium, and (to a lesser extent) ACTH. ACTH is released from pituitary corticotrophs on the basis of feedback regulation—if there is a decrease in the blood cortisol concentration, pulsatile corticotropin-releasing hormone (CRH) and ACTH secretion increase and raise the cortisol level again, which in turn inhibits further CRH and ACTH release. The hypothalamic–pituitary–adrenal axis feedback control is accompanied by a diurnal variation in ACTH secretion. The ACTH pulse frequency and amplitude are maximal between 2 and 8 AM. After 8 AM, there is a gradual daytime decrease in ACTH and cortisol secretion, reaching a nadir in the late evening hours. The circadian rhythm is dependent on both sleep–wake and day–night patterns. With overseas travel, it may take 10 to 14 days for the circadian rhythm to reset to the new time zone.

The diurnal rhythm in cortisol secretion is abolished in individuals with Cushing syndrome, whether the syndrome is caused by a primary adrenal tumor, ectopic ACTH, or ectopic ACTH hypersecretion. The feedback inhibition of ACTH by cortisol may be interrupted at any time by an overriding mechanism (e.g., stress). Stressful stimuli (e.g., fever, trauma, hypoglycemia, hypotension) reaching the cerebral cortex release the inhibition of the reticular formation or of the limbic system on hypothalamic centers in and around the tuberoinfundibular nucleus and the median eminence. Large neurons then secrete hypothalamic CRH. Vasopressin also has an ACTH-releasing effect. The proinflammatory cytokines (e.g., interleukins) increase ACTH secretion either directly or by augmenting CRH secretion. The greater the stress, the more ACTH is secreted. The upper secretory limit of endogenous cortisol is approximately 250 mg/d.

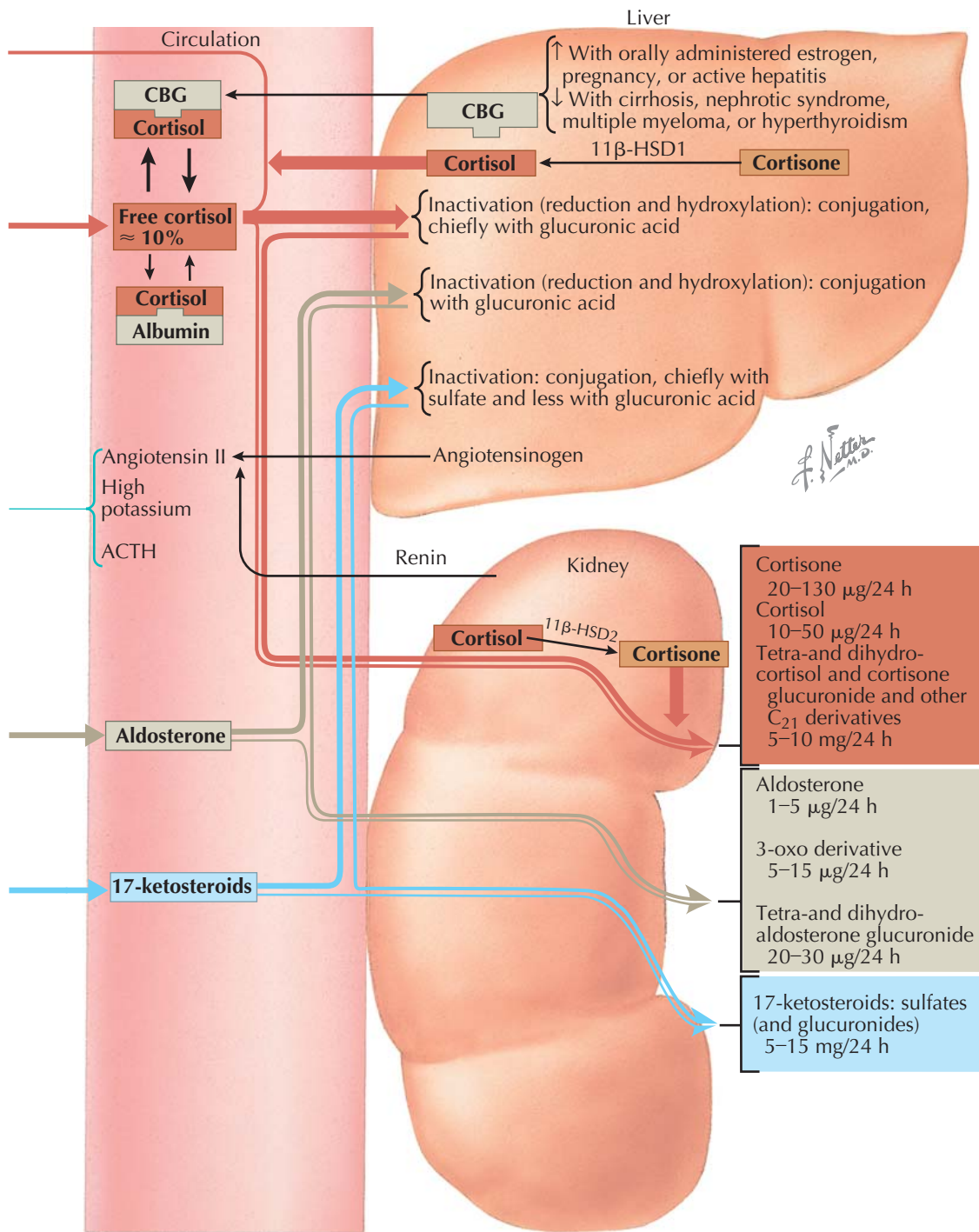
Cholesterol derived from acetate is stored in the adrenal cortex. Its cyclopentanophenanthrene 4-ring hydrocarbon nucleus (3 cyclohexane rings and a single cyclopentane ring) is modified by enzymes that induce hydroxyl groups into the ring (hydroxylases), but other enzymes (dehydrogenases) may remove hydrogen from a hydroxyl group, and others (oxidases) remove hydrogen from a CH group. Chemical structure determines



Site of action of each specific enzyme on steroid nucleus is indicated in ring: ○

function; for example, glucocorticoids are distinguished by an  $\alpha$ -ketol group and an 11-hydroxyl group. Cleaving cholesterol into pregnenolone (the C21 precursor of all active steroid hormones) and isopropylaldehyde is the critical first step and occurs in a limited number of sites in the body (e.g., adrenal cortex, testicular Leydig cells, ovarian theca cells, trophoblast cells of the placenta, and certain glial and neuronal cells of the brain). The roles of different steroidogenic tissues are determined by how this process is regulated and in how

pregnenolone is subsequently metabolized. Most of the steroidogenic enzymes are unidirectional, so the accumulation of product does not drive flux back to the substrate. In addition, whereas the P450-mediated hydroxylations and carbon–carbon bond cleavage reactions are irreversible, the hydroxysteroid dehydrogenase reactions are reversible. Glucocorticoids and progestogens have 21 carbon atoms (C21 steroids), androgens have 19 carbon atoms (C19 steroids), and estrogens have 18 carbon atoms (C18 steroids).



17-hydroxyprogesterone through the activity of 17 $\alpha$ -hydroxylase (P450c17). 17-Hydroxylation is a prerequisite for glucocorticoid synthesis (the zona glomerulosa does not express P450c17). P450c17 also possesses 17,20-lyase activity, which results in the production of the C<sub>19</sub> adrenal androgens (dehydroepiandrosterone [DHEA] and androstenedione). Most of the adrenal androstenedione production is dependent on the conversion of dehydroepiandrosterone to androstenedione by 3 $\beta$ -HSD. 21-Hydroxylation of either progesterone in the zona glomerulosa or 17-hydroxyprogesterone (zona fasciculata) is performed by 21-hydroxylase (P450c21) to yield deoxycorticosterone or 11-deoxycortisol, respectively. The final step in cortisol biosynthesis—the conversion of 11-deoxycortisol to cortisol by 11 $\beta$ -hydroxylase (P450c11 $\beta$ )—takes place in the mitochondria. In the zona glomerulosa, P450c11 $\beta$  and aldosterone synthase (P450c11AS) convert deoxycorticosterone to corticosterone. P450c11AS is also required for the 18-hydroxylation and 18-methyloxidation steps to convert corticosterone to aldosterone via the intermediate 18-hydroxycorticosterone. Whereas aldosterone secretion is confined to the zona glomerulosa through the restricted expression of *CYP11B2*, the zona glomerulosa cannot synthesize cortisol because it does not express *CYP17*. In the zona reticularis, high levels of cytochrome b5 facilitate 17,20-lyase activity on P450c17, and the production of DHEA. DHEA is either converted to androstenedione by 3 $\beta$ -HSD or sulfated in the zona reticularis by the DHEA sulfotransferase (*SULT2A1*) to form DHEA sulfate (DHEA-S). Androstenedione may be converted to testosterone by 17 $\beta$ -ketosteroid reductase (17 $\beta$ -HSD3) in the adrenal glands or gonads.

Under normal conditions, 10 to 20 mg of cortisol and 0.1 to 0.15 mg of aldosterone are secreted over 24 hours. The adult adrenal gland secretes approximately 4 mg of DHEA, 10 mg of DHEA-S, 1.5 mg of androstenedione, and 0.05 mg of testosterone over 24 hours. However, testosterone has 60 times the androgenic potency of even the most potent 17-ketosteroid (characterized by an oxygen atom in the 17 position). The adrenal androgens supply approximately 50% of circulating androgens in premenopausal women. The adrenal glands secrete small amounts of estradiol (derived from testosterone) and estrone (derived from androstenedione); both become important after menopause when the adrenal glands are the only source of estrogens in women.

### BIOSYNTHESIS AND METABOLISM OF ADRENAL CORTICAL HORMONES (Continued)

The steroidogenic acute regulatory protein (StAR) mobilizes cholesterol from the outer mitochondrial membrane to the inner mitochondrial membrane, where the rate-limiting steroid side-chain cleavage enzyme (P450scc) cleaves cholesterol to pregnenolone. StAR is induced by an increase in intracellular cyclic adenosine monophosphate (cAMP) after receptor activation by ACTH. P450scc and the CYP11B enzymes (11 $\beta$ -hydroxylase and aldosterone synthase)

are mitochondrial enzymes and require an electron shuttle system (adrenodoxin/adrenodoxin reductase) to oxidize steroids, whereas 17 $\alpha$ -hydroxylase and 21-hydroxylase are located in the endoplasmic reticulum, and electron transfer is accomplished from nicotinamide adenine dinucleotide phosphate by the enzyme P450 oxidoreductase (P450 OR). Finally, the 17,20-lyase activity of P450 CYP17 requires flavoprotein b5 that functions as an allosteric facilitator of the CYP17 and P450 OR interaction.

In the cytoplasm, pregnenolone is converted to progesterone by 3 $\beta$ -hydroxysteroid dehydrogenase (3 $\beta$ -HSD) by a reaction involving dehydrogenation of the 3-hydroxyl group and isomerization of the double bond at C5. Progesterone is hydroxylated to



ADRENAL STEROIDOGENIC ENZYMES, THEIR GENES, LOCATIONS, AND SUBSTRATES

| Enzyme name   | Abbreviation     | Gene           | Location                                 | Substrate  |
|---|------------------|----------------|--|--|
| Cholesterol side-chain cleavage (desmolase)                                 | P-450scc         | <i>CYP11A1</i> | ZG, ZF, ZR, gonads, placenta, brain      | Cholesterol  |
| 3 $\beta$ -Hydroxysteroid dehydrogenase (3 $\beta$ -HSD1) (type I isozyme)  | 3 $\beta$ -HSD1  | <i>HSD3B1</i>  | Placenta, liver, brain                   | Pregnenolone, 17 $\alpha$ -OH-pregnenolone   |
| 3 $\beta$ -Hydroxysteroid dehydrogenase (3 $\beta$ -HSD2) (type II isozyme) | 3 $\beta$ -HSD2  | <i>HSD3B2</i>  | ZG, ZF, ZR, gonads                       | DHEA, Pregnenolone, 17 $\alpha$ -OH-Pregnenolone                                       |
| 17 $\alpha$ -Hydroxylase/17,20 lyase  | P-450c17         | <i>CYP17</i>   | ZF, ZR, gonads, brain                    | Pregnenolone, 17 $\alpha$ -OH-pregnenolone, progesterone, 17 $\alpha$ -OH-progesterone |
| 21-Hydroxylase  | P-450c21         | <i>CYP21A2</i> | ZG, ZF, ZR                               | Progesterone, 17 $\alpha$ -OH-progesterone   |
| 11 $\beta$ -Hydroxylase   | P-450c11 $\beta$ | <i>CYP11B1</i> | ZG, ZR, brain                            | 11-Deoxycortisol, 11-deoxycorticosterone   |
| Aldosterone synthase  | P-450c11AS       | <i>CYP11B2</i> | ZG, brain, heart                         | Deoxycorticosterone, 18-OH-corticosterone  |
| Aromatase   | P-450arom        | <i>CYP19A1</i> | Gonads, placenta, brain, bone, fat       | Testosterone, androstenedione  |
| 17 $\beta$ -Ketosteroid reductase   | 17 $\beta$ -HSD1 | <i>HSD17B1</i> | Gonads, placenta, breast                 | Estrone  |
| 17 $\beta$ -Hydroxysteroid dehydrogenase                                    | 17 $\beta$ -HSD2 | <i>HSD17B2</i> | Broadly                                  | Estradiol, testosterone  |
| 17 $\beta$ -Ketosteroid reductase   | 17 $\beta$ -HSD3 | <i>HSD17B3</i> | Gonads                                   | Androstenedione  |
| 11 $\beta$ Hydroxysteroid dehydrogenase 1                                   | 11 $\beta$ -HSD1 | <i>HSD11B1</i> | Liver, brain, placenta, fat              | Cortisone  |
| 11 $\beta$ Hydroxysteroid dehydrogenase 2                                   | 11 $\beta$ -HSD2 | <i>HSD11B2</i> | Kidney, colon, salivary glands, placenta | Cortisol   |

Abbreviations: DHEA, dehydroepiandrosterone; ZF, adrenal zona fasciculata; ZG, adrenal zona glomerulosa, ZR, adrenal zona reticularis.

## BIOSYNTHESIS AND METABOLISM OF ADRENAL CORTICAL HORMONES (Continued)

Approximately 90% of cortisol in the plasma is bound, primarily by cortisol-binding globulin (CBG) and to a lesser extent by albumin. The hepatic production of CBG is increased in patients taking orally administered estrogen (e.g., oral contraceptive pill or postmenopausal estrogen replacement therapy), in pregnant women, and in patients with active hepatitis. Blood CBG concentrations are decreased in patients with cirrhosis, nephrotic syndrome, multiple myeloma, or hyperthyroidism. When cortisol is measured in the blood, it is the sum of the bound and free forms; thus, the CBG concentration has a substantial effect on the measured level of cortisol, appearing high in patients taking oral estrogen and low in patients with low CBG concentrations. In these settings, the clinician can measure the unbound or free cortisol concentration in the blood or the excretion of free cortisol through the kidneys, termed *urinary free cortisol* (which represents approximately 1% of the total cortisol secretion rate).

The circulating half-life of cortisol varies between 60 and 120 minutes. The interconversion of cortisol and cortisone via 11 $\beta$ -hydroxysteroid dehydrogenase (11 $\beta$ -HSD) regulates local corticosteroid hormone action. There are 2 distinct 11 $\beta$ -HSD isozymes: type 1 (11 $\beta$ -HSD1) is expressed primarily in the liver and converts cortisone to cortisol; type 2 (11 $\beta$ -HSD2) is found near the mineralocorticoid receptor in the kidney, colon, and salivary glands and inactivates cortisol to cortisone. Apparent mineralocorticoid excess is the result of impaired 11 $\beta$ -HSD2 activity. Cortisol can be a potent mineralocorticoid, and as a result of the enzyme deficiency, high levels of cortisol accumulate in the kidney. Thus, 11 $\beta$ -HSD2 normally excludes physiologic glucocorticoids from the nonselective mineralocorticoid receptor by converting them to the inactive 11-keto compound, cortisone. Decreased 11 $\beta$ -HSD2 activity may be hereditary or secondary to pharmacologic inhibition of enzyme activity by glycyrrhizic acid, the active principle of licorice root (*Glycyrrhiza glabra*). The clinical phenotype of patients with apparent mineralocorticoid excess includes hypertension, hypokalemia, metabolic alkalosis, low plasma renin activity, low plasma aldosterone concentration, and normal plasma cortisol levels. The diagnosis is confirmed by demonstrating an abnormal ratio of cortisol to

cortisone (e.g., >10:1) in a 24-hour urine collection. The apparent mineralocorticoid excess state caused by ectopic ACTH secretion, commonly seen in patients with Cushing syndrome, is related to the high rates of cortisol production that overwhelm 11 $\beta$ -HSD2 activity.

The usual level of cortisone in the urine is approximately two- to threefold higher than the level of cortisol. The subsequent metabolism of cortisol and cortisone then follows similar pathways with reduction of the C4–5 double bond to form dihydrocortisol or dihydrocortisone followed by a hydroxylation step to form tetrahydrocortisol and tetrahydrocortisone, which are rapidly conjugated with glucuronic acid and excreted in the urine. Thus, primary sites of cortisol metabolism are the liver and kidney.

Aldosterone is also metabolized in the liver, where it undergoes tetrahydro reduction and is excreted by the kidneys as 3-glucuronide tetrahydroaldosterone; 20 to 30  $\mu$ g of this conjugate is excreted daily in the urine. In addition, 5 to 15  $\mu$ g per day of the aldosterone 3-oxoglucuronic acid conjugate is found in the urine as hydrolyzable aldosterone. A much smaller fraction of aldosterone (1–5  $\mu$ g) appears in the urine in the free form.

## THE BIOLOGIC ACTIONS OF CORTISOL

### CARBOHYDRATE, PROTEIN, AND LIPID METABOLISM

Because of their actions on glycogen, protein, and lipid metabolism, glucocorticoids increase blood glucose concentrations. Glucocorticoids stimulate glycogen deposition in the liver by inhibiting the glycogen-mobilizing enzyme (glycogen phosphorylase) and by increasing glycogen synthase. They increase hepatic glucose output by activation of the gluconeogenic enzymes (glucose-6-phosphatase and phosphoenolpyruvate kinase). Lipolysis is activated in adipose tissue, increasing blood free fatty acid concentrations. Because of their enhancing and synergistic effects on the actions of other hormones (e.g., glucagon and catecholamines), increased glucocorticoid concentrations cause insulin resistance and an increased blood glucose concentration. Thus, over the short term, glucocorticoids support stress responses that require glucose for rapid and intense exertion. With long-term excess, glucocorticoids are diabetogenic. In addition, there is enhanced adipogenesis, especially in the visceral or central adipose tissue depots (centripetal distribution).

### SKIN, MUSCLE, AND CONNECTIVE TISSUES

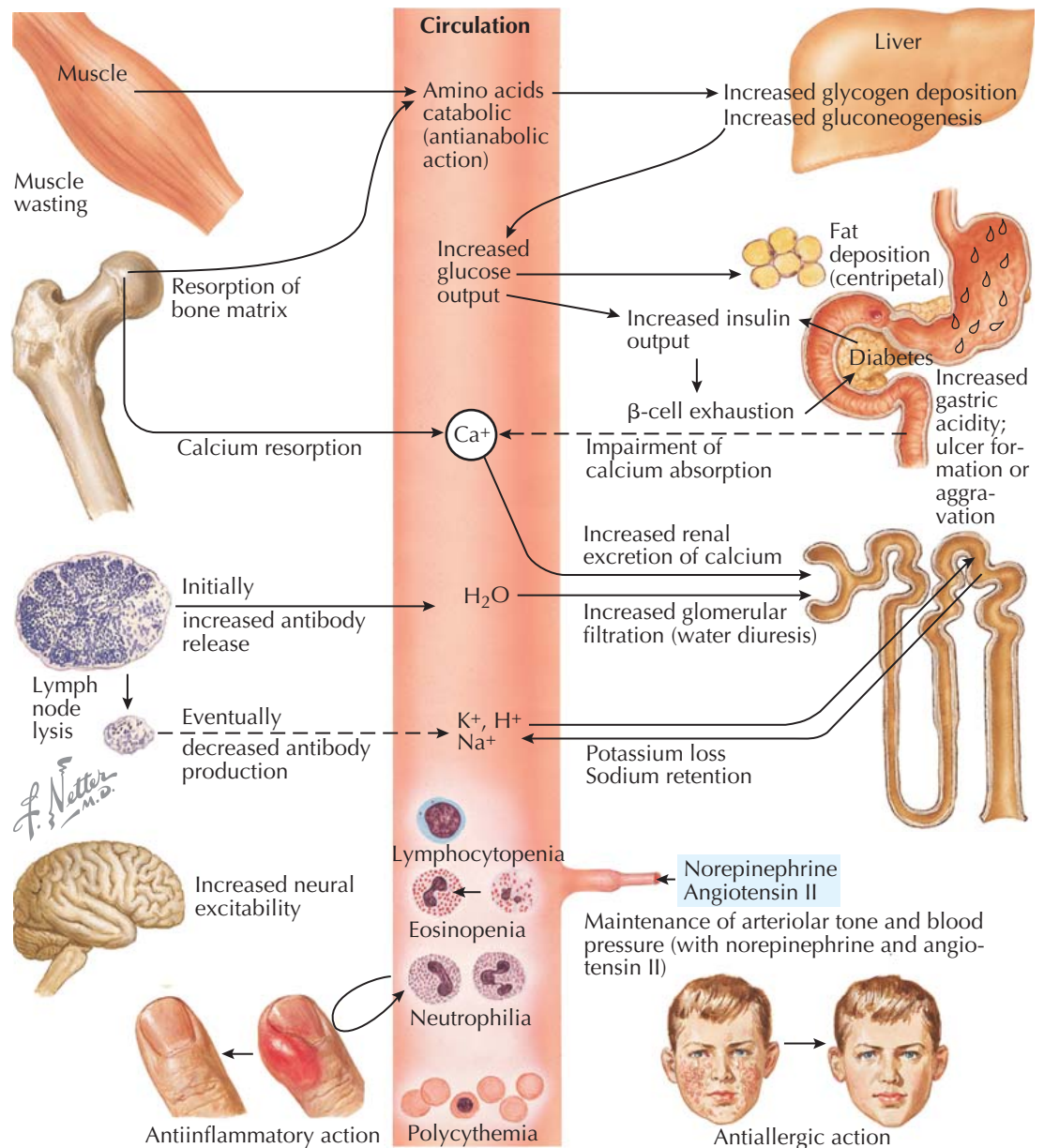
Excess glucocorticoids are catabolic and divert amino acids from muscle to the liver for deamination, resulting in muscle wasting and proximal muscle weakness. There is decreased protein synthesis and increased resorption of bone matrix, resulting in growth arrest in children. Glucocorticoids decrease collagen synthesis and production and inhibit epidermal cell division and DNA synthesis.

### BONE AND CALCIUM METABOLISM

Excess glucocorticoids cause osteopenia and osteoporosis by inhibiting osteoblast function and enhancing resorption of bone matrix. The most serious bone-related complication from excess glucocorticoids is osteonecrosis (avascular necrosis); it is caused by osteocyte apoptosis, resulting in focal deterioration and collapse of bone that primarily affects the femoral head. Excess glucocorticoids inhibit intestinal calcium absorption and increase renal calcium excretion, resulting in a negative calcium balance.

### BLOOD PRESSURE CONTROL

Glucocorticoids increase glomerular filtration rate, proximal tubular epithelial sodium transport, and free water clearance. Excess glucocorticoids can overwhelm renal  $11\beta$ -hydroxysteroid dehydrogenase isozyme type 2 ( $11\beta$ -HSD2), allowing access of cortisol to the mineralocorticoid receptor (see Plates 3-6 and 3-7) and resulting in renal sodium retention and potassium loss. Under normal physiologic conditions, glucocorticoids increase sensitivity to pressor agents such as catecholamines and angiotensin II in vascular smooth muscle. In addition, the synthesis of angiotensinogen is increased by glucocorticoids.



### ANTIINFLAMMATORY ACTIONS

Glucocorticoids suppress the immunologic responses of autoimmune and inflammatory conditions. They reduce blood lymphocyte counts (by redistributing them from the intravascular compartment to spleen, lymph nodes, and bone marrow), inhibit immunoglobulin synthesis, stimulate lymphocyte apoptosis, and inhibit proinflammatory cytokine production. Glucocorticoid administration also increases blood neutrophil counts and decreases eosinophil counts. Another mechanism underlying the antiinflammatory effects of glucocorticoids involves inhibition of monocyte differentiation into macrophages and subsequent macrophage phagocytosis and cytotoxic activity. They reduce the local inflammatory response by preventing the action of histamine and plasminogen activators and by impairing prostaglandin synthesis. A mild polycythemia may be present in patients treated with pharmacologic dosages of glucocorticoids.

### CENTRAL NERVOUS SYSTEM AND EYES

Behavioral changes are frequently observed with both excess and deficient glucocorticoids. Depression,

euphoria, psychosis, apathy, or lethargy may be observed in patients treated with pharmacologic dosages of glucocorticoids. The increased neuroexcitability frequently results in insomnia. Depression and lassitude may be seen in individuals with glucocorticoid deficiency. Glucocorticoids may also cause glaucoma by raising intraocular pressure via increased aqueous humor production and prevention of aqueous drainage by matrix deposition in the trabecular meshwork.

### GASTROINTESTINAL TRACT

Administration of supraphysiologic dosages of glucocorticoids increases the risk of developing peptic ulcer disease because of increased secretion of hydrochloric acid and pepsin and mucus thinning in the stomach.

### ENDOCRINE EFFECTS

Glucocorticoids directly decrease thyrotropin secretion and inhibit  $5'$  deiodinase activity that converts thyroxine to triiodothyronine. They also inhibit hypothalamic gonadotropin-releasing hormone pulsatility and release of pituitary gonadotropins.



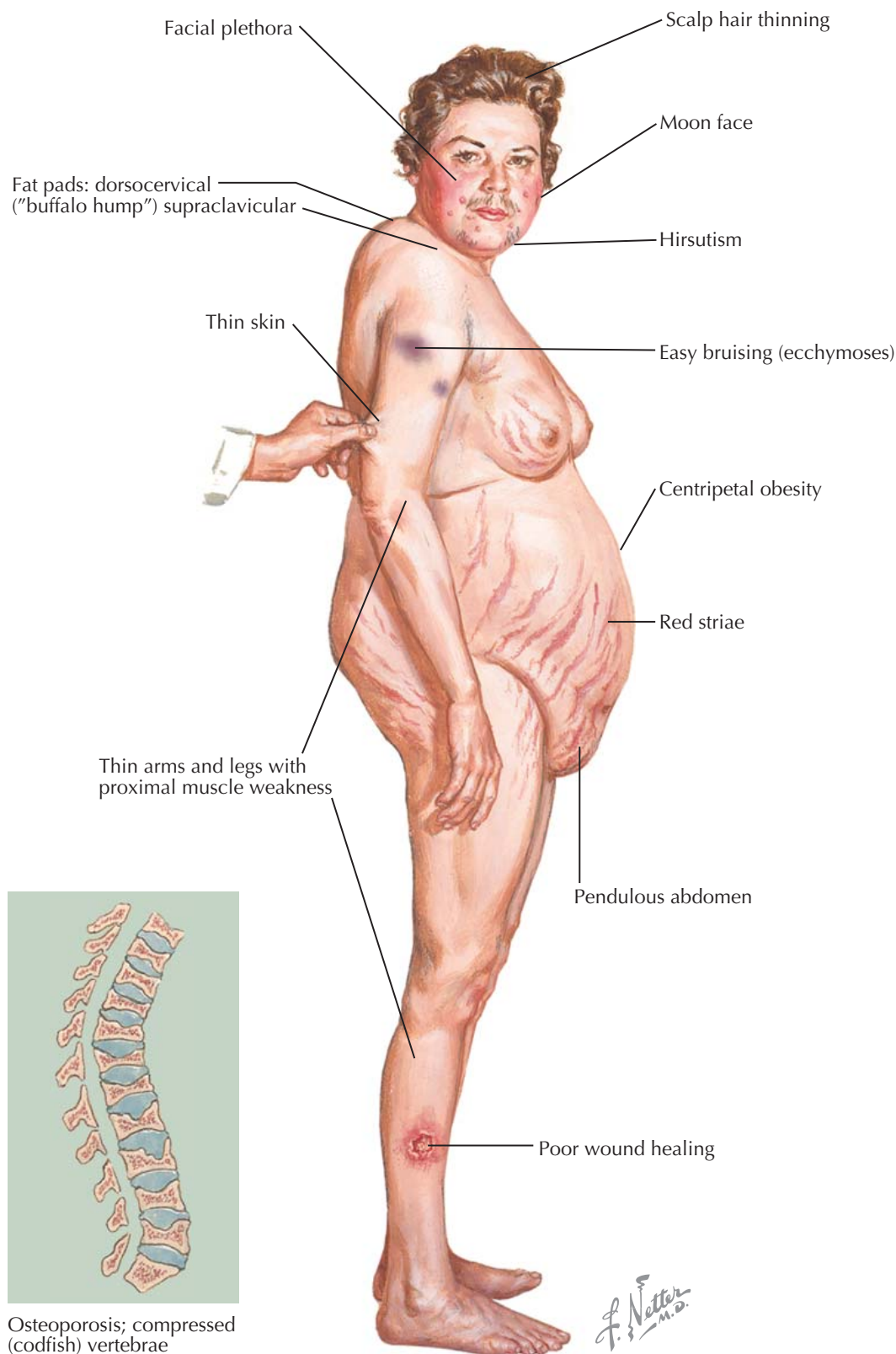
## CUSHING SYNDROME—CLINICAL FINDINGS

Cushing syndrome is a symptom complex that results from prolonged exposure to supraphysiologic concentrations of glucocorticoids. The most common cause of Cushing syndrome is the use of synthetic glucocorticoids to treat an inflammatory condition, termed *exogenous* or *iatrogenic Cushing syndrome*. Endogenous or spontaneous Cushing syndrome is rare and is caused by hypersecretion of corticotropin (adrenocorticotropic hormone [ACTH]) (ACTH-dependent Cushing syndrome) or by primary adrenal hypersecretion of glucocorticoids (ACTH-independent Cushing syndrome).

Although Cushing syndrome is not common, the clinical features of hypercortisolism are common. The clinician's role is to (1) recognize Cushing syndrome, (2) confirm endogenous Cushing syndrome with biochemical tests, (3) determine the cause of Cushing syndrome, and (4) provide a definitive cure.

Typical signs and symptoms of Cushing syndrome include weight gain with central (centripetal) obesity; facial rounding with fat deposition in the temporal fossae and cheeks ("moon face") and plethora; supraclavicular fat pads; dorsocervical fat pad ("buffalo hump"); easy ("spontaneous") bruising (ecchymoses); fine "cigarette paper–thin skin" (subcutaneous blood vessels can be seen) that tears easily; poor wound healing; red-purple striae (usually >1 cm in diameter located over the abdomen, flanks, axilla, breasts, hips, and inner thighs); hyperpigmentation over the extensor surfaces and palmar creases (typically only apparent with markedly increased levels of ACTH); scalp hair thinning; proximal muscle weakness associated with muscle loss and resulting in thin extremities; emotional and cognitive changes (e.g., irritability, crying, depression, insomnia, restlessness); hirsutism and hyperandrogenism (e.g., acne); hypertension; osteopenia and osteoporosis with vertebral compression fractures; low back pain (associated with vertebral compression fractures, muscle wasting, and lordotic posture from abdominal weight gain); renal lithiasis; glucose intolerance and diabetes mellitus (caused by glucocorticoid-induced gluconeogenesis and peripheral insulin resistance from increased body fat); polyuria; hyperlipidemia; opportunistic and fungal infections (e.g., mucocutaneous candidiasis, tinea versicolor, pityriasis); menstrual dysfunction (oligomenorrhea or amenorrhea); and infertility. In addition to the preceding features, children with Cushing syndrome may present with generalized obesity and growth retardation.

The clinical features of Cushing syndrome may occur slowly over time; thus, comparison of the patient's current appearance with his or her appearance in old photographs is invaluable. Many of the signs and symptoms in the preceding text are common and are not distinguishing features (e.g., obesity, hypertension, abnormal glucose tolerance, menstrual dysfunction). Clinical suspicion for Cushing syndrome should increase with the simultaneous development of some of the more specific features (e.g., supraclavicular fat pads, wide purple striae, proximal muscle weakness). Because of the catabolic effect of glucocorticoids on skeletal muscle, most patients describe difficulty climbing stairs and an inability to rise from a seated position without using their arms. Cortisol has no androgenic activity, and the presence of hirsutism and acne depends on androgen excess, a finding more common in women with ACTH-dependent Cushing syndrome or adrenocortical carcinoma. The most common form



of facial hair associated with Cushing syndrome in women is thin vellus hair over the sideburn area, cheeks, and upper lip. When Cushing syndrome is caused by an adrenal adenoma, it typically secretes only cortisol.

Standard laboratory studies may reveal fasting hyperglycemia, hyperlipidemia, hypokalemia (from glucocorticoid activity at the mineralocorticoid receptor), leukocytosis with relative lymphopenia, and albuminuria. Marked hypokalemia and severe hypertension are more common in persons with the more severe

hypercortisolism of ectopic ACTH syndrome or adrenocortical carcinoma. When bone mineral density is measured, most patients with Cushing syndrome have osteoporosis. Causation is multifactorial and includes decreased intestinal calcium absorption, increased bone resorption, decreased bone formation, and decreased renal calcium reabsorption. These patients are also at increased risk for thrombophlebitis and thromboembolic events. Untreated Cushing syndrome can be lethal.

## TESTS USED IN THE DIAGNOSIS OF CUSHING SYNDROME

The evaluation of Cushing syndrome can be considered in three steps: (1) case-detection testing, (2) confirmatory testing, and (3) subtype testing.

### CASE-DETECTION TESTING

Case detection testing should start with measurements of 24-hour urinary free cortisol (UFC), 11 PM salivary cortisol, and serum cortisol concentrations measured at 8 AM and 4 PM. Unfortunately, the diagnosis of the Cushing syndrome is usually not straightforward. For example, a normal 24-hour UFC value does not exclude Cushing syndrome—10% to 15% of patients with Cushing syndrome have normal 24-hour UFC excretion in one of four measurements. In addition, all forms of endogenous Cushing syndrome can produce cortisol in a cyclical fashion that confounds the biochemical documentation and interpretation of suppression testing. If the clinical suspicion for Cushing syndrome is high and the 24-hour UFC excretion results are normal, obtaining multiple 24-hour UFC measurements is indicated (every month for 4 months). The baseline 24-hour UFC measurements may also be increased by alcoholism, depression, severe illness, or high urine volume (>4 L). When measured by tandem mass spectrometry, the upper limit of the reference range for 24-hour UFC is 45  $\mu\text{g}$  (124 nmol).

Salivary cortisol concentrations, obtained at 11 PM, are 92% sensitive for Cushing syndrome. Lack of diurnal variation in serum cortisol concentrations is a finding that is also supportive evidence for glucocorticoid secretory autonomy.

The 1-mg overnight dexamethasone suppression test (DST) is an additional case-detection test. At 11 PM, 1 mg of dexamethasone is administered, and serum cortisol is measured the following morning at 8 AM. The serum cortisol concentration in healthy persons suppresses to below 1.8  $\mu\text{g}/\text{dL}$  (50 nmol/L). In addition to Cushing syndrome, causes for cortisol nonsuppression with the overnight 1-mg DST include patient error in taking dexamethasone, increased cortisol-binding globulin (e.g., with estrogen therapy or pregnancy), obesity, ingestion of a drug that accelerates dexamethasone metabolism (e.g., anticonvulsants, phenobarbital, primidone, rifampin), renal failure, alcoholism, psychiatric disorder (e.g., depression), stress, or laboratory error.

### CONFIRMATORY TESTING

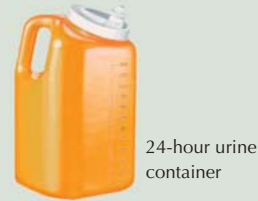Additional confirmatory studies are not needed if the baseline 24-hour UFC excretion is more than 200  $\mu\text{g}/24\text{ h}$  (>552 nmol/24 h) and the clinical picture is consistent with Cushing syndrome. However, when the clinical findings are “soft” and when the 24-hour UFC excretion is less than 200  $\mu\text{g}/24\text{ h}$  (<552 nmol/24 h), autonomous hypercortisolism should be confirmed with the 2-day low-dose DST (dexamethasone, 0.5 mg orally every 6 hours for 48 hours). A 24-hour UFC excretion more than 10  $\mu\text{g}/24\text{ h}$  (28 nmol/24 h) confirms the diagnosis. However, the low-dose DST is far from perfect (79% sensitivity, 74% specificity, and 71% accuracy). The low-dose DST works best when the clinician has a low index of suspicion for Cushing syndrome. If clinical suspicion is high, normal suppression with low-dose DST does not exclude corticotropin (adrenocorticotropic hormone [ACTH])–dependent Cushing syndrome; patients with mild pituitary-dependent disease can demonstrate suppression with low-dose DST.

## THE EVALUATION OF CUSHING SYNDROME CAN BE CONSIDERED IN 3 STEPS:

### 1. Case-detection testing: Case-detection testing should start with:

#### a. Measurements of 24-hour urinary free cortisol (UFC)

If the 24-hour UFC excretion is normal and the clinical suspicion for Cushing syndrome is high, multiple 24-hour UFC measurements are indicated

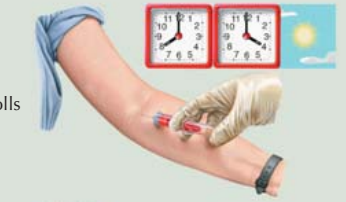

#### b. 11 PM salivary cortisol

The patient places the swab in his/her mouth without touching it with fingers and rolls swab in mouth for 2 minutes. Following this procedure, the swab is returned to the insert, which is introduced into the centrifuge tube and closed with the stopper.

#### c. Diurnal serum cortisols

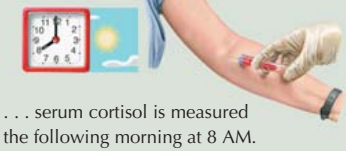Blood samples collected at 8 AM and 4 PM



#### d. Overnight DST



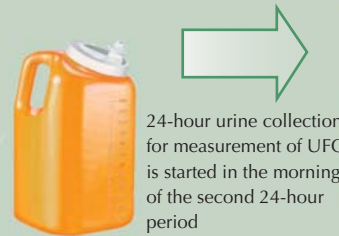
The DST is an additional case-detection test. 1 mg of dexamethasone is taken at 11 PM and...



C. Machado M.D.

### 2. Confirmatory Testing:

When case-detection testing is positive, but the 24-hour UFC excretion is less than 200  $\mu\text{g}/24\text{ h}$ ...



...autonomous hypercortisolism should be confirmed with the 2-day low-dose DST

Dexamethasone 0.5 mg every 6 hours for 48 hours

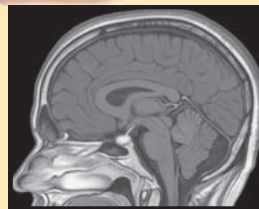
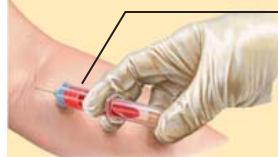| First 24-hour period | Second 24-hour period |
|----------------------|-----------------------|
| 6 AM                 | 6 AM                  |
| 12 PM                | 12 PM                 |
| 6 PM                 | 6 PM                  |
| 12 AM                | 12 AM                 |
|                      | 6 AM                  |

### 3. Subtype Testing: Subtype evaluation tests should not be performed unless Cushing syndrome is confirmed.

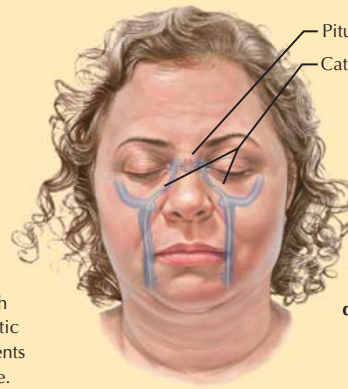
#### a. Plasma ACTH

The plasma ACTH concentration classifies the subtype of hypercortisolism as ACTH-dependent or ACTH-independent.

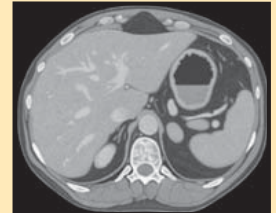
c. Inferior petrosal sinus sampling (IPSS). IPSS should be performed in patients with ACTH-dependent Cushing's syndrome who do not have an obvious pituitary tumor on MRI.



b. Head MRI. A pituitary-dedicated MRI with gadolinium-diethyl-enetriaminepenta-acetic acid enhancement is indicated in all patients with ACTH-dependent Cushing syndrome.



Pituitary  
Catheters in the inferior petrosal sinuses



d. Abdominal CT. In patients with ACTH-independent Cushing's syndrome, computerized imaging of the adrenal glands usually indicates the type of adrenal disease.

### SUBTYPE TESTING

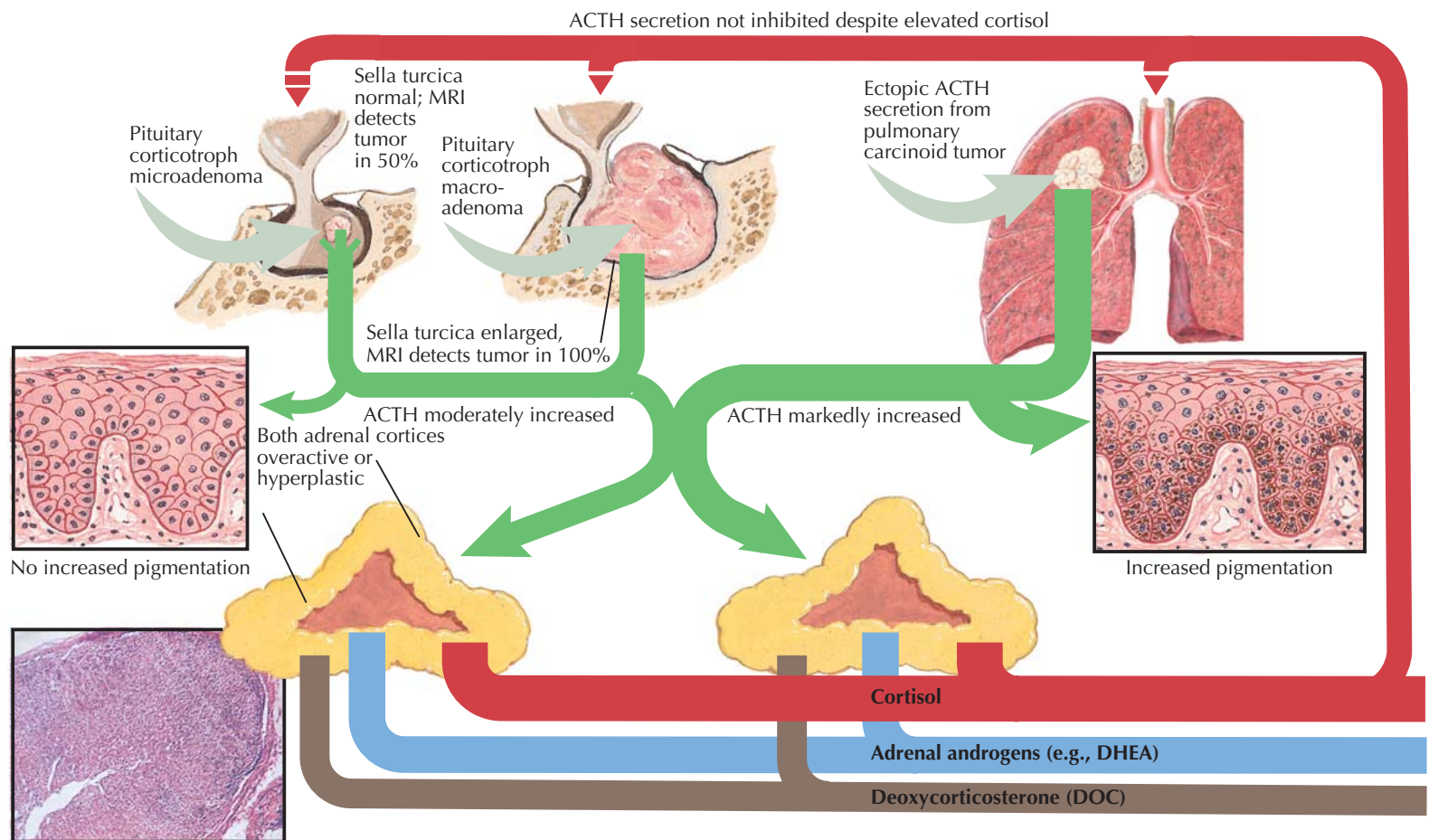
Subtype evaluation tests should not be performed unless Cushing syndrome is confirmed. The application of these tests should be personalized; there is no algorithm that can be applied to all patients with Cushing syndrome. Many of these tests may be superfluous and would delay lifesaving therapy in patients with severe clinical Cushing syndrome.

The plasma ACTH concentration classifies the subtype of hypercortisolism as ACTH dependent (normal to high levels of ACTH) or ACTH independent (undetectable ACTH). A pituitary-dedicated magnetic resonance image (MRI) with gadolinium-diethyl-enetriaminepenta-acetic acid enhancement is indicated in all patients with ACTH-dependent Cushing syndrome. If a definite pituitary tumor is found ( $\geq 4$  mm or larger) and the clinical scenario is consistent with pituitary disease (e.g., female gender, slow onset of disease, and baseline 24-hour UFC <

fivefold increased above the reference range), then additional studies are usually not required before definitive treatment. Smaller apparent pituitary lesions (<4 mm) are common in healthy persons and should be considered nonspecific; inferior petrosal sinus sampling (IPSS) should be performed. Also, if the pituitary MRI findings are normal (seen in ~50% of patients with pituitary-dependent Cushing syndrome), performing IPSS should be seriously considered.

In patients with ACTH-independent Cushing syndrome, computed tomography (CT) imaging of the adrenal glands usually indicates the type of adrenal disease—adrenal adenoma (usually 3–6 cm in diameter), adrenocortical carcinoma (usually 5–20 cm in diameter), bilateral macronodular hyperplasia (massive nodular bilateral adrenal enlargement), or primary pigmented nodular adrenocortical disease (PPNAD) (on CT, the adrenal glands may appear normal or micronodular).





## CUSHING SYNDROME: PATHOPHYSIOLOGY

The underlying pathophysiology of endogenous Cushing syndrome is either corticotropin (adrenocorticotrophic hormone [ACTH]) dependent or ACTH independent.

ACTH-dependent Cushing syndrome results in bilateral adrenocortical hyperplasia. An ACTH-secreting pituitary adenoma (Cushing disease) is the most common cause of endogenous hypercortisolism. Tumorous ectopic hypersecretion of ACTH (ectopic ACTH syndrome) or corticotropin-releasing hormone (CRH) are less common causes. Ectopic CRH hypersecretion is a very rare cause.

ACTH-independent Cushing syndrome may be caused by adrenocortical adenoma, adrenocortical carcinoma, ACTH-independent macronodular adrenal hyperplasia (AIMAH), or primary pigmented nodular adrenocortical disease (PPNAD) (see Plate 3-12).

The clinical presentation of Cushing syndrome is determined by the underlying pathophysiology. When there are markedly excessive adrenal androgens (e.g., with ectopic ACTH syndrome or adrenocortical carcinoma), hirsutism, acne, and scalp hair recession may be prominent. When the cortisol levels are markedly increased (e.g., with ectopic ACTH syndrome), severe hypertension and hypokalemia may be prominent. When the hypercortisolism develops slowly over years (e.g., pituitary-dependent Cushing syndrome, AIMAH, or PPNAD), central obesity, osteoporosis, and proximal muscle weakness may be the most prominent features. With markedly increased levels of ACTH (e.g.,

with ectopic ACTH syndrome or pituitary macroadenoma-dependent Cushing syndrome), skin hyperpigmentation may be a prominent feature.

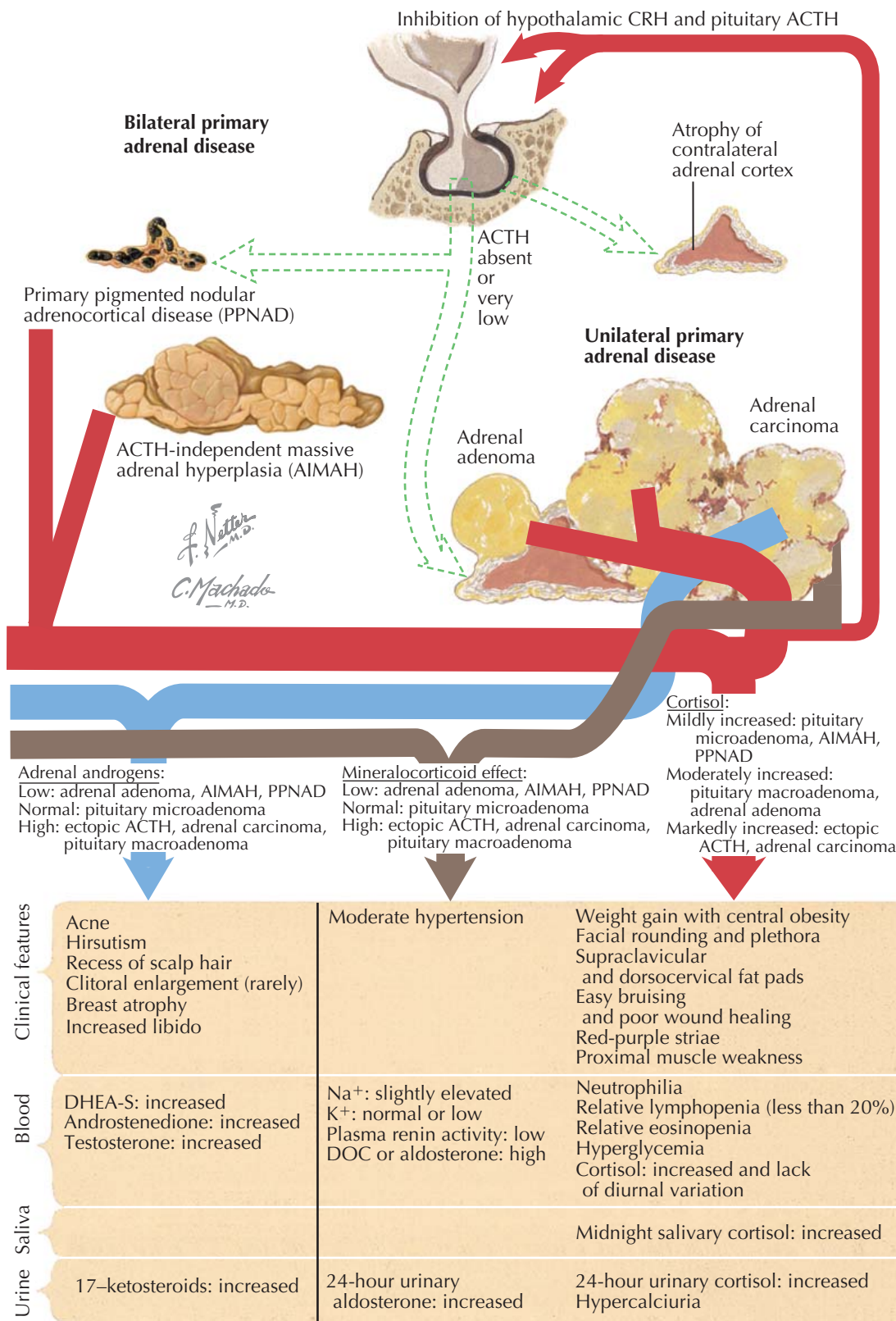
### ADRENOCORTICOTROPIC HORMONE-DEPENDENT CUSHING SYNDROME

Most patients with Cushing syndrome have pituitary-dependent disease. Approximately 95% of pituitary corticotroph tumors are microadenomas ( $\leq 10$  mm), and 50% of the time they are not visible on pituitary-dedicated magnetic resonance imaging. The serum ACTH concentrations in patients with ACTH-secreting microadenomas are typically in the reference range but are inappropriate for the prevailing hypercortisolism. In contrast, the serum ACTH concentrations in patients with ACTH-secreting macroadenomas are usually above the reference range and may result in hyperpigmentation. The increased blood concentrations of ACTH result in bilateral adrenocortical hyperplasia and hypersecretion of cortisol. The adrenal cortices are typically mildly hyperplastic and typically weigh 6 to 12 g each (the normal adrenal gland weight is 4–6 g each). With ectopic ACTH syndrome, the adrenal glands usually weigh more than 12 g each.

The signs and symptoms, as well as the pathology, of Cushing syndrome are primarily caused by excess cortisol, but adrenal androgens may be elevated, and there may be excess mineralocorticoid effect. When a corticotroph adenoma of the pituitary is the source of excess ACTH, histologic sections of the pituitary gland typically demonstrate a pituitary microadenoma that stains for ACTH on immunohistochemistry, and the surrounding nontumorous corticotrophs are hyalinized—known as *Crooke hyaline change*. The latter is also seen

in all forms of hypercortisolism (e.g., ectopic ACTH, adrenal dependent, and exogenous). It is atrophy of the normally ACTH-producing basophilic corticotrophs because of negative feedback by cortisol. The corticotroph adenoma cells are relatively resistant to negative feedback inhibition by cortisol. The blood concentration of dehydroepiandrosterone sulfate (DHEA-S)—an ACTH-dependent adrenal androgen—is mildly increased in patients with pituitary-dependent Cushing syndrome. Selective transnasal endoscopic adenectomy is the treatment of choice for patients with ACTH-secreting pituitary tumors.

The nonpituitary tumor hypersecretion of ACTH in the ectopic ACTH syndrome results in marked bilateral adrenocortical hyperplasia and hypercortisolism. The increased serum cortisol concentrations inhibit hypothalamic CRH and pituitary ACTH secretion. The most common cause of ectopic ACTH syndrome is a bronchial carcinoid tumor. Other tumors that can produce ACTH include small cell lung cancer, medullary thyroid carcinoma, thymic carcinoid, pancreatic neuroendocrine tumors, and pheochromocytoma. The mineralocorticoid excess state caused by ectopic ACTH secretion is related to the high rates of cortisol production that overwhelm  $11\beta$ -hydroxysteroid dehydrogenase type 2 enzyme activity, allowing free access of cortisol to the mineralocorticoid receptor. Deoxycorticosterone (DOC) levels may also be increased in severe ACTH-dependent Cushing syndrome and contribute to the hypertension and hypokalemia in this disorder. Complete resection of the ectopic ACTH-secreting tumor is the treatment of choice to cure Cushing syndrome. If the tumor cannot be resected, bilateral laparoscopic adrenalectomy should be considered.



to a cortisol-secreting adrenal adenoma become atrophic. Adrenal adenomas typically secrete only cortisol, so that the ACTH-dependent adrenal androgens (measured as DHEA-S in the blood and 17-ketosteroids in the urine) are very low (frequently below the assay limit of detection). To generate enough cortisol secretion to cause clinical Cushing syndrome, cortisol-secreting adrenal adenomas are typically at least 2.5 cm in diameter. Unilateral laparoscopic adrenalectomy is the treatment of choice to cure Cushing syndrome associated with solitary adrenocortical adenoma.

A carcinoma of the adrenal cortex may be limited to the adrenal gland or may be metastatic (regional lymph nodes or distant to liver and lungs). Here, too, the adjacent cortex and the contralateral adrenal gland become atrophic. Approximately half of adrenocortical carcinomas are hormone producing; they may hypersecrete a single hormone or multiple hormones (e.g., glucocorticoids, mineralocorticoids, adrenal androgens). With hormonally active adrenocortical carcinomas, the blood concentration of DHEA-S is typically increased. In addition, DOC and aldosterone may be hypersecreted, resulting in hypokalemic hypertension. Open laparotomy with en bloc tumor resection, if possible, is the treatment of choice for adrenocortical carcinomas. However, even with apparent curative surgery, the recurrence rate is high, and the overall 5-year survival is 30%.

AIMAH is bilateral massive macronodular cortical hyperplasia (the adrenal glands typically weigh 100–500 g each). In some cases, the pathogenesis of AIMAH involves inappropriate expression of ectopic receptors (e.g., gastric inhibitory polypeptide, β-adrenergic, vasopressin, serotonin, or luteinizing hormone) or overexpression of ectopic receptors. The mechanism underlying the promiscuous expression of the ectopic receptors is unknown. These patients typically have mild and slowly progressive Cushing syndrome. If feasible, bilateral laparoscopic adrenalectomy is the treatment of choice to cure Cushing syndrome associated with AIMAH.

PPNAD may occur in sporadic or familial forms (as part of the Carney complex) (see Plate 3-12). The hypercortisolism in individuals with PPNAD is caused by multiple, pigmented, autonomously functioning adrenocortical nodules. Patients with PPNAD tend to be young and have mild signs and symptoms related to hypercortisolism, have marked osteoporosis (presumably because of long-standing mild hypercortisolism before clinical detection), and may have cyclic disease. Baseline hormonal evaluation documents increased levels of cortisol in the blood and urine, suppressed ACTH, suppressed serum DHEA-S, and a paradoxical increase in urinary free cortisol with dexamethasone-suppression testing. In patients with PPNAD, the adrenal glands are usually of normal size, and most are studded with black, brown, or red nodules ranging in size from 1 mm to 3 cm. Most of the pigmented nodules are smaller than 4 mm in diameter and are interspersed in the adjacent atrophic cortex. PPNAD may occur as part of the Carney complex, which is characterized by spotty skin pigmentation (pigmented lentigines and blue nevi on the face—including the eyelids, vermilion borders of the lips, the conjunctivae, the sclera—and the labia and scrotum); myxomas (cardiac atrium, cutaneous, and mammary); testicular large-cell calcifying Sertoli cell tumors; growth hormone-secreting pituitary adenomas; and psammomatous melanotic schwannomas. Bilateral laparoscopic adrenalectomy is the treatment of choice to cure Cushing syndrome associated with PPNAD.

**CUSHING SYNDROME: PATHOPHYSIOLOGY (Continued)**

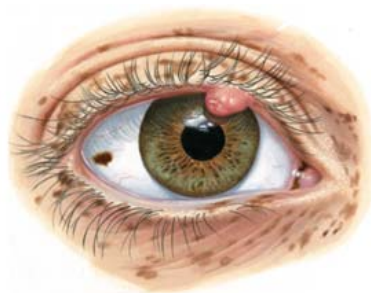In the rare case of ectopic CRH syndrome, the CRH secretion by the ectopic neoplasm (e.g., bronchial carcinoid tumor, pheochromocytoma) causes pituitary corticotroph hyperplasia and hypersecretion of ACTH.

**ADRENOCORTICOTROPIC HORMONE-INDEPENDENT CUSHING SYNDROME**

In the presence of a cortisol-secreting benign cortical adenoma of the adrenal cortex, there is a complete inhibition of hypothalamic CRH and pituitary ACTH production through the negative feedback mechanism by excess cortisol. Thus, the adrenal cortex from the contralateral adrenal and the ipsilateral cortex adjacent



## CUSHING'S SYNDROME IN A PATIENT WITH THE CARNEY COMPLEX



The Carney complex is characterized by spotty skin pigmentation. Pigmented lentigines and blue nevi can be seen on the face—including the eyelids, vermilion borders of the lips, the conjunctivae, the sclera—and the labia and scrotum.

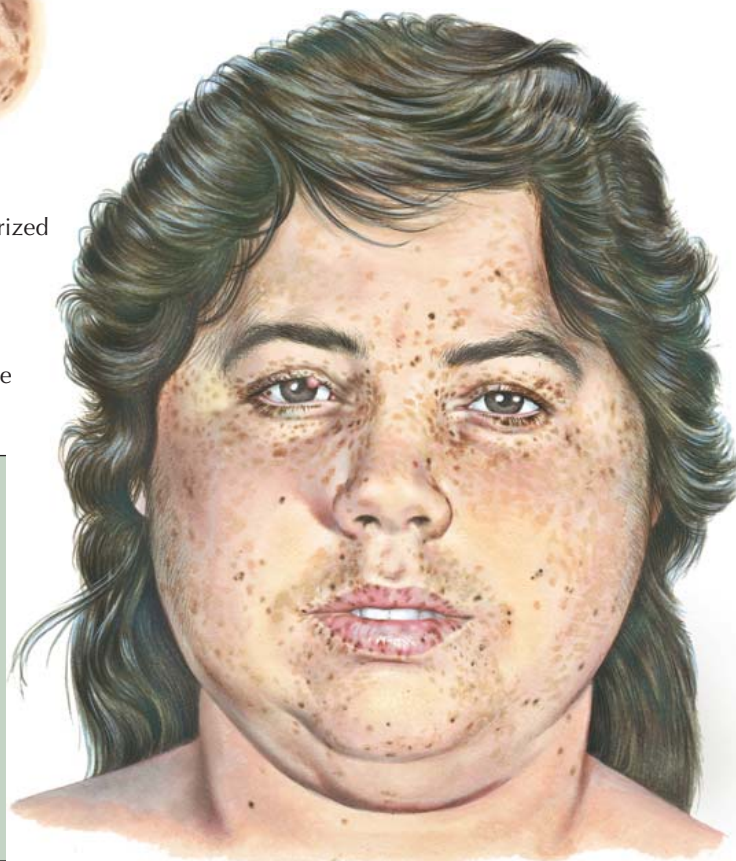
### CUSHING SYNDROME CAUSED BY PRIMARY PIGMENTED NODULAR ADRENOCORTICAL DISEASE

A rare form of Cushing syndrome is corticotropin (adrenocorticotrophic hormone [ACTH])-independent primary pigmented nodular adrenocortical disease (PPNAD), which may be sporadic or familial (as part of the Carney complex). The hypercortisolism in individuals with PPNAD is caused by multiple, pigmented, autonomously functioning adrenocortical nodules. Patients with PPNAD may present with the typical signs and symptoms of hypercortisolism, including central weight gain, hyperglycemia, proximal muscle weakness, purple-red abdominal striae, hypertension, and menstrual cycle disturbance. However, patients with PPNAD tend to be young (i.e., younger than 30 years), have mild signs and symptoms related to hypercortisolism, have marked osteoporosis (presumably because of long-standing mild hypercortisolism before clinical detection), and may have cyclic disease. Baseline hormonal evaluation documents increased levels of cortisol in the blood and urine, suppressed ACTH, suppressed serum dehydroepiandrosterone sulfate, and a paradoxical increase in urinary free cortisol with dexamethasone suppression testing.

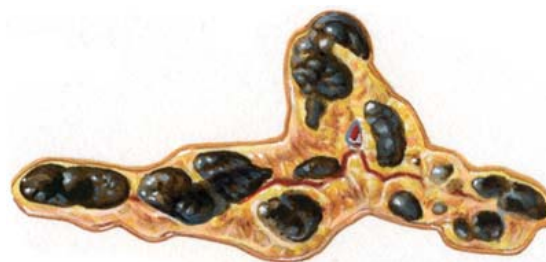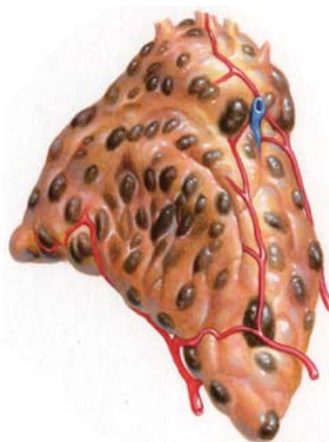
In patients with this disease, the adrenal glands are usually of normal size, and most are studded with black, brown, or red nodules ranging in size from 1 mm to 3 cm. Most of the pigmented nodules are smaller than 4 mm in diameter and are interspersed in the adjacent atrophic cortex. The weight of a PPNAD adrenal gland is either normal (e.g., 4 g) or mildly enlarged (e.g., 5–15 g). The cells in the PPNAD nodules contain granular brown pigment (lipofuscin) and are globular with clear or eosinophilic cytoplasm. PPNAD may occur as part of the Carney complex, which is characterized by spotty skin pigmentation (pigmented lentigines and blue nevi on the face—including the eyelids, vermilion borders of the lips, the conjunctivae, and the sclera—and the labia and scrotum); myxomas (cardiac atrium, cutaneous, and mammary); testicular large-cell calcifying Sertoli cell tumors; growth hormone-secreting pituitary adenomas; and psammomatous melanotic schwannomas.

Additional features of the Carney complex can include:

- ▶ Myxomas: cardiac atrium, cutaneous (e.g., eyelid), and mammary
- ▶ Testicular large-cell calcifying Sertoli cell tumors
- ▶ Growth hormone-secreting pituitary adenomas
- ▶ Psammomatous melanotic schwannomas



C. Machado  
—M.D.



PPNAD adrenal glands are usually of normal size, and most are studded with black, brown, or red nodules. Most of the pigmented nodules are less than 4 mm in diameter and interspersed in the adjacent atrophic cortex.

Approximately half of the patients diagnosed with PPNAD prove to have the Carney complex. Approximately 60% of the cases of the Carney complex are familial. Thus far, mutations in three genes have been associated with PPNAD: *PRKARIA*, *PDE11A*, and *MYH8*. However, because there are families with Carney complex that do not have mutations in one of these three genes, studies are ongoing to identify additional loci. Heterozygous inactivating mutations in *PRKARIA*—an apparent tumor suppressor gene that

encodes the protein kinase A regulatory 1 $\alpha$  subunit—are found in approximately 70% of patients with the Carney complex. In most familial cases, the Carney complex appears to be autosomal dominant in inheritance. Germline mutations in *PRKARIA* may also be present in patients with isolated PPNAD.

Bilateral laparoscopic adrenalectomy is the treatment of choice to cure Cushing syndrome associated with PPNAD.

## MAJOR BLOCKS IN ABNORMAL STEROIDOGENESIS

Genetically determined deficiencies in the enzymes responsible for the biosynthesis of cortisol are referred to as *blocks in adrenal steroidogenesis*. Congenital adrenal hyperplasia (CAH) refers to clinical disorders associated with the decreased production of cortisol and the secondary corticotropin (adrenocorticotropic hormone [ACTH])–driven increased production of precursor steroids that have precursor-specific activity at the mineralocorticoid or androgen receptors.

### I. CONGENITAL LIPOID HYPERPLASIA

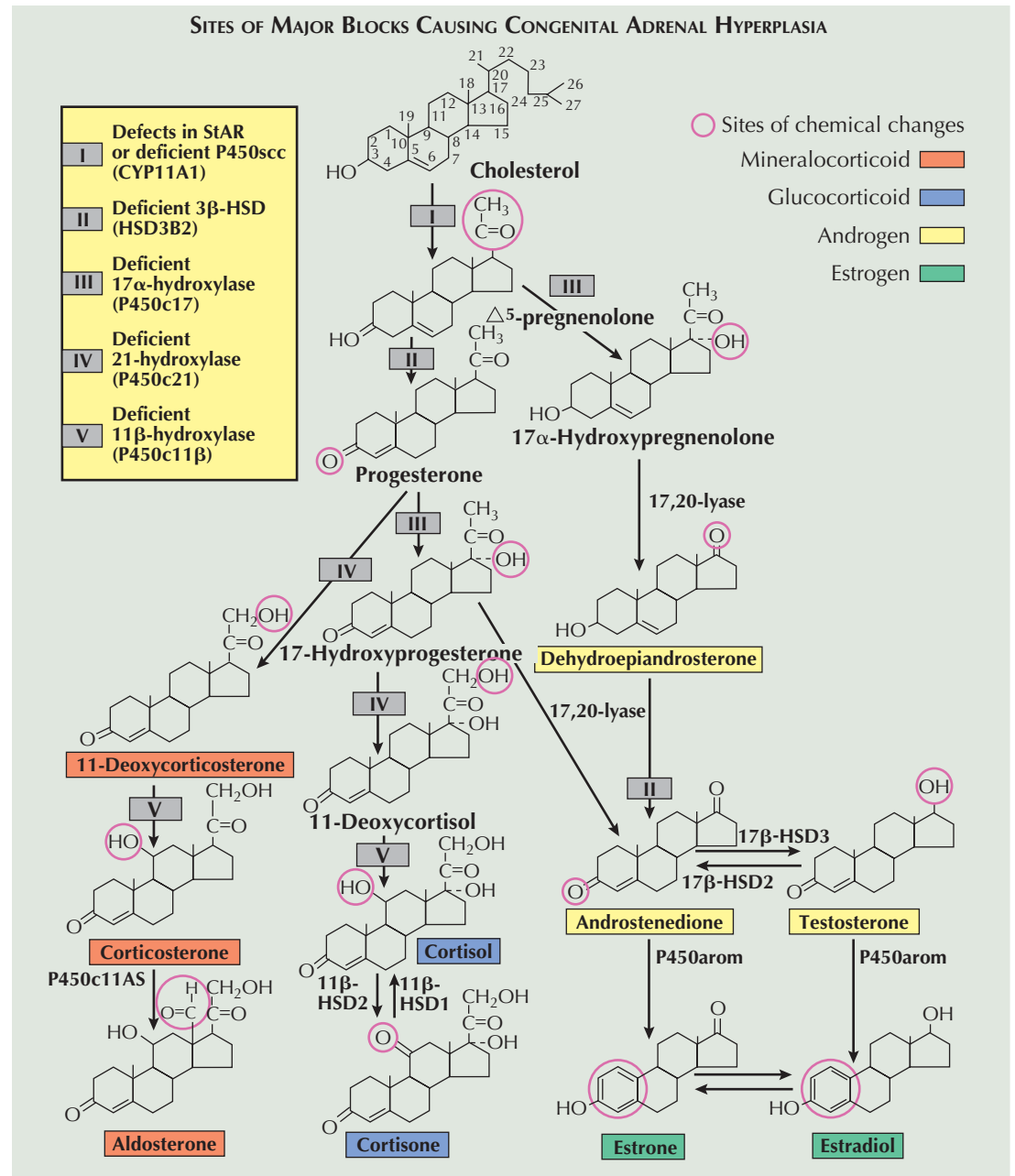
The steroidogenic acute regulatory protein (StAR) mobilizes cholesterol from the outer mitochondrial membrane to the inner mitochondrial membrane, where the rate-limiting steroid side-chain cleavage enzyme (P450<sub>scc</sub>) cleaves cholesterol to pregnenolone. Mutations in the genes encoding either StAR or P450<sub>scc</sub> result in congenital lipoid adrenal hyperplasia, the most severe form of CAH. This disorder is characterized by a deficiency in all adrenal and gonadal steroid hormones and an ACTH-driven buildup of cholesterol esters in the adrenal cortex. Congenital lipoid adrenal hyperplasia is an autosomal recessive disorder usually caused by mutations in the gene that encodes StAR. The steroidogenic defect progresses with age, suggesting that the cholesterol ester accumulation causes further dysfunction of the adrenocortical cells.

### II. 3 $\beta$ -HYDROXYSTEROID DEHYDROGENASE DEFICIENCY

Pregnenolone is converted to progesterone by 3 $\beta$ -hydroxysteroid dehydrogenase (3 $\beta$ -HSD) by a reaction involving dehydrogenation of the 3-hydroxyl group to a keto group and isomerization of the double bond at C5. The type I isoenzyme of 3 $\beta$ -HSD (3 $\beta$ -HSD1) is present in the placenta, liver, and brain, and the type II isoenzyme of 3 $\beta$ -HSD (3 $\beta$ -HSD2) is present in the adrenal cortex and gonads. Mutations in the 3 $\beta$ -HSD2 gene (*HSD3B2*) cause a rare form of CAH associated with deficiencies in cortisol, aldosterone, and gonadal steroids. Because of the block at 3 $\beta$ -HSD2, there is an accumulation of  $\Delta^5$ -pregnenolone, 17 $\alpha$ -hydroxypregnenolone, dehydroepiandrosterone (DHEA), and DHEA sulfate (DHEA-S).

### III. 17 $\alpha$ -HYDROXYLASE DEFICIENCY

Progesterone is hydroxylated to 17-hydroxyprogesterone through the activity of 17 $\alpha$ -hydroxylase (P450c17). 17-Hydroxylation is a prerequisite for glucocorticoid synthesis (the zona glomerulosa does not express P450c17). P450c17 also possesses 17,20-lyase activity, which results in the production of the C19 adrenal androgens (DHEA and androstenedione). Deficiency of P450c17 is another rare form of CAH caused by mutations in *CYP17A1*. It is inherited in an autosomal recessive fashion and causes an ACTH-driven increased production of 11-deoxycorticosterone and corticosterone—both of which have some activity at the mineralocorticoid receptor—leading to hypokalemia and hypertension. The deficiency in 17,20-lyase activity results in decreased androgen and estrogen production because the androgen substrate is not present to be aromatized to estrogens.



### IV. 21-HYDROXYLASE DEFICIENCY

21-Hydroxylation of either progesterone in the zona glomerulosa or 17-hydroxyprogesterone in the zona fasciculata is performed by 21-hydroxylase (P450c21) to yield 11-deoxycorticosterone or 11-deoxycortisol, respectively. Deficiency of P450c21 is the most common form of CAH, accounting for more than 90% of cases. 21-Hydroxylase deficiency is inherited in an autosomal recessive fashion and leads to an ACTH-driven increased production of progesterone, 17-hydroxyprogesterone, and adrenal androgens.

### V. 11 $\beta$ -HYDROXYLASE DEFICIENCY

The final step in cortisol biosynthesis is the conversion of 11-deoxycortisol to cortisol by 11 $\beta$ -hydroxylase (P450c11 $\beta$ ). Deficiency of P450c11 $\beta$  is the second most common form of CAH. 11 $\beta$ -Hydroxylase deficiency is inherited in an autosomal recessive fashion and leads to an ACTH-driven buildup of 11-deoxycortisol, 11-deoxycorticosterone, and adrenal androgens. This disorder is caused by mutations in the *CYP11B1* gene.

### Additional Enzymatic Steps

In the zona glomerulosa, aldosterone synthase (P450c11AS) converts corticosterone to aldosterone via the intermediate 18-hydroxycorticosterone. Whereas aldosterone secretion is confined to the zona glomerulosa through the restricted expression of aldosterone synthase, the zona glomerulosa cannot synthesize cortisol because it does not express 17 $\alpha$ -hydroxylase. In the zona reticularis, high levels of cytochrome b5 facilitate 17,20-lyase activity on P450c17 and the production of DHEA. DHEA is either converted to androstenedione by 3 $\beta$ -HSD or sulfated in the zona reticularis by the DHEA sulfotransferase to form DHEA-S. Androstenedione may be converted to testosterone by 17 $\beta$ -ketosteroid reductase (17 $\beta$ -HSD3) in the adrenal glands or gonads. The interconversion of cortisol and cortisone via 11 $\beta$ -hydroxysteroid dehydrogenase (11 $\beta$ -HSD) regulates local corticosteroid hormone action. There are two distinct 11 $\beta$ -HSD isozymes. Type 1 (11 $\beta$ -HSD1) is expressed primarily in the liver and converts cortisone to cortisol; type 2 (11 $\beta$ -HSD2) is found in the mineralocorticoid receptor in the kidney, colon, and salivary glands and inactivates cortisol to cortisone.



## CLASSIC CONGENITAL ADRENAL HYPERPLASIA

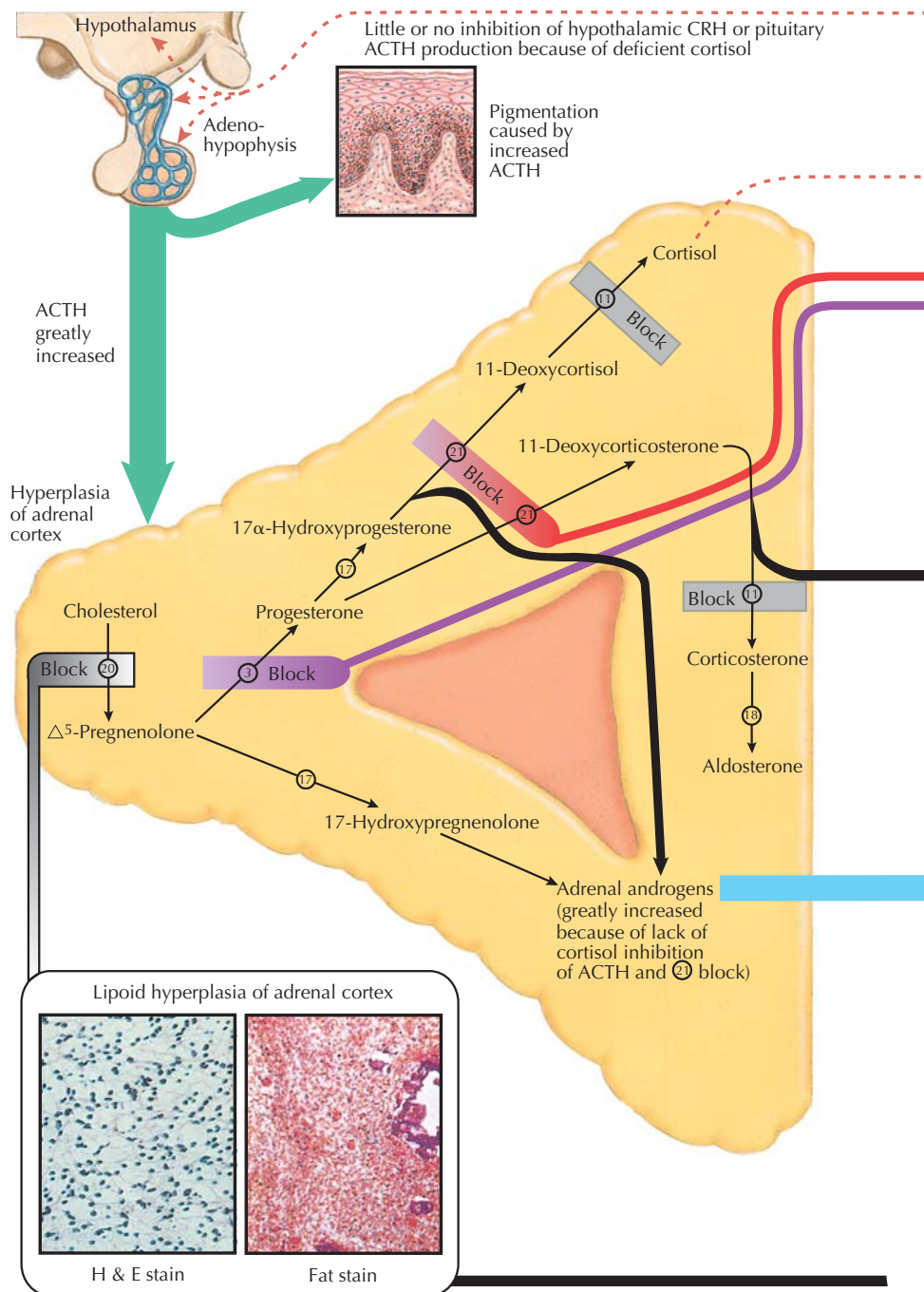
Congenital adrenal hyperplasia (CAH) refers to the clinical disorders associated with the decreased production of cortisol because of blocks in the cortisol synthetic enzyme pathway (see Plate 3-13). With decreased cortisol production, there is a secondary corticotropin (adrenocorticotropic hormone [ACTH])–driven buildup of precursor steroids that have precursor-specific activity at the mineralocorticoid or androgen receptors. In addition, depending on the site of enzymatic deficiency, deficiency of mineralocorticoid or androgen production may occur. Depending on the mutation and resultant degree of protein dysfunction, the deficiency in adrenal enzyme activity may be severe or mild. The most severe forms of CAH are referred to as *classic*, and the milder forms of CAH are referred to as *late-onset* or *nonclassic* (see Plate 3-16).

## CONGENITAL LIPOID HYPERPLASIA

Mutations in the genes encoding either the steroidogenic acute regulatory protein (StAR) or the steroid side-chain cleavage enzyme (P450<sub>scc</sub>) result in congenital lipid adrenal hyperplasia, the most severe form of CAH. This disorder is characterized by a deficiency in all adrenal and gonadal steroid hormones and an ACTH-driven buildup of cholesterol esters in the adrenal cortex. Neonates with congenital lipid hyperplasia usually present with signs and symptoms of marked adrenocortical insufficiency (e.g., hyperemesis, hypotension, hyperkalemia, hyponatremia) shortly after birth. Because of the lack of testicular androgen production, infants with a 46,XY karyotype have female external genitalia (see Plates 4-13 and 4-15). Laboratory testing shows low serum cortisol and plasma aldosterone concentrations and increased serum ACTH concentration and plasma renin activity. If not recognized and treated, congenital lipid hyperplasia is lethal. Treatment consists of glucocorticoid and mineralocorticoid replacement.

## 3 $\beta$ -HYDROXYSTEROID DEHYDROGENASE DEFICIENCY

Pregnenolone is converted to progesterone by 3 $\beta$ -hydroxysteroid dehydrogenase (3 $\beta$ -HSD). Mutations in the 3 $\beta$ -HSD2 gene (*HSD3B2*) cause a rare form of CAH associated with deficiency in cortisol, aldosterone, and gonadal steroids. The clinical presentation of CAH caused by 3 $\beta$ -HSD deficiency is similar to that of StAR deficiency—infants present with signs and symptoms of both cortisol and aldosterone deficiencies. The excess dehydroepiandrosterone (DHEA) may cause mild virilization in infants with a 46,XX karyotype. The phenotype in infants with a 46,XY karyotype varies from normal to hypospadias to female external genitalia. Late-onset forms of 3 $\beta$ -HSD also exist (see Plate 3-16). In addition to hyperkalemia, hyponatremia, cortisol deficiency, and aldosterone deficiency, laboratory studies show increased baseline blood concentrations of DHEA and DHEA sulfate (DHEA-S). Because most of the adrenal androstenedione production is dependent on the conversion of DHEA to androstenedione by 3 $\beta$ -HSD, androstenedione levels are not increased in this form of CAH. Exaggerated increases in the blood concentrations of  $\Delta^5$ -pregnenolone and DHEA are observed with the cosyntropin-stimulation test.

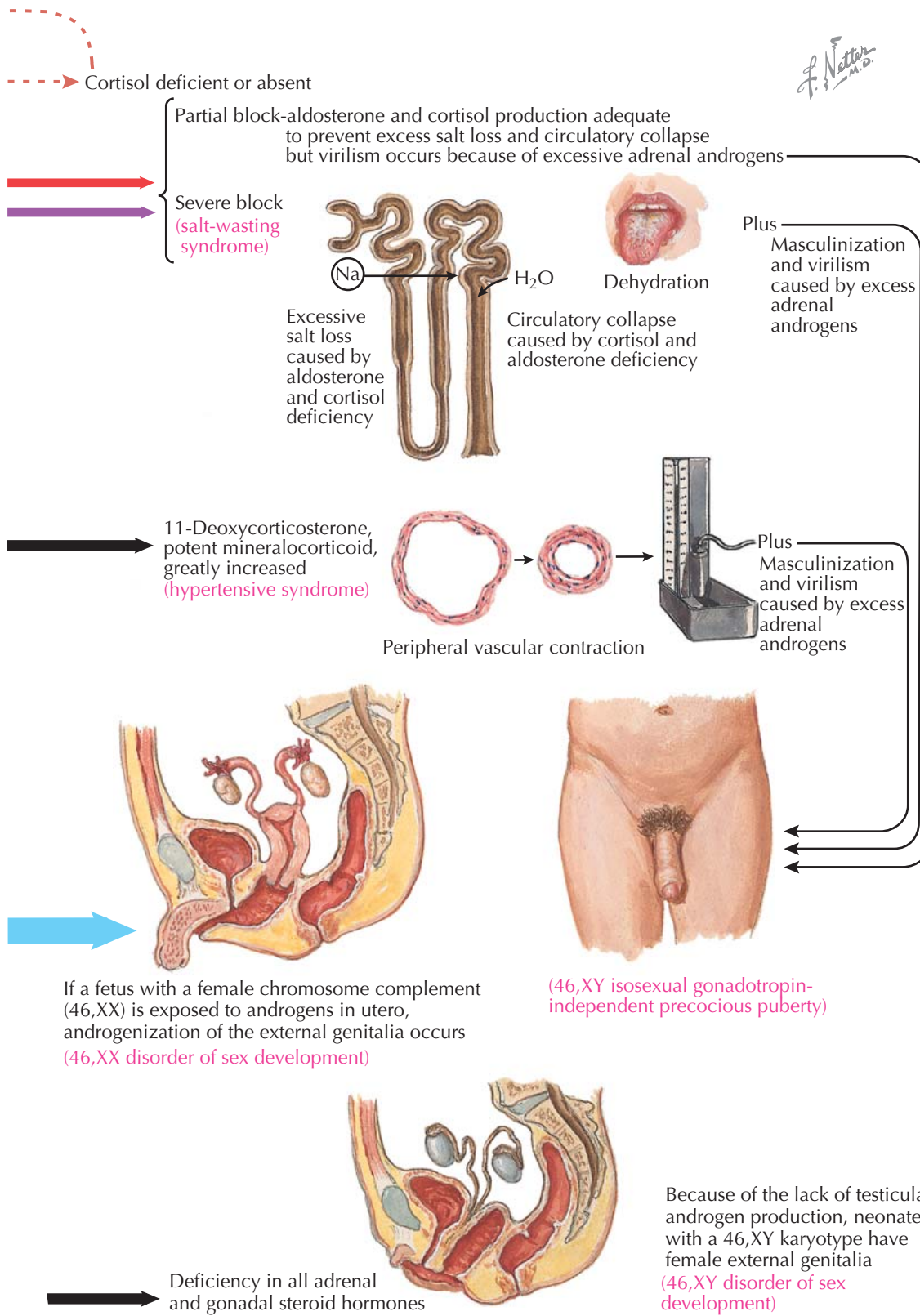


Affected patients are treated with glucocorticoid and mineralocorticoid replacement and, at puberty, with gonadal steroid replacement.

## 17 $\alpha$ -HYDROXYLASE DEFICIENCY

Progesterone is hydroxylated to 17-hydroxyprogesterone through the activity of 17 $\alpha$ -hydroxylase (P450<sub>c17</sub>). 17 $\alpha$ -Hydroxylase deficiency is a rare form of CAH caused by mutations in *CYP17A1*. It is inherited in an autosomal recessive fashion and causes ACTH-driven increased production of 11-deoxycorticosterone and corticosterone—both of which have some activity at the mineralocorticoid receptor—leading to hypokalemia and hypertension. The deficiency in 17,20-lyase activity results in decreased androgen and estrogen production because the androgen substrate is not present to be aromatized to estrogens. The clinical presentation may

not occur until puberty when individuals with a 46,XX karyotype are found to have primary amenorrhea, absent secondary sexual development, hypertension, and hypokalemia. Individuals with a 46,XY karyotype, who are phenotypically female, are usually not evaluated until the lack of pubertal development; they have female external genitalia, intraabdominal testes, short vagina, absent uterus and fallopian tubes, hypertension, and hypokalemia (see Plate 4-15). Laboratory studies show hypokalemia, low plasma renin activity, and low plasma aldosterone concentration. Blood concentrations of ACTH, progesterone, 11-deoxycorticosterone, luteinizing hormone, and follicle-stimulating hormone are increased. Decreased blood concentrations of 17-hydroxyprogesterone, 11-deoxycortisol, cortisol, DHEA, DHEA-S, androstenedione, testosterone, and estradiol are observed. Treatment includes replacement of glucocorticoid and gonadal steroids.



*F. Netter M.D.*

both forms of classic 21-hydroxylase deficiency, a markedly increased (greater than sixfold above the upper limit of the reference range) blood concentration of 17-hydroxyprogesterone is diagnostic. In borderline cases, a cosyntropin-stimulation test may be needed to demonstrate the enzymatic block. Additional blood tests usually show low blood concentrations of 11-deoxycortisol, cortisol, 11-deoxycorticosterone, and aldosterone (the latter two in the salt-wasting form). Increased blood concentrations of the following are usually observed: progesterone, 17-hydroxyprogesterone, androstenedione, and ACTH. Plasma renin activity is usually increased. Newborn screening for 21-hydroxylase deficiency by measuring 17-hydroxyprogesterone in a dried blood sample is routinely performed in the United States and in many other countries.

**11β-HYDROXYLASE DEFICIENCY**

Deficiency of 11β-hydroxylase (P450c11β) is the second most common form of CAH. With more severe defects in 11β-hydroxylase function, neonates with a 46,XX karyotype are born with ambiguous genitalia, and neonates with a 46,XY karyotype are born with penile enlargement. With *CYP11B1* mutations that result in decreased, but not absent, 11β-hydroxylase activity, affected individuals may present later in childhood with hypertension and precocious puberty or in young adulthood with hypertension, acne, hirsutism, and oligomenorrhea or amenorrhea. Although 11-deoxycortisol has no glucocorticoid activity, 11-deoxycorticosterone has mineralocorticoid activity, and when produced in excess, it can cause hypertension, hypokalemia, low plasma renin activity, and low plasma aldosterone concentration. Additional findings on laboratory testing in patients with 11β-hydroxylase deficiency include increased blood concentrations of 11-deoxycortisol, 11-deoxycorticosterone, DHEA, DHEA-S, androstenedione, and testosterone.

**APPARENT MINERALOCORTICOID EXCESS**

The interconversion of cortisol and cortisone via 11β-hydroxysteroid dehydrogenase (11β-HSD) regulates local corticosteroid hormone action. There are two distinct 11β-HSD isozymes. Type 1 (11β-HSD1) converts cortisone to cortisol; type 2 (11β-HSD2) inactivates cortisol to cortisone. Apparent mineralocorticoid excess is the result of impaired 11β-HSD2 activity. Cortisol can be a potent mineralocorticoid, and as a result of the enzyme deficiency, high levels of cortisol accumulate in the kidneys. Thus, 11β-HSD2 normally excludes physiologic glucocorticoids from the nonselective mineralocorticoid receptor by converting them to the inactive 11-keto compound, cortisone. Decreased 11β-HSD2 activity may be hereditary or secondary to pharmacologic inhibition of enzyme activity by glycyrrhizic acid, the active component of licorice root (*Glycyrrhiza glabra*). The clinical phenotype of patients with apparent mineralocorticoid excess includes hypertension, hypokalemia, metabolic alkalosis, low plasma renin activity, low plasma aldosterone concentration, and normal plasma cortisol levels. The diagnosis is confirmed by demonstrating an abnormal ratio of cortisol to cortisone (e.g., >10:1) in a 24-hour urine collection. The apparent mineralocorticoid excess state caused by ectopic ACTH secretion, seen in patients with Cushing syndrome, is related to the high rates of cortisol production that overwhelm 11β-HSD2 activity.

**CLASSIC CONGENITAL ADRENAL HYPERPLASIA (Continued)**

**21-HYDROXYLASE DEFICIENCY**

21-Hydroxylation of either progesterone in the zona glomerulosa or 17-hydroxyprogesterone in the zona fasciculata is performed by 21-hydroxylase (P450c21) to yield deoxycorticosterone or 11-deoxycortisol,

respectively. Deficiency of P450c21 is the most common form of CAH, accounting for more than 90% of all cases. Classic 21-hydroxylase deficiency presents in infancy with typical signs and symptoms of adrenal insufficiency and androgen excess. Ambiguous genitalia are found in infants with a 46,XX karyotype (see Plate 4-12). Depending on the severity of the enzymatic defect and its effect on the mineralocorticoid synthetic pathway, classic 21-hydroxylase deficiency may be referred to as *salt wasting* or *simple virilizing*. In



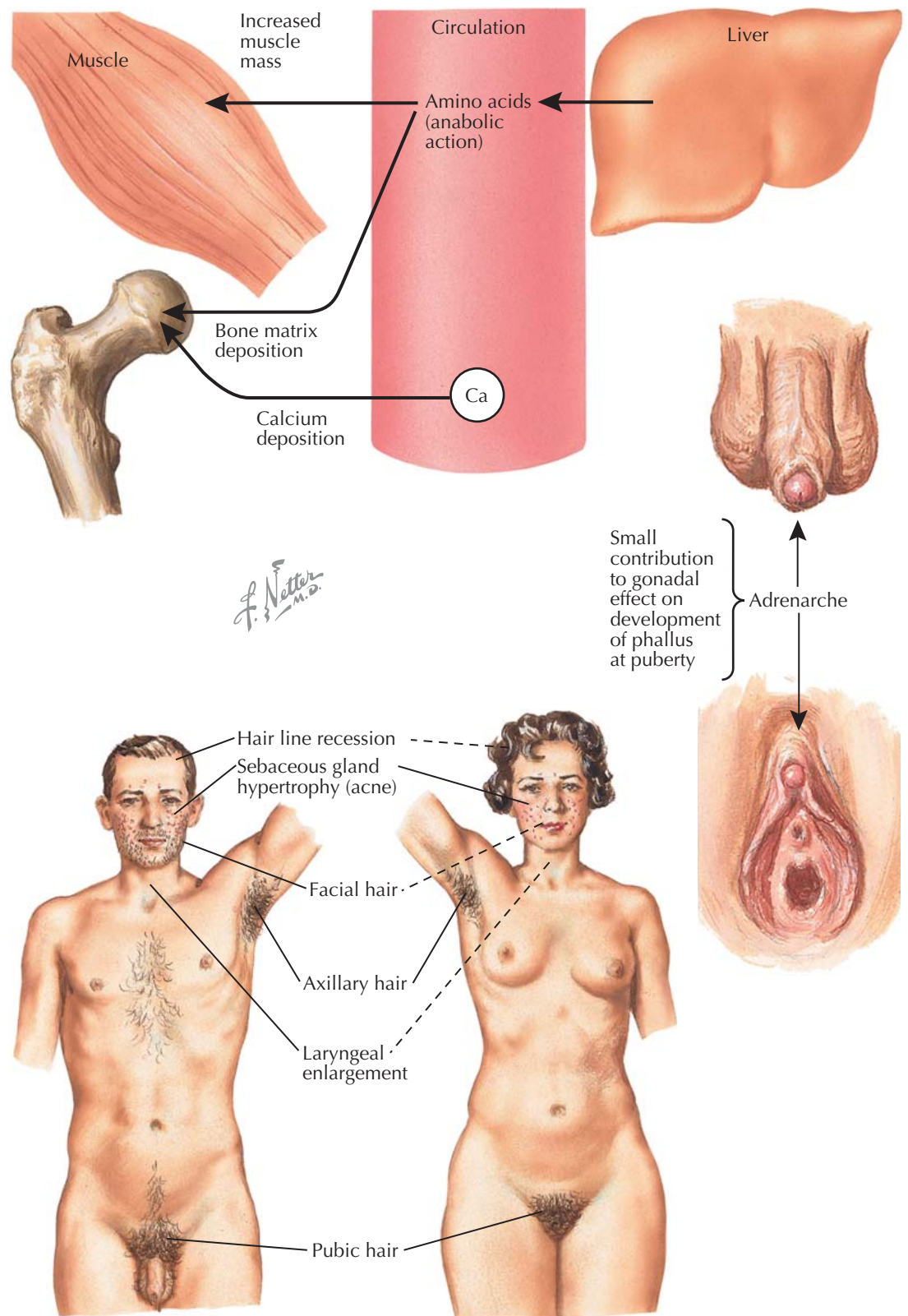
## THE BIOLOGIC ACTIONS OF ADRENAL ANDROGENS

Androgens produced by the adrenal cortex in both sexes include dehydroepiandrosterone (DHEA), DHEA sulfate (DHEA-S), androstenedione, and testosterone. In varying degrees, adrenal androgens have an anabolic effect leading to increased muscle mass. They stimulate male sex characteristics, including an increase in facial hair, recession of the scalp hairline, hypertrophy of sebaceous glands and acne, enlargement of larynx resulting in the deep male voice, secondary sex hair growth in axillary and pubic regions, hair growth over the chest and around the nipples, and development of the phallus in puberty. Although the main source of androgens in men is gonadal, in most women, the adrenal glands are the primary source of androgens. Indeed, a key sign of primary adrenal failure in women is loss of axillary and pubic hair.

Adrenarche is a biochemical event, defined as the increase in adrenal androgens that occurs between 6 and 8 years of age. Pubarche is a phenotypic event, defined as the growth of sexual hair in the suprapubic area and the axillae. Adrenal androgens are the primary factors that facilitate pubic and axillary hair growth in girls; labial hair usually precedes axillary hair growth. In boys, the role of adrenal androgens is not as clear because of the dominant role of testicular testosterone production. Adrenal androgens appear to be an important factor in the onset of puberty and the maturation of the hypothalamic-pituitary-gonadal complex. Adrenarche and pubarche are considered premature when pubic hair growth appears before age 8 years in girls and before age 9 years in boys. Premature adrenarche, which is more common in girls, is associated with taller height, increased body odor and acne, and a bone age that is advanced by 1 to 2 years.

Adrenal androgens may have additional physiologic roles yet to be delineated. DHEA-S may serve as a large sex steroid depot. DHEA-S is converted to testosterone and estradiol in peripheral tissues; a sulfatase converts DHEA-S to DHEA, which is then converted to androstenedione by 3 $\beta$ -hydroxysteroid dehydrogenase. Androstenedione is metabolized to either testosterone or estradiol by 17 $\beta$ -hydroxysteroid dehydrogenase and P450 aromatase, respectively. DHEA may also act as a neurosteroid in the central nervous system; however, a DHEA-specific receptor has not yet been identified.

Androgenic (anabolic) steroids have been used surreptitiously by athletes to increase muscle mass and to enhance physical performance. The prevalence of their use is difficult to determine, but approximately 6% of high school boys and 2% of high school girls have reported using androgenic steroids at least once. Anabolic steroids are prohibited by the International Olympic Committee and the National Collegiate Athletic Association for use in competition. Athletes often take several performance-enhancing drugs in various patterns (e.g., simultaneously, consecutively, escalating doses, or intermittently) in an attempt to increase the



overall effect on performance. Adverse effects include suppression of endogenous testicular function (resulting in transient infertility and decreased testicular size), gynecomastia (because testosterone is aromatized to estradiol), erythrocytosis, increased liver enzymes and peliosis hepatitis (only with oral 17- $\alpha$ -alkylated androgens), mood disorders and aggressive behavior, decreased serum high-density lipoprotein cholesterol concentrations, increased low-density lipoprotein cholesterol concentrations, virilization in women (e.g.,

hirsutism, temporal hair recession, acne, deepening of the voice, and clitoral enlargement), premature epiphyseal fusion, and stunting of growth in adolescents. Athletes may take additional agents to mask the visible side effects of high-dose anabolic steroids; for example, athletes may take human chorionic gonadotropin to counteract the decrease in testicular size, an aromatase inhibitor or estrogen receptor antagonist to counteract the gynecomastia, and a 5 $\alpha$ -reductase inhibitor to prevent balding and acne.

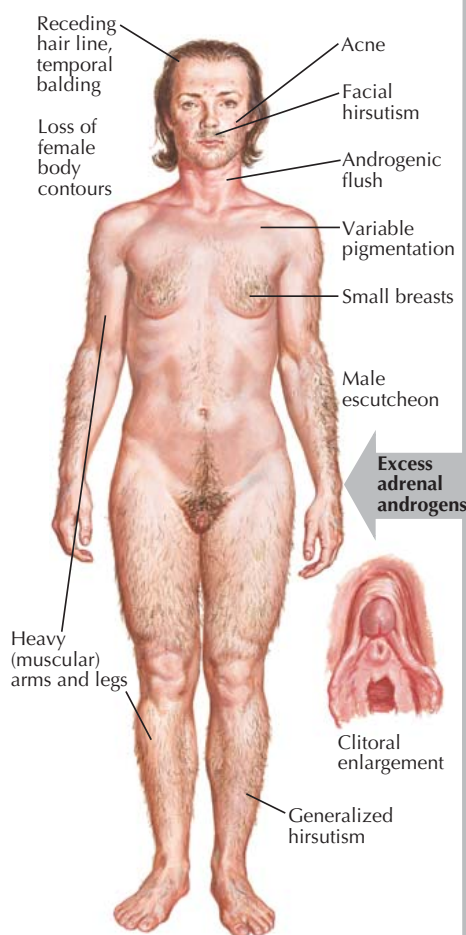
## ADULT ANDROGENITAL SYNDROMES

Adult adrenogenital syndromes are disorders associated with excess adrenal androgen effects in adults. The causes of adrenal androgen excess in adults include late-onset (nonclassic) congenital adrenal hyperplasia (CAH), familial glucocorticoid resistance, Cushing syndrome, and androgen-secreting adrenal neoplasms. Because of the presence of more potent testicular androgens, adrenal androgen excess in men may go undetected because of lack of symptomatology. However, women with adrenal androgen excess usually present with varying degrees of masculinization and menstrual dysfunction (see Plates 4-14 and 4-15).

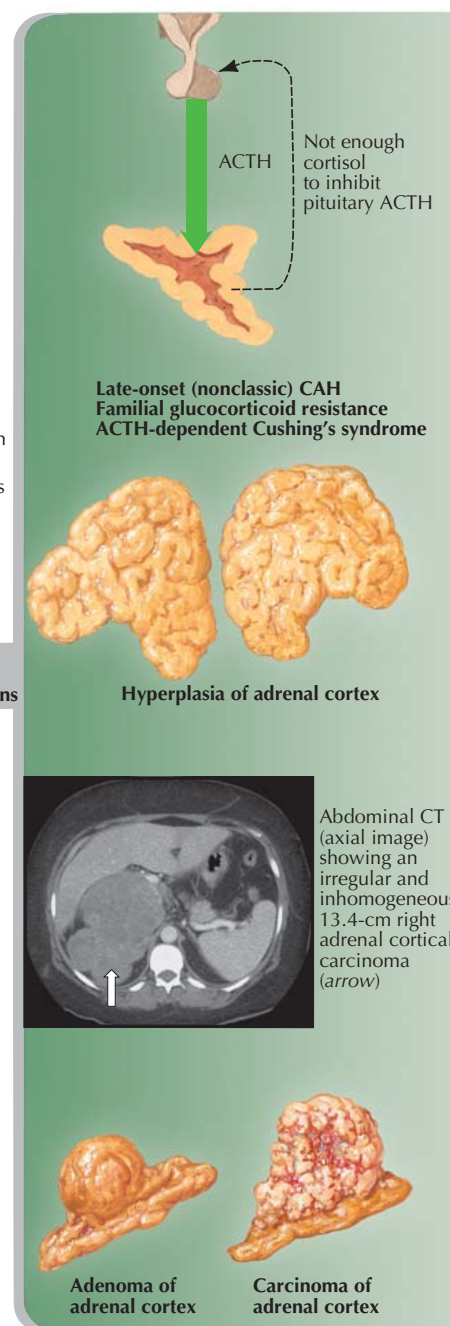
Hirsutism is defined as excessive male-pattern coarse hair growth in women (e.g., cheeks, upper lip, chin, midline chest, male escutcheon, inner thighs, and midline lower back). Virilization, reflecting a more severe form of androgen excess, is defined as the development of signs and symptoms of masculinization in women. The signs and symptoms of masculinization include increased muscle bulk, loss of female body contours, deepening of the voice, breast atrophy, clitoromegaly, temporal balding, and androgenic flush (plethora of the face, neck, and upper chest). The normal size of the clitoris is smaller than 10 mm in length and smaller than 7 mm in width.

### LATE-ONSET (NONCLASSIC) CONGENITAL ADRENAL HYPERPLASIA

Partial enzymatic blocks in  $3\beta$ -hydroxysteroid dehydrogenase, 21-hydroxylase, and  $11\beta$ -hydroxylase may all present in late-onset or nonclassic forms (also referred to as adult-onset, attenuated, incomplete, and cryptic adrenal hyperplasia) and be responsible for hirsutism, menstrual irregularities, and varying degrees of virilization. Late-onset  $3\beta$ -hydroxysteroid dehydrogenase deficiency should be suspected in symptomatic women who have markedly increased blood concentrations of dehydroepiandrosterone sulfate (DHEA-S) and low levels of androstenedione. The diagnosis can be confirmed with cosyntropin-stimulation testing and demonstration of a marked increase in 17-hydroxyprogrenolone and DHEA but no increase in 17-hydroxyprogesterone and androstenedione. Late-onset 21-hydroxylase deficiency may have an identical presentation to that of  $3\beta$ -hydroxysteroid dehydrogenase deficiency, but the laboratory profile is different. With 21-hydroxylase deficiency, the baseline levels of progesterone, 17-hydroxyprogesterone, and androstenedione are increased above the reference range, and all three increase dramatically after cosyntropin stimulation. A partial block at  $11\beta$ -hydroxylase is associated with increased blood concentrations of 11-deoxycortisol, 11-deoxycorticosterone, DHEA, and androstenedione. In addition to symptoms related to androgen excess, individuals with partial  $11\beta$ -hydroxylase deficiency may have hypertension and hypokalemia. Cosyntropin-stimulation testing may be needed to confirm the block at  $11\beta$ -hydroxylase. Treatment for late-onset CAH includes glucocorticoid replacement to suppress the excess corticotropin (adrenocorticotropic hormone [ACTH]) secretion, with the goal of avoiding overtreatment and resultant Cushing syndrome.



*F. Netter M.D.*



### FAMILIAL GLUCOCORTICOID RESISTANCE

Familial glucocorticoid resistance is caused by mutations in the glucocorticoid receptor gene. These mutations inhibit the action of cortisol, leading to increased ACTH secretion and adrenocortical hyperplasia. With the increased mass action of cortisol production, there is increased production of adrenal androgens (e.g., DHEA) and mineralocorticoids (e.g., 11-deoxycorticosterone). Thus, individuals with familial glucocorticoid resistance present clinically in a very similar way to those with late-onset  $11\beta$ -hydroxylase deficiency with signs and symptoms of androgen excess, hypertension, and hypokalemia.

### ADRENOCORTICOTROPIC HORMONE-DEPENDENT CUSHING SYNDROME

The hypersecretion of ACTH in patients with ACTH-dependent Cushing syndrome leads to the production

of excess adrenal androgens and weak mineralocorticoids (see Plate 3-9).

### ANDROGEN-SECRETING ADRENAL NEOPLASMS

Androgen-secreting adrenal neoplasms are rare. Androgen hypersecretion occurs more often with adrenocortical carcinoma than with adrenal adenomas. The most common hypersecreted androgen is DHEA, followed by androstenedione and testosterone. The distinction between adenoma and carcinoma can usually be made before surgery on the basis of the imaging phenotype on computed tomography (CT). Whereas testosterone-secreting adenomas are usually small (e.g., 1 cm in diameter), homogeneous, and low in density on CT, androgen-secreting adrenocortical carcinomas are almost always more than 4 cm in diameter (average diameter, 10 cm), are inhomogeneous, and have a higher density on CT.



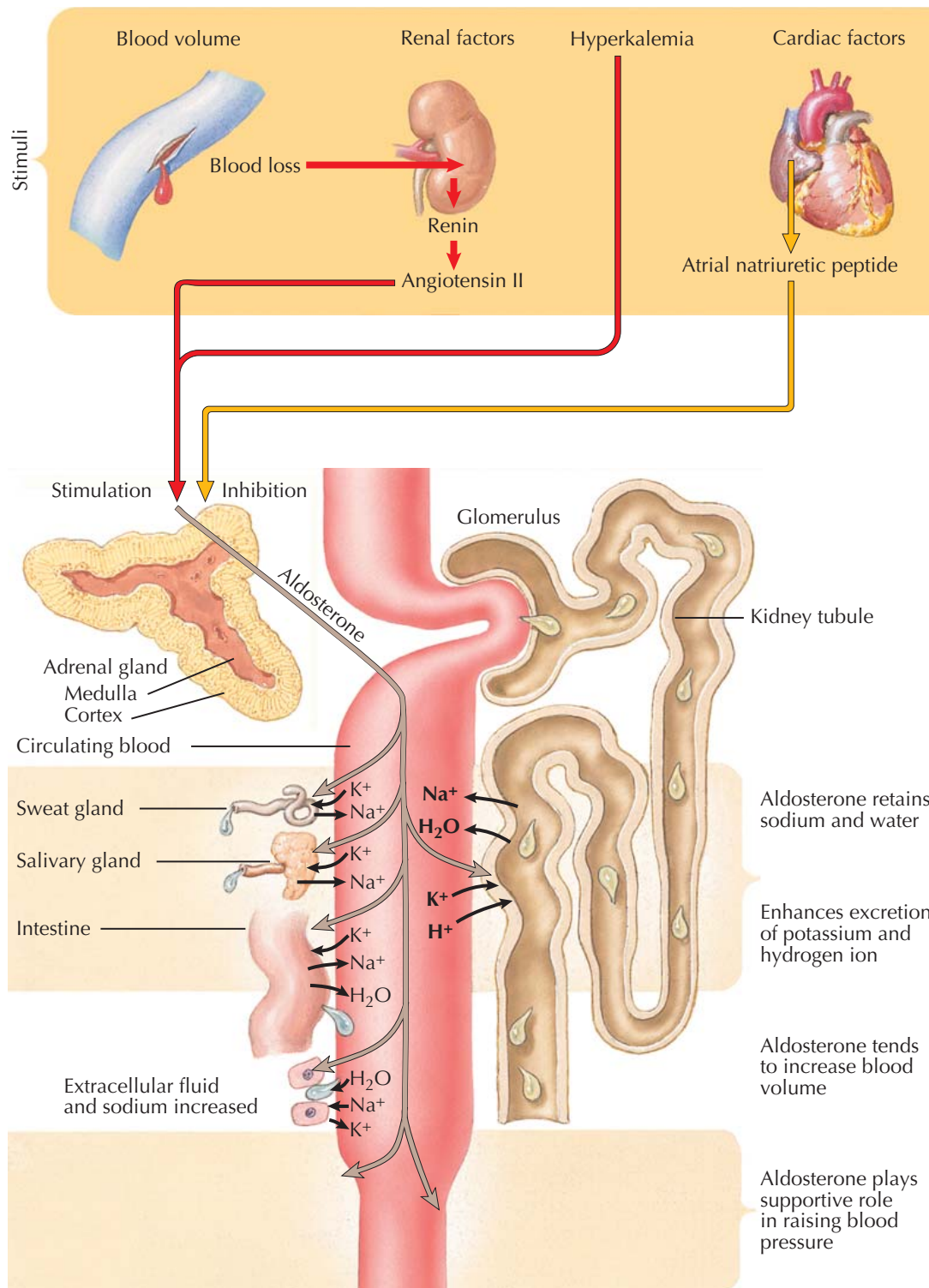
## THE BIOLOGIC ACTIONS OF ALDOSTERONE

Aldosterone secretion is stimulated by angiotensin II, hyperkalemia, and (to a lesser extent) corticotropin; aldosterone secretion is inhibited by atrial natriuretic factor and hypokalemia. Approximately 50% to 70% of aldosterone circulates bound to either albumin or weakly to corticosteroid-binding globulin; 30% to 50% of total plasma aldosterone is free. Thus, aldosterone has a relatively short half-life of 15 to 20 minutes. In the liver, aldosterone is rapidly inactivated to tetrahydroaldosterone. The normal peripheral blood concentration of aldosterone ranges between 0 and 21 ng/dL.

The classic functions of aldosterone are regulation of extracellular volume and control of potassium homeostasis. These effects are mediated by binding of free aldosterone to the mineralocorticoid receptor in the cytosol of epithelial cells, principally the distal tubules in the kidney, where it facilitates the exchange of sodium for potassium and hydrogen ions. The action of angiotensin II on aldosterone involves a negative feedback loop that also includes extracellular fluid volume. The main function of this feedback loop is to modify sodium homeostasis and, secondarily, to regulate blood pressure. Thus, sodium restriction activates the renin-angiotensin-aldosterone axis. The effects of angiotensin II on both the adrenal cortex and the renal vasculature promote renal sodium conservation. Conversely, with suppression of renin release and suppression of the level of circulating angiotensin, aldosterone secretion is reduced and renal blood flow is increased, thereby promoting sodium loss. The renin-angiotensin-aldosterone loop is very sensitive to dietary sodium intake. Sodium excess enhances the renal and peripheral vasculature responsiveness and reduces the adrenal responsiveness to angiotensin II. Sodium restriction has the opposite effect. Thus, sodium intake modifies target tissue responsiveness to angiotensin II, a fine tuning that appears to be critical to maintaining normal sodium homeostasis without a chronic effect on blood pressure.

Mineralocorticoid receptors have tissue-specific expression. For example, the tissues with the highest concentrations of these receptors are the distal nephron, colon, and hippocampus. Lower levels of mineralocorticoid receptors are found in the rest of the gastrointestinal tract, sweat glands, salivary glands, and heart. Transport to the nucleus and binding to specific binding domains on targeted genes lead to their increased expression. Aldosterone-regulated kinase appears to be a key intermediary, and its increased expression leads to modification of the apical sodium channel, resulting in increased sodium ion transport across the cell membrane. The increased luminal negativity augments tubular secretion of potassium by the tubular cells and hydrogen ion by the interstitial cells. Glucocorticoids and mineralocorticoids bind equally to the mineralocorticoid receptor. Specificity of action is provided in many tissues by the presence of a glucocorticoid-degrading enzyme,  $11\beta$ -hydroxysteroid dehydrogenase, which prevents glucocorticoids from interacting with the receptor. Mineralocorticoid "escape" refers to the counterregulatory mechanisms that are manifested after 3 to 5 days of excessive mineralocorticoid administration. Several mechanisms contribute to this escape, including renal hemodynamic factors and an increased level of atrial natriuretic peptide.

In addition to the classic genomic actions mediated by aldosterone binding to cytosolic receptors,



mineralocorticoids have acute, nongenomic actions caused by activation of an unidentified cell surface receptor. This action involves a G protein signaling pathway and probably modification of the sodium-hydrogen exchange activity. This effect has been demonstrated in both epithelial and nonepithelial cells.

Aldosterone has additional, nonclassic effects primarily on nonepithelial cells. These actions, although probably genomic and therefore mediated by activation of the cytosolic mineralocorticoid receptor, do not include modification of sodium-potassium balance.

Aldosterone-mediated actions include the expression of several collagen genes; genes controlling tissue growth factors, such as transforming growth factor  $\beta$  and plasminogen activator inhibitor type 1; or genes mediating inflammation. The resultant actions lead to microangiopathy; acute necrosis; and fibrosis in various tissues such as the heart, vasculature, and kidney. Increased levels of aldosterone are not necessary to cause this damage; an imbalance between the volume or sodium balance state and the level of aldosterone appears to be the critical factor.

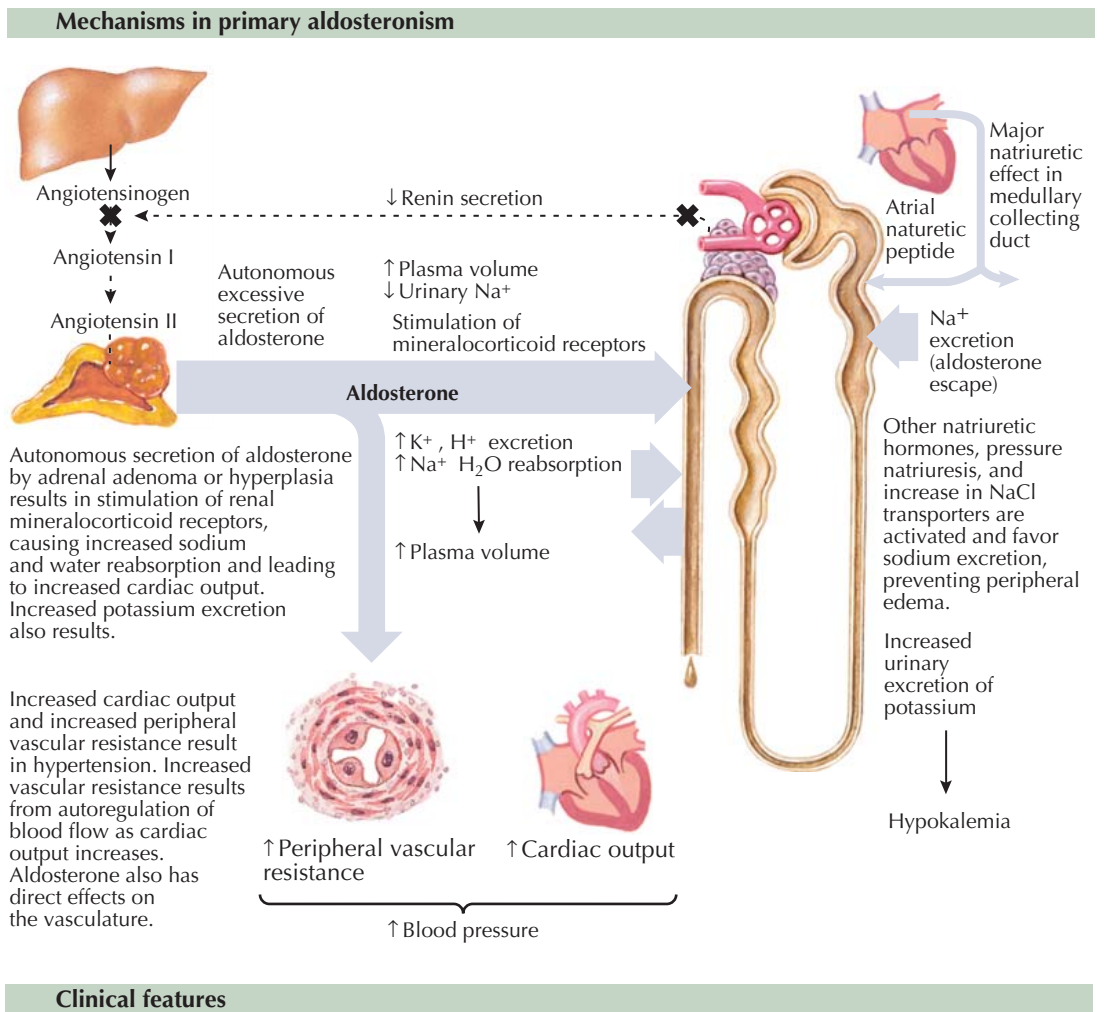
JOHNA CRAIG MD

## PRIMARY ALDOSTERONISM

Hypertension, suppressed renin, and increased aldosterone secretion characterize the syndrome of primary aldosteronism (PA), which was first described in 1955 by Jerome Conn. Bilateral idiopathic hyperaldosteronism (IHA) and aldosterone-producing adenoma (APA) are the most common subtypes of PA. A much less common form, unilateral adrenal hyperplasia (UAH), is caused by zona glomerulosa hyperplasia of predominantly one adrenal gland. Two forms of familial hyperaldosteronism (FH) have been described: FH type I and FH type II. FH type I, or glucocorticoid-remediable aldosteronism (GRA), is autosomal dominant in inheritance and is associated with variable degrees of hyperaldosteronism, and aldosterone hypersecretion suppresses with exogenous glucocorticoids. FH type II refers to the familial occurrence of APA, IHA, or both. Very rarely, excessive aldosterone may be secreted by a neoplasm outside of the adrenal gland (e.g., ovary).

PA is the most common form of identifiable secondary hypertension, affecting 5% of all patients with hypertension. Most patients with PA do not have hypokalemia and present with asymptomatic hypertension, which may be mild or severe. Aldosterone excess results in the renal loss of potassium and hydrogen ions. When hypokalemia does occur, it is usually associated with alkalosis, and patients may present with nocturia and polyuria (caused by hypokalemia-induced failure in renal concentrating ability), palpitations, muscle cramps, or positive Chvostek and Trousseau signs. Patients with hypertension and hypokalemia, treatment-resistant hypertension, hypertension and adrenal incidentaloma, onset of hypertension younger than 20 years, or severe hypertension should undergo testing for PA, as should patients for whom a diagnosis of secondary hypertension is being considered. Case finding can be completed with a simple morning (8–10 AM) blood test (ratio of plasma aldosterone concentration [PAC] to plasma renin activity [PRA]) in a seated, ambulatory patient. The patient may take any antihypertensive drugs except mineralocorticoid receptor (MR) antagonists or high-dose amiloride. Hypokalemia is associated with false-negative ratios, and any potassium deficit should be corrected before testing. The PAC:PRA ratio is a case-finding test with sensitivity and specificity of approximately 75%. All patients with an increased PAC:PRA ratio should undergo confirmatory testing, a step completed with aldosterone-suppression testing (e.g., oral sodium loading, saline-suppression testing, captopril-stimulation testing, or fludrocortisone-suppression testing).

Unilateral adrenalectomy in patients with APA or UAH results in normalization of hypokalemia in all; hypertension is improved in all and is cured in approximately 30% to 60% of these patients. In IHA, unilateral or bilateral adrenalectomy seldom corrects the hypertension. IHA and GRA should be treated medically. Therefore, for patients who want to pursue a surgical cure, the accurate distinction between the subtypes of PA is a critical step. The subtype evaluation may require one or more tests, the first of which is imaging the adrenal glands with computed tomography (CT). When a small, solitary, hypodense macroadenoma (>1 cm and <2 cm) and normal contralateral adrenal morphology are found on CT in a patient younger than 40 years with PA, unilateral adrenalectomy is a reasonable therapeutic option. However, in many cases, CT may show



### Clinical features

↑ Blood pressure

Hypokalemic alkalosis may cause Chvostek and Trousseau signs

↑ Muscle weakness and cramps

↑ Plasma aldosterone concentration (PAC)

↓ Plasma renin activity (PRA)

↑ Polyuria and nocturia

*JOHN A. CRAIG MD*  
with E. Hatton

Primary aldosteronism  
Plasma aldosterone concentration (PAC) >15 ng/dL

+

Plasma renin activity (PRA) <1 ng/mL/hr

↓

↑ PAC:PRA ratio

↓

Confirmatory testing

↓

Subtype testing

CT (axial image) shows a 1-cm aldosterone-producing adenoma (arrow) in the lateral aspect of the right adrenal gland.

normal-appearing adrenal glands, minimal unilateral adrenal limb thickening, unilateral microadenomas (≤1 cm), or bilateral macroadenomas. Thus, adrenal venous sampling (AVS) is usually essential to direct appropriate therapy in patients with PA who want to pursue a surgical treatment option (see Plate 3-19). The treatment goal is to prevent the morbidity and mortality associated with hypertension, hypokalemia, and cardiovascular damage. The cause of the PA helps to determine the appropriate treatment. Normalization of blood pressure should not be the only

goal in managing patients with PA. In addition to the kidney and colon, MRs are present in the heart, brain, and blood vessels. Excessive secretion of aldosterone is associated with increased cardiovascular morbidity. Therefore, normalization of circulating aldosterone concentrations or MR blockade should be part of the management plan for all patients with PA. Unilateral laparoscopic adrenalectomy is an excellent treatment option for patients with APA or UAH. Patients with IHA and GRA should be treated medically with an MR antagonist.



## ADRENAL VENOUS SAMPLING FOR PRIMARY ALDOSTERONISM

Most patients with primary aldosteronism have either bilateral idiopathic hyperaldosteronism, which is optimally treated medically with mineralocorticoid receptor blockade, or a unilateral aldosterone-producing adenoma, which may be treated surgically with unilateral laparoscopic adrenalectomy (see Plate 3-18). Multiple studies have shown that the accuracy of adrenal computed tomography in localizing the source of aldosterone excess is poor (~50%) and that in patients with primary aldosteronism who wish to pursue the surgical option for hypertension management, adrenal venous sampling (AVS) is a key step.

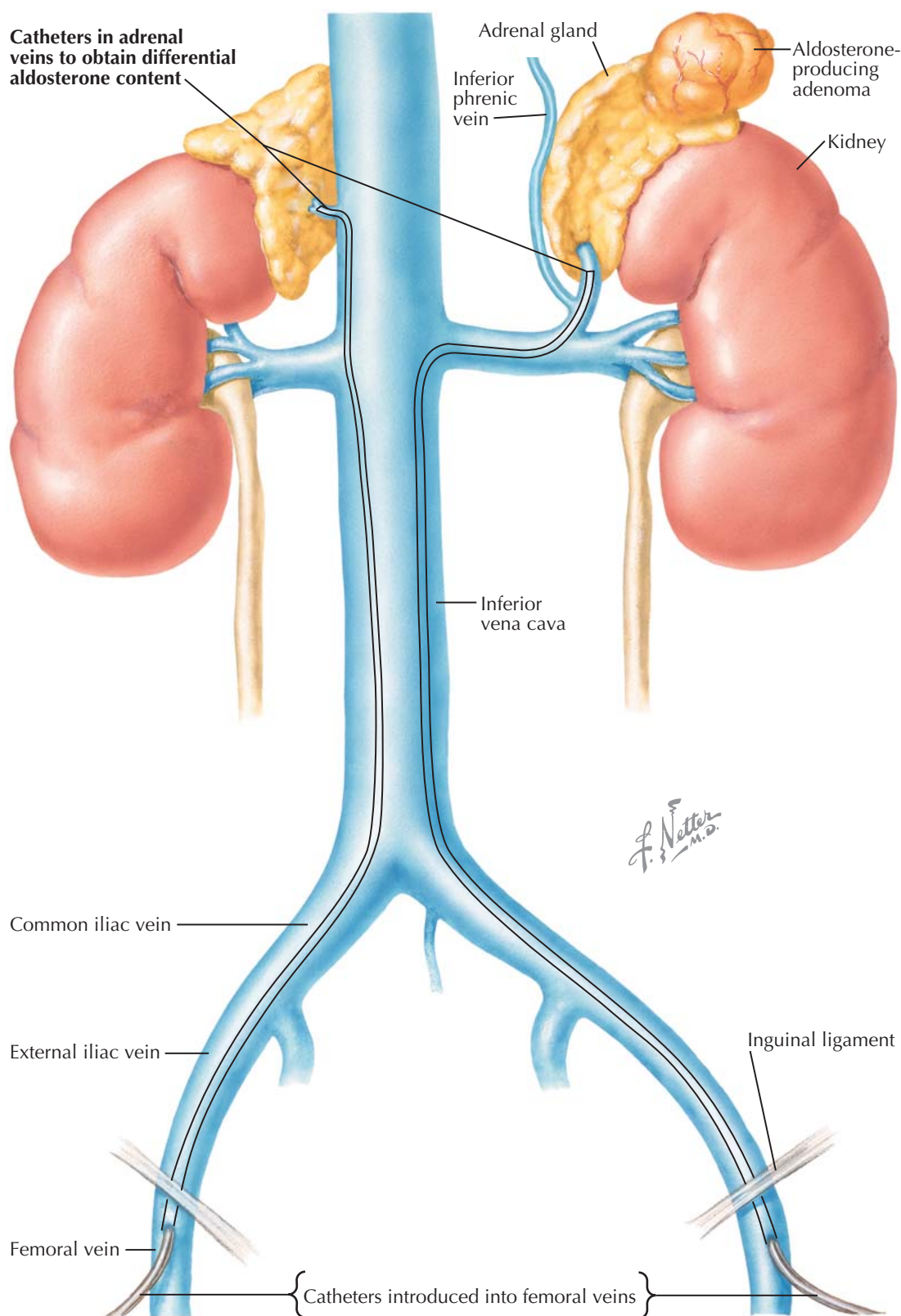
The keys to successful AVS include appropriate patient selection, careful patient preparation, focused technical expertise, a defined protocol, and accurate data interpretation. A center-specific, written protocol is mandatory. Most centers use a continuous cosyntropin infusion (50 µg/h started 30 minutes before sampling and continued throughout the procedure) during AVS for the following reasons: (1) to minimize stress-induced fluctuations in aldosterone secretion during nonsimultaneous AVS, (2) to maximize the gradient in cortisol from adrenal vein to inferior vena cava (IVC) and thus confirm successful sampling of the adrenal veins, and (3) to maximize the secretion of aldosterone from an aldosterone-producing adenoma.

The adrenal veins are sequentially catheterized through the percutaneous femoral vein approach under fluoroscopic guidance. Correct catheter tip location is confirmed with injection of a small amount of contrast medium. Blood is obtained by gentle aspiration from both adrenal veins. Successful catheterization may require an array of catheter configurations; intraprocedural steam-shaping of the catheter tip may be helpful to facilitate access to the adrenal veins. In addition, the placement of side holes very close to the catheter tip may facilitate the blood draw.

The right adrenal vein enters the IVC posteriorly several centimeters above the right renal vein. It is more difficult to catheterize than the left one for a variety of reasons—it is short, small in caliber, and often has an angulated path causing the catheter tip to impact the intima, making blood aspiration problematic. Because of its short length, sometimes it does not support a stable catheter position during respiratory motion. Rarely, it arises in conjunction with a hepatic vein branch and needs to be separately engaged using a specific catheter shape to match the anatomy. Additionally, some physicians confuse the right adrenal vein with adjacent small hepatic vein branches, which are frequently encountered entering the IVC near the adrenal vein region. However, contrast injections clearly distinguish hepatic vein anatomy from that of the adrenal gland.

The left adrenal vein is a tributary of the inferior phrenic vein, which enters the roof of the left renal vein near the lateral margin of the vertebral column in almost all patients. The venous sample from the left side is typically obtained from the common inferior phrenic vein close to the junction of the adrenal vein. Usually, it is rapidly catheterized, and the blood aspiration is easy to achieve.

The final sample needs to be from a pure background source isolated from any possible contamination from the adrenal venous drainage. Traditionally, it is stated



to be the “IVC” sample, although it should be from the external iliac vein; it is free of contamination from collateral left adrenal venous effluent, which on rare occasions drains through a large left gonadal vein caudally into the internal iliac veins.

To minimize the time lag between the sampling of the adrenal veins, the right adrenal vein is sampled first because it is usually more time consuming and will be quickly followed by the left sample in almost all cases. The final sample is from the external iliac vein. This

approach allows all three samples to be close in physiologic time frame. Aldosterone and cortisol concentrations are measured in the blood from all three sites (i.e., right adrenal vein, left adrenal vein, and IVC). All of the blood samples should be assayed at 1:1, 1:10, and 1:50 dilutions; absolute values are mandatory.

At centers with experience with AVS, the complication rate is 2.5% or less. Complications can include symptomatic groin hematoma, adrenal hemorrhage, and dissection of an adrenal vein.

## RENIN-ANGIOTENSIN-ALDOSTERONE SYSTEM AND RENOVASCULAR HYPERTENSION

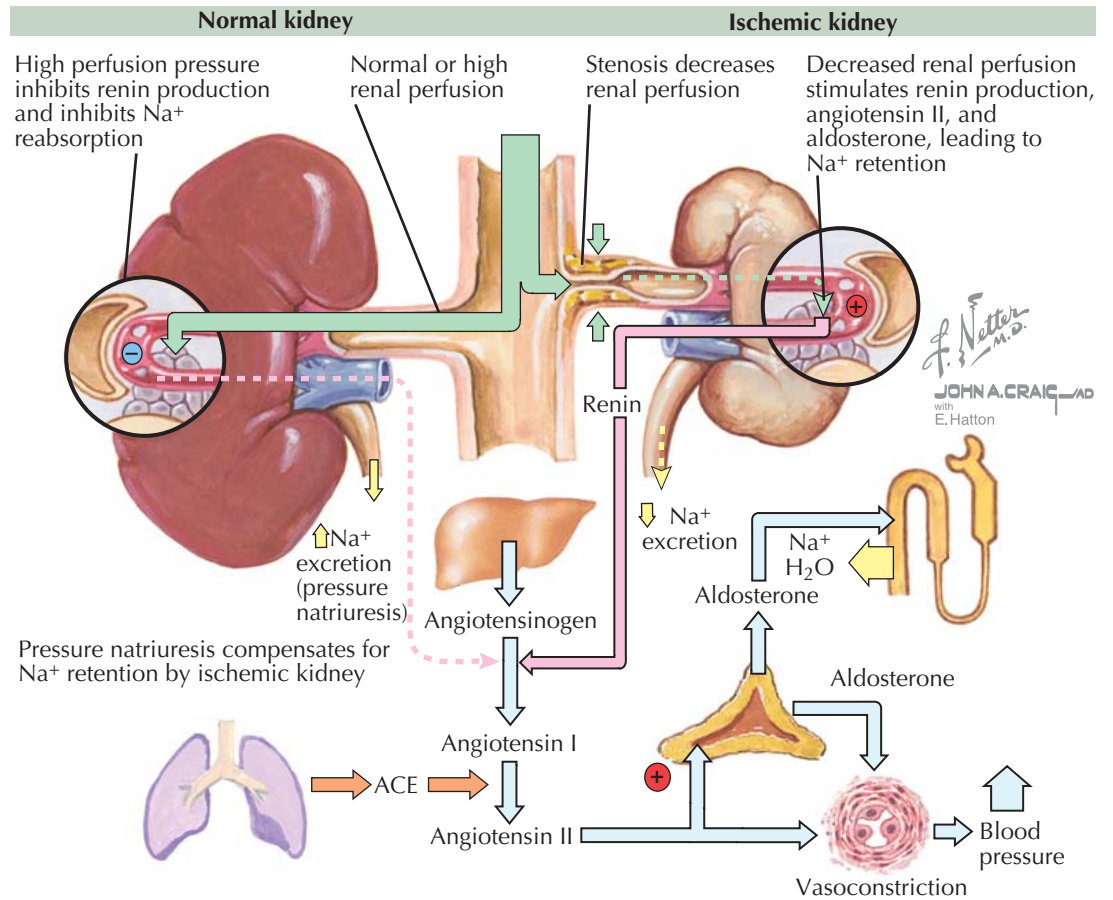
Aldosterone is secreted from the zona glomerulosa under the control of angiotensin II, potassium, and corticotropin (adrenocorticotropic hormone [ACTH]). Renin is an enzyme produced primarily in the juxtaglomerular apparatus of the kidney, and its release into the circulation is the rate-limiting step in the renin-angiotensin-aldosterone system (RAAS). Renal renin release is controlled by four factors: (1) the macula densa, a specialized group of distal convoluted tubular cells that function as chemoreceptors for monitoring the sodium and chloride loads present in the distal tubule; (2) juxtaglomerular cells acting as pressure transducers that sense stretch of the afferent arteriolar wall and thus renal perfusion pressure; (3) the sympathetic nervous system, which modifies the release of renin, particularly in response to upright posture; and (4) humoral factors, including potassium, angiotensin II, and atrial natriuretic peptides. Thus, renin release is maximized in conditions of low renal perfusion pressure or low tubular sodium content (e.g., renal artery stenosis, hemorrhage, dehydration). Renin release is suppressed by elevated perfusion pressure at the kidney (e.g., hypertension) and high-sodium diets. Renin release is increased directly by hypokalemia and decreased by hyperkalemia.

Angiotensinogen, an  $\alpha_2$ -globulin synthesized in the liver, is the substrate for renin and is broken down into the angiotensin peptides. The action of renin on angiotensinogen produces angiotensin I. Angiotensin I is composed of the first 10 amino acids of the sequence following the presegment and does not appear to have biologic activity. Angiotensin II, the main form of biologically active angiotensin, is formed by cleavage of the two carboxyl-terminal peptides of angiotensin I by angiotensin-converting enzyme (ACE). ACE is localized to cell membranes in the lung and intracellular granules in certain tissues that produce angiotensin II. Angiotensin II functions through the angiotensin receptor to maintain normal extracellular volume and blood pressure by (1) increasing aldosterone secretion from the zona glomerulosa by increasing transcription of aldosterone synthase (*CYP11B2*); (2) constricting vascular smooth muscle, thereby increasing blood pressure and reducing renal blood flow; (3) releasing norepinephrine and epinephrine from the adrenal medulla; (4) enhancing the activity of the sympathetic nervous system by increasing central sympathetic outflow, thereby increasing norepinephrine discharge from sympathetic nerve terminals; and (5) promoting the release of vasopressin.

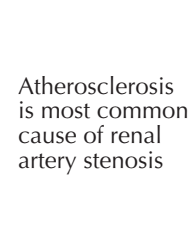
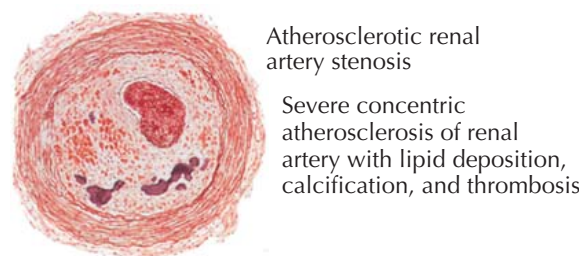
The classic functions of aldosterone are regulation of extracellular volume and control of potassium homeostasis. These effects are mediated by binding of free aldosterone to the mineralocorticoid receptor in the cytosol of epithelial cells, principally in the kidney. Mineralocorticoid receptors have a tissue-specific expression. For example, the tissues with the highest concentrations of these receptors are the distal nephron, colon, and hippocampus. Lower levels of mineralocorticoid receptors are found in the rest of the gastrointestinal tract and heart.

Excess aldosterone secretion causes hypertension through two main mechanisms: (1) mineralocorticoid-induced expansion of plasma and extracellular fluid volume and (2) increase in total peripheral vascular

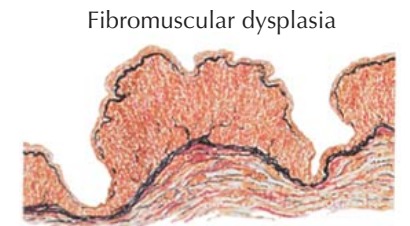
### PATHOPHYSIOLOGY OF RENOVASCULAR HYPERTENSION IN UNILATERAL RENAL ARTERY STENOSIS



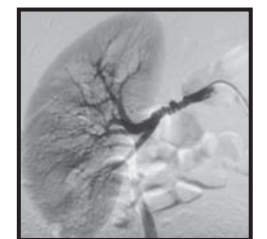### Causes of renovascular hypertension



CT angiogram. Atherosclerotic bilateral renal artery ostial stenoses



Renal arteriogram is criterion standard in diagnosis and assessment of severity of renal artery stenosis



Renal arteriogram. Characteristic beaded appearance caused by alternating stenoses and aneurysmal dilations

resistance. Renovascular disease, which is caused by atherosclerosis or fibromuscular dysplasia, is a correctable cause of secondary hypertension. It should be suspected in patients with onset of hypertension before the age of 30 years (especially if there is no family history and no other risk factors for hypertension such as obesity); onset of severe hypertension ( $\geq 160/100$  mm Hg) after the age of 55 years; an acute elevation in blood pressure over a previously stable baseline; moderate to

severe hypertension and an unexplained atrophic kidney; or an acute elevation in serum creatinine that occurs shortly after the institution of therapy with an ACE inhibitor or angiotensin-receptor blocker. The criterion standard for diagnosing renal artery stenosis is renal arteriography. However, several less invasive tests may be used for case-finding purposes (e.g., magnetic resonance angiography, computed tomographic angiography, duplex Doppler ultrasonography).



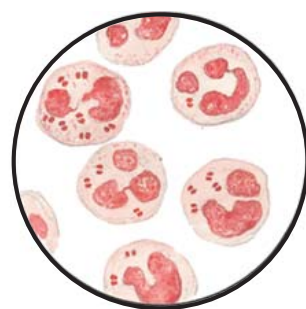
## ACUTE ADRENAL FAILURE— ADRENAL CRISIS

Acute adrenal failure or adrenal crisis is an endocrine emergency and is fatal if untreated. The presentation of adrenal crisis is dominated by dehydration and cardiovascular collapse. Adrenal crisis may occur in the following clinical settings: patients with known primary adrenal failure who have omitted glucocorticoid replacement therapy or who have not increased their replacement dosage for physical illness; patients with undiagnosed primary adrenal insufficiency undergoing a major physical stress (e.g., infection, surgery); and patients with necrosis of the adrenals caused by intraadrenal hemorrhage or infarction. Although much less common because of intact mineralocorticoid secretion, adrenal crisis can also be seen in these settings in patients with secondary adrenal insufficiency, whether associated with hypopituitarism or exogenous glucocorticoid administration.

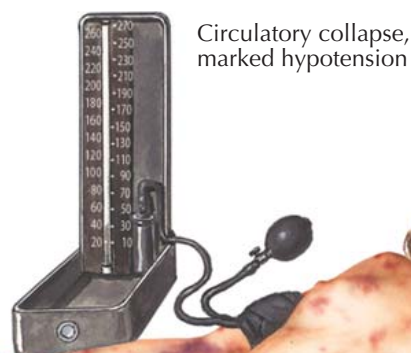
Adrenal hemorrhage should be considered in the setting of circulatory collapse and known underlying infection, trauma, anticoagulant therapy (e.g., heparin or warfarin), or coagulopathy (e.g., antiphospholipid syndrome). Adrenal hemorrhage may be associated with upper back, flank, or abdominal pain. Intraadrenal bleeding may occur in severe septicemia, especially in children with *Pseudomonas aeruginosa* septicemia. Fulminating meningococcal septicemia may result in hemorrhagic destruction of both adrenal glands and is known as *Waterhouse-Friderichsen syndrome*, most often occurring in children and young adults. These patients present with extensive purpura, meningitis, prostration, and shock. The initial presentation of meningitis caused by *Neisseria meningitidis* consists of sudden onset of fever (typically biphasic), nausea, vomiting, headache, cognitive dysfunction, and myalgias. There may be rapid progression to disseminated intravascular coagulation (DIC) and purpura fulminans, which occurs in 20% of patients with meningococemia. Purpura fulminans is characterized by cutaneous hemorrhage and necrosis caused by vascular thrombosis and DIC.

In addition to shock, patients with adrenal crisis usually have additional symptoms that include anorexia, nausea, emesis, generalized abdominal pain, lethargy, fever, or confusion. The symptoms and signs of previously undiagnosed primary adrenal insufficiency may also be present (e.g., hyperpigmentation, weight loss, hyponatremia, hyperkalemia). When these signs are not recognized and when the presentation is dominated by fever and abdominal pain, it may lead to the misdiagnosis of acute surgical abdomen and result in disastrous surgical misadventure.

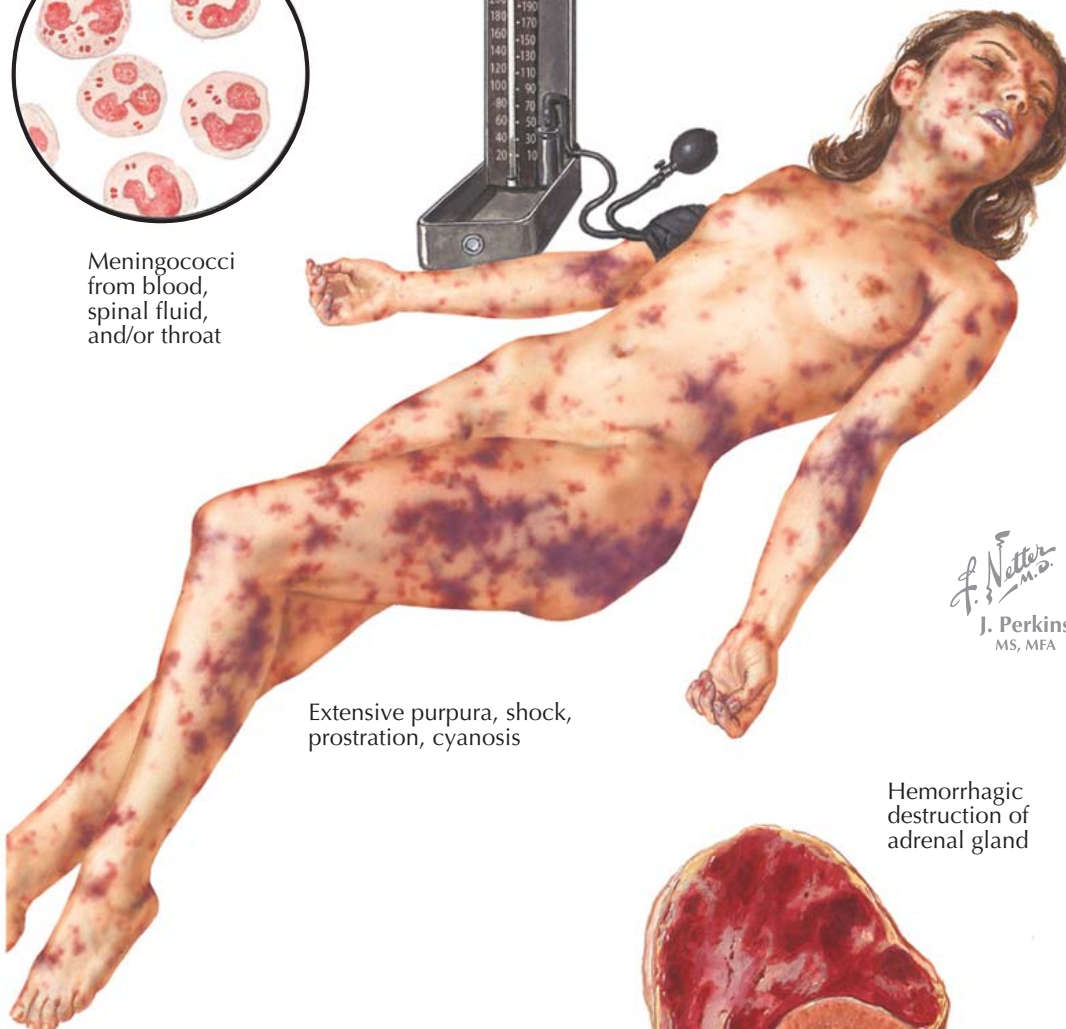
Empiric treatment for possible adrenal failure should be considered in all severely ill patients with shock that is refractory to volume expansion and pressor agents. If adrenal failure has not been diagnosed, the following guidelines for treatment should not be postponed pending the results of tests for diagnosing adrenal insufficiency. The therapeutic approach to acute adrenal insufficiency should include (1) hydrocortisone sodium succinate at a dose of 100 mg administered intravenously as a bolus; (2) rapid intravascular volume repletion with dextrose in isotonic saline (~2–4 L over the first 4 hours) depending on the degree of dehydration, presence of other cardiovascular or renal



Meningococci  
from blood,  
spinal fluid,  
and/or throat

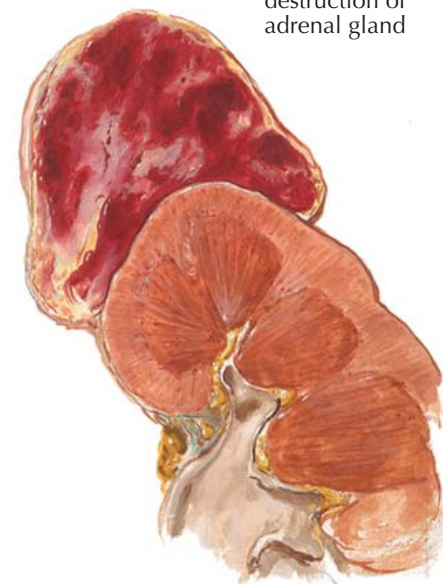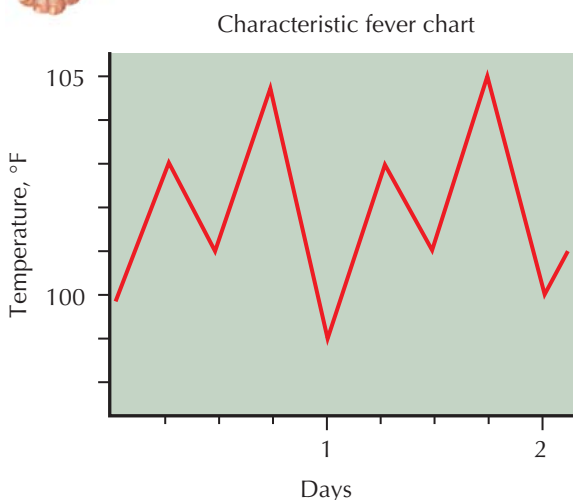


Circulatory collapse,  
marked hypotension



Extensive purpura, shock,  
prostration, cyanosis

Hemorrhagic  
destruction of  
adrenal gland



disorders, and the clinical response; (3) diagnostic assessment for the precipitating cause (e.g., infection); and (4) frequent monitoring of serum electrolytes, acid-base balance, blood glucose level, and renal function. The dosage of hydrocortisone sodium succinate is continued at 100 mg intravenously every 6 to 8 hours until remission of the underlying illness; the dose may then be decreased by 50% per day until maintenance doses are achieved.

For each patient, all of the causes of adrenal insufficiency should be considered; the possibility of autoimmune adrenal disease should be considered, and patients should be assessed for other glandular dysfunction (primary thyroid failure, diabetes mellitus, hypoparathyroidism, and gonadal failure). Adrenal crisis may be precipitated by other acute illnesses such as infectious diseases. Each patient should be evaluated for an underlying triggering disease.

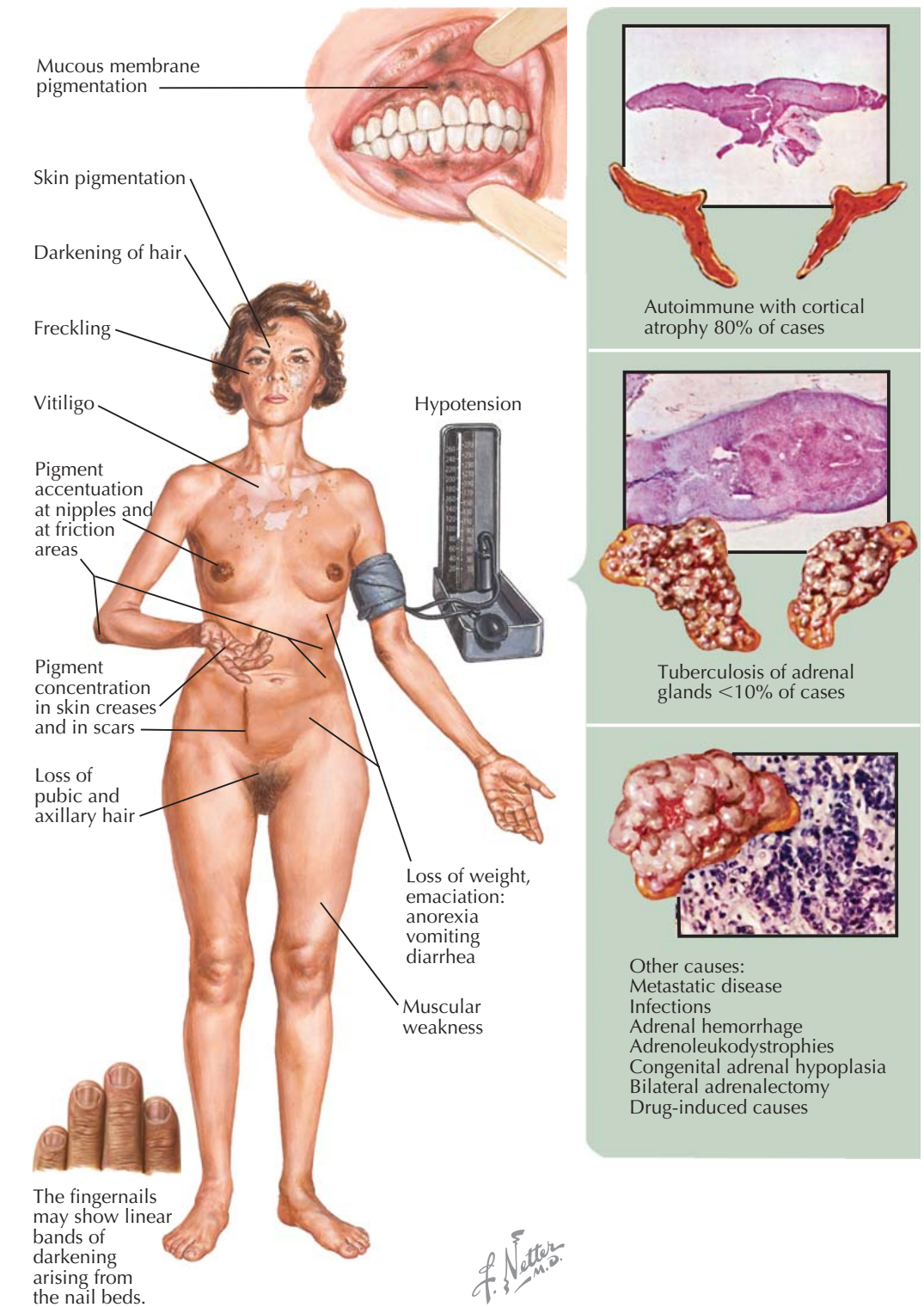
## CHRONIC PRIMARY ADRENAL FAILURE—ADDISON DISEASE

The normal adrenal cortex has a remarkable functional reserve; adrenal failure does not become clinically evident until more than 90% of the cortex has been destroyed. Thus, the clinical presentation of adrenal insufficiency depends on both the rate and extent of adrenocortical destruction. If it is slowly progressive, the patient may not come to clinical detection until an illness (e.g., infection) or other stress (e.g., trauma, surgery) precipitates an adrenal crisis. The typical chronic signs and symptoms relate to both glucocorticoid and mineralocorticoid insufficiency, and these include fatigue, generalized weakness, diffuse myalgias and arthralgias, anorexia, weight loss, nausea, emesis, abdominal pain, psychiatric symptoms, auricular-cartilage calcification (in men), postural lightheadedness, hypotension, hyperpigmentation (skin and hair), hyponatremia, hyperkalemia, and anemia. The hyponatremia is dilutional in nature and caused by inappropriate secretion of antidiuretic hormone and decreased renal free-water clearance. Low blood pressure and postural lightheadedness are associated with both mineralocorticoid and glucocorticoid deficiencies; some patients may present with spontaneous resolution of long-standing hypertension. Hypoglycemia, which is more common in children with adrenal insufficiency, may occur in the setting of a prolonged fast. The recognition of early adrenal insufficiency may be difficult because of the nonspecific nature of its symptoms.

Generalized hyperpigmentation is caused by corticotropin (adrenocorticotrophic hormone [ACTH])–driven increased melanin production in the epidermal melanocytes. The extensor surfaces (e.g., knees, knuckles, elbows) and other friction areas (e.g., belt line, brassiere strap) tend to be even more hyperpigmented. Other sites of prominent hyperpigmentation include the inner surfaces of the lips, buccal mucosa, gums, hard palate, recent surgical scars, areolae, freckles, and palmar creases (the latter may be a normal finding in darker-skinned individuals). The fingernails may show linear bands of darkening arising from the nail beds. With adequate glucocorticoid replacement, the hyperpigmentation resolves over several months; however, the hyperpigmentation in scars may be permanent. Vitiligo (depigmented skin), which is caused by autoimmune destruction of melanocytes, is seen in approximately 20% of patients with autoimmune primary adrenal failure.

In women with primary adrenal failure, secondary sex hair (axillary and pubic hair) may be lost and libido decreased because of loss of adrenal androgen secretion. These findings are not present in men because the testicles are the main source of androgens.

The most common cause of primary adrenal failure has evolved over time, from tuberculosis in 1855 when Thomas Addison first described the clinical features and autopsy findings in 11 patients with primary adrenal failure, to autoimmune disease in the 21st century (in ~80% of cases). Other less common causes of primary adrenal failure include metastatic disease (e.g., lymphoma, lung cancer, breast cancer, melanoma), infections (e.g., fungal, HIV, tuberculosis), adrenal hemorrhage, adrenoleukodystrophies, congenital adrenal hypoplasia (e.g., *NR0B1* [DAX1] or *NR5A1* [SF-1] mutations), bilateral adrenalectomy, and drug-induced causes (e.g., mitotane, ketoconazole). Antibodies directed against 21-hydroxylase can be found in



The fingernails may show linear bands of darkening arising from the nail beds.

nearly all patients with autoimmune primary adrenal failure, and they are absent in patients with other causes of adrenal insufficiency.

Approximately half of patients with autoimmune adrenal failure have one or more other autoimmune endocrine disorders. In such patients, the cause of their findings may be autoimmune polyglandular syndrome type II (APS2). Affected patients typically present between the ages of 20 to 40 years with primary adrenal insufficiency as the main manifestation. Autoimmune thyroid disease (e.g., Hashimoto thyroiditis, Graves disease) and type 1 diabetes mellitus are common in patients with APS2. APS2 was previously referred to as

Schmidt syndrome and is three times more common in women than in men. The inheritance can be autosomal recessive, autosomal dominant, or polygenic.

APS1 is a rare autosomal recessive disorder that most commonly affects females and is most prevalent in individuals of Finnish and Sardinian descent (see Plate 8-6). It is less common than APS2 and is caused by mutations in the autoimmune regulator (*AIRE*) gene. Hypoparathyroidism or chronic mucocutaneous candidiasis is usually the first manifestation that typically appears during childhood or early adolescence and is followed shortly thereafter (average age, 15 years) by primary adrenal insufficiency.



### LABORATORY FINDINGS AND TREATMENT OF PRIMARY ADRENAL INSUFFICIENCY

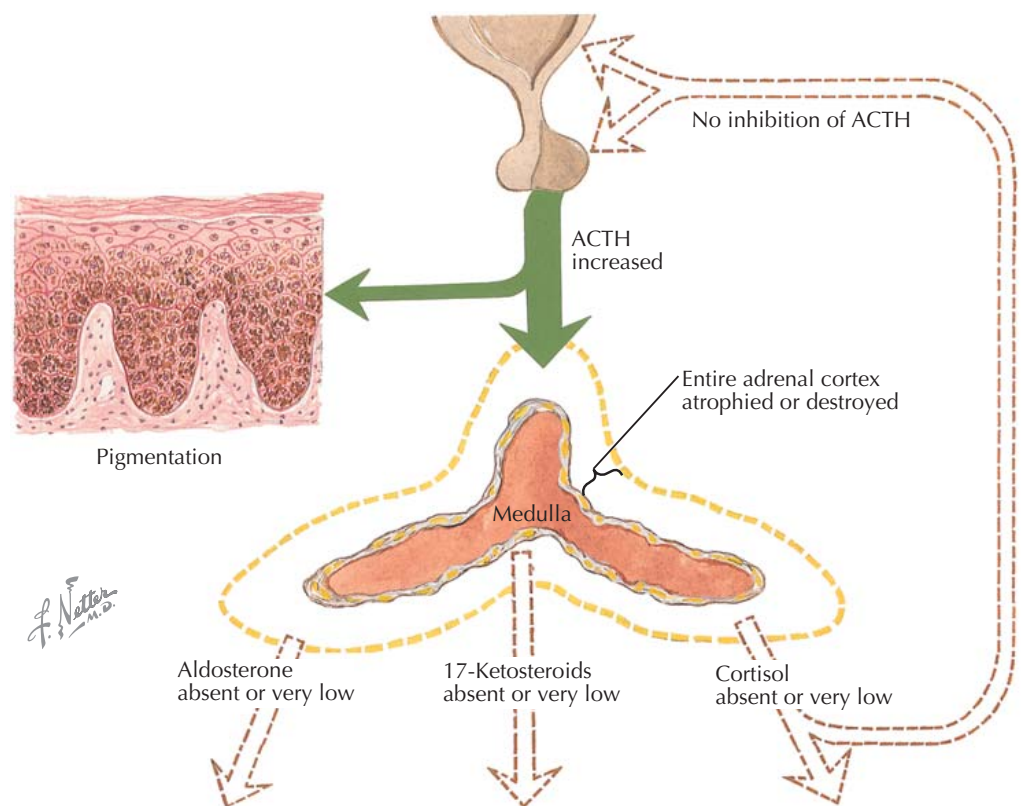
In addition to the cortisol deficiency associated with primary adrenal insufficiency, there is a loss of aldosterone and adrenal androgens. Therefore, primary adrenal insufficiency is also associated with hyponatremia and hyperkalemia. The hyponatremia is associated with an inappropriate increase in vasopressin secretion and a cortisol-related decreased clearance at the kidney. The hyperkalemia is a direct result of lack of aldosterone effect at the mineralocorticoid receptor. Aldosterone concentrations in the blood and urine are inappropriately low for the degree of hyperkalemia and the increased levels of plasma renin activity. The hypotension and dehydration may lead to secondary renal insufficiency and an increase in serum creatinine. Normochromic-normocytic anemia and neutropenia with relative lymphocytosis are usually present.

Blood levels of the adrenal androgens—dehydroepiandrosterone sulfate (DHEA-S), androstenedione, and testosterone—are low, and the 24-hour urinary excretion of 17-ketosteroids is low. The decreased adrenal androgen secretion leads to loss of axillary and pubic hair in women.

The serum cortisol concentrations are low in the presence of the high blood concentration of corticotropin (adrenocorticotropic hormone [ACTH]). In addition, the 24-hour urinary cortisol excretion is low. In symptomatic patients, all that is needed to confirm the diagnosis is an 8 AM serum ACTH concentration greater than 500 pg/mL and a simultaneous serum cortisol concentration less than 5 µg/dL. In this setting, stimulation testing with cosyntropin is not needed. When the cosyntropin-stimulation test is performed in patients with primary adrenal failure, the serum cortisol concentration does not change from baseline (the baseline value is typically <5 µg/dL, and the increment after cosyntropin administration is <7 µg/dL), and the peak value remains below 18 µg/dL.

For guidance on maintenance glucocorticoid replacement, see Plate 3-24. Patients should be told to (1) increase the replacement dosage of glucocorticoids two- to threefold during major physical stress (e.g., fever >101°F, acute illness, tooth extraction); (2) seek medical care if more than 3 days of stress glucocorticoid coverage is required; (3) avoid long-term supraphysiologic dosages because of the potential for iatrogenic Cushing syndrome; (4) be aware that increased glucocorticoid dosage is not required for mental stress, headaches, or minor illness; (5) administer the increased glucocorticoid dose intramuscularly if it cannot be taken orally because of nausea or emesis; and (6) carry and wear medical identification (a wallet card and bracelet or necklace) that includes the diagnosis (“adrenal insufficiency”) and the words “give cortisone,” so that appropriate glucocorticoid treatment can be given if the patient is found unconscious. Complete patient understanding of these instructions is key to successful treatment.

Three syringes, each to be filled with 4 mg (4 mg/mL) of dexamethasone, should be prescribed for patients to keep at home, at work, and with them if possible (they should avoid exposure to extreme heat). A single dose may be repeated in 8 hours if symptoms of the underlying illness persist and a physician is not available. Instructions on self-injection technique should be given and periodically reviewed. Expired medication should be replaced promptly.



|                   |             |   |  |  |
|-------------------|-------------|---|--|--|
| Clinical features | Hypotension | Less pubic and axillary hair in women<br>Loss of muscle mass<br>Loss of libido in women   | Hyperpigmentation<br>Fatigue<br>Generalized weakness<br>Diffuse myalgias and arthralgias<br>Anorexia and weight loss<br>Nausea and emesis<br>Abdominal pain<br>Hypotension |  |
|                   | Blood       | Blood volume — low<br>Na <sup>+</sup> — low<br>K <sup>+</sup> — elevated<br>Creatinine — elevated<br>Aldosterone — low<br>Plasma renin activity — low | DHEA-S — low<br>Androstenedione — low<br>Testosterone (in women) — low   | ACTH — high<br>Anemia<br>normocytic, normochromic, hemoglobin — low<br>Neutropenia<br>Relative lymphocytosis<br>Moderate hypoglycemia<br>Cortisol — low<br>inadequate rise after cosyntropin |
|                   | Urine       | Aldosterone — low<br>(<5 µg/24 h)   | 17-ketosteroids — low<br>(<5 mg/24 h)  | Cortisol — low<br>(<10 µg/24 h)  |

Surgical procedures with general anesthesia require coverage with stress doses of glucocorticoid. A standard glucocorticoid preparation preoperatively is 20 to 40 mg of methylprednisolone sodium succinate administered intramuscularly the morning of the operation and again the evening of the operation; the dosage is tapered to 20 mg and 10 mg intramuscularly every 12 hours on the first and second postoperative days, respectively. The patient's clinical condition is the guide to how much further to taper the dosage to parallel clinical improvement and when to reinstate maintenance glucocorticoid therapy. Patients who take fludrocortisone daily do not usually require supplemental mineralocorticoid until oral intake is resumed postoperatively.

In secondary adrenal failure, the renin-angiotensin-aldosterone axis is intact, and mineralocorticoid replacement is not needed. However, in primary adrenal insufficiency, mineralocorticoid replacement is important. Aldosterone is not available for therapeutic use. Fludrocortisone, a very potent steroid, is the only medication commonly used for this purpose. Typically, 50 to 200 µg (100 µg/d is the usual dosage) is administered orally in a single dose daily. The dosage is titrated to achieve a normal serum level of potassium. Inadequate dosage causes dehydration, hyponatremia, and hyperkalemia. Excessive dosage results in hypertension, weight gain, and hypokalemia. Most patients are advised to maintain a sodium intake of approximately 150 mEq/d.

## LABORATORY FINDINGS AND TREATMENT OF SECONDARY ADRENAL INSUFFICIENCY

The clinical features of secondary (pituitary corticotropin adrenocorticotrophic hormone [ACTH] deficiency) or tertiary (hypothalamic corticotropin-releasing hormone deficiency) adrenal insufficiency are similar to those of primary adrenal insufficiency, with a few notable exceptions. ACTH has a melanocyte-stimulating effect, and patients with primary adrenal insufficiency (high ACTH levels) have a “muddy” type of hyperpigmentation (especially in the palmar creases and over extensor surfaces) and tan easily in the sun. In contrast, secondary adrenal insufficiency (low ACTH levels) is associated with relative pallor and sun sensitivity. In addition, aldosterone secretion and normokalemia are maintained in secondary adrenal insufficiency because the renin-angiotensin-aldosterone axis is intact. Thus, dehydration is less common in secondary adrenal insufficiency.

Hyponatremia may be present and is caused by an inappropriate increase in vasopressin secretion and by decreased free-water clearance at the kidney. Hypoglycemia in children is more common in secondary adrenal insufficiency, in part because of concomitant growth hormone deficiency. Normochromic-normocytic anemia and neutropenia with relative lymphocytosis are usually present.

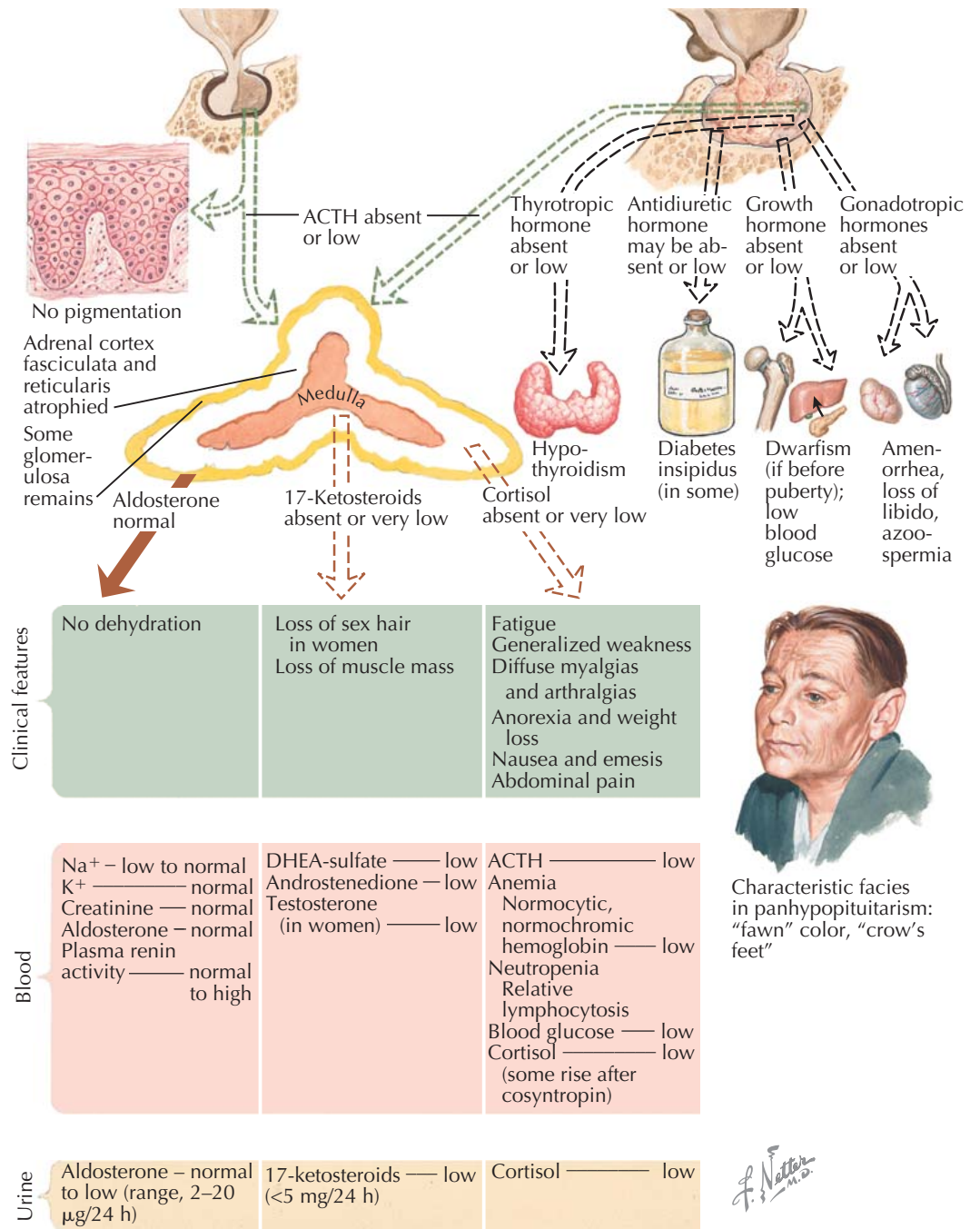
Recognizing that the presentation and laboratory findings in secondary adrenal insufficiency may be dominated by the sellar or hypothalamic process and the associated hormonal deficiencies or tumoral hypersecretion is important. Thus, the presentation may be complicated by hypothyroidism, diabetes insipidus, growth hormone deficiency, and secondary hypogonadism. Because of the decreased free-water clearance associated with adrenal insufficiency, diabetes insipidus may only become evident after glucocorticoid replacement. Mass-effect symptoms (e.g., visual field loss, headaches) related to the sellar or hypothalamic mass may also be observed. In panhypopituitarism, the patient may have the characteristic facies with fawn-colored skin, fine facial wrinkling and crow’s feet around the eyes, and thinning of the lateral third of the eyebrows that is associated with hypothyroidism and hypogonadism. In addition, ACTH may be the only pituitary hormone that is deficient (isolated secondary adrenal insufficiency) and usually associated with lymphocytic hypophysitis.

Aldosterone concentrations in the blood and urine are usually normal for the prevailing renin secretion. Blood levels of the adrenal androgens—dehydroepiandrosterone sulfate (DHEA), androstenedione, and testosterone—are low, and the 24-hour urinary excretion of 17-ketosteroids is low. The decreased adrenal androgen secretion leads to loss of axillary and pubic hair in women.

The serum cortisol concentration is low because of the low blood concentration of ACTH. In addition, the 24-hour urinary cortisol excretion is low. In symptomatic patients, all that is needed to confirm the diagnosis of secondary adrenal insufficiency is an 8 AM serum ACTH concentration that is undetectable and a simultaneous serum cortisol concentration less than 5 µg/dL. In this setting, stimulation testing with insulin-induced hypoglycemia or cosyntropin is not needed. When the cosyntropin-stimulation test is performed in patients with secondary adrenal failure, the serum

Isolated ACTH deficiency caused by autoimmune hypophysitis

Panhypopituitarism caused by pituitary neoplasm, cyst, metastatic cancer, surgery, or infarction



Characteristic facies in panhypopituitarism: “fawn” color, “crow’s feet”

*F. Netter M.D.*

cortisol concentration may start to change from baseline at the 60-minute time point, but the peak value typically remains less than 18 µg/dL.

ACTH is not used for replacement therapy because of the need for parenteral administration, the potential for allergic reactions, and the increased cost. Hydrocortisone, cortisone acetate, and prednisone are the most frequently used preparations in standard replacement therapy. The catabolism of synthetic steroids is affected by interindividual variability and the effects of concomitantly administered drugs. For these reasons, most clinicians prefer the major glucocorticoid secreted by the adrenal cortex, hydrocortisone. In an attempt to replicate the normal glucocorticoid circadian rhythm, two-thirds of the glucocorticoid dose (hydrocortisone,

10 or 15 mg) is administered in the morning, and one-third (hydrocortisone, 5 or 10 mg) is administered before the evening meal. Giving the afternoon dose later in the evening may cause insomnia. Lower doses or a single morning dose of hydrocortisone may be given to patients who have partial ACTH deficiency. Clinical judgment and lack of symptoms of glucocorticoid deficiency or excess are the primary means for determining dosage adequacy. Hepatic enzyme inducers such as rifampin and phenobarbital may accelerate hepatic glucocorticoid catabolism and necessitate an increased maintenance dosage. Because of the short half-life of hydrocortisone, serum cortisol concentration is not a useful index for dosage adequacy. For guidance on stress dosage management, see Plate 3-23.

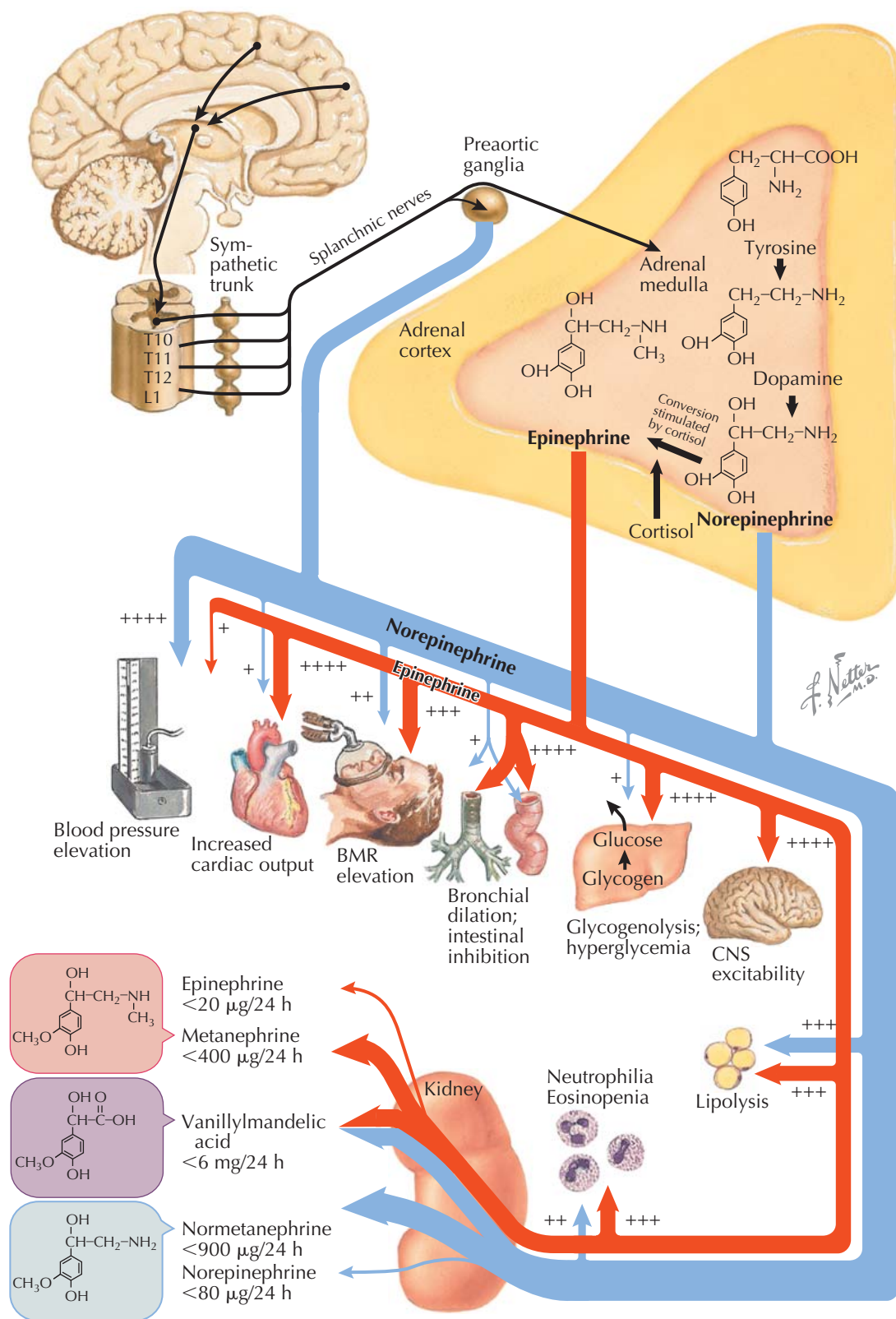


## ADRENAL MEDULLA AND CATECHOLAMINES

The adrenal medulla occupies the central portion of the adrenal gland and accounts for 10% of the total adrenal gland volume. Adrenomedullary cells are called *chromaffin cells* (which stain brown with chromium salts) or *pheochromocytomas*. Cytoplasmic granules turn dark when stained with chromic acid because of the oxidation of epinephrine and norepinephrine to melanin. Chromaffin cells differentiate in the center of the adrenal gland in response to cortisol; some chromaffin cells also migrate to form paraganglia, collections of chromaffin cells on both sides of the aorta. The preganglionic sympathetic neurons receive synaptic input from neurons within the pons, medulla, and hypothalamus, providing regulation of sympathetic activity by the brain. Axons from the lower thoracic and lumbar preganglionic neurons (from T10–L1), via splanchnic nerves, directly innervate the cells of the adrenal medulla. Stressful stimuli (e.g., myocardial infarction, anesthesia, hypoglycemia) trigger adrenal medullary catecholamine secretion. Acetylcholine from preganglionic sympathetic fibers stimulates nicotinic cholinergic receptors and causes depolarization of adrenomedullary chromaffin cells. Depolarization leads to activation of voltage-gated calcium channels, which results in exocytosis of secretory vesicle contents.

The term *catecholamine* refers to substances that contain catechol (ortho-dihydroxybenzene) and a side chain with an amino group—the catechol nucleus. Epinephrine is synthesized and stored in the adrenal medulla and released into the systemic circulation. Norepinephrine is synthesized and stored not only in the adrenal medulla but also in the peripheral sympathetic nerves. Dopamine (DA), the precursor of norepinephrine found in the adrenal medulla and peripheral sympathetic nerves, acts primarily as a neurotransmitter in the central nervous system (CNS).

Catecholamines affect many cardiovascular and metabolic processes, including increasing the heart rate, blood pressure, myocardial contractility, and cardiac conduction velocity. Specific receptors mediate the biological actions. The three types of adrenergic receptors ( $\alpha$ ,  $\beta$ , DA) and their receptor subtypes ( $\alpha_1$ ,  $\alpha_2$ ,  $\beta_1$ ,  $\beta_2$ ,  $\beta_3$ , DA<sub>1</sub>, DA<sub>2</sub>) have led to an understanding of the physiologic responses to exogenous and endogenous administration of catecholamines. The  $\alpha_1$  subtype is a postsynaptic receptor that mediates vascular and smooth muscle contraction; stimulation causes vasoconstriction and increased blood pressure. The  $\alpha_2$  receptors are located on presynaptic sympathetic nerve endings and, when activated, inhibit release of norepinephrine; stimulation causes suppression in central sympathetic outflow and decreased blood pressure. For example, the central  $\alpha_2$ -agonists clonidine,  $\alpha$ -methyl-dopa, and guanfacine are used as antihypertensive agents. There are three main  $\beta$ -receptor subtypes. The  $\beta_1$  receptor mediates cardiac effects and is more responsive to isoproterenol than to epinephrine or norepinephrine; stimulation causes positive inotropic and chronotropic effects on the heart, increased renin secretion in the kidney, and lipolysis in adipocytes. The  $\beta_2$  receptor mediates bronchial, vascular, and uterine smooth muscle relaxation; stimulation causes bronchodilation, vasodilatation in skeletal muscle, glycogenolysis, and increased release of norepinephrine from sympathetic nerve terminals. The  $\beta_3$  receptor regulates



energy expenditure and lipolysis. DA<sub>1</sub> receptors are localized to the cerebral, renal, mesenteric, and coronary vasculatures; stimulation causes vasodilation in these vascular beds. DA<sub>2</sub> receptors are presynaptic and localized to sympathetic nerve endings, sympathetic ganglia, and brain; stimulation inhibits the release of norepinephrine, ganglionic transmission, and prolactin release, respectively.

Most cells in the body have adrenergic receptors. The pharmacologic development of selective  $\alpha$ - and

$\beta$ -adrenergic agonists and antagonists has advanced the pharmacotherapy for various clinical disorders. For example,  $\beta_1$ -antagonists, such as atenolol and metoprolol, are considered standard therapies for angina pectoris, hypertension, and cardiac arrhythmias. Administration of  $\beta_2$ -agonists (terbutaline and albuterol) causes bronchial smooth muscle relaxation; these agents are commonly prescribed in inhaled formulations for the treatment of asthma.

## CATECHOLAMINE SYNTHESIS, STORAGE, SECRETION, METABOLISM, AND INACTIVATION

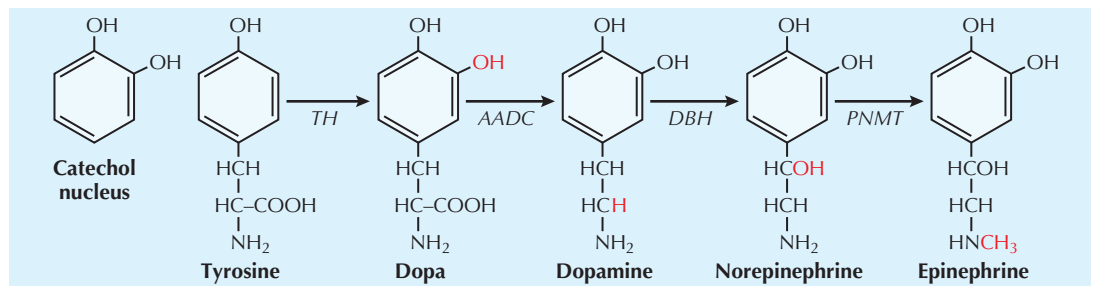
### CATECHOLAMINE SYNTHESIS

Catecholamines are synthesized from tyrosine by a process of hydroxylation and decarboxylation. Tyrosine is derived from ingested food or synthesized from phenylalanine in the liver, and it enters neurons and chromaffin cells by active transport. Tyrosine is converted to 3,4-dihydroxyphenylalanine (dopa) by tyrosine hydroxylase (TH); this step provides the clinician with the option to treat patients with pheochromocytoma with a TH inhibitor,  $\alpha$ -methyl-para-tyrosine (metyrosine). Aromatic L-amino acid decarboxylase (AADC) converts dopa to dopamine. Dopamine is hydroxylated to norepinephrine by dopamine  $\beta$ -hydroxylase (DBH), the rate-limiting step in catecholamine synthesis. Increased intracellular levels of catechols downregulate the activity of tyrosine hydroxylase; as catecholamines are released from secretory granules in response to a stimulus, cytoplasmic catecholamines are depleted, and the feedback inhibition of tyrosine hydroxylase is released. Transcription of tyrosine hydroxylase is stimulated by glucocorticoids, cyclic adenosine monophosphate (cAMP)-dependent protein kinases, calcium/phospholipid-dependent protein kinase, and calcium/calmodulin-dependent protein kinase.  $\alpha$ -Methyl-paratyrosine (metyrosine) is a tyrosine hydroxylase inhibitor that may be used therapeutically in patients with catecholamine-secreting tumors.

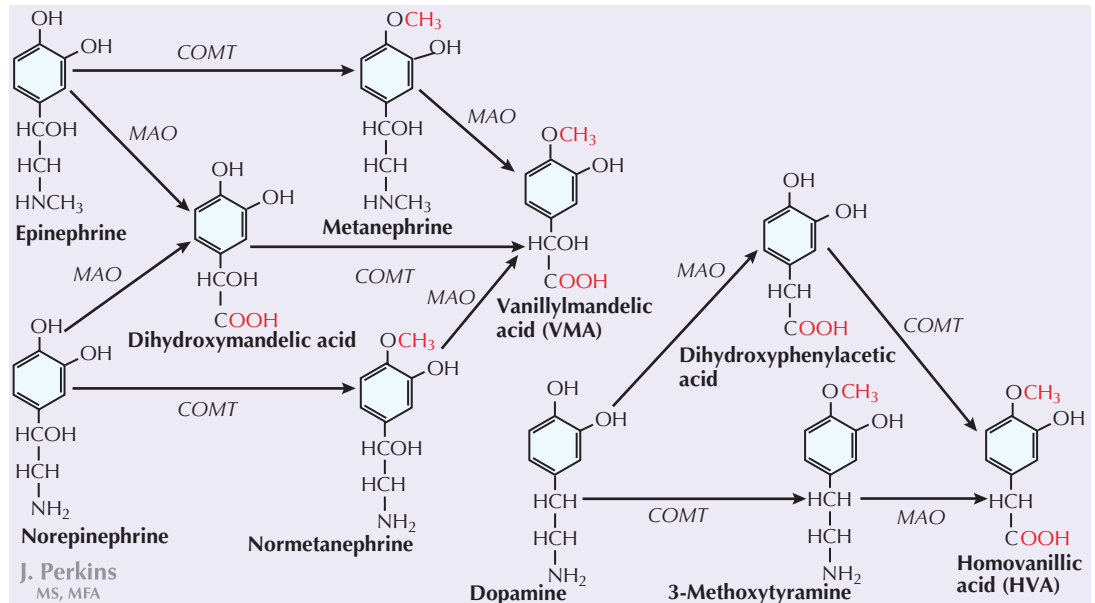
Aromatic L-amino acid decarboxylase catalyzes the decarboxylation of dopa to dopamine. Dopamine is actively transported into granulated vesicles to be hydroxylated to norepinephrine by the copper-containing enzyme dopamine  $\beta$ -hydroxylase. Ascorbic acid is a cofactor and hydrogen donor. The enzyme is structurally similar to tyrosine hydroxylase, and they may share similar transcriptional regulatory elements. Both are stimulated by glucocorticoids and cAMP-dependent kinases. These reactions occur in the synaptic vesicle of adrenergic neurons in the central nervous system, the peripheral nervous system, and the chromaffin cells of the adrenal medulla. In the adrenal medulla, norepinephrine is released from the granule into the cytoplasm, where the cytosolic enzyme phenylethanolamine *N*-methyltransferase (PNMT) converts it to epinephrine. Epinephrine is then transported back into another storage vesicle. The *N*-methylation reaction by PNMT involves *S*-adenosylmethionine as the methyl donor, as well as oxygen and magnesium. PNMT expression is regulated by the presence of glucocorticoids, which are in high concentration in the adrenal medulla through the corticomedullary portal system. Thus, catecholamine-secreting tumors that secrete primarily epinephrine are localized to the adrenal medulla. In normal adrenal medullary tissue, approximately 80% of the catecholamine released is epinephrine.

### CATECHOLAMINE STORAGE AND SECRETION

Catecholamines are found in the adrenal medulla and sympathetically innervated organs. Catecholamines are stored in electron-dense granules that also contain adenosine triphosphate (ATP), neuropeptides (e.g., adrenomedullin, corticotropin adrenocorticotrophic hormone [ACTH]), vasoactive intestinal polypeptide, calcium, magnesium, and chromogranins. Uptake into the storage vesicles is facilitated by active transport using vesicular monoamine transporters (VMATs). The VMAT ATP-driven pump maintains a steep electrical gradient. For every monoamine transported, ATP is hydrolyzed, and 2 hydrogen ions are transported from the vesicle into the cytosol. Iodine 123 and



Biosynthetic pathway for catecholamines. The term catecholamine comes from the catechol (orthodihydroxybenzene) structure and a side chain with an amino group — the “catechol nucleus” (shown on left). Tyrosine is converted to 3,4-dihydroxyphenylalanine (dopa) in the rate limiting step by tyrosine hydroxylase (TH); this step provides the clinician with the option to treat patients with pheochromocytoma with a TH inhibitor,  $\alpha$ -methyl-para-tyrosine (metyrosine). Aromatic L-amino acid decarboxylase (AADC) converts dopa to dopamine. Dopamine is hydroxylated to norepinephrine by dopamine  $\beta$ -hydroxylase (DBH). Norepinephrine is converted to epinephrine by phenylethanolamine *N*-methyltransferase (PNMT); cortisol serves as a cofactor for PNMT and this is why epinephrine-secreting pheochromocytomas are almost exclusively localized to the adrenal medulla.



Catecholamine metabolism. Metabolism of catecholamines occurs through 2 enzymatic pathways. Catechol *O*-methyltransferase (COMT) converts epinephrine to metanephrine and converts norepinephrine to normetanephrine by meta-*O*-methylation. Metanephrine and normetanephrine are oxidized by monoamine oxidase (MAO) to vanillylmandelic acid (VMA) by oxidative deamination. MAO also may oxidize epinephrine and norepinephrine to dihydroxymandelic acid, which is then converted by COMT to VMA. Dopamine is also metabolized by MAO and COMT with the final metabolite, homovanillic acid (HVA).

$^{131}\text{I}$ -labeled metaiodobenzylguanidine (MIBG) are imported by VMATs into the storage vesicles in the adrenal medulla, which makes  $^{123}\text{I}$ -MIBG useful for imaging localization of catecholamine-secreting tumors and  $^{131}\text{I}$ -MIBG potentially useful in treating malignant catecholamine-secreting tumors. Catecholamine uptake, as well as MIBG, is inhibited by reserpine.

Stressful stimuli (e.g., myocardial infarction, anesthesia, hypoglycemia) trigger adrenal medullary catecholamine secretion. Acetylcholine from preganglionic sympathetic fibers stimulates nicotinic cholinergic receptors and causes depolarization of adrenomedullary chromaffin cells. Depolarization leads to activation of voltage-gated calcium channels, which results in exocytosis of secretory vesicle contents. A calcium-sensing receptor appears to be involved in the process of exocytosis. During exocytosis, all the granular contents are released into the extracellular space. Norepinephrine modulates its own release by activating the  $\alpha_2$ -receptors on the presynaptic membrane. Stimulation of the presynaptic  $\alpha_2$ -receptors inhibits norepinephrine release (the mechanism of action of some antihypertensive medications such as clonidine and guanfacine). Catecholamines are among the shortest lived signaling molecules in plasma; the initial biologic half-life of circulating catecholamines is between 10 and 100 seconds. Approximately half of the catecholamines circulate in plasma in loose association with albumin. Thus, plasma concentrations of catecholamines fluctuate widely.

### CATECHOLAMINE METABOLISM AND INACTIVATION

Catecholamines are removed from the circulation either by reuptake by sympathetic nerve terminals or by metabolism through two enzyme pathways, followed by sulfate conjugation and renal excretion. Most of the metabolism of catecholamines occurs in the same cell in which they are synthesized. Almost 90% of catecholamines released at sympathetic synapses are taken up locally by the nerve endings, termed *uptake-1*. Uptake-1 can be blocked by cocaine, tricyclic antidepressants, and phenothiazines. Extraneuronal tissues also take up catecholamines, and this is termed *uptake-2*. Most of these catecholamines are metabolized by catechol *O*-methyltransferase (COMT).

Although COMT is found primarily outside neural tissue, *O*-methylation in the adrenal medulla is the predominant source of metanephrine (COMT converts epinephrine to metanephrine) and a main source of normetanephrine (COMT converts norepinephrine to normetanephrine) by methylating the 3-hydroxy group. *S*-Adenosylmethionine is used as the methyl donor, and calcium is required. Metanephrine and normetanephrine are oxidized by monoamine oxidase (MAO) to vanillylmandelic acid (VMA) by oxidative deamination. MAO may also oxidize epinephrine and norepinephrine to 3,4-dihydroxymandelic acid, which is then converted by COMT to VMA. In the storage vesicle, norepinephrine is protected from metabolism by MAO. MAO and COMT metabolize dopamine to homovanillic acid.



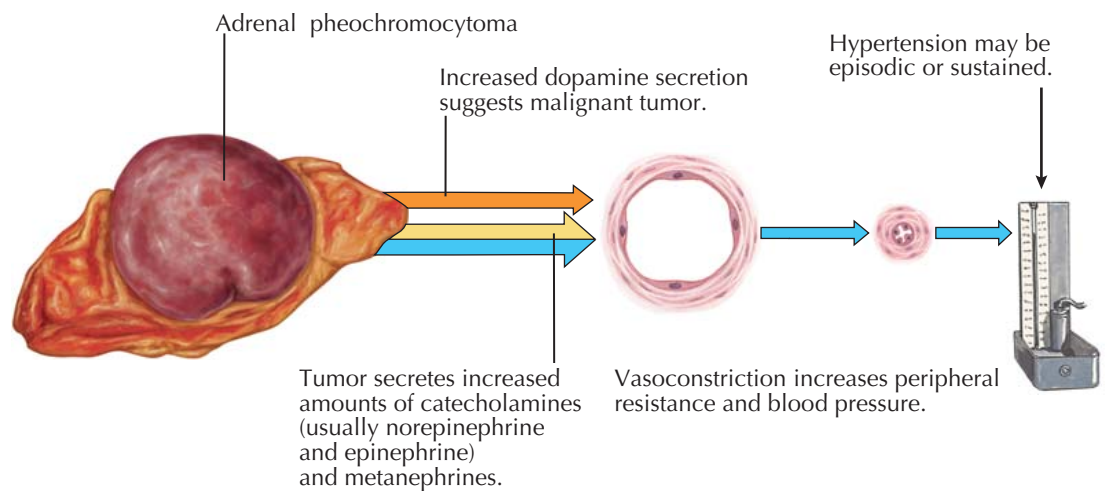
## PHEOCHROMOCYTOMA AND PARAGANGLIOMA

Catecholamine-secreting tumors that arise from chromaffin cells of the adrenal medulla and the sympathetic ganglia are referred to as *pheochromocytomas* and *catecholamine-secreting paragangliomas*, respectively. Because the tumors have similar clinical presentations and are treated with similar approaches, many clinicians use the term *pheochromocytoma* to refer to both adrenal pheochromocytomas and catecholamine-secreting paragangliomas. However, the distinction between pheochromocytoma and paraganglioma is an important one because of implications for associated neoplasms, risk for malignancy, and genetic testing. Catecholamine-secreting tumors are rare, with an annual incidence of two to eight cases per million people. Nevertheless, it is important to suspect, confirm, localize, and resect these tumors because (1) the associated hypertension is curable with surgical removal of the tumor; (2) a risk of lethal paroxysm exists; (3) at least 10% of the tumors are malignant; and (4) 10% to 20% of the tumors are familial, and detection of this tumor in the proband may result in early diagnosis in other family members.

The association between adrenal medullary tumors and symptoms was first recognized by Fränkel in 1886. He described Fraulein Minna Roll, age 18 years, who had intermittent attacks of palpitation, anxiety, vertigo, headache, chest pain, cold sweats, and vomiting. She had a hard, noncompressible pulse and retinitis. Despite champagne therapy and injections of ether, she died. At autopsy, bilateral adrenal tumors were initially thought to be angiosarcomas, but a positive chromaffin reaction later confirmed the pheochromocytoma lesion.

The term *paraganglioma*, introduced in 1908, was defined as an extra-adrenal chromaffin tumor arising in a paraganglion. The term *pheochromocytoma*, proposed by Pick in 1912, comes from the Greek words *phaios* (dusky), *chroma* (color), and *cytoma* (tumor) because of the dark staining reaction that is caused by the oxidation of intracellular catecholamines when exposed to dichromate salts. In 1926, Roux in Lausanne, Switzerland, and Mayo in Rochester, Minnesota, successfully surgically removed adrenal pheochromocytomas. In 1929, it was discovered that pheochromocytomas contain an excess amount of a pressor agent. Subsequently, epinephrine (in 1936) and norepinephrine (in 1949) were isolated from pheochromocytoma tissue. In 1950, it was observed that patients with pheochromocytoma excreted increased amounts of epinephrine, norepinephrine, and dopamine in the urine.

Catecholamine-secreting tumors occur with equal frequency in men and women, primarily in the third, fourth, and fifth decades of life. These tumors are rare in children, and when discovered, they may be multifocal and associated with a hereditary syndrome. When symptoms are present, they are attributable to the pharmacologic effects of excess concentrations of circulating catecholamines. The resulting hypertension may be sustained (in ~half of patients) or paroxysmal (in ~one-third of patients). The remaining patients have normal blood pressure. The lability in blood pressure is attributed to episodic release of catecholamines, chronic volume depletion, and impaired sympathetic reflexes. Symptoms of orthostatic hypotension (e.g., lightheadedness, presyncope, syncope) may dominate the presentation, especially in patients with epinephrine-predominant or dopamine-predominant tumors.



Pheochromocytoma is a chromaffin cell tumor secreting excessive catecholamines resulting in increased peripheral vascular resistance and hypertension.

### Clinical features of pheochromocytoma

Headache

Facial pallor, diaphoresis

24-hour urine sample

The diagnosis must be confirmed biochemically by the presence of increased concentrations of fractionated catecholamines and fractionated metanephrines in the blood or a 24-hour urine collection.

Anxiety

Nausea

Palpitations/ chest pains

Weakness

Epigastric pain

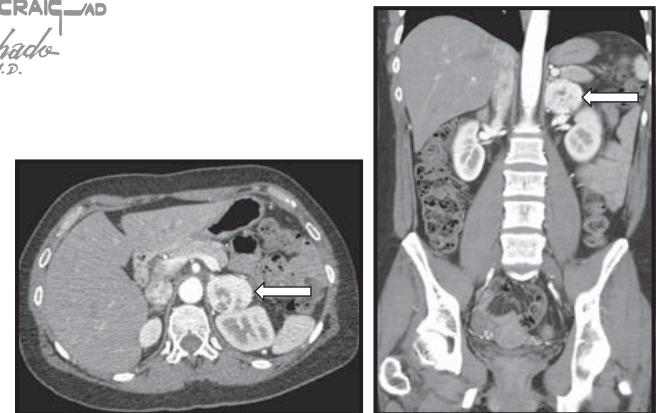
Tremor

Blood pressure

JOHN A. CRAIG, M.D.

C. Machado, M.D.

Symptoms are secondary to excessive catecholamine secretion and are usually paroxysmal. However, because of the increased use of CT imaging and familial testing, pheochromocytoma is diagnosed in up to 50% of patients before any symptoms develop.



Computer-assisted imaging of the abdomen and pelvis with CT or MRI should be the first localization test in a patient with a biochemically confirmed catecholamine-secreting tumor. A left adrenal pheochromocytoma (arrow) can be seen on the axial (above left) and coronal (above right) images of a contrast-enhanced CT scan of the abdomen.

Episodic symptoms may occur in spells, or paroxysms, that can be extremely variable in presentation but typically include forceful heartbeat, pallor, tremor, headache, and diaphoresis. The spell may start with a sensation of a rush in the chest and a sense of shortness of breath followed by a pounding heartbeat in the chest that typically progresses to a throbbing headache. Peripheral vasoconstriction with a spell results in cool or cold hands and feet and facial pallor. Increased sense of body heat and sweating are common symptoms that

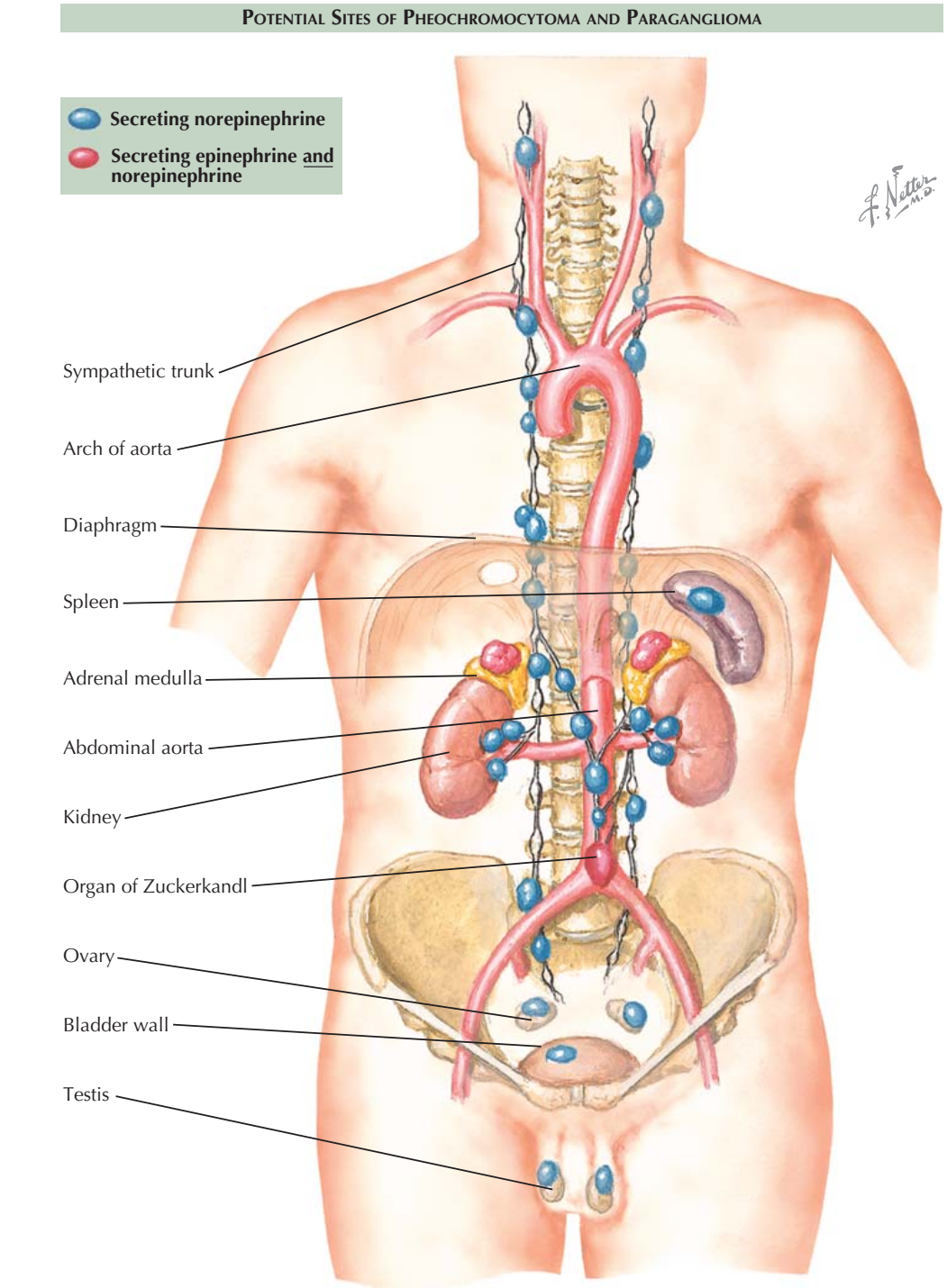
occur toward the end of the spell. Spells may be either spontaneous or precipitated by postural change, anxiety, medications (e.g., metoclopramide, anesthetic agents), exercise, or maneuvers that increase intraabdominal pressure (e.g., change in position, lifting, defecation, exercise, colonoscopy, pregnancy, trauma). Although the types of spells experienced across the patient population are highly variable, spells tend to be stereotypical for each patient. Spells may occur multiple times daily or as infrequently as once monthly.

## PHEOCHROMOCYTOMA AND PARAGANGLIOMA (Continued)

The typical duration of a pheochromocytoma-related spell is 15 to 20 minutes, but it may be much shorter or last several hours. However, the clinician must recognize that most patients with spells do not have a pheochromocytoma.

Additional clinical signs of catecholamine-secreting tumors include hypertensive retinopathy, orthostatic hypotension, angina, nausea, constipation (megacolon may be the presenting symptom), hyperglycemia, diabetes mellitus, hypercalcemia, Raynaud phenomenon, livedo reticularis, erythrocytosis, and mass effects from the tumor. Although the hypercalcemia may be a sign of multiple endocrine neoplasia type 2 (MEN 2), it is usually isolated and resolves with resection of the catecholamine-secreting tumor. Calcitonin secretion is a catecholamine-dependent process, and serum calcitonin concentrations are frequently elevated in patients with catecholamine-secreting tumors and are usually unrelated to MEN 2. Fasting hyperglycemia and diabetes mellitus are caused in part by the  $\alpha$ -adrenergic inhibition of insulin release. Painless hematuria and paroxysmal attacks induced by micturition and defecation are associated with urinary bladder paragangliomas. Some of the cosecreted hormones that may dominate the clinical presentation include corticotropin (adrenocorticotropic hormone [ACTH]) (Cushing syndrome), parathyroid hormone-related peptide (hypercalcemia), vasopressin (syndrome of inappropriate antidiuretic hormone secretion), vasoactive intestinal peptide (watery diarrhea), and growth hormone-releasing hormone (acromegaly). Cardiomyopathy and congestive heart failure are the symptomatic presentations caused by pheochromocytoma that perhaps are most frequently unrecognized by clinicians. The cardiomyopathy, whether dilated or hypertrophic, may be totally reversible with tumor resection. Myocarditis and myocardial infarction with normal coronary arteries seen on angiography are cardiac-based presentations that may not be recognized as being caused by pheochromocytoma. The myocarditis is characterized by infiltration of inflammatory cells and focal contraction-band necrosis. Many physical examination findings are associated with genetic syndromes that predispose to pheochromocytoma; these findings include retinal angiomas, marfanoid body habitus, café au lait spots, axillary freckling, subcutaneous neurofibromas, and mucosal neuromas on the eyelids and tongue. Some patients with pheochromocytoma may be asymptomatic despite high circulating levels of catecholamines, likely reflecting adrenergic receptor desensitization related to chronic stimulation.

A “rule of 10” has been quoted for describing the characteristics of catecholamine-secreting tumors: 10% are extra-adrenal; 10% occur in children; 10% are multiple or bilateral; 10% recur after surgical removal; 10% are malignant; 10% are familial; and 10% of benign, sporadic adrenal pheochromocytomas are found as adrenal incidentalomas. None of these rules is precisely 10%. For example, recent studies have suggested that up to 20% of catecholamine-secreting tumors are familial. Because of the increased use of computed tomography (CT) imaging and familial testing, pheochromocytoma is diagnosed in up to 50% of patients before any symptoms develop. Although these incidentally discovered tumors in asymptomatic patients are typically small (e.g., <3 cm), they may be as large as 10 cm.



The diagnosis must be confirmed biochemically by the presence of increased concentrations of fractionated catecholamines and fractionated metanephrines in the blood or a 24-hour urine collection. Localization studies should not be initiated until biochemical studies have confirmed the diagnosis of a catecholamine-secreting tumor.

Pheochromocytomas are localized to the adrenal glands and have an average diameter of 4.5 cm. Paragangliomas occur where there is chromaffin tissue, including along the para-aortic sympathetic chain, within the organs of Zuckerkandl (at the origin of the inferior mesenteric artery), in the wall of the urinary bladder, and along the sympathetic chain in the neck or mediastinum. During early postnatal life, the

extra-adrenal sympathetic paraganglionic tissues are prominent; they then degenerate, leaving residual foci associated with the vagus nerves, carotid vessels, aortic arch, pulmonary vessels, and mesenteric arteries. Unusual locations for paragangliomas include the intraatrial cardiac septum, spermatic cord, vagina, scrotum, and sacrococcygeal region. Whereas paragangliomas in the head and neck region (e.g., carotid body tumors, glomus tumors, chemodectomas) usually arise from parasympathetic tissue and typically do not hypersecrete catecholamines and metanephrines, paragangliomas in the mediastinum, abdomen, and pelvis usually arise from sympathetic chromaffin tissue and typically do hypersecrete catecholamines and metanephrines.

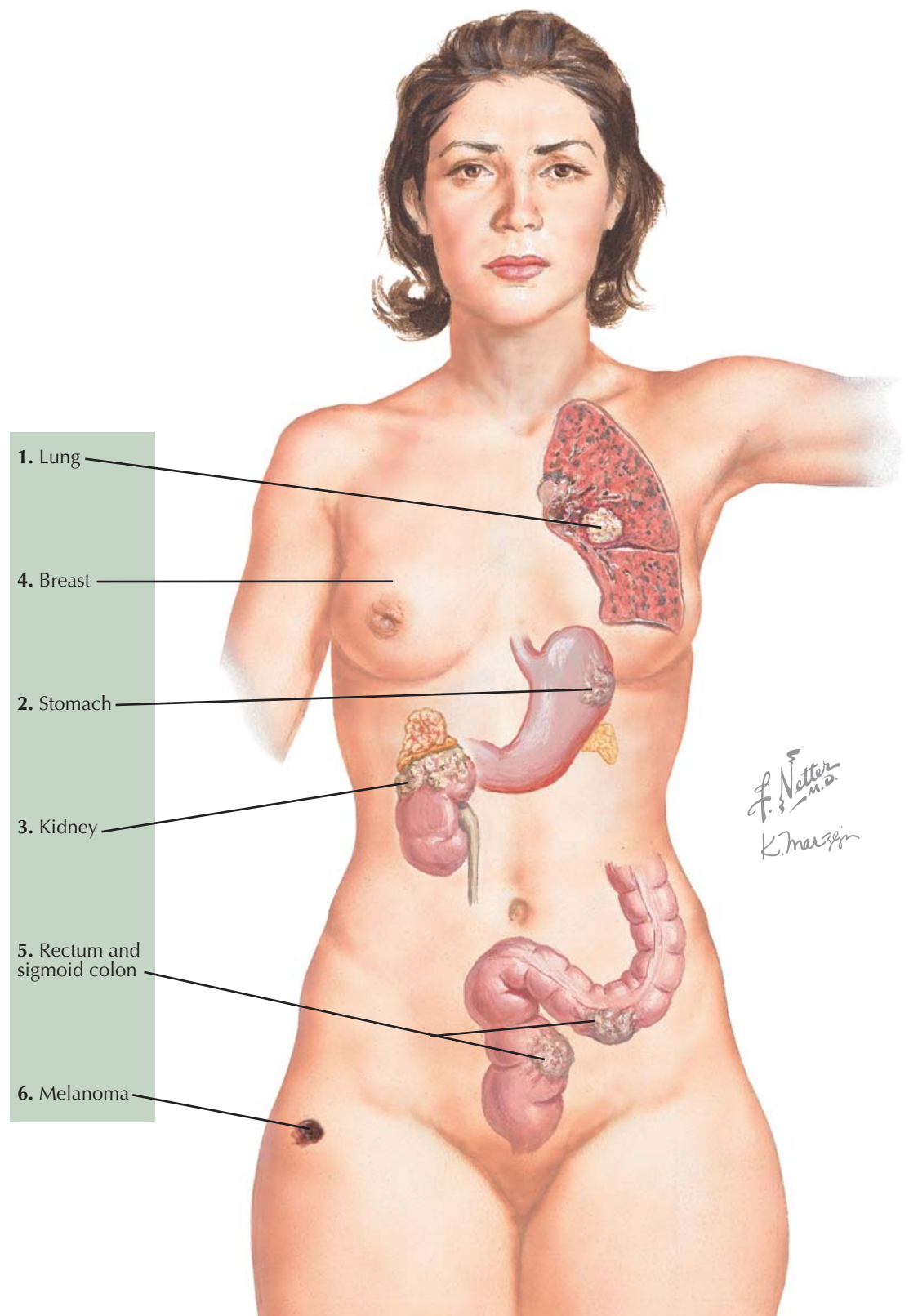


## TUMORS METASTATIC TO THE ADRENAL GLANDS

Metastatic disease to the adrenal glands is common. Although the reason for its frequency is not clear, it likely relates to the high concentrations of glucocorticoids and the rich sinusoidal blood supply. At autopsy, adrenal metastases are found in 50% of patients with disseminated lung or breast cancer, in 30% of patients with melanoma, and in 15% of patients with stomach or colon cancer. The adrenal metastases are bilateral in approximately half of the cases. However, clinically evident adrenal metastases or adrenal insufficiency is seen in only 4% of patients with tumors metastatic to the adrenal glands because most of the adrenal cortex of both adrenal glands must be destroyed before hypo-function becomes symptomatic.

In the past, when metastatic disease to the adrenal glands was detected during life, the most common clinical presentation was an insidious onset of signs and symptoms related to primary adrenal insufficiency (e.g., fatigue, myalgias, nausea, anorexia, orthostatic hypotension, hyperpigmentation) or flank pain. However, asymptomatic metastases to the adrenal glands are becoming more commonly detected during life because of the widespread use of computed tomography imaging and positron emission tomography in staging malignancies. Adenocarcinoma is the most common cell type. The most common organ locations for the primary malignancy (in order of frequency) are the lung, stomach, kidney, breast, colon, skin (melanoma), and pancreas. Adrenal metastases from primary tumors of the esophagus, liver, and bile ducts are more common in individuals of Asian ancestry. In approximately 70% of cases, the adrenal metastasis is discovered concurrently with the primary malignancy; in the remaining patients, the adrenal metastases are typically found over a median duration of 7 to 30 months after the detection of the primary tumor. The longest interval between the diagnosis of primary cancer and the discovery of the adrenal metastasis is found in patients with lymphoma, breast cancer, renal cell carcinoma, and colorectal carcinoma.

Accurate identification of the type of metastatic lesion usually relies on image-guided fine-needle aspiration biopsy and use of adjunctive immunocytochemical techniques on the biopsy specimen. The possibility of an incidentally discovered adrenal pheochromocytoma should be excluded with biochemical tests before proceeding with any biopsy procedure.



Nearly 100% of these patients have metastatic disease to sites in addition to the adrenal glands. Metastatic disease to the adrenal glands is a poor prognostic sign; the 1-year mortality rate is 80%. However, patients with adrenal metastases that are removed surgically have better survival rates than patients who do not have surgery. Long-term survivors after surgical treatment for adrenal metastasis have been reported. More recently, needlescopic adrenal ablative therapy has been used for the management of small (<5 cm in largest

lesional diameter) adrenal masses. Needlescopic ablation offers an effective minimally morbid intervention for patients who are poor surgical candidates. Ablative techniques include radiofrequency ablation, cryoablation, and chemical ablation. Most of these procedures can be performed under percutaneous radiographic guidance in the outpatient setting. Potential complications at the time of ablative therapy include hypertensive crisis and damage to adjacent tissues.

# REPRODUCTION



## DIFFERENTIATION OF GONADS

### FACTORS INFLUENCING NORMAL AND ABNORMAL GONADAL DIFFERENTIATION

Whether the primordial gonad differentiates as a testis or as an ovary is determined by genetic information coded on the X and Y chromosomes. The differentiation of all the other anatomic and functional features that distinguish male from female stem secondarily from the effect of testicular or ovarian secretions on their respective primordial structures. The Y chromosome possesses male-determining genes that direct the primitive gonad to develop as a testis, even in the presence of more than one X chromosome. Two X chromosomes are essential for the formation of normal ovaries; individuals with a single X chromosome (karyotype, 45,XO; Turner syndrome) develop gonads that usually display only the most rudimentary form of differentiation.

Although many patients with congenitally defective gonads have an abnormal karyotype caused by meiotic nondisjunction, similar patients may have normal-appearing sex chromosomes or chromosomal abnormalities not explainable on this basis. In individuals with chromosomal mosaicism, the various tissues may have multiple cell lines of differing chromosomal makeup. Mosaicism arises from mitotic nondisjunction or chromosomal loss occurring after fertilization. Other patients may have deletions or translocations of small chromosomal fragments. If these rearrangements disrupt the sex-determining genes, the effect on gonadal structure may be as devastating as in instances where a total chromosome is lost. In other individuals, mutations in sex-determining genes may cause a specific enzymatic error, leading to defective gonadal structure or hormonal secretion.

### STAGES IN GONADAL DIFFERENTIATION

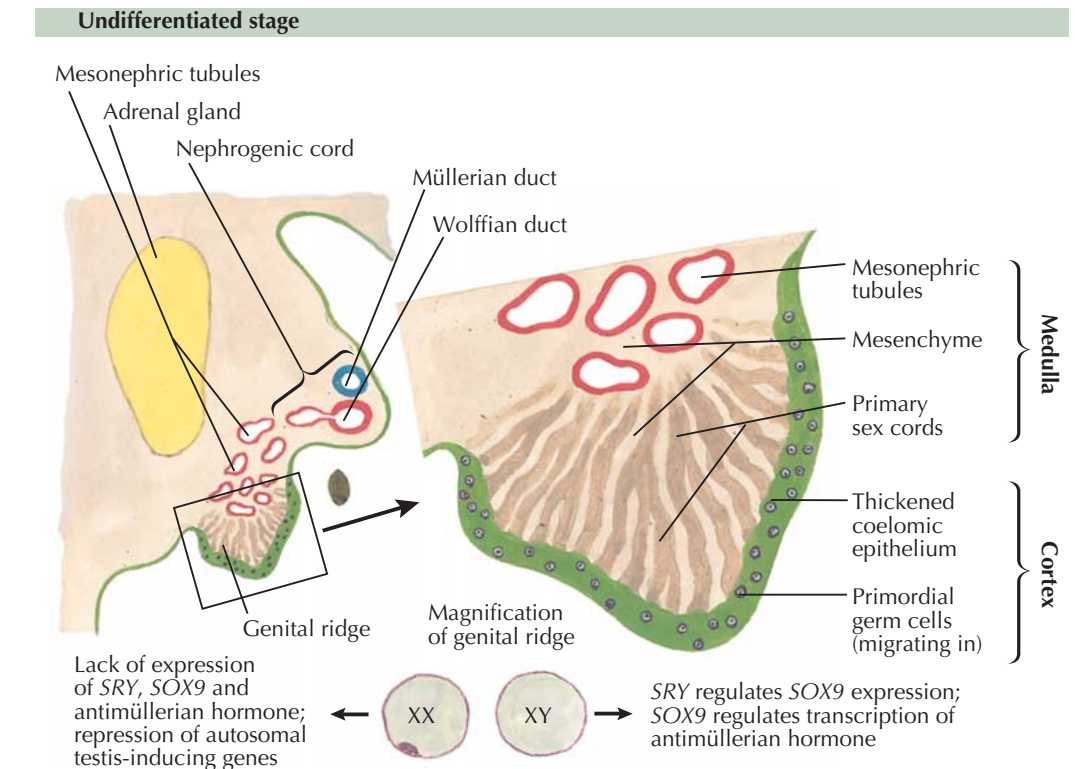
#### Undifferentiated Stage

At the sixth week of gestation, the primitive gonad is represented by a well-demarcated genital ridge running along the dorsal root of the mesentery. The cortical portion of the ridge consists of a cloak of coelomic epithelial cells. The mature ovary is derived principally from these cortical cells. Large primordial germ cells are also found in these superficial layers that are capable of differentiating as either oogonia or spermatogonia.

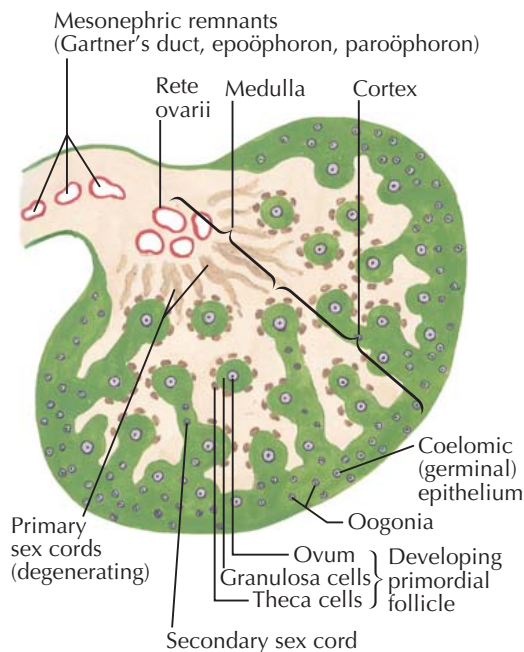
The medullary, or interior, portion of the primitive gonad is composed of a mesenchyme, in which sheets of epithelial cells are condensed to form the primary sex cords. This medullary portion has the potential to further differentiate as a testis.

#### Testicular Differentiation

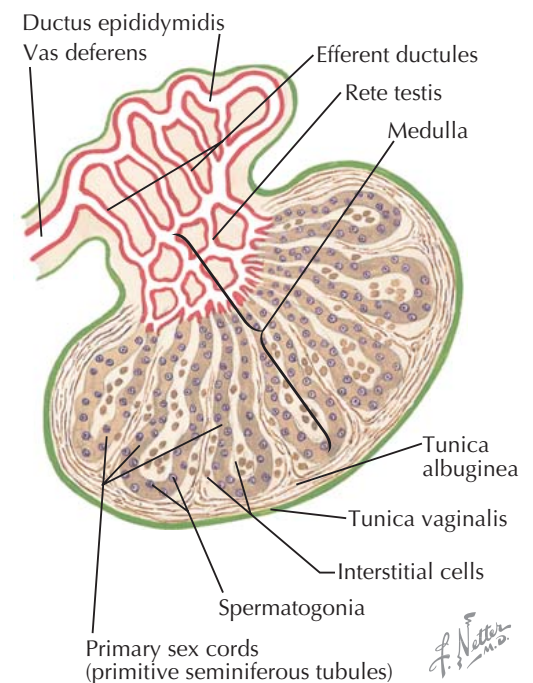
Testicular differentiation is determined by the Y chromosome *SRY* gene and a related homeobox gene, *SOX9* (an autosomal gene). *SRY* regulates *SOX9* expression. *SOX9* in turn directly regulates transcription of anti-müllerian hormone (AMH) by Sertoli cell precursors. AMH causes müllerian duct regression. As the primitive gonad becomes a testis, the inner portion of the primary sex cords becomes a collecting system connecting the seminiferous tubules with the mesonephric, or wolffian, duct. The peripheral portions of the sex cords join with ingrowths of coelomic epithelium (containing primordial germ cells) to form seminiferous tubules. Most of the cortex, however, becomes isolated by the tunica albuginea and the tunica vaginalis, which are the only cortical vestiges in the mature testis. Interstitial



#### Female (primitive ovary)



#### Male (primitive testis)

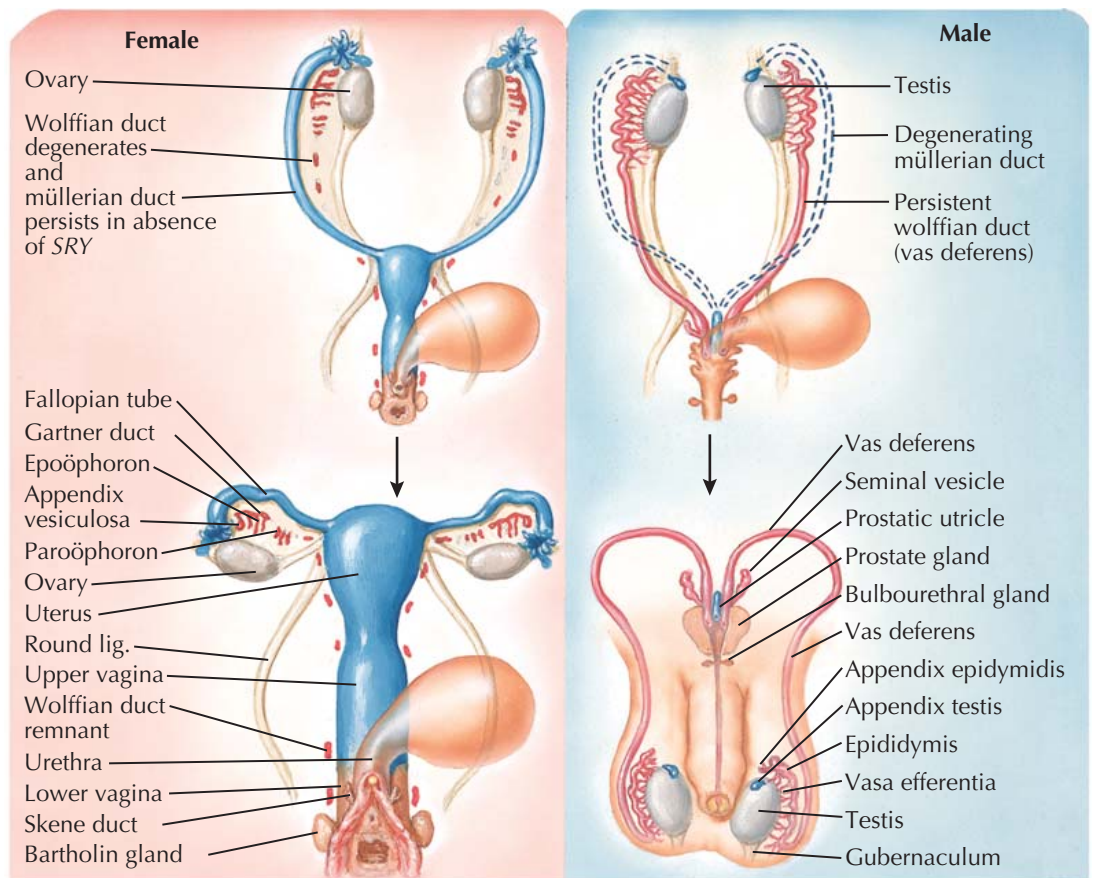
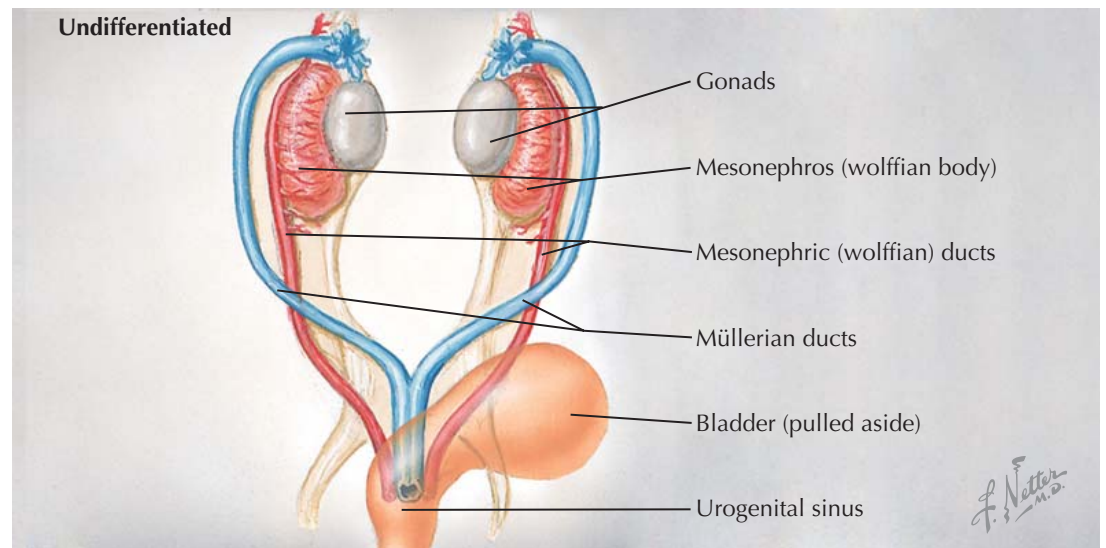


cells of Leydig become abundant at about 8 weeks and secrete androgenic hormone necessary for the development of male external genitalia. Leydig cells disappear shortly after birth and are not seen again until the onset of adolescence.

#### Ovarian Differentiation

Ovarian development occurs several weeks later than testicular differentiation. Ovarian differentiation is determined by the lack of expression of *SRY*, *SOX9*, and AMH. There is likely a mechanism to repress autosomal testis-inducing genes (e.g., *SOX9*) and to activate

ovary-inducing genes (e.g., *WNT4* and *NROB1* [*DAX1*]). At this time, the cortex undergoes intense proliferation, and strands of epithelial cells (called secondary sex cords) push into the interior of the gonad. Primordial germ cells are carried along in this inward migration. Clumps from the secondary sex cords fragment off to form primordial follicles. While the ovary is thus forming, the primary sex cords recede to the hilum, leaving stromal and connective tissue cells behind. Leydig cells and the rete ovarii persist as medullary remnants in the ovary. Proliferation of the cortex ceases at about 6 months.



## DIFFERENTIATION OF GENITAL DUCTS

The early embryo of either sex is equipped with identical primitive gonads that have the capacity to develop into either testes or ovaries. In the case of the internal genital ducts, however, the early embryo has both a male and a female set of primordial structures. The müllerian ducts have the potential to develop into fallopian tubes, a uterus, and the upper portion of the vagina. The mesonephric, or wolffian, ducts have the capacity to develop into the vas deferens and the seminal vesicles. The large wolffian body, containing the proximal mesonephric ducts, becomes the epididymis.

During the third fetal month, either the müllerian or the wolffian structures normally complete their development, and involution occurs simultaneously in the other set. Vestigial remnants of the other duct system, however, persist into adult life. In females, the mesonephric structures are represented by the epoöphoron, paroöphoron, and the ducts of Gartner. In males, the only müllerian remnant normally present is the appendix testis.

The direction in which these genital ducts develop is a direct consequence of the gonadal differentiation that occurred somewhat earlier. Testicular differentiation is determined by the Y chromosome *SRY* gene and a related homeobox gene, *SOX9* (an autosomal gene). *SRY* regulates *SOX9* expression. *SOX9* in turn directly regulates transcription of antimüllerian hormone (AMH) by Sertoli cell precursors. AMH causes müllerian duct regression through apoptosis and mesenchymal-epithelial cell remodeling. Müllerian ducts are nearly completely absent by 10 weeks; then the derivatives of the mesonephric system complete their normal male development.

Ovarian differentiation is determined by the lack of expression of *SRY*, *SOX9*, and AMH. There is likely a

In the female, ovarian differentiation is determined by the lack of expression of *SRY*, *SOX9*, and antimüllerian hormone. Müllerian structures proceed to become the uterus and fallopian tubes, and the wolffian ducts become vestigial.

mechanism to repress autosomal testis-inducing genes (e.g., *SOX9*) and to activate ovary-inducing genes (e.g., *WNT4* and *NR0B1* [*DAX1*]). In this setting, the müllerian structures proceed to become the uterus and fallopian tubes, and the mesonephric structures become vestigial. It should be emphasized that female development is not dependent on any ovarian secretion because in the absence of any gonads at all, the uterus and fallopian tubes develop normally.

In the male, the Y chromosome–encoded *SRY* regulates *SOX9* expression. *SOX9* regulates transcription of antimüllerian hormone, causing the müllerian ducts to degenerate and wolffian ducts to persist and differentiate.

It is clear that *SRY* is the key factor in testis determination. However, multiple other factors must be repressed or activated for normal testicular development. This concept is evidenced by the findings of 46,XX males with testes who do not have a Y chromosome and by 46,XY females with gonadal dysgenesis who have an intact *SRY* gene. Thus, non-Y chromosomal factors must contribute in a clinically important way to testis determination.



## DIFFERENTIATION OF EXTERNAL GENITALIA

Before the ninth week of gestation, both sexes have a urogenital sinus and an identical external appearance. At this undifferentiated stage, the external genitalia consist of a genital tubercle beneath which is a urethral groove, bounded laterally by urethral folds and labioscrotal swellings. The male and female derivatives of these structures are shown in Plate 4-3.

The urogenital slit is formed at an even earlier stage when the perineal membrane partitions it from a single cloacal opening. Thereafter, the bladder and both genital ducts find a common outlet in this sinus.

The vagina develops as a diverticulum of the urogenital sinus in the region of the müllerian tubercle and becomes contiguous with the distal end of the müllerian ducts. About two-thirds of the vagina originates in the urogenital sinus, and about one-third is of müllerian origin.

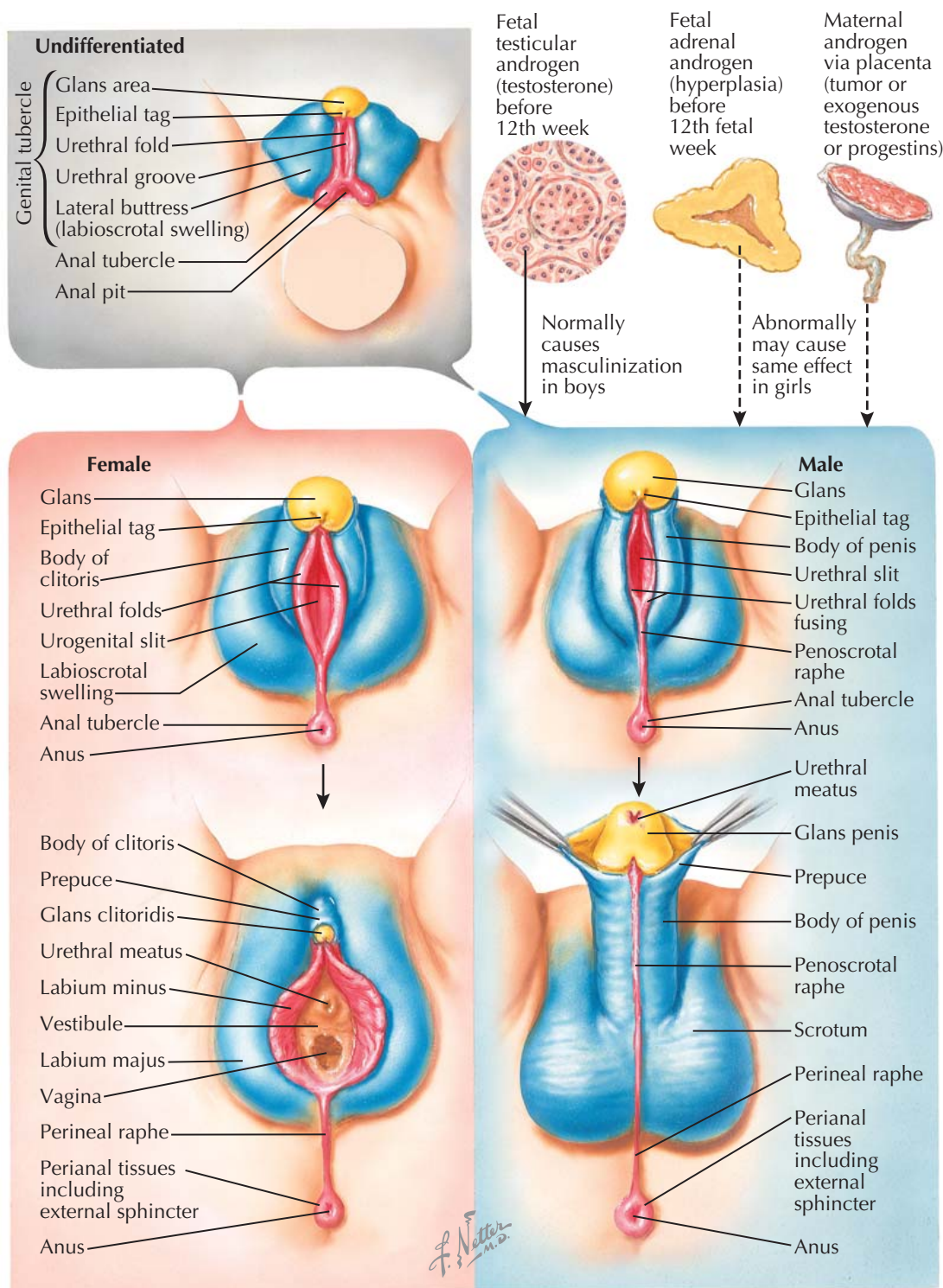
In normal male development, the vaginal remnant is tiny because the müllerian structures atrophy before this diverticulum develops very far. In male pseudohermaphroditism, however, a sizable remnant of this vaginal diverticulum may persist as a blind vaginal pouch.

In normal female development, the vagina is pushed posteriorly by a downgrowth of connective tissue, so that by the 12th fetal week, it has acquired a separate external opening. In female pseudohermaphroditism, the growth of this septum is inhibited, leading to persistence of the urogenital sinus.

The principal distinctions between male and female external genitalia at this stage of development are the location and size of the vaginal diverticulum, the size of the phallus, and the degree of fusion of the urethral folds and labioscrotal swellings.

As in the case of the genital ducts, there is an inherent tendency for the external genitalia to develop along feminine lines. Masculinization of the external genitalia is brought about by exposure to androgenic hormones during the process of differentiation. Normally, the androgenic hormone is testosterone, derived from the Leydig cells of the fetal testis. The critical factor in determining whether masculinization will occur, however, is not the source of the androgen but rather its timing and its amount. In female pseudohermaphroditism caused by congenital adrenal hyperplasia, the fetal adrenal glands secrete sufficient androgen to bring about some masculinization of the external genitalia. In other instances, androgenic hormone may be derived from the maternal circulation.

By the 12th fetal week, the vagina has migrated posteriorly, and androgens will no longer cause fusion of the urethral and labioscrotal folds. Clitoral hypertrophy, however, may occur at any time in fetal life or even after birth.



Female and male derivatives of urogenital sinus and external genitalia

| Female derivative   | Primordial structure                          | Male derivative  |
|---|---|--|
| Vagina (lower two-thirds)<br>Paraurethral glands (of Skene)<br>Bartholin glands | Urogenital sinus                              | Prostatic utricle (vagina masculina)<br>Prostate<br>Bulbourethral glands (of Cowper) |
| Clitoris<br>Corpora cavernosa<br>Glands clitoridis                              | External genitalia<br><i>Genital tubercle</i> | Penis<br>Corpora cavernosa<br>Glans penis  |
| Labia minora  | <i>Urethral folds</i>                         | Corpus spongiosum (enclosing penile urethra)   |
| Labia majora  | <i>Labioscrotal swellings</i>                 | Scrotum  |

## TESTOSTERONE AND ESTROGEN SYNTHESIS

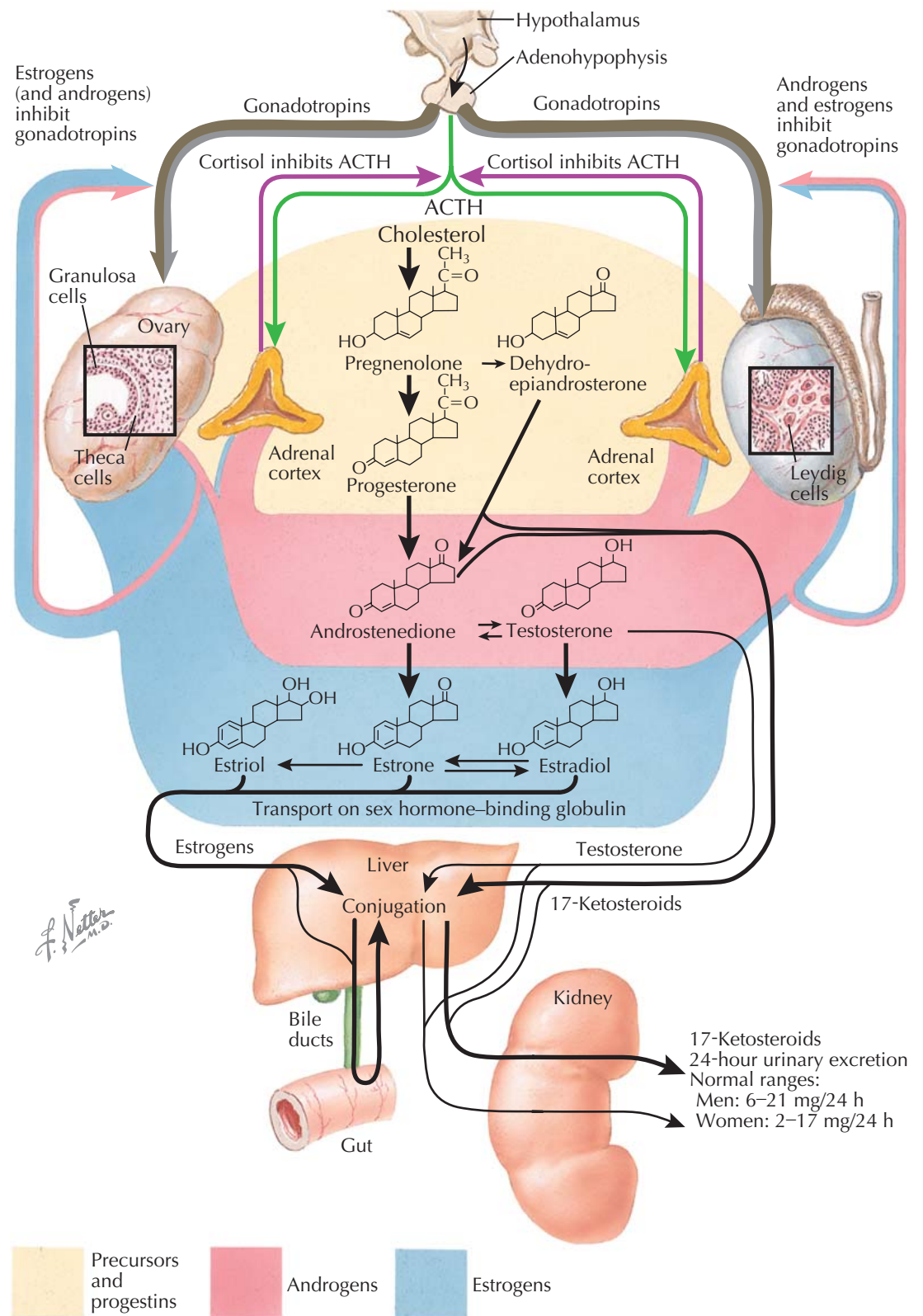
Three glands that originate in the coelomic cavity—the adrenal cortex, the ovary, and the testis—produce steroids under the influence of tropic hormones of the anterior pituitary, corticotropin (adrenocorticotropic hormone [ACTH]) and gonadotropins. Cleaving cholesterol into pregnenolone (the C<sub>21</sub> precursor of all active steroid hormones) and isocaproaldehyde is the critical first step, and it occurs in a limited number of sites in the body (adrenal cortex, testicular Leydig cells, ovarian theca cells, trophoblast cells of the placenta, and certain glial and neuronal cells of the brain). The roles of different steroidogenic tissues are determined by how this process is regulated and how pregnenolone is subsequently metabolized. Androgens have 19 carbon atoms (C<sub>19</sub> steroids), and estrogens have 18 carbon atoms (C<sub>18</sub> steroids).

Pregnenolone is converted to 17 $\alpha$ -hydroxypregnenolone by 17 $\alpha$ -hydroxylase (P450c17). P450c17 also possesses 17,20-lyase activity, which results in the production of the C<sub>19</sub> adrenal androgens (dehydroepiandrosterone [DHEA] and androstenedione). Most of the adrenal androstenedione production is dependent on the conversion of DHEA to androstenedione by 3 $\beta$ -hydroxysteroid dehydrogenase. Androstenedione may be converted to testosterone by 17 $\beta$ -ketosteroid reductase (17 $\beta$ -HSD3) in the adrenal glands or gonads.

Androstenedione and testosterone are secretory products of the Leydig cells, which are found in abundance in the testis but are present in only small numbers in the hilar region of the ovary. In men, 95% of testosterone (7 mg/d) is produced by the testicles under the control of luteinizing hormone. The local effect of testosterone can be amplified by conversion via type 2 5 $\alpha$ -reductase to the more potent dihydrotestosterone. This local amplification system occurs at the hair follicle and the prostate gland. Testosterone is bound to sex hormone-binding globulin in the blood. Conjugation with glucuronic acid takes place in the liver. Much of the conjugated testosterone is excreted in its water-soluble form by the kidney with a little free, unconjugated testosterone.

DHEA, a precursor of androstenedione and testosterone, is found mostly in the 17-ketosteroid fraction in the urine and is derived largely from the adrenal cortex. It is a weak androgen that makes up more than 60% of the 17-ketosteroids. The normal excretion value for 17-ketosteroids is higher in men than in women, presumably because of the contribution by the testis of some DHEA and a variety of other 17-ketosteroids.

The ovary contains at least three differential secretory zones: the granulosa cells of the follicle, engaged in estrogen formation; the theca cells, having a tendency to produce somewhat more androgens; and the



hilar cells, predominantly involved in androgen formation. The balance of these cellular elements ensures a normal degree of femininity; conversely, an imbalance leads to androgenicity. Within the ovary there are also the cells of the corpus luteum, which produce the bulk of progesterone.

Testosterone and androstenedione, respectively, are precursors of estradiol and estrone. Hydroxylation of the 19-carbon initiates a series of reactions that aromatize the A ring of the steroid nucleus, and this aromatization

is, in fact, characteristic of estrogens. Estradiol is more potent than estrone; estriol is purely an excretory product, which is extremely weak biologically.

The estrogens are bound in blood by sex hormone-binding globulin and albumin. Inactivation of estrogen occurs in the liver through conversion to less active estrogens (i.e., estradiol to estrone to estriol), oxidation to totally inert compounds, or conjugation to glucuronic acid. There is considerable enterohepatic circulation because estrogens are excreted in the bile.

17-Ketosteroids  
24-hour urinary excretion  
Normal ranges:  
Men: 6–21 mg/24 h  
Women: 2–17 mg/24 h



## TANNER STAGES OF BREAST DEVELOPMENT

## NORMAL PUBERTY

## TIMING OF PUBERTY

Although it is often thought of as a distinct event, puberty is part of a lifelong process of hypothalamic-pituitary-gonadal development. Puberty is a biologic transition during which secondary sex characteristics develop, a linear growth spurt occurs, fertility is realized, and psychosocial changes occur. *Adrenarche* refers to the adrenal component of pubertal maturation and usually occurs earlier than gonadarche (the maturation of the hypothalamic-pituitary-gonadal system). *The-larche* refers to pubertal breast development.

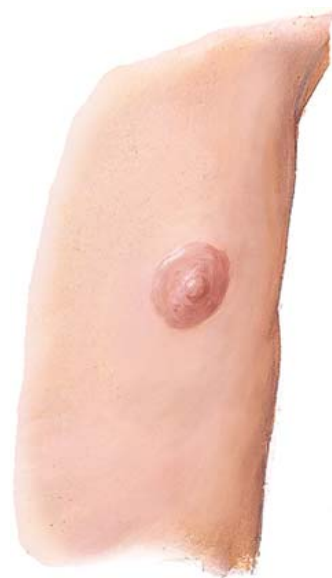Before the onset of puberty, conspicuous physical differences between boys and girls are largely confined to the anatomy of their genital organs. The mean age of puberty onset is 10.6 years (range, 7–13 years) in white girls and 8.9 years (range, 6–13 years) in African American girls. The mean age of puberty onset in boys is 11 years (range, 9–14 years); some African American boys start puberty between 8 to 9 years.

The factors that lead to the maturation of the gonadotropin-releasing hormone pulse generator and thus trigger the onset of puberty are multiple and not yet fully understood. For example, body weight is one factor that triggers puberty, and the mechanism may involve leptin, a hormone produced in adipocytes. Puberty does not occur in animal models that are deficient in leptin but can be induced by leptin administration.

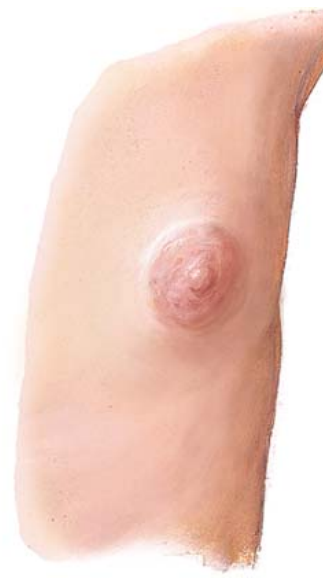Most of the physical changes that begin at puberty are attributable to an increase in androgens and estrogens from the gonads and reticular zone of the adrenal cortex. The gonads are activated by pituitary luteinizing hormone (LH) and follicle-stimulating hormone (FSH), which, until this time, are not secreted in clinically important amounts in normally developing children. Corticotropin (adrenocorticotropic hormone [ACTH]) and a yet to be identified adrenal androgen-stimulating factor (perhaps of pituitary origin) appear to be responsible for adrenarche.

The capacity to secrete both androgens and estrogens is inherent in the adrenal glands, as well as in the gonads of both sexes. Enlargement of the reticular zone of the adrenal cortex and increased secretion of adrenal androgens occur at about the same time that the ovaries exhibit heightened activity. Androgenic hormones from both the adrenals and ovaries increase the growth rate and the development of pubic hair, later axillary hair, and seborrhea and acne. Both androgens and estrogens have a stimulatory effect on epiphyseal maturation, and as fusion occurs, the rate of linear growth rapidly decelerates.

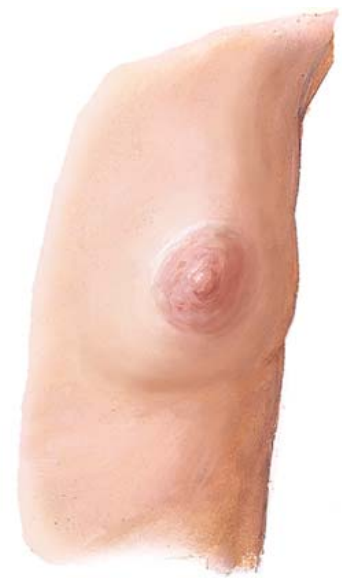Approximately 18% of total adult height accrues during the pubertal growth spurt. Although the pubertal growth velocity is slightly lower in girls, they reach their peak height velocity about 2 years earlier than boys. In boys, the peak height velocity is approximately



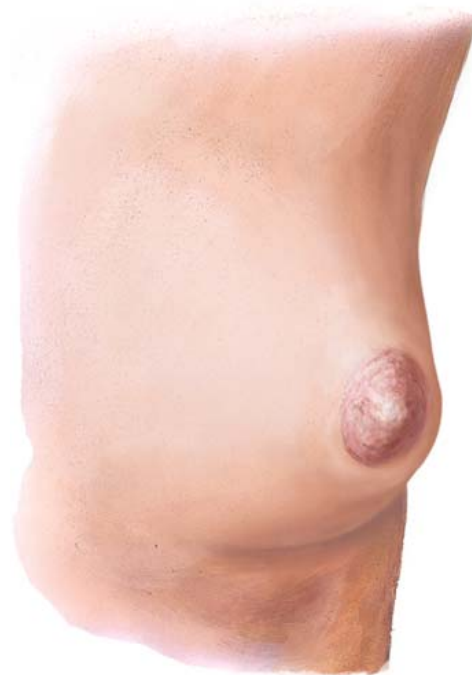**Stage 1**  
Elevation of papilla only



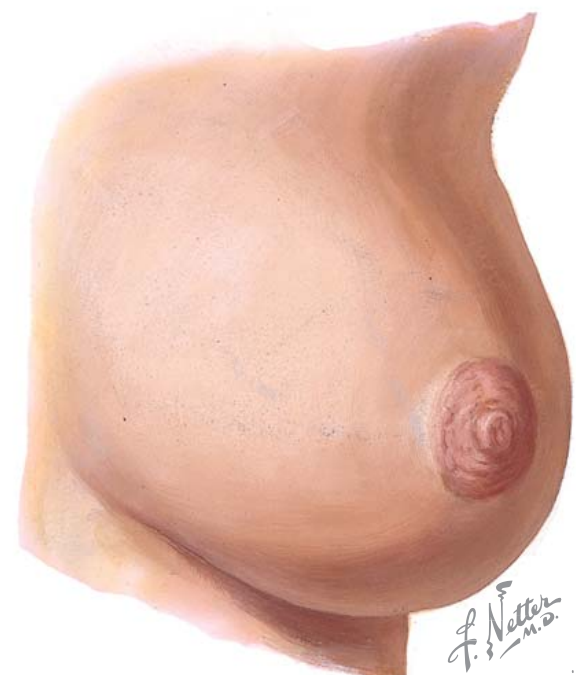**Stage 2**  
Breast bud: elevation of breast and papilla as a small mound and enlargement of areolar diameter



**Stage 3**  
Additional enlargement of breast and areola with no separation of their contours



**Stage 4**  
Areola and papilla project from surface of breast to form secondary mound



**Stage 5**  
Mature stage with projection of papilla only with recession of the areola to the general contour of the breast

9.5 cm per year at an average age of 13.5 years, whereas, in girls, the peak height velocity is approximately 8.3 cm per year at an average age of 11.5 years. Because of a longer duration of pubertal growth, boys on average gain 10 more centimeters of increased height than girls through the pubertal growth spurt, thus accounting for the general difference in sex-dependent adult height. Normal growth spurt in girls is dependent on growth hormone, insulinlike growth factor 1 (IGF-1), and

estrogen. In boys, growth is dependent on growth hormone, IGF-1, estrogen, and testosterone. Increased pubertal blood estradiol concentrations appear to trigger hypothalamic-pituitary activity that results in increased growth hormone pulse amplitude and frequency. Serum IGF-1 concentrations peak during puberty and remain increased for approximately 2 years after the pubertal growth spurt before falling into the adult reference ranges.

## TANNER STAGES OF FEMALE PUBIC HAIR DEVELOPMENT

## NORMAL PUBERTY (Continued)

The upper body to lower body segment ratio (U:L ratio) is defined as the distance from the top of the head to the top of the pubic ramus, divided by the length from the bottom of the feet to the top of the pubic ramus. The U:L ratio is approximately 1.7 at birth, 1.4 at 1 year of age, 1.0 at 10 years of age, 0.92 in white adults, and 0.85 in African American adults. The U:L ratios are the same in females and males. Eunuchoid proportions (decreased U:L ratio) develop in patients with hypogonadism, in whom epiphyseal fusion is delayed and the extremities grow for a prolonged period of time. Eunuchoid proportions are also seen in patients with estrogen receptor deficiency or defects in estrogen synthesis. Patients who produce excess estrogen (aromatase excess), however, have advanced skeletal maturation, an increased U:L ratio, and short adult height.

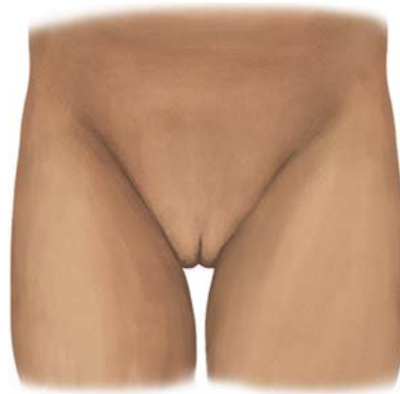
Almost 50% of total body calcium in girls and slightly more than 50% in boys is laid down in bone mineral during puberty. After puberty, boys have 50% more total body calcium than girls. During puberty, the hips enlarge more in girls, and the shoulders become wider in boys. The pelvic inset widens in girls because of the growth of the os acetabuli. Men have 50% more lean body mass and skeletal mass than women, and women generally have twice the amount of body adipose tissue (distributed in the upper arms, thighs, and upper back) than men. Cardiovascular changes that occur during puberty include a greater aerobic reserve.

Marshall and Tanner developed a staging system to document the sequence of changes of secondary sexual characteristics. The Tanner stages are based on visual criteria to document five stages of pubertal development with regard to breast and pubic hair development in girls and genital and pubic hair development in boys. Stage 1 is the prepubertal state, and stage 5 is the adult state.

## FEMALE PUBERTY

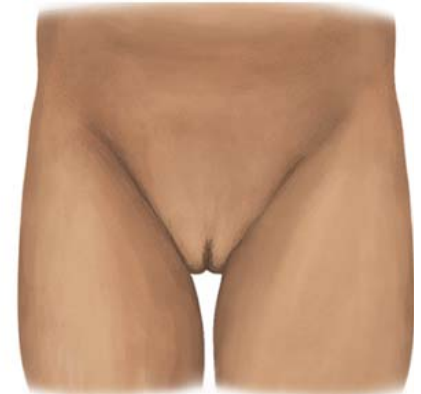The three main phenotypic pubertal events in girls are increased height velocity, breast development (thelarche, under the control of ovarian estrogen secretion), and growth of axillary and pubic hair (under the control of androgens secreted by the ovaries and adrenal glands). An increase in height velocity is usually the first sign of puberty in girls. Most girls grow only approximately 2.5 cm in height after menarche. The stages of breast and pubic hair development usually progress in concert, but discordance may occur, and they are best classified separately. The mean age of puberty onset is 10.6 years (range, 7–13 years) in white girls and 8.9 years (range, 6–13 years) in African American girls.

Pubertal breast enlargement (thelarche) is associated with increased amounts of glandular and connective tissue. The size and shape of breasts are determined by genetic factors, nutritional factors, and exposure to



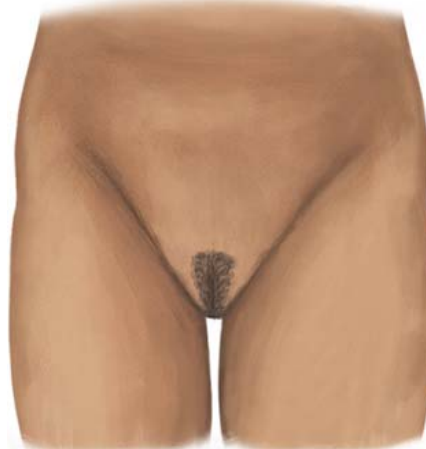Stage 1

The vellus over the pubes is the same as that over the anterior abdominal wall



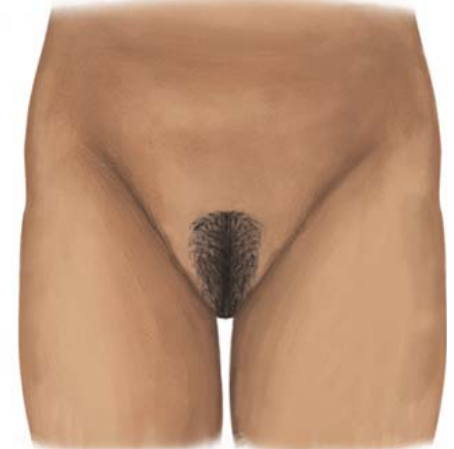Stage 2

Sparse slightly pigmented, downy hair along the labia that is straight or only slightly curled



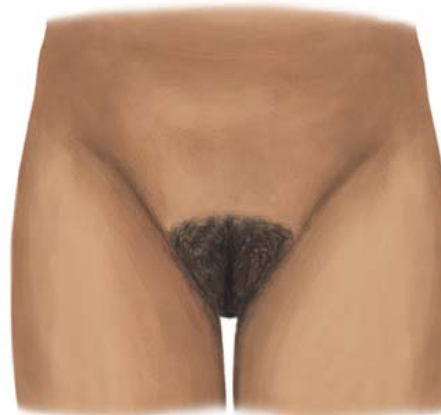Stage 3

Hair spreads sparsely over the pubic region and is darker, coarser, and curlier



Stage 4

Hair is adult type, but the area covered is smaller than in most adults, and there is no spread to the medial surface of the thighs



Stage 5

Hair is adult in quantity and type, distributed as an inverse triangle, and spreads to the medial surface of the thighs but not up the midline anterior abdominal wall

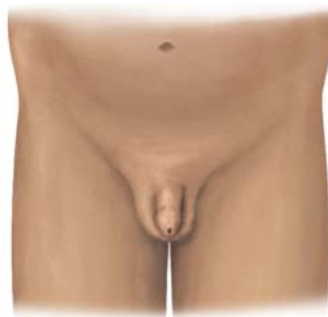K. Marshall

estrogen. Initially, breast development may be unilateral and then asynchronous. In the prepubertal girl (Tanner stage 1), there is elevation of papilla (see Plate 4-5). Tanner stage 2 is the breast bud stage, with enlargement of the areolar diameter and elevation of breast and papilla as a small mound. The mean age of onset of Tanner stage 2 breast development is 10.3 years in white girls and 9.5 years in African American girls. In Tanner stage 3, there is further enlargement of breast

and areola, but with no separation of their contours. In Tanner stage 4, the areola and papilla project above the level of the breast to form a secondary mound. In Tanner stage 5, the mature breast has formed, with recession of the areola, and only the papilla projects from the surface of the breast. The diameter of the papilla increases from 3 to 4 mm (in Tanner breast stages 1 through 3) to an average diameter of 9 mm in Tanner stage 5.



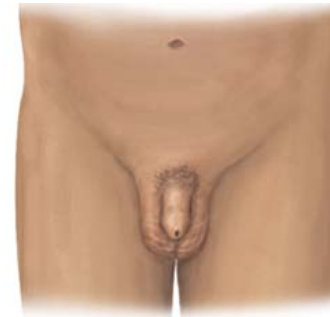## TANNER STAGES OF MALE PUBIC HAIR AND GENITAL DEVELOPMENT



Stage 1

Penis, testes, and scrotum are the same size and proportion as in early childhood

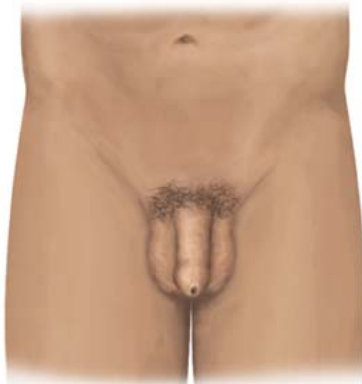The vellus hair over the pubic region is the same as that on the abdominal wall



Stage 2

Testes and scrotum enlarge, and scrotal skin shows a change in texture and reddening

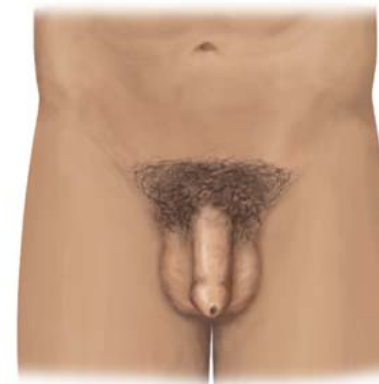Sparse growth of straight or slightly curled pigmented hair appearing at the base of the penis



Stage 3

Penile growth in length more than width; further growth of the testes and scrotum

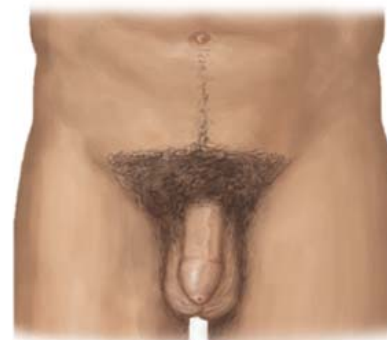Hair is coarser, curlier, and darker, spread sparsely over the junction of the pubes



Stage 4

Further penile growth and development of the glans; further enlargement of testes and scrotum

Adult-type hair, but area covered less than in most adults; no spread to the medial surface of the thighs



Stage 5

Genitalia are adult in size and shape

Adult in quantity and type of hair, distributed as an inverse triangle; spread is to the medial surface of the thighs

## NORMAL PUBERTY (Continued)

In the prepubertal girl (Tanner pubic hair stage 1), there is vellus-type hair over the pubic region, but it is not different from that over the anterior abdominal wall (see Plate 4-6). In Tanner stage 2, early pubic hair becomes evident; it is slightly pigmented and straight or slightly curled, appearing along the labia. The mean age of onset of Tanner stage 2 pubic hair development is 10.4 years in white girls and 9.4 years in African American girls. During Tanner stage 3, the hair spreads sparsely over the pubic region, and it becomes coarser, darker, and curlier. In Tanner stage 4, the hair is adult in type, but it covers a smaller area than in most adults and it does not appear on the medial surface of the thighs. In Tanner stage 5, the appearance is that of an adult in distribution (including the medial surface of the thighs), quantity, and type.

During the progression through the pubic hair stages, the vaginal mucosa undergoes changes because of estrogen effects. The vaginal mucosa loses its prepubertal reddish glistening form and becomes thickened and dull because of cornification of the vaginal epithelium. Several months before menarche, there is vaginal secretion of clear or whitish discharge. The length of the vagina increases, and the labia minor and majora become thickened and rugated. There is a rounding of body contours, a fat pad develops in the mons pubis, and the clitoris increases in size. The uterus enlarges from a prepubertal length of 3 cm to a postpubertal length of 8 cm. The endometrium begins to proliferate during the first stages of puberty.

In white girls in the United States, the average age of menstruation (menarche) onset is 12.8 years; it is 6 months earlier in African American girls. Menarche occurs 1 to 3 years after the onset of puberty, typically during Tanner stage 4. Ovulation does not occur until some additional months have elapsed. Until then, the menses are often erratic, and even then, anovulatory cycles are common for the first 2 years after menarche. Progesterone is secreted only as corpora lutea are formed after ovulation. When this occurs, the proliferative endometrium is transformed into a secretory type. The peak in ovarian primordial follicles is reached at 20 weeks of fetal life, and no additional germ cells develop after this time point. Under gonadotropin stimulation during puberty, the ovaries become microcystic with the development of follicles more than 4 mm in diameter. The ovarian volume increases from a prepubertal size of 0.2 to 1.6 mL to 2.8 to 15 mL during puberty.

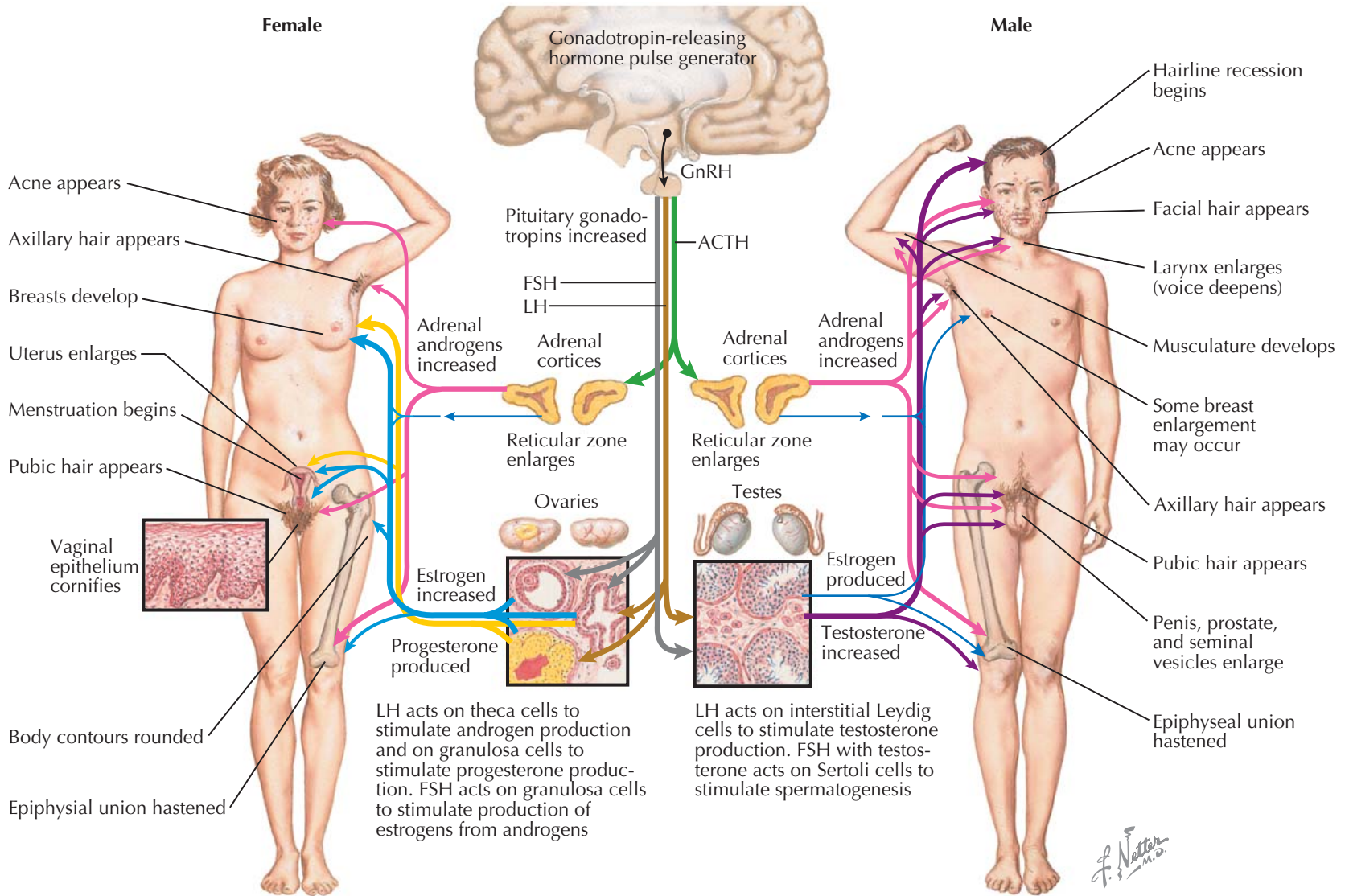
Axillary hair development is evident by age 12 years in more than 90% of African American girls and 70% of white girls. The development of acne—sometimes

the most obvious initial sign of puberty in a girl—is caused by adrenal and ovarian androgen secretion. Acne represents a dysfunction of the pilosebaceous unit, where there is follicular occlusion and inflammation as a result of androgenic stimulation. Facial changes occur during puberty in both boys and girls with enlargement of the nose, mandible, maxilla, and frontal sinuses. In girls, the pituitary gland increases in height from an average of 6 mm before puberty to an average of 10 mm by Tanner stage 5.

## MALE PUBERTY

The three main phenotypic pubertal events in boys are increased height velocity, genitalia development (under the control of pituitary gonadotropins and testicular testosterone secretion), and growth of axillary and pubic hair (under the control of androgens secreted by the testicles and adrenal glands). The first sign of puberty in boys is usually testicular growth; in the United States, this occurs approximately 6 months after the onset of breast development in girls.

**HORMONAL EVENTS IN FEMALE AND MALE PUBERTY**



**NORMAL PUBERTY (Continued)**

Testicular volume, which correlates with the stages of puberty, can be measured by comparing the testes with model ellipsoids (orchidometer) that have volumes ranging from 1 to 35 mL. The increase in size is primarily caused by seminiferous tubule growth. The main cell type in the seminiferous cords before puberty is the Sertoli cell, whereas in mature men, germ cells are the predominant cell type. With the increased LH levels with puberty, adult-type Leydig cells appear. Spermatogenesis starts between ages 11 and 15 years. Onset of puberty is predicted when a testis is more than 4 mL in volume. In adults, the average testicle has a volume of 29 mL; the right testis is usually slightly larger than the left, and the left testis is usually located lower in the scrotum than the right testis. When the phallus is measured, it should be flaccid and stretched. The phallus length is approximately 6 cm prepubertally and 12 cm in white men. The male areolar diameter also increases during puberty. The normal age range for onset of puberty in boys is 9 to 14 years.

In Tanner genital development stage 1 (prepubertal), the penis, testes, and scrotum are the same as in early childhood (see Plate 4-7). In Tanner stage 2, the testes and scrotum start to enlarge, and the scrotal skin starts to redden and change in texture. The average age at Tanner genital stage 2 is 11.2 years. In Tanner stage 3, penile growth has started, more evident in length than width, and there is also further enlargement of the testes and scrotum. In Tanner stage 4, the penis increases in size (both length and width), and the glans of the penis starts to develop; the testicles and scrotum continue to enlarge, and the scrotal skin becomes darker. In Tanner stage 5, the genitalia are adult in size and shape, and no further enlargement occurs.

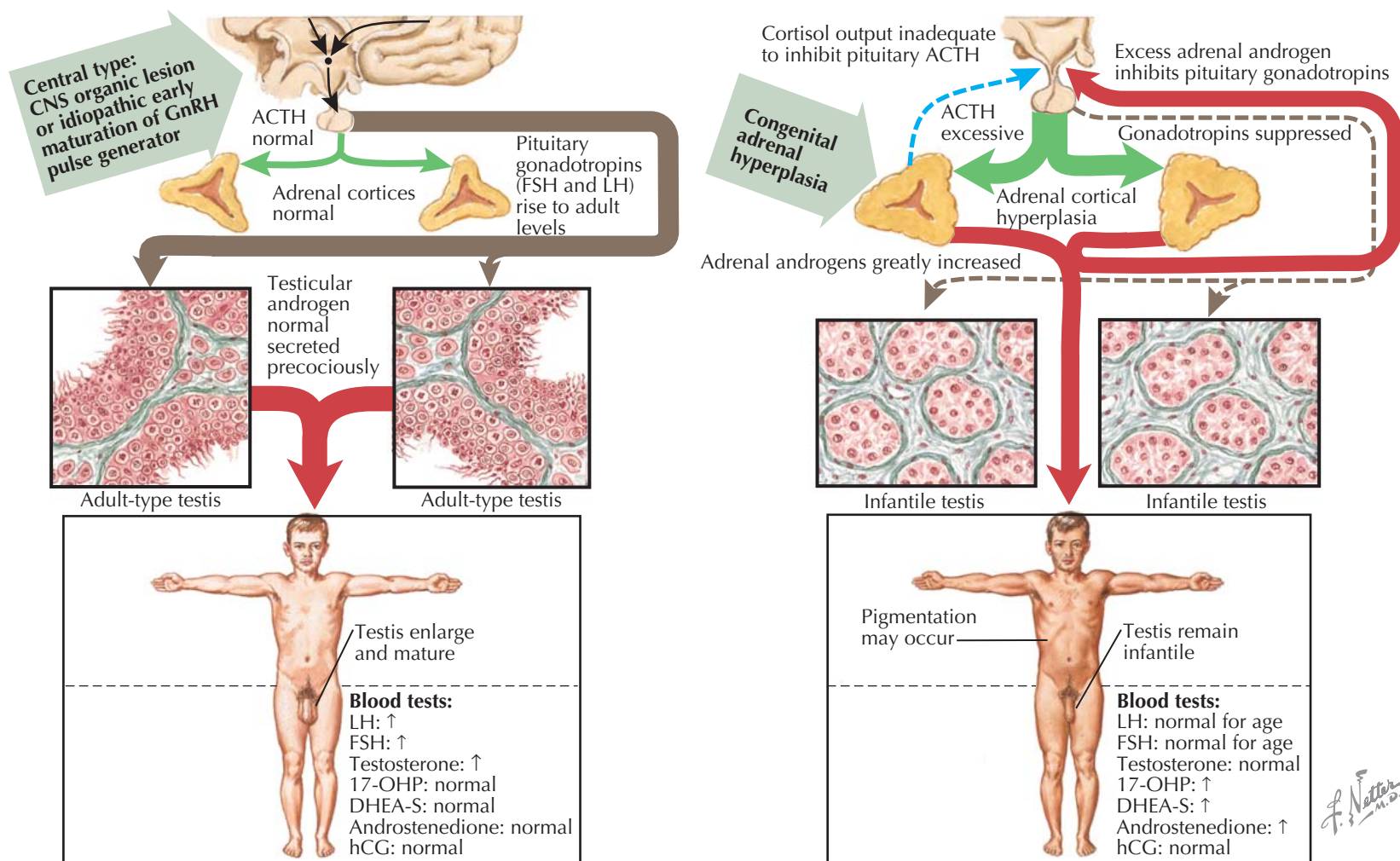
In Tanner pubic hair development stage 1 in boys, the hair over the pubic region is vellus in type and is the same as that on the abdominal wall (see Plate 4-7). In Tanner stage 2, there is sparse, straight or slightly curved, lightly pigmented hair that appears at the base of the penis. In Tanner stage 3, the hair is spread sparsely over the pubic area, and it is curlier, darker, and coarser. In Tanner stage 4, the hair, although adult in type, covers a smaller area than in most adults, and it

has not yet spread to the medial surface of the thighs. In Tanner stage 5, the hair is adult in type and quantity and is distributed to the medial surface of the thighs.

The vocal cords lengthen during puberty, and the larynx, cricothyroid cartilage, and laryngeal muscles enlarge. The pitch of the voice changes dramatically between Tanner genital stages 3 and 4. The average age when the adult voice is reached is 15 years. During Tanner pubic hair stage 3, facial hair starts to appear, initially at the corners of the upper lip and cheeks, then spreading to below the lower lip and eventually (after achieving Tanner pubic and genital stages 5) extending to the sides of the cheeks and chin. Axillary hair development is evident at age 14 years in boys. Acne, caused by testicular and adrenal androgen secretion, appears at an average age of 12 years (range, 9–15 years) and progresses through puberty. Pubertal gynecomastia occurs in about 50% of normally developing boys at an average age of 13 years, and it usually resolves spontaneously over 1 to 2 years (see Plate 4-25).

Facial changes occur during puberty in both boys and girls with enlargement of the nose, mandible, maxilla, and frontal sinuses.





## PRECOCIOUS PUBERTY

Precocious puberty is the initiation of puberty before the age of 8 years in girls and 9 years in boys. The cause may be benign (normal variant early adrenarche) or more serious (malignant germinoma). When the sexual characteristics are appropriate for the child's sex, it is termed *isosexual precocious puberty*. Inappropriate virilization in girls or feminization in boys is termed *contrasexual precocious puberty*. Precocious puberty is 10-fold more common in girls, in whom the cause is usually central in nature.

### GONADOTROPIN-DEPENDENT PRECOCIOUS PUBERTY

Central or true precocious puberty is gonadotropin-dependent and attributable to early maturation of the gonadotropin-releasing hormone (GnRH) pulse generator, a finding that is 20-fold more common in girls than in boys. Although this form of precocious puberty may be triggered by a central nervous system (CNS) process, the cause cannot be identified in 90% of affected girls. This development leads to premature

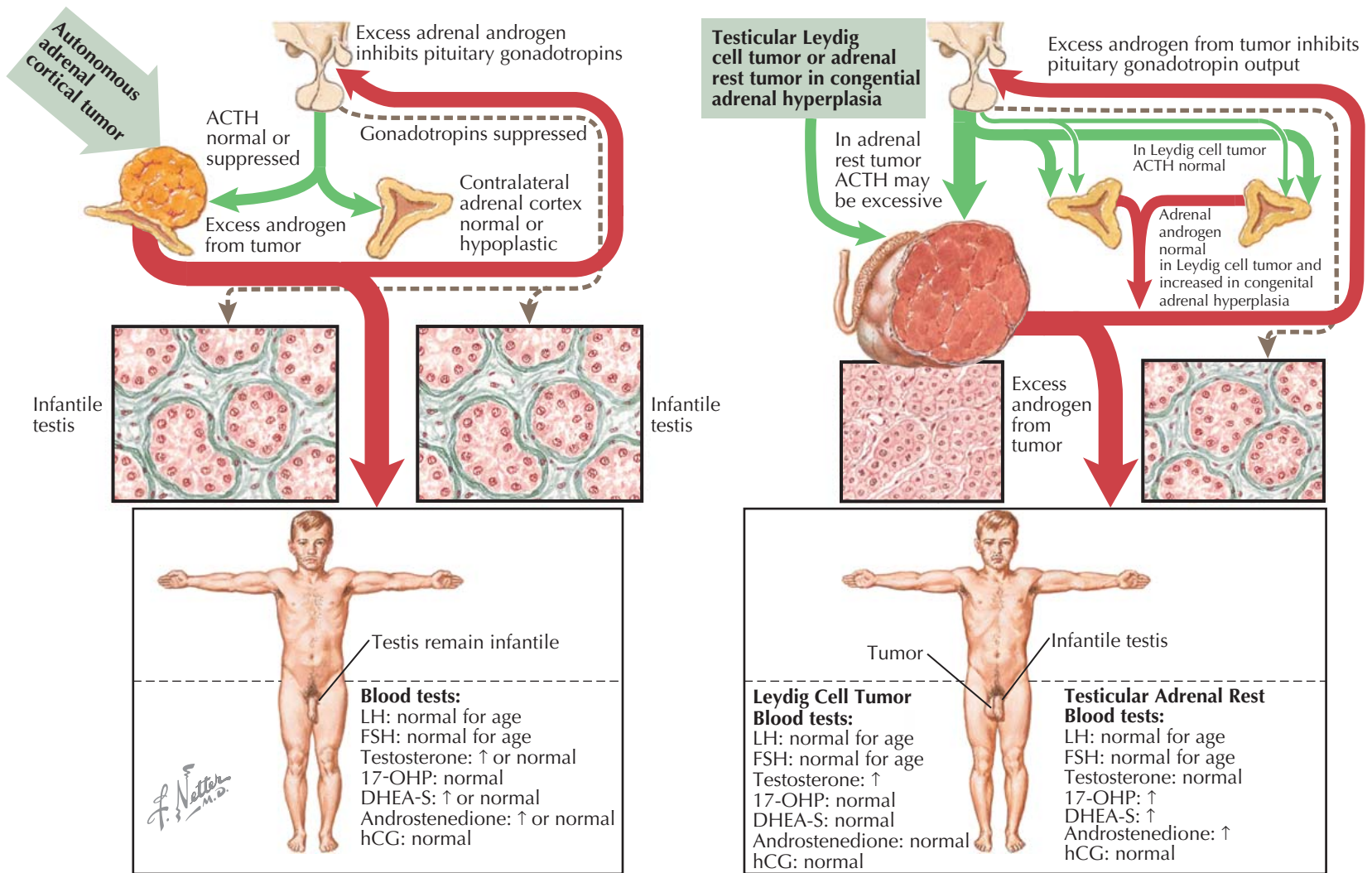
breast (thelarche) and pubic hair (pubarche) changes in girls and premature pubarche and testicular enlargement (gonadarche) in boys. When pubertal changes start, they progress at a pace and in an order found in puberty that starts at a normal age. The blood concentrations of luteinizing hormone (LH), follicle-stimulating hormone (FSH), testosterone, and estradiol are characteristic of those seen in normal puberty. These patients have an advanced bone age and accelerated growth for their age.

Although the etiology is usually idiopathic in girls, head magnetic resonance imaging (MRI) is indicated to exclude a CNS disorder. In boys with central precocious puberty, the etiology is idiopathic in half and a CNS abnormality in the other half. Some considerations in this setting include the following: hamartomas of the tuber cinereum that contain GnRH neurosecretory neurons and function as an ectopic GnRH pulse generator; astrocytoma; ependymoma; hypothalamic or optic gliomas in patients with neurofibromatosis type 1; any neoplasm in the hypothalamic region (e.g., craniopharyngioma) that impinges on the posterior hypothalamus; an adverse effect of CNS radiotherapy (e.g., for tumors or leukemia); hydrocephalus; CNS inflammatory disorder (e.g., sarcoidosis); congenital midline defects; and

pineal neoplasms. Hamartomas of the tuber cinereum are not actually tumors but rather congenital malformations that appear on MRI as an isodense fullness of the prepontine, interpeduncular, and posterior suprasellar cisterns. When the diameter of the hamartoma exceeds 1 cm, there is a high risk for seizures, which may be gelastic (laughing), petit mal, or generalized tonic-clonic. A rare cause is a gonadotropin-secreting pituitary tumor. Exposure to androgens (exogenous or endogenous) can trigger maturation of the GnRH pulse generator and central precocious puberty.

### GONADOTROPIN-INDEPENDENT PRECOCIOUS PUBERTY

Peripheral or gonadotropin-independent precocious puberty (also referred to as *pseudoprecocious puberty*) is caused by excess secretion of estrogen or testosterone from gonadal or adrenal sources. These patients usually do not follow the normal sequence and pace of puberty (e.g., menstrual bleeding may be the first sign). Depending on the type of sex hormone excess, gonadotropin-independent precocious puberty may be isosexual or contrasexual. Blood concentrations of LH and FSH are suppressed in these patients.



**PRECOCIOUS PUBERTY (Continued)**

The possible causes of isosexual gonadotropin-independent precocious puberty in girls include the following: exogenous estrogen (e.g., estrogen-containing creams and ointments), follicular ovarian cysts, ovarian neoplasms (e.g., granulosa-cell tumors, gonadoblastoma, and Leydig cell tumors), estrogen-secreting adrenal neoplasms, and McCune-Albright syndrome. McCune-Albright syndrome is associated with mutations in the *GNAS* gene that encodes the  $\alpha$ -subunit of the guanosine triphosphate (GTP)-binding protein (Gs) that is involved in adenylate cyclase activation. The disorder is caused by a postzygotic somatic mutation; thus, the extent of tissue involvement depends on how early in development the mutation occurs. The clinical presentation of McCune-Albright syndrome is the triad of gonadotropin-independent precocious puberty, irregularly edged café au lait spots that usually do not cross the midline, and bony fibrous dysplasia (e.g., hyperostosis of the skull base and facial asymmetry) (see Plate 4-11). Based on the tissue distribution of the somatic mutation, other endocrine hyperfunction disorders may be seen in

patients with McCune-Albright syndrome, including Cushing syndrome (bilateral adrenal hyperplasia), thyrotoxicosis, hyperparathyroidism (adenoma or hyperplasia), hypophosphatemic vitamin D-resistant rickets, and gigantism (mammotroph hyperplasia). McCune-Albright syndrome-related sexual precocity usually begins in the first 2 years of life with menstrual bleeding caused by autonomously functioning ovarian luteinized follicular cysts.

In boys with isosexual peripheral precocious puberty, the diagnostic considerations include the following: testicular Leydig cell tumors (usually benign); human chorionic gonadotropin (hCG)-secreting germ cell tumors (hCG is an LH receptor agonist) that arise from sites of embryonic germ cells (pineal region of the brain, posterior mediastinum, liver [malignant hepatoma and hepatoblastoma], retroperitoneum, and testicles). Germ cell tumors are malignant but may be indolent (e.g., dysgerminoma) or more aggressive (e.g., choriocarcinoma, embryonal cell carcinoma). Androgen-secreting adrenal tumors and congenital adrenal hyperplasia (e.g., 21-hydroxylase deficiency or, less commonly, 11 $\beta$ -hydroxylase deficiency) are additional considerations of isosexual gonadotropin-independent precocious puberty. Boys can also have a germline autosomal dominant activating mutation in the LH receptor gene

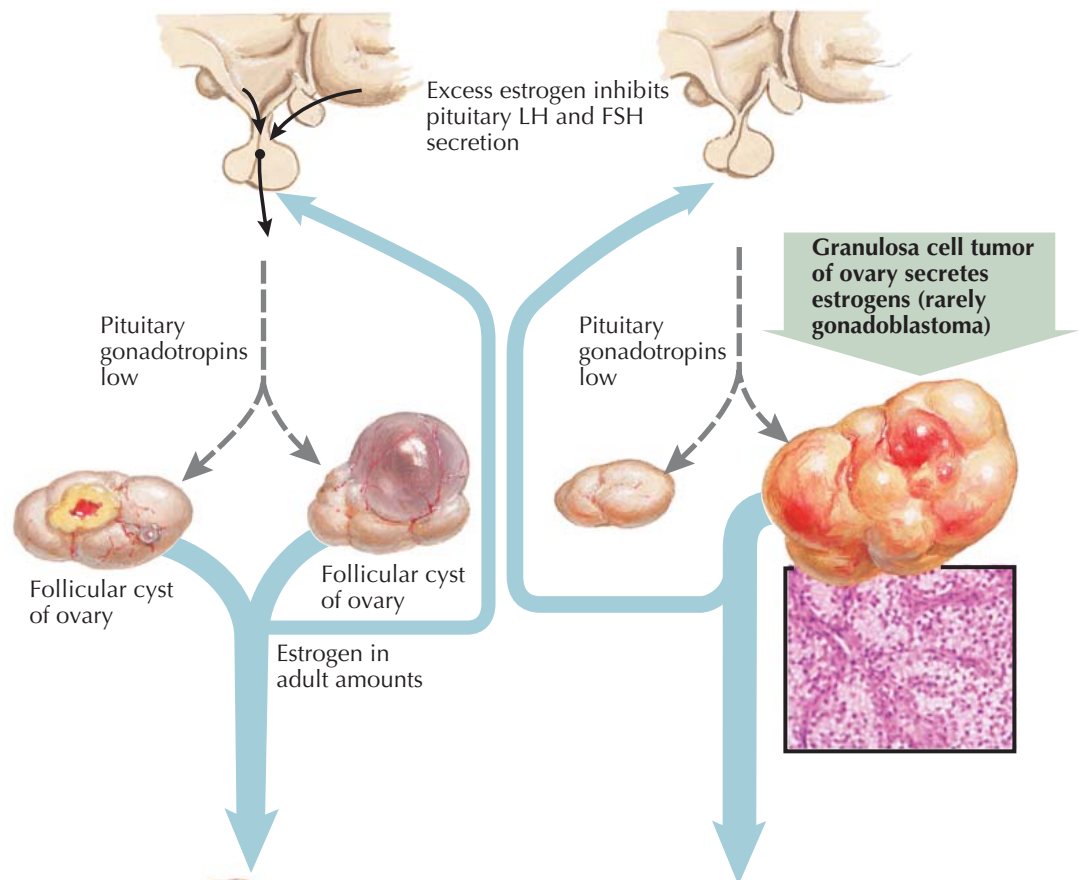
that predisposes to early Leydig cell development and testosterone secretion (testotoxicosis). McCune-Albright syndrome does occur in boys, although its occurrence is 50% less common than in girls.

Causes of contrasexual gonadotropin-independent precocious puberty in girls include exogenous androgens (e.g., testosterone gel), androgen-secreting adrenal neoplasms, and congenital adrenal hyperplasia. Causes of contrasexual gonadotropin-independent precocious puberty in boys include exogenous estrogen (e.g., estrogen-containing creams and ointments) and adrenal estrogen-secreting neoplasms.

**INCOMPLETE PRECOCIOUS PUBERTY**

Incomplete precocious puberty is the descriptor used for premature thelarche or premature adrenarche, both of which may be variants of normal puberty. Usually bone age is not advanced in these settings. Thus, premature thelarche may occur in isolation in normally developing girls, with no other signs of puberty. However, a subset of girls with premature thelarche or premature adrenarche may progress to gonadotropin-dependent precocious puberty. In addition, incomplete precocious puberty may be caused by long-standing, untreated primary hypothyroidism.





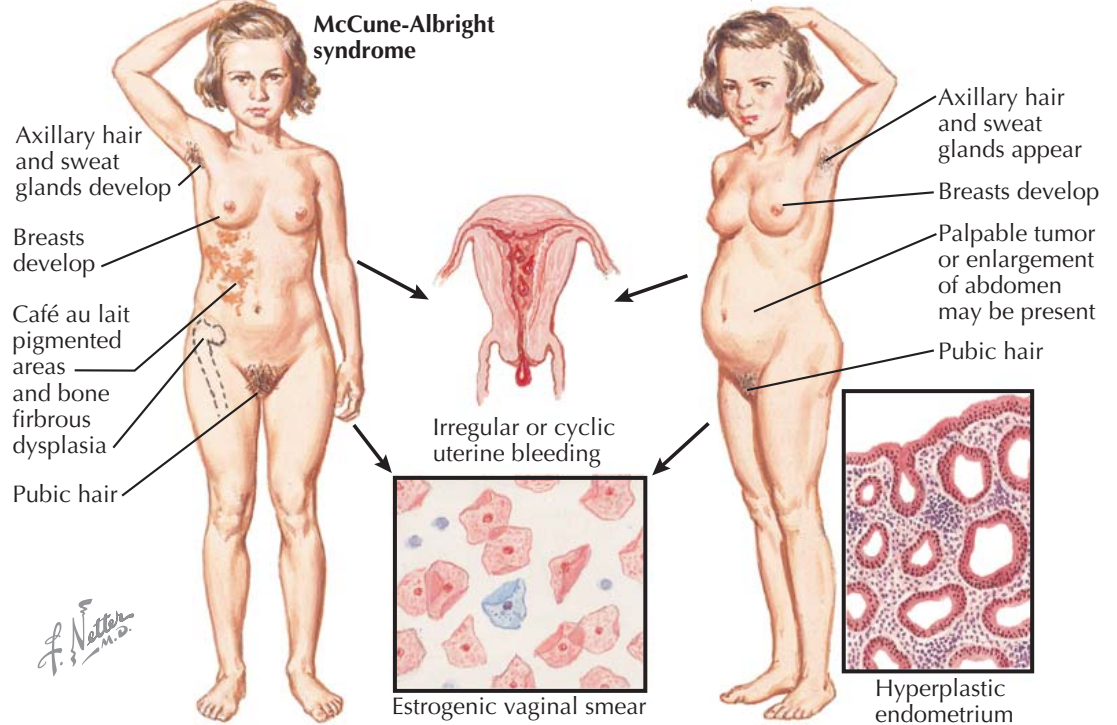
## PRECOCIOUS PUBERTY

(Continued)

### DIAGNOSTIC EVALUATION AND TREATMENT

A focused history and physical examination usually provide clues as to the cause of precocious puberty. For example, headaches, visual changes, or symptoms of diabetes insipidus should increase the suspicion for a mass in the hypothalamic region. All previous height measurements should be plotted on a growth chart. On physical examination, a detailed description of secondary sexual characteristics on the basis of the Tanner staging should be documented (see Plates 4-5 to 4-7). Measurements should be made of testicular volume and penile length in boys and of diameter of breast tissue in girls. The patient should be examined for the presence of multiple café au lait spots; in neurofibromatosis type 1, they are smoother in outline (“coast of California” appearance) than those associated with McCune-Albright syndrome (“coast of Maine” appearance). Complete neurologic examination may provide clues to an underlying CNS process. The abdominal and pelvic examination may detect a hepatic or ovarian mass. Testicular examination may show symmetric testicular enlargement in patients with central precocious puberty or a unilateral nodular enlargement in boys with Leydig cell tumors. Bone age should be evaluated to see if it is advanced compared with chronologic age. Basal blood concentrations of LH, FSH, estradiol, testosterone, 17-hydroxyprogesterone (17-OHP), dehydroepiandrosterone sulfate (DHEA-S), and androstenedione distinguish between central and peripheral precocious puberty. Serum thyrotropin should be measured in all patients with precocious puberty. Blood concentrations of  $\beta$ -hCG and  $\alpha$ -fetoprotein may be measured in select cases. Performing a GnRH stimulation test for LH may be necessary to confirm central precocious puberty, in which LH is expected to increase after GnRH administration.

Head MRI is indicated in patients with gonadotropin-dependent precocious puberty. Abdominal and gonadal



imaging are indicated in patients with gonadotropin-independent precocious puberty.

Treatment is determined by the cause and pace of precocious puberty. If a CNS lesion is discovered in patients with gonadotropin-dependent precocious puberty, treatment options are usually clear. For example, a dysgerminoma is usually confirmed by biopsy and then treated with radiation therapy, chemotherapy, or both. In patients with idiopathic gonadotropin-dependent precocious puberty (a

diagnosis of exclusion), treatment with a GnRH agonist is an effective option to arrest pubertal development, and it improves final adult height compared with final height of patients who are not treated.

The treatment of patients with gonadotropin-independent precocious puberty is directed at the source of sex hormone excess. For example, androgen excess associated with congenital adrenal hyperplasia caused by 21-hydroxylase deficiency is very effectively treated with glucocorticoid replacement.

## DISORDERS OF SEX DEVELOPMENT

### CLASSIFICATION

The distinction between the male and female phenotypes at birth is usually clear. However, ambiguous genitalia—found in every one of 4000 births—may delay sex assignment. Disorders of sex development (DSD) occur when there is a congenital discrepancy between external genitalia and the gonadal and chromosomal sex. For clinical purposes, the three main categories of DSD are:

#### 1. Sex chromosome DSD

- Turner syndrome: 45,X
- Klinefelter syndrome: 47,XXY
- Mixed gonadal dysgenesis: 45,X/46,XY
- Chimerism: 46,XX/46,XY

#### 2. 46,XX DSD (virilized XX female)

- Disorders of gonadal development (gonadal dysgenesis, ovotesticular DSD, testicular DSD)
- Androgen excess (fetal, maternal)

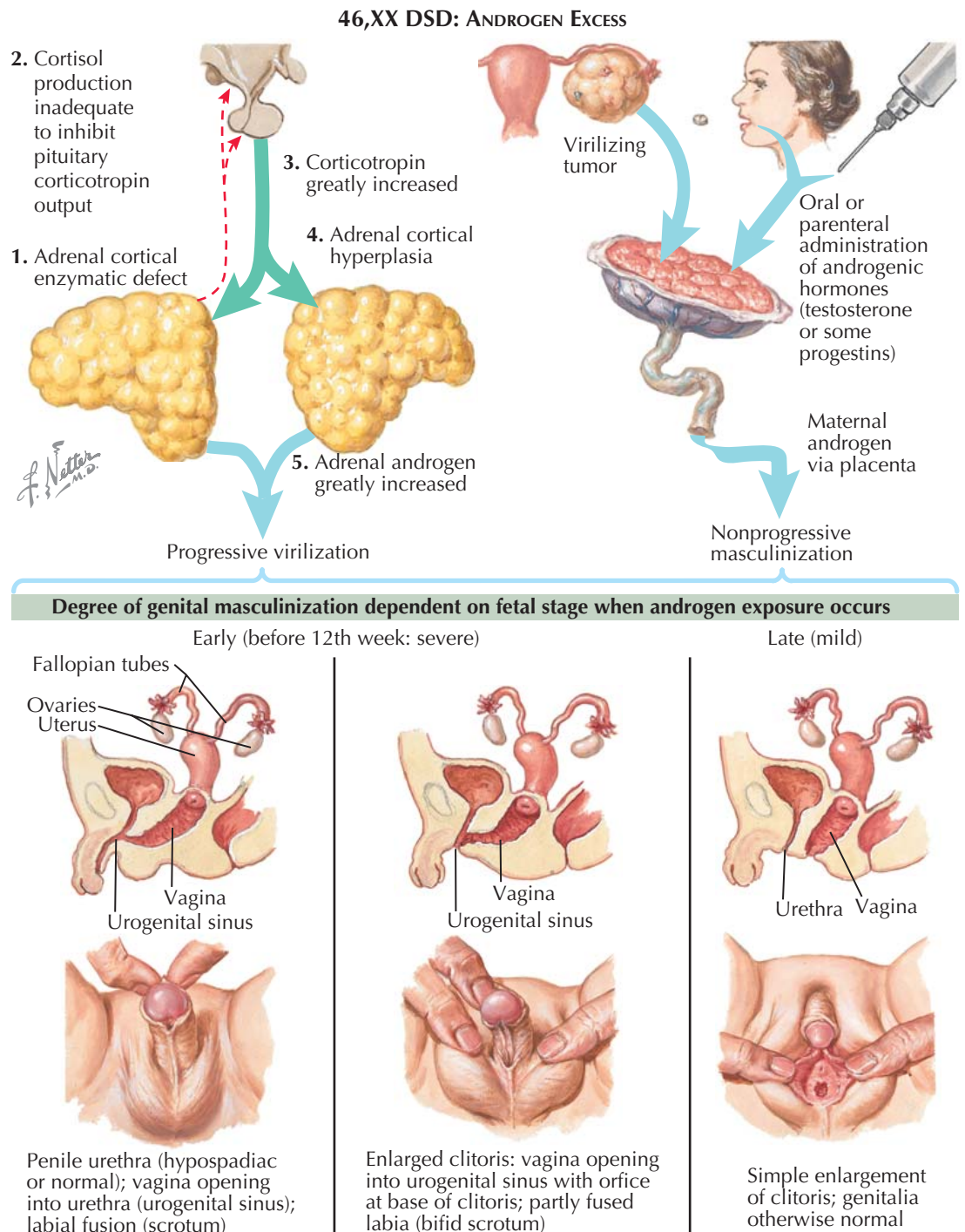
#### 3. 46,XY DSD (undervirilized XY male)

- Disorders of testis development (complete or partial gonadal dysgenesis, ovotesticular DSD, testis regression)
- Disorders of androgen synthesis or action (congenital adrenal hyperplasia [CAH], luteinizing hormone [LH] receptor mutations, 5 $\alpha$ -reductase 2 deficiency)

Sex determination can be considered to have three main components: chromosomal sex (e.g., 46,XX or 46,XY), phenotypic sex (e.g., male or female external genitalia), and gonadal sex (e.g., presence of ovaries or testicles). Psychosocial development is superimposed on these three components. DSD are congenital disorders in which the development of chromosomal, phenotypic, or gonadal sex is atypical. For example, ambiguous genitalia in a newborn may be caused by CAH, in which case it should be classified as 46,XX DSD. If the cause is partial androgen insensitivity syndrome, it should be classified as 46,XY DSD. For conceptual and practical purposes, DSD can be divided into sex chromosome DSD, disorders of testicular development and androgenization (46,XY DSD [male pseudohermaphroditism]), and disorders of ovarian development and androgen excess (46,XX DSD [female pseudohermaphroditism]).

### CHROMOSOMAL SEX

Chromosomal sex is determined at fertilization and usually results in 46,XY (male) or 46,XX (female) zygotes. However, meiotic nondisjunction may lead to gain or loss of sex chromosomal material in the ova



or sperm—sex chromosome aneuploidy—resulting in zygotes with chromosome complements such as 47,XXY (Klinefelter syndrome) and 45,X (Turner syndrome). Mitotic nondisjunction can occur in a zygote and lead to chromosomal mosaicism (e.g., 45,X/46,XX).

### GONADAL SEX

Gonadal sex is determined by the presence of ovaries or testicles. *SRY* is the testis-determining gene on the Y chromosome (see Plates 4-1 and 4-2). *SRY* and *SOX9* expression in the embryo leads to cellular proliferation and migration of mesonephric cells into the developing testis. However, many factors have a role in normal testicular development. Normal ovarian development is dependent on both expression of factors that prevent testis development and lack of expression of antimüllerian hormone (AMH).

### PHENOTYPIC SEX

#### Male Sexual Differentiation

Sexual differentiation is mediated by the secretion of several steroid and peptide hormones. For example, Sertoli cells produce AMH and inhibin B. The secretion of AMH (under the regulation of *SOX9* and other transcription factors) starts in seventh week of gestation and causes regression of müllerian structures (uterus, fallopian tubes, and the upper two-thirds of the vagina). If a fetus with a male chromosome complement (46,XY) has mutations in either AMH or its receptor or if there is Sertoli cell dysfunction, persistent müllerian duct syndrome (PMDS) and undescended testes (46,XY DSD) can result (see Plate 4-14). If a defect is limited to Leydig cell steroidogenesis, PMDS does not occur because Sertoli cell production of AMH is not affected.



## DISORDERS OF SEX DEVELOPMENT (Continued)

Fetal Leydig cells start to secrete androgens by the ninth week of gestation and are stimulated by placental human chorionic gonadotropin during the first two trimesters and by fetal pituitary LH in the last trimester of pregnancy. Cholesterol is taken up into Leydig cells, and LH stimulates the steroidogenic acute regulatory protein to generate its movement from the outer to the inner mitochondrial membrane. The cholesterol side chain is then cleaved by P450<sub>sc</sub> (CYP11A1) to produce pregnenolone. Pregnenolone is converted to either progesterone by 3 $\beta$ -hydroxysteroid dehydrogenase type 2 (HSD3B2) or to 17-hydroxypregnenolone by 17 $\alpha$ -hydroxylation by P450c17 (CYP17). Then 17-hydroxypregnenolone is converted to dehydroepiandrosterone (DHEA) by P450c17. DHEA is then converted to androstenedione by 3 $\beta$ -hydroxysteroid dehydrogenase type 2, and androstenedione is converted to testosterone by 17 $\beta$ -hydroxysteroid dehydrogenase type 3 (HSD17B3). Testosterone is converted to dihydrotestosterone (DHT) by 5 $\alpha$ -reductase type 2. DHT has high affinity for the androgen receptor and is the mediator of androgenization of the external genitalia and urogenital sinus. Testosterone production stabilizes the wolffian structures (vas deferens, epididymis, and seminal vesicles) (see Plate 4-2). The urogenital sinus becomes the prostate and prostatic urethra. The genital tubercle becomes the glans penis. The urogenital folds fuse to become the shaft of the penis. The urogenital swellings become the scrotum. Testicular descent has two stages: transabdominal and transinguinal. The transabdominal descent is initiated by the testes and starts at 12 weeks' gestation and is dependent on the contraction and thickening of the gubernacular ligament. The transinguinal descent is triggered by LH and androgens.

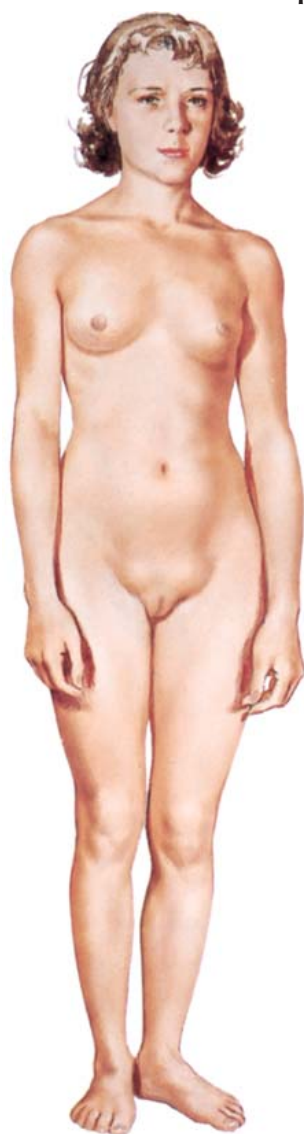### Female Sexual Differentiation

In females, the müllerian structures form the uterus, the upper portion of the vagina, and the fallopian tubes. Without local testosterone production from the testes, the wolffian structures degenerate. Normal uterine development can occur without the presence of ovaries. The urogenital sinus becomes the lower portion of the vagina and the urethra (see Plate 4-2). The genital tubercle becomes the clitoris. The urogenital folds become the labia minora, and the urogenital swellings become the labia majora. The ovaries express receptors for LH and follicle-stimulating hormone (FSH) at approximately 16 weeks' gestation. Circulating fetal FSH levels peak at week 20, and primary follicles form in the ovaries. Very little estrogen is secreted by fetal ovaries.

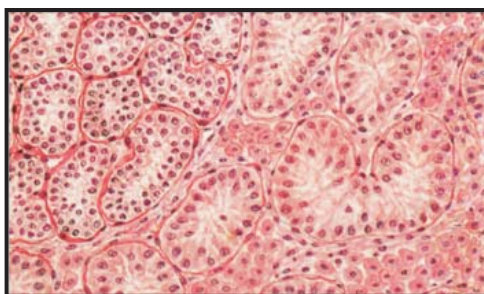
If a fetus with a female chromosome complement (46,XX) is exposed to androgens in utero (e.g., from the adrenal glands in the setting of CAH), androgenization of the external genitalia occurs (see Plate 4-12). In this setting, a uterus is present, and the testosterone concentrations are usually not high enough to stabilize wolffian structures.

### PSYCHOSOCIAL DEVELOPMENT

*Gender identity* is an individual's self-identification as female or male, and *gender role* refers to sex-specific behaviors (e.g., physical aggression, toy preferences, peer group interactions). *Sexual orientation* refers to the inclination of an individual with respect to heterosexual, homosexual, and bisexual behavior. Psychosocial



Relatively normal female habitus (inguinal herniae)

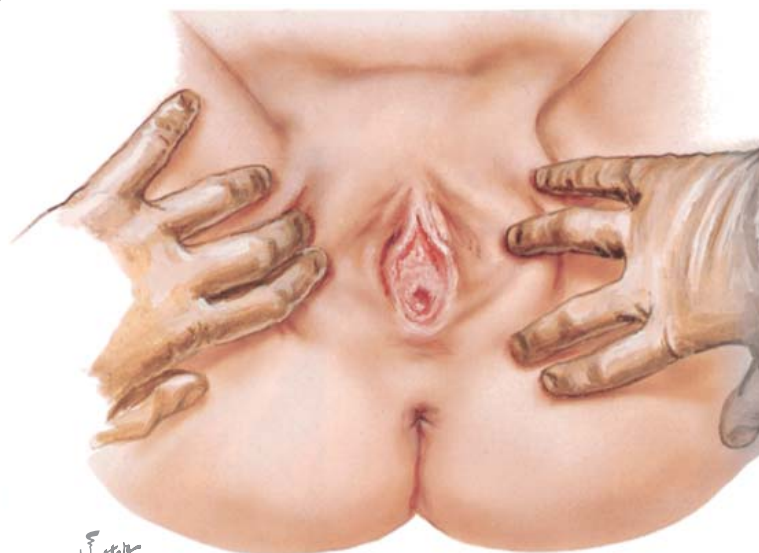

Section of testis typical of cryptorchidism (in situ neoplasia in upper left corner)

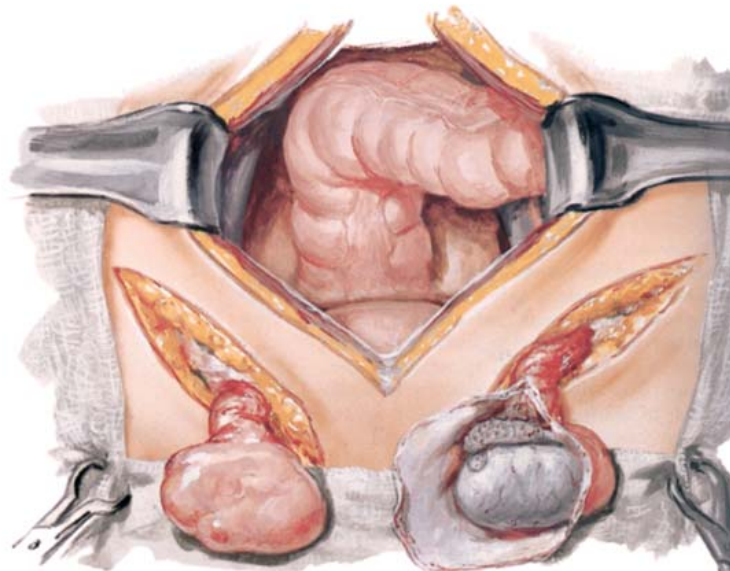
development is complex and depends in part on prenatal endocrine and innate chromosomal factors. It appears that the Y chromosome is not a major factor; for example, phenotypic women with complete androgen insensitivity syndrome have female psychosocial development despite an 46,XY karyotype. Psychosocial development may evolve; for example, children with 5 $\alpha$ -reductase deficiency may change their gender roles in adolescence.

The presenting phenotype in DSD is extremely variable and depends on the underlying condition.

## 46,XY DSD: ANDROGEN INSENSITIVITY SYNDROME



Normal female external genitalia (or slightly masculinized) vagina ends blindly



Testes operatively exposed in groins; laparotomy reveals complete absence of uterus, fallopian tubes, and ovaries

Defining the basis for DSD is important with respect to gender assignment, treatment, and associated medical implications.

### SEX CHROMOSOME DISORDERS OF SEX DEVELOPMENT

Sex chromosome aneuploidy is sex chromosome DSD. The most common examples are Klinefelter syndrome (47,XXY) and Turner syndrome (45,X) (see Plates 4-17 to 4-20).



**DISORDERS OF SEX DEVELOPMENT** (Continued)

**Mixed Gonadal Dysgenesis**

The 45,X/46,XY mosaic karyotype is a form of mixed gonadal dysgenesis that is associated with a wide range of external genitalia phenotypes (normal female external genitalia, clitoromegaly, ambiguous genitalia, hypospadias, or normal male external genitalia).

The gonadal phenotypes range from ovary-like stroma with primordial follicles to intraabdominal streak gonads to normal testes in the scrotum. When AMH production by Sertoli cells is impaired, müllerian structures may be evident (see Plate 4-14). Physical features can range from those seen with Turner syndrome (e.g., short stature) to those characterizing a normal male phenotype.

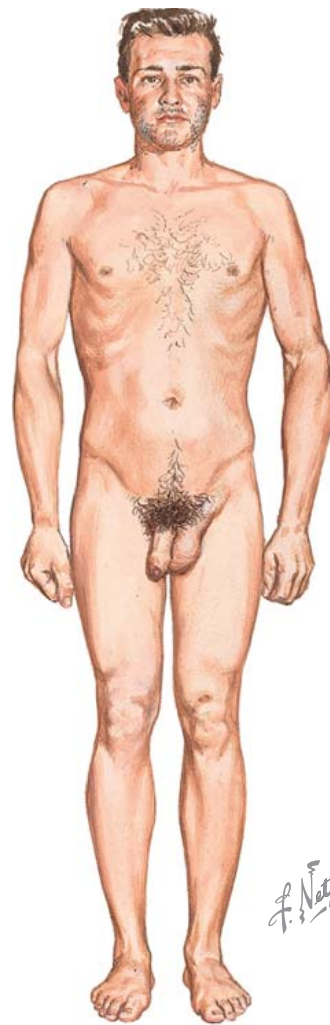In this setting, the infant is usually raised as a girl if there is only minimally androgenized genitalia. In this circumstance, the dysgenic intraabdominal gonads should be removed, and estrogen replacement should be initiated at the time of puberty. If a uterus is present, a progestational agent should be added.

When the ambiguous genitalia are limited to hypospadias, the infant is usually raised as a boy. The hypospadias is repaired, and if the testicles have not descended, orchiopexy should be performed. Exogenous testosterone therapy may be needed at the time of puberty.

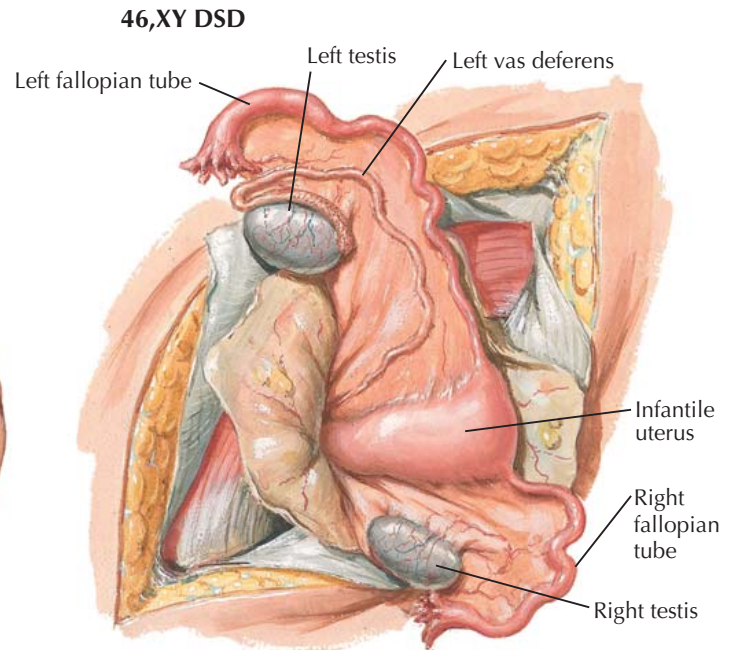
When the genitalia are highly ambiguous, a multidisciplinary approach and parental involvement are needed because management is complex. When raised as girls, these patients require urogenital surgery and gonadectomy, and they are infertile because they lack a uterus. When raised as boys, they require gonadectomy and surgery for hypospadias, and they have poor erectile function.

**Chimerism**

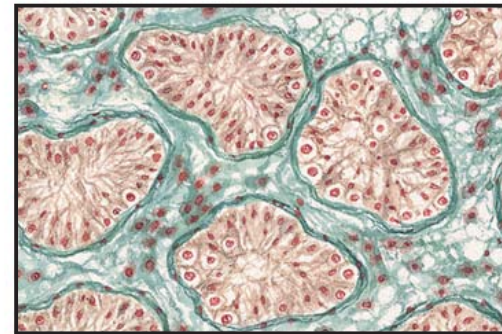
46,XX/46,XY chimerism results from double fertilization or from ovum fusion and can result in ovarian and testicular tissue in the same or opposite gonads (true hermaphroditism) (see discussion under 46,XX DSD).



Normal male habitus with inguinal hernia

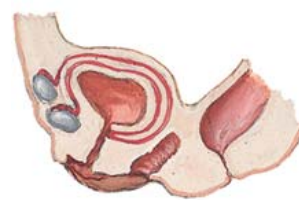

Persistent müllerian duct syndrome with testes, uterus, and fallopian tubes in hernial sac

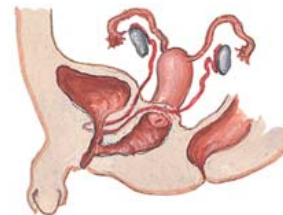


Testes usually atrophic, characteristic of cryptorchidism; spermatogenesis occasionally present

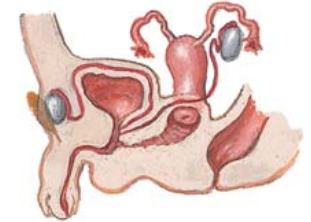
**Some variations in male sexual differentiation**



Androgen insensitivity syndrome with normal antimüllerian hormone secretion and function



Testicular dysgenesis with varying deficiencies of androgens and antimüllerian hormone resulting in a wide range of findings



Persistent müllerian duct syndrome caused by Sertoli cell dysfunction or mutations in either the antimüllerian hormone gene or its receptor

**46,XX DISORDERS OF SEX DEVELOPMENT**

The causes of 46,XX DSD include disorders of ovarian development (gonadal dysgenesis, ovotesticular DSD, testicular DSD) and androgen excess (CAH, gestational hyperandrogenism). However, it should be recognized that most causes of XX virilization remain undefined.

**Congenital Adrenal Hyperplasia**

CAH is the most common cause of virilized infants with a female chromosome complement (46,XX) (see Plate 4-12). The most frequent steroid synthetic enzymatic defect is in 21 $\alpha$ -hydroxylase (CYP21A2), followed by 11 $\beta$ -hydroxylase and 3 $\beta$ -hydroxysteroid dehydrogenase deficiencies (see Plates 3-13 and 3-14).

**Gestational Hyperandrogenism**

Exposure of an XX fetus to excess maternal androgens during development can lead to virilization with normal female internal anatomy (see Plate 4-12). In addition to CAH, causes include theca-lutein cysts and placental aromatase enzyme deficiency.

**Testicular Disorders of Sex Development**

46,XX DSD with evidence of functioning testicular tissue may be caused by translocation of *SRY* or by *SOX9* duplication. These abnormalities may be detected

by using fluorescence in situ hybridization probes for the *SRY* and *SOX9* genes.

**Ovotesticular Disorders of Sex Development (True Hermaphroditism)**

Ovotesticular DSD is defined as the presence of both testicular and ovarian tissue in the opposite or the same gonads (see Plate 4-15). Most of these patients have a 46,XX karyotype, and there are probably multiple underlying causes. Less commonly, they have 46,XX/46,XY chimerism that results from double fertilization or ovum fusion. Most patients with ovotesticular

DSD have a unilateral ovotestis on one side and an ovary or testis on the other side. Approximately 30% of affected patients have ovarian and testicular tissue bilaterally (e.g., ovotestes). The least common form of ovotesticular DSD is characterized by a testis on one side and an ovary on the other side. When an ovary is present, it is typically in the usual anatomic location. However, a testis or ovotestis is usually undescended. The genital ducts typically develop as does the gonad. For example, a hemiuterus is usually present on the side of the ovary or ovotestis. Menses and pubertal breast development may occur.



## DISORDERS OF SEX DEVELOPMENT (Continued)

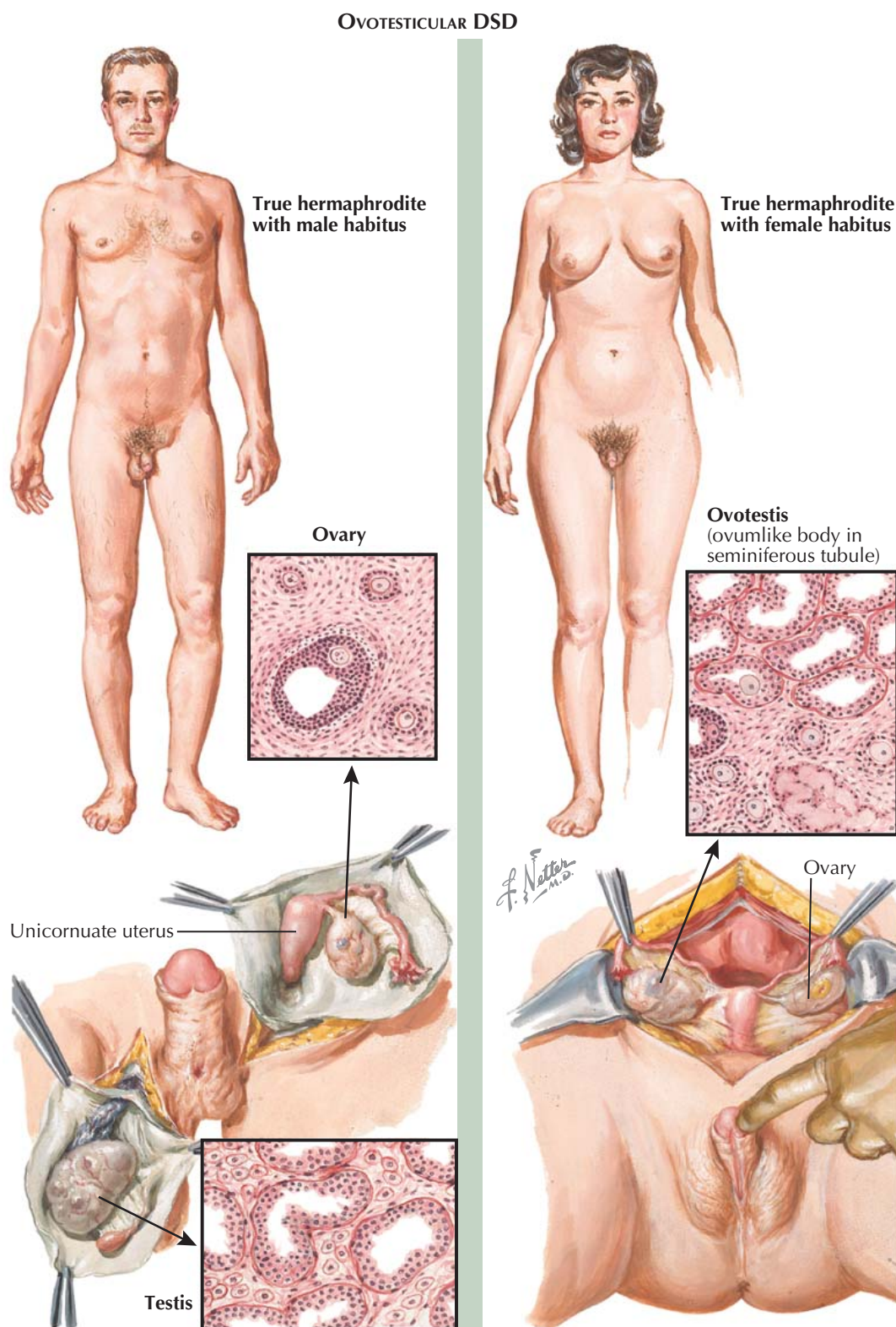
When there is a clinically important amount of testicular tissue, the male changes at puberty may dominate. Gender assignment in infants with ovotesticular DSD follows similar steps as those highlighted in the discussion on mixed gonadal dysgenesis.

### 46,XY DISORDERS OF SEX DEVELOPMENT

The causes of undervirilization of male infants (46,XY DSD) include abnormalities in testicular development, androgen synthesis, or androgen action. Complete testicular dysgenesis (Swyer syndrome) may be caused by insufficient AMH production or action and results in persistent müllerian structures and lack of androgenization of the external genitalia (see Plate 4-14). Partial testicular dysgenesis may result in ambiguous genitalia with or without a uterus and vagina. Milder variants may present with hypospadias, micropenis, or infertility. Although the cause of testicular dysgenesis is infrequently found, many molecular genetic abnormalities have been identified (mutations in the following genes: *SRY*, steroidogenic factor 1 gene [*SFI*], androgen receptor gene [*AR*], LH receptor gene [*LHCGR*], Wilms tumor–related gene [*WT1*], sex-determining region Y-box 9 gene [*SOX9*], desert hedgehog homolog gene [*DHH*], aristaless-related homeobox gene [*ARX*], TSPY-like 1 gene [*TSPYL1*]).

Decreased androgen synthesis may also result from CAH caused by  $17\alpha$ -hydroxylase deficiency,  $3\beta$ -hydroxysteroid dehydrogenase deficiency, P450 side-chain cleavage deficiency, and steroidogenic acute regulatory protein deficiency (lipoid hyperplasia). LH receptor defects (resulting in Leydig cell hypoplasia),  $5\alpha$ -reductase deficiency, and  $17\beta$ -hydroxysteroid dehydrogenase type 3 deficiency (the most common defect in testosterone synthesis) can also cause abnormal androgen production. Steroid  $5\alpha$ -reductase deficiency is an autosomal recessive disorder in which individuals with a male chromosome complement (46,XY) who have bilateral testes and normal testosterone formation have impaired external virilization during embryogenesis because of defective conversion of testosterone to dihydrotestosterone.

Causes of decreased androgen action include androgen insensitivity syndrome (AIS), which may be partial (PAIS) or complete (CAIS) (see Plate 4-13). In the past, CAIS was termed *complete testicular feminization*. AIS is associated with mutations in the androgen receptor gene (*AR*) so that despite the presence of testes and normal testosterone production, there is absent (CAIS) or partial (PAIS) virilization. PAIS, referred to in the past as *incomplete testicular feminization*, may be diagnosed in infants with ambiguous genitalia, adolescent girls who become virilized, adolescent boys with pubertal delay or gynecomastia, and men with infertility. CAIS typically does not present until inguinal hernias or labial masses are noted in young girls or primary amenorrhea becomes evident. These phenotypic women lack secondary sex hair and a uterus; the karyotype is 46,XY, and the serum testosterone level is in the reference range for a male. Gonadectomy should be performed to prevent tumor formation in cryptorchid testes.

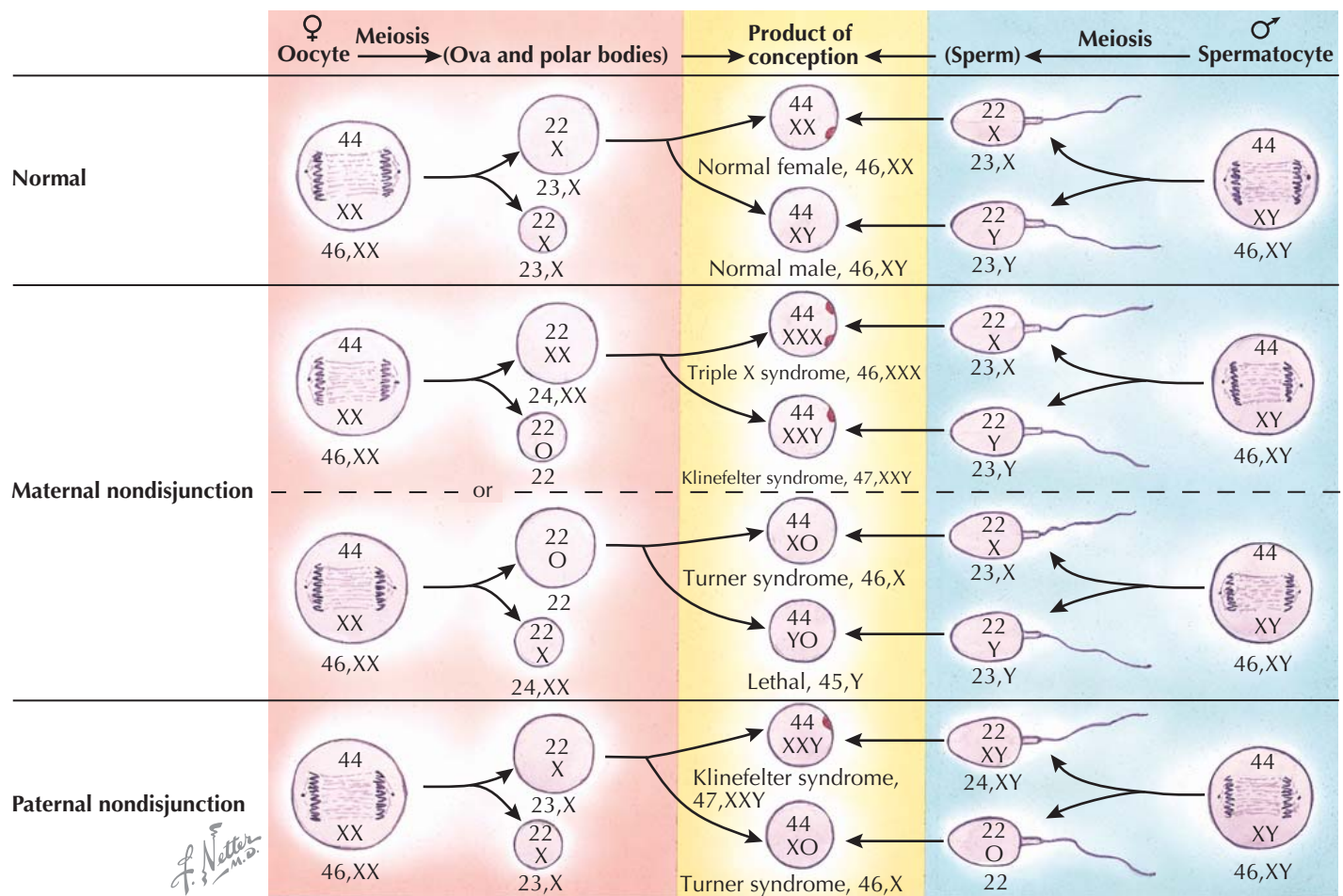


### EVALUATION AND TREATMENT

The evaluation of infants with ambiguous genitalia should include a history to ascertain whether there are other affected family members and to document maternal treatments and exposures during pregnancy; physical examination to document external genitalia findings and to check for gonads in the labia or inguinal canal; laboratory tests to assess for CAH (e.g., serum electrolytes, corticotropin,  $17$ -hydroxyprogesterone,  $11$ -deoxycortisol, cortisol, and DHEA); karyotype analysis,

including fluorescence in situ hybridization with *SRY* probe; and ultrasonography of pelvic and abdominal structures to determine whether a uterus, gonads, and a vagina are present. The initial goal is to determine whether the infant has sex chromosome DSD, 46,XX DSD, or 46,XY DSD; additional tests are recommended on the basis of this distinction.

The cause of DSD has important implications for gender assignment, treatment, risk of tumor formation in cryptorchid testes, determination of future fertility options, and counseling of patients and their families.



### ERRORS IN CHROMOSOMAL SEX

Many abnormalities in sex differentiation can be attributed to errors in chromosomal number or to morphologic abnormalities in the sex chromosomes. Humans have 46 chromosomes—22 pairs of autosomes (numbered 1 to 22 based on size) and one pair of sex chromosomes (XX or XY). During mitosis, each of the 46 chromosomes replicates itself exactly, so that each daughter cell again has the diploid number. A different process occurs in the production of germ cells, in which each primary spermatocyte or primary oocyte undergoes two meiotic divisions, to form, respectively, either four sperm cells or two ova and two polar bodies. Each of these cells contains the haploid number of 23 chromosomes. Chromosomal sex is determined at fertilization, in which two haploid gametes—sperm and ova—fuse to produce a diploid zygote with 46 chromosomes. A normal ova has one X chromosome, and a normal sperm has either a single X chromosome or a single Y chromosome. This process, in a single meiotic division, is illustrated in the upper section of the plate.

Errors in chromosomal number may be caused by faulty cell division of the parental gametocytes in meiosis or by faulty cell division in the zygote after fertilization (mitosis). Although exact halving of the chromosome number during meiosis and exact

replication of the 46 chromosomes during mitosis ideally takes place, occasionally a chromosome becomes misplaced on the spindle and migrates to the wrong pole. In such instances, one daughter cell contains an extra chromosome, and the other daughter cell is deficient. This phenomenon, known as *nondisjunction*, may occur during either meiosis or mitosis. Fertilization of these abnormal gametes results in a zygote with an abnormal sex chromosome number. Examples of sex chromosome aneuploidy include 45,X; 47,XXY; 47,XXX; and 45,Y. Zygotes that lack X chromosomal material (e.g., 45,Y) are not viable.

The 45,X karyotype (Turner syndrome), which occurs in approximately one in 2500 live-born phenotypic female births, is caused by nondisjunction or chromosome loss during gametogenesis in either parent. The paternal X chromosome ( $X^p$ ) is retained in one-third of patients, and the maternal X chromosome ( $X^m$ ) is retained in the remaining two-thirds. Approximately 25% of patients with Turner syndrome have chromosome mosaicism (e.g., 45,X/46,XX) caused by mitotic errors that occurred in a zygote with an initially normal chromosome complement.

Klinefelter syndrome, which occurs in approximately one in 1000 live-born phenotypic male births, is the result of extra X chromosome material—most commonly 47,XXY and less commonly 48,XXXY; 46,XY/47,XXY mosaicism; and 46,XX (phenotypic males). The 47,XXY karyotype is caused by nondisjunction of sex

chromosomes during the meiotic division of gametogenesis in either parent. Mosaicism such as 46,XY/47,XXY results when mitotic errors occur in a zygote with an initially normal chromosome complement.

Triple X syndrome (47,XXX), also called trisomy X, occurs in one in 1000 newborn girls. Although triple X syndrome does not have an abnormal phenotype, individuals with this chromosome complement may be taller than average; have an increased risk of learning disabilities; and have delayed development of speech, language, and motor skills. These individuals have normal sexual development and are fertile.

The karyotype—an analysis of chromosome number and morphology—is determined from DNA in peripheral blood leukocytes. Cytogenetic techniques used to detect sex chromosome abnormalities include examination of chromosome number, banding patterns, Y-chromatin fluorescence, and fluorescence in situ hybridization (FISH). In some cases, the documentation of mosaic status requires karyotyping other tissues (e.g., skin or gonads). However, even with these additional analyses, sometimes additional molecular genetic techniques are required. For example, the sex-determining region Y gene (*SRY*) on the Y chromosome may be translocated to the X chromosome, resulting in a 46,XX male. In addition, mutations in *SRY* may result in 46,XY females with gonadal dysgenesis. Molecular genetic testing can identify the presence of an abnormal *SRY* sequence.



## KLINEFELTER SYNDROME

Klinefelter syndrome is the most common genetic cause of primary hypogonadism, occurring in approximately one in 1000 live-born phenotypic male births. Klinefelter syndrome is the result of extra X-chromosome material—most commonly 47,XXY and less commonly 48,XXXY; 46,XY/47,XXY mosaicism; and 46,XX (phenotypic male). The 47,XXY karyotype is caused by nondisjunction of sex chromosomes during the meiotic division of gametogenesis in either parent (see Plate 4-16). Mosaicism such as 46,XY/47,XXY results when mitotic errors occur in a zygote with an initially normal chromosome complement. The extra X chromosome produces little or no abnormality until adolescence, when affected patients develop small, firm testes with hyalinized seminiferous tubules and clumped Leydig cells; azoospermia; small phallus; gynecomastia; mild to moderate degrees of eunuchoidism; decreased virilization; and elevations in blood concentrations of luteinizing hormone (LH) and follicle-stimulating hormone (FSH).

The eunuchoid body proportions are attributable to testosterone deficiency and delayed epiphyseal fusion. Although nearly always infertile, these men may show a spectrum of inadequate masculinization ranging from moderately severe eunuchoidism to an almost normal male phenotype. Blood concentrations of LH and FSH are usually elevated because of Leydig cell and seminiferous tubule dysfunction, respectively. The degree of gynecomastia is highly variable and is associated with the degree of testosterone deficiency.

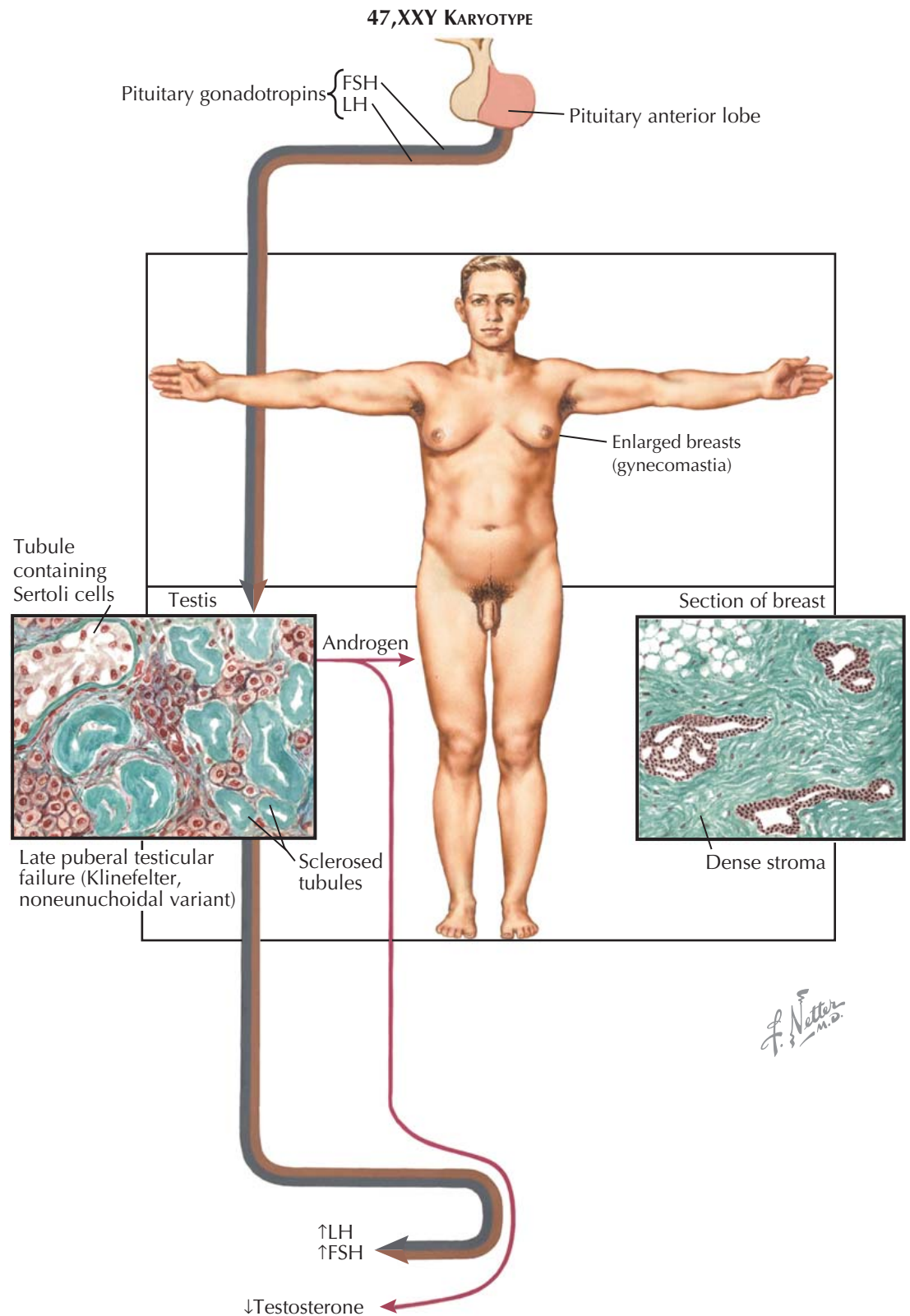
Characteristically, the gonads exhibit an irregular distribution of tubules and tubular scars, separated by loose connective tissue and clumps of Leydig cells. The number of Leydig cells is often increased, and nests of them may assume the configuration of adenomas. There is considerable variation in the size of nonhyalinized tubules; some contain only Sertoli cells, and others reveal germ cells in early stages of maturation. The basement membrane of the seminiferous tubules is thickened and sclerosed, and many tubules contain large depositions of hyalin. The elastic membrane is frequently absent or poorly developed. Before adolescence, the testes are relatively normal, although subtle changes may be apparent to a pathologist skilled in testicular histopathology.

Men with Klinefelter syndrome usually do not have multiple congenital abnormalities (as in Turner syndrome), but they may have mild mental impairment, anxiety, or depression. In addition, psychosocial issues are common. For example, they may lack insight, have difficult social interactions, demonstrate poor judgment, and have cognitive deficits in verbal processing.

These individuals are also at increased risk for the development of pulmonary disorders (e.g., emphysema, bronchiectasis), cancer (e.g., mediastinal germ cell tumors, breast cancer), diabetes mellitus, and varicose veins.

Phenotypic men with a 46,XX karyotype have a similar phenotype to Klinefelter syndrome, with the exception of hypospadias and short stature. This disorder results from the translocation of the *SRY* gene from the Y chromosome to the short arm of the X chromosome.

The 47,XXY karyotype results in phenotypically normal males. Testicular function is usually normal, and they are fertile. Males with this karyotype do seem



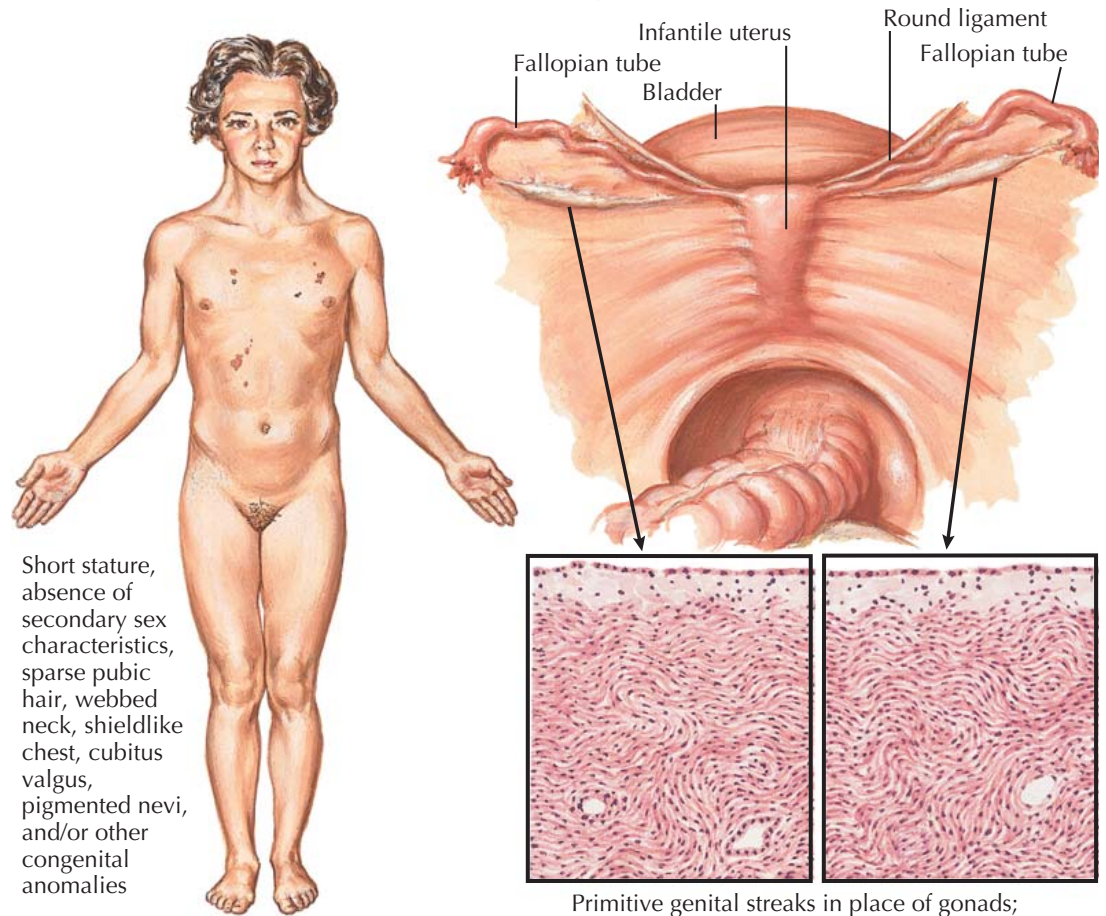
to have an increased risk of learning disabilities and delayed speech and language development.

The diagnosis of Klinefelter syndrome should be suspected in tall adolescent or adult males with gynecomastia and small testicles. The clinical suspicion can be confirmed with peripheral leukocyte karyotype. Blood levels of testosterone and inhibin-B are low. Serum estradiol levels are in the reference range for males.

Blood concentrations of LH and FSH are increased. Semen analysis typically shows azoospermia, although spontaneous fertility may occur in patients with 46,XY/47,XXY mosaicism.

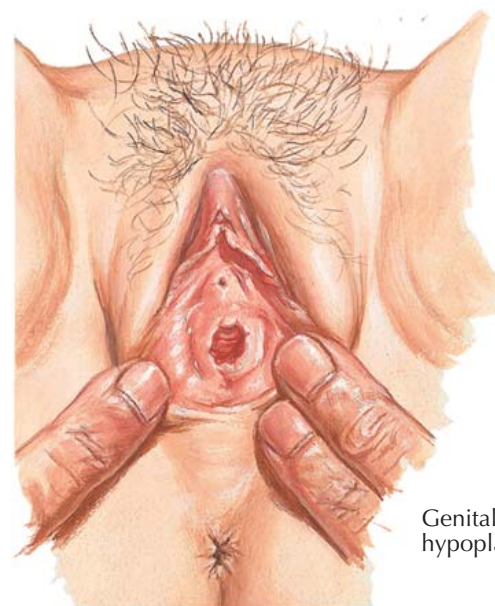
Testosterone replacement usually effectively treats the signs and symptoms associated with hypogonadism. The testosterone dosage should be adjusted for a mid-normal serum testosterone concentration.

TURNER SYNDROME: 45,X KARYOTYPE

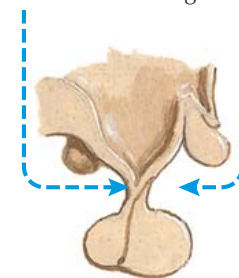


Short stature, absence of secondary sex characteristics, sparse pubic hair, webbed neck, shieldlike chest, cubitus valgus, pigmented nevi, and/or other congenital anomalies

Primitive genital streaks in place of gonads; wavy stroma with absence of germinal elements



Genitalia female but infantile; hypoplasia of labia minora common



Gonadal estrogen failure stimulates high output of pituitary gonadotropins

TURNER SYNDROME (GONADAL DYSGENESIS)

Turner syndrome (gonadal dysgenesis), or X-chromosome monosomy, is an important clinical consideration in young women with short stature and primary amenorrhea. As classically described by Turner in 1938, patients with this syndrome are short and may display a variety of visible congenital abnormalities such as a short, webbed neck (pterygium colli); cubitus valgus; and a broad, shieldlike chest. This disorder occurs in approximately one in 2500 live-born phenotypic female births. The 45,X karyotype appears to be caused by nondisjunction or chromosome loss during gametogenesis in either parent (see Plate 4-16). The paternal X chromosome ( $X^p$ ) is retained in one-third of patients, and the maternal X chromosome ( $X^m$ ) is retained in the remaining two-thirds. Approximately 25% of patients with Turner syndrome have mosaicism (e.g., 45,X/46,XX) caused by mitotic errors that occurred in a zygote that initially had a normal chromosome complement. The short stature in Turner syndrome, present in nearly all affected patients, is associated with loss of the short stature homeobox gene (*SHOX*) on the pseudoautosomal region of the short arms of the X chromosome (Xp22), where it encodes an osteogenic factor. Haploinsufficiency of *SHOX* is also the cause of other skeletal anomalies in Turner syndrome, such as cubitus valgus and short fourth metacarpals.

At puberty, most patients with Turner syndrome have primary amenorrhea and do not develop secondary sex characteristics. However, some patients with 45,X/46,XX mosaic karyotypes experience pubertal development and have secondary amenorrhea, and others may have normal menstrual cycles. Pelvic exploration usually reveals a normal but infantile uterus and fallopian tubes, with only rudimentary gonadal development. The gonads are usually represented by fibrous streaks in the broad ligament. However, as inferred by the diverse clinical presentations and the potential for mosaicism, the extent of ovarian defects is variable.

Patients with classic Turner syndrome rarely reach 5 feet in stature and are usually abnormally short at birth and throughout childhood. The upper-to-lower body

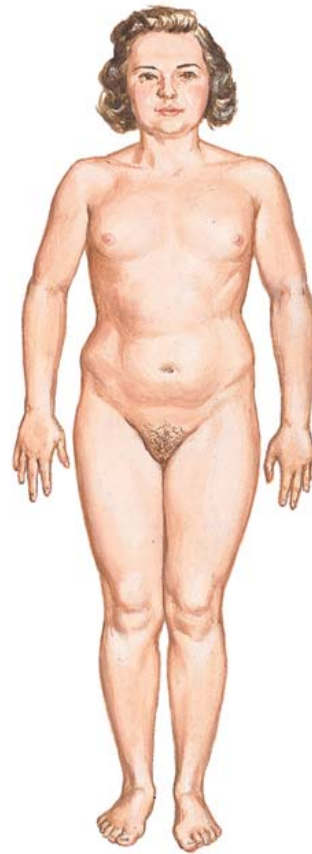
segment ratio is increased in most patients. Congenital lymphedema of the hands and feet in a phenotypic female neonate is an early sign of this genetic disorder. In addition to short stature, the characteristic physical appearance includes two or more of the following: a short, webbed neck; high, arched palate; broad, shieldlike chest; widely spaced, hypoplastic nipples; shortened fourth metacarpal bones; and cubitus valgus. Additional findings include micrognathia, "fishmouth" appearance, low-set or deformed ears, hypoplastic nails, and a

hairline in back that extends downward to the shoulders. Pigmented nevi, telangiectases, and abnormalities of the eyes (e.g., strabismus, amblyopia, ptosis) and ears (e.g., eustachian tube anomalies resulting in frequent otitis media) are common. Coarctation of the aorta and other congenital cardiac malformations (e.g., bicuspid aortic valve, elongation of the transverse aortic arch), hypertension, aortic dissection, renal abnormalities (e.g., horseshoe kidney, ureteropelvic junction anomalies), and a variety of other defects have been reported.

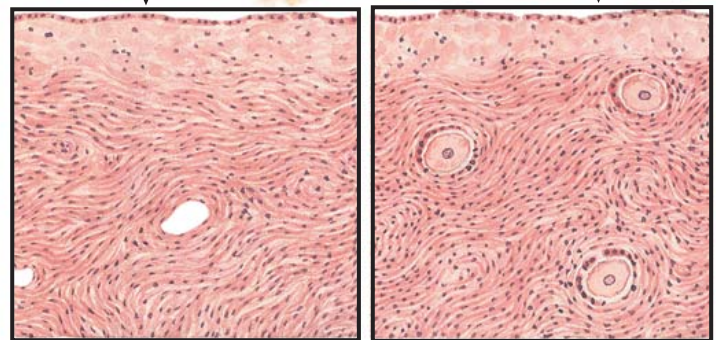
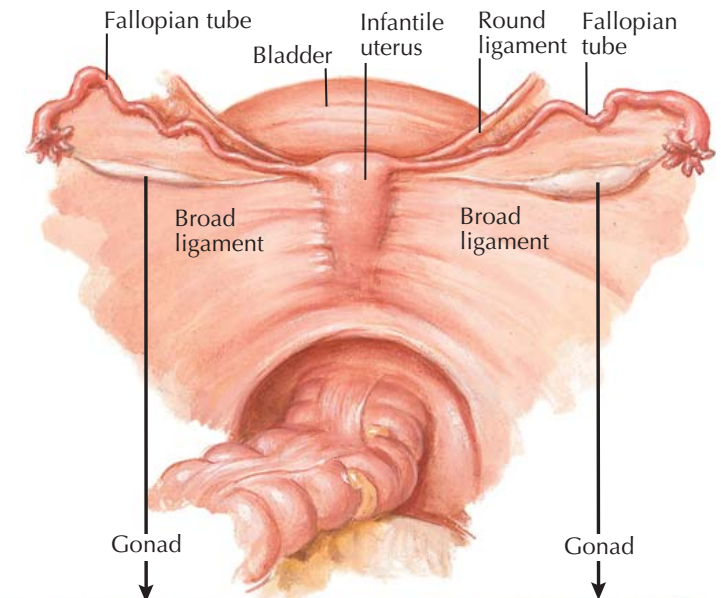
*F. Netter M.D.*



TURNER SYNDROME: 45,X/46,XX KARYOTYPE

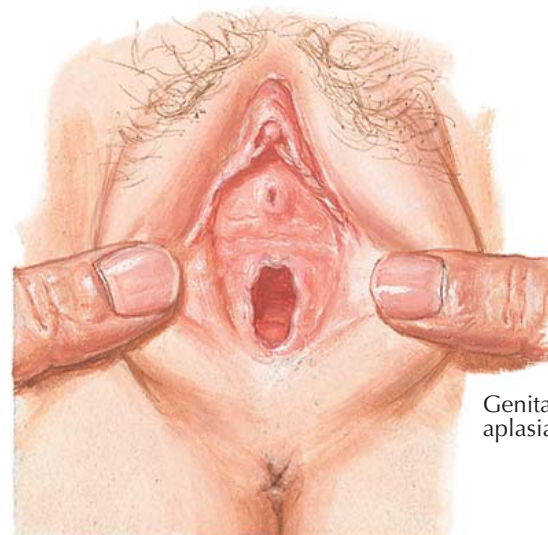


Stigmata of Turner syndrome may or may not be present

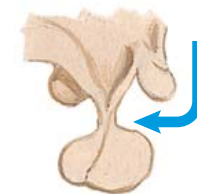


Wavy stroma with no germinal elements

Ovarian stroma with few primordial follicles



Genitalia relatively normal but infantile; aplasia or hypoplasia of labia minora common



Gonadal estrogen may be adequate to prevent high pituitary gonadotropin output

**TURNER SYNDROME (GONADAL DYSGENESIS) (Continued)**

Although intelligence is usually normal, forms of neurocognitive dysfunction (e.g., attention-deficit disorder, visual-spatial organization) may be evident. Neurocognitive dysfunction is more common in individuals whose sole X chromosome is an X<sup>m</sup> rather than X<sup>p</sup>. An example of abnormal social cognition in such patients is the difficulty in inferring affective intention from facial appearance. Head magnetic resonance imaging and positron emission tomography show decreased tissue volumes and glucose metabolism in the right parietal and occipital lobes, findings consistent with the visual-perceptual spatiotemporal processing abnormalities. Mental retardation is associated with the rare small ring X chromosome (karyotype 46,X,r[X]). Hypothyroidism (Hashimoto thyroiditis), sensorineural hearing loss, celiac disease, and liver function test abnormalities are common. The frequent bone fractures and osteoporosis in women with Turner syndrome appear to be multifactorial, with contributions from estrogen deficiency and haploinsufficiency for bone-related genes on the X chromosome. Finally, patients with Turner syndrome frequently develop keloids at sites of surgical incisions.

In patients with 45,X/46,XX mosaicism, the gonad may differentiate beyond its primitive state, and the cortex may differentiate to the extent of forming primordial follicles that are normal in appearance but are diminished in number. Girls with primordial follicles eventually may experience some breast enlargement and scanty menstrual periods. However, these estrogenic manifestations usually develop late, and at the usual age of adolescence, the classic picture is that of sexual infantilism. Such girls may or may not exhibit characteristic stigmata of Turner syndrome, and often they are tall and eunuchoid rather than short. In the least severely affected individuals, only infertility and subnormal development of the estrogen-dependent sex characteristics may be present. Pregnancy is possible in a few of these patients.

If virilization occurs, it is likely caused by mixed gonadal dysgenesis because of Y-chromosome mosaicism (45,X/46,XY) (see Plate 4-14). Other karyotypes (e.g., 45,X/47,XXY; 45,X/46XY/47,XXY) in this setting are observed much less frequently. These individuals may have typical gonadal dysgenesis, clitoral enlargement, ambiguous genitalia, hypospadiac phallus, or a normal-appearing penis (see Plate 4-20). The testicular

differentiation in these patients ranges from streak gonads to functioning testes. Gender assignment may be difficult and is usually dictated by the appearance of the external genitalia. If Y-chromosome mosaicism is confirmed, prophylactic gonadectomy is indicated. Malignant germ cell tumors (e.g., dysgerminomas) may arise from the gonadoblastoma or dysgenic gonads.

If the medullary component of the primitive gonad develops beyond its rudimentary stage in patients

with 45,X/46,XY mosaicism, the secretion of duct-organizing substances and androgen is expected to parallel the morphologic development of the testis. If the testis remains rudimentary, the genital ducts and external genitalia likewise are ambiguous or hermaphroditic in appearance. Because the duct-organizing substance secreted from a testis exerts its action unilaterally, asymmetric duct development is expected to occur if the two testes do not mature equally.

*F. Netter M.D.*



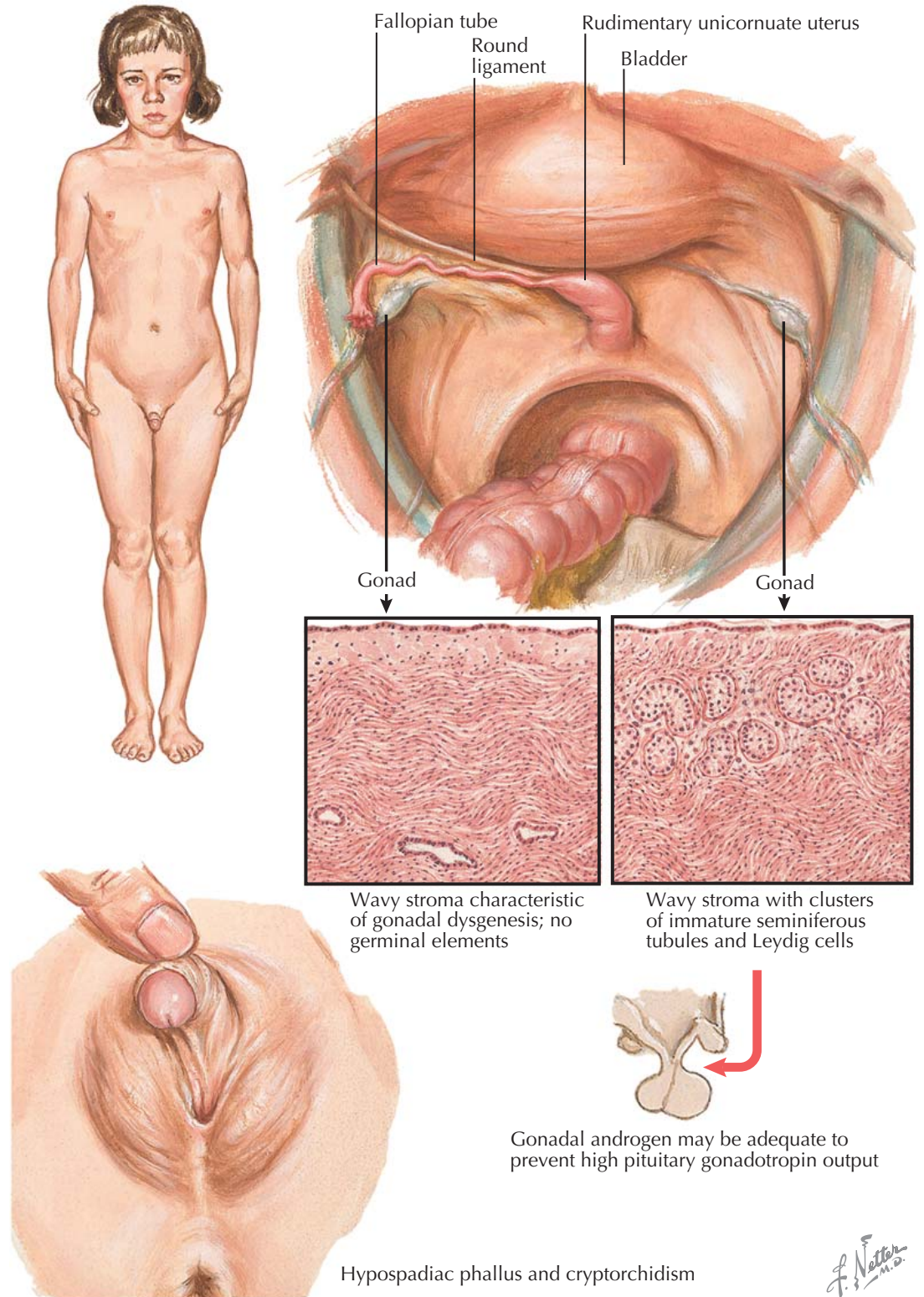
TURNER SYNDROME AND MIXED GONADAL DYSGENESIS: 45,X/46,XY KARYOTYPE

**TURNER SYNDROME (GONADAL DYSGENESIS)** *(Continued)*

In the most primitive of such rudimentary testes, only rete tubules and nests of Leydig cells can be identified. In other instances, solid cords of cells resembling the primary sex cords are enmeshed within an abundant mesenchymal matrix. The spectra of testicular development in these cases find their counterparts in all the stages through which a normal testis passes in its embryonic differentiation. The hormonal pattern that emerges at adolescence is frequently a recapitulation of the performance of the Leydig cells in utero. Thus, if these cells were sufficiently abundant to produce virilization of the external genitalia in utero, at adolescence they may be expected to produce androgenic hormones and bring about male secondary sex characteristics. Likewise, gonads in which the cortical elements have differentiated beyond the primitive stage may be expected to bring about some degree of feminization at adolescence.

The time in life when Turner syndrome becomes clinically evident is variable. For example, Turner syndrome may be evident at birth with the typical physical anomalies and lymphedema of the extremities and cutis laxa. It may be diagnosed in childhood because of growth failure, in adolescence with pubertal failure and primary amenorrhea, or later in life with secondary amenorrhea. Turner syndrome should be suspected in all prepubertal girls who are of short stature (<2 standard deviations below the mean height for age) and have at least two of the physical stigmata. In the past, a buccal smear for assessment of Barr bodies (nuclear heterochromatin) was performed in this setting. However, because this technique lacks sensitivity and specificity, it is no longer performed. If Turner syndrome is suspected, a peripheral blood karyotype analysis is indicated. A 46,X karyotype is documented in approximately 75% of patients with Turner syndrome, and the remainder proves to have mosaic forms (e.g., 45,X/46,XX). Blood concentrations of luteinizing hormone and follicle-stimulating hormone are increased above normal in most of these patients throughout all age groups.

Treatment depends in part on the age at diagnosis and the presence of congenital anomalies. Although the short stature is not caused by growth hormone



deficiency, the administration of recombinant human growth hormone in childhood—typically initiated when height falls below the fifth percentile for age—enhances growth and final adult height (the typical height gain is between 2 and 6 inches). The reasons for estrogen replacement therapy include inducing sexual development, optimizing adolescent bone development, and optimizing cognitive function. Typically,

low-dose estrogen replacement is started around age 13 to 14 years. A progestin is given with the estrogenic agent to prevent endometrial hyperplasia. Treatment of the adult patient with Turner syndrome includes surveillance for potential cardiovascular anomalies with periodic echocardiography. Because of the high risk for hypothyroidism, annual measurement of serum thyrotropin concentration is indicated.



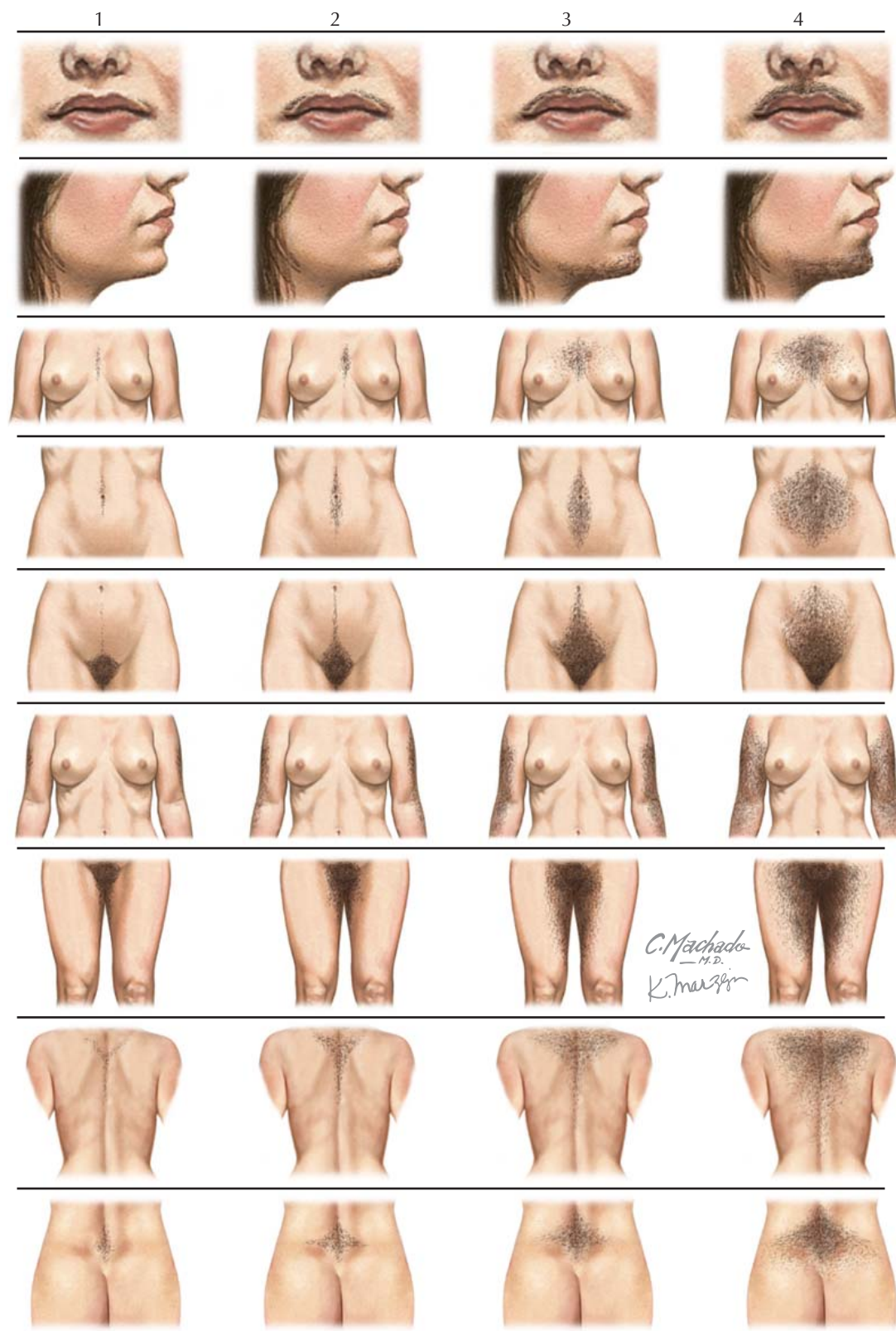
## HIRSUTISM AND VIRILIZATION

Hirsutism is defined as excessive male-pattern hair growth in women. The causes of hirsutism are many and diverse—from an ethnic or hereditary disposition toward superfluous hair growth to hyperplasia or neoplasia of the adrenal gland or ovaries. Virilization, reflecting a more severe form of androgen excess, is defined as the development of signs and symptoms of masculinization in a woman (increased muscle bulk, loss of female body contours, deepening of the voice, breast atrophy, clitoromegaly, temporal balding) (see Plate 3-16). Hypertrichosis is not true hirsutism but rather a diffuse increase in total body hair in women or men that may be drug induced (e.g., minoxidil) or associated with other conditions (e.g., anorexia nervosa, malnutrition).

Hair growth has three phases: growth phase (anagen), involution phase (catagen), and rest phase (telogen). Although hair follicle number does not change over time, the size and shape of the hair follicles can change. Hair is either vellus (not pigmented, fine, soft) or terminal (pigmented, thick, coarse). Vellus hair is present on most of the skin. Androgens, in addition to increasing hair follicle size and hair diameter, increase the proportion of time that terminal hairs remain in growth phase at androgen-sensitive body sites. Thus, hirsutism is the development of terminal hair in areas where it does not usually occur in women (e.g., face, midline chest, abdomen, and back). At the scalp, androgens reduce the time that hair is in the growth phase and can result in hair thinning.

The degree of male-pattern terminal hair growth in a woman can be assessed with a modified scale originally developed by Ferriman and Gallwey (see Plate 4-21). The degree of terminal hair growth is graded at nine body areas: upper lip, chin, upper back, lower back, upper abdomen, lower abdomen, upper arms, and thighs. Each area is scored 0 to 4 (0 = no growth of terminal hair and 4 = complete and heavy cover). The sum of these numbers is the modified Ferriman Gallwey hirsutism score. Most women have a modified Ferriman Gallwey hirsutism score of less than 8 (maximum score, 36), but 5% to 10% of women have scores above 8, a level consistent with the diagnosis of hirsutism. Ethnicity has a major influence on body hair in women. For example, despite equivalent circulating androgen levels, most American Indian and Asian women have little body hair, and women of Mediterranean descent have much more.

Hirsutism is usually caused by increased androgen effect, associated with either increased circulating androgen levels or increased local conversion of testosterone to the more potent dihydrotestosterone (DHT) at the hair follicle. The conversion of testosterone to DHT is catalyzed by 5 $\alpha$ -reductase and amplifies the androgenic effect. DHT is produced primarily by target tissues. Thus, androgen action is determined in part by the target tissue androgen receptors and 5 $\alpha$ -reductase activity. The adrenal glands produce dehydroepiandrosterone (DHEA) and androstenedione. DHEA has no direct androgenic effects but rather serves as a substrate for conversion to androstenedione (which is also androgenically inactive) and then to testosterone. In the ovary, much of the testosterone is aromatized to estradiol. Blood testosterone concentrations in



premenopausal women are determined by direct ovarian secretion (one-third of total) and by the peripheral conversion of androstenedione to testosterone in adipose tissue and skin (two-thirds of total). Increased blood testosterone concentrations usually originate from the ovaries, and increased DHEA sulfate (DHEA-S) concentrations usually originate from the adrenal glands. Excess androstenedione secretion can come from either the adrenal glands or the ovaries.

Polycystic ovary syndrome (PCOS) is the most common cause of clinically evident androgen excess. Hirsutism is often concomitant with obesity, amenorrhea, and infertility. These women typically have anovulatory, irregular menstrual cycles; signs of excess androgen effect (e.g., hirsutism, acne); or increased blood concentrations of androgens. PCOS usually becomes evident shortly after the onset of puberty, and the signs and symptoms gradually progress with age.

## HIRSUTISM AND VIRILIZATION

(Continued)

Hyperthecosis, a severe variant of PCOS, is caused by increased ovarian stromal tissue with luteinized theca cells distributed among sheets of fibroblast-like cells. There is a positive correlation between the degree of hyperthecosis and insulin resistance. The hyperinsulinism appears to stimulate proliferation of thecal interstitial cells. Virilization occurs in some patients with hyperthecosis because of the markedly increased serum testosterone levels.

Idiopathic hirsutism is the second most common diagnosis in women with hirsutism. It is associated with normal menstrual cycles and normal blood androgen concentrations, and no other cause of hirsutism can be identified on evaluation. It may be that these patients have increased cutaneous 5 $\alpha$ -reductase activity.

Congenital causes of virilization of female neonates include congenital adrenal hyperplasia (CAH), which is characterized by an enzymatic defect in cortisol metabolism (see Plates 3-13 and 3-14). In this setting, corticotropin (adrenocorticotropic hormone [ACTH]) from the pituitary gland is not inhibited by the normal feedback mechanism, and in an effort to produce cortisol, the adrenal glands continue to produce DHEA and other androgenic precursors. As a result, clitoral hypertrophy and hirsutism may be apparent in the newborn. Similar to exogenous androgenic hormones in pill or injected forms taken in early pregnancy, an excess of androgenic steroids from a secretory ovarian or adrenal tumor in the pregnant mother may cause the same fetal changes because these steroids can cross the placental barrier into the fetal circulation. Patients with late-onset or nonclassic CAH (usually caused by partial 21-hydroxylase deficiency) may not present until after puberty with hirsutism and oligomenorrhea (see Plate 3-16). Thus, the clinical presentation of late-onset CAH is very similar to that of PCOS. CAH is more common in persons of Ashkenazi Jewish, central European, and Hispanic descent.

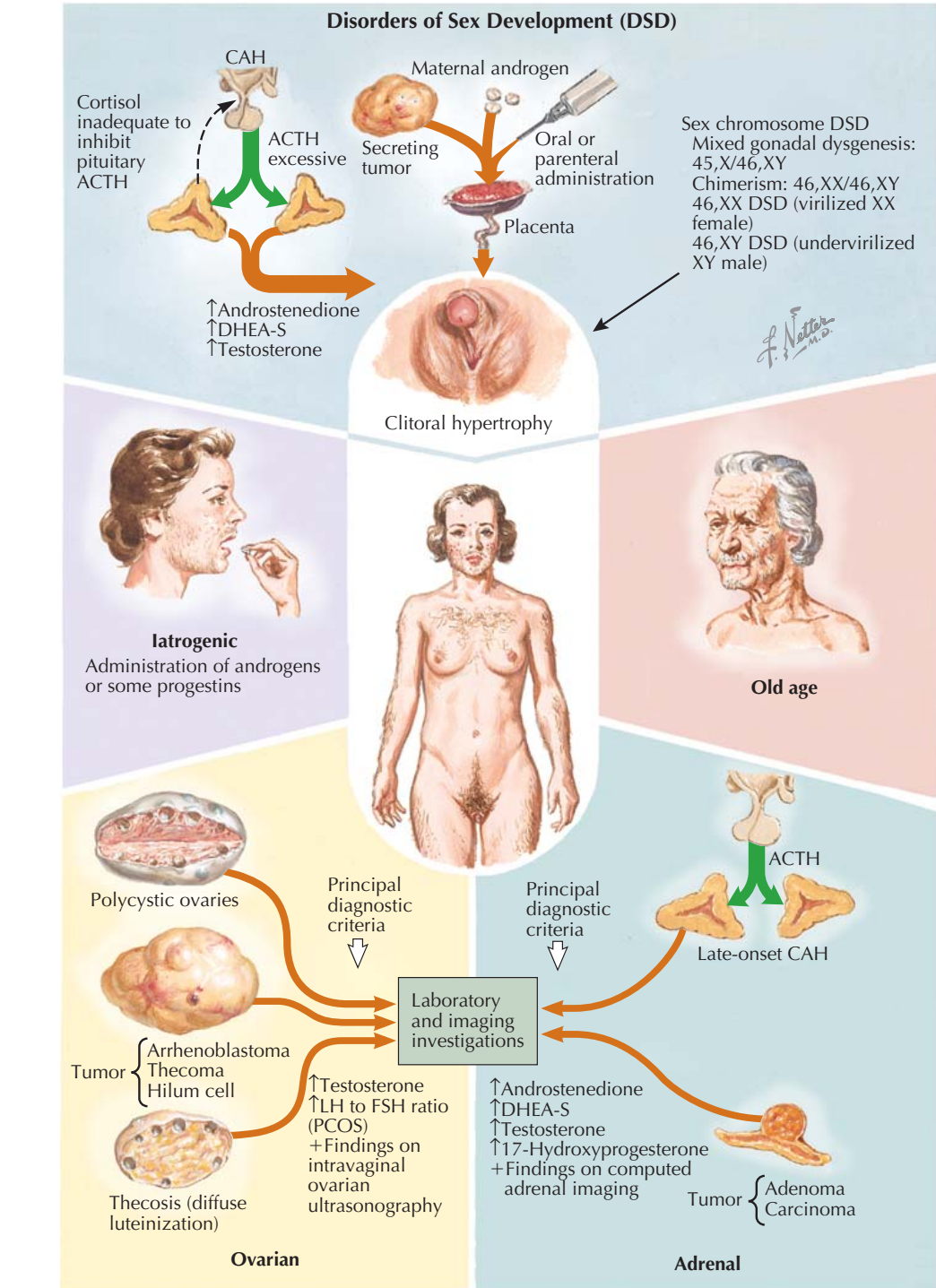
Androgen-secreting Sertoli-Leydig cell tumors (arrhenoblastoma), granulosa-theca cell tumors, and hilum-cell tumors are associated with rapidly progressive signs and symptoms of androgen excess and markedly increased serum testosterone concentrations. In patients who present with signs and symptoms of androgen excess, Sertoli-Leydig cell tumors are usually large, but hilum-cell ovarian tumors are small and may escape detection with imaging studies. Adrenal androgen-secreting tumors—much less common than androgen-secreting neoplasms that arise from the ovary—are usually adrenocortical carcinomas producing excess DHEA. Rarely, benign adrenal cortical adenomas or adrenocortical carcinomas hypersecrete testosterone.

In old age, facial hair is considered to be the result of adrenal androgens that are not balanced by any of the estrogenic hormones after ovarian failure at menopause.

Hirsutism and virilization can result from androgenic medications (e.g., anabolic steroids). Rare causes of hirsutism include Cushing syndrome and glucocorticoid resistance syndrome.

### EVALUATION OF WOMEN WITH HIRSUTISM

In the circulation, testosterone exists in three forms: tightly bound to sex hormone-binding globulin (SHBG), loosely bound to albumin, or unbound (free). The biologically active testosterone fraction includes

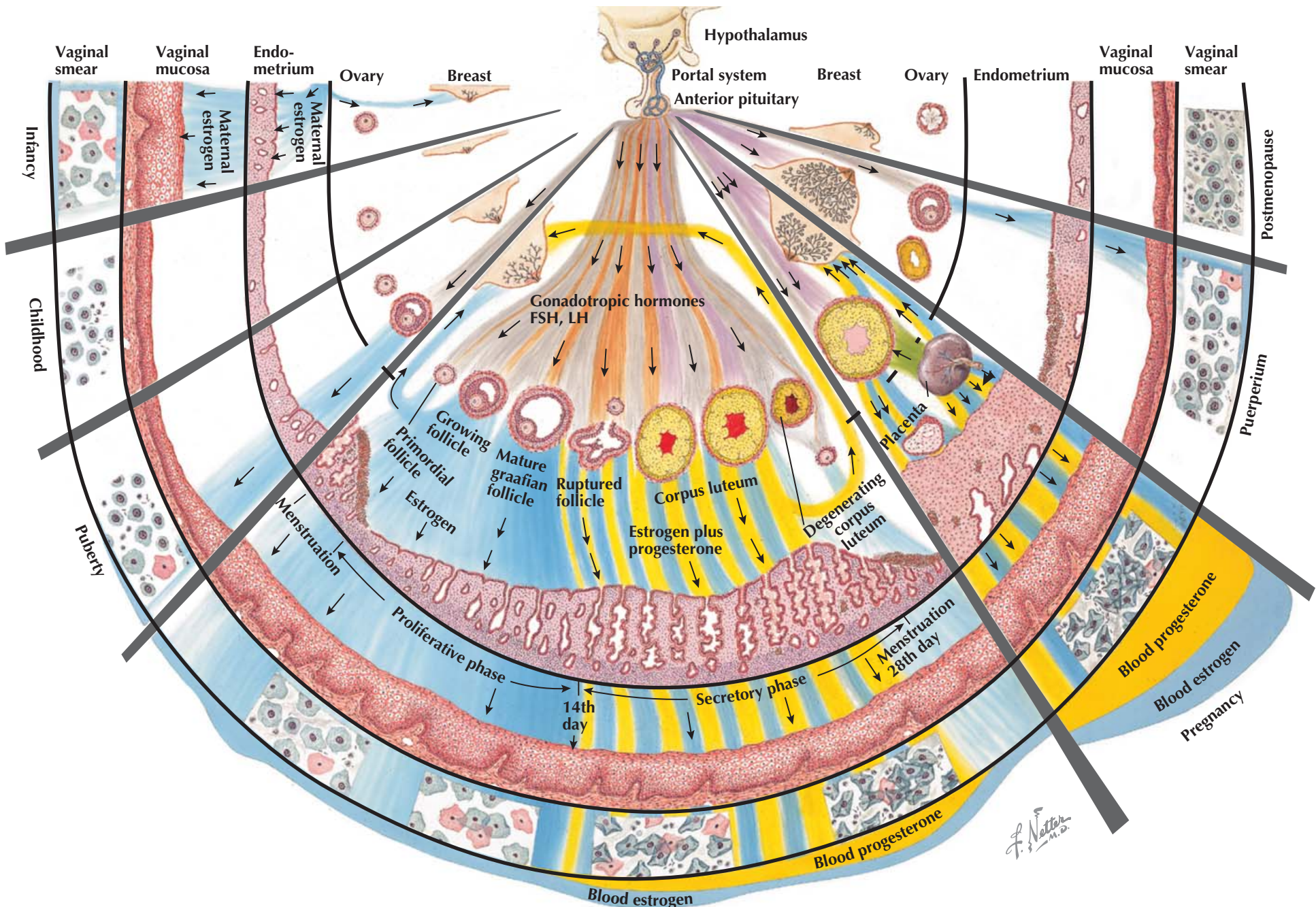


the loosely bound and free fractions and is termed the *bioavailable fraction*. Some disorders (e.g., obesity, hypothyroidism, liver disease) decrease SHBG binding and increase bioavailable testosterone levels. Thus, the measurement of bioavailable testosterone concentrations in the blood provides a more accurate assessment of the testosterone effect than the measurement of total testosterone.

When serum testosterone levels are increased in a woman with hirsutism, the five most likely causes are PCOS, nonclassic CAH, hyperthecosis, hypothyroidism, or an androgen-secreting ovarian or adrenal tumor. An androgen-secreting neoplasm should be suspected when serum testosterone concentrations are more than threefold increased above the upper limit of

the reference range. Tests that may be needed to differentiate among these diagnostic possibilities include serum DHEA-S and androstenedione concentrations (increased in most patients with androgen-secreting adrenal tumors and in some patients with CAH), serum thyrotropin concentration (to exclude hypothyroidism), serum 8 AM 17-hydroxyprogesterone concentration at baseline and after cosyntropin administration (abnormal in most patients with CAH), serum concentrations of luteinizing hormone (LH) and follicle-stimulating hormone (FSH) (an increased ratio of LH to FSH is consistent with PCOS), 24-hour urinary-free cortisol excretion (to exclude Cushing syndrome), and imaging with transvaginal ultrasonography (ovary) or computed tomography (adrenal) to assess for neoplasia.





- Pituitary hormones**
- FSH
  - LH
  - Prolactin

- Ovarian and choriionic hormones**
- Estrogen
  - Progesterone
  - Chorionic gonadotropin

## INFLUENCE OF GONADAL HORMONES ON THE FEMALE REPRODUCTIVE CYCLE FROM BIRTH TO OLD AGE

From birth to old age, all female mammals exhibit a succession of biologic events characterized by the phases of infancy, childhood, puberty (sexual maturation), adult reproductive years, and, finally, postmenopause and senility. The physiologic indices that differentiate one phase from another are induced primarily by the secretion of ovarian estrogens.

Although ovulation may be considered the chief function of the ovaries, their production of estrogens and progestogens is no less essential to maintain and nourish all parts of the procreative apparatus and to also contribute to the function and maintenance of skin; hair growth; and the skeletal, vascular, and electrolyte systems. Finally, the effects of these hormones in achieving emotional stability during adolescence have their counterpart in psychologic changes associated with estrogen deficiency after menopause and after oophorectomy.

In neonates, the placenta does not block exposure to the high concentration of maternal estrogens before parturition. A female infant's breasts may show some enlargement, and "witch's milk" can occasionally be expressed from the nipples. The external genitalia are precociously developed, and the endometrium has been stimulated to proliferate. The vaginal mucosa is a many-celled layer of stratified epithelium. Vaginal smears show the large, flat, polygonal cells characterized as estrogen stimulated by their small pyknotic nuclei and extensive cornification.

Within 1 week or so after birth, all the above stigmata of estrogen stimulation recede. The newborn ovaries are small structures made up entirely of primordial follicles, disclosing no elements capable of producing estrogens.

In the decade of childhood, from the postnatal recession changes to the time of puberty, the ovaries gradually show a buildup of interstitial tissue from an accumulation of fibrous stroma, as a constant succession of primordial follicles degenerate in atresia. The vaginal smear shows predominantly basal and parabasal cells mixed with bacteria and amorphous debris. The breasts remain infantile.

In the initiation of puberty, the uterus is first to respond to estrogenic hormones. The endometrium proliferates with the development of straight, tubular glands. Next, the vagina thickens and becomes stratified, with cornified superficial estrogenic cells appearing in the vaginal smear. In the ovary, primordial follicles progress beyond the stage of a one- or

two-layer granulosa with a tiny antrum and exhibit identifiable several cell thickness granulosa and theca interna layers. In the breast, the areolae show pigmentation along with a domelike change, becoming elevated as a conical protuberance (see Plate 4-5). Fat is deposited about the shoulder girdle, hips, and buttocks, and the patterns of adult pelvic and, later, axillary hair typical of the female begin to develop.

An intricate balance of stimulation and response between pituitary gonadotropins and ovarian steroids is essential for the proper sequence of events that result in normal ovulatory cycles. In adolescence, as well as at menopause, minor disturbances are responsible for irregular, anovulatory uterine bleeding.

In the mature cycle, the upper two-thirds of the endometrium are sloughed away in the first 48 to 72 hours of menstruation; the bleeding surface is rapidly repaired in the following 2 or 3 days from a spreading proliferation of epithelium from broken glands and arterioles under the stimulus of estrogen secreted by numbers of ovarian follicles in response to follicle-stimulating hormone (FSH) from the anterior pituitary. By day 12 in a typical 28-day cycle, one follicle attains ascendancy and exhibits a rapid growth toward maturity, associated with thickening of the proliferative endometrium and increased desquamation of precornified and cornified cells from the vagina. The release of luteinizing hormone (LH) at midcycle on day 14 is responsible for ovulation of the mature follicle and for initiation of progesterone secretion from the rapidly forming corpus luteum. Endometrial glands become sawtoothed and secretory; the vaginal smear shows a regression toward intermediate cell types that are clumped together, with folded and wrinkled cytoplasm. If fertilization and implantation do not occur, the corpus luteum degenerates on about day 26, and, consequently, with the rapid withdrawal of its estrogen and progesterone secretion, the endometrium shrinks, becomes ischemic, and breaks away with bleeding on day 28.

Through the changes described above, the juvenile breast has become mature, with branching and extension of both ducts (estrogens) and alveoli (progesterone). Toward the latter half of the cycle, there is often congestion of the lobules, with an increased sensitivity of the areolae and nipples.

Both estrogen and, to a lesser extent, progesterone are associated not only with the transient accumulation of edema fluid in the endometrium (most marked in the secretory phase) but, at times, also with a diffuse premenstrual edema in peripheral tissues, clinically recognized by subjective descriptions of bloating, increased girth, and weight gain.

In the decade of adolescence, the skeletal system reacts to estrogen, first, by an accelerated growth rate of the long bones, and, second, by a hastening of epiphyseal closure, the balance affecting final height.

When conception occurs, the early secretion of chorionic gonadotropin from the chorionic elements of a securely implanted embryo maintains the corpus luteum, preventing it from degenerating in 2 weeks. In pregnancy, the peak production of chorionic hormone is seen by about day 90 after the last menstrual period, declining thereafter to a plateau. The corpus luteum is responsible for increasing progesterone and estrogens throughout the first 3 months, after which the placenta takes over until the end of the pregnancy. The augmentation of both estrogen and progesterone is approximately linear throughout the 9 months of gestation, accounting for the cessation of any demonstrable ovarian activity through the suppression of pituitary FSH and LH secretion. The breasts react to the increasing steroid stimulation and pituitary prolactin secretion with an extension of both ductile and alveolar growth, and there is congestion without actual lactation. The vaginal smear shows the marked effect of the increased progesterone level, with massive clumping of the cells and the appearance of a particular form from the intermediate layer, called the navicular cell of pregnancy.

The puerperium is an inconstant phase of endocrine readjustment. The massive withdrawal of estrogen after placental delivery and the psychoneural mechanisms initiated by the suckling reflex bring about the release of oxytocin and prolactin. Breast tissues, already conditioned by growth, respond with milk production and letdown. Ovarian activity is held in abeyance during lactation and nursing, for several months in many cases and even for 1 year or more. However, reestablishment of the pituitary-ovarian cycle can, and often does, take place before weaning, so that another conception can occur before the advent of a menstrual flow. The raw and bleeding endometrial bed of the placental attachment takes from days to weeks to reepithelialize. The vaginal mucosa is thin, and the smear is relatively atrophic until ovarian estrogen is again produced.

Menopause—defined as the cessation of menstrual periods—normally occurs at a mean age of 51.4 years. Premature ovarian failure is defined as primary hypogonadism in a woman younger than 40 years. The ovaries no longer contain any follicles capable of responding to pituitary gonadotropins. Increasing amounts of FSH are secreted because of the lack of negative feedback from inhibin and ovarian estrogen secretion. This estrogen deficiency is reflected by senile changes in the breasts, uterus, vagina, skin, bony skeleton, and vascular system.

Childhood and senility represent phases of tranquility in gonadal activity. Proper hormonal interactions through the menstrual cycle, pregnancy, and puerperium are determined fundamentally by appropriate modulations of estrogenic secretions.

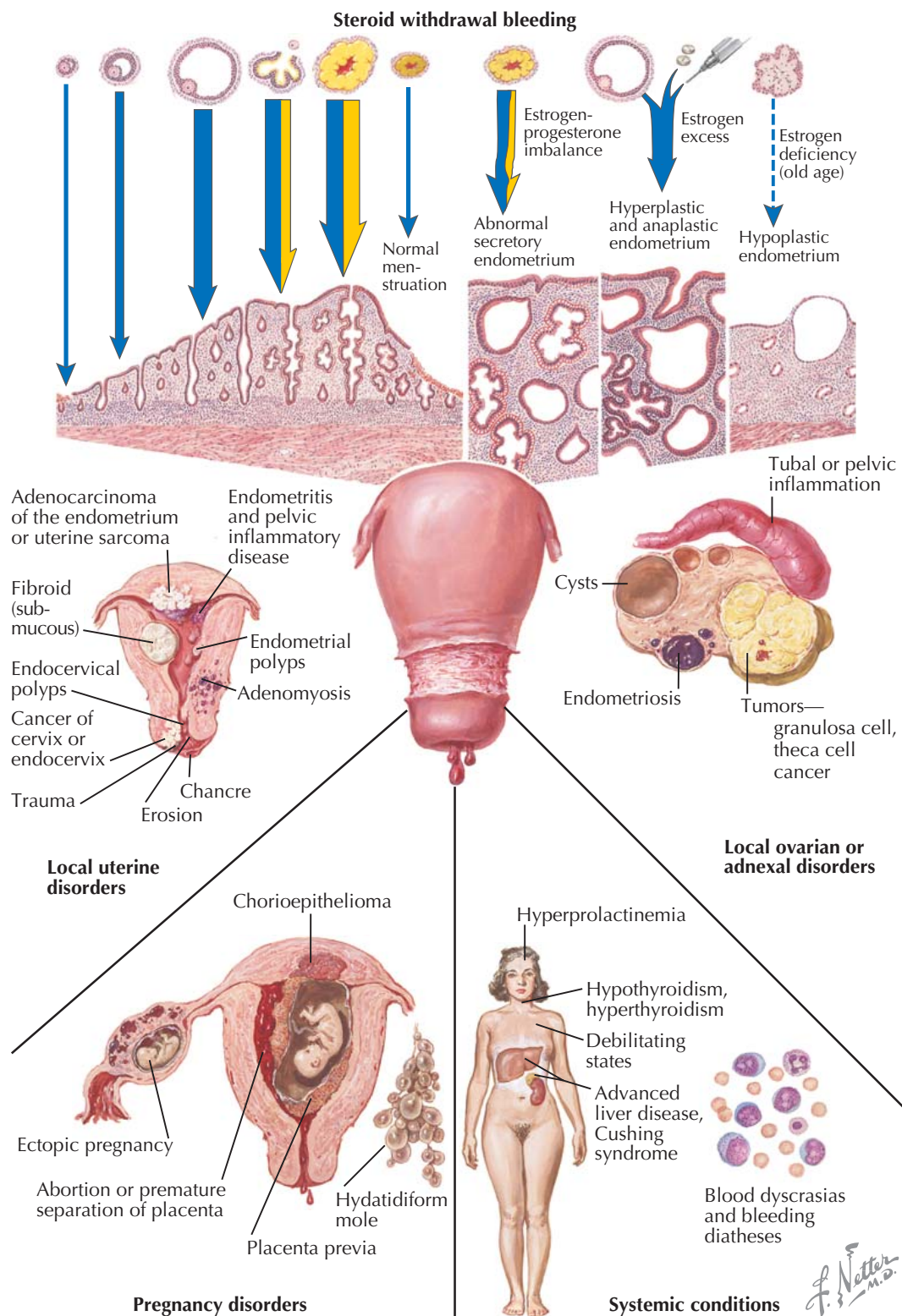


## FUNCTIONAL AND PATHOLOGIC CAUSES OF UTERINE BLEEDING

The uterine mucosa is the only tissue in the body in which the regular, periodic occurrence of necrosis and desquamation with bleeding is usually a sign of health rather than of disease. This periodic blood loss is controlled through a delicate balance of pituitary and ovarian hormones and results from the specific response of the target tissue, the endometrium. The normal ebb and flow of estrogen and progesterone, through a monthly cycle, first builds up and then takes away, in regular sequence, the support of the endometrium; therefore, a menstrual flow characterized by repeated regularity in timing, amount, and duration of bleeding bears witness to a normal and ordered chain of endocrine events for that individual. Irregularity in any of these characteristics suggests a functional disturbance or an organic pathology. The main categories of pathologic states that can cause or be accompanied by either menorrhagia (heavy or prolonged flow) or metrorrhagia (spotting or bleeding between menstrual flows) are discussed below.

The concept of bleeding caused by a decrease or withdrawal of ovarian steroids explains the unpredictable flow associated with persistent estrogen phases and anovulatory cycles. Anovulatory uterine bleeding is noncyclical and variable in duration and flow. Common causes of anovulation include adolescent age, perimenopausal state, polycystic ovary syndrome, weight loss, strenuous exercise, thyroid dysfunction, and advanced liver or renal disease. In the normal cycle, a progressive increase in estrogen production, with a sharp rise from the maturing follicle toward the 14th day, causes parallel development of all elements in the endometrium—the stroma, glands, and coiled superficial arteries. At or soon after ovulation, the advent of progesterone from the corpus luteum slows growth and proliferation and modifies the tissue into a secretory pattern. If conception and pregnancy do not occur, the corpus luteum regresses in 14 days. Its production of both estrogen and progesterone wanes, and the following are observed: shrinkage of the endometrium, congestion of the nutrient arteries, anoxemia, necrosis, and desquamation. Duration of flow is typically 2 to 7 days with a volume less than 80 mL. Occasionally, irregular shedding from an imbalance of the estrogen-to-progesterone ratio, producing a mixed endometrium with both proliferative and secretory glands in an abnormal luteal phase pattern, may cause menorrhagia. Persistent estrogen production from a series of follicles that fail to ovulate tends to build up a hyperplastic endometrium in which nests of anaplastic glands may develop. The circulating level of estrogen fluctuates in accordance with haphazard spurts of follicle growth. Sporadic reduction in circulating estrogen, spontaneously or because of medication, undermines the vascular support of the uterine mucosa and initiates the changes inevitably followed by necrosis and bleeding. In old age, the hypoplastic, estrogen-deficient endometrium sometimes breaks down and bleeds from a vulnerability to mild trauma or infection.

In addition to the uterus, abnormal bleeding in the genital area may arise from the ovaries, fallopian tubes, cervix, vagina, vulva, urethra, urinary bladder, or bowel. Local ovarian or adnexal disorders may involve primary malignancies, including cystic or solid ovarian tumors that secrete steroids. Cervical lesions are usually not responsible for heavy bleeding but rather are sporadic and caused by postcoital spotting.



Local uterine disorders causing abnormal bleeding include uterine polyps, uterine leiomyomas (fibroids), adenomyosis (ectopic endometrial tissue in the uterine musculature), hysterotomy scar, adenocarcinoma of the endometrium, uterine sarcoma, metastatic disease to the endometrium, uterine arteriovenous malformation, cancer of the cervix or endocervix, trauma, or endometritis and pelvic inflammatory disease.

Pregnancy-related disorders caused not only by placenta previa, premature placental separation, abortion, or deficiencies as illustrated under systemic conditions but also by ectopic gestation or gestational

trophoblastic disease constitute frequent causes of uterine hemorrhage.

A variety of systemic conditions may be responsible for abnormal bleeding. Conditions such as bleeding diatheses (e.g., von Willebrand disease, clotting factor deficiencies, and platelet abnormalities), acute leukemia, advanced liver disease, or anticoagulant therapy usually show signs of bleeding elsewhere. Chronic disease states such as hypothyroidism, hyperthyroidism, hyperprolactinemia, and Cushing syndrome can produce abnormal flow as well as undermine placental function.

## GYNECOMASTIA

Enlargement of the male breast, caused by an increase in its glandular component, is known as gynecomastia. The degree of enlargement is variable, ranging from a barely visible, small, central, subareolar disk of mammary tissue to the proportions of a normal female adolescent breast. It may be unilateral or bilateral and is often painful and tender. Its presence is sometimes difficult to ascertain in obese men because their breast enlargement may be caused entirely, or in large part, by fat deposition (pseudogynecomastia). The first step in the evaluation of apparent gynecomastia is to differentiate true gynecomastia (glandular tissue) from pseudogynecomastia (adipose tissue) and breast cancer.

The histopathology is characterized by stimulation of ducts and proliferation of stroma. The ducts undergo lengthening and branching, with budding and formation of new ducts but no alveoli. Epithelial hyperplasia occurs. Simultaneously, there is an increase in the bulk of the stromal tissue, which is often hyalinized. These changes are caused by a decreased ratio of androgen to estrogen activity. The cause is physiologic (e.g., pubertal gynecomastia) or pathologic (e.g., hypogonadism, medication related, cirrhosis, malnutrition).

### PHYSIOLOGIC STATES

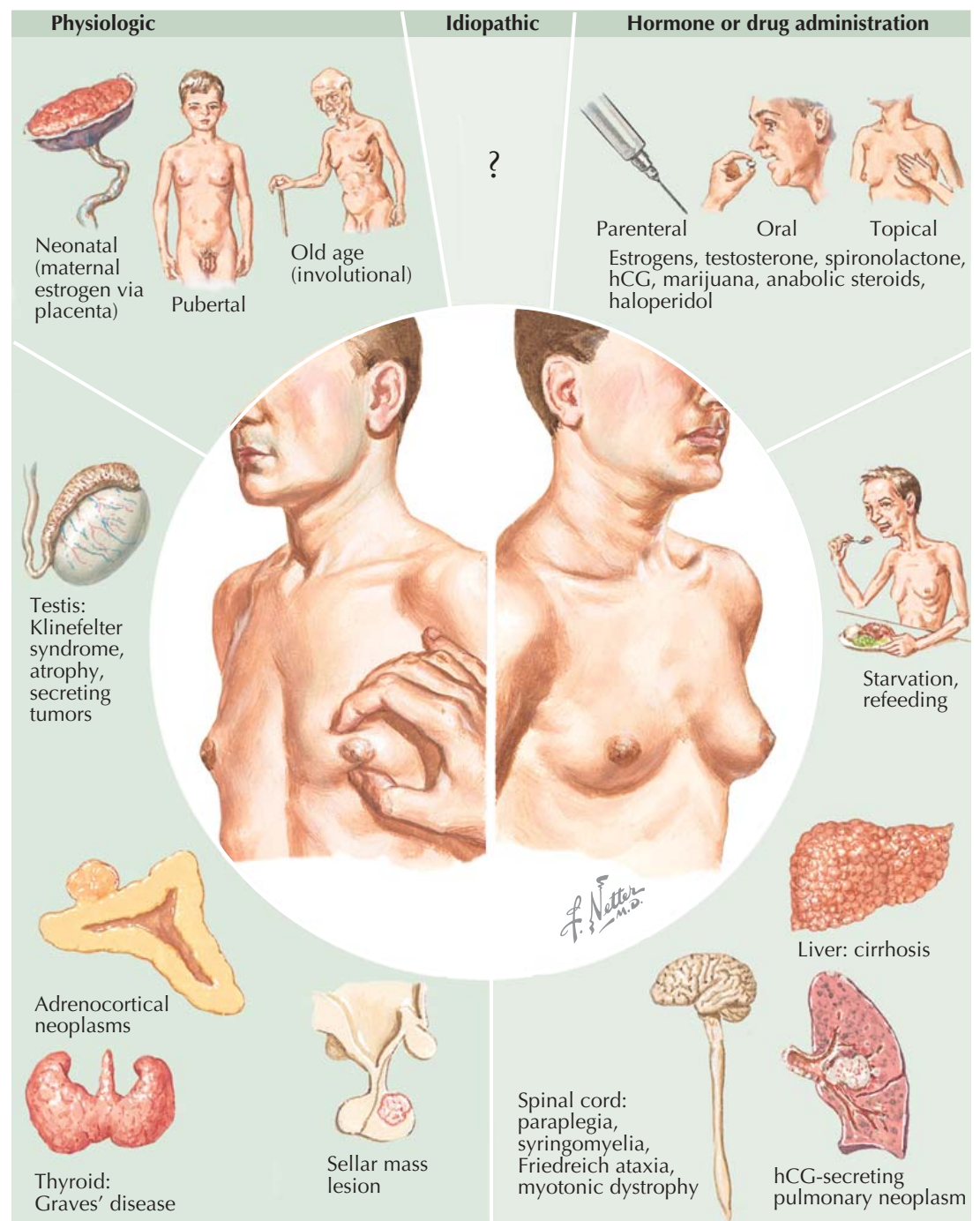
Neonatally, slight transitory breast enlargement is common in both sexes—this is presumably caused by high levels of maternal estrogen. Pubertal gynecomastia, often slight, bilateral, and painful, occurs in about 50% of boys during puberty and is the single most common cause of gynecomastia. The cause appears to be enhanced aromatization of androgens to estrogens; blood estrogen concentrations reach the range expected for healthy men before testosterone reaches adult levels. Pubertal gynecomastia subsides spontaneously within 1 to 2 years in more than 90% of affected adolescent boys. When it persists into adulthood, it is termed *persistent pubertal gynecomastia*. Involutional breast enlargement occurs in some men later in life, presumably caused by the gradual decline in testosterone production with age.

### PATHOLOGIC CONDITIONS

Medications are a common cause of gynecomastia. Less common causes include hypogonadism (primary or secondary), cirrhosis, malnutrition, testicular tumors, and hyperthyroidism. Often a cause for gynecomastia is not found, and it is termed *idiopathic gynecomastia*.

Medications that may cause gynecomastia include antiandrogens (e.g., flutamide, spironolactone), antibiotics (e.g., isoniazid, ketoconazole), oncologic agents (e.g., alkylating agents, imatinib), antiulcer drugs (e.g., cimetidine), cardiovascular agents (e.g., digoxin, methyl dopa), illicit drugs (e.g., marijuana, heroin), hormonal drugs (e.g., estrogens, androgens, anabolic steroids, human chorionic gonadotropin [hCG]), and psychoactive agents (e.g., haloperidol, phenothiazines). Some of these agents have multiple mechanisms of action. For example, spironolactone blocks the effect of testosterone at the testosterone receptor, enhances the aromatization of testosterone to estradiol, decreases testicular testosterone secretion, and increases the clearance of testosterone.

Hypogonadism, whether primary (testicular failure) or secondary (pituitary failure), is a common cause of gynecomastia. Primary hypogonadism may be



caused by a genetic abnormality (e.g., Klinefelter syndrome; see Plate 4-17) or by some other process that affects testicular function (e.g., infection, trauma). Secondary hypogonadism is most commonly caused by illness or a nonfunctioning pituitary macroadenoma that destroys or inhibits the function of the pituitary gonadotrophs. Prolactin-secreting pituitary tumors cause gynecomastia by prolactin-induced decreases in luteinizing hormone (LH) and follicle-stimulating hormone (FSH). Prolactin does not directly cause gynecomastia.

Persons with cirrhosis have increased adrenal androgen production and enhanced aromatization to estrogens. In addition, many patients with cirrhosis are treated with spironolactone.

With severe illness and starvation, secondary hypogonadism develops, but adrenal estrogen production is unaffected. Thus, the ratio between androgens and estrogens declines in these settings and predisposes to

gynecomastia. With improved nutrition, the secondary hypogonadism recovers and recreates the pubertal-like state with enhanced gynecomastia.

Germ cell tumors of the testis hypersecrete hCG, which increases testicular testosterone production but also enhances Leydig cell aromatase activity. hCG may also be hypersecreted by neoplasms in the lung, stomach, kidney, and liver.

More than 25% of men with hyperthyroidism have gynecomastia. These patients have increased LH secretion that leads to both increased Leydig cell testosterone production and aromatization. The peripheral aromatization of androgens to estrogens is also enhanced in these patients. In addition, sex hormone-binding globulin is increased, which decreases free testosterone concentrations.

Rarely, patients with gynecomastia have an estrogen-secreting tumor of the adrenal gland; most of these are adrenocortical carcinomas.



## GALACTORRHEA

Galactorrhea (abnormal lactation) refers to the inappropriate mammary secretion of milky fluid that occurs more than 6 months' postpartum in a woman who is not breastfeeding. It is usually bilateral but may be unilateral and spontaneous or expressible. The onset may date back to normal postpartum lactation that failed to stop. Galactorrhea is extremely rare in men.

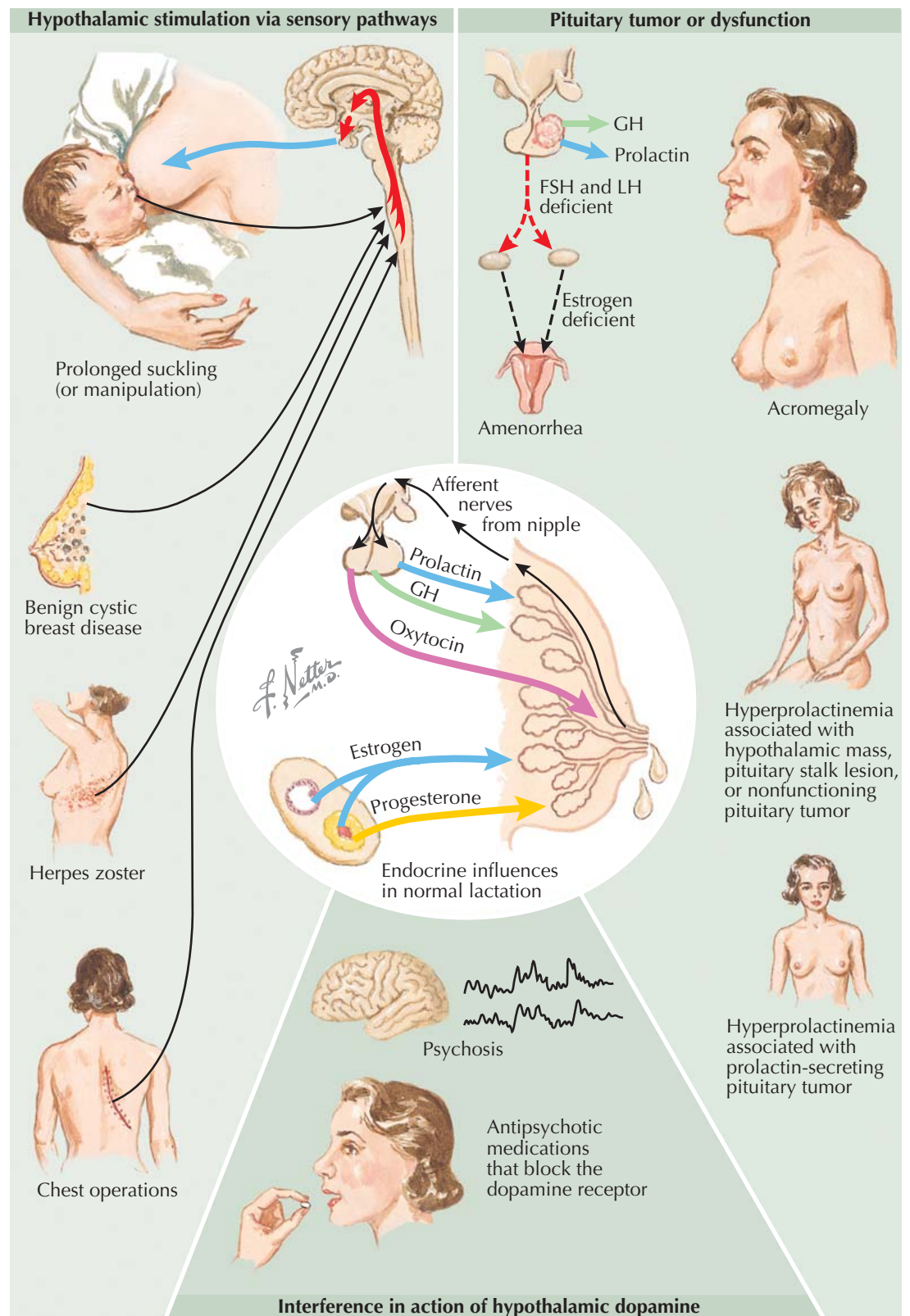
For normal lactation and galactopoiesis (maintenance of lactation), the basic requirements include optimal amounts of prolactin from the anterior pituitary gland and estrogen and progesterone from the ovaries for duct formation and lobule-alveolar development, respectively. Blood prolactin concentrations increase progressively through pregnancy and peak at the time of delivery to levels approximately 10 times the upper limit of the reference range for nonlactating individuals. The increasing blood estrogen levels in pregnancy promote prolactin secretion by binding to a prolactin response element in the pituitary lactotroph cell. Suckling has a dual action in the promotion and maintenance of lactation; it stimulates the release of prolactin and oxytocin. The latter leads to the contraction of the myoepithelial cells of the mammary acini, thereby allowing the free flow of milk into the larger ducts. Prolactin secretion is inhibited by dopamine, the prolactin-inhibiting factor that is continuously released by the hypothalamus and reaches the pituitary lactotrophs via the pituitary stalk.

The causes of galactorrhea are quite diverse, but a common pathway is hyperprolactinemia. Any process (e.g., hypothalamic mass, pituitary stalk lesions, or pituitary macroadenomas) that interferes with the transmission of dopamine from the hypothalamus to the anterior pituitary lactotrophs may result in hyperprolactinemia. Frequently, the initial presentation of a prolactin-secreting pituitary tumor (prolactinoma) is galactorrhea (see Plate 1-21). Drugs that block the effect of dopamine at the dopamine receptors on the lactotrophs (e.g., risperidone, phenothiazines, metoclopramide) can cause hyperprolactinemia. Hyperprolactinemia also occurs in patients with primary hypothyroidism when increased hypothalamic thyrotropin-releasing hormone stimulates lactotroph prolactin release. Chronic renal failure causes hyperprolactinemia because of increased prolactin secretion and decreased metabolic clearance.

Anything that stimulates the effect of a suckling infant (e.g., chronic nipple stimulation) can result in galactorrhea. This mechanism is also responsible for galactorrhea associated with thoracotomy and healing chest wall wounds, chest wall injuries, cervical spine lesions, and herpes zoster affecting the chest wall.

Approximately 50% of women with acromegaly have galactorrhea, frequently in the absence of hyperprolactinemia. Growth hormone (GH) is a potent lactogen itself.

The most common cause of galactorrhea, accounting for approximately 50% of cases, is end-organ breast



hypersensitivity in which the serum prolactin concentration is normal. In this setting, the menstrual cycles are typically regular. This form of idiopathic galactorrhea usually occurs postpartum and persists when the menses restart.

In general, galactorrhea is most effectively treated by correcting the hyperprolactinemia. Dopamine agonists (e.g., bromocriptine, cabergoline) are the treatment of choice for patients with prolactin-secreting pituitary

tumors (see Plate 1-21). These agents normalize serum prolactin and resolve galactorrhea. Although hyperprolactinemia associated with stalk effect of nonfunctioning pituitary tumors can be corrected with a dopamine agonist, these agents do not address the tumor itself. When a medication is identified as the cause of hyperprolactinemia, an alternative medication should be prescribed.

# PANCREAS



This page intentionally left blank

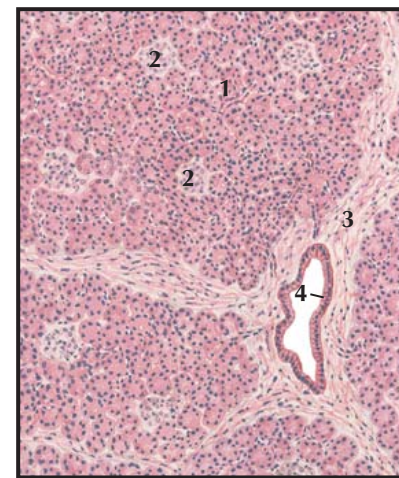
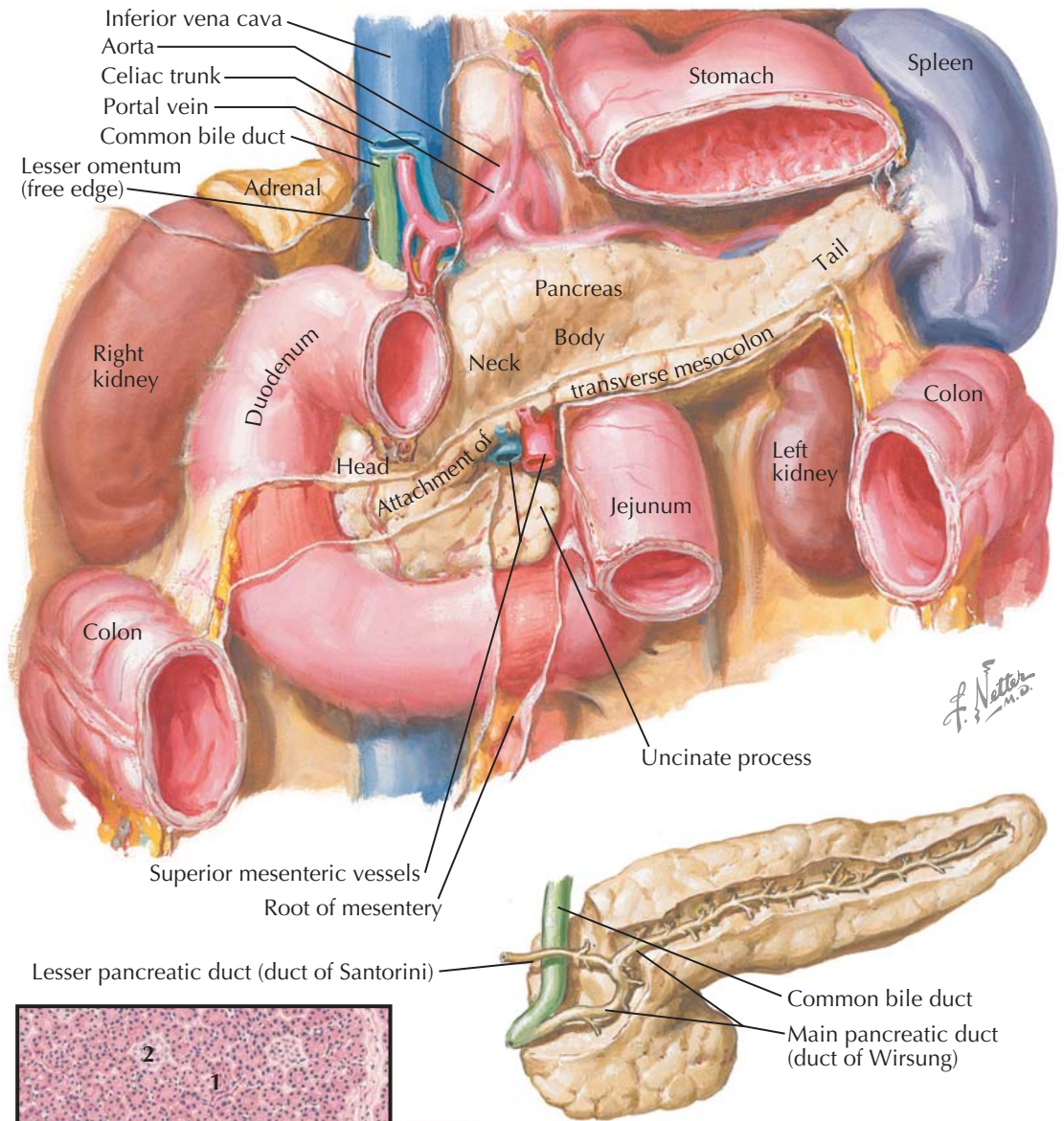
## PANCREAS ANATOMY AND HISTOLOGY

The pancreas is a retroperitoneal organ that lies in an oblique position, where it slopes upward from the duodenum to the hilum of the spleen. The pancreas is 15 to 20 cm long and weighs 75 to 100 g. The four general regions of the pancreas are the head, neck, body, and tail. The head of the pancreas is located in the C-loop of the duodenum, posterior to the transverse mesocolon and anterior to the vena cava, right renal artery, and both renal veins. The uncinate process is the posterior and medial aspects of the head of the pancreas, and it lies behind the portal vein and superior mesenteric vessels. The neck of the pancreas is anterior to the portal vein and first and second lumbar vertebral bodies. The body of the pancreas lies anterior to the aorta at the origin of the superior mesenteric artery. The body and tail of the pancreas lie anterior to the splenic artery and vein. The tail of the pancreas is anterior to the left kidney. The anterior surface of the pancreas is covered by peritoneum. The base of the transverse mesocolon attaches to the inferior margin of the body and tail of the pancreas.

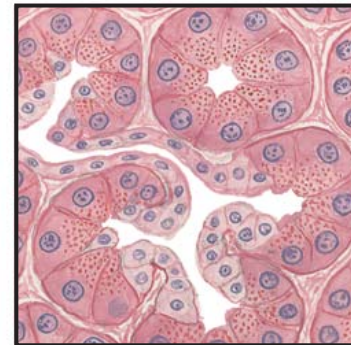
The embryologic origin of the pancreas is the result of fusion of the ventral and dorsal buds. The duct from the smaller ventral bud connects directly to the common bile duct and becomes the duct of Wirsung. The ventral bud becomes the inferior portion of the pancreatic head and uncinate process. The duct from the larger dorsal bud drains directly into the duodenum and becomes the duct of Santorini. The dorsal bud becomes the body and tail of the pancreas. The ducts from each anlage fuse in the pancreatic head so that most of the exocrine pancreas drains through the duct of Wirsung or the main pancreatic duct and then into the common channel formed by the bile duct and pancreatic duct to empty at the ampulla of Vater on the medial aspect of the second portion of the duodenum. The flow of pancreatic and biliary secretions is controlled by the sphincter of Oddi, a group of muscle fibers at the ampulla of Vater.

The blood supply to the pancreas includes multiple branches from the superior mesenteric and celiac arteries. The gastroduodenal artery comes off the common hepatic artery and supplies the head and uncinate process. The body and tail of the pancreas are supplied by multiple branches of the splenic artery. The inferior pancreatic artery arises from the superior mesenteric artery. Three arteries that connect the splenic and inferior pancreatic arteries run perpendicular to the long axis of the pancreas and form an arterial arcade supplying the body and tail of the pancreas. The venous drainage includes an anterior and posterior venous arcade within the head of the pancreas that drains into the portal and mesenteric veins. The venous outflow from the body and tail of the pancreas drain into the splenic vein. The lymphatic drainage of the pancreas includes a profuse network of lymphatic vessels and lymph nodes.

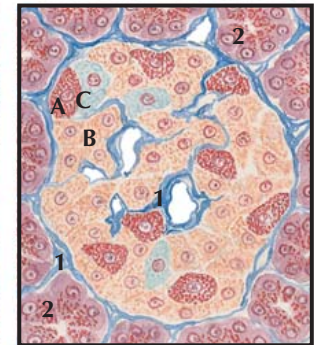
Both the sympathetic and parasympathetic nervous systems innervate the acinar cells (exocrine secretion), islet cells (endocrine secretion), and islet vasculature. In general, the parasympathetic system stimulates endocrine and exocrine secretions, and the sympathetic system inhibits secretions. The neurons that innervate the pancreas also release unique transmitters that include peptides and amines (e.g., somatostatin, galanin,



Low-power section of pancreas  
1. Acini, 2. islet, 3. interlobular septum, 4. interlobular duct



High magnification: acini, intercalated duct, and zymogen granules



Pancreatic islet: A ( $\alpha$ -cell), B ( $\beta$ -cell), and C ( $\delta$ -cell).  
1. Reticulum, 2. acini

vasoactive intestinal polypeptide, and calcitonin gene-related peptide). A rich supply of afferent sensory nerve fibers is responsible for the intense abdominal pain associated with pancreatic inflammation.

The distribution of pancreatic mass is 85% exocrine, 2% endocrine, 10% extracellular matrix, and 4% blood vessels and ducts. The exocrine cells are clustered in acini (lobules) divided by connective tissue and connected to a duct that drains into the pancreatic duct and into the duodenum. The acinar cells have a high content

of endoplasmic reticulum and are apically located eosinophilic zymogen granules. Small clusters of endocrine cells—islets of Langerhans—are embedded within the acini. The three main types of endocrine cells are  $\beta$ -cells (75% of endocrine cell mass) that produce insulin,  $\alpha$ -cells (20% of endocrine cell mass) that produce glucagon, and the  $\delta$ -cells (5% of endocrine cell mass) that secrete somatostatin. Within the islet, the  $\beta$ -cells are in the center and surrounded by the  $\alpha$ -cells and  $\delta$ -cells.



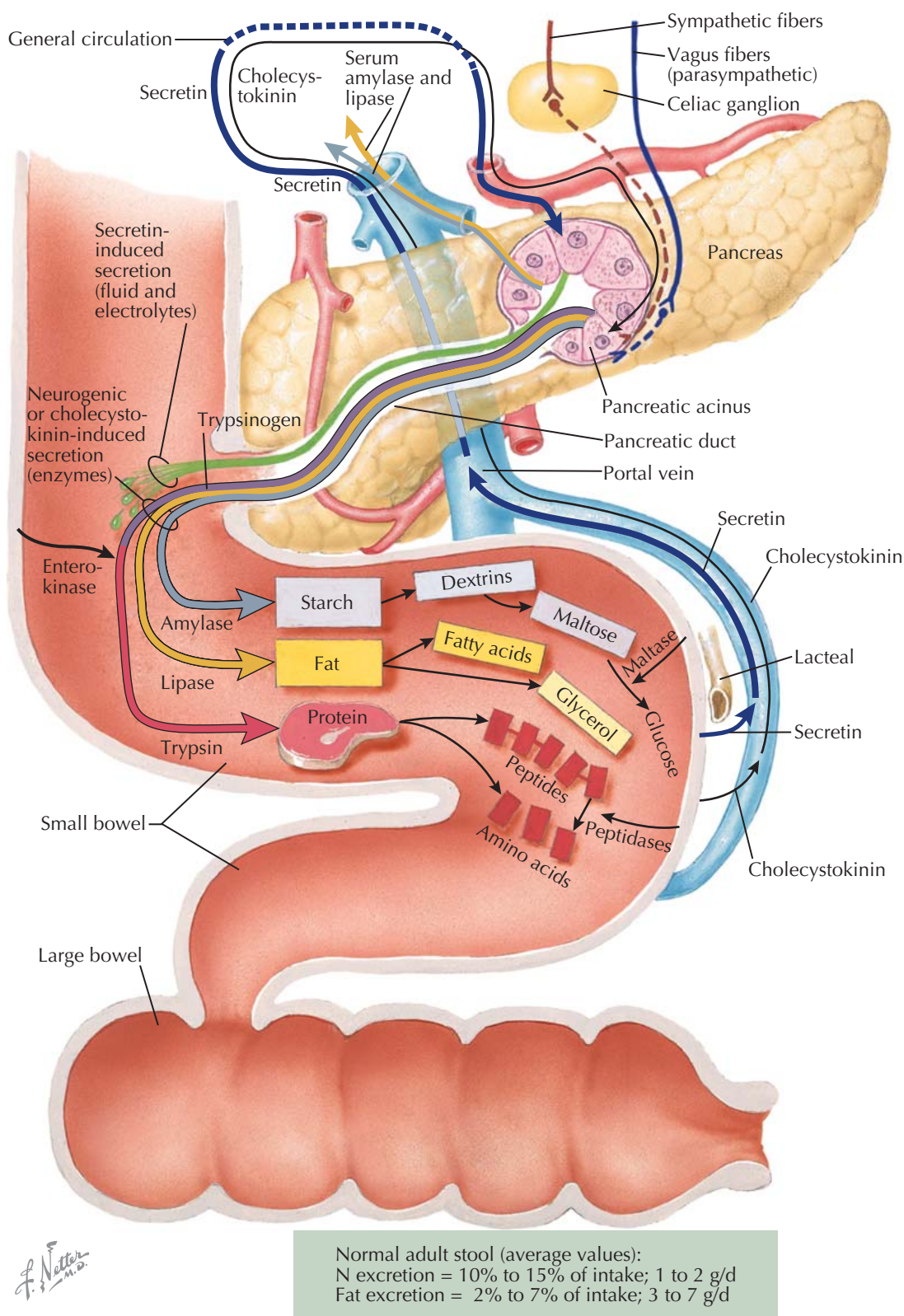
## EXOCRINE FUNCTIONS OF THE PANCREAS

Each day the pancreas secretes approximately 1 L of alkaline isosmotic pancreatic juice that originates from the pancreatic acinar cells and pancreatic ducts. The colorless, bicarbonate-rich, and protein-rich pancreatic juice plays key roles in duodenal alkalization and food digestion. The acinar cells secrete the enzymes required for the digestion of the three main food types: amylase for carbohydrate (starch) digestion, proteases (e.g., trypsin) for protein digestion, and lipases for fat digestion. The acinar cells are pyramidal in shape with the apices facing the lumen of the acinus, where the enzyme-containing zymogen granules fuse with the apical cell membrane for release. Acinar cells, unlike the endocrine cells of the pancreas, are not specialized and produce all three types of pancreatic enzymes from the same cell type.

Amylase is secreted in its active form and hydrolyzes starch and glycogen to the simple sugars of dextrins and maltose; maltose is then metabolized to glucose by intestinal maltase. The proteolytic enzymes are secreted as proenzymes and must be activated in the duodenum. For example, trypsinogen is converted in the duodenum to trypsin by enterokinase. Intrapancreatic conversion of trypsinogen is prevented by a pancreatic secretory trypsin inhibitor, a step that prevents pancreatic auto-digestion. Another example of a proteolytic enzyme that is secreted as a proenzyme is chymotrypsinogen, which is activated in the duodenum to chymotrypsin. The actions of trypsin, chymotrypsin, and other proteolytic enzymes (e.g., elastase, carboxypeptidase A and B, intestinal peptidases) cleave bonds between amino acids in peptide chains, yielding smaller peptides that stimulate the intestinal endocrine cells to release cholecystokinin and secretin, which further stimulate the pancreas to release more digestive enzymes and bicarbonate. The amino acids and dipeptides are actively transported into enterocytes.

Pancreatic lipase is secreted in its active form, and it hydrolyzes triglycerides to fatty acids and glycerol. Phospholipase A cleaves the fatty acid off lecithin to form lysolecithin. Phospholipase B cleaves the fatty acid off lysolecithin to form glycerol phosphatidylcholine. Phospholipase A2 is activated by trypsin in the duodenum, where it serves to hydrolyze phospholipids. Hydrolyzed fat is organized in micelles and is transported into the enterocytes.

There are approximately 40 acinar cells per acinus. The acinar cells near the center of the acinus are termed *centroacinar cells*. Centroacinar cells and pancreatic duct cells secrete electrolytes, bicarbonate, and water into the pancreatic juice. At rest, secretion occurs at a

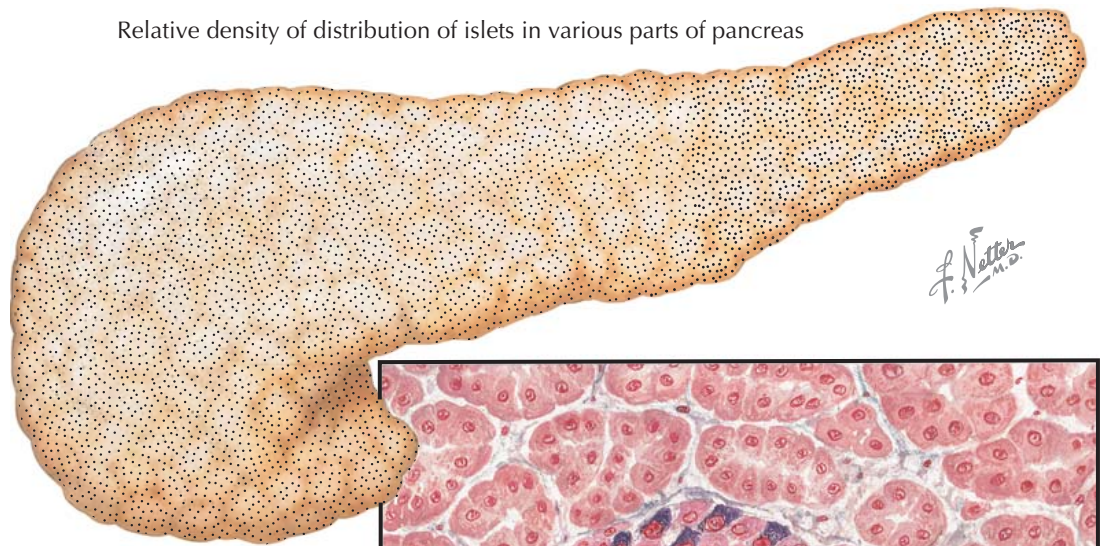


basal rate (~2% of maximal). The pancreas' response to a meal occurs in three phases. The cephalic phase—in response to the smell, sight, and taste of food—accounts for 10% of meal-stimulated pancreatic secretion and is mediated by peripherally released acetylcholine. The gastric phase—in response to gastric distension from food—accounts for 10% of meal-stimulated pancreatic secretion. With gastric distension, gastrin is released, and vagal afferents are stimulated to directly mediate pancreatic enzyme secretion and enhance gastric acid

secretion and duodenal acidification. The intestinal phase accounts for 80% of meal-stimulated pancreatic secretion. The duodenal hormone secretin is released in response to acid chyme (pH <3.0) and bile passing into the duodenum. Secretin then stimulates increased production of centroacinar cell bicarbonate to buffer the acidic chyme. Cholecystokinin is also released in response to protein and fat in the proximal small intestine, and it enhances the centroacinar cell response to secretin.



Relative density of distribution of islets in various parts of pancreas



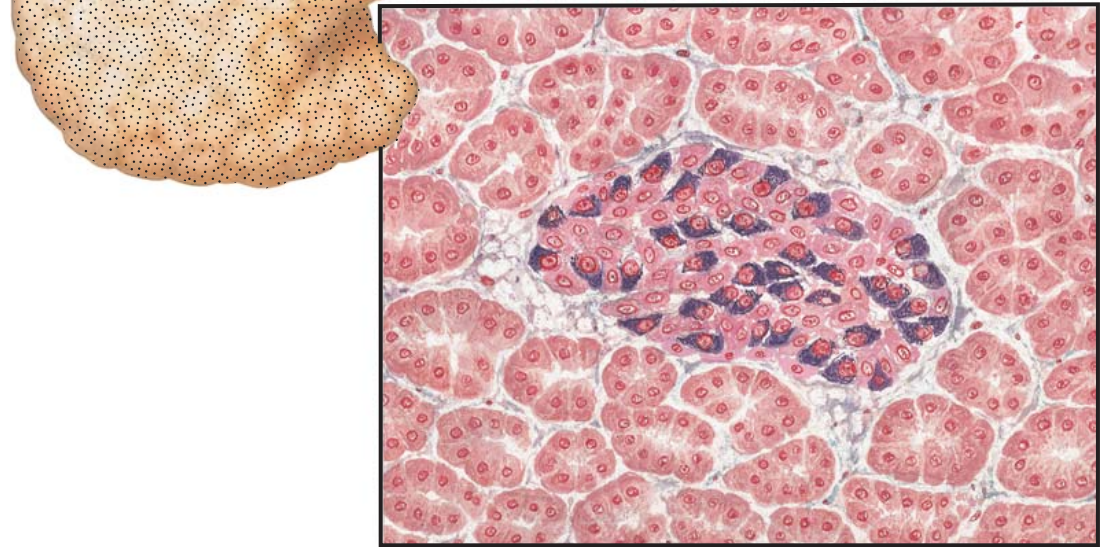
## NORMAL HISTOLOGY OF PANCREATIC ISLETS

The pancreas is the union of an endocrine gland (pancreatic islets) and an exocrine gland (acinar and ductal cells). Approximately 85% of pancreatic mass is exocrine, 2% endocrine, 10% extracellular matrix, and 3% blood vessels and ducts. The exocrine (acinar) cells are clustered in acini, divided by connective tissue, and connected to a duct that drains into the pancreatic duct and into the duodenum. Small clusters of endocrine cells—*islets of Langerhans*—are embedded within the acini of the pancreas. The three main types of endocrine cells are  $\beta$ -cells (75% of endocrine cell mass) that produce insulin,  $\alpha$ -cells (20% of endocrine cell mass) that produce glucagon, and  $\delta$ -cells (5% of endocrine cell mass) that secrete somatostatin. The  $\delta$ -cells secrete vasoactive intestinal polypeptide. The pancreatic polypeptide-producing (PP) cells secrete pancreatic polypeptide. Within the islet, the  $\beta$ -cells are in the center and surrounded by the  $\alpha$ -cells,  $\delta$ -cells, and PP cells.

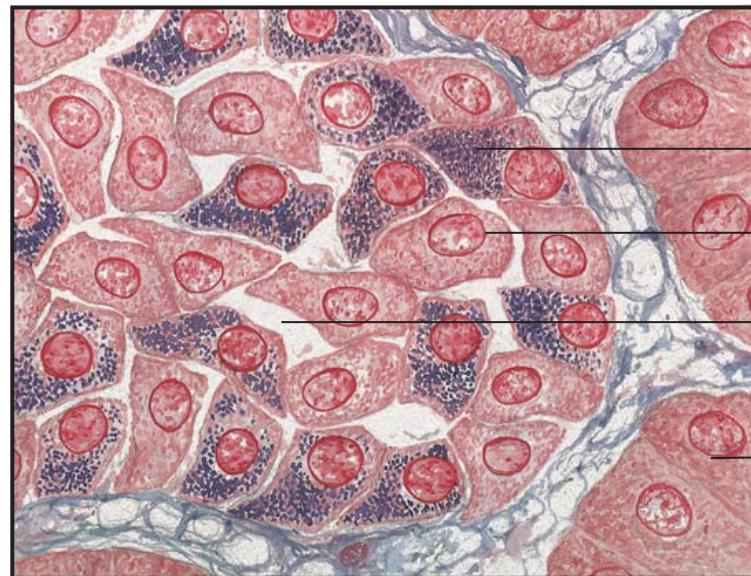
The adult pancreas contains about 1 million islets (varying in size from 40–300  $\mu\text{m}$ ) that are more densely distributed in the tail of the gland. The entire mass of islets in a single pancreas weighs only approximately 1 g. Each islet contains approximately 3000 cells. The  $\beta$ -cells are polyhedral in shape and are distributed equally in islets across the pancreas. The  $\alpha$ -cells are columnar in shape and are located primarily in islets in the body and tail of the pancreas. The  $\delta$ -cells are smaller than the  $\alpha$ - and  $\beta$ -cells and are frequently dendritic. The PP cells are located primarily in islets in the head and uncinata process of the pancreas. The Gomori aldehyde fuchsin and Ponceau techniques stain the insulin-containing granules in  $\beta$ -cells a deep bluish-purple; the  $\alpha$ -cells appear pink or red.

Insulin, discovered in 1920 by Banting and Best, is a 56-amino acid peptide with two chains ( $\alpha$  and  $\beta$  chains) joined by two disulfide bridges.  $\beta$ -Cell synthesis of insulin is regulated by plasma glucose concentrations, neural signals, and paracrine effects. The enteric hormones gastric inhibitory peptide, glucagon-like peptide-1 (GLP-1), and cholecystokinin also augment insulin secretion. Somatostatin, amylin, and pancreastatin inhibit insulin release. Cholinergic and  $\beta$ -adrenergic sympathetic innervation stimulate insulin release, and  $\alpha$ -adrenergic sympathetic innervation inhibits insulin secretion. Insulin acts by inhibiting hepatic glucose production, glycogenolysis, fatty acid breakdown, and ketone formation. Insulin also facilitates glucose transport into cells and stimulates protein synthesis.

Glucagon is a 29-amino acid single-chain peptide hormone that counteracts the effects of insulin by promoting hepatic glycogenolysis and gluconeogenesis. Glucagon release is inhibited by increased levels of plasma glucose and by GLP-1, insulin, and somatostatin. Glucagon secretion is stimulated by the amino acids



Section of an islet surrounded by acini ( $\times 220$ ); Gomori aldehyde fuchsin and Ponceau stain:  $\beta$ -granules stain deep purple;  $\alpha$ -cells, orange-pink



Portion of islet greatly magnified ( $\times 1200$ ); Gomori aldehyde fuchsin and Ponceau stain

arginine and alanine. As with insulin, cholinergic and  $\beta$ -adrenergic sympathetic innervation stimulate glucagon release, and  $\alpha$ -adrenergic sympathetic innervation inhibits glucagon secretion.

Somatostatin is a peptide that has two bioactive forms—14-amino acid and 28-acid forms. In general, somatostatin inhibits pancreatic endocrine and exocrine secretions.

Pancreatic polypeptide is a 36-amino acid hormone that inhibits bile secretion, gallbladder contraction, and

exocrine pancreatic secretion. Pancreatic polypeptide also regulates hepatic insulin receptor expression. Enteral protein and fat stimulate pancreatic polypeptide secretion.

Amylin (also referred to as islet amyloid polypeptide) is a 37-amino acid hormone secreted by  $\beta$ -cells in concert with insulin. Amylin is synergistic with insulin by slowing gastric emptying, inhibiting digestive secretions, and inhibiting glucagon release. The effects of amylin are centrally mediated.



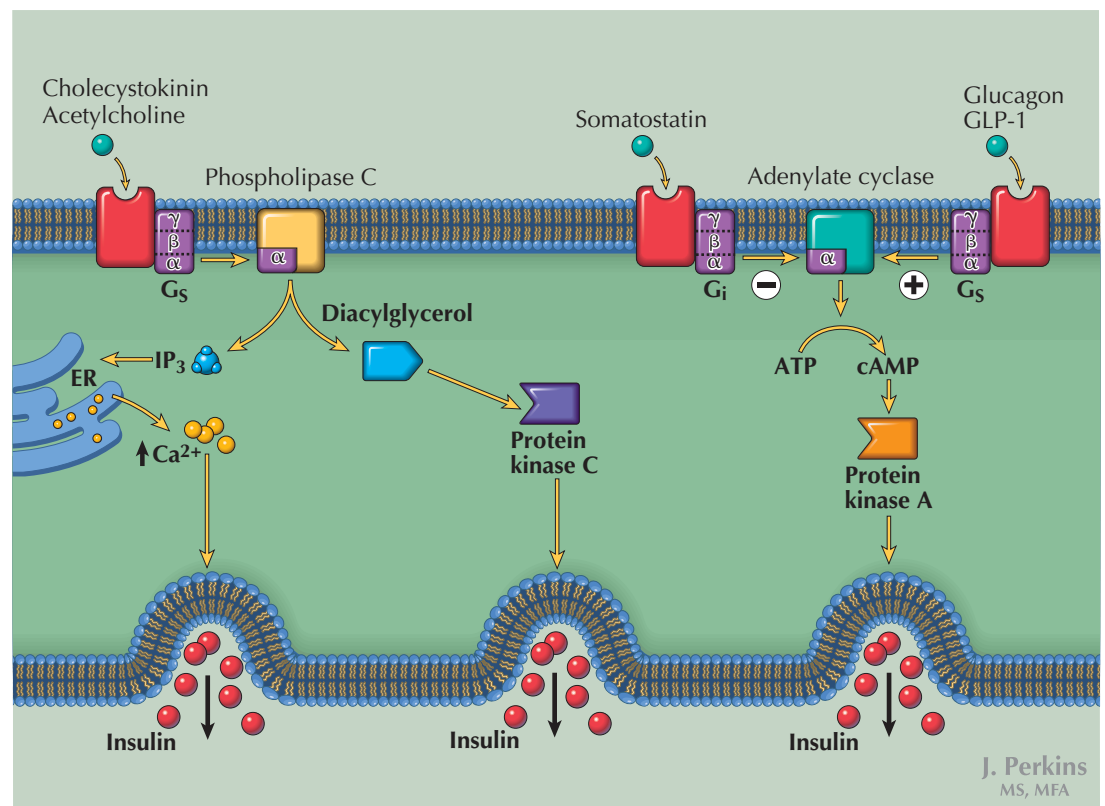
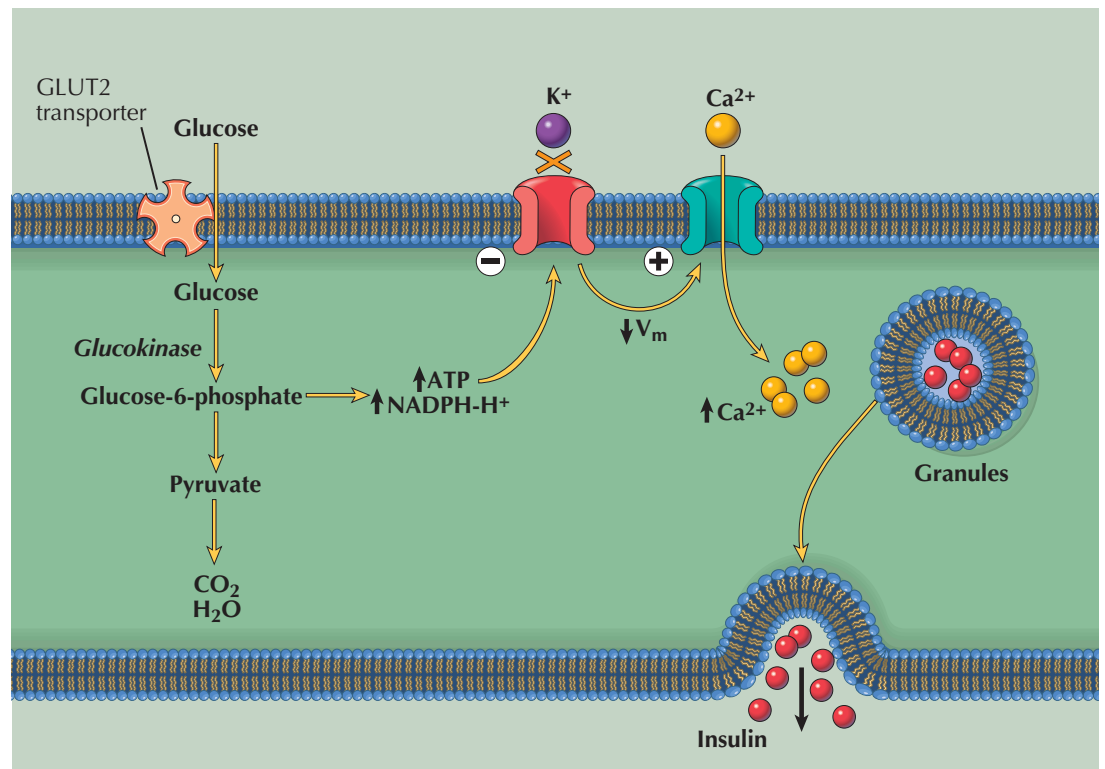
## INSULIN SECRETION

Pancreatic  $\beta$ -cell production of insulin is regulated by plasma glucose concentration, neural inputs, and the effects of other hormones by paracrine and endocrine actions. Proinsulin consists of an amino-terminal  $\beta$ -chain, a carboxy-terminal  $\alpha$ -chain, and a connecting peptide (C-peptide) in the middle. C-peptide functions by allowing folding of the molecule and the formation of disulfide bonds between the  $\alpha$ - and  $\beta$ -chains. C-peptide is cleaved from proinsulin by endopeptidases in the  $\beta$ -cell endoplasmic reticulum (ER) to form insulin. Insulin and C-peptide are packaged into secretory granules in the Golgi apparatus. The secretory granules are released into the portal circulation by exocytosis. Insulin is degraded in the liver, kidney, and target tissues; it has a circulating half-life of 3 to 8 minutes. C-peptide does not act at the insulin receptor and is not degraded by the liver; it has a circulating half-life of 35 minutes. Thus, measurement of serum C-peptide concentration serves as a measure of  $\beta$ -cell secretory capacity. Defects in the synthesis and cleavage of insulin can lead to rare forms of diabetes mellitus (e.g., Wakayama syndrome, proinsulin syndromes).

Insulin is released in a pulsatile and rhythmic background pattern throughout the day and serves to suppress hepatic glucose production and mediates glucose disposal by adipose tissue. Superimposed on the background secretion of insulin is the meal-induced insulin release. There are two phases of caloric intake-induced insulin secretion. In the first phase, prestored insulin is released over 4 to 6 minutes. The second phase is a slower onset and longer sustained release because of the production of new insulin.

The regulators of insulin release include nutrients (e.g., glucose and amino acids), hormones (e.g., glucagon-like peptide 1 [GLP-1], somatostatin, insulin, and epinephrine), and neurotransmitters (e.g., acetylcholine, norepinephrine). The  $\beta$ -cells are exquisitely sensitive to small changes in glucose concentration; maximal stimulation of insulin secretion occurs at plasma glucose concentrations more than 400 mg/dL. Glucose enters the  $\beta$ -cells by a membrane-bound glucose transporter (GLUT 2). Glucose is then phosphorylated by glucokinase as the first step in glycolysis (leading to the generation of acetyl-coenzyme A and adenosine triphosphate (ATP) through the Krebs cycle (see Plate 5-6). The rise in intracellular ATP closes (inhibits) the ATP-sensitive potassium ( $K^+$ ) channels and reduces the efflux of  $K^+$ , which causes membrane depolarization and opening (activation) of the voltage-dependent calcium ( $Ca^{2+}$ ) channels. The resultant  $Ca^{2+}$  influx increases the concentration of intracellular  $Ca^{2+}$ , which triggers the exocytosis of insulin secretory granules into the circulation. The  $\beta$ -cell  $Ca^{2+}$  concentrations can also be increased by the ATP generated from amino acid metabolism.

Insulin release from  $\beta$ -cells can be amplified by cholecystokinin, acetylcholine, gastric inhibitory polypeptide (GIP), glucagon, and GLP-1. Orally administered glucose stimulates a greater insulin response than an equivalent amount of glucose administered intravenously because of the release of enteric hormones (e.g., GLP-1, GIP) that potentiate insulin secretion. This phenomenon is referred to as the *incretin effect*, a finding that has led to new pharmacotherapeutic options in the treatment of patients with type 2 diabetes mellitus (see Plate 5-20). Acetylcholine and cholecystokinin bind to cell surface receptors and activate adenylate cyclase and phospholipase C, which leads to inositol triphosphate ( $IP_3$ ) breakdown and



J. Perkins  
MS, MFA

mobilization of  $Ca^{2+}$  from intracellular stores; activation of protein kinase C also triggers insulin secretion. GLP-1 receptor activation leads to increased cyclic adenosine monophosphate (cAMP) and activation of the cAMP-dependent protein kinase A; the  $Ca^{2+}$  signal is amplified by decreasing  $Ca^{2+}$  uptake by cellular stores and by activation of proteins that trigger exocytosis of insulin. Somatostatin and catecholamines inhibit insulin secretion through G-protein-coupled receptors and inhibition of adenylate cyclase.

Normal insulin secretion is dependent on the maintenance of an adequate number of functional  $\beta$ -cells (referred to as  *$\beta$ -cell mass*). The  $\beta$ -cells must be able to sense the key regulators of insulin secretion (e.g., blood glucose concentration). In addition, the rates of proinsulin synthesis and processing must be sufficient to maintain adequate insulin secretion. Defects in any of these steps in insulin secretion can lead to hyperglycemia and diabetes mellitus.

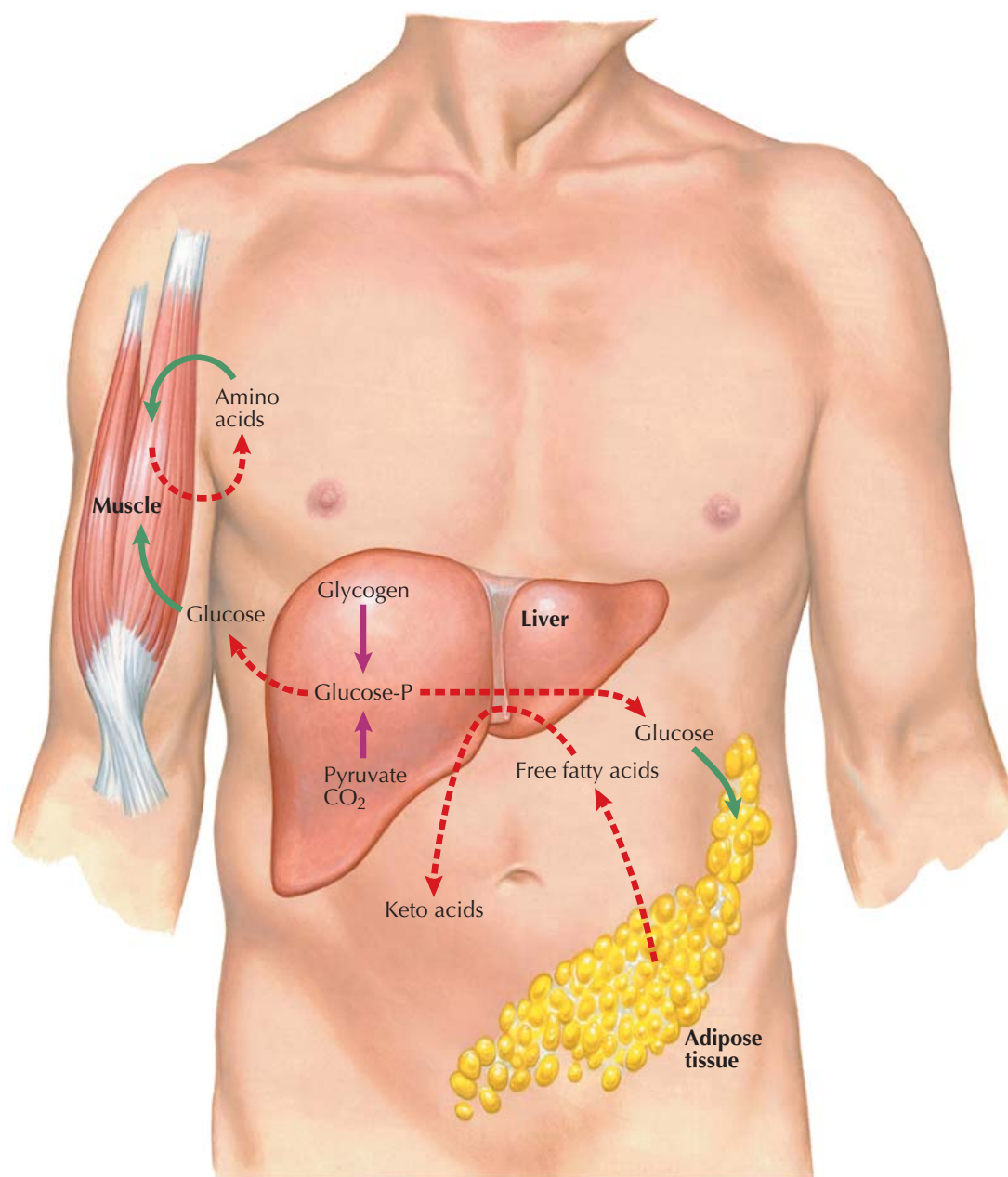
## ACTIONS OF INSULIN

Insulin is a 56–amino acid polypeptide that consists of two peptide chains ( $\alpha$  and  $\beta$ ) that are joined by two disulfide bridges. Insulin is secreted into the portal vein and delivered directly to the liver. Approximately 80% of insulin is cleared by the hepatic cell surface insulin receptors with the first pass through the liver. Insulin acts through the insulin receptor and has anabolic effects at target organs to promote synthesis of carbohydrate, fat, and protein.

The insulin receptor, a member of the growth factor receptor family, is a heterotetrameric glycoprotein membrane receptor that has two  $\alpha$ - and two  $\beta$ -subunits that are linked by disulfide bonds. The  $\alpha$ -subunits form the extracellular portion where insulin binds. The  $\beta$ -subunits form the transmembrane and intracellular portions of the receptor and contain an intrinsic tyrosine kinase activity. Insulin binding to the receptor triggers autophosphorylation on the intracellular tyrosine residues and leads to phosphorylation of insulin receptor substrates (IRS-1, IRS-2, IRS-3, and IRS-4). The phosphorylation of the IRS proteins activates the phosphatidylinositol-3-kinase (PI<sub>3</sub> kinase) and mitogen-activated protein kinase (MAPK) pathways. The PI<sub>3</sub> kinase pathway mediates the metabolic (e.g., glucose transport, glycolysis, glycogen synthesis, and protein synthesis) and antiapoptotic effects of insulin. The MAPK pathway has primarily proliferative and differentiation effects. The number of insulin receptors expressed on the cell membrane can be modulated by diet, body type, exercise, insulin, and other hormones. Obesity and high serum insulin concentrations down-regulate the number of insulin receptors. Exercise and starvation upregulate the number of insulin receptors.

Glucose oxidation is the major energy source for many tissue types. Cell membranes are impermeable to hydrophilic molecules such as glucose and require a carrier system to transport glucose across the lipid bilayer cell membrane. Glucose transporter 1 (GLUT 1) is present in all tissues and has a high affinity for glucose to mediate a basal glucose uptake in the fasting state. GLUT 2 has a low affinity for glucose and functions primarily at high plasma glucose concentrations (e.g., after a meal). GLUT 3 is a high-affinity glucose transporter for neuronal tissues. GLUT 4 is localized primarily to muscle and adipose tissues.

In muscle, activation of the insulin receptor and the PI<sub>3</sub> kinase pathway leads to recruitment of the glucose transporter GLUT 4 from the cytosol to the plasma membrane. Increased expression of GLUT 4 leads to active transport of glucose across the myocyte cell



**Insulin**  
Stimulates  
→  
Inhibits  
- - - →

*C. Machado*  
—M.D.

membrane. Insulin promotes myocyte glycogen synthesis by increasing the activity of glycogen synthase and inhibiting the activity of glycogen phosphorylase. Insulin also enhances protein synthesis by increasing amino acid transport and by phosphorylation of a serine/threonine protein kinase.

In adipose tissue, insulin inhibits lipolysis by promoting dephosphorylation of hormone-sensitive (intracellular) lipase. The decreased breakdown of adipocyte triglycerides to fatty acids and glycerol leads to decreased substrate for ketogenesis. Insulin also induces the production of the endothelial cell-bound lipoprotein lipase, which hydrolyzes triglycerides from circulating lipoproteins to provide free fatty acids for adipocyte uptake. Insulin stimulates lipogenesis by activating acetyl-coenzyme A carboxylase. Increased

glucose transport into adipocytes increases the availability of  $\alpha$ -glycerol phosphate that is used in the esterification of free fatty acids into triglycerides. The decreased fatty acid delivery to the liver is a key factor in the net impact of insulin to decrease hepatic gluconeogenesis and ketogenesis.

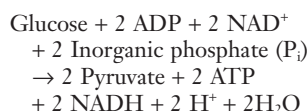
In the liver, insulin stimulates the synthesis of enzymes that are involved in glucose utilization (e.g., pyruvate kinase, glucokinase) and inhibits the synthesis of enzymes involved in glucose production (e.g., glucose 6-phosphatase, phosphoenolpyruvate carboxykinase). Insulin enhances glycogen synthesis by increasing phosphatase activity, causing dephosphorylation of glycogen synthase and glycogen phosphorylase. Insulin also promotes hepatic synthesis of triglycerides, very low-density lipoprotein, and proteins.



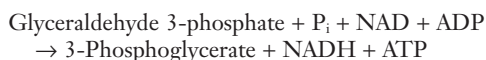
## GLYCOLYSIS

Glycolysis is the major pathway for glucose metabolism, and it occurs in the cytosol of all cells. Glycolysis breaks down glucose (a 6-carbon molecule) into pyruvate (a 3-carbon molecule). Glycolysis can function either aerobically or anaerobically, depending on the availability of oxygen and the electron transport chain. The ability of glycolysis to provide energy in the form of adenosine triphosphate (ATP) from adenosine diphosphate (ADP) in the absence of oxygen allows tissues to survive anoxia.

Glycolysis occurs when a molecule of glucose 6-phosphate is transformed to pyruvate:

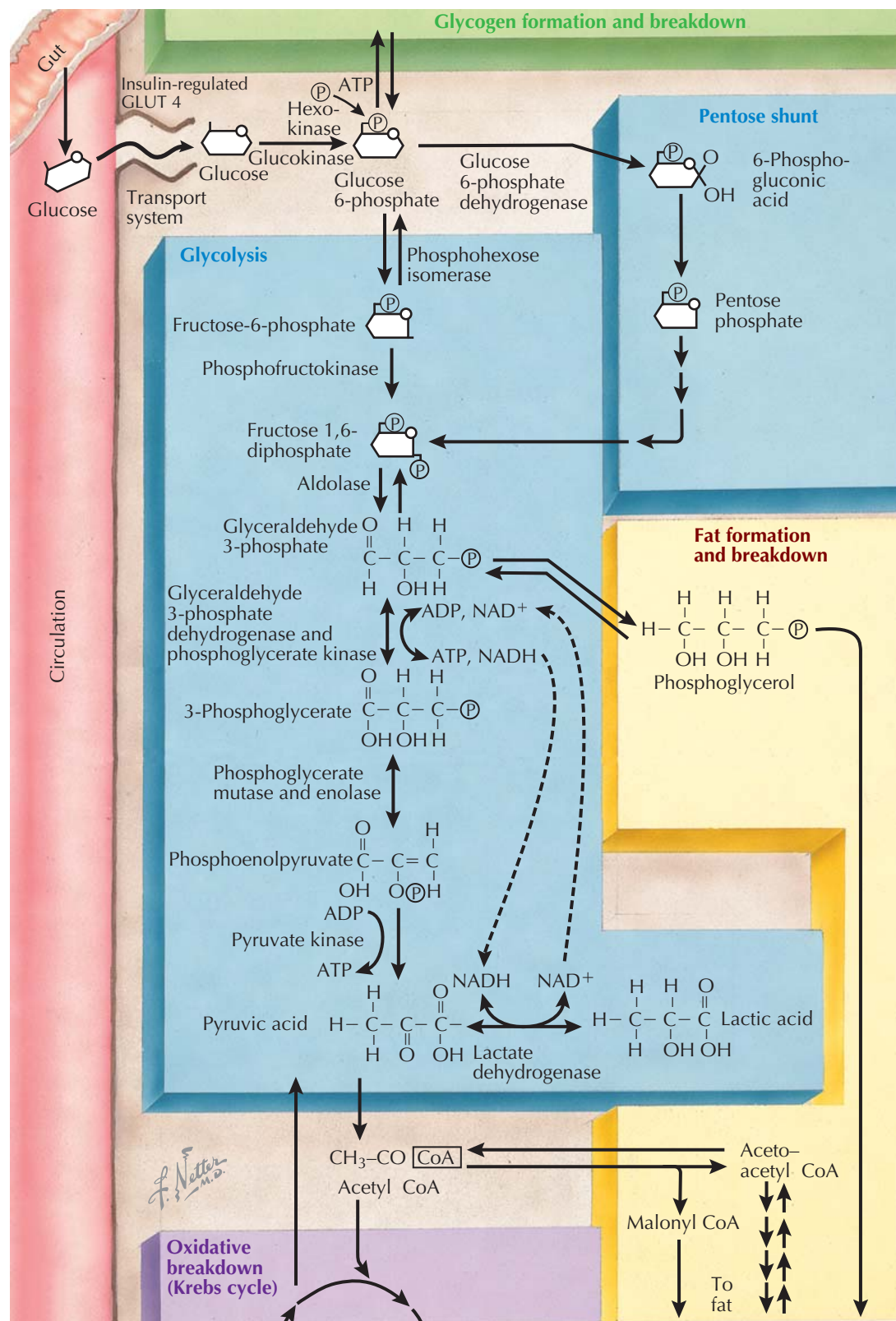


Glucose enters glycolysis by phosphorylation to glucose 6-phosphate, an irreversible reaction catalyzed by hexokinase, and ATP serves as the phosphate donor. Glucose 6-phosphate is converted to fructose-6-phosphate by phosphohexose isomerase. This intermediate is then phosphorylated to yield fructose-1,6-diphosphate. At this stage, the hexose molecule is cleaved by aldolase into two 3-carbon compounds: glyceraldehyde 3-phosphate and dihydroxyacetone phosphate. Dihydroxyacetone phosphate is quickly converted to glyceraldehyde 3-phosphate. The aldehyde group (CHO) of glyceraldehyde 3-phosphate is oxidized by a nicotinamide adenine dinucleotide (NAD)-dependent enzyme, and a phosphate group is attached, yielding 1,3-bisphosphoglycerate. The energy of this oxidative step now rests in the phosphate bond at position 1. This energy is transferred to a molecule of ADP, forming ATP.

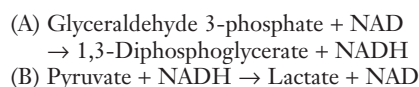


The above reaction yields energy that is not immediately given off as heat but is stored in the form of ATP. Because two molecules of glyceraldehyde 3-phosphate are produced for every molecule of glucose, two molecules of ATP are formed at this step per molecule of glucose undergoing glycolysis. An ensuing transformation of phosphoenolpyruvate to pyruvate (catalyzed by pyruvate kinase) gives rise to another ATP (2 molecules of ATP per molecule of glucose oxidized).

When a tissue possesses the systems for further oxidation of pyruvate, provided oxygen is present, pyruvate is cleaved to acetyl coenzyme A (CoA), and it enters the tricarboxylic acid cycle (see Plate 5-7). However, when the oxidative systems are absent (e.g., in erythrocytes that lack mitochondria) or if oxygen is excluded or is present in insufficient amounts (e.g., under



anaerobic conditions), pyruvate is reduced to lactic acid by the enzyme lactate dehydrogenase. This system provides for the reoxidation of NADH and thus enables its participation again in oxidizing glyceraldehyde 3-phosphate; otherwise, the latter reaction would stop as soon as all the molecules of NAD were reduced.



The coupling of these two reactions allows the provision of energy by carbohydrates in the absence of oxygen, albeit at the expense of considerable amounts of carbohydrate. Under aerobic conditions, approximately 30 molecules of ATP are generated per molecule of glucose that is oxidized to  $\text{CO}_2$  and  $\text{H}_2\text{O}$ , but only two molecules of ATP when oxygen is absent. Glycolysis is regulated by the three enzymes that catalyze nonequilibrium reactions: hexokinase, phosphofructokinase, and pyruvate kinase.

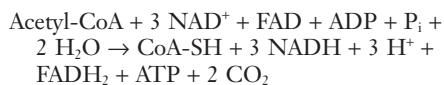
## TRICARBOXYLIC ACID CYCLE

The tricarboxylic acid (TCA) cycle, also referred to as the citric acid cycle or the Krebs cycle, is the final common pathway for oxidation of carbohydrate, lipid, and protein. Most of these nutrients are metabolized to acetyl-coenzyme A (acetyl-CoA) or one of the intermediates in the TCA cycle. For example, in protein catabolism, proteins are broken down by proteases into their constituent amino acids. The carbon backbone of these amino acids can become a source of energy by being converted to acetyl-CoA and entering into the TCA cycle. The TCA cycle also provides carbon skeletons for gluconeogenesis and fatty acid synthesis.

The TCA cycle starts with a reaction between the acetyl moiety of acetyl-CoA and the 4-carbon dicarboxylic acid, oxaloacetate, to form a 6-carbon tricarboxylic acid, citrate. In the reactions that follow, two molecules of CO<sub>2</sub> are released and oxaloacetate is regenerated. This process is aerobic and requires oxygen as the final oxidant of the reduced coenzymes.

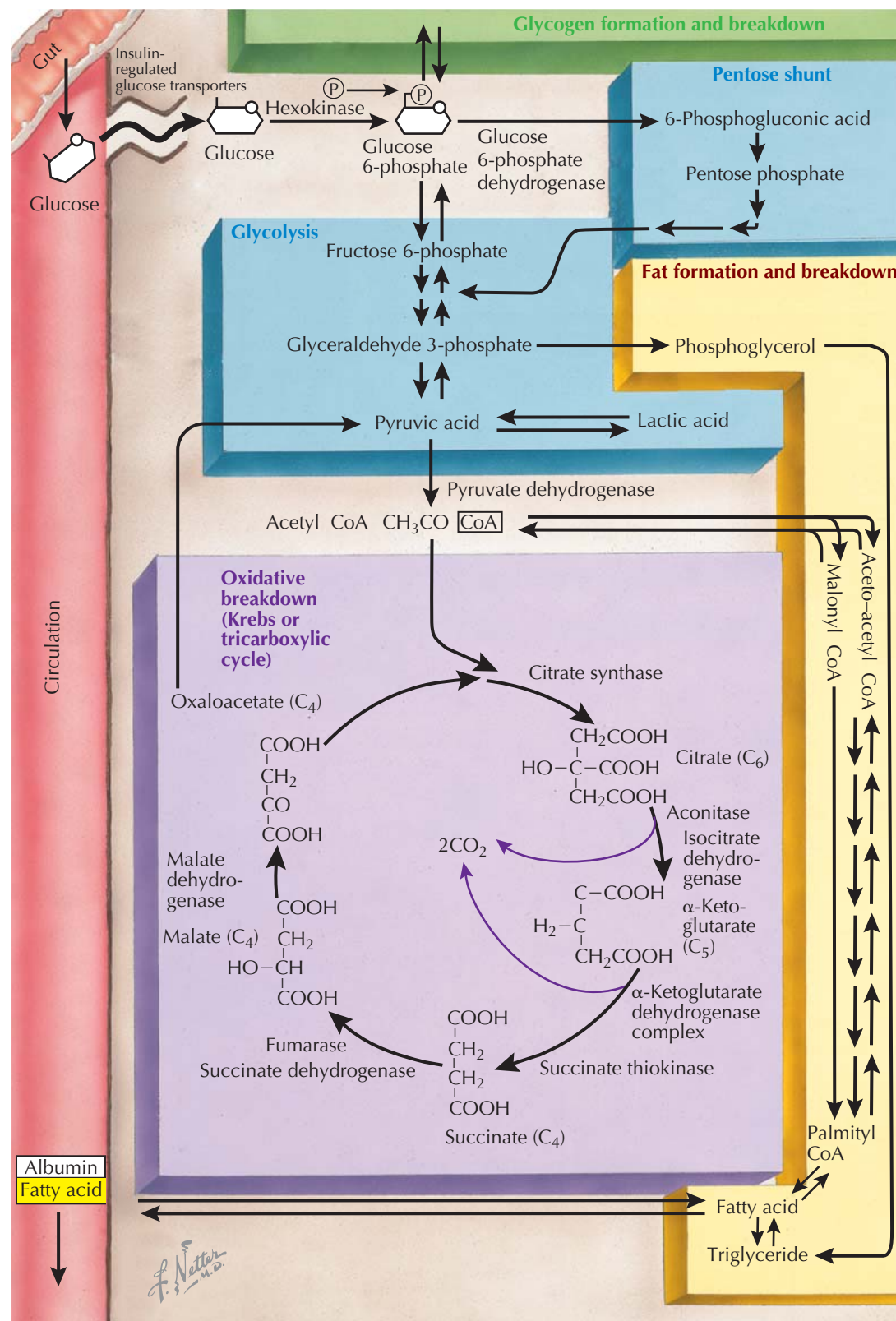
From one molecule of glucose, glycolysis (see Plate 5-6) provides two molecules of pyruvate. Pyruvate is split to acetyl-CoA and CO<sub>2</sub> by pyruvate dehydrogenase, a step that generates one molecule of reduced nicotinamide adenine dinucleotide (NADH). Citrate synthase catalyzes the initial reaction between acetyl-CoA and oxaloacetate. Citrate is then isomerized to isocitrate by aconitase. Isocitrate is dehydrogenated by isocitrate dehydrogenase to form oxalosuccinate and then  $\alpha$ -ketoglutarate.  $\alpha$ -Ketoglutarate then undergoes oxidative decarboxylation to form succinyl-CoA, a step that is catalyzed by a multienzyme complex referred to as the  $\alpha$ -ketoglutarate dehydrogenase complex. Succinyl-CoA is converted to succinate by succinyl-CoA synthetase. Succinate is then dehydrogenated to fumarate by succinate dehydrogenase. Fumarate is converted to malate by fumarate hydratase. Malate is converted to oxaloacetate by malate dehydrogenase. Oxaloacetate can then reenter the TCA cycle.

Because of the oxidations catalyzed by the dehydrogenases in the TCA cycle, three molecules of the reduced form of NADH and one molecule of flavin adenine dinucleotide H<sub>2</sub> (FADH<sub>2</sub>) are produced for each molecule of acetyl-CoA catabolized in one turn of the cycle.



In addition, the pyruvate dehydrogenase step provides one molecule of NADH. These reducing equivalents are transferred to the respiratory chain, and reoxidation of each NADH results in approximately 2.5 adenosine triphosphate (ATP) molecules and each FADH<sub>2</sub> translates to approximately 1.5 ATP molecules. In addition, one ATP equivalent is generated from the phosphorylation step of succinyl-CoA catalyzed by succinate thiokinase. Thus, including the pyruvate dehydrogenase step, approximately 12 ATP molecules are formed per turn of the TCA cycle.

Four of the B vitamins have key roles in the TCA cycle. Riboflavin (vitamin B<sub>2</sub>) in the form of FAD is a cofactor for succinate dehydrogenase. Niacin (vitamin B<sub>3</sub>) in the form of NAD is the electron acceptor for



isocitrate dehydrogenase,  $\alpha$ -ketoglutarate dehydrogenase, and malate dehydrogenase. Pantothenic acid (vitamin B<sub>5</sub>) is part of CoA. Thiamine (vitamin B<sub>1</sub>) serves as the coenzyme for decarboxylation of the  $\alpha$ -ketoglutarate dehydrogenase step.

Recent studies have shown a link between intermediates of the TCA cycle and the regulation of hypoxia-inducible factors (HIFs). HIFs have a key role in the regulation of oxygen homeostasis. HIFs are transcription factors that have broad targets, which include

apoptosis, angiogenesis, vascular remodeling, glucose use, and iron transport. Dysregulation of HIFs appears central to the development of paragangliomas and pheochromocytomas in individuals with von Hippel-Lindau syndrome, where the *VHL* tumor suppressor gene encodes a protein that regulates hypoxia-induced proteins (see Plate 8-4). In addition, the familial paraganglioma syndromes are associated with mutations in the genes that encode key subunits of succinate dehydrogenase (*SDHB*, *SDHD*, *SDHC*, *SDHA*, *SDHAF2*).



## GLYCOGEN METABOLISM

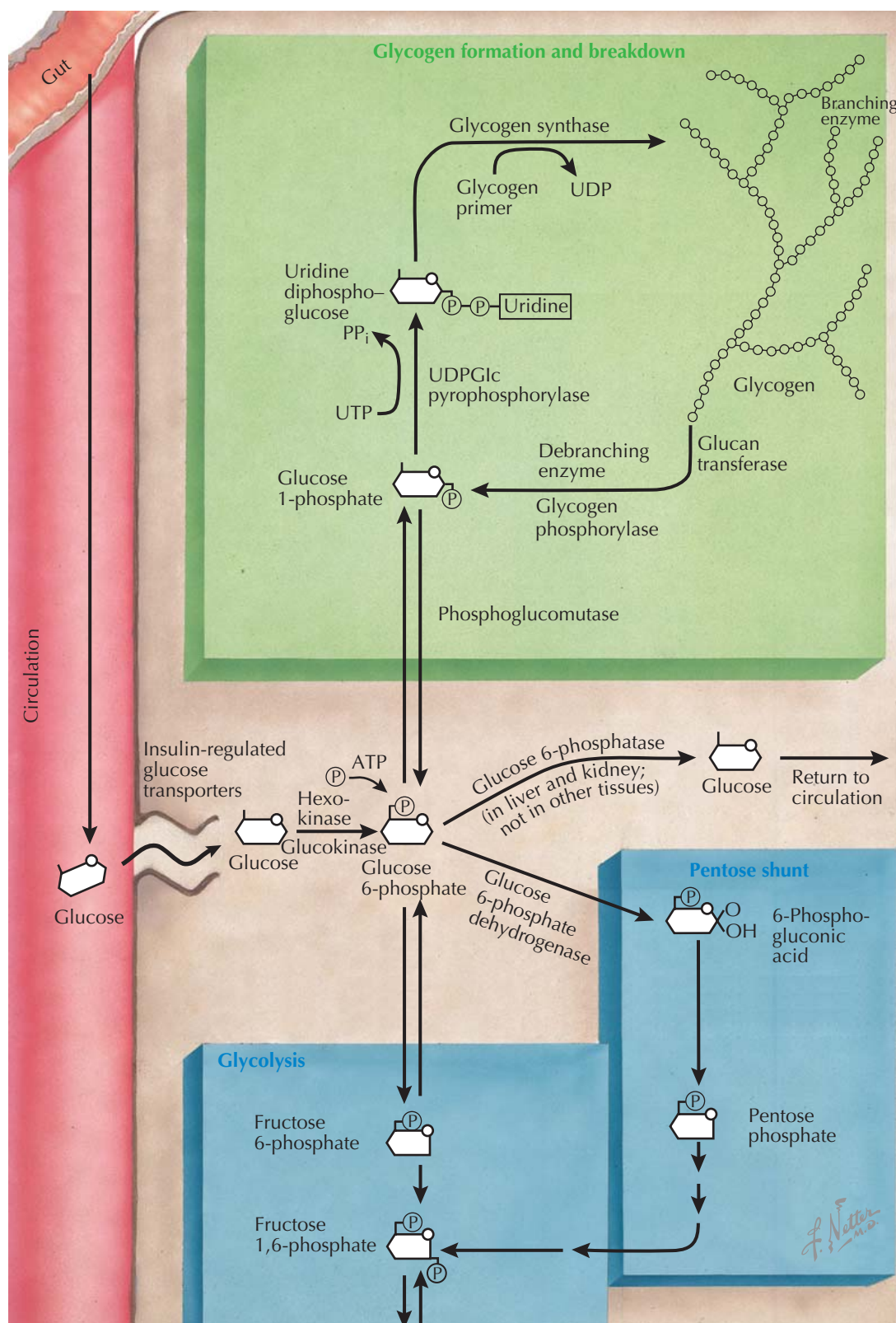
Glycogen is a branched polymer of  $\alpha$ -D-glucose and is the major depot of carbohydrates in the body, primarily in muscle and liver. Glycogen is the analog of starch, which is a less branched glucose polymer in plants.

### GLYCOGENESIS

Glycogenesis occurs mainly in the liver and muscle. Catalyzed by glucokinase in the liver and hexokinase in the muscle, glucose is phosphorylated to glucose 6-phosphate. Glucose 6-phosphate is isomerized to glucose 1-phosphate by the action of phosphoglucomutase. Glucose 1-phosphate interacts with uridine triphosphate (UTP) to form uridine diphosphate glucose (UDPGlc) and pyrophosphate in a reaction catalyzed by UDPGlc pyrophosphorylase. Glycogen synthase catalyzes the bond between C<sub>1</sub> of the glucose of UDPGlc with the C<sub>4</sub> terminal glucose residue (1→4 linkage) of glycogen and uridine diphosphate (UDP) liberated in the process. This step keeps repeating until the glycogen chain is at least 11 glucose residues long; at that point, branching enzyme transfers six or more glucose residues to a neighboring chain to form a 1→6 linkage to establish a branch point.

### GLYCOGENOLYSIS

The rate-limiting step of glycogenolysis is the cleavage of the 1→4 linkages of glycogen by glycogen phosphorylase to produce glucose 1-phosphate. This cleaving starts at the terminal glucosyl residues until 4 glucose residues remain on either side of a 1→6 linkage, at which point glucan transferase transfers a trisaccharide unit from one branch to the other to expose the 1→6 linkage. Debranching enzyme can then hydrolyze the 1→6 linkage, and further phosphorylase actions proceed to completely convert the glycogen chain to glucose 1-phosphate. The glucose 6-phosphate molecules have three possible fates: (1) transformation to glucose 1-phosphate by phosphoglucomutase and proceeding to glycogenesis; (2) hydrolyzation by glucose 6-phosphatase in the liver and kidney to produce glucose for release into the bloodstream; or (3) proceeding on to the glycolysis or the pentose phosphate (pentose shunt) pathways.



### REGULATION OF GLYCOGENESIS AND GLYCOGENOLYSIS

The rate-limiting enzymes are glycogen synthase and glycogen phosphorylase. Glycogen serves as a rapid and short-term source of glucose. The liver releases glycogen-derived glucose during fasting. After ingesting a meal containing carbohydrates, blood glucose concentrations rise and stimulate the pancreas to release insulin. Insulin-regulated glucose transporters provide

glucose to the hepatocyte. Insulin also stimulates glycogen synthase. Glucose continues to be added to the glycogen chains as long as glucose and insulin are supplied. After food digestion, blood glucose concentrations fall, and insulin release is decreased, leading to a cessation in glycogen synthesis. Approximately 4 hours after a meal, because of decreasing blood glucose levels, the pancreas begins to secrete glucagon. Glucagon and epinephrine are the main hormones that activate glycogenolysis.

## CONSEQUENCES OF INSULIN DEPRIVATION

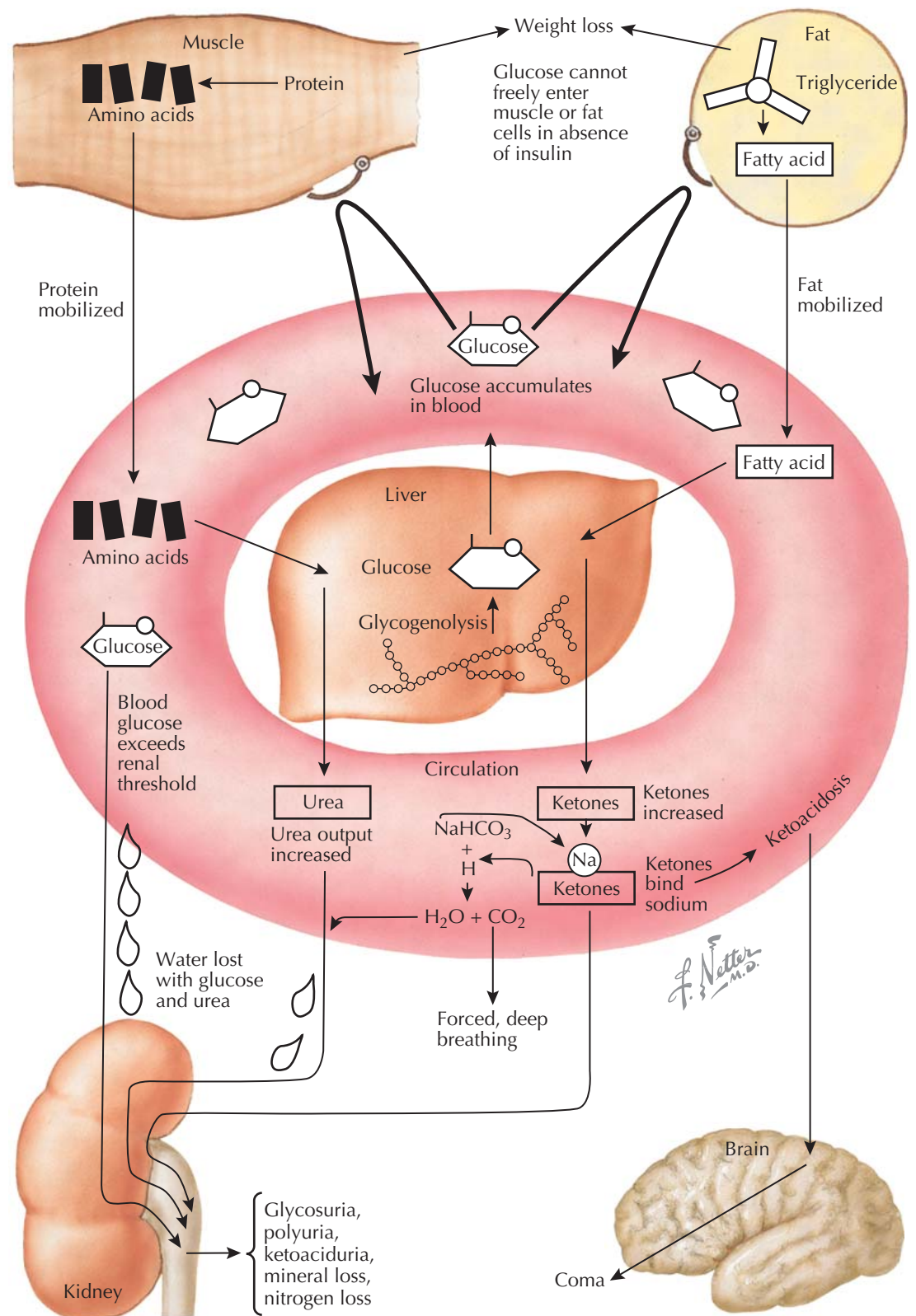
The absence of insulin is incompatible with life. Insulin deprivation can result from surgical removal (pancreatectomy) or autoimmune destruction of  $\beta$ -cells (type 1 diabetes mellitus); both lead to absence or severe curtailment of insulin production and release. In these settings, insulin-sensitive tissues (e.g., muscle, adipose tissue, liver) are deprived of insulin and its actions. Cell membranes are impermeable to hydrophilic molecules such as glucose and require a carrier system (e.g., GLUT 1, 2, 3, 4) to transport glucose across the lipid bilayer cell membrane. Because of decreased insulin-induced activation of the cell membrane glucose transporters, the transit of glucose from the blood into cells is diminished. At the same time, in the absence of insulin, glycogenesis is slowed. The suppressive effect of insulin on glucagon is removed, and glucagon enhances hepatic gluconeogenesis, which is fueled by the increased availability of precursors (e.g., glycerol and alanine) from accelerated fat and muscle breakdown. Thus, in the setting of insulin deprivation, there is impaired glucose utilization in peripheral tissues, increased glycogenolysis, and increased gluconeogenesis.

When the blood glucose concentration increases above 200 mg/dL, the renal tubules begin to exceed their capacity for glucose reabsorption (renal threshold). Excess glucose is lost in the urine (glucosuria) which, because of osmotic forces, takes water and sodium with it. Weight loss, thirst, polyuria, and hunger occur. Patients with indolent uncontrolled diabetes over months can present with wasting and cachexia similar to that seen in those with advanced malignancies.

In insulin-sensitive tissues, metabolic adjustments occur as a consequence of the curtailed glucose supply. Proteins are broken down faster than they can be synthesized; hence, amino acids are liberated from muscle, brought to the liver, and transformed to urea. The nonprotein nitrogen excreted in the urine rises and a negative nitrogen balance results.

Lipolysis is enhanced in the setting of insulin deprivation. There is a net liberation of stored fat as free fatty acids, which are used by many tissues for energy production. Hepatic uptake and metabolism of fatty acids lead to excess production of the ketones acetoacetate and  $\beta$ -hydroxybutyrate, strong organic acids that lead to ketoacidosis (see Plate 5-10). Ketones provide an alternate energy source when the utilization of glucose is impaired. The circulating  $\beta$ -hydroxybutyrate and acetoacetate obtain their sodium from  $\text{NaHCO}_3$ , thus leading to a metabolic acidosis. In addition, acetoacetate and  $\beta$ -hydroxybutyrate are excreted readily by the kidney, accompanied by base, and fixed base is lost. The severity of the metabolic acidosis depends on the rate and duration of ketoacid production.

Insulin deprivation also leads to deficits in minerals. A potassium deficit results from urinary losses with the glucose osmotic diuresis and in an effort to maintain



electroneutrality as ketoacid anions are excreted. A negative phosphate balance is a result of phosphaturia caused by hyperglycemic-induced osmotic diuresis.

The outcomes of severe insulin deprivation include negative nitrogen balance, weight loss, ketosis, and acidosis. These are the hallmarks of the most severe state of metabolic decompensation characteristic of insulin deprivation in individuals with no endogenous source of insulin (e.g., type 1 diabetes mellitus). Acidosis, when

not compensated for, exerts its major effect on brain function. In addition, acidosis affects the contractile responses of the small blood vessels throughout the body that, when coupled with osmotic diuresis-induced volume loss, results in hypotension and vascular collapse. Thus, diabetic coma and death—the fate of all those with type 1 diabetes mellitus before the advent of insulin replacement therapy—are the end result of uncompensated and untreated insulin deprivation.



## DIABETIC KETOACIDOSIS

Diabetic ketoacidosis (DKA) is a serious complication of diabetes mellitus characterized by the triad of hyperglycemia, anion gap metabolic acidosis, and ketonemia. DKA results from severe insulin deficiency with resultant hyperglycemia, excessive lipolysis, increased fatty acid oxidation, and excess ketone body production. The deficiency of insulin and the excess secretion of glucagon, catecholamines, glucocorticoids, and growth hormone stimulate glycogenolysis and gluconeogenesis while simultaneously impairing glucose disposal. DKA is primarily a complication of type 1 diabetes mellitus because it is usually only seen in the setting of severe insulin deficiency. DKA may be the initial presentation of new-onset type 1 diabetes mellitus.

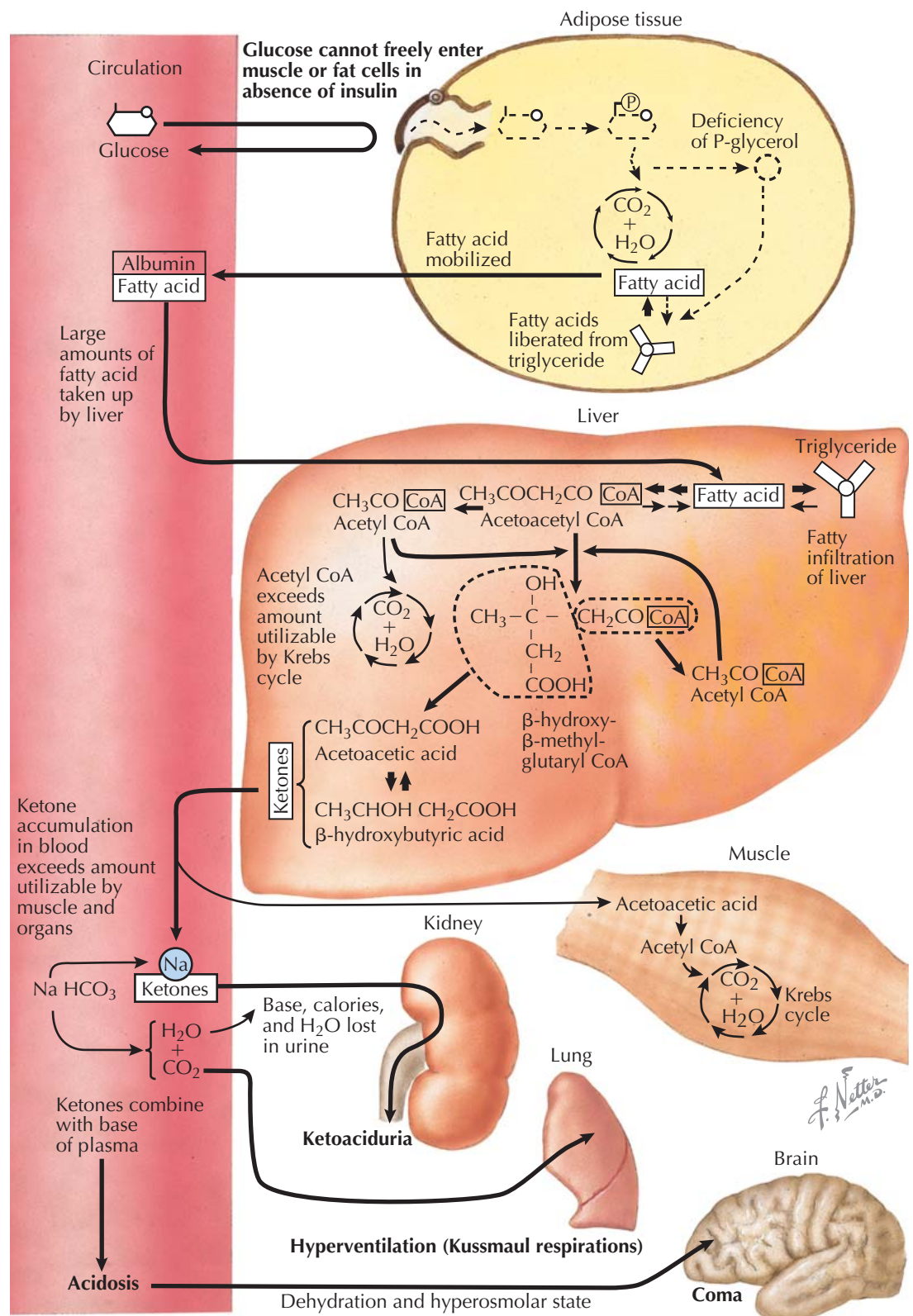
Most patients with DKA have preceding symptoms of polyuria, polydipsia, and weight loss that result from a partially compensated state. However, with absolute insulin deficiency, metabolic decompensation can intervene rapidly over 24 hours. Typical DKA presenting symptoms include nausea; emesis; abdominal pain; lethargy; and hyperventilation with slow, deep breaths (Kussmaul respirations). On physical examination, most patients with DKA have a low-normal blood pressure, increased heart rate, increased respiratory rate, signs of volume depletion (e.g., decreased skin turgor, low jugular venous pressure, and dry oral mucosa), and breath that smells of acetone (a fruity odor similar to nail polish remover). With profound dehydration, patients may be obtunded or comatose.

The laboratory profile in patients with DKA includes low serum bicarbonate ( $\text{HCO}_3^-$ ) concentration (<10 mEq/L); increased serum concentrations of ketoacids (acetoacetate,  $\beta$ -hydroxybutyrate); increased anion gap (calculated by subtracting the sum of the serum concentrations of chloride and bicarbonate from that of sodium; reference range, <14 mEq/L; DKA usually >20 mEq/L); increased serum glucose concentration (500–900 mg/dL); and decreased arterial pH (<7.3).

The differential diagnosis of DKA includes other causes of metabolic acidosis (e.g., lactic acidosis, starvation ketosis, alcoholic ketoacidosis, uremic acidosis, and toxin ingestion [e.g., salicylate intoxication]).

### TREATMENT

Keys to successful outcomes in DKA are prompt recognition and management. The three main thrusts of treatment are fluid repletion, insulin administration, and management of electrolyte abnormalities. All patients with DKA have some degree of volume contraction, which contributes to decreased renal clearance of ketone bodies and glucose. Most patients with DKA should be treated with 1 L of normal saline over the first hour followed by 200 to 500 mL per hour until volume repletion. The rate and type of volume repletion should be guided by clinical and laboratory responses. Insulin should be administered intravenously to avoid slow absorption from hypoperfused subcutaneous tissues. Insulin is usually started with a 10-U priming dose and followed by a low-dose continuous infusion (e.g., 0.1 U/kg body weight/h). Serum glucose usually decreases by 50 to 75 mg/dL per hour. As the serum glucose concentration decreases to approximately 200 mg/dL, the insulin infusion rate should be decreased so that hypoglycemia and cerebral edema are avoided (the latter can result from too rapid a



correction from the hyperosmolar state). With volume repletion, resolving acidosis, and improving blood glucose concentrations, an underlying potassium deficit usually becomes evident and should be replaced when the serum potassium concentration decreases below 5.3 mEq/L.

Most patients with DKA should be admitted to an intensive care unit setting in the hospital to facilitate close monitoring with continuous electrocardiography and hourly measurement of blood concentrations of glucose, potassium, chloride, and bicarbonate. Other

blood parameters should be monitored every 2 hours (e.g., calcium, magnesium, and phosphate). DKA can be corrected in most patients over 12 to 36 hours.

It is important to address the cause of DKA. The most common cause is noncompliance with insulin therapy in a patient with known type 1 diabetes mellitus. Underlying infection (e.g., pneumonia, meningitis, or urinary tract infection) or severe illness (e.g., myocardial infarction, cerebrovascular accident, or pancreatitis) may be a trigger for DKA in a patient with type 1 diabetes.



## ISLET CELL PATHOLOGY IN DIABETES

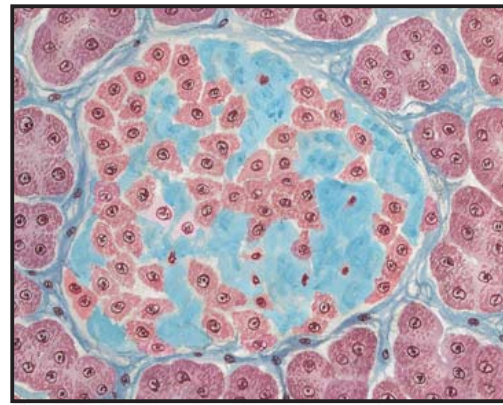
## TYPE 1 DIABETES MELLITUS

The diagnosis of diabetes mellitus is established when a patient presents with typical symptoms of hyperglycemia (polyuria, polydipsia, weight loss) and has a fasting plasma glucose concentration of 126 mg/dL or higher or a random value of 200 mg/dL or higher, which is confirmed on another occasion. There are three general types of diabetes: type 1, type 2 (see Plate 5-12), and gestational (see Plate 5-19). Type 1 diabetes mellitus affects less than 10% of all patients diagnosed with diabetes. Type 1 diabetes mellitus is the result of pancreatic  $\beta$ -cell destruction; in more than 95% of the cases, it has an autoimmune basis caused by an apparent selected loss of immune tolerance. If untreated, type 1 diabetes is a fatal catabolic disorder (see Plate 5-10). Because of absolute insulin deficiency, all persons with type 1 diabetes require insulin replacement therapy.

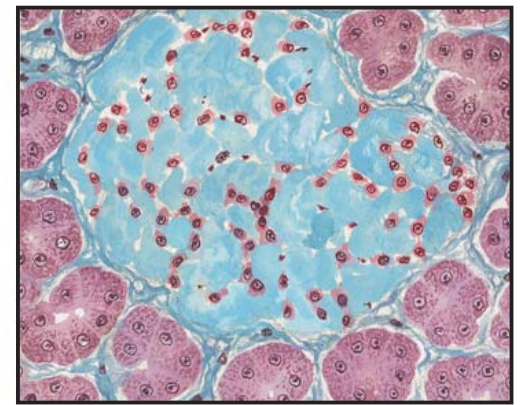
Immune-mediated type 1 diabetes is most common in northern Europe, where the approximate annual incidence is 30 per 100,000 persons. The lowest incidence of type 1 diabetes is in China (one per 100,000 persons per year). The peak life stage of onset is in children or young adults. The offspring of a mother with type 1 diabetes have a 3% risk of developing diabetes; the offspring of a father with type 1 diabetes have a 6% risk. Environmental factors (infectious or toxic environmental insult) have a major role in disease development; only 50% of identical twins of type 1 diabetic patients develop diabetes. Individuals with certain human leukocyte antigen (HLA) types are predisposed to type 1 diabetes. HLA class II molecules DQ and DR code for antigens expressed on the surface of B lymphocytes and macrophages. Approximately 95% of individuals with type 1 diabetes have HLA-DR3, HLA-DR4, or both, findings present in 50% of nondiabetic control subjects. Some DQ alleles (e.g., HLA-DQA1\*0102, HLA-DQB1\*0602) are associated with a decreased risk of diabetes. Non-HLA genes also affect susceptibility to type 1 diabetes. For example, polymorphisms in a lymphocyte-specific tyrosine phosphatase (PTN22) and in a promoter of the insulin gene are associated with an increased risk of type 1 diabetes.

The immune system mistakenly targets  $\beta$ -cell proteins that share homologies with viral or other foreign peptides, a concept termed *molecular mimicry*. Most patients with newly diagnosed type 1 diabetes have circulating antibodies (islet cell antibody, antibody to glutamic acid decarboxylase [GAD], antibody to tyrosine phosphatases [insulinoma-associated protein 2], cation efflux zinc transporter, or insulin autoantibody). GAD is an enzyme in pancreatic  $\beta$ -cells that has homology to coxsackievirus B.

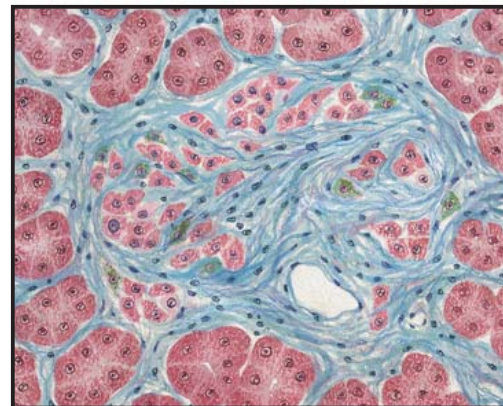
The autoimmune destruction of  $\beta$ -cells progresses over months and years, during which time affected individuals are euglycemic and asymptomatic (termed the *latent period*). Impaired glucose tolerance usually precedes the onset of overt diabetes. By the time patients come to clinical attention, they have lost more than 90% of their  $\beta$ -cell mass. The progressive hyperglycemia has a toxic effect on the remaining islets with increased rate of apoptosis and impaired insulin secretion. These toxic hyperglycemic effects can be reversed over the short term with exogenous insulin treatment; the pancreas seems to recover for a period of time,



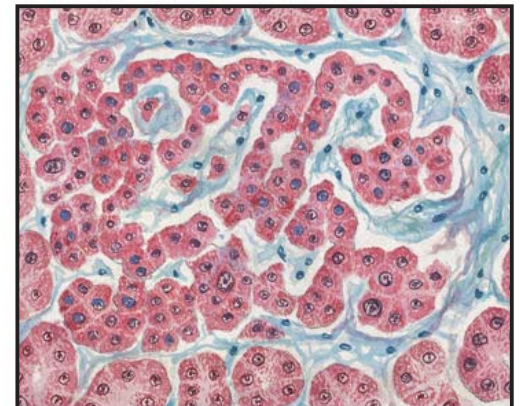
Partial hyalinization  
(Mallory aniline blue stain)



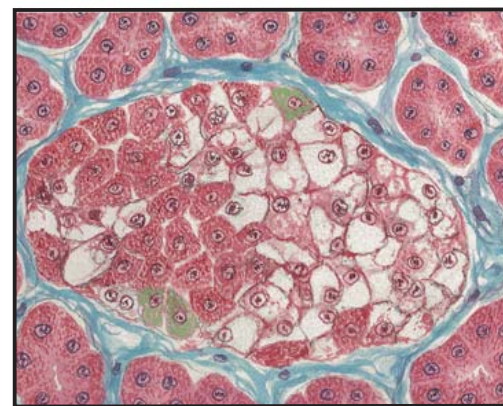
Complete hyalinization  
(Mallory aniline blue stain)



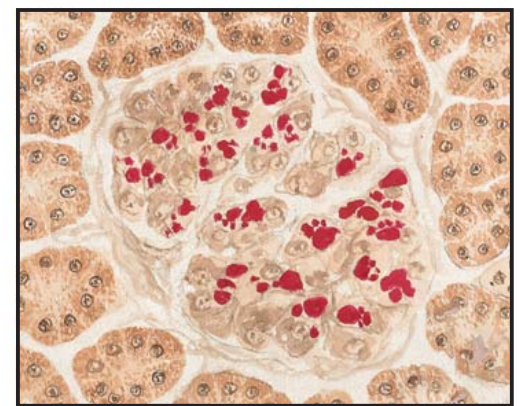
Fibrosis  
(Mallory aniline blue stain)



Cordlike formation  
(Mallory aniline blue stain)



Hydropic change (vacuolization)  
(Gomori aldehyde fuchsin and Ponceau stain)



Glycogen demonstrated in vacuoles  
by periodic acid-Schiff reagent

*F. Netter M.D.*

termed the *honeymoon period*. Eventually, the viability of the remaining  $\beta$ -cells is exhausted.

Histopathology studies from the 1960s showed that hydropic changes (vacuolization) were the initial step in islet destruction. This change was actually attributable to infiltration with glycogen as shown with periodic acid-Schiff reagent. There is a selective destruction of  $\beta$ -cells. At the time of clinical presentation, a chronic inflammatory infiltrate of the islets is present (insulinitis). The inflammatory infiltrate consists primarily of T lymphocytes (CD8 cells outnumber CD4 cells). Eventually, the islets become hyalinized, a process that partially or completely replaces an islet.

## CLINICAL PRESENTATION

Sustained hyperglycemia that exceeds the renal threshold for glucose reabsorption causes an osmotic diuresis, resulting in polyuria and polydipsia. The hyperosmolar state may also cause blurred vision caused by osmolar impact on lens and retina. Weight loss is caused by depletion of water, glycogen, fat, and muscle. Volume depletion may cause postural lightheadedness. Paresthesias are a result of neurotoxicity from sustained hyperglycemia. As insulin deficiency becomes nearly complete, the signs and symptoms of diabetic ketoacidosis predominate (see Plate 5-10).



## TYPE 2 DIABETES MELLITUS

The diagnosis of diabetes mellitus is established when a patient presents with typical symptoms of hyperglycemia (polyuria, polydipsia, weight loss) and has a fasting plasma glucose concentration of 126 mg/dL or higher or a random value of 200 mg/dL or higher confirmed on another occasion. In asymptomatic individuals, the finding of fasting plasma glucose concentrations higher than 126 mg/dL on more than one occasion is diagnostic of diabetes. Individuals with fasting glucose levels from 100 to 125 mg/dL are considered to have impaired fasting glucose. Individuals with plasma glucose concentrations at or above 140 mg/dL, but not over 200 mg/dL, 2 hours after a 75-g oral glucose load are considered to have impaired glucose tolerance.

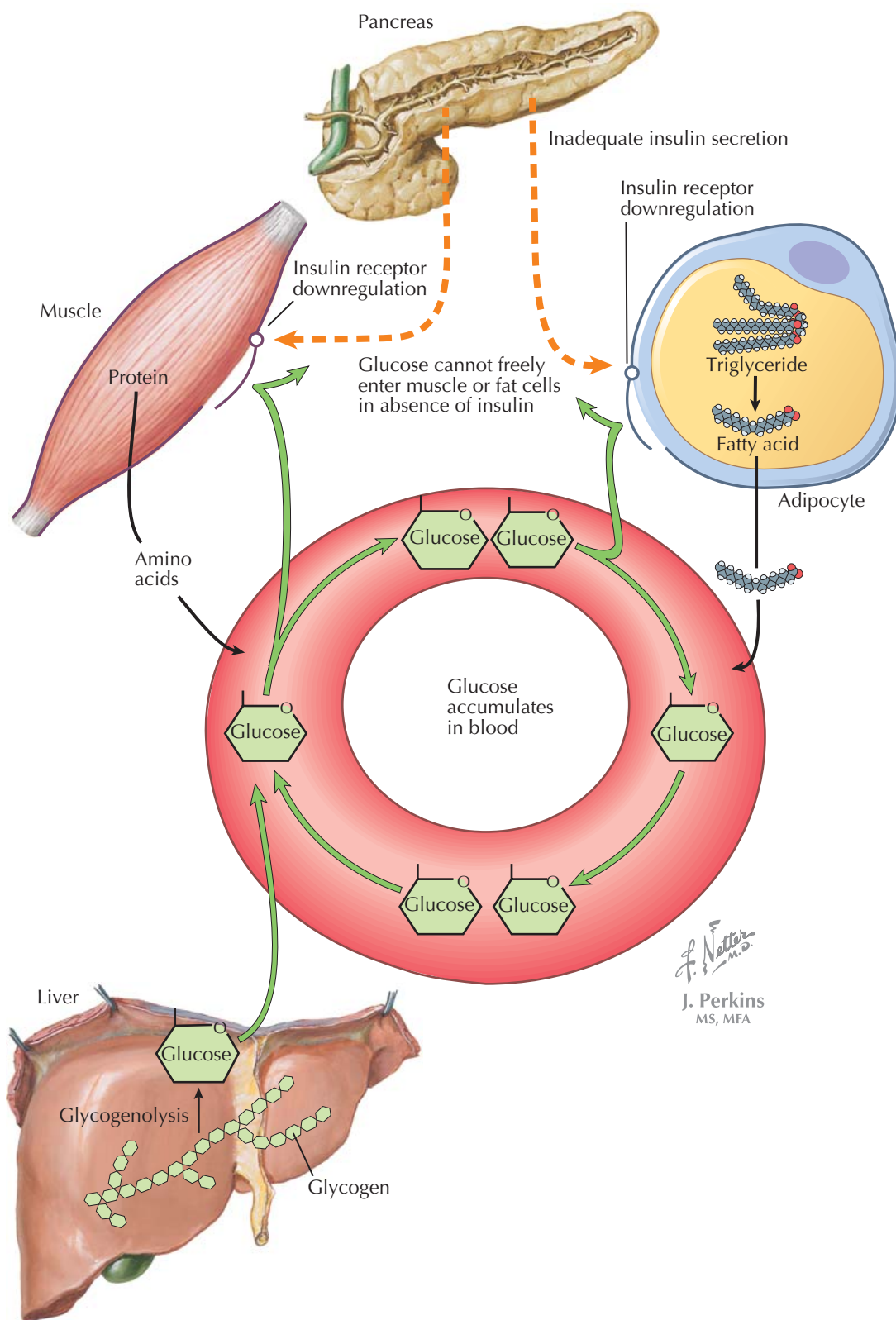
There are three general types of diabetes—type 1 (see Plate 5-11), type 2, and gestational (see Plate 5-19). Type 2 diabetes mellitus accounts for more than 90% of patients diagnosed with diabetes. Unlike type 1 diabetes, in which the individual has an absolute insulin deficiency, individuals with type 2 diabetes have a relative insulin deficiency in part because of a resistance to insulin action. Most patients with type 2 diabetes are obese and are diagnosed after the age of 30 years.

Insulin resistance in patients with type 2 diabetes is related to polygenic factors, abdominal visceral obesity, sedentary lifestyle, and aging. Approximately 40% of patients with type 2 diabetes have a least one parent with the disorder. The concordance of type 2 diabetes in monozygotic twins is 90%. Although many genetic factors are yet to be discovered, several common genetic polymorphisms increase the risk for type 2 diabetes. The basic pathogenesis of type 2 diabetes is inadequate pancreatic  $\beta$ -cell insulin secretory response for the prevailing blood glucose concentration. Sustained hyperglycemia magnifies the underlying insulin resistance and  $\beta$ -cell dysfunction, both of which improve with treatment and improved glycemic control. The impaired insulin secretion in patients with type 2 diabetes is multifactorial but is partly attributable to decreased  $\beta$ -cell mass associated with increased  $\beta$ -cell apoptosis.

Obesity (body mass index [BMI]  $>30$  kg/m<sup>2</sup>) is present in 80% of individuals with type 2 diabetes that are of European, North American, or African descent. Only 30% of individuals with type 2 diabetes of Japanese and Chinese descent are obese. The combination of abdominal obesity, hyperglycemia, hyperinsulinemia, dyslipidemia, and hypertension has been referred to as the *metabolic syndrome* (see Plate 7-15). Abdominal obesity aggravates insulin resistance that results in hyperglycemia leading to further hyperinsulinemia. Type 2 diabetes occurs when the hyperinsulinemia is insufficient to correct the hyperglycemia.

Diffuse damage to more than 70% of the pancreas can cause diabetes. Examples of such insults include pancreatitis, trauma, pancreatic carcinoma, hemochromatosis, and partial pancreatectomy. Excess production of the four insulin counterregulatory hormones can also cause diabetes. For example, diabetes may be the initial presentation of the following endocrine disorders: pheochromocytoma (catecholamines), acromegaly (growth hormone), glucagonoma (glucagon), and Cushing syndrome (glucocorticoids). Patients with thyrotoxicosis or somatostatinomas may also have diabetes. The hyperglycemia in patients with these endocrinopathies typically is cured by effective treatment of the underlying disorder.

Approximately 5% of individuals with type 2 diabetes have a monogenic disorder, maturity-onset diabetes of



the young (MODY), resulting in a defect in glucose-induced insulin release. These individuals are usually not obese and are diagnosed with diabetes in late childhood or as young adults. Six types of autosomal dominant MODY have been described. MODY 2 is caused by impaired conversion of glucose to glucose 6-phosphate in the  $\beta$ -cell because of a mutation in the gene encoding the glucokinase enzyme. Glucokinase serves as a glucose sensor in the  $\beta$ -cell. The other forms of MODY are caused by mutations of genes that encode transcription factors that regulate  $\beta$ -cell gene

expression. For example, MODY 3 (the most common form of MODY) and MODY 1 are caused by mutations in the gene that encodes hepatocyte nuclear factor 1 $\alpha$  (HNF-1 $\alpha$ ) and HNF-4 $\alpha$ , respectively. MODY 4 is caused by mutations in insulin promoter factor-1 (IPF-1), which mediates insulin gene transcription and regulates other  $\beta$ -cell genes (e.g., glucokinase and glucose transporter 2). MODY 5 is caused by mutations in the gene encoding HNF-1 $\beta$ , and MODY 6 is caused by mutations in the gene encoding islet transcription factor neuroD1.

## DIABETIC RETINOPATHY

Diabetic retinopathy, a microvascular complication of chronic hyperglycemia, causes a 25-fold increased incidence of blindness in patients with diabetes compared with the general population. Vision loss is caused by retinal hemorrhage, macular edema, retinal detachment, or neovascular glaucoma. Patients with both type 1 and type 2 diabetes are at risk of developing diabetic retinopathy. Nearly all patients with type 1 diabetes and more than 50% of patients with type 2 diabetes develop some degree of retinopathy within 20 years of their diagnosis.

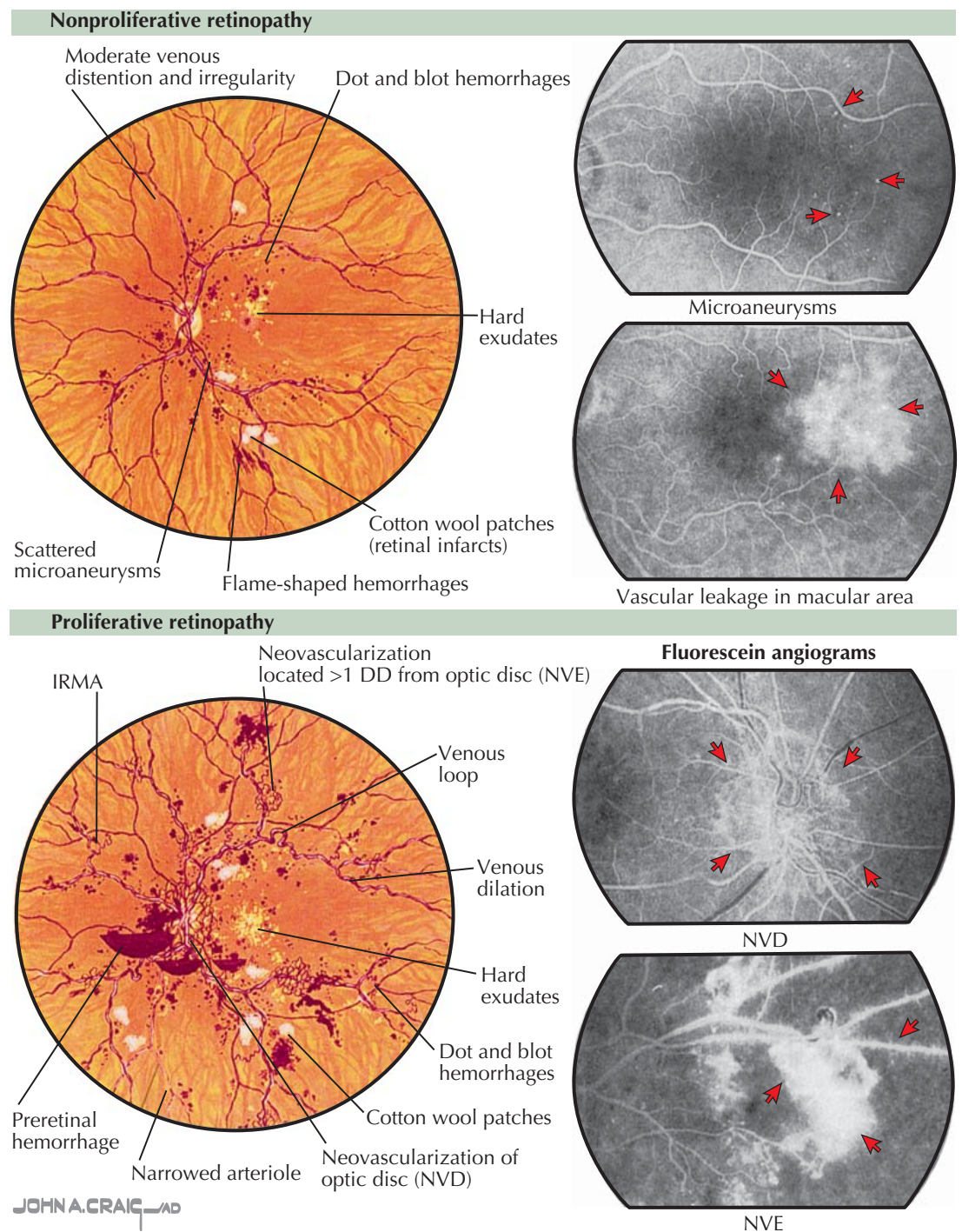
The pathogenesis of diabetic retinopathy is complex and related to abnormal retinal vessel permeability and vascular occlusion with ischemia. The retina is exquisitely sensitive to both ischemia and substrate imbalance. Chronic hyperglycemia causes impaired autoregulation of retinal blood flow, accumulation of advanced glycosylation end products, and accumulation of retinal cell sorbitol. Normally, retinal blood flow is tightly autoregulated. For example, retinal blood flow does not change in normal individuals unless the mean arterial blood pressure is raised more than 40%. Hyperglycemia impairs this autoregulation, and retinal blood flow increases lead to increased shear stress, vascular leakage, and extracellular fluid accumulation. Retinal pericytes and microvascular cells become damaged and dysfunctional. Microaneurysms are saccular outpouchings that appear in retinal vessels at sites of retinal pericyte loss. Microthrombosis and occlusion of retinal capillaries lead to retinal ischemia and capillary leakage. Retinal ischemia triggers the release of vascular growth factors (e.g., vascular endothelial growth factor, platelet-derived growth factor, fibroblast growth factor, erythropoietin, and insulinlike growth factor 1). These growth factors promote the development of new blood vessels (neovascularization) in an attempt to revascularize ischemic retina. The two major forms of diabetic retinopathy are nonproliferative and proliferative.

### NONPROLIFERATIVE DIABETIC RETINOPATHY

Nonproliferative diabetic retinopathy (NPDR) is associated with the findings of microvascular abnormalities (e.g., dilated retinal veins, occluded vessels with resultant dot-and-blot hemorrhages, and microaneurysms), nerve fiber layer retinal infarcts (cotton-wool patches), intraretinal hemorrhages, macular edema, and hard exudates (leakage of lipid and proteinaceous material). The macular edema in patients with NPDR is responsible for vision loss. The severity of NPDR predicts the risk of progressing to proliferative retinopathy. For example, although the 1-year risk of progression to proliferative retinopathy for patients with mild NPDR is 5%, the risk is 75% for those with very severe NPDR.

### PROLIFERATIVE DIABETIC RETINOPATHY

Proliferative diabetic retinopathy (PDR) is distinguished from NPDR by the presence of neovascularization that arises from retinal vessels or the optic disc. The neovascularization leads to acute vision loss caused by hemorrhage (preretinal and vitreous), fibrosis, and traction retinal detachment (see Plate 5-14). PDR usually arises from a background of NPDR. Arteriolar narrowing is usually evident on the fundus examination. The ischemia-induced release of vascular growth



factors triggers the development of new vessels from adjacent retinal vessels. The intraluminal proliferation of cells results in vascular occlusion and rupture, resulting in the appearance of flame-shaped (occur in inner retina closer to the vitreous) and dot-and-blot hemorrhages (occur deeper in the retina) proximal to the occlusion and intraretinal infarcts (cotton-wool patches) distal to the occlusion. In the early stages of PDR, the new vessels can be seen as fine loops, and existing veins may become tortuous and beaded and develop loops. As PDR progresses, there is marked neovascularization covering more than 50% of the optic disc and an increased risk for preretinal and vitreous hemorrhage. If severe PDR is not treated, there is a 60% risk of progression to vision loss over 5 years. The findings of PDR are evident on the fundus examination. Intravenously administered fluorescein dye (fluorescein angiography) can assess areas of capillary under perfusion

and leakage from sites of neovascularization. Neovascularization at the disc (NVD) refers to neovascularization occurring at or within 1500  $\mu\text{m}$  (or  $\leq 1$  disc diameter [DD]) of the optic disc. Neovascularization elsewhere (NVE) refers to neovascularization that is located more than 1500  $\mu\text{m}$  (or  $>1$  DD) away from the optic disc.

### MACULAR EDEMA

Macular edema is retinal thickening and edema involving the macula, and it may complicate PDR or NPDR. Macular edema is the most common cause of vision loss from diabetes and can be diagnosed by stereoscopic fundus examination or fluorescein angiography. It is termed *clinically significant macular edema* when the thickening in the macular region is of sufficient extent and location to threaten central visual function.



## COMPLICATIONS OF PROLIFERATIVE DIABETIC RETINOPATHY

Proliferative diabetic retinopathy (PDR) is associated with neovascularization that arises from retinal vessels or the optic disc. As PDR progresses, the marked neovascularization increases the risk for preretinal and vitreous hemorrhage. Severe PDR leads to acute vision loss caused by hemorrhage (preretinal and vitreous), fibrosis, and traction retinal detachment. If severe PDR is not treated, there is a 60% risk of progression to vision loss over 5 years. Puberty and pregnancy can accelerate retinopathy progression.

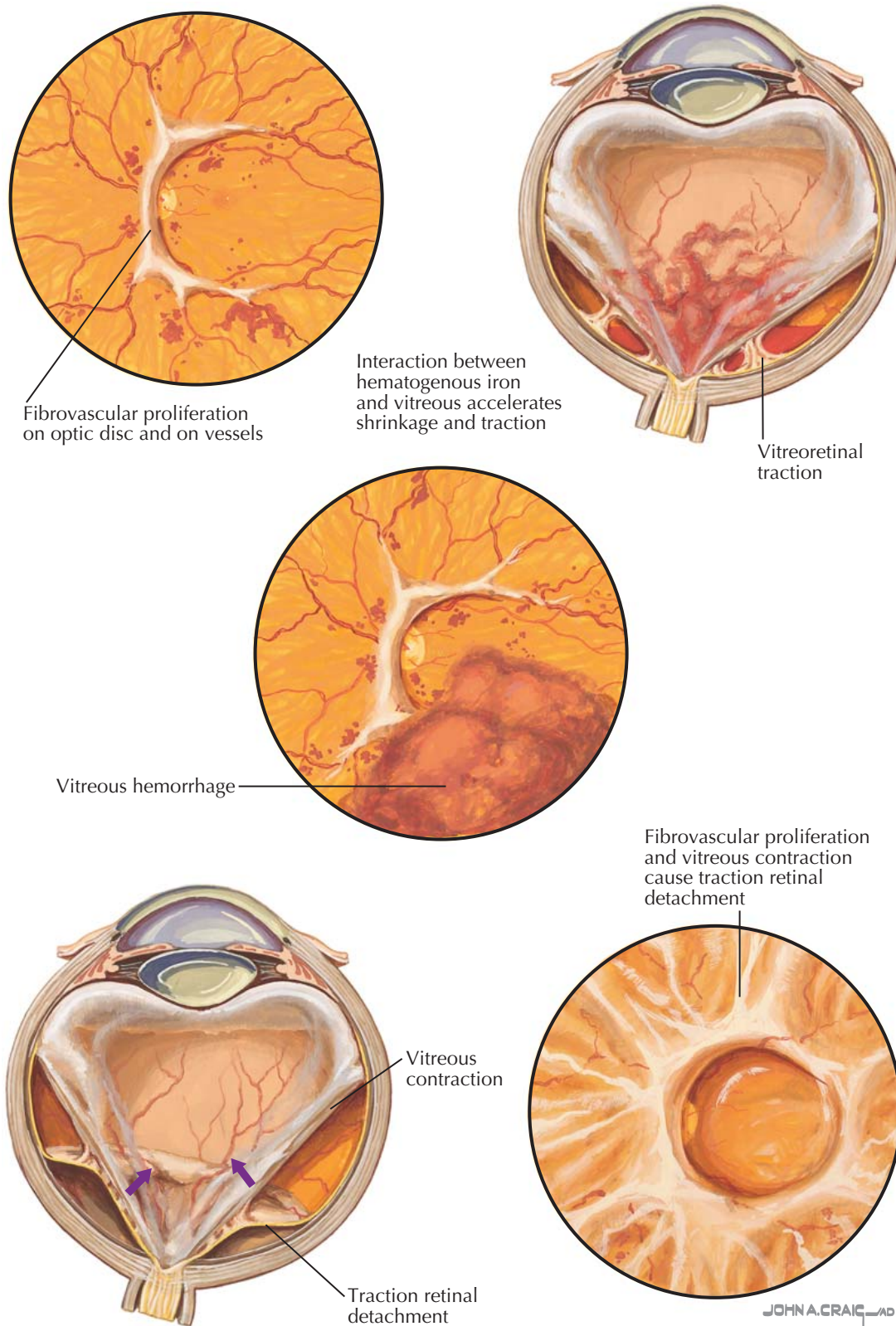
Diabetic retinopathy (DR) is usually asymptomatic until the late stages. Symptoms include decreased visual acuity related to macular edema, a “curtain falling” sensation with a vitreous hemorrhage, and floaters during the resolution phase of vitreous bleeds. Eye-directed therapy decreases the rate of disease progression. Thus, annual screening for DR is important so that preventative therapy can be instituted. A comprehensive eye examination with slit-lamp biomicroscopy combined with indirect ophthalmoscopy on dilated fundi by an experienced ophthalmologist and seven-field digital stereoscopic retinal photography are standard screening methods. Eye examinations should be done more frequently during pregnancy.

The newly recruited vessels of neovascularization initially grow along the plane of the retina. However, as the vitreous gradually pulls away and detaches from the retina, the new vessels extend into the vitreous cavity. These aberrant vessels are fragile and at high risk for rupture with resultant vitreous hemorrhage. The neovascularization process can also lead to a fibrovascular proliferation that can distort the retina and predispose to retinal detachment.

Before the advent of tight glycemic control, studies showed that the prevalence of DR increased progressively in patients with increasing duration of diabetes; DR would start within 3 to 5 years of the diagnosis of type 1 diabetes. Subsequent studies documented that improved glycemic control dramatically decreased the development and progression of DR. Thus, the first steps in treatment should be to prevent the development of DR or to prevent progression of existing DR by maximizing efforts at good glycemic control. In addition, if hypertension is present, treatment should be targeted for average blood pressure less than 130/80 mm Hg.

In patients with established PDR, the treatment goals are to preserve vision, repair high-risk lesions, and reduce the rate of progression. Panretinal (scatter) laser photocoagulation is the primary treatment for patients with severe PDR. Administering approximately 1200 to 1800 laser burns (in grid that targets peripheral retinal tissue and avoids large vessels and the optic disc) per eye over two to three sessions decreases the risk of severe vision loss by 50%. Panretinal laser treatment decreases viable hypoxic growth factor-generating cells, increases oxygen delivery to the inner retina, and increases relative perfusion to viable retina.

Focal laser photocoagulation is the optimal treatment for clinically significant macular edema. Laser treatment is directed at microaneurysms and the



microvascular lesions around hard exudates, avoiding the fovea region.

Vitreous hemorrhage results from rupture of fragile new vessels or from contraction of the fibrovascular proliferation that causes avulsion of retinal vessels. Whereas blood that collects behind the detached posterior vitreous face is absorbed over many weeks, blood in the vitreous itself can turn white and is absorbed much more slowly. This opaque vitreous humor can be surgically removed.

Vitreous contraction also predisposes to traction retinal detachment, which leads to vision loss when the fovea or the macula is involved. Surgical vitrectomy can relieve vitreous traction.

Pharmacologic approaches for treating PDR are under investigation. Candidate agents include intravitreal administration of vascular endothelial growth factor inhibitors.



## DIABETIC NEPHROPATHY

Diabetic nephropathy is a major cause of morbidity and mortality in patients with type 1 or type 2 diabetes mellitus. Diabetic nephropathy is characterized as the triad of proteinuria, hypertension, and renal impairment. Approximately 40% of patients with type 1 diabetes and 20% of patients with type 2 diabetes develop some degree of diabetic nephropathy. Diabetes is the single most common cause of end-stage renal disease (ESRD).

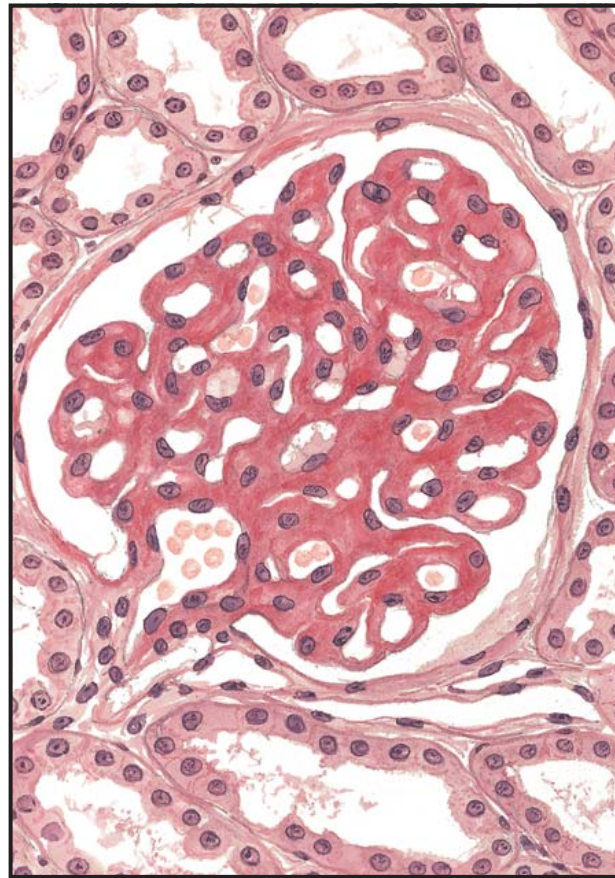
Diabetic nephropathy can be considered in five stages or phases. The initial phase of diabetic nephropathy is hyperfiltration with increased capillary glomerular pressure and elevated glomerular filtration rate (GFR) (e.g., >150 mL/min). The glomerular hyperfiltration is associated with glomerular hypertrophy and increased renal size. The second stage is termed the *silent stage*. In this stage, although the GFR is normal and there is no proteinuria, glomerular basement membrane thickening and mesangial expansion are occurring. The third stage is termed *incipient nephropathy*, during which the urinary albumin excretion rate becomes abnormal (e.g., 30–300 mg/24 hr). Also at this stage, systemic hypertension may become evident. The fourth stage of diabetic nephropathy is the *overt nephropathy* or *macroalbuminuria* stage. In this stage, the 24-hour urinary albumin excretion is more than 300 mg, and creatinine levels in the blood rise. The majority of patients at this stage have systemic hypertension. Untreated hypertension can accelerate the decline in GFR, which in turn accelerates systemic hypertension. The fifth and final stage is *uremia*, the effective treatment of which requires renal replacement therapy.

As with diabetic retinopathy, the pathogenesis of diabetic nephropathy is complex and related to a hyperglycemia-triggered cascade of mechanisms. Chronic hyperglycemia causes impaired autoregulation of renal blood flow with intraglomerular hypertension, accumulation of advanced glycosylation end products, generation of mitochondrial reactive oxygen species, activation of protein kinase C, and accumulation of sorbitol. Improved glycemic control in patients with diabetes can slow the development of nephropathy.

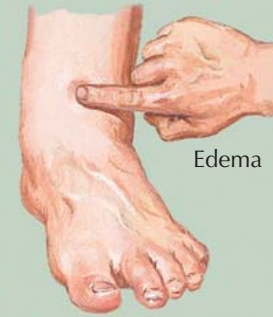
Glomerular basement membrane thickening and mesangial expansion are prominent glomerular abnormalities in diabetes that progress to nodular (Kimmelstiel-Wilson lesion) or diffuse glomerulosclerosis. Nodular glomerulosclerosis is associated with hyaline deposits in the glomerular arterioles. A diabetic tubulopathy can also develop and may result in a type IV renal tubular acidosis with hyperkalemia and hyperchloremic metabolic acidosis, an outcome associated with hyporeninemic hypoaldosteronism.

The cornerstones of treatment for diabetic nephropathy are optimizing glycemic control and hypertension management. Decreases in glycosylated hemoglobin are associated with a decreased risk of development of microalbuminuria and decreased rate of progression through the stages of diabetic nephropathy. Angiotensin-converting enzyme (ACE) inhibitors and angiotensin receptor blockers (ARBs) are the antihypertensive drug classes of choice because these agents appear to have renoprotective effects that exceed their antihypertensive effects. ACE inhibitors and ARBs decrease urinary albumin excretion by more than 30% and retard the progression from microalbuminuria to overt proteinuria. In addition, exposure to agents that have adverse effects on blood pressure or renal function should be avoided. For example, nonsteroidal

### GLOMERULOSCLEROSIS



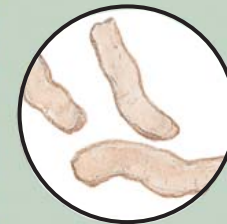#### Diffuse glomerulosclerosis



Edema

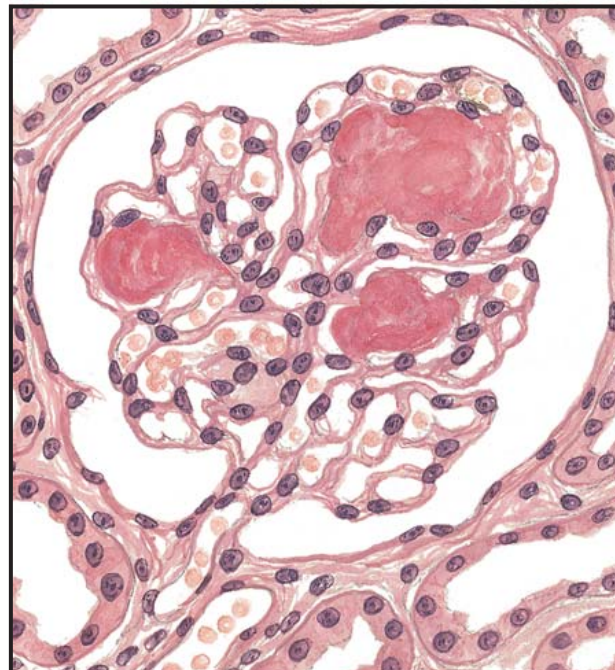


Albuminuria



Waxy casts

May cause nephrotic syndrome and/or renal failure, with or without hypertension



#### Nodular glomerulosclerosis

This nodular component (Kimmelstiel-Wilson nodules) associated with hyaline deposits in the glomerular arterioles is pathognomonic for diabetic nephropathy

*F. Netter M.D.*

antiinflammatory drugs and cyclo-oxygenase-2 inhibitors should be avoided because of their adverse impact on hypertension. In addition, radiographic contrast dye should be avoided because of its adverse impact on renal function and risk for acute renal failure.

Progressive diabetic nephropathy may result in severe proteinuria and associated symptoms that are referred to as the *nephrotic syndrome*. Nephrotic syndrome is defined by urinary protein excretion of more

than 3.5 g/1.73 m<sup>2</sup> per 24 hours, hypoalbuminemia (serum albumin concentration <3 g/dL), and peripheral edema. Microscopic examination of the urine sediment may show waxy casts (degenerated cellular casts of collecting tubules), which are found in patients with severe chronic renal disease. For patients who progress to ESRD, renal replacement options include hemodialysis, peritoneal dialysis, renal transplantation, and combined pancreas–kidney transplantation.



## DIABETIC NEUROPATHY

Approximately 50% of those with diabetes of more than 25 years' duration develop symptomatic diabetic neuropathy. Diabetic neuropathy is not a single disorder, but rather multiple disorders depending on the types of nerve fibers involved.

### FOCAL NEUROPATHIES

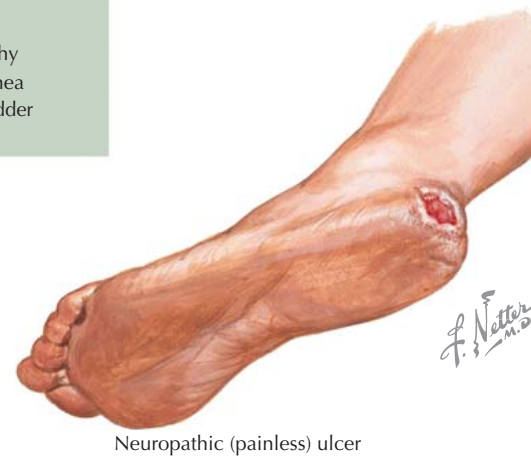
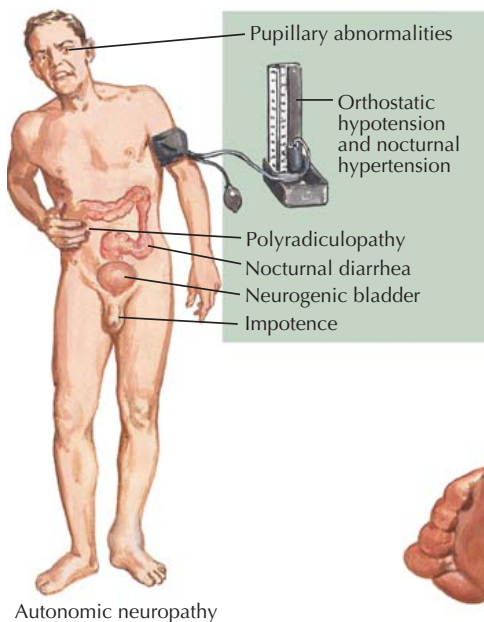
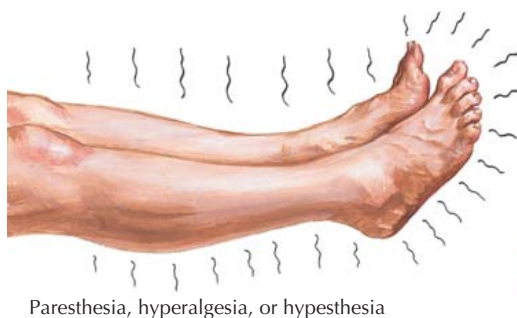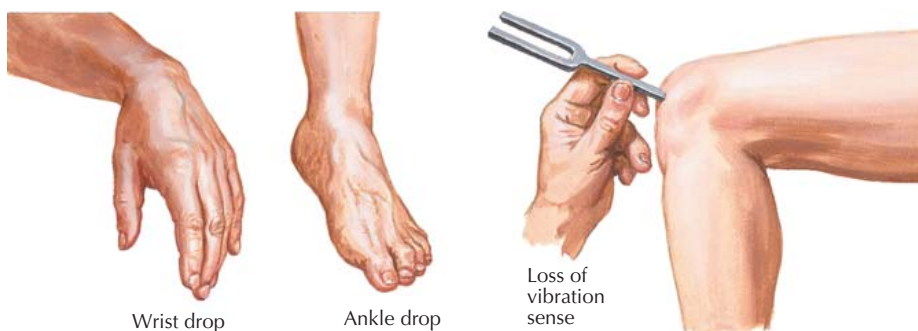
In general, mononeuropathies occur in older patients with diabetes. Mononeuropathies are a result of vascular obstruction and are typically acute in onset, associated with pain and motor weakness, and self-limited (most resolve over 2 months). Nerves that are commonly involved include cranial nerves III, VI, and VII; the ulnar nerve; and the peroneal nerve. Patients may present with wrist drop or ankle drop. With third cranial nerve involvement, patients complain of diplopia, and examination shows ptosis and ophthalmoplegia. Diabetic polyradiculopathy is characterized by severe pain in the distribution of one or more nerve roots and may be accompanied by motor weakness. For example, intercostal or truncal radiculopathy presents with pain over the thorax or abdomen. Diabetic polyradiculopathy is usually self-limited and resolves over 1 year.

### PROXIMAL MOTOR NEUROPATHIES

Proximal motor neuropathies (also known as diabetic amyotrophy, proximal neuropathy, femoral neuropathy, diabetic neuropathic cachexia, and Ellenberg cachexia) affect primarily older patients with type 2 diabetes. Symptoms usually start with thigh and pelvic girdle pains that progress to marked atrophy of the quadriceps muscles. Patients present with symptoms caused by lower extremity proximal muscle weakness (e.g., must use arms to assist them when rising from a chair). The signs and symptoms may start unilaterally but usually progress to bilateral involvement. Pain may be a predominant component of the clinical presentation, and profound weight loss and depression are common. Axonal loss is the primary pathophysiologic process, and electromyography shows lumbosacral plexopathy. Most of these patients prove to have chronic inflammatory demyelinating polyneuropathy, monoclonal gammopathy, ganglioside antibody syndrome, or an inflammatory vasculitis.

### DISTAL SYMMETRIC POLYNEUROPATHY

Distal symmetric polyneuropathy (DSPN) is the most common form of diabetic neuropathy. The onset of DSPN is usually slow and involves small and/or large fibers of either sensory and/or motor nerves. Small fiber neuropathy usually manifests as paresthesia, hyperalgesia (increased pain response to a normally painful stimulus), allodynia (pain response from a stimulus that is not normally painful), or hypesthesia involving the feet and lower extremities. The pain is usually described as burning. The paresthesias are described as pins and needles, numbness, tingling, cold, or burning. Physical examination usually reveals reduced pinprick and light touch sensations and loss of thermal sensitivity. An acute painful small fiber neuropathy may develop with the initiation of therapy to improve glycemic control.



Large-fiber neuropathies involve the myelinated and rapidly conducting sensory or motor nerves that are normally responsible for vibration perception, cold thermal perception, position sense, and motor function. Typical initial symptoms include a sensation of walking on pebbles or cotton, inability to discriminate among coins, and trouble turning pages of a book. Large-fiber neuropathies are easily detected on physical examination (e.g., loss of vibration sense, loss of proprioception, loss of deep tendon reflexes). There may be wasting of the small muscles in the feet and hands.

Usually DSPN presents with signs and symptoms of both small- and large-fiber nerve damage. The longer nerves are especially vulnerable, and most patients have a stocking-and-glove type sensory loss that may spread proximally. Neuropathic foot ulcers and Charcot's arthropathy (neurogenic arthropathy) can result from loss of proprioception, pain, and temperature perceptions (see Plate 5-18).

### AUTONOMIC NEUROPATHY

Dysfunction of the sympathetic and parasympathetic nervous systems has the potential to cause malfunction of almost all body systems. Examples of organ systems that may be affected by autonomic neuropathy include pupillary abnormalities with Argyll-Robertson-type pupil and decreased diameter of dark-adapted pupil; cardiovascular system with orthostatic hypotension, nocturnal hypertension, resting tachycardia, silent myocardial infarction, and heat and exercise intolerance; genitourinary system with erectile dysfunction, retrograde ejaculation, and neurogenic bladder with urinary retention; gastrointestinal system with gastroparesis, constipation, nocturnal diarrhea, and fecal incontinence; sweating disturbances with gustatory sweating, hyperhidrosis, and anhidrosis; and blunted adrenomedullary response to hypoglycemia, leading to hypoglycemic unawareness.



## ATHEROSCLEROSIS IN DIABETES

The type of macrovascular disease in patients with diabetes mellitus is similar to that in individuals without diabetes. However, the vascular disease is more extensive and rapidly progressive in the setting of diabetes, even when adjustments are made for other risk factors that are more prevalent in people with diabetes (e.g., hypertension and dyslipidemia). Glycosylated hemoglobin has been shown to be an independent risk factor for macrovascular disease. Thus, diabetes should be considered a coronary heart disease (CHD) risk equivalent when assessing cardiovascular risk and designing treatment programs for hyperlipidemia (see Plate 7-5).

After adjusting for all known cardiovascular risk factors, insulin resistance is an independent risk factor for macrovascular disease. Insulin resistance at the adipocyte leads to increased free fatty acid release that stimulates hepatic very low-density lipoprotein (VLDL) secretion, which in turn leads to proatherogenic dyslipidemia, defined as low serum concentration of high-density lipoprotein (HDL) cholesterol, high serum concentration of VLDL, and high serum concentration of small dense low-density lipoprotein (LDL) cholesterol. Small dense LDL cholesterol is more efficient at penetrating the blood vessel wall to prompt the atherogenic process (see Plates 7-12 and 7-13).

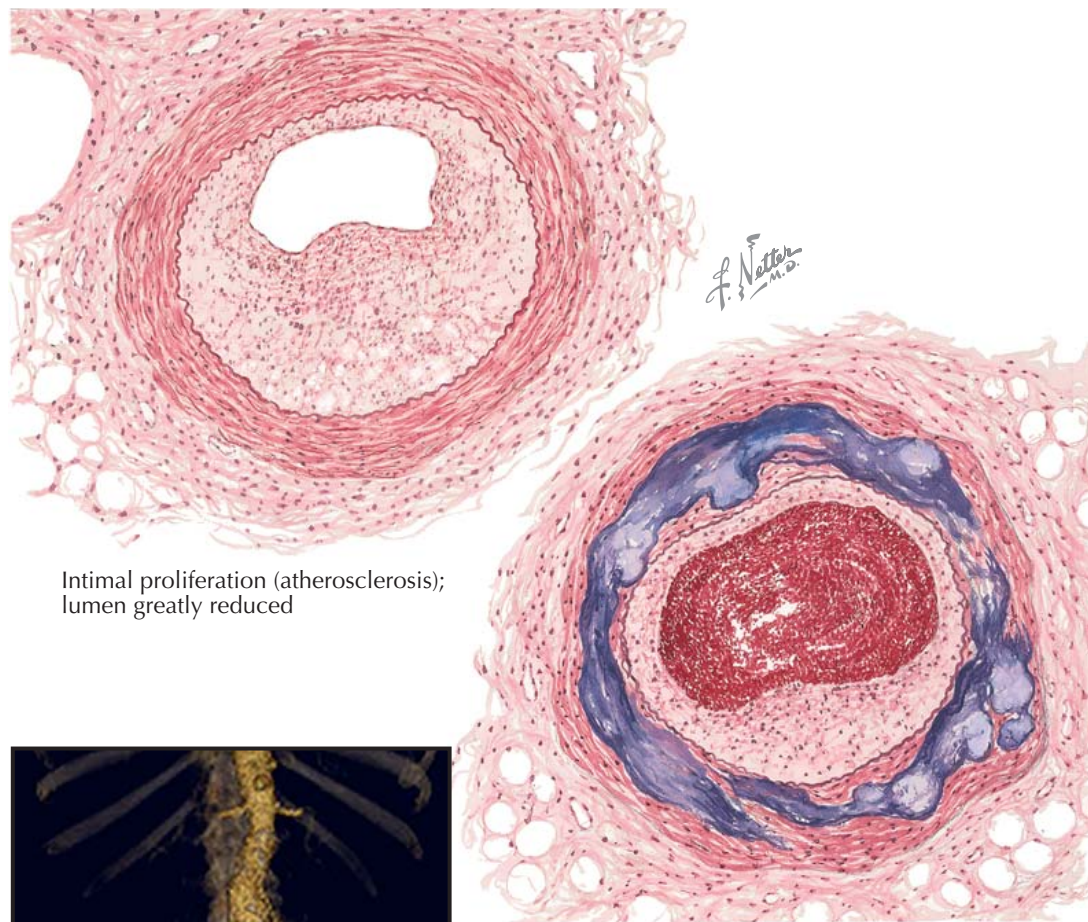
Insulin itself has proatherogenic properties. Insulin and hyperglycemia potentiate the effects of platelet-derived growth factor on vascular smooth muscle cell proliferation. Insulin also stimulates vascular smooth muscle cells to produce plasminogen activator inhibitor 1. Hyperglycemia inhibits endothelial cell nitric oxide production and potentiates collagen-induced platelet activation.

Mönckeberg arteriosclerosis (medial calcific sclerosis) is a form of arteriosclerosis that is more common in patients with diabetes. In advanced cases, the arteries become rigid and lose their distensibility and are referred to as *pipestem arteries*. The calcification may be evident on plain radiographs.

## CARDIOVASCULAR RISK REDUCTION

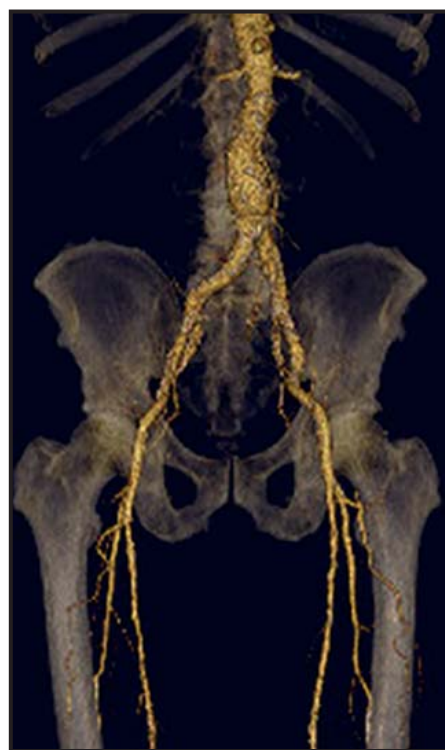Traditional CHD risk factors (dyslipidemia, obesity, hypertension, insulin resistance) are commonly present in individuals with type 2 diabetes. Thus, the atherosclerosis risk in individuals with diabetes is multifactorial and likely synergistic. Intensive long-term treatment of these associated risk factors lowers the risk of macrovascular events by at least 50%. Lowering serum LDL cholesterol concentrations (even when pretreatment levels are in the reference range) with hydroxymethylglutaryl coenzyme A reductase inhibitors (statins) reduces cardiovascular events in patients with diabetes. Thus, lipid-directed pharmacologic therapy is a key intervention along with lifestyle modification (weight reduction, regular isotonic exercise, and smoking cessation), optimizing glycemic control, treatment of hypertension, and aspirin therapy.

The fatality rate with myocardial infarction (MI) is twice as high in patients with diabetes than in nondiabetic patients. This increased risk is likely related to multiple factors (e.g., more severe underlying CHD, early reinfarction caused by impaired fibrinolysis, autonomic neuropathy predisposing to a sympathovagal imbalance, or maladaptive remodeling of the left ventricle). Blood glucose concentrations at the time of

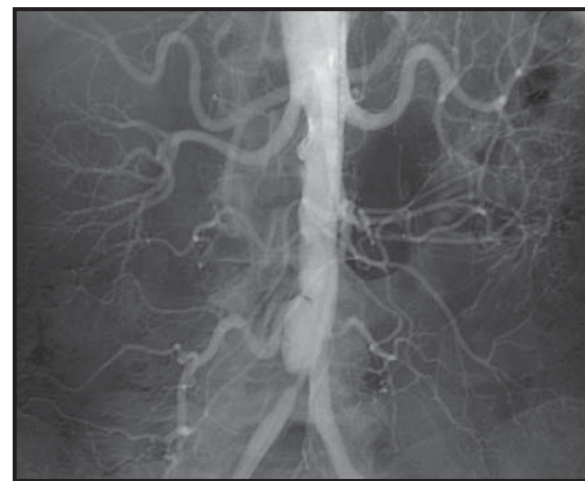


Intimal proliferation (atherosclerosis); lumen greatly reduced

Medial calcification (Mönckeberg type of sclerosis) plus some intimal thickening and thrombosis



CT angiogram of the abdominal aorta shows the infrarenal abdominal aorta is mildly ectatic. There is a stenosis at the origin of the left internal iliac artery.



Aortogram showing advanced atheromatous disease involving the infrarenal abdominal aorta with multiple areas of ulceration. Tight atheromatous stenosis involving the origin of the right common iliac artery.

hospital admission are independently correlated with both early and late mortality after an MI. Optimizing glycemic control can improve myocardial cell metabolism by shifting from free fatty acid oxidation to glucose oxidation for generation of adenosine triphosphate. Treatment with an angiotensin-converting enzyme inhibitor also decreases mortality in patients with diabetes after an MI. The mechanisms of this benefit are likely related to limitation of infarct size and improving endothelial cell function and fibrinolysis.

Cardioselective  $\beta$ -adrenergic inhibitors are routinely given to patients with diabetes in the setting of acute coronary syndromes to decrease mortality rates. The  $\beta$ -adrenergic inhibitors likely decrease the unrestrained sympathetic nervous system overactivity related to autonomic neuropathy. Aspirin has been shown to lower the risk of MI in individuals with diabetes. Thus, aspirin (81–325 mg/d) is indicated for both primary and secondary macrovascular event protection in all patients with diabetes.



## VASCULAR INSUFFICIENCY IN DIABETES: THE DIABETIC FOOT

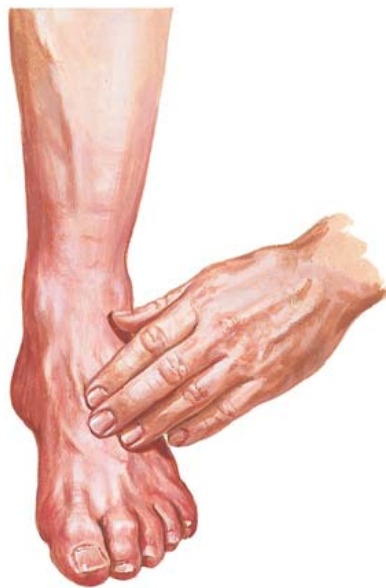Diabetic foot ulcers occur in approximately 10% of patients with type 1 or type 2 diabetes mellitus. Approximately 1% of patients with diabetes require an amputation, a last-resort surgical step that is usually preceded by foot ulcers. Diabetes is the most common non-trauma cause of lower limb amputation. Diabetic foot ulcers are more common in patients who also have other evidence of other micro- or macrovascular disease (retinopathy, nephropathy, or coronary heart disease).

Diabetic neuropathy (see Plate 5-16) plays a key role in diabetic foot ulcers. For example, sympathetic autonomic neuropathy may result in dry skin (from decreased sweat production), leading to scaling, cracks, and fissures, which provide a portal for infection. Motor neuropathy affects the small intrinsic muscles of the feet so that the larger muscles in the anterior tibial compartment are unopposed, causing subluxation of the proximal interphalangeal-metatarsal joints (claw toe deformity). The prominent metatarsal heads become the point of impact of body weight and friction and a common site of diabetic foot ulcer development. Diabetic neuropathy-induced proprioceptive loss decreases the patient's recognition of these sites of irritation and inflammation. Plantar callus, which predisposes to ulceration, may build up at these high pressure sites. The presence of neuropathy increases the risk of diabetic ulcer formation sevenfold.

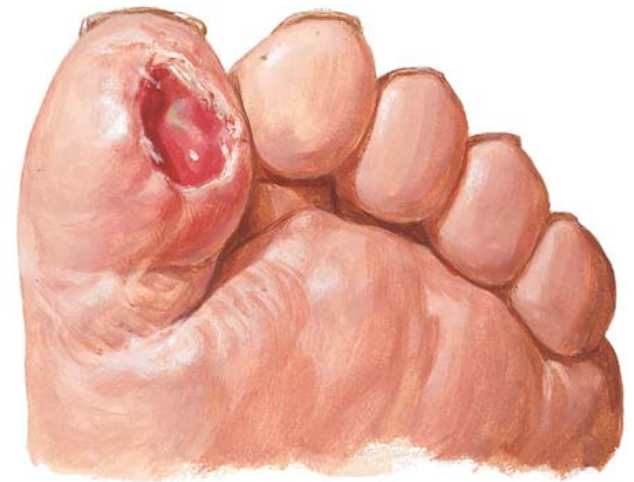Patients with diabetes should have annual comprehensive foot examinations to assess for evidence of neuropathic or vascular deficits, deformity, callus formation, or dry skin. Vibration sensation should be tested with a 128-Hz tuning fork at the great toe. Pressure sensation should be tested with a Semmes-Weinstein 5.07 (10-g) monofilament applied to buckling pressure on the plantar surface of the foot. In addition, the Achilles tendon reflex and temperature sensation should be checked. Vascular insufficiency can be evaluated with assessment of pulses (dorsal pedis, posterior tibial), skin temperature, presence of hair on skin, color of skin, and assessment for dependent rubor. Dependent rubor is present when the skin and nail beds are dark red because of the inadequate arterial flow and the presence of venous blood containing reduced hemoglobin in dilated venous capillaries; when the foot is raised above the level of the heart, the venous blood drains away and unmasks the pallid tissues supplied by insufficient arterial flow. Patients who are determined to have risk factors for foot ulcer formation should be advised by a foot care team that includes diabetes physician specialists, diabetes nurse educators, podiatrists, orthotic specialists, orthopedic surgeons, and vascular surgeons. Prophylactic measures to prevent diabetic foot ulcers include smoking cessation; avoiding walking barefoot; checking water temperature before stepping into a bath; keeping the toenails trimmed; inspecting the feet daily for blisters, swelling, or redness; and wearing properly fitting shoes.

The Wagner diabetic foot ulcer classification scheme is as follows:

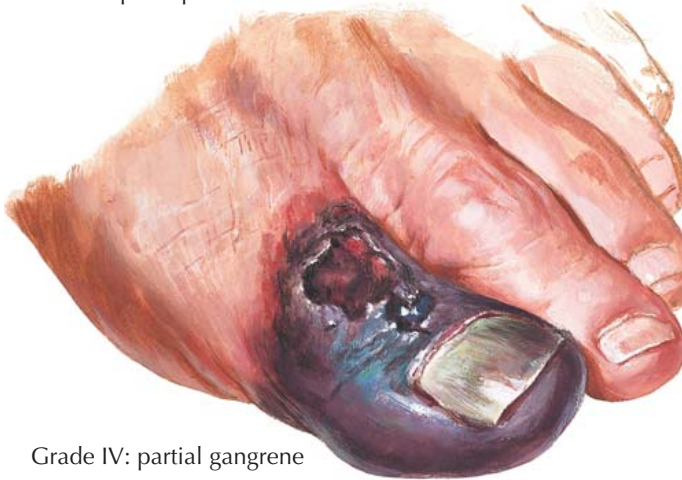
- Grade 0: No ulcer but high-risk (e.g., deformity, callus, insensitivity)
- Grade 1: Superficial full-thickness ulcer
- Grade 2: Deeper ulcer that penetrates tendons but does not involve bone
- Grade 3: Deeper ulcer with bone involvement (osteitis)



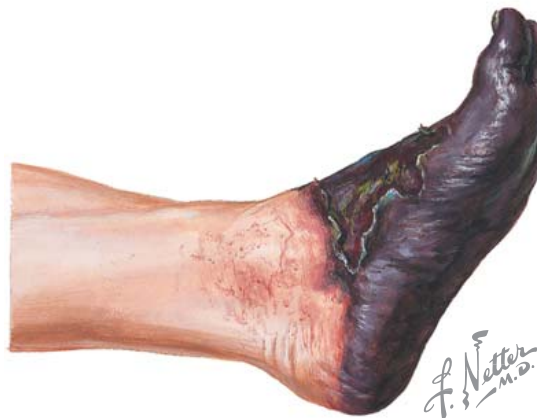Dependent rubor, absence of dorsalis pedis pulsation



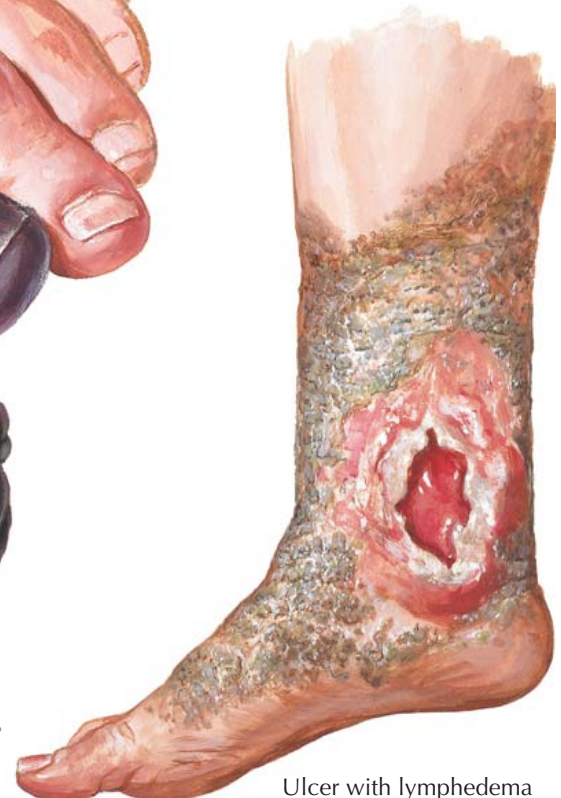Grade I: superficial full-thickness ulcer



Grade IV: partial gangrene



Grade V: gangrene of the whole foot



Ulcer with lymphedema

Grade 4: Partial gangrene (e.g., toes and forefoot)

Grade 5: Gangrene of the whole foot

Key steps to ensure effective healing of diabetic foot ulcers include confirming adequate arterial blood flow, treating underlying infection, removing pressure from the wound and surrounding area, and debriding all dead and macerated tissue. Pressure relief can usually be achieved with a removable cast boot. A nonhealing foot ulcer should be investigated for ischemia with noninvasive techniques and arteriography in some cases. If osteomyelitis is suspected, additional imaging

is indicated with a combination of plain radiographs, magnetic resonance imaging, and bone scintigraphy. The treatment of osteomyelitis requires systemic antibiotic therapy and, in many cases, surgical removal of infected bone. Localized gangrene of a toe that is not associated with infection may be allowed to self-amputate. However, more extensive gangrene is a medical urgency that requires hospitalization, treatment of the underlying infection, optimizing glycemic control, vascular assessment, and consultation with vascular and orthopedic surgeons.

## DIABETES MELLITUS IN PREGNANCY

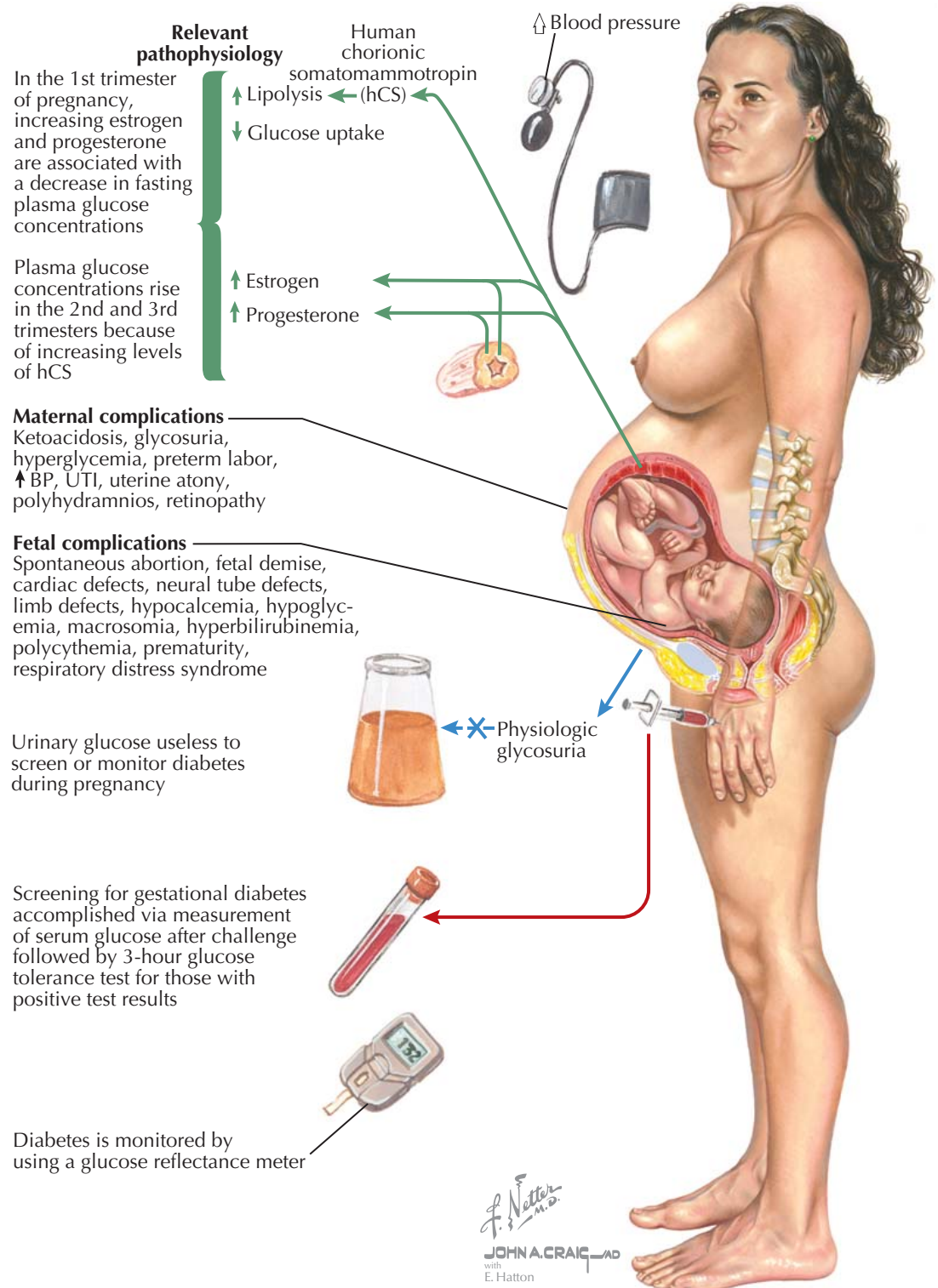
Diabetes mellitus is the most common medical complication of pregnancy. Gestational diabetes mellitus (GDM) complicates 4% of pregnancies, and preexisting type 1 or type 2 diabetes mellitus (pregestational diabetes) complicates 0.5% of all pregnancies. Diabetes in pregnancy is associated with unique risks for the fetus and the mother. Poorly controlled diabetes is associated with high risks for spontaneous abortion, major congenital malformations, premature birth, preeclampsia, and stillbirths. Although maternal glucose crosses the placenta, insulin does not, resulting in increased fetal pancreas production of insulin, which leads to increased fetal somatic growth.

Fetal macrosomia (fetal birth weight >4500 g) can complicate delivery and predispose to birth trauma. To prevent these risks, pregestational diabetes should be under optimal glycemic control for months before conception and throughout pregnancy. In addition, all pregnant women should be tested for GDM and treated when identified.

In the first trimester of pregnancy, the increasing blood concentrations of estrogen and progesterone are associated with a decrease in fasting plasma glucose concentrations by an average of 15 mg/dL. Plasma glucose concentrations rise in the second and third trimesters of pregnancy, primarily because of increasing circulating levels of human chorionic somatomammotropin (hCS), also called human placental lactogen. The structure of hCS is very similar to that of human growth hormone and has most of the actions of growth hormone; hCS enhances lipolysis and decreases glucose utilization.

The diagnostic criteria for pregestational type 1 or type 2 diabetes are as outlined in Plates 5-11 and 5-12. GDM is defined as hyperglycemia or glucose intolerance with an onset or first recognition during pregnancy. All women without known diabetes should be tested for GDM between weeks 24 and 28 of gestation. Testing for GDM should be done earlier in pregnancy if risk factors are present (pre-pregnancy body mass index >30 kg/m<sup>2</sup>, history of GDM, prior infant with a major congenital malformation, or family history of diabetes in a first-degree relative). The initial screening test is a 50-g oral glucose challenge test (GCT) with measurement of plasma glucose 1 hour later. Glucose levels above 130 mg/dL should trigger confirmatory testing with a 3-hour 100-g oral glucose tolerance test (OGTT). If the 1-hour GCT glucose is more than 180 mg/dL and fasting plasma glucose is more than 95 mg/dL, then GDM is confirmed, and a 3-hour OGTT is not needed. In addition, GDM is confirmed on the 3-hour OGTT if two or more of the following plasma glucose concentrations are exceeded: fasting above 95 mg/dL, 1 hour above 180 mg/dL, 2 hours above 155 mg/dL, or 3 hours above 140 mg/dL.

Patients with GDM should be treated with daily exercise, diet (with relative carbohydrate restriction [33%–40% of calories] and guidance on caloric allotment and calorie distribution), and pharmacologic therapy if needed. Patients should do self-monitoring of blood glucose at least four times daily (fasting and 1 to 2 hours postprandial). Target glucose levels during pregnancy are 70 to 95 mg/dL fasting and less than 120 mg/dL at 1 to 2 hours after a meal. Insulin treatment is needed in about 15% of women with GDM because they cannot achieve these glycemic targets with diet and exercise. Insulin doses should be titrated based on findings on



Management objectives involve efforts to return glucose levels to as close to normal as possible through a combination of diet, exercise, insulin (as indicated), and tight control in patients with pregestational diabetes

blood glucose self-monitoring. Fetal growth and development should be monitored by ultrasonography.

Diabetes comorbidities, including hypertension (increased blood pressure [BP]), retinopathy in patients with pregestational diabetes, ketoacidosis, and urinary tract infections (UTIs), should be monitored and treated during pregnancy as indicated.

In most women with GDM, the blood glucose concentrations return to normal postpartum; however, there is a 60% risk of recurrent GDM with future

pregnancies. In addition, women who are diagnosed with GDM are at a 50% risk of developing permanent diabetes over the subsequent 10 years.

There are also long-term effects on children whose mothers had diabetes in pregnancy. The in utero exposure to maternal hyperglycemia promotes fetal hyperinsulinemia and an increase in fetal fat cells, changes that have been linked to obesity and insulin resistance in children and impaired glucose tolerance and diabetes in adults.



## TREATMENT OF TYPE 2 DIABETES MELLITUS

Improved glycemic control in individuals with type 2 diabetes mellitus is associated with decreased rates of microvascular complications (retinopathy, nephropathy, and neuropathy). The treatment goal should be to maintain the hemoglobin A<sub>1c</sub> (HbA<sub>1c</sub>) at a level less than 7%, recognizing that HbA<sub>1c</sub> values in the normal range (<6%) are optimal. Additional glycemic targets include fasting and premeal plasma glucose of 70 to 130 mg/dL and 2-hour postprandial glucose of less than 180 mg/dL.

### NONPHARMACOLOGIC THERAPY

The key to successful implementation of lifestyle interventions is comprehensive diabetes education with emphasis on self-management. Interventions include dietary modification based on nutrition counseling, regular isotonic exercise, weight reduction, behavior modification, and self-monitoring of blood glucose (SMBG). Exercise improves glycemic control, insulin sensitivity, and cardiovascular fitness. The frequency and timing of SMBG depend on the type of pharmacologic therapy.

### PHARMACOTHERAPY

Pharmacotherapeutic options for the management of type 2 diabetes include seven broad classes of drugs that are targeted at different pathophysiologic mechanisms that contribute to hyperglycemia.

#### Insulin Sensitizers with Primary Action in the Liver—Biguanides

Metformin, the only biguanide currently available in the United States, activates the adenosine monophosphate-activated protein kinase. Metformin reduces hepatic insulin resistance, resulting in decreased hepatic gluconeogenesis. There is no risk for hypoglycemia, and this agent should be considered in all patients with type 2 diabetes. The main side effect is gastrointestinal intolerance. Because of the risk of lactic acidosis, metformin should not be used in patients with renal insufficiency.

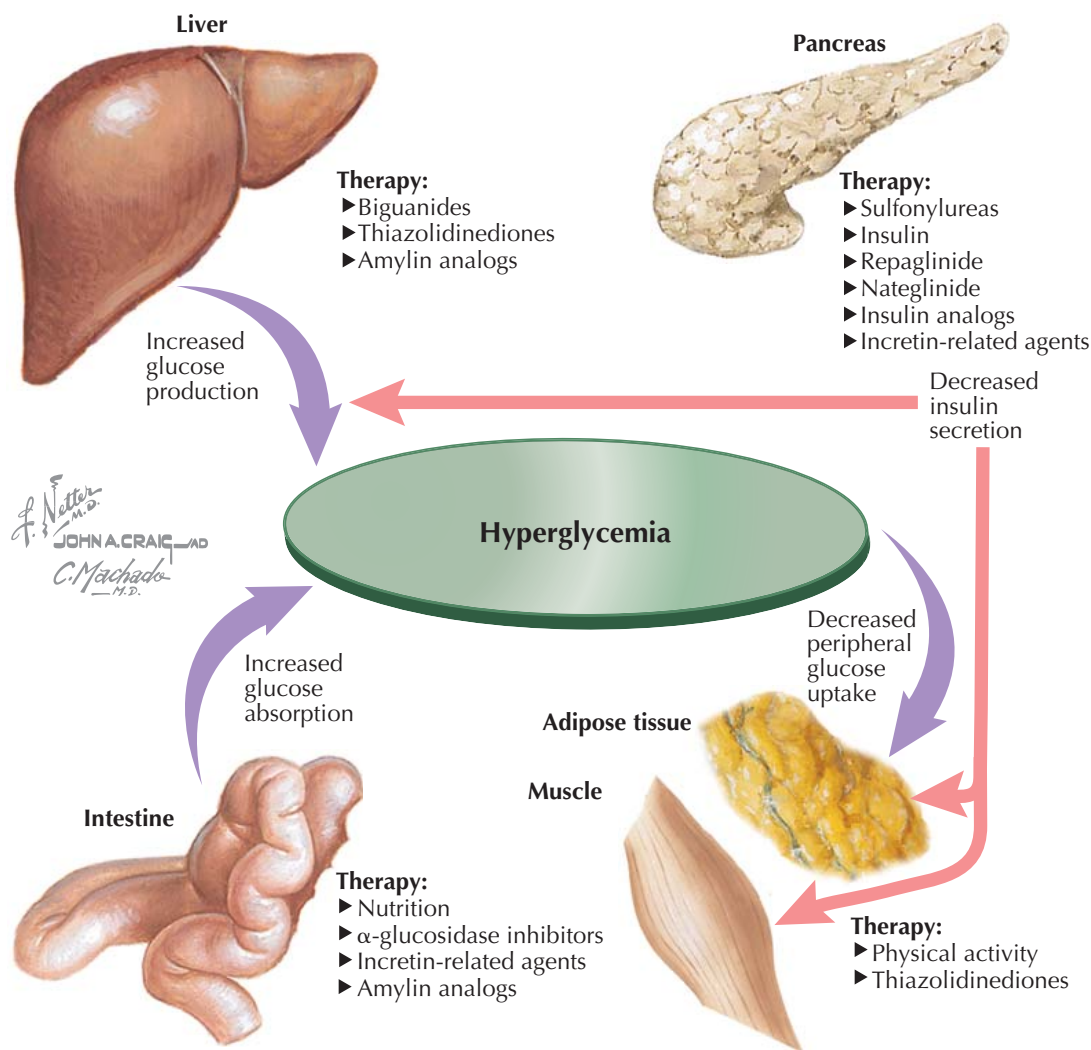
#### Insulin Sensitizers with Primary Action on Peripheral Tissues—Thiazolidinediones

Pioglitazone and rosiglitazone, the two thiazolidinediones (TZDs) currently available, modulate peroxisome proliferator-activated receptors (PPARs). TZDs decrease peripheral insulin resistance and lower serum triglyceride levels. The main side effects are weight gain caused by subcutaneous fat accumulation and fluid retention.

#### Insulin Secretagogues—Sulfonylurea Receptor Agonists

The sulfonylurea receptor (SUR2) is a subunit of the adenosine triphosphate-sensitive potassium channel on the plasma membrane of the  $\beta$ -cell, where it functions as a glucose sensor to trigger insulin secretion. Sulfonylureas include first-generation agents (acetohexamide, chlorpropamide, tolazamide, and tolbutamide) and second-generation agents (glipizide, glyburide, and glimepiride). Long-acting forms of sulfonylureas facilitate once-daily dosing. Repaglinide and nateglinide are agents in the meglitinide family of insulin secretagogues, which activate a distinct SUR1 binding site. Because of their short half-lives, repaglinide and

### MATCHING PHARMACOLOGY TO PATHOPHYSIOLOGY



nateglinide are administered with each meal. Insulin secretagogues can cause hypoglycemia.

#### Agents that Slow Enteric Carbohydrate Absorption— $\alpha$ -Glucosidase Inhibitors

$\alpha$ -glucosidase inhibitors (AGIs) (acarbose, miglitol) inhibit the terminal step of carbohydrate digestion at the intestinal epithelium and delaying carbohydrate absorption. They must be administered at the beginning of each meal. The main side effects are flatulence and diarrhea.

#### Incretin-Related Agents

The finding that orally administered glucose has a greater stimulatory effect on insulin secretion than intravenously administered glucose is called the *incretin effect*. Glucagon-like peptide 1 (GLP-1) and gastric inhibitory peptide (GIP) mediate the incretin effect. GLP-1 stimulates insulin secretion, slows gastric emptying, and reduces appetite. GLP-1 has a short plasma half-life because of rapid degradation by dipeptidyl peptidase IV (DPP-IV). Exenatide is an incretin mimetic that is structurally similar to GLP-1. It is administered subcutaneously twice daily and is resistant to DPP-IV degradation. Nausea is the most common side effect. Liraglutide is a DPP-IV-resistant GLP-1 analogue that is administered subcutaneously once daily. Sitagliptin, saxagliptin, and vildagliptin are orally administered DPP-IV inhibitors that result in mild increases in endogenous GLP-1 and GIP.

#### Amylin Analogues

Amylin is cosecreted with insulin by the  $\beta$ -cell and has complementary actions to insulin by delaying gastric emptying, reducing appetite, and suppressing glucagon secretion. Pramlintide is an amylin analogue that is administered subcutaneously at each meal.

#### Insulin

Subcutaneous administration of insulin serves to supplement endogenous insulin production. The types of insulin include rapid-acting insulin analogues (lispro, aspart, glulisine), short-acting analogues (regular insulin), intermediate-acting analogues (neutral protamine Hagedorn [NPH]), and long-acting analogues (glargine, detemir). Side effects include hypoglycemia and weight gain.

#### INITIAL APPROACH TO MEDICAL MANAGEMENT

In general, metformin along with diet and exercise should be the initial therapy for patients with type 2 diabetes. For patients with newly diagnosed diabetes who have fasting glucose concentration more than 250 mg/dL, more than one pharmacologic agent is usually needed (e.g., metformin and a sulfonylurea or insulin). For established patients with suboptimal glycemic control because of postprandial hyperglycemia, the addition of AGIs, rapid-acting insulin, or exenatide should be considered.

## TREATMENT OF TYPE 1 DIABETES MELLITUS

It has been clearly demonstrated that optimizing glycemic control with intensive insulin therapy in patients with type 1 diabetes mellitus leads to clinically significant decreased risks for retinopathy, nephropathy, neuropathy, and cardiovascular disease. The treatment goal should be to maintain the hemoglobin A<sub>1c</sub> (HbA<sub>1c</sub>) at a level less than 7%, recognizing that HbA<sub>1c</sub> values in the normal range (<6%) are optimal. Additional glycemic targets include fasting and premeal plasma glucose at 70 to 130 mg/dL and 2-hour postprandial glucose less than 180 mg/dL. Two methods of insulin delivery that can be used to achieve this glycemic targets are continuous subcutaneous insulin infusion (CSII; insulin pump) and multiple daily injections (MDIs) of insulin.

The types of insulin currently available include rapid-acting insulin analogues (lispro, aspart, glulisine) with an onset of action at 15 minutes and peak effect at 1 hour; short-acting (regular insulin) analogues with an onset of action at 30 to 60 minutes and peak effect at 2 to 4 hours; intermediate-acting analogues (neutral protamine Hagedorn [NPH]) with an onset of action at 1 to 3 hours and a peak effect at 6 to 8 hours; and long-acting analogues (glargine, detemir) with an onset of action at 1 hour, peak effect at 9 or more hours, and duration of effect for 24 hours.

### MONOMERIC INSULIN ANALOGUES

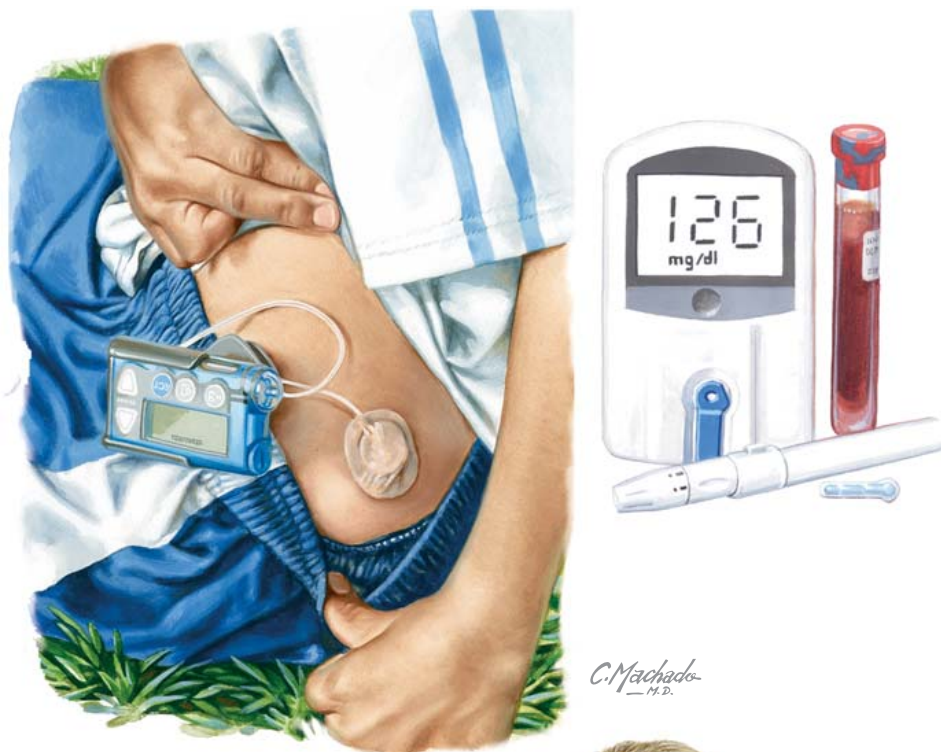
Modifications of the human insulin molecule can change its kinetics. For example, rapid-acting insulin analogues are made with recombinant DNA technology by modifying insulin structure to decrease the ability of insulin to self-aggregate after subcutaneous injection, leading to rapid absorption and action. Insulin lispro is synthesized by reversing the amino acids at positions 28 and 29 in the  $\beta$ -chain of human insulin (lysine at  $\beta$ -28 and proline at  $\beta$ -29). Aspartic acid is substituted for proline at  $\beta$ -28 to form insulin aspart. Insulin glulisine is produced by substituting lysine for asparagine at  $\beta$ -3 and substituting glutamic acid for lysine at  $\beta$ -29.

### LONG-ACTING INSULIN ANALOGUES

Insulin glargine is modified from human insulin by replacing asparagine at  $\alpha$ -21 with glycine and by adding two arginine amino acids to the C-terminus of the  $\beta$ -chain. Insulin glargine is solubilized in an acidic solution, and after it has been administered subcutaneously, it microprecipitates and is slowly absorbed over 24 hours to simulate basal production of insulin. Insulin detemir is modified from human insulin by removing the threonine at  $\beta$ -30, and a C14 fatty acid is attached to the amino acid at  $\beta$ -29. Insulin detemir remains soluble after subcutaneous injection; the long duration of action relates to the molecular modifications.

### AMYLIN ANALOGUES

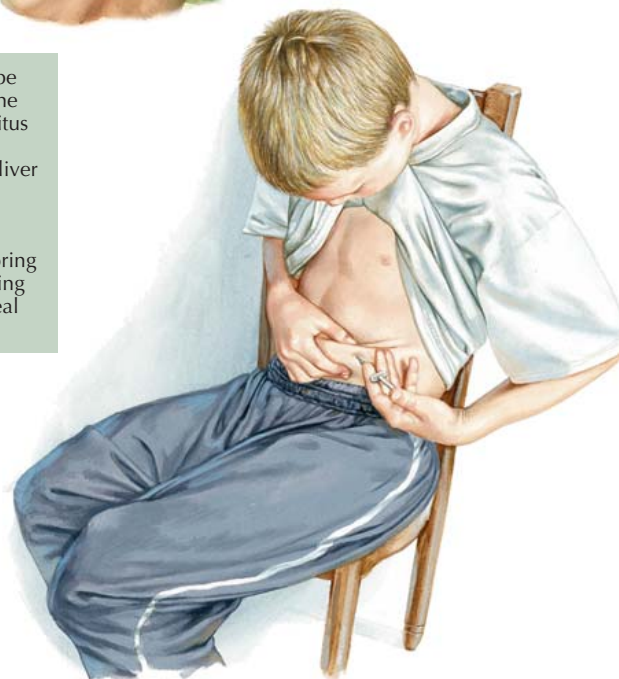
Amylin is cosecreted with insulin by the  $\beta$ -cell and has complementary actions to insulin by delaying gastric emptying, reducing appetite, and suppressing glucagon secretion. In addition to insulin, patients with type 1 diabetes are also deficient in amylin. Pramlintide is an amylin analogue that is administered subcutaneously at each meal. The addition of pramlintide improves HbA<sub>1c</sub> to a modest degree and decreases preprandial insulin requirements.



Intensive insulin therapy should be started as soon as possible after the diagnosis of type 1 diabetes mellitus

The MDI and CSII methods to deliver insulin are designed to replicate normal physiology

CSII and MDI require self-monitoring of blood glucose and then adjusting and/or supplementing the pre-meal insulin doses



### CONTINUOUS SUBCUTANEOUS INSULIN INFUSION AND MULTIPLE DAILY INJECTIONS

Intensive insulin therapy should be started as soon as possible after the diagnosis of type 1 diabetes. Intensive insulin therapy programs require a team approach that includes the patient, diabetes nurse educators, registered dietitians, medical social workers, and physicians with an interest in diabetes management. A portable closed-loop system that continuously measures blood glucose and administers appropriate insulin doses has not yet been developed. Thus, CSII and MDI require self-monitoring of blood glucose (SMBG) and adjusting and/or supplementing the premeal insulin treatment. With MDI, a long-acting insulin analogue is administered at bedtime, and rapid-acting analogues are administered before meals. With CSII, an external

mechanical pump continuously administers rapid-acting insulin analogues through a catheter that is inserted into the abdominal wall subcutaneous fat. The pump delivers preprogrammed basal insulin (e.g., 1 unit per hour), and the patient directs the pump to administer boluses premeal. The basal rate can be programmed to change over the 24 hours (e.g., an increased basal rate may be needed in the early morning hours).

Hypoglycemia is the most serious complication of both forms of intensive insulin programs. Hypoglycemia can result in falls, motor vehicle accidents, and seizures. Autonomic neuropathy may mask the usual adrenergic-type symptoms (e.g., tremor, tachycardia, sweat) to alert the patient to hypoglycemia; this is termed *hypoglycemic unawareness*. All patients should have readily available carbohydrate (e.g., glucose tablets) and injectable glucagon kits.



**INSULINOMA**

Hypoglycemia due to excess endogenous insulin production is usually caused by a neoplasm of the pancreatic  $\beta$ -cells, termed *insulinoma*. Insulinomas are rare (4 cases per million people per year), usually benign (~95%), and sporadic (~95%). Approximately 5% of insulinoma patients have multiple endocrine neoplasia type 1 (MEN 1) (see Plate 8-1). Insulinomas are usually solitary (~85%) but may be multiple (~10%) (especially in MEN 1) or malignant (~5%). Pancreatic  $\beta$ -cell hyperplasia can also cause hypoglycemia (see Plate 5-23). In patients with insulinomas, insulin secretion fails to decrease normally as plasma glucose concentrations decrease.

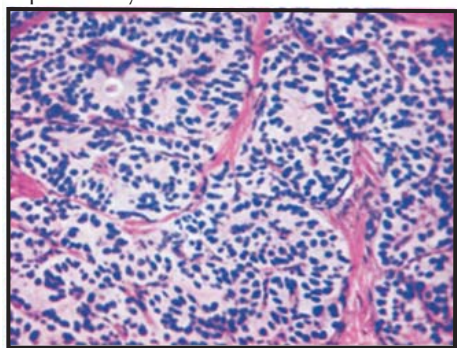
Patients with insulinomas typically note discrete episodes of neuroglycopenia (visual change, confusion, and unusual behavior) and sympathoadrenal symptoms (tremulousness, sweating, and palpitations). Less commonly, patients with insulinoma have episodes of unconsciousness and rarely hypoglycemia-induced seizures. Whipple triad—neuroglycopenia and sympathoadrenal symptoms consistent with hypoglycemia, documented low plasma glucose concentration at the time of symptoms, and relief of symptoms with caloric ingestion—should be documented in all patients with suspected hypoglycemia. The hypoglycemia in patients with insulinoma is caused primarily by an insulin-induced decrease in hepatic glucose output in the fasting state.

Confirmation of endogenous hyperinsulinemic hypoglycemia requires the documentation of hypoglycemia (laboratory-based measurement of venous plasma glucose  $<45$  mg/dL) with inappropriate levels of plasma insulin, C-peptide, and proinsulin. These findings can usually be obtained with fasting—either a short overnight fast in a supervised outpatient setting or a 72-hour fast in a hospital setting—or after a mixed-meal test (for the minority of insulinoma patients who have primarily postprandial symptoms). Most patients with insulinoma become hypoglycemic within 48 hours of fasting. Laboratory values, obtained when the patient becomes symptomatic during a fast, that are consistent with insulinoma include plasma glucose level below 45 mg/dL, plasma insulin above 3  $\mu$ U/mL, plasma C-peptide above 200 pmol/L, proinsulin above 5 pmol/L, and  $\beta$ -hydroxybutyrate below 2.7 mmol/L. At the time of documented hypoglycemia, a drug screen should be obtained for sulfonylureas and other insulin secretagogues (e.g., nateglinide, repaglinide). In addition, at the end of the fast, 1 mg of glucagon should be administered intravenously. Insulin is antiglycogenolytic, and hyperinsulinemia permits retention of glycogen within the liver. Whereas normal individuals have released virtually all glucose from the liver at the end of a 72-hour fast and do not have a glucose response glucagon, insulinoma patients have an increase in plasma glucose of more than 25 mg/dL within 30 minutes of glucagon administration.

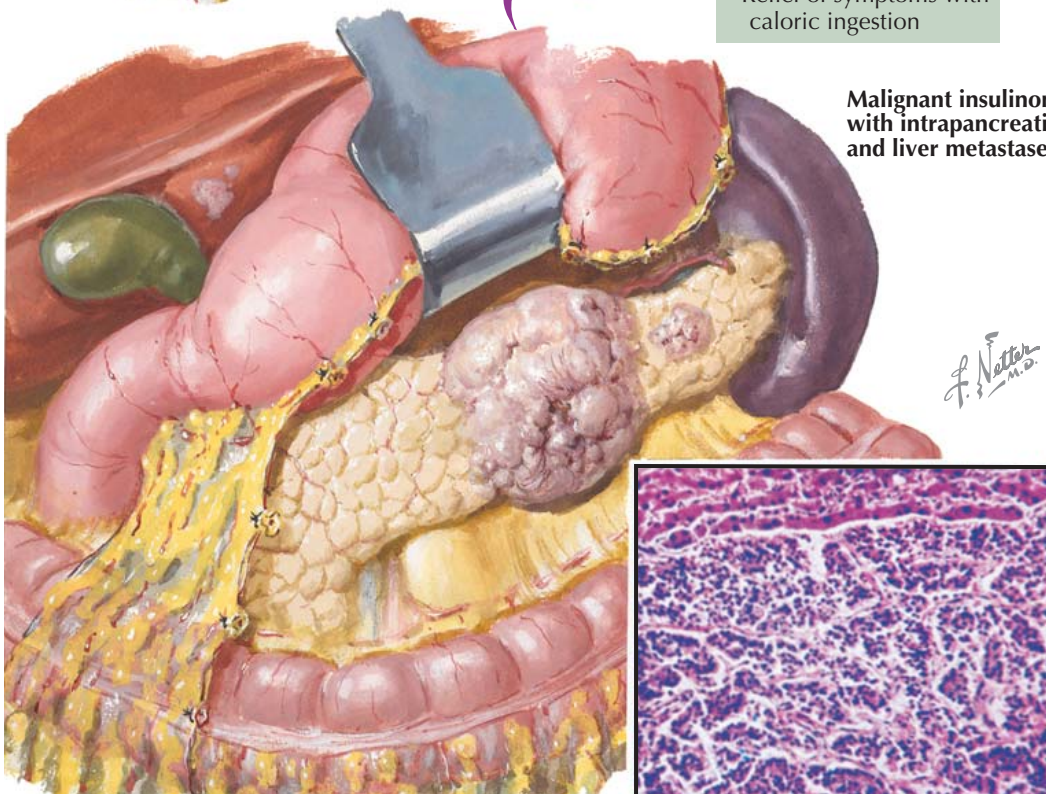
The differential diagnosis of disorders that can cause hypoglycemia is broad and includes insulinoma, nesidioblastosis, insulin-autoimmune hypoglycemia, drugs (e.g., sulfonylurea, insulin, or alcohol), critical illness (e.g., hepatic failure, renal failure, or sepsis), counter-regulatory hormone deficiency (e.g., Addison disease), and large mesenchymal tumors.

Preoperative localization of an insulinoma is important for operative planning. Localization of the insulinoma within the pancreas may be difficult because they are usually small (40% are  $<1.0$  cm in largest lesional diameter). Approximately 75% of insulinomas can be detected on contrast-enhanced computed tomography.

Microscopic view showing nests of islet cells separated by delicate fibrous strands and capillaries

**Whipple triad:**

- ▶ Neuroglycopenia
- ▶ Low plasma glucose concentration
- ▶ Relief of symptoms with caloric ingestion

**Malignant insulinoma with intrapancreatic and liver metastases**

Microscopic view showing irregular nests of more polymorphic, partly atypical islet cells

Transabdominal and endoscopic ultrasonography can usually localize 90% of these tumors. In selected patients, additional localization tests may be needed. For example, the selective arterial calcium stimulation with hepatic venous sampling can regionalize the insulinoma within the pancreas (see Plate 5-23). Intraoperative pancreatic ultrasonography provides confirmatory localization.

The treatment of choice for insulinoma is complete surgical resection; it may be possible to enucleate the tumor and spare normal pancreas tissue or a partial

pancreatectomy may be required. When the insulinoma is located in the pancreatic head and enucleation is not possible, a Whipple procedure (resection of the head of the pancreas, duodenectomy, gastrectomy, and splenectomy) may be required. Malignant insulinomas should be removed if possible. When metastatic, the liver is the most common site. Additional treatment approaches for metastatic and unresectable insulin-secreting neoplasms include embolization, radiofrequency ablation, cryoablation, endoscopic ultrasound-guided ethanol ablation, diazoxide, octreotide, or chemotherapy.



## PRIMARY PANCREATIC $\beta$ -CELL HYPERPLASIA

Primary pancreatic  $\beta$ -cell hyperplasia is a rare cause of hypoglycemia in children and adults. The hyperplastic process may be focal or diffuse. Nesidioblastosis, the neof ormation of islets of Langerhans from pancreatic duct epithelium, is present in some patients with pancreatic  $\beta$ -cell hyperplasia.

### CONGENITAL HYPERINSULINISM

Congenital hyperinsulinism is a rare (one in 50,000 live births) autosomal dominant or autosomal recessive disorder usually caused by mutations in the genes that encode the adenosine triphosphate-sensitive potassium channels (e.g., sulfonylurea receptor type 1 subunit [SUR1], potassium channel subunit [Kir6.2]). These loss-of-function mutations result in closure of the potassium channel and persistent  $\beta$ -cell membrane depolarization and insulin release despite the prevailing hypoglycemia. Diffuse  $\beta$ -cell hyperplasia and intractable hypoglycemia result. Congenital hyperinsulinism may also be caused by activating mutations in the genes that encode glutamate dehydrogenase or glucokinase.

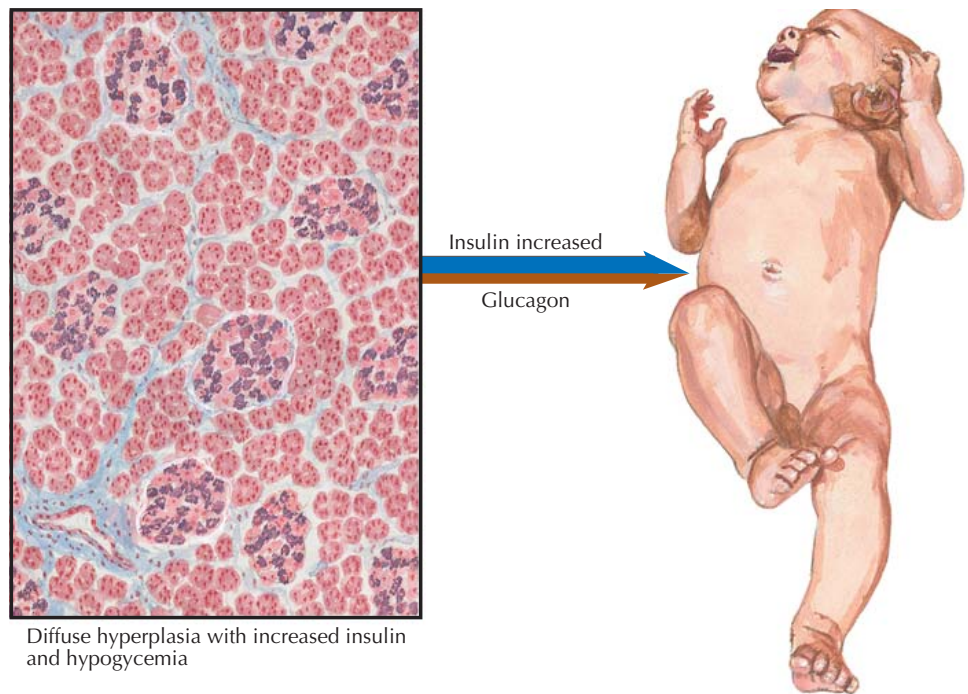
Focal adenomatous islet-cell hyperplasia may result from focal loss of the normal maternally inherited allele and somatic expression of the paternally inherited abnormal genes encoding SUR1 or Kir6.2 (*ABCC8* and *KCNJ11*, respectively), which cause  $\beta$ -cell hyperplasia only in the involved cells. Whereas focal islet-cell hyperplasia can be cured by resection of the focally hyperplastic areas of the pancreas, diffuse hyperplasia may require more extensive pancreatic resections.

Signs of hypoglycemia in neonates include changes in level of consciousness, tremor, hypotonia, seizures, apnea, and cyanotic spells. Symptoms are usually evident in the first days after birth. Detection may be delayed until later in childhood in those with partial or mild defects in the *ABCC8* or *KCNJ11* genes. Early diagnosis can prevent neurologic damage from recurrent episodes of hypoglycemia. Macrosomia is common in newborns with congenital hyperinsulinism.

The differential diagnosis of hypoglycemia in infancy and childhood includes hyperinsulinism (congenital hyperinsulinism, nesidioblastosis, insulinoma, infant of a diabetic mother, maternal drugs [e.g., sulfonylurea]); drugs; severe illness; transient intolerance of fasting; lack of counterregulatory hormones (e.g., hypopituitarism); Beckwith-Wiedemann syndrome; or enzymatic defects in the metabolism of carbohydrate (e.g., glycogen storage diseases, glycogen synthase deficiency), protein (e.g., branched-chain  $\alpha$ -keto acid dehydrogenase complex deficiency), or fat (e.g., defects in fatty acid oxidation). Transient intolerance of fasting is seen in premature infants and relates to incomplete development of glycogen stores and gluconeogenic mechanisms.

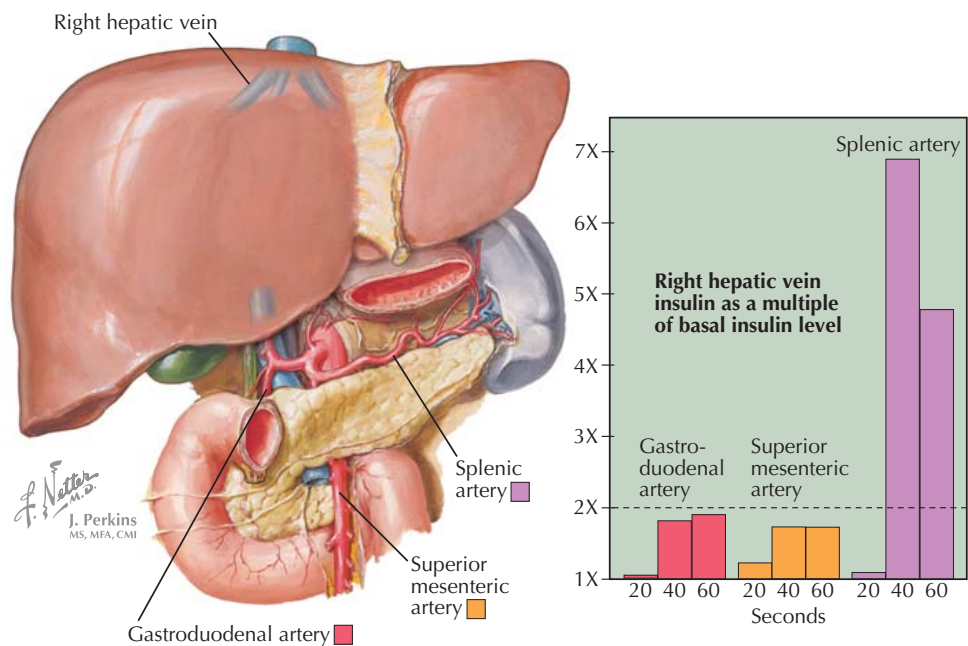
### NONINSULINOMA PANCREATOGENOUS HYPOGLYCEMIA SYNDROME AND POST-GASTRIC BYPASS HYPOGLYCEMIA

Noninsulinoma pancreatogenous hypoglycemia syndrome (NIPHS) is a form of islet-cell hyperplasia that presents with postprandial symptoms caused by hyperinsulinemic hypoglycemia. The signs and symptoms are cured with partial pancreatectomy. Pathologic examination shows  $\beta$ -cell hypertrophy with or without



Diffuse hyperplasia with increased insulin and hypoglycemia

### Selective arterial calcium stimulation test



hyperplasia. Nesidioblastosis is usually present. Similar presentation and pathologic findings have been found after Roux-en-Y gastric bypass surgery for obesity, in which symptomatic postprandial hypoglycemia can develop 6 months to 8 years after surgery. The underlying pathophysiology is uncertain but may relate to decreased ghrelin, unidentified small intestine factors, or an inability to reset from the preoperative state of insulin-resistant hyperinsulinemia.

### EVALUATION

Islet-cell hyperplasia may predispose to hypoglycemia, primarily in the postprandial state rather than in the fasting state as is seen with insulinoma. With the exception of the timing of hypoglycemia, the laboratory abnormalities are identical to those of patients with insulinomas (see Plate 5-22). The diagnosis of

postprandial hypoglycemia should not be based on results of oral glucose tolerance testing but rather on results after a mixed meal.

$\beta$ -Cell hyperplasia may be diffuse, asymmetric, or focal. Imaging studies are usually not helpful in localizing  $\beta$ -cell hyperplasia. Selective arterial calcium stimulation with hepatic venous sampling can regionalize the dysfunctional  $\beta$ -cells to arterial distributions within the pancreas. Calcium gluconate is selectively injected into the gastroduodenal, splenic, and superior mesenteric arteries, with timed hepatic venous sampling for measurement of insulin. Calcium stimulates the release of insulin from abnormal  $\beta$ -cells but not from normal  $\beta$ -cells. An abnormal result is defined as more than a two- to threefold increase from baseline in hepatic venous insulin concentrations. The selective arterial calcium stimulation test can lead to a gradient-guided partial pancreatectomy.



This page intentionally left blank

# BONE AND CALCIUM



## HISTOLOGY OF THE NORMAL PARATHYROID GLANDS

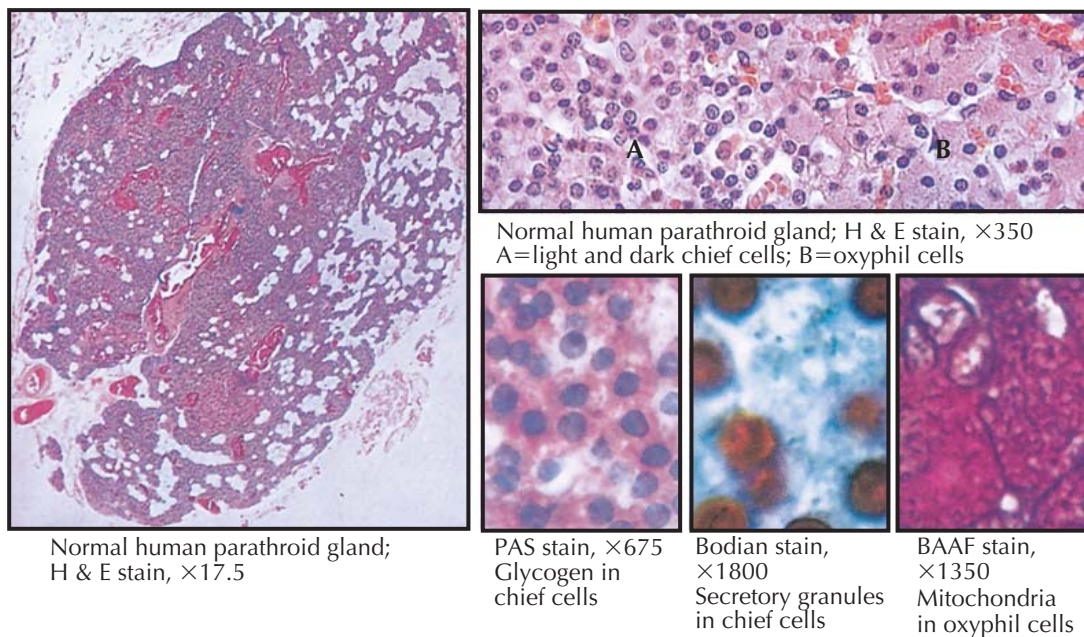
The parathyroid glands are derived from branchial pouches III and IV and number between two to six glands, although four is the usual number. In adults, each of these ovoid (bean-shaped) glands measures 4 to 6 mm × by 2 to 4 mm × 0.5 to 2 mm and weighs approximately 30 mg (the lower parathyroid glands are generally larger than the upper glands). They vary in color from yellow to tan, depending on vascularity and percentage of oxyphil cells and stromal fat.

In infants and children, the glands are composed of sheets of closely packed chief cells, with little intervening stroma. Oxyphil (or oncocytic) cells first make their appearance at the time of puberty. Fat cells begin to appear in the stroma in late childhood. Both the oxyphil cells and the fat cells increase in number until they may occupy more than 50% of the volume of the glands during the fifth and sixth decades of life.

In adults, the glands are composed of cords, sheets, and acini of chief cells in a loose areolar stroma containing numerous mature fat cells. Chief cells appear in an active synthetic phase (“dark chief cell”) with well-formed endoplasmic reticulum and prominent Golgi apparatus or in a resting phase (“light chief cell”) with less well-developed endoplasmic reticulum. Scattered individually or in groups among these chief cells are the oxyphil cells. The chief cell measures approximately 8 μm in diameter. It has a well-defined cell membrane and a 4- to 5-μm centrally located nucleus. The chromatin is densely packed, appearing almost pyknotic, or it is finely fibrillar with peripheral margination. Nucleoli are rare. The cell cytoplasm is clear and amphophilic in hematoxylin and eosin (H&E) preparations. The periodic acid–Schiff (PAS) reaction reveals abundant glycogen in these cells. Chief cells also contain abundant intracytoplasmic neutral lipid droplets demonstrated with azure B or Erie garnet A procedures or with oil red O or Sudan IV stains. Immunohistochemical studies show stronger staining for parathyroid hormone in chief cells than in oxyphilic cells.

The oxyphilic cells are larger than chief cells (12–20 μm in diameter) and are polygonal in shape. The cell membranes are usually clear, and the nucleus is identical to that of the chief cell. The cytoplasm is composed of highly eosinophilic fine granules, which stain carmine with Bensley acid aniline fuchsin (BAAF) and dark blue with phosphotungstic acid hematoxylin. These cells contain tightly packed mitochondria filling the cytoplasm and have high levels of oxidative enzymes. Unlike chief cells, the oxyphilic cells have very little intracytoplasmic lipid or glycogen. Variants of the oxyphilic cells include transitional oxyphilic cells, which are smaller and contain less eosinophilic cytoplasm.

The ultrastructure of the active form of the chief cell and the mode of secretion are schematized in the



Normal human parathyroid gland; H & E stain, ×17.5

Normal human parathyroid gland; H & E stain, ×350  
A=light and dark chief cells; B=oxyphil cells

PAS stain, ×675  
Glycogen in chief cells

Bodian stain, ×1800  
Secretory granules in chief cells

BAAF stain, ×1350  
Mitochondria in oxyphil cells

### Ultrastructure of parathyroid gland

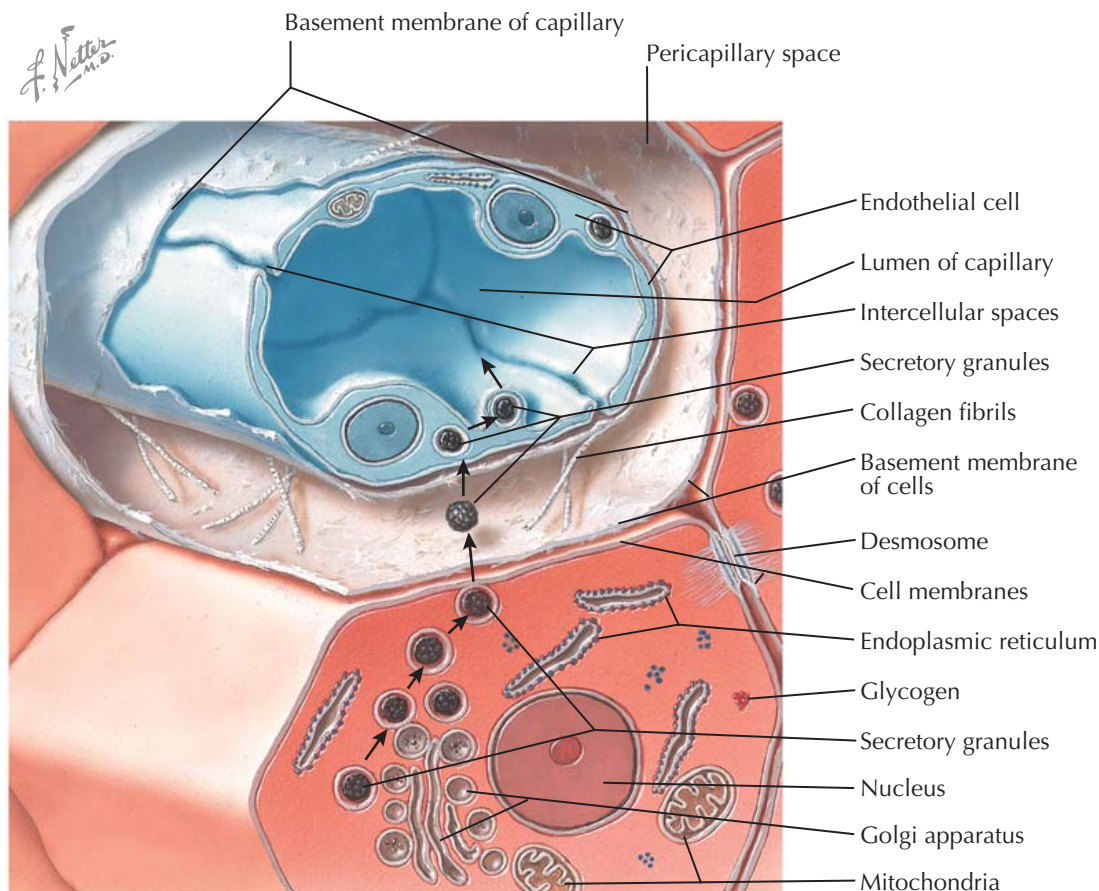


illustration. The chief cells are arranged in cords and nests and separated from the interstitium by basal laminae. The chief cells have straight plasma membranes and are attached to other cells by desmosomes. During the active phase, in addition to the usual organelles, the Golgi apparatus enlarges, numerous vacuoles and vesicles appear in the Golgi apparatus, and many mature secretory granules (50–300 nm in diameter) appear in the cell. The mature secretory granule

is oval to dumbbell-shaped and has a single membrane surrounding a thin clear space inside of which is a dense area composed of short rodlike profiles. The granule migrates out of the cell through the basement membrane into the wide pericapillary space. It then goes through the capillary basement membrane and into the fenestrated endothelial cells that line the capillaries, from which parathyroid hormone is liberated into the bloodstream.







## BONE REMODELING UNIT

Bone is composed of a collagen matrix, distributed in a lamellar pattern and strengthened by pyridinoline crosslinks between the triple-helical collagen molecules, on which calcium and phosphorus are deposited to form hydroxyapatite. The bone matrix also includes calcium-binding proteins such as osteocalcin. The resulting bone mineral is complex crystals of hydroxyapatite that contain fluoride and carbonate.

Bone modeling is the process of change in bone size and shape in childhood, where linear growth is the result of cartilaginous growth at the epiphyses, and bone width enlargement results from endosteal resorption and periosteal apposition. During puberty and early adulthood, endosteal apposition occurs, and peak bone mass is achieved.

Bone remodeling is the lifelong process of bone repair, which has three phases: resorption, reversal, and formation. The bone remodeling unit (osteon) involves a cycle of coupled osteoclastic and osteoblastic activities.

Osteoblasts develop from determined osteoblast progenitor cells that originate from mesenchymal stem cells. The osteoblast progenitor cells are localized to the periosteum and bone marrow. Osteoblasts have receptors for parathyroid hormone, 1, 25-dihydroxyvitamin D, testosterone, estrogen, glucocorticoids, growth hormone, thyroid hormone, and insulinlike growth factors. After osteoblasts lay down collagen and noncollagen proteins, some of the osteoblasts become osteocytes that are buried in the bone matrix. The remaining osteoblasts either become the less metabolically active, flattened lining cells or undergo apoptosis.

Osteoclasts, derived from monocytes and macrophages, are multinucleated, large cells that dissolve bone mineral and degrade matrix. Osteoclast progenitors can be found in the bone marrow and the spleen. Osteoclastic differentiation is triggered by the production of macrophage colony-stimulation factor. Excessive osteoclastic activity is associated with Paget disease, hyperparathyroidism, and a subset of osteoporosis.

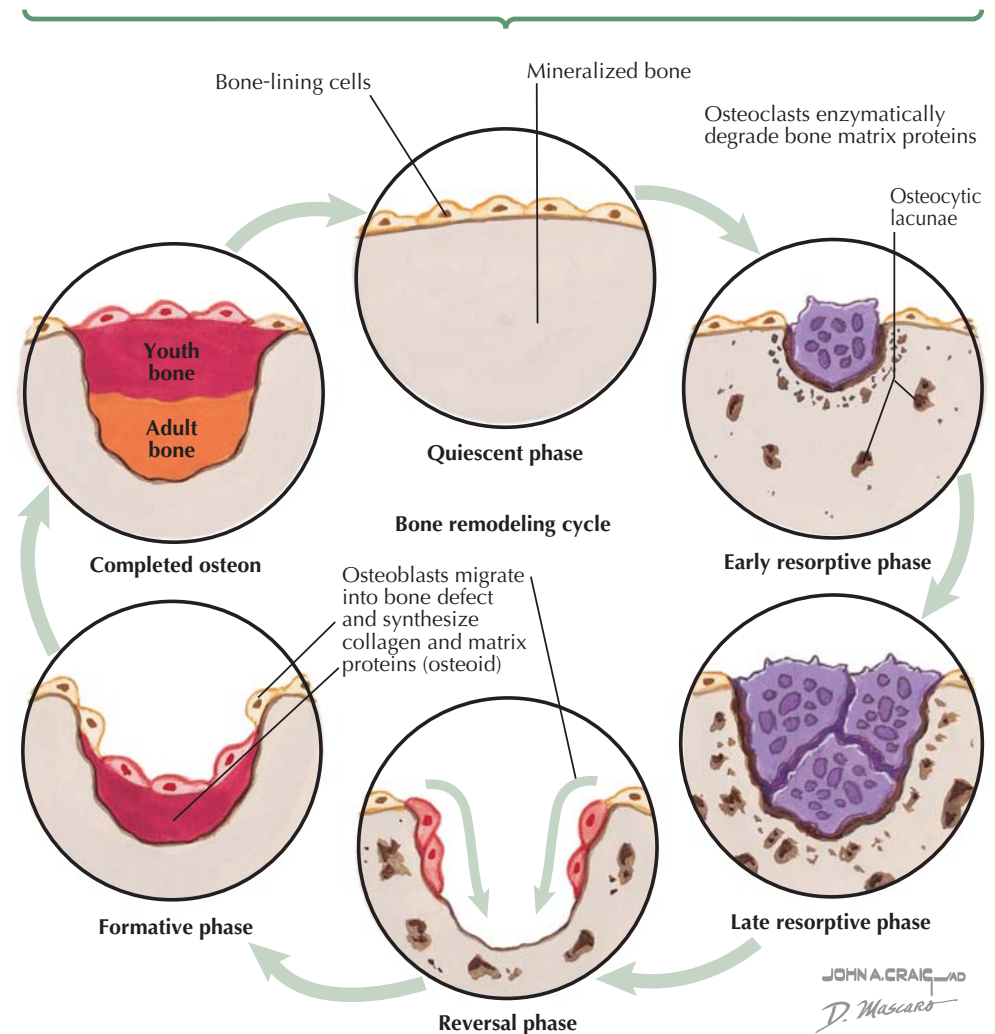
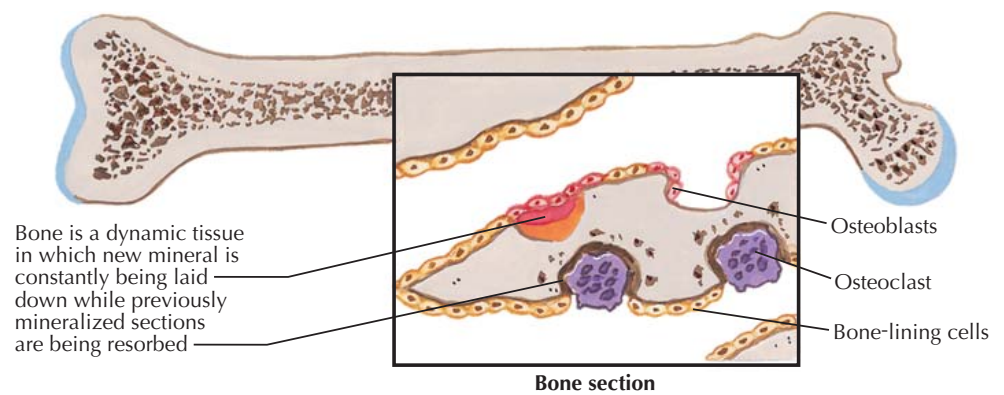
### RESORPTION

The bone remodeling cycle is activated by osteoblast cells that release collagenase, macrophage colony-stimulating factor, and receptor activator of NF- $\kappa$  B (RANK) ligand. RANK ligand interacts with the RANK receptor and activates osteoclast formation and the initiation of bone resorption. RANK ligand also binds to osteoprotegerin, which is an osteoclastogenesis inhibitory factor. Macrophage colony-stimulating factor is also required for normal osteoclast activation. This initial osteoblast activation of osteoclasts can be affected by multiple hormones and factors. For example, parathyroid hormone induces the osteoblastic production of RANK ligand and inhibits production of osteoprotegerin. Vitamin D also increases the production of RANK ligand.

Osteoclasts enzymatically degrade bone matrix protein and remove mineral within cortical bone or on the trabecular surfaces. This process is self-limited—perhaps by high local concentrations of calcium or bone matrix substances—and is completed over 2 weeks.

### REVERSAL

After osteoclastic resorption, the reversal phase is initiated by mononuclear cells that lay down a



glycoprotein-rich material (cement) on the resorbed surface and signal for osteoblast differentiation. The new osteoblasts adhere to this material. The reversal phase is approximately 4 weeks in duration.

### FORMATION

During the formation phase, osteoblasts lay down osteoid (collagen and matrix proteins) until the resorbed bone is completely replaced. The formation phase takes approximately 16 weeks to complete. Normally, the new bone formed is equivalent to what was resorbed. When the formation phase is complete, the bone surface is covered with bone-lining cells, and very little cellular activity occurs until another bone remodeling cycle begins.

### DEFECTIVE BONE REMODELING

In a normal bone remodeling unit, resorption and formation are tightly coupled. However, a mismatch between resorption and formation can lead to abnormally thin or dense bones. For example, if the osteoclastic resorption depth is excessive, it can perforate and weaken trabecular structure; if the osteoblasts do not completely fill the deep resorption cavity, bone density and quality decline. If the resorptive process is incomplete because the osteoclasts are not fully activated (e.g., with macrophage colony-stimulating factor deficiency) or if they are dysfunctional, excessively dense bones may result (osteopetrosis).

## PATHOPHYSIOLOGY OF PRIMARY HYPERPARATHYROIDISM

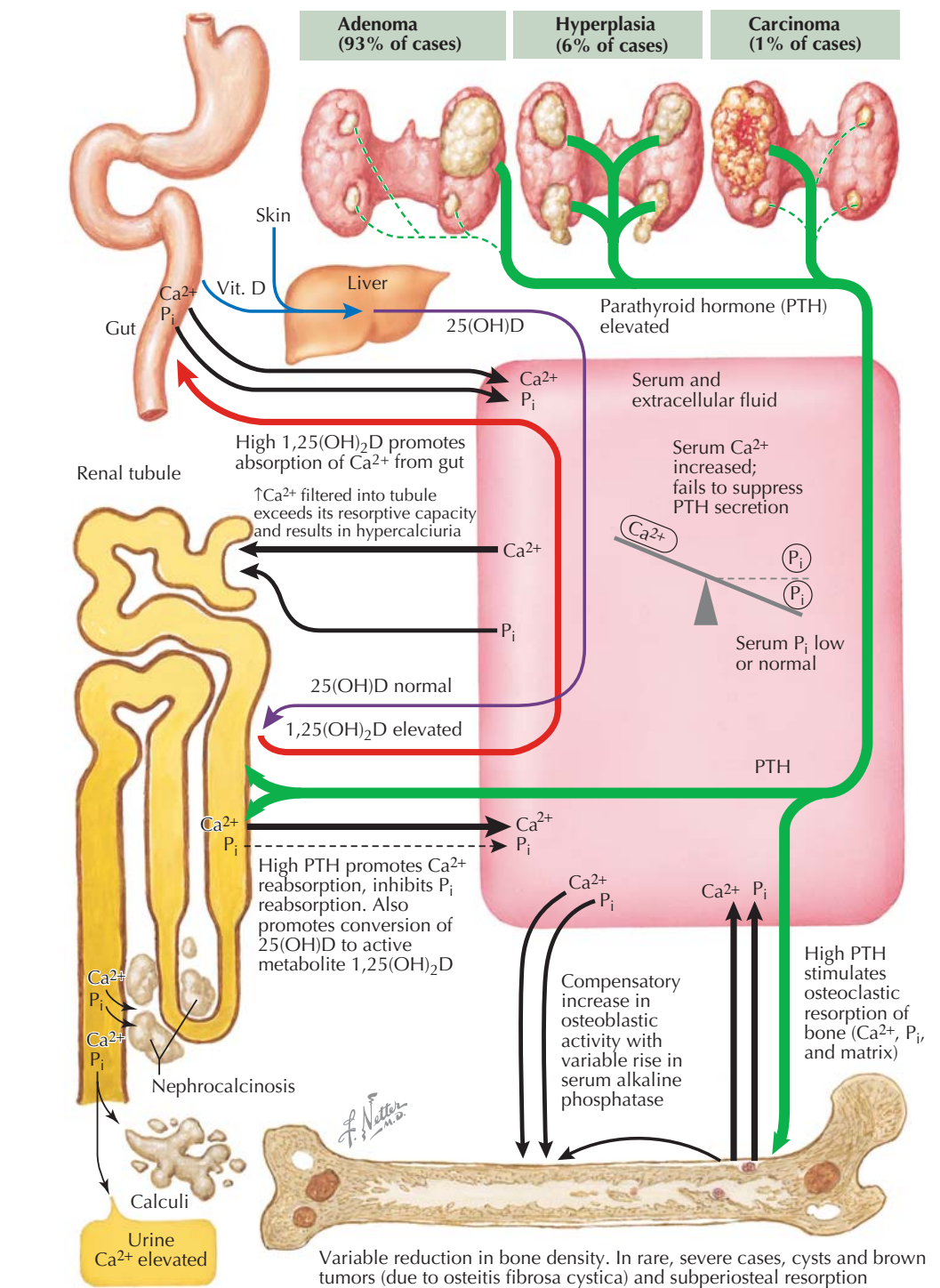
The annual incidence of primary hyperparathyroidism (HPT) is approximately four in 100,000. HPT is twice as common in women, and most patients are diagnosed after age 45 years. Primary HPT is caused by a single parathyroid adenoma (89%), multiple (“double”) parathyroid adenomas (4%), multigland parathyroid hyperplasia (6%), or parathyroid carcinoma (1%). The distinction between these forms of primary HPT directs the surgical approach.

Most parathyroid adenomas are encapsulated and arise from chief cells; the others are composed of oxyphilic cells. Parathyroid adenomas are usually localized to the neck, but ectopic parathyroid tumors may arise anywhere in the anterior mediastinum or even in the posterior mediastinum. The cells in the adenomas are monoclonal and are a result of somatic mutations in genes that control growth. For example, the cyclin D1 proto-oncogene (*CCND1*) encodes a major regulator of the cell cycle. Overexpression of cyclin D1 is found in approximately 30% of parathyroid adenomas. Multiple endocrine neoplasia (MEN) type 1 (see Plate 8-1) is caused by germline mutations in *MEN1*, a tumor suppressor gene, and somatic mutations are found in approximately 15% of sporadic parathyroid adenomas.

Multiple-gland hyperplasia, characterized by enlargement of all four glands, is occasionally mistaken for multiple adenomas. Chief cell hyperplasia is much more common than clear cell hyperplasia (the latter is associated with hyperplasia primarily of the superior parathyroid glands). Parathyroid hyperplasia may be sporadic or associated with a familial syndrome (e.g., MEN 1, MEN 2A, HPT–jaw tumor syndrome, or familial isolated hyperparathyroidism). Distinguishing between parathyroid gland hyperplasia and normal parathyroid tissue can be difficult for the pathologist. In general, abnormal parathyroid glands are increased in size and contain less fat. Primary HPT affects almost all patients with MEN 1, and the hypercalcemia is typically present by the third decade of life, but primary HPT affects only 10% of patients with MEN 2A and tends to occur later in life. Parathyroid adenomas and hyperplasia are multiple and cystic in patients with HPT–jaw tumor syndrome. The jaw tumor is usually fibrous in nature.

The diagnosis of parathyroid carcinoma is based on local invasion of contiguous tissues or metastases (lymph node or distant). Both sporadic and germline inactivating mutations in *CDC73* (previously known as *HRPT2*) are responsible for HPT–jaw tumor syndrome, which is associated with an increased risk for parathyroid carcinoma.

A normal serum concentration of ionized calcium ( $\text{Ca}^{2+}$ ) is critical for many extracellular and cellular functions, and it is normally maintained in the very narrow range through a tightly regulated calcium–PTH homeostatic system. In healthy individuals, a small decrease in serum ionized calcium triggers the calcium-sensing receptor, and there is a prompt increase in PTH secretion. The increased blood PTH concentration leads to an immediate increase in bone resorption and renal  $1\alpha$ -hydroxylation of 25-hydroxyvitamin D to the more potent 1, 25-dihydroxyvitamin D (calcitriol). Calcitriol leads to increased intestinal calcium absorption over several days. Finally, PTH leads to an immediate decrease in urinary calcium excretion by stimulating calcium reabsorption at the distal renal tubule. Because



of these three mechanisms of action, the serum ionized calcium concentration increases, and the serum PTH concentration decreases.

Patients with primary HPT have abnormal regulation of PTH secretion by calcium, a finding partly caused by an elevation in the set point. The set point for calcium-dependent feedback suppression of PTH release is 15% to 30% above normal. It is important to note that PTH secretion in primary HPT is not completely autonomous and can usually be partially inhibited by a further rise in serum calcium. The excessive production of PTH leads to hypercalcemia by increased stimulation of the osteoclastic activity of bone (with the release of calcium and phosphate), increased absorption of calcium from the gut, and increased reabsorption of calcium by the renal tubules. In addition, PTH inhibits

the tubular reabsorption of inorganic phosphate ( $\text{P}_i$ ), causing an excessive loss of phosphate. The net effect of these chemical changes is an increase in serum calcium and a decrease in serum phosphate, with increasing amounts of both calcium and phosphate being excreted in the urine. This predisposes to the formation of calcium phosphate and calcium oxalate renal stones. At times, there may be precipitation of calcium in the soft tissues of the kidneys, producing nephrocalcinosis.

Roughly 25% of patients with primary HPT have evidence of bone disease, with marked bone resorption and a compensatory increase in osteoblastic activity. Bone mineral is formed by small hydroxyapatite crystals that contain carbonate, magnesium, sodium, and potassium.



### PATHOLOGY AND CLINICAL MANIFESTATIONS OF PRIMARY HYPERPARATHYROIDISM

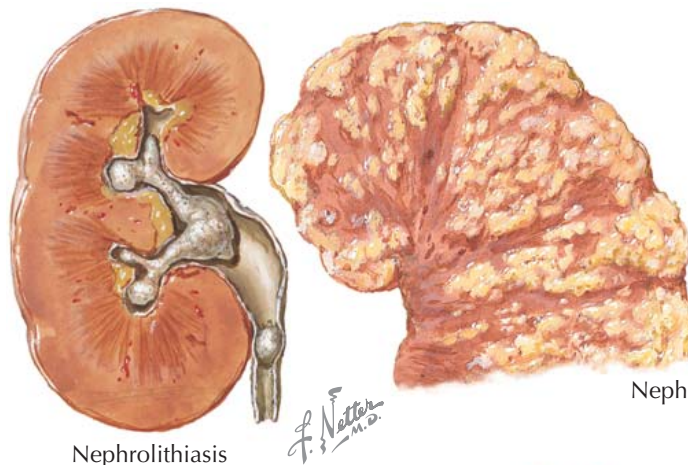
Approximately 80% of patients with primary hyperparathyroidism (HPT) are asymptomatic, and hypercalcemia is detected by routine biochemical testing. Less commonly, primary HPT is diagnosed during the evaluation of symptomatic hypercalcemia, renal lithiasis, osteoporosis, or osteitis fibrosa cystica. Although most patients with primary HPT do not have overt symptoms, it may be responsible for more subtle symptomatology (e.g., weakness, fatigue, depressed mood, or mild cognitive dysfunction).

The more overt signs and symptoms of long-standing, untreated primary HPT have been referred to as “bones, stones, abdominal moans, and groans.” The “stones” refer to nephrolithiasis, which occurs in 20% of patients with primary HPT. The nephrolithiasis is caused by the hypercalciuria (a result of increased filtered calcium in the setting of hypercalcemia) that predisposes to the development of calcium oxalate stones. The most common effect on bones is osteopenia and osteoporosis. Less common bone-related sequelae of severe, long-standing primary HPT include absence of the lamina dura around the teeth; subperiosteal resorption of the bone, especially around the radial margins of the phalanges, around the sternal end of the clavicle, and along the margins of other bones; diffuse “salt-and-pepper” decalcification of the skull, resembling multiple myeloma; fractures of the terminal phalanges with telescoping, giving the appearance of pseudoclubbing (the phalangeal joints may show increased flexibility); large bone cysts (osteitis fibrosa cystica) in various locations (fractures through these cysts or fractures through rarefied bone may occur); diffuse demineralization of the skeleton, especially of the spine, with “codfishing” of the vertebral bodies; and brown tumors (also known as giant cell tumors, osteoclastoma, or epulis), which are radiolucent bone tumors that may develop in the jaw and other bones.

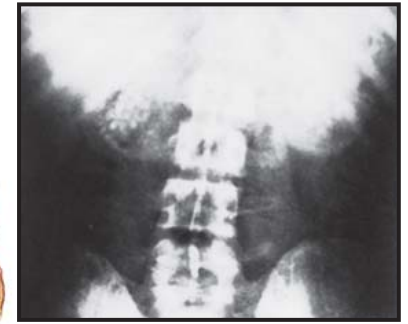
Hypercalcemia may also cause nausea, anorexia, constipation, nephrogenic diabetes insipidus (polyuria and polydipsia), glucose intolerance, peptic ulcer disease, pancreatitis, and hypertension. Parathyroid crisis occurs with severe hypercalcemia (calcium >15 mg/dL), and affected patients present with central nervous system dysfunction (e.g., confusion, coma). Parathyroid crisis—typically precipitated by volume depletion—is treated with volume repletion with isotonic saline and an agent to decrease bone resorption (e.g., a bisphosphonate).

Physical examination typically reveals no specific findings for primary HPT. Parathyroid adenomas are not palpable; when a parathyroid tumor is palpable, it is usually parathyroid carcinoma. With a slit-lamp examination of the eyes, calcium phosphate deposition may be seen in a semicircular form around the limbus of the cornea and is termed *band keratopathy*.

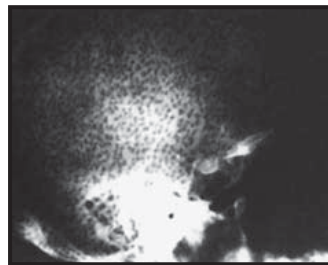
Laboratory abnormalities in patients with primary HPT include increased serum total and ionized calcium concentrations, decreased serum phosphorus concentration (parathyroid hormone [PTH] inhibits the proximal renal tubular reabsorption of phosphate), serum PTH concentration that is either above the reference range or inappropriately (in the setting of hypercalcemia) within the reference range, and increased serum



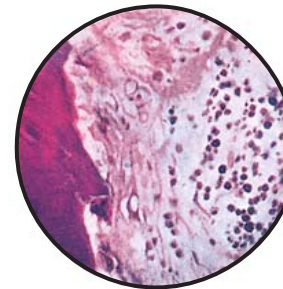
Nephrolithiasis



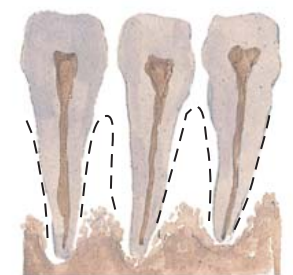Nephrocalcinosis



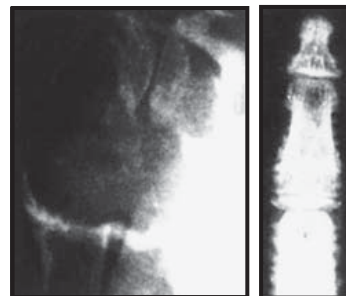
“Salt and pepper” skull



Bone biopsy (focal resorption)

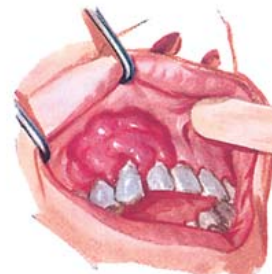

Absence of lamina dura (broken line indicates normal contour)

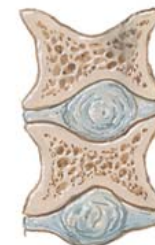


Bone rarefaction; cysts fractures

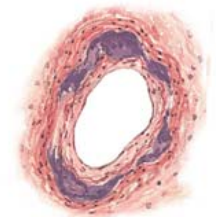
Subperiosteal resorption



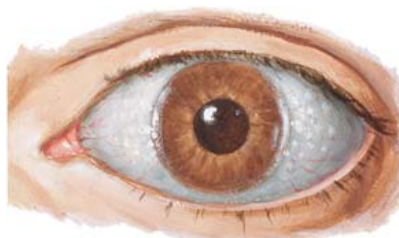Brown tumor (giant cell tumor or osteoclastoma)



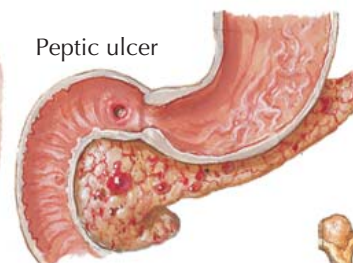
“Codfishing” of vertebrae



Calcium deposits in blood vessels; hypertension

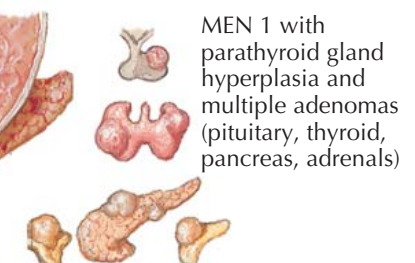


Limbus keratopathy



Peptic ulcer

Pancreatitis



MEN 1 with parathyroid gland hyperplasia and multiple adenomas (pituitary, thyroid, pancreas, adrenals)

calcitriol concentration (a result of PTH-stimulated renal hydroxylation of 25-hydroxyvitamin D). Serum creatinine concentrations can be increased in patients with marked and long-standing primary HPT and can be associated with nephrocalcinosis. Patients with severe primary HPT may also have a normochromic normocytic anemia.

Vitamin D deficiency is frequently present in patients with primary HPT, a state that can attenuate the degree

of hypercalcemia. Treating the vitamin D deficiency in this setting can aggravate the hypercalcemia and hypercalciuria.

The treatment of primary HPT rests on the surgical removal of the parathyroid adenoma (for single-gland disease) or, rarely, of 3.5 hyperplastic parathyroid glands in the setting of diffuse parathyroid hyperplasia (e.g., with multiple endocrine neoplasia [MEN] type 1).

## TESTS FOR THE DIFFERENTIAL DIAGNOSIS OF THE CAUSES OF HYPERCALCEMIA

The most common causes of hypercalcemia are primary hyperparathyroidism (HPT) and malignancy. The first question the clinician should ask is whether the hypercalcemia is a persistent finding; thus, a serum calcium ( $\text{Ca}^{2+}$ ) concentration should be remeasured. If levels of serum calcium have been measured in the past, they should be reviewed. Whereas long-standing mild hypercalcemia ( $<11$  mg/dL) is typical of primary HPT, an abrupt onset of severe hypercalcemia ( $>13$  mg/dL) is more typical of hypercalcemia of malignancy. The patient's diet and medications should be reviewed for clues suggestive of milk-alkali syndrome and medication-related hypercalcemia.

For patients with persistent hypercalcemia, the first step is to determine whether it is parathyroid hormone (PTH) mediated. Whereas PTH-mediated hypercalcemia is primary HPT, non-PTH-mediated hypercalcemia is usually caused by underlying malignancy, granulomatous disease, or vitamin D intoxication.

### PARATHYROID HORMONE-MEDIATED HYPERCALCEMIA




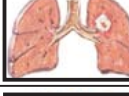


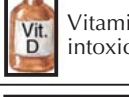


Most patients with primary HPT have serum PTH concentrations above the reference range. However, 20% of patients with primary HPT have serum PTH concentrations in the upper portion of the reference range, but they are inappropriately in the reference range for the setting of hypercalcemia. Measurement of serum inorganic phosphate ( $\text{P}_i$ ) concentration and 24-hour urinary excretion of calcium are usually helpful in confirming PTH-mediated disease. Hypophosphatemia results from the PTH-related inhibition of renal proximal tubular phosphate reabsorption. Although hypophosphatemia may also be seen with PTH-related protein (PTHrP)-mediated hypercalcemia, it is not seen with the other forms of non-PTH-mediated hypercalcemia. The 24-hour urinary excretion of calcium is either at the high end of the reference range or above the reference range in most patients with primary HPT. However, this finding is not specific to primary HPT and is seen with most other causes of hypercalcemia. The 24-hour urinary excretion of calcium is typically less than 100 mg in patients with milk-alkali syndrome or familial hypocalciuric hypercalcemia or in patients treated with thiazide diuretics. Serum 1,25-dihydroxyvitamin D (calcitriol;  $1,25[\text{OH}]_2\text{D}$ ) concentrations are usually increased in patients with primary HPT because PTH increases the  $1\alpha$ -hydroxylation of 25-hydroxyvitamin D (calcidiol;  $25[\text{OH}]\text{D}$ ) in the kidney.

### NON-PARATHYROID HORMONE-MEDIATED HYPERCALCEMIA

When the serum PTH concentration is low in a patient with hypercalcemia, additional stepwise testing to consider includes measurement of  $25(\text{OH})\text{D}$ ,  $1,25(\text{OH})_2\text{D}$ , PTHrP, serum thyrotropin (TSH) (for hyperthyroidism), and vitamin A and performance of serum protein electrophoresis (for multiple myeloma).

PTHrP—the hormone responsible for humoral hypercalcemia of malignancy—is an agonist at the PTH receptor and may be hypersecreted by solid malignancies. However, unlike PTH, PTHrP does not induce renal conversion of  $25(\text{OH})\text{D}$  to  $1,25(\text{OH})_2\text{D}$ .

### DIFFERENTIAL DIAGNOSIS OF HYPERCALCEMIC STATES

| Condition  | Serum $\text{Ca}^{2+}$ | Serum $\text{P}_i$ | Serum PTH   | Serum $25(\text{OH})\text{D}$ | Serum $1,25(\text{OH})_2\text{D}$ | Associated findings  |
|--|------------------------|--------------------|-------------|-------------------------------|-----------------------------------|--|
|  Primary hyperparathyroidism                  | ↑                      | N or ↓             | High N or ↑ | N                             | N or ↑                            | 80% Asymptomatic<br>Nephrolithiasis<br>Osteoporosis<br>Hypercalcemic sx                                      |
|  Cancer with extensive bone metastases        | ↑                      | N or ↑             | ↓           | N                             | ↓ or N                            | History of primary tumor, destructive lesions on radiograph, bone scan                                       |
|  Multiple myeloma and lymphoma                | ↑                      | N or ↑             | ↓           | N                             | ↓ or N                            | Abnormal serum or urine protein electrophoresis, abnormal bone radiographs                                   |
|  Humoral hypercalcemia of malignancy          | ↑                      | N or ↓             | ↓           | N                             | ↓ or N                            | ↑PTHrP<br>Solid malignancy usually evident   |
|  Sarcoidosis and other granulomatous diseases | ↑                      | N or ↑             | ↓           | N                             | ↑                                 | Hilar adenopathy<br>interstitial lung disease,<br>elevated angiotensin-converting enzyme                     |
|  Hyperthyroidism                              | ↑                      | N                  | ↓           | N                             | N                                 | Symptoms of hyperthyroidism, elevated serum thyroxine  |
|  Vitamin D intoxication                      | ↑                      | N or ↑             | ↓           | Very ↑                        | N or ↑                            | History of excessive vitamin D intake  |
|  Milk-alkali syndrome                       | ↑                      | N or ↑             | ↓           | N                             | N or ↓                            | History of excessive calcium and alkali ingestion, heavy use of over-the-counter calcium-containing antacids |
|  Total body immobilization                  | ↑                      | N or ↑             | ↓           | N                             | ↓ or N                            | Multiple fractures, paralysis (children, adolescents, patients with Paget disease of bone)                   |

If the serum concentration of PTHrP is low, serum concentrations of  $25(\text{OH})\text{D}$  and  $1,25(\text{OH})_2\text{D}$  should be measured. Whereas a markedly increased serum concentration of  $25(\text{OH})\text{D}$  is consistent with vitamin D intoxication, increased serum concentrations of  $1,25(\text{OH})_2\text{D}$  may be seen with the enhanced extrarenal  $1\alpha$ -hydroxylation of  $25(\text{OH})\text{D}$  that occurs in granulomatous disorders and lymphoma. In this setting, sarcoidosis is usually evident on a plain chest radiograph or computed tomography; these images usually demonstrate bilateral hilar adenopathy and reticular pulmonary opacities.

If vitamin D and PTHrP levels are low in a patient with non-PTH-mediated hypercalcemia, then serum protein electrophoresis should be performed, and serum TSH and vitamin A concentrations should be measured. In this setting, hypercalcemia is usually associated with stimulation of bone resorption (e.g., multiple myeloma, hyperthyroidism, vitamin A intoxication, or immobilization) or increased calcium intake in the setting of renal insufficiency (milk-alkali syndrome).

### OTHER CAUSES OF APPARENT HYPERCALCEMIA

Increased serum total calcium concentration is usually the result of an increased amount of free (ionized)

calcium—the physiologically relevant fraction. Rarely, an increased measured amount of total blood calcium may be attributable to increased amounts of calcium bound to protein (e.g., in multiple myeloma with increased calcium-binding paraprotein) and the ionized fraction is normal; this is termed *pseudohypercalcemia*.

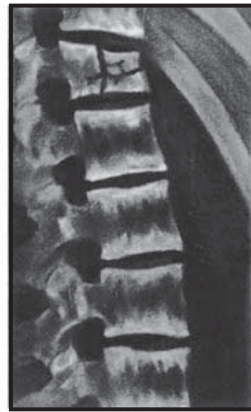Familial hypocalciuric hypercalcemia (FHH) is a rare autosomal dominant disorder associated with an inactivating mutation in the gene encoding the calcium-sensing receptor. Typically identified because of incidental discovery of hypercalcemia, these patients have hypocalciuria with the fractional urinary excretion of calcium less than 1%. Patients with FHH have mild hypercalcemia with either normal or slightly increased concentrations of serum PTH. The mutation responsible for FHH makes the calcium-sensing receptor less sensitive to calcium. Thus, a higher than normal serum calcium concentration is required to reduce PTH release; an increase in tubular calcium and magnesium reabsorption in the kidney results in hypercalcemia, hypocalciuria, and hypermagnesemia. These patients are asymptomatic; FHH has a benign natural history, and no treatment is required. All first-degree relatives should be tested for hypercalcemia and alerted that it is not primary HPT and that no surgery is needed.



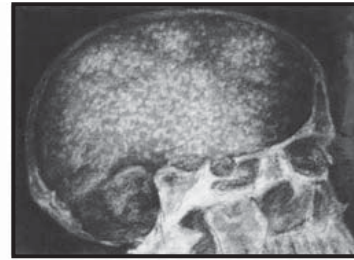


**BONY MANIFESTATION OF RENAL OSTEODYSTROPHY**

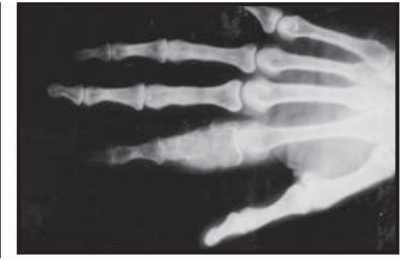Secondary hyperparathyroidism



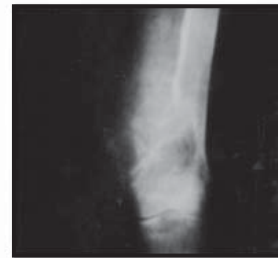Radiograph shows banded sclerosis of spine and sclerosis of upper and lower margins of vertebrae, with rarefaction between. Note compression fracture.



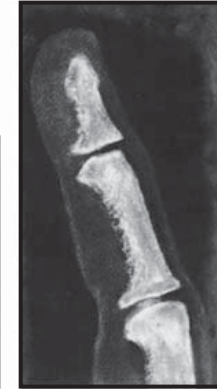Radiograph shows spotty decalcification of skull ("salt-and-pepper" skull)



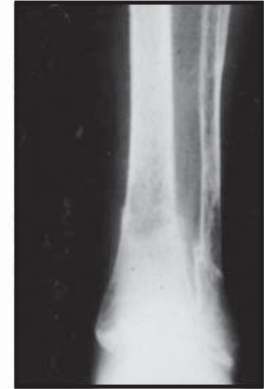Brown tumor of proximal phalanx



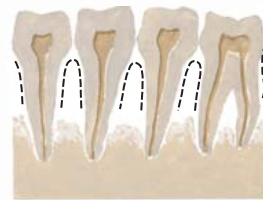Osteitis fibrosa cystica of distal femur



Subperiosteal resorption of phalanges (chiefly on palmar aspect of middle phalanx)



Osteitis fibrosa cystica of tibia with brown tumor



Loss of lamina dura of teeth (*broken lines indicate normal contours*)

**RENAL OSTEODYSTROPHY**

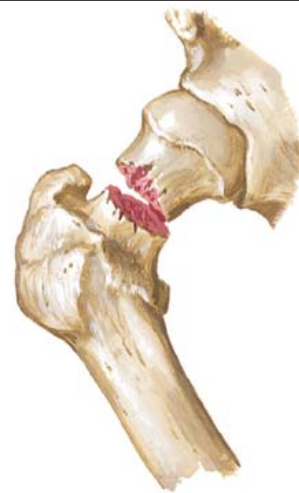(Continued)

Subperiosteal resorption of the phalanges may be evident—primarily on the palmar aspect of the middle phalanx. In children, renal osteodystrophy results in growth retardation and skeletal deformities.

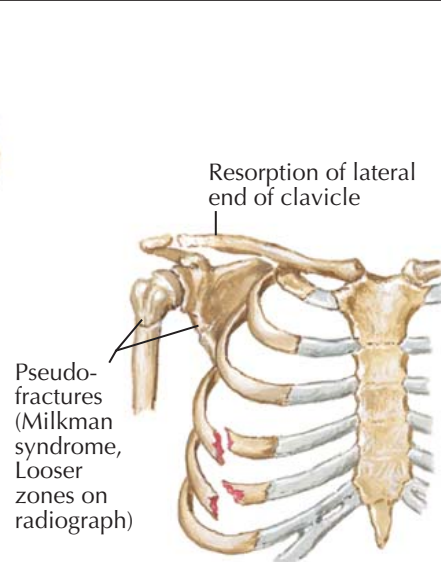
The most common bony abnormality in patients treated with peritoneal dialysis or hemodialysis is adynamic bone disease—bone turnover does not occur, and bone cell activity is absent. Unlike what is observed with osteomalacia, osteoid formation does not increase. Adynamic bone disease is, in part, a result of excess PTH suppression with calcium-based phosphate binders and vitamin D analogues. Adynamic bone disease predisposes to bone fractures (e.g., hip fracture). This disorder can be confirmed by bone biopsy or by a serum PTH concentration less than 100 pg/mL. The key to treatment is to allow PTH to increase by decreasing or discontinuing calcium-based phosphate binders and vitamin D analogues.

Osteomalacia is the result of decreased bone turnover and an increase in unmineralized bone caused by either vitamin D deficiency or aluminum intoxication (the latter from aluminum-containing antacids). There is decreased bone density with thinning of the cortex. Looser zones are a characteristic radiologic finding in osteomalacia (see Plates 6-8 and 6-22). Looser zones are pseudofractures or narrow radiolucent lines (2–5 mm in width) with sclerotic borders that lie perpendicular to the cortical margin. Frequently bilateral and symmetric, they are located in the scapula, femoral neck, medial part of the femoral shaft, ribs, pubic and ischial rami, and clavicle. Bone resorption may be seen at the lateral ends of the clavicles. Milkman syndrome refers to the findings of bilateral and symmetric pseudofractures in a patient with osteomalacia. Fractures may occur with minimal or no trauma and usually involve the long bones (e.g., hip), ribs, and vertebral bodies. A bone biopsy—usually obtained from the iliac

Osteomalacia



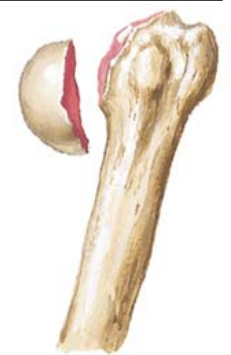Fracture of long bones



Pseudo-fractures (Milkman syndrome, Looser zones on radiograph)

Resorption of lateral end of clavicle

Fractured ribs



Slipped capital femoral epiphysis

crest after the administration of tetracycline markers to determine the rate of new bone formation (see Plate 6-22)—may be needed to determine the pathogenesis of renal osteodystrophy.

Other contributing factors to bone disease in patients with renal failure include vitamin K deficiency (required for carboxylation of bone matrix proteins) and bone morphogenetic protein-7 (required for normal osteoblast differentiation and produced in the normal kidney).

The goals of treatment should be to maintain normal serum calcium and phosphorus concentrations while minimizing the exposure to aluminum. These targets are achieved by a low-phosphate diet, addition of phosphate binders when GFR is below 25% of normal, and vitamin D supplementation to maintain a normal blood concentration of 1,25(OH)<sub>2</sub>D. With advanced renal failure and tertiary HPT, parathyroidectomy may be indicated.



## HISTOLOGY OF THE PARATHYROID GLANDS IN HYPERPARATHYROIDISM

Primary hyperparathyroidism (HPT) is caused by a single parathyroid adenoma (89%), multiple (“double”) parathyroid adenomas (4%), multigland parathyroid hyperplasia (6%), or parathyroid carcinoma (1%).

### PARATHYROID ADENOMA

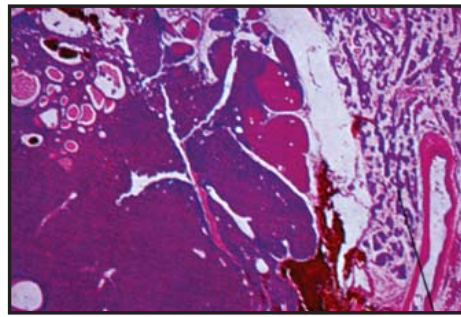
Most parathyroid adenomas are encapsulated and arise from chief cells; the others are composed of oxyphilic cells. The adenoma is composed of tightly packed sheets, cords, and acini of predominantly chief cells. Clear cells and oxyphilic cells, singly and in groups, are often present, and some adenomas may be composed entirely of oxyphilic cells. The tumor may be homogeneous or nodular. The chief cell of an adenoma is usually somewhat larger than a normal chief cell. The nuclei are variable in size, and mononuclear giant cells with hyperchromatic nuclei, not indicative of malignancy, are often present. Multinuclear giant cells are frequently seen in adenomas. Immunohistochemical staining is typically positive for parathyroid hormone (PTH) and chromogranin A. The most important criterion for differentiating an adenoma from chief cell hyperplasia is the identification of normal parathyroid tissue in a patient with an adenoma; this may occur either as a rim outside the capsule of the adenoma or in another gland. This “normal” parathyroid in the presence of an adenoma is composed almost entirely of large, light, inactive chief cells, with abundant glycogen, small Golgi apparatuses, and rare secretory granules. The cells in the adenomas are monoclonal and result from somatic mutations in genes that control growth. For example, the cyclin D1 proto-oncogene (*CCND1*) encodes a major regulator of the cell cycle. Overexpression of cyclin D1 is found in approximately 30% of parathyroid adenomas. Multiple endocrine neoplasia (MEN) type 1 is caused by germline mutations in *MEN1*, a tumor suppressor gene, and somatic mutations are found in approximately 15% of sporadic parathyroid adenomas.

### PRIMARY CHIEF CELL HYPERPLASIA

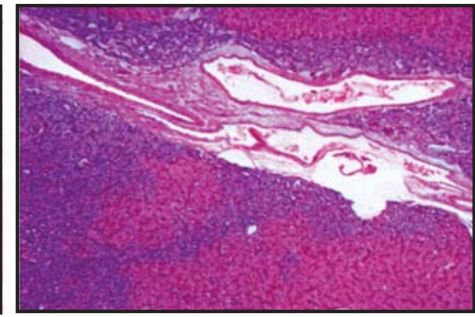
Chief cell hyperplasia is much more common than clear cell hyperplasia (the latter is associated with hyperplasia primarily of the superior parathyroid glands). In hyperplasia, all four glands are invariably involved. Each gland is composed of cords; sheets; and acini of tightly packed chief, oxyphilic, and clear cells. The cells are similar in size to or slightly more enlarged than normal cells. The gland is often nodular, owing to separation of the cells by stroma or to aggregation of cell types. In primary chief cell hyperplasia, the appearance of each gland may be identical to that of an adenoma except for the absence of normal parathyroid tissue. Immunohistochemical studies show diffuse staining for PTH and chromogranin A. Parathyroid hyperplasia may be sporadic or associated with a familial syndrome (e.g., MEN 1, MEN 2A, hyperparathyroidism–jaw tumor syndrome, or familial isolated hyperparathyroidism).

### PRIMARY CLEAR CELL HYPERPLASIA

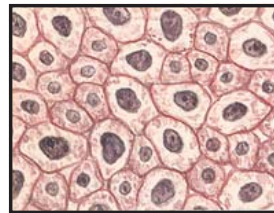
The four glands are composed of sheets; cords; and acini of uniform, large (10–40  $\mu\text{m}$ ) cells, with distinct



**Adenoma.** Rim of relatively normal parathyroid tissue about compact adenoma; H & E stain,  $\times 11.5$

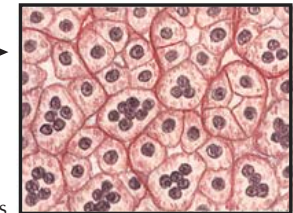


**Adenoma.** Mixture of oxyphil cells and chief cells in adenoma; H & E stain,  $\times 35$

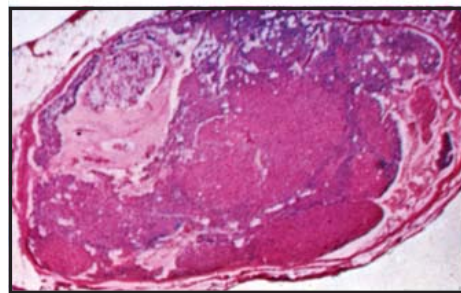


Mononuclear giant cells

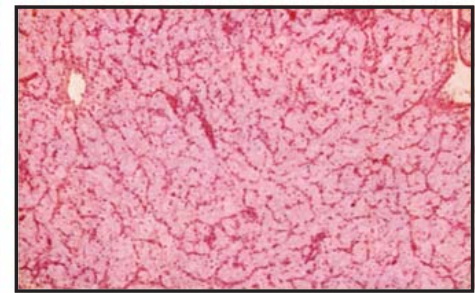
← Frequent characteristics of chief cells in adenomas →



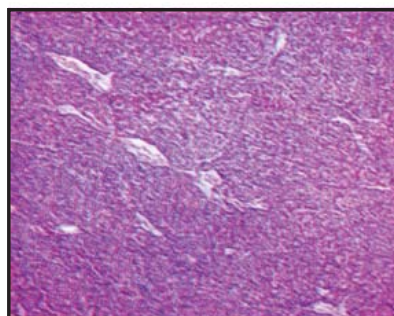
Multinuclear giant cells and acinar structures



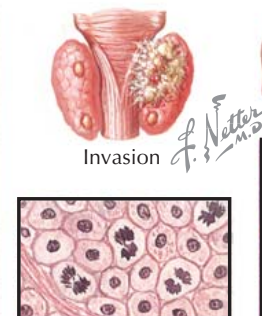**Primary hyperplasia: chief cell**



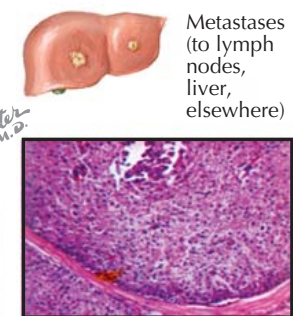
**Primary hyperplasia: clear cell**



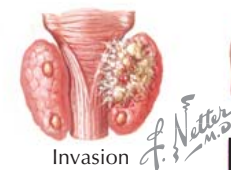**Secondary hyperplasia**



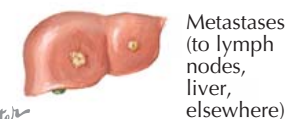
Mitosis



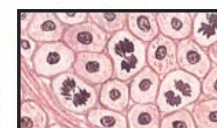
Fibrous bands and hyperchromicity



Invasion



Metastases (to lymph nodes, liver, elsewhere)



**Carcinoma**

cell membranes and empty-appearing cytoplasm (wasserhelle cells). The nuclei are small and densely stained. There is a tendency for nuclear palisading, generally at the pole of the cell adjacent to the stroma and vessel, giving a “bunch of berries” appearance. Immunohistochemical staining is usually weak for PTH and strong for chromogranin A.

### SECONDARY PARATHYROID GLAND HYPERPLASIA

Secondary parathyroid gland hyperplasia is often indistinguishable from primary chief cell hyperplasia, although nodularity is somewhat less common in secondary hyperplasia, and each gland is often composed of uniform sheets of small, dark chief cells. Oxyphilic cells and clear cells are occasionally seen.

Immunohistochemical staining is typically positive for PTH and chromogranin A.

### CARCINOMA

The diagnosis of parathyroid carcinoma is based on local invasion of contiguous tissues or metastases (lymph node or distant). A large, dense, fibrous capsule (with invasion of the capsule) and broad, dense, fibrous bands traversing the tumor are present. The cells are large and uniform and have distinct cell membranes. The nuclei are large, regular, and hyperchromatic. Mitotic figures are almost invariably seen. A rim of normal parathyroid tissue may rarely be noted. Both somatic and germline inactivating mutations in *CDC73* (formerly *HRPT2*) are responsible for hyperparathyroidism–jaw tumor syndrome, which is associated with an increased risk for parathyroid carcinoma.



### **PATHOPHYSIOLOGY OF HYPOPARATHYROIDISM**

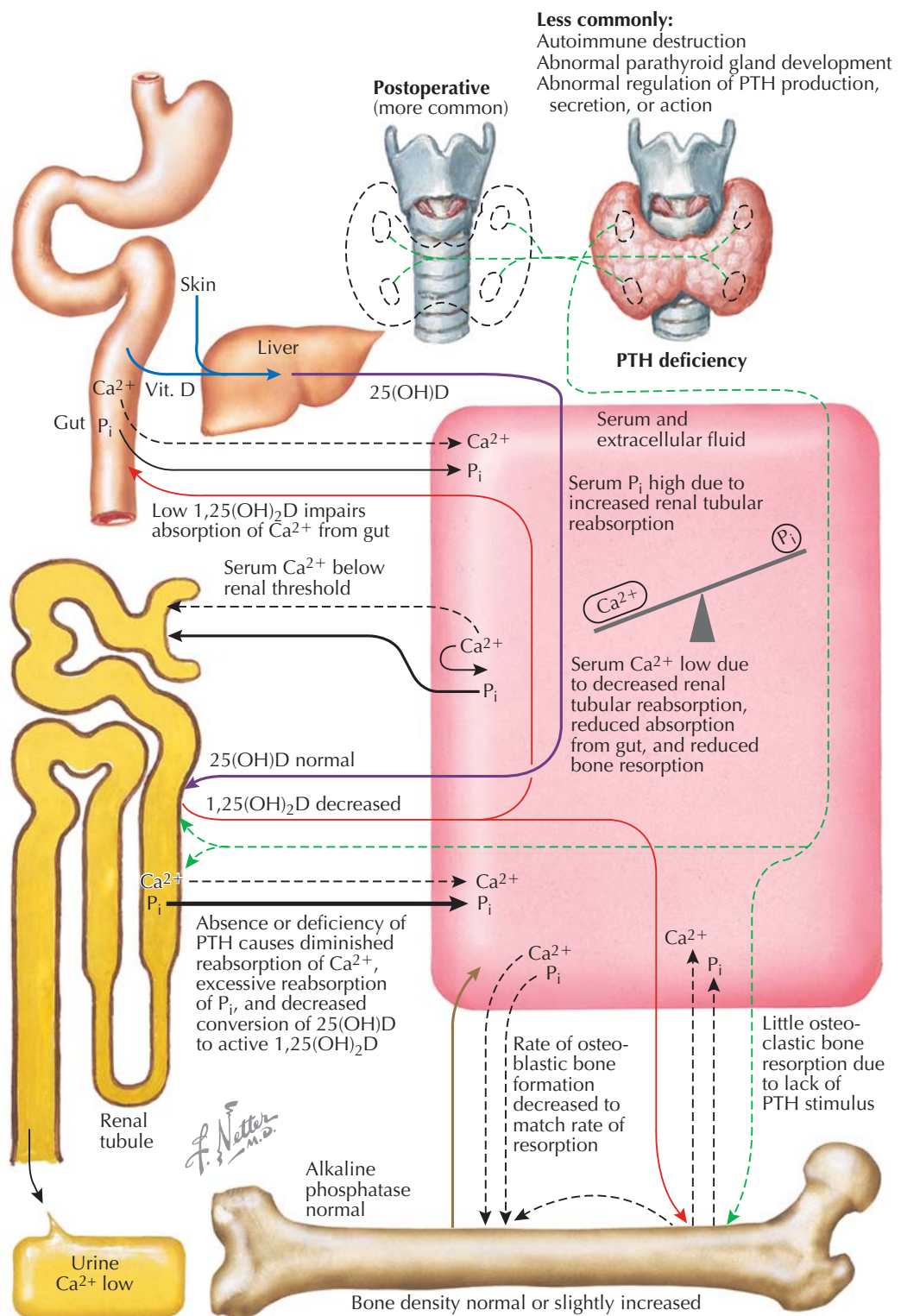
The chemical picture of hypoparathyroidism is a low serum calcium concentration (usually <7 mg/dL), a high serum inorganic phosphorus (P<sub>i</sub>) concentration (typically >5 mg/dL), and decreased excretion of calcium and phosphorus in the urine. These chemical features can be explained by the absence of the major actions of parathyroid hormone (PTH). The calcium level is low because of the following: (1) decreased PTH-dependent stimulation of the osteoclastic activity of bone, causing little resorption of calcium and (2) decreased PTH-dependent stimulation of the renal conversion of 25-hydroxyvitamin D (25(OH)D) to the more potent 1,25-dihydroxyvitamin D (1,25(OH)<sub>2</sub>D), with resultant diminished absorption of calcium from the gastrointestinal tract. Because the serum calcium level is usually below the kidney threshold of 7 mg/dL, little urinary calcium is found. By contrast, the serum phosphorus concentration is elevated because there is excessive reabsorption of phosphate by the renal tubules, which is not blocked by PTH. The high serum phosphorus level has the additional effect of depressing the serum calcium level. A great deal of calcium is “bound” in the gastrointestinal tract by the high phosphate concentration, and the action of vitamin D on calcium absorption is less effective in the presence of high phosphate concentrations. The combination of a low serum calcium concentration, a high serum phosphorus level, and a normal alkaline phosphatase concentration in the absence of renal failure or malabsorption is pathognomonic of a state of hypoparathyroidism.

PTH deficiency is most commonly seen as a complication after neck surgery (e.g., subtotal or total thyroidectomy, parathyroid gland surgery, or neck cancer surgery). Surgery-induced hypoparathyroidism may be transient (if viable parathyroid tissue persists) or permanent. Transient hypoparathyroidism may complicate as many as 20% of operations for thyroid cancer that require total or near-total thyroidectomy. Transient hypoparathyroidism is also seen in patients after resection of a parathyroid adenoma associated with severe and long-standing hypercalcemia. In this setting, the normal parathyroid glands are suppressed, and calcium is avidly taken up by the bones (“hungry bone syndrome”). Less commonly, the cause of hypoparathyroidism may relate to autoimmune destruction; abnormal parathyroid gland development; or abnormal regulation of PTH production, secretion, or action.

When hypoparathyroidism is acquired in a patient who has not had neck surgery, it most commonly results from autoimmune destruction of the parathyroid glands. Autoimmune hypoparathyroidism usually occurs as part of the polyglandular autoimmune syndrome type 1; these patients are also at increased risk for primary adrenal insufficiency and chronic mucocutaneous candidiasis (see Plate 8-6). A rarer cause of acquired primary hypoparathyroidism is the development of activating autoantibodies to the calcium-sensing receptor (CaSR).

### **GENETIC CAUSES OF HYPOPARATHYROIDISM**

Congenital hypoparathyroidism is associated with abnormal parathyroid development or PTH synthesis.



**Less commonly:**  
 Autoimmune destruction  
 Abnormal parathyroid gland development  
 Abnormal regulation of PTH production, secretion, or action

Abnormal parathyroid gland development may be caused by X-linked or autosomal recessive mutations (e.g., mutations in *GCM2*, a gene encoding a transcription factor). Mutations in the gene responsible for the synthesis of preproPTH may result in defects of the production of biologically active PTH. In addition, autosomal dominant activating mutations in gene encoding the CaSR decrease the set point for calcium feedback; thus, PTH secretion is not triggered until the patient is markedly hypocalcemic. Because of the activated CaSR at the kidney, the urinary calcium excretion is high (unlike what is observed in all other forms of hypoparathyroidism).

### **PSEUDOHYPOPARATHYROIDISM—HYPOCALCEMIA DESPITE A HIGH SERUM PARATHYROID HORMONE CONCENTRATION**

In patients with pseudohypoparathyroidism, the hypocalcemia stimulates release of PTH from the parathyroid glands. However, because PTH is ineffective in mobilizing calcium from bone or in increasing the renal conversion of 25(OH)D to 1,25(OH)<sub>2</sub>D, hypocalcemia persists. The causes of this clinical scenario include PTH resistance and vitamin D deficiency (see Plates 6-12 and 6-13).



## CLINICAL MANIFESTATIONS OF ACUTE HYPOCALCEMIA

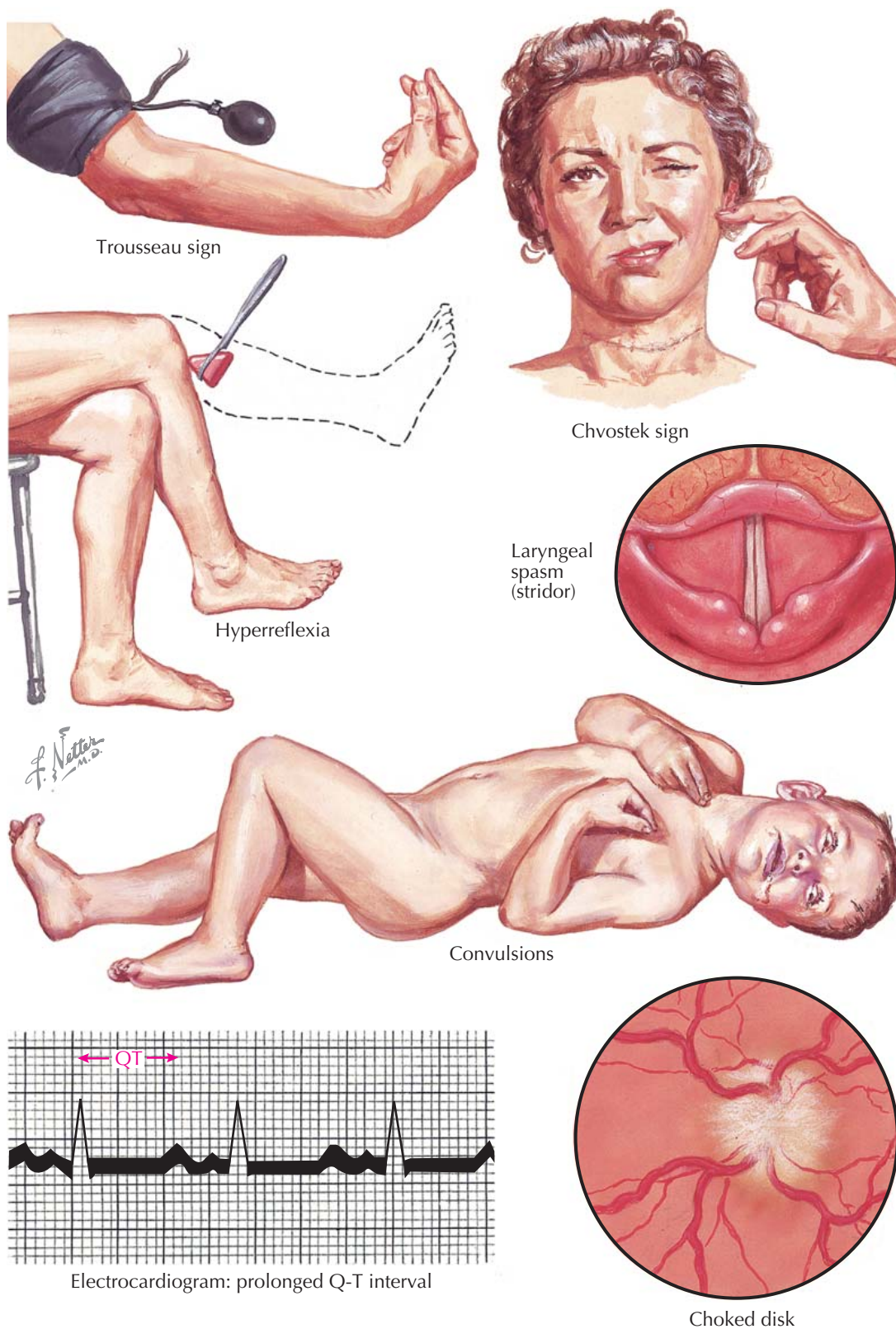
The classic manifestations of acute hypocalcemia vary from minor to severe symptoms with tetany, seizures, laryngospasm, papilledema (choked disk), or heart failure. The degree of symptoms relates not only to the severity of hypocalcemia but also to the rapidity of onset. The dominant clinical features of chronic hypocalcemia are cataracts, basal ganglia calcification, extrapyramidal disorders, and changes in dentition.

Tetany is the result of acute increased peripheral neuromuscular irritability; early and mild symptoms include anxiety, muscle spasms and cramps, hyperreflexia, photophobia, diplopia, perioral and acral paresthesias, and hyperirritability. Advanced and more severe symptoms of tetany include carpopedal spasm (the forced adduction of the thumb, extension of the fingers, and flexion of the wrist and metacarpophalangeal joints), laryngospasm and stridor (caused by muscular spasm of the glottis), and seizures (grand mal, petit mal, or focal). Tetany usually does not occur unless the serum total calcium concentration falls below 7.0 mg/dL. However, tetany may be aggravated by alkalosis, hypomagnesemia, and hypokalemia. Patient anxiety related to the perioral and acral paresthesias may lead to hyperventilation, resulting in respiratory alkalosis that further aggravates tetany. Acidosis can completely suppress the clinical manifestations of hypocalcemia.

The Trousseau sign is the induction of carpopedal spasm by inflating a sphygmomanometer cuff above the systolic blood pressure for 3 minutes. For example, if the systolic blood pressure is 120 mm Hg, the sphygmomanometer cuff should be inflated to 140 mm Hg and kept it at that pressure for 3 minutes. The ischemia induced by the Trousseau maneuver increases the excitability of the forearm nerve trunks. With a positive Trousseau sign, patients are unable to open the hand.

The Chvostek sign is the demonstration of ipsilateral facial muscle contraction by tapping the facial nerve just anterior to the ear and below the zygoma. In severe hypocalcemic states, contracture of the orbicularis oculi and even contraction of the contralateral facial muscles may be seen. Both the Trousseau and Chvostek signs are not specific for hypocalcemia; they can also be elicited in alkalotic states (e.g., hyperventilation, primary aldosteronism with severe hypokalemia).

Dental anomalies (e.g., defective enamel, dental hypoplasia) can occur if hypocalcemia is present in early



development. Chronic hypocalcemia usually results in dry and coarse skin. The fingernails may become brittle and have transverse grooves. Scalp hair can be sparse, coarse, and brittle.

In addition to hypocalcemia-related heart failure, the Q-T interval on electrocardiography may be prolonged. QRS and ST changes may mimic acute myocardial infarction. Hypocalcemia can trigger torsades de pointes.

The most common cause of severe hypocalcemia is acute hypoparathyroidism related to the removal of a parathyroid neoplasm or accidental removal of the parathyroid glands at the time of thyroid surgery.

The diagnosis of severe and symptomatic hypocalcemia is an endocrine emergency, and immediate treatment is indicated to prevent seizures, laryngospasm, cardiac events, and death. Correction of the hypocalcemia reverses the signs and symptoms.

**PATHOPHYSIOLOGY OF PSEUDOHYPOPARATHYROIDISM**

Pseudohypoparathyroidism (PHP) is the result of end-organ resistance to parathyroid hormone (PTH). The key laboratory findings are hypocalcemia, hyperphosphatemia, and increased blood PTH concentration. There are two forms of PHP, known as type 1 and type 2.

**PSEUDOHYPOPARATHYROIDISM TYPE 1**

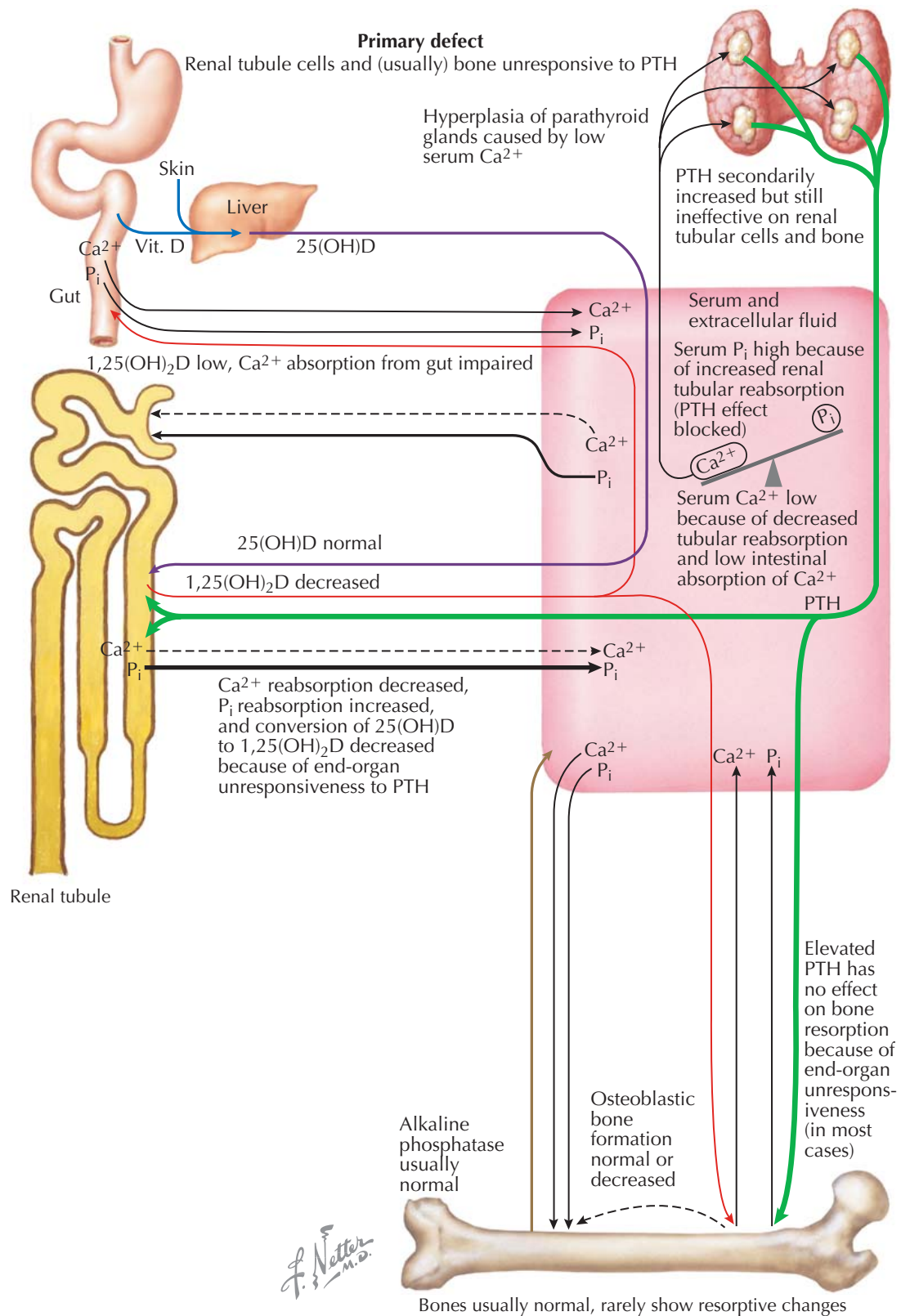
PHP type 1 is characterized by decreased renal production of cyclic adenosine monophosphate (cAMP) when exogenous PTH is administered. The pathophysiology of this type of PHP relates to mutations in the gene encoding the  $\alpha$ -subunit of the G protein (*GNAS*) that is coupled to the PTH receptor. Mutations in *GNAS* lead to lack of adenylyl cyclase activation when PTH binds to its receptor. This lack of signal transduction prevents PTH activity. *GNAS* is associated with tissue-specific parental imprinting. For example, *GNAS* expression in the kidney, pituitary, gonads, and thyroid is determined by the maternal allele. This tissue-specific parental imprinting has led to a subclassification of PHP type 1 into three subtypes.

PHP type 1a, also known as Albright hereditary osteodystrophy, is caused by an autosomal dominant, maternally transmitted loss-of-function mutation in *GNAS*. PHP type 1a has a unique phenotype with short stature, a rounded face, obesity, ocular abnormalities, short fourth and fifth metacarpals, dental hypoplasia, developmental delay, mental retardation, and subcutaneous calcifications (see Plate 6-13). The secondary hyperparathyroidism found in PHP type 1a is ineffective in producing phosphaturia because the renal tubule is relatively unresponsive, but in some instances, the other end-organ, bone, can show overstimulation of the osteoclasts, and bone resorptive changes may be seen. PTH is also ineffective in converting 25-hydroxyvitamin D (25[OH]D) to the more potent 1,25-dihydroxyvitamin D (1,25[OH]<sub>2</sub>D). Because individuals with PHP type 1a PHP also have resistance to other G-coupled hormones (at the thyroid, pituitary, and gonads), they may have signs and symptoms of thyroid and gonadal dysfunction.

Pseudopseudohypoparathyroidism occurs when the inactivating *GNAS* mutation is paternally transmitted. Affected individuals have the body phenotype characteristic of Albright hereditary osteodystrophy but without resistance to PTH action at the kidney because of the presence of the normal maternal allele. Thus, these individuals have normal blood concentrations of calcium, phosphate, and PTH. However, they can have excessive dermal ossification caused by progressive osseous heteroplasia.

PHP type 1b is caused by maternal transmission of mutations in the regulatory elements for *GNAS*. These individuals lack the characteristic body phenotype of Albright hereditary osteodystrophy but have PTH resistance at the kidney. Thus, affected patients have hypocalcemia, hyperphosphatemia, and increased blood PTH concentrations.

PHP type 1c is caused by mutations that affect the coupling of the G protein to the PTH receptor. Thus, the adenylyl cyclase system is intact, but it is not coupled to the binding of PTH to its receptor. These patients have the body phenotype characteristic of Albright hereditary osteodystrophy, hypocalcemia, hyperphosphatemia, and increased blood PTH concentrations.



**PSEUDOHYPOPARATHYROIDISM TYPE 2**

Individuals with PHP type 2 have the same biochemical profile as those with PHP type 1, which includes hypocalcemia, hyperphosphatemia, and increased blood concentrations of PTH. Individuals with PHP type 2 do not have the body phenotype characteristic of Albright hereditary osteodystrophy and do not have resistance to other hormones. In addition, they have a

normal renal cAMP response to exogenous PTH administration. However, PTH does not lead to phosphaturia. Thus, the PTH receptor-adenylyl cyclase complex functions normally, but the resistance is at the level of activity of cAMP, suggesting a defect in cAMP-dependent protein kinase A. PHP type 2 is not familial, and the age of onset ranges from infancy to senescence. Thus, PHP type 2 is an acquired disorder; however, the precise cause has not yet been determined.

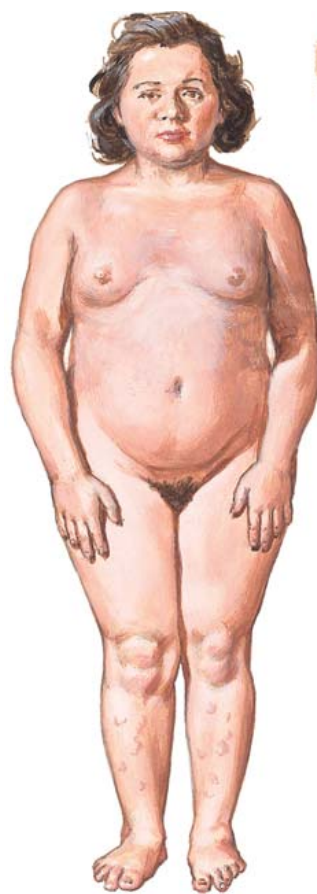

## CLINICAL MANIFESTATIONS OF PSEUDOHYPOPARATHYROIDISM TYPE 1A

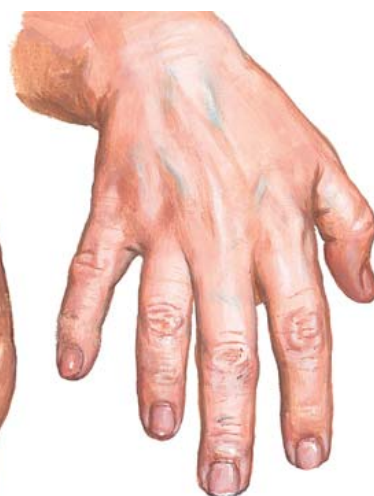Pseudohypoparathyroidism (PHP) is a congenital disorder associated with end-organ resistance to parathyroid hormone (PTH). PHP type 1a, also known as Albright hereditary osteodystrophy, is caused by an autosomal dominant, maternally transmitted loss-of-function mutation in *GNAS* (see Plate 6-12). Affected children usually develop symptomatic hypocalcemia between ages 3 and 8 years as serum phosphate and PTH concentrations rise. PHP type 1a has a unique phenotype with short stature, a rounded face, a short neck, obesity, a flattened nose bridge, ocular abnormalities, short fourth and fifth metacarpals, dental hypoplasia, developmental delay, mental retardation, and subcutaneous calcifications. The most outstanding distinguishing feature is brachydactyly with shortening of the fourth and fifth (and sometimes the third) metacarpal and metatarsal bones. This can be demonstrated not only on radiographs but also by having the patient make a fist, which demonstrates the so-called “knuckle, knuckle, dimple, dimple sign,” first described by Albright. Instead of a proper knuckle appearing, the short metacarpal leads to a depression. The short metacarpals result from premature fusion of the epiphyses and failure of the proper appearance of some of the epiphyses, not only of the metacarpals but also of the phalanges, which, therefore, are short. The distal phalanx of the thumb is typically short (“potter’s thumb”). Other long bones also can be short (e.g., ulna) or deformed (e.g., bowed radius). The skull can show hyperostosis frontalis interna. In addition to these features, there may be multiple exostoses, resembling a dyschondroplasia, and striking subcutaneous calcification and ossification, at times in the form of osseous plaques or nodules, which may be seen and felt in soft tissues or skin (osteoma cutis). Stone-hard papular or nodular lesions occur at sites of minor trauma (e.g., over the anterior surface of the lower legs). Ocular abnormalities include microphthalmia, strabismus, hypertelorism, diplopia, nystagmus, optic atrophy, and macular degeneration.

Because the *GNAS* gene has a role in many functions throughout the body, patients with PHP type 1a can also have clinical presentations dominated by resistance to other hormones (e.g., thyrotropin, gonadotropins, or growth hormone–releasing hormone). Hypothyroidism is common in individuals with PHP type 1a; serum thyrotropin concentrations are above the reference range, and free thyroxine concentrations are below the reference range. Women with PHP type 1a can have delayed puberty, oligomenorrhea, and infertility. Men with PHP type 1a frequently have low serum testosterone concentrations and infertility. Most patients with PHP type 1a have growth hormone deficiency. G proteins are also associated with signal transduction pathways for vision, olfaction, and taste. Thus, patients with PHP type 1a may have symptoms related to olfactory, gustatory, and auditory dysfunction. Mild to moderate mental retardation is common and presumably related to the effect of the *GNAS* mutation on brain tissue.

Although PTH can lack activity at the renal tubule, it can be functional at the bone. Therefore, all of the manifestations of secondary hyperparathyroidism may be seen at times, especially if the skeleton responds to this stimulation. Subperiosteal resorptive changes in the digits and changes in the epiphyses, which are indistinguishable from renal osteitis fibrosa, can be seen.



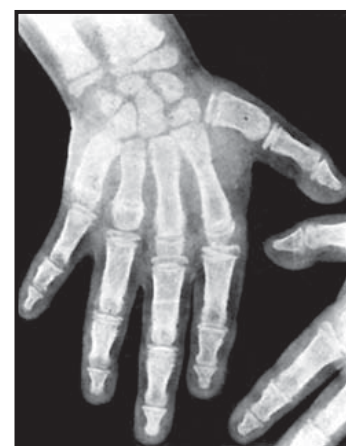Short thickset figure; round face



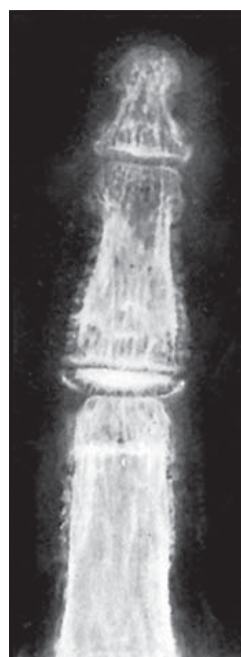Short 4th and 5th metacarpals



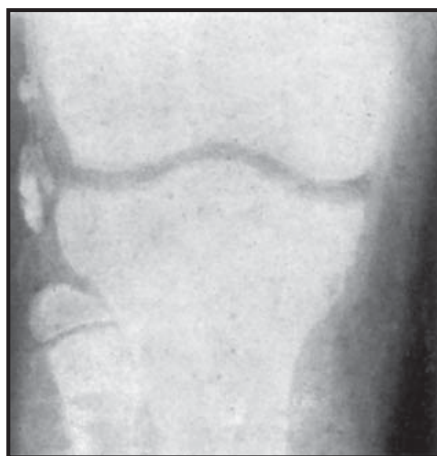“Knuckle, knuckle, dimple, dimple” sign



Short metacarpal bones, resorptive changes

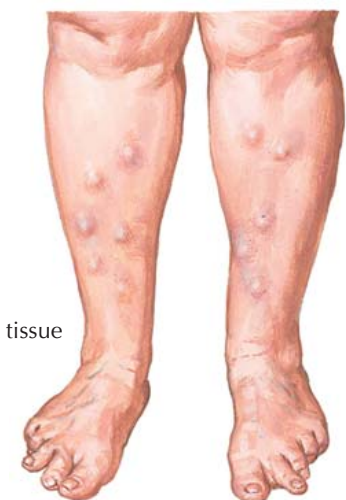

Subperiosteal resorption



Subcutaneous osseous plaques

Nodules in soft tissue with ulceration



Short metatarsals; deformity of toes

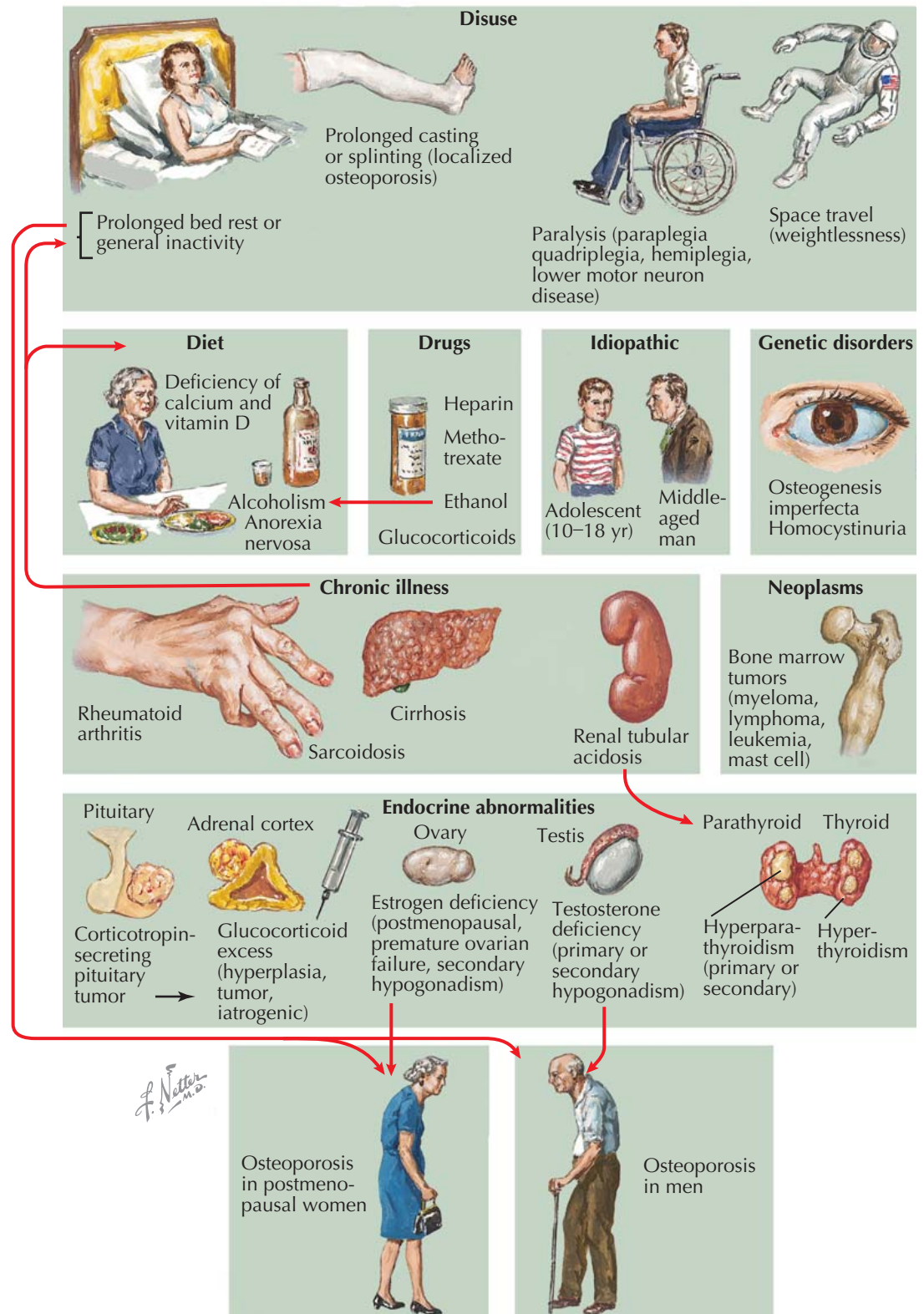
Pseudopseudohypoparathyroidism occurs when the inactivating *GNAS* mutation is paternally transmitted. Affected individuals have the body phenotype characteristic of Albright hereditary osteodystrophy but without resistance to PTH action at the kidney because of the presence of the normal maternal allele. Thus, these individuals have normal blood concentrations of calcium, phosphate, and PTH. However, they may have excessive dermal ossification caused by progressive osseous heteroplasia.

PHP type 1b is caused by maternal transmission of mutations in the regulatory elements for *GNAS*. These

individuals lack the body phenotype characteristic of Albright hereditary osteodystrophy but have PTH resistance at the kidney.

PHP type 1c is caused by mutations that affect the coupling of the G protein to the PTH receptor. Thus, the adenylyl cyclase system is intact, but it is not coupled to the binding of PTH to its receptor. These patients have the body phenotype characteristic of Albright hereditary osteodystrophy, hypocalcemia, hyperphosphatemia, and increased blood PTH concentrations.

RISK FACTORS FOR OSTEOPOROSIS



**PATHOGENESIS OF OSTEOPOROSIS**

Osteoporosis is a common structural skeletal disorder characterized by low bone mass and bone fragility that increase the risk of bone fracture (see Plates 6-15 to 6-17). Bone structural integrity is jeopardized as the bony microarchitecture is disrupted (e.g., the trabecular plates become perforated and discontinuities develop in the trabecular struts). The cause of low bone mass in patients with osteoporosis is usually a combination of factors that include low peak bone mass, increased bone resorption, and decreased bone formation. High-turnover osteoporosis occurs when increased bone resorption is dominant, and low-turnover osteoporosis occurs when decreased bone formation predominates. Approximately 50% of peak bone mass is genetically determined, and 50% is determined by environmental factors (e.g., physical activity and calcium intake).

The main contributor to osteoporosis in postmenopausal women is estrogen deficiency. When present, estrogen inhibits bone resorption by affecting osteoclast function. Prolonged estrogen deficiency in premenopausal women (e.g., hypogonadotropic hypogonadism that may occur with eating disorders, low body fat, excessive exercise, hypopituitarism, or hyperprolactinemia) also results in decreased bone mass. Estrogen also has a role in maintaining bone density in men; osteoporosis occurs in men who lack estrogen (e.g., aromatase deficiency). Testosterone deficiency in men predisposes them to osteoporosis.

Advancing age, a history of fragility (low-impact trauma) fracture, glucocorticoid therapy, low body mass index, family history of hip fracture, cigarette smoking, excessive alcohol use, and low bone mineral density (BMD) are the most consistent and strongest predictors of bone fracture risk.

Additional risk factors for osteoporosis include dietary deficiency in calcium and vitamin D, medications (e.g., anticonvulsants, heparin, methotrexate), frailty and recurrent falls, prolonged bed rest or general inactivity, neurologic disorders that limit mobility (e.g., paralysis), and weightlessness (e.g., space travel).

Glucocorticoid excess inhibits bone formation by negatively affecting the differentiation and life span of osteoblasts. A dosage-dependent relationship exists between chronic glucocorticoid therapy and fracture risk. Although excess glucocorticoid exposure is most commonly caused by medical therapy for an underlying inflammatory disorder (e.g., asthma, arthritis), it may also result from endogenous Cushing syndrome (pituitary or adrenal dependent).

Hyperparathyroidism (primary or secondary) results in decreasing bone mass and, if untreated, in osteoporosis.

The prevalence of osteoporosis is increased in patients affected by medical disorders that are associated with inflammation (e.g., rheumatoid arthritis, inflammatory bowel disease, sarcoidosis), malabsorption (e.g., celiac disease, cystic fibrosis), renal excretion of calcium (e.g., renal tubular acidosis), thyroid hormone excess (endogenous or exogenous), or direct

bone involvement (e.g., multiple myeloma, leukemia, systemic mastocytosis, lymphoma).

The osteoporosis that occurs in women with anorexia nervosa results not only from dietary insufficiencies of calcium and vitamin D but also from the estrogen deficiency with secondary hypogonadism.

Genetic disorders that cause osteoporosis include osteogenesis imperfecta (see Plates 6-25 and 6-26) and homocystinuria.



## OSTEOPOROSIS IN POSTMENOPAUSAL WOMEN

Osteoporosis in postmenopausal women refers to markedly low bone mass that can occur with estrogen deficiency and aging. Osteoporosis is usually clinically silent until a bone fracture occurs; even then, most vertebral fractures are asymptomatic. The most common sites of bone fracture in postmenopausal women with osteoporosis are vertebral, hip, rib, and distal radius (Colles fracture). Multiple vertebral fractures lead to progressive thoracic kyphosis (dowager's hump), loss of height, and abdominal protrusion. Osteoporosis also predisposes to appendicular fractures (e.g., proximal femur, distal radius, and proximal humerus) that may occur with minor trauma.

Bone strength is derived from bone mass (size, shape, and microarchitecture) and bone turnover status (rates of formation and resorption). Bone mass can be estimated by measuring bone mineral density (BMD) with dual energy-x-ray absorptiometry (DXA) at the hip and lumbar spine. The risk of fracture is inversely proportional to BMD. The BMD T score is the standard deviation (SD) difference between a patient's BMD and that of a young adult reference population. Normal bone density is defined as a BMD value within 1 SD of the mean in a young adult reference group. Based on increased risk of fracture, osteoporosis is defined as a BMD T score that is  $-2.5$  SD or more below the mean of the young adult reference population. The value obtained when a patient's BMD is compared with that of an age-matched population is termed the Z score. A Z score less than  $-2.0$  SD is considered low.

BMD may be low because the individual's peak bone mass reached as a young adult was low, bone formation is decreased, bone resorption is increased, or a combination of all three of these factors. Excessive bone resorption is a major contributor to osteoporosis in postmenopausal women.

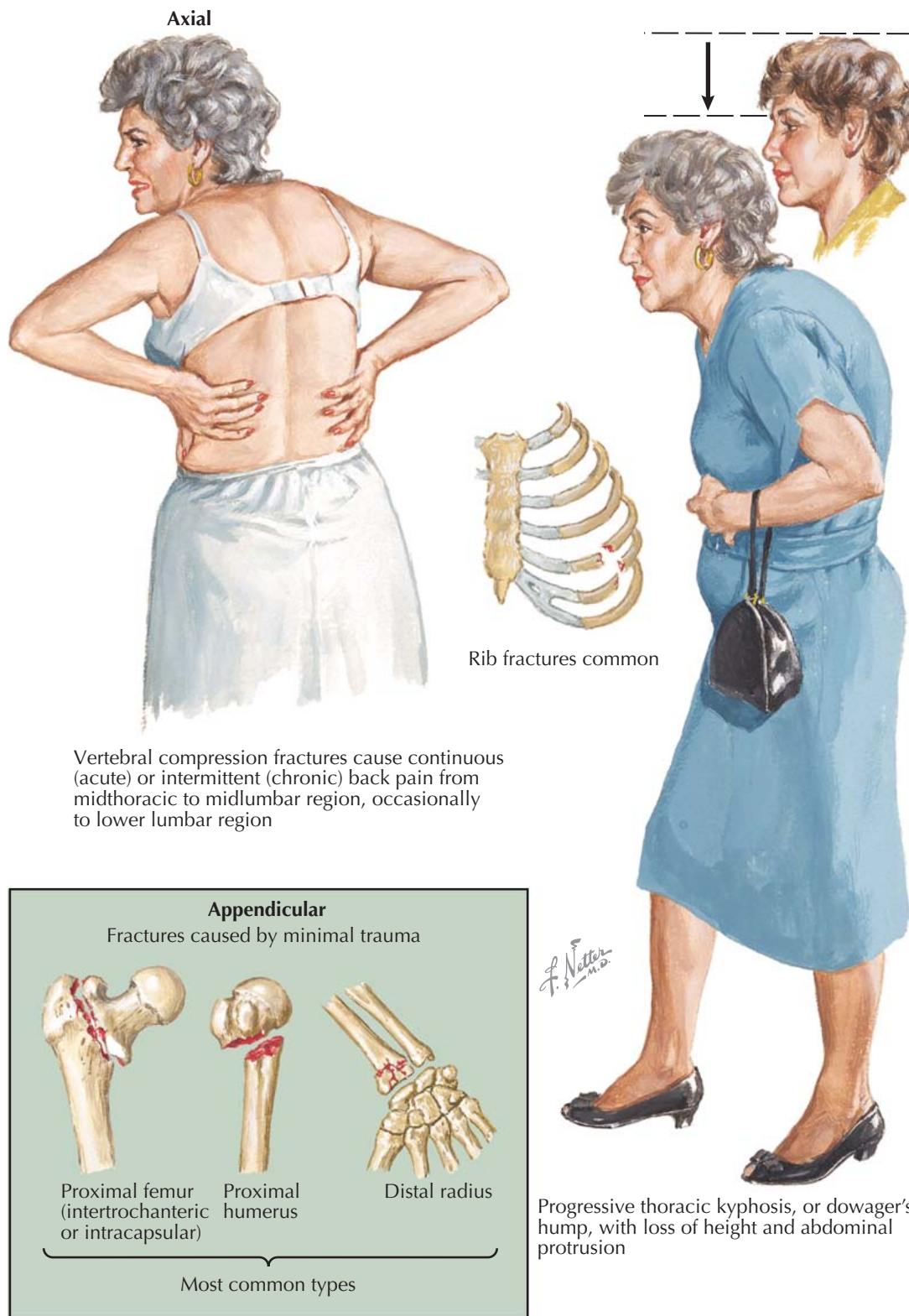
Secondary osteoporosis should be considered in all patients with low BMD, and evaluation for the following disorders should be considered: vitamin D deficiency, osteomalacia, hyperthyroidism, hyperparathyroidism, celiac disease, mast cell disease, and hypercortisolism. The first step of evaluation is a thorough interview and physical examination. Laboratory evaluation should include complete blood cell count and measurement of blood concentrations of calcium, phosphorus, liver enzymes, creatinine, thyrotropin, and 25-hydroxyvitamin D. The role of additional laboratory testing is based on the findings from the history and physical examination. Bone turnover markers may be helpful for some patients in assessing fracture risk, selecting treatment, and monitoring response to therapy.

### TREATMENT

Nonpharmacologic treatment—diet, exercise, smoking cessation, and avoidance of medications that increase bone loss (e.g., glucocorticoids)—is key to the successful management of osteoporosis. The daily intake of calcium and vitamin D should average 1500 mg and 800 IU, respectively. Regular weight-bearing exercise (e.g., walking) helps maintain BMD and reduce the risk of hip fracture (the latter is likely because of improved muscular strength).

The decision of when to institute pharmacologic therapy can be guided by fracture risk assessment. A fracture risk assessment tool (FRAX), available from the

### CLINICAL MANIFESTATIONS OF OSTEOPOROSIS



Vertebral compression fractures cause continuous (acute) or intermittent (chronic) back pain from midthoracic to midlumbar region, occasionally to lower lumbar region

Progressive thoracic kyphosis, or dowager's hump, with loss of height and abdominal protrusion

World Health Organization's website, provides personalized data on 10-year probabilities of hip fracture and osteoporotic fractures.

Pharmacologic treatment options include antiresorptive agents and anabolic agents. Antiresorptive medications include estrogen, selective estrogen receptor modulators, bisphosphonates, and calcitonin. The main anabolic agent is parathyroid hormone 1-34 (teriparatide). Additional emerging pharmacologic options

include monoclonal antibody against the osteoclastogenesis factor receptor activator of NF- $\kappa$ B ligand (RANKL), sclerostin inhibitors, integrin inhibitors, and cathepsin K inhibitors.

Treatment effectiveness can be monitored with bone markers at baseline and 3 to 6 months after initiation of treatment. DXA of the lumbar spine and hip should be performed 1 year after treatment initiation and periodically (e.g., every 2-3 years) thereafter.

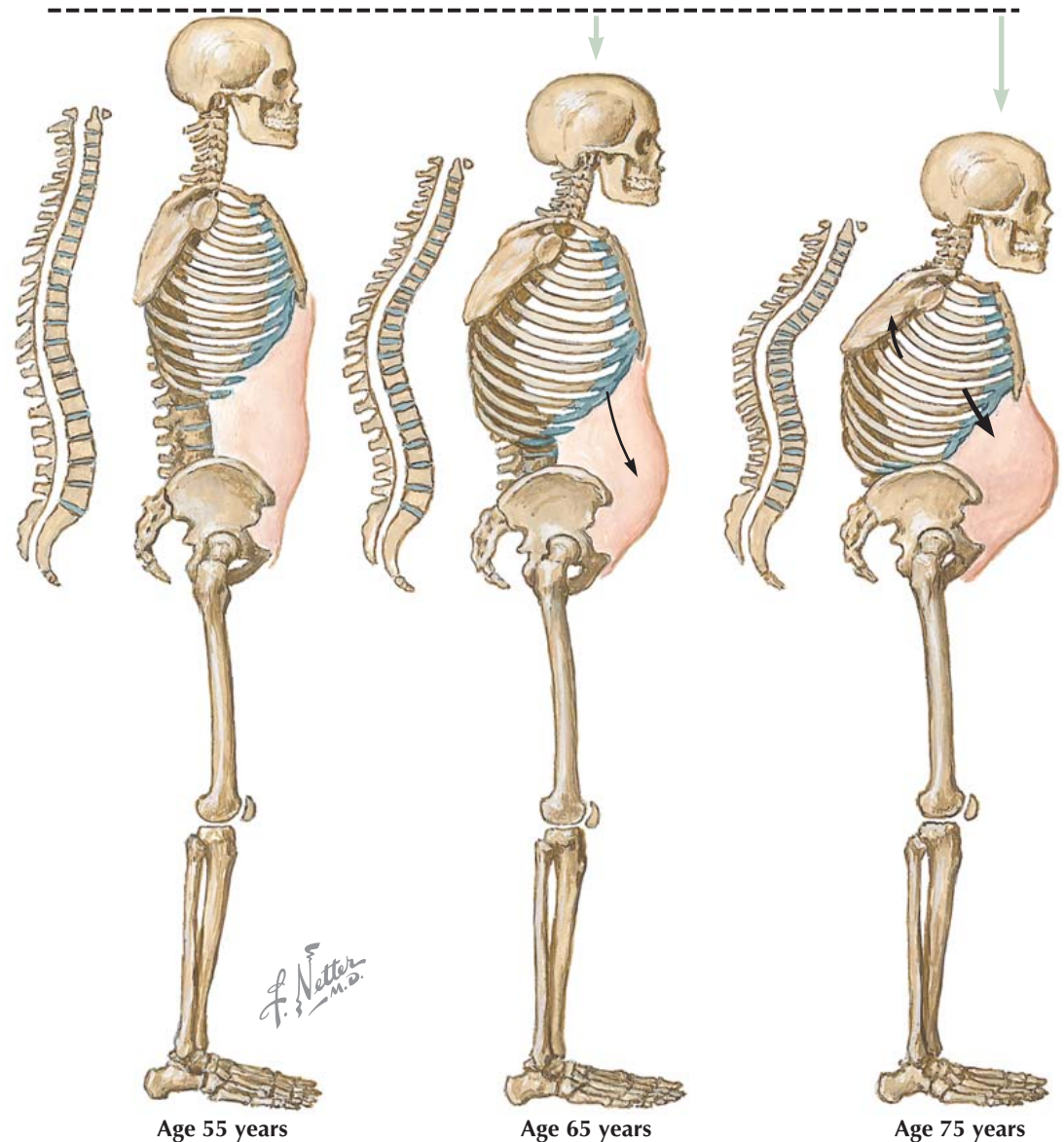
## PROGRESSIVE SPINAL DEFORMITY IN OSTEOPOROSIS

## OSTEOPOROSIS IN MEN

Although bone mineral density (BMD) is routinely measured in postmenopausal women, it is not often measured in men. Thus, osteoporosis in men is diagnosed after low-impact trauma fractures or incidental finding of osteopenia on radiographs performed for other reasons. Osteoporosis may also be found in men because of purposeful case-detection testing in high-risk groups (e.g., those taking glucocorticoid therapy and those with long-standing hypogonadism, hyperparathyroidism, or malabsorption). Compression fractures of the thoracic vertebral bodies lead to loss of height and progressive thoracic kyphosis. With multiple vertebral compression fractures, the lower ribs may reach the iliac crests, and abdominal distension becomes more evident.

Osteoporosis occurs when there is low bone mass and skeletal fragility, leading to an increased risk of fracture (e.g., vertebral bodies, hips, and ribs). Measurement of BMD is a key tool to assess the risk of bone fracture. BMD measurement with dual energy-x-ray absorptiometry (DXA) at the lumbar spine and hip should be considered in men in the following clinical settings: low-trauma fractures, incidental finding of apparent osteopenia on plain radiographs, loss of more than 4 cm of height, or presence of a known risk factor for osteoporosis (e.g., glucocorticoid therapy, long-standing hypogonadism, hyperparathyroidism, malabsorption). A DXA T score less than or equal to  $-2.5$  is consistent with osteoporosis. A DXA T score between  $-1.0$  and  $-2.5$  is consistent with osteopenia.

A secondary osteoporosis evaluation is indicated in men with low-impact fractures or a DXA bone mass T score less than  $-2.5$ . These men should be evaluated for underlying malabsorption (e.g., celiac disease), hypogonadism, Cushing syndrome, hepatic and renal disorders, hypercalciuria, hyperparathyroidism, genetic disorders (e.g., osteogenesis imperfecta), and bone marrow tumors (e.g., multiple myeloma, mastocytosis). Many of these diagnoses may be evident on a thorough interview and physical examination. Initial laboratory testing should include complete blood cell count; serum protein electrophoresis; and measurement of blood concentrations of testosterone, calcium, phosphorus, parathyroid hormone, 25-hydroxyvitamin D, tissue transglutaminase antibodies, hepatic enzymes, creatinine, and trypsin. A 24-hour urine collection should be completed to measure cortisol, calcium, and creatinine. Findings on these tests may lead to further case-directed testing (e.g., dexamethasone suppression testing for suspected Cushing syndrome). Measurement of markers of bone formation and resorption may be helpful in selected cases.



Compression fractures of thoracic vertebrae lead to loss of height and progressive thoracic kyphosis (dowager's hump). Lower ribs eventually rest on iliac crests, and downward pressure on viscera causes abdominal distension

## TREATMENT

The treatment of osteoporosis in men includes lifestyle measures and pharmacologic therapy.

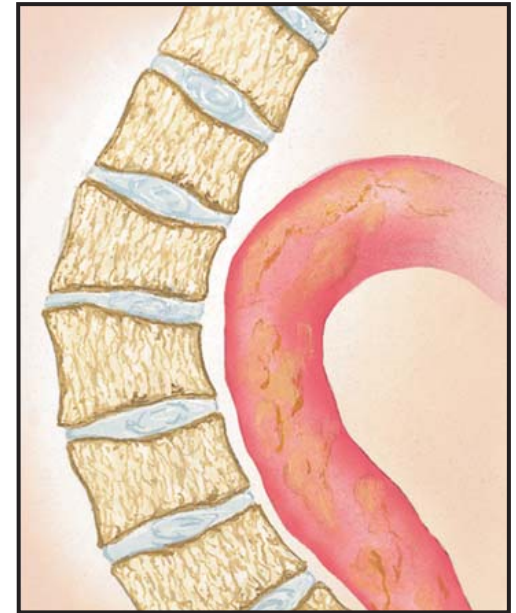
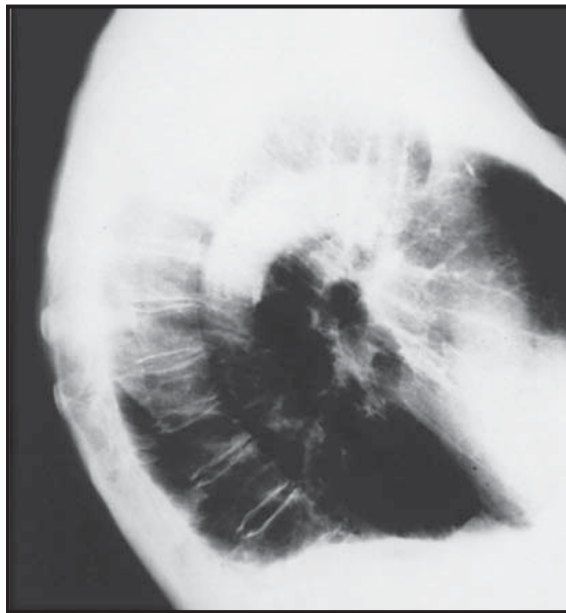
Lifestyle measures include weight-bearing exercise (e.g., walking), smoking cessation, and avoidance of excessive alcohol use. These men should be advised to take calcium (1500 mg/d) and vitamin D (800 IU/d) supplementation. If the patient has secondary osteoporosis, treatment of the underlying disorder is the mainstay of therapy (e.g., testosterone replacement in men with long-standing hypogonadism).

Pharmacologic therapy is indicated in men age 50 years or older who have a history of hip or vertebral fracture or who have been diagnosed with osteoporosis on the basis of BMD (DXA T score of  $-2.5$  or less). Pharmacologic treatment for men with osteopenia determined by BMD (DXA T score between  $-1.0$  and

$-2.5$ ) should be considered when the 10-year probability of hip fracture reaches 3% or when the 10-year probability of osteoporotic fractures combined reaches 20%. These 10-year fracture probabilities can be calculated with a fracture risk assessment tool (FRAX) available from the World Health Organization's website. FRAX provides personalized data on 10-year probabilities of hip fracture and osteoporotic fractures. In addition, pharmacologic treatment should be considered for men who do not meet these FRAX risk cutoffs but are at high risk for progressive bone loss (e.g., chronic high-dose glucocorticoid therapy).

Bisphosphonates are the primary form of pharmacologic therapy for osteoporosis in men. Parathyroid hormone 1-34 (teriparatide) treatment is reserved for men with progressive bone loss despite secondary factors being addressed and treatment with a bisphosphonate.





Marked kyphosis is evident. Anterior wedge and biconcave (codfish) deformities are present.

## CLINICAL MANIFESTATIONS OF OSTEOPOROTIC VERTEBRAL COMPRESSION FRACTURES

Compression fractures of the thoracic and lumbar vertebral bodies are the most common type of fracture in patients with osteoporosis. Because of less resistance to anteroposterior displacement, the most common location for vertebral fractures is in the region of the thoracolumbar junction (thoracic vertebrae 11 and 12 and lumbar vertebrae 1 and 2). Vertebral compression fractures may be asymptomatic and detected incidentally on chest radiographs. In patients with osteoporosis, vertebral compression fractures may occur spontaneously or with low-impact trauma. When present, the pain—dull or sharp in character and aggravated by movement—related to a compression fracture may be severe and radiate around the flanks to the anterior abdomen. The severe pain related to vertebral compression fractures usually resolves over 4 to 8 weeks; however, chronic back discomfort may be permanent.

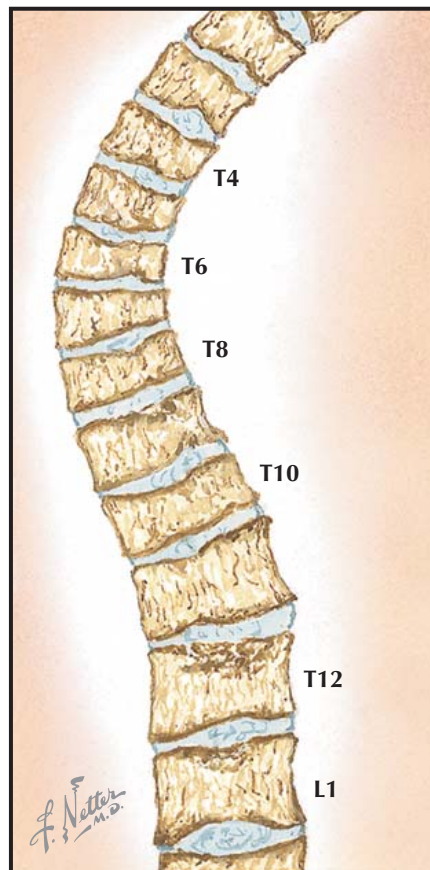
Kyphosis results from multiple thoracic vertebral compression fractures. Both the kyphosis and the loss of vertical vertebral body height lead to loss of total body height. Patients with thoracic kyphosis may present with multiple symptoms. For example, neck discomfort may result from the persistent neck extension required to keep the head vertical. Also, with height loss, compression of the abdominal organs causes increased abdominal prominence and restrictive pulmonary physiology. The lowest rib may contact the iliac crest and cause pain near the 12th thoracic vertebral body and at the iliac crest.

The occurrence of a vertebral fracture is highly predictive of future vertebral fractures; approximately 20% of these patients experience a second fracture within 1 year of their first one.

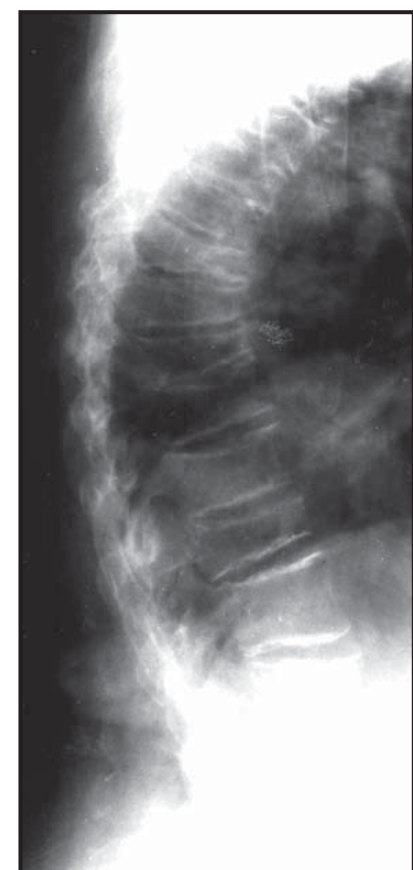The types of vertebral fractures include anterior wedge, biconcave (“codfish”) deformity, and compression. Fractures can be graded as grade 1, 20% to 25% deformity; grade 2, 26% to 40% deformity; and grade 3, more than 40% deformity.

## EVALUATION AND TREATMENT

Patients with symptoms consistent with acute vertebral fracture should be evaluated with plain spine films. If



Multiple grade 3 compression fractures are evident in the thoracic vertebral bodies, resulting in marked kyphosis.



radicular symptoms are present, magnetic resonance imaging of the spine may be needed. Bone mineral density testing is indicated in all patients with vertebral compression fractures. The underlying cause of the vertebral fracture should be determined to direct disease-specific therapy to prevent future fractures. For example, if postmenopausal osteoporosis is the underlying cause predisposing the patient to vertebral fractures, treatment with an antiresorptive agent (e.g., bisphosphonates) should be considered.

Pain control, with nonopioid medications if possible, is important to allow normal physical activity. For patients with severe or persistent pain, vertebroplasty or kyphoplasty should be considered. These interventions involve the percutaneous injection of polymethylmethacrylate bone cement into the collapsed vertebral body, which resolves the acute pain, prevents long-term pain, and prevents height loss.

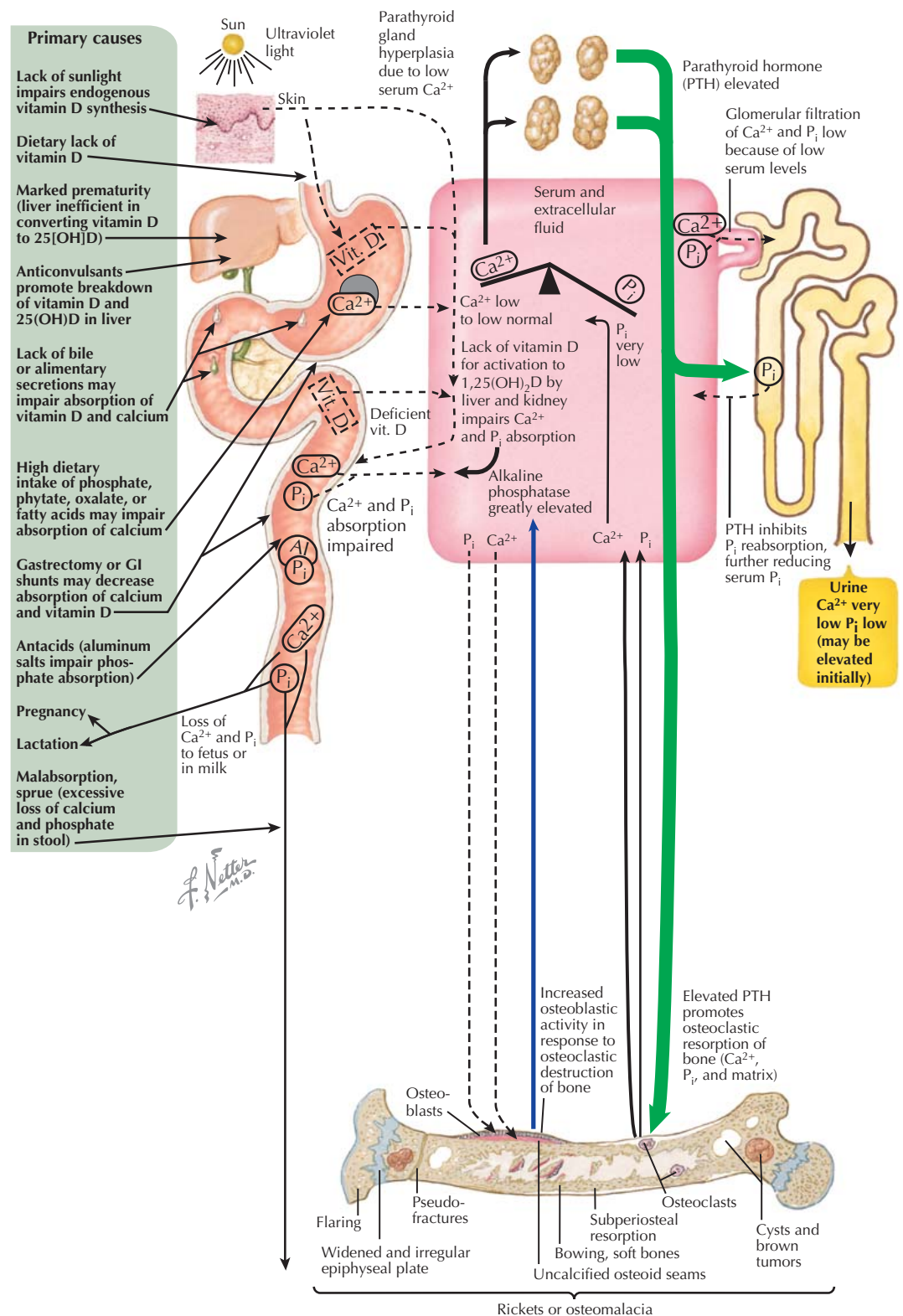
## NUTRITIONAL-DEFICIENCY RICKETS AND OSTEOMALACIA

Calcium and phosphate—the two main mineral components of bone—are required for normal bone growth and mineralization. Rickets occurs in children with deficient mineralization at the growth plate and causes widened and irregular epiphyseal plates. Osteomalacia refers to deficient mineralization of bone matrix, resulting in uncalcified osteoid seams, soft bones with bowing, and pseudofractures. Nutritional-deficiency rickets and osteomalacia may result from deficiencies in calcium, phosphate, or both.

Calcipenic rickets and osteomalacia are caused by decreased intestinal absorption of calcium, either because of lack of dietary calcium or decreased absorption of intestinal calcium. Decreased absorption of intestinal calcium occurs with malabsorption (e.g., celiac disease) and with decreased action of vitamin D at its receptor—a result of vitamin D deficiency, a defect in the  $1\alpha$ -hydroxylation of vitamin D, or an abnormality at the vitamin D receptor. The hypocalcemia of calcipenic rickets and osteomalacia leads to secondary hyperparathyroidism, which may partially correct the hypocalcemia, but because of increased urinary inorganic phosphate ( $P_i$ ) excretion, it also results in hypophosphatemia. Thus, with nutritional-deficiency rickets and osteomalacia, the serum phosphorus concentration is below the lower limit of the reference range, and the serum calcium concentration is in the low-normal range or below the lower limit of the reference range. In addition, secondary hyperparathyroidism leads to increased osteoclastic reabsorption of bone. Increased osteoblastic activity with deposition of bone matrix occurs in response to the osteoclast activation. However, the bone matrix cannot be mineralized because of low blood levels of calcium and phosphorus, leading to rickets in children and osteomalacia in adults.

Vitamin D (calciferol) is a fat-soluble compound with a 4-ringed cholesterol structure. The synthesis of vitamin  $D_3$  (cholecalciferol) from 7-dehydrocholesterol occurs in the skin with exposure to ultraviolet rays in sunlight (photoisomerization). Vitamin D in the form of ergocalciferol (vitamin  $D_2$ ) is ingested in the diet, primarily from plants, fish, eggs, and fortified products (e.g., milk and cereals). Cholecalciferol and ergocalciferol are hydroxylated in the liver by 25-vitamin D hydroxylase to form 25-hydroxyvitamin D (25[OH]D; calcidiol). 25(OH)D is  $1\alpha$ -hydroxylated in the proximal convoluted tubule cells of the kidney to form the more potent 1,25-dihydroxyvitamin D (1,25[OH] $_2$ D; calcitriol). Vitamin D deficiency can occur at multiple levels—decreased exposure to sunlight; decreased dietary intake of vitamin D; decreased gastrointestinal absorption of vitamin D (e.g., after gastric surgery or with long-term, high-dose glucocorticoid therapy); decreased hepatic 25-hydroxylation of vitamin D (e.g., in premature infants, in patients with advanced liver disease) or renal  $1\alpha$ -hydroxylation of vitamin D; accelerated breakdown of vitamin D at the liver (e.g., with medications that induce P450 enzyme activity such as anticonvulsants); renal loss of vitamin D (e.g., nephrotic syndrome); or end-organ insensitivity to vitamin D (see Plate 6-19).

Vitamin D-deficient rickets usually presents in the first 3 years of life, when bone growth is high and exposure to sunlight may be limited. Vitamin D in fetuses is dependent on placental transfer of maternal 25(OH)D. Adequate vitamin D in infants is dependent on dietary intake and exposure to sunlight. Infants and



children require approximately 400 IU of vitamin D per day. Whereas breast milk contains 25 IU of vitamin D per liter, infant formulas contain at least 400 IU of vitamin D per liter. Thus, breastfed infants are at increased risk for vitamin D deficiency and should be supplemented with 400 IU vitamin D daily.

### TREATMENT

Effective treatment of vitamin D deficiency rickets and osteomalacia can usually be accomplished with vitamin

$D_2$  (ergocalciferol). The treatment dosage of vitamin  $D_2$  is adjusted based on patient age and clinical response. Optimizing calcium intake is also important ( $\geq 1000$  mg/d of total dietary calcium). Treatment effectiveness should be monitored by measurement of serum calcium, phosphorus, 25(OH)D, and alkaline phosphatase. Urinary calcium excretion can also be monitored to document recovery. Radiographs should be obtained to document bone healing.



## PSEUDOVITAMIN D-DEFICIENCY RICKETS AND OSTEOMALACIA

Pseudovitamin D-deficient rickets is caused either by lack of 1,25-dihydroxyvitamin D (1,25(OH)<sub>2</sub>D; calcitriol) or by target-organ resistance to the actions of 1, 25(OH)<sub>2</sub>D. Type 1 pseudovitamin D-deficient rickets occurs when renal 1 $\alpha$ -hydroxylase deficiency results in insufficient conversion of 25-hydroxyvitamin D (25(OH)<sub>2</sub>D; calcidiol) to the more potent 1,25(OH)<sub>2</sub>D. Type 2 pseudovitamin D-deficient rickets results from end-organ resistance to the action of 1, 25(OH)<sub>2</sub>D and is also referred to as hereditary vitamin D-resistant rickets.

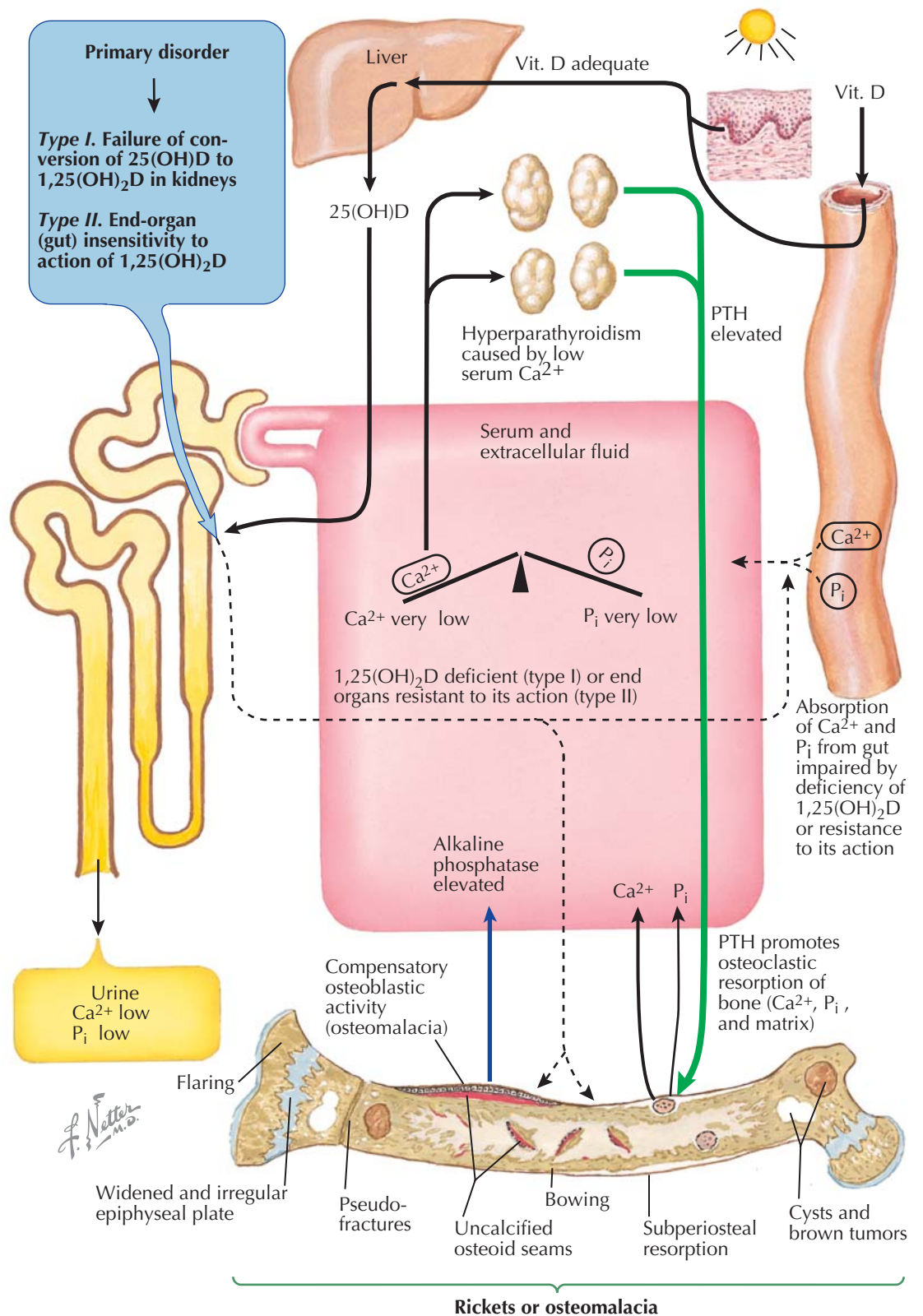
### TYPE 1 PSEUDOVITAMIN D-DEFICIENT RICKETS: RENAL 1 $\alpha$ -HYDROXYLASE DEFICIENCY

Type 1 pseudovitamin D-deficient rickets is an autosomal recessive disorder caused by inactivating mutations in the gene encoding the 1 $\alpha$ -hydroxylase enzyme that leads to no or minimal conversion of 25(OH)<sub>2</sub>D to 1,25(OH)<sub>2</sub>D. Affected children usually present in the first year of life with hypocalcemia, hypophosphatemia, phosphaturia, normal or increased blood concentrations of 25(OH)<sub>2</sub>D, decreased blood concentrations of 1,25(OH)<sub>2</sub>D, elevated blood concentrations of alkaline phosphatase, increased blood concentrations of parathyroid hormone (PTH), and the typical signs and symptoms of rickets and osteomalacia (see Plates 6-18 and 6-21). Additional presenting symptoms include motor retardation, muscle weakness, and growth failure.

The mainstay of therapy for patients with renal 1 $\alpha$ -hydroxylase deficiency is lifelong administration of calcitriol in physiologic doses (e.g., 1  $\mu$ g/d) with treatment goals of healing the bones and maintaining normal blood concentrations of calcium, phosphorus, PTH, creatinine, and alkaline phosphatase. Adequate calcium supplementation is important, especially during the bone-healing phase. Overtreatment with calcitriol—resulting in hypercalcemia, hypercalciuria, and nephrocalcinosis—should be avoided.

### TYPE 2 PSEUDOVITAMIN D-DEFICIENT RICKETS: HEREDITARY VITAMIN D-RESISTANT RICKETS

Hereditary vitamin D-resistant rickets is an autosomal recessive disorder resulting from mutations in the gene encoding the vitamin D receptor, which lead to decreased target-organ responsiveness to 1,25(OH)<sub>2</sub>D. The clinical presentation depends on the mutations and the amount of residual vitamin D-receptor activity. Affected children usually present in the first 2 years of life with hypocalcemia, hypophosphatemia, phosphaturia, blood concentrations of 1,25(OH)<sub>2</sub>D increased



three- to fivefold above the upper limit of the reference range, elevated blood concentrations of alkaline phosphatase, increased blood concentrations of PTH, and the typical signs and symptoms of rickets and osteomalacia (see Plates 6-18 and 6-21). The lack of vitamin D-receptor activation in keratinocytes causes alopecia totalis in some kindreds.

In addition to oral calcium supplementation, administration of high-dose calcitriol (e.g., 5–60  $\mu$ g/d) in an

attempt to overcome the receptor resistance should be tried in these patients. If high-dose calcitriol is ineffective, long-term, intravenously administered calcium infusions should be considered. Treatment effectiveness should be monitored with bone radiographs and measurement of blood levels of calcium, phosphorus, PTH, creatinine, and alkaline phosphatase. The correct calcitriol dosage is the dosage that heals the rachitic bone and normalizes the laboratory parameters.

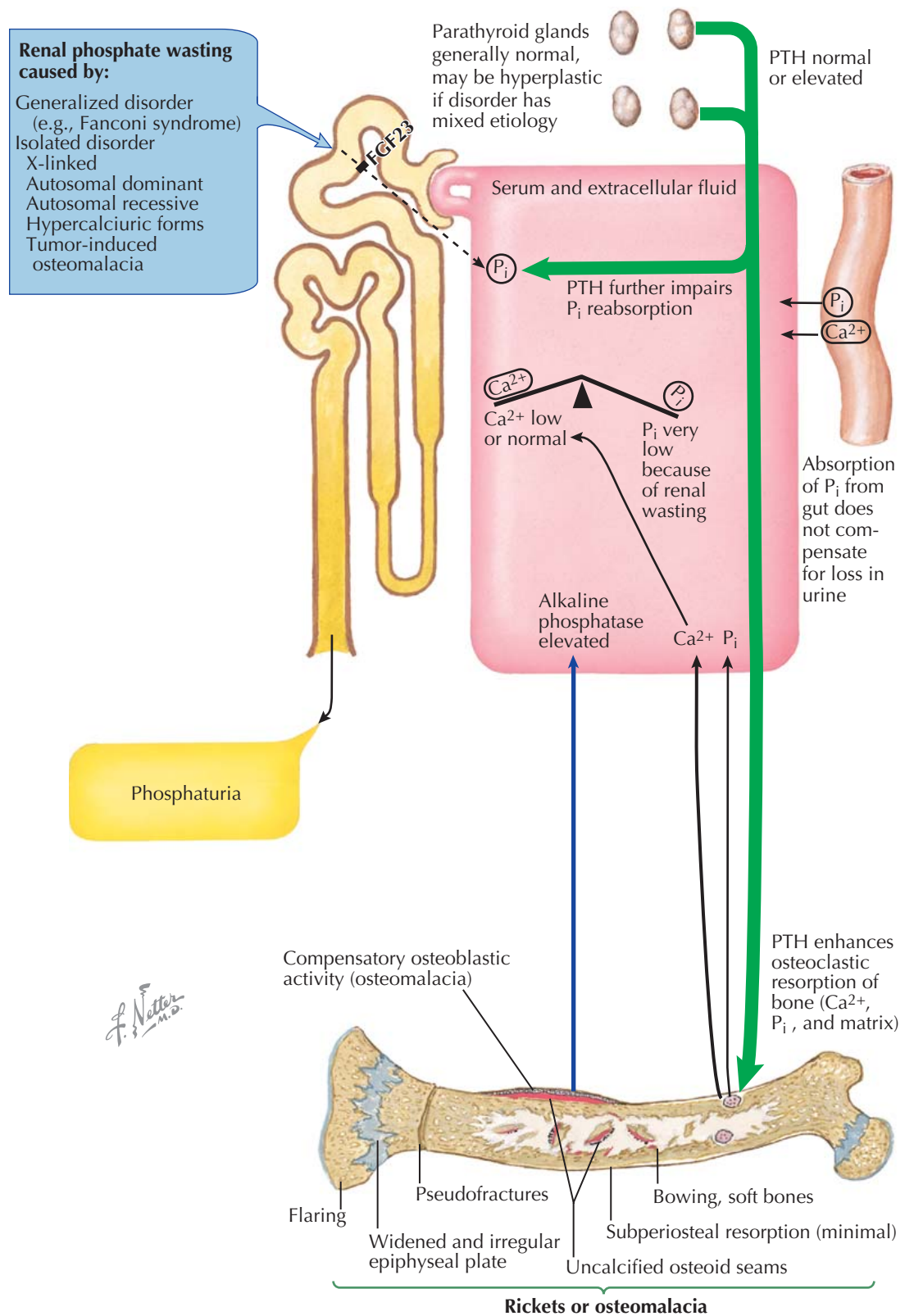
### HYPOPHOSPHATEMIC RICKETS

Hypophosphatemic rickets is caused by renal inorganic phosphate ( $P_i$ ) wasting, either in isolation or as a component of a more generalized renal disorder (e.g., Fanconi syndrome). The usual biochemical profile includes hypophosphatemia, normal serum calcium concentration, normal serum parathyroid hormone (PTH) concentration, and increased blood concentration of fibroblast growth factor 23 (FGF23). The most common hereditary form of hypophosphatemic rickets is X-linked followed by autosomal dominant forms (associated with activating mutations in the *FGF23* gene), autosomal recessive forms (associated with inactivating mutations in the dentin matrix protein 1 gene [*DMP1*] that result in increased *FGF23* expression), and forms associated with hypercalciuria (e.g., Dent disease). If the onset of hypophosphatemia is delayed until adolescence, the differential diagnosis should include tumor-induced osteomalacia (see following text).

### X-LINKED HYPOPHOSPHATEMIC RICKETS

The incidence of X-linked hypophosphatemic rickets is approximately one case per 20,000 live births. Mutations in the phosphate regulating endopeptidase homolog on the X chromosome gene (*PHEX*) are responsible for this disorder. Although penetrance is 100%, the expression is variable, even in affected individuals from the same kindred. *PHEX* regulates the degradation and production of FGF23. Excess circulating levels of FGF23 mediate renal phosphate wasting by inhibiting phosphate reabsorption by the renal sodium-phosphate cotransporter. Children with X-linked hypophosphatemic rickets usually present with typical signs and symptoms of osteomalacia (see Plate 6-21) and retarded linear growth. Additional findings unique to X-linked hypophosphatemic rickets include calcification of ligaments and tendons (enthesopathy) and abnormal dentin predisposing to early tooth decay and tooth abscesses. Typical laboratory findings include low serum concentrations of phosphorus and calcitriol (the effects of FGF23 at the renal tubule also impair calcitriol synthesis), increased serum FGF23 concentration and 24-hour urinary phosphate excretion, normal to increased blood concentrations of PTH and alkaline phosphatase, and normal blood concentrations of calcium and calcidiol. The diagnosis can be confirmed with molecular genetic testing for germline mutations in *PHEX*.

In children, treatment includes orally administered phosphate (sodium phosphate or potassium phosphate) and calcitriol. Calcitriol therapy is needed to prevent the secondary hyperparathyroidism (which can cause further renal phosphate wasting) that occurs with phosphate replacement therapy. The goals of therapy in children are resolution of bone and joint pain and normal growth. Laboratory parameters that should be followed during treatment include blood concentrations of phosphorus, calcium, alkaline phosphatase, creatinine, and PTH and urinary calcium excretion. Periodic radiographs of the hand and wrist should be obtained to document bone age and to identify any recurrence of rickets. In adults, the goals of therapy are to prevent bone pain and fractures. In patients who are not closely monitored, hypercalcemia and hypercalciuria may result in calcium-phosphate deposition in the renal tubules (nephrocalcinosis) and renal tubular acidosis.



### TUMOR-INDUCED OSTEOMALACIA

Tumor-induced osteomalacia is an acquired disorder caused by small, benign mesenchymal tumors (e.g., sclerosing type of hemangiopericytoma) that hypersecrete FGF23. The clinician should suspect tumor-induced osteomalacia in patients who present with signs, symptoms, and laboratory profiles identical to those observed in patients with X-linked hypophosphatemic rickets but who do not have a personal or family history of the genetic disorder. The main challenge is to localize the small tumor; it may be a small subcutaneous lesion on an extremity or more centrally located. Localization studies usually include somatostatin receptor imaging with indium In 111-diethylenetriamine pentaacetic acid-pentetreotide and total body magnetic resonance imaging. Tumor resection corrects all biochemical abnormalities.

phatemic rickets but who do not have a personal or family history of the genetic disorder. The main challenge is to localize the small tumor; it may be a small subcutaneous lesion on an extremity or more centrally located. Localization studies usually include somatostatin receptor imaging with indium In 111-diethylenetriamine pentaacetic acid-pentetreotide and total body magnetic resonance imaging. Tumor resection corrects all biochemical abnormalities.



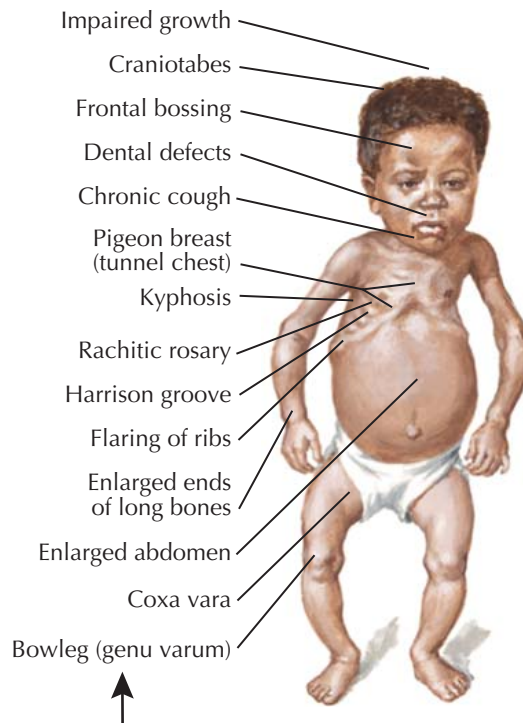
## CLINICAL MANIFESTATIONS OF RICKETS IN CHILDHOOD

Rickets, a result of chronic hypocalcemia or hypophosphatemia, occurs before closure of the epiphyses and is usually most evident at sites of rapid bone growth (e.g., knees, costochondral junctions, distal forearm). Enlargement of the costochondral junctions results in visible nodules—the “rachitic rosary”—and chest wall deformities (e.g., tunnel chest). The wrist enlarges, and there is bowing of the distal ulna and radius. Impaired mineralization causes weak long bones, leading to weight-bearing-dependent skeletal deformities. For example, whereas an affected infant may have posterior bowing of the distal tibia, children who can walk may have lateral bowing of the femur and tibia (genu varum). In infants, the closure of the fontanelles may be delayed, and parietal and frontal bossing and evidence of soft skull bones (craniotabes) may be present. The “Harrison groove” refers to the indentation that results from the muscular pull of the diaphragmatic attachments to the lower ribs.

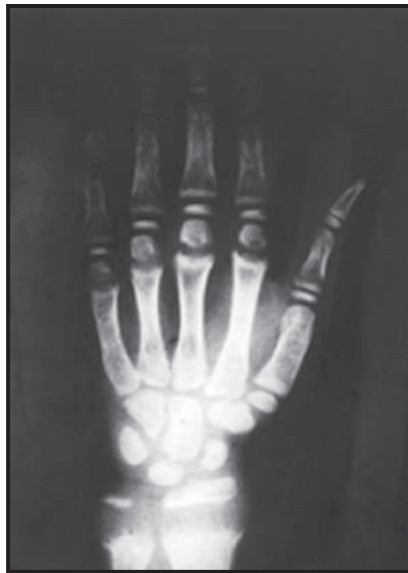The clinical presentation of rickets is dominated by skeletal pain, skeletal deformity, fracture, slippage of epiphyses, and retarded growth. Hip pain and deformity may result in a waddling or antalgic gait. In patients with hypocalcemic rickets, extraskeletal symptoms may include decreased muscle tone, proximal myopathy, hypocalcemic seizures, hyperhidrosis, and predisposition to infections.

A uniform component of the laboratory profile in patients with rickets is a marked increase in the blood concentration of alkaline phosphatase. The serum calcium concentration is low in patients with hypocalcemic rickets and is either normal or slightly depressed in those with hypophosphatemic rickets; serum phosphorus is low in both hypocalcemic and hypophosphatemic rickets. The serum parathyroid hormone (PTH) concentration is above the reference range in patients with hypocalcemic rickets and is normal in those with hypophosphatemic rickets.

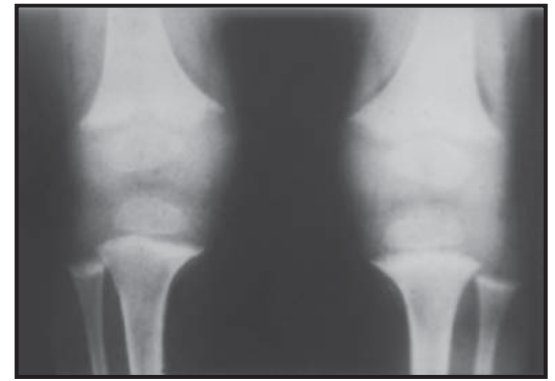
Radiographs of the distal ulna usually show findings of impaired mineralization, widening of the epiphyseal plates, irregular trabeculation, thin cortices, subperiosteal erosions (caused by the marked secondary hyperparathyroidism), and increased axial width of the epiphyseal line. Similar findings are evident in radiographs of the knees, which show flaring of the metaphyseal ends of the tibia and femur and thick and irregular growth plates. The zones of provisional calcification at the epiphyseal–metaphyseal interface are fuzzy and indistinct. With advanced rickets, the epiphyseal plates become more irregular and cupped. Osteopenia is evident in the long bones. Pelvic radiographs may disclose variegated rarefaction of the pelvic bones, coxa vara (where the angle between the ball and the shaft of the femur is reduced to <120 degrees, resulting in a shortened leg), deepened acetabula, pathologic fractures, and pseudofractures (Looser zones). Pseudofractures are narrow (2–4 mm) radiolucent lines with sclerotic borders that are perpendicular to the cortical bone margin and a few millimeters to several centimeters in length. Pseudofractures are frequently bilateral and symmetric and can be seen in the pubic rami, ischial rami, medial part of the femoral shaft, femoral neck, outer edge of the scapula, clavicle, ulna, and ribs. Pseudofractures appear at sites where major arteries cross the bone and may be caused by the mechanical forces of normal arterial pulsation on poorly mineralized bone (see Plate 6-22).



**Clinical findings** (all or some present in variable degree)

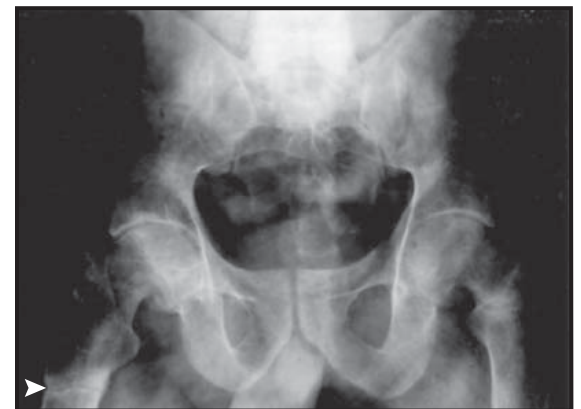

Radiograph of rachitic hand shows decreased bone density, irregular trabeculation, and thin cortices of metacarpal and proximal phalanges. Note increased axial width of epiphyseal line, especially in radius and ulna

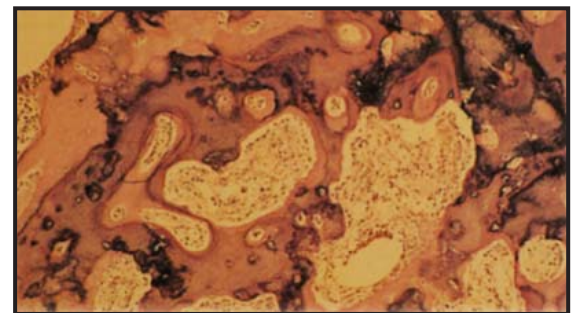


Flaring of metaphyseal ends of tibia and femur. Growth plates thickened, irregular, cupped, and axially widened. Zones of provisional calcification fuzzy and indistinct. Bone cortices thinned and medullae rarefied

### Radiographic findings



Radiograph shows variegated rarefaction of pelvic bones, coxa vara, deepened acetabula, and subtrochanteric pseudofracture of right femur



Section of rachitic bone shows sparse, thin trabeculae surrounded by much uncalcified osteoid (osteoid seams) and cavities caused by increased resorption

In children with suspected rickets, obtaining thorough dietary (e.g., calcium and vitamin D) and medication histories is key. Initial laboratory studies should exclude renal failure and hepatic disease. Laboratory testing should include measurement of blood concentrations of calcium, phosphorus, PTH, and 25-hydroxyvitamin D. For a description of the typical laboratory findings in patients with nutritional-deficiency rickets, pseudovitamin D-deficient rickets, and hypophosphatemic rickets, see Plates 6-18, 6-19,

and 6-20. Although bone biopsies are usually not needed to confirm rickets, they show sparse, thin trabeculae; thick layers of uncalcified osteoid (osteoid seams); and large bone resorption cavities.

Effective treatment of patients with rickets is determined by the underlying cause. Deformities that occur before age 4 years usually slowly correct themselves with effective therapy. When deformities occur after age 4 years (e.g., bowleg, knock-knee), they may be permanent.

### CLINICAL MANIFESTATIONS OF OSTEOMALACIA IN ADULTS

Osteomalacia is a disorder of impaired mineralization of newly formed osteoid in adults. Bone is composed of a collagen matrix (osteoid) distributed in a lamellar pattern and strengthened by pyridinoline crosslinks between the triple-helical collagen molecules, on which alkaline phosphate facilitates the deposition of calcium and phosphorus to form hydroxyapatite (see Plate 6-3). Bone remodeling is a continuous process, and new bone formation requires osteoid production from osteoblasts followed by mineralization of the osteoid. The mineralization step requires an adequate supply of calcium and phosphorus in extracellular fluid and normal bio-activity of alkaline phosphatase. Hypophosphatemia is the most common cause of osteomalacia (see Plate 6-20). Hypophosphatasia, a rare inherited disorder, is associated with low concentrations of alkaline phosphatase in serum and bone that cause defective bone and tooth mineralization, resulting in osteomalacia and severe periodontal disease (see Plate 6-27).

The clinical presentation of osteomalacia ranges from incidental detection of osteopenia on radiographs to markedly symptomatic patients with diffuse bone pain (most prominent in the pelvis, lower extremities, and lower spine), proximal muscle weakness, muscle wasting, hypotonia, and waddling gait. Low-impact fractures of the ribs and vertebral bodies may also be the initial presentation.

Radiographs typically show osteopenia with thinning of the cortex and loss of vertebral body trabeculae. With advanced vertebral body softening, end-plate concavities develop ("codfish" deformities) (see Plate 6-17). Looser zones (pseudofractures) are narrow (2-4 mm) radiolucent lines with sclerotic borders that are perpendicular to the cortical bone margin and a few millimeters to several centimeters in length. Pseudofractures are frequently bilateral and symmetric and can be seen in the pubic rami, ischial rami, medial part of the femoral shaft, femoral neck, outer edge of the scapula, clavicle, ulna, and ribs. Pseudofractures appear at sites where major arteries cross the bone and may be caused by the mechanical forces of normal arterial pulsation on poorly mineralized bone. Pseudofractures appear as hot spots on bone scintigraphy. Because Milkman initially recognized pseudofractures in 1930, the term *Milkman syndrome* has been used when a patient with osteomalacia has multiple, bilateral, symmetric pseudofractures. If secondary hyperparathyroidism is present, additional radiographic findings may be evident (e.g., subperiosteal resorption, bone cysts). With severe and long-standing osteomalacia, bowing of the tibia, radius, and ulna, as well as coxa profunda hip deformities, may occur.

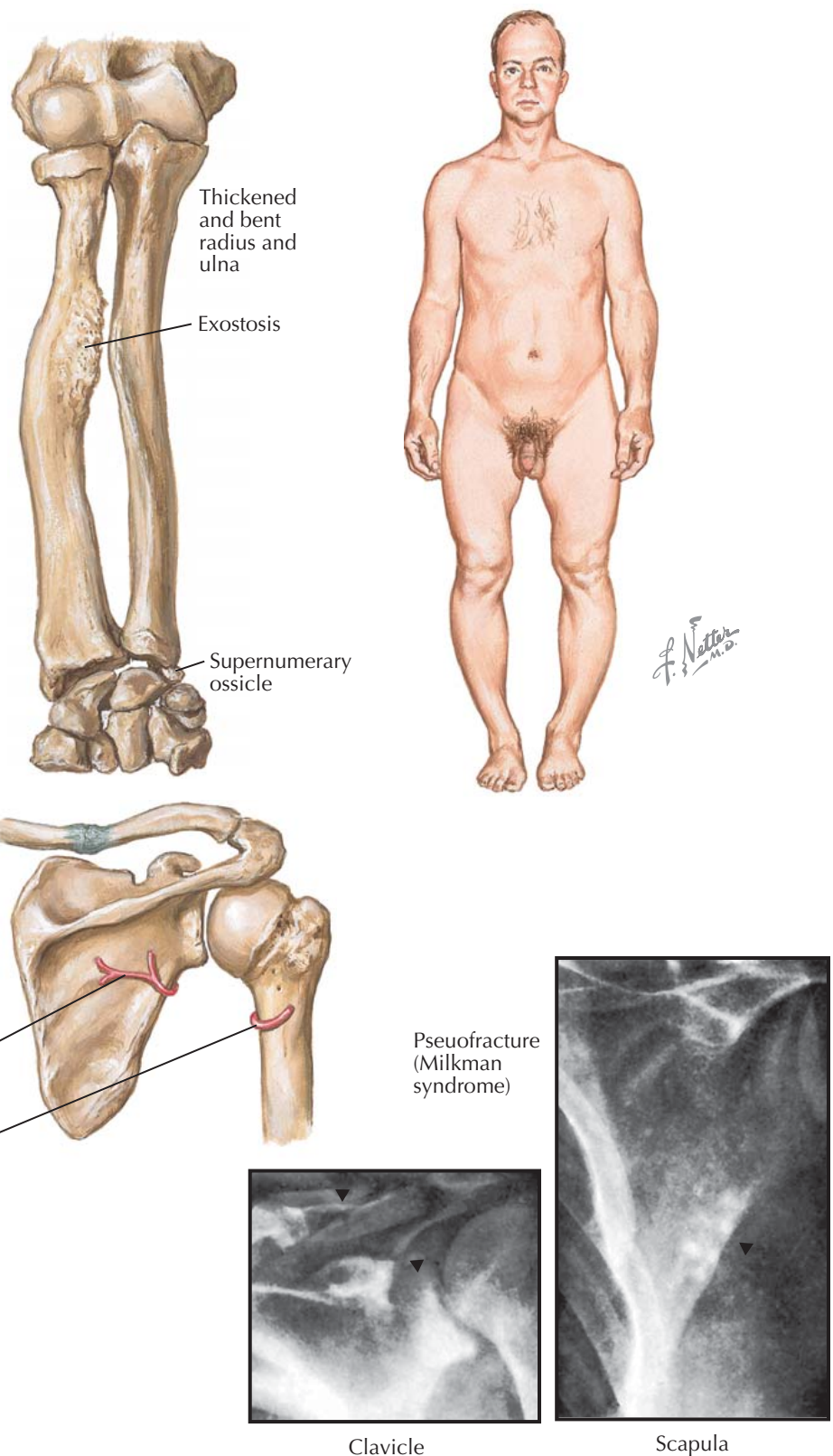
The findings on laboratory testing in adults with osteomalacia depend on the underlying pathophysiology. For example, the typical laboratory profile in patients with osteomalacia caused by nutritional vitamin D deficiency includes hypocalcemia, hypophosphatemia, low blood concentration of 25-hydroxyvitamin D, and increased blood concentration of parathyroid hormone (see Plate 6-18).

If there is doubt about the diagnosis of osteomalacia, a bone biopsy using double labeling with tetracycline

can be performed. Tetracyclines are fluorescent; they are deposited in a band at the mineralization front and are easily seen with a fluorescence microscope. A tetracycline is administered for 3 days, and the dosing is repeated 11 to 14 days later. An iliac crest bone biopsy is performed 3 to 5 days after the second tetracycline course is completed. The bone growth rate can be estimated on the basis of the distance between the two

bands of deposited tetracycline. Normal bone growth rate is 1  $\mu\text{m}$  per day. In patients with osteomalacia, the bone growth rate is slow, and there are large amounts of unmineralized osteoid.

The treatment of osteomalacia is guided by the underlying cause. For example, patients with vitamin D deficiency should be treated with vitamin D and calcium supplementation.



F. Netter M.D.



**Manifestations of advanced, diffuse Paget disease of bone** (may occur singly or in combination)**PAGET DISEASE OF THE BONE**

Paget disease of the bone (osteitis deformans) is a localized skeletal disorder of uncontrolled, highly active, large osteoclasts that results in increased bone resorption, which triggers intense and chaotic osteoblastic bone formation. Increased local bone blood flow is observed, and fibrous tissue develops in the adjacent bone marrow. The new bone lacks the usual lamellar structure and is disorganized. This disorder affects approximately 3% of adults older than 40 years; it is usually asymptomatic and evolves slowly.

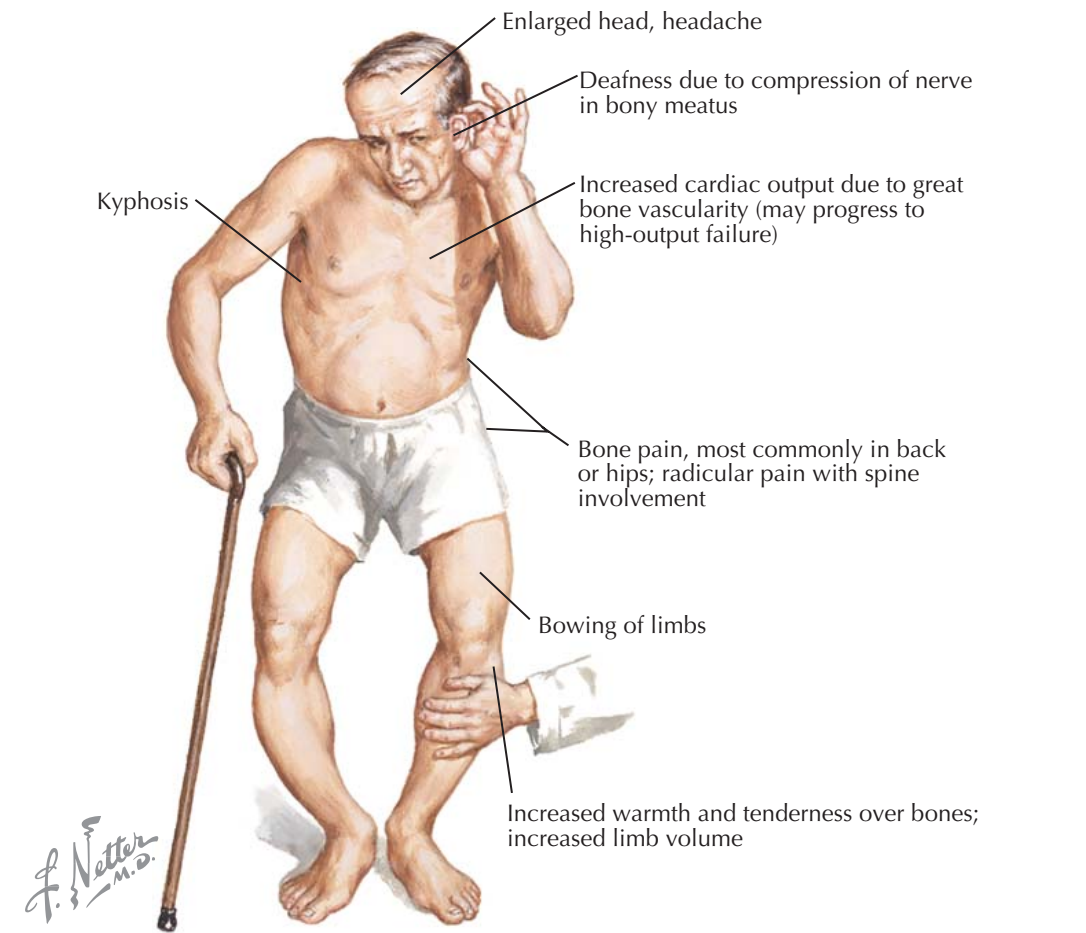
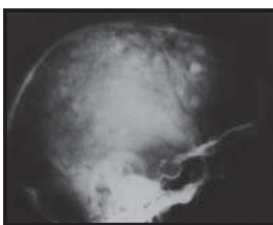
Although the prevalence of Paget disease is the same in men and women, it is more commonly symptomatic in men. The typical age at the time of detection is in the sixth decade of life. The method of detection is frequently incidental (e.g., increased serum alkaline phosphatase observed on routine blood testing or evidence seen on a radiograph done for other reasons). When symptomatic, the primary symptom is pain caused by periosteal stretching or microfractures. The bone pain is aggravated by weight bearing. The skin may be warm over pagetic bone because of the increased blood flow. Paget disease can affect one bone (monostotic) or multiple bones (polyostotic). The most common bones to be involved are the pelvis, spine, femur, skull, and tibia. With femur or tibia involvement, bowing of the legs is common. The bowing deformities in the bones of the lower extremities lead to gait changes. Transverse traumatic and pathologic bone fractures are common complications.

Spine involvement can lead to kyphosis and symptoms related to spinal cord compression. Hearing loss (caused by compression of the eighth cranial nerve or pagetic involvement of the middle ear ossicles) and skull deformities (frontal and occipital areas) are common when the skull is involved. Compression of the second, fifth, and seventh cranial nerves in the skull may result in visual symptoms and facial palsy. Skull base involvement predisposes to platybasia (invagination of the skull by cervical vertebral bodies) and hydrocephalus by compression of the cerebral aqueduct.

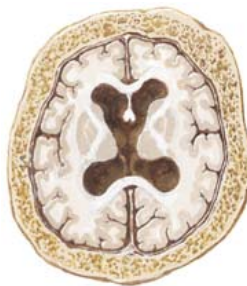Other complications of Paget disease may develop over time. Bony neoplasia (giant cell tumors [osteoclastomas], fibrosarcomas, chondrosarcomas, and osteosarcoma) occurs more frequently in patients with Paget disease. Primary hyperparathyroidism is also more common. The increased blood flow to bone (when more than 20% of the skeleton is involved) can lead to high-output heart failure.

**EVALUATION**

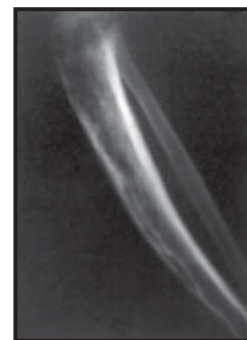
A thorough history and physical examination are important. A radionuclide bone scan can be helpful in identifying the sites of involved bone; areas of pagetic bone appear as focal areas of increased uptake. Plain radiographs should be obtained of all the sites identified on the bone scan to confirm Paget disease and its extent. For patients with skull involvement, baseline and annual audiograms should be performed. Because

**Mild cases often asymptomatic** (may be discovered incidentally on radiographs taken for other reasons)

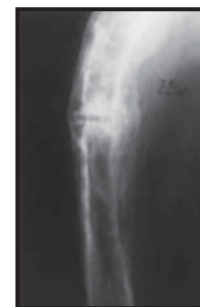Lateral radiograph shows patchy density of skull, with areas of osteopenia (osteoporosis circumscripta cranii)



Extremely thickened skull bones, which may encroach on nerve foramina or brainstem and cause hydrocephalus (shown) by compressing cerebral aqueduct



Characteristic radiographic findings in tibia include thickening, bowing, and coarse trabeculation, with advancing radiolucent wedge



Healing chalk-stick fracture

of the increased risk of primary hyperparathyroidism, serum calcium should be measured. If the imaging studies cannot distinguish between Paget disease and metastatic neoplasm, a bone biopsy may be needed. On bone biopsy, an irregular marble bone-type pattern and giant osteoclasts are seen. Measurement of bone markers at baseline and with treatment is useful. Markers of bone formation include blood concentrations of bone-specific alkaline phosphatase (reflecting cellular activity of osteoblasts), osteocalcin (an estimate

of the rate of synthesis of osteocalcin by osteoblasts), and C-terminal and N-terminal propeptides of type I collagen (reflecting changes in synthesis of new collagen). Bone resorption can be followed by measuring urinary excretion of hydroxyproline (reflecting breakdown of collagen in bone) and the collagen N-telopeptide and C-telopeptide crosslinks. Both the resorption and synthetic markers are increased in patients with untreated Paget disease and normalize with effective treatment.

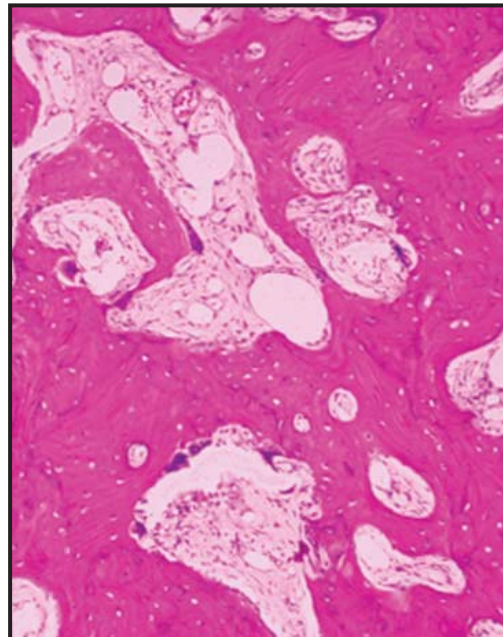
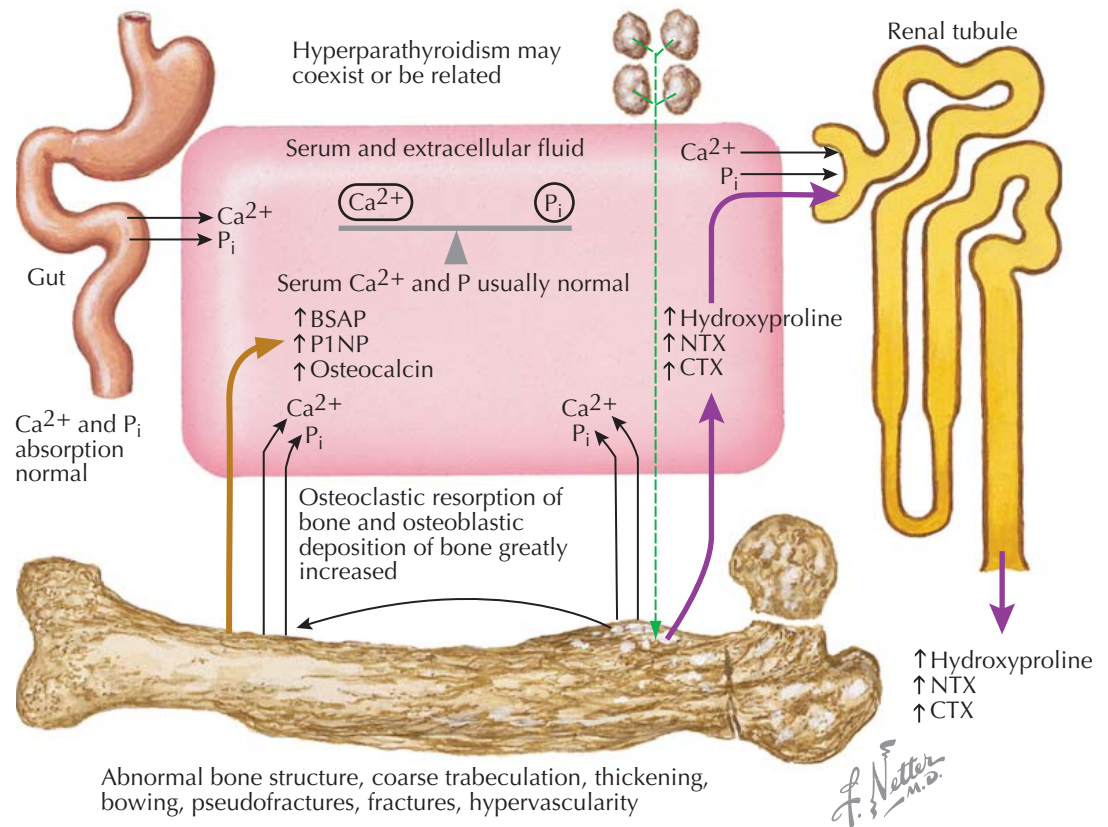
### PATHOGENESIS AND TREATMENT OF PAGET DISEASE OF THE BONE

The cause of Paget disease may be a viral trigger superimposed on a genetic predisposition. Viral inclusions are common in the pagetic osteoclasts and are absent in normal osteoclasts. Approximately 30% of patients with Paget disease have a family history of this disorder. The understanding of this genetic predisposition is evolving; mutations in the ubiquitin-associated domain of the gene encoding sequestosome 1 (*SQSTM1*) have been found in patients with familial and sporadic Paget disease. Likely a consequence of Paget disease, primary hyperparathyroidism is also more common in affected patients.

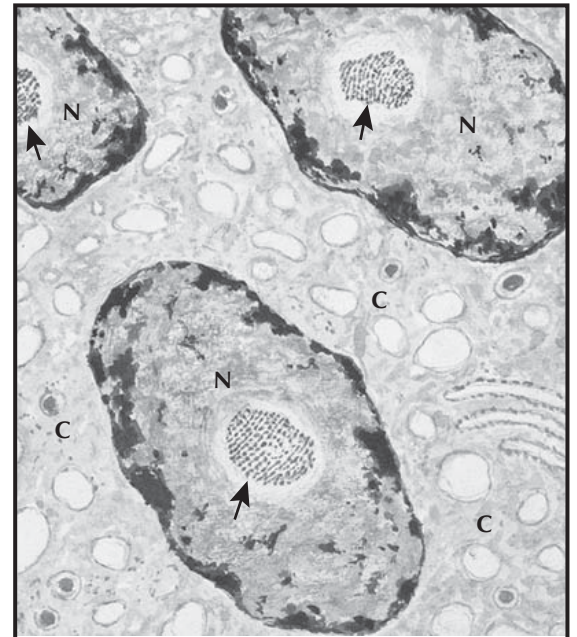
Most patients with Paget disease are asymptomatic and do not require treatment. The main indications for treatment are to ameliorate symptoms (e.g., bone pain, nerve compression) and to prevent complications. Treatment should be considered in asymptomatic patients who have moderately active disease (e.g., serum alkaline phosphatase concentration higher than three-fold above the upper limit of the reference range), sites of disease that can predispose to complications (e.g., major weight-bearing bones, joints), or extensive skull involvement. Also, early treatment in young patients should be considered with a goal of preventing more advanced disease.

The key to treatment is to suppress osteoclastic activity. In the past, the cornerstones of pharmacologic therapy were calcitonin and plicamycin. However, bisphosphonates specifically inhibit osteoclast activity and are the treatment of choice. Bisphosphonates (e.g., etidronate, pamidronate, alendronate, tiludronate, risedronate, and zoledronic acid) are long-acting pyrophosphate analogues that are poorly absorbed from the gastrointestinal tract. They are given either in large oral doses or intravenously. For example, in patients with mild disease, a single dose of intravenous pamidronate or zoledronic acid may maintain a biochemical remission for 12 to 18 months. The main adverse effect of intravenous bisphosphonates is a flulike symptom complex in 20% of patients that lasts for 1 or 2 days after the infusion. With oral bisphosphonates, the main adverse effect is esophageal irritation; thus, they should be taken in the fasting state with 240 mL of water, and patients should remain in the upright position for at least 30 minutes. Oral bisphosphonates are administered for 4 to 6 months or until the bone markers normalize. Because bisphosphonates can lower the serum calcium level and cause secondary hyperparathyroidism, all patients should take optimal oral calcium and vitamin D supplementation. Adequate vitamin D repletion should be documented with measurement of the serum 25-hydroxyvitamin D concentration.

Measurement of bone resorption and formation markers at baseline and with treatment is useful. With bisphosphonate treatment, resorption markers decrease first followed by bone formation markers. Markers of bone formation include blood concentrations of bone-specific alkaline phosphatase (BSAP) (reflecting cellular activity of osteoblasts), osteocalcin (an estimate of the rate of synthesis of osteocalcin by osteoblasts), and



Section of bone shows intense osteoclastic and osteoblastic activity and mosaic of lamellar bone



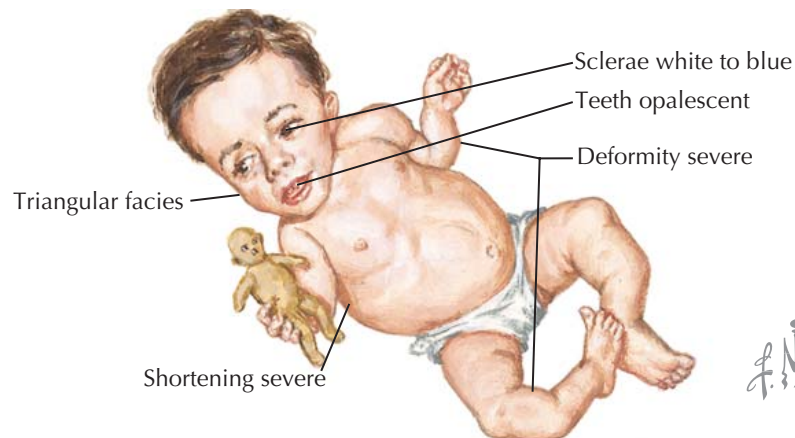
Electron-microscopic view of multinucleated osteoclast with nuclear inclusions that may be viruses (arrows). C = cytoplasm; N = nuclei

N-terminal propeptides of type I collagen (P1NP) (reflecting changes in synthesis of new collagen). Bone resorption can be followed by measuring urinary excretion of hydroxyproline (reflecting breakdown of collagen in bone) and the collagen crosslinks N-telopeptide (NTX) and the C-telopeptide crosslink (CTX). Both the resorption and synthetic markers are increased in patients with untreated Paget disease and normalize with effective treatment.

Bone markers can be periodically measured every 2 to 6 months after a single intravenous infusion of a bisphosphonate, and when they start to rise above the reference range, an additional infusion can be considered. A similar strategy with oral bisphosphonates can be used: treatment with an oral agent for 4 to 6 months or until the bone markers normalize, then treatment reinitiation when the bone markers become abnormal again.



## MODERATE TO SEVERE OSTEOGENESIS IMPERFECTA TYPES III, IV, V, VI, VII, AND VIII



*F. Netter M.D.*

## OSTEOGENESIS IMPERFECTA

Osteogenesis imperfecta (OI), frequently referred to as “brittle bone disease,” is a rare (one per 200,000 live births) hereditary connective tissue disorder with a variable clinical presentation. Moderate to severe OI is evident in infancy with bone fractures associated with little or no trauma; mild OI may not become clinically evident until adulthood when affected individuals present with premature osteoporosis.

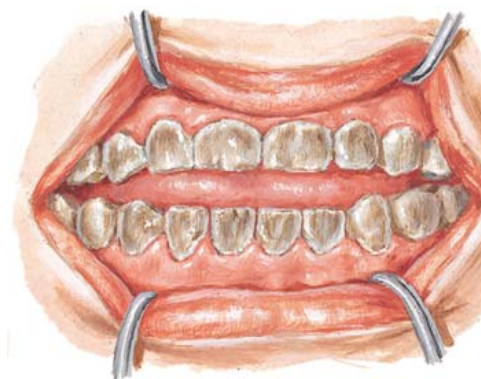
Approximately 90% of individuals with OI have autosomal dominant germline mutations in the genes encoding the proteins that form type I collagen (*COL1A1* and *COL1A2*). Both normal structure and normal amount of type I collagen are necessary for normal bones, sclerae, tendons, ligaments, teeth, and skin. Mutations in other collagen-related genes have been found in a minority of patients with OI. For example, germline mutations in the gene encoding the cartilage-associated protein—important for the post-translational modification of collagen types I and II—have been documented in some patients with OI. Affected individuals in the same family may have markedly different disease severity, implicating other genetic or environmental factors that affect the pathogenesis of OI.

The key clinical features of OI include recurrent bone fractures, blue sclerae, opalescent teeth (dentinogenesis imperfecta with fragile and discolored teeth), easy bruising, basilar skull deformities, hearing loss, and increased ligament laxity. OI can be classified clinically on the basis of disease severity.

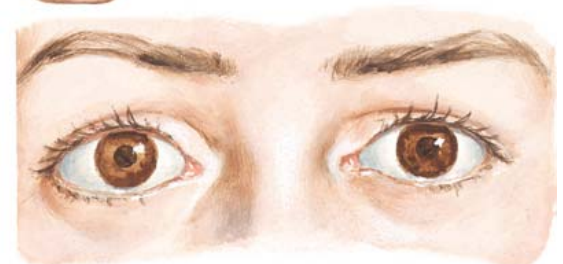Type I OI (mild OI) is associated with mild manifestations, including infrequent bone fractures (primarily long bones and ribs), normal stature, premature osteoporosis, mild scoliosis, blue sclerae, teeth that appear normal or opalescent, and premature hearing loss. Locomotion is usually normal. Type I OI is usually caused by a deletion of one allele of the *COL1A1* procollagen gene, resulting in normal collagen structure but decreased production.

Type II OI (lethal perinatal OI), characterized by multiple severe fractures and respiratory failure, leads to death in utero or shortly after birth.

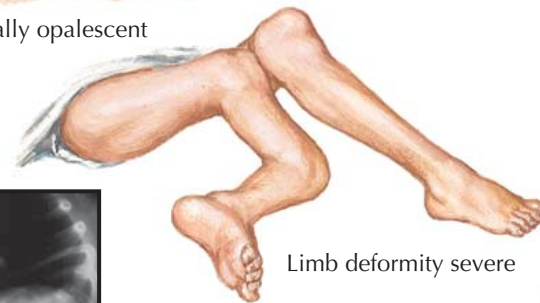
OI types III, IV, V, VI, VII, and VIII are associated with severe bone fragility. Children present with frequent fractures and severe limb deformities. Fractures can even include the ossicles of the ear, resulting in conductive hearing loss. Kyphoscoliosis and short stature are typical of moderate to severe OI. Locomotion is usually severely limited. Hypermobility of the



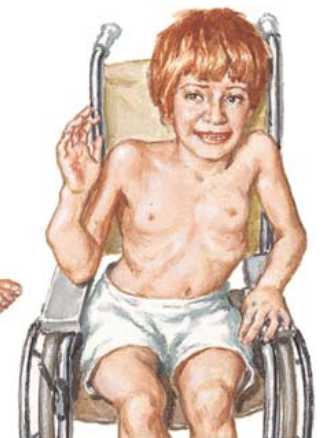Teeth usually opalescent



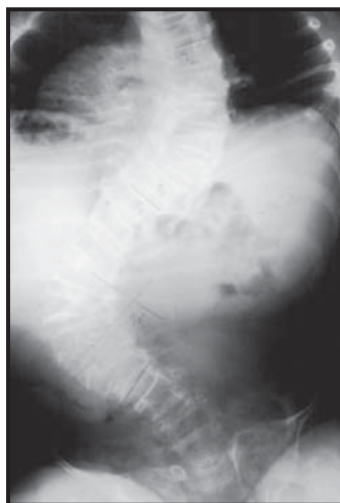
Sclerae normal to blue



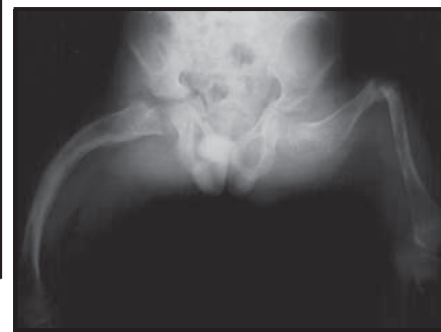Limb deformity severe



Locomotion severely limited



Radiograph shows severe scoliosis and chest deformity

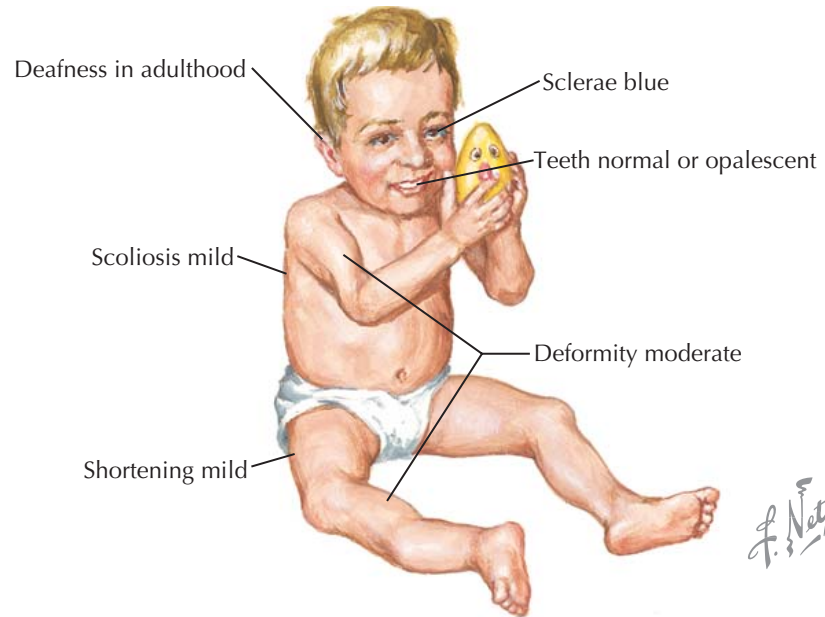


Radiograph shows very thin and osteoporotic bones; fracture rate high

joints at the wrists, hands, and feet may be evident. Patients with OI types IV, V, VI, VII, or VIII can have normal sclerae. Type III is a progressive deforming form of OI that eventually results in the use of a wheelchair. Type IV OI is associated with less growth retardation than type III. Type V OI, previously termed “congenital brittle bones with redundant callus formation,” is not associated with dentinogenesis imperfecta. Type VI OI, previously termed “congenital brittle bones with

mineralization defect,” is associated with an accumulation of osteoid in bone tissue and a fish-scale pattern of bone lamellation. Type VII OI, previously termed “congenital brittle bones with rhizomelia,” is recessive in inheritance and has been identified in only one kindred. Type VIII OI is recessive in inheritance and is associated with prolyl 3-hydroxylase 1 deficiency, resulting in undermineralized ribs and long bones and matrix disorganization.

MILD OSTEOGENESIS IMPERFECTA TYPE I



*F. Netter M.D.*

**OSTEOGENESIS IMPERFECTA**

(Continued)

All laboratory parameters can be normal in patients with OI. Hypercalciuria may be present, and it correlates with the severity of bone disease (increased life-long risk of fractures and shorter stature). In patients with more severe disease, bone marker measurement may be abnormal. Decreased levels of bone formation markers may be found. For example, the blood concentrations of the following bone formation markers may be low: bone-specific alkaline phosphatase (reflecting cellular activity of osteoblasts), osteocalcin (an estimate of the rate of synthesis of osteocalcin by osteoblasts), and the C-terminal and N-terminal propeptides of type I collagen (reflecting changes in synthesis of new collagen). Bone resorption markers that may be increased above the upper limit of the reference range are urinary excretion of hydroxyproline (reflecting breakdown of collagen in bone) and collagen crosslinks (N-telopeptide crosslinks and the C-telopeptide crosslink).

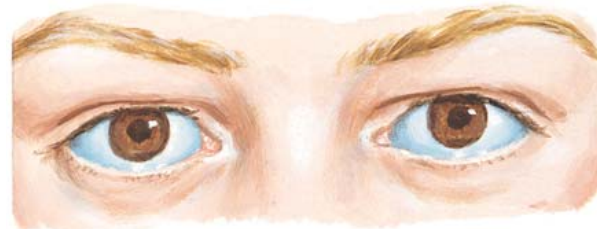
A bone biopsy is usually not needed to confirm the diagnosis. However, if performed, bone histology shows disorganized bone, increased bone turnover, decreased cortical width, decreased trabecular number and width, and decreased cancellous bone volume.

The diagnosis of OI is based on the presentation of increased bone fragility, positive family history of bone fragility, blue sclerae, dentinogenesis imperfecta, hearing loss, and molecular genetic testing for mutations in *COL1A1* and *COL1A2*. In addition to OI, the differential diagnosis of frequent bone fractures in childhood includes rickets and child abuse. Less common disorders to consider include idiopathic juvenile osteoporosis (nonhereditary form of isolated and transient childhood osteoporosis), hypophosphatasia (autosomal recessive disorder caused by a deficiency of tissue nonspecific alkaline phosphatase; see Plate 6-27), juvenile Paget disease (autosomal recessive disorder), polyostotic fibrous dysplasia (McCune-Albright syndrome) with bony cystic or ground glass lesions, Ehlers-Danlos syndrome (caused by a deficiency in the collagen crosslinking enzyme lysyl oxidase), Menkes disease (copper deficiency that impairs the function of the collagen crosslinking enzyme lysyl oxidase), and Cole-Carpenter syndrome (osteoporosis, craniosynostosis, hydrocephalus, proptosis, and short stature).

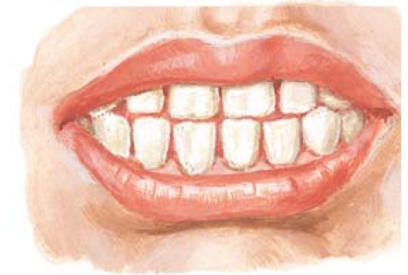**TREATMENT**

A multidisciplinary team—including specialists in genetics, orthopedics, neurology, physical therapy, occupational therapy, dental care, otolaryngology, psychology, and endocrinology—is needed for effective treatment of symptoms and complications related to OI. Treatment goals include decreasing bone fracture incidence, enhancing mobility, preventing bone deformities and scoliosis, and managing pain effectively.

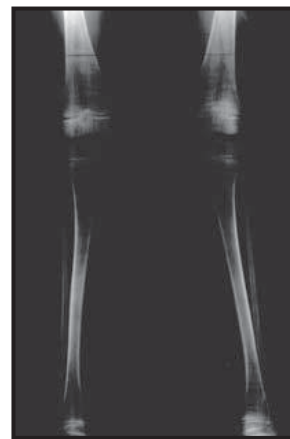Patients with OI should be evaluated regularly for bone mineral density (BMD), fractures detected on



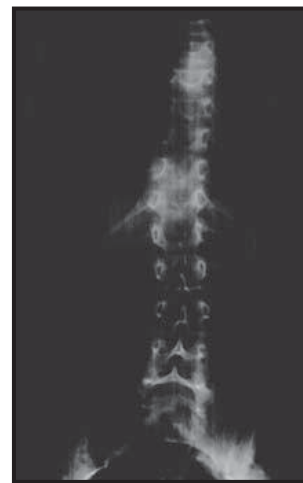Sclerae usually blue



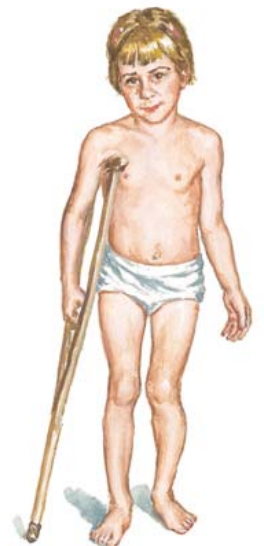Teeth normal or opalescent



Radiograph shows thin and osteoporotic bones (variable). Fracture rate moderate; deformity mild, often amenable to intramedullary fixation



Radiograph shows mild scoliosis



Locomotion normal or with crutch

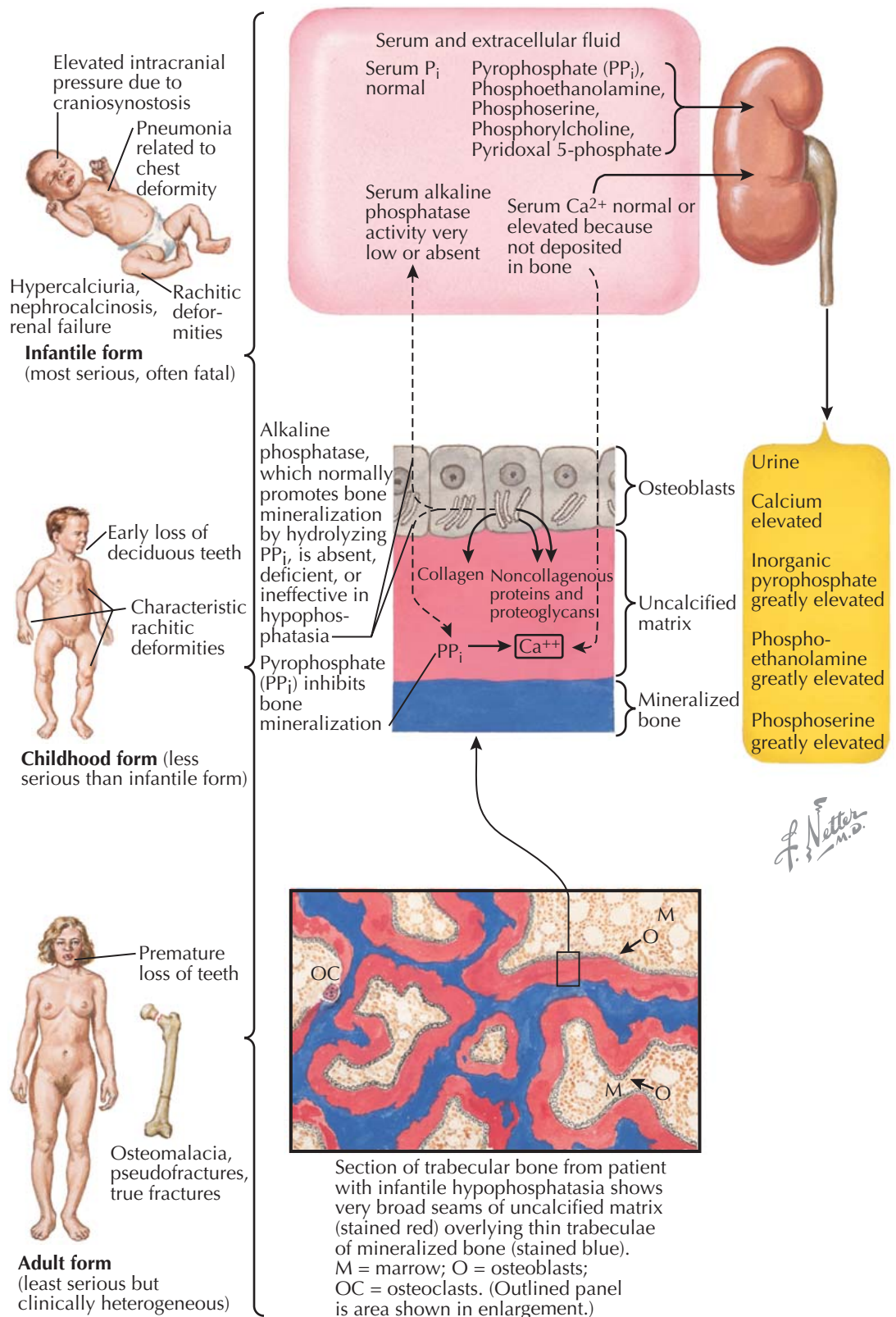
skeletal radiographs, pulmonary function, and hearing loss. Patients with OI type III should also have periodic echocardiograms to assess for aortic valve insufficiency caused by aortic root dilation. Nerve compression syndromes may develop with basilar skull deformities.

Pharmacologic therapy with a bisphosphonate agent should be considered in patients with any form of OI unless there is a mineralization defect (e.g., type VI OI). Bisphosphonate therapy inhibits bone resorption and

bone turnover and results in improved BMD, decreased number of fractures, and improved mobility. Treatment options under investigation include growth hormone, bone marrow transplantation, and gene therapy.

Individuals with type I OI have a normal life expectancy. Individuals with moderately severe OI may have a shortened lifespan related to thoracic deformities and immobility.





## HYPHOSPHATASIA

Hypophosphatasia, a rare inherited disorder, is associated with low concentrations of alkaline phosphatase in serum and bone that cause defective bone and tooth mineralization, resulting in osteomalacia and severe periodontal disease. Hypophosphatasia results from mutations in the alkaline phosphatase gene (*ALPL*) that encodes the tissue-nonspecific isoenzyme of alkaline phosphatase. Perinatal and infantile forms are inherited in an autosomal recessive manner, and milder forms that present later in life can be either autosomal dominant or autosomal recessive, depending on the specific gene mutation(s).

The perinatal lethal form, with an estimated prevalence of one in 100,000, results from complete absence of alkaline phosphatase. Perinatal lethal hypophosphatasia causes lack of mineralized bone in utero, severe deformities with skin-covered osteochondral spurs protruding from the legs and forearms, rachitic deformities of the chest, hypoplastic lungs, premature craniosynostosis with secondary increased intracranial pressure, seizures, hypercalcemia, nephrocalcinosis, and renal failure.

Milder *ALPL* mutations, characterized by autosomal dominant transmission and variable expressivity, are associated with presentation during childhood or in adulthood with early loss of teeth and osteomalacia. Childhood hypophosphatasia presents with skeletal deformities (e.g., enlarged joints), focal defects at the end of long bones, short stature, and premature loss of teeth. The bone disease may seem to spontaneously resolve, only to reappear in adulthood. Individuals with the adult form of hypophosphatasia usually become symptomatic in the fourth or fifth decades of life. Presenting symptoms include thigh pain caused by femoral pseudofractures, metatarsal stress fractures, chondrocalcinosis, and odontohypophosphatasia (severe dental caries, loose teeth on dental examination, and premature exfoliation of primary teeth [especially incisors]).

Alkaline phosphatases catalyze the hydrolysis of phosphomonoesters with release of inorganic phosphorus. At the osteoblast cell surface, tissue-nonspecific isoenzyme of alkaline phosphatase generates inorganic phosphate that is needed for hydroxyapatite crystallization. In addition, the buildup of pyrophosphate inhibits bone mineralization.

Hypophosphatasia should be suspected when the blood concentration of total alkaline phosphatase is below the reference range. Blood total alkaline phosphatase concentrations may be decreased in other settings (e.g., early pregnancy, anemia, or hypothyroidism).

Hypophosphatasia can be confirmed by finding increased blood and urine concentrations of organic phosphate compounds (e.g., phosphoethanolamine, phosphorylcholine, and pyridoxal 5-phosphate). Findings on bone biopsy are indistinguishable from findings of other forms of rickets. In adults, blood concentrations of calcium and phosphorus are normal.

Genetic testing is a key step to confirm the diagnosis of hypophosphatasia. Most mutations in the *ALPL* gene are missense mutations; the rest are deletions, splice site

mutations, nonsense mutations, or small insertions. The array of different mutations is responsible in part for the variable clinical expression; in other words, patients with severe disease have *ALPL* mutations that result in no enzyme activity, and patients with mild disease have *ALPL* mutations that result in some tissue-nonspecific isoenzyme of alkaline phosphatase activity.

Treatment is directed at signs and symptoms. To date, there is no curative treatment.

# **LIPIDS AND NUTRITION**



This page intentionally left blank

## CHOLESTEROL SYNTHESIS AND METABOLISM

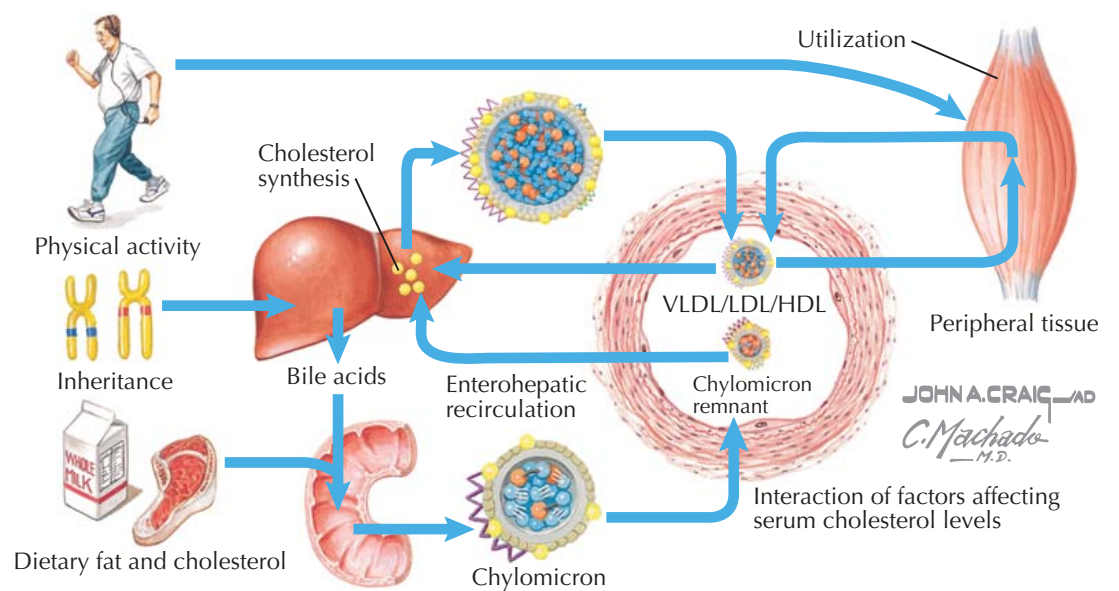
Cholesterol is a 4-ring hydrocarbon structure with an 8-carbon side chain. Cholesterol serves as a key component of cell membranes, and it is the substrate for synthesis of steroid hormones and bile acids. Cholesterol is either synthesized endogenously or obtained exogenously by ingestion of animal fats (e.g., meat, eggs, and dairy products). The biosynthesis of cholesterol starts with three molecules of acetate that are condensed to form 3-hydroxy-3-methylglutaryl coenzyme A (HMG-CoA). HMG-CoA is then converted to mevalonic acid by HMG-CoA reductase—the rate-limiting step in cholesterol biosynthesis—and mevalonic acid is converted to cholesterol. Competitive inhibitors of HMG-CoA reductase (statins) are used clinically to decrease cholesterol biosynthesis and to lower serum cholesterol concentrations.

Cholesterol is metabolized by the biliary excretion of free cholesterol or by conversion to bile acids that are secreted into the intestine. Approximately 50% of biliary cholesterol and 97% of bile acids are reabsorbed in the small intestine and recirculate to the liver (enterohepatic circulation); the remaining biliary cholesterol and bile acids are excreted in the feces.

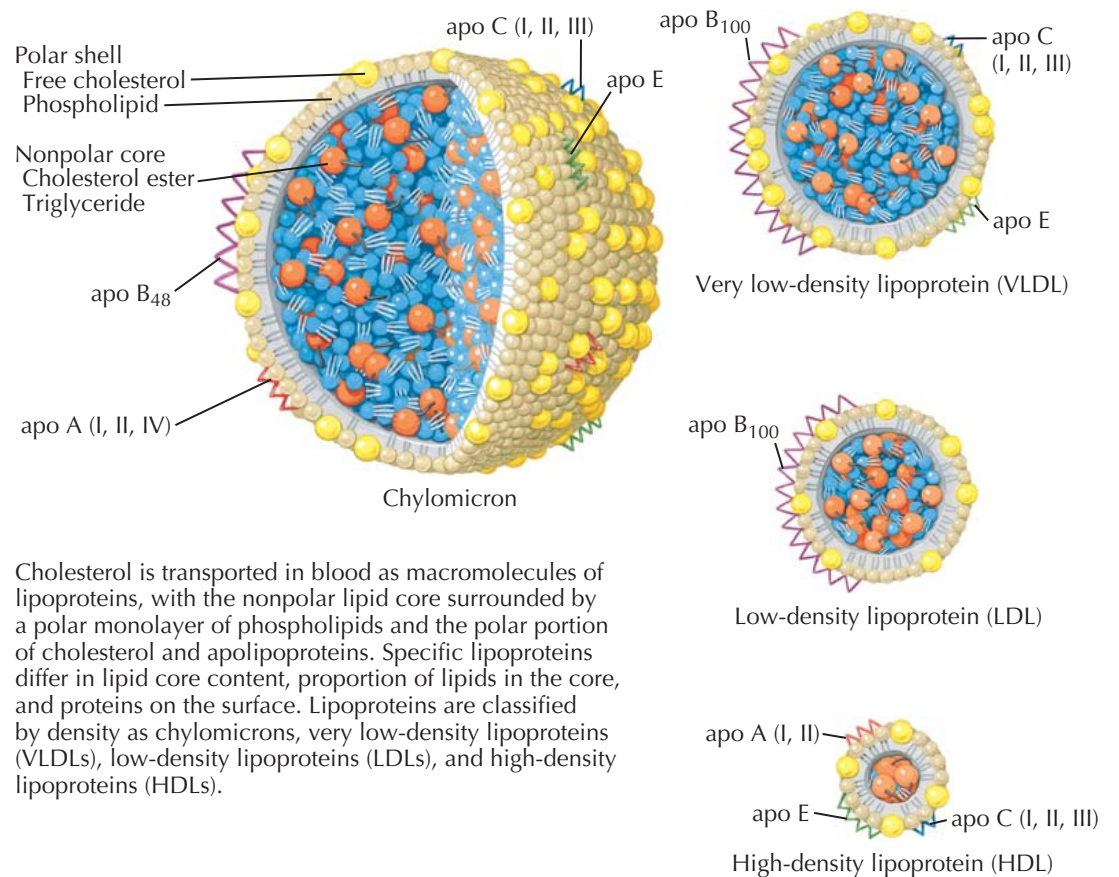
Lipoproteins, which are composed of protein, triglycerides, cholesterol esters, and free cholesterol, are macromolecules that transport cholesterol and triglycerides in the blood to target tissues (for bile acid formation, adrenal and gonadal steroidogenesis, energy production). The 12 proteins in the lipoproteins are termed *apolipoproteins* (apo) and are given letter designations. The apolipoproteins act as ligands for receptors and as cofactors for enzymes. The lipoproteins have a nonpolar lipid core surrounded by a polar monolayer of phospholipids and the polar portions of cholesterol and apolipoproteins. Specific lipoproteins differ in the lipid core content, the proportion of lipids in the core, and the protein on the surface. Lipoproteins are classified on the basis of density as chylomicrons, very low-density lipoprotein (VLDL), low-density lipoprotein (LDL), and high-density lipoprotein (HDL).

- Chylomicrons are large, low-density particles that transport dietary lipid (see Plate 7-2). The associated apolipoproteins include apo A (I, II, IV); apo B<sub>48</sub>; apo C (I, II, III), and apo E.
- VLDL transports primarily triglycerides. The associated apolipoproteins include apo B<sub>100</sub>, apo C (I, II, III), and apo E.
- LDL transports primarily cholesterol esters and is associated with apo B<sub>100</sub>.
- HDL also transports cholesterol esters. HDL is associated with apo A (I, II), apo C (I, II, III), and apo E.

How lipids are transported and metabolized is determined in large part by the apolipoproteins. For example, apo AI is not only a structural protein in HDL, but it also activates lecithin-cholesterol acyltransferase (LCAT). Apo AII is a structural protein of HDL and activates hepatic lipase. Apo AIV is an activator for



### Lipoprotein structure



Cholesterol is transported in blood as macromolecules of lipoproteins, with the nonpolar lipid core surrounded by a polar monolayer of phospholipids and the polar portion of cholesterol and apolipoproteins. Specific lipoproteins differ in lipid core content, proportion of lipids in the core, and proteins on the surface. Lipoproteins are classified by density as chylomicrons, very low-density lipoproteins (VLDLs), low-density lipoproteins (LDLs), and high-density lipoproteins (HDLs).

lipoprotein lipase (LPL) and LCAT. Apo B<sub>100</sub> is a structural protein for VLDL and LDL and serves as a ligand for the LDL receptor. Apo B<sub>48</sub> is critical for the formation and secretion of chylomicrons. Apo CI serves to activate LCAT. Apo CII is a key cofactor for LPL. Apo CIII inhibits the hydrolysis of triglycerides by LPL. The three genetically determined isoforms of apo E clear lipoproteins (VLDL and chylomicrons) from the circulation by serving as ligands for the VLDL remnant receptor. The presence of two copies of the apo E2

isoform (homozygous) results in less efficient clearance of chylomicrons and VLDL and is clinically referred to as *familial dysbetalipoproteinemia* (see Plate 7-9).

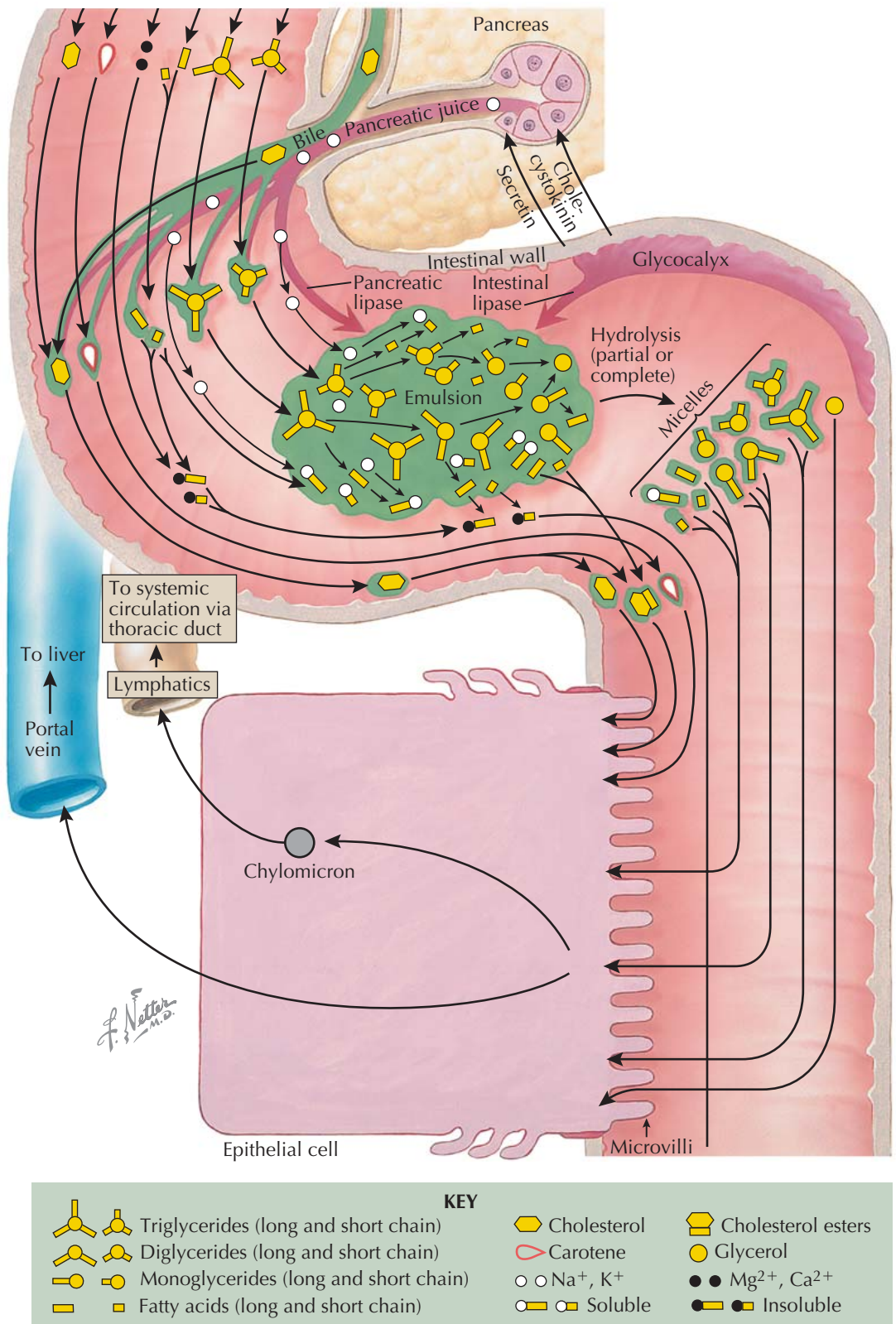
The cholesterol concentration in the blood is controlled by the LDL receptor. The LDL receptor mediates the endocytosis of apo B- and apo E-containing lipoproteins (LDL, chylomicron remnants, VLDL, and VLDL remnants) into cells. The number of LDL receptors on the cell surface is regulated to maintain normal intracellular cholesterol content.



### GASTROINTESTINAL ABSORPTION OF CHOLESTEROL AND TRIGLYCERIDES

Dietary fat digestion starts in the stomach and is completed in the small intestine. Most dietary lipid is in the form of long-chain triglycerides (three fatty acids [with at least 12 carbon atoms each] that are esterified to glycerol). Other dietary lipids include phospholipids, plant sterols, cholesterol, and fat-soluble vitamins (vitamins A, D, E, and K). Gastric peristalsis and mixing serve to disperse dietary triglycerides and phospholipids into an emulsion. Intestinal (gastric) lipase acts on the oil droplets in the emulsion to generate free fatty acids and diglycerides. The presence of fatty acids in the small intestine leads to the secretion of cholecystokinin. Cholecystokinin promotes the secretion and release of pancreatic enzymes into the intestinal lumen (see Plate 5-2); it also promotes contraction of the gallbladder, leading to release of concentrated bile. The pancreatic lipase metabolizes triglycerides to fatty acids and monoglycerides. Another pancreatic enzyme is phospholipase A<sub>2</sub>, which breaks down dietary phospholipids.

By partially solubilizing water-insoluble lipids, bile salt micelles facilitate intestinal transport of lipids to the intestinal epithelial cells (enterocytes) for absorption. Specific carrier proteins facilitate diffusion of lipids across the brush border membrane. In addition, enterocytes in the duodenum and proximal jejunum directly take up long-chain fatty acids by passive transfer. Medium-chain fatty acids (six to 12 carbon atoms) are not esterified, and the enterocytes release these directly into the portal venous system along with other absorbed nutrients. Long-chain fatty acids and monoglycerides are re-esterified into triglyceride in the smooth endoplasmic reticulum of the enterocyte. In addition, cholesterol is esterified by cholesterol acyltransferase. The reassembled lipids are coated with apolipoproteins (apo) (see Plate 7-1) to produce chylomicrons in the Golgi apparatus. The primary intestinal apolipoproteins are apo B<sub>48</sub>, apo AI, and apo AIV. Chylomicrons acquire apo C and apo E during transit in the lymph and blood. Approximately 85% of the chylomicron is composed of triglyceride. The chylomicrons are too large to cross intercellular junctions linking to capillary epithelial cells. Thus, chylomicrons are transported across the basolateral membrane by exocytosis into the



mesenteric lymphatic system that flows to the thoracic duct, where they enter the systemic circulation. Chylomicrons are therefore present in postprandial plasma but are absent with fasting. Apo CII is a cofactor for lipoprotein lipase, the enzyme that hydrolyzes the core triglycerides of the chylomicron and releases free fatty acids. Lipoprotein lipase is bound to the capillary endothelial cells in muscle, adipose, and breast tissues. The activity of lipoprotein lipase is regulated based on energy needs. For example, in the fasting state,

lipoprotein lipase activity increases in heart muscle and decreases in adipose tissue. In addition, in the postpartum state, breast lipoprotein lipase activity increases 10-fold to promote milk production. Because of the action of lipoprotein lipase, the circulating chylomicrons become progressively smaller, and triglyceride-poor chylomicron remnants are removed from the circulation in the liver, where apo E is the ligand for the hepatic low-density lipoprotein receptor-related protein.

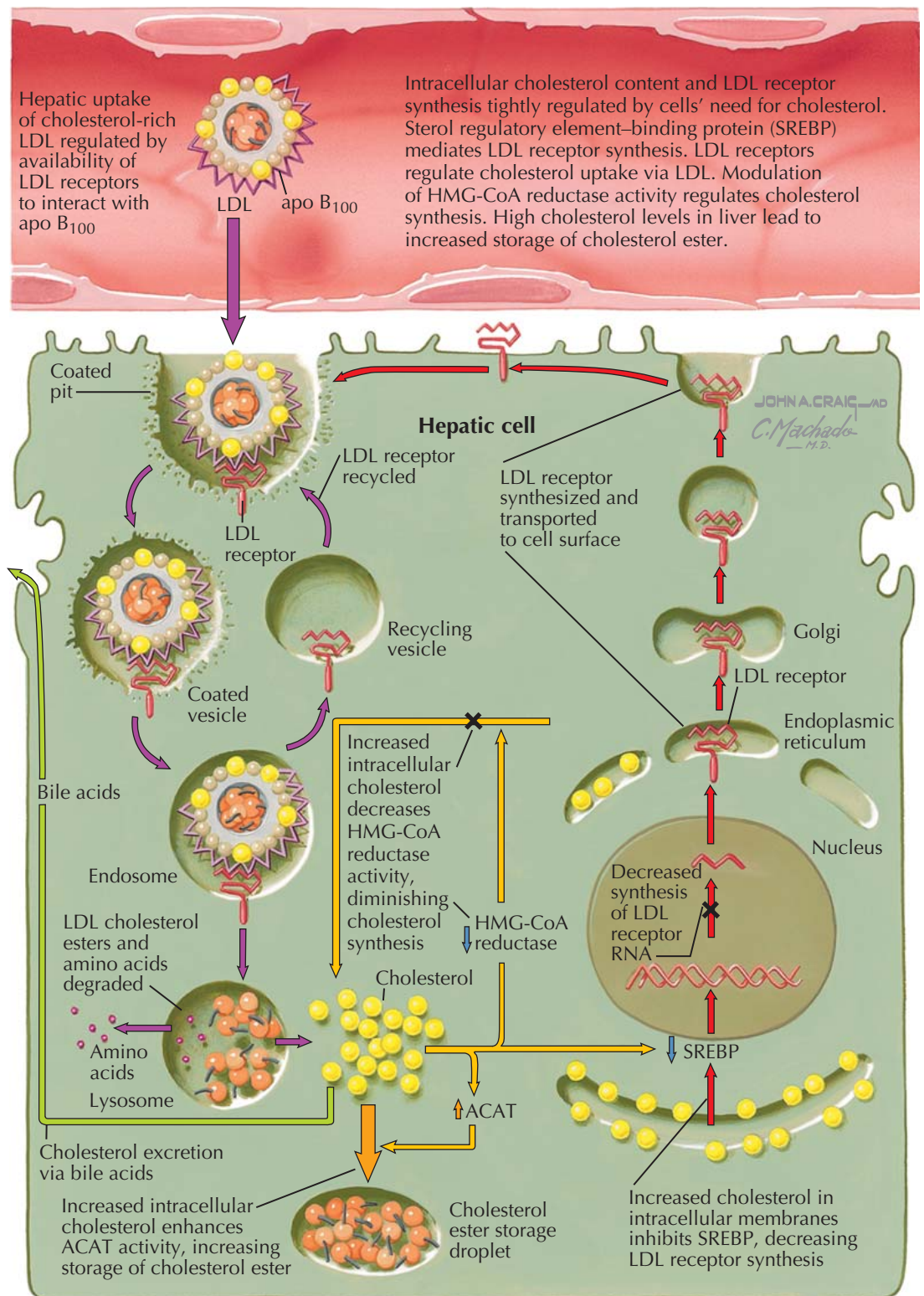
## REGULATION OF LOW-DENSITY LIPOPROTEIN RECEPTOR AND CHOLESTEROL CONTENT

The cholesterol concentration in the blood is controlled primarily by the low-density lipoprotein (LDL) pathway. Approximately 70% of total plasma cholesterol is LDL. The LDL receptor—located on the surface of all cells—facilitates the internalization of lipoproteins. Approximately 75% of LDL is taken up by hepatocytes. The number of LDL receptors on each cell is in flux and is tightly regulated to keep the intracellular cholesterol concentration constant. Sterol regulatory element-binding protein (SREBP) mediates LDL receptor synthesis. Thus, when a cell's cholesterol content is in positive balance, LDL receptor expression is downregulated by decreased expression of SREBP. In addition, with increased cellular cholesterol, the cholesterol synthetic enzyme 3-hydroxy-3-methylglutaryl coenzyme A (HMG-CoA) reductase is also downregulated. When a cell's cholesterol content is in negative balance, increased expression of SREBP leads to increased numbers of LDL receptors and enhanced cholesterol uptake from the circulation.

The LDL receptor binds lipoproteins that contain the apolipoproteins (apo) apo B<sub>100</sub> and apo E (e.g., LDL, chylomicron remnants, very low-density lipoprotein [VLDL], and VLDL remnants). The lipoprotein-LDL receptor complex localizes to an area of the cell membrane referred to as the "coated pit." The coated pit contains clathrin that facilitates the clustering of LDL receptors to an area of the cell membrane that can invaginate to form an intracellular vesicle (endosome). As the endosome becomes more acidic, the LDL receptor and lipoprotein dissociate and the lipoproteins are degraded in lysosomes. The free LDL receptor returns to the cell surface in a recycling vesicle. The intracellular pool of cholesterol and cholesterol esters in the hepatocyte is dynamic. Increased intracellular cholesterol enhances acyl-CoA:cholesterol acyltransferase (ACAT) activity, increasing the esterification and storage of cholesterol. In turn, cholesterol ester hydrolase can generate free cholesterol.

The guidelines from the 2002 National Cholesterol Education Program suggest the following cutoffs for plasma total cholesterol concentrations: less than 200 mg/dL, desirable; between 200 and 240 mg/dL, borderline high; and greater than 240 mg/dL, high. Increased blood concentrations of cholesterol are related to increased production or secretion into the circulation or to decreased clearance or removal from the circulation (or both).

Familial hypercholesterolemia (FH) is an autosomal dominant disorder that increases susceptibility to coronary heart disease (CHD). FH is caused by mutations in the gene encoding the LDL receptor, leading to two- to threefold increased plasma cholesterol concentrations in heterozygous individuals (prevalence of one in 500) and a three- to sixfold increase above the upper limit of the reference range in homozygous individuals. These patients may have characteristic physical findings (see Plates 7-6 and 7-7). Familial defective apo B<sub>100</sub> is a disorder caused by mutations in the gene encoding apo B<sub>100</sub>. Defective apo B<sub>100</sub> apolipoprotein binding to the LDL receptor results in a high plasma LDL concentration and an increased CHD risk.



Type III hyperlipoproteinemia (familial dysbetalipoproteinemia) is an autosomal recessive disorder characterized by moderate to severe hypercholesterolemia and hypertriglyceridemia and is the result of mutations in the gene encoding apo E, with resultant defective lipoprotein binding to the LDL receptor (see Plate 7-9).

Elevated plasma lipoprotein(a) (Lp[a]) is a disorder characterized by increased concentrations of modified LDL particles in the plasma, in which the apo B<sub>100</sub> protein of LDL is covalently bonded to Lp(a). Lp(a) has

structural similarity to plasminogen and can interfere with fibrinolysis. Increased plasma Lp(a) is associated with increased CHD risk.

Polygenic hypercholesterolemia refers to combinations of multiple genetic and environmental factors that contribute to hypercholesterolemia. Polygenic hypercholesterolemia is diagnosed by exclusion of other primary genetic causes, absence of tendon xanthomas, and documentation that hypercholesterolemia is present in fewer than 10% of first-degree relatives.



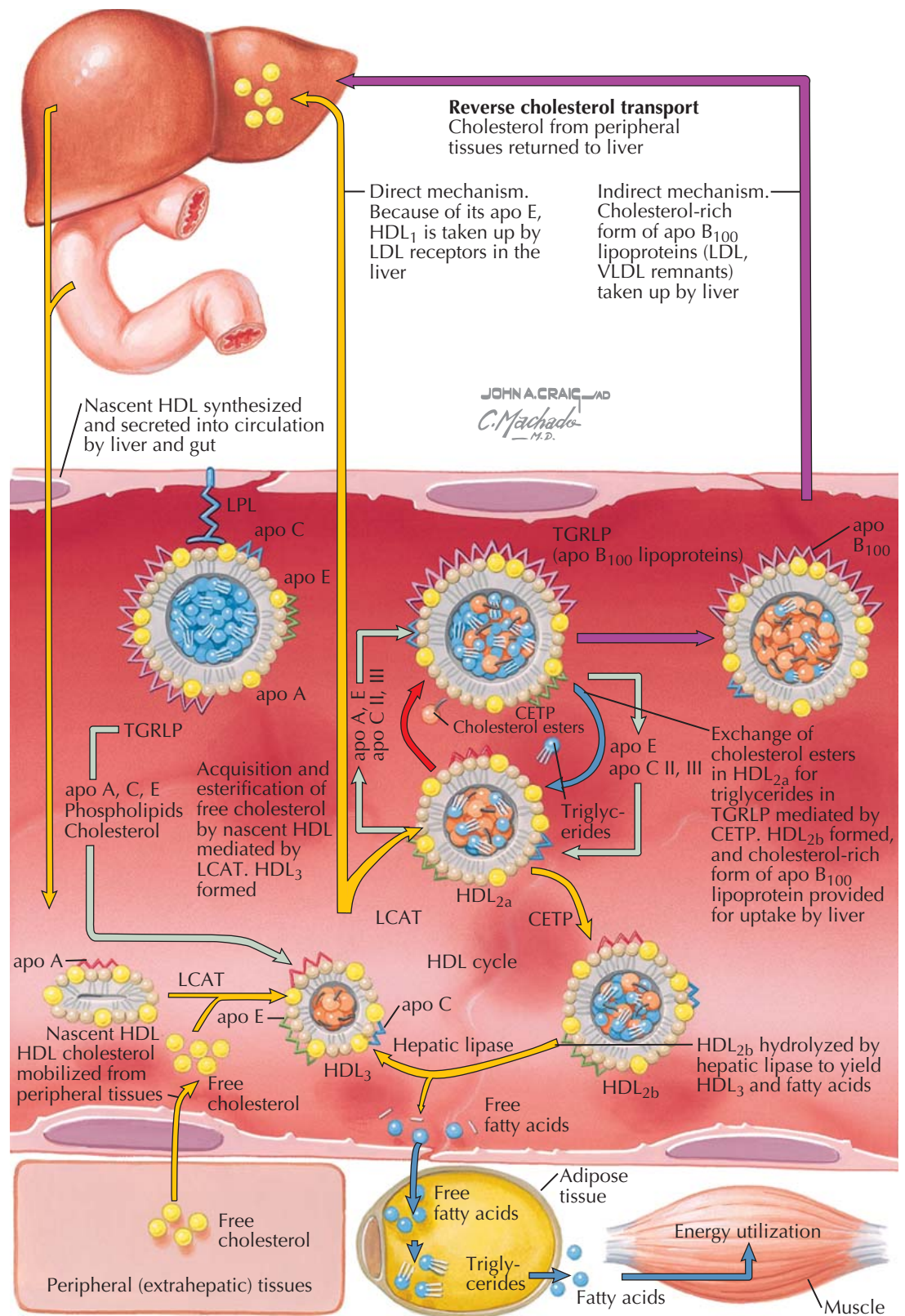
## HIGH-DENSITY LIPOPROTEIN METABOLISM AND REVERSE CHOLESTEROL TRANSPORT

High-density lipoproteins (HDLs) are small particles that contain 50% lipid (phospholipid, cholesteryl esters, free cholesterol, triglyceride) and 50% protein. The main apolipoproteins (apo) are apo AI (65%), apo AII (25%), and smaller amounts of apo C and apo E. The two major subclasses of HDL are HDL<sub>2</sub> and HDL<sub>3</sub>. HDL<sub>1</sub> is a minor subclass and is associated with apo E. HDLs function to redistribute lipids among cells and lipoproteins by a process referred to as *reverse cholesterol transport*, in which HDL acquires cholesterol from cells and transports it either to other cells or to the liver.

The steps in the formation and metabolism of HDL include the following: small nascent or precursor HDL disks composed of apo AI and phospholipid are synthesized in the liver and small intestine; precursor HDL disks accept free cholesterol from cells or from other lipoproteins (triglyceride-rich lipoproteins [TGRL] and chylomicron and very low-density lipoprotein [VLDL] remnants); and HDL free cholesterol is esterified by the apo AI-activated enzyme, lecithin-cholesterol acyltransferase (LCAT). The esterified cholesterol increases its hydrophobicity, and it moves away from the surface of the disk to form a cholesteryl ester-rich core and changes the HDL shape from a disk to a sphere. The spherical, mature HDL<sub>2</sub> particles function to remove excess cholesterol, and as they enlarge, the particle is termed HDL<sub>3</sub>. HDL acquires cholesterol by aqueous transfer from cells (passive desorption) or by transport that is facilitated by cell surface-binding proteins. Several cell surface proteins facilitate the efflux of free cholesterol. For example, ABCA1 binds apo AI and facilitates the transfer of free cholesterol and phospholipids onto HDL. Mutations in the gene that encodes ABCA1 can prevent this transfer process, resulting in a lipid disorder called Tangier disease (see Plate 7-8).

Because of its apo E, HDL<sub>1</sub> is taken up by LDL receptors in the liver. In addition, cholesteryl ester transfer protein (CETP) transfers cholesteryl esters (in exchange for triglycerides) from HDL<sub>2</sub> to TGRL (e.g., VLDL, LDL, and remnants), which are then delivered to the liver. An additional pathway of cholesterol redistribution from HDL is via scavenger receptor B1 (SR-B1) facilitation of selective uptake of cholesteryl esters by the adrenal glands, gonads, and liver. The HDL<sub>2</sub> particles that have been partially depleted of cholesteryl esters and enriched with triglycerides by CETP can be converted back to HDL<sub>3</sub> by the action of hepatic lipase that hydrolyzes the triglycerides.

Reverse cholesterol transport—with a redistribution of cholesterol from cells with excess (e.g., arterial walls) to cells requiring cholesterol or to the liver for excretion—is antiatherogenic. There is an inverse relationship between plasma HDL concentration and cardiovascular risk. In addition to reverse cholesterol



transport, HDL has other antiatherogenic properties. For example, the HDL-associated enzyme paraoxonase serves to inhibit oxidation of LDL. In addition, HDL and apo AI stabilize the erythrocyte cell membrane and prevent transbilayer diffusion of anionic lipids, a step that is required for prothrombin activation and thrombus formation.

Several alterations in the HDL pathway can result in low or high plasma HDL concentrations. For example, mutations in the gene encoding apo AI can decrease

HDL formation because of lack of LCAT activation; resultant plasma concentrations are less than 10 mg/dL (reference ranges: low, less than 40 mg/dL; normal, 40 to 60 mg/dL; desirable, greater than 60 mg/dL). Increased plasma HDL concentrations are found in individuals with CETP deficiency because of the decreased transfer of cholesteryl esters from HDL to apo B-containing lipoproteins. CETP deficiency homozygotes have HDL concentrations greater than 100 mg/dL.

## HYPERCHOLESTEROLEMIA

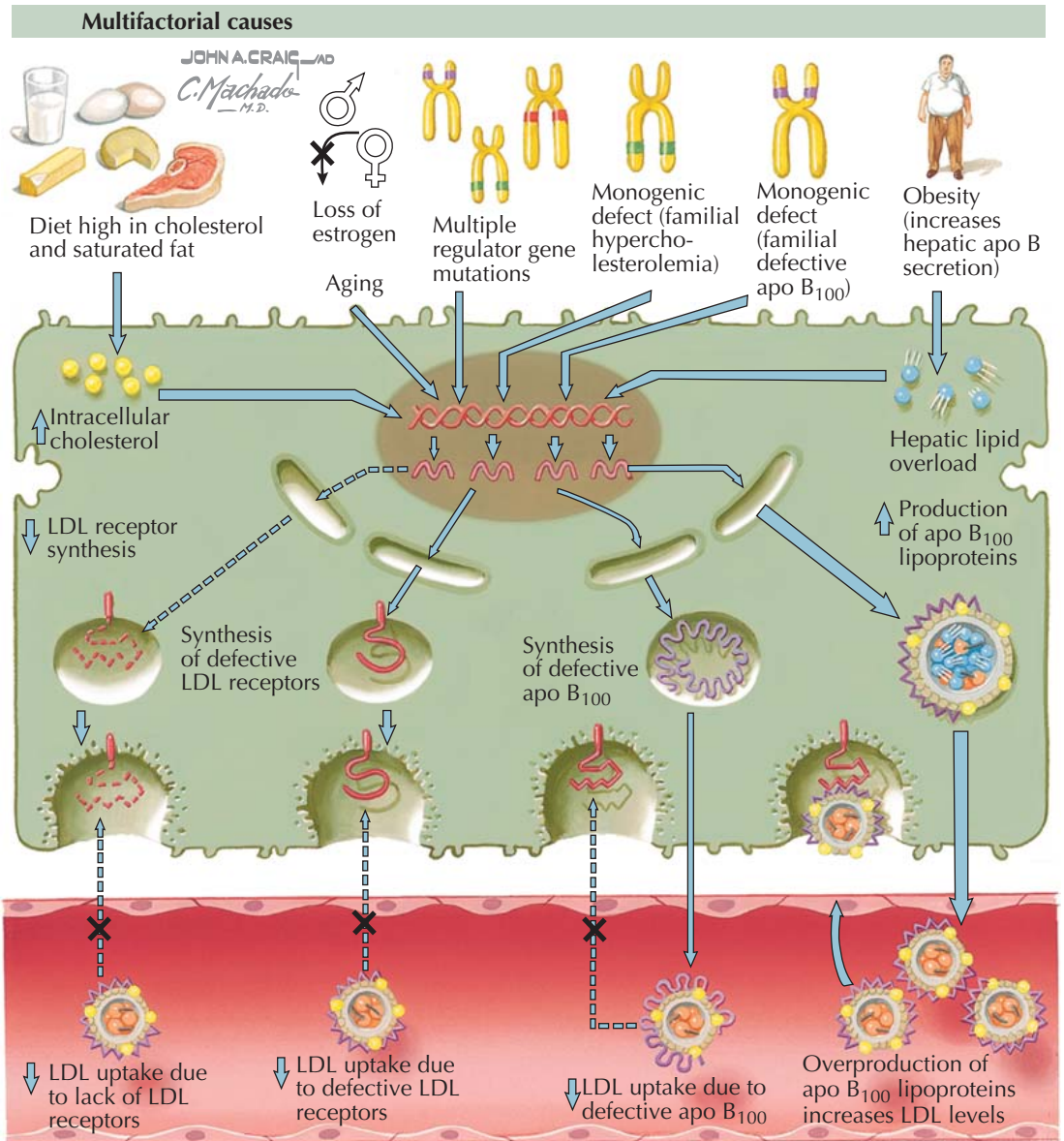
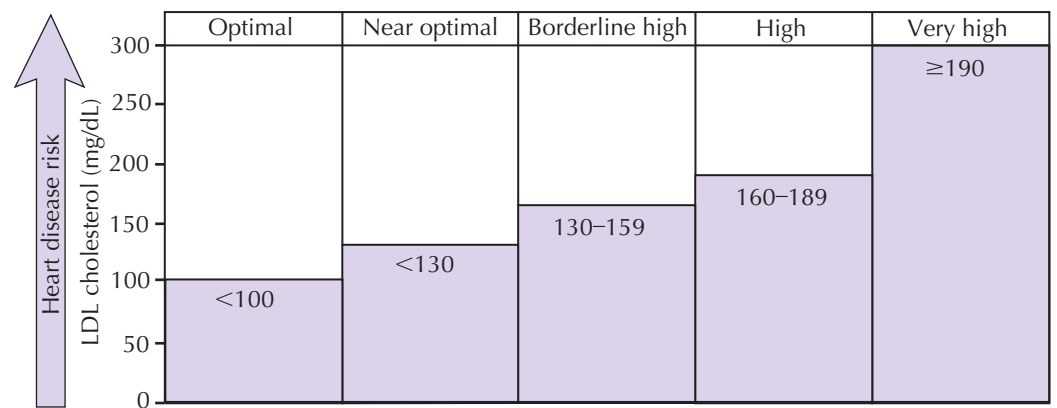
Cholesterol has a chief role in the function of cell membranes and serves as a precursor of steroid hormones. However, when blood concentrations of low-density lipoprotein (LDL) cholesterol exceed certain levels, it is termed *hypercholesterolemia*. Hypercholesterolemia can predispose to atherosclerosis and increase the risk for vascular disease (e.g., coronary heart disease [CHD], cerebrovascular disease, and peripheral vascular disease).

The National Heart Lung and Blood Institute of the National Institutes of Health has published a series of three guidelines (1988, 1993, 2002), each updating the existing recommendations for clinical management of high blood cholesterol. The Third Report of the Expert Panel on Detection, Evaluation, and Treatment of High Blood Cholesterol in Adults is termed the Adult Treatment Panel III (ATP III) and is the most recent version from the National Cholesterol Education Program (NCEP). ATP III set cutoffs for blood LDL cholesterol concentrations on the basis of cardiovascular risk. For example, a plasma LDL concentration less than 100 mg/dL is considered optimal. As plasma LDL levels increase, cardiovascular risk increases. The presence of risk factors (e.g., cigarette smoking, hypertension, low plasma concentration of high-density lipoprotein [HDL] cholesterol, family history of premature CHD, age [men,  $\geq 45$  years; women,  $\geq 55$  years]) should modify the target for LDL cholesterol. For example, the presence of CHD or CHD risk equivalents (e.g., diabetes mellitus) decreases the LDL cholesterol goal to less than 100 mg/dL; if there are two or more risk factors, the LDL cholesterol goal should be less than 130 mg/dL; if there is zero to one risk factor, the LDL cholesterol goal should be less than 160 mg/dL. These targets may be modified when NCEP ATP IV guidelines are published in the fall of 2011.

Many factors contribute to high plasma LDL concentrations. For example, diets high in saturated fats and cholesterol lead to increased blood cholesterol concentrations. Although the level of cholesterol in the blood is controlled at multiple sites, the primary regulator is the LDL receptor pathway. LDL receptors are present on the cell surface of most cells and mediate the uptake of lipoproteins that contain the apolipoproteins (apo) apo B<sub>100</sub> and apo E (e.g., LDL, chylomicron remnants, very low-density lipoproteins [VLDL], VLDL remnants, and HDL<sub>1</sub>).

Familial hypercholesterolemia is a relatively common disorder caused by mutations in the gene that encodes the LDL receptor. Decreased synthesis or synthesis of defective LDL receptors leads to increased plasma concentrations of LDL cholesterol (three- and sixfold increased above the reference range in heterozygotes and homozygotes, respectively) (see Plates 7-6 and 7-7).

Mutations in the gene that encodes apo B<sub>100</sub> are relatively common and lead to defective binding of LDL cholesterol to the LDL receptor. The clinical findings



and the blood lipid profile are similar to those of familial hypercholesterolemia (see Plates 7-6 and 7-7).

Familial hyperapobetalipoproteinemia (with overproduction of apo B<sub>100</sub>) and familial combined hyperlipidemia are both inherited in an autosomal dominant fashion. Although the genetic defects underlying these conditions have yet to be identified (probably multiple genetic defects), they are relatively common disorders and are associated with elevations of plasma LDL cholesterol and triglyceride concentrations and increased

susceptibility to CHD. Other associations include moderate decrease in plasma HDL cholesterol concentrations, fasting hyperglycemia, obesity, and hyperuricemia. Familial combined hyperlipidemia should be suspected in individuals with moderate hypercholesterolemia in combination with moderate hypertriglyceridemia in the setting of a family history of premature CHD. Xanthomas are not seen in individuals with familial hyperapobetalipoproteinemia or with familial combined hyperlipidemia.



## HYPERCHOLESTEROLEMIC XANTHOMATOSIS

Severe hypercholesterolemia can lead to cutaneous and tendinous xanthomas. These cutaneous protuberances represent the accumulation of large (10–20  $\mu\text{m}$  in diameter), cholesterol-filled macrophages. The high concentrations of low-density lipoprotein (LDL) cholesterol in the blood are taken up by the nonsaturable scavenger receptors on macrophages. Xanthelasma of the eyelids is frequently accompanied by premature arcus corneae (i.e., in persons younger than 40 years). Plain and tuberous xanthomas are most frequently found over the elbows, knees, and buttocks, possibly related to continuous irritation by garments. Tuberous xanthomas are seen most frequently in individuals with homozygous mutations in the gene that encodes the LDL receptor (see the following text).

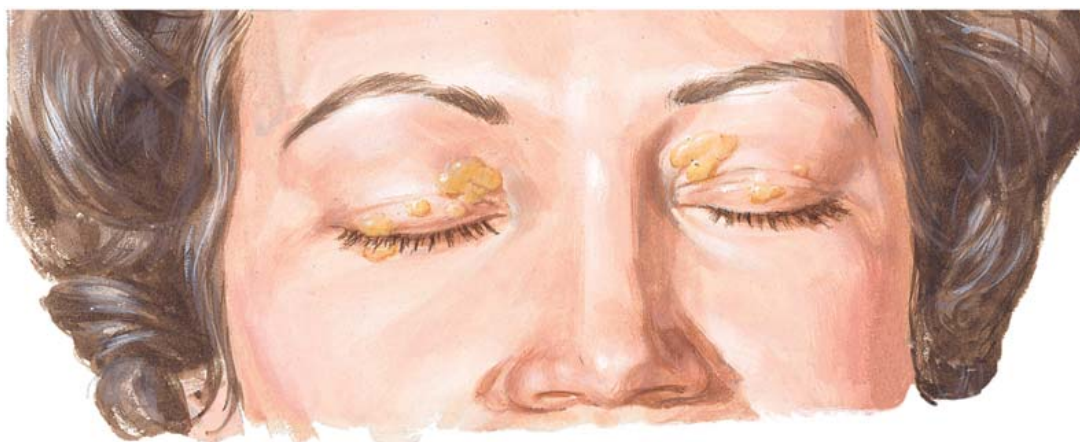The characteristic lesions of tendinous xanthoma are actually part of the tendon, from which they cannot be mechanically separated. The nodules are found in the extensor tendons of the hands, Achilles tendons, and patellar tendons. This type of nodular lesion may be easily confused with the nodules of rheumatoid arthritis, but it can readily be distinguished because a xanthoma is not painful, and patients with rheumatoid arthritis lack the marked increase in blood LDL cholesterol concentrations that are seen in patients with xanthomas.

In the first phase, atherosclerotic lesions consist of cushionlike elevations of lipid-filled macrophages (foam cells) beneath the intima. Later, they become sclerotic (see Plates 7-12 and 7-13). The atheroma of the arterial intima is the most dangerous feature of familial hypercholesterolemic xanthomatosis because of its frequent occurrence in the coronary vessels, which may cause angina and myocardial infarction at an early age.

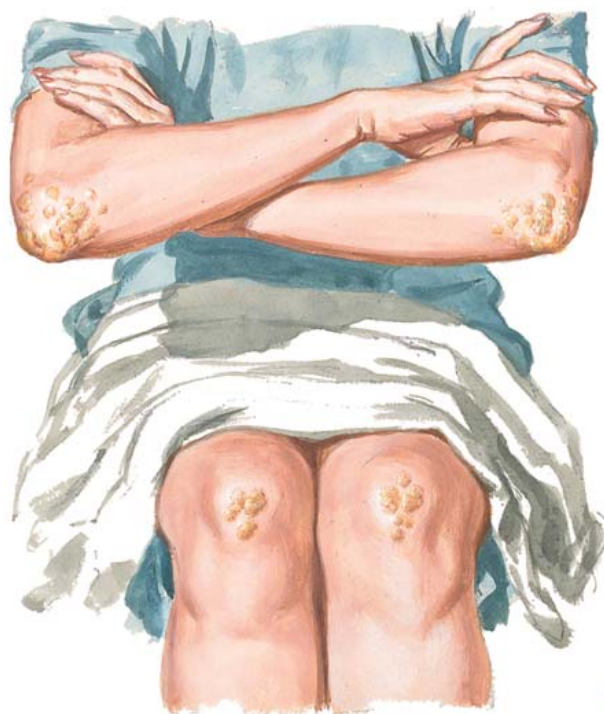
Hypercholesterolemic xanthomatosis is a manifestation of either familial hypercholesterolemia (FH) (an autosomal dominant disorder caused by mutations in the gene that encodes the LDL receptor) or familial defective apolipoprotein apo B<sub>100</sub> (caused by mutations in the gene that encodes apo B<sub>100</sub>).

### FAMILIAL HYPERCHOLESTEROLEMIA—LOW-DENSITY LIPOPROTEIN RECEPTOR MUTATIONS

FH is a monogenic disorder caused by mutations in the gene that encodes the LDL receptor. Thus, LDL cholesterol is not effectively cleared from the circulation, and plasma concentrations of LDL cholesterol are increased. There is increased uptake of LDL cholesterol by the macrophage scavenger receptors, with marked lipid accumulation in the macrophages (foam cells). More than 900 different mutations in the LDL receptor have been identified to cause FH. The types of mutations in the gene that encodes the LDL receptor include mutations that cause the following: decreased LDL receptor synthesis, decreased intracellular transport of the LDL receptor from the endoplasmic reticulum to the Golgi apparatus, defective binding of LDL cholesterol to the LDL receptor, and a defect in the internalization of the LDL receptor after binding LDL cholesterol. Thus, the impact of the LDL receptor mutation on plasma LDL cholesterol concentrations and coronary heart disease (CHD) risk is very dependent on the specific mutation. In addition, individuals with homozygous LDL receptor mutations are much more severely affected than heterozygous individuals.



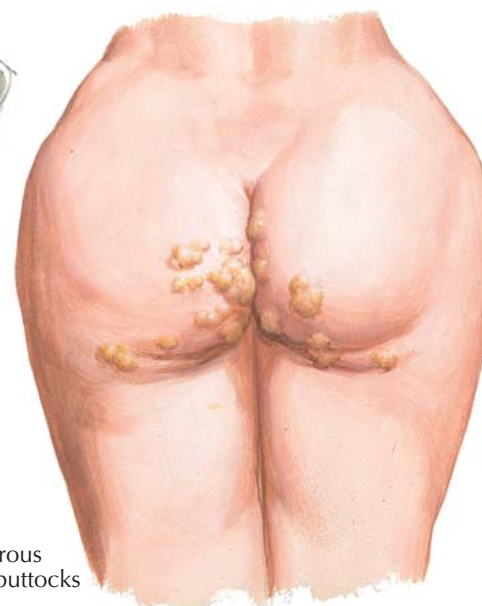Xanthelasma of eyelids



Plain and tuberous xanthomas of elbows and knees



Clear serum



Plain and tuberous xanthomas of buttocks

Heterozygous FH is a relatively common disorder, affecting one in 500 persons, and its manifestations are present from birth. In individuals with heterozygous FH, the plasma total cholesterol concentrations are typically more than 300 mg/dL, and the LDL cholesterol concentrations are more than 250 mg/dL. Plasma triglycerides are not elevated in this condition. Approximately 75% of patients with heterozygous FH have xanthelasma and tendon xanthomas. Also, premature CHD and heart valvular disease occurring before age

45 years are common. Heterozygous FH should be suspected in individuals with high plasma concentrations of LDL cholesterol, normal plasma triglyceride concentrations, tendon xanthomas, and a family history of premature CHD. The diagnosis of heterozygous FH is made on clinical grounds. Because of the large number of potential mutations, germline mutation testing for abnormalities in the gene that encodes the LDL receptor is not routinely done.



## HYPERCHOLESTEROLEMIC XANTHOMATOSIS (Continued)

Fortunately, homozygous FH is rare. These individuals come to clinical attention either because of a family history of premature CHD or the appearance of xanthomas at a young age (i.e., younger than 10 years). Typical plasma total cholesterol concentrations range from 600 to 1000 mg/dL; plasma LDL cholesterol concentrations range from 550 to 950 mg/dL. Tuberos xanthomas usually develop before age 6 years and are unique to homozygous FH; these individuals also develop the xanthelasma and tendon xanthomas that are common in individuals who are heterozygous for mutations in the LDL receptor gene. Symptomatic CHD can occur before age 10 years, and fatal myocardial infarction usually occurs before age 20 years if the hypercholesterolemia is not treated. Aortic valvular disease (e.g., aortic stenosis) is more common (occurring in ~50% of affected individuals) and is more severe in homozygous FH than in heterozygous FH. The diagnosis of homozygous FH should be suspected when the plasma LDL cholesterol concentration is more than 500 mg/dL.

Treatment of individuals with heterozygous FH includes a low-cholesterol diet and pharmacologic therapy with a 3-hydroxy-3-methylglutaryl coenzyme A (HMG-CoA) reductase inhibitor. Some patients may require the addition of a bile acid sequestrant or an intestinal cholesterol absorption inhibitor.

Treatment of individuals with homozygous FH is problematic. Because of very little residual LDL cholesterol binding, pharmacologic therapy with HMG-CoA reductase inhibitors, bile acid sequestrants, and intestinal cholesterol absorption inhibitors is suboptimally effective. The most effective therapy involves the periodic (i.e., every 1–3 weeks) selective removal of LDL cholesterol by extracorporeal apheresis.

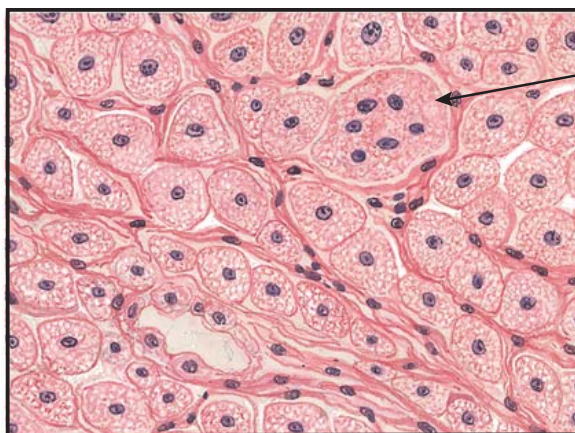
## FAMILIAL DEFECTIVE APOLIPOPROTEIN B<sub>100</sub>

Familial defective apo B<sub>100</sub> is relatively common disorder affecting in one in 500 persons that is caused by a mutation in the gene encoding apo B<sub>100</sub>. To date, most affected patients have the same single point mutation at nucleotide number 3500. Apo B<sub>100</sub> is the ligand that binds LDL cholesterol to the LDL receptor; thus, biochemical and clinical phenotypes are very similar to those in individuals with LDL receptor mutations. These individuals have isolated elevations in plasma LDL cholesterol concentrations, xanthelasma, tendon xanthomas, and premature CHD. In general, the clinical presentations of heterozygous and homozygous familial defective apo B<sub>100</sub> are less severe than those of the heterozygous and homozygous forms of FH, respectively. Clinically, familial defective apo B<sub>100</sub> cannot be distinguished from FH; germline mutation testing is the only method currently available to make this distinction.

Treatment of familial defective apo B<sub>100</sub> is similar to that of heterozygous FH, with emphasis on a low-cholesterol diet and pharmacologic therapy with HMG-CoA reductase inhibitors, bile acid sequestrants, and intestinal cholesterol absorption inhibitors.

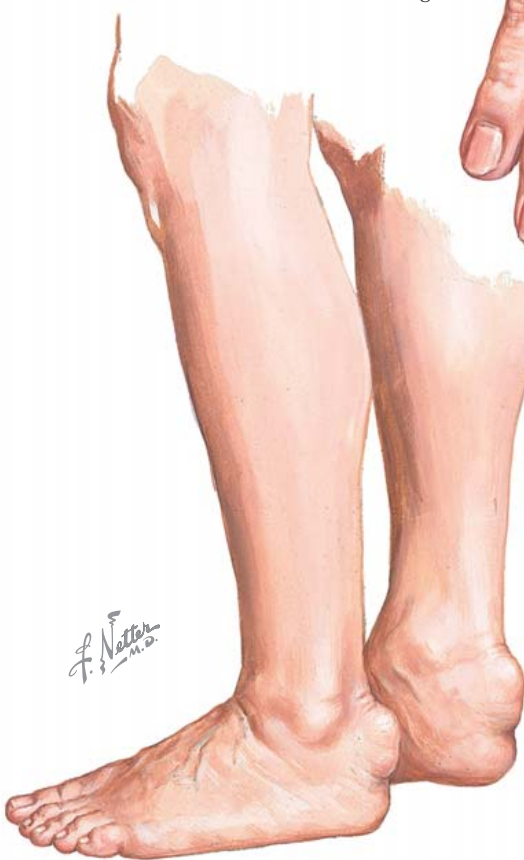## SITOSTEROLEMIA AND CEREBROTENDINOUS XANTHOMATOSIS

Tendon xanthomas and premature CHD can also occur independently of an abnormality in LDL cholesterol

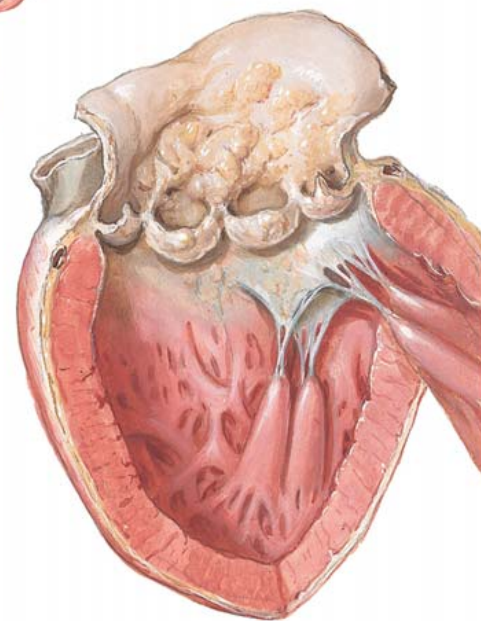


Tuberos xanthoma (high magnification): xanthoma cells and multinucleated giant cell (Touton cell) with fibrous tissue

Xanthomas in extensor tendons of fingers



Large xanthomas of both Achilles tendons



Xanthomatous infiltration of aortic valve and aortic intima around coronary orifice

metabolism. Sitosterolemia is an autosomal recessive disorder resulting from mutations in the genes encoding the adenosine triphosphate-binding cassettes G5 and G8 that normally limit plant sterol absorption. There is a resultant increase in gastrointestinal absorption of cholesterol and plant sterols. The plant sterols and LDL cholesterol accumulate in the plasma and peripheral tissues, leading to premature CHD and tendon xanthomas. Plasma levels of LDL cholesterol are high. Gas-liquid chromatography shows high levels of plant sterols.

Cerebrotendinous xanthomatosis (CTX) is an autosomal recessive lipid storage disease and a form of

leukodystrophy. CTX is caused by a block in bile acid synthesis because of absent 27-hydroxylase (caused by mutations in *CYP27A1*), resulting in an accumulation of cholesterol and cholestanol in all tissues. The plasma lipid levels in individuals with CTX are normal. Xanthomas develop in the central nervous system, tendons, skin, bones, and lungs. Because of the associated defects in synthesis and maintenance of the myelin sheath of nerves, CTX has dominant effects on the central nervous system with resultant cerebellar ataxia and pyramidal tract signs.



## ABETALIPOPROTEINEMIA AND TANGIER DISEASE

Two familial syndromes are characterized by severe deficiency or absence of specific lipoproteins: abetalipoproteinemia and Tangier disease.

### ABETALIPOPROTEINEMIA

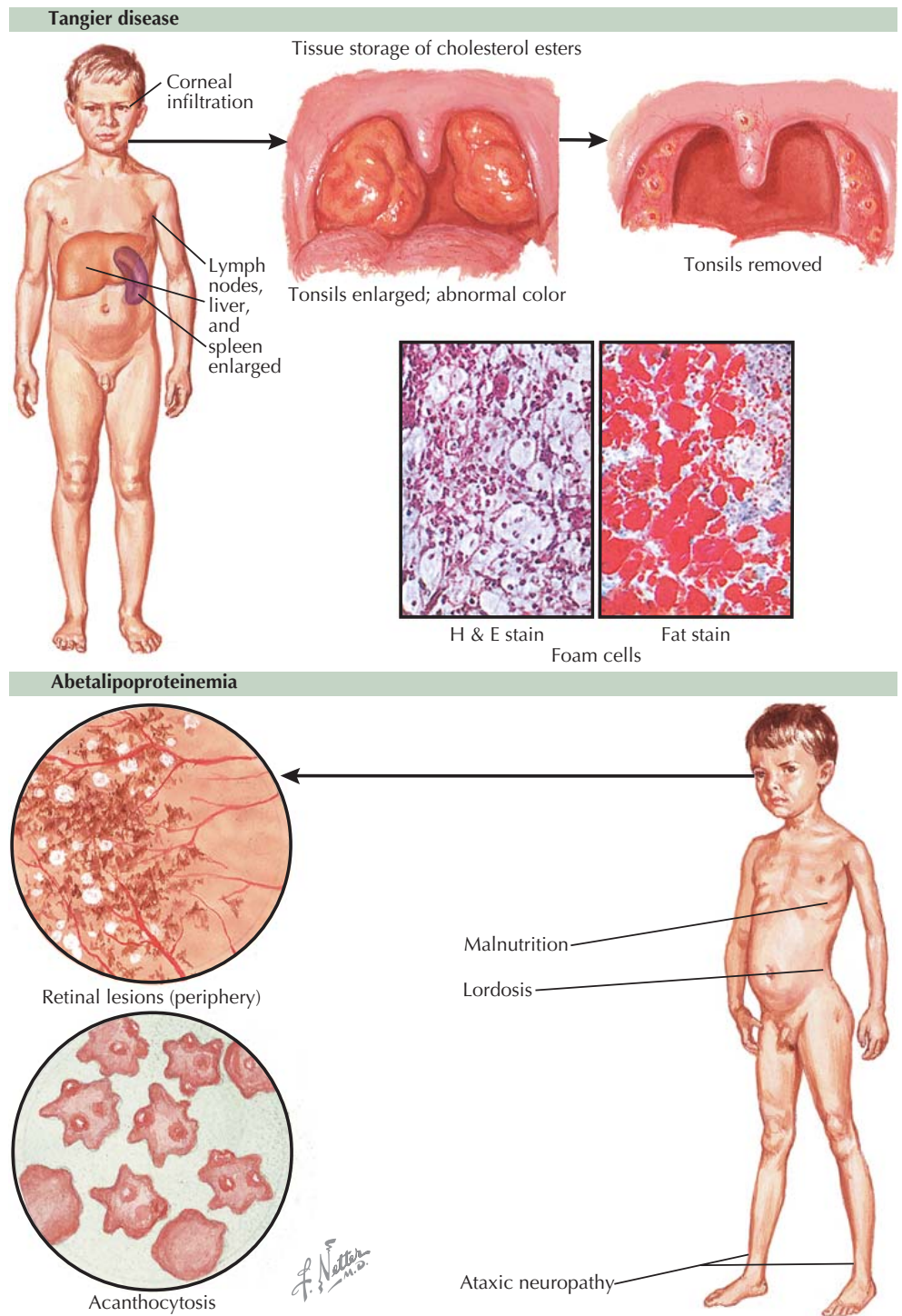
Abetalipoproteinemia (OMIM 200100) is a rare autosomal recessive disorder that usually presents in infancy with fat malabsorption, hypocholesterolemia, and acanthocytosis. Later in life, deficiencies in fat-soluble vitamins result in atypical retinitis pigmentosa, posterior column neuropathy, and myopathy. Abetalipoproteinemia is caused by mutations in the gene encoding the large subunit of microsomal triglyceride transfer protein, resulting in abnormal production and secretion of apolipoprotein B (apo B) and apo B-containing lipoproteins. Microsomal triglyceride transfer protein is key in the transfer of triglycerides and phospholipids into the lumen of the endoplasmic reticulum of the enterocyte for the assembly of very low-density lipoprotein (VLDL), a step required for normal hepatic secretion of apo B<sub>100</sub>. Insufficient lipidation of these nascent particles prevents synthesis and secretion of chylomicrons and VLDL by the intestine and liver. This defect results in gastrointestinal fat malabsorption and extremely low plasma concentrations of cholesterol and VLDL triglycerides and absent betalipoprotein.

The absence of apo B results in steatorrhea, symptoms associated with deficiency of fat-soluble vitamins (vitamins A, D, E, and K), neurologic manifestations (e.g., retinitis pigmentosa, peripheral neuropathy, ataxia, lordosis caused by muscular weakness, sensory motor neuropathy, mental retardation), and acanthocytosis (crenated appearance of erythrocytes). In individuals who are homozygous for mutations in the disease-causing gene, there may be deficient adrenocortical glucocorticoid production. The neurologic manifestations may dominate the clinical presentation with early onset (e.g., age 1–2 years) of generalized weakness, distal muscular atrophy, loss of proprioception, posterior column degeneration with sensory neuropathy, and cerebellar atrophy with ataxia and nystagmus. Children with abetalipoproteinemia appear malnourished and have growth retardation. Some patients may have hepatic steatosis and cirrhosis, which can result from treatment with medium-chain triglycerides. In one patient who underwent liver transplantation for hepatic cirrhosis, the serum lipoprotein profile normalized but gastrointestinal fat malabsorption persisted.

Laboratory studies show the absence of plasma apo B-containing proteins and extremely low levels of total cholesterol (<50 mg/dL). Early diagnosis and treatment are key to avoid growth retardation and neuroretinal complications. Treatment includes a lipid-poor diet (e.g., 5 g/d in children) to treat digestive intolerance and allow normal absorption of carbohydrates and proteins, provision of dietary essential fatty acids in the form of vegetable oils, and high doses of fat-soluble vitamins (vitamins A, D, E, and K).

### TANGIER DISEASE

Tangier disease (OMIM 205400) is an autosomal dominant disorder that results in low serum concentrations of high-density lipoprotein (HDL) cholesterol. Tangier disease was originally described and named on the basis



of a kindred living on Tangier Island in Chesapeake Bay. Tangier disease is caused by mutations in the adenosine triphosphate-binding cassette transporter-1 gene (*ABCA1*), which encodes the cholesterol efflux regulatory protein. *ABCA1* is critical for intracellular cholesterol transport, the impairment of which results in decreased cholesterol efflux onto nascent HDL particles, leading to lipid-depleted particles that are then rapidly catabolized. Thus, the inability of newly synthesized apolipoproteins to acquire cellular lipids by the *ABCA1* pathway leads to their rapid degradation and an overaccumulation of cholesterol in macrophages. *ABCA1* has a critical role in modulating flux of tissue cholesterol and phospholipids into the reverse cholesterol transport pathway. The impaired HDL-mediated

cholesterol efflux from macrophages leads to massive accumulation of cholesteryl esters (foam cells) throughout the body and resultant hepatosplenomegaly. These individuals frequently develop premature coronary disease. Individuals with homozygous mutations in *ABCA1* have absent plasma HDL, and heterozygotes have HDL concentrations about 50% of those in individuals with two normal alleles.

Findings on physical examination include orange tonsils (caused by cholesterol deposits), corneal opacities, hepatosplenomegaly, and peripheral neuropathy. Findings from laboratory studies show absent HDL cholesterol and low total cholesterol concentrations. Currently, there is no disease-specific treatment for Tangier disease.

## HYPERTRIGLYCERIDEMIA

Based on coronary risk, serum triglyceride concentrations can be stratified as follows: normal, less than 150 mg/dL; borderline high, 150 to 199 mg/dL; high, 200 to 499 mg/dL; and very high, 500 mg/dL or greater. Serum triglyceride concentrations greater than 199 mg/dL are termed hypertriglyceridemia and are associated with an increased risk of cardiovascular disease. Hypertriglyceridemia can be caused by or exacerbated by obesity, poorly controlled diabetes mellitus, nephrotic syndrome, hypothyroidism, and orally administered estrogen therapy.

Hypertriglyceridemia results from the accumulation of triglyceride-rich lipoproteins (e.g., very low-density lipoproteins [VLDL], VLDL remnants, and chylomicrons) in blood. Hypertriglyceridemia is associated with variable degrees of hypercholesterolemia because the triglyceride-rich lipoproteins also transport cholesterol. Triglycerides in chylomicrons and VLDL are hydrolyzed by lipoprotein lipase (LPL), and the free fatty acid molecules are used as an energy source. LPL also facilitates the transfer of cholesterol to high-density lipoprotein (HDL) cholesterol. Thus, when LPL activity is deficient, hypertriglyceridemia and low blood HDL cholesterol concentrations occur.

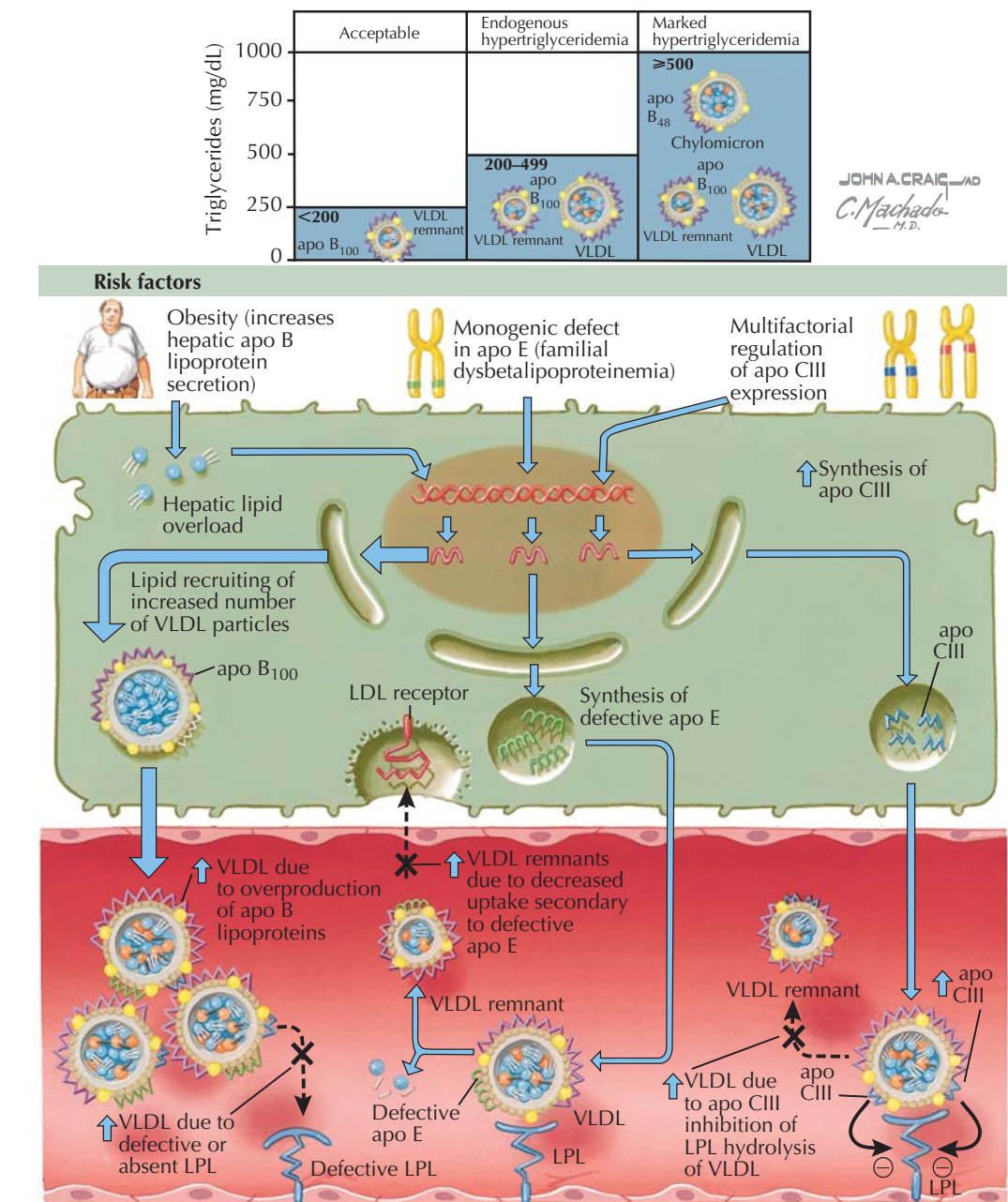
Disorders in lipid metabolism can be categorized by the Fredrickson hyperlipoproteinemia phenotype classification, which is based on the pattern of lipoproteins on electrophoresis or ultracentrifugation:

- Phenotype I (LPL deficiency): increased serum chylomicron concentration and markedly increased serum triglyceride concentration. The serum has a creamy top layer.
- Phenotype IIa (familial hypercholesterolemia): increased serum LDL cholesterol and total cholesterol concentrations. The serum is clear.
- Phenotype IIb: increased serum concentrations of LDL and VLDL cholesterol. The serum is clear.
- Phenotype III (familial dysbetalipoproteinemia): increased serum concentrations of VLDL remnants and chylomicrons. The serum is turbid.
- Phenotype IV (familial hypertriglyceridemia): increased serum concentrations of VLDL. The serum is turbid.
- Phenotype V (mixed hypertriglyceridemia): increased serum concentrations of chylomicrons and VLDL. The serum has a creamy top layer and a turbid bottom layer.

The type I hyperlipoproteinemia phenotype is caused by rare recessive disorders and is associated with complete absence of either LPL activity or apolipoprotein (apo) CII (the ligand for LPL on chylomicrons and VLDL). Severe hypertriglyceridemia results because the clearance of triglyceride-rich lipoproteins from plasma is blocked. Chylomicronemia syndrome is a frequent finding in patients with type I hyperlipoproteinemia (see Plates 7-10 and 7-11).

Type IIa hyperlipoproteinemia is familial hypercholesterolemia and is associated with LDL receptor deficiency, resulting in markedly increased serum concentrations of LDL (see Plates 7-6 and 7-7). Type IIb hyperlipoproteinemia is combined hyperlipidemia caused by decreased LDL receptor availability or function and increased apo B, resulting in increased blood levels of LDL cholesterol and VLDL (see Plate 7-5).

Familial dysbetalipoproteinemia, also termed type III hyperlipoproteinemia, is associated with specific isoforms of the *APOE* gene; however, other genetic and



environmental factors probably contribute to disease development and severity. Apo E is required for receptor-mediated clearance of chylomicron and VLDL remnants. The most common *APOE* genotype is *APOE\*E3/APOE\*E3*. The E2 isoform has lower affinity for the LDL receptor than the E3 isoform, which leads to poor clearance of VLDL and chylomicron remnants that contain the E2 isoform. Familial dysbetalipoproteinemia occurs when individuals are homozygous for the E2 allele. This defect leads to premature coronary heart disease and peripheral vascular disease. Tuberoeruptive xanthomas may be evident on physical examination (see Plates 7-6 and 7-7).

Familial hypertriglyceridemia (type IV hyperlipoproteinemia phenotype) is an autosomal dominant disorder caused by inactivating mutations in the gene encoding LPL and is associated with moderately increased serum triglyceride concentrations (200–500 mg/dL), normal serum LDL cholesterol concentrations, and low serum HDL cholesterol concentrations. The degree of hypertriglyceridemia can be aggravated by exogenous

agents (e.g., orally administered estrogen replacement therapy). Familial hypertriglyceridemia is usually associated with obesity, insulin resistance, hyperglycemia, and hypertension.

Mixed hypertriglyceridemia (type V hyperlipoproteinemia phenotype) is characterized by triglyceride levels above the 99th percentile of normal. The plasma supernatant is creamy, and there are increased concentrations of chylomicrons and VLDL. The clinical manifestations include hepatosplenomegaly and eruptive xanthomas.

Familial combined hyperlipidemia is a genetically heterogeneous disorder caused by overproduction of hepatically derived apolipoprotein B<sub>100</sub> associated with VLDL. Affected patients typically present with hypercholesterolemia and hypertriglyceridemia.

The C apolipoproteins also regulate triglyceride metabolism. Apo CI and apo CIII modulate the uptake of triglyceride-rich lipoproteins (chylomicron remnants, VLDL) by interfering with the ability of apo E to mediate binding to lipoprotein receptor pathways.



## CLINICAL MANIFESTATIONS OF HYPERTRIGLYCERIDEMIA

Hypertriglyceridemia is usually asymptomatic. However, serum triglyceride concentrations higher than 1000 mg/dL may result in chylomicronemia syndrome. Signs and symptoms associated with chylomicronemia syndrome include abdominal pain, pancreatitis, eruptive xanthoma, flushing with alcohol intake, memory loss, and lipemia retinalis. The acute pancreatitis can be life threatening, and the patients most commonly affected are those with poorly controlled diabetes mellitus or alcoholism. Serum triglyceride values higher than 1000 mg/dL result in opalescent serum caused by an increase in very low-density lipoprotein (VLDL). At markedly increased levels, the serum may be milky because of hyperchylomicronemia.

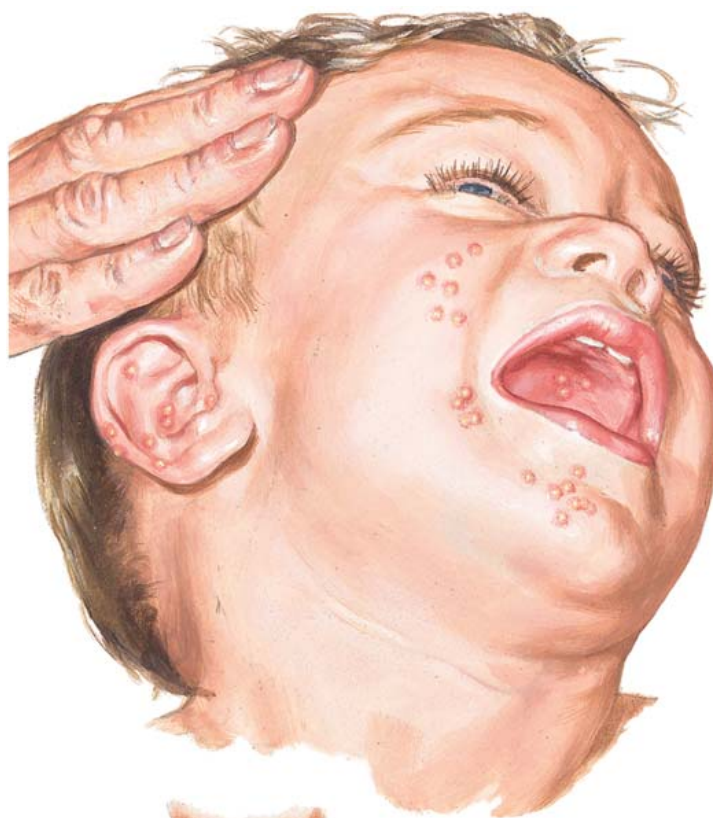Triglycerides in chylomicrons and VLDL are hydrolyzed by lipoprotein lipase (LPL), and the free fatty acid molecules are used as an energy source in muscle for triglyceride synthesis or for storage in adipocytes or formation of hepatic VLDL. LPL is synthesized by adipocytes, myocytes, and macrophages. LPL attaches to heparan sulfate proteoglycans on the surface of capillary endothelial cells, where it interacts with circulating chylomicrons and VLDL. Apolipoprotein (apo) CII is a cofactor for LPL. Mutations that inactivate LPL or apo CII result in severe hypertriglyceridemia (see following text).

Hepatic lipase is synthesized by hepatocytes and is found in capillary endothelial cells of the liver, adrenals, and gonads. Hepatic lipase—activated by androgens and suppressed by estrogens—functions to release lipids from lipoproteins by hydrolyzing triglycerides in the processing of chylomicron remnants and also to convert high-density lipoprotein (HDL) cholesterol from HDL<sub>2</sub> to HDL<sub>3</sub> by removing phospholipid and triglyceride from HDL<sub>2</sub>. Thus, when the hepatic lipase activity is high, serum concentrations of total HDL cholesterol levels are low. Unlike LPL, apo CII is not a cofactor for hepatic lipase. Defects or deficiencies in hepatic lipase result in an accumulation of remnant lipoproteins and HDL<sub>2</sub>.

### LIPOPROTEIN LIPASE DEFICIENCY

Mutations in the gene encoding LPL can result in deficient LPL activity, a rare autosomal recessive disorder that manifests with severe hypertriglyceridemia because the clearance of triglyceride-rich lipoproteins from the plasma is blocked. Individuals heterozygous for a mutation in the *LPL* gene (approximate frequency of one in 500) may have LPL activity that is 50% of normal, leading to mild hypertriglyceridemia.

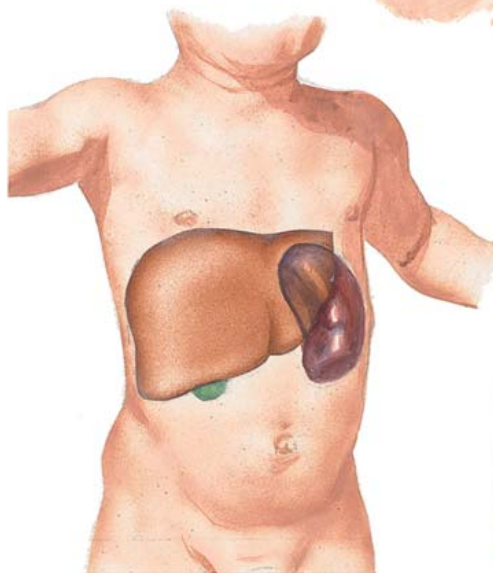
Normally, chylomicrons are cleared from plasma within 8 hours of eating. In persons with complete LPL deficiency, the chylomicrons can take days to be cleared after a single meal. Chylomicronemia syndrome results when there are massive accumulations of these lipoproteins in the blood. LPL deficiency is usually diagnosed in infancy or childhood when individuals present with chylomicronemia syndrome. Manifestations of chylomicronemia syndrome include recurrent abdominal pain, pancreatitis, hepatosplenomegaly caused by the accumulation of triglycerides in reticuloendothelial cells, eruptive xanthomas, lipemia retinalis, lipemic plasma, neurologic manifestations, dyspnea, and severe hypertriglyceridemia (>2000 mg/dL). The pancreatitis resulting from chemical irritation by fatty acids and



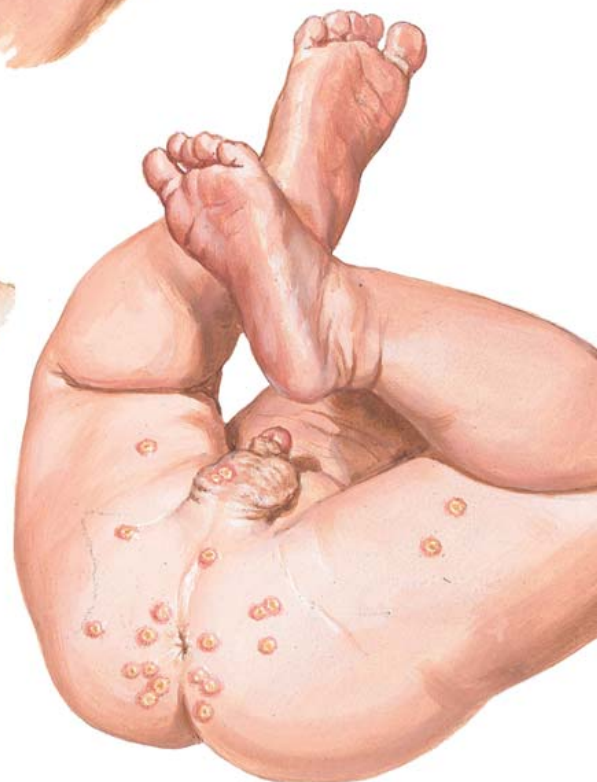
LPL or apo CII deficiency:  
eruptive xanthomas of cheek,  
chin, ear, and palate



Creamy serum



Hepatosplenomegaly



Umbilicated eruptive xanthomas of  
buttocks, thighs, and scrotum

lysocleithin can be life threatening. Chylomicrons are usually present whenever the triglyceride concentration is higher than 1000 mg/dL in a fasting blood sample. The serum appears creamy. Because of the effect on blood volume, severe hypertriglyceridemia can lead to measurement errors in serum electrolytes. For example, if serum is not cleared of triglyceride-rich lipoproteins by centrifugation, serum sodium may appear low (pseudohyponatremia).

LPL deficiency should be suspected in infants and children with recurrent abdominal pain and pancreatitis. Eruptive xanthomas are usually present in this setting, especially when serum triglyceride concentrations are higher than 2000 mg/dL. LPL deficiency can be confirmed with the heparin infusion test. Heparin displaces LPL from heparan sulfate proteoglycans on the surface of capillary endothelial cells, and LPL activity can be assayed in plasma.

*F. Netter M.D.*



## CLINICAL MANIFESTATIONS OF HYPERTRIGLYCERIDEMIA

(Continued)

When patients with LPL deficiency present with pancreatitis, the initial treatment should include a fat-free diet. Long term, patients with LPL deficiency should be treated with a fat-restricted diet, with fat accounting for less than 10% of total calories. The therapeutic goal is to maintain serum triglyceride concentrations at less than 1000 mg/dL. Pharmacologic options are limited for patients with LPL deficiency (see following text).

### APOLIPOPROTEIN CII DEFICIENCY

Apo CII deficiency is another rare autosomal recessive disorder that can cause the chylomicronemia syndrome. The clinical presentation is identical to that of LPL deficiency. The lack of apo CII, an activating cofactor for LPL, results in a functional LDL deficiency. Apo CII deficiency can be confirmed by the absence of apo CII on electrophoresis of plasma apolipoproteins. The treatment of apo CII deficiency is identical to that of LPL deficiency.

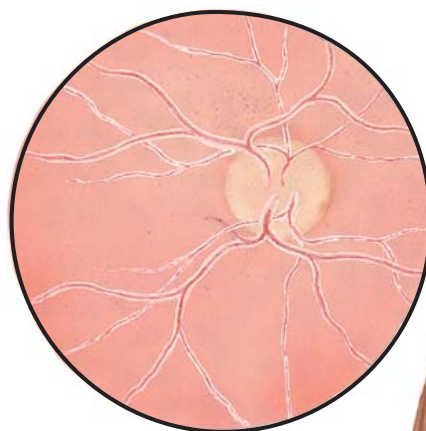
### FAMILIAL HYPERTRIGLYCERIDEMIA

Individuals with familial hypertriglyceridemia overproduce VLDL triglycerides, resulting in serum triglyceride concentrations in the range of 200 to 500 mg/dL and normal LDL cholesterol concentrations. The hypertriglyceridemia typically occurs in concert with low serum HDL cholesterol levels and obesity. Because of the relative mild degree of hypertriglyceridemia and the lack of associated symptomatology, most affected patients are not diagnosed until adulthood. The degree of hypertriglyceridemia is usually less than 1000 mg/dL unless aggravated by alcohol use, orally administered estrogen, or hypothyroidism. Treatment of individuals with familial hypertriglyceridemia includes avoidance of alcohol and orally administered estrogens, as well as implementation of some of the nonpharmacologic and pharmacologic approaches outlined in the following text.

### TREATMENT

Hypertriglyceridemia promotes atherosclerosis, and treatment should be considered when serum triglyceride concentrations are higher than 200 mg/dL. Nonpharmacologic treatment options include weight loss in obese patients, a regular isotonic exercise program, improved glycemic control in patients with diabetes mellitus, limitation of alcohol intake, and avoidance of free carbohydrates in the diet. Pharmacologic therapy is indicated when hypertriglyceridemia persists despite nonpharmacologic interventions.

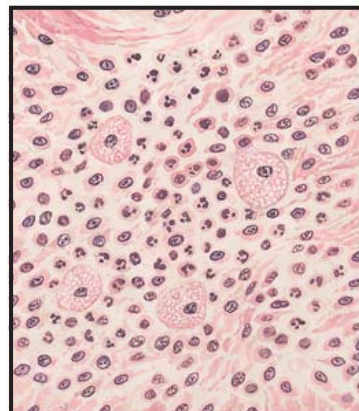
When serum LDL cholesterol concentrations are elevated in concert with serum triglycerides, a 3-hydroxy-3-methylglutaryl coenzyme A (HMG-CoA) reductase inhibitor may lower the blood triglyceride concentration, as well as the LDL cholesterol concentration. When the main lipid profile anomaly is hypertriglyceridemia, it can be treated with a fibric acid



Hyperlipemia retinalis

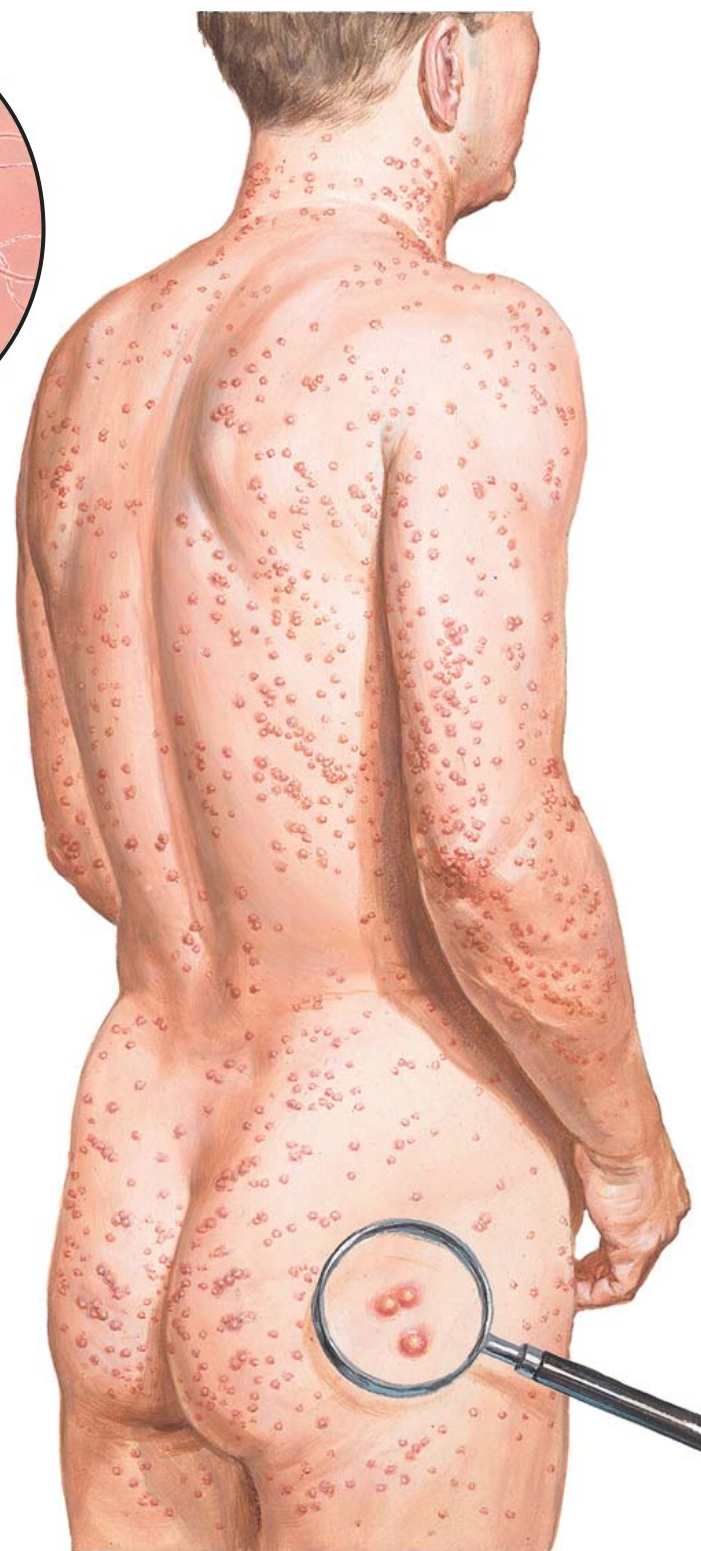#### Chylomicronemia syndrome:

- ▶ Recurrent abdominal pain
- ▶ Pancreatitis
- ▶ Hepatosplenomegaly
- ▶ Eruptive xanthomas
- ▶ Lipemia retinalis
- ▶ Lipemic plasma
- ▶ Severe hypertriglyceridemia (e.g., >2000 mg/dL)



Hyperlipemic xanthomatous nodule (high magnification): few foam cells amid inflammatory exudate

*F. Netter M.D.*



Eruptive xanthomatosis

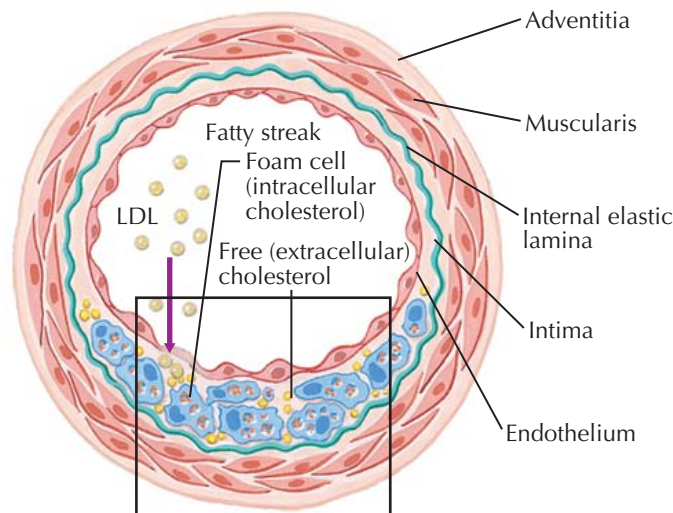
derivative (i.e., fenofibrate or gemfibrozil), nicotinic acid, or omega-3 fatty acids (e.g., fish oil at doses >3 g/d). Fish oil decreases VLDL production and can lower serum triglyceride concentrations by as much as 50%. Nicotinic acid may cause hyperglycemia and should be avoided in patients with hyperglycemia or impaired glucose tolerance. Gemfibrozil may increase the risk for HMG-CoA reductase inhibitor-related myositis and should be avoided in these patients. Orlistat may be helpful in patients with type V

hyperlipoproteinemia and very high serum triglyceride levels that are refractory to the aforementioned therapies because it inhibits gastrointestinal fat absorption and decreases intestinal chylomicron synthesis.

When the serum triglyceride concentration is very high ( $\geq 500$  mg/dL), the first goal is to avoid pancreatitis. Prompt institution of pharmacologic therapy with nicotinic acid or a fibrate is indicated. For example, gemfibrozil can lower serum triglyceride concentrations in this setting by as much as 70%.



## ATHEROGENESIS: FATTY STREAK FORMATION

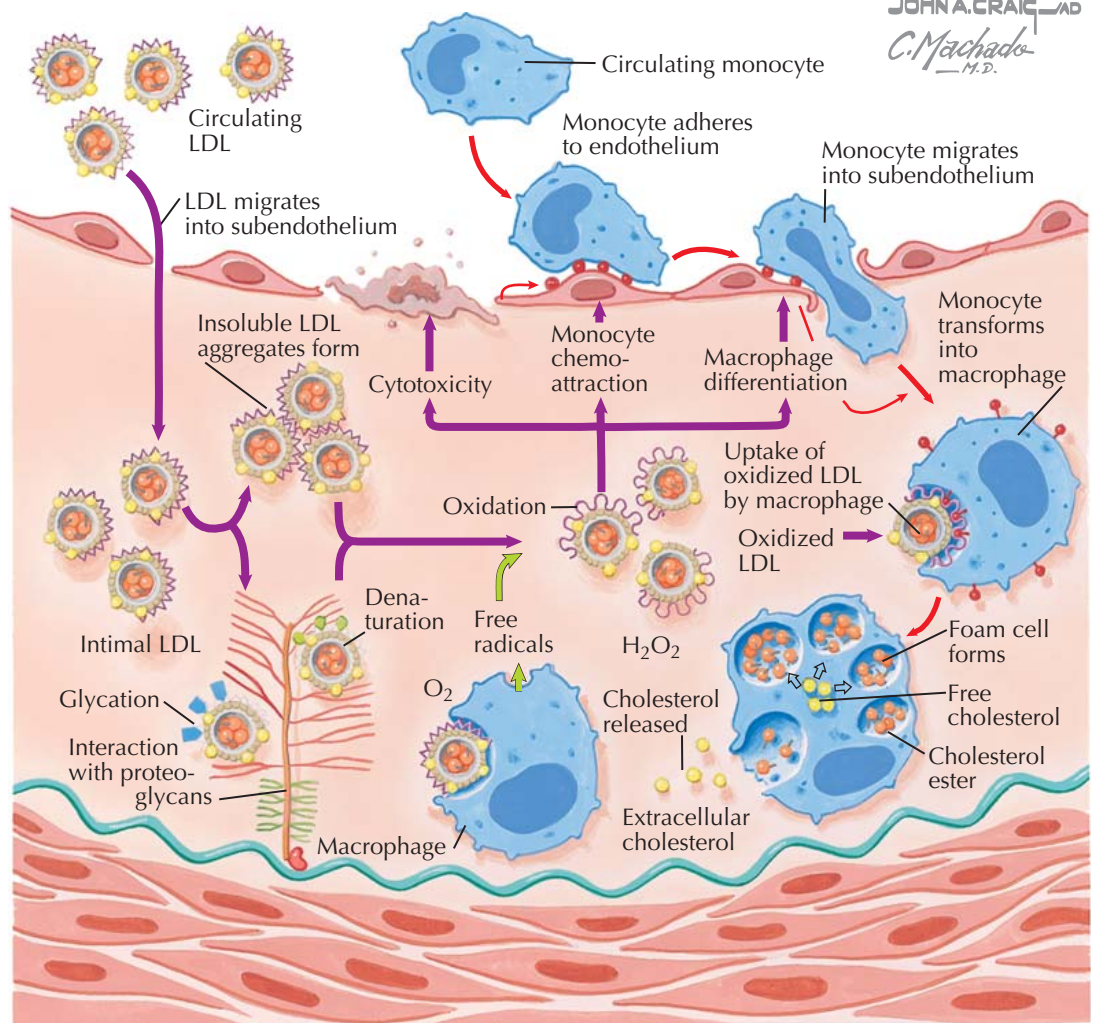


Extracellular cholesterol and cholesterol-filled macrophages (foam cells) accumulate in subendothelial space. Subsequent structural modifications of LDL particles render them more atherogenic. Oxidation of subendothelial LDL attracts monocytes, which enter subendothelium and change into macrophages. Macrophages may take up oxidized LDL to form foam cells.

## ATHEROSCLEROSIS

Atherogenesis starts in the arterial wall and eventually may lead to vascular disease (coronary heart disease [CHD], peripheral vascular disease, or cerebrovascular disease). Occlusive arterial disease resulting from atherosclerosis is a leading cause of disability and death. Atherosclerosis, a result of a chronic inflammatory response to vascular injury, is the buildup of plaque in the walls of arteries that is composed of lipoproteins, inflammatory cells, extracellular matrix, vascular smooth muscle cells, and calcium. The sites of atherosclerosis are typically those parts of the arterial vascular tree associated with increased turbulent blood flow (bifurcations and curvatures). Typical locations for symptomatic atherosclerotic lesions are the proximal left anterior descending coronary artery, proximal renal arteries, and carotid bifurcations. These sites have an upregulation of proinflammatory adhesion molecules for inflammatory cells (e.g., monocytes and T cells). Risk factors for endothelial dysfunction and injury include increased serum concentrations of low-density lipoprotein (LDL) cholesterol, decreased serum concentrations of high-density lipoprotein (HDL) cholesterol, increased oxidant stress (e.g., cigarette smoking, hypertension, diabetes mellitus), and aging. The serum concentration of LDL cholesterol is a strong predictor of CHD and atherosclerosis; more than 70% of individuals with premature CHD have hyperlipidemia. Total serum cholesterol concentrations less than 160 mg/dL markedly decrease CHD risk.

Atherogenesis is a slow process that occurs over years. The clinical manifestations of atherosclerosis may be chronic (e.g., stable angina pectoris or intermittent claudication) or acute (e.g., myocardial infarction, stroke). However, most atheromata produce no symptoms. The normal arterial wall is composed of the endothelial cell layer, intima and subendothelial space, internal elastic lamina, media (muscularis layer formed by smooth muscle cells), and adventitia (loose connective tissue). The initial events in atherosclerosis involve movement of electronegative LDL cholesterol and other apolipoprotein (apo) B<sub>100</sub>-containing lipoproteins (e.g., very low-density lipoprotein, lipoprotein[a]) from the blood into the subendothelial space where they are retained because of a charge-mediated interaction with the positively charged proteoglycans. Small LDL particles penetrate the endothelial barrier more effectively than large LDL particles. LDL cholesterol in the subendothelial space becomes oxidized. The presence of oxidized LDL promotes synthesis of monocyte



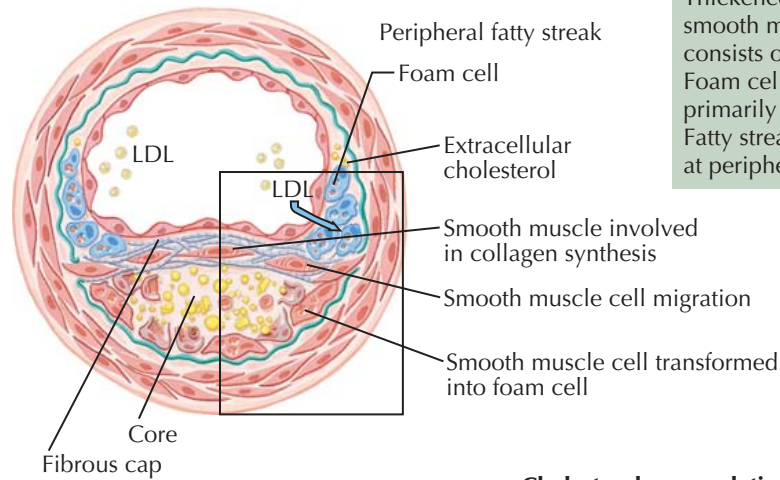
chemoattractant protein 1 and other chemoattractants by endothelial and smooth muscle cells. Circulating monocytes then attach to the surface of endothelial cells and subsequently migrate between these cells to enter the subendothelial space, where they differentiate into macrophages. The activated macrophage releases mitogens and chemoattractants, which recruit more macrophages and smooth muscle cells. The macrophages take up the oxidized LDL cholesterol in an unregulated fashion by scavenger receptors. The

internalization of oxidized LDL cholesterol leads to formation of lipid peroxides and facilitates the accumulation of cholesterol esters, resulting in foam cell formation. As foam cells accumulate, they form a visible atherosclerotic lesion—the fatty streak. Fatty streaks, the initial lesion of atherosclerosis, can be seen in infants and young children. The fatty streak may resolve (based on HDL cholesterol reverse cholesterol transport) or may mature into a fibrous plaque that extends into the vessel lumen.



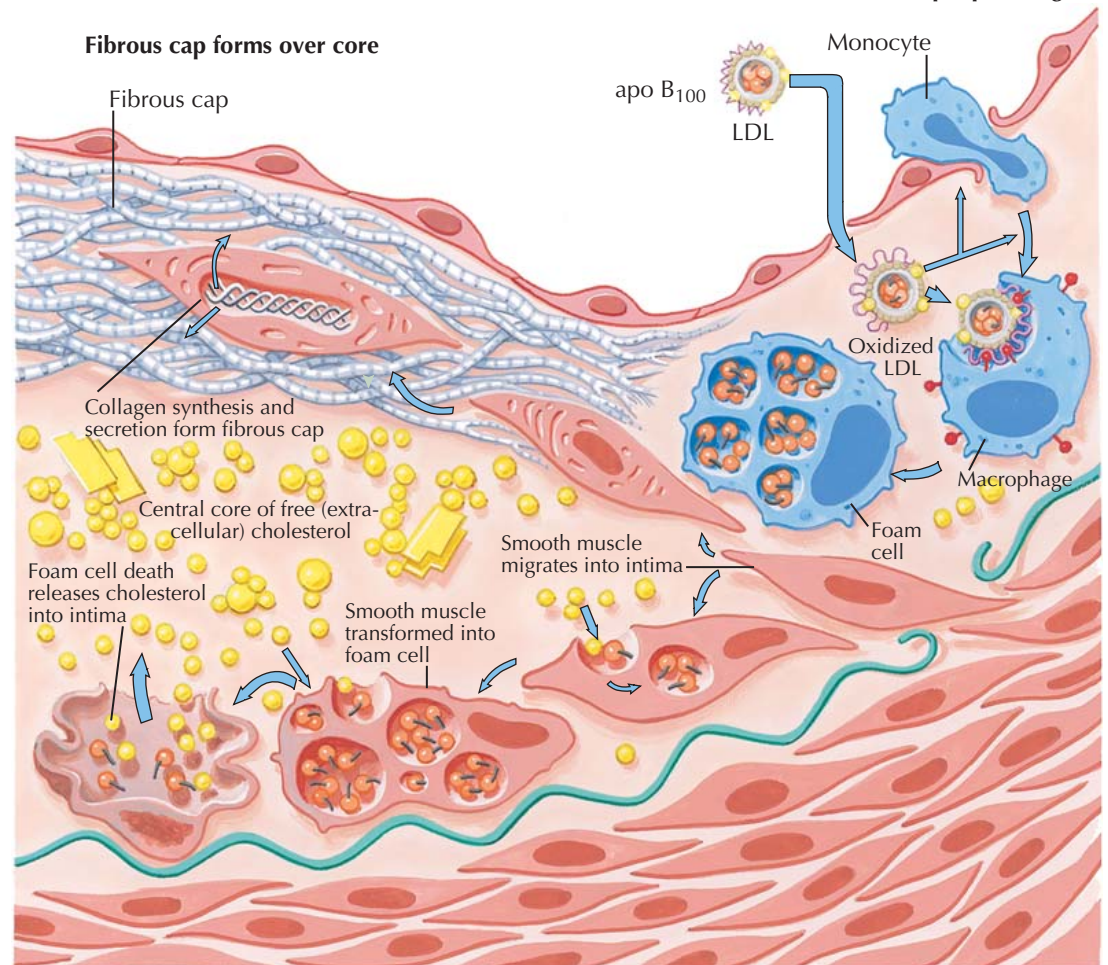
ATHEROGENESIS: FIBROUS PLAQUE FORMATION

Fibrous plaque is larger than fatty streak and occupies more of arterial lumen. Thickened cap synthesized by modified smooth muscle cells. Central core consists of extracellular cholesterol. Foam cells surrounding core derived primarily from smooth muscle cells. Fatty streaks may continue to form at periphery of plaque.



JOHN A. CRAIG, MD  
C. Machado, M.D.

Cholesterol accumulation continues at plaque margins



ATHEROSCLEROSIS (Continued)

As fibrous plaques enlarge and age, foam cells necrose and release oxidized LDL, intracellular enzymes, and oxygen free radicals that can damage the vessel wall. Oxidized LDL induces apoptosis of endothelial cells and vascular smooth muscle cells. The extracellular cholesterol deposition and continued inflammatory response promote smooth muscle cell proliferation and migration and collagen synthesis. Smooth muscle cells become the main cell type, lying in parallel layers with proteoglycan and basement membrane in between. Continued inflammation results in the recruitment of increased numbers of macrophages and lymphocytes that release proteolytic enzymes, cytokines, chemokines, and growth factors. Focal necrosis develops, and free cholesterol forms the central lipid core of the fibrous plaque. Some smooth muscle cells accumulate lipid to become foam cells. Cycles of accumulation of mononuclear cells, migration and proliferation of smooth muscle cells, and formation of fibrous tissue lead to a continuous restructuring of the atherosclerotic lesion. A fibrous cap develops that overlies the core of lipid and necrotic tissue.

With progression of an atherosclerotic lesion, new microvessels arise from the arterial vasa vasorum. The microvessels provide a portal of entry for monocytes and lymphocytes into the developing plaque. The microvessels are fragile and are prone to rupture, resulting in small focal hemorrhages within the plaque. Calcification may occur as a late event in fibrous plaques, and the elasticity of the arterial wall becomes limited. Bone-related proteins (e.g., osteopontin and osteocalcin) can be found in atherosclerotic plaques. Coronary calcification is a marker of atherosclerosis that can be quantified with the use of cardiac computed tomography (CT), and it is proportional to the extent and severity of atherosclerotic disease. Cardiac CT is a noninvasive tool to assess the presence of coronary artery disease. Increased cardiac CT calcium scores indicate higher risk for CHD in both asymptomatic and symptomatic individuals and can be used to guide

management decisions. For example, aggressive preventive medical therapy (see Plate 7-17) and risk factor modification (see Plate 7-14) should be considered for asymptomatic individuals with high cardiac CT calcium scores.

The plaque can progress to a complicated lesion, where the surface endothelial cells may be lost, and the fibrous cap ruptures to expose the subendothelial space. Platelets adhere to the exposed surface, and thrombus formation is initiated. Platelets release their granules,

which contain cytokines, growth factors, and thrombin, resulting in further proliferation and migration of smooth muscle cells and monocytes. A large thrombus may form in unstable ruptured plaques where blood dissects into the artery wall. The plaque rupture and thrombosis can lead to acute ischemic syndromes and sudden cardiac death. Plaque rupture is responsible for approximately 75% of fatal coronary thrombi; these plaques tend to have thin fibrous caps, increased macrophage content, and large lipid cores.



## ATHEROSCLEROSIS RISK FACTORS

The main modifiable cardiovascular risk factors are hypercholesterolemia with increased low-density lipoprotein (LDL) cholesterol, hypertension, cigarette smoking, and diabetes mellitus.

### HYPERLIPIDEMIA

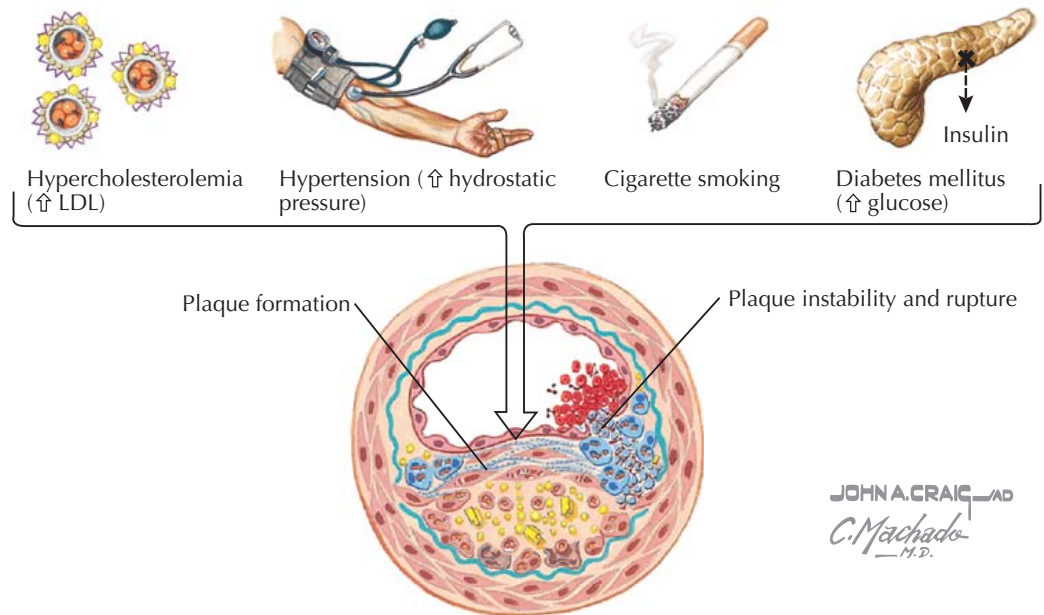
The Third Report of the Expert Panel on Detection, Evaluation, and Treatment of High Blood Cholesterol in Adults is termed the Adult Treatment Panel III (ATP III) and is the most recent version from the National Cholesterol Education Program (NCEP). ATP III guidelines recommend lipid screening (total cholesterol, triglycerides, LDL cholesterol, and high-density lipoprotein [HDL] cholesterol) every 5 years in all adults older than 20 years. The 10-year risk for developing coronary heart disease (CHD) can be determined based on data from the Framingham database. The risk factors included in the Framingham calculation are age, total cholesterol, HDL cholesterol, systolic blood pressure, treatment of hypertension, and cigarette smoking. An online risk calculator is found at <http://hp2010.nhlbi.nih.net/atpiiii/calculator.asp>. The intensity of treatment of hypercholesterolemia should be personalized on the basis of CHD risk. ATP III set cutoffs for blood LDL cholesterol concentrations on the basis of cardiovascular risk. For example, a plasma LDL cholesterol concentration less than 100 mg/dL is considered optimal. As plasma LDL cholesterol levels increase, cardiovascular risk increases. The presence of risk factors (cigarette smoking, hypertension, low plasma concentration of HDL cholesterol, family history of premature CHD, older age [men,  $\geq 45$  years; women,  $\geq 55$  years]) should modify the target LDL cholesterol concentration. For example, the presence of CHD or CHD risk equivalents (e.g., diabetes mellitus) decreases the LDL cholesterol goal to less than 100 mg/dL; if there are two or more risk factors, the LDL cholesterol goal should be less than 130 mg/dL; if there is zero to 1 risk factor, the LDL cholesterol goal should be less than 160 mg/dL. These targets may be modified when NCEP ATP IV guidelines are published in the fall of 2011.

Although LDL-lowering treatments do not markedly regress known obstructing coronary artery lesions, they do markedly decrease coronary events. Thus, the benefit of lipid lowering in patients with known CHD may not be plaque regression but rather plaque stabilization. In addition, the consistent benefit of LDL lowering by 3-hydroxy-3-methylglutaryl coenzyme A (HMG-CoA) reductase inhibitors (statins) may depend not only on their effects on LDL cholesterol but also on their direct influence on plaque biology.

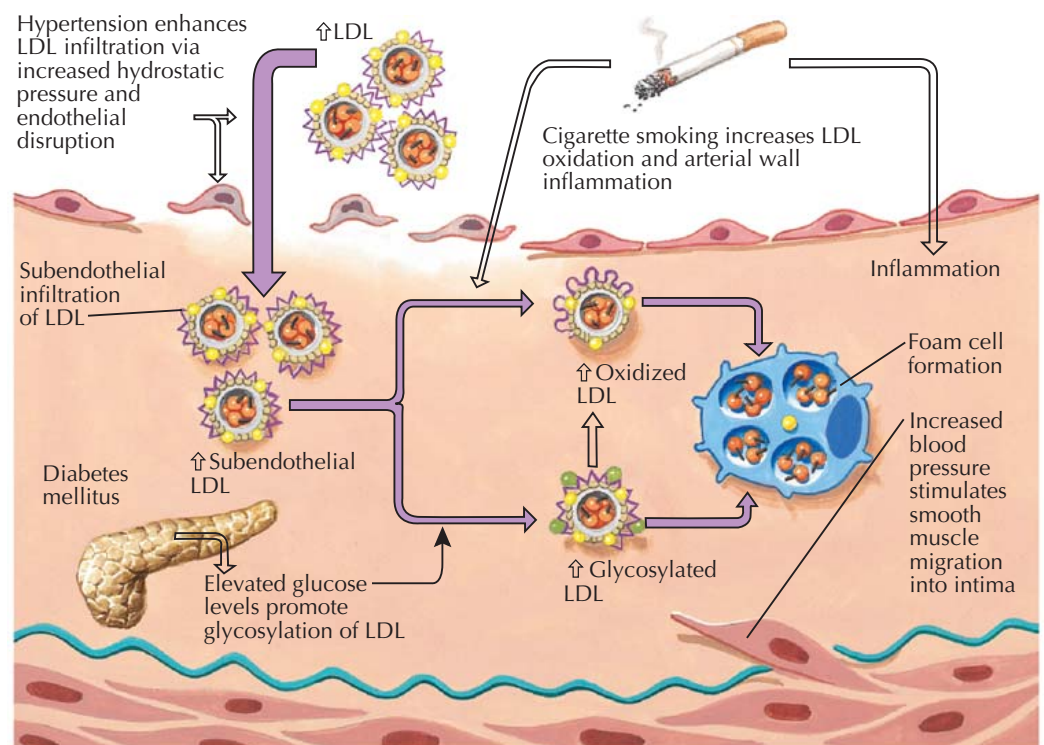
### HYPERTENSION

The cause-and-effect relationship between hypertension and CHD risk is well established. Normalization of blood pressure by nonpharmacologic measures (e.g., weight reduction, sodium-restricted diet, regular isotonic exercise) and pharmacologic measures reduces the risk of stroke, heart failure, and CHD events. The Seventh Report of the Joint National Committee on Prevention, Detection, Evaluation, and Treatment of High Blood Pressure (JNC7) determined that starting at a blood pressure of 115/75 mm Hg, cardiovascular risk doubles for each incremental increase of 20/10 mm

### RISK FACTORS IN CORONARY HEART DISEASE



### Interaction of risk factors in atherogenesis



Hg. JNC7 recommends that prehypertensive individuals (systolic blood pressure, 120–139 mm Hg or diastolic blood pressure, 80–89 mm Hg) engage in health-promoting lifestyle modifications to prevent the progressive increase in blood pressure and the development of cardiovascular disease.

### DIABETES MELLITUS

Most individuals with diabetes mellitus die of atherosclerosis complications. The increased prevalence of atherosclerosis in individuals with diabetes is partly caused by the presence of small and dense LDL

cholesterol, low serum HDL cholesterol concentrations, and increased serum triglyceride concentrations. Increased blood glucose levels also promote glycosylation of LDL cholesterol.

### CIGARETTE SMOKING

The understanding of the mechanisms involved in cigarette smoking-related atherosclerosis is not complete. However, cigarette smoking clearly increases inflammation, thrombosis, and oxidation of LDL cholesterol, leading to increased oxidative stress and arterial wall inflammation.

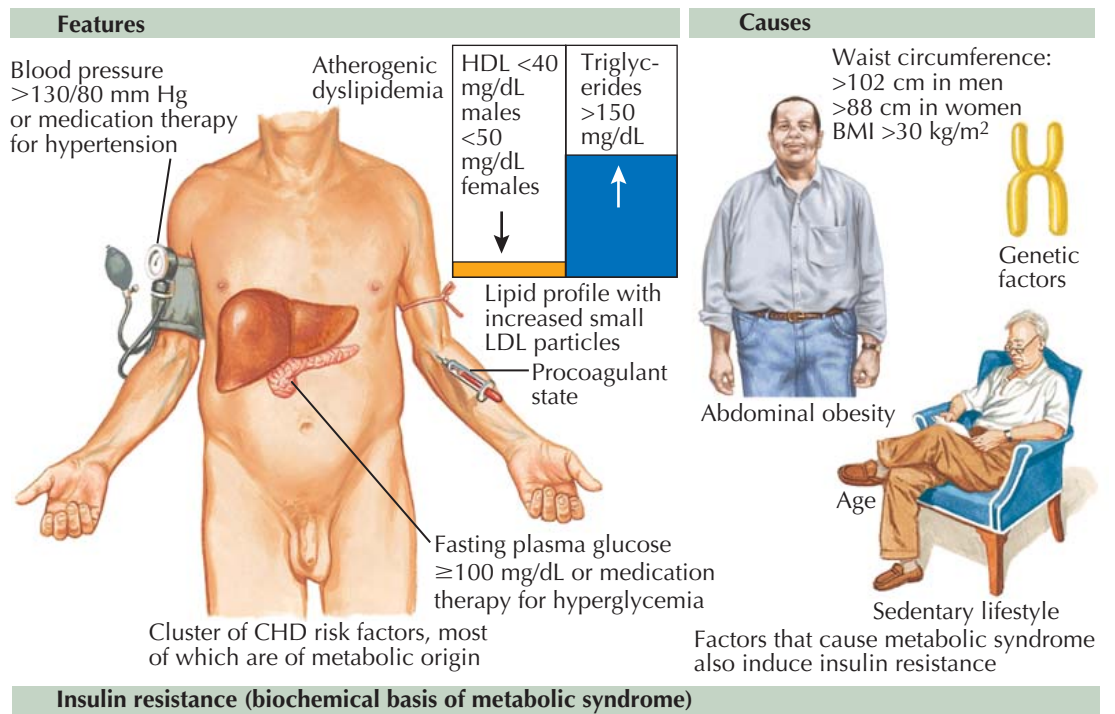
## METABOLIC SYNDROME

The metabolic syndrome is characterized by insulin resistance, hyperinsulinemia, predisposition to diabetes mellitus, dyslipidemia, atherosclerotic vascular disease, and hypertension. Most individuals with the components of the metabolic syndrome are overweight (body mass index [BMI], 25–29 kg/m<sup>2</sup>) or obese (BMI ≥30 kg/m<sup>2</sup>). Excess abdominal visceral fat is very characteristic. Based on the Third Report of the Expert Panel on Detection, Evaluation, and Treatment of High Blood Cholesterol in Adults (Adult Treatment Panel III [ATP III]) guidelines, approximately 50 million people in the United States have the metabolic syndrome. Individuals with this diagnosis have a two- to fourfold increase in subsequent cardiovascular events. It is debated whether the metabolic syndrome is truly a unique entity and whether it confers risk beyond its individual components. However, identifying and treating components of the metabolic syndrome are important to decrease morbidity and mortality related to cardiovascular disease and diabetes.

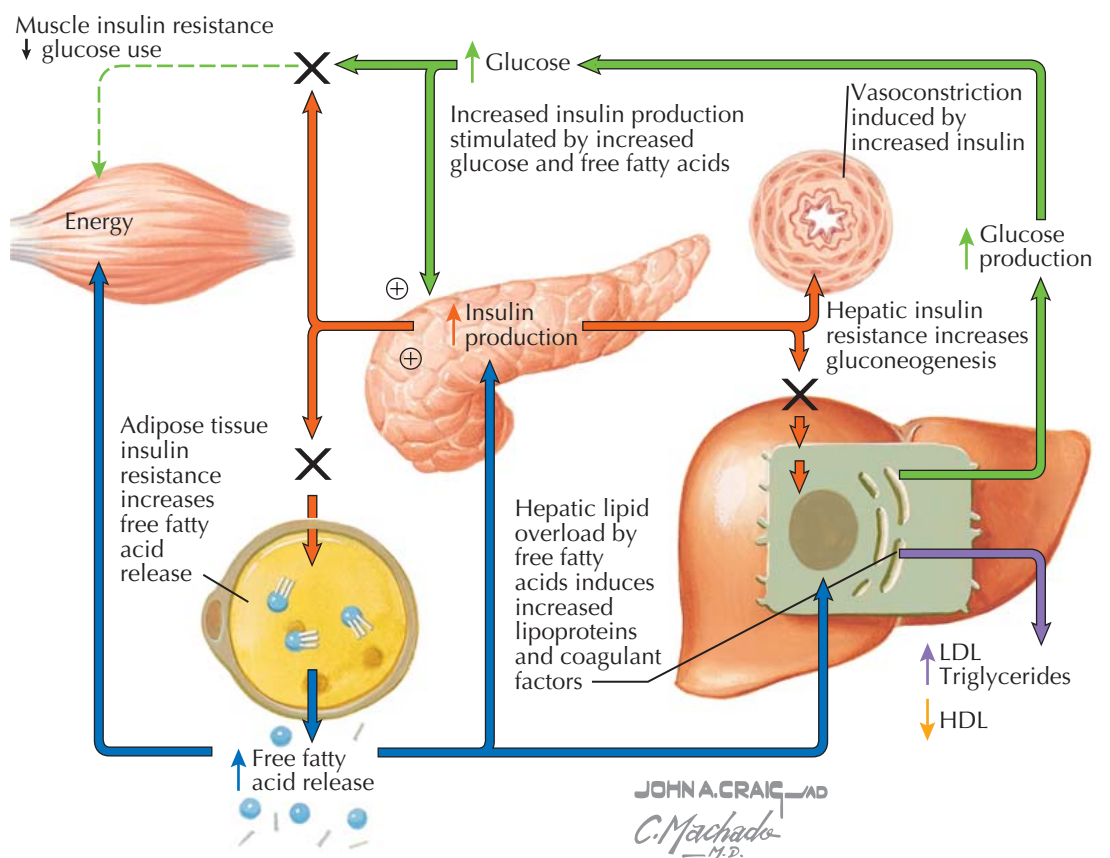
Insulin resistance occurs when more than normal amounts of insulin are required to elicit a normal biologic response, a situation inferred by high fasting levels of blood insulin. Insulin resistance affects muscle, liver, and adipose tissues and results in decreased peripheral glucose and fatty acid use. Biomarkers consistent with the concept that the metabolic syndrome is a prothrombotic and proinflammatory state include increased serum levels of C-reactive protein, plasminogen activator inhibitor 1, interleukin 6, and adipocyte cytokines (e.g., adiponectin).

No single test is available to diagnose the metabolic syndrome. The ATP III diagnostic criteria include the presence of any three of the following five traits: (1) abdominal obesity defined as a waist circumference larger than 102 cm in men or larger than 88 cm in women; (2) serum triglyceride concentration above 150 mg/dL or medication therapy for hypertriglyceridemia; (3) serum high-density lipoprotein (HDL) cholesterol concentration below 40 mg/dL in men or below 50 mg/dL in women or medication therapy for low HDL cholesterol; (4) blood pressure above 130/80 mm Hg or medication therapy for hypertension; and (5) fasting plasma glucose concentration 100 mg/dL or above or medication therapy for hyperglycemia. The diagnostic criteria from the World Health Organization include insulin resistance (identified by type 2 diabetes mellitus, impaired fasting glucose, or impaired glucose tolerance) plus any two of the following five traits: (1) antihypertensive medication use or high blood pressure (i.e., ≥140/90 mm Hg); (2) serum triglyceride concentration 150 mg/dL or above; (3) serum HDL cholesterol concentration below 35 mg/dL in men or below 39 mg/dL in women; (4) BMI above 30 kg/m<sup>2</sup> or a waist-to-hip ratio above 0.9 in men or above 0.85 in women; and (5) urinary albumin excretion rate 20 μg/min or above or albumin-to-creatinine ratio 30 mg/g or above.

Clinical assessment of patients with one or more risk factors for the metabolic syndrome should include a history, physical examination (including blood pressure measurement, determination of BMI, and waist circumference measurement), fasting lipid profile, and fasting plasma glucose.



### Insulin resistance (biochemical basis of metabolic syndrome)



The cornerstone of treatment of the metabolic syndrome is lifestyle modification with weight loss and increased physical activity. Diet and exercise can delay the onset of diabetes in patients with impaired glucose tolerance. Exercise (e.g., ≥30 minutes of moderate-intensity physical activity daily) has the potential to decrease abdominal fat. Cigarette smoking should be discouraged. In patients with impaired fasting glucose or type 2 diabetes, the addition of metformin can very effectively improve glycemic control because it enhances

insulin action. The overall management of diabetes in patients with the metabolic syndrome should follow clinical guidelines for diabetes (see Plate 5-20). The metabolic syndrome is a coronary risk equivalent, and serum cholesterol targets should follow clinical guidelines (see Plates 7-5 and 7-17). If the Framingham coronary artery risk score (see Plate 7-14) is more than 10%, the addition of low-dose aspirin (e.g., 81 mg/d) should also be considered.



## MECHANISMS OF ACTION OF LIPID-LOWERING AGENTS

Lipid-lowering agents include cholesterol absorption inhibitors, 3-hydroxy-3-methylglutaryl coenzyme A (HMG-CoA) reductase inhibitors (statins), bile acid sequestrants, nicotinic acid, fibric acid derivatives, and fish oil. Each drug class differs with regard to mechanism of action and type of and degree of lipid lowering. The benefits seen with lipid lowering are multifaceted and extend beyond regression of atherosclerosis to include decreased thrombogenesis, reversal of endothelial dysfunction, and atherosclerotic plaque stabilization.

### CHOLESTEROL ABSORPTION INHIBITORS

Ezetimibe is the first drug in a class of cholesterol absorption inhibitors that impair cholesterol absorption at the brush border of the intestine. Ezetimibe does not affect the absorption of triglycerides or fat-soluble vitamins. Its mechanism of action involves Niemann-Pick C1-like 1 proteins that have a role in intestinal cholesterol transport. Thus, there is decreased intestinal delivery of cholesterol to the liver. At a dose of 10 mg/d, ezetimibe lowers the serum low-density lipoprotein (LDL) cholesterol concentration by an average of 17%. The effect of ezetimibe is additive to that of statins.

### STATINS

Statins are competitive inhibitors of HMG-CoA reductase—the rate-limiting step in cholesterol biosynthesis. The statin-induced decrease in hepatocyte cholesterol content results in increased LDL-receptor turnover and LDL-receptor cycling. Statins lower serum LDL cholesterol concentrations by 30% to 60%. In addition, statins modify the atherogenic lipoprotein phenotype by decreasing the serum concentration of small dense LDL cholesterol. Most statins lower triglyceride concentrations by 20% to 40% and increase high-density lipoprotein (HDL) cholesterol by 5% to 10%. Currently available statins include lovastatin, simvastatin, pravastatin, fluvastatin, atorvastatin, pitavastatin, and rosuvastatin.

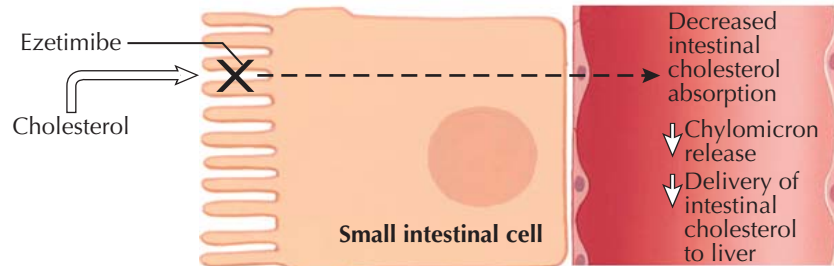
### BILE ACID SEQUESTRANTS

Bile acid sequestrants bind bile acids in the intestine and thus interrupt the usually efficient (90%) reabsorption of bile acids. The resultant reduction in intrahepatic cholesterol promotes the synthesis of LDL receptors. The increased numbers of hepatocyte LDL receptors bind LDL cholesterol from the plasma and thus reduce the serum LDL cholesterol concentration by 10% to 24%. The cholesterol-lowering effect of bile acid sequestrants is additive to that of statins. Currently available bile acid sequestrants include cholestyramine, colestipol, and colesevelam.

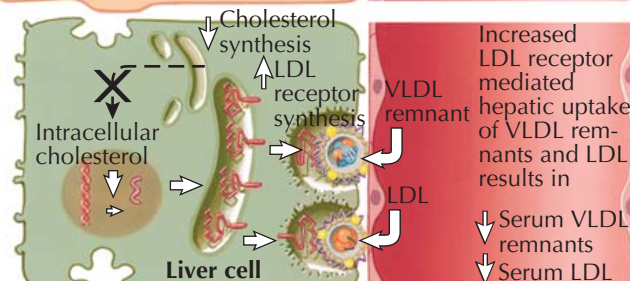
### NICOTINIC ACID

Nicotinic acid inhibits the hepatic production of very low-density lipoproteins (VLDL), which results in reduced lipolysis to LDL cholesterol. Nicotinic acid also increases serum HDL cholesterol concentrations by up to 35% by decreasing lipid transfer of cholesterol from HDL to VLDL and by inhibiting HDL clearance. Nicotinic acid is available in immediate-release (crystalline) and sustained-release formulations.

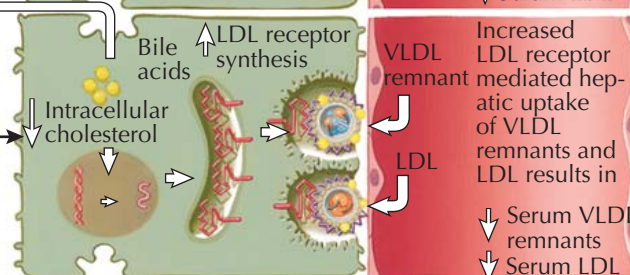
**Ezetimibe.**  
Localizes at intestinal brush border of small intestine  
Blocks absorption of intestinal cholesterol



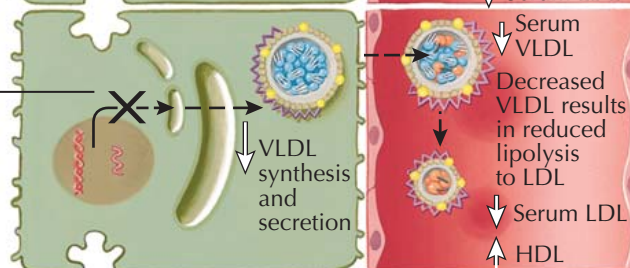
**Statins (HMG-CoA reductase inhibitors).**  
Reduce cholesterol synthesis, lowering intracellular cholesterol, which stimulates LDL receptor synthesis



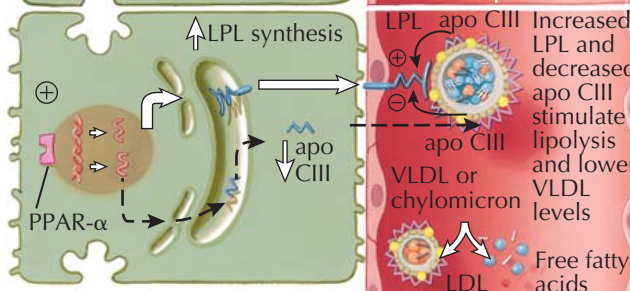
**Bile acid sequestrants.**  
Bind bile acids in gut, decreasing intracellular cholesterol content, which stimulates LDL receptor synthesis



**Nicotinic acid.**  
Decreases hepatic production of VLDL



**Fibric acids.** Stimulate PPAR- $\alpha$  nuclear receptor, increasing LPL synthesis and decreasing apo CIII synthesis



JOHN A. CRAIG — M.D.  
C. Machado — M.D.

### FIBRIC ACIDS

Fibric acids lower serum triglyceride concentrations and increase serum HDL cholesterol concentrations by activation of peroxisome proliferator-activated receptor- $\alpha$  (PPAR- $\alpha$ ). Fibric acids reduce serum triglyceride concentrations by reducing hepatic secretion of VLDL and by stimulating lipoprotein lipase (LPL) activity that increases the clearance of triglyceride-enriched lipoproteins. These effects are also mediated by downregulation of apolipoprotein (apo) CIII gene expression. Fibric acids increase serum HDL cholesterol concentrations by stimulating synthesis of apo AI and apo AII. Fibric acid administration lowers serum triglyceride concentrations by 35% to 50%, increases serum HDL cholesterol concentrations by 15% to 25%, and lowers serum lipoprotein(a) concentrations to a variable degree. Currently available fibric acids are gemfibrozil and fenofibrate.

### FISH OIL

The active components in fish oil are the long-chain omega-3 fatty acids, eicosapentaenoic acid (EPA, 20:5n-3) and docosahexaenoic acid (DHA, 22:6n-3). Ingested EPA and DHA are absorbed in the small intestine and transported to the liver as triglycerides in chylomicron particles. The liver releases EPA and DHA into the circulation as triglycerides in lipoprotein particles (e.g., LDL cholesterol and HDL cholesterol). EPA and DHA decrease the hepatic secretion of triglyceride-rich lipoproteins; the exact mechanism of this effect is not yet known. Daily intake of 3 to 4 g of EPA and DHA lowers serum triglyceride concentrations by 20% to 50%. Fish oil supplementation also increases serum HDL cholesterol concentrations by 3% and lowers the proportion of small, dense LDL cholesterol.

## TREATMENT OF HYPERLIPIDEMIA

All patients with elevated serum concentrations of low-density lipoprotein (LDL) cholesterol should engage in lifestyle modifications such as regular aerobic exercise, a prudent diet that is low in saturated fat and high in fiber, and weight loss in overweight patients. The impact of lifestyle measures on serum LDL cholesterol concentrations is quite variable and depends in part on baseline dietary habits. The treatment of hyperlipidemia is influenced by the absence (primary prevention) or the presence (secondary prevention) of coronary heart disease (CHD).

### PRIMARY PREVENTION


If the serum LDL cholesterol concentration remains increased despite lifestyle measures and if the CHD risk assessment (see Plate 7-14) suggests that pharmacologic therapy should be initiated, the drug class of choice is 3-hydroxy-3-methylglutaryl coenzyme A (HMG-CoA) reductase inhibitors (statins). Treatment with a statin lowers CHD risk by 20% to 30%. Typical starting doses are 10 mg of atorvastatin or 20 mg of lovastatin, pravastatin, or simvastatin. Statins lower serum LDL cholesterol by 30% to 60%. Atorvastatin and rosuvastatin are the most potent statins; in addition, these two statins have a triglyceride-lowering effect. The effect of statin treatment is additive to that achieved with a prudent diet. Elevation in hepatic enzymes and diffuse myalgias are unusual but potentially serious adverse effects. Very rarely (one case per 15 million prescriptions), statins cause rhabdomyolysis, a serious adverse effect that is more common in patients also treated with a fibrate (the risk is much greater with gemfibrozil than with fenofibrate) or cyclosporine.

### SECONDARY PREVENTION


The risk of a future myocardial infarction is 20 times higher in individuals with CHD than in those without CHD. Large trials have shown that cholesterol lowering in individuals with CHD is associated with a 13% to 16% reduction in mortality. In addition, serial angiographic studies have shown that cholesterol lowering can slow the progression and induce regression of coronary atherosclerosis, a finding most evident when LDL cholesterol concentrations are reduced below 100 mg/dL. In patients with stable CHD or a CHD equivalent (e.g., diabetes mellitus), the statin dosage can be titrated upward every 6 weeks to achieve the LDL cholesterol target (usually <100 mg/dL). The lowest dosage of a statin that achieves this LDL cholesterol target should be used. In patients who present with an acute myocardial infarction, it is reasonable to start the statin in the hospital at a high dosage (e.g., atorvastatin 80 mg/d) with an LDL cholesterol target less than 70 mg/dL. If the target serum LDL cholesterol concentration cannot be achieved with a statin alone, then a second lipid-lowering agent should be added. The add-on agent is usually a cholesterol absorption inhibitor (e.g., ezetimibe) or a bile acid sequestrant. In addition, patients with stable CHD who do not tolerate a statin (e.g., because of myopathy) should be treated with either an agent from an alternative lipid-lowering class


**Dietary management**

**Weight control**




Reduce consumption of foods high in cholesterol, saturated fat, trans fatty acids, and salt. Decrease total caloric intake.






**Increase exercise**

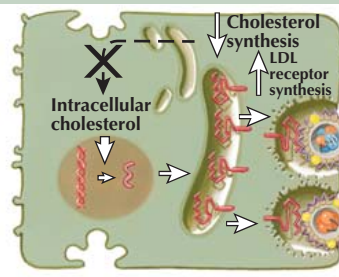
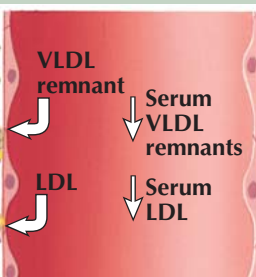
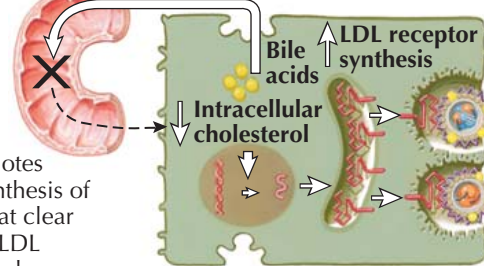
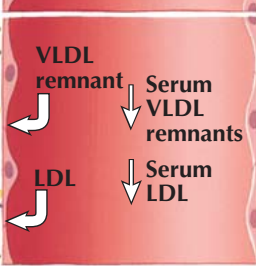
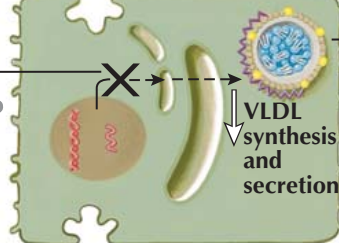
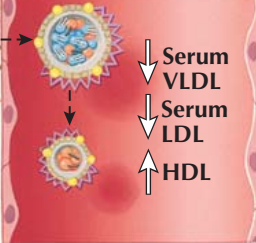
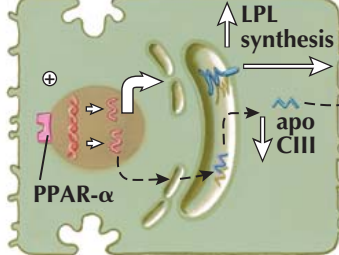
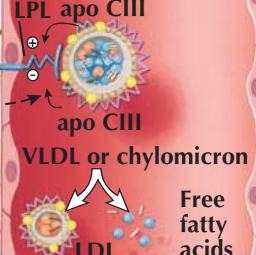


Increase consumption of food low in saturated fat and high in fiber.

Fish oil supplements 

Appropriate diet and exercise are cornerstones of cholesterol management. Dietary counseling and reinforcement and a planned program of physical activity are recommended.

**Actions of lipid-lowering medications**

|  |  |   |   |
|--|--|---|---|
| <p><b>Statins</b><br/>Statins (HMG-CoA reductase inhibitors) inhibit cholesterol synthesis and increase LDL receptor uptake of LDL</p>   |    |    | <p>Increased LDL receptor-mediated hepatic uptake of VLDL remnants and LDL</p>        |
| <p><b>Bile acid sequestrants</b><br/>Bind bile acids in the intestine and the resultant reduction in intrahepatic cholesterol promotes the increased synthesis of LDL receptors that clear more VLDL and LDL cholesterol from plasma</p>   |   |   | <p>Increased LDL receptor-mediated hepatic uptake of VLDL remnants and LDL</p>        |
| <p><b>Nicotinic acid</b><br/>Inhibits the hepatic production of VLDL</p> <p style="font-size: small; color: gray;">JOHN A. CRAIG, MD<br/>C. Machado, M.D.</p>  |  |  | <p>Decreased VLDL results in reduced lipolysis to LDL</p>                             |
| <p><b>Fibric acid derivatives</b><br/>Interact with peroxisome proliferator-activated receptor <math>\alpha</math> (PPAR-<math>\alpha</math>) to reduce serum triglyceride concentrations by reducing hepatic secretion VLDL and by stimulating lipoprotein lipase (LPL) activity that increases the clearance of triglyceride-enriched lipoproteins</p> |  |  | <p>Increased LPL and decreased apo CIII stimulate lipolysis and lower VLDL levels</p> |

or pravastatin. Pravastatin is associated with a decreased risk of myopathy.

### RAISING HIGH-DENSITY LIPOPROTEIN CHOLESTEROL

Low serum concentrations of high-density lipoprotein (HDL) cholesterol are common in individuals with premature CHD. Exercise, weight loss in obese individuals, and smoking cessation can all increase serum HDL cholesterol concentrations. Medications (e.g., androgens, benzodiazepines, or  $\beta$ -adrenergic antagonists) that are known to lower serum HDL cholesterol should be discontinued. Agents that have the potential to increase serum HDL cholesterol concentrations by 15% to 30% include nicotinic acid, gemfibrozil, and estrogen replacement therapy in postmenopausal women.

### HYPERTRIGLYCERIDEMIA

Treatment directed at hypertriglyceridemia (see Plates 7-10 and 7-11) should be considered in patients who also have hypercholesterolemia. Triglyceride-rich lipoproteins (very low-density lipoproteins [VLDL]) also transport cholesterol, and the hypercholesterolemia is partly caused by the hypertriglyceridemia.

### MONITORING

Monitoring the fasting lipid panel every 6 to 8 weeks until the serum LDL cholesterol target is achieved is reasonable. Thereafter, rechecks every 6 to 12 months are indicated. With each dose change, liver function tests should be performed at the time of blood sampling.



## ABSORPTION OF ESSENTIAL VITAMINS

Vitamins are organic substances that cannot be synthesized by humans; they must be ingested in the diet. They are divided into water-soluble and fat-soluble vitamins.

### WATER-SOLUBLE VITAMINS

All water-soluble vitamins (with the exception of vitamin B<sub>12</sub>; see following discussion) are absorbed in the jejunum and ileum by passive diffusion and by a sodium (Na<sup>+</sup>)-coupled active transport pump. The water-soluble vitamins leave the enterocyte to the portal circulation by a Na<sup>+</sup>-coupled adenosine-5'-triphosphate (ATP)-dependent pump.

Vitamin B<sub>1</sub> (thiamine) has limited tissue storage, and its biologic half-life is 10 to 20 days. Thiamine is a key cofactor for enzymes involved in amino acid and carbohydrate metabolism. The main food sources of thiamine are yeast, brown rice, whole-grain cereals, legumes, and pork.

Vitamin B<sub>2</sub> (riboflavin) is a flavin and is incorporated as a component of flavin-adenine dinucleotide. Flavo-proteins serve as catalysts in a number of mitochondrial oxidative and reductive reactions and function as electron transporters. The dietary sources of riboflavin include meats, fish, milk, eggs, yeast, green vegetables, and enriched foods.

Vitamin B<sub>3</sub> (niacin) is nicotinic acid and nicotinamide. Through a series of biochemical reactions in the mitochondria, niacin, nicotinamide, and tryptophan form nicotinamide adenine dinucleotide (NAD) and NAD phosphate (NADP). As essential components of redox reactions and hydrogen transport, NAD and NADP are crucial in the synthesis and metabolism of carbohydrates, fatty acids, and proteins. Food sources of niacin include meats (especially liver), yeasts, cereals, legumes, and seeds.

Vitamin B<sub>5</sub> (pantothenic acid) is an essential cofactor in many acetylation reactions, including the tricarboxylic acid cycle. Following ATP-dependent phosphorylation, pantothenic acid becomes coenzyme A. The main dietary sources of pantothenic acid are egg yolk, liver, broccoli, milk, chicken, beef, potatoes, and whole grains.

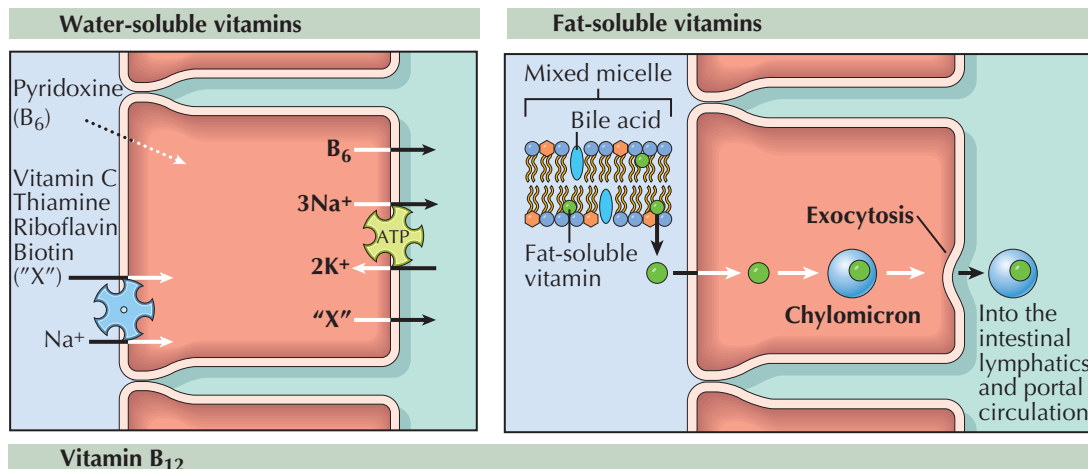
Vitamin B<sub>6</sub> (pyridoxine) is absorbed by passive diffusion in the jejunum and ileum. Pyridoxine is involved in many metabolic steps, including decarboxylation of amino acids and gluconeogenesis. Pyridoxine and pyridoxamine are found in meats, whole grains, vegetables, and nuts.

Biotin functions as a cofactor to the carboxylase enzyme. Biotin is an essential component of several enzyme complexes in carbohydrate and lipid metabolism, where it acts as a carbon dioxide carrier on the surface of each enzyme. Biotin is found in liver, egg yolk, soybean products, and yeast.

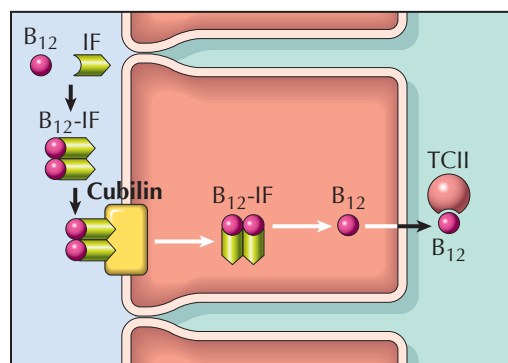
Vitamin C (ascorbic acid) functions as a cofactor and cosubstrate in providing reducing equivalents for a number of biochemical reactions involving iron and copper. Ascorbic acid provides electrons needed to reduce molecular oxygen. Food sources of vitamin C include citrus fruits, tomatoes, Brussels sprouts, potatoes, cauliflower, broccoli, strawberries, cabbage, and spinach.

Vitamin B<sub>12</sub> (cobalamin) binds to gastric-derived intrinsic factor (IF) in the small intestine. The IF-vitamin B<sub>12</sub> complex binds to a specific ileal receptor,

| Water-soluble vitamins       |                   |                                    |
|------------------------------|-------------------|------------------------------------|
| Vitamin C                    | Ileum             | Na <sup>+</sup> -coupled/2° active |
| Thiamine (B <sub>1</sub> )   | Jejunum           | Na <sup>+</sup> -coupled/2° active |
| Riboflavin (B <sub>2</sub> ) | Jejunum           | Na <sup>+</sup> -coupled/2° active |
| Biotin                       | Jejunum           | Na <sup>+</sup> -coupled/2° active |
| Vitamin B <sub>12</sub>      | Ileum             | Facilitated diffusion              |
| Pyridoxine (B <sub>6</sub> ) | Jejunum and ileum | Passive diffusion                  |
| Fat-soluble vitamins         |                   |                                    |
| Vitamin A                    | Jejunum and ileum | Passive diffusion                  |
| Vitamin D                    | Jejunum and ileum | Passive diffusion                  |
| Vitamin E                    | Jejunum and ileum | Passive diffusion                  |
| Vitamin K                    | Jejunum and ileum | Passive diffusion                  |



### Vitamin B<sub>12</sub>



J. Perkins  
MS, MFA

cubilin, from which it is absorbed into the enterocyte in an energy-requiring process. Vitamin B<sub>12</sub> then enters the plasma and is bound to transcobalamins (TCs); the vitamin B<sub>12</sub>-TCII complex is the most physiologically important one. Vitamin B<sub>12</sub> is required for DNA synthesis in cells undergoing rapid turnover. Meat and dairy products are the only dietary sources of vitamin B<sub>12</sub>.

### FAT-SOLUBLE VITAMINS

Fat-soluble vitamins are released from dietary proteins via proteolysis in the stomach and by the proteolytic action of pancreatic enzymes in the small intestine. Bile salts then solubilize the vitamins into micelles for absorption into enterocytes, where they are incorporated into chylomicrons, thereby facilitating absorption into the intestinal lymphatics and portal circulation for transport to the liver.

Vitamin A is part of a family of lipid-soluble compounds (retinols,  $\beta$ -carotenes, and carotenoids) referred to as retinoic acids. Vitamin A has a major role in phototransduction and cellular differentiations in the eyes. The best food sources of retinols are liver, egg

yolk, and butter.  $\beta$ -carotene is found in green leafy vegetables.

Vitamin D (calciferol) includes a group of lipid-soluble compounds with a four-ringed cholesterol backbone. Vitamin D is critical for normal calcium absorption and bone metabolism. Sunlight and ultraviolet light photoisomerize provitamin D to vitamin D<sub>3</sub> (cholecalciferol) in the skin. Intestinal absorption is the other major source of vitamin D. The main dietary sources of vitamin D are fortified milk, fatty fish, cod liver oil, and eggs.

Vitamin E functions as a free radical scavenger and protects polyunsaturated fatty acids (that serve as structural components of cell membranes) from peroxidation. Vitamin E is found in a variety of foods, including oils, meat, eggs, and leafy vegetables.

Vitamin K is a cofactor required for the activity of several key proteins in the coagulation pathway. For example, vitamin K is necessary for activation of coagulation factors VII, IX, X, and prothrombin. Dietary vitamin K<sub>1</sub> (phylloquinone) is found in green leafy vegetables. In addition, gut microflora synthesize vitamin K<sub>2</sub> (menaquinone), which provides a portion of the dietary requirement of vitamin K.

## VITAMIN B<sub>1</sub> DEFICIENCY: BERIBERI

Vitamin B<sub>1</sub> (thiamine) deficiency (beriberi) was first described in Chinese medical texts as early as 2697 BC. Thiamine is a water-soluble vitamin that consists of a pyrimidine and a thiazole moiety. Dietary thiamine is obtained primarily from whole-grain cereals, whole-wheat bread, brown rice, legumes, yeast, and fresh meats. The thiamine molecule is denatured at high temperatures or at an alkaline pH; thus, cooking, baking, pasteurization, and canning can destroy the bioactivity of thiamine.

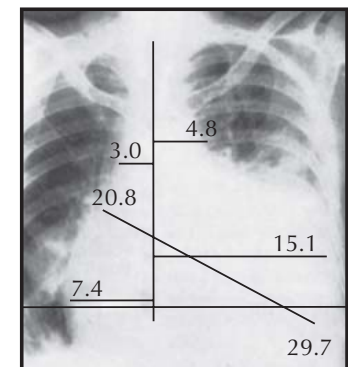
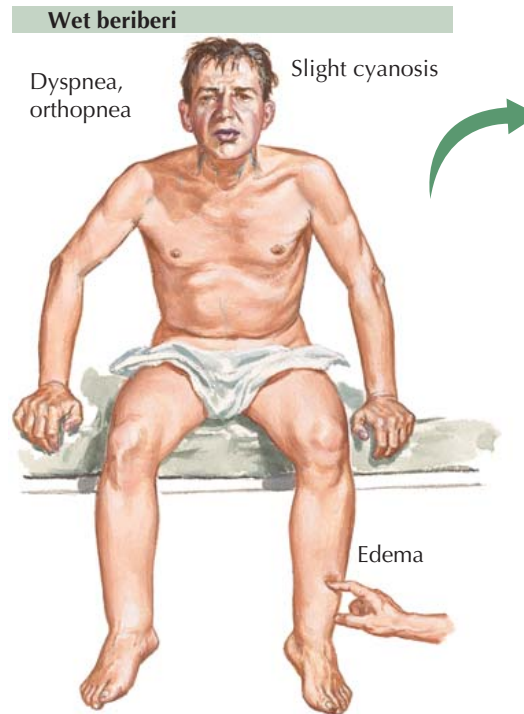
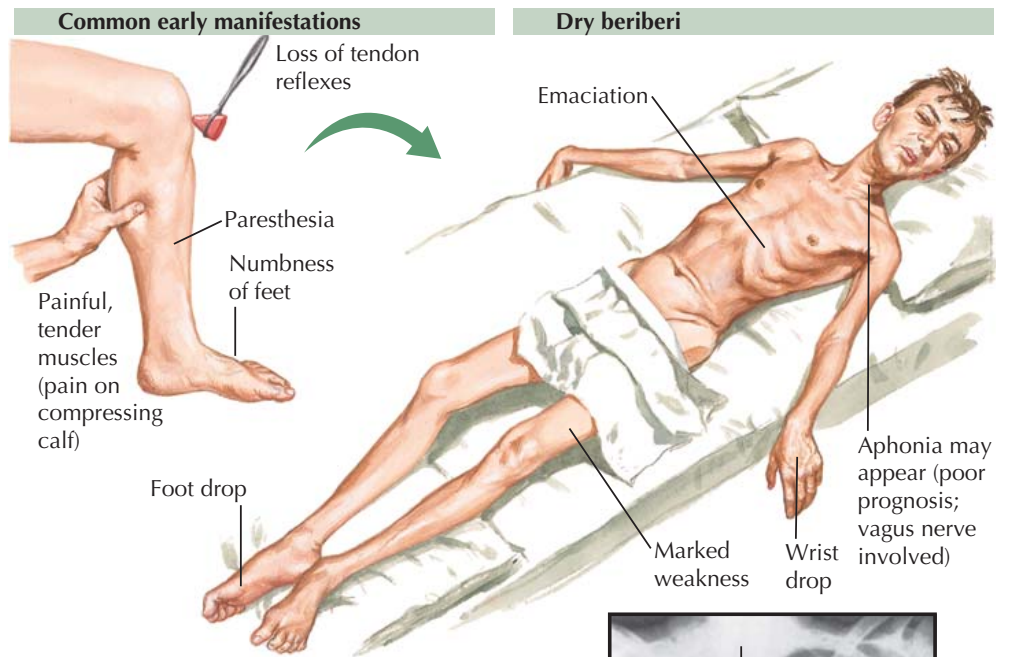
Thiamine is absorbed in the jejunum and ileum (see Plate 7-18). Upon entering the bloodstream, thiamine is bound to albumin, and it enters cells by passive diffusion and active transport. Thiamine is localized primarily to the heart, skeletal muscles, brain, liver, and kidneys. Because thiamine does not have large functional tissue depots, its biologic half-life is only 10 to 20 days. Thus, continuous dietary intake is required.

Thiamine serves as a cofactor for enzymes involved in carbohydrate and amino acid metabolism. For example, thiamine catalyzes the conversion of pyruvate to acetyl coenzyme A (see Plates 5-6 and 5-7). Thiamine also has a key role in the pentose phosphate pathway (see Plate 5-8). Normal nerve impulse propagation is dependent on thiamine. The main disorders associated with thiamine deficiency are beriberi and Wernicke-Korsakoff syndrome.

### BERIBERI

Beriberi results from nutritional deficiency in thiamine. Beriberi can occur in infants who are breastfed by mothers who are deficient in thiamine. More often it occurs in children and adults whose diets are deficient in thiamine (e.g., diets in which the primary caloric source is polished rice or alcohol). The clinical manifestations of thiamine deficiency are variable and depend on the severity and duration of deprivation. Muscle and nerve tissue symptoms predominate. Infantile beriberi usually becomes apparent by 2 months with central nervous system disability (vomiting, nystagmus, purposeless movements, or seizures), cardiac disease (cardiomegaly, tachycardia, or cyanosis), and sudden death. In adults, the manifestations are primarily those of peripheral neuropathy and muscular disease affecting function of skeletal and cardiac muscles. “Dry beriberi” refers to a primarily neurologic presentation, with gradual onset of symmetric peripheral neuropathy (e.g., distal paresthesias); myalgias; and weakness that may advance to foot drop, wrist drop, flaccid paralysis, muscle wasting, aphonia, and emaciation. “Wet beriberi” refers to a primarily cardiac presentation with signs (e.g., cardiomegaly) and symptoms (e.g., dyspnea, orthopnea, peripheral edema, or tachycardia) of congestive heart failure.

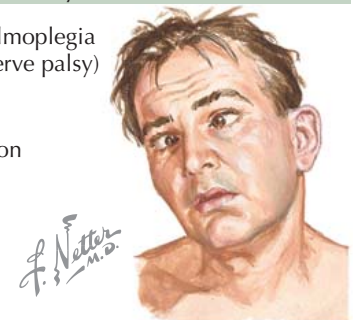
In addition to supportive care, patients with beriberi should be treated with thiamine that is initially administered intravenously or intramuscularly. The daily dose for the first 2 weeks should be 50 to 100 mg. Thereafter, an oral dosage of 10 mg/d can be given until full recovery is achieved. All patients with thiamine deficiency should also be assessed for other potential vitamin deficiencies.



Dilatation of right heart; heart failure

### Wernicke syndrome

Ophthalmoplegia (sixth nerve palsy)  
 ↓  
 Confusion  
 ↓  
 Coma  
 ↓  
 Death



### WERNICKE-KORSAKOFF SYNDROME

Wernicke-Korsakoff syndrome is the most serious form of thiamine deficiency in adults. The Wernicke encephalopathy phase is characterized by ophthalmoplegia (sixth cranial nerve palsy), nystagmus, ataxia, and confusion that may progress to coma. Survival requires prompt recognition and treatment with 50 mg of intravenously administered thiamine daily until the same dosage can be given orally. Wernicke encephalopathy is seen primarily in alcoholic individuals who deplete thiamine stores through prolonged bouts of alcohol use. The Korsakoff phase is the chronic neurologic condition of impaired short-term memory and confabulation—the end result of the Wernicke encephalopathy phase.

### DIAGNOSIS

When thiamine deficiency is suspected, it can be confirmed by measuring the blood thiamine concentration (reference range, 80–150 nmol/L).

### PREVENTION

The recommended daily allowance for thiamine in the United States is 1.2 mg for men and 1.0 mg for women (1.4 mg during pregnancy and lactation). These amounts of thiamine are easily obtained from a nutritious diet that is rich in whole-grain cereals, whole-wheat bread, brown rice, legumes, yeast, and fresh meats.



## VITAMIN B<sub>3</sub> DEFICIENCY: PELLAGRA

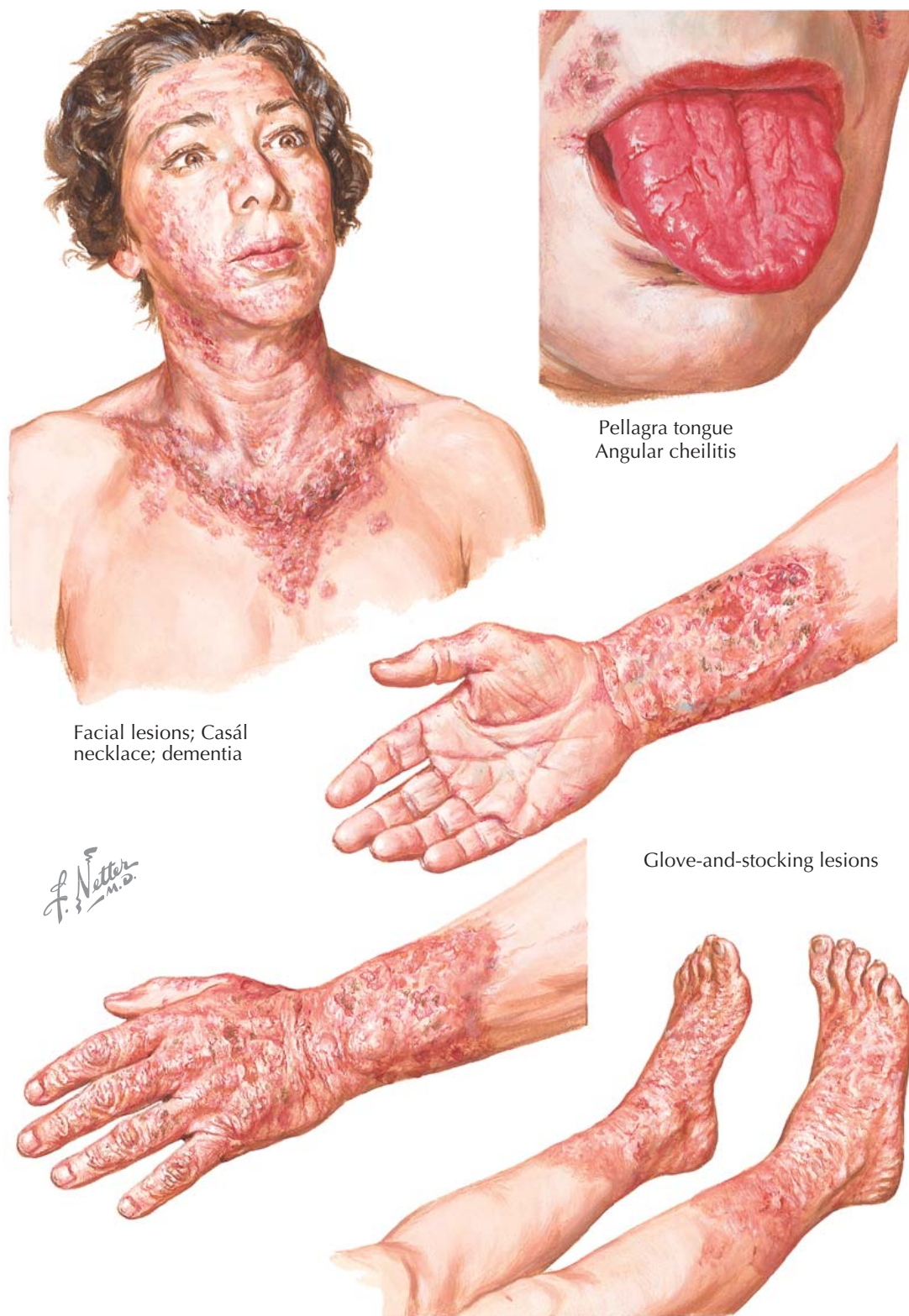
Pellagra (“raw skin”) is a nutritional deficiency disorder caused by insufficient intake of vitamin B<sub>3</sub> (niacin). Pellagra was first described by Casál in 1735 in Spanish peasants eating maize-based diets. Subsequently, it was found worldwide where maize and corn were the principal foodstuffs. Although still a problem in some areas of India, China, and Africa, pellagra is only seen in the United States as a complication of gastrointestinal malabsorptive disorders, anorexia nervosa, and alcoholism. Food sources of niacin include meats (especially liver), yeasts, whole-grain cereals, legumes, and seeds.

Nicotinic acid and nicotinamide are the principal forms of vitamin B<sub>3</sub>. Mitochondria transform niacin, nicotinamide, and tryptophan to form nicotinamide adenine dinucleotide (NAD) and NAD phosphate (NADP). Many enzymatic reactions depend on NAD and NADP. As essential components of redox reactions and hydrogen transport, NAD and NADP are crucial in the synthesis and metabolism of carbohydrates, fatty acids, and proteins (see Plates 5-6 and 5-7). Niacin is absorbed in the jejunum and ileum (see Plate 7-18). Upon entering the bloodstream, niacin is rapidly taken up by the liver, kidneys, and erythrocytes. Intracellular nicotinamide and nicotinic acid are converted to the coenzyme forms NAD and NADP, which are used and stored in tissues with high metabolic activities (e.g., liver and muscle).

Pellagra is characterized by dermatitis, stomatitis, gastritis, diarrhea, encephalopathy, anemia, and peripheral neuropathy. The “3 D’s” (dermatitis, diarrhea, and dementia) describe most cases. The dermatitis is characterized by photosensitivity with symmetric lesions with a sharp line of demarcation between involved and uninvolved skin. These lesions are typically located on the extensor surfaces of the hands, arms, and feet; they may have a “glove-and-stocking” distribution. Another prominent site is the exposed area of the neck, where the circumferential lesion is termed *Casál necklace*. The facial lesions tend to be distributed over the alae of the nose and on the forehead. Intertriginous folds and areas of skin such as the perineum and under the breasts are other typical sites of involvement. The dermatitis begins with an erythema resembling sunburn, which then becomes reddish-brown, roughened, and scaly. Desquamation usually starts in the center of the lesion and reveals underlying skin, which is red and thickened. The skin becomes permanently roughened and pigmented. Patients typically describe a sore mouth, angular cheilitis, and indigestion. The tongue is bright red, with flattened papillae. The diarrhea is watery and may contain blood and pus. The encephalopathy of pellagra may mimic mental disease with depression and suicidal behavior predominating. Other signs of pellagra encephalopathy are anxiety, disorientation, hallucinations, confusion, delirium, dementia, and coma.

### DIAGNOSIS

The clinical features of this diagnosis are quite recognizable. However, because of its rare occurrence in the United States, clinicians may not be very familiar with



Facial lesions; Casál necklace; dementia

Pellagra tongue  
Angular cheilitis

Glove-and-stocking lesions

the signs and symptoms. When niacin deficiency is suspected, it can be confirmed by measuring the blood niacin concentration (reference ranges, 0.50–8.45  $\mu\text{g}/\text{mL}$  if older than 10 years; 0.50–8.91  $\mu\text{g}/\text{mL}$  if 10 years or younger).

### PREVENTION

The recommended daily dietary allowance for niacin is 16 niacin equivalents per day for men and 14 niacin

equivalents for women (18 niacin equivalents during pregnancy and 17 niacin equivalents daily during lactation). One niacin equivalent is 1 mg of niacin or 6 mg of tryptophan. Increased supplementation may be needed for those who have had a malabsorptive procedure to treat obesity (see Plate 7-27) or for individuals treated with renal dialysis. Balanced diets that include meat, yeasts, whole-grain cereals, legumes, and seeds provide sufficient niacin.



## VITAMIN C DEFICIENCY: SCURVY

Scurvy is a nutritional deficiency disorder resulting from a lack of vitamin C (ascorbic acid). Known since antiquity, during the fifteenth and sixteenth centuries scurvy became well recognized as an important disorder of seafaring men and was related to lack of fresh foods on prolonged journeys. In 1754, a British naval surgeon Dr. James Lind noted that consumption of oranges or lemons could prevent scurvy. Humans cannot synthesize ascorbic acid, and it is an essential dietary nutrient. Food sources high in ascorbic acid content include citrus fruits, tomatoes, potatoes, cabbage, spinach, Brussels sprouts, cauliflower, broccoli, and strawberries. Scurvy can occur as early as 3 months of being on an ascorbic acid-free diet.

Ascorbic acid is the enolic form of  $\alpha$ -ketolactone and functions as a cofactor and cosubstrate in providing reducing equivalents for a number of biochemical reactions involving iron and copper. Ascorbic acid provides electrons needed to reduce molecular oxygen. For example, ascorbic acid serves as an enzymatic cofactor for carnitine synthesis. Ascorbic acid is necessary for normal collagen synthesis, where it is a cofactor for the enzymatic hydroxylation of proline and lysine. Deficiency in this hydroxylation step results in impaired wound healing, defective tooth formation, and impaired osteoblast function. Ascorbic acid is also a cofactor for dopamine  $\beta$ -hydroxylase that converts dopamine to norepinephrine (see Plate 3-26). Absorbed in the jejunum and ileum (see Plate 7-18), blood levels of ascorbic acid are regulated by renal excretion.

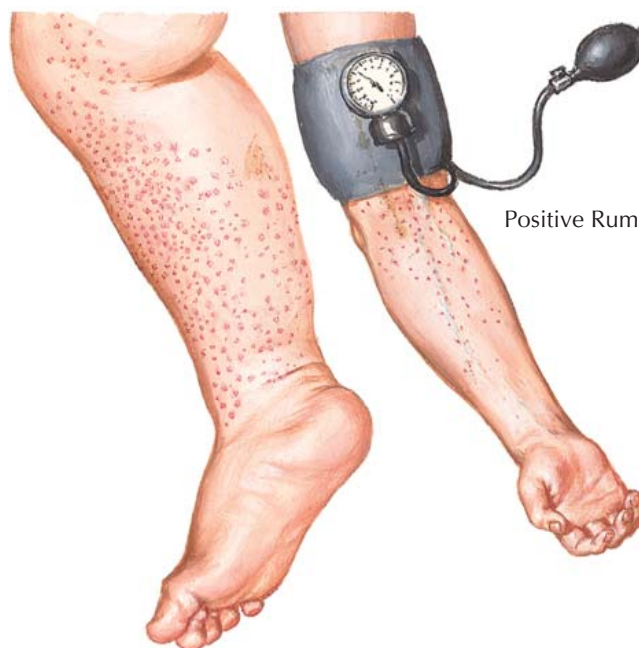Scurvy usually develops with an insidious onset of weakness, malaise, shortness of breath, bone pain, myalgias, arthralgias, edema, neuropathy, and vasomotor instability. Impaired collagen and connective tissue functions result in dry, rough skin with impaired wound healing, hyperkeratotic papules, perifollicular hemorrhages, and follicular hyperkeratosis (hair follicles may be coiled and fragmented). Petechial hemorrhages occur in the lower extremities initially and then may involve the skin around the joints or along other irritated areas. Affected patients have positive test results for the Rumpel-Leede test for abnormal capillary fragility; after inflating the blood pressure cuff between the systolic and diastolic blood pressure for 1 minute, numerous petechial hemorrhages occur. Massive hemorrhages with ecchymoses and proptosis caused by retrobulbar hemorrhage may occur. Hemorrhages into joints result in marked pain, swelling, and immobility. Subungual "splinter" hemorrhages may be seen. Gingival tissues may become swollen, reddish-blue in color, spongy, and friable, and teeth may loosen and fall out.

Subperiosteal hemorrhages in infants with scurvy prompt a less painful "frog leg" position, and infants may have "pseudoparalysis" caused by pain. Radiographs show large periosteal calcium deposits and central epiphyseal lucency. Also in infants, the costochondral junctions may be prominent, which is termed the *scorbutic rosary*. Affected children have impaired growth because of osteoblast dysfunction.

Death may occur in individuals with scurvy because of widespread cerebral petechial hemorrhages with associated hyperpyrexia, tachycardia, cyanosis, hypotension, and Cheyne-Stokes respirations.

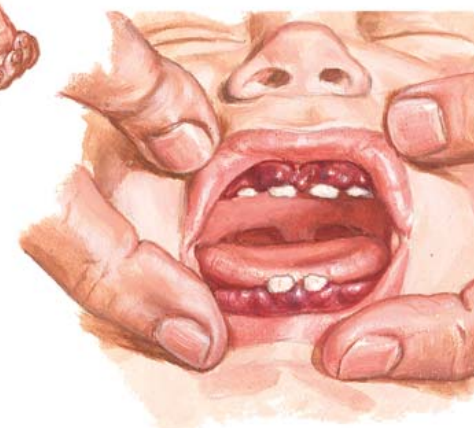### DIAGNOSIS

In the United States, scurvy may be seen in severely malnourished individuals. If vitamin C

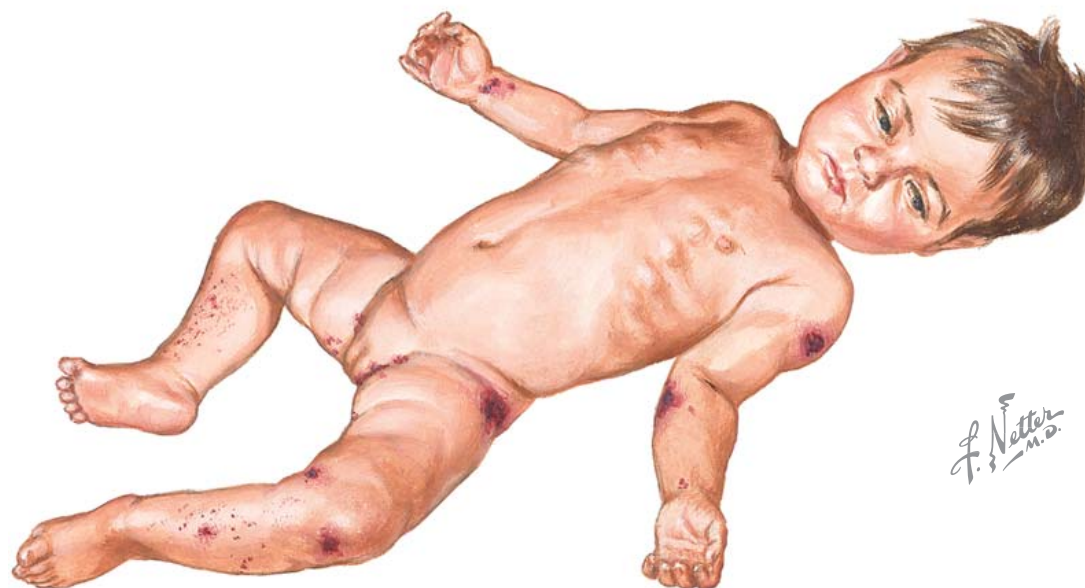

Positive Rumpel-Leede test result

Multiple perifollicular hemorrhages



Swollen, congested, bleeding gums



Typical "frog leg" position, scorbutic rosary, multiple ecchymoses

deficiency is suspected, a blood test for ascorbic acid may be performed (reference range, 0.6–2.0 mg/dL; values <0.3 mg/dL indicate significant deficiency).

### TREATMENT

Scurvy is treated by the administration of 500 mg daily of ascorbic acid until all signs and symptoms resolve. Also, the factors that predisposed to the dietary deficiency must be addressed.

### PREVENTION

The recommended daily dietary allowance of ascorbic acid is 90 mg daily for men and 75 mg daily for women (120 mg daily for pregnant or lactating women). These amounts of ascorbic acid are easily achieved with a balanced diet that includes citrus fruits and vegetables.





## CELIAC DISEASE AND MALABSORPTION

The signs and symptoms of celiac disease—also known as gluten-sensitive enteropathy and nontropical sprue—were first described by Aretaeus in the second century AD.

In the 1940s, it was recognized that the ingestion of foods that contained wheat, barley, and rye caused malabsorption, which resolved when these food sources were eliminated from the diet. Eventually, the source of this sensitivity was identified as the gliadin component of gluten. Celiac disease is a small bowel disorder associated with mucosal inflammation, villous atrophy, and crypt hyperplasia. The clinical presentations of celiac disease are those of malabsorption (e.g., steatorrhea, weight loss) and vitamin and nutrient deficiencies.

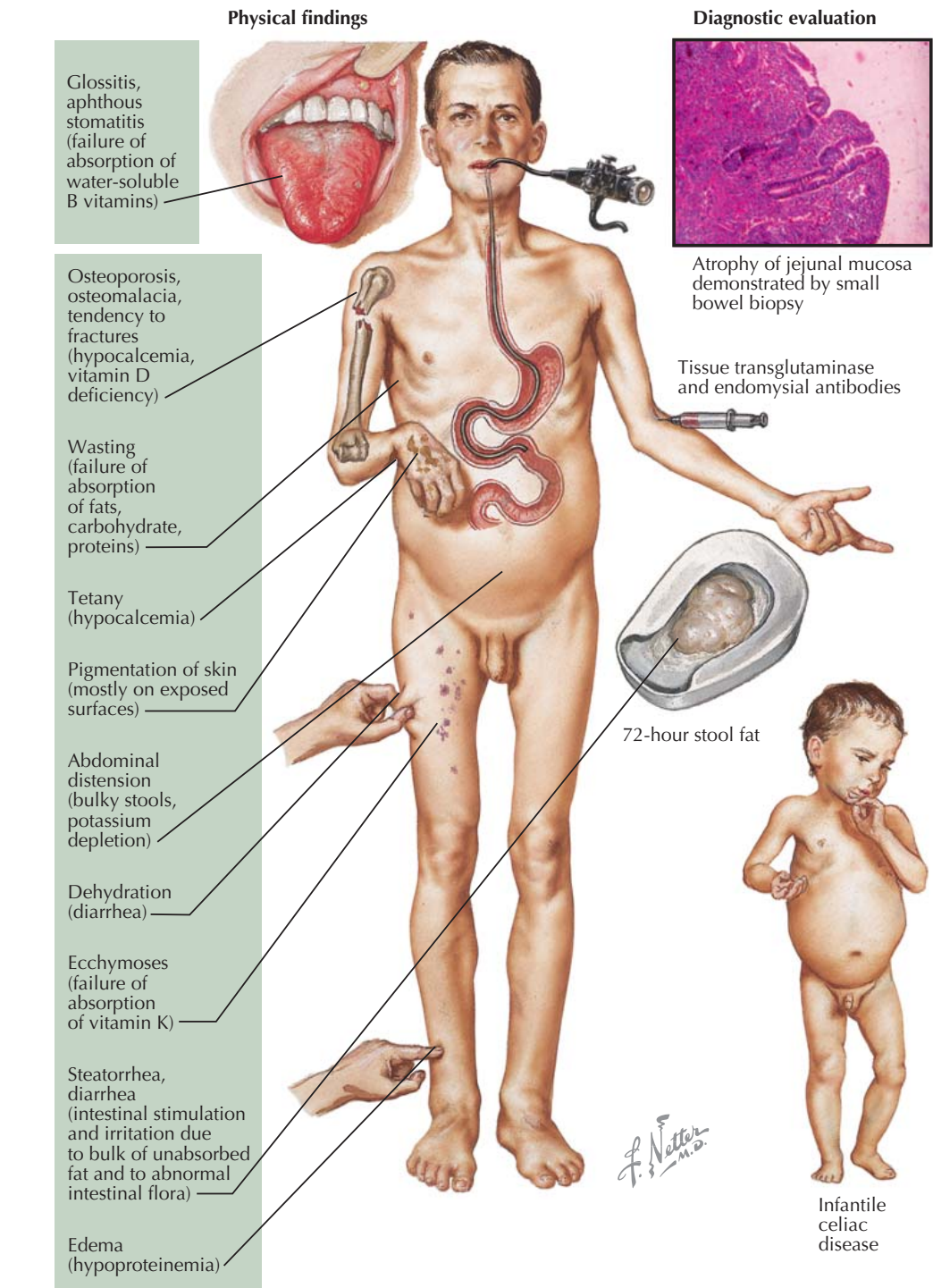
Celiac disease is relatively common with a prevalence of approximately one in 300 individuals. However, it is less common in individuals of Chinese, Japanese, or African descent. Celiac disease is a genetically determined immune disorder that becomes evident with the environmental exposure to gluten. The presence of immunoglobulin (Ig) IgA antibodies to endomysium (located in connective tissue surrounding smooth muscle cells) and to the autoantigen tissue transglutaminase are sensitive and specific for celiac disease. Tissue transglutaminase is an intracellular enzyme that is released by inflamed endothelial cells and fibroblasts. When released by small bowel enterocytes, tissue transglutaminase deamidates glutamine residues in gliadin to glutamic acid, creating a more immunogenic peptide.

The classic clinical presentation of celiac disease includes diarrhea with steatorrhea (foul-smelling, floating stools); abdominal pain; weight loss; growth failure in children; microcytic (iron deficiency) or macrocytic (vitamin B<sub>12</sub> deficiency) anemia; vitamin B deficiency signs and symptoms (e.g., glossitis, peripheral neuropathy, myalgias, weakness); ecchymoses (vitamin K malabsorption); dental enamel defects; edema; and osteopenia, osteoporosis, or osteomalacia associated with deficiencies in vitamin D and calcium. Mild forms of celiac disease may go undetected (subclinical) because of limited signs and symptoms.

Disorders associated with celiac disease include Down syndrome, dermatitis herpetiformis, type 1 diabetes mellitus, autoimmune thyroid disease, IgA deficiency, and liver disease. Dermatitis herpetiformis is caused by autoantibodies to epidermal transglutaminase, and patients present with pruritic papulovesicles on the trunk and extremities. Approximately 5% of individuals with type 1 diabetes and 16% of those with Down syndrome have celiac disease.

### DIAGNOSTIC EVALUATION

Celiac disease should be suspected when initial investigations are unrevealing in patients with gastrointestinal symptoms (e.g., diarrhea, malabsorption, abdominal distension, weight loss), abnormal liver function test results, iron-deficiency anemia, vitamin deficiencies, osteoporosis, osteomalacia, infertility, short stature, or delayed puberty. Testing should be completed while individuals are on a gluten-containing diet. An assessment of the presence and degree of steatorrhea can be determined with a 72-hour stool fat measurement. Excretion of more than 7 g of fat per 24 hours, when on a diet of 100 g to 150 g of fat, is suggestive of a malabsorption defect. The evaluation for possible celiac



disease should start with serologic testing for the presence of IgA tissue transglutaminase antibody and IgA endomysial antibody. If the antibody test results are negative, it is extremely unlikely that celiac disease is present. When the clinical suspicion for celiac disease is high but the IgA tissue transglutaminase and endomysial antibodies are absent, IgA deficiency should be considered. In the setting of IgA deficiency, the IgG-anti-tissue transglutaminase test should be obtained. If the IgA or IgG tissue transglutaminase or IgA endomysial antibody test results are positive, then a small bowel biopsy is indicated for histopathologic confirmation. Findings are small bowel biopsy that are consistent with celiac disease include increased intraepithelial lymphocytes, flat mucosa with mucosal atrophy, complete loss of villi, and crypt hyperplasia.

### TREATMENT

The small intestine mucosa improves morphologically when individuals with celiac disease are treated with a gluten-free diet. Thus, the treatment of choice is a lifelong gluten-free diet. The primary sources of gluten are wheat, rye, and barley. Individuals should be counseled by a dietitian and must carefully read labels on prepared foods to determine if gluten is present. In addition, any identified nutritional deficiencies (e.g., vitamin D and other fat-soluble vitamins, water-soluble vitamins, calcium, and iron) should be addressed. Most patients have symptomatic improvement in their malabsorption symptoms within 2 weeks of initiating a gluten-free diet. The most common reason for lack of symptomatic response is lack of compliance with a true gluten-free diet.



## LYSOSOMAL STORAGE DISORDERS: SPHINGOLIPIDOSES

Lysosomes are membrane-bound, cytoplasmic organelles that contain enzymes responsible for the degradation of sphingolipids, mucopolysaccharides, and glycoproteins. Lysosomal enzyme deficiencies lead to the accumulation of partially degraded substrate, cell distension, and disruption of cellular function. The clinical presentation of lysosomal storage disorders depends on the site(s) and extent of abnormal substrate accumulation. The general categories of lysosomal storage disorders include the following:

### Sphingolipidoses

Mucopolysaccharidoses (e.g., Hurler syndrome)

Glycoproteinoses (e.g., sialidosis mannosidosis)

Mucolipidoses (disorders of lysosomal enzyme transport)

Lysosomal membrane transport disorders (e.g., sialic acid storage disease, cystinosis)

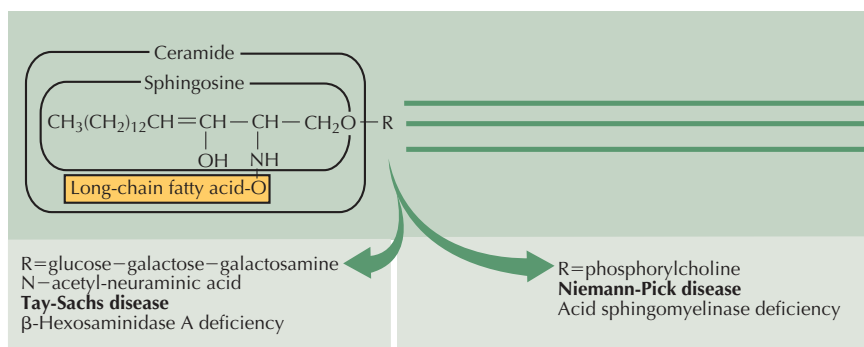
The heritable disorders characterized by the accumulation of sphingolipids include Tay-Sachs disease, Niemann-Pick disease, Gaucher disease, metachromatic leukodystrophy, Fabry disease, GM1 gangliosidosis, Krabbe disease, and multiple sulfatase deficiency. Sphingolipids contain sphingosine, an 18-carbon amino alcohol synthesized in the body from palmitic acid and serine. A long-chain fatty acid is bound in peptide linkage to the amide group of sphingosine to form ceramide. The sphingolipids are distinguished by the polar group linked to the C-1 hydroxyl of their ceramide moiety (R). Some are concentrated in nervous tissue, either in ganglion cells (gangliosides) or in myelin (cerebrosides, cerebroside sulfatides); others are distributed more widely in cell membranes (globosides, various glycolipids). Sphingomyelin, the phosphorylcholine ester of ceramide, is found in almost every cell type.

### TAY-SACHS DISEASE

Tay-Sachs disease (gangliosidosis), characterized by the accumulation of excessive amounts of gangliosides, is caused by a deficiency in the lysosomal enzyme  $\beta$ -hexosaminidase A (Hex A). This is an inherited autosomal recessive disease with a carrier frequency of one in 25 in the Ashkenazi Jewish population, resulting in a disease incidence of one in 3600 in this ethnic group (compared with one in 360,000 in the non-Jewish population). It is usually detected by 6 months of age, with progressive neurologic deficits such as hypotonia, hyperreflexia, weakness, spasticity, seizures, blindness, and loss of motor function). Destructive swelling of ganglion cells and gliosis are so widespread that the cranium becomes abnormally enlarged. Cherry-red spots may be seen on the macula. Tay-Sachs is a progressive disease with a life expectancy of 2 to 5 years. Testing includes DNA mutation analysis and enzyme assays to measure leukocyte Hex A activity.

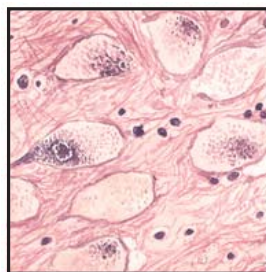
### NIEMANN-PICK DISEASE

Niemann-Pick disease (NPD; sphingomyelin-cholesterol lipidosis) is a rare autosomal recessive disorder that results in lysosomal accumulation of sphingomyelin. NPD has three clinical forms. NPD disease types A and B are caused by mutations in the gene encoding sphingomyelin phosphodiesterase-1 that result in a deficiency of acid sphingomyelinase activity. NPD type A, because of a complete absence of acid

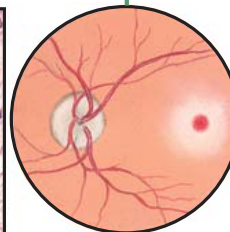


R=glucose-galactose-galactosamine  
N-acetyl-neuraminic acid  
**Tay-Sachs disease**  
 $\beta$ -Hexosaminidase A deficiency

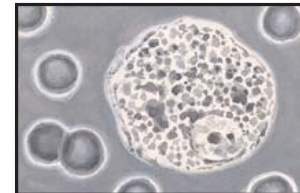
R=phosphorylcholine  
**Niemann-Pick disease**  
Acid sphingomyelinase deficiency



Ganglion cells of brain swollen; nuclei displaced or disintegrated; Nissl substance lost



Cherry-red spot in macula found in both Tay-Sachs disease and Niemann-Pick disease



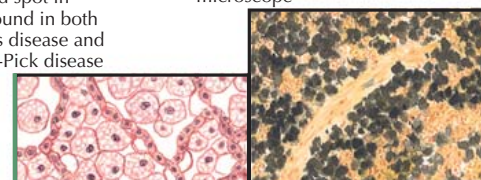
Foam cell in bone marrow aspirate: supravital preparation under phase microscope

Enlargement of head (advanced stage)

**Progressive neurologic deficits:**

- ▶ Hypotonia
- ▶ Hyperreflexia
- ▶ Weakness
- ▶ Spasticity
- ▶ Seizures
- ▶ Blindness
- ▶ Loss of motor function

No enlargement of liver or spleen



Phospholipids in spleen; Smith-Ditrich stain

Foam cells clogging lung

Delayed cognitive and skeletal maturation

**Niemann-Pick disease type A:** Hepatosplenomegaly is usually evident by 3 months of age; large lipid-laden foam cells found in most tissues; respiratory failure and neurologic dysfunction lead to death by age 2 or 3 years

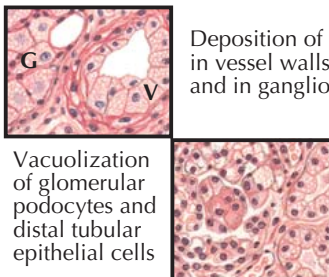
sphingomyelinase activity, is an early-onset neuropathic form that presents with hepatosplenomegaly (evident at 3 months of age), respiratory failure, and neurologic dysfunction that leads to death by age 2 or 3 years. Macular cherry-red spots are found in most patients by 1 year of age. Large lipid-laden foam cells are found in most tissues. NPD type B is characterized by a partial deficiency in acid sphingomyelinase (5% of normal) and has a later onset than NPD type A. Hepatosplenomegaly and secondary thrombocytopenia are evident in early childhood. Most affected children have delayed skeletal maturation, short stature, interstitial lung involvement, and macular cherry-red spots. However, neurologic abnormalities are absent or delayed in onset in NPD type B. NPD types A and B can be detected by biochemical testing for acid sphingomyelinase activity and confirmed with molecular genetic testing.

NPD type C is caused by mutations in either the *NPC1* or *NPC2* gene and may become clinically evident at any age with cerebellar signs (e.g., ataxia), impaired

vertical gaze, cognitive dysfunction, dysphagia, and hepatosplenomegaly. *NPC1* and *NPC2* encode proteins that have key roles in intracellular cholesterol transport, and when defective, lipid accumulation and neuronal degeneration occur. NPD type C can be detected with biochemical tests on cultured fibroblasts and confirmed with molecular genetic testing.

### GAUCHER DISEASE

Gaucher disease (GD; glucocerebrosidosis) is caused by a deficiency in glucocerebrosidase due to autosomal recessive mutations in the gene encoding this protein. Glucocerebrosides accumulate in macrophages (Gaucher cells with a wrinkled tissue paper appearance) throughout the liver, spleen, bone marrow, and lungs. The cerebroside in visceral tissues is ceramide-glucose instead of the normal ceramide-galactose. GD is the most common lysosomal storage disorder (one in 75,000 births). There are three clinical types of GD.

|   |   |  |
|---|---|--|
| <p>R=glucose<br/><b>Gaucher disease</b><br/>Glucocerebrosidase deficiency</p>   | <p>R=hexose-sulfatide<br/><b>Metachromatic leukodystrophy</b><br/>Arylsulfatase A deficiency</p>  | <p>R=glucose-galactose-galactose and galactose-galactose<br/><b>Fabry disease</b><br/><math>\alpha</math>-Galactosidase A deficiency</p>   |
| <p>Type 1 form in adult</p> <ul style="list-style-type: none"> <li>Normal cognitive function</li> <li>Pingueculae in eyes</li> <li>Marked enlargement and cirrhosis of liver</li> <li>Splenomegaly             <ul style="list-style-type: none"> <li>Anemia</li> <li>Thrombocytopenia</li> <li>Leukopenia</li> </ul> </li> <li>Bone lesions: Dislocation of hip, Fracture, "Erlenmeyer flask" deformity</li> <li>Pigmentation</li> </ul> <p>Gaucher cell in bone marrow biopsy: Supravital preparation under phase microscope appears in <u>both</u> forms of disease</p> <p>Type 2 form (acute neuronopathic) in a child: Evident in the first year of life; signs and symptoms of rapid neurologic deterioration</p> <ul style="list-style-type: none"> <li>Marked enlargement of liver, spleen, and lymph nodes</li> <li>Retroflexion of head</li> <li>Laryngospasm</li> <li>Lung infiltration</li> </ul> | <p>Accumulation of PAS-staining granular material in brain: myelin degeneration</p> <p>Metachromatic substance in liver, spleen, and kidney without organ enlargement</p> <p>Fibrosis of gallbladder</p> <p>Severe neurologic involvement</p> <p>Spastic or flaccid paralysis, hypotonia</p> <p>Urine Acetic acid Toluidine blue</p> <p>Filter paper</p> <p>Normal Metachromatic leukodystrophy</p> | <p>Cerebrovascular disease</p> <p>Corneal opacities, engorged retinal veins</p> <p>Anhidrosis</p> <p>Cardiac and renal involvement</p> <p>Punctate maculopapular skin eruption</p> <p>Paresthesias, distal arthropathy</p> <p>Perineural infiltration</p> <p>Paresthesias, frequent edema of extremities</p> <p>Deposition of lipid in vessel walls (V) and in ganglion cells (G)</p> <p>Vacuolization of glomerular podocytes and distal tubular epithelial cells</p>  |

**LYSOSOMAL STORAGE DISORDERS: SPHINGOLIPIDOSES**  
(Continued)

Type 1 GD—the chronic adult form—is most common and accounts for 90% of cases, with an increased prevalence in the Ashkenazi Jewish population. The clinical presentation is variable and clinically evident anywhere from 1 year of age to adulthood. The presentation of GD type 1 is dominated by visceral involvement (e.g., massive splenomegaly, hepatomegaly), bone disease (e.g., osteoporosis, avascular necrosis, bone pain), and bleeding caused by thrombocytopenia. Abnormal bone remodeling of the metaphysis results in an Erlenmeyer flask deformity of the distal femur. Pingueculae (single yellow nodules that may occur on either side of the cornea but more commonly on the nasal aspect) are found frequently on the conjunctiva. GD types 2 and 3 are associated with neurologic involvement in addition to visceral involvement. Type 2 GD (acute neuronopathic) is the rarest form and is usually fatal by age 2 years. Type 2 GD becomes evident in the first year of life with signs and symptoms of rapid neurologic deterioration such as oculomotor

dysfunction, hypertonia, arching, retroflexion of the head, rigidity, laryngospasm, and seizures. Type 3 GD (chronic neuronopathic) is later in onset and is not as severe as type 2 GD. Testing includes DNA mutation analysis and enzyme assays to measure leukocyte glucocerebrosidase activity.

**METACHROMATIC LEUKODYSTROPHY**

Metachromatic leukodystrophy (MLD; sulfatidosis) is caused by a deficiency in arylsulfatase A due to autosomal recessive mutations in the gene encoding this enzyme. Because of defective desulfation, cerebroside sulfate accumulates in the central nervous system and peripheral nerves, leading to central and peripheral demyelination. MLD may present at different ages. The late infantile form presents between age 6 months and 2 years with ataxia, hypotonia, regression of motor skills, and optic atrophy. There are also juvenile and adult onset forms of MLD. Visceral involvement is not prominent, but excess sulfatides are found in the liver, kidney, and spleen. Biliary excretion of sulfatides results in fibrosis and gallbladder dysfunction. Electromyography shows decreased nerve conduction velocities, and cerebrospinal fluid examination shows increased protein

concentration. Testing includes enzyme assays to measure arylsulfatase A activity in leukocytes. Similar to other acidic polysaccharides, certain dyes may be used to detect the sulfatides by the metachromasia they produce.

**FABRY DISEASE**

Fabry disease, caused by a deficiency in  $\alpha$ -galactosidase A, is the second most common lysosomal storage disorder. The gene that encodes  $\alpha$ -galactosidase A is located on the X chromosome, and the disease is inherited in an X-linked recessive manner.  $\alpha$ -Galactosidase A cleaves the terminal galactose from globotriaosylceramide (Gb3). In individuals with Fabry disease, Gb3 accumulates in the vascular endothelium, glomeruli, and distal renal tubules. Clinical manifestations typically start in the second decade of life and include neuropathic pain in the extremities; diffuse angiokeratomas located primarily in the periumbilical, groin, and hip regions; corneal opacities (cornea verticillata); anhidrosis; coronary artery disease; cerebrovascular disease; peripheral vascular disease; proteinuria; edema; and renal failure. The diagnosis can be confirmed by documenting low leukocyte  $\alpha$ -galactosidase A activity. Molecular genetic testing is also available.



## ANOREXIA NERVOSA

The diagnosis of anorexia nervosa includes four criteria: (1) refusal to maintain weight within a normal range for height and age (i.e., >15% below ideal body weight, which equates to a body mass index of approximately  $\leq 18.5 \text{ kg/m}^2$ ); (2) fear of weight gain; (3) severe body image disturbance with the body image becoming a predominant measure of self-worth; and (4) amenorrhea in women. Although rare in men, the lifetime prevalence of anorexia nervosa among women is 1%. "Restricting" anorexia nervosa occurs when weight loss is maintained primarily by caloric restriction and exercise. "Binge eating/purging" anorexia nervosa is characterized by binge eating and self-induced vomiting (usually supplemented by laxative and diuretic abuse).

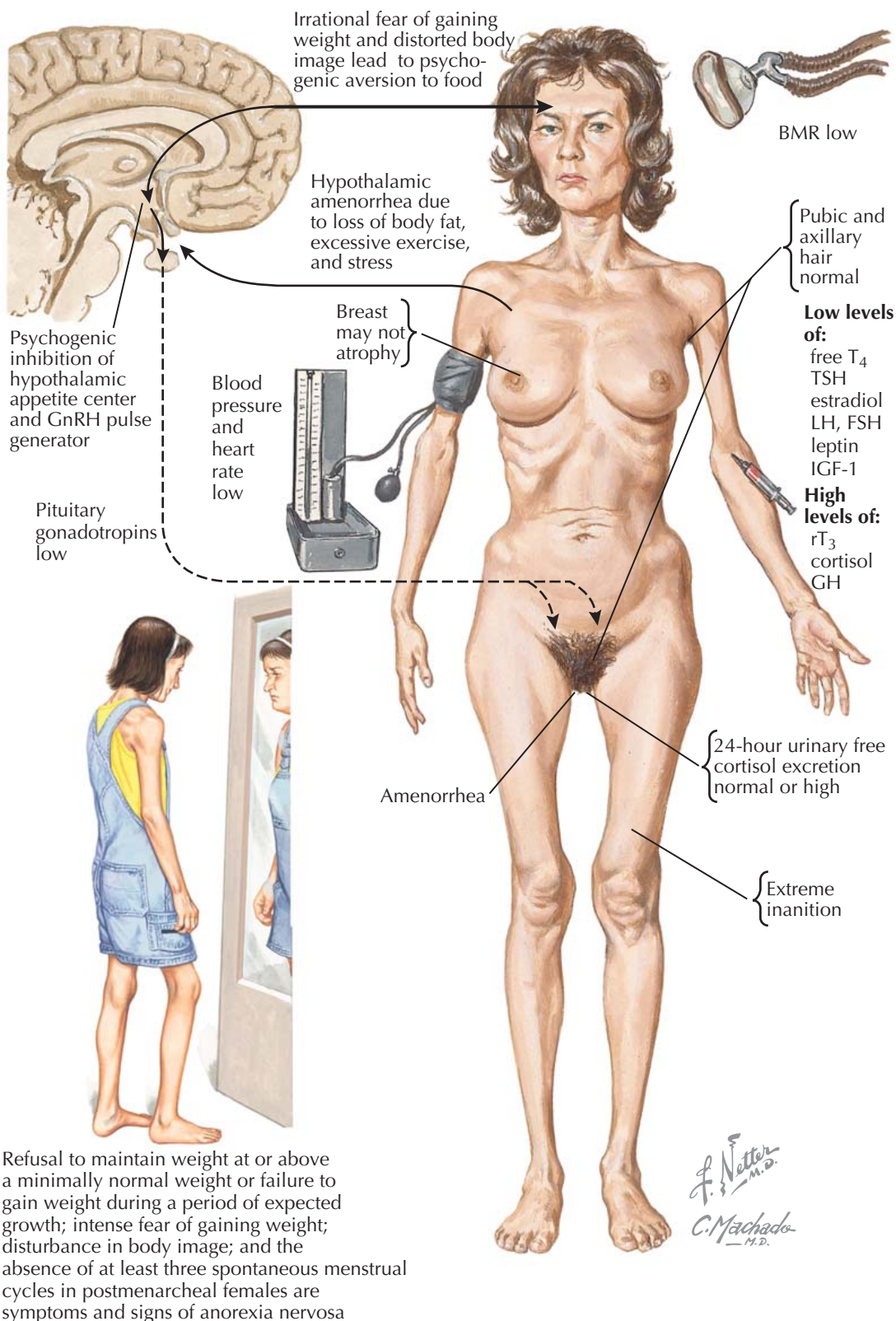
Although the cause is unknown, anorexia nervosa is associated with cultural, biologic, and psychologic risk factors. In general, individuals who develop anorexia nervosa are perfectionists. Although the concordance is higher in monozygotic twins than in dizygotic twins, specific genes that contribute to anorexia nervosa have not been identified. Most of the neurochemical, metabolic, and hormonal changes seen in individuals with anorexia nervosa are a result of weight loss and are not a cause of the disorder.

The signs and symptoms of anorexia nervosa usually begin in middle to late adolescence; the disorder rarely develops after age 40 years. The onset of anorexia nervosa may be triggered by a stressful life event. Individuals with anorexia nervosa, despite being underweight, are irrationally afraid of gaining weight. In addition, they have a distorted body image and think they are "too fat." Weight loss provides a sense of accomplishment, and weight gain a sense of failure. Affected individuals tend to become socially withdrawn and focus on dieting, exercise, and work or study.

Individuals with anorexia nervosa usually have very few physical complaints. They may have cold intolerance and constipation. On physical examination, they may be hypothermic, hypotensive, and bradycardic. Lanugo hair may be evident on the cheeks of women. Enlargement of the salivary glands is common and associated with starvation and then binge eating and emesis. A diet of predominantly yellow and orange vegetables, which have a high  $\beta$ -carotene content, results in a yellow tint to the skin, especially evident on the palms.

Typical laboratory findings include normochromic normocytic anemia, mild leukopenia, increased serum creatinine concentration caused by dehydration, increased hepatic enzymes, low-normal fasting plasma glucose concentration, and moderately increased total serum cholesterol concentration. Recurrent emesis or diuretic abuse may result in hypokalemic alkalosis. Other causes of weight loss should be excluded (e.g., human immunodeficiency virus, inflammatory bowel disease, diabetes mellitus, or central nervous system neoplasm).

The severe weight loss in individuals with anorexia nervosa affects most of the endocrine glands. Hypothalamic amenorrhea—with low serum concentrations of luteinizing hormone (LH), follicle-stimulating hormone (FSH), and estradiol—is a key component of the diagnosis in women. The hypothalamic gonadotropin-releasing



Refusal to maintain weight at or above a minimally normal weight or failure to gain weight during a period of expected growth; intense fear of gaining weight; disturbance in body image; and the absence of at least three spontaneous menstrual cycles in postmenarcheal females are symptoms and signs of anorexia nervosa

hormone (GnRH) pulse generator is very sensitive to loss of body fat, excessive exercise, and stress. Adequate circulating leptin is a key factor for normal function of the GnRH pulse generator. Serum leptin concentrations are low because of the decreased fat mass. Serum cortisol concentrations and 24-hour urinary free cortisol excretion are increased, but patients with anorexia nervosa lack signs and symptoms of Cushing syndrome. Thyroid hormone test results are consistent with euthyroid sick

syndrome, with low levels of free thyroxine ( $T_4$ ), low levels of triiodothyronine ( $T_3$ ), increased levels of reverse  $T_3$  ( $rT_3$ ), low normal or suppressed thyrotropin (thyroid-stimulating hormone [TSH]), and low basal metabolic rate (BMR). The serum growth hormone (GH) concentration is usually increased, but insulinlike growth factor 1 (IGF-1) levels are low. Bone mineral density is low and related to nutritional deficiencies in vitamin D and calcium and to decreased gonadal steroids.

## OBESITY

Obesity is a global epidemic, and its prevalence is increasing in children, adolescents, and adults. More than 66% of adults in the United States are overweight or obese. The increased morbidity and mortality in individuals who are obese is a result of the increased prevalence of diabetes mellitus, hypertension, coronary heart disease (CHD), hyperlipidemia, obstructive sleep apnea, and cancer.

The diagnosis of obesity includes measurement of body mass index (BMI), waist circumference, and hip circumference. BMI is calculated by dividing body weight in kilograms by height in meters squared. BMI correlates with body fat mass; however, BMI may overestimate fat mass in individuals who are very muscular (e.g., professional athletes). BMI-based categories of body weight are:

Underweight: BMI <18.5 kg/m<sup>2</sup>

Normal weight: BMI ≥18.5–24.9 kg/m<sup>2</sup>

Overweight: BMI ≥25.0–29.9 kg/m<sup>2</sup>

Class I obesity (obese): BMI ≥30.0–34.9 kg/m<sup>2</sup>

Class II obesity (moderately obese): BMI ≥35.0–39.9 kg/m<sup>2</sup>

Class III obesity (severely obese): BMI ≥40.0–49.9 kg/m<sup>2</sup>

Class IV obesity (super morbidly obese): BMI ≥50 kg/m<sup>2</sup>

For Asians, a BMI between 23.0 and 29.9 kg/m<sup>2</sup> is considered overweight, and a BMI of 30 kg/m<sup>2</sup> or above is consistent with obesity.

Because excess centrally distributed fat mass is uniquely associated with increased morbidity and mortality (associated with CHD, diabetes mellitus, hyperlipidemia, and hypertension), waist circumference measurement is helpful in guiding clinical decision making. The waist circumference should be measured on a horizontal plane at the level of the iliac crest, which is usually in line with the umbilicus. Waist circumferences greater than 88 cm for women and 102 cm for men are associated with an increased risk of CHD, hyperlipidemia, type 2 diabetes mellitus, and hypertension. Waist circumferences more than 80 cm in Asian women and more than 90 cm in Asian men are consistent with abdominal obesity. Waist/hip ratios more than 0.9 in men or more than 0.85 in women are also consistent with abdominal obesity.

## EVALUATION

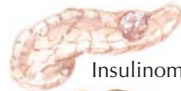Obesity is usually the result of increased caloric intake and a sedentary lifestyle. A complete history and physical examination should be performed to exclude secondary causes of obesity. Key pieces of the history include age at onset of weight gain, body weight at different life stages, current and past dietary patterns, exercise habits, details on previous weight loss efforts, current and past medications, patient motivation to lose weight, and history of smoking cessation. Patients should be queried on symptoms of obstructive sleep apnea (loud snoring, apneic episodes while sleeping, feeling not rested on waking in the morning, or daytime hypersomnolence), the presence of cardiovascular risk factors, and the presence of obesity-related comorbidities (e.g., degenerative joint disease). Medications that can contribute to weight gain include corticosteroids, antipsychotics, antidepressants, antiepileptics, thiazolidinediones, and insulin. Very rarely, a patient with new-onset obesity will have a medical disorder that is responsible (e.g., Cushing syndrome, hypothalamic



High caloric intake



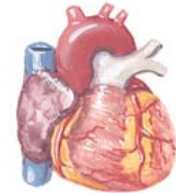Hypertrophy or hyperplasia of adipocytes



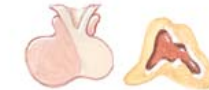Insulinoma



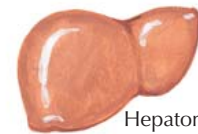
Hypothalamic disorders



Cardiomegaly



Cushing's syndrome



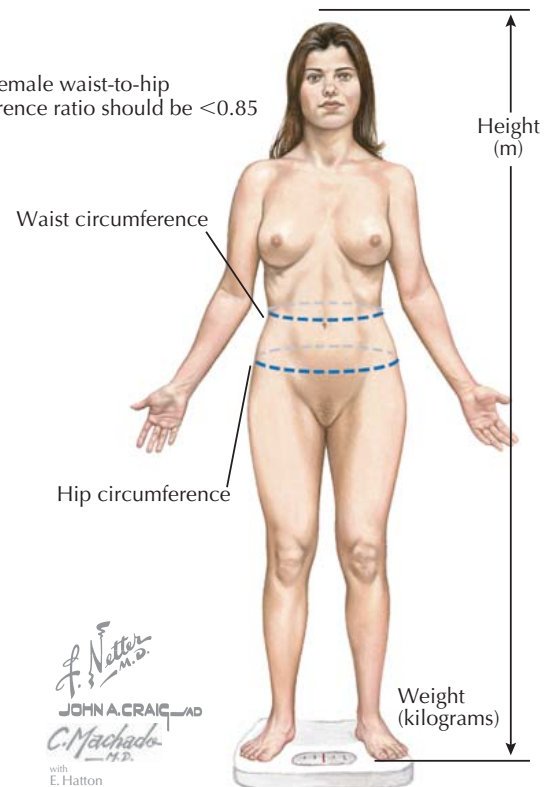
Hepatomegaly



Corticosteroids

Cardiomegaly and hepatomegaly (fatty liver) are common in obesity

Normal female waist-to-hip circumference ratio should be <0.85



disease, or hypothyroidism). The physical examination should include blood pressure measurement, waist circumference, and an assessment of potential secondary forms of obesity. Laboratory studies should include fasting plasma glucose levels and a lipid profile. Testing (e.g., overnight oximetry) for obstructive sleep apnea is indicated in obese patients suspected to have this disorder.

## TREATMENT

Weight loss is associated with a decrease in obesity-associated morbidity. Thus, the goal of treatment is to improve current obesity-related comorbid conditions and to decrease the risk of developing additional comorbidities in the future. Treatment options include

dietary interventions, lifestyle modification, pharmacotherapy, and surgery (see Plate 7-26). A reasonable initial weight loss target is 10% weight loss over 6 months. The main focus of the diet is to reduce overall caloric intake, a goal that can be achieved by choosing meals with smaller portions, increasing the proportion of fruits and vegetables, decreasing dietary fats (20%–30% of daily calories), increasing dietary fiber, and drinking water instead of calorie-containing beverages. Regular (30 min/d) isotonic exercise is key to maintaining weight loss. Monitoring daily activity with a pedometer can be a useful technique. Cognitive behavioral therapy strategies (journaling, exercise monitoring, stress management, problem solving, stimulus control, cognitive restructuring) should be used to help reinforce the modified dietary and physical activity plans.

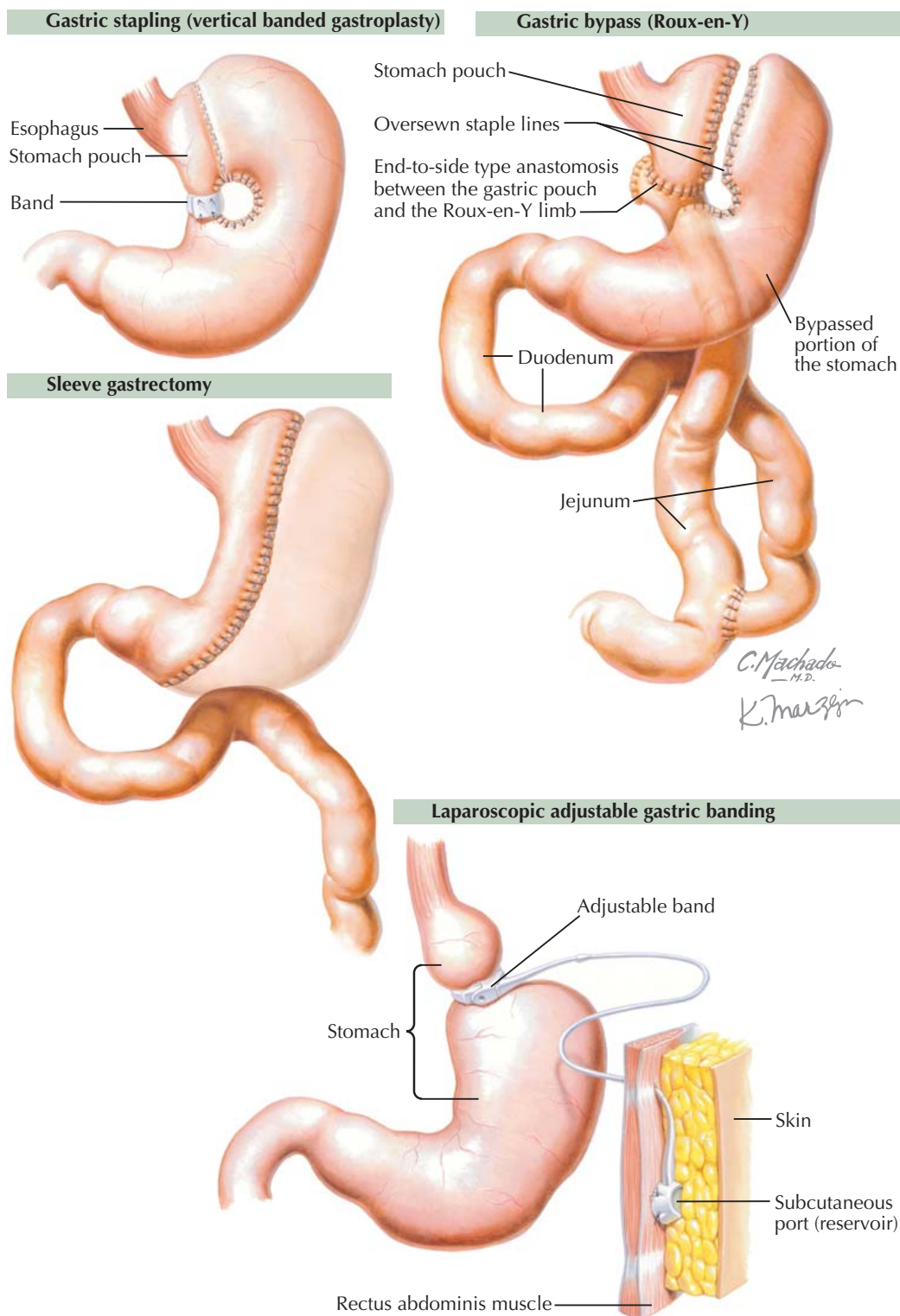


## SURGICAL TREATMENT OPTIONS FOR OBESITY

Surgical treatment for obesity can be considered for patients with class IV obesity (super morbidly obese; body mass index [BMI]  $\geq 50$  kg/m<sup>2</sup>), class III obesity (severely obese; BMI  $\geq 40$ –49.9 kg/m<sup>2</sup>), or class II obesity (moderately obese; BMI  $\geq 35.0$ –39.9 kg/m<sup>2</sup>) who have serious obesity-related medical conditions. Bariatric surgery is the most effective currently available treatment option for patients with clinically severe obesity; an average weight loss of 30% to 35% of total body weight is maintained in 60% of patients at 5 years after surgery. This degree of weight loss improves quality of life and cures or improves obesity-related comorbidities (diabetes mellitus, obstructive sleep apnea, hypertension, hyperlipidemia, fatty liver). Evidence supporting a benefit from bariatric surgery is strongest in patients with a BMI more than 40 kg/m<sup>2</sup>. Contraindications for bariatric surgery include patients with binge eating disorders, drug or alcohol abuse, major depression or psychosis, other medical diagnoses associated with prohibitive anesthetic risks, or predicted inability to comply with postoperative nutritional requirements. Bariatric surgery needs to be a component of a larger management program that includes nutritional and behavioral followup. The surgical options can be classified as restrictive and combined restrictive-malabsorptive.

Restrictive surgical options limit the amount of food that can occupy the stomach and slow the rate of gastric emptying. With restrictive procedures, the absorptive function of the small intestine is intact. Gastric stapling (vertical banded gastroplasty) is an example of a restrictive surgical procedure in which the upper part of the stomach is partitioned by a vertical staple line with a tight outlet (stoma) that is wrapped by a band or prosthetic mesh. However, because of limited long-term efficacy and need for revisions (because of stomal stenosis, staple line disruption, band erosion, or pouch dilatation), the gastric stapling procedure has been replaced with laparoscopic adjustable gastric banding. A silicone band is placed at the gastric cardia near the gastroesophageal junction to limit food intake. The diameter of the band can be adjusted by injecting or removing saline from a reservoir that is implanted under the skin. Laparoscopic gastric banding has a low complication rate and does not require intestinal resection or division of the stomach. Sleeve gastrectomy consists of laparoscopic partial gastrectomy with removal of the greater curvature of the stomach (creating a tubular stomach with a small capacity and resistance to stretching). Sleeve gastrectomy appears to have an advantage over other restrictive procedures because of better appetite control related to removing the major source of ghrelin.

Restrictive-malabsorptive procedures decrease the efficacy of nutrient absorption by shortening the length of functioning small intestine. Mean weight loss is greater after a combined restrictive-malabsorptive procedure compared with a restrictive bariatric surgical procedure. The most common restrictive-malabsorptive procedure is the Roux-en-Y gastric bypass (RYGB) in which a small gastric pouch (e.g., <30 mL) limits oral intake, and the small bowel modification leads to dumping physiology and mild malabsorption. There is a proximal biliopancreatic limb that transports the secretions from the pancreas, liver, and gastric remnant. The alimentary limb (Roux limb) is anastomosed to the gastric pouch. The biliopancreatic limb and Roux limb are connected anywhere from 75 to 150 cm distal to the



gastrojejunostomy (increasing Roux limb length leads to more malabsorption). RYGB can be performed either with an open laparotomy or laparoscopically; the laparoscopic approach is associated with decreased postoperative pain and shorter hospital stays. The two other procedures in the restrictive-malabsorptive category are the biliopancreatic diversion and biliopancreatic diversion with duodenal switch. Biliopancreatic diversion includes a partial gastrectomy and gastroileostomy with a long segment of Roux limb. Biliopancreatic diversion is associated with high rates of stomal ulceration, anemia, protein malnutrition, and diarrhea.

The biliopancreatic diversion with duodenal switch differs by preserving the pylorus, resulting in fewer complications with stomal ulceration and diarrhea.

The bariatric surgery-related mortality rate is less than 1%. The most common complications are stenosis of the stoma and marginal ulcers in approximately 15% of patients; these patients present with nausea, vomiting, and an inability to tolerate solid foods. The combined restrictive-malabsorptive procedures are associated with an increased risk of deficiencies in micronutrients and vitamins (iron; calcium; folate; and vitamins B<sub>12</sub>, D, and E).

# **GENETICS AND ENDOCRINE NEOPLASIA**



This page intentionally left blank

## MULTIPLE ENDOCRINE NEOPLASIA TYPE 1

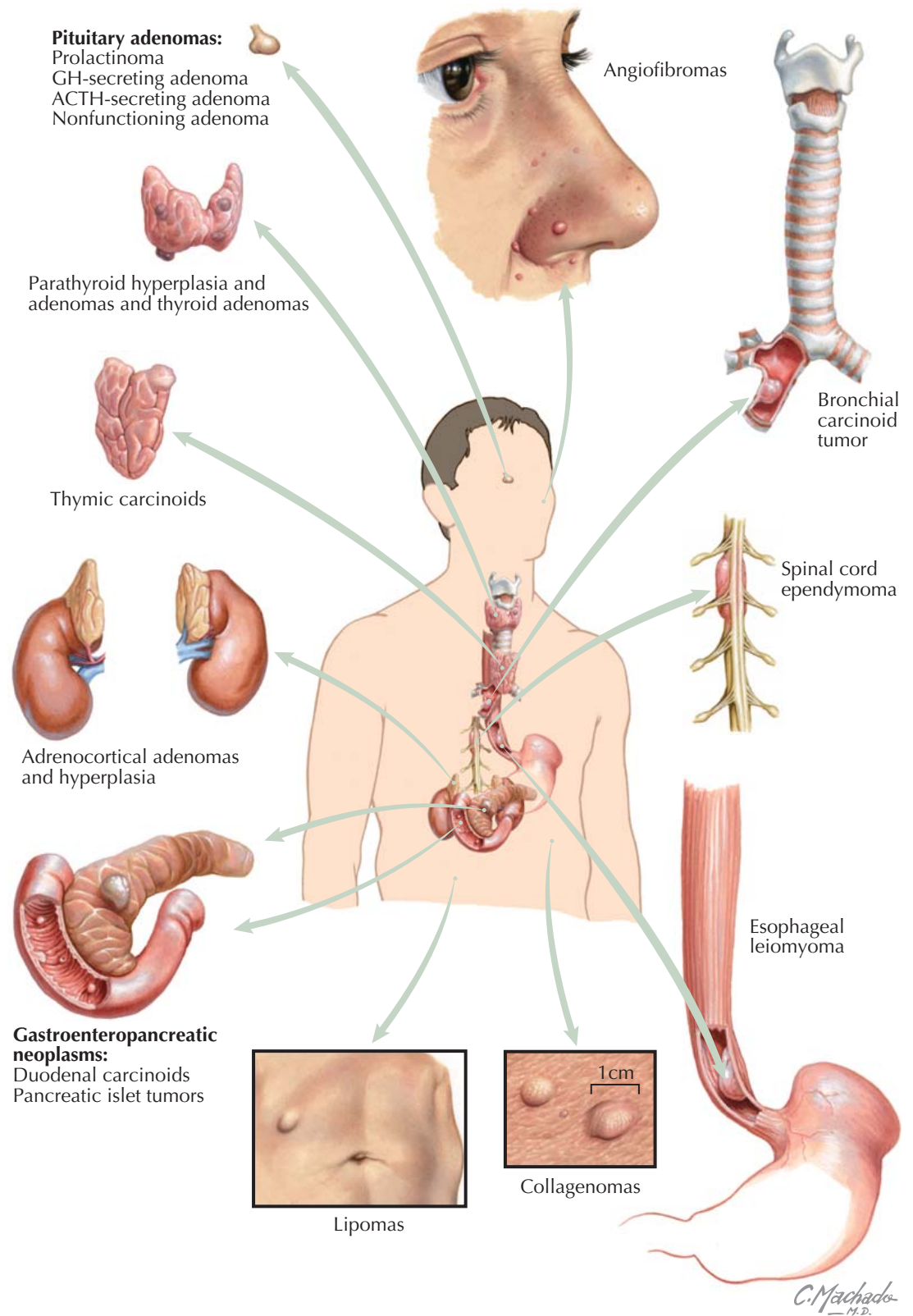
Multiple endocrine neoplasia type 1 (MEN 1) is a rare (prevalence ~two per 100,000) autosomal dominant endocrine disorder that is characterized by neoplasms of the pituitary, parathyroid, and pancreas. In addition, neoplasms may arise in the adrenal glands, duodenum (gastrinoma), lung (carcinoid tumor), thymus gland (carcinoid tumor), and esophagus (leiomyoma). An *MEN1* mutation is highly probable in a patient with two of the three main MEN 1 tumor types (pituitary, parathyroid, or gastroenteropancreatic [GEP] endocrine neoplasms).

Primary hyperparathyroidism is the most common manifestation of MEN 1; the penetrance is 100% by age 50 years. The diagnosis is biochemical with documentation of hypercalcemia and a nonsuppressed serum parathyroid hormone (PTH) concentration. All four (or occasionally five) of the parathyroid glands are involved, and removing 3.5 of the parathyroid glands is the treatment of choice. Recurrent hypercalcemia may require reoperation or percutaneous ethanol injection.

Pituitary adenomas are found in 20% of patients with MEN 1. Prolactinomas are the most common pituitary tumor. However, all pituitary tumor cell types have been identified in MEN 1 kindreds, including growth hormone (GH), corticotropin (adrenocorticotropic hormone [ACTH]), gonadotropin, and null cell. The management of pituitary tumors in patients with MEN 1 is the same as that for patients with sporadic pituitary neoplasms (see Plates 1-19 to 1-24).

The GEP neoplasms are the major life-threatening manifestation of MEN 1. Pancreatic islet cell (often nonfunctioning) and duodenal carcinoid tumors are frequently malignant and may metastasize. Peptic ulcer disease is the most common symptomatic presentation related to GEP tumors and is caused by gastrin-secreting neoplasms (Zollinger-Ellison syndrome). Zollinger-Ellison syndrome is the initial manifestation of MEN 1 in 40% of patients. The gastrinomas are frequently small, multifocal, and localized to the duodenum. The hypercalcemia from primary hyperparathyroidism may aggravate gastrin hypersecretion in Zollinger-Ellison syndrome. Thus, normalization of the serum calcium concentration is important in the management of patients with this syndrome. Proton pump inhibitors very effectively control the signs and symptoms related to hypergastrinemia. Removal of the gastrin-secreting duodenal carcinoids may be considered at the time of a pancreatic operation.

The pancreatic islet tumors may hypersecrete insulin, glucagon, human pancreatic polypeptide, chromogranin A, and vasoactive intestinal polypeptide. Insulinomas in MEN 1 may be small and numerous (see Plate 5-22). Cushing syndrome (see Plate 3-9) in individuals with MEN 1 may be caused by an ACTH-secreting pituitary tumor, a cortisol-secreting adrenal adenoma, or ectopic ACTH secretion from an islet cell tumor. Symptomatic islet cell tumors (e.g., insulinomas) should be resected. Pancreatic surgery should also be considered in patients with MEN 1 when a nonfunctioning pancreatic islet cell tumor is approaching 2 cm in diameter; larger islet cell tumors are more likely to be malignant and are prone to metastasize. The hormonal status of the GEP tumors can be monitored by annual measurement of gastrin, glucagon, human pancreatic polypeptide, and chromogranin A.



Patients with MEN 1 may have several skin manifestations. Angiofibromas, collagenomas, and subcutaneous lipomas occur in about 75% of patients with MEN 1. The dermal and subcutaneous lesions are benign and should be removed only if symptomatic. Patients with MEN 1 are also at risk of developing spinal cord ependymomas.

The *MEN1* protein product is menin, and most *MEN1* mutations inactivate or disrupt menin function.

This tumor suppressor gene has no strong genotype-phenotype correlations. Most individuals with MEN 1 inherit 1 inactivated copy of *MEN1* from an affected parent; tumorigenesis requires the subsequent somatic inactivation (e.g., gene deletion) of the remaining normal copy in a cell from a susceptible gland (e.g., parathyroid, pituitary, and pancreas). When an endocrine cell lacks menin tumor suppressor function, it begins the process of proliferation and neoplasia.



## MULTIPLE ENDOCRINE NEOPLASIA TYPE 2

Multiple endocrine neoplasia type 2 (MEN 2) is an autosomal dominant disorder with an estimated prevalence of 2.5 per 100,000 in the general population, and it is classified into three distinct syndromes—MEN 2A, MEN 2B, and familial medullary thyroid cancer (FMTC). MEN 2A is characterized by medullary thyroid cancer (MTC) in all patients, pheochromocytoma in 50%, primary hyperparathyroidism in 20%, and cutaneous lichen amyloidosis in 5%. MEN 2B is characterized by MTC in all patients, pheochromocytoma in 50%, mucocutaneous neuromas (typically involving the tongue, lips, and eyelids) in most patients, skeletal deformities (kyphoscoliosis or lordosis), joint laxity, myelinated corneal nerves, and intestinal ganglioneuromas (Hirschsprung disease). FMTC is a variant of MEN 2A, and the clinical presentation is limited to MTC.

### MEDULLARY THYROID CARCINOMA

MTC is a neuroendocrine tumor of the parafollicular C cells of the thyroid gland and accounts for approximately 3% to 5% of all primary thyroid cancers. C cells—representing 0.1% of thyroid mass and concentrated in the upper third of the thyroid gland—are neuroendocrine cells derived from the ultimobranchial bodies. Multicentric C-cell hyperplasia is found in all patients with MEN 2, and nearly all eventually develop MTC. The C cells produce calcitonin, a 32-amino acid peptide that regulates blood calcium levels in fish. However, a physiologic role for this hormone in humans is unknown. MTC in MEN 2 is multicentric and is concentrated in the upper third of the thyroid gland, reflecting the normal distribution of C cells. Approximately 25% of all patients with MTC have a family history of this disease, whereas in MEN 2A and FMTC, the peak incidence of clinical detection of index cases is in the third decade of life, the typical age of presentation of sporadic MTC is in the fifth to sixth decades of life. When diagnosed as an index case, the clinical presentation (e.g., thyroid nodule) and manifestations (e.g., cervical adenopathy) of MEN 2-associated MTC are similar to those of sporadic MTC. Serum calcitonin concentrations have a positive correlation with tumor mass. MTC in patients with MEN 2B is earlier in onset and more aggressive (e.g., metastatic disease at a young age).

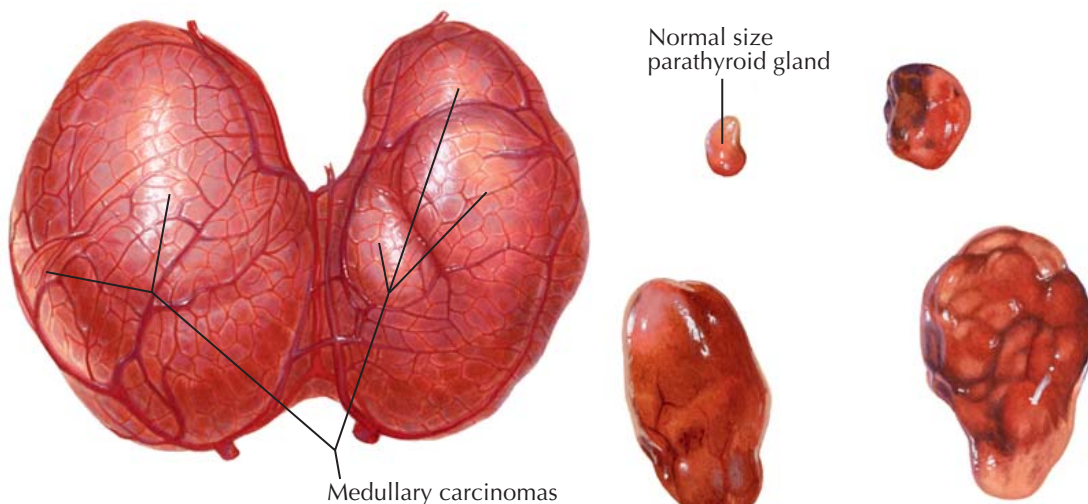
### PHEOCHROMOCYTOMA

Pheochromocytomas—affecting approximately 50% of patients with MEN 2A and 2B—frequently involve both adrenal glands and are multicentric. MTC is usually detected before pheochromocytoma in patients with MEN 2. In this patient population, pheochromocytomas are typically diagnosed when asymptomatic because of routine annual case-detection testing. However, patients with MEN 2 who are not followed up regularly or who are new index cases may present with symptoms of pheochromocytoma such as paroxysms of hypertension, forceful heart beat, hyperhidrosis, headache, and pallor.

### PRIMARY HYPERPARATHYROIDISM

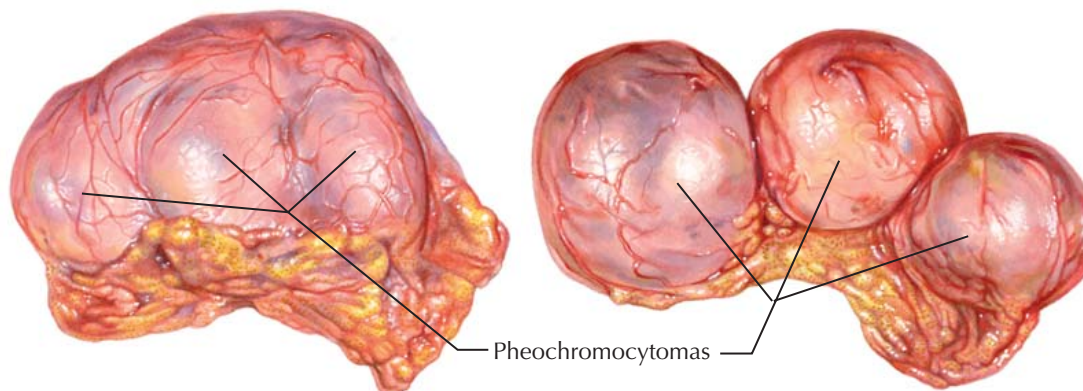
Approximately 20% of patients with MEN 2A have primary hyperparathyroidism, and when it occurs, two or more parathyroid glands are involved.

### MEN 2A



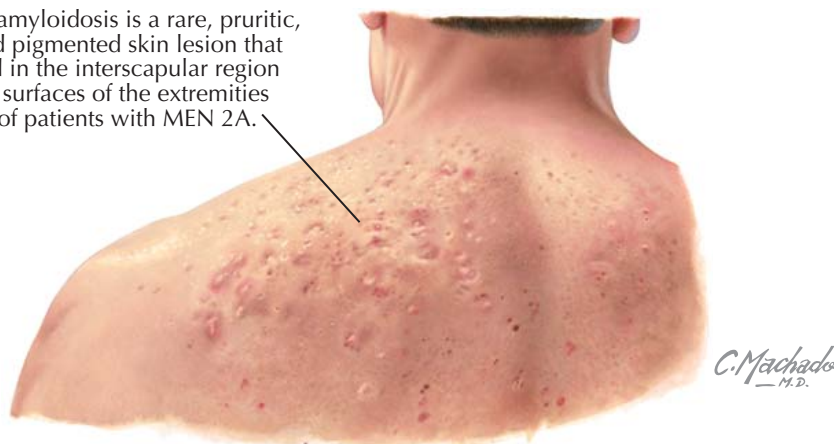
Multicentric C-cell hyperplasia, which eventually evolves into multicentric medullary thyroid carcinoma.

Approximately 20% of patients with MEN 2A have primary hyperparathyroidism, and when it occurs, 2 or more parathyroid glands are involved.



50% of patients with MEN 2A and 2B are affected with pheochromocytomas that are usually multicentric involve both adrenal glands

Cutaneous lichen amyloidosis is a rare, pruritic, papular, scaly, and pigmented skin lesion that is typically located in the interscapular region or on the extensor surfaces of the extremities that occurs in 5% of patients with MEN 2A.



### CUTANEOUS LICHEN AMYLOIDOSIS

Cutaneous lichen amyloidosis is a rare skin disorder that may occur in patients with MEN 2A. It is a pruritic, papular, scaly, and pigmented skin lesion that is typically located in the interscapular region or on the extensor surfaces of the extremities.

### HIRSCHSPRUNG DISEASE

Hirschsprung disease may occur in individuals with MEN 2B and is characterized by the absence of autonomic ganglion cells within the distal colon parasympathetic plexus, resulting in chronic obstruction and megacolon.



## MULTIPLE ENDOCRINE NEOPLASIA TYPE 2 (Continued)

### GENETICS

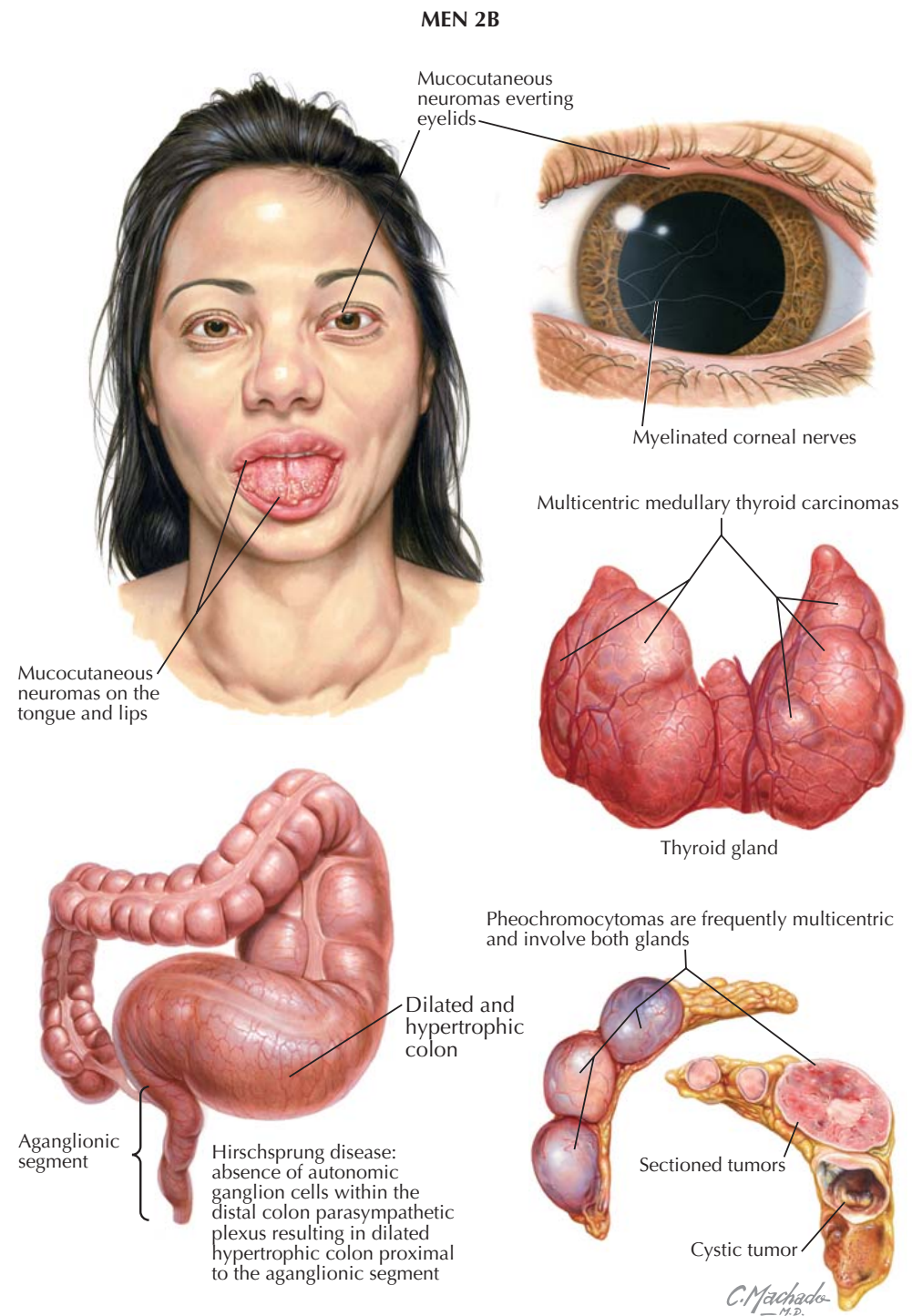
MEN 2A, MEN 2B, and FMTC are inherited in an autosomal dominant pattern with a high degree of penetrance. The mutations causing these disorders occur in the *RET* proto-oncogene on chromosome 10. The *RET* protein is a receptor tyrosine kinase that controls growth and differentiation signals in several tissues, including those derived from the neural crest. Interestingly, there is overlap in the specific *RET* mutations causing MEN 2A and FMTC; however, MEN 2B is caused by different *RET* mutations. Most mutations in MEN 2A kindreds (93%–98%) and in FMTC kindreds (80%–96%) involve one of six cysteine residues in the cysteine-rich region of the *RET* protein's extracellular domain encoded in *RET* exons 10 (codons 609, 611, 618, and 620) or 11 (codons 630 or 634).

Eighty-five percent of individuals with MEN 2A have a mutation in codon 634, particularly p.Cys634Arg. These extracellular MEN 2A/FMTC cysteine mutations lead to constitutive activation of intracellular signaling pathways. Less common mutations in MEN 2A and FMTC occur in exon 13 (codons 790 and 791). MEN 2B-associated tumors are caused by mutations in the *RET* protein's intracellular domain. A single methionine to threonine missense mutation in exon 16 (p.Met918Thr) is responsible for more than 95% of MEN 2B cases. Another mutation—alanine to phenylalanine at codon 883 in exon 15—has been found in 4% of MEN 2B kindreds. Other infrequent missense mutations in exons 14, 15, and 16 (codons 804, 806, 904, and 922) have been found in individuals with MEN 2B. Germline mutations in codons 768 (exon 13), 804 (exon 14), and 891 (exon 15) are found only in FMTC but account for a minority of FMTC cases.

The germline *RET* mutations causing MEN 2 and FMTC result in a gain-of-function defect; this is different from almost all other inherited neoplasia syndromes, which are caused by heritable “loss of function” mutations that inactivate tumor suppressor proteins. Other mutations in *RET* can produce disorders seemingly unrelated to MEN 2. For example, tissue-specific inactivating mutations of *RET* have been associated with Hirschsprung disease (congenital megacolon). Thus, in some families with a *RET* mutation, both Hirschsprung disease and MEN 2B are present.

There are genotype–phenotype correlations in MEN 2 that help direct clinical management. For example, the risk of MTC has been stratified into three categories according to *RET* mutations:

- Children with MEN 2B or *RET* mutations in codons 883, 918, or 922 have the highest risk of aggressive MTC and should undergo total thyroidectomy with central node dissection within the first 6 months of life.
- Children with *RET* mutations in codons 611, 618, 620, or 634 have a high risk of MTC. Total thyroidectomy should be performed before age 5 years, with or without central node dissection.
- Children with *RET* mutations in codons 609, 768, 790, 791, 804, or 891 have a less aggressive and slowly growing MTC and may be operated at a later stage. Some clinicians recommend a prophylactic thyroidectomy by age 5 years, but others suggest thyroidectomy by age 10 years.
- For individuals with other known *RET* mutations, no specific recommendations can be made at



present because there is not sufficient experience with these kindreds.

Genetic information can also be useful to assess the risk of developing pheochromocytoma. Individuals with *RET* mutations in codons 609, 611, 618, 620, 630, 634, 790, 883, 918, or 922 (or the specific mutation p.Val804Leu) should have annual biochemical screening. In contrast, it is unlikely that pheochromocytoma will develop in patients with mutations in codon 768 or in those with the mutation p.Val804Met.

Genetic testing for mutations in the *RET* protooncogene is commercially available and should be considered for patients with bilateral pheochromocytoma, family history of pheochromocytoma, or cophenotype

disorders. More than 95% of patients with MEN 2A and more than 98% of those with MEN 2B have an identifiable mutation in the *RET* protooncogene. In a family with MEN 2, a family member with a clinical diagnosis of MEN 2 should be tested first. When a *RET* mutation is found, all family members of unknown status should be offered genotyping. Genetic counseling consultation should be considered before genetic testing is performed. In families with known MEN 2, genetic testing shortly after birth facilitates prompt surgical management of the thyroid gland—an element of care especially important in MEN 2B families in which the thyroid gland should be removed in the first 6 months of life.



## VON HIPPEL-LINDAU SYNDROME

von Hippel-Lindau (VHL) syndrome is an autosomal dominant disorder that may present with a variety of benign and malignant neoplasms, including pheochromocytoma (frequently bilateral), paraganglioma (mediastinal, abdominal, pelvic), hemangioblastoma (involving the cerebellum, spinal cord, or brain stem), retinal angioma, clear cell renal cell carcinoma (RCC), pancreatic neuroendocrine tumors, endolymphatic sac tumors of the middle ear, serous cystadenomas of the pancreas, and papillary cystadenomas of the epididymis and broad ligament. The average age of symptomatic presentation is 26 years. Retinal angiomas and cerebellar hemangioblastomas are usually detected in the third decade of life; RCC is typically detected in the fifth decade. Penetrance is very high; the probability of developing RCC, retinal angiomas, and cerebellar hemangioblastomas is approximately 75%. Pheochromocytoma occurs in 20% of patients with VHL syndrome, and the occurrence depends on the subtype of VHL (see following text). The most common cause of death in patients with VHL syndrome is RCC.

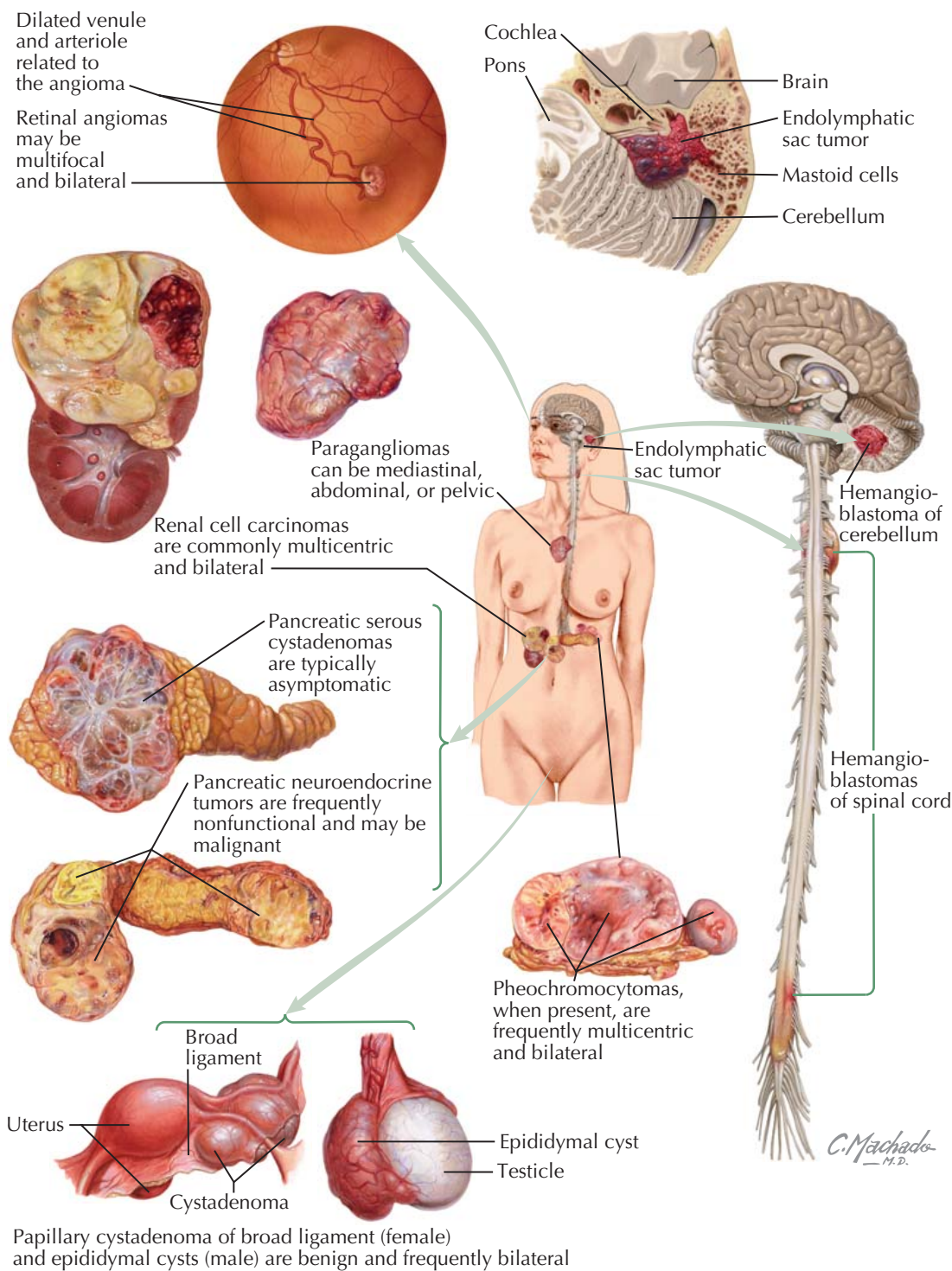
Patients with VHL syndrome may be divided into two groups: type I and type II. Patients from kindreds with type I syndrome do not develop pheochromocytoma, but patients from kindreds with type II syndrome are at high risk for developing pheochromocytoma. In addition, kindreds with type II VHL syndrome are subdivided into type IIA (low risk for RCC), type IIB (high risk for RCC), and type IIC (pheochromocytomas only).

The prevalence of VHL is approximately one in 35,000 persons. The *VHL* tumor suppressor gene, chromosomal location 3p25-26, encodes a protein that regulates hypoxia-induced proteins. More than 300 germline *VHL* mutations have been identified that lead to loss of function of the VHL protein. Nearly 100% of patients with VHL have an identifiable gene mutation. Genotype-phenotype correlations have been documented for this disorder, and specific mutations are associated with particular patterns of tumor formation. In up to 98% of cases, pheochromocytoma is associated with missense mutations, rather than truncating or null mutations, in the *VHL* gene. Certain missense mutations appear to be associated with the type IIC presentation of VHL (pheochromocytomas only). Genetic testing for VHL is commercially available and should be considered for patients with bilateral pheochromocytoma, family history of pheochromocytoma, diagnosis of pheochromocytoma at a young age (i.e., 30 years or younger), or cophenotype disorders.

Pheochromocytomas and paragangliomas occurring in patients with VHL produce predominately norepinephrine and normetanephrine. Patients with VHL should have annual biochemical testing for catecholamine-secreting neoplasms.

Hemangioblastomas are vascular neoplasms that are benign and usually do not invade locally or metastasize. They may be asymptomatic or cause mass-effect symptoms because of pressure on adjacent structures or hemorrhage. Annual or every 2-year imaging surveillance (e.g., magnetic resonance imaging [MRI] of brain and spine) is indicated. However, surgery or stereotactic radiotherapy (or both) is typically reserved for rapidly growing or symptomatic lesions.

RCC is typically multicentric and bilateral and may arise in conjunction with cysts or from noncystic renal parenchyma. Early tumor detection and selective resec-



tion with renal-sparing surgery or ablative therapies is the optimal management strategy. Annual imaging (e.g., computed tomography, MRI, or ultrasonography) of the kidneys is indicated.

Retinal angiomas develop in the retina and within the optic nerve and may be multifocal and bilateral. Annual ophthalmologic examinations are indicated. When left untreated, these lesions can hemorrhage and lead to vision loss. Laser photocoagulation and cryotherapy are very effective treatments for angiomas that do not involve the optic nerve.

Pancreatic abnormalities in VHL syndrome are common and include simple cysts (70%), serous cystadenomas (10%), and neuroendocrine tumors (20%). The cysts and serous cystadenomas are typically asymp-

tomatic. The neuroendocrine tumors of the pancreas are similar to those found in multiple endocrine neoplasia type 1, and they are frequently nonfunctional; however, they may cause symptoms related to hormone hypersecretion (e.g., glucagon, insulin, vasoactive intestinal polypeptide), and they can metastasize. The pancreas should be visualized at the time of annual renal imaging.

The epididymal cysts (frequently bilateral) in men and the papillary cystadenomas in the broad ligament in women are benign and usually asymptomatic. Papillary cystadenomas of the endolymphatic sac are vascular lesions arising within the posterior temporal bone, and affected patients may present with tinnitus, hearing loss, and vertigo.

## NEUROFIBROMATOSIS TYPE 1 (VON RECKLINGHAUSEN DISEASE)

Neurofibromatosis is a common neurocutaneous disorder affecting one in 3000 individuals. Neurofibromatosis type 1 (NF1), also known as von Recklinghausen disease, is the most common form (85%). NF1 is an autosomal dominant disorder characterized by neurofibromas, multiple café au lait spots, axillary and inguinal freckling, iris hamartomas (Lisch nodules), bony abnormalities, central nervous system gliomas, pheochromocytoma and paraganglioma, macrocephaly, and cognitive deficits. The expression of these features is variable.

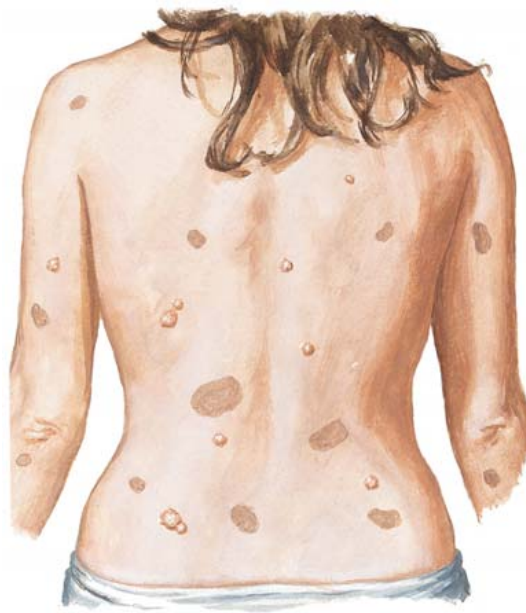The *NF1* tumor suppressor gene (chromosomal location 17q11.2) spans 350 kb and contains 60 exons encoding a 2818-amino acid protein, neurofibromin. Neurofibromin is a GTPase-activating protein that inhibits Ras activity. Inactivating *NF1* mutations causes the disorder. More than 95% of *NF1* mutations can be identified with a multistep testing protocol. Approximately half of newly detected NF1 cases are inherited, and the rest are caused by de novo mutations. Only one genotype–phenotype correlation has been identified: the c.2970-2972 delAAT (p.990delM) mutation is associated with a lack of cutaneous neurofibromas. This correlation may be because most *NF1* mutations truncate or prevent neurofibromin formation, but the c.2970-2972 delAAT mutation results in a single amino acid deletion.

At least two of the following clinical features must be present to diagnose NF1: six or more café au lait spots larger than 5 mm in prepubertal individuals and larger than 15 mm in postpubertal individuals, two or more neurofibromas of any type or 1 plexiform neurofibroma, axillary or inguinal freckling, optic glioma, two or more iris hamartomas (Lisch nodules), osseous lesions (e.g., sphenoid dysplasia), or a first-degree relative with NF1.

Café au lait spots are uniformly hyperpigmented, flat macules that appear during the first year after birth and usually increase in number during early childhood. Although up to 25% of healthy individuals have one to three café au lait spots, six or more of these spots is highly suggestive of NF1. Dense axillary and inguinal freckling are rarely found in the absence of NF1. Dense freckling may also be seen on the neck.

Neurofibromas are benign tumors composed of a mixture of Schwann cells, fibroblasts, and mast cells. The four types of neurofibromas are cutaneous, subcutaneous, nodular plexiform, and diffuse plexiform. Cutaneous neurofibromas—the most common type—are soft and fleshy tumors that arise from the peripheral nerve sheath and start to appear during adolescence and increase in size and number with age. Patients may have just a few or may have hundreds, with the trunk being the most common location. Subcutaneous neurofibromas are firm, tender nodules along the course of peripheral nerves. Nodular plexiform neurofibromas are similar to subcutaneous neurofibromas, but they occur in clusters along proximal nerve roots and major nerves. Diffuse plexiform neurofibromas are congenital lesions and are a main cause of morbidity and disfigurement in young children with NF1. In addition, plexiform neurofibromas can undergo malignant transformation to malignant peripheral nerve sheath tumors (neurofibrosarcomas).

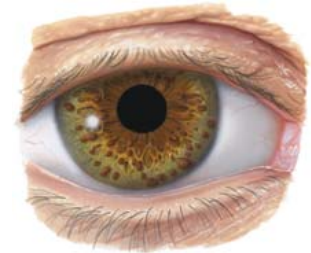
Lisch nodules on the iris—identified with an ophthalmoscope if the nodules are large and the iris is light



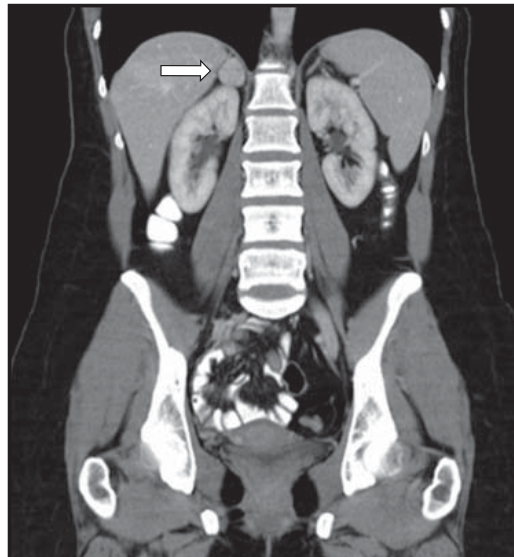Café-au-lait spots are uniformly hyperpigmented flat macules—6 or more café-au-lait spots are highly suggestive of NF1. Cutaneous neurofibromas are soft and fleshy tumors that arise from the peripheral nerve sheath, the trunk being the most common location.



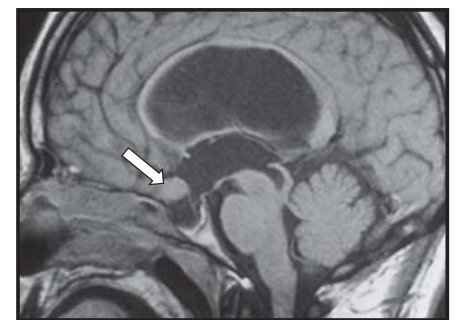Dense axillary and inguinal freckling is rarely found in the absence of NF1.



Lisch nodules are hamartomas on the iris. They are raised and frequently pigmented.



CT scan (coronal image) showing right adrenal pheochromocytoma (arrow).



MRI scan (sagittal image) showing optic nerve glioma (arrow) and third ventricular hydrocephalus caused by aqueductal stenosis.

C. Machado  
M.D.

in color or by slit-lamp examination—are raised and frequently pigmented hamartomas.

Bone-related conditions in patients with NF1 include vertebral body scalloping caused by dural ectasia, cortical thinning of the long bones, sphenoid wing dysplasia (causing facial asymmetry), short stature, and kyphoscoliosis.

Patients with NF1 are at increased risk of developing central nervous system neoplasms, including optic pathway gliomas, astrocytomas, and brainstem gliomas. Patients with optic gliomas may present with vision loss or mass effect symptoms; magnetic resonance imaging (MRI) typically shows an enlargement of the optic nerve or chiasm. Annual ophthalmologic examination and head MRI every 3 years starting in childhood are

indicated. Another central nervous system finding in NF1 is noncommunicating hydrocephalus caused by aqueductal stenosis (the aqueduct between the third and fourth ventricles is long and narrow, making it vulnerable to internal obstruction and external compression).

Hypertension is common in patients with NF1, and it may be idiopathic or associated with reno-vascular disease or catecholamine-secreting tumors. Approximately 2% of patients with NF1 develop catecholamine-secreting tumors; the mean age at diagnosis is 42 years. In these patients, the catecholamine-secreting tumor is usually a solitary benign adrenal pheochromocytoma, occasionally a bilateral adrenal pheochromocytoma, and rarely an abdominal paraganglioma.



## CLINICAL MANIFESTATIONS OF AUTOIMMUNE POLYGLANDULAR SYNDROME TYPE 1

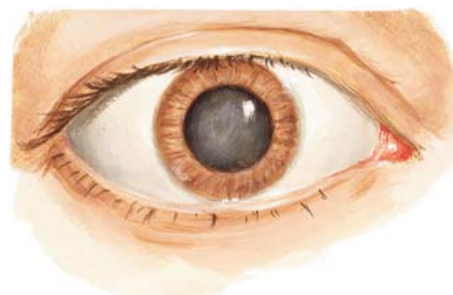Autoimmune polyglandular syndrome type I (APS1) (MIM 240300), also referred to as autoimmune polyendocrinopathy–candidiasis–ectodermal dystrophy (APECED), is a rare autosomal recessive disorder that is most prevalent in individuals of Finnish and Sardinian descent. It is less common than APS2 (see following text) and is caused by mutations in the autoimmune regulator (*AIRE*) gene. Hypoparathyroidism or chronic mucocutaneous candidiasis are usually the first manifestations that typically appear during infancy or childhood and are followed shortly thereafter (average age, 15 years) by primary adrenal insufficiency. The candidiasis—typically involving the skin, nail beds, and oral and perianal mucosa—is chronic and recurrent and can be refractory to treatment. Other features of this disorder include primary hypogonadism in 60% of patients, malabsorption in 25%, alopecia totalis or areata in 20%, pernicious anemia in 16%, and vitiligo in 4%. Initially, the alopecia may be spotty before progressing to complete loss of hair (including the eyebrows). Half of patients with APS1 develop all three main components of this syndrome, which are hypoparathyroidism, chronic cutaneous candidiasis, and primary adrenal insufficiency. The presence of at least two of these three components is needed to clinically diagnose APS1; siblings of an affected individual need only one of these components to confirm the diagnosis. Diabetes mellitus and autoimmune thyroid disease (e.g., Hashimoto thyroiditis, Graves disease) rarely occur with this disorder. However, the clinical presentation can be variable, probably because of environmental and genetic factors.

The signs and symptoms of chronic hypocalcemia attributable to hypoparathyroidism can be subtle, and it may not be diagnosed until after permanent damage has occurred. The less obvious symptoms of chronic hypocalcemia include mental lassitude, personality changes, sleepiness, or blurred vision. Mental retardation may result from childhood onset of long-standing, undetected hypocalcemia. In patients with chronic untreated hypoparathyroidism, careful examination of the eye with a slit lamp shows spiculated opacities in the posterior subcapsular area of the lens, which may progress to cataract formation and blindness. The status of the teeth may give a clue as to the time of disease onset. If it began before age 6 years, dental hypoplasia, with poor dental root formation, is usually present. If it began later in childhood, crumbling of the teeth because of poor enamel structure is observed. However, the lamina dura of the teeth may be quite dense. If the disease has been lifelong, a general stunting of growth may occur. Radiographs of the skull may show typical calcification of the basal ganglia.

APS2 (MIM 269200), previously referred to as Schmidt syndrome, typically presents between the ages of 20 and 40 years with primary adrenal insufficiency as the main manifestation. Autoimmune thyroid disease (e.g., Hashimoto thyroiditis, Graves disease) and type 1 diabetes mellitus are common in patients with APS2. This disorder is three times more common in women than in men. The inheritance pattern can be autosomal recessive, autosomal dominant, or polygenic. Primary hypogonadism may also occur in patients with APS2. However, a key distinction is that the hypoparathyroidism and mucocutaneous candidiasis of APS1 do not occur in patients with APS2, but the following have



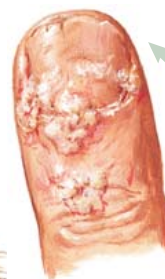Spiculate opacities of lens seen on oblique slit-lamp examination



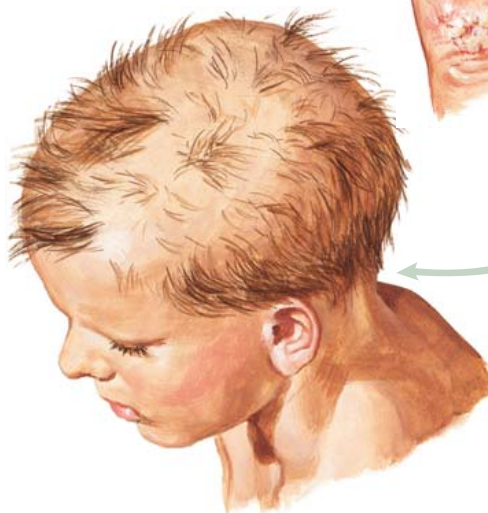Cataract (posterior subcapsular)



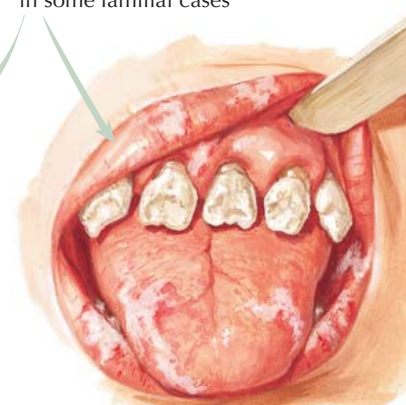
Lethargy; thick lenses needed after cataract extraction



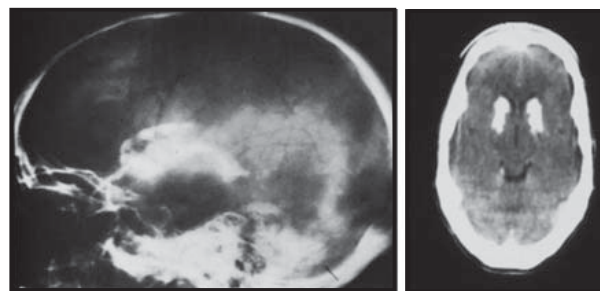
Candidiasis of nails and mouth in some familial cases



Spotty alopecia



Dental hypoplasia



Lateral radiograph and CT scan of skull show calcification of basal ganglia

been found with varying frequencies in patients with APS2: alopecia, pernicious anemia, hypopituitarism caused by autoimmune hypophysitis, vitiligo, myasthenia gravis, Sjögren syndrome, and rheumatoid arthritis.

Other rare polyendocrine autoimmune disorders include Hirata disease presenting with hypoglycemia (associated with insulin autoantibodies); immunodysregulation polyendocrinopathy enteropathy X-linked syndrome (IPEX) presenting with type 1 diabetes mellitus (associated with mutations in the *FOXP3* gene); Kearns-Sayre syndrome presenting with hypoparathyroidism, primary gonadal failure, nonautoimmune diabetes, and hypopituitarism (associated with deletions in

mitochondrial DNA); syndrome of polyneuropathy, organomegaly, endocrinopathy (diabetes and primary gonadal failure), M protein spike, and skin changes (POEMS [polyneuropathy, organomegaly, endocrinopathy, edema, M-protein, and skin abnormalities] syndrome) associated with plasma cell dyscrasia and excess cytokine production; thymic tumors presenting with myasthenia gravis, autoimmune thyroid disease, and adrenal insufficiency; type B insulin resistance associated with insulin receptor autoantibodies; and Wolfram syndrome characterized by diabetes insipidus, non-autoimmune diabetes mellitus, bilateral optic atrophy, and sensorineural deafness (associated with mutations in the *WFS1* gene).

## CARCINOID SYNDROME

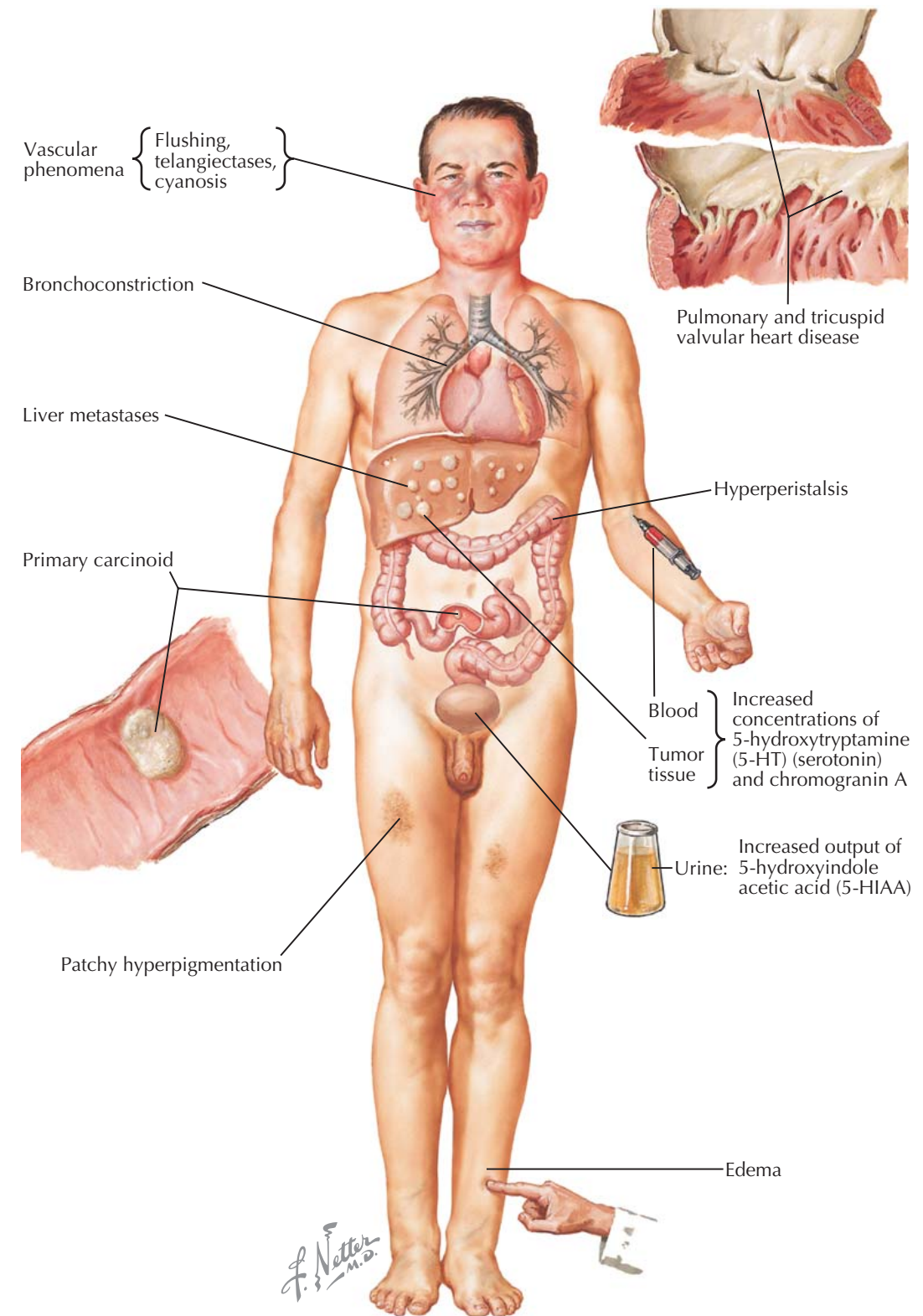
The term *carcinoid* was first used in 1907 to describe tumors that behaved in a more indolent fashion than typical adenocarcinomas. It was not until the 1950s that carcinoid tumors were recognized to be associated with a syndrome of flushing, diarrhea, right-sided valvular heart disease, and increased urinary levels of 5-hydroxyindoleacetic acid (5-HIAA). Seventy-five percent of carcinoid tumors are in the gastrointestinal tract (most commonly in the small intestine with lower frequencies in the rectum and the stomach), and 25% are bronchopulmonary carcinoids. In approximately 15% of patients, metastatic disease is evident at the time of diagnosis. The incidence of carcinoid tumors is two per 100,000 people per year. The median age at diagnosis is 55 years, and there is no gender predisposition.

Carcinoid tumors arise from the neuroendocrine cell system that consists of neuronal and epithelial cells; together, they synthesize biogenic amines and peptide hormones. They are distributed diffusely in the mucosa of the lungs and gastrointestinal tract. The underlying pathophysiology of tumorigenesis of these cells is unknown. However, some genetic conditions, such as multiple endocrine neoplasia type 1, predispose to carcinoid tumors. When metastatic, these tumors spread primarily to the regional lymph nodes, liver, bone, and the brain. Carcinoid tumor cells retain the capability to produce biogenic amines and peptide hormones, which can result in varying clinical presentations. Chromogranin A is secreted together with hormones and amines; all three secretory products can be used as tumor markers. Neuroendocrine cells often contain somatostatin and other peptide receptors on the cell surface, a finding that may be used diagnostically with somatostatin receptor scintigraphy or therapeutically with somatostatin analogues.

Pulmonary carcinoids usually have low serotonin content and rarely present with carcinoid syndrome; rather, they often secrete precursors of serotonin such as 5-hydroxytryptophan and many polypeptide hormones that may dominate the clinical presentation. For example, patients with bronchial carcinoid tumors that secrete corticotropin-releasing hormone and corticotropin present with Cushing syndrome. Other hormones that bronchial carcinoids may secrete include growth hormone-releasing hormone, antidiuretic hormone, gastrin, somatostatin, glucagon, tachykinins, and chromogranin A.

Small bowel carcinoids that secrete serotonin and chromogranin A are responsible for most cases of classic carcinoid syndrome. Typical carcinoid syndrome includes flushing, diarrhea, and right-sided valvular heart disease. Less common components include telangiectasia, wheezing caused by bronchoconstriction, patchy hyperpigmentation, and edema. Most patients with the carcinoid syndrome presentation have liver metastases, so that the usual hepatic degradation of amines and peptides is bypassed. The diarrhea is attributable to hyperperistalsis caused by a variety of factors, including serotonin, tachykinins, histamine, kallikrein, and prostaglandins.

Carcinoid heart disease (plaquelike fibrous thickening of the valves) is hemodynamically significant in only 15% of patients. This valvular involvement most commonly results in tricuspid insufficiency; less common outcomes are tricuspid stenosis, pulmonary regurgitation, and pulmonary stenosis. The pathophysiology of this right-sided heart fibrosis is probably



related to high serotonin levels. The hypersecretion of tachykinins and bradykinins is the most probable cause of bronchoconstriction.

The biochemical diagnosis of carcinoid syndrome rests primarily on measurement of the serotonin metabolite 5-HIAA in a 24-hour urine collection. Ancillary biochemical diagnostic tests include measurement of blood levels of chromogranin A and serotonin.

The carcinoid tumor is localized with a combination of imaging techniques that include somatostatin receptor scintigraphy with [<sup>111</sup>In]-trisodium zinc

diethylenetriamine pentaacetate-octreotide, computed tomography (CT) of the chest and abdomen, CT enterography, rectal ultrasonography, bronchoscopy, positron emission tomography with radiolabeled (<sup>11</sup>C)5-hydroxytryptophan or <sup>18</sup>F-fluorodeoxyglucose, upper intestinal endoscopy or endoscopic ultrasonography, and magnetic resonance imaging of the liver. The selection of imaging tests and the order in which they are performed depend on the clinical presentation and the clinical suspicion for pulmonary or gastrointestinal location.



This page intentionally left blank

# GLOSSARY OF ABBREVIATIONS

- 1,25[OH]<sub>2</sub>D** 1,25-dihydroxyvitamin D (calcitriol)  
**3β-HSD1** 3β-hydroxysteroid dehydrogenase type I isozyme  
**3β-HSD2** 3β-hydroxysteroid dehydrogenase type II isozyme  
**5-HIAA** 5-hydroxyindoleacetic acid  
**11β-HSD1** 11β-hydroxysteroid dehydrogenase type 1  
**11β-HSD2** 11β-hydroxysteroid dehydrogenase type 2  
**17β-HSD1** 17β-ketosteroid reductase  
**17β-HSD2** 17β-hydroxysteroid dehydrogenase  
**17β-HSD3** 17β-ketosteroid reductase  
**17-OHP** 17-hydroxyprogesterone  
**25[OH]D** 25-hydroxyvitamin D (calcidiol)  
**AADC** aromatic L-amino acid decarboxylase  
**ACAT** acyl-CoA:cholesterol acyltransferase  
**ACE** angiotension-converting enzyme  
**ACTH** adrenocorticotrophic hormone (corticotropin)  
**ADH** antidiuretic hormone  
**ADP** adenosine diphosphate  
**AGI** α-glucosidase inhibitor  
**AIH** androgen insensitivity syndrome  
**AIMAH** adrenocorticotrophic hormone–independent macronodular adrenal hyperplasia  
**AMH** antimüllerian hormone  
**APA** aldosterone-producing adenoma  
**APECED** autoimmune polyendocrinopathy–candidiasis–ectodermal dystrophy  
**apo** apolipoprotein  
**APS1** autoimmune polyglandular syndrome type I  
**APS2** autoimmune polyglandular syndrome type II  
**ARB** angiotensin receptor blocker  
**ATC** anaplastic thyroid carcinoma  
**ATP** adenosine triphosphate  
**ATP III** Adult Treatment Panel III  
**AVS** adrenal venous sampling  
  
**BAAF** Bensley acid aniline fuchsin  
**BMD** bone mineral density  
**BMI** body mass index  
  
**Ca<sup>2+</sup>** calcium  
**CAH** congenital adrenal hyperplasia  
**CAIS** complete androgen insensitivity syndrome  
**cAMP** cyclic adenosine monophosphate  
**CaSR** calcium-sensing receptor  
**CBG** cortisol-binding globulin  
**CETP** cholesteryl ester transfer protein  
**CHD** coronary heart disease  
**CNS** central nervous system  
**CoA** coenzyme A  
**COMT** catechol *O*-methyltransferase  
**CRH** corticotropin-releasing hormone  
**CSII** continuous subcutaneous insulin infusion  
**CT** computed tomography  
**CTX** c-telopeptide crosslink or cerebrotendinous xanthomatosis  
**CXR** chest radiograph  
  
**DA** dopamine  
**DBH** dopamine β-hydroxylase  
**DD** disc diameter  
**DHA** docosahexaenoic acid  
**Dhal-1** dehalogenase 1 isoenzyme  
**DHEA** dehydroepiandrosterone  
  
**DHEA-S** dehydroepiandrosterone sulfate  
**DHT** dihydrotestosterone  
**DI** diabetes insipidus  
**DIDMOAD** diabetes insipidus, diabetes mellitus, optic atrophy, and deafness  
**DIT** diiodotyrosine  
**DKA** diabetic ketoacidosis  
**DNA** deoxyribonucleic acid  
**DOC** deoxycorticosterone  
**DPP-IV** dipeptidyl peptidase IV  
**DR** diabetic retinopathy  
**DSD** disorder of sex development  
**DSPN** distal symmetric polyneuropathy  
**DST** dexamethasone suppression test  
**DXA** dual energy–x-ray absorptiometry  
  
**EPA** eicosapentaenoic acid  
**ER** endoplasmic reticulum  
**ESR** erythrocyte sedimentation rate  
**ESRD** end-stage renal disease  
  
**FAD** flavin adenine dinucleotide  
**FGF23** fibroblast growth factor 23  
**FH** familial hypercholesterolemia or familial hyperaldosteronism  
**FHH** familial hypocalciuric hypercalcemia  
**FISH** fluorescence in situ hybridization  
**FMTC** familial medullary thyroid carcinoma  
**FNA** fine-needle aspiration  
**FRAX** fracture risk assessment tool  
**FSH** follicle-stimulating hormone  
**FTC** follicular thyroid carcinoma  
  
**GABA** γ-aminobutyric acid  
**GAD** glutamic acid decarboxylase  
**GAG** glycosaminoglycan  
**Gb3** globotriaosylceramide  
**GCT** glucose challenge test  
**GD** Gaucher disease  
**GDM** gestational diabetes mellitus  
**GEP** gastroenteropancreatic  
**GFR** glomerular filtration rate  
**GH** growth hormone  
**GHRH** growth hormone–releasing hormone  
**GI** gastrointestinal  
**GIP** gastric inhibitory polypeptide  
**GLP-1** glucagon-like peptide 1  
**GLUT** glucose transporter  
**GnRH** gonadotropin-releasing hormone  
**GRA** glucocorticoid-remediable aldosteronism  
**GTP** guanosine triphosphate  
  
**H&E** hematoxylin–eosin  
**HbA<sub>1c</sub>** hemoglobin A<sub>1c</sub>  
**HCC** Hürthle cell carcinoma  
**HCO<sub>3</sub>** bicarbonate  
**hCG** human chorionic gonadotropin  
**hCS** human chorionic somatomammotropin  
**HDL** high-density lipoprotein  
**Hex A** hexosaminidase A  
**HIF** hypoxia-inducible factor  
**HLA** human leukocyte antigen  
**HMG-CoA** 3-hydroxy-3-methylglutaryl coenzyme A  
**HNF** hepatocyte nuclear factor  
**HPT** hyperparathyroidism  
**HVA** homovanillic acid  
  
**I<sup>-</sup>** inorganic iodine  
**IF** intrinsic factor  
**Ig** immunoglobulin  
**IGF-1** insulinlike growth factor 1  
**IHA** bilateral idiopathic hyperaldosteronism  
**IP3** inositol triphosphate  
**IPEX** immunodysregulation polyendocrinopathy enteropathy X-linked syndrome  
**IPSS** inferior petrosal sinus sampling  
**IRS** insulin receptor substrate  
**IVC** inferior vena cava  
  
**JNC7** Seventh Report of the Joint National Committee on Prevention, Detection, Evaluation, and Treatment of High Blood Pressure  
  
**K<sup>+</sup>** potassium  
**KClO<sub>4</sub><sup>-</sup>** potassium perchlorate  
  
**LCAT** lecithin-cholesterol acyltransferase  
**LDL** low-density lipoprotein  
**LH** luteinizing hormone  
**Lp(a)** lipoprotein(a)  
**LPL** lipoprotein lipase  
  
**MAO** monoamine oxidase  
**MAPK** mitogen-activated protein kinase  
**MDI** multiple daily injections  
**MEN 1** multiple endocrine neoplasia type 1  
**MEN 2** multiple endocrine neoplasia type 2  
**MI** myocardial infarction  
**MIBG** metaiodobenzylguanidine  
**MIT** monoiodotyrosine  
**MLD** metachromatic leukodystrophy  
**MODY** maturity-onset diabetes of the young  
**MR** mineralocorticoid receptor  
**MRI** magnetic resonance imaging  
**MTC** medullary thyroid carcinoma  
  
**NAD** nicotinamide adenine dinucleotide  
**NADP** nicotinamide adenine dinucleotide phosphate  
**NCEP** National Cholesterol Education Program  
**NF1** neurofibromatosis type 1  
**NIPHS** noninsulinoma pancreatogenous hypoglycemia syndrome  
**NIS** sodium-iodide symporter  
**NPD** Niemann-Pick disease  
**NPDR** nonproliferative diabetic retinopathy  
**NPH** neutral protamine Hagedorn  
**NTX** N-telopeptide crosslinks  
**NVD** neovascularization at the disc  
**NVE** neovascularization elsewhere  
  
**OGTT** oral glucose tolerance test  
**OI** osteogenesis imperfecta  
  
**P450aro** aromatase  
**P450c11AS** aldosterone synthase  
**P450c11β** 11β-hydroxylase  
**P450c17** 17α-hydroxylase  
**P450c21** 21-hydroxylase  
**P450scc** cholesterol side-chain cleavage (desmolase)  
**PA** primary aldosteronism  
**PAC** plasma aldosterone concentration  
**PAIS** partial androgen insensitivity syndrome  
**PAS** periodic acid–Schiff



|                                 |  |                       |   |                  |  |
|---------------------------------|--|-----------------------|---|------------------|--|
| <b>PCOS</b>                     | polycystic ovary syndrome  | <b>RANKL</b>          | NF- $\kappa$ B ligand                     | <b>THOX2</b>     | thyroid oxidase 2                      |
| <b>PDR</b>                      | proliferative diabetic retinopathy   | <b>RBP</b>            | retinol-binding proteins                  | <b>TPO</b>       | thyroid peroxidase                     |
| <b>PHP</b>                      | pseudohypoparathyroidism   | <b>rT<sub>3</sub></b> | reverse triiodothyronine                  | <b>TRH</b>       | thyrotropin-releasing hormone          |
| <b>PI3 kinase</b>               | phosphatidylinositol-3-kinase  | <b>RYGB</b>           | Roux-en-Y gastric bypass                  | <b>TSH</b>       | thyrotropin                            |
| <b>PMDS</b>                     | persistent müllerian duct syndrome   | <b>SD</b>             | standard deviation                        | <b>TZD</b>       | thiazolidinedione                      |
| <b>PNMT</b>                     | phenylethanolamine <i>N</i> -methyltransferase   | <b>SDH</b>            | succinate dehydrogenase                   | <b>UAH</b>       | unilateral adrenal hyperplasia         |
| <b>POEMS syndrome</b>           | polyneuropathy, organomegaly, endocrinopathy, edema, M-protein, and skin abnormalities | <b>SHBG</b>           | sex hormone-binding globulin              | <b>UFC</b>       | urinary free cortisol                  |
| <b>PPAR <math>\alpha</math></b> | peroxisome proliferator-activated receptor $\alpha$                                    | <b>SMBG</b>           | self-monitoring of blood glucose          | <b>U:L ratio</b> | upper body to lower body segment ratio |
| <b>PPNAD</b>                    | primary pigmented nodular adrenocortical disease                                       | <b>SON</b>            | supraoptic nucleus                        | <b>UDP</b>       | uridine diphosphate                    |
| <b>PRA</b>                      | plasma renin activity  | <b>SREBP</b>          | sterol regulatory element-binding protein | <b>UDPGlc</b>    | uridine diphosphate glucose            |
| <b>PTC</b>                      | papillary thyroid carcinoma  | <b>StAR</b>           | steroidogenic acute regulatory protein    | <b>UTI</b>       | urinary tract infection                |
| <b>PTH</b>                      | parathyroid hormone  | <b>SUR</b>            | sulfonylurea receptor                     | <b>UTP</b>       | uridine triphosphate                   |
| <b>PTHrP</b>                    | parathyroid hormone-related protein  | <b>T<sub>2</sub></b>  | diiodothyronine                           | <b>VHL</b>       | von Hippel-Lindau                      |
| <b>POMC</b>                     | pro-opiomelanocortin   | <b>T<sub>3</sub></b>  | triiodothyronine                          | <b>VLDL</b>      | very low-density lipoprotein           |
| <b>PPAR</b>                     | peroxisome proliferator-activated receptor   | <b>T<sub>4</sub></b>  | thyroxine                                 | <b>VMA</b>       | vanillylmandelic acid                  |
| <b>PVN</b>                      | paraventricular nucleus  | <b>TBG</b>            | thyroxine-binding globulin                | <b>VMAT</b>      | vesicular monoamine transporter        |
| <b>RAAS</b>                     | renin-angiotensin-aldosterone system   | <b>TC</b>             | transcobalamins                           | <b>ZF</b>        | adrenal zona fasciculata               |
| <b>RANK</b>                     | receptor activator of NF- $\kappa$ B   | <b>TCA</b>            | tricarboxylic acid                        | <b>ZG</b>        | adrenal zona glomerulosa               |
|                                 |  | <b>Tg</b>             | thyroglobulin                             | <b>ZR</b>        | adrenal zona reticularis               |
|                                 |  | <b>TGRL</b>           | triglyceride-rich lipoproteins            |                  |  |
|                                 |  | <b>TH</b>             | tyrosine hydroxylase                      |                  |  |

## Section 1: Pituitary and Hypothalamus

- Abe T. Lymphocytic infundibulo-neurohypophysitis and infundibulo-panhypophysitis regarded as lymphocytic hypophysitis variant. *Brain Tumor Pathol* 2008;25(2):59–66.
- ACOG Practice Bulletin: Clinical Management Guidelines for Obstetrician-Gynecologists Number 76, October 2006: postpartum hemorrhage. *Obstet Gynecol* 2006;108(4):1039–47.
- Agrawal D, Mahapatra AK. Visual outcome of blind eyes in pituitary apoplexy after transsphenoidal surgery: a series of 14 eyes. *Surg Neurol* 2005;63(1):42–6; discussion 46.
- Alatzoglou KS, Dattani MT. Genetic forms of hypopituitarism and their manifestation in the neonatal period. *Early Hum Dev* 2009;85(11):705–12.
- Alatzoglou KS, Kelberman D, Dattani MT. The role of SOX proteins in normal pituitary development. *J Endocrinol* 2009;200(3):245–58.
- Alkemade A, Frieseema EC, Unmehopa UA, Fabriek BO, Kuiper GG, Leonard JL, et al. Neuroanatomical pathways for thyroid hormone feedback in the human hypothalamus. *J Clin Endocrinol Metab* 2005;90(7):4322–34.
- Asa SL, Ezzat S, Watson RE Jr, Lindell EP, Horvath E. Gonadotropin producing adenoma. In: DeLellis RA, Lloyd RV, Heitz PU, Eng C, editors. *World Health Organization Classification of Tumours. Pathology and Genetics of Tumours of Endocrine Organs*. Lyon: IARC Press; 2004. p. 30–2.
- Ascoli P, Cavagnini F. Hypopituitarism. *Pituitary* 2006;9(4):335–42.
- Assie G, Bahurel H, Coste J, Silvera S, Kujas M, Dugue MA, et al. Corticotroph tumor progression after adrenalectomy in Cushing's Disease: A reappraisal of Nelson's Syndrome. *J Clin Endocrinol Metab* 2007;92(1):172–9.
- Atkinson JL, Young WF Jr, Meyer FB, Davis DH, Nippoldt TB, Erickson D, et al. Sublabial transseptal vs transnasal combined endoscopic microsurgery in patients with Cushing disease and MRI-depicted microadenomas. *Mayo Clin Proc* 2008;83(5):550–3.
- Atmaca H, Tanriverdi F, Gokce C, Unluhizarci K, Kelestimur F. Posterior pituitary function in Sheehan's syndrome. *Eur J Endocrinol* 2007;156(5):563–7.
- Barkan AL. Biochemical markers of acromegaly: GH vs. IGF-I. *Growth Horm IGF Res* 2004;14(Suppl A):S97–100.
- Bell J, Parker KL, Swinford RD, Hoffman AR, Maneatis T, Lippe B. Long-term safety of recombinant human growth hormone in children. *J Clin Endocrinol Metab* 2010;95(1):167–77.
- Ben-Shlomo A. Pituitary gland: predictors of acromegaly-associated mortality. *Nat Rev Endocrinol* 2010;6(2):67–9.
- Bertagna X, Guignat L, Grossin L, Bertherat J. Cushing's disease. *Best Pract Res Clin Endocrinol Metab* 2009;23(5):607–23.
- Bhasin S, Cunningham GR, Hayes FJ, Matsumoto AM, Snyder PJ, Swerdloff RS, et al. Testosterone therapy in adult men with androgen deficiency syndromes: an endocrine society clinical practice guideline. *J Clin Endocrinol Metab* 2006;91(6):1995–2010.
- Billir BM, Grossman AB, Stewart PM, Melmed S, Bertagna X, Bertherat J, et al. Treatment of adrenocorticotropic-dependent Cushing's syndrome: a consensus statement. *J Clin Endocrinol Metab* 2008;93(7):2454–62.
- Blanks AM, Thornton S. The role of oxytocin in parturition. *BJOG* 2003;110(Suppl 20):46–51.
- Boscaro M, Arnaldi G. Approach to the patient with possible Cushing's syndrome. *J Clin Endocrinol Metab* 2009;94(9):3121–31.
- Bougueres P, Pantalone L, Linglart A, Rothenbuhler A, Le Stunff C. Endocrine manifestations of the rapid-onset obesity with hypoventilation, hypothalamic, autonomic dysregulation, and neural tumor syndrome in childhood. *J Clin Endocrinol Metab* 2008;93(10):3971–80.
- Bouligand J, Ghervan C, Tello JA, Brailly-Tabard S, Salenave S, Chanson P, et al. Isolated familial hypogonadotropic hypogonadism and a GNRH1 mutation. *N Engl J Med* 2009;360(26):2742–8.
- Brewster UC, Hayslett JP. Diabetes insipidus in the third trimester of pregnancy. *Obstet Gynecol* 2005;105(5 Pt 2):1173–6.
- Buchfelder M, Schlaffer S. Surgical treatment of pituitary tumours. *Best Pract Res Clin Endocrinol Metab* 2009;23(5):677–92.
- Buurman H, Saeger W. Subclinical adenomas in postmortem pituitaries: classification and correlations to clinical data. *Eur J Endocrinol* 2006;154(5):753–8.
- Carpinteri R, Patelli I, Casanueva FF, Giustina A. Pituitary tumours: inflammatory and granulomatous expansive lesions of the pituitary. *Best Pract Res Clin Endocrinol Metab* 2009;23(5):639–50.
- Carrim ZI, Reeks GA, Chohan AW, Dunn LT, Hadley DM. Predicting impairment of central vision from dimensions of the optic chiasm in patients with pituitary adenoma. *Acta Neurochir (Wien)* 2007;149(3):255–60; discussion 260.
- Castinetti F, Saveanu A, Reynaud R, Quentien MH, Buffin A, Brauner R, et al. A novel dysfunctional LHX4 mutation with high phenotypical variability in patients with hypopituitarism. *J Clin Endocrinol Metab* 2008;93(7):2790–9.
- Cavallo LM, Prevedello D, Esposito F, Laws ER Jr, Dusick JR, Messina A, et al. The role of the endoscope in the transsphenoidal management of cystic lesions of the sellar region. *Neurosurg Rev* 2008;31(1):55–64; discussion 64.
- Chamathi B, Morris CA, Kaiser UB, Katz JT, Loscalzo J. Clinical problem-solving. Stalking the diagnosis. *N Engl J Med* 2010;362(9):834–9.
- Chan YM, de Guillebon A, Lang-Muritano M, Plummer L, Cerrato F, Tsiaras S, et al. GNRH1 mutations in patients with idiopathic hypogonadotropic hypogonadism. *Proc Natl Acad Sci U S A* 2009;106(28):11703–8.
- Chandler WF, Barkan AL. Treatment of pituitary tumors: a surgical perspective. *Endocrinol Metab Clin North Am* 2008;37(1):51–66.viii.
- Chanson P, Salenave S, Kamenicky P, Cazabat L, Young J. Pituitary tumours: acromegaly. *Best Pract Res Clin Endocrinol Metab* 2009;23(5):555–74.
- Chatterton RT Jr, Hill PD, Aldag JC, Hodges KR, Belknap SM, Zinaman MJ. Relation of plasma oxytocin and prolactin concentrations to milk production in mothers of preterm infants: influence of stress. *J Clin Endocrinol Metab* 2000;85(10):3661–8.
- Chiamolera MI, Wondisford FE. Minireview: Thyrotropin-releasing hormone and the thyroid hormone feedback mechanism. *Endocrinology* 2009;150(3):1091–6.
- Choh NA, Choh SA, Jehangir M, Yousuf R. Posterior pituitary ectopia with absent pituitary stalk—a rare cause of hypopituitarism. *J Pediatr Endocrinol Metab* 2009;22(5):407–8.
- Chow JT, Thompson GB, Grant CS, Farley DR, Richards ML, Young WF Jr. Bilateral laparoscopic adrenalectomy for corticotrophin-dependent Cushing's syndrome: a review of the Mayo Clinic experience. *Clin Endocrinol (Oxf)* 2008;68(4):513–19.
- Clark SL, Simpson KR, Knox GE, Garite TJ. Oxytocin: new perspectives on an old drug. *Am J Obstet Gynecol* 2009;200(1):35 e31–36.
- Colao A, Di Somma C, Savastano S, Rota F, Savanelli MC, Aimaretti G, et al. A reappraisal of diagnosing GH deficiency in adults: role of gender, age, waist circumference, and body mass index. *J Clin Endocrinol Metab* 2009;94(11):4414–22.
- Colao A, Loche S. Prolactinomas in Children and Adolescents. *Endocr Dev* 2010;17:146–59.
- Colvin SC, Mullen RD, Pfaffle RW, Rhodes SJ. LHX3 and LHX4 transcription factors in pituitary development and disease. *Pediatr Endocrinol Rev* 2009;6(Suppl 2):283–90.
- Cordero RA, Barkan AL. Current diagnosis of acromegaly. *Rev Endocr Metab Disord* 2008;9(1):13–19.
- Coya R, Vela A, Perez de Nancrales G, Rica I, Castano L, Busturia MA, et al. Panhypopituitarism: genetic versus acquired etiological factors. *J Pediatr Endocrinol Metab* 2007;20(1):27–36.
- D'Ambrosio N, Soohoo S, Warshall C, Johnson A, Karimi S. Craniofacial and intracranial manifestations of Langerhans cell histiocytosis: report of findings in 100 patients. *AJR Am J Roentgenol* 2008;191(2):589–97.
- Darzy KH. Radiation-induced hypopituitarism after cancer therapy: who, how and when to test. *Nat Clin Pract Endocrinol Metab* 2009;5(2):88–99.
- Darzy KH, Shalet SM. Hypopituitarism following radiotherapy. *Pituitary* 2009;12(1):40–50.
- De Bellis A, Ruocco G, Battaglia M, Conte M, Coronella C, Tirelli G, et al. Immunological and clinical aspects of lymphocytic hypophysitis. *Clin Sci (Lond)* 2008;114(6):413–21.
- De Marinis L, Bonadonna S, Bianchi A, Maira G, Giustina A. Primary empty sella. *J Clin Endocrinol Metab* 2005;90(9):5471–7.
- Decaux G, Soupart A, Vassart G. Non-peptide arginine-vasopressin antagonists: the vaptans. *Lancet* 2008;371(9624):1624–32.
- Dekkers OM, Lagro J, Burman P, Jorgensen JO, Romijn JA, Pereira AM. Recurrence of hyperprolactinemia after withdrawal of dopamine agonists: systematic review and meta-analysis. *J Clin Endocrinol Metab* 2010;95(1):43–51.
- Delman BN. Imaging of pediatric pituitary abnormalities. *Endocrinol Metab Clin North Am* 2009;38(4):673–98.
- Desai NR, Cheng S, Nohria A, Halperin F, Giugliano RP. Clinical problem-solving. When past is prologue. *N Engl J Med* 2009;360(10):1016–22.
- di Iorgi N, Secco A, Napoli F, Calandra E, Rossi A, Maghnie M. Developmental abnormalities of the posterior pituitary gland. *Endocr Dev* 2009;14:83–94.
- Dubuisson AS, Stevenaert A, Martin DH, Flandroy PP. Intracellular arachnoid cysts. *Neurosurgery* 2007;61(3):505–13; discussion 513.
- Dunser MW, Lindner KH, Wenzel V. A century of arginine vasopressin research leading to new therapeutic strategies. *Anesthesiology* 2006;105(3):444–5.
- Dutta P, Bhansali A, Singh P, Rajput R, Khandelwal N, Bhadada S. Congenital hypopituitarism: clinico-radiological correlation. *J Pediatr Endocrinol Metab* 2009;22(10):921–8.
- Elliott RE, Hsieh K, Hochm T, Belitskaya-Levy I, Wisoff J, Wisoff JH. Efficacy and safety of radical resection of primary and recurrent craniopharyngiomas in 86 children. *J Neurosurg Pediatr* 2010;5(1):30–48.
- Ellison DH, Berl T. Clinical practice. The syndrome of inappropriate antidiuresis. *N Engl J Med* 2007;356(20):2064–72.
- Ersahin Y, Kesikli H, Ruksen M, Aydin C, Mutluer S. Endoscopic treatment of suprasellar arachnoid cysts. *Childs Nerv Syst* 2008;24(9):1013–20.
- Eugster EA, Pescovitz OH. Gigantism. *J Clin Endocrinol Metab* 1999;84(12):4379–84.
- Fazio N, Spaggiari L, Pelosi G, Presicci F, Preda L. Langerhans' cell histiocytosis. *Lancet* 2005;365(9459):598.
- Fernandez A, Brada M, Zabulienė L, Karavitaki N, Wass JA. Radiation-induced hypopituitarism. *Endocr Relat Cancer* 2009;16(3):733–72.
- Fewtrell MS, Loh KL, Blake A, Ridout DA, Hawdon J. Randomised, double blind trial of oxytocin nasal spray in mothers expressing breast milk for preterm infants. *Arch Dis Child Fetal Neonatal Ed* 2006;91(3):F169–174.
- Freda PU. Monitoring of acromegaly: what should be performed when GH and IGF-1 levels are discrepant? *Clin Endocrinol (Oxf)* 2009;71(2):166–70.
- Fujimoto N, Saeki N, Miyauchi O, Adachi-Usami E. Criteria for early detection of temporal hemianopia in asymptomatic pituitary tumor. *Eye (Lond)* 2002;16(6):731–8.
- Gandhi CD, Christiano LD, Eloy JA, Prestigiacomo CJ, Post KD. The historical evolution of transsphenoidal surgery: facilitation by technological advances. *Neurosurg Focus* 2009;27(3):E8.
- Gaston-Massuet C, Andoniadou CL, Signore M, Sajedi E, Bird S, Turner JM, et al. Genetic interaction between the homeobox transcription factors HESX1 and SIX3 is required for normal pituitary development. *Dev Biol* 2008;324(2):322–33.
- Geddes JF, Jansen GH, Robinson SF, Gomori E, Holton JL, Monson JP, et al. "Gangliocytomas" of the pituitary: a heterogeneous group of lesions with differing histogenesis. *Am J Surg Pathol* 2000;24(4):607–13.
- Giustina A, Barkan A, Chanson P, Grossman A, Hoffman A, Ghigo E, et al. Guidelines for the treatment of growth hormone excess and growth hormone deficiency in adults. *J Endocrinol Invest* 2008;31(9):820–38.
- Goldenberg N, Racine MS, Thomas P, Degnan B, Chandler W, Barkan A. Treatment of pituitary gigantism with the growth hormone receptor antagonist pegvisomant. *J Clin Endocrinol Metab* 2008;93(8):2953–6.
- Goswami R, Kochupillai N, Crock PA, Jaleel A, Gupta N. Pituitary autoimmunity in patients with Sheehan's syndrome. *J Clin Endocrinol Metab* 2002;87(9):4137–41.
- Greenman Y, Stern N. How should a nonfunctioning pituitary macroadenoma be monitored after debulking surgery? *Clin Endocrinol (Oxf)* 2009;70(6):829–32.
- Gruber A, Clayton J, Kumar S, Robertson I, Howlett TA, Mansell P. Pituitary apoplexy: retrospective review of 30 patients—is surgical intervention always necessary? *Br J Neurosurg* 2006;20(6):379–85.
- Hamilton BE, Salzman KL, Osborn AG. Anatomic and pathologic spectrum of pituitary infundibulum lesions. *AJR Am J Roentgenol* 2007;188(3):W223–232.
- Hattori N, Ishihara T, Saiki Y. Macroprolactinaemia: prevalence and aetiologies in a large group of hospital workers. *Clin Endocrinol (Oxf)* 2009;71(5):702–8.
- Herman TE, Siegel MJ. Langerhans cell histiocytosis: radiographic images in pediatrics. *Clin Pediatr (Phila)* 2009;48(2):228–31.
- Heshmati HM, Scheithauer BW, Young WF Jr. Metastases to the pituitary gland. *Endocrinology* 2002;12:45–9.
- Ishunina TA, Swaab DF. Vasopressin and oxytocin neurons of the human supraoptic and paraventricular nucleus: size changes in relation to age and sex. *J Clin Endocrinol Metab* 1999;84(12):4637–44.



- Jane JA Jr, Prevedello DM, Alden TD, Laws ER Jr. The transphenoidal resection of pediatric craniopharyngiomas: a case series. *J Neurosurg Pediatr* 2010;5(1):49–60.
- Kano H, Niranjana A, Kondziolka D, Flickinger JC, Lunsford LD. Stereotactic radiosurgery for pituitary metastases. *Surg Neurol* 2009;72(3):248–55; discussion 255–246.
- Karavitaki N, Wass JA. Non-adenomatous pituitary tumours. *Best Pract Res Clin Endocrinol Metab* 2009;23(5):651–65.
- Kaushal K, Shalet SM. Defining growth hormone status in adults with hypopituitarism. *Horm Res* 2007;68(4):185–94.
- Kelberman D, Dattani MT. Role of transcription factors in midline central nervous system and pituitary defects. *Endocr Dev* 2009;14:67–82.
- Kelberman D, Turton JP, Woods KS, Mehta A, Al-Khawari M, Greening J, et al. Molecular analysis of novel PROP1 mutations associated with combined pituitary hormone deficiency (CPHD). *Clin Endocrinol (Oxf)* 2009;70(1):96–103.
- Kelestimur F. Sheehan's syndrome. *Pituitary* 2003;6(4):181–8.
- Kelly PA, Samandouras G, Grossman AB, Afshar F, Besser GM, Jenkins PJ. Neurosurgical treatment of Nelson's syndrome. *J Clin Endocrinol Metab* 2002;87(12):5465–9.
- Klibanski A. Clinical practice. Prolactinomas. *N Engl J Med* 2010;362(13):1219–26.
- Komninos J, Vlassopoulou V, Protosapa D, Korfiatis S, Kontogeorgos G, Sakas DE, et al. Tumors metastatic to the pituitary gland: case report and literature review. *J Clin Endocrinol Metab* 2004;89(2):574–80.
- Kontogeorgos G, Watson RE Jr, Lindell EP, Barkan AL, Farrell WE, Lloyd RV. Growth hormone producing adenoma. In: DeLellis RA, Lloyd RV, Heitz PU, Eng C, editors. *World Health Organization Classification of Tumours. Pathology and Genetics of Tumours of Endocrine Organs*. Lyon: IARC Press; 2004. p. 14–19.
- Kosmorsky GS, Dupps WJ Jr, Drake RL. Nonuniform pressure generation in the optic chiasm may explain bitemporal hemianopsia. *Ophthalmology* 2008;115(3):560–5.
- Kovacs K. Sheehan syndrome. *Lancet* 2003;361(9356):520–2.
- Kovacs K, Horvath E, Vidal Ruibal S, Watson RE Jr, Lindell EP, Ezzat S, Asa SL. Secondary tumours. In: DeLellis RA, Lloyd RV, Heitz PU, Eng C, editors. *World Health Organization Classification of Tumours. Pathology and Genetics of Tumours of Endocrine Organs*. Lyon: IARC Press; 2004. p. 45–7.
- Kristof RA, Rother M, Neuloh G, Klingmuller D. Incidence, clinical manifestations, and course of water and electrolyte metabolism disturbances following transphenoidal pituitary adenoma surgery: a prospective observational study. *J Neurosurg* 2009;111(3):555–62.
- Krsmanovic LZ, Hu L, Leung PK, Feng H, Catt KJ. The hypothalamic GnRH pulse generator: multiple regulatory mechanisms. *Trends Endocrinol Metab* 2009;20(8):402–8.
- Laws ER Jr, Jane JA Jr. Craniopharyngioma. *J Neurosurg Pediatr* 2010;5(1):27–8; discussion 28–29.
- Lawson EA, Buchbinder BR, Daniels GH. Hypopituitarism associated with a giant aneurysm of the internal carotid artery. *J Clin Endocrinol Metab* 2008;93(12):4616.
- Lee MM. Clinical practice. Idiopathic short stature. *N Engl J Med* 2006;354(24):2576–82.
- Leonidas JC, Gueflguat M, Valderrama E. Langerhans' cell histiocytosis. *Lancet* 2003;361(9365):1293–5.
- Lloyd RV, Douglas BR, Young WF Jr. Pituitary gland. In: King DW, editor. *Atlas of Nontumor Pathology: Endocrine Diseases*. 1st ed. Washington D.C.: American Registry of Pathology and the Armed Forces Institute of Pathology; 2002. p. 1–43.
- Low MJ. Neuroendocrinology. In: Kronenberg HM, Melmed S, Polonsky KS, Larsen PR, editors. *Williams Textbook of Endocrinology*. 11th ed. Philadelphia: Saunders; 2008. p. 85–154.
- Lury KM. Inflammatory and infectious processes involving the pituitary gland. *Top Magn Reson Imaging* 2005;16(4):301–6.
- Mauermann WJ, Sheehan JP, Chernavsky DR, Laws ER, Steiner L, Vance ML. Gamma Knife surgery for adrenocorticotrophic hormone-producing pituitary adenomas after bilateral adrenalectomy. *J Neurosurg* 2007;106(6):988–93.
- McKenna TJ. Should macroprolactin be measured in all hyperprolactinaemic sera? *Clin Endocrinol (Oxf)* 2009;71(4):466–9.
- McVary KT. Clinical practice. Erectile dysfunction. *N Engl J Med* 2007;357(24):2472–81.
- Mehta A, Hindmarsh PC, Mehta H, Turton JP, Russell-Eggitt I, Taylor D, et al. Congenital hypopituitarism: clinical, molecular and neuroradiological correlates. *Clin Endocrinol (Oxf)* 2009;71(3):376–82.
- Melmed S. Medical progress: Acromegaly. *N Engl J Med* 2006;355(24):2558–73.
- Melmed S. Acromegaly pathogenesis and treatment. *J Clin Invest* 2009;119(11):3189–202.
- Melmed S, Colao A, Barkan A, Molitch M, Grossman AB, Kleinberg D, et al. Guidelines for acromegaly management: an update. *J Clin Endocrinol Metab* 2009;94(5):1509–17.
- Melmed SM, Kleinberg D. Anterior pituitary. In: Kronenberg HM, Melmed S, Polonsky KS, Larsen PR, editors. *Williams Textbook of Endocrinology*. 11th ed. Philadelphia: Saunders; 2008. p. 155–262.
- Milardi D, Giampietro A, Baldelli R, Pontecorvi A, De Marinis L. Fertility and hypopituitarism. *J Endocrinol Invest* 2008;31(9 Suppl):71–4.
- Molitch ME, Clemmons DR, Malozowski S, Merriam GR, Shalet SM, Vance ML, et al. Evaluation and treatment of adult growth hormone deficiency: an Endocrine Society Clinical Practice Guideline. *J Clin Endocrinol Metab* 2006;91(5):1621–34.
- Muller HL. Childhood craniopharyngioma. Recent advances in diagnosis, treatment and follow-up. *Horm Res* 2008;69(4):193–202.
- Murad-Kejbou S, Eggenberger E. Pituitary apoplexy: evaluation, management, and prognosis. *Curr Opin Ophthalmol* 2009;20(6):456–61.
- Nakamoto J. Laboratory diagnosis of multiple pituitary hormone deficiencies: issues with testing of the growth and thyroid axes. *Pediatr Endocrinol Rev* 2009;6(Suppl 2):291–7.
- Nakhlia M, Polychronakos C. Monogenic and other unusual causes of diabetes mellitus. *Pediatr Clin North Am* 2005;52(6):1637–50.
- Narayananam V, Rettig KR, Bhowmick SK. Excessive growth. *Clin Pediatr (Phila)* 2008;47(7):705–8.
- Nawar RN, AbdelMannan D, Selman WR, Arafah BM. Pituitary tumor apoplexy: a review. *J Intensive Care Med* 2008;23(2):75–90.
- Nemerug EC, Zuo Z, Jane JA Jr, Laws ER Jr. Predictors of diabetes insipidus after transphenoidal surgery: a review of 881 patients. *J Neurosurg* 2005;103(3):448–54.
- Nieman LK, Biller BM, Findling JW, Newell-Price J, Savage MO, Stewart PM, et al. The diagnosis of Cushing's syndrome: an Endocrine Society Clinical Practice Guideline. *J Clin Endocrinol Metab* 2008;93(5):1526–40.
- Ozkan Y, Colak R. Sheehan syndrome: clinical and laboratory evaluation of 20 cases. *Neuro Endocrinol Lett* 2005;26(3):257–60.
- Pardanani A, Philylyk RL, Li CY, Tefferi A. 2-Chlorodeoxyadenosine therapy for disseminated Langerhans cell histiocytosis. *Mayo Clin Proc* 2003;78(3):301–6.
- Pascual JM, Carrasco R, Prieto R, Gonzalez-Llanos F, Alvarez F, Roda JM. Craniopharyngioma classification. *J Neurosurg* 2008;109(6):1180–1182; author reply 1182–3.
- Patil CG, Prevedello DM, Lad SP, Vance ML, Thorner MO, Katznelson L, et al. Late recurrences of Cushing's disease after initial successful transphenoidal surgery. *J Clin Endocrinol Metab* 2008;93(2):358–62.
- Patil CG, Veeravagu A, Prevedello DM, Katznelson L, Vance ML, Laws ER Jr. Outcomes after repeat transphenoidal surgery for recurrent Cushing's disease. *Neurosurgery* 2008;63(2):266–70; discussion 270–261.
- Petersenn S, Buchfelder M, Gerbert B, Franz H, Quabbe HJ, Schulte HM, et al. Age and sex as predictors of biochemical activity in acromegaly: analysis of 1485 patients from the German Acromegaly Register. *Clin Endocrinol (Oxf)* 2009;71(3):400–5.
- Petit JH, Biller BM, Yock TI, Swearingen B, Coen JJ, Chapman P, et al. Proton stereotactic radiotherapy for persistent adrenocorticotropin-producing adenomas. *J Clin Endocrinol Metab* 2008;93(2):393–9.
- Pitteloud N, Dwyer AA, DeCruz S, Lee H, Boepple PA, Crowley WF Jr, et al. Inhibition of luteinizing hormone secretion by testosterone in men requires aromatization for its pituitary but not its hypothalamic effects: evidence from the tandem study of normal and gonadotropin-releasing hormone-deficient men. *J Clin Endocrinol Metab* 2008;93(3):784–91.
- Prodan F, Pagano L, Corneli G, Golisano G, Belcastro S, Busti A, et al. Update on epidemiology, etiology, and diagnosis of adult growth hormone deficiency. *J Endocrinol Invest* 2008;31(9 Suppl):6–11.
- Quereda V, Malumbres M. Cell cycle control of pituitary development and disease. *J Mol Endocrinol* 2009;42(2):75–86.
- Raper DM, Besser M. Clinical features, management and recurrence of symptomatic Rathke's cleft cyst. *J Clin Neurosci* 2009;16(3):385–9.
- Raverot G, Jacob M, Jouanneau E, Delemer B, Vighetto A, Pugeat M, et al. Secondary deterioration of visual field during cabergoline treatment for macroprolactinoma. *Clin Endocrinol (Oxf)* 2009;70(4):588–92.
- Raverot G, Wierinckx A, Dantony E, Auger C, Chapas G, Villeneuve L, et al. Prognostic factors in prolactin pituitary tumors: clinical, histological, and molecular data from a series of 94 patients with a long postoperative follow-up. *J Clin Endocrinol Metab* 2010;95(4):1708–16.
- Reid TJ, Post KD, Bruce JN, Nabi Kanibir M, Reyes-Vidal CM, Freda PU. Features at diagnosis of 324 patients with acromegaly did not change from 1981 to 2006; acromegaly remains under-recognized and under-diagnosed. *Clin Endocrinol (Oxf)* 2010;72:203–8.
- Reynaud R, Gueydan M, Saveanu A, Vallette-Kasic S, Enjalbert A, Brue T, et al. Genetic screening of combined pituitary hormone deficiency: experience in 195 patients. *J Clin Endocrinol Metab* 2006;91(9):3329–36.
- Robertson DM, Hale GE, Jolley D, Fraser IS, Hughes CL, Burger HG. Interrelationships between ovarian and pituitary hormones in ovulatory menstrual cycles across reproductive age. *J Clin Endocrinol Metab* 2009;94(1):138–44.
- Robinson AG, Verbalis JG. Posterior pituitary. In: Kronenberg HM, Melmed S, Polonsky KS, Larsen PR, editors. *Williams Textbook of Endocrinology*. 11th ed. Philadelphia: Saunders; 2008. p. 263–98.
- Romero CJ, Nesi-Franca S, Radovick S. The molecular basis of hypopituitarism. *Trends Endocrinol Metab* 2009;20(10):506–16.
- Rudolph T, Frisen L. Influence of ageing on visual field defects due to stable lesions. *Br J Ophthalmol* 2007;91(10):1276–8.
- Rupp D, Molitch M. Pituitary stalk lesions. *Curr Opin Endocrinol Diabetes Obes* 2008;15(4):339–45.
- Saeger W, Horvath E, Kovacs K, Nose V, Farrell WE, Lloyd RV, Watson RE Jr, Lindell EP. Prolactin producing adenoma. In: DeLellis RA, Lloyd RV, Heitz PU, Eng C, editors. *World Health Organization Classification of Tumours. Pathology and Genetics of Tumours of Endocrine Organs*. Lyon: IARC Press; 2004. p. 20–3.
- Saito T, Sato N, Kimoto M, Asano T, Aoki A, Ikoma A, et al. Incomplete deficiency of hypothalamic hormones in hypothalamic hypopituitarism associated with an old traumatic brain injury. *Endocr J* 2009;56(8):945–50.
- Saleem SN, Said AH, Lee DH. Lesions of the hypothalamus: MR imaging diagnostic features. *Radiographics* 2007;27(4):1087–108.
- Sano T, Yamada S, Watson RE Jr, Lindell EP, Ezzat S, Asa SL. Null cell adenoma. In: DeLellis RA, Lloyd RV, Heitz PU, Eng C, editors. *World Health Organization Classification of Tumours. Pathology and Genetics of Tumours of Endocrine Organs*. Lyon: IARC Press; 2004. p. 33–4.
- Saraga-Babic M, Bazina M, Vukojevic K, Bocina I, Stefanovic V. Involvement of pro-apoptotic and anti-apoptotic factors in the early development of the human pituitary gland. *Histol Histopathol* 2008;23(10):1259–68.
- Schlechte JA. Clinical practice. Prolactinoma. *N Engl J Med* 2003;349(21):2035–41.
- Schneider HJ, Aimaretti G, Kreitschmann-Andermahr I, Stalla GK, Ghigo E. Hypopituitarism. *Lancet* 2007;369(9571):1461–70.
- Schulze F, Buhler K, Neubauer A, Kanitsar A, Holton L, Wolfsberger S. Intra-operative virtual endoscopy for image guided endonasal transphenoidal pituitary surgery. *Int J Comput Assist Radiol Surg* 2010;5(2):143–54.
- Semple PL, Jane JA, Lopes MB, Laws ER. Pituitary apoplexy: correlation between magnetic resonance imaging and histopathological results. *J Neurosurg* 2008;108(5):909–15.
- Sharp RJ. Land of the giants. *Growth Horm IGF Res* 2009;19(4):291–3.
- Sheehan HL. Post-partum necrosis of the anterior pituitary. *J Pathol Bact* 1937;45:189–214.
- Sherlock M, Aragon Alonso A, Reulen RC, Ayuk J, Clayton RN, Holder G, et al. Monitoring disease activity using GH and IGF-I in the follow-up of 501 patients with acromegaly. *Clin Endocrinol (Oxf)* 2009;71(1):74–81.
- Shi XE, Wu B, Fan T, Zhou ZQ, Zhang YL. Craniopharyngioma: surgical experience of 309 cases in China. *Clin Neurol Neurosurg* 2008;110(2):151–9.
- Shou XF, Wang YF, Li SQ, Wu JS, Zhao Y, Mao Y, et al. Microsurgical treatment for typical pituitary apoplexy with 44 patients, according to two pathological stages. *Minim Invasive Neurosurg* 2009;52(5–6):207–11.
- Sinha S, Sharma BS. Giant pituitary adenomas—an enigma revisited. Microsurgical treatment strategies and outcome in a series of 250 patients. *Br J Neurosurg* 2010;24(1):31–9.
- Smith ER, Loeffler J, Misra M, Pomerantz SR, Stemmer-Rachamimov A, Post MD. Case records of the Massachusetts General Hospital. Case 37—2008. A 17-year-old boy with a pituitary tumor and skull abnormalities. *N Engl J Med* 2008;359(22):2367–77.
- Spisek R, Kolouchova E, Jensovsky J, Rusina R, Fendrych P, Plas J, et al. Combined CNS and pituitary involvement as a primary manifestation of Wegener granulomatosis. *Clin Rheumatol* 2006;25(5):739–42.
- Tashiro T, Sano T, Xu B, Wakatsuki S, Kagawa N, Nishioka H, et al. Spectrum of different types of hypophysitis: a clinicopathologic study of hypophysitis in 31 cases. *Endocr Pathol* 2002;13(3):183–95.
- Trainer PJ, Drake WM, Katznelson L, Freda PU, Herman-Bonert V, van der Lely AJ, et al. Treatment of acromegaly with the growth hormone-receptor antagonist pegvisomant. *N Engl J Med* 2000;342(16):1171–7.
- Trainer PJ, Ezzat S, D'Souza GA, Layton G, Strasburger CJ. A randomized, controlled, multicentre trial comparing pegvisomant alone with combination therapy of pegvisomant and

- long-acting octreotide in patients with acromegaly. *Clin Endocrinol (Oxf)* 2009;71(4):549–57.
- Trouillas J, Barkan AL, Watson RE Jr, Lindell EP, Farrell WE, Lloyd RV. ACTH producing adenoma. In: DeLellis RA, Lloyd RV, Heitz PU, Eng C, editors. *World Health Organization Classification of Tumours. Pathology and Genetics of Tumours of Endocrine Organs*. Lyon: IARC Press; 2004. p. 26–9.
- Turton JP, Reynaud R, Mehta A, Torpiano J, Saveanu A, Woods KS, et al. Novel mutations within the POU1F1 gene associated with variable combined pituitary hormone deficiency. *J Clin Endocrinol Metab* 2005;90(8):4762–70.
- Ueda T, Yokoyama Y, Irahara M, Aono T. Influence of psychological stress on suckling-induced pulsatile oxytocin release. *Obstet Gynecol* 1994;84(2):259–62.
- Unlu E, Puyan FO, Bilgi S, Kemal Hamamcioglu M. Granulomatous hypophysitis: presentation and MRI appearance. *J Clin Neurosci* 2006;13(10):1062–6.
- Vaidya A, Morris CA, Ross JJ. Interactive medical case. Stalking the diagnosis. *N Engl J Med* 2010;362(6):e16.
- Válasi E, Biller BM, Swearingen B, Pecori Giraldi F, Losa M, Mortini P, et al. Delayed remission after transphenoidal surgery in patients with Cushing's disease. *J Clin Endocrinol Metab* 2010;95(2):601–10.
- Válasi E, Klibanski A, Biller BM. Clinical Review#. Potential cardiac valve effects of dopamine agonists in hyperprolactinemia. *J Clin Endocrinol Metab* 2010;95(3):1025–33.
- van Aken MO, Lamberts SW. Diagnosis and treatment of hypopituitarism: an update. *Pituitary* 2005;8(3–4):183–91.
- Vandervliet EJ, Vanhoenacker FM, De Praeter G, Vangeneugden J, Parizel PM. Symptomatic Rathke's cleft cyst. *JBR-BTR* 2009;92(3):180–1.
- Varan A, Cila A, Akyuz C, Kale G, Kutluk T, Buyukpamukcu M. Radiological evaluation of patients with pituitary Langerhans cell histiocytosis at diagnosis and at follow-up. *Pediatr Hematol Oncol* 2008;25(6):567–74.
- Vassallo R, Ryu JH, Schroeder DR, Decker PA, Limper AH. Clinical outcomes of pulmonary Langerhans-cell histiocytosis in adults. *N Engl J Med* 2002;346(7):484–90.
- Vella A, Young WF Jr. Pituitary apoplexy. *Endocrinologist* 2001;11:282–8.
- Verbalis JG, Goldsmith SR, Greenberg A, Schrier RW, Sterns RH. Hyponatremia treatment guidelines 2007: expert panel recommendations. *Am J Med* 2007;120(11 Suppl 1):S1–21.
- Vieira TC, Boldarin VT, Abucham J. Molecular analysis of PROP1, PTT1, HESX1, LHX3, and LHX4 shows high frequency of PROP1 mutations in patients with familial forms of combined pituitary hormone deficiency. *Arq Bras Endocrinol Metabol* 2007;51(7):1097–103.
- Vinchon M, Weill J, Delestret I, Dhellemmes P. Craniopharyngioma and hypothalamic obesity in children. *Childs Nerv Syst* 2009;25(3):347–52.
- Viswanathan V, Eugster EA. Etiology and treatment of hypogonadism in adolescents. *Endocrinol Metab Clin North Am* 2009;38(4):719–38.
- von Stebut E, Schadmand-Fischer S, Brauning W, Kreft A, Doberauer C, Steinbrink K. Successful treatment of adult multi-systemic Langerhans cell histiocytosis with psoralen-UV-A, prednisolone, mercaptopurine, and vinblastine. *Arch Dermatol* 2008;144(5):649–53.
- Watt A, Pobereskin L, Vaidya B. Pituitary apoplexy within a macroprolactinoma. *Nat Clin Pract Endocrinol Metab* 2008;4(11):635–41.
- Weiss G, Skurnick JH, Goldsmith LT, Santoro NF, Park SJ. Menopause and hypothalamic-pituitary sensitivity to estrogen. *JAMA* 2004;292(24):2991–6.
- Windebank K, Nanduri V. Langerhans cell histiocytosis. *Arch Dis Child* 2009;94(11):904–8.
- Yong TY, Li JY, Amato L, Mahadevan K, Phillips PJ, Coates PS, et al. Pituitary involvement in Wegener's granulomatosis. *Pituitary* 2008;11(1):77–84.
- Zada G, Ditty B, McNatt SA, McComb JG, Krieger MD. Surgical treatment of Rathke cleft cysts in children. *Neurosurgery* 2009;64(6):1132–1137; author reply 1037–1038.
- Zygmunt-Gorska A, Starzyk J, Adamek D, Radwanska E, Sucharski P, Herman-Sucharska I, et al. Pituitary enlargement in patients with PROP1 gene inactivating mutation represents cystic hyperplasia of the intermediate pituitary lobe. Histopathology and over 10 years follow-up of two patients. *J Pediatr Endocrinol Metab* 2009;22(7):653–60.
- Section 2: Thyroid**
- Abalovich M, Amino N, Barbour LA, Cobin RH, De Groot LJ, Glinner D, et al. Management of thyroid dysfunction during pregnancy and postpartum: an Endocrine Society Clinical Practice Guideline. *J Clin Endocrinol Metab* 2007;92(8 Suppl):S1–47.
- Asari R, Koperek O, Scheuba C, Riss P, Kaserer K, Hoffmann M, et al. Follicular thyroid carcinoma in an iodine-replete endemic goiter region: a prospectively collected, retrospectively analyzed clinical trial. *Ann Surg* 2009;249(6):1023–31.
- Bahn RS. Graves' ophthalmopathy. *N Engl J Med* 2010;362(8):726–38.
- Ball DW. Selectively targeting mutant BRAF in thyroid cancer. *J Clin Endocrinol Metab* 2010;95(1):60–1.
- Bartalena L, Tanda ML. Clinical practice. Graves' ophthalmopathy. *N Engl J Med* 2009;360(10):994–1001.
- Bindra A, Braunstein GD. Thyroiditis. *Am Fam Physician* 2006;73(10):1769–76.
- Boelaert K, Newby PR, Simmonds MJ, Holder RL, Carr-Smith JD, Heward JM, et al. Prevalence and relative risk of other autoimmune diseases in subjects with autoimmune thyroid disease. *Am J Med* 2010;123(2):183 e181–189.
- Bradly DP, Reddy V, Prinz RA, Gattuso P. Incidental papillary carcinoma in patients treated surgically for benign thyroid diseases. *Surgery* 2009;146(6):1099–104.
- Brent GA. Clinical practice. Graves' disease. *N Engl J Med* 2008;358(24):2594–605.
- Brent GA, Larsen PR, Davies TF. Hypothyroidism and thyroiditis. In: Kronenberg HM, Melmed S, Polonsky KS, Larsen PR, editors. *Williams Textbook of Endocrinology*. 11th ed. Philadelphia: Saunders; 2008. p. 377–410.
- Cantara S, Capezone M, Marchisotta S, Capuano S, Busonero G, Toti P, et al. Impact of proto-oncogene mutation detection in cytological specimens from thyroid nodules improves the diagnostic accuracy of cytology. *J Clin Endocrinol Metab* 2010;95(3):1365–9.
- Chan JK, C, Hirokawa M, Evnas H, Williams ED, Osamura Y, Cady B, Sobrinho-Simoes M, Derwahl M, Paschke R, Belge G, Oriola J, Studer H, Eng C, Asa SL, Lloyd RV, Baloch Z, Ghossein R, Mazzaferri E, Fagin JA. Follicular adenoma. In: DeLellis RA, Lloyd RV, Heitz PU, Eng C, editors. *World Health Organization Classification of Tumours. Pathology and Genetics of Tumours of Endocrine Organs*. Lyon: IARC Press; 2004. p. 98–103.
- Chen H, Nicol TL, Udelsman R. Clinically significant, isolated metastatic disease to the thyroid gland. *World J Surg* 1999;23(2):177–80; discussion 181.
- Cheung K, Roman SA, Wang TS, Walker HD, Sosa JA. Calcitonin measurement in the evaluation of thyroid nodules in the United States: a cost-effectiveness and decision analysis. *J Clin Endocrinol Metab* 2008;93(6):2173–80.
- Choi JS, Kim J, Kwak JY, Kim MJ, Chang HS, Kim EK. Pre-operative staging of papillary thyroid carcinoma: comparison of ultrasound imaging and CT. *AJR Am J Roentgenol* 2009;193(3):871–8.
- Cichon S, Anielski R, Konturek A, Barczynski M, Cichon W. Metastases to the thyroid gland: seventeen cases operated on in a single clinical center. *Langenbecks Arch Surg* 2006;391(6):581–7.
- Cooper DS. Hyperthyroidism. *Lancet* 2003;362(9382):459–68.
- Cooper DS. Approach to the patient with subclinical hyperthyroidism. *J Clin Endocrinol Metab* 2007;92(1):3–9.
- Corbetta C, Weber G, Cortinovis F, Calebiro D, Passoni A, Vigone MC, et al. A 7-year experience with low blood TSH cutoff levels for neonatal screening reveals an unsuspected frequency of congenital hypothyroidism (CH). *Clin Endocrinol (Oxf)* 2009;71(5):739–45.
- Couto JP, Prazeres H, Castro P, Lima J, Maximo V, Soares P, et al. How molecular pathology is changing and will change the therapeutics of patients with follicular cell-derived thyroid cancer. *J Clin Pathol* 2009;62(5):414–21.
- Davies L, Welch HG. Increasing incidence of thyroid cancer in the United States, 1973–2002. *JAMA* 2006;295(18):2164–7.
- Davies TF, Larsen PR. Thyrotoxicosis. In: Kronenberg HM, Melmed S, Polonsky KS, Larsen PR, editors. *Williams Textbook of Endocrinology*. 11th ed. Philadelphia: Saunders; 2008. p. 333–76.
- DeLellis R. Secondary tumours of the thyroid. In: DeLellis RA, Lloyd RV, Heitz PU, Eng C, editors. *World Health Organization Classification of Tumours. Pathology and Genetics of Tumours of Endocrine Organs*. Lyon: IARC Press; 2004. p. 122–3.
- Diez JJ. Goiter in adult patients aged 55 years and older: etiology and clinical features in 634 patients. *J Gerontol A Biol Sci Med Sci* 2005;60(7):920–3.
- Douglas RS, Afifiyan NF, Hwang CJ, Chong K, Haider U, Richards P, et al. Increased generation of fibrocytes in thyroid-associated ophthalmopathy. *J Clin Endocrinol Metab* 2010;95(1):430–8.
- Duggan MA, Di Francesco L, Alakija P, Falk V. A pathologic review of follicular thyroid neoplasms: the impact of changing the threshold for the diagnosis of the follicular variant of papillary thyroid carcinoma. *Surgery* 2009;145(6):687–8; author reply 688–689.
- Elisei R, Molinaro E, Agate L, Bottici V, Masserini L, Ceccarelli C, et al. Are the clinical and pathological features of differentiated thyroid carcinoma really changed over the last 35 years? Study on 4187 patients from a single Italian institution to answer this question. *J Clin Endocrinol Metab* 2010;95(4):1516–27.
- Eit D, Faquin WC, Gaz R, Randolph G, DeLellis RA, Pilch BZ. Histopathologic and clinical features of medullary microcarcinoma and C-cell hyperplasia in prophylactic thyroidectomies for medullary carcinoma: a study of 42 cases. *Arch Pathol Lab Med* 2008;132(11):1767–73.
- Fatourechi V, Aniszewski JP, Fatourechi GZ, Atkinson EJ, Jacobsen SJ. Clinical features and outcome of subacute thyroiditis in an incidence cohort: Olmsted County, Minnesota, study. *J Clin Endocrinol Metab* 2003;88(5):2100–5.
- Few J, Thompson NW, Angelos P, Simeone D, Giordano T, Reeve T. Riedel's thyroiditis: treatment with tamoxifen. *Surgery* 1996;120(6):993–8; discussion 998–999.
- Ghossein R. Problems and controversies in the histopathology of thyroid carcinomas of follicular cell origin. *Arch Pathol Lab Med* 2009;133(5):683–91.
- Giles Senyurek Y, Tunca F, Boztepe H, Alagol F, Terzioglu T, Tezelman S. The long term outcome of papillary thyroid carcinoma patients without primary central lymph node dissection: expected improvement of routine dissection. *Surgery* 2009;146(6):1188–95.
- Gopalakrishnan S, Chugh PK, Chhillar M, Ambardar VK, Sahoo M, Sankar R. Goitrous autoimmune thyroiditis in a pediatric population: a longitudinal study. *Pediatrics* 2008;122(3):e670–674.
- Gulcelik NE, Gulcelik MA, Kuru B. Risk of malignancy in patients with follicular neoplasm: predictive value of clinical and ultrasonographic features. *Arch Otolaryngol Head Neck Surg* 2008;134(12):1312–15.
- Hanief MR, Igali L, Grama D. Hurthle cell carcinoma: diagnostic and therapeutic implications. *World J Surg Oncol* 2004;2:27.
- Haugen BR, Kane MA. Approach to the thyroid cancer patient with extracervical metastases. *J Clin Endocrinol Metab* 2010;95(3):987–93.
- Haugen BR, Nawaz S, Cohn A, Shroyer K, Bunn PA Jr, Liechty DR, et al. Secondary malignancy of the thyroid gland: a case report and review of the literature. *Thyroid* 1994;4(3):297–300.
- Hay ID, Hutchinson ME, Gonzalez-Losada T, McIver B, Reinalda ME, Grant CS, et al. Papillary thyroid microcarcinoma: a study of 900 cases observed in a 60-year period. *Surgery* 2008;144(6):980–7; discussion 987–988.
- Hegedus L. Clinical practice. The thyroid nodule. *N Engl J Med* 2004;351(17):1764–71.
- Iraci GS, Fux-Otta C. Images in clinical medicine. Graves' hyperthyroidism. *N Engl J Med* 2009;360(24):e31.
- Kebebew E, Greenspan FS, Clark OH, Woebler KA, McMillan A. Anaplastic thyroid carcinoma. Treatment outcome and prognostic factors. *Cancer* 2005;103(7):1330–5.
- Klubo-Gwiezdzinska J, Wartofsky L. Thyrotropin blood levels, subclinical hypothyroidism, and the elderly patient. *Arch Intern Med* 2009;169(21):1949–51.
- Kushcheyeva Y, Duh QY, Kebebew E, Clark OH. Prognostic indications for Hurthle cell cancer. *World J Surg* 2004;28(12):1266–70.
- Lam KY, Lo CY. Metastatic tumors of the thyroid gland: a study of 79 cases in Chinese patients. *Arch Pathol Lab Med* 1998;122(1):37–41.
- Larson PR, Davies TF, Schlumberger MJ, Hay ID. Thyroid physiology and diagnostic evaluation of patients with thyroid disorders. In: Kronenberg HM, Melmed S, Polonsky KS, Larsen PR, editors. *Williams Textbook of Endocrinology*. 11th ed. Philadelphia: Saunders; 2008. p. 299–332.
- Lebouleux S, Schroeder PR, Buisaidi NL, Auperin A, Corone C, Jaculle HA, et al. Assessment of the incremental value of recombinant thyrotropin stimulation before 2-[18F]-Fluoro-2-deoxy-D-glucose positron emission tomography/computed tomography imaging to localize residual differentiated thyroid cancer. *J Clin Endocrinol Metab* 2009;94(4):1310–16.
- LiVolsi VA, Albores-Saavedra J, Asa SL, Balouch ZW, Sobrinho-Simoes M, Wenig B, DeLellis RA, Cady B, Mazzaferri EL, Hay I, Fagin JA, Weber AL, Caruso P, Voutilainen PE, Franssila KO, Williams ED, Schneider AB, Nikiforov Y, Rabes HM, Akslen L, Ezzat S, Santoro M, Eng C, Harach HR. Papillary carcinoma. In: DeLellis RA, Lloyd RV, Heitz PU, Eng C, editors. *World Health Organization Classification of Tumours. Pathology and Genetics of Tumours of Endocrine Organs*. Lyon: IARC Press; 2004. p. 57–66.
- Lloyd RV, Douglas BR, Young WF Jr. Parathyroid gland. In: King DW, editor. *Atlas of Nontumor Pathology: Endocrine Diseases*. 1st ed. Washington D.C.: American Registry of Pathology and the Armed Forces Institute of Pathology; 2002. p. 45–90.
- Matias-Guiu X, DeLellis R, Moley JF, Gagel RF, Albores-Saavedra J, Bussolati G, Kaserer K, Williams ED, Baloch Z. Medullary thyroid carcinoma. In: DeLellis RA, Lloyd RV, Heitz PU, Eng C, editors. *World Health Organization Classification of Tumours. Pathology and Genetics of Tumours of Endocrine Organs*. Lyon: IARC Press; 2004. p. 86–91.
- McDermott MT. In the clinic. Hypothyroidism. *Ann Intern Med* 2009;151(11):ITC61.



- McLachlan SM, Nagayama Y, Pichurin PN, Mizutori Y, Chen CR, Misharin A, et al. The link between Graves' disease and Hashimoto's thyroiditis: a role for regulatory T cells. *Endocrinology* 2007;148(12):5724-33.
- Menon MP, Khan A. Micro-RNAs in thyroid neoplasms: molecular, diagnostic and therapeutic implications. *J Clin Pathol* 2009;62(11):978-85.
- Michels AW, Eisenbarth GS. Immunologic endocrine disorders. *J Allergy Clin Immunol* 2010;125(2 Suppl 2):S226-237.
- Moo-Young TA, Traugott AL, Moley JF. Sporadic and familial medullary thyroid carcinoma: state of the art. *Surg Clin North Am* 2009;89(5):1193-204.
- Morris JC. How do you approach the problem of TSH elevation in a patient on high-dose thyroid hormone replacement? *Clin Endocrinol (Oxf)* 2009;70(5):671-3.
- Moshynska OV, Saxena A. Clonal relationship between Hashimoto thyroiditis and thyroid lymphoma. *J Clin Pathol* 2008;61(4):438-44.
- Nakhjavani MK, Gharib H, Goellner Jr, van Heerden JA. Metastasis to the thyroid gland. A report of 43 cases. *Cancer* 1997;79(3):574-8.
- Nyirenda MJ, Taylor PN, Stoddart M, Beckett GJ, Toft AD. Thyroid-stimulating hormone-receptor antibody and thyroid hormone concentrations in smokers vs nonsmokers with Graves disease treated with carbimazole. *JAMA* 2009;301(2):162-4.
- Okosieme OE, Chan D, Price SA, Lazarus JH, Premawardhana LD. The utility of radioiodine uptake and thyroid scintigraphy in the diagnosis and management of hyperthyroidism. *Clin Endocrinol (Oxf)* 2010;72(1):122-7.
- O'Neill JP, O'Neill B, Condron C, Walsh M, Bouchier-Hayes D. Anaplastic (undifferentiated) thyroid cancer: improved insight and therapeutic strategy into a highly aggressive disease. *J Laryngol Otol* 2005;119(8):585-91.
- Ordóñez N, Baloch Z, Matias-Guiu X, Evans H, Farid NR, Fagin JA, Kitamura Y, Tallini G, Eng C, Haigh PI, Faquin WC, Sugitani I, Giuffrida D, Boerner S. Undifferentiated (anaplastic) carcinoma. In: DeLellis RA, Lloyd RV, Heitz PU, Eng C, editors. *World Health Organization Classification of Tumours. Pathology and Genetics of Tumours of Endocrine Organs*. Lyon: IARC Press; 2004. p. 77-80.
- Pacifico F, Crescenzi E, Mellone S, Iannetti A, Porrino N, Liguoro D, et al. Nuclear factor- $\kappa$ B contributes to anaplastic thyroid carcinomas through up-regulation of miR-146a. *J Clin Endocrinol Metab* 2010;95(3):1421-30.
- Pan D, Shin YH, Gopalakrishnan G, Hennessey J, De Groot LJ. Regulatory T cells in Graves' disease. *Clin Endocrinol (Oxf)* 2009;71(4):587-93.
- Papi G, LiVolsi VA. Current concepts on Riedel thyroiditis. *Am J Clin Pathol* 2004;121(Suppl):S50-63.
- Peter F, Muzsnai A. Congenital disorders of the thyroid: hypo/hyper. *Endocrinol Metab Clin North Am* 2009;38(3):491-507.
- Pharoah PO. Thyroid hormones and embryogenesis. *J Pediatr* 2009;155(3):455-6; author reply 456-457.
- Raef H, Al-Rijjal R, Al-Shehri S, Zou M, Al-Mana H, Baitei EY, et al. Biallelic p.R2223H mutation in the thyroglobulin gene causes thyroglobulin retention and severe hypothyroidism with subsequent development of thyroid carcinoma. *J Clin Endocrinol Metab* 2010;95(3):1000-6.
- Raymond J, LaFranchi SH. Fetal and neonatal thyroid function: review and summary of significant new findings. *Curr Opin Endocrinol Diabetes Obes* 2010;17(1):1-7.
- Razvi S, Weaver JU, Vanderpump MP, Pearce SH. The incidence of ischemic heart disease and mortality in people with subclinical hypothyroidism: reanalysis of the Whickham Survey cohort. *J Clin Endocrinol Metab* 2010;95(4):1734-40.
- Rivkees SA, Mattison DR. Ending propylthiouracil-induced liver failure in children. *N Engl J Med* 2009;360(15):1574-5.
- Roelfsema F, Pereira AM, Adriaanse R, Endert E, Fliers E, Romijn JA, et al. Thyrotropin secretion in mild and severe primary hypothyroidism is distinguished by amplified burst mass and basal secretion with increased spikiness and approximate entropy. *J Clin Endocrinol Metab* 2010;95(2):928-34.
- Roman S, Lin R, Sosa JA. Prognosis of medullary thyroid carcinoma: demographic, clinical, and pathologic predictors of survival in 1252 cases. *Cancer* 2006;107(9):2134-42.
- Schlumberger MJ, Filetti S, Hay ID. Nontoxic diffuse and nodular goiter and thyroid neoplasia. In: Kronenberg HM, Melmed S, Polonsky KS, Larsen PR, editors. *Williams Textbook of Endocrinology*. 11th ed. Philadelphia: Saunders; 2008. p. 411-44.
- Shakoor SK, Aldibbiat A, Ingoe LE, Campbell SC, Sibal L, Shaw J, et al. Endothelial progenitor cells in subclinical hypothyroidism: the effect of thyroid hormone replacement therapy. *J Clin Endocrinol Metab* 2010;95(1):319-22.
- Sillery JC, Reading CC, Charboneau JW, Henrichsen TL, Hay ID, Mandrekar JN. Thyroid follicular carcinoma: sonographic features of 50 cases. *AJR Am J Roentgenol* 2010;194(1):44-54.
- Simonsick NM, Newman AB, Ferrucci L, Satterfield S, Harris TB, Rodondi N, et al. Subclinical hypothyroidism and functional mobility in older adults. *Arch Intern Med* 2009;169(21):2011-17.
- Sobrinho-Simoes M, Asa SL, Kroll TG, Nikiforov Y, DeLellis R, Farid P, Kitamura Y, Noguchi SU, Eng C, Harach HR, Williams ED, Schneider AB, Fagin JA, Ghossein RA, Mazzaferri EL, Lloyd RV, LiVolsi V, Chan JK. C, Baloch Z, Clark OH. Follicular carcinoma. In: DeLellis RA, Lloyd RV, Heitz PU, Eng C, editors. *World Health Organization Classification of Tumours. Pathology and Genetics of Tumours of Endocrine Organs*. Lyon: IARC Press; 2004. p. 67-72.
- Song Y, Ruf J, Lothaire P, Dequanter D, Andry G, Willemse E, et al. Association of duoxes with thyroid peroxidase and its regulation in thyrocytes. *J Clin Endocrinol Metab* 2010;95(1):375-82.
- Stiebel-Kalish H, Robenshtok E, Hasanreisoglu M, Ezrachi D, Shimon I, Leibovici L. Treatment modalities for Graves' ophthalmopathy: systematic review and metaanalysis. *J Clin Endocrinol Metab* 2009;94(8):2708-16.
- Stucchi CM, Vaccaro V, Magherini A, Di Gregorio C, Greco G, Livolsi VA, et al. Hurthle cell follicular carcinoma of the thyroid gland presenting with diffuse meningeal carcinomatosis and evolving to anaplastic carcinoma. *J Clin Pathol* 2007;60(7):831-2.
- Suliburk J, Delbridge L. Surgical management of well-differentiated thyroid cancer: state of the art. *Surg Clin North Am* 2009;89(5):1171-91.
- Surks MI, Boucai L. Age- and race-based serum thyrotropin reference limits. *J Clin Endocrinol Metab* 2010;95(2):496-502.
- Toft A. Bioequivalence of generic preparations of levothyroxine. *Clin Endocrinol (Oxf)* 2009;71(4):603; author reply 603-4.
- Toft AD. Clinical practice. Subclinical hyperthyroidism. *N Engl J Med* 2001;345(7):512-16.
- Wang Y, Tsang R, Asa S, Dickson B, Arenovich T, Brierley J. Clinical outcome of anaplastic thyroid carcinoma treated with radiotherapy of once- and twice-daily fractionation regimens. *Cancer* 2006;107(8):1786-92.
- Wolpin BM, Weller PF, Katz JT, Levy BD, Loscalzo J. Clinical problem-solving. The writing on the wall. *N Engl J Med* 2009;361(14):1387-92.

### Section 3: Adrenal

- Anagnostis P, Athyros VG, Tziomalos K, Karagiannis A, Mikhailidis DP. Clinical review: The pathogenetic role of cortisol in the metabolic syndrome: a hypothesis. *J Clin Endocrinol Metab* 2009;94(8):2692-701.
- Arlt W. The approach to the adult with newly diagnosed adrenal insufficiency. *J Clin Endocrinol Metab* 2009;94(4):1059-67.
- Arlt W, Walker EA, Draper N, Ivison HE, Ride JP, Hammer F, et al. Congenital adrenal hyperplasia caused by mutant P450 oxidoreductase and human androgen synthesis: analytical study. *Lancet* 2004;363(9427):2128-35.
- Armengaud JB, Charkaluk ML, Trivin C, Tardy V, Breart G, Brauner R, et al. Precocious pubarche: distinguishing late-onset congenital adrenal hyperplasia from premature adrenarche. *J Clin Endocrinol Metab* 2009;94(8):2835-40.
- Auchus RJ, Michaelis C, Wians FH Jr, Dolmatch BL, Josephs SC, Trimmer CK, et al. Rapid cortisol assays improve the success rate of adrenal vein sampling for primary aldosteronism. *Ann Surg* 2009;249(2):318-21.
- Baid SK, Lai EW, Wesley RA, Ling A, Timmers HJ, Adams KT, et al. Brief communication: radiographic contrast infusion and catecholamine release in patients with pheochromocytoma. *Ann Intern Med* 2009;150(1):27-32.
- Baid SK, Rubino D, Sinai N, Ramsey S, Frank A, Nieman LK. Specificity of screening tests for Cushing's syndrome in an overweight and obese population. *J Clin Endocrinol Metab* 2009;94(10):3857-64.
- Basaria S. Androgen abuse in athletes: detection and consequences. *J Clin Endocrinol Metab* 2010;95(4):1533-43.
- Bens S, Mohn A, Yuksel B, Kulle AE, Michalek M, Chiarelli F, et al. Congenital lipid adrenal hyperplasia: functional characterization of three novel mutations in the STAR gene. *J Clin Endocrinol Metab* 2010;95(3):1301-8.
- Bergthorsdottir R, Leonsson-Zachrisson M, Oden A, Johannsson G. Premature mortality in patients with Addison's disease: a population-based study. *J Clin Endocrinol Metab* 2006;91(12):4849-53.
- Bertherat J, Horvath A, Groussin L, Grabar S, Boikos S, Cazabat L, et al. Mutations in regulatory subunit type 1A of cyclic adenosine 5'-monophosphate-dependent protein kinase (PRKARIA): phenotype analysis in 353 patients and 80 different genotypes. *J Clin Endocrinol Metab* 2009;94(6):2085-91.
- Bessell-Browne R, O'Malley ME. CT of pheochromocytoma and paraganglioma: risk of adverse events with i.v. administration of nonionic contrast material. *AJR Am J Roentgenol* 2007;188(4):970-4.
- Bidet M, Bellanne-Chantelot C, Galand-Portier MB, Golmard JL, Tardy V, Morel Y, et al. Fertility in women with nonclassical congenital adrenal hyperplasia due to 21-hydroxylase deficiency. *J Clin Endocrinol Metab* 2010;95(3):1182-90.
- Bidet M, Bellanne-Chantelot C, Galand-Portier MB, Tardy V, Billaud L, Laborde K, et al. Clinical and molecular

- characterization of a cohort of 161 unrelated women with non-classical congenital adrenal hyperplasia due to 21-hydroxylase deficiency and 330 family members. *J Clin Endocrinol Metab* 2009;94(5):1570-8.
- Biller BM, Grossman AB, Stewart PM, Melmed S, Bertagna X, Bertherat J, et al. Treatment of adrenocorticotropic-dependent Cushing's syndrome: a consensus statement. *J Clin Endocrinol Metab* 2008;93(7):2454-62.
- Bonfig W, Pozza SB, Schmidt H, Pagel P, Knorr D, Schwarz HP. Hydrocortisone dosing during puberty in patients with classical congenital adrenal hyperplasia: an evidence-based recommendation. *J Clin Endocrinol Metab* 2009;94(10):3882-8.
- Born-Frontsberg E, Reincke M, Rump LC, Hahner S, Diederich S, Lorenz R, et al. Cardiovascular and cerebrovascular comorbidities of hypokalemic and normokalemic primary aldosteronism: results of the German Conn's Registry. *J Clin Endocrinol Metab* 2009;94(4):1125-30.
- Bornstein SR. Predisposing factors for adrenal insufficiency. *N Engl J Med* 2009;360(22):2328-39.
- Boscaro M, Arnaldi G. Approach to the patient with possible Cushing's syndrome. *J Clin Endocrinol Metab* 2009;94(9):3121-31.
- Brown ML, Zayas GE, Abel MD, Young WF Jr, Schaff HV. Mediastinal paragangliomas: the mayo clinic experience. *Ann Thorac Surg* 2008;86(3):946-51.
- Bruynzeel H, Feelders RA, Groenland TH, van den Meiracker AH, van Eijck CH, Lange JF, et al. Risk Factors for Hemodynamic Instability during Surgery for Pheochromocytoma. *J Clin Endocrinol Metab* 2010;95(2):678-85.
- Canzanello VJ, Garovic VD. Renal vascular disease: a vexing challenge for the clinician. *Prog Cardiovasc Dis* 2009;52(3):181-3.
- Cardoso EM, Arregger AL, Tumilasci OR, Contreras LN. Diagnostic value of salivary cortisol in Cushing's syndrome (CS). *Clin Endocrinol (Oxf)* 2009;70(4):516-21.
- Carney JA, Gordon H, Carpenter PC, Shenoy BV, Go VL. The complex of myxomas, spotty pigmentation, and endocrine over-activity. *Medicine (Baltimore)* 1985;64(4):270-83.
- Chow JT, Thompson GB, Grant CS, Farley DR, Richards ML, Young WF Jr. Bilateral laparoscopic adrenalectomy for corticotropin-dependent Cushing's syndrome: a review of the Mayo Clinic experience. *Clin Endocrinol (Oxf)* 2008;68(4):513-19.
- Chrysochou C, Kalra PA. Epidemiology and natural history of atherosclerotic renovascular disease. *Prog Cardiovasc Dis* 2009;52(3):184-95.
- Cooper MS, Stewart PM. 11Beta-hydroxysteroid dehydrogenase type 1 and its role in the hypothalamus-pituitary-adrenal axis, metabolic syndrome, and inflammation. *J Clin Endocrinol Metab* 2009;94(12):4645-54.
- Covic A, Gusbeth-Tatomir P. The role of the renin-angiotensin-aldosterone system in renal artery stenosis, renovascular hypertension, and ischemic nephropathy: diagnostic implications. *Prog Cardiovasc Dis* 2009;52(3):204-8.
- Daunt N. Adrenal vein sampling: how to make it quick, easy, and successful. *Radiographics* 2005;25(Suppl 1):S143-58.
- Donadille B, Groussin L, Waintrop C, Abbas H, Tenenbaum F, Dugue MA, et al. Management of Cushing's syndrome due to ectopic adrenocorticotropic secretion with 1,ortho-1, para'-dichloro-diphenyl-dichloro-ethane: findings in 23 patients from a single center. *J Clin Endocrinol Metab* 2010;95(2):537-44.
- Douma S, Petidis K, Doumas M, Papaefthimiou P, Triantafyllou A, Kartali N, et al. Prevalence of primary hyperaldosteronism in resistant hypertension: a retrospective observational study. *Lancet* 2008;371(9628):1921-6.
- Eisenhofer G, Bornstein SR, Brouwers FM, Cheung NK, Dahia PL, de Krijger RR, et al. Malignant pheochromocytoma: current status and initiatives for future progress. *Endocr Relat Cancer* 2004;11(3):423-36.
- Elfstrom P, Montgomery SM, Kampe O, Ekblom A, Ludvigsson JF. Risk of primary adrenal insufficiency in patients with celiac disease. *J Clin Endocrinol Metab* 2007;92(9):3595-8.
- Elliott DD, Pitman MB, Bloom L, Faquin WC. Fine-needle aspiration biopsy of Hurthle cell lesions of the thyroid gland: A cytomorphologic study of 139 cases with statistical analysis. *Cancer* 2006;108(2):102-9.
- Erichsen MM, Lovas K, Skiningsrud B, Wolff AB, Ludlien DE, Svartberg J, et al. Clinical, immunological, and genetic features of autoimmune primary adrenal insufficiency: observations from a Norwegian registry. *J Clin Endocrinol Metab* 2009;94(12):4882-90.
- Erickson D, Huston J, 3rd Young WF Jr, Carpenter PC, Wermers RA, Bonelli FS, et al. Internal jugular vein sampling in adrenocorticotropic hormone-dependent Cushing's syndrome: a comparison with inferior petrosal sinus sampling. *Clin Endocrinol (Oxf)* 2004;60(4):413-19.
- Eric Z, Neumann HP. When should genetic testing be obtained in a patient with pheochromocytoma or paraganglioma? *Clin Endocrinol (Oxf)* 2009;70(3):354-7.
- Freel EM, Stanson AW, Thompson GB, Grant CS, Farley DR, Richards ML, et al. Adrenal venous sampling for catecholamines:

- a normal value study. *J Clin Endocrinol Metab* 2010;95(3):1328–32.
- Frisen L, Nordenstrom A, Falhammar H, Filipsson H, Holmdahl G, Janson PO, et al. Gender role behavior, sexuality, and psychosocial adaptation in women with congenital adrenal hyperplasia due to CYP21A2 deficiency. *J Clin Endocrinol Metab* 2009;94(9):3432–9.
- Funder JW. Aldosterone and mineralocorticoid receptors in the cardiovascular system. *Prog Cardiovasc Dis* 2010;52(5):393–400.
- Funder JW, Carey RM, Fardella C, Gomez-Sanchez CE, Mantero F, Stowasser M, et al. Case detection, diagnosis, and treatment of patients with primary aldosteronism: an endocrine society clinical practice guideline. *J Clin Endocrinol Metab* 2008;93(9):3266–81.
- Gaal J, Burnichon N, Korpershoek E, Roncelin I, Bertherat J, Plouin PF, et al. Isocitrate dehydrogenase mutations are rare in pheochromocytomas and paragangliomas. *J Clin Endocrinol Metab* 2010;95(3):1274–8.
- Ghossein RA, Hiltzik DH, Carlson DL, Patel S, Shaha A, Shah JP, et al. Prognostic factors of recurrence in encapsulated Hurthle cell carcinoma of the thyroid gland: a clinicopathologic study of 50 cases. *Cancer* 2006;106(8):1669–76.
- Gittens PR Jr, Solish AF, Trabulsi EJ. Surgical management of metastatic disease to the adrenal gland. *Semin Oncol* 2008;35(2):172–6.
- Guerrero MA, Schreinemakers JM, Vriens MR, Suh I, Hwang J, Shen WT, et al. Clinical spectrum of pheochromocytoma. *J Am Coll Surg* 2009;209(6):727–32.
- Haigh PI, Urbach DR. The treatment and prognosis of Hurthle cell follicular thyroid carcinoma compared with its non-Hurthle cell counterpart. *Surgery* 2005;138(6):1152–7; discussion 1157–8.
- Havekes B, King K, Lai EW, Romijn JA, Corssmit EP, Pacak K. New imaging approaches to pheochromocytomas and paragangliomas. *Clin Endocrinol (Oxf)* 2010;72:137–45.
- Karrer-Voegeli S, Rey F, Raymond MJ, Meuwly JY, Gaillard RC, Gomez F. Androgen dependence of hirsutism, acne, and alopecia in women: retrospective analysis of 228 patients investigated for hyperandrogenism. *Medicine (Baltimore)* 2009;88(1):32–45.
- Kempers MJ, Lenders JW, van Oudeusden L, van der Wilt GJ, Schultze Kool LJ, Hermus AR, et al. Systematic review: diagnostic procedures to differentiate unilateral from bilateral adrenal abnormality in primary aldosteronism. *Ann Intern Med* 2009;151(5):329–37.
- Kim SH, Brennan MF, Russo P, Burt ME, Coit DG. The role of surgery in the treatment of clinically isolated adrenal metastasis. *Cancer* 1998;82(2):389–94.
- Kimura N, Capella C, De Krijger RR, Thompson LD, R, Lam KY, Komminoth P, Tischler AS, Young WF Jr. Extra-adrenal sympathetic paraganglioma: superior and inferior paraaortic. In: DeLellis RA, Lloyd RV, Heitz PU, Eng C, editors. *World Health Organization Classification of Tumours. Pathology and Genetics of Tumours of Endocrine Organs*. Lyon: IARC Press; 2004. p. 164–5.
- Kong MF, Lawden M, Howlett T. The Addison's disease dilemma—autoimmune or ALD? *Lancet* 2008;371(9628):1970.
- Kudva YC, Sawka AM, Young WF Jr. Clinical review 164: The laboratory diagnosis of adrenal pheochromocytoma: the Mayo Clinic experience. *J Clin Endocrinol Metab* 2003;88(10):4533–9.
- Lam KY, Lo CY. Metastatic tumours of the adrenal glands: a 30-year experience in a teaching hospital. *Clin Endocrinol (Oxf)* 2002;56(1):95–101.
- Lenders JW, Pacak K, Huynh TT, Sharabi Y, Mannelli M, Bratslavsky G, et al. Low sensitivity of glucagon provocative testing for diagnosis of pheochromocytoma. *J Clin Endocrinol Metab* 2010;95(1):238–45.
- Lerman LO, Textor SC, Grande JP. Mechanisms of tissue injury in renal artery stenosis: ischemia and beyond. *Prog Cardiovasc Dis* 2009;52(3):196–203.
- Lloyd RV, Douglas BR, Young WF Jr. Adrenal gland. In: King DW, editor. *Atlas of Nontumor Pathology: Endocrine Diseases*. 1st ed. Washington D.C.: American Registry of Pathology and the Armed Forces Institute of Pathology; 2002. p. 171–257.
- Lloyd RV, Kawashima A, Tischler AS. Secondary tumours. In: DeLellis RA, Lloyd RV, Heitz PU, Eng C, editors. *World Health Organization Classification of Tumours. Pathology and Genetics of Tumours of Endocrine Organs*. Lyon: IARC Press; 2004. p. 172–3.
- Lo CY, van Heerden JA, Soreide JA, Grant CS, Thompson GB, Lloyd RV, et al. Adrenalectomy for metastatic disease to the adrenal glands. *Br J Surg* 1996;83(4):528–31.
- Louiset E, Stratakis CA, Perraudin V, Griffin KJ, Libe R, Cabrol S, et al. The paradoxical increase in cortisol secretion induced by dexamethasone in primary pigmented nodular adrenocortical disease involves a glucocorticoid receptor-mediated effect of dexamethasone on protein kinase A catalytic subunits. *J Clin Endocrinol Metab* 2009;94(7):2406–13.
- Mandel LR. Endocrine and autoimmune aspects of the health history of John F. Kennedy. *Ann Intern Med* 2009;151(5):350–4.
- Marik PE, Varon J. Requirement of perioperative stress doses of corticosteroids: a systematic review of the literature. *Arch Surg* 2008;143(12):1222–6.
- McMahon GT, Blake MA, Wu CL. Case records of the Massachusetts General Hospital. Case 1–2010. A 75-year-old man with hypertension, hyperglycemia, and edema. *N Engl J Med* 2010;362(2):156–66.
- McNicol AM, Young WF Jr, Kawashima A, Komminoth P, Tischler AS. Benign pheochromocytoma. In: DeLellis RA, Lloyd RV, Heitz PU, Eng C, editors. *World Health Organization Classification of Tumours. Pathology and Genetics of Tumours of Endocrine Organs*. Lyon: IARC Press; 2004. p. 151–5.
- Melck A, Bugis S, Baliski C, Irvine R, Anderson DW, Wilkins G, et al. Hemithyroidectomy: the preferred initial surgical approach for management of Hurthle cell neoplasm. *Am J Surg* 2006;191(5):593–7.
- Merke DP. Approach to the adult with congenital adrenal hyperplasia due to 21-hydroxylase deficiency. *J Clin Endocrinol Metab* 2008;93(3):653–60.
- Metherell LA, Naville D, Halaby G, Begeot M, Huebner A, Nurnberg G, et al. Nonclassic lipid congenital adrenal hyperplasia masquerading as familial glucocorticoid deficiency. *J Clin Endocrinol Metab* 2009;94(10):3865–71.
- Mulatero P, Bertello C, Sukor N, Gordon R, Rossato D, Daunt N, et al. Impact of different diagnostic criteria during adrenal vein sampling on reproducibility of subtype diagnosis in patients with primary aldosteronism. *Hypertension* 2010;55(3):667–73.
- Mulatero P, Stowasser M, Loh KC, Fardella CE, Gordon RD, Mosso L, et al. Increased diagnosis of primary aldosteronism, including surgically correctable forms, in centers from five continents. *J Clin Endocrinol Metab* 2004;89(3):1045–50.
- Neumann HP, Bausch B, McWhinney SR, Bender BU, Gimm O, Franke G, et al. Germ-line mutations in nonsyndromic pheochromocytoma. *N Engl J Med* 2002;346(19):1459–66.
- New MI. Extensive clinical experience: nonclassical 21-hydroxylase deficiency. *J Clin Endocrinol Metab* 2006;91(11):4205–14.
- Nieman LK, Biller BM, Findling JW, Newell-Price J, Savage MO, Stewart PM, et al. The diagnosis of Cushing's syndrome: an Endocrine Society Clinical Practice Guideline. *J Clin Endocrinol Metab* 2008;93(5):1526–40.
- Parajes S, Loidi L, Reisch N, Dhir V, Rose IT, Hampel R, et al. Functional consequences of seven novel mutations in the CYP11B1 gene: four mutations associated with nonclassic and three mutations causing classic 11[beta]-hydroxylase deficiency. *J Clin Endocrinol Metab* 2010;95(2):779–88.
- Pereira AM, Hes FJ, Horvath A, Woortman S, Greene E, Bimpaki E, et al. Association of the M1V PRKARIA mutation with primary pigmented nodular adrenocortical disease in two large families. *J Clin Endocrinol Metab* 2010;95(1):338–42.
- Perry CG, Sawka AM, Singh R, Thabane L, Bajnarek J, Young WF Jr. The diagnostic efficacy of urinary fractionated metanephrines measured by tandem mass spectrometry in detection of pheochromocytoma. *Clin Endocrinol (Oxf)* 2007;66(5):703–8.
- Petri BJ, van Eijck CH, de Herder WW, Wagner A, de Krijger RR. Pheochromocytomas and sympathetic paragangliomas. *Br J Surg* 2009;96(12):1381–92.
- Pham TH, Moir C, Thompson GB, Zarroug AE, Hamner CE, Farley D, et al. Pheochromocytoma and paraganglioma in children: a review of medical and surgical management at a tertiary care center. *Pediatrics* 2006;118(3):1109–17.
- Porterfield Jr, Thompson GB, Young WF Jr, Chow JT, Fryrear RS, van Heerden JA, et al. Surgery for Cushing's syndrome: an historical review and recent ten-year experience. *World J Surg* 2008;32(5):659–77.
- Powell AC, Stratakis CA, Patronas NJ, Steinberg SM, Batista D, Alexander HR, et al. Operative management of Cushing syndrome secondary to micronodular adrenal hyperplasia. *Surgery* 2008;143(6):750–8.
- Raff H. Utility of salivary cortisol measurements in Cushing's syndrome and adrenal insufficiency. *J Clin Endocrinol Metab* 2009;94(10):3647–55.
- Reincke M, Rump LC, Quinkler M, Hahner S, Diederich S, Lorenz R, et al. Risk factors associated with a low glomerular filtration rate in primary aldosteronism. *J Clin Endocrinol Metab* 2009;94(3):869–75.
- Rossi GP, Belfiore A, Bernini G, Fabris B, Caridi G, Ferri C, et al. Body mass index predicts plasma aldosterone concentrations in overweight-obese primary hypertensive patients. *J Clin Endocrinol Metab* 2008;93(7):2566–71.
- Rossi GP, Bernini G, Caliumi C, Desideri G, Fabris B, Ferri C, et al. A prospective study of the prevalence of primary aldosteronism in 1,125 hypertensive patients. *J Am Coll Cardiol* 2006;48(11):2293–300.
- Sasano H, Young WF Jr, Chrousos GP, Koch CA, Giordano TJ, Kawashima A. Adrenal cortical adenoma. In: DeLellis RA, Lloyd RV, Heitz PU, Eng C, editors. *World Health Organization Classification of Tumours. Pathology and Genetics of Tumours of Endocrine Organs*. Lyon: IARC Press; 2004. p. 139–42.
- Whaley-Connell A, Johnson MS, Sowers JR. Aldosterone: role in the cardiometabolic syndrome and resistant hypertension. *Prog Cardiovasc Dis* 2010;52(5):401–9.
- Classification of Tumours. Pathology and Genetics of Tumours of Endocrine Organs. Lyon: IARC Press; 2004. p. 143–6.
- Sechi LA, Di Fabio A, Bazzocchi M, Uzzau A, Catena C. Intrarenal hemodynamics in primary aldosteronism before and after treatment. *J Clin Endocrinol Metab* 2009;94(4):1191–7.
- Sechi LA, Novello M, Lapenna R, Baroselli S, Nadalini E, Colussi GL, et al. Long-term renal outcomes in patients with primary aldosteronism. *JAMA* 2006;295(22):2638–45.
- Shulman DI, Palmert MR, Kemp SF. Adrenal insufficiency: still a cause of morbidity and death in childhood. *Pediatrics* 2007;119(2):e484–94.
- Sjoqvist F, Garle M, Rane A. Use of doping agents, particularly anabolic steroids, in sports and society. *Lancet* 2008;371(9627):1872–82.
- Stewart PM. The adrenal cortex. In: Kronenberg HM, Melmed S, Polonsky KS, Larsen PR, editors. *Williams Textbook of Endocrinology*. 11th ed. Philadelphia: Saunders; 2008. p. 445–504.
- Stratakis CA, Carney JA. Carney complex. In: DeLellis RA, Lloyd RV, Heitz PU, Eng C, editors. *World Health Organization Classification of Tumours. Pathology and Genetics of Tumours of Endocrine Organs*. Lyon: IARC Press; 2004. p. 249–52.
- Stratakis CA, Kirschner LS, Carney JA. Clinical and molecular features of the Carney complex: diagnostic criteria and recommendations for patient evaluation. *J Clin Endocrinol Metab* 2001;86(9):4041–6.
- Stratakis CA, Sarlis N, Kirschner LS, Carney JA, Doppman JL, Nieman LK, et al. Paradoxical response to dexamethasone in the diagnosis of primary pigmented nodular adrenocortical disease. *Ann Intern Med* 1999;131(8):585–91.
- Sukor N, Kogovsek C, Gordon RD, Robson D, Stowasser M. Improved quality of life, blood pressure, and biochemical status following laparoscopic adrenalectomy for unilateral primary aldosteronism. *J Clin Endocrinol Metab* 2010;95(3):1360–4.
- Swain JM, Grant CS, Schlinkert RT, Thompson GB, vanHeerden JA, Lloyd RV, et al. Corticotropin-independent macronodular adrenal hyperplasia: a clinicopathologic correlation. *Arch Surg* 1998;133(5):541–5; discussion 545–546.
- Tardy V, Menassa R, Sulmont V, Lienhardt-Roussie A, Lecointre C, Brauner R, et al. Phenotype-genotype correlations of 13 rare CYP21A2 mutations detected in 46 patients affected with 21-hydroxylase deficiency and in one carrier. *J Clin Endocrinol Metab* 2010;95(3):1288–300.
- Textor SC. Current approaches to renovascular hypertension. *Med Clin North Am* 2009;93(3):717–32.
- Thompson LD, R, Young WF Jr, Kawashima A, Komminoth P, Tischler AS. Malignant adrenal pheochromocytoma. In: DeLellis RA, Lloyd RV, Heitz PU, Eng C, editors. *World Health Organization Classification of Tumours. Pathology and Genetics of Tumours of Endocrine Organs*. Lyon: IARC Press; 2004. p. 147–50.
- Timmers HJ, Chen CC, Carrasquillo JA, Whatley M, Ling A, Havekes B, et al. Comparison of 18F-fluoro-L-DOPA, 18F-fluoro-deoxyglucose, and 18F-fluorodopamine PET and 123I-MIBG scintigraphy in the localization of pheochromocytoma and paraganglioma. *J Clin Endocrinol Metab* 2009;94(12):4757–67.
- Todd GR, Acerini CL, Ross-Russell R, Zahra S, Warner JT, McCance D. Survey of adrenal crisis associated with inhaled corticosteroids in the United Kingdom. *Arch Dis Child* 2002;87(6):457–61.
- Valassi E, Swearingen B, Lee H, Nachtigall LB, Donoho DA, Klibanski A, et al. Concomitant medication use can confound interpretation of the combined dexamethasone-corticotropin releasing hormone test in Cushing's syndrome. *J Clin Endocrinol Metab* 2009;94(12):4851–9.
- van Helvoort-Postulard D, Dirksen CD, Nelemans PJ, Kroon AA, Kessels AG, de Leeuw PW, et al. Renal artery stenosis: cost-effectiveness of diagnosis and treatment. *Radiology* 2007;244(2):505–13.
- Van Zaane B, Nur E, Squizzato A, Dekkers OM, Twickler MT, Fliers E, et al. Hypercoagulable state in Cushing's syndrome: a systematic review. *J Clin Endocrinol Metab* 2009;94(8):2743–50.
- Vanderveen KA, Thompson SM, Callstrom MR, Young WF Jr, Grant CS, Farley DR, et al. Biopsy of pheochromocytomas and paragangliomas: potential for disaster. *Surgery* 2009;146(6):1158–66.
- Venkatesan AM, Locklin J, Lai EW, Adams KT, Fojo AT, Pacak K, et al. Radiofrequency ablation of metastatic pheochromocytoma. *J Vasc Interv Radiol* 2009;20(11):1483–90.
- Weiss LM, Bertagna X, Chrousos GP, Kawashima A, Kleihues P, Koch CA, Giordano TJ, Medeiros LJ, Merino MJ, Ordonez NG, Sasano H. Adrenal cortical carcinoma. In: DeLellis RA, Lloyd RV, Heitz PU, Eng C, editors. *World Health Organization Classification of Tumours. Pathology and Genetics of Tumours of Endocrine Organs*. Lyon: IARC Press; 2004. p. 139–42.
- Whaley-Connell A, Johnson MS, Sowers JR. Aldosterone: role in the cardiometabolic syndrome and resistant hypertension. *Prog Cardiovasc Dis* 2010;52(5):401–9.



- Wolff AS, Erichsen MM, Meager A, Magitta NF, Myhre AG, Bollerslev J, et al. Autoimmune polyendocrine syndrome type 1 in Norway: phenotypic variation, autoantibodies, and novel mutations in the autoimmune regulator gene. *J Clin Endocrinol Metab* 2007;92(2):595–603.
- Young AL, Baysal BE, Deb A, Young WF Jr. Familial malignant catecholamine-secreting paraganglioma with prolonged survival associated with mutation in the succinate dehydrogenase B gene. *J Clin Endocrinol Metab* 2002;87(9):4101–5.
- Young WF Jr. Paragangliomas: clinical overview. *Ann N Y Acad Sci* 2006;1073:21–9.
- Young WF Jr. Clinical practice. The incidentally discovered adrenal mass. *N Engl J Med* 2007;356(6):601–10.
- Young WF. Primary aldosteronism: renaissance of a syndrome. *Clin Endocrinol (Oxf)* 2007;66(5):607–18.
- Young WF. Endocrine hypertension. In: Kronenberg HM, Melmed S, Polonsky KS, Larsen PR, editors. *Williams Textbook of Endocrinology*. 11th ed. Philadelphia: Saunders Elsevier; 2008. p. 505–37.
- Young WF Jr. Primary aldosteronism—one picture is not worth a thousand words. *Ann Intern Med* 2009;151(5):357–8.
- Young WF Jr, Carney JA, Musa BU, Wulffraat NM, Lens JW, Drexhage HA. Familial Cushing's syndrome due to primary pigmented nodular adrenocortical disease. Reinvestigation 50 years later. *N Engl J Med* 1989;321(24):1659–64.
- Young WF Jr, du Plessis H, Thompson GB, Grant CS, Farley DR, Richards ML, et al. The clinical conundrum of corticotropin-independent autonomous cortisol secretion in patients with bilateral adrenal masses. *World J Surg* 2008;32(5):856–62.
- Young WF, Stanson AW. What are the keys to successful adrenal venous sampling (AVS) in patients with primary aldosteronism? *Clin Endocrinol (Oxf)* 2009;70(1):14–17.
- Young WF, Stanson AW, Thompson GB, Grant CS, Farley DR, van Heerden JA. Role for adrenal venous sampling in primary aldosteronism. *Surgery* 2004;136(6):1227–35.
- Zarnegar R, Young WF Jr, Lee J, Sweet MP, Kebebew E, Farley DR, et al. The aldosteronoma resolution score: predicting complete resolution of hypertension after adrenalectomy for aldosteronoma. *Ann Surg* 2008;247(3):511–18.
- Zhang L, Smyrk TC, Young WF Jr, Stratakis CA, Carney JA. Gastric stromal tumors in Carney triad are different clinically, pathologically, and behaviorally from sporadic gastrointestinal stromal tumors: findings in 104 cases. *Am J Surg Pathol* 2010;34(1):53–64.
- Section 4: Reproduction**
- Achermann JC, Hughes IA. Disorders of sex development. In: Kronenberg HM, Melmed S, Polonsky KS, Larsen PR, editors. *Williams Textbook of Endocrinology*. 11th ed. Philadelphia: Saunders; 2008. p. 783–848.
- ACOG Practice Bulletin No. 108: Polycystic ovary syndrome. *Obstet Gynecol* 2009;114(4):936–49.
- Amundson E, Boman UW, Barrenas ML, Bryman I, Landin-Wilhelmsen K. Impact of growth hormone therapy on quality of life in adults with Turner syndrome. *J Clin Endocrinol Metab* 2010;95(3):1355–9.
- Armengaud JB, Charkaluk ML, Trivin C, Tardy V, Breart G, Brauner R, et al. Precocious pubarche: distinguishing late-onset congenital adrenal hyperplasia from premature adrenarche. *J Clin Endocrinol Metab* 2009;94(8):2835–40.
- Audi L, Fernandez-Cancio M, Carrascosa A, Andaluz P, Toran N, Piro C, et al. Novel (60%) and recurrent (40%) androgen receptor gene mutations in a series of 59 patients with a 46,XY disorder of sex development. *J Clin Endocrinol Metab* 2010;95(4):1876–88.
- Bannink EM, van Sassen C, van Buuren S, de Jong FH, Lequin M, Mulder PG, et al. Puberty induction in Turner syndrome: results of oestrogen treatment on development of secondary sexual characteristics, uterine dimensions and serum hormone levels. *Clin Endocrinol (Oxf)* 2009;70(2):265–73.
- Bhasin S. Testicular disorders. In: Kronenberg HM, Melmed S, Polonsky KS, Larsen PR, editors. *Williams Textbook of Endocrinology*. 11th ed. Philadelphia: Saunders; 2008. p. 645–700.
- Braunstein GD. Clinical practice. Gynecomastia. *N Engl J Med* 2007;357(12):1229–37.
- Bruining H, Swaab H, Kas M, van Engeland H. Psychiatric characteristics in a self-selected sample of boys with Klinefelter syndrome. *Pediatrics* 2009;123(5):e865–70.
- Bulun SE, Adashi EY. The physiology and pathology of the female reproductive axis. In: Kronenberg HM, Melmed S, Polonsky KS, Larsen PR, editors. *Williams Textbook of Endocrinology*. 11th ed. Philadelphia: Saunders; 2008. p. 541–614.
- Carel JC, Eugster EA, Rogol A, Ghizzoni L, Palmert MR, Antoniazzi F, et al. Consensus statement on the use of gonadotropin-releasing hormone analogs in children. *Pediatrics* 2009;123(4):e752–62.
- Carel JC, Leger J. Clinical practice. Precocious puberty. *N Engl J Med* 2008;358(22):2366–77.
- Colin JF. Gynaecomastia: drugs and surgical concerns. *BMJ* 2008;336(7648):790.
- Conway GS. Adult care of pediatric conditions: lessons from Turner's syndrome. *J Clin Endocrinol Metab* 2009;94(9):3185–7.
- Cosma M, Swiglo BA, Flynn DN, Kurtz DM, Labella ML, Mullan RJ, et al. Clinical review: insulin sensitizers for the treatment of hirsutism: a systematic review and metaanalysis of randomized controlled trials. *J Clin Endocrinol Metab* 2008;93(4):1135–42.
- Davenport ML. Approach to the patient with Turner syndrome. *J Clin Endocrinol Metab* 2010;95(4):1487–95.
- Dayner JE, Lee PA, Houk CP. Medical treatment of intersex: parental perspectives. *J Urol* 2004;172(4 Pt 2):1762–5; discussion 1765.
- de Boer H, van Gastel P, van Sorge A. Luteinizing hormone-releasing hormone and postmenopausal flushing. *N Engl J Med* 2009;361(12):1218–19.
- de Vries L, Guz-Mark A, Lazar L, Reches A, Phillip M. Premature thelarche: age at presentation affects clinical course but not clinical characteristics or risk to progress to precocious puberty. *J Pediatr* 2010;156(3):466–71.
- de Vries L, Shtaf B, Phillip M, Gat-Yablonski G. Kisspeptin serum levels in girls with central precocious puberty. *Clin Endocrinol (Oxf)* 2009;71(4):524–8.
- El-Mansoury M, Barrenas ML, Bryman I, Hanson C, Landin-Wilhelmsen K. Impaired body balance, fine motor function and hearing in women with Turner syndrome. *Clin Endocrinol (Oxf)* 2009;71(2):273–8.
- Euling SY, Herman-Giddens ME, Lee PA, Selevan SG, Juul A, Sorensen TI, et al. Examination of US puberty-timing data from 1940 to 1994 for secular trends: panel findings. *Pediatrics* 2008;121(Suppl 3):S172–91.
- Euling SY, Selevan SG, Pescovitz OH, Skakkebaek NE. Role of environmental factors in the timing of puberty. *Pediatrics* 2008;121(Suppl 3):S167–71.
- Ferriman D, Gallwey JD. Clinical assessment of body hair growth in women. *J Clin Endocrinol Metab* 1961;21:1440–7.
- Gault EJ, Donaldson MD. Oestrogen replacement in Turner syndrome: current prescribing practice in the UK. *Clin Endocrinol (Oxf)* 2009;71(5):753–5.
- Goldstein SR. Abnormal uterine bleeding: the role of ultrasound. *Radiol Clin North Am* 2006;44(6):901–10.
- Grady D. Clinical practice. Management of menopausal symptoms. *N Engl J Med* 2006;355(22):2338–47.
- Himes JH, Park K, Styne D. Menarche and assessment of body mass index in adolescent girls. *J Pediatr* 2009;155(3):393–7.
- Hindmarsh PC. How do you initiate oestrogen therapy in a girl who has not undergone puberty? *Clin Endocrinol (Oxf)* 2009;71(1):7–10.
- Hines SL, Tan W, Larson JM, Thompson KM, Jorn HK, Files JA. A practical approach to guide clinicians in the evaluation of male patients with breast masses. *Geriatrics* 2008;63(6):19–24.
- Houk CP, Kunselman AR, Lee PA. Adequacy of a single unstimulated luteinizing hormone level to diagnose central precocious puberty in girls. *Pediatrics* 2009;123(6):e1059–63.
- Hyun G, Kolon TF. A practical approach to intersex in the newborn period. *Urol Clin North Am* 2004;31(3):435–43.viii.
- Johnson RE, Murad MH. Gynecomastia: pathophysiology, evaluation, and management. *Mayo Clin Proc* 2009;84(11):1010–15.
- Jorgensen KT, Rostgaard K, Bache I, Biggar RJ, Nielsen NM, Tommerup N, et al. Autoimmune diseases in women with Turner's syndrome. *Arthritis Rheum* 2010;62(3):658–66.
- Karrer-Voegeli S, Rey F, Reymond MJ, Meuwly JY, Gaillard RC, Gomez F. Androgen dependence of hirsutism, acne, and alopecia in women: retrospective analysis of 228 patients investigated for hyperandrogenism. *Medicine (Baltimore)* 2009;88(1):32–45.
- Karthikeyan A. Precocious puberty. *Clin Pediatr (Phila)* 2008;47(7):718.
- Kaunitz AM. Clinical practice. Hormonal contraception in women of older reproductive age. *N Engl J Med* 2008;358(12):1262–70.
- Koulouri O, Conway GS. Management of hirsutism. *BMJ* 2009;338:b847.
- Kumar R, St John J, Devendra D. Hirsutism. *BMJ* 2009;339:b3090.
- Lanfranco F, Kamischke A, Zitzmann M, Nieschlag E. Klinefelter's syndrome. *Lancet* 2004;364(9430):273–83.
- Lee JM, Kaciroti N, Appugliese D, Corwyn RF, Bradley RH, Lumeng JC. Body mass index and timing of pubertal initiation in boys. *Arch Pediatr Adolesc Med* 2010;164(2):139–44.
- Lopez L, Arheart KL, Colan SD, Stein NS, Lopez-Mitnik G, Lin AE, et al. Turner syndrome is an independent risk factor for aortic dilation in the young. *Pediatrics* 2008;121(6):e1622–7.
- Marshall WA, Tanner JM. Variations in pattern of pubertal changes in girls. *Arch Dis Child* 1969;44(235):291–303.
- Marshall WA, Tanner JM. Variations in the pattern of pubertal changes in boys. *Arch Dis Child* 1970;45(239):13–23.
- Martin KA, Chang RJ, Ehrmann DA, Ibanez L, Lobo RA, Rosenfield RL, et al. Evaluation and treatment of hirsutism in premenopausal women: an endocrine society clinical practice guideline. *J Clin Endocrinol Metab* 2008;93(4):1105–20.
- Matura LA, Ho VB, Rosing DR, Bondy CA. Aortic dilatation and dissection in Turner syndrome. *Circulation* 2007;116(15):1663–70.
- Mendonca BB, Domenice S, Arnhold IJ, Costa EM. 46,XY disorders of sex development (DSD). *Clin Endocrinol (Oxf)* 2009;70(2):173–87.
- Mermejo LM, Elias LL, Marui S, Moreira AC, Mendonca BB, de Castro M. Refining hormonal diagnosis of type II 3beta-hydroxysteroid dehydrogenase deficiency in patients with premature pubarche and hirsutism based on HSD3B2 genotyping. *J Clin Endocrinol Metab* 2005;90(3):1287–93.
- Mouat F, Hoffman PL, Jefferies C, Gunn AJ, Cutfield WS. Initial growth deceleration during GnRH analogue therapy for precocious puberty. *Clin Endocrinol (Oxf)* 2009;70(5):751–6.
- Nelson LM. Clinical practice. Primary ovarian insufficiency. *N Engl J Med* 2009;360(6):606–14.
- Nield LS, Cakan N, Kamat D. A practical approach to precocious puberty. *Clin Pediatr (Phila)* 2007;46(4):299–306.
- Norman RJ, Dewailly D, Legros RS, Hickey TE. Polycystic ovary syndrome. *Lancet* 2007;370(9588):685–97.
- Ogilvy-Stuart AL, Brain CE. Early assessment of ambiguous genitalia. *Arch Dis Child* 2004;89(5):401–7.
- Papadimitriou A, Pantisotou S, Douros K, Papadimitriou DT, Nicolaidou P, Fretzayas A. Timing of pubertal onset in girls: evidence for non-Gaussian distribution. *J Clin Endocrinol Metab* 2008;93(11):4422–5.
- Pawlowski EJ, Nield LS. Gynecomastia and hypogonadism. *Clin Pediatr (Phila)* 2008;47(3):313–5; comment 314–315.
- Poomthavorn P, Stargatt R, Zacharin M. Psychosexual and psychosocial functions of anorichd young adults. *J Clin Endocrinol Metab* 2009;94(7):2502–5.
- Rosenfield RL. Clinical practice. Hirsutism. *N Engl J Med* 2005;353(24):2578–88.
- Sachdev V, Matura LA, Sidenko S, Ho VB, Arai AE, Rosing DR, et al. Aortic valve disease in Turner syndrome. *J Am Coll Cardiol* 2008;51(19):1904–9.
- Sathyapalan T, Atkin SL. Investigating hirsutism. *BMJ* 2009;338:b912.
- Schoemaker MJ, Swerdlow AJ, Higgins CD, Wright AF, Jacobs PA. Mortality in women with Turner syndrome in Great Britain: a national cohort study. *J Clin Endocrinol Metab* 2008;93(12):4735–42.
- Setji TL, Brown AJ. Polycystic ovary syndrome: diagnosis and treatment. *Am J Med* 2007;120(2):128–32.
- Styne DM, Grumbach MM. Puberty: ontogeny, neuroendocrinology, physiology, and disorders. In: Kronenberg HM, Melmed S, Polonsky KS, Larsen PR, editors. *Williams Textbook of Endocrinology*. 11th ed. Philadelphia: Saunders; 2008. p. 969–1168.
- Susman EJ, Houts RM, Steinberg L, Belsky J, Cauffman E, Dehart G, et al. Longitudinal development of secondary sexual characteristics in girls and boys between ages 9 1/2 and 15 1/2 years. *Arch Pediatr Adolesc Med* 2010;164(2):166–73.
- Swiglo BA, Cosma M, Flynn DN, Kurtz DM, Labella ML, Mullan RJ, et al. Clinical review: Antiandrogens for the treatment of hirsutism: a systematic review and metaanalysis of randomized controlled trials. *J Clin Endocrinol Metab* 2008;93(4):1153–60.
- van Dongen H, de Kroon CD, Jacobi CE, Trimbos JB, Jansen FW. Diagnostic hysteroscopy in abnormal uterine bleeding: a systematic review and meta-analysis. *BJOG* 2007;114(6):664–75.
- van Dongen H, Janssen CA, Smeets JF, Emanuel MH, Jansen FW. The clinical relevance of hysteroscopic polypectomy in premenopausal women with abnormal uterine bleeding. *BJOG* 2009;116(10):1387–90.
- Verkauskas G, Jaubert F, Lortat-Jacob S, Malan V, Thibaud E, Nihoul-Fekete C. The long-term followup of 33 cases of true hermaphroditism: a 40-year experience with conservative gonadal surgery. *J Urol* 2007;177(2):726–31; discussion 731.
- Zacharin M. Disorders of ovarian function in childhood and adolescence: evolving needs of the growing child. An endocrine perspective. *BJOG* 2010;117(2):156–62.
- Zeger MP, Zinn AR, Lahlou N, Ramos P, Kowal K, Samango-Sprouse C, et al. Effect of ascertainment and genetic features on the phenotype of Klinefelter syndrome. *J Pediatr* 2008;152(5):716–22.
- Section 5: Pancreas**
- Balsells M, Garcia-Patterson A, Gich I, Corcoy R. Maternal and fetal outcome in women with type 2 versus type 1 diabetes mellitus: a systematic review and metaanalysis. *J Clin Endocrinol Metab* 2009;94(11):4284–91.
- Barnett AH. New treatments in type 2 diabetes: a focus on the incretin-based therapies. *Clin Endocrinol (Oxf)* 2009;70(3):343–53.
- Besirli CG, Johnson MW. Proliferative diabetic retinopathy. *Mayo Clin Proc* 2009;84(12):1054.
- Bingley PJ. Clinical applications of diabetes antibody testing. *J Clin Endocrinol Metab* 2010;95(1):25–33.
- Boulton AJ, Kirsner RS, Vileikyte L. Clinical practice. Neuropathic diabetic foot ulcers. *N Engl J Med* 2004;351(1):48–55.

- Brownlee M, Aiello LP, Cooper ME, Vinik AI, Nesto RW, Boulton AJ. M. Complications of diabetes mellitus. In: Kronenberg HM, Melmed S, Polonsky KS, Larsen PR, editors. *Williams Textbook of Endocrinology*. 11th ed. Philadelphia: Saunders; 2008. p. 1417–502.
- Buse JB, Polonsky KS, Burant CF. Type 2 diabetes mellitus. In: Kronenberg HM, Melmed S, Polonsky KS, Larsen PR, editors. *Williams Textbook of Endocrinology*. 11th ed. Philadelphia: Saunders; 2008. p. 1329–90.
- Camilleri M. Clinical practice. Diabetic gastroparesis. *N Engl J Med* 2007;356(8):820–9.
- Cheer K, Shearman C, Jude EB. Managing complications of the diabetic foot. *BMJ* 2009;339:b4905.
- Cheung BM, Ong KL, Cherny SS, Sham PC, Tso AW, Lam KS. Diabetes prevalence and therapeutic target achievement in the United States, 1999 to 2006. *Am J Med* 2009;122(5):443–53.
- Chun SH, Li AH. Association of proliferative diabetic retinopathy with insulin use and microalbuminuria. *Arch Ophthalmol* 2010;128(1):146; author reply 146–7.
- Conway BN, Miller RG, Klein R, Orchard TJ. Prediction of proliferative diabetic retinopathy with hemoglobin level. *Arch Ophthalmol* 2009;127(11):1494–9.
- Cryer PE. Glucose homeostasis and hypoglycemia. In: Kronenberg HM, Melmed S, Polonsky KS, Larsen PR, editors. *Williams Textbook of Endocrinology*. 11th ed. Philadelphia: Saunders; 2008. p. 1503–36.
- Cryer PE, Axelrod L, Grossman AB, Heller SR, Montori VM, Seaquist ER, et al. Evaluation and management of adult hypoglycemic disorders: an Endocrine Society Clinical Practice Guideline. *J Clin Endocrinol Metab* 2009;94(3):709–28.
- Currie CJ, Peters JR, Tynan A, Evans M, Heine RJ, Bracco OL, et al. Survival as a function of HbA(1c) in people with type 2 diabetes: a retrospective cohort study. *Lancet* 2010;375(9713):481–9.
- DeFronzo RA. Current issues in the treatment of type 2 diabetes. Overview of newer agents: where treatment is going. *Am J Med* 2010;123(3 Suppl):S38–48.
- Diagnosis and classification of diabetes mellitus. *Diabetes Care* 2010;33(Suppl 1):S62–9.
- Dluhy RG, McMahon GT. Intensive glycemic control in the ACCORD and ADVANCE trials. *N Engl J Med* 2008;358(24):2630–3.
- Duckworth W, Abraira C, Moritz T, Reda D, Emanuele N, Reaven PD, et al. Glucose control and vascular complications in veterans with type 2 diabetes. *N Engl J Med* 2009;360(2):129–39.
- Eisenbarth GS, Polonsky KS, Buse JB. Type 1 diabetes mellitus. In: Kronenberg HM, Melmed S, Polonsky KS, Larsen PR, editors. *Williams Textbook of Endocrinology*. 11th ed. Philadelphia: Saunders; 2008. p. 1391–416.
- Fante RJ, Durairaj VD, Oliver SC. Diabetic retinopathy: an update on treatment. *Am J Med* 2010;123(3):213–16.
- Ferrannini E, Mari A, Nofrate V, Sosenko JM, Skyler JS. Progression to diabetes in relatives of type 1 diabetic patients: mechanisms and mode of onset. *Diabetes* 2010;59(3):679–85.
- Finfer S, Chittock DR, Su SY, Blair D, Foster D, Dhingra V, et al. Intensive versus conventional glucose control in critically ill patients. *N Engl J Med* 2009;360(13):1283–97.
- Frye RL, August P, Brooks MM, Hardison RM, Kelsey SF, MacGregor JM, et al. A randomized trial of therapies for type 2 diabetes and coronary artery disease. *N Engl J Med* 2009;360(24):2503–15.
- Gerstein HC, Miller ME, Byington RP, Goff DC Jr, Bigger JT, Buse JB, et al. Effects of intensive glucose lowering in type 2 diabetes. *N Engl J Med* 2008;358(24):2545–59.
- Ghetti S, Lee JK, Sims CE, Demaster DM, Glaser NS. Diabetic ketoacidosis and memory dysfunction in children with type 1 diabetes. *J Pediatr* 2010;156(1):109–14.
- Goldfine AB. Assessing the cardiovascular safety of diabetes therapies. *N Engl J Med* 2008;359(11):1092–5.
- Hedderson MM, Gunderson EP, Ferrara A. Gestational weight gain and risk of gestational diabetes mellitus. *Obstet Gynecol* 2010;115(3):597–604.
- Holman RR, Farmer AJ, Davies MJ, Levy JC, Darbyshire JL, Keenan JE, et al. Three-year efficacy of complex insulin regimens in type 2 diabetes. *N Engl J Med* 2009;361(18):1736–47.
- Holman RR, Paul SK, Bethel MA, Matthews DR, Neil HA. 10-year follow-up of intensive glucose control in type 2 diabetes. *N Engl J Med* 2008;359(15):1577–89.
- Holman RR, Paul SK, Bethel MA, Neil HA, Matthews DR. Long-term follow-up after tight control of blood pressure in type 2 diabetes. *N Engl J Med* 2008;359(15):1565–76.
- Horvath K, Koch K, Jeitler K, Matyas E, Bender R, Bastian H, et al. Effects of treatment in women with gestational diabetes mellitus: systematic review and meta-analysis. *BMJ* 2010;340:c1395.
- Inzucchi SE. Clinical practice. Management of hyperglycemia in the hospital setting. *N Engl J Med* 2006;355(18):1903–11.
- Inzucchi SE, Siegel MD. Glucose control in the ICU—how tight is too tight? *N Engl J Med* 2009;360(13):1346–9.
- Jessen L, D'Alessio D. The incretins and beta-cell health: contrasting glucose-dependent insulinotropic polypeptide and glucagon-like peptide-1 as a path to understand islet function in diabetes. *Gastroenterology* 2009;137(6):1891–4.
- Kao SL, Chan CL, Tan B, Lim CC, Dalan R, Gardner D, et al. An unusual outbreak of hypoglycemia. *N Engl J Med* 2009;360(7):734–6.
- Katavetin P, Katavetin P. Renal and retinal effects of enalapril and losartan in type 1 diabetes. *N Engl J Med* 2009;361(14):1410–11; author reply 1411.
- Kitabchi AE, Umpierrez GE, Fisher JN, Murphy MB, Stentz FB. Thirty years of personal experience in hyperglycemic crises: diabetic ketoacidosis and hyperglycemic hyperosmolar states. *J Clin Endocrinol Metab* 2008;93(5):1541–52.
- Komminoth P, Perren A, Oberk G, Rindi G, Heitz Ph U, Kloppel G. Insulinoma. In: DeLellis RA, Lloyd RV, Heitz PU, Eng C, editors. *World Health Organization Classification of Tumours. Pathology and Genetics of Tumours of Endocrine Organs*. Lyon: IARC Press; 2004. p. 183–6.
- Koul PB. Diabetic ketoacidosis: a current appraisal of pathophysiology and management. *Clin Pediatr (Phila)* 2009;48(2):135–44.
- Landon MB, Spong CY, Thom E, Carpenter MW, Ramin SM, Casey B, et al. A multicenter, randomized trial of treatment for mild gestational diabetes. *N Engl J Med* 2009;361(14):1339–48.
- Lloyd RV, Douglas BR, Young WF Jr. Diffuse neuroendocrine system. In: King DW, editor. *Atlas of Nontumor Pathology: Endocrine Diseases*. 1st ed. Washington D.C.: American Registry of Pathology and the Armed Forces Institute of Pathology; 2002. p. 259–308.
- Ludvigsson J, Faresjo M, Hjorth M, Axelsson S, Cheramy M, Pihl M, et al. GAD treatment and insulin secretion in recent-onset type 1 diabetes. *N Engl J Med* 2008;359(18):1909–20.
- Malik VS, Popkin BM, Bray GA, Despres JP, Hu FB. Sugar-sweetened beverages, obesity, type 2 diabetes mellitus, and cardiovascular disease risk. *Circulation* 2010;121(11):1356–64.
- Mathur A, Gorden P, Libutti SK. Insulinoma. *Surg Clin North Am* 2009;89(5):1105–21.
- Mauer M, Zimman B, Gardiner R, Suissa S, Sinaiko A, Strand T, et al. Renal and retinal effects of enalapril and losartan in type 1 diabetes. *N Engl J Med* 2009;361(1):40–51.
- Meltzer SJ. Treatment of gestational diabetes. *BMJ* 2010;340:c1708.
- Miller ME, Bonds DE, Gerstein HC, Seaquist ER, Bergenstal RM, Calles-Escandon J, et al. The effects of baseline characteristics, glycaemia treatment approach, and glycated haemoglobin concentration on the risk of severe hypoglycaemia: post hoc epidemiological analysis of the ACCORD study. *BMJ* 2010;340:b5444.
- Mudaliar S, Henry RR. Effects of incretin hormones on beta-cell mass and function, body weight, and hepatic and myocardial function. *Am J Med* 2010;123(3 Suppl):S19–27.
- Nakagawa T, Kosugi T, Haneda M, Rivard CJ, Long DA. Abnormal angiogenesis in diabetic nephropathy. *Diabetes* 2009;58(7):1471–8.
- Nathan DM. Clinical practice. Initial management of glycemia in type 2 diabetes mellitus. *N Engl J Med* 2002;347(17):1342–9.
- Nathan DM, Zimman B, Cleary A, Backlund JY, Genuth S, Miller R, et al. Modern-day clinical course of type 1 diabetes mellitus after 30 years' duration: the diabetes control and complications trial/epidemiology of diabetes interventions and complications and Pittsburgh epidemiology of diabetes complications experience (1983–2005). *Arch Intern Med* 2009;169(14):1307–16.
- Oyibo SO, Jude EB, Tarawneh I, Nguyen HC, Harkless LB, Boulton AJ. A comparison of two diabetic foot ulcer classification systems: the Wagner and the University of Texas wound classification systems. *Diabetes Care* 2001;24(1):84–8.
- Parving HH, Persson F, Lewis JB, Lewis EJ, Hollenberg NK. Aliskiren combined with losartan in type 2 diabetes and nephropathy. *N Engl J Med* 2008;358(23):2433–46.
- Pascuzzi RM. Peripheral neuropathy. *Med Clin North Am* 2009;93(2):317–42.vii–viii.
- Patel A, MacMahon S, Chalmers J, Neal B, Billot L, Woodward M, et al. Intensive blood glucose control and vascular outcomes in patients with type 2 diabetes. *N Engl J Med* 2008;358(24):2560–72.
- Perkins BA, Aiello LP, Krolewski AS. Diabetes complications and the renin-angiotensin system. *N Engl J Med* 2009;361(1):83–5.
- Peters A. Incretin-based therapies: review of current clinical trial data. *Am J Med* 2010;123(3 Suppl):S28–37.
- Pirkola J, Pouta A, Bloigu A, Miettola S, Hartikainen AL, Jarvelin MR, et al. Prepregnancy overweight and gestational diabetes as determinants of subsequent diabetes and hypertension after 20-year follow-up. *J Clin Endocrinol Metab* 2010;95(2):772–8.
- Placzowski KA, Vella A, Thompson GB, Grant CS, Reading CC, Charboneau JW, et al. Secular trends in the presentation and management of functioning insulinoma at the Mayo Clinic, 1987–2007. *J Clin Endocrinol Metab* 2009;94(4):1069–73.
- Proia AD, Caldwell MC. Intraretinal neovascularization in diabetic retinopathy. *Arch Ophthalmol* 2010;128(1):142–4.
- Raffel A, Krausch MM, Anlauf M, Wieben D, Braunstein S, Kloppel G, et al. Diffuse nesidioblastosis as a cause of hyperinsulinemic hypoglycemia in adults: a diagnostic and therapeutic challenge. *Surgery* 2007;141(2):179–84; discussion 185–176.
- Rahier J, Guiot Y, Sempoux C. Persistent hyperinsulinaemic hypoglycaemia of infancy: a heterogeneous syndrome unrelated to nesidioblastosis. *Arch Dis Child Fetal Neonatal Ed* 2000;82(2):F108–112.
- Remuzzi G, Schieppati A, Ruggenenti P. Clinical practice. Nephropathy in patients with type 2 diabetes. *N Engl J Med* 2002;346(15):1145–51.
- Retnakaran R, Qi Y, Connelly PW, Sermer M, Zimman B, Hanley AJ. Glucose intolerance in pregnancy and postpartum risk of metabolic syndrome in young women. *J Clin Endocrinol Metab* 2010;95(2):670–7.
- Rishi P, Bhende PS. Images in clinical medicine. Proliferative diabetic retinopathy. *N Engl J Med* 2009;360(9):912.
- Robinson AH, Pasapula C, Brodsky JW. Surgical aspects of the diabetic foot. *J Bone Joint Surg Br* 2009;91(1):1–7.
- Roden M. Optimal insulin treatment in type 2 diabetes. *N Engl J Med* 2009;361(18):1801–3.
- Rostambeigi N, Thompson GB. What should be done in an operating room when an insulinoma cannot be found? *Clin Endocrinol (Oxf)* 2009;70(4):512–15.
- Selvin E, Steffes MW, Zhu H, Matsushita K, Wagenknecht L, Pankow J, et al. Glycated hemoglobin, diabetes, and cardiovascular risk in nondiabetic adults. *N Engl J Med* 2010;362(9):800–11.
- Service FJ. Hypoglycemic disorders. *N Engl J Med* 1995;332(17):1144–52.
- Service FJ, Natt N, Thompson GB, Grant CS, van Heerden JA, Andrews JC, et al. Noninsulinoma pancreatogenous hypoglycemia: a novel syndrome of hyperinsulinemic hypoglycemia in adults independent of mutations in Kir6.2 and SUR1 genes. *J Clin Endocrinol Metab* 1999;84(5):1582–9.
- Service FJ, O'Brien PC. Increasing serum beta-hydroxybutyrate concentrations during the 72-hour fast: evidence against hyperinsulinemic hypoglycemia. *J Clin Endocrinol Metab* 2005;90(8):4555–8.
- Service GJ, Thompson GB, Service FJ, Andrews JC, Collazo-Clavell ML, Lloyd RV. Hyperinsulinemic hypoglycemia with nesidioblastosis after gastric-bypass surgery. *N Engl J Med* 2005;353(3):249–54.
- Smith RJ, Nathan DM, Arslanian SA, Groop L, Rizza RA, Rotter JI. Individualizing therapies in type 2 diabetes mellitus based on patient characteristics: what we know and what we need to know. *J Clin Endocrinol Metab* 2010;95(4):1566–74.
- Stals B. A review of bile acid sequestrants: potential mechanism(s) for glucose-lowering effects in type 2 diabetes mellitus. *Postgrad Med* 2009;121(3 Suppl 1):25–30.
- Stanley CA. Hyperinsulinism in infants and children. *Pediatr Clin North Am* 1997;44(2):363–74.
- Stolar M. Glycemic control and complications in type 2 diabetes mellitus. *Am J Med* 2010;123(3 Suppl):S3–11.
- Tamborlane WV, Beck RW, Bode BW, Buckingham B, Chase HP, Clemons R, et al. Continuous glucose monitoring and intensive treatment of type 1 diabetes. *N Engl J Med* 2008;359(14):1464–76.
- Teh J, Berendt T, Lipsky BA. Rational Imaging . Investigating suspected bone infection in the diabetic foot. *BMJ* 2009;339:b4690.
- Thompson GB, Service FJ, Andrews JC, Lloyd RV, Natt N, van Heerden JA, et al. Noninsulinoma pancreatogenous hypoglycemia syndrome: an update in 10 surgically treated patients. *Surgery* 2000;128(6):937–44; discussion 944–935.
- Thrower SL, Bingle PJ. Strategies to prevent type 1 diabetes. *Diabetes Obes Metab* 2009;11(10):931–8.
- Torn C, Mueller PW, Schlosser M, Bonifacio E, Bingley PJ. Diabetes Antibody Standardization Program: evaluation of assays for autoantibodies to glutamic acid decarboxylase and islet antigen-2. *Diabetologia* 2008;51(5):846–52.
- Wagner FW Jr. The dysvascular foot: a system for diagnosis and treatment. *Foot Ankle* 1981;2(2):64–122.
- Willcox A, Richardson SJ, Bone AJ, Foulis AK, Morgan NG. Analysis of islet inflammation in human type 1 diabetes. *Clin Exp Immunol* 2009;155(2):173–81.
- Yeh HC, Duncan BB, Schmidt MI, Wang NY, Brancati FL. Smoking, smoking cessation, and risk for type 2 diabetes mellitus: a cohort study. *Ann Intern Med* 2010;152(1):10–7.
- Yogev, Chen, Hod, Coustan, Oats, McIntyre, Metzger, Lowe, Dyer, Dooley, Trimble, McCance, Hadden, Persson, Rogers; Hyperglycemia and Adverse Pregnancy Outcome (HAPO) Study Cooperative Research Group. Hyperglycemia and Adverse Pregnancy Outcome (HAPO) study: preeclampsia. *Am J Obstet Gynecol* 2010;202(3), 255:e251–257.

## Section 6: Bone and Calcium

Adams JS, Hewison M. Update in vitamin D. *J Clin Endocrinol Metab* 2010;95:471–8.



- Asari R, Passler C, Kaczirek K, Scheuba C, Niederle B. Hypoparathyroidism after total thyroidectomy: a prospective study. *Arch Surg* 2008;143(2):132–7; discussion 138.
- Astrom E, Jorulf H, Soderhall S. Intravenous pamidronate treatment of infants with severe osteogenesis imperfecta. *Arch Dis Child* 2007;92(4):332–8.
- Bachrach LK, Ward LM. Clinical review 1: bisphosphonate use in childhood osteoporosis. *J Clin Endocrinol Metab* 2009;94(2):400–9.
- Barnes AM, Carter EM, Cabral WA, Weis M, Chang W, Makareeva E, et al. Lack of cyclophilin B in osteogenesis imperfecta with normal collagen folding. *N Engl J Med* 2010;362(6):521–8.
- Barrett-Connor E, Nielson CM, Orwoll E, Bauer DC, Cauley JA. Epidemiology of rib fractures in older men: Osteoporotic Fractures in Men (MrOS) prospective cohort study. *BMJ* 2010;340:c1069.
- Bastin S, Bird H, Gamble G, Cundy T. Paget's disease of bone—becoming a rarity? *Rheumatology (Oxford)* 2009;48(10):1232–5.
- Bikle D. Nonclassic actions of vitamin D. *J Clin Endocrinol Metab* 2009;94(1):26–34.
- Bilezikian JP, Silverberg SJ. Clinical practice. Asymptomatic primary hyperparathyroidism. *N Engl J Med* 2004;350(17):1746–51.
- Bolland MJ, Grey A. Disparate outcomes from applying U.K. and U.S. osteoporosis treatment guidelines. *J Clin Endocrinol Metab* 2010;95(4):1856–60.
- Bolland MJ, Grey AB, Gamble GD, Reid IR. Effect of osteoporosis treatment on mortality: a meta-analysis. *J Clin Endocrinol Metab* 2010;95(3):1174–81.
- Bondeson L, Grimelius L, DeLellis RA, Lloyd R, Akerstrom G, Larsson G, Arnold A, Eng C, Shane E, Bilezikian JP. Parathyroid carcinoma. In: DeLellis RA, Lloyd RV, Heitz PU, Eng C, editors. *World Health Organization Classification of Tumours. Pathology and Genetics of Tumours of Endocrine Organs*. Lyon: IARC Press; 2004. p. 124–7.
- Bringham FR, Demay MB, Kronenberg HM. Hormones and disorders of mineral metabolism. In: Kronenberg HM, Melmed S, Polonsky KS, Larsen PR, editors. *Williams Textbook of Endocrinology*. 11th ed. Philadelphia: Saunders; 2008. p. 1203–68.
- Buchbinder R, Osborne RH, Ebeling PR, Wark JD, Mitchell P, Wriedt C, et al. A randomized trial of vertebroplasty for painful osteoporotic vertebral fractures. *N Engl J Med* 2009;361(6):557–68.
- Bumpous JM, Goldstein RL, Flynn MB. Surgical and calcium outcomes in 427 patients treated prospectively in an image-guided and intraoperative PTH (IOPTH) supplemented protocol for primary hyperparathyroidism: outcomes and opportunities. *Laryngoscope* 2009;119(2):300–6.
- Cahill RA, Wenkert D, Perlman SA, Steele A, Coburn SP, McAlister WH, et al. Infantile hypophosphatasia: transplantation therapy trial using bone fragments and cultured osteoblasts. *J Clin Endocrinol Metab* 2007;92(8):2923–30.
- Canalis E. Update in new anabolic therapies for osteoporosis. *J Clin Endocrinol Metab* 2010;95(4):1496–504.
- Cheng S, Massaro JM, Fox CS, Larson MG, Keyes MJ, McCabe EL, et al. Adiposity, cardiometabolic risk, and vitamin D status: the Framingham Heart Study. *Diabetes* 2010;59(1):242–8.
- Clarke BL. New and emerging treatments for osteoporosis. *Clin Endocrinol (Oxf)* 2009;71(3):309–21.
- Cooper M. Bone protective therapy in the young patient with fractures and chronic disease: what drug(s) should be given and for how long? *Clin Endocrinol (Oxf)* 2009;70(2):188–91.
- Cooper MS, Gittoes NJ. Diagnosis and management of hypocalcaemia. *BMJ* 2008;336(7656):1298–302.
- Cox G, Einhorn TA, Tzioupis C, Giannoudis PV. Bone-turnover markers in fracture healing. *J Bone Joint Surg Br* 2010;92(3):329–34.
- Cummings SR, San Martin J, McClung MR, Siris ES, Eastell R, Reid IR, et al. Denosumab for prevention of fractures in postmenopausal women with osteoporosis. *N Engl J Med* 2009;361(8):756–65.
- Drake MT, Clarke BL, Khosla S. Bisphosphonates: mechanism of action and role in clinical practice. *Mayo Clin Proc* 2008;83(9):1032–45.
- Eastell R, Arnold A, Brandi ML, Brown EM, D'Amour P, Hanley DA, et al. Diagnosis of asymptomatic primary hyperparathyroidism: proceedings of the third international workshop. *J Clin Endocrinol Metab* 2009;94(2):340–50.
- Ebeling PR. Clinical practice. Osteoporosis in men. *N Engl J Med* 2008;358(14):1474–82.
- Ebeling PR. Approach to the patient with transplantation-related bone loss. *J Clin Endocrinol Metab* 2009;94(5):1483–90.
- Fernandez-Rebollo E, Barrio R, Perez-Nanclares G, Carcavilla A, et al. New mutation type in pseudohypoparathyroidism type 1a. *Clin Endocrinol (Oxf)* 2008;69(5):705–12.
- Fernandez-Rebollo E, Garcia-Cuartero B, Garin I, Largo C, Martinez F, Garcia-Lacalle C, et al. Intragenic GNAS deletion involving exon A/B in pseudohypoparathyroidism type 1A resulting in an apparent loss of exon A/B methylation: potential for misdiagnosis of pseudohypoparathyroidism type 1B. *J Clin Endocrinol Metab* 2010;95(2):765–71.
- Finkelstein JS, Wyland JJ, Lee H, Neer RM. Effects of teriparatide, alendronate, or both in women with postmenopausal osteoporosis. *J Clin Endocrinol Metab* 2010;95(4):1838–45.
- Fraser WD. Hyperparathyroidism. *Lancet* 2009;374(9684):145–58.
- Glorieux FH. Experience with bisphosphonates in osteogenesis imperfecta. *Pediatrics* 2007;119(Suppl 2):S163–5.
- Goasguen N, Chirica M, Roger N, Munoz-Bongrand N, Zohar S, Noullet S, et al. Primary hyperparathyroidism from parathyroid microadenoma: specific features and implications for a surgical strategy in the era of minimally invasive parathyroidectomy. *J Am Coll Surg* 2010;210(4):456–62.
- Goji K, Ozaki K, Sadewa AH, Nishio H, Matsuo M. Somatic and germline mosaicism for a mutation of the PHEX gene can lead to genetic transmission of X-linked hypophosphatemic rickets that mimics an autosomal dominant trait. *J Clin Endocrinol Metab* 2006;91(2):365–70.
- Grimelius L, DeLellis RA, Bondeson L, Akerstrom G, Arnold A, Franssila KO, Hendy GN, Dupuy D, Eng C. Parathyroid adenoma. In: DeLellis RA, Lloyd RV, Heitz PU, Eng C, editors. *World Health Organization Classification of Tumours. Pathology and Genetics of Tumours of Endocrine Organs*. Lyon: IARC Press; 2004. p. 128–32.
- Harrison B. What steps should be considered in the patient who has had a negative cervical exploration for primary hyperparathyroidism? *Clin Endocrinol (Oxf)* 2009;71(5):624–7.
- Holick MF. High prevalence of vitamin D inadequacy and implications for health. *Mayo Clin Proc* 2006;81(3):353–73.
- Holmes J, Lazarus A. Sarcoidosis: extrathoracic manifestations. *Dis Mon* 2009;55(11):675–92.
- Husebye ES. Functional autoantibodies cause hypoparathyroidism. *J Clin Endocrinol Metab* 2009;94(12):4655–7.
- Ichikawa S, Sorenson AH, Imel EA, Friedman NE, Gertner JM, Econs MJ. Intronic deletions in the SLC34A3 gene cause hereditary hypophosphatemic rickets with hypercalciuria. *J Clin Endocrinol Metab* 2006;91(10):4022–7.
- Imel EA, Peacock M, Pitukcheewanont P, Heller HJ, Ward LM, Shulman D, et al. Sensitivity of fibroblast growth factor 23 measurements in tumor-induced osteomalacia. *J Clin Endocrinol Metab* 2006;91(6):2055–61.
- Jan de Beur SM. Tumor-induced osteomalacia. *JAMA* 2005;294(10):1260–7.
- Jehan F, Gaucher C, Nguyen TM, Walrant-Debray O, Lahlou N, Sinding C, et al. Vitamin D receptor genotype in hypophosphatemic rickets as a predictor of growth and response to treatment. *J Clin Endocrinol Metab* 2008;93(12):4672–82.
- Joshi D, Center Jr, Eisman JA. Investigation of incidental hypercalcaemia. *BMJ* 2009;339:b4613.
- Kallmes DF, Comstock BA, Heagerty PJ, Turner JA, Wilson DJ, et al. A randomized trial of vertebroplasty for osteoporotic spinal fractures. *N Engl J Med* 2009;361(6):569–79.
- Khosla S. Increasing options for the treatment of osteoporosis. *N Engl J Med* 2009;361(8):818–20.
- Khosla S. Update in male osteoporosis. *J Clin Endocrinol Metab* 2010;95(1):3–10.
- Khosla S, Melton LJ, 3rd. Clinical practice. Osteopenia. *N Engl J Med* 2007;356(22):2293–300.
- Khosla S, Westendorf JJ, Oursler MJ. Building bone to reverse osteoporosis and repair fractures. *J Clin Invest* 2008;118(2):421–8.
- Kitanaka S, Murayama A, Sakaki T, Inouye K, Seino Y, Fukumoto S, et al. No enzyme activity of 25-hydroxyvitamin D3 1 $\alpha$ -hydroxylase gene product in pseudovitamin D deficiency rickets, including that with mild clinical manifestation. *J Clin Endocrinol Metab* 1999;84(11):4111–17.
- Kitanaka S, Takeyama K, Murayama A, Sato T, Okumura K, Nogami M, et al. Inactivating mutations in the 25-hydroxyvitamin D3 1 $\alpha$ -hydroxylase gene in patients with pseudovitamin D-deficiency rickets. *N Engl J Med* 1998;338(10):653–61.
- Lew JI, Solorzano CC. Surgical management of primary hyperparathyroidism: state of the art. *Surg Clin North Am* 2009;89(5):1205–25.
- Lloyd RV, Douglas BR, Young WF Jr. Parathyroid gland. In: King DW, editor. *Atlas of Nontumor Pathology: Endocrine Diseases*. 1st ed. Washington D.C.: American Registry of Pathology and the Armed Forces Institute of Pathology; 2002. p. 45–90.
- Lorenzo JA, Canalis E, Raisz LG. Metabolic bone disease. In: Kronenberg HM, Melmed S, Polonsky KS, Larsen PR, editors. *Williams Textbook of Endocrinology*. 11th ed. Philadelphia: Saunders; 2008. p. 1269–310.
- Ma RC, Cockram CS. Pseudopseudohypoparathyroidism. *Lancet* 2009;374(9707):2090.
- Mantovani G, de Sanctis L, Barbieri AM, Elli FM, Bollati V, Vaira V, et al. Pseudohypoparathyroidism and GNAS epigenetic defects: clinical evaluation of albright hereditary osteodystrophy and molecular analysis in 40 patients. *J Clin Endocrinol Metab* 2010;95(2):651–8.
- Medarov BI. Milk-alkali syndrome. *Mayo Clin Proc* 2009;84(3):261–7.
- Menezes AH. Osteogenesis imperfecta. *J Neurosurg* 2006;105(3):359; discussion 359–60.
- Milkman LA. Pseudofractures (hunger osteopathy, late rickets, osteomalacia): Report of a case. *Am J Roentgenol* 1930;24:29–37.
- Mornet E. Hypophosphatasia. *Best Pract Res Clin Rheumatol* 2008;22(1):113–27.
- Pasiaka JL, Parsons L, Jones J. The long-term benefit of parathyroidectomy in primary hyperparathyroidism: a 10-year prospective surgical outcome study. *Surgery* 2009;146(6):1006–13.
- Peach CA, Zhang Y, Wordsworth BP. Mutations of the tissue non-specific alkaline phosphatase gene (TNAP) causing a non-lethal case of perinatal hypophosphatasia. *Rheumatology (Oxford)* 2007;46(6):1037–40.
- Perrier ND, Balachandran D, Wefel JS, Jimenez C, Busaidy N, Morris GS, et al. Prospective, randomized, controlled trial of parathyroidectomy versus observation in patients with “asymptomatic” primary hyperparathyroidism. *Surgery* 2009;146(6):1116–22.
- Petje G, Meizer R, Radler C, Aigner N, Grill F. Deformity correction in children with hereditary hypophosphatemic rickets. *Clin Orthop Relat Res* 2008;466(12):3078–85.
- Pilz S, Dobnig H, Nijpels G, Heine RJ, Stehouwer CD, Snijder MB, et al. Vitamin D and mortality in older men and women. *Clin Endocrinol (Oxf)* 2009;71(5):666–72.
- Prockop DJ. Targeting gene therapy for osteogenesis imperfecta. *N Engl J Med* 2004;350(22):2302–4.
- Raisz LG. Clinical practice. Screening for osteoporosis. *N Engl J Med* 2005;353(2):164–71.
- Ralston SH, Langston AL, Reid IR. Pathogenesis and management of Paget's disease of bone. *Lancet* 2008;372(9633):155–63.
- Rauch F, Glorieux FH. Osteogenesis imperfecta. *Lancet* 2004;363(9418):1377–85.
- Ray D, Goswami R, Gupta N, Tomar N, Singh N, Sreenivas V. Predisposition to vitamin D deficiency osteomalacia and rickets in females is linked to their 25(OH)D and calcium intake rather than vitamin D receptor gene polymorphism. *Clin Endocrinol (Oxf)* 2009;71(3):334–40.
- Riches PL, McRorie E, Fraser WD, Determann C, van't Hof R, Ralston SH. Osteoporosis associated with neutralizing autoantibodies against osteoprotegerin. *N Engl J Med* 2009;361(15):1459–65.
- Rosen CJ. Clinical practice. Postmenopausal osteoporosis. *N Engl J Med* 2005;353(6):595–603.
- Ruda JM, Hollenbeck CS, Stack BC Jr. A systematic review of the diagnosis and treatment of primary hyperparathyroidism from 1995 to 2003. *Otolaryngol Head Neck Surg* 2005;132(3):359–72.
- Saintonge S, Bang H, Gerber LM. Implications of a new definition of vitamin D deficiency in a multiracial us adolescent population: the National Health and Nutrition Examination Survey III. *Pediatrics* 2009;123(3):797–803.
- Shoback D. Update in osteoporosis and metabolic bone disorders. *J Clin Endocrinol Metab* 2007;92(3):747–53.
- Shoback D. Clinical practice. Hypoparathyroidism. *N Engl J Med* 2008;359(4):391–403.
- Stewart AF. Clinical practice. Hypercalcemia associated with cancer. *N Engl J Med* 2005;352(4):373–9.
- Tencza AL, Ichikawa S, Dang A, Kenagy D, McCarthy E, Econs MJ, et al. Hypophosphatemic rickets with hypercalciuria due to mutation in SLC34A3/type IIc sodium-phosphate cotransporter: presentation as hypercalciuria and nephrolithiasis. *J Clin Endocrinol Metab* 2009;94(11):4433–8.
- Thacher TD, Obadofin MO, O'Brien KO, Abrams SA. The effect of vitamin D2 and vitamin D3 on intestinal calcium absorption in Nigerian children with rickets. *J Clin Endocrinol Metab* 2009;94(9):3314–21.
- Unnanuntana A, Gladnick BP, Donnelly E, Lane JM. The assessment of fracture risk. *J Bone Joint Surg Am* 2010;92(3):743–53.
- Wagner CL, Greer FR. Prevention of rickets and vitamin D deficiency in infants, children, and adolescents. *Pediatrics* 2008;122(5):1142–52.
- Watts NB, Diab DL. Long-term use of bisphosphonates in osteoporosis. *J Clin Endocrinol Metab* 2010;95(4):1555–65.
- Weinstein RS, Roberson PK, Manolagas SC. Giant osteoclast formation and long-term oral bisphosphonate therapy. *N Engl J Med* 2009;360(1):53–62.
- Whyte MP. Clinical practice. Paget's disease of bone. *N Engl J Med* 2006;355(6):593–600.
- Whyte MP, Mumm S, Deal C. Adult hypophosphatasia treated with teriparatide. *J Clin Endocrinol Metab* 2007;92(4):1203–8.
- Yu N, Donnan PT, Murphy MJ, Leese GP. Epidemiology of primary hyperparathyroidism in Tayside, Scotland, UK. *Clin Endocrinol (Oxf)* 2009;71(4):485–93.

## Section 7: Lipids and Nutrition

- American Psychiatric Association. *Diagnostic and Statistical Manual of Mental Disorders*. 4th ed. Washington D.C.: American Psychiatric Association; 1994.
- Aasheim ET, Hofso D, Sovik TT. Vitamin supplements after bariatric surgery. *Clin Endocrinol (Oxf)* 2010;72(1):134–5.

- Abel LA, Walterfang M, Fietz M, Bowman EA, Velakoulis D. Saccades in adult Niemann-Pick disease type C reflect frontal, brainstem, and biochemical deficits. *Neurology* 2009;72(12):1083–6.
- Al Badarin FJ, Kullo JJ, Kopecky SL, Thomas RJ. Impact of ezetimibe on atherosclerosis: is the jury still out? *Mayo Clin Proc* 2009;84(4):353–61.
- Alberti KG, Eckel RH, Grundy SM, Zimmet PZ, Cleeman JI, Donato KA, et al. Harmonizing the metabolic syndrome: a joint interim statement of the International Diabetes Federation Task Force on Epidemiology and Prevention; National Heart, Lung, and Blood Institute; American Heart Association; World Heart Federation; International Atherosclerosis Society; and International Association for the Study of Obesity. *Circulation* 2009;120(16):1640–5.
- Ambrose JA, Srikanth S. Vulnerable plaques and patients: improving prediction of future coronary events. *Am J Med* 2010;123(1):10–16.
- Anagnostis P, Athyros VG, Tziomalos K, Karagiannis A, Mikhailidis DP. Clinical review: The pathogenetic role of cortisol in the metabolic syndrome: a hypothesis. *J Clin Endocrinol Metab* 2009;94(8):2692–701.
- Arnlov J, Ingelsson E, Sundstrom J, Lind L. Impact of body mass index and the metabolic syndrome on the risk of cardiovascular disease and death in middle-aged men. *Circulation* 2010;121(2):230–6.
- Ashen MD, Blumenthal RS. Clinical practice. Low HDL cholesterol levels. *N Engl J Med* 2005;353(12):1252–60.
- Ashourian N, Mousdicas N. Images in clinical medicine. Pellagra-like dermatitis. *N Engl J Med* 2006;354(15):1614.
- Atia E, Walsh BT. Behavioral management for anorexia nervosa. *N Engl J Med* 2009;360(5):500–6.
- August GP, Caprio S, Fenoy I, Freemark M, Kaufman FR, Lustig RH, et al. Prevention and treatment of pediatric obesity: an endocrine society clinical practice guideline based on expert opinion. *J Clin Endocrinol Metab* 2008;93(12):4576–99.
- Batis JA, Lopez-Jimenez F, Collazo-Clavell ML, Clark MM, Somers VK, Sarr MG. Quality of life after bariatric surgery: a population-based cohort study. *Am J Med* 2009;122(11):1055 e1051–1055 e1010.
- Belfort R, Berria R, Cornell J, Cusi K. Fenofibrate reduces systemic inflammation markers independent of its effects on lipid and glucose metabolism in patients with the metabolic syndrome. *J Clin Endocrinol Metab* 2010;95(2):829–36.
- Brabin B. Infant vitamin A supplementation: consensus and controversy. *Lancet* 2007;369(9579):2054–6.
- Braegger CP, Belli DC, Mentha G, Steinmann B. Persistence of the intestinal defect in abetalipoproteinemia after liver transplantation. *Eur J Pediatr* 1998;157(7):576–8.
- Briel M, Ferreira-Gonzalez I, You JJ, Karanickolas PJ, Akl EA, Wu P, et al. Association between change in high density lipoprotein cholesterol and cardiovascular disease morbidity and mortality: systematic review and meta-regression analysis. *BMJ* 2009;338:b92.
- Brooks AM, Paisey RB, Waterson MJ, Smith JC. Diagnostic difficulties with a lipaemic blood sample. *BMJ* 2010;340:b530.
- Brown TM, Voeks JH, Bittner V, Safford MM. Variations in prevalent cardiovascular disease and future risk by metabolic syndrome classification in the REasons for Geographic and Racial Differences in Stroke (REGARDS) study. *Am Heart J* 2010;159(3):385–91.
- Brunzell JD. Clinical practice. Hypertriglyceridemia. *N Engl J Med* 2007;357(10):1009–17.
- Califf RM, Harrington RA, Blazing MA. Premature release of data from clinical trials of ezetimibe. *N Engl J Med* 2009;361(7):712–17.
- Carpenter KJ. The history of scurvy and vitamin C. New York: Cambridge University Press; 1986.
- Cheng TO. Lind's SCURVY trial. *J Lab Clin Med* 2004;144(1):53.
- Chillaron JJ, Goday A, Flores-Le-Roux JA, Benaiges D, Carrera MJ, Puig J, et al. Estimated glucose disposal rate in assessment of the metabolic syndrome and microvascular complications in patients with type 1 diabetes. *J Clin Endocrinol Metab* 2009;94(9):3530–4.
- Cho NH, Chan JC, Jang HC, Lim S, Kim HL, Choi SH. Cigarette smoking is an independent risk factor for type 2 diabetes: a four-year community-based prospective study. *Clin Endocrinol (Oxf)* 2009;71(5):679–85.
- Choh CT, Rai S, Abdelhamid M, Lester W, Vohra RK. Unrecognized scurvy. *BMJ* 2009;339:b3580.
- Civeira F, Jarauta E, Cenarro A, Garcia-Otin AL, Tejedor D, Zambon D, et al. Frequency of low-density lipoprotein receptor gene mutations in patients with a clinical diagnosis of familial combined hyperlipidemia in a clinical setting. *J Am Coll Cardiol* 2008;52(19):1546–53.
- Civeira F, Ros E, Jarauta E, Plana N, Zambon D, Puzo J, et al. Comparison of genetic versus clinical diagnosis in familial hypercholesterolemia. *Am J Cardiol* 2008;102(9):1187–93.
- Cole RP. Heparin treatment for severe hypertriglyceridemia in diabetic ketoacidosis. *Arch Intern Med* 2009;169(15):1439–41.
- Comabella M, Canton A, Montalban X, Codina A. Iatrogenic fulminant beriberi. *Lancet* 1995;346(8968):182–3.
- Crane AM. Anorexia nervosa. Awareness is key. *BMJ* 2010;340:c295.
- Crow SJ, Peterson CB, Swanson SA, Raymond NC, Specker S, Eckert ED, et al. Increased mortality in bulimia nervosa and other eating disorders. *Am J Psychiatry* 2009;166(12):1342–6.
- Davidson MH, Rosenson RS. Novel targets that affect high-density lipoprotein metabolism: the next frontier. *Am J Cardiol* 2009;104(10 Suppl):52E–7E.
- Davis HR Jr, Murgolo NJ, Graziano MP. Simvastatin with or without ezetimibe in familial hypercholesterolemia. *N Engl J Med* 2008;359(5):531; author reply 532–3.
- Deedwania P, Singh V, Davidson MH. Low high-density lipoprotein cholesterol and increased cardiovascular disease risk: an analysis of statin clinical trials. *Am J Cardiol* 2009;104(10 Suppl):3E–9E.
- Di Sabatino A, Corazza GR. Coeliac disease. *Lancet* 2009;373(9673):1480–93.
- Dietz WH, Robinson TN. Clinical practice. Overweight children and adolescents. *N Engl J Med* 2005;352(20):2100–9.
- Ding EL, Smit LA, Hu FB. The metabolic syndrome as a cluster of risk factors: is the whole greater than the sum of its parts?: comment on “The metabolic syndrome, its component risk factors, and progression of coronary atherosclerosis”. *Arch Intern Med* 2010;170(5):484–5.
- Dod HS, Bhardwaj R, Sajja V, Weidner G, Hobbs GR, Konat GW, et al. Effect of intensive lifestyle changes on endothelial function and on inflammatory markers of atherosclerosis. *Am J Cardiol* 2010;105(3):362–7.
- Donnino M. Gastrointestinal beriberi: a previously unrecognized syndrome. *Ann Intern Med* 2004;141(11):898–9.
- Doosti M, Najafi M, Reza JZ, Nikzamid A. The role of ATP-binding-cassette-transporter-A1 (ABCA1) gene polymorphism on coronary artery disease risk. *Transl Res* 2010;155(4):185–90.
- Duggan CP, Westra SJ, Rosenberg AE. Case records of the Massachusetts General Hospital. Case 23–2007. A 9-year-old boy with bone pain, rash, and gingival hypertrophy. *N Engl J Med* 2007;357(4):392–400.
- Eckel RH. Clinical practice. Nonsurgical management of obesity in adults. *N Engl J Med* 2008;358(18):1941–50.
- Eckel RH, Alberti KG, Grundy SM, Zimmet PZ. The metabolic syndrome. *Lancet* 2010;375(9710):181–3.
- Fazio S, Guyton Jr, Polis AB, Adewale AJ, Tomassini JE, Ryan NW, et al. Long-term safety and efficacy of triple combination ezetimibe/simvastatin plus extended-release niacin in patients with hyperlipidemia. *N Engl J Med* 2010;105(4):487–94.
- Fletcher RH, Fairfield KM. Vitamins for chronic disease prevention in adults: clinical applications. *JAMA* 2002;287(23):3127–9.
- Ford ES, Li C, Zhao G, Pearson WS, Mokdad AH. Hypertriglyceridemia and its pharmacologic treatment among US adults. *Arch Intern Med* 2009;169(6):572–8.
- Franks PW, Hanson RL, Knowler WC, Sievers ML, Bennett PH, Looker HC. Childhood obesity, other cardiovascular risk factors, and premature death. *N Engl J Med* 2010;362(6):485–93.
- Fredrickson DS. The inheritance of high density lipoprotein deficiency (Tangier disease). *J Clin Invest* 1964;43:228–36.
- Garcia-Otin AL, Cofan M, Junyent M, Recalde D, Cenarro A, Pucovi M, et al. Increased intestinal cholesterol absorption in autosomal dominant hypercholesterolemia and no mutations in the low-density lipoprotein receptor or apolipoprotein B genes. *J Clin Endocrinol Metab* 2007;92(9):3667–73.
- Ghali WA, Rondoni N. HDL cholesterol and cardiovascular risk. *BMJ* 2009;338:a3065.
- Girish MP, Gupta MD. Xanthomas pseudospectacles in familial hypercholesterolemia. *N Engl J Med* 2005;352(23):2424.
- Goldberger J. The etiology of pellagra. 1914. *Public Health Rep* 2006;121(Suppl 1):77–9; discussion 76.
- Gottlieb MG V, Mancia da Cruz IB, Duarte MM.F, Moresco RN, Wiehe M, Schwanke CHA, Bodanese LC. Associations among metabolic syndrome, ischemia, inflammatory, oxidatives, and lipids biomarkers. *J Clin Endocrinol Metab* 2010;95:586–91.
- Grabowski GA. Phenotype, diagnosis, and treatment of Gaucher's disease. *Lancet* 2008;372(9645):1263–71.
- Graham GG. Starvation in the modern world. *N Engl J Med* 1993;328(14):1058–61.
- Guardamagna O, Restagno G, Rolfo E, Pederiva C, Martini S, Abello F, et al. The type of LDLR gene mutation predicts cardiovascular risk in children with familial hypercholesterolemia. *J Pediatr* 2009;155(2):199–204 e192.
- Gull AT. On certain affection of the skin, vitiligoidea—(a) plana: (b) tuberosa with remarks. *Guy's Hosp Rep* 1851;7.
- Gustafson JK, Yanoff LB, Easter BD, Brady SM, Keil MF, Roberts MD, et al. The stability of metabolic syndrome in children and adolescents. *J Clin Endocrinol Metab* 2009;94(12):4828–34.
- Hayes BB, Boyd AS. Eruptive xanthomas. Papules may indicate underlying lipid disorder. *Postgrad Med* 2005;118(2):11–12.
- Hegele RA. Familial hypercholesterolemia. *N Engl J Med* 2007;356(17):1779; author reply 1779–80.
- Houston MC, Fazio S, Chilton FH, Wise DE, Jones KB, Barringer TA, et al. Nonpharmacologic treatment of dyslipidemia. *Prog Cardiovasc Dis* 2009;52(2):61–94.
- Kamanna VS, Kashyap ML. Mechanism of action of niacin. *Am J Cardiol* 2008;101(8A):20B–6B.
- Karthiga S, Dube S, Garber S, Watts R. Scurvy: MRI appearances. *Rheumatology (Oxford)* 2008;47(7):1109.
- Kastelein JJ, Bots ML. Statin therapy with ezetimibe or niacin in high-risk patients. *N Engl J Med* 2009;361(22):2180–3.
- Klein S, Romijn JA. Obesity. In: Kronenberg HM, Melmed S, Polonsky KS, Larsen PR, editors. *Williams Textbook of Endocrinology*. 11th ed. Philadelphia: Saunders; 2008. p. 1563–88.
- Ladenson PW, Kristensen JD, Ridgway EC, Olsson AG, Carlsson B, Klein I, et al. Use of the thyroid hormone analogue eprotirome in statin-treated dyslipidemia. *N Engl J Med* 2010;362(10):906–16.
- Lawson EA, Donoho D, Miller KK, Misra M, Meenaghan E, Lydecker J, et al. Hypercortisolemia is associated with severity of bone loss and depression in hypothalamic amenorrhea and anorexia nervosa. *J Clin Endocrinol Metab* 2009;94(12):4710–16.
- Leff DR, Heath D. Surgery for obesity in adulthood. *BMJ* 2009;339:b3402.
- Leggett J, Convery R. Images in clinical medicine. Scurvy. *N Engl J Med* 2001;345(25):1818.
- Li SG. Images in clinical medicine. Familial hypercholesterolemia. *N Engl J Med* 2009;360(18):1885.
- Libby P, Ridker PM, Hansson GK. Inflammation in atherosclerosis: from pathophysiology to practice. *J Am Coll Cardiol* 2009;54(23):2129–38.
- Livingston EH. Surgical treatment of obesity in adolescence. *JAMA* 2010;303(6):559–60.
- Logue J, Thompson L, Romanes F, Wilson DC, Thompson J, Sattar N. Management of obesity: summary of SIGN guideline. *BMJ* 2010;340:e154.
- Ludvigsson JF, Montgomery SM, Ekbohm A, Brandt L, Granath F. Small-intestinal histopathology and mortality risk in celiac disease. *JAMA* 2009;302(11):1171–8.
- Mahley RW, Weisgraber KH, Bersot TP. Disorders of lipid metabolism. In: Kronenberg HM, Melmed S, Polonsky KS, Larsen PR, editors. *Williams Textbook of Endocrinology*. 11th ed. Philadelphia: Saunders; 2008. p. 1589–654.
- Malinowski SS. Nutritional and metabolic complications of bariatric surgery. *Am J Med Sci* 2006;331(4):219–25.
- Mantaring M, Rhyne J, Ho Hong S, Miller M. Genotypic variation in ATP-binding cassette transporter-1 (ABCA1) as contributors to the high and low high-density lipoprotein-cholesterol (HDL-C) phenotype. *Transl Res* 2007;149(4):205–10.
- Martins AM, Valadares ER, Porta G, Coelho J, Semionato Filho J, Pianovski MA, et al. Recommendations on diagnosis, treatment, and monitoring for Gaucher disease. *J Pediatr* 2009;155(4 Suppl):S10–18.
- Mathieu P, Lemieux I, Despres JP. Obesity, inflammation, and cardiovascular risk. *Clin Pharmacol Ther* 2010;87(4):407–16.
- Matrana MR, Vasireddy S, Davis WE. The skinny on a growing problem: dry beriberi after bariatric surgery. *Ann Intern Med* 2008;149(11):842–4.
- McGowan KE, Castiglione DA, Butzner JD. The changing face of childhood celiac disease in north america: impact of serological testing. *Pediatrics* 2009;124(6):1572–8.
- McKnight R, Boughton N. A patient's journey. Anorexia nervosa. *BMJ* 2009;339:b3800.
- Mehler PS. Clinical practice. Bulimia nervosa. *N Engl J Med* 2003;349(9):875–81.
- Moreno PR, Sanz J, Fuster V. Promoting mechanisms of vascular health: circulating progenitor cells, angiogenesis, and reverse cholesterol transport. *J Am Coll Cardiol* 2009;53(25):2315–23.
- Mulleman D, Goupille P. Medical mystery: extensive ecchymosis—the answer. *N Engl J Med* 2006;354(4):419–20.
- Mziray-Andrew CH, Sentongo TA. Nutritional deficiencies in intestinal failure. *Pediatr Clin North Am* 2009;56(5):1185–200.
- Natarajan P, Ray KK, Cannon CP. High-density lipoprotein and coronary heart disease: current and future therapies. *J Am Coll Cardiol* 2010;55(13):1283–99.
- National Cholesterol Education Program (NCEP) Expert Panel on Detection, Evaluation, and Treatment of High Blood Cholesterol in Adults (Adult Treatment Panel III). Third Report of the National Cholesterol Education Program (NCEP) Expert Panel on Detection, Evaluation, and Treatment of High Blood Cholesterol in Adults (Adult Treatment Panel III) final report. *Circulation* 2002. 106(25):3143–421.
- Navab M, Anantharamiah GM, Reddy ST, Van Lenten BJ, Fogelman AM. HDL as a biomarker, potential therapeutic target, and therapy. *Diabetes* 2009;58(12):2711–17.
- Nayak KR, Daly RG. Images in clinical medicine. Eruptive xanthomas associated with hypertriglyceridemia and new-onset diabetes mellitus. *N Engl J Med* 2004;350(12):1235.
- Nichols GA, Ambegaonkar BM, Sazonov V, Brown JB. Frequency of obtaining national cholesterol education program adult treatment panel III goals for all major serum lipoproteins after initiation of lipid altering therapy. *Am J Cardiol* 2009;104(12):1689–94.
- O'Brien PE, Sawyer SM, Laurie C, Brown WA, Skinner S, Veit F, et al. Laparoscopic adjustable gastric banding in severely obese adolescents: a randomized trial. *JAMA* 2010;303(6):519–26.



- O'Mahony C, Elliott P. Anderson-Fabry disease and the heart. *Prog Cardiovasc Dis* 2010;52(4):326–35.
- Pemberton J. Unrecognised scurvy. Signs and requirements. *BMJ* 2010;340:c590.
- Penniston KL, Tanumihardjo SA. The acute and chronic toxic effects of vitamin A. *Am J Clin Nutr* 2006;83(2):191–201.
- Pournaras DJ, le Roux CW. After bariatric surgery, what vitamins should be measured and what supplements should be given? *Clin Endocrinol (Oxf)* 2009;71(3):322–5.
- Preiss D, Sattar N. Lipids, lipid modifying agents and cardiovascular risk: a review of the evidence. *Clin Endocrinol (Oxf)* 2009;70(6):815–28.
- Rader DJ, Brewer HB Jr. Abetalipoproteinemia. New insights into lipoprotein assembly and vitamin E metabolism from a rare genetic disease. *JAMA* 1993;270(7):865–9.
- Rajakumar K. Pellagra in the United States: a historical perspective. *South Med J* 2000;93(3):272–7.
- Rajakumar K. Infantile scurvy: a historical perspective. *Pediatrics* 2001;108(4):E76.
- Richey R, Howdle P, Shaw E, Stokes T. Recognition and assessment of coeliac disease in children and adults: summary of NICE guidance. *BMJ* 2009;338:b1684.
- Ridker PM, Danielson E, Fonseca FA, Genest J, Gotto AM Jr, Kastelein JJ, et al. Reduction in C-reactive protein and LDL cholesterol and cardiovascular event rates after initiation of rosuvastatin: a prospective study of the JUPITER trial. *Lancet* 2009;373(9670):1175–82.
- Rosenzweig JL, Ferrannini E, Grundy SM, Haffner SM, Heine RJ, Horton ES, et al. Primary prevention of cardiovascular disease and type 2 diabetes in patients at metabolic risk: an endocrine society clinical practice guideline. *J Clin Endocrinol Metab* 2008;93(10):3671–89.
- Rubino F, Kaplan LM, Schauer PR, Cummings DE. The Diabetes Surgery Summit consensus conference: recommendations for the evaluation and use of gastrointestinal surgery to treat type 2 diabetes mellitus. *Ann Surg* 2010;251(3):399–405.
- Sampietro T, Puntoni M, Bigazzi F, Pennato B, Sbrana F, Dal Pino B, et al. Images in cardiovascular medicine. Tangier disease in severely progressive coronary and peripheral artery disease. *Circulation* 2009;119(20):2741–2.
- Sattar N, Preiss D, Murray HM, Welsh P, Buckley BM, de Craen AJ, et al. Statins and risk of incident diabetes: a collaborative meta-analysis of randomised statin trials. *Lancet* 2010;375(9716):735–42.
- Schipping S, Orth M, Beisiegel U, Rosenkranz T, Vogel P, Munchau A, et al. Severe Tangier disease with a novel ABCA1 gene mutation. *Neurology* 2008;71(18):1454–5.
- Schuppan D, Junker Y, Barisani D. Celiac disease: from pathogenesis to novel therapies. *Gastroenterology* 2009;137(6):1912–33.
- Shah AS, Dolan LM, Kimball TR, Gao Z, Khoury PR, Daniels SR, et al. Influence of duration of diabetes, glycemic control, and traditional cardiovascular risk factors on early atherosclerotic vascular changes in adolescents and young adults with type 2 diabetes mellitus. *J Clin Endocrinol Metab* 2009;94(10):3740–5.
- Shai I, Spence JD, Schwarzfuchs D, Henkin Y, Parraga G, Rudich A, et al. Dietary intervention to reverse carotid atherosclerosis. *Circulation* 2010;121(10):1200–8.
- Sharma M, Ansari MT, Abou-Setta AM, Soares-Weiser K, Ooi TC, Sears M, et al. Systematic review: comparative effectiveness and harms of combination therapy and monotherapy for dyslipidemia. *Ann Intern Med* 2009;151(9):622–30.
- Singh IM, Shishehbor MH, Ansell BJ. High-density lipoprotein as a therapeutic target: a systematic review. *JAMA* 2007;298(7):786–98.
- Siri-Tarino PW, Sun Q, Hu FB, Krauss RM. Saturated fat, carbohydrate, and cardiovascular disease. *Am J Clin Nutr* 2010;91(3):502–9.
- Stalenhoef AF. Images in clinical medicine. Phytosterolemia and xanthomatosis. *N Engl J Med* 2003;349(1):51.
- Staretz-Chacham O, Lang TC, LaMarca ME, Krasnewich D, Sidransky E. Lysosomal storage disorders in the newborn. *Pediatrics* 2009;123(4):1191–207.
- Strang AC, Hovingh GK, Stroes ES, Kastelein JJ. The genetics of high-density lipoprotein metabolism: clinical relevance for therapeutic approaches. *Am J Cardiol* 2009;104(10 Suppl):22E–31E.
- Superko HR. Cardiovascular event risk: high-density lipoprotein and paraoxonase. *J Am Coll Cardiol* 2009;54(14):1246–8.
- Suskind DL. Nutritional deficiencies during normal growth. *Pediatr Clin North Am* 2009;56(5):1035–53.
- Tall AR. The effects of cholesterol ester transfer protein inhibition on cholesterol efflux. *Am J Cardiol* 2009;104(10 Suppl):39E–45E.
- Tanigawa H, Billheimer JT, Tohyama J, Fuki IV, Ng DS, Rothblat GH, et al. Lecithin: cholesterol acyltransferase expression has minimal effects on macrophage reverse cholesterol transport in vivo. *Circulation* 2009;120(2):160–9.
- Towbin A, Inge TH, Garcia VF, Roehrig HR, Clements RH, Harmon CM, et al. Beriberi after gastric bypass surgery in adolescence. *J Pediatr* 2004;145(2):263–7.
- Treasure J, Claudino AM, Zucker N. Eating disorders. *Lancet* 2010;375(9714):583–93.
- van der Graaf A, Fouchier SW, Vissers MN, Defesche JC, Wiegman A, Sankatsing RR, et al. Familial defective apolipoprotein B and familial hypobetalipoproteinemia in one family: two neutralizing mutations. *Ann Intern Med* 2008;148(9):712–14.
- Vega GL, Barlow CE, Grundy SM. Prevalence of the metabolic syndrome as influenced by the measure of obesity employed. *Am J Cardiol* 2010;105(9):1306–12.
- Ward H, Mitrou PN, Bowman R, Luben R, Wareham NJ, Khaw KT, et al. APOE genotype, lipids, and coronary heart disease risk: a prospective population study. *Arch Intern Med* 2009;169(15):1424–9.
- Weiner M, Van Eys J. The discovery of nicotinic acid as a nutrient: clinical pharmacology. In: Weiner M, editor. *Nicotinic acid: Nutrient-cofactor-drug*. New York: Marcel Dekker; 1983. p. 3.
- Yager J, Andersen AE. Clinical practice. Anorexia nervosa. *N Engl J Med* 2005;353(14):1481–8.
- Zarate YA, Hopkin RJ. Fabry's disease. *Lancet* 2008;372(9647):1427–35.
- Zhang Y, McGillicuddy FC, Hinkle CC, O'Neill S, Glick JM, Rothblat GH, et al. Adipocyte modulation of high-density lipoprotein cholesterol. *Circulation* 2010;121(11):1347–55.

## Section 8: Genetics and Endocrine Neoplasia

- Akerstrom G, Stalberg P. Surgical management of MEN-1 and -2: state of the art. *Surg Clin North Am* 2009;89(5):1047–68.
- Alimohammadi M, Bjorklund P, Hallgren A, Pontynen N, Szinnai G, Shikama N, et al. Autoimmune polyendocrine syndrome type 1 and NALP5, a parathyroid autoantigen. *N Engl J Med* 2008;358(10):1018–28.
- Anderson MS. Update in endocrine autoimmunity. *J Clin Endocrinol Metab* 2008;93(10):3663–70.
- Arnold A. Pathogenesis of endocrine tumors. In: Kronenberg HM, Melmed S, Polonsky KS, Larsen PR, editors. *Williams Textbook of Endocrinology*. 11th ed. Philadelphia: Saunders; 2008. p. 1697–704.
- Barker JM, Gottlieb PA, Eissenbarth GS. The immunoendocrinopathy syndromes. In: Kronenberg HM, Melmed S, Polonsky KS, Larsen PR, editors. *Williams Textbook of Endocrinology*. 11th ed. Philadelphia: Saunders; 2008. p. 1747–62.
- Bhattacharyya S, Davar J, Dreyfus G, Caplin ME. Carcinoid heart disease. *Circulation* 2007;116(24):2860–5.
- Blansflavsky G, Choyke L, Morita SY, Choyke PL, Pingpank JF, Alexander HR, et al. Clinical, genetic and radiographic analysis of 108 patients with von Hippel-Lindau disease (VHL) manifested by pancreatic neuroendocrine neoplasms (PNETs). *Surgery* 2007;142(6):814–8; discussion 818 e811–812.
- Boedeker CC, Eric Z, Richard S, Kontny T, Gimenez-Roqueplo AP, Cascon A, et al. Head and neck paragangliomas in von Hippel-Lindau disease and multiple endocrine neoplasia type 2. *J Clin Endocrinol Metab* 2009;94(6):1938–44.
- Bratslavsky G, Liu JJ, Johnson AD, Sudarshan S, Choyke PL, et al. Salvage partial nephrectomy for hereditary renal cancer: feasibility and outcomes. *J Urol* 2008;179(1):67–70.
- Burgess J. How should the patient with multiple endocrine neoplasia type 1 (MEN 1) be followed? *Clin Endocrinol (Oxf)* 2010;72(1):13–16.
- Butman JA, Linehan WM, Lonsler RR. Neurologic manifestations of von Hippel-Lindau disease. *JAMA* 2008;300(11):1334–42.
- Calender A, Morrison CD, Komminoth P, Scaozze JY, Sweet KM, Teh BT. Multiple endocrine neoplasia type 1. In: DeLellis RA, Lloyd RV, Heitz PU, Eng C, editors. *World Health Organization Classification of Tumours. Pathology and Genetics of Tumours of Endocrine Organs*. Lyon: IARC Press; 2004. p. 218–27.
- Clark PE, Cookson MS. The von Hippel-Lindau gene: turning discovery into therapy. *Cancer* 2008;113(7 Suppl):1768–78.
- Dittmar M, Kahaly GJ. Polyglandular autoimmune syndromes: immunogenetics and long-term follow-up. *J Clin Endocrinol Metab* 2003;88(7):2983–92.
- Drucker JJ. Gastrointestinal hormones and gut endocrine tumors. In: Kronenberg HM, Melmed S, Polonsky KS, Larsen PR, editors. *Williams Textbook of Endocrinology*. 11th ed. Philadelphia: Saunders; 2008. p. 1675–94.
- Elisei R, Romei C, Cosci B, Agate L, Bottici V, Molinaro E, et al. RET genetic screening in patients with medullary thyroid cancer and their relatives: experience with 807 individuals at one center. *J Clin Endocrinol Metab* 2007;92(12):4725–9.
- Evans DG. R, Komminoth P, Scheithauer BW, Peltonen J. Neurofibromatosis type 1. In: DeLellis RA, Lloyd RV, Heitz PU, Eng C, editors. *World Health Organization Classification of Tumours. Pathology and Genetics of Tumours of Endocrine Organs*. Lyon: IARC Press; 2004. p. 243–8.
- Gaal J, van Nederveen FH, Eric Z, Korpershoek E, Oldenburg R, Boedeker CC, et al. Parasympathetic paragangliomas are part of the Von Hippel-Lindau syndrome. *J Clin Endocrinol Metab* 2009;94(11):4367–71.
- Gagel RF, Marx SJ. Multiple endocrine neoplasia. In: Kronenberg HM, Melmed S, Polonsky KS, Larsen PR, editors. *Williams Textbook of Endocrinology*. 11th ed. Philadelphia: Saunders; 2008. p. 1705–46.

- Gauger PG, Doherty GM, Broome JT, Miller BS, Thompson NW. Completion pancreatectomy and duodenectomy for recurrent MEN-1 pancreaticoduodenal endocrine neoplasms. *Surgery* 2009;146(4):801–6; discussion 807–808.
- Gavalas NG, Kemp EH, Krohn KJ, Brown EM, Watson PF, Weetman AP. The calcium-sensing receptor is a target of autoantibodies in patients with autoimmune polyendocrine syndrome type 1. *J Clin Endocrinol Metab* 2007;92(6):2107–14.
- Goudet P, Murat A, Binquet C, Cardot-Bauters C, Costa A, et al. Risk factors and causes of death in MEN1 disease. A GTE (Groupe d'Etude des Tumeurs Endocrines) cohort study among 758 patients. *World J Surg* 2010;34(2):249–55.
- Grimm O, Morrison CD, Suster S, Komminoth P, et al. Multiple endocrine neoplasia type 2. In: DeLellis RA, Lloyd RV, Heitz PU, Eng C, editors. *World Health Organization Classification of Tumours. Pathology and Genetics of Tumours of Endocrine Organs*. Lyon: IARC Press; 2004. p. 211–17.
- Jagannathan J, Lonsler RR, Smith R, DeVroom HL, Oldfield EH. Surgical management of cerebellar hemangioblastomas in patients with von Hippel-Lindau disease. *J Neurosurg* 2008;108(2):210–22.
- Jensen RT, Berna MJ, Bingham DB, Norton JA. Inherited pancreatic endocrine tumor syndromes: advances in molecular pathogenesis, diagnosis, management, and controversies. *Cancer* 2008;113(7 Suppl):1807–43.
- Kamaoui I, De-Luca V, Ficarelli S, Mennesson N, Lombard-Bohas C, Pilleul F. Value of CT enterocystography in suspected small-bowel carcinoid tumors. *AJR Am J Roentgenol* 2010;194(3):629–33.
- Lloyd RV, Douglas BR, Young WF Jr. Diffuse neuroendocrine system. In: King DW, editor. *Atlas of Nontumor Pathology: Endocrine Diseases*. 1st ed. Washington D.C.: American Registry of Pathology and the Armed Forces Institute of Pathology; 2002. p. 259–308.
- Maher ER, Nathanson K, Komminoth P, Neumann HP, H, Plate KH, Bohling T, Schneider K. Von Hippel-Lindau syndrome (VHL). In: DeLellis RA, Lloyd RV, Heitz PU, Eng C, editors. *World Health Organization Classification of Tumours. Pathology and Genetics of Tumours of Endocrine Organs*. Lyon: IARC Press; 2004. p. 230–7.
- Messiaen L, Yao S, Brems H, Callens T, Sathienkijkanchai A, et al. Clinical and mutational spectrum of neurofibromatosis type 1-like syndrome. *JAMA* 2009;302(19):2111–18.
- Morrow EH, Norton JA. Surgical management of Zollinger-Ellison syndrome; state of the art. *Surg Clin North Am* 2009;89(5):1091–103.
- Neumann HP, Vortmeyer A, Schmidt D, Werner M, Eric Z, et al. Evidence of MEN-2 in the original description of classic pheochromocytoma. *N Engl J Med* 2007;357(13):1311–15.
- Nunley KS, Gao F, Albers AC, Bayliss SJ, Gutmann DH. Predictive value of café au lait macules at initial consultation in the diagnosis of neurofibromatosis type 1. *Arch Dermatol* 2009;145(8):883–7.
- Oberg KE. Carcinoid tumors, carcinoid syndrome, and related disorders. In: Kronenberg HM, Melmed S, Polonsky KS, Larsen PR, editors. *Williams Textbook of Endocrinology*. 11th ed. Philadelphia: Saunders; 2008. p. 1821–40.
- Pasieka JL. Carcinoid tumors. *Surg Clin North Am* 2009;89(5):1123–37.
- Powell AC, Libutti SK. Multiple endocrine neoplasia type 1: clinical manifestations and management. *Cancer Treat Res* 2010;153:287–302.
- Quayle FJ, Fialkowski EA, Benveniste R, Moley JF. Pheochromocytoma penetrance varies by RET mutation in MEN 2A. *Surgery* 2007;142(6):800–5; discussion 805 e801.
- Skinner MA, Moley JA, Dillely WG, Ozwar K, DeBenedetti MK, Wells SA Jr. Prophylactic thyroidectomy in multiple endocrine neoplasia type 2A. *N Engl J Med* 2005;353(11):1105–13.
- Su MA, Giang K, Zumer K, Jiang H, Owen I, Rinn JL, et al. Mechanisms of an autoimmunity syndrome in mice caused by a dominant mutation in Aire. *J Clin Invest* 2008;118(5):1712–26.
- Taieb A, Picardo M. Clinical practice. Vitiligo. *N Engl J Med* 2009;360(2):160–9.
- Tham E, Grandell U, Lindgren E, Toss G, Skogseid B, Nordenskjöld M. Clinical testing for mutations in the MEN1 gene in Sweden: a report on 200 unrelated cases. *J Clin Endocrinol Metab* 2007;92(9):3389–95.
- Turner JJ, Christie PT, Pearce SH, Turpenney PD, Thakker RV. Diagnostic challenges due to phenocopies: lessons from Multiple Endocrine Neoplasia type 1 (MEN1). *Hum Mutat* 2010;31(11):E1089–101.
- Williams VC, Lucas J, Babcock MA, Gutmann DH, Korf B, Maria BL. Neurofibromatosis type 1 revisited. *Pediatrics* 2009;123(1):124–33.
- Wilson SD, Krzywdy EA, Zhu YR, Yen TW, Wang TS, Sugg SL, et al. The influence of surgery in MEN-1 syndrome: observations over 150 years. *Surgery* 2008;144(4):695–701; discussion 701–692.
- You YN, Thompson GB, Young WF Jr, Larson D, Farley DR, Richards M, et al. Pancreatoduodenal surgery in patients with multiple endocrine neoplasia type 1: operative outcomes, long-term function, and quality of life. *Surgery* 2007;142(6):829–36; discussion 836; e821.

## A

- ABCA1* gene mutations, in Tangier disease, 190
- Abdomen, pendulous, in Cushing syndrome, 76
- Abdominal aorta, 69
- Abdominal obesity  
in Cushing syndrome, 76  
in diabetes mellitus, 140  
measurement of, 209  
in metabolic syndrome, 197
- Abducens nerve, 6, 7
- Abetalipoproteinemia, 190
- Acanthocytosis, in abetalipoproteinemia, 190
- Acarbose, for diabetes mellitus, 148
- Acetyl-CoA, in tricarboxylic acid cycle, 135
- Achilles tendon, xanthoma of, 189
- Acidosis  
diabetic, 138  
from insulin deprivation, 137
- Acinar cells, pancreatic, 129, 130, 131
- Acini, pancreatic, 129, 130
- Acne, 84, 106, 107
- Acromegaly, 22
- ACTH (adrenocorticotropic hormone). *See* Corticotropin.
- Adenectomy, transsphenoidal selective, for corticotropin-secreting pituitary tumor, 24
- Adenohypophysis. *See* Pituitary gland, anterior.
- Adenoma  
adrenal, 79  
aldosterone-producing, 87, 88  
basophil, 24  
corticotroph, 24, 25  
gonadotroph, 26  
null cell, 26  
pituitary, 13, 24, 25, 26, 213  
toxic, 47, 48
- Adenosine triphosphate (ATP), formation of  
in glycolysis, 134  
in tricarboxylic acid cycle, 135
- ADH (antidiuretic hormone). *See* Vasopressin.
- Adrenal artery, 68, 69, 71
- Adrenal crisis, 90
- Adrenal glands, 65–98, 129  
accessory, 67  
adenoma of, 79  
anatomy of, 68, 69  
androgens and. *See* Androgen, adrenal.  
blood supply of, 68, 71  
cortex of  
atrophy of, 18, 79  
carcinoma of, 79  
cells of, 71  
development of, 67  
hormones of, 72–74. *See also specific hormones, e.g.,* Cortisol.  
insufficiency of. *See* Adrenal insufficiency.  
primary pigmented nodular disease of, 79, 80  
steroidogenic enzymes of, 74  
tumors of, 85, 109, 121  
development of, 67  
in gonadal development, 100  
hemorrhage of, 90  
histology of, 71  
hyperplasia of. *See* Adrenal hyperplasia.  
in hypothalamic-pituitary-adrenal (HPA) axis, 72  
innervation of, 70  
medulla of, 94  
catecholamines and, 94  
cells of, 71, 94  
development of, 67  
metastatic disease to, 98  
pheochromocytoma arising in, 96–97  
surgical approaches to, 69  
tuberculosis of, 91
- Adrenal hyperplasia  
congenital  
classic, 82–83  
late-onset (nonclassic), 85  
major blocks causing, 81  
precocious puberty in, 108  
virilization in, 111, 113, 121  
in Cushing syndrome, 78  
lipoid, 81, 82  
massive, ACTH-independent, 79
- Adrenal insufficiency  
acute, 90  
autoimmune, 91  
primary  
in autoimmune polyglandular syndrome, 218  
chronic, 91  
laboratory findings in, 92  
treatment of, 92  
secondary, 11, 16, 17  
laboratory findings in, 93  
treatment of, 93
- Adrenal nerves, 70
- Adrenal rest tumor, testicular, 109
- Adrenal vein, 68, 69, 71
- Adrenal venous sampling, 87, 88
- Adrenalectomy  
approaches to, 69  
bilateral, Nelson syndrome after, 25  
for primary aldosteronism, 87  
for primary pigmented nodular adrenocortical disease, 80
- Adrenarcho, 84, 104  
premature, 109
- Adrenergic inhibitors, beta, in diabetes mellitus, 145
- Adrenergic receptors, 71, 94
- Adrenocorticotropic hormone (ACTH). *See* Corticotropin.
- Adrenogenital syndromes, adult, 85
- Albright hereditary osteodystrophy, 165, 166
- Albumin, in diabetic nephropathy, 143
- Alcoholism, Wernicke-Korsakoff syndrome in, 201
- Aldosterone  
adenoma producing, 87, 88  
in adrenal insufficiency, 92  
biologic actions of, 86  
deficiency, 83  
metabolism of, 74  
in renin-angiotensin-aldosterone system, 89  
secretion of, 71, 73, 86
- Aldosterone synthase, 74
- Aldosteronism  
adrenal venous sampling for, 88  
hypertension in, 87, 89  
primary, 87, 88
- Alkaline phosphatase  
in hypophosphatasia, 180  
in rickets, 174
- Alopecia, in autoimmune polyglandular syndrome type I, 218
- Alpha cells, pancreatic, 131
- Amenorrhea  
in anorexia nervosa, 208  
in hypothyroidism, 49
- Amylase, 130
- Amylin, 131
- Amylin analogues, for diabetes mellitus, 148, 149
- Amyloidosis, cutaneous lichen, in multiple endocrine neoplasia type 2, 214
- Anaplastic thyroid carcinoma, 62
- Androgen  
adrenal, 72, 73, 103, 104  
biologic actions of, 84  
in congenital adrenal hyperplasia, 83  
deficiency of, in adrenal insufficiency, 92, 93
- Androgen (*Continued*)  
excess of, 85  
neoplasms secreting, 85, 121  
at puberty, 107  
deficiency of, 15, 114  
excess of  
in 46,XX disorders of sex development, 111, 113–114  
in adult adrenogenital syndromes, 85  
in hirsutism and virilization, 111, 113, 120–121  
in masculinization of external genitalia, 102, 111  
in precocious puberty, 109, 110  
in women, 120, 121  
gonadal, 104  
potency of, 73  
at puberty, 107  
synthesis of, 103
- Androgen insensitivity syndrome, 112, 113, 114
- Androgenization, 112
- Androstenedione  
adrenal metabolism of, 73  
biologic actions of, 84  
excess of, in women, 120, 121  
production of, 103
- Anemia  
in hypothyroidism, 50  
pernicious, in autoimmune polyglandular syndrome type I, 218
- Angiofibroma, in multiple endocrine neoplasia type 1, 213
- Angiography, computed tomography  
in atherosclerosis, 145  
in neurofibromatosis type 1, 217
- Angioma, retinal, in von Hippel-Lindau syndrome, 216
- Angiotensin-converting enzyme (ACE), 89
- Angiotensin-converting enzyme (ACE) inhibitors  
in diabetes mellitus, 145  
for diabetic nephropathy, 143
- Angiotensin I, 89
- Angiotensin II, 86, 89
- Angiotensin receptor blockers, for diabetic nephropathy, 143
- Ankle drop, in diabetes mellitus, 144
- Anorexia nervosa, 208
- Ansa hypoglossi, 36
- Anterior commissure, 6
- Antidiuretic hormone (ADH). *See* Vasopressin.
- Antimüllerian hormone, in gonadal differentiation, 100
- Aorta  
abdominal, 69  
dorsal, 38  
topographic relationships of, 68, 129  
xanthoma of, 189
- Aortic arch  
first, 38  
fourth, 38
- Aorticorenal ganglion, 70
- Aortogram, in atherosclerosis, 145
- APOE* genotype, in familial dysbetalipoproteinemia, 191
- Apolipoprotein, 183, 184
- Apolipoprotein A mutations, HDL concentration and, 186
- Apolipoprotein B, absence of, 190
- Apolipoprotein B<sub>100</sub>  
excess of, 187  
familial defective, 185, 189  
mutations of, hypercholesterolemia from, 187
- Apolipoprotein CI, 191
- Apolipoprotein CII, deficiency of, 192, 193
- Apolipoprotein CIII, 191
- Appendix epididymis, 101
- Appendix testis, 101
- Appendix vesiculosa, 101
- Appetite center, 11



- Aquaporins, 28  
 Aqueductal stenosis, in neurofibromatosis type 1, 217  
 Aromatase, 74  
 Arteries. *See* Blood supply; *named arteries*.  
 Arteriosclerosis, Mönckeberg, 145  
 Ascites, in hypothyroidism, 49  
 Ascorbic acid  
   absorption of, 200  
   deficiency of, 203  
   recommended dietary allowance for, 203  
 Aspirin  
   in diabetes mellitus, 145  
   low-dose, in metabolic syndrome, 197  
 Atheroma, in hypercholesterolemic xanthomatosis, 188  
 Atherosclerosis, 194–196. *See also* Coronary heart disease.  
   in diabetes mellitus, 145  
   fatty streaks in, 194  
   fibrous plaques in, 195  
   renal artery stenosis in, 189  
   risk factors for, 196  
   sites of, 194  
   thrombosis in, 195  
 Atrial fibrillation, in Graves disease, 44  
 Autoimmune polyglandular syndrome  
   type I, 218  
   type II, 91, 218  
 Autonomic neuropathy, in diabetes mellitus, 144  
 Axillary hair, development of, 84, 106, 107
- B**  
 Bariatric surgery, 151, 210  
 Bartholin's gland, 101, 102  
 Basal ganglia, calcification of, in autoimmune polyglandular syndrome type I, 218  
 Basal metabolic rate (BMR), in toxic adenoma and toxic multinodular goiter, 47  
 Basilar plexus, 7  
 Basophil adenoma, 24  
 Beriberi, 201  
 Beta cells, pancreatic, 131  
   autoimmune destruction of, 139  
   hyperplasia of, 151  
 Biguanides, for diabetes mellitus, 148  
 Bile acid sequestrants, 198  
 Bile duct, common, 129  
 Biliopancreatic diversion, 210  
 Binge eating, in anorexia nervosa, 208  
 Biotin, absorption of, 200  
 Bisphosphonates  
   for osteogenesis imperfecta, 179  
   for osteoporosis, 169  
   for Paget disease of bone, 177  
 Bitemporal hemianopsia, from pituitary tumors, 13  
 Bitot spots, in vitamin A deficiency, 204  
 Bleeding. *See also* Hemorrhage.  
   from gums, in scurvy, 203  
   from uterus, causes of, 124  
 Blindness  
   in diabetic retinopathy, 141  
   night, in vitamin A deficiency, 204  
 Blood pressure. *See also* Hypertension.  
   glucocorticoid effects on, 75  
 Blood supply. *See also named arteries and veins*.  
   of adrenal glands, 68, 71  
   of pancreas, 129  
   of pituitary gland, 5  
   of thyroid and parathyroid glands, 36–37  
 Blood tests, in toxic adenoma and toxic multinodular goiter, 47  
 Body image, in anorexia nervosa, 208  
 Body mass index (BMI), 209  
 Bone. *See also* Osteo- *entries*.  
   biopsy of  
     in osteomalacia, 175  
     in Paget disease of bone, 177  
   disease of  
     in hyperparathyroidism, 157, 158  
     in hypophosphatasia, 175, 180  
     in Langerhans cell histiocytosis, 30, 31  
 Bone (*Continued*)  
   in neurofibromatosis type 1, 217  
   in pseudohypoparathyroidism type 1, 166  
   in renal osteodystrophy, 161  
   formation of, 156  
   glucocorticoid effects on, 75  
   growth of, in vitamin A deficiency, 204  
   loss of. *See* Osteoporosis.  
   metastasis to, hypercalcemia in, 159  
   occipital, 8  
   Paget disease of, 176–177  
   pain in, in Paget disease of bone, 176  
   palatine, 8  
   rachitic, in rickets, 174  
   remodeling of, 156  
     defective, 156  
   resorption of, 156  
     in Graves disease, 44  
   scintigraphy of, in Paget disease of bone, 176  
   sphenoid, 8  
 Bone mass, peak, 167  
 Bone mineral density (BMD)  
   in anorexia nervosa, 208  
   in osteoporosis, 168, 169  
   during puberty, 105  
 Bone remodeling unit (osteon), 156  
 Bowing of limbs, in Paget disease of bone, 176  
 Brachydactyly, in pseudohypoparathyroidism type 1, 166  
 Brain  
   glucocorticoid effects on, 75  
   temporal pole of, 6  
   tumors of  
     diabetes insipidus and, 29  
     in neurofibromatosis type 1, 217  
     precocious puberty and, 108, 110  
 Branchial arch/cleft  
   first, 38  
   fourth, 38  
 Breast  
   development of  
     premature, 109  
     pubertal, 104, 105  
   male, enlargement of. *See* Gynecomastia.  
 Bromocriptine, for prolactinoma, 23  
 Bronchoconstriction, in carcinoid tumors, 219  
 Bruising  
   in Cushing syndrome, 76  
   in scurvy, 203  
 Buccopharyngeal membrane, disintegrating, 38  
 Bulbourethral gland, 101, 102  
 Buttocks, xanthoma of, 188, 192
- C**  
 C-peptide, 132  
 Cabergoline, for prolactinoma, 23  
 Café au lait spots, in neurofibromatosis type 1, 217  
 Calciferol, 200  
 Calcification  
   in atherosclerosis, 145  
   of basal ganglia, in autoimmune polyglandular syndrome type I, 218  
   coronary, 195  
 Calcipenic rickets and osteomalacia, 171  
 Calcitonin  
   in catecholamine-secreting tumors, 97  
   in medullary thyroid carcinoma, 60  
 Calcitriol  
   actions of, 155  
   for pseudovitamin D–deficiency rickets and osteomalacia, 172  
   for X-linked hypophosphatemic rickets, 173  
 Calcium  
   absorption and excretion of, 155  
   disturbances of. *See* Hypercalcemia; Hypocalcemia.  
   excretion of, in hypercalcemia, 159  
   insulin secretion and, 132  
   intake of, in osteoporosis, 168  
   metabolism of, 75, 155  
   parathyroid hormone secretion and, 155  
 Calcium (*Continued*)  
   serum, in rickets, 174  
   total body, during puberty, 105  
 Calcium-sensing receptor, 155  
 Calcium stimulation test, for islet-cell hyperplasia, 151  
 Calculi, in hyperparathyroidism, 157  
 Cancer. *See* Carcinoma; Metastatic disease; Tumors.  
 Candidiasis, in autoimmune polyglandular syndrome type I, 218  
 Carbohydrate, metabolism of, 75, 130  
 Carcinoid syndrome, 219  
 Carcinoid tumors, 213, 219  
 Carcinoma  
   adrenocortical, 79  
   hypercalcemia in, 159  
   parathyroid, 157, 162  
   renal cell, in von Hippel-Lindau syndrome, 216  
   thyroid. *See* Thyroid gland, carcinoma of.  
 Cardiac output, in Graves disease, 43  
 Cardiomyopathy, in pheochromocytoma, 97  
 Carney complex, 80  
 Carotene, 204  
 Carotid artery  
   aneurysm of, 14  
   common, 36, 37  
   external, 37  
   internal, 7, 38  
 Cataract, in autoimmune polyglandular syndrome type I, 218  
 Catechol-O-methyltransferase, 95  
 Catecholamines, 94  
   biologic actions of, 94  
   metabolism of, 95  
   secretion of, 70, 95  
   storage of, 95  
   synthesis of, 95  
   tumors secreting, 96–97  
 Cavernous sinus, pituitary relationship of, 7  
 Celiac disease, 205  
 Celiac ganglion and plexus, 70  
 Celiac trunk, 69, 129  
 Central nervous system  
   glucocorticoid effects on, 75  
   neoplasms of, in neurofibromatosis type 1, 217  
 Central precocious puberty, 108, 110  
 Centroacinar cells, 130  
 Cerebellar hemangioblastoma, in von Hippel-Lindau syndrome, 216  
 Cerebrospinal fluid rhinorrhea, in prolactinoma, 23  
 Cerebrotendinous xanthomatosis, 189  
 Cervical nerve, transverse, 36  
 Chemotherapy  
   for follicular thyroid carcinoma, 59  
   for papillary thyroid carcinoma, 58  
 Chiasmatic cistern, 6  
 Chiasmatic sulcus, 8  
 Chief cells, parathyroid, 162  
 Chimerism, 113  
 Cholecystokinin, 130, 132, 184  
 Cholesterol  
   adrenal, 72  
   concentration of, regulation of, 185  
   deposition of  
     in atherosclerosis, 194, 195  
     in Tangier disease, 190  
   excess of. *See* Hypercholesterolemia.  
   gastrointestinal absorption of, 184  
   metabolism of, 73, 103, 183, 184  
   plasma total, guidelines on, 185  
   reverse transport of, 186  
   synthesis of, 183  
   transport of, 183. *See also* Lipoprotein(s).  
 Cholesterol absorption inhibitors, mechanisms of action of, 198  
 Cholesterol ester transfer protein (CETP), 186  
   deficiency of, HDL concentration and, 186  
 Cholesterol side-chain cleavage, 74  
 Chorionic gonadotropin, reproductive cycle influence of, 122, 123  
 Choroid plexus, of third ventricle, 6

- Chromaffin cells, 67, 70, 71, 94  
tumors of, 96–97
- Chromosomal sex, 100, 111  
analysis of, 115  
errors in. *See* Sex chromosome disorder of sex development.
- Chvostek sign, 164
- Chylomicronemia syndrome, 192, 193
- Chylomicrons, 183, 184
- Chymotrypsin, 130
- Chymotrypsinogen, 130
- Circadian rhythms, 9
- Circulatory collapse, in adrenal crisis, 90
- Cirrhosis, gynecomastia in, 125
- Citric acid cycle, 135
- Clavicle, 36
- Clear cells, parathyroid, hyperplasia of, 162
- Clinoid process, 8
- Clitoris, development of, 102
- Clivus, 8
- Clubbing, in Graves disease, 43
- Cobalamin, 200
- Coelomic, 100
- Collagen-related genes, in osteogenesis imperfecta, 178, 179
- Collagenoma, in multiple endocrine neoplasia type 1, 213
- Collecting duct, in water homeostasis, 28
- Colloid goiter, 54
- Colon, 129
- Coma, diabetic, 137
- Communicating artery, 7
- Communicating vein, 36
- Computed tomography  
of aldosterone-producing adenoma, 87  
of catecholamine-secreting tumors, 96, 97  
in coronary heart disease, 195  
in Cushing syndrome, 77  
in Langerhans cell histiocytosis, 31  
in renal artery stenosis, 89
- Computed tomography angiography  
in atherosclerosis, 145  
in neurofibromatosis type 1, 217
- Congenital anomalies  
of pituitary gland, 14  
of thyroid gland, 37, 40
- Connective tissue, glucocorticoid effects on, 75
- Convulsions, in hypocalcemia, 164
- Corneal thinning, in vitamin A deficiency, 204
- Coronary heart disease. *See also* Atherosclerosis.  
diabetes mellitus and, 145  
hypercholesterolemia and, 188, 189, 194, 196  
risk factors for, 196
- Corpora cavernosa, 102
- Corpus callosum, 6
- Corpus spongiosum, 102
- Corticotropin  
adrenal gland structure and function and, 71  
in adrenal insufficiency, 92  
adrenarcho and, 104  
Cushing syndrome associated with, 77, 78–79, 85  
deficiency of, 15, 17, 18, 93  
pituitary tumor secreting, 24, 25, 78  
at puberty, 107  
secretion of, 9, 72
- Corticotropin-releasing hormone, 9  
deficiency of, 93
- Cortisol  
biologic actions of, 75  
biosynthesis of, 72–74  
major blocks in, 81. *See also* Adrenal hyperplasia, congenital.  
deficiency of, in congenital adrenal hyperplasia, 82, 83  
metabolism of, 72–74  
salivary, in Cushing syndrome, 77  
secretion of, 71, 72  
serum  
in adrenal insufficiency, 92, 93  
in anorexia nervosa, 208  
in Cushing syndrome, 76, 78, 79
- Cortisol (*Continued*)  
in primary pigmented nodular adrenocortical disease, 80  
urinary free, in Cushing syndrome, 77
- Cortisol-binding globulin, 74
- Cortisone, 73, 74
- Craniopharyngioma, 12
- Craniotomy, 24
- Cricoid cartilage, 37
- Cricothyroid ligament, 37
- Cricothyroid muscle, 37
- Crooke hyaline change, 24, 78
- Cushing disease, 78
- Cushing syndrome, 76–80  
ACTH-dependent, 77, 78–79, 85  
ACTH-independent, 77, 79  
clinical findings in, 76  
diagnostic testing in, 77  
in multiple endocrine neoplasia type 1, 213  
pathophysiology of, 78–79
- Cutaneous lichen amyloidosis, in multiple endocrine neoplasia type 2, 214
- Cyanosis, in adrenal crisis, 90
- Cyst  
epididymal, in von Hippel-Lindau syndrome, 216  
follicular, precocious puberty from, 110  
thyroglossal, 40
- Cystadenoma, papillary, in von Hippel-Lindau syndrome, 216
- D**
- Dehydro-epiandrosterone, 103
- Delphian nodes, 37
- Delta cells, pancreatic, 131
- Dementia, in pellagra, 202
- Dental hypoplasia, in autoimmune polyglandular syndrome type I, 218
- Dermatitis herpetiformis, celiac disease and, 205
- Dermopathy, infiltrative, in Graves disease, 43, 44
- Desmolase, 74
- Dexamethasone, low-dose, in Cushing syndrome, 77
- Dexamethasone suppression test  
in adrenal insufficiency, 92  
in Cushing syndrome, 77
- Dextrose, for adrenal crisis, 90
- DHEA (dehydroepiandrosterone)  
adrenal synthesis and metabolism of, 73  
biologic actions of, 84  
production of, 103
- DHEA (dehydroepiandrosterone) sulfate  
biologic actions of, 84  
excess of, in women, 120, 121
- Diabetes insipidus  
central, 29  
from craniopharyngioma, 12  
from hypothalamic lesions, 11
- Diabetes mellitus  
atherosclerosis in, 145  
in autoimmune polyglandular syndrome type II, 218  
celiac disease and, 205  
coronary heart disease risk and, 196  
foot ulcers in, 146  
gestational, 147  
histopathology of, 139  
ketoacidosis in, 138  
maturity-onset, of young, 140  
in metabolic syndrome, 197  
nephropathy in, 143  
neuropathy in, 144, 146  
in pregnancy, 147  
retinopathy in, 141–142  
type 1, 139  
treatment of, 149  
type 2, 139  
treatment of, 148  
vascular insufficiency in, 146
- Diaphragma sellae, 6, 7
- Diarrhea, in small intestinal carcinoids, 219
- Diet  
gluten-free, 205  
in hyperlipidemia, 199  
in metabolic syndrome, 197
- Digastric muscle, 36
- Disorders of sex development (DSD), 111–114  
46,XX, 111, 113–114  
46,XY, 112, 113, 114  
classification of, 111  
evaluation of, 114  
ovotesticular, 113, 114  
psychosocial development and, 112  
sex chromosome, 112–113, 115–119. *See also* Sex chromosome disorder of sex development.  
treatment of, 114
- Disorders of sexual development (DSD), hirsutism and virilization in, 120–121
- Docosahexaenoic acid (DHA), 198
- Dopamine  
biologic actions of, 94  
metabolism of, 95  
synthesis of, 95
- Dopamine agonists  
for galactorrhea, 126  
for prolactinoma, 23
- Dorsum sellae, 8
- Dowager's hump, 168
- Down syndrome, 52  
celiac disease and, 205
- Duodenal switch, biliopancreatic diversion with, 210
- Duodenojejunal flexure, 68
- Duodenum  
carcinoids of, in multiple endocrine neoplasia type 1, 213  
topographic relationships of, 68, 129
- Dwarfism  
in congenital hypothyroidism, 52  
in hypothalamic lesions, 11  
in panhypopituitarism, 15
- Dysbetalipoproteinemia, familial, 185, 191
- Dyslipidemia. *See also specific disorders, e.g.,* Hypercholesterolemia.  
in diabetes mellitus, 140  
in metabolic syndrome, 197
- E**
- Ecchymoses  
in Cushing syndrome, 76  
in scurvy, 203
- Edema  
macular, in diabetic retinopathy, 141, 142  
periocular  
in Graves disease, 45  
in hypothyroidism, 49
- Eicosapentaenoic acid, 198
- Elbow, xanthoma of, 188
- Elderly, hirsutism in, 121
- Electrocardiography, in hypocalcemia, 164
- Emaciation, from hypothalamic lesions, 11
- Embryonic cleft, 4
- Empty sella, 14
- Encephalopathy  
in pellagra, 202  
Wernicke, 201
- Enterokinase, 130
- Enteropathy, gluten-sensitive, 205
- Epididymal cysts, in von Hippel-Lindau syndrome, 216
- Epididymis, 101
- Epinephrine  
biologic actions of, 94  
in glycogenolysis, 136  
metabolism of, 95  
secretion of, 95, 97  
synthesis of, 95  
tumors secreting, 97
- Epiphysis, femoral, slipped capital, 161
- Epoöphoron, 101
- Ergocalciferol, for vitamin D-deficient rickets and osteomalacia, 171



- Esophagus, 36, 37, 38, 69  
 Estradiol, 73, 103  
 Estriol, 103  
 Estrogen  
   adrenal, 72  
   deficiency of, osteoporosis and, 167, 168  
   excess of, precocious puberty from, 110  
   at puberty, 107  
   reproductive cycle influence of, 122, 123  
   supplementation of, for Turner syndrome, 119  
   synthesis of, 103  
 Estrone, 73, 103  
 Eunuchoidal habitus, 15, 17, 105, 116  
 Euthyroid goiter, 53, 54, 55  
 Exercise  
   in metabolic syndrome, 197  
   in osteoporosis, 168  
 Eye(s)  
   glucocorticoid effects on, 75  
   in Graves disease, 43, 44, 45  
 Eyelid  
   lag of, in Graves disease, 44, 45  
   xanthelasma of, 188
- F**  
 Fabry disease, 207  
 Face  
   in acromegaly, 22  
   in Cushing syndrome, 76  
   in hypothyroidism, 50  
   in panhypopituitarism, 93  
   in pellagra, 202  
   in pseudohypoparathyroidism type 1, 166  
   pubertal changes in, 107  
 Facial artery, 36  
 Facial nerve, marginal mandibular branch of, 36  
 Facial vein, 36  
 Fallopian tube, 101  
 Falx cerebri, 7  
 Fascia, renal (Gerota), 68  
 Fasciculata, zona, 71  
 Fat. *See also* Lipid(s).  
   stool, in celiac disease, 205  
 Fat pads, in Cushing syndrome, 76  
 Fatty acids, long-chain, 184  
 Fatty streaks, in atherosclerosis, 194  
 Femoral epiphysis, slipped capital, 161  
 Femoral vein, 88  
 Fetal macrosomia, in gestational diabetes, 147  
 Fever, in adrenal crisis, 90  
 Fibric acid derivatives  
   for hypertriglyceridemia, 193  
   mechanisms of action of, 198  
 Fibrous plaques, in atherosclerosis, 195  
 Fight-or-flight reaction, 70  
 Fish oil  
   for hypertriglyceridemia, 193  
   mechanisms of action of, 198  
 Fludrocortisone, for adrenal insufficiency, 92  
 Flushing, in carcinoid tumors, 219  
 Follicle stimulating hormone (FSH), 9  
   deficiency of, 18  
   in boys, 15  
   at puberty, 104, 107  
   reproductive cycle influence of, 122, 123  
 Follicular cyst, precocious puberty from, 110  
 Foot  
   diabetic, 144, 146  
 Foramen cecum, 38  
 Foramen lacerum, 8  
 Foramen magnum, 8  
 Foramen ovale, 8  
 Foramen rotundum, 8  
 Foramen spinosum, 8  
 Fornix, 6  
 Fractures. *See also* Pseudofractures (Looser zones).  
   frequent, differential diagnosis of, 179  
   in hyperparathyroidism, 158  
   in osteogenesis imperfecta, 178, 179
- Fractures (*Continued*)  
   in osteoporosis, 168, 169  
   in renal osteodystrophy, 161  
 Freckling, in neurofibromatosis type 1, 217  
 Frog leg position, in scurvy, 203  
 Frontal bossing, in acromegaly, 22  
 Frontal sinus, 8
- G**  
 Galactorrhea, 23, 126  
 $\alpha$ -Galactosidase A deficiency, 207  
 Ganglion  
   aorticorenal, 70  
   basal, calcification of, in autoimmune polyglandular syndrome type I, 218  
   celiac, 70  
   mesenteric, superior, 70  
   renal, 70  
 Gangliosidosis, 206  
 Gangrene, in diabetic foot ulcers, 146  
 Gartner's duct, 101  
 Gastrectomy, sleeve, 210  
 Gastric banding, laparoscopic, 210  
 Gastric bypass surgery, 151, 210  
 Gastric stapling, 210  
 Gastrinoma, in multiple endocrine neoplasia type 1, 213  
 Gastroduodenal artery, 129  
 Gastroenteropancreatic neoplasms, in multiple endocrine neoplasia type 1, 213  
 Gastrointestinal tract  
   carcinoid tumors in, 219  
   glucocorticoid effects on, 75  
 Gastroplasty, vertical banded, 210  
 Gaucher disease, 206  
 Gemfibrozil, for hypertriglyceridemia, 193  
 Gender assignment, in Turner syndrome, 118  
 Gender identity, 112  
 Gender role, 112  
 Genital ducts, 101  
 Genital ridge, 100  
 Genital tubercle, 102  
 Genitalia  
   ambiguous  
     in disorders of sex development, 111–114  
     in 21-hydroxylase deficiency, 83  
   development of, during puberty, 104, 105, 106, 107  
   external, differentiation of, 102  
 Germ cells, primordial, 100  
 Gestational diabetes mellitus, 147  
 Gestational hyperandrogenism, virilization in, 111, 113  
 Gigantism, 21  
 Gill slits, persistent, 38  
 Glans  
   clitoris, 102  
   penis, 102  
 Glioma, optic, in neurofibromatosis type 1, 217  
 Globe lag, in Graves disease, 45  
 Glomerular hyperfiltration, in diabetic nephropathy, 143  
 Glomerulosclerosis, in diabetic nephropathy, 143  
 Glove-and-stocking lesions, in pellagra, 202  
 Glucagon  
   in glycogenolysis, 136  
   regulation of, 131  
 Glucagon-like peptide-1 (GLP-1), insulin secretion and, 132  
 Glucocerebroside, 206–207  
 Glucocorticoids, 72. *See also* Cortisol.  
   for adrenal insufficiency, 92  
   biologic actions of, 75  
   biosynthesis and metabolism of, 72–74  
   for congenital adrenal hyperplasia, 82  
   for corticotropin-secreting pituitary tumor, 24  
   excess of, osteoporosis and, 167  
   resistance to, familial, 85  
   for Riedel thyroiditis, 56  
   for subacute thyroiditis, 57  
 Glucose. *See also* Glycemic control.  
   concentration of, insulin secretion and, 132  
   disturbances of. *See* Hyperglycemia; Hypoglycemia.
- Glucose (*Continued*)  
   fasting, in diabetes mellitus, 140  
   insulin actions and, 133  
 Glucose-1-phosphatase, 136  
 Glucose-6-phosphatase  
   in glycogenolysis, 136  
   in glycolysis, 134  
 Glucose challenge test, in gestational diabetes, 147  
 Glucose tolerance test, oral, in gestational diabetes, 147  
 Glucose transporters, 133  
 Gluten-sensitive enteropathy, 205  
 Glycemic control  
   in diabetes mellitus, 148, 149  
   for diabetic retinopathy, 142  
 Glycogen, metabolism of, 135, 136  
 Glycogenesis, 136  
 Glycogenolysis, 136  
 Glycolysis, 134, 135, 136  
 Glycosaminoglycans, in Graves disease, 45  
 Glycosuria, from insulin deprivation, 137  
*GNAS* mutations, in pseudohypoparathyroidism type 1, 165, 166  
 Goiter  
   colloid, 54  
   congenital hypothyroidism associated with, 52  
   euthyroid (nontoxic), 53, 54, 55  
   in Graves disease, 43, 46  
   in thyroiditis, 56, 57  
   toxic multinodular, 47, 48  
 Gonad(s), 101. *See also* Ovary; Testis.  
   activation of, 104  
   atrophy of, 18  
   differentiation of, 100, 101  
   abnormal, factors influencing, 100  
   dysgenesis of  
     mixed, 113, 118, 119  
     Turner syndrome as, 115, 117–119  
 Gonadal hormones. *See* Estrogen; Progesterone; Testosterone.  
   decreased production of. *See* Hypogonadism.  
 Gonadal sex, 111  
 Gonadotroph adenoma, 26  
 Gonadotropin-releasing hormone (GnRH), 9  
   in anorexia nervosa, 208  
   early maturation of, precocious puberty from, 108, 110  
   early pulses of, 107  
   at puberty, 107  
 Gonadotropins, 103  
   deficiency of, 15, 16, 17, 18  
   precocious puberty associated with, 108  
   at puberty, 107  
   reproductive cycle influence of, 122, 123  
 Granulomatous hypophysitis, 14  
 Granulosa cells, 100  
   tumors of, ovarian, 110  
 Graves disease, 43–46  
   in autoimmune polyglandular syndrome type II, 218  
   clinical manifestations of, 43–44  
   goiter in, 43, 46  
   hyperthyroidism in, 43  
   ophthalmopathy in, 45  
   thyroid pathology in, 46  
 Growth  
   deficiency of (dwarfism)  
     in congenital hypothyroidism, 52  
     from hypothalamic lesions, 11  
     in panhypopituitarism, 15  
   phases of, 15  
   during puberty, 104  
 Growth hormone  
   deficiency of, 15, 16, 17, 18  
   pituitary tumors secreting  
     acromegaly from, 22  
     gigantism from, 21  
   secretion of, 9  
   for Turner syndrome, 119  
 Growth hormone-releasing hormone, 9  
   hypersecretion of, 21  
 Gubernaculum, 101  
 Gums, bleeding, in scurvy, 203

- Gynecomastia, 125  
 in Klinefelter syndrome, 116  
 neonatal, 125  
 pathologic conditions causing, 125  
 pubertal, 107, 125
- H**
- Hair  
 in adrenal insufficiency, 91  
 axillary, development of, 84, 106, 107  
 facial, development of, 107  
 growth phases of, 120  
 in hypothyroidism, 49, 50  
 male-pattern  
   adrenal androgen effects on, 84  
   in women. *See* Hirsutism.  
 pubic, development of, 84, 105, 106, 107  
 thinning of, in Cushing syndrome, 76
- Hashimoto thyroiditis, 51, 56, 218
- Head trauma, hypopituitarism from, 14
- Heart, enlarged, in hypothyroidism, 49
- Heart disease  
 carcinoid, 219  
 coronary. *See also* Atherosclerosis.  
   diabetes mellitus and, 145  
   hypercholesterolemia and, 188, 189, 194, 196  
   risk factors for, 196  
 valvular, in carcinoid tumors, 219
- Heart failure, in Graves disease, 44
- Height  
 excessive, growth hormone-induced, 21  
 loss of, in osteoporosis, 170  
 velocity of, during puberty, 105
- Hemangioblastoma, in von Hippel-Lindau syndrome, 216
- Hemianopsia, from pituitary tumors, 13
- Hemorrhage  
 of adrenal glands, 90  
 perifollicular, in scurvy, 203  
 of pituitary gland, 20  
 uterine, causes of, 124
- Henle, loop of, in water homeostasis, 28
- Hepatosplenomegaly, in hypertriglyceridemia, 192
- Hermaphroditism  
 pseudo-, 111–113  
 true, 113, 114
- Hirata disease, 218
- Hirschsprung disease, 214, 215
- Hirsutism, 85, 120–121  
 causes of, 120–121  
 in Cushing syndrome, 76  
 definition of, 120  
 evaluation of, 121
- Histiocytosis, Langerhans cell, 29, 30, 31
- HLA (human leukocyte antigen) phenotypes, in diabetes mellitus, 139
- HMG-CoA reductase, 183
- HMG-CoA reductase inhibitors. *See* Statins.
- Homonymous hemianopsia, from pituitary tumors, 13
- Homovanillic acid, 95
- Human chorionic gonadotropin, reproductive cycle influence of, 122, 123
- Human leukocyte antigen (HLA) phenotypes, in diabetes mellitus, 139
- Hürthle cell thyroid carcinoma, 61
- Hydrocephalus  
 in craniopharyngioma, 12  
 in neurofibromatosis type 1, 217
- Hydrocortisone  
 for adrenal crisis, 90  
 for adrenal insufficiency, 93  
 for corticotropin-secreting pituitary tumor, 24
- 3-Hydroxy-3-methylglutaryl coenzyme A (HMG-CoA), 183
- Hydroxyapatite, 155
- 5-Hydroxyindole acetic acid, in carcinoid tumors, 219
- 11 $\beta$ -Hydroxylase, 74  
 deficiency of, 81, 83
- 17 $\alpha$ -Hydroxylase, 74  
 deficiency of, 81, 82
- $\alpha$ 1-Hydroxylase deficiency, 172
- 21-Hydroxylase deficiency, 81, 83
- 3 $\beta$ -Hydroxysteroid dehydrogenase, 74  
 deficiency of, 81, 82  
 late-onset, 85
- 11 $\beta$ -Hydroxysteroid dehydrogenase, 74  
 deficiency of, 83  
 late-onset, 85
- 17 $\beta$ -Hydroxysteroid dehydrogenase, 74
- Hyoid bone, 36, 37
- Hyperalgesia, in diabetes mellitus, 144
- Hyperapobetalipoproteinemia, familial, 187
- Hypercalcemia  
 clinical manifestations of, 155  
 differential diagnosis of, 159  
 hyperparathyroidism and, 157, 158, 159  
 hypocalciuric, familial, 159  
 parathyroid hormone-mediated, 159
- Hypercholesterolemia, 187  
 coronary heart disease risk and, 188, 189, 194, 196  
 etiology of, 187  
 familial, 185, 187, 188–189, 191  
 guidelines on, 187  
 polygenic, 185  
 xanthomatosis in, 188–189
- Hypercortisolism  
 in Cushing syndrome, 76, 78  
 in primary pigmented nodular adrenocortical disease, 80
- Hyperglycemia  
 in diabetes mellitus, 139, 140, 148  
 maternal, 147  
 treatment of, 148
- Hyperinsulinism. *See* Insulin resistance (hyperinsulinemia).
- Hyperkalemia, in adrenal insufficiency, 92
- Hyperkeratinization, in vitamin A deficiency, 204
- Hyperlipemia retinalis, 193
- Hyperlipidemia  
 coronary heart disease risk and, 194, 196  
 familial combined, 187, 191  
 monitoring in, 199  
 prevention of, 199  
 treatment of, 199
- Hyperlipoproteinemia  
 classification of, 191  
 type I, 191  
 type III, 185, 191  
 type IV, 191  
 type V, 191
- Hypernatremia, in adrenal insufficiency, 92
- Hyperparathyroidism  
 histology in, 162  
 hypercalcemia and, 157, 158, 159  
 in multiple endocrine neoplasia, 213, 214  
 in osteoporosis, 167  
 in Paget disease of bone, 177  
 primary  
   clinical manifestations of, 158  
   pathology of, 158  
   pathophysiology of, 157  
 in pseudohypoparathyroidism type 1, 166  
 in renal osteodystrophy, 160, 161
- Hyperphosphatemia  
 in hypoparathyroidism, 163  
 in renal osteodystrophy, 160
- Hyperpigmentation  
 in adrenal insufficiency, 91  
 in carcinoid tumors, 219  
 in Nelson syndrome, 25
- Hyperprolactinemia, 23  
 from clinically nonfunctioning pituitary tumor, 26  
 galactorrhea in, 126
- Hyperreflexia, in hypocalcemia, 164
- Hypertension  
 in aldosteronism, 87, 89  
 coronary heart disease risk and, 196  
 in diabetic nephropathy, 143  
 in hypothyroidism, 49
- Hypertension (*Continued*)  
 in neurofibromatosis type 1, 217  
 renovascular, in renal artery stenosis, 89
- Hyperthecosis, 121
- Hyperthyroidism  
 in Graves disease, 43  
 gynecomastia in, 125  
 hypercalcemia in, 159  
 in toxic adenoma and toxic multinodular goiter, 47, 48
- Hypertriglyceridemia, 191–193  
 in apolipoprotein CII deficiency, 192, 193  
 borderline, 191  
 clinical manifestations of, 192  
 familial, 191, 193  
 in lipoprotein lipase deficiency, 192–193  
 mixed, 191  
 risk factors for, 191  
 treatment of, 193, 199
- Hypesthesia, in diabetes mellitus, 144
- Hypocalcemia  
 acute, clinical manifestations of, 164  
 in autoimmune polyglandular syndrome type I, 218  
 clinical manifestations of, 155  
 in hypoparathyroidism, 163  
 in pseudohypoparathyroidism type 1, 166
- Hypoglycemia  
 in adrenal insufficiency, 93  
 differential diagnosis of, 151  
 from insulinoma, 150  
 from islet-cell hyperplasia, 151  
 noninsulinoma pancreatogenous, 151
- Hypogonadism  
 gynecomastia in, 125  
 hypogonadotropic, prolactin-dependent, 23  
 from hypothalamic lesions, 11  
 primary, in autoimmune polyglandular syndrome type I and II, 218
- Hypokalemia, in aldosteronism, 87
- Hyponatremia, in adrenal insufficiency, 93
- Hypoparathyroidism  
 in autoimmune polyglandular syndrome type I, 218  
 congenital, 163  
 pathophysiology of, 163
- Hypophosphatasia, 175, 180
- Hypophosphatemia  
 in hypercalcemia, 159  
 osteomalacia in, 175
- Hypophosphatemic rickets, 173
- Hypophyseal artery, 5, 9
- Hypophyseal fossa, 8
- Hypophyseal portal system, 5
- Hypophyseal portal vein, 5
- Hypophyseal vein, 5
- Hypophysis. *See* Pituitary gland.
- Hypophysitis  
 granulomatous, 14  
 lymphocytic, 14, 17
- Hypopituitarism, 15, 16  
 adrenal insufficiency with, 93  
 from craniopharyngioma, 12  
 from nontumorous lesions, 14  
 selective and partial, 17  
 severe, 18  
 in Sheehan syndrome, 19
- Hypotension  
 in adrenal crisis, 90  
 in adrenal insufficiency, 91
- Hypothalamic artery, 9
- Hypothalamic inhibitory regulatory factors, 9
- Hypothalamic-pituitary-adrenal (HPA) axis, 72
- Hypothalamic-releasing hormones, 9
- Hypothalamic sulcus, 6
- Hypothalamo-hypophysial tract, 4
- Hypothalamus  
 craniopharyngioma compressing, 12  
 lesions of  
   diabetes insipidus from, 29  
   hypopituitarism from, 15, 16  
   manifestations of, 11  
 relationship of, to pituitary gland, 4, 6



- Hypothyroidism  
 in adults, 49–51  
 in anorexia nervosa, 208  
 central (hypothalamic or pituitary), 11, 51, 52  
 congenital, 52  
 etiology of, 50–51  
 primary, 50–51  
 in pseudohypoparathyroidism type 1, 166  
 signs and symptoms of, 49–50  
 treatment of, 51
- Hypoxia-inducible factor (HIF), regulation of, 135
- I**
- Iliac vein, 88
- Immobilization, hypercalcemia from, 159
- Immunoglobulin A deficiency, 205
- Incretin effect, 132
- Incretin-related agents, for diabetes mellitus, 148
- Infarction  
 myocardial, in diabetes mellitus, 145  
 of pituitary gland, postpartum, 19
- Inflammation, glucocorticoid effects on, 75
- Infradian rhythms, 9
- Infundibular artery, 5  
 spasm of, postpartum, 19
- Infundibular process, 3, 4, 5
- Infundibular stem, 4
- Insulin  
 actions of, 133  
 administration of  
 for diabetes mellitus, 148, 149  
 for diabetic ketoacidosis, 138  
 for gestational diabetes, 147  
 deficiency of, consequences of, 137  
 in glycogenolysis, 136  
 regulation of, 131  
 secretion of, 132  
 synthesis of, 131
- Insulin-like growth factor-1, 9  
 during puberty, 104  
 secretion of, 9
- Insulin receptor, 133
- Insulin resistance (hyperinsulinemia)  
 atherosclerosis and, 145  
 congenital, islet-cell hyperplasia from, 151  
 in diabetes mellitus, 140  
 fetal, 147  
 hyperthecosis and, 121  
 in insulinoma, 150  
 in metabolic syndrome, 197  
 type B, 218
- Insulin secretagogues, for diabetes mellitus, 148
- Insulin sensitizers, for diabetes mellitus, 148
- Insulinoma, 150  
 in multiple endocrine neoplasia type 1, 213
- Interpeduncular cistern, 6
- Interventricular foramen, 6
- Intralingual thyroid tissue, 40
- Intratracheal thyroid tissue, 40
- Iodine  
 deficiency of, goiter from, 54, 55  
 metabolism of, 42  
 radioactive  
 for follicular thyroid carcinoma, 59  
 for papillary thyroid carcinoma, 58  
 for toxic adenoma and toxic multinodular goiter, 47  
 uptake of  
 in Graves disease, 46  
 in subacute thyroiditis, 57  
 in toxic adenoma and toxic multinodular goiter, 47
- IPEX syndrome, 218
- Iris, Lisch nodules on, in neurofibromatosis type 1, 217
- Iron overload, 14
- Islets of Langerhans. *See* Pancreatic islets.
- J**
- Jejunum, 129
- Jugular vein  
 anterior, 36  
 external, 36  
 internal, 36, 37
- K**
- Kearns-Sayre syndrome, 218
- Keratinization, in vitamin A deficiency, 204
- Ketoacidosis, diabetic, 138
- Ketoaciduria, from insulin deprivation, 137
- $\alpha$ -Ketoglutarate, 135
- 17-Ketosteroid deficiency, in adrenal insufficiency, 92, 93
- 17 $\beta$ -Ketosteroid reductase, 74
- Kimmelstiel-Wilson nodules, in diabetic nephropathy, 143
- Klinefelter syndrome, 115, 116
- Knee, xanthoma of, 188
- Krebs cycle, 135
- Kyphosis  
 in Paget disease of bone, 176  
 thoracic, in osteoporosis, 168, 169, 170
- L**
- Labia majora and minora, development of, 102
- Labioscrotal swellings, 102
- Labor induction, oxytocin in, 27
- Lactation  
 abnormal. *See* Galactorrhea.  
 oxytocin in, 27
- Lactic acid, 134
- Lamina terminalis, 6
- Langerhans, islets of. *See* Pancreatic islets.
- Langerhans cell histiocytosis, 29, 30, 31
- Laparoscopic adjustable gastric banding, 210
- Laryngeal nerve  
 recurrent, 36, 37  
 superior, external branch of, 37
- Laryngeal spasm, in hypocalcemia, 164
- Larynx, 38
- Laser photocoagulation, for diabetic retinopathy, 142
- Lens opacities, in autoimmune polyglandular syndrome type I, 218
- Leptin  
 in anorexia nervosa, 208  
 puberty and, 104
- Lethargy, in hypothyroidism, 49
- Leukodystrophy, metachromatic, 207
- Levothyroxine  
 for follicular thyroid carcinoma, 59  
 for hypothyroidism, 51  
 for papillary thyroid carcinoma, 58  
 for thyroiditis, 56, 57
- Leydig cells, 100, 107  
 fetal, 112  
 in Klinefelter syndrome, 116  
 tumor of, 109
- Ligament  
 cricothyroid, 37  
 round, 101
- Limbs  
 bowing of, in Paget disease of bone, 176  
 deformities of, in osteogenesis imperfecta, 178, 179
- Lingual thyroid, 40
- Lipase, 130, 184, 192
- Lipid(s). *See also* Dyslipidemia; Hyperlipidemia.  
 dietary, 184  
 fasting, monitoring of, 199  
 metabolism of, 130, 134, 183, 184  
 glucocorticoids in, 75  
 transport of, 183, 184. *See also* Lipoprotein(s).
- Lipid-lowering therapy  
 coronary heart disease risk and, 196  
 for familial hypercholesterolemia, 189  
 mechanisms of action of, 198
- Lipid screening tests, recommendations for, 196
- Lipidosis, sphingomyelin-cholesterol, 206
- Lipogenesis, insulin stimulation of, 133
- Lipoid hyperplasia, congenital, 81, 82
- Lipolysis, from insulin deprivation, 137
- Lipoma, in multiple endocrine neoplasia type 1, 213
- Lipoprotein(a), plasma, elevated, 185
- Lipoprotein(s). *See also* Apolipoprotein.  
 classification of, 183  
 excess of. *See* Hyperlipoproteinemia.  
 high-density, 183  
 antiatherogenic properties of, 186  
 deficiency of, in Tangier disease, 190  
 metabolism of, 186  
 raising, 199  
 synthesis of, 186
- low-density, 183  
 excess of. *See* Hypercholesterolemia.  
 extracorporeal removal of, for familial hypercholesterolemia, 189  
 structure of, 183  
 very-low-density, 183  
 overproduction of, in familial hypertriglyceridemia, 193
- Lipoprotein lipase  
 actions of, 191  
 deficiency of, 192–193  
 synthesis of, 192
- Lipoprotein receptor, low-density, 183  
 mutations of, hypercholesterolemia from, 187, 188–189  
 regulation of, 185
- Lisch nodules, in neurofibromatosis type 1, 217
- Longus colli muscle, 36
- Looser zones (pseudofractures)  
 in osteomalacia, 175  
 in renal osteodystrophy, 161  
 in rickets, 174
- Lordosis, in abetalipoproteinemia, 190
- Lumbar splanchnic nerve, 70
- Lung  
 carcinoids of, 219  
 Langerhans cell histiocytosis in, 30, 31
- Lung bud, 38
- Luteinizing hormone (LH), 9  
 deficiency of, 18  
 in boys, 15  
 at puberty, 104, 107  
 reproductive cycle influence of, 122, 123
- Lymph node  
 pretracheal, 37  
 thyroid, 36, 37
- Lymph vessels, thyroid, 37
- Lymphatic drainage, of thyroid and parathyroid glands, 36, 37
- Lymphocytic hypophysitis, 14, 17
- Lymphocytic infiltration, in Graves disease, 46
- Lymphocytic (Hashimoto) thyroiditis, 51, 56
- Lymphoma, hypercalcemia in, 159
- Lysosomal storage disorders, 206–207
- M**
- Macroadenoma, pituitary, 13
- Macroglossia, in hypothyroidism, 49, 50
- Macrosomia, fetal, in gestational diabetes, 147
- Macular edema, in diabetic retinopathy, 141, 142
- Magnetic resonance imaging  
 of clinically nonfunctioning pituitary tumor, 26  
 of corticotropin-secreting pituitary tumor, 24  
 of craniopharyngioma, 12  
 in Cushing syndrome, 77  
 of growth hormone–secreting pituitary tumor, 21, 22  
 in Langerhans cell histiocytosis, 31  
 in neurofibromatosis type 1, 217  
 in pituitary apoplexy, 20  
 of pituitary macroadenoma, 13  
 posterior pituitary bright spot on, 10  
 of prolactinoma, 23
- Malabsorption  
 in autoimmune polyglandular syndrome type I, 218  
 in celiac disease, 205
- Malnutrition, in abetalipoproteinemia, 190

- Mammillary bodies, 6
- Masculinization  
of external genitalia, 102, 111  
genital, 112, 113–114  
signs and symptoms of, 85
- Maturity-onset diabetes of the young (MODY), 140
- Maxillary nerve, 7
- Maxillary process, 38
- McCune-Albright syndrome, precocious puberty in, 109, 110
- Median eminence, 3, 4
- Medullary thyroid carcinoma, 60  
in multiple endocrine neoplasia type 2, 60, 214, 215
- MEN1* mutations, 213
- Menopause  
hormonal influences in, 123  
osteoporosis after, 168
- Menorrhagia, in hypothyroidism, 49
- Menstruation  
normal, 124  
onset of, 106
- Mental retardation, in congenital hypothyroidism, 52
- Mesenteric artery, superior, 69
- Mesenteric ganglion, superior, 70
- Mesenteric vessels, superior, 129
- Mesentery, 129
- Mesonephric body, 101
- Mesonephric duct, 100, 101
- Mesonephric remnants, 100
- Mesonephric tubules, 100
- Metabolic syndrome, 140, 197
- Metacarpals, short, in pseudohypoparathyroidism type 1, 166
- Metachromatic leukodystrophy, 207
- Metanephrine, 94, 95
- Metastatic disease  
to adrenal glands, 98  
to bone, hypercalcemia in, 159  
to pituitary gland, 32  
to thyroid gland, 63
- Metformin, for diabetes mellitus, 148
- Methimazole, for toxic adenoma and toxic multinodular goiter, 47
- Miglitol, for diabetes mellitus, 148
- Milk-alkali syndrome, hypercalcemia in, 159
- Milk letdown, oxytocin in, 27
- Milkman syndrome  
in osteomalacia, 175  
in renal osteodystrophy, 161  
in rickets, 174
- Mineral loss, from insulin deprivation, 137
- Mineralocorticoid receptors, 86
- Mineralocorticoids. *See also* Aldosterone.  
for adrenal insufficiency, 92  
apparent excess of, 83  
for congenital adrenal hyperplasia, 82
- Mitogen-activating protein kinase signaling pathway, 133
- Mönckeberg arteriosclerosis, 145
- Mononeuropathy, in diabetes mellitus, 144
- Moon face, in Cushing syndrome, 76
- Mosaicism  
45,X/46,XX, 117, 118  
chromosomal, 100
- Mucocutaneous neuroma, in multiple endocrine neoplasia type 2, 215
- Müllerian duct, 100, 101  
persistent, 113
- Multiple endocrine neoplasia type 1, 214  
carcinoid tumors in, 219
- Multiple endocrine neoplasia type 2  
cutaneous lichen amyloidosis in, 214  
genetics of, 215  
Hirschsprung disease in, 214  
hyperparathyroidism in, 214  
medullary thyroid carcinoma in, 60, 214, 215  
pheochromocytoma in, 214
- Muscles. *See also named muscles.*  
adrenal androgen effects on, 84  
androgenic (anabolic) steroid effects on, 84  
glucocorticoid effects on, 75  
wasting of, in Graves disease, 44  
weakness of  
in Cushing syndrome, 76  
in Graves disease, 44
- Myeloma, multiple, hypercalcemia in, 159
- Mylohyoid muscle, 36
- Myocardial infarction, in diabetes mellitus, 145
- Myocarditis, in pheochromocytoma, 97
- Myopathy  
cardiac, in pheochromocytoma, 97  
thyroid, 44
- Myxedema, in Graves disease, 43, 44
- Myxedema madness, 49
- N**
- Nasal septum, 6, 8
- Nasopharynx, 6, 7
- Neck surgery, hypoparathyroidism after, 163
- Nelson syndrome, 25
- Neonate, hormonal influences in, 123, 125
- Nephrocalcinosis, in hyperparathyroidism, 157, 158
- Nephrogenic cord, 100
- Nephrolithiasis, in hyperparathyroidism, 158
- Nephropathy, diabetic, 143
- Nephrotic syndrome, in diabetic nephropathy, 143
- Nerve supply. *See also named nerves.*  
of adrenal glands, 70  
of pancreas, 129  
of pituitary gland, 4, 7  
of thyroid and parathyroid glands, 36, 37
- Nesidioblastosis, in islet-cell hyperplasia, 151
- Neurocognitive dysfunction, in Turner syndrome, 118
- Neurofibromatosis type 1, 217
- Neuroglycopenia, in insulinoma, 150
- Neurohypophysis. *See* Pituitary gland, posterior.
- Neuroma, mucocutaneous, in multiple endocrine neoplasia type 2, 215
- Neuropathy  
in abetalipoproteinemia, 190  
diabetic, 144, 146  
in pellagra, 202
- Nevi, in Carney complex, 80
- NFI* mutations, in neurofibromatosis type 1, 217
- Niacin  
absorption of, 200  
deficiency of, 202  
recommended dietary allowance for, 202
- Nicotinic acid  
for hypertriglyceridemia, 193  
mechanisms of action of, 198
- Niemann-Pick disease, 206
- Night blindness, in vitamin A deficiency, 204
- Nitrogen loss, from insulin deprivation, 137
- Nodules  
in goiter, 47, 53, 54  
Kimmelstiel-Wilson, in diabetic nephropathy, 143  
Lisch, in neurofibromatosis type 1, 217  
in papillary thyroid carcinoma, 58  
in primary pigmented nodular adrenocortical disease, 79, 80  
in pseudohypoparathyroidism type 1, 166  
in toxic multinodular goiter, 48
- Nondisjunction, sex chromosome, 115
- Noninsulinoma pancreatogenous hypoglycemia syndrome, 151
- Nonsteroidal antiinflammatory drugs (NSAIDs), for subacute thyroiditis, 57
- Norepinephrine  
biologic actions of, 94  
metabolism of, 95  
secretion of, 95, 97  
synthesis of, 95  
tumors secreting, 97
- Normetanephrine, 94, 95
- Nutritional-deficiency rickets, 171
- O**
- Obesity, 209–210  
central (abdominal)  
in Cushing syndrome, 76  
in diabetes mellitus, 140  
measurement of, 209  
in metabolic syndrome, 197  
evaluation of, 209  
from hypothalamic lesions, 11  
surgical treatment options for, 210  
treatment of, 209
- Occipital bone, 8
- Oculomotor nerve, 6, 7  
compressed, in pituitary apoplexy, 20  
palsy of, in diabetes mellitus, 144
- Omentum, lesser, 36
- Omoxyoid muscle, 36
- Onycholysis, in Graves disease, 43
- Oogonia, 100
- Ophthalmic nerve, 7
- Ophthalmopathy, in Graves disease, 45
- Optic chiasm  
compressed  
in clinically nonfunctioning pituitary tumor, 26  
in pituitary apoplexy, 20  
pituitary gland and, 6, 7  
pituitary tumor compressing or invading, 13
- Optic disk  
in hypocalcemia, 164  
neovascularization at, in diabetic retinopathy, 141
- Optic foramen, 8
- Optic glioma, in neurofibromatosis type 1, 217
- Optic nerve, 6
- Optic tract, right, 6
- Orlistat, for hypertriglyceridemia, 193
- Osmolality of body fluids, vasopressin and, 28
- Osmoreceptors, 28
- Osteitis deformans, 176–177
- Osteitis fibrosa cystica, 161
- Osteoblasts, 156
- Osteoclasts, 156
- Osteodystrophy  
Albright hereditary, 165, 166  
renal, 160–161
- Osteogenesis imperfecta, 178–179
- Osteomalacia  
calcipenic, 171  
clinical manifestations of, 175  
pseudovitamin D–deficiency, 172  
in renal osteodystrophy, 161  
tumor-induced, 173  
vitamin D–deficiency, 171
- Osteon, 156
- Osteoporosis  
clinical manifestations of, 168  
in men, 169  
pathogenesis of, 167  
in postmenopausal women, 168  
spinal deformity in, 169
- Ovarian hormones. *See also* Estrogen; Progesterone.  
reproductive cycle influence of, 122, 123
- Ovary, 101  
differentiation of, 100, 101  
follicular cyst of, precocious puberty from, 110  
granulosa cell tumor of, 110
- Ovotestis, 113, 114
- Ovulation  
failure of, causes of, 124  
onset of, 106
- Ovum, 100
- Oxytocin, 10, 27
- P**
- Paget disease of bone, 176–177
- Pain  
bone, in Paget disease of bone, 176  
in thyroiditis, 57
- Palatine bone, 8
- Palatine plate, 8



- Pancreas  
 abnormalities of, in von Hippel-Lindau syndrome, 216  
 anatomy and physiology of, 129  
 damage to, diabetes mellitus after, 140  
 development of, 129  
 exocrine functions of, 130  
 Pancreatic artery, 129  
 Pancreatic ducts, 129  
 Pancreatic islets  
 histology of, 129, 131  
 hyperplasia of, 151  
 insulin production in, 132  
 pathology of, in diabetes mellitus, 139  
 tumors of, in multiple endocrine neoplasia type 1, 213  
 Pancreatic juice, 130  
 Pancreatic polypeptide, 131  
 Panhypopituitarism, 15, 16, 18, 93  
 Pantothenic acid, 200  
 Papillary cystadenoma, in von Hippel-Lindau syndrome, 216  
 Papillary thyroid carcinoma, 58  
 Papilledema, from pituitary tumors, 13  
 Paraganglioma  
 catecholamine-secreting, 96–97  
 in von Hippel-Lindau syndrome, 216  
 Parathyroid gland  
 adenoma of, 157, 162  
 anatomy of, 36–37  
 in bone remodeling, 156  
 carcinoma of, 157, 162  
 development of, 39  
 hyperplasia of, primary, 157, 162  
 physiology of, 155  
 Parathyroid hormone  
 abnormalities of. *See* Hyperparathyroidism;  
 Hypoparathyroidism.  
 end-organ resistance to, 163, 165, 166  
 hypercalcemia mediated by, 159  
 secretion of, 155  
 serum, in rickets, 174  
 supplementation of, for osteoporosis, 168, 169  
 Parathyroid hormone-related peptide, in hypercalcemia, 159  
 Paraurethral glands, 102  
 Paraventricular nucleus, 9, 27  
 Paresthesia, in diabetes mellitus, 144  
 Paroöphoron, 101  
 Parotid gland, 36  
 Pars distalis (pars glandularis), 3, 4  
 Pars intermedia, 3, 4  
 Pars nervosa, 3  
 Pars tuberalis, 3, 4  
 Pellagra, 202  
 Pendred syndrome, 55  
 Pendrin, 42  
 Penis, development of, 102, 106, 107  
 Pentose shunt, 134, 135, 136  
 Peptic ulcer disease, in multiple endocrine neoplasia type 1, 213  
 Periorbital edema  
 in Graves disease, 45  
 in hypothyroidism, 49  
 Peritoneum, 68  
 Petechial hemorrhage, in scurvy, 203  
 Petrosal sinus, superior, 7  
 Phalanges, resorption of, in renal osteodystrophy, 161  
 Pharyngeal cavity, 38  
 Pharyngeal constrictor muscle, 37  
 Pharyngeal pituitary, 3  
 Pharyngeal pouches, 38, 39  
 Pharynx, development of, 38, 39  
 Phenotypic sex, 111–112  
 Pheochromocytoma, 96–97  
 in multiple endocrine neoplasia type 2, 214  
 in neurofibromatosis type 1, 217  
 in von Hippel-Lindau syndrome, 216  
*PHEX* gene, in X-linked hypophosphatemic rickets, 173  
 Phosphatidylinositol-3-kinase pathway, 133  
 Phosphate  
 absorption and excretion of, 155  
 disturbances of. *See* Hyperphosphatemia;  
 Hypophosphatemia.  
 glomerular filtration of, in renal osteodystrophy, 160  
 serum, in hypercalcemia, 159  
 supplementation of, for X-linked hypophosphatemic rickets, 173  
 Phospholipase A, 130  
 Phospholipids, dietary, 184  
 Photocoagulation, laser, for diabetic retinopathy, 142  
 Phrenic artery, 68, 69, 70  
 Phrenic nerve, 36, 70  
 Phrenic plexus, 70  
 Phrenic vein, 69, 88  
 Pigmentation disorders  
 in adrenal insufficiency, 91  
 in carcinoid tumors, 219  
 in Nelson syndrome, 25  
 Pineal gland, 6  
 Pioglitazone, for diabetes mellitus, 148  
 Pituitary apoplexy, 20  
 Pituitary gland, 3–33. *See also* Hypopituitarism.  
 acute hemorrhage of, 20  
 adenoma of, 13, 24, 25, 26, 213  
 anatomy of, 6  
 anomalies of, 14  
 anterior, 4  
 deficiency of  
 in adults, 16  
 in boys, 15  
 development of, 3  
 divisions of, 4  
 hormones and feedback control of, 9  
 blood supply of, 5  
 craniopharyngioma compressing, 12  
 development of, 3  
 divisions of, 4  
 hormones of  
 anterior, 9  
 posterior, 10  
 reproductive cycle influence of, 122, 123  
 in hypothalamic-pituitary-adrenal (HPA) axis, 72  
 infarction of, postpartum, 19  
 nerve supply of, 4, 7  
 nontumorous lesions of, 14  
 posterior, 4, 10  
 development of, 3  
 divisions of, 4  
 hormones of, 10  
 relationship of  
 to cavernous sinus, 7  
 to hypothalamus, 4, 6  
 to optic chiasm, 6  
 to pineal gland, 6  
 surgical approaches to, 33  
 tumors of  
 clinically nonfunctioning, 26  
 corticotropin-secreting, 24, 25, 78  
 growth hormone-secreting  
 acromegaly from, 22  
 gigantism from, 21  
 metastatic, 32  
 prolactin-secreting (prolactinoma), 23  
 TSH-secreting, 41  
 visual effects of, 13  
 Pituitary stalk, 4  
 nontumorous lesions of, 14  
 Plaques  
 fibrous, in atherosclerosis, 195  
 subcutaneous osseous, in pseudohypoparathyroidism type 1, 166  
 Platysma, 36  
 Plexus  
 basilar, 7  
 celiac, 70  
 of hypophyseal portal system, 5  
 phrenic, 70  
 renal, 70  
 Plummer's nails, in Graves disease, 43  
 POEMS syndrome, 218  
 Polycystic ovarian syndrome, androgen excess in, 120–121  
 Polyendocrine disorders, autoimmune, 91, 218  
 Polyglandular autoimmune syndrome,  
 hypoparathyroidism after, 163  
 Polyneuropathy, distal symmetric, in diabetes mellitus, 144  
 Polypeptide-producing cells, 131  
 Polyradiculopathy, in diabetes mellitus, 144  
 Polyuria  
 in diabetes insipidus, 29  
 from insulin deprivation, 137  
 Pons, 6  
 Pontine cistern, 6  
 Portal vein, 129  
 Potassium  
 deficiency of, in aldosteronism, 87  
 excess of, in adrenal insufficiency, 92  
 insulin secretion and, 132  
 supplementation of, for diabetic ketoacidosis, 138  
 Pregnenolone, 73, 103  
 Pregnancy  
 diabetes mellitus in, 147  
 hyperandrogenism in, virilization in, 111, 113  
 uterine bleeding abnormalities in, 124  
 Prelaryngeal thyroid tissue, 40  
*PRKARIA* gene mutations, in primary pigmented nodular adrenocortical disease, 80  
 Progesterone  
 adrenal, 73  
 at puberty, 107  
 reproductive cycle influence of, 122, 123  
 synthesis of, 103  
 Progestogens, 72  
 Prognathism, in acromegaly, 22  
 Proinsulin, 132  
 Prolactin, 9  
 deficiency of, 16, 17, 18  
 excess of, 23  
 from clinically nonfunctioning pituitary tumor, 26  
 galactorrhea in, 126  
 hypogonadotropic hypogonadism associated with, 23  
 reproductive cycle influence of, 122, 123  
 Prolactinoma, 23  
*PROPI* mutations, hypopituitarism from, 14  
 Proptosis, in Graves disease, 45, 46  
 Propylthiouracil, for toxic adenoma and toxic multinodular goiter, 47  
 Prostate gland, 101, 102  
 Prostatic utricle, 101, 102  
 Protein, metabolism of, 75, 130  
 Proteinuria, in diabetic nephropathy, 143  
 Proteolytic enzymes, 130  
 Proximal motor neuropathy, in diabetes mellitus, 144  
 Pseudofractures (Looser zones)  
 in osteomalacia, 175  
 in renal osteodystrophy, 161  
 in rickets, 174  
 Pseudogynecomastia, 125  
 Pseudohermaphroditism, 111–113  
 Pseudohypercalcemia, 159  
 Pseudohypoparathyroidism, 163  
 pathophysiology of, 165  
 type 1, 165, 166  
 type 2, 165  
 Pseudovitamin D–deficiency rickets and osteomalacia, 172  
 Psychosis, in hypothyroidism, 49  
 Psychosocial development, in disorders of sex development, 112  
 Pubarche, 84  
 Puberty  
 delayed, 17, 18  
 female, 104, 105–106, 107  
 gynecomastia in, 125  
 hormonal events in, 107, 123  
 male, 104, 106–107  
 normal, 104–107  
 precocious, 108–110

- Puberty (*Continued*)  
 diagnosis and treatment of, 110  
 gonadotropin-dependent, 108  
 gonadotropin-independent, 108–109  
 from hypothalamic lesions, 11  
 incomplete, 109  
 timing of, 104–105
- Pubic hair, development of, 84, 105, 106, 107
- Pulse, in hypothyroidism, 49
- Purging, in anorexia nervosa, 208
- Pyridoxine, 200
- Pyruvate, 134
- Q**
- QT interval, prolonged, in hypocalcemia, 164
- R**
- Rachitic bone, in rickets, 174
- Radiography  
 in osteogenesis imperfecta, 178, 179  
 in osteoporosis, 170  
 in Paget disease of bone, 176  
 in renal osteodystrophy, 161  
 in rickets, 174  
 in vertebral compression fracture, 170
- Radioiodine  
 for follicular thyroid carcinoma, 59  
 for papillary thyroid carcinoma, 58  
 for toxic adenoma and toxic multinodular goiter, 47
- Radiotherapy  
 for follicular thyroid carcinoma, 59  
 for Hürthle cell thyroid carcinoma, 61  
 for papillary thyroid carcinoma, 58
- RANK ligand, 156
- Rash, in Langerhans cell histiocytosis, 31
- Rathke pouch, 3
- Red striae, in Cushing syndrome, 76
- Renal artery, 68, 69  
 stenosis of, renovascular hypertension in, 89
- Renal cell carcinoma, in von Hippel-Lindau syndrome, 216
- Renal (Gerota) fascia, 68
- Renal ganglion and plexus, 70
- Renal osteodystrophy, 160–161
- Renal stones, in hyperparathyroidism, 157
- Renal vein, 68, 69
- Renin-angiotensin-aldosterone system, 86, 89
- Renovascular hypertension, in renal artery stenosis, 89
- Reproductive cycle, gonadal hormonal influences on, 122, 123
- Resiliency testing, in Graves disease, 45
- RET* mutations, 60, 213, 215
- Rete ovarii, 100
- Rete testis, 100
- Retina  
 angioma of, in von Hippel-Lindau syndrome, 216  
 detachment of, in diabetic retinopathy, 142  
 lesions of, in abetalipoproteinemia, 190
- Retinohypothalamic tract, 9
- Retinopathy, diabetic, 141  
 macular edema in, 141  
 nonproliferative, 141  
 proliferative, 141, 142
- Retroperitoneoscopic adrenalectomy, 69
- Rhinorrhea, cerebrospinal fluid, in prolactinoma, 23
- Rib  
 first, 37  
 fracture of, in osteoporosis, 168
- Riboflavin, 200
- Rickets  
 calcipenic, 171  
 clinical manifestations of, 174  
 hereditary vitamin D-resistant, 172  
 hypophosphatemic, 173  
 nutritional-deficiency, 171  
 pseudovitamin D-deficiency, 172  
 from renal  $\alpha$ 1-hydroxylase deficiency, 172  
 vitamin D-deficiency, 171
- Riedel thyroiditis, 56
- Rosiglitazone, for diabetes mellitus, 148
- Round ligament, 101
- Roux-en-Y gastric bypass surgery, 151, 210
- Rubor, dependent, in diabetic foot ulcers, 146
- Rumpel-Leede test, in scurvy, 203
- S**
- Sagittal sinus, superior, 7
- Saline, for diabetic ketoacidosis, 138
- Salt wasting, 81, 83
- Santorini, duct of, 129
- Sarcoidosis, hypercalcemia in, 159
- Satiety center, 11
- Scalene muscle, 36
- Scintigraphy, bone, in Paget disease of bone, 176
- Sclerae, blue, in osteogenesis imperfecta, 178, 179
- Sclerosis, in renal osteodystrophy, 161
- Scorbutic rosary, 203
- Scotoma, from pituitary tumors, 13
- Scrotum, development of, 102, 106, 107
- Scurvy, 203
- Secretin, 130
- Sella, empty, 14
- Sella turcica, 8, 14
- Seminal vesicle, 101
- Seminiferous tubules, 100
- Sertoli cell, 107
- Sertoli-Leydig cell tumors, virilization in, 121
- Sex  
 chromosomal, 100, 111  
 analysis of, 115  
 errors in. *See* Sex chromosome disorder of sex development.  
 gonadal, 111  
 phenotypic, 111–112
- Sex characteristics  
 male, adrenal androgen effects on, 84  
 secondary  
 absence of, in Turner syndrome, 117  
 development of, 104, 105, 106
- Sex chromosome disorder of sex development, 112–113, 115  
 45,X, 117  
 45,X/46,XX, 118  
 45,X/46,XY (mixed gonadal dysgenesis), 113, 118, 119  
 46,XX/46,XY (chimerism), 113  
 47,XXX (triple X syndrome), 115  
 47,XXY, 116  
 Klinefelter syndrome as, 115, 116  
 Turner syndrome as, 115, 117–119
- Sex cords  
 primary, 100  
 secondary, 100
- Sex hormone-binding globulin, in Graves disease, 44
- Sexual differentiation  
 female, 112  
 male, 111–112  
 variations in, 113, 114
- Sexual orientation, 112
- Sheehan syndrome, 19
- Shock, in adrenal crisis, 90
- Short stature, 15  
 in pseudohypoparathyroidism type 1, 166  
 in Turner syndrome, 117
- Sitosterolemia, 189
- Skeleton deformities, in rickets, 174
- Skene's duct, 101
- Skin  
 in adrenal crisis, 90  
 in Carney complex, 80  
 in Cushing syndrome, 76  
 glucocorticoid effects on, 75  
 in Graves disease, 43  
 hyperkeratinization of, in vitamin A deficiency, 204  
 hyperpigmentation of  
 in adrenal insufficiency, 91  
 in carcinoid tumors, 219  
 in Nelson syndrome, 25
- Skin (Continued)*  
 in hypothyroidism, 49, 50  
 in Langerhans cell histiocytosis, 31  
 in multiple endocrine neoplasia type 1, 213  
 in neurofibromatosis type 1, 217
- Skull lesions, in Langerhans cell histiocytosis, 30
- Small intestine, carcinoids of, 219
- Smoking, coronary heart disease risk and, 196
- Sodium  
 abnormalities of, in adrenal insufficiency, 92, 93  
 aldosterone effects on, 86
- Sodium-iodide symporter (NIS), block of, 55
- Soft tissue overgrowth, in acromegaly, 22
- Somatostatin, 131, 132
- Somnolence, from hypothalamic lesions, 11
- SOX9* gene, in gonadal differentiation, 100
- Spermatogenesis, 107
- Spermatogonia, 100
- Sphenoid bone, 8
- Sphenoid sinus, 3, 6, 7, 8
- Sphenoparietal sinus, 7
- Sphincter of Oddi, 129
- Sphingolipidoses, 206–207
- Sphingomyelin-cholesterol lipidosis, 206
- Spinal deformity, in osteoporosis, 169
- Splanchnic nerve, 70
- Spleen  
 enlargement of, in hypertriglyceridemia, 192  
 topographic relationships of, 68, 129
- Splenic artery, 129
- Splenic vein, 129
- Sprue  
 celiac, 205  
 nontropical, 205
- SRP* gene, in gonadal differentiation, 100, 101
- Stare, in Graves disease, 44, 45
- Statins  
 coronary heart disease risk and, 196  
 in diabetes mellitus, 145  
 for familial hypercholesterolemia, 189  
 for hyperlipidemia, 199  
 for hypertriglyceridemia, 193  
 mechanisms of action of, 198
- Stature  
 short, 15  
 in pseudohypoparathyroidism type 1, 166  
 in Turner syndrome, 117  
 tall, 21
- Steatorrhea, in celiac disease, 205
- Sternocleidomastoid muscle, 36
- Sternohyoid muscle, 36
- Sternothyroid muscle, 36
- Steroid withdrawal bleeding, 124
- Steroidogenesis  
 adrenal, major blocks in, 81  
 regulation of, 103
- Steroidogenic acute regulatory protein (StART), 73  
 deficiency of, 81, 82
- Steroidogenic enzymes, adrenal, 74
- Steroids. *See also* Glucocorticoids.  
 adrenal, biosynthesis and metabolism of, 72–74  
 androgenic (anabolic), 84
- Sterol regulatory element-binding protein (SREBP), 185
- Stomach, 129
- Stress, corticotropin secretion and, 72
- Stridor, in hypocalcemia, 164
- Subarachnoid cistern, 6
- Subclavian artery, 37
- Subclavian vein, 37
- Sublingual thyroid tissue, 40
- Submandibular gland, 36
- Substernal thyroid tissue, 40
- Sulfatidosis, 207
- Sulfonylurea receptor agonists, for diabetes mellitus, 148
- Supraclavicular nerve, 36
- Supraoptic nucleus, 9
- Supraopticohypophysial tract, 4
- Suprarenal glands. *See* Adrenal glands.
- Suprasellar disease, 11



- Swyer syndrome, 114  
 Sympathetic trunk, 36, 70
- T**
- Tall stature, 21  
 Tamoxifen, for Riedel thyroiditis, 56  
 Tangier disease, 190  
 Tanner stages  
   of breast development, 104  
   of female pubic hair development, 105  
   of male pubic hair and genital development, 106  
 Tay-Sachs disease, 206  
 Temporal pole of brain, 6  
 Tendons, xanthoma of, 188, 189  
 Testis, 101  
   adrenal rest tumor of, precocious puberty from, 109  
   appendix, 101  
   descent of, 112  
   development of  
     disorders of, 113  
     during puberty, 106–107  
   differentiation of, 100, 101  
   dysgenesis of, 112, 114  
 Testosterone  
   adrenal, 72, 73, 103, 104  
     biologic actions of, 84  
     excess of, 85  
     neoplasms secreting, 85, 121  
     in secondary adrenal insufficiency, 93  
   deficiency of, 15, 114  
   excess of  
     in 46,XX disorders of sex development, 112, 113–114  
     adult adrenogenital syndromes associated with, 85  
     in hirsutism and virilization, 120–121  
     in masculinization of external genitalia, 102, 111  
     in precocious puberty, 109, 110  
     virilization in, 111, 113  
     in women, 120, 121  
   gonadal, 104  
   for Klinefelter syndrome, 116  
   potency of, 73  
   at puberty, 107  
   synthesis of, 103  
 Tetany, 164  
 Tetracycline, bone biopsy with, in osteomalacia, 175  
 Thalamus, 6  
 Theca cells, 100  
 Thelarche, 104, 105  
   premature, 109  
   pubertal, 104, 105  
 Thiamine  
   absorption of, 200  
   deficiency of, 201  
   recommended dietary allowance for, 201  
 Thiazolidinediones, for diabetes mellitus, 148  
 Thionamides, for toxic adenoma and toxic multinodular goiter, 47  
 Thirst, 28  
   for cold liquids, in diabetes insipidus, 29  
 Thoracic kyphosis, in osteoporosis, 168, 169, 170  
 Thoracic splanchnic nerve, 70  
 Thrombosis, in atherosclerosis, 195  
 Thymus gland, 38  
   development of, 39  
   tumors of, 218  
 Thyrocervical trunk, 37  
 Thyroglobulin  
   antibodies to, in Hashimoto thyroiditis, 56  
   inhibition of, 55  
   in subacute thyroiditis, 57  
 Thyroglossal cyst, 40  
 Thyroglossal duct, 38, 40  
 Thyrohyoid membrane, 37  
 Thyrohyoid muscle, 36  
 Thyroid artery, 36, 37  
 Thyroid-binding globulin (TBG), 42  
 Thyroid cartilage, 36, 37  
 Thyroid follicles, 38  
 Thyroid gland, 35–63  
   anatomy of, 36–37  
   anomalies of, 37, 40  
   carcinoma of  
     anaplastic, 62  
     follicular, 59  
     Hürthle cell, 61  
     medullary, 60, 214, 215  
     in multiple endocrine neoplasia type 2, 60, 214, 215  
     papillary, 58  
   development of, 38–39  
   dysgenesis of, 52  
   enlargement of. *See* Goiter.  
   hyperplasia of, goiter after, 55  
   metastatic disease to, 63  
   pathology of, in Graves disease, 46  
   pyramidal lobe of, 39  
   thyrotropin effects on, 41  
 Thyroid hormones  
   in anorexia nervosa, 208  
   deficiency of, 16, 55  
   disturbances of. *See* Hyperthyroidism; Hypothyroidism.  
   physiology of, 42  
   reduced sensitivity to, 55  
 Thyroid isthmus, 38  
 Thyroid peroxidase  
   antibodies to, in Hashimoto thyroiditis, 56  
   inhibition of, 42, 55  
 Thyroid-stimulating hormone (TSH). *See* Thyrotropin.  
 Thyroid tissue, aberrant, 40  
 Thyroid vein, 37  
 Thyroidectomy  
   for follicular thyroid carcinoma, 59  
   for Hürthle cell thyroid carcinoma, 61  
   hypoparathyroidism after, 163  
   for medullary thyroid carcinoma, 60  
   for papillary thyroid carcinoma, 58  
 Thyroiditis  
   acute nonsuppurative, 57  
   chronic lymphocytic (Hashimoto), 51, 56  
   fibrous (Riedel), 56  
   subacute (de Quervain), 57  
 Thyrotropin, 9  
   deficiency of, 15, 17, 18, 51  
   effects of, on thyroid gland, 41  
   in hypothyroidism, 50  
   pituitary tumor secreting, 41  
   in subacute thyroiditis, 57  
 Thyrotropin receptor, 41  
   mutations of, goiter from, 47, 55  
 Thyrotropin-releasing hormone (TRH), 9, 41  
 Thyroxine, 41  
   in hypothyroidism, 50  
   physiology of, 42  
   in subacute thyroiditis, 57  
 Tongue, 38  
   in hypothyroidism, 49, 50  
   in pellagra, 202  
 Tonsil  
   in pellagra, 202  
   in Tangier disease, 190  
 Tooth (teeth)  
   in autoimmune polyglandular syndrome type I, 218  
   loss of, in hypophosphatasia, 180  
   malocclusion of, in acromegaly, 22  
   opalescent, in osteogenesis imperfecta, 178, 179  
 Toxic adenoma, 47, 48  
 Toxic multinodular goiter, 47, 48  
 Trabecula, artery of, 5  
 Trachea, 36, 38  
   compression of, by anaplastic thyroid carcinoma, 62  
 Transabdominal adrenalectomy, 69  
 Transnasal approach to pituitary, 33  
 Transseptal approach to pituitary, 33  
 Transsphenoidal approach to pituitary, 24, 33  
 Tremor, in Graves disease, 43  
 Tricarboxylic acid cycle, 135  
 Trigeminal nerve, 6, 7  
 Triglycerides. *See also* Hypertriglyceridemia.  
   dietary, 184  
   gastrointestinal absorption of, 184  
   metabolism of, 191  
   serum, 191  
 Triiodothyronine, 41  
   in hypothyroidism, 50  
   physiology of, 42  
   in subacute thyroiditis, 57  
 Triple X syndrome, 115  
 Trochlear nerve, 6, 7  
 Trousseau sign, 164  
 TSH (thyroid-stimulating hormone). *See* Thyrotropin.  
 Tube, fallopian, 101  
 Tuber cinereum, 6  
 Tuberculosis, of adrenal glands, 91  
 Tuberculum sellae, 8  
 Tuberohypophysial tract, 4  
 Tuberos xanthoma, 188, 189  
 Tumors. *See also* Carcinoma.  
   adrenal rest, testicular, 109  
   adrenocortical, 85, 109, 121  
   of brain  
     diabetes insipidus and, 29  
     in neurofibromatosis type 1, 217  
     precocious puberty and, 108, 110  
   carcinoid, 213, 219  
   catecholamine-secreting, 96–97  
   granulosa cell, of ovary, 110  
   Leydig cell, 109  
   metastatic. *See* Metastatic disease.  
   osteomalacia associated with, 173  
   pituitary. *See* Pituitary gland, tumors of.  
   Sertoli-Leydig cell, virilization in, 121  
   of thymus gland, 218  
 Tunica albuginea, 100  
 Tunica vaginalis, 100  
 Turner syndrome, 115, 117–119  
   45,X, 117  
   45,X/46,XX mosaicism, 117, 118  
 Tyrosine, 95
- U**
- Ulcer  
   neuropathic, in diabetes mellitus, 144, 146  
   peptic, in multiple endocrine neoplasia type 1, 213  
 Ultradian rhythms, 9  
 Uncinate process, 129  
 Upper body to lower body segment ratio (U:L ratio), 105  
 Urethra, 101  
 Urethral folds, 102  
 Urethral groove, 102  
 Urogenital sinus, 102  
 Urogenital slit, 102  
 Uterus  
   bleeding from, causes of, 124  
   contraction of, oxytocin in, 27  
   development of, 101  
 Utricle, prostatic, 101, 102
- V**
- Vagal trunk, 70  
 Vagina, 101  
   development of, 102, 106  
   remnant of, 102  
 Vagus nerve, 36, 37  
 Valvular heart disease, in carcinoid tumors, 219  
 Vanillylmandelic acid, 94, 95  
 Vas deferens, 100, 101  
 Vasa efferentia, 101  
 Vascular insufficiency, in diabetes mellitus, 146  
 Vasopressin  
   deficiency of  
     in diabetes insipidus, 29  
     in Langerhans cell histiocytosis, 30

- Vasopressin (*Continued*)  
 overview of, 10  
 secretion and action of, 28
- Veins. *See* Blood supply; *named veins*.
- Vena cava  
 inferior, 68, 69, 88, 129  
 superior, 37
- Ventricle, third, 7
- Vertebral body, 36
- Vertebral compression fracture, in osteoporosis, 168, 169, 170
- Vesiculosa, appendix, 101
- VHL* tumor suppressor gene, in von Hippel-Lindau syndrome, 216
- Vibration sense, loss of, in diabetes mellitus, 144
- Virchow nodes, 37
- Virilization, 85, 120–121  
 causes of, 112, 113–114, 120–121  
 definition of, 85, 120  
 simple, 83  
 in Turner syndrome, 118  
 under-, of male infants, 113, 114
- Visual apparatus, pituitary tumor effects on, 13
- Visual loss  
 from craniopharyngioma, 12  
 in diabetic retinopathy, 141  
 from hypothalamic lesions, 11  
 from pituitary tumors, 13
- Vitamin(s)  
 absorption of, 200  
 fat-soluble, 200  
 water-soluble, 200
- Vitamin A  
 absorption of, 200  
 deficiency of, 204  
 recommended dietary allowance for, 204
- Vitamin B, in tricarboxylic acid cycle, 135
- Vitamin B<sub>1</sub> (thiamine)  
 absorption of, 200  
 deficiency of, 201  
 recommended dietary allowance for, 201
- Vitamin B<sub>2</sub> (riboflavin), 200
- Vitamin B<sub>3</sub> (niacin)  
 absorption of, 200  
 deficiency of, 202  
 recommended dietary allowance for, 202
- Vitamin B<sub>5</sub> (pantothenic acid), 200
- Vitamin B<sub>6</sub> (pyridoxine), 200
- Vitamin B<sub>12</sub> (cobalamin), 200
- Vitamin C (ascorbic acid)  
 absorption of, 200  
 deficiency of, 203  
 recommended dietary allowance for, 203
- Vitamin D  
 absorption of, 200  
 deficiency of, in hyperparathyroidism, 158  
 intake of, in osteoporosis, 168  
 intoxication with, hypercalcemia in, 159  
 serum, in hypercalcemia, 159
- Vitamin D receptor gene, mutations of, 172
- Vitamin D–deficiency rickets and osteomalacia, 171
- Vitamin E, 200
- Vitamin K, 200
- Vitiligo, in autoimmune polyglandular syndrome type I, 218
- Vitreous hemorrhage, in diabetic retinopathy, 142
- Voice changes  
 adrenal androgens and, 84  
 in hypothyroidism, 49  
 during puberty, 107
- Volume repletion  
 for adrenal crisis, 90  
 for diabetic ketoacidosis, 138
- Von Hippel-Lindau syndrome, 216
- Von Recklinghausen disease, 217
- W**
- Waist circumference. *See* Abdominal obesity.
- Water homeostasis, vasopressin and, 28
- Waterhouse-Friderichsen syndrome, 90
- Weight gain. *See* Obesity.
- Weight loss  
 in anorexia nervosa, 208  
 in Graves disease, 44  
 from insulin deprivation, 137  
 for obesity, 209–210
- Wernicke-Korsakoff syndrome, 201
- Whipple procedure, for insulinoma, 150
- Whipple triad, in insulinoma, 150
- Wirsung, duct of, 129
- Wolffian body, 101
- Wolffian duct, 100, 101
- Wolfram syndrome, 29, 218
- Wound healing, in Cushing syndrome, 76
- Wrist drop, in diabetes mellitus, 144
- X**
- X-linked hypophosphatemic rickets, 173
- Xanthoma  
 hypercholesterolemic, 188–189  
 in hypertriglyceridemia, 192, 193
- Xanthomatosis, cerebrotendinous, 189
- Z**
- Zollinger-Ellison syndrome, in multiple endocrine neoplasia type 1, 213
- Zona fasciculata, 71
- Zona glomerulosa, 71
- Zona reticularis, 71
- Zuckerkind organ, 67